

# World Journal of *Hepatology*

*World J Hepatol* 2016 March 18; 8(8): 385-420





## Editorial Board

2014-2017

The *World Journal of Hepatology* Editorial Board consists of 469 members, representing a team of worldwide experts in hepatology. They are from 53 countries, including Algeria (1), Argentina (6), Armenia (1), Australia (1), Austria (4), Bangladesh (2), Belgium (3), Botswana (2), Brazil (13), Bulgaria (2), Canada (3), Chile (1), China (98), Czech Republic (1), Denmark (2), Egypt (12), France (6), Germany (19), Greece (11), Hungary (5), India (15), Indonesia (2), Iran (4), Israel (1), Italy (52), Japan (35), Jordan (1), Malaysia (2), Mexico (3), Moldova (1), Netherlands (3), Nigeria (1), Pakistan (1), Philippines (2), Poland (1), Portugal (2), Qatar (1), Romania (6), Russia (2), Saudi Arabia (4), Singapore (1), South Korea (11), Spain (20), Sri Lanka (1), Sudan (1), Sweden (1), Switzerland (1), Thailand (4), Turkey (21), Ukraine (3), United Kingdom (17), and United States (56).

### EDITORS-IN-CHIEF

Clara Balsano, *Rome*  
Wan-Long Chuang, *Kaohsiung*

### GUEST EDITORIAL BOARD MEMBERS

King-Wah Chiu, *Kaohsiung*  
Tai-An Chiang, *Tainan*  
Chi-Tan Hu, *Hualien*  
Sen-Yung Hsieh, *Taoyuan*  
Wenya Huang, *Tainan*  
Liang-Yi Hung, *Tainan*  
Jih RU Hwu, *Hsinchu*  
Jing-Yi Lee, *Taipei*  
Mei-Hsuan Lee, *Taipei*  
Chih-Wen Lin, *Kaohsiung*  
Chun-Che Lin, *Taichung*  
Wan-Yu Lin, *Taichung*  
Tai-Long Pan, *Tao-Yuan*  
Suh-Ching Yang, *Taipei*  
Chun-Yan Yeung, *Taipei*

### MEMBERS OF THE EDITORIAL BOARD



**Algeria**

Samir Rouabhia, *Batna*



**Argentina**

Fernando O Bessone, *Rosario*  
Maria C Carrillo, *Rosario*  
Melisa M Dirchwolf, *Buenos Aires*  
Bernardo Frider, *Buenos Aires*

Jorge Quarleri, *Buenos Aires*  
Adriana M Torres, *Rosario*



**Armenia**

Narina Sargsyants, *Yerevan*



**Australia**

Mark D Gorrell, *Sydney*



**Austria**

Harald Hofer, *Vienna*  
Gustav Paumgartner, *Vienna*  
Matthias Pinter, *Vienna*  
Thomas Reiberger, *Vienna*



**Bangladesh**

Shahinul Alam, *Dhaka*  
Mamun Al Mahtab, *Dhaka*



**Belgium**

Nicolas Lanthier, *Brussels*  
Philip Meuleman, *Ghent*  
Luisa Vonghia, *Antwerp*



**Botswana**

Francesca Cainelli, *Gaborone*

Sandro Vento, *Gaborone*



**Brazil**

Edson Abdala, *Sao Paulo*  
Ilka FSF Boin, *Campinas*  
Niels OS Camara, *Sao Paulo*  
Ana Carolina FN Cardoso, *Rio de Janeiro*  
Roberto J Carvalho-Filho, *Sao Paulo*  
Julio CU Coelho, *Curitiba*  
Flavio Henrique Ferreira Galvao, *São Paulo*  
Janaina L Narciso-Schiavon, *Florianopolis*  
Sílvia HC Sales-Peres, *Bauru*  
Leonardo L Schiavon, *Florianópolis*  
Luciana D Silva, *Belo Horizonte*  
Vanessa Souza-Mello, *Rio de Janeiro*  
Jaques Waisberg, *Santo André*



**Bulgaria**

Mariana P Penkova-Radicheva, *Stara Zagora*  
Marieta Simonova, *Sofia*



**Canada**

Runjan Chetty, *Toronto*  
Michele Molinari, *Halifax*  
Giada Sebastiani, *Montreal*



**Chile**

Luis A Videla, *Santiago*



## China

Guang-Wen Cao, Shanghai  
 En-Qiang Chen, Chengdu  
 Gong-Ying Chen, Hangzhou  
 Jin-lian Chen, Shanghai  
 Jun Chen, Changsha  
 Alfred Cheng, Hong Kong  
 Chun-Ping Cui, Beijing  
 Shuang-Suo Dang, Xi'an  
 Ming-Xing Ding, Jinhua  
 Zhi-Jun Duang, Dalian  
 He-Bin Fan, Wuhan  
 Xiao-Ming Fan, Shanghai  
 James Yan Yue Fung, Hong Kong  
 Yi Gao, Guangzhou  
 Zuo-Jiong Gong, Wuhan  
 Zhi-Yong Guo, Guangzhou  
 Shao-Liang Han, Wenzhou  
 Tao Han, Tianjin  
 Jin-Yang He, Guangzhou  
 Ming-Liang He, Hong Kong  
 Can-Hua Huang, Chengdu  
 Bo Jin, Beijing  
 Shan Jin, Hohhot  
 Hui-Qing Jiang, Shijiazhuang  
 Wan-Yee Joseph Lau, Hong Kong  
 Guo-Lin Li, Changsha  
 Jin-Jun Li, Shanghai  
 Qiang Li, Jinan  
 Sheng Li, Jinan  
 Zong-Fang Li, Xi'an  
 Xu Li, Guangzhou  
 Xue-Song Liang, Shanghai  
 En-Qi Liu, Xi'an  
 Pei Liu, Shenyang  
 Zhong-Hui Liu, Changchun  
 Guang-Hua Luo, Changzhou  
 Yi Lv, Xi'an  
 Guang-Dong Pan, Liuzhou  
 Wen-Sheng Pan, Hangzhou  
 Jian-Min Qin, Shanghai  
 Wai-Kay Seto, Hong Kong  
 Hong Shen, Changsha  
 Xiao Su, Shanghai  
 Li-Ping Sun, Beijing  
 Wei-Hao Sun, Nanjing  
 Xue-Ying Sun, Harbin  
 Hua Tang, Tianjin  
 Ling Tian, Shanghai  
 Eric Tse, Hong Kong  
 Guo-Ying Wang, Changzhou  
 Yue Wang, Beijing  
 Shu-Qiang Wang, Chengdu  
 Mary MY Wayne, Hong Kong  
 Hong-Shan Wei, Beijing  
 Danny Ka-Ho Wong, Hong Kong  
 Grace Lai-Hung Wong, Hong Kong  
 Bang-Fu Wu, Dongguan  
 Feng Wu, Chongqing  
 Xiong-Zhi Wu, Tianjin  
 Chun-Fang Xu, Suzhou  
 Rui-An Xu, Quanzhou  
 Rui-Yun Xu, Guangzhou  
 Wei-Li Xu, Shijiazhuang  
 Shi-Ying Xuan, Qingdao  
 Ming-Xian Yan, Jinan  
 Lv-Nan Yan, Chengdu  
 Jin Yang, Hangzhou  
 Ji-Hong Yao, Dalian  
 Winnie Yeo, Hong Kong

Zheng Zeng, Beijing  
 Qi Zhang, Hangzhou  
 Shi-Jun Zhang, Guangzhou  
 Xiao-Lan Zhang, Shijiazhuang  
 Xiao-Yong Zhang, Guangzhou  
 Xin-Chen Zhang, Harbin  
 Yong Zhang, Xi'an  
 Hong-Chuan Zhao, Hefei  
 Ming-Hua Zheng, Wenzhou  
 Yu-Bao Zheng, Guangzhou  
 Ren-Qian Zhong, Shanghai  
 Fan Zhu, Wuhan  
 Xiao Zhu, Dongguan



## Czech Republic

Kamil Vysloulzil, Olomouc



## Denmark

Henning Gronbaek, Aarhus  
 Christian Mortensen, Hvidovre



## Egypt

Ihab T Abdel-Raheem, Damanhour  
 NGB G Bader EL Din, Cairo  
 Hatem Elalfy, Mansoura  
 Mahmoud M El-Bendary, Mansoura  
 Mona El SH El-Raziky, Cairo  
 Mohammad El-Sayed, Cairo  
 Yasser M Fouad, Minia  
 Mohamed AA Metwally, Benha  
 Hany Shehab, Cairo  
 Mostafa M Sira, Shebin El-koom  
 Ashraf Taye, Minia  
 MA Ali Wahab, Mansoura



## France

Laurent Alric, Toulouse  
 Sophie Conchon, Nantes  
 Daniel J Felmlee, Strasbourg  
 Herve Lerat, Creteil  
 Dominique Salmon, Paris  
 Jean-Pierre Vartanian, Paris



## Germany

Laura E Buitrago-Molina, Hannover  
 Enrico N De Toni, Munich  
 Oliver Ebert, Muenchen  
 Rolf Gebhardt, Leipzig  
 Janine V Hartl, Regensburg  
 Sebastian Hinz, Kiel  
 Benjamin Juntermanns, Essen  
 Roland Kaufmann, Jena  
 Viola Knop, Frankfurt  
 Veronika Lukacs-Kornek, Homburg  
 Benjamin Maasoumy, Hannover  
 Jochen Mattner, Erlangen  
 Nadja M Meindl-Beinker, Mannheim  
 Ulf P Neumann, Aachen  
 Margarete Odenthal, Cologne  
 Yoshiaki Sunami, Munich

Christoph Roderburg, Aachen  
 Frank Tacke, Aachen  
 Yuchen Xia, Munich



## Greece

Alex P Betrosian, Athens  
 George N Dalekos, Larissa  
 Ioanna K Delladetsima, Athens  
 Nikolaos K Gatselis, Larissa  
 Stavros Gourgiotis, Athens  
 Christos G Savopoulos, Thessaloniki  
 Tania Siahaniidou, Athens  
 Emmanouil Sinakos, Thessaloniki  
 Nikolaos G Symeonidi, Thessaloniki  
 Konstantinos C Thomopoulos, Larissa  
 Konstantinos Tziomalos, Thessaloniki



## Hungary

Gabor Banhegyi, Budapest  
 Peter L Lakatos, Budapest  
 Maria Papp, Debrecen  
 Ferenc Sipos, Budapest  
 Zsolt J Tulassay, Budapest



## India

Deepak N Amarapurkar, Mumbai  
 Girish M Bhopale, Pune  
 Sibnarayan Datta, Tezpur  
 Nutan D Desai, Mumbai  
 Sorabh Kapoor, Mumbai  
 Jaswinder S Maras, New Delhi  
 Nabeen C Nayak, New Delhi  
 C Ganesh Pai, Manipal  
 Amit Pal, Chandigarh  
 K Rajeshwari, New Delhi  
 Anup Ramachandran, Vellore  
 D Nageshwar Reddy, Hyderabad  
 Shivaram P Singh, Cuttack  
 Ajith TA, Thrissur  
 Balasubramaniyan Vairappan, Pondicherry



## Indonesia

Cosmas RA Lesmana, Jakarta  
 Neneng Ratnasari, Yogyakarta



## Iran

Seyed M Jazayeri, Tehran  
 Sedigheh Kafi-Abad, Tehran  
 Iradj Maleki, Sari  
 Fakhraddin Naghibalhossaini, Shiraz



## Israel

Stephen DH Malnick, Rehovot



## Italy

Francesco Angelico, Rome



Alfonso W Avolio, *Rome*  
 Francesco Bellanti, *Foggia*  
 Marcello Bianchini, *Modena*  
 Guglielmo Borgia, *Naples*  
 Mauro Borzio, *Milano*  
 Enrico Brunetti, *Pavia*  
 Valeria Cento, *Roma*  
 Beatrice Conti, *Rome*  
 Francesco D'Amico, *Padova*  
 Samuele De Minicis, *Fermo*  
 Fabrizio De Ponti, *Bologna*  
 Giovan Giuseppe Di Costanzo, *Napoli*  
 Luca Fabris, *Padova*  
 Giovanna Ferraioli, *Pavia*  
 Andrea Galli, *Florence*  
 Matteo Garcovich, *Rome*  
 Edoardo G Giannini, *Genova*  
 Rossano Girometti, *Udine*  
 Alessandro Granito, *Bologna*  
 Alberto Grassi, *Rimini*  
 Alessandro Grasso, *Savona*  
 Salvatore Gruttadauria, *Palermo*  
 Francesca Guerrieri, *Rome*  
 Quirino Lai, *Aquila*  
 Andrea Lisotti, *Bologna*  
 Marcello F Maida, *Palermo*  
 Lucia Malaguarnera, *Catania*  
 Andrea Mancuso, *Palermo*  
 Luca Maroni, *Ancona*  
 Francesco Marotta, *Milano*  
 Pierluigi Marzuillo, *Naples*  
 Sara Montagnese, *Padova*  
 Giuseppe Nigri, *Rome*  
 Claudia Piccoli, *Foggia*  
 Camillo Porta, *Pavia*  
 Chiara Raggi, *Rozzano (MI)*  
 Maria Rendina, *Bari*  
 Maria Ripoli, *San Giovanni Rotondo*  
 Kryssia I Rodriguez-Castro, *Padua*  
 Raffaella Romeo, *Milan*  
 Amedeo Sciarra, *Milano*  
 Antonio Solinas, *Sassari*  
 Aurelio Sonzogni, *Bergamo*  
 Giovanni Squadrito, *Messina*  
 Salvatore Sutti, *Novara*  
 Valentina Svicher, *Rome*  
 Luca Toti, *Rome*  
 Elvira Verduci, *Milan*  
 Umberto Vespasiani-Gentilucci, *Rome*  
 Maria A Zocco, *Rome*



**Japan**

Yasuhiro Asahina, *Tokyo*  
 Nabil AS Eid, *Takatsuki*  
 Kenichi Ikejima, *Tokyo*  
 Shoji Ikuo, *Kobe*  
 Yoshihiro Ikura, *Takatsuki*  
 Shinichi Ikuta, *Nishinomiya*  
 Kazuaki Inoue, *Yokohama*  
 Toshiya Kamiyama, *Sapporo*  
 Takanobu Kato, *Tokyo*  
 Saiho Ko, *Nara*  
 Haruki Komatsu, *Sakura*  
 Masanori Matsuda, *Chuo-city*  
 Yasunobu Matsuda, *Niigata*  
 Yoshifumi Nakayama, *Kitakyushu*  
 Taichiro Nishikawa, *Kyoto*

Satoshi Oeda, *Saga*  
 Kenji Okumura, *Urayasu*  
 Michitaka Ozaki, *Sapporo*  
 Takahiro Sato, *Sapporo*  
 Junichi Shindoh, *Tokyo*  
 Ryo Sudo, *Yokohama*  
 Atsushi Suetsugu, *Gifu*  
 Haruhiko Sugimura, *Hamamatsu*  
 Reiji Sugita, *Sendai*  
 Koichi Takaguchi, *Takamatsu*  
 Shinji Takai, *Takatsuki*  
 Akinobu Takaki, *Okayama*  
 Yasuhito Tanaka, *Nagoya*  
 Takuji Tanaka, *Gifu City*  
 Atsunori Tsuchiya, *Niigata*  
 Koichi Watashi, *Tokyo*  
 Hiroshi Yagi, *Tokyo*  
 Taro Yamashita, *Kanazawa*  
 Shuhei Yoshida, *Chiba*  
 Hitoshi Yoshiji, *Kashiwara*



**Jordan**

Kamal E Bani-Hani, *Zarqa*



**Malaysia**

Peng Soon Koh, *Kuala Lumpur*  
 Yeong Yeh Lee, *Kota Bahru*



**Mexico**

Francisco J Bosques-Padilla, *Monterrey*  
 María de F Higuera-de la Tijera, *Mexico City*  
 José A Morales-Gonzalez, *México City*



**Moldova**

Angela Peltec, *Chishinev*



**Netherlands**

Wybrich R Cnossen, *Nijmegen*  
 Frank G Schaap, *Maastricht*  
 Fareeba Sheedfar, *Groningen*



**Nigeria**

CA Asabamaka Onyekwere, *Lagos*



**Pakistan**

Bikha Ram Devrajani, *Jamshoro*



**Philippines**

Janus P Ong, *Pasig*  
 JD Decena Sollano, *Manila*



**Poland**

Jacek Zielinski, *Gdansk*



**Portugal**

Rui T Marinho, *Lisboa*  
 Joao B Soares, *Braga*



**Qatar**

Reem Al Olaby, *Doha*



**Romania**

Bogdan Dorobantu, *Bucharest*  
 Liana Gheorghe, *Bucharest*  
 George S Gherlan, *Bucharest*  
 Romeo G Mihaila, *Sibiu*  
 Bogdan Procopet, *Cluj-Napoca*  
 Streba T Streba, *Craiova*



**Russia**

Anisa Gumerova, *Kazan*  
 Pavel G Tarazov, *St.Petersburg*



**Saudi Arabia**

Abdulrahman A Aljumah, *Riyadh*  
 Ihab MH Mahmoud, *Riyadh*  
 Ibrahim Masoodi, *Riyadh*  
 Mhoammad K Parvez, *Riyadh*



**Singapore**

Ser Yee Lee, *Singapore*



**South Korea**

Young-Hwa Chung, *Seoul*  
 Dae-Won Jun, *Seoul*  
 Bum-Joon Kim, *Seoul*  
 Do Young Kim, *Seoul*  
 Ji Won Kim, *Seoul*  
 Moon Young Kim, *Wonju*  
 Mi-Kyung Lee, *Suncheon*  
 Kwan-Kyu Park, *Daegu*  
 Young Nyun Park, *Seoul*  
 Jae-Hong Ryoo, *Seoul*  
 Jong Won Yun, *Kyungsan*



**Spain**

Ivan G Marina, *Madrid*  
 Juan G Acevedo, *Barcelona*  
 Javier Ampuero, *Sevilla*  
 Jaime Arias, *Madrid*  
 Andres Cardenas, *Barcelona*  
 Agustin Castiella, *Mendaro*  
 Israel Fernandez-Pineda, *Sevilla*  
 Rocio Gallego-Duran, *Sevilla*  
 Rita Garcia-Martinez, *Barcelona*

José M González-Navajas, *Alicante*  
 Juan C Laguna, *Barcelona*  
 Elba Llop, *Madrid*  
 Laura Ochoa-Callejero, *La Rioja*  
 Albert Pares, *Barcelona*  
 Sonia Ramos, *Madrid*  
 Francisco Rodríguez-Frias, *Córdoba*  
 Manuel L Rodríguez-Peralvarez, *Córdoba*  
 Marta R Romero, *Salamanca*  
 Carlos J Romero, *Madrid*  
 Maria Traperó-Marugán, *Madrid*



#### **Sri Lanka**

Niranga M Devanarayana, *Ragama*



#### **Sudan**

Hatim MY Mudawi, *Khartoum*



#### **Sweden**

Evangelos Kalaitzakis, *Lund*



#### **Switzerland**

Christoph A Maurer, *Liestal*



#### **Thailand**

Taned Chitapanarux, *Chiang mai*  
 Temduang Limpaboon, *Khon Kaen*  
 Sith Phongkitkarun, *Bangkok*  
 Yong Poovorawan, *Bangkok*



#### **Turkey**

Osman Abbasoglu, *Ankara*  
 Mesut Akarsu, *Izmir*  
 Umit Akyuz, *Istanbul*  
 Hakan Alagozlu, *Sivas*  
 Yasemin H Balaban, *Istanbul*  
 Bulent Baran, *Van*  
 Mehmet Celikbilek, *Yozgat*

Levent Doganay, *Istanbul*  
 Fatih Eren, *Istanbul*  
 Abdurrahman Kadayifci, *Gaziantep*  
 Ahmet Karaman, *Kayseri*  
 Muhsin Kaya, *Diyarbakir*  
 Ozgur Kemik, *Van*  
 Serdar Moralioglu, *Uskudar*  
 A Melih Ozel, *Gebze - Kocaeli*  
 Seren Ozenirler, *Ankara*  
 Ali Sazci, *Kocaeli*  
 Goktug Sirin, *Kocaeli*  
 Mustafa Sunbul, *Samsun*  
 Nazan Tuna, *Sakarya*  
 Ozlem Yonem, *Sivas*



#### **Ukraine**

Rostyslav V Bubnov, *Kyiv*  
 Nazarii K Kobylak, *Kyiv*  
 Igor N Skrypnyk, *Poltava*



#### **United Kingdom**

Safa Al-Shamma, *Bournemouth*  
 Jayantha Arnold, *Southall*  
 Marco Carbone, *Cambridge*  
 Rajeev Desai, *Birmingham*  
 Ashwin Dhanda, *Bristol*  
 Matthew Hoare, *Cambridge*  
 Stefan G Hubscher, *Birmingham*  
 Nikolaos Karidis, *London*  
 Lemonica J Koumbi, *London*  
 Patricia Lalor, *Birmingham*  
 Ji-Liang Li, *Oxford*  
 Evaggelia Liaskou, *Birmingham*  
 Rodrigo Liberal, *London*  
 Wei-Yu Lu, *Edinburgh*  
 Richie G Madden, *Truro*  
 Christian P Selinger, *Leeds*  
 Esther Una Cidon, *Bournemouth*



#### **United States**

Naim Alkhouri, *Cleveland*  
 Robert A Anders, *Baltimore*  
 Mohammed Sawkat Anwer, *North Grafton*  
 Kalyan Ram Bhamidimarri, *Miami*

Brian B Borg, *Jackson*  
 Ronald W Busuttil, *Los Angeles*  
 Andres F Carrion, *Miami*  
 Saurabh Chatterjee, *Columbia*  
 Disaya Chavalitdhamrong, *Gainesville*  
 Mark J Czaja, *Bronx*  
 Jonathan M Fenkel, *Philadelphia*  
 Catherine Frenette, *La Jolla*  
 Lorenzo Gallon, *Chicago*  
 Kalpana Ghoshal, *Columbus*  
 Grigoriy E Gurvits, *New York*  
 Hie-Won L Hann, *Philadelphia*  
 Shuang-Teng He, *Kansas City*  
 Wendong Huang, *Duarte*  
 Rachel Hudacko, *Suffern*  
 Lu-Yu Hwang, *Houston*  
 Ijaz S Jamall, *Sacramento*  
 Neil L Julie, *Bethesda*  
 Hetal Karsan, *Atlanta*  
 Ahmed O Kaseb, *Houston*  
 Zeid Kayali, *Pasadena*  
 Kusum K Kharbanda, *Omaha*  
 Timothy R Koch, *Washington*  
 Gursimran S Kochhar, *Cleveland*  
 Steven J Kovacs, *East Hanover*  
 Mary C Kuhns, *Abbott Park*  
 Jiang Liu, *Silver Spring*  
 Li Ma, *Stanford*  
 Francisco Igor Macedo, *Southfield*  
 Sandeep Mukherjee, *Omaha*  
 Natalia A Osna, *Omaha*  
 Jen-Jung Pan, *Houston*  
 Christine Pocha, *Minneapolis*  
 Yury Popov, *Boston*  
 Davide Povero, *La Jolla*  
 Phillip Ruiz, *Miami*  
 Takao Sakai, *Cleveland*  
 Nicola Santoro, *New Haven*  
 Eva Schmelzer, *Pittsburgh*  
 Zhongjie Shi, *Philadelphia*  
 Nathan J Shores, *New Orleans*  
 Siddharth Singh, *Rochester*  
 Veysel Tahan, *Iowa City*  
 Mehlika Toy, *Boston*  
 Hani M Wadei, *Jacksonville*  
 Gulam Waris, *North Chicago*  
 Ruliang Xu, *New York*  
 Jun Xu, *Los Angeles*  
 Matthew M Yeh, *Seattle*  
 Xuchen Zhang, *West Haven*  
 Lixin Zhu, *Buffalo*  
 Sasa Zivkovic, *Pittsburgh*

**MINIREVIEWS**

- 385 Management of hepatitis B reactivation in immunosuppressed patients: An update on current recommendations

*Bessone F, Dirchwolf M*

- 395 Management of human factors engineering-associated hemochromatosis: A 2015 update

*Sivakumar M, Powell LW*

**ORIGINAL ARTICLE****Basic Study**

- 401 Role of interleukin-1 and its antagonism of hepatic stellate cell proliferation and liver fibrosis in the Abcb4<sup>-/-</sup> mouse model

*Reiter FP, Wimmer R, Wotke L, Artmann R, Nagel JM, Carranza MO, Mayr D, Rust C, Fickert P, Trauner M, Gerbes AL, Hohenester S, Denk GU*

**Retrospective Study**

- 411 Retrocaval liver lifting maneuver and modifications of total hepatic vascular exclusion for liver tumor resection

*Ko S, Kirihataya Y, Matsumoto Y, Takagi T, Matsusaka M, Mukogawa T, Ishikawa H, Watanabe A*

**ABOUT COVER**

Editorial Board Member of *World Journal of Hepatology*, Xiao-Ming Fan, MD, PhD, Professor, Department of Gastroenterology, Jinshan Hospital of Fudan University, Shanghai 201508, China

**AIM AND SCOPE**

*World Journal of Hepatology* (*World J Hepatol*, *WJH*, online ISSN 1948-5182, DOI: 10.4254), is a peer-reviewed open access academic journal that aims to guide clinical practice and improve diagnostic and therapeutic skills of clinicians.

*WJH* covers topics concerning liver biology/pathology, cirrhosis and its complications, liver fibrosis, liver failure, portal hypertension, hepatitis B and C and inflammatory disorders, steatohepatitis and metabolic liver disease, hepatocellular carcinoma, biliary tract disease, autoimmune disease, cholestatic and biliary disease, transplantation, genetics, epidemiology, microbiology, molecular and cell biology, nutrition, geriatric and pediatric hepatology, diagnosis and screening, endoscopy, imaging, and advanced technology. Priority publication will be given to articles concerning diagnosis and treatment of hepatology diseases. The following aspects are covered: Clinical diagnosis, laboratory diagnosis, differential diagnosis, imaging tests, pathological diagnosis, molecular biological diagnosis, immunological diagnosis, genetic diagnosis, functional diagnostics, and physical diagnosis; and comprehensive therapy, drug therapy, surgical therapy, interventional treatment, minimally invasive therapy, and robot-assisted therapy.

We encourage authors to submit their manuscripts to *WJH*. We will give priority to manuscripts that are supported by major national and international foundations and those that are of great basic and clinical significance.

**INDEXING/  
ABSTRACTING**

*World Journal of Hepatology* is now indexed in PubMed, PubMed Central, and Scopus.

**FLYLEAF**

**I-IV** Editorial Board

**EDITORS FOR  
THIS ISSUE**

**Responsible Assistant Editor:** *Xiang Li*  
**Responsible Electronic Editor:** *Su-Qing Liu*  
**Proofing Editor-in-Chief:** *Lian-Sheng Ma*

**Responsible Science Editor:** *Fang-Fang Ji*  
**Proofing Editorial Office Director:** *Xiu-Xia Song*

**NAME OF JOURNAL**  
*World Journal of Hepatology*

**ISSN**  
ISSN 1948-5182 (online)

**LAUNCH DATE**  
October 31, 2009

**FREQUENCY**  
36 Issues/Year (8<sup>th</sup>, 18<sup>th</sup>, and 28<sup>th</sup> of each month)

**EDITORS-IN-CHIEF**  
**Clara Balsano, PhD, Professor**, Departement of Biomedicine, Institute of Molecular Biology and Pathology, Rome 00161, Italy

**Wan-Long Chuang, MD, PhD, Doctor, Professor**, Hepatobiliary Division, Department of Internal Medicine, Kaohsiung Medical University Hospital, Kaohsiung Medical University, Kaohsiung 807, Taiwan

**EDITORIAL OFFICE**  
Jin-Lei Wang, Director

Xiu-Xia Song, Vice Director  
*World Journal of Hepatology*  
Room 903, Building D, Ocean International Center,  
No. 62 Dongsihuan Zhonglu, Chaoyang District,  
Beijing 100025, China  
Telephone: +86-10-59080039  
Fax: +86-10-85381893  
E-mail: editorialoffice@wjgnet.com  
Help Desk: <http://www.wjgnet.com/esps/helpdesk.aspx>  
<http://www.wjgnet.com>

**PUBLISHER**  
Baishideng Publishing Group Inc  
8226 Regency Drive,  
Pleasanton, CA 94588, USA  
Telephone: +1-925-223-8242  
Fax: +1-925-223-8243  
E-mail: [bpgoffice@wjgnet.com](mailto:bpgoffice@wjgnet.com)  
Help Desk: <http://www.wjgnet.com/esps/helpdesk.aspx>  
<http://www.wjgnet.com>

**PUBLICATION DATE**  
March 18, 2016

**COPYRIGHT**

© 2016 Baishideng Publishing Group Inc. Articles published by this Open Access journal are distributed under the terms of the Creative Commons Attribution Non-commercial License, which permits use, distribution, and reproduction in any medium, provided the original work is properly cited, the use is non commercial and is otherwise in compliance with the license.

**SPECIAL STATEMENT**

All articles published in journals owned by the Baishideng Publishing Group (BPG) represent the views and opinions of their authors, and not the views, opinions or policies of the BPG, except where otherwise explicitly indicated.

**INSTRUCTIONS TO AUTHORS**

Full instructions are available online at [http://www.wjgnet.com/bpg/g\\_info\\_20160116143427.htm](http://www.wjgnet.com/bpg/g_info_20160116143427.htm)

**ONLINE SUBMISSION**

<http://www.wjgnet.com/esps/>

## Management of hepatitis B reactivation in immunosuppressed patients: An update on current recommendations

Fernando Bessone, Melisa Dirchwolf

Fernando Bessone, Department of Gastroenterology and Hepatology, School of Medicine, University of Rosario, Rosario 2000, Argentina

Melisa Dirchwolf, Department of Hepatology, Muñiz Hospital, Buenos Aires 1282, Argentina

**Author contributions:** Bessone F and Dirchwolf M contributed equally to this review article.

**Conflict-of-interest statement:** None of the authors have received fees for serving as a speaker or consultant, nor have they received research funding in relation to this manuscript.

**Open-Access:** This article is an open-access article which was selected by an in-house editor and fully peer-reviewed by external reviewers. It is distributed in accordance with the Creative Commons Attribution Non Commercial (CC BY-NC 4.0) license, which permits others to distribute, remix, adapt, build upon this work non-commercially, and license their derivative works on different terms, provided the original work is properly cited and the use is non-commercial. See: <http://creativecommons.org/licenses/by-nc/4.0/>

**Correspondence to:** Fernando Bessone, MD, Full Professor of Gastroenterology, Department of Gastroenterology and Hepatology, School of Medicine, University of Rosario, Urquiza 3100, Rosario 2000, Argentina. [bessonefernando@gmail.com](mailto:bessonefernando@gmail.com)  
Telephone: +54-341-4393511  
Fax: +54-341-4393511

Received: May 23, 2015  
Peer-review started: May 25, 2015  
First decision: August 16, 2015  
Revised: January 15, 2016  
Accepted: March 7, 2016  
Article in press: March 9, 2016  
Published online: March 18, 2016

### Abstract

The proportion of hepatitis B virus (HBV) previously

exposed patients who receive immunosuppressive treatment is usually very small. However, if these individuals are exposed to potent immunosuppressive compounds, the risk of HBV reactivation (HBVr) increases with the presence of hepatitis B surface antigen (HBsAg) in the serum. Chronic HBsAg carriers have a higher risk than those who have a total IgG anticore as the only marker of resolved/occult HBV disease. The loss of immune control in these patients may result in the reactivation of HBV replication within hepatocytes. Upon reconstitution of the immune system, infected hepatocytes are once again targeted and damaged by immune surveillance in an effort to clear the virus. There are different virological scenarios, and a wide spectrum of associated drugs with specific and stratified risk for the development of HBVr. Some of these agents can trigger a severe degree of hepatocellular damage, including hepatitis, acute liver failure, and even death despite employment of effective antiviral therapies. Currently, HBVr incidence seems to be increasing around the world; a fact mainly related to the incessant appearance of more powerful immunosuppressive drugs launched to the market. Moreover, there is no consensus on the length of prophylactic treatment before the patients are treated with immunosuppressive therapy, and for how long this therapy should be extended once treatment is completed. Therefore, this review article will focus on when to treat, when to monitor, what patients should receive HBV therapy, and what drugs should be selected for each scenario. Lastly, we will update the definition, risk factors, screening, and treatment recommendations based on both current and different HBV management guidelines.

**Key words:** Anti-tumor necrosis factor- $\alpha$  drugs; Acute liver failure; Biologic therapy; Immunosuppressive therapy; Hepatitis B

© The Author(s) 2016. Published by Baishideng Publishing Group Inc. All rights reserved.



**Core tip:** Chronic hepatitis B surface antigen carriers have a high risk to develop hepatitis B virus (HBV) reactivation (HBVr) when exposed to immunosuppressive therapy. The loss of immune control in these patients may result in an increase in HBV replication. There is a wide spectrum of associated drugs with specific and stratified risk for the development of HBVr. Currently, HBVr incidence seems to increase worldwide, mainly due to the appearance of more powerful immunosuppressive drugs. This review article focuses on when to treat, when to monitor, what patients should receive HBV therapy, and what drugs should be selected in each scenario. We updated here current HBV management guidelines.

Bessone F, Dirchwolf M. Management of hepatitis B reactivation in immunosuppressed patients: An update on current recommendations. *World J Hepatol* 2016; 8(8): 385-394 Available from: URL: <http://www.wjgnet.com/1948-5182/full/v8/i8/385.htm> DOI: <http://dx.doi.org/10.4254/wjh.v8.i8.385>

## INTRODUCTION

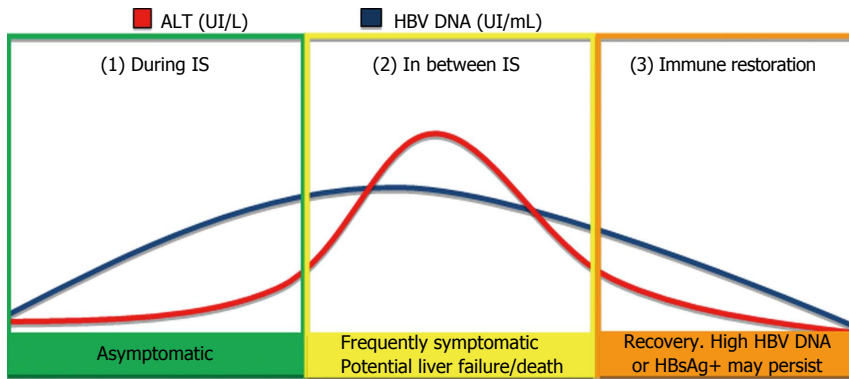
Hepatitis B virus (HBV) infection is a major public health problem worldwide; roughly, 30% of the world population shows serological evidence of current or past infection<sup>[1]</sup>, and it is largely considered that there are 350 million chronic carriers globally<sup>[2,3]</sup>. Although chronic infection can lead to progressive liver injury, most patients (60%-85%) are asymptomatic, and therefore the infection remains unrecognized until the appearance of signs or symptoms of chronic liver disease/cirrhosis<sup>[4,5]</sup>. Even though a small percentage of patients who were previously in contact with HBV will probably require immunosuppression as treatment of different illnesses (malignant, autoimmune, chronic rheumatic diseases) or to avoid post-transplantation rejection. However, treatment with such agents raises the risk of HBV reactivation (HBVr). This holds particularly true for patients with previously undetected chronic HBV infection, but also for those with resolved or occult infection [hepatitis B surface antigen (HBsAg)-negative, antibody to hepatitis B core antigen (antiHBc)-positive, with or without antibody to hepatitis B surface antigen (antiHBs)-positive serology]<sup>[6-10]</sup>. These events are referred to as HBVr; they were first described 40 years ago as a complication of renal transplantation and cancer chemotherapy. Since then, HBVr has become well recognized in numerous immunosuppression (IS) settings. Despite of that, HBVr due to IS continues to cause severe hepatitis, liver failure, and even death in spite of the availability of effective HBV vaccines, easily available and cheap tests to define patients at risk, and safe and effective antiviral therapies. A more worrisome issue is that the occurrence of this severe clinical event appears to increase around the globe<sup>[11]</sup>; perhaps, this is due to the permanent changing landscape of IS

agents involved, the heterogeneous screening, definition and treatment guidelines, and the multiple available therapeutic options<sup>[12]</sup>. This revision aims to update HBVr definition, risk factors, screening, and treatment recommendations based on the currently published evidence.

## HOST AND VIRAL INTERACTION: HBVR CLINICAL FEATURES

Hepatocellular inflammation and injury in HBV infection is suggested to be directly related to the intensity of host immune response<sup>[13]</sup>. In the initial phase of immune tolerance, infected children have high levels of viral replication, with no associated liver injury. As the immune system matures, the infected person enters a phase of immune clearance, in which the hepatocytes infected with HBV are targeted and damaged, resulting in hepatitis flares. In most individuals, the immune system is eventually able to control viremia, leading to hepatitis B e antigen clearance, suppression of HBV DNA levels, and normalization of liver biochemical test. The immune control phase usually endures; however, in cases of iatrogenic or natural IS, the loss of immune control results in reactivation of HBV replication inside hepatocytes. Upon reconstitution of the immune system, these hepatocytes are once again targeted and damaged by immune surveillance, in an effort to clear the virus<sup>[5,14,15]</sup>. HBVr has been described as a three-phase event (Figure 1). Initially, an increase in HBV DNA levels in an HBsAg positive person, or a reappearance of either HBsAg (seroreversion) or HBV DNA occurs; this period is usually asymptomatic. When the following phase takes place, HBV DNA levels show a sustained increase in viral load, accompanied by concomitant elevations in aminotransferase levels, which may also be associated to the development of severe hepatocellular damage; to note, even acute liver failure and ultimately death may occur. The aforementioned events result from a reconstitution syndrome of the host immune response. Finally, liver damage resolves due to recovery of the immune system strength (spontaneously or as a result of immunosuppressive therapy suspension) or due to the administration of antiviral drugs. This event may result in complete resolution of hepatic inflammation, or in fewer cases, a higher HBV DNA viral load in previously HBsAg positive patients can be observed<sup>[3,14,15]</sup>. Despite the fact that HBVr is usually found in chronically infected patients; it has also been reported in patients with resolved or occult HBV infection (*i.e.*, HBsAg negative, antiHBc positive), since these individuals still have traces of HBV DNA replication in their liver.

The reactivation risk depends on a combination between the degree and duration of IS<sup>[4,16]</sup>. Reactivation of HBV replication during IS can occur in an indirect fashion, through abolition of specific T-cell control, but also in a straightforward manner, when stimulation of a glucocorticoid-responsive element in the HBV



**Figure 1 Hepatitis B reactivation phases.** In the initial phase, there is an increase in HBV DNA levels, usually with an asymptomatic evolution. In the second phase, both ALT and HBV DNA are elevated; symptoms are frequently present, and they may be severe. The third phase is determined by resolution, although HBsAg (if reappeared), or elevated HBV DNA, may persist<sup>[3,17,55]</sup>. IS: Immunosuppression; HBV: Hepatitis B virus; ALT: Alanine aminotransferase; HBsAg: Hepatitis B surface antigen.

genome occurs, leading to up regulation of HBV gene expression<sup>[17]</sup>.

## HBVR DEFINITIONS: A HETEROGENEOUS GROUP

One of the major difficulties assessing the impact of HBVr is the different diagnostic criteria found in the literature<sup>[16]</sup>. Although reports of HBVr and its consequences are not scarce, the data are often difficult to contrast, because of the different definitions used. Some studies consider HBV DNA level elevations<sup>[18]</sup>, some evaluate reappearance of HBsAg<sup>[19]</sup>, and others evaluate episodes of hepatitis syndrome, utilizing different grading (severity) systems<sup>[4]</sup>. Consensus has not been reached, even in the major clinical guidelines; both the European Association for the Study of the Liver (EASL) and Asian Pacific Association for the Study of the Liver (APASL) chronic hepatitis B guidelines, when addressing HBVr, considers HBsAg seroreversion and rise in HBV DNA levels as diagnostic criteria<sup>[20,21]</sup>, whereas the American Association for the Study of Liver Diseases (AASLD) defines HBVr as reappearance of active necro-inflammatory disease of the liver in an individual at an inactive HBsAg carrier state or who was known to have resolved hepatitis B<sup>[5]</sup>. Recently, at the Reactivation of Hepatitis B AASLD meeting held in 2013, the first attempt to establish a standardized nomenclature was made. Reactivation of HBV replication was defined as a marked increase in HBV replication ( $\geq 2$  log increase from baseline levels or a new appearance of HBV DNA to a level of  $\geq 100$  IU/mL) in a person with previously stable or undetectable levels. The types of reactivation were described as reverse HBsAg seroconversion (reappearance of HBsAg), or appearance of HBV DNA in serum in the absence of HBsAg. The severity of reactivation, defined by the presence or absence of jaundice and liver failure; and its outcome (return to baseline status or persistence in an activated state, need for liver transplantation or death) should also be reported<sup>[2,17]</sup>. A universal grading system that also

includes the consequences related to the IS therapy was recently proposed by Visram *et al.*<sup>[4]</sup>, in an additional effort to standardize HBVr grading and its consequences.

## MEDICAL INTERVENTIONS ASSOCIATED WITH HBVR

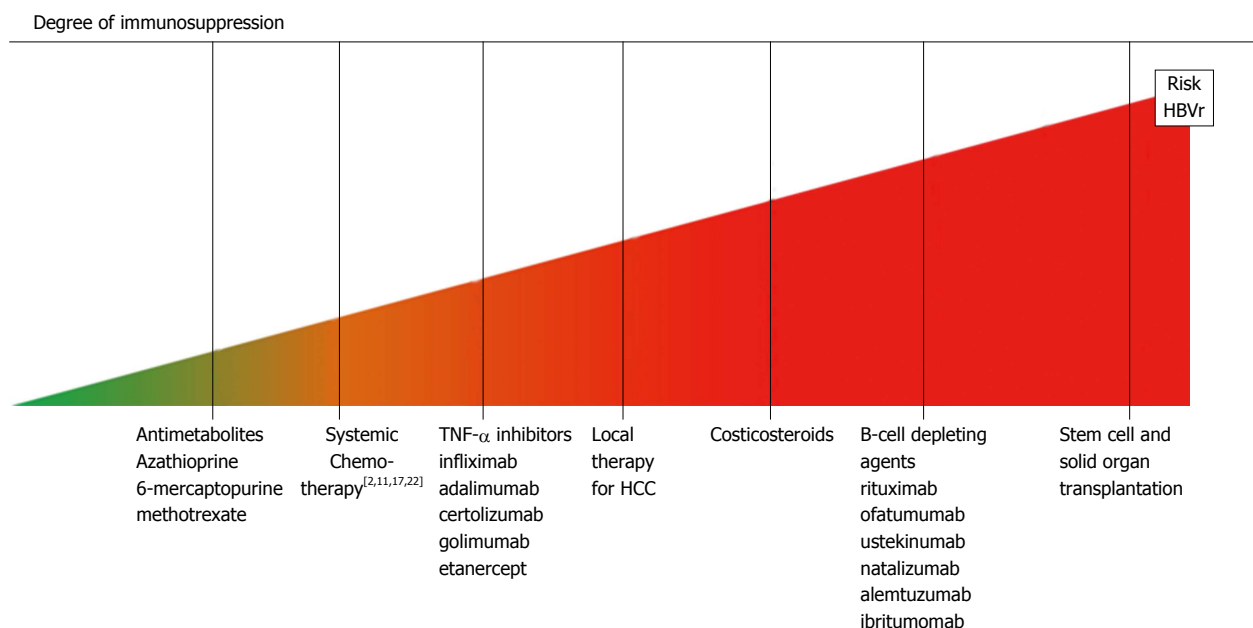
Several agents have been associated with the risk of HBVr, depending on the type and intensity of IS caused by these medical interventions<sup>[2]</sup>. The most relevant ones are described below, and displayed according to the risk of HBVr in Figure 2.

### Antimetabolites

HBVr during IS with low doses of azathioprine or methotrexate, when used as monotherapy, is uncommon<sup>[3,22]</sup>. In a thorough review recently published, no report was found in which azathioprine used alone was documented to cause HBVr<sup>[12]</sup>. Similarly, although several reports associated with methotrexate-induced HBVr are available, most of them involved the concomitant use of other immunomodulators<sup>[22]</sup>. Indeed, this antimetabolite has been in clinical use for more than 50 years, and only a small number of cases have been described in published reports in which HBVr was attributable to this agent when used alone. Based on these findings, they are considered to be drugs with low risk of HBVr<sup>[12,23]</sup>.

### Tumor necrosis factor- $\alpha$ inhibitors

Tumor necrosis factor- $\alpha$  (TNF- $\alpha$ ) is a pro-inflammatory and immunoregulatory cytokine involved in the pathogenesis of several inflammatory disorders. The inhibition of TNF- $\alpha$  signaling can lead to increased HBV replication and reactivation<sup>[2,24]</sup>. Anti-TNF- $\alpha$  agents are approved to treat rheumatoid arthritis, intestinal inflammatory diseases and psoriasis; in this context, several (*e.g.*, infliximab, adalimumab, certolizumab, golimumab and etanercept) have been associated with HBVr<sup>[22]</sup>. In a meta-analysis published by Lee *et al.*<sup>[25]</sup> evaluating the risk of HBVr in 468 isolated antiHBc patients with rheumatic conditions treated with different anti-TNF- $\alpha$



**Figure 2** Immunosuppressing agents and related risk of hepatitis B reactivation. HCC: Hepatocellular carcinoma; TNF- $\alpha$ : Tumor necrosis factor- $\alpha$ ; HBVr: Hepatitis B virus reactivation.

(mostly etanercept), HBVr was found in 1.7% of the cases. The same author reported much higher rates of HBVr in HBsAg-positive patients (12.3%) in a similar cohort of rheumatic patients<sup>[26]</sup>. Additionally, several severe HBVr have been communicated, particularly following infliximab administration<sup>[3,27]</sup>. However, it is unclear whether the risk of HBVr is the same with every TNF- $\alpha$  inhibitor. Most cases have been associated with the more potent IS drugs such as infliximab or adalimumab rather than etanercept. Comparative risk assessment between these agents is doubtful when incidence is derived from case report and retrospective rather than well-designed prospective studies. Therefore, a moderate level of confidence can be given to estimation that the risk of HBVr during anti-TNF- $\alpha$  monotherapy is between 1% and 10% in HBsAg carriers, and quite lower in isolated antiHBe<sup>[12]</sup>.

#### Locoregional therapy for hepatocellular carcinoma

Several therapeutic strategies for hepatocellular carcinoma (HCC) have been inferred to cause HBVr<sup>[28,29]</sup>. Transarterial chemoembolization (TACE) has been directly associated with an increased rate of HBVr<sup>[30]</sup>. Even though this procedure has little systemic effect due to the administration of chemotherapeutic agents directly into a branch of the hepatic artery<sup>[2]</sup>, it may cause systemic symptoms if arterio-venous shunts or peritumoral microcirculation are present; this is why host immune system is often compromised. Additionally, anthracyclines (*i.e.*, doxorubicin) are frequently used as part of intra-arterial chemotherapy. In experimental models, anthracyclines have stimulated HBV DNA secretion from HCC cell lines; this mechanism may help to explain the higher risk of HBVr in patients treated with doxorubicin-containing TACE<sup>[12]</sup>. HBVr during radio-

therapy, with or without TACE, has also been examined in several studies<sup>[27,31]</sup>. In a prospective study conducted by Huang evaluating 69 HBV patients with HCC treated with conformal radiotherapy, almost 25% of them suffered HBVr, and 21.7% HBVr induced hepatitis<sup>[32]</sup>. HBVr in patients who underwent HCC surgical resection and local ablation therapy have also been extensively reported<sup>[27,30]</sup>.

#### Corticosteroids

Prednisone is the cornerstone of several chemotherapeutic regimens, and an important agent to induce remission in inflammatory bowel disease<sup>[2]</sup>. This and other corticosteroids have been associated with an increased risk of HBVr (both in monotherapy and especially when combined with other IS drugs)<sup>[22]</sup>. The HBVr is thought to be mediated by abolition of specific T-cell control, and also by direct viral stimulation. The risk of infection has been stratified according to the dosage and time of exposure to the corticosteroid<sup>[33]</sup>. Based on these variables, in a meta-analysis that included every well-documented report on HBVr, a risk stratification score was proposed: HBsAg positive patients who received more than 10 mg/daily of prednisone for 4 wk or longer were included in the high-risk group (> 10% chance of HBVr); HBsAg positive patients that received less than 10 mg/daily of prednisone or HBsAg-negative, antiHBe positive patients that were treated with less than 20 mg/daily of prednisone for less than 4 wk are included in the moderate-risk group (1%-10% risk of HBVr). Finally, antiHBe positive patients treated with less than 10 mg/daily of prednisone for less than 4 wk, and patients with local steroid treatment (such as intra-articular infusion) were included in the low risk group<sup>[12]</sup>. Therefore, corticosteroid use is an independent risk

factor for HBVr<sup>[12,22]</sup>.

### Systemic chemotherapy

This is one of the therapeutic interventions more frequently related with HBVr; not only associated with the degree of immunosuppression but also with the type of malignancy treated<sup>[14,16,34]</sup>. HBsAg-positive chronic carriers with hematologic diseases are at the highest risk of developing HBVr during IS, reaching an incidence of 40%-50%, or even higher, according to different series<sup>[12,27]</sup>. One of the most frequently cited study is related to the risk of HBVr in lymphoma patients, with reactivation rates reaching almost 50%, and an associated mortality of 4%<sup>[14,17,18,22,35]</sup>. Other studies report on an incidence of HBVr in this setting between 24%-67%, and an elevated mortality rate of 4%-41%. One of the reasons for this elevated risk relies on the intensive chemotherapy necessary for lymphoma treatment, especially when most chemotherapies schemes include high doses of steroids and/or rituximab. It may also be due to the rather high prevalence of HBV observed in this cohort of patients<sup>[14,36]</sup>. HBVr has also been described in patients receiving chemotherapy for treatment of solid tumors (*i.e.*, breast, colon and lung cancer)<sup>[21,22,37]</sup>. These patients fall within the intermediate risk category (HBVr chance of 10%-30%). Finally, the low risk group includes patients with gastrointestinal malignancies receiving 5-fluorouracil based therapy<sup>[27]</sup>.

### Biologic antibodies

Rituximab is considered a high-risk factor for HBVr<sup>[38]</sup>. This cytolytic monoclonal antibody is directed against the CD20 antigen of immature and mature B cells; it is used for the treatment of numerous hematological malignancies, severe rheumatic conditions, and (off-label) solid organ transplantation (in the latter scenario, as an adjunctive agent to mitigate humoral allograft response)<sup>[13]</sup>. When combined with standard-of-care chemotherapy for non-Hodgkin's lymphoma, HBVr has been observed in up to 25% of patients with resolved infection; this reactivation may occur even 12 mo after the therapy has been completed; including those patients with isolated antiHBc<sup>[22,39]</sup>. A preliminary analysis of the post marketing data from the Food and Drug Administration (FDA) Adverse Event Reporting System found 109 cases of HBV-related acute liver failure associated with rituximab and ofatumumab (another anti-CD20 monoclonal antibody). They occurred during the 13 years of rituximab and 3 years of ofatumumab commercialization<sup>[17]</sup>. Due to these reports, in the year 2013 a boxed warning was included in the label issued by the FDA for both drugs, describing HBVr resulting in "fulminant hepatitis, hepatic failure and death". This advisement underlines the potential for HBVr especially in chronically infected patients, but also in those who have resolved a previous HBV infection<sup>[13,17]</sup>. Due to these events, all antibodies directed against CD20 have been compelled by the FDA to add HBVr to the boxed

warning; recommending HBV screening tests before initiation of therapy and therapy when positive results are found<sup>[17]</sup>. Other biologic agents, such as specific tyrosine kinase inhibitors imatinib and nilotinib, have been implied in well-documented cases of HBVr; however, newly developed drugs including cytokine and integrin inhibitors such as ustekinumab, natalizumab, alemtuzumab and vedolizumab, have few or no reports of HBVr as yet. Since they all share the same mechanism of action, it is expected for them to convey at least a low to moderate risk of this complication<sup>[12,22]</sup>.

### Stem cell and solid organ transplantation

Patients undergoing stem cell/bone marrow transplantation are at the highest HBVr-risk position followed closely by those receiving solid organ transplantation.

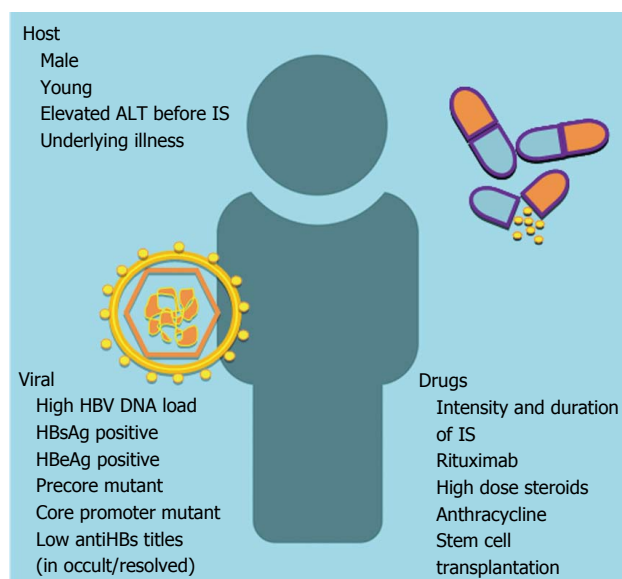
Bone marrow/stem cell transplanted patients typically get intense chemotherapy to induce remission of the underlying malignancy, followed by additional chemotherapy and radiation therapy to ablate bone marrow<sup>[17,40]</sup>. The profound IS and loss of pre-existing HBV-specific immunity allows for HBVr in the liver to occur, and the return of active viral replication<sup>[19]</sup>. In this setting, the HBVr rate reaches 50% in both HBsAg-positive and isolated antiHBc-positive patients. In the latter group, antiHBs titles below 10 mUI/mL were a predictor of HBsAg seroreversion<sup>[17]</sup>. Due to the considerable delay in immune system reconstitution that typically occurs in this subset of patients, the risk of seroreversion can endure for several years; furthermore, these patients are prone to develop chronic infection once the virus is reactivated<sup>[19]</sup>. In a retrospective study that evaluated 137 HBsAg negative and antiHBc positive patients who underwent hematopoietic cell transplant patients, the prevalence of HBVr reached 10%, occurring within 9 to 77 mo after transplantation<sup>[40]</sup>.

When considering solid organ transplantation, HBVr risk has been known to reach 50%-90% in HBsAg-positive patients after kidney transplantation. In these cases, reactivation has the potential to cause liver failure, progression to cirrhosis, HCC, and increased liver-related mortality. Other solid transplant recipients (*e.g.*, heart, lung) have been the subject of similar reports<sup>[17]</sup>.

## WHOM TO CHECK: UNIVERSAL SCREENING VS HIGH-RISK PROFILING

The key to prevent HBVr is the timely identification of HBV-infected patients prior to immunosuppressive therapy<sup>[41,42]</sup>. The proportion of patients ignorant of their chronic HBV infection reaches 35% in United States; this proportion is far higher (90%) in the European Union<sup>[4,17]</sup>, whereas in Latin America the figures are unknown. To note, HBV screening is mandatory in high-risk groups in only 15% of the countries located of this region<sup>[43]</sup>. Lack of standardized risk factor assessment, the fact that many patients are not aware (or might not acknowledge)





**Figure 3 Risk factors for hepatitis B reactivation in patients with current/past hepatitis B infection.** ALT: Alanine aminotransferase; HBV: Hepatitis B virus; HBsAg: Hepatitis B surface antigen; HBeAg: Hepatitis B e antigen; IS: Immunosuppression<sup>[2,4,27,56,57]</sup>.

that they have had risk behaviors, and the scarce time dedicated by most physicians to systematically screen their patients for HBV risk factors when they are about to start immunosuppressive therapy worsen the situation<sup>[14,17,44]</sup>. Risk factors for HBV infection are well-known (patients born in areas with intermediate-high HBV prevalence, patients who use intravenous drugs, patients that have had multiple sexual partners, patients with sexually transmitted diseases, etc.)<sup>[5,20]</sup>, but factors associated with HBVr have been less described; these are relevant for the decision and timing of HBV treatment. The most relevant ones are shown in Figure 3.

The combination of several of these risk factors has been suggested to stratify patients into high-, intermediate-, and low-risk for HBVr<sup>[6,12]</sup>. The relevance of risk assessment relies on the screening strategy adopted by the physician. Several HBV diagnostic consensus statements suggest universal screening, including the Centers for Disease Control and Prevention recommendations, as well as the EASL and the APASL guidelines<sup>[6,20]</sup>. The benefits of this approach are not only the identification of every chronically infected HBV patient, but also the recognition of patients previously exposed to the virus, thus eliminating the possibility of missing patients without clearly identified risk factors. The alternative screening strategy involves testing only patients at high risk for HBV infection; these recommendations are endorsed by the AASLD, the American Society of Clinical Oncology, and the National Comprehensive Cancer Network<sup>[6,17,45]</sup>. This targeted approach has been praised in relation to its lower cost, however, it may fail to identify chronic HBV carriers and previously exposed patients, and perhaps more importantly, it has been challenging for physicians to accomplish<sup>[6]</sup>.

**Table 1 Diagnostic tools suggested for hepatitis B screening prior to immunosuppression therapy by different major guidelines**

Recommendations	Hepatitis B screening tests before immunosuppression			
	HBsAg	AntiHBc	HBV DNA	AntiHBs
CDC	Yes	Yes	No	Yes
AASLD	High risk	High risk	No	No
EASL	Yes	Yes	No	No
APASL	Yes	No	No	No
ASCO	High risk	High risk	No	Yes <sup>1</sup>

<sup>1</sup>Only suggested in antiHBc-positive patients. CDC: Center for Disease Control; AASLD: American Association for the Study of Liver Disease; EASL: European Association for the Study of the Liver; APASL: Asian Pacific Association for the Study of the Liver; ASCO: American Society Clinical Oncology; HBV: Hepatitis B virus; HBsAg: Hepatitis B surface antigen; AntiHBc: Antibody to hepatitis B core antigen; AntiHBs: Antibody to hepatitis B surface antigen.

## SCREENING TOOLS: HETEROGENEOUS RECOMMENDATIONS

Currently, there are no universally accepted screening tests adopted into clinical practice. Again, lack of consensus regarding testing for hepatitis B current/resolved infection complicates the picture<sup>[2]</sup>. Recommendations of different serologic testing for HBV screening prior to IS are shown in Table 1. HBsAg testing is endorsed by all major societies without consensus regarding risk evaluation, as already stated<sup>[6]</sup>. AntiHBc is not a required test by the APASL due to the high prevalence of HBV in this region (up to one third of the population)<sup>[46]</sup>. Whether to include antiHBs and HBV DNA testing among antiHBc-positive subjects is still controversial, since it is not based on prospective data<sup>[6,46]</sup>. Finally, regarding the moment for testing, it has been suggested that the major benefit is reached when it is done prior to initiation of therapy<sup>[16,27,47]</sup>.

## TREATMENTS FOR HBVR: SEVERAL MATTERS TO ADDRESS

The rationale for the identification of patients infected by HBV is to allow proper antiviral therapy, if needed, or otherwise to undertake careful monitoring<sup>[17]</sup>. Once again, several decisions have to be made by physicians on this point, some of which have different endorsements according to the consulted guideline. The decision-making stages are the following ones.

### When to treat

Several definitions have been used to classify treatment initiation timing. Treatment prophylaxis refers to antiviral therapy started before or concurrently as the initiation of immunosuppressive therapy, and before aminotransferase or HBV DNA levels rise occurs. On the other hand, in pre-emptive treatments, the occurrence of serum HBV DNA or aminotransferase elevation deter-

**Table 2** Recommendations for treatment and follow-up in different clinical scenarios, according to Asian Pacific Association for the Study of the Liver, American Association for the Study of Liver Disease and European Association for the Study of the Liver guidelines

Recommendations in different clinical scenarios					
	HBsAg (+) HBV DNA $\geq$ 2000 U/mL	HBsAg (+) HBV DNA < 2000 U/mL	HBsAg (-) antiHBc (+)	HBsAg (-) antiHBc (-) antiHBs (-)	HBV-HCC TACE
Action	Treat	Treat	Close mon/treat if HBV DNA (+) or rituximab/stem cell transplant <sup>1</sup>	Vaccination	Treat <sup>3</sup>
Onset	Before IS	Before IS	Before IS	-	Before IS
Duration	6-12 mo (except CI)	6-12 mo (except CI)	6-12 mo	-	-
Drug	Short IS: LAM (LdT) preferred ETV/TDF	Short IS: LAM (LdT) (ETV/TDF)	Short IS: LAM (LdT) (ETV/TDF)	-	LAM (ETV/TDF)
Follow-up	-	-	Every 1-3 mo/treat if HBV DNA (+) <sup>2</sup>	-	-

In HBsAg-positive patients, duration could be determined by CI as in immunocompetent patients. A 12-mo treatment was only endorsed by EASL. Drug selection depends on treatment duration and clinical setting. <sup>1</sup>In isolated antiHBc-positive patients when treated with biologic agents, close follow-up and treatment, if necessary, is suggested by AASLD/APASL; however, EASL proposes that isolated antiHBc-positive patients, if HBV DNA-positive, antiHBs-negative or undergoing rituximab/stem cell transplantation, should be treated with the same strategy as HBsAg positive patients; <sup>2</sup>When monitored, treatment should start when HBV DNA becomes positive, before ALT rise (EASL); <sup>3</sup>Treatment in all HBV-related HCC patients undergoing TACE is suggested by APASL guidelines. CI: Clinical indication; IS: Immunosuppression; HBsAg: Hepatitis B surface antigen; AntiHBc: Hepatitis B core antibody; AntiHBs: Hepatitis B surface antibody; HBV: Hepatitis B virus; HCC: Hepatocellular carcinoma; TACE: Transarterial chemoembolization; LAM: Lamivudine; ETV: Entecavir; TDF: Tenofovir; LdT: Telbivudine (only listed as an option in AASLD guidelines); AASLD: American Association for the Study of Liver Disease; APASL: Asian Pacific Association for the Study of the Liver; EASL: European Association for the Study of the Liver.

mine the initiation of antivirals (before symptoms, if any, appear)<sup>[17]</sup>. The latter definition has been included in what referred to as “deferred treatment” in more recent publications<sup>[12]</sup>. Regarding HBsAg-positive patients, most treatment guidelines recommend prophylactic treatment; such as the AASLD (initiation of antivirals at the onset of IS), and the APASL guidelines (initiation of antivirals one week prior to chemotherapy)<sup>[5,30]</sup> (Table 2). The EASL mentions the “pre-emptive” treatment strategy, but defines it as antiviral administration during therapy regardless of HBV DNA levels, similar as the aforementioned guidelines<sup>[20]</sup>.

Several studies have compared these starting-point strategies. In the technical review by Perrillo *et al.*<sup>[12]</sup> where results of two randomized controlled trials of antiviral prophylaxis with lamivudine in HBsAg-positive patients undergoing chemotherapy were evaluated, an HBVr rate of 55% was found in the untreated group. There was biochemical evidence of hepatitis in 86% of these patients, which resulted in hepatic failure in 10% of the cohort<sup>[12]</sup>. In a recent meta-analysis published by Zheng *et al.*<sup>[48]</sup> where the efficacy of prophylactic use of lamivudine in HBsAg-positive patients undergoing chemotherapy for breast cancer was evaluated, the rate of HBVr was diminished by 91%, and there was a similar reduction in chemotherapy disruption in the prophylactic lamivudine group. HBsAg-negative and antiHBc-positive patients, when compared with HBsAg-positive patients, appear to have a lower risk of HBVr when exposed to moderate-risk immunosuppressive drugs. This would explain why certain scientific societies such as APASL suggest close monitoring and treatment in this patient’s population only when reactivation occurs<sup>[30]</sup>. In contrast, when high-risk agents such as rituximab are used in isolated antiHBc-positive patients, high rates of reactivation in excess of 10% occur, and antiviral prophylaxis can be expected to result in similar

absolute risk reduction, as described for HBsAg-positive patients<sup>[5,12,30]</sup>.

### Whom to treat and what antiviral to choose

Most guidelines agree on recommendations for HBsAg-positive patients<sup>[49]</sup>. In this group, the choice of antiviral and length of therapy will depend on the clinical status of the HBV infection. When considering HBsAg-positive patients, antiviral therapy should commence in the context of immunosuppression. If the patient has clinical indications for HBV treatment (*i.e.*, HBV DNA > 2000 IU/mL), either tenofovir or entecavir should be chosen, and therapy should be maintained until they reach therapeutic endpoints for chronic hepatitis B. Otherwise, prophylactic therapy could be initiated with lamivudine, although more powerful antiviral could be chosen as well<sup>[5,20,30,50]</sup>. This rule also applies to all HBV-related, HCC patients who are to undergo TACE<sup>[30]</sup>. Lamivudine will only be sufficient in a finite and short-term course of immunosuppressive therapy. Elseways, in those patients with elevated HBV DNA viral load and/or in those receiving prolonged cycles of IS, protection with entecavir or tenofovir is preferred, due to their higher potency and stronger barrier of resistance<sup>[20,51-53]</sup>. Lamivudine resistance increases according to treatment duration, reaching a 10%-20% rate in the first year, and increasing longitudinally with time (especially with high initial HBV DNA viremia). In addition, given that drug-resistant variants are archived and reemerge quickly on re-exposure to the antiviral drug, patients with a history of prior lamivudine or telbivudine treatment would be best treated with tenofovir, as this is the most effective drug for patients with prior resistance. The recommendation of both entecavir and tenofovir are based on the evidence of efficacy of these drugs in treating chronic HBV patients outside the prophylaxis setting, since their utility in the immunosuppressive

scenario has been less studied. There are no studies of tenofovir use, but several cohort studies and a randomized trial using entecavir<sup>[12,54]</sup>. Preliminary results of 121 patients with lymphoma treated with R-CHOP (chemotherapy treatment including rituximab, cyclophosphamide, doxorubicin, vincristine and prednisone) randomized to lamivudine and entecavir prophylaxis, HBVr was seen in 8% of the lamivudine-treated patients and none among the entecavir-treated patients. Recommendations for tenofovir use must be based on anticipated parallel benefits to entecavir, as both drugs are of high antiviral potency and have low risk of resistance with prolonged therapy<sup>[49]</sup>.

There is no consensus regarding the duration of treatment; AASLD and APASL societies suggest 6 mo of maintenance after IS cessation, whereas EASL recommends its extension to 12 mo<sup>[5,20,30]</sup>. Both AASLD and APASL guidelines consider that in HBsAg-negative but antiHBc- and antiHBs-positive patients, and in those with isolated antiHBc, reactivation is infrequent. Therefore these patients should be monitored and antiviral therapy initiated when HBVr occurs<sup>[5,30]</sup>. However, EASL suggests that this subgroup of patients should be tested for HBV DNA, and if present, they should be treated similarly as HBsAg-positive patients. Furthermore in antiHBs negative patients and/or when close monitoring of HBV DNA is not guaranteed, this guideline recommends prophylaxis therapy with antivirals in patients receiving rituximab, bone-marrow or stem-cell transplantation and/or combined regimens for hematological malignancies. The optimal duration of prophylaxis for these indications is unknown<sup>[20]</sup>.

## CONCLUSION

Ambiguity on the nomenclature of HBVr is a major problem that has led to the uncertain estimation of its incidence. A proper standardization of both terminology and definitions are required to reach better estimates of the frequency and associated risk factors of HBVr in different clinical settings. Furthermore, this standard definitions should be employed in safety and efficacy trials for new IS agents.

HBV screening before starting immunosuppressive therapy is a key factor to prevent HBVr. We need consensus on how and when to screen HBV in patients at high risk for HBVr. The call for large, collaborative, population-based studies is eagerly awaited to determine with confidence the efficiency of the HBV screening methods, and the consequent optimal antiviral prophylaxis, aimed to HBVr prevention.

Many HBV-infected patients are unconscious of their disease or risk factors. An appeal from scientific societies for physicians to spend enough time to assess patients for HBV risk factors prior to begin immunosuppression therapy is mandatory.

Finally, to make progress in this field, consensus from major societies composing the scientific hepatology community in the construction of clear guidelines to

define HBVr management (*i.e.*, antiviral selection, treatment onset and duration) and follow-up are essential.

## REFERENCES

- 1 Trépo C, Chan HL, Lok A. Hepatitis B virus infection. *Lancet* 2014; **384**: 2053-2063 [PMID: 24954675 DOI: 10.1016/s0140-6736(14)60220-8]
- 2 Seetharam A, Perrillo R, Gish R. Immunosuppression in Patients with Chronic Hepatitis B. *Curr Hepatol Rep* 2014; **13**: 235-244 [PMID: 25101233 DOI: 10.1007/s11901-014-0238-2]
- 3 Roche B, Samuel D. The difficulties of managing severe hepatitis B virus reactivation. *Liver Int* 2011; **31** Suppl 1: 104-110 [PMID: 21205146 DOI: 10.1111/j.1478-3231.2010.02396.x]
- 4 Visram A, Feld JJ. Defining and grading HBV reactivation: Defining and Grading HBV Reactivation. *Clinical Liver Disease* 2015; **5**: 35-38 [DOI: 10.1002/cld.426]
- 5 Lok AS, McMahon BJ. Chronic hepatitis B: update 2009. *Hepatology* 2009; **50**: 661-662 [PMID: 19714720 DOI: 10.1002/hep.23190]
- 6 Etzion O, Ghany MG. Screening for hepatitis B virus to prevent viral reactivation - who and when? *Clinical Liver Disease* 2015; **5**: 47-50 [DOI: 10.1002/cld.458]
- 7 Lim R, Holt A. Hepatitis B and C prophylaxis in patients receiving chemotherapy. *Viral Hepat Pract* 2014; **6**: 10-13 [PMID: 25893086]
- 8 Larrubia JR. Occult hepatitis B virus infection: a complex entity with relevant clinical implications. *World J Gastroenterol* 2011; **17**: 1529-1530 [PMID: 21472115 DOI: 10.3748/wjg.v17.i12]
- 9 Gwak GY, Koh KC, Kim HY. Fatal hepatic failure associated with hepatitis B virus reactivation in a hepatitis B surface antigen-negative patient with rheumatoid arthritis receiving low dose methotrexate. *Clin Exp Rheumatol* 2007; **25**: 888-889 [PMID: 18173926]
- 10 Wu JM, Huang YH, Lee PC, Lin HC, Lee SD. Fatal reactivation of hepatitis B virus in a patient who was hepatitis B surface antigen negative and core antibody positive before receiving chemotherapy for non-Hodgkin lymphoma. *J Clin Gastroenterol* 2009; **43**: 496-498 [PMID: 19247200 DOI: 10.1097/MCG.0b013e3181945942]
- 11 Perrillo RP. Hepatitis B reactivation from immunosuppressive drug therapy: A global menace: Editor's comment for february issue of clinical liver disease. *Clinical Liver Disease* 2015; **5**: 39-42 [DOI: 10.1002/cld.448]
- 12 Perrillo RP, Gish R, Falck-Ytter YT. American Gastroenterological Association Institute technical review on prevention and treatment of hepatitis B virus reactivation during immunosuppressive drug therapy. *Gastroenterology* 2015; **148**: 221-244.e3 [PMID: 25447852 DOI: 10.1053/j.gastro.2014.10.038]
- 13 Martin ST, Cardwell SM, Nailor MD, Gabardi S. Hepatitis B reactivation and rituximab: a new boxed warning and considerations for solid organ transplantation. *Am J Transplant* 2014; **14**: 788-796 [PMID: 24592928 DOI: 10.1111/ajt.12649]
- 14 Lubel JS, Angus PW. Hepatitis B reactivation in patients receiving cytotoxic chemotherapy: diagnosis and management. *J Gastroenterol Hepatol* 2010; **25**: 864-871 [PMID: 20546439 DOI: 10.1111/j.1440-1746.2010.06243.x]
- 15 Bessone F. Re-appraisal of old and new diagnostic tools in the current management of chronic hepatitis B. *Liver Int* 2014; **34**: 991-1000 [PMID: 25098191 DOI: 10.1111/liv.12499]
- 16 Hwang JP, Barbo AG, Perrillo RP. Hepatitis B reactivation during cancer chemotherapy: an international survey of the membership of the American Association for the Study of Liver Diseases. *J Viral Hepat* 2015; **22**: 346-352 [PMID: 25220947 DOI: 10.1111/jvh.12305]
- 17 Hwang JP, Lok AS. Management of patients with hepatitis B who require immunosuppressive therapy. *Nat Rev Gastroenterol Hepatol* 2014; **11**: 209-219 [PMID: 24247262 DOI: 10.1038/nrgastro.2013.216]
- 18 Totani H, Kusumoto S, Ishida T, Masuda A, Yoshida T, Ito A,



- Ri M, Komatsu H, Murakami S, Mizokami M, Ueda R, Niimi A, Inagaki H, Tanaka Y, Iida S. Reactivation of hepatitis B virus (HBV) infection in adult T-cell leukemia-lymphoma patients with resolved HBV infection following systemic chemotherapy. *Int J Hematol* 2015; **101**: 398-404 [PMID: 25633779 DOI: 10.1007/s12185-015-1750-z]
- 19 **Palmore TN**, Shah NL, Loomba R, Borg BB, Lopatin U, Feld JJ, Khokhar F, Lutchman G, Kleiner DE, Young NS, Childs R, Barrett AJ, Liang TJ, Hoofnagle JH, Heller T. Reactivation of hepatitis B with reappearance of hepatitis B surface antigen after chemotherapy and immunosuppression. *Clin Gastroenterol Hepatol* 2009; **7**: 1130-1137 [PMID: 19577007 DOI: 10.1016/j.cgh.2009.06.027]
- 20 **European Association For The Study Of The Liver**. EASL clinical practice guidelines: Management of chronic hepatitis B virus infection. *J Hepatol* 2012; **57**: 167-185 [PMID: 22436845 DOI: 10.1016/j.jhep.2012.02.010]
- 21 **Liu CJ**, Chen PJ, Chen DS, Kao JH. Hepatitis B virus reactivation in patients receiving cancer chemotherapy: natural history, pathogenesis, and management. *Hepatol Int* 2013; **7**: 316-326 [PMID: 21670970 DOI: 10.1007/s12072-011-9279-6]
- 22 **Reynolds JA**, Manch RA, Gish RG. Medical interventions associated with HBV reactivation: Common and less common. *Clinical Liver Disease* 2015; **5**: 32-34 [DOI: 10.1002/cld.413]
- 23 **Laohapand C**, Arromdee E, Tanwandee T. Long-term use of methotrexate does not result in hepatitis B reactivation in rheumatologic patients. *Hepatol Int* 2015; **9**: 202-208 [PMID: 25788188 DOI: 10.1007/s12072-014-9597-6]
- 24 **Manzano-Alonso ML**, Castellano-Tortajada G. Reactivation of hepatitis B virus infection after cytotoxic chemotherapy or immunosuppressive therapy. *World J Gastroenterol* 2011; **17**: 1531-1537 [PMID: 21472116 DOI: 10.3748/wjg.v17.i12.1531]
- 25 **Lee YH**, Bae SC, Song GG. Hepatitis B virus (HBV) reactivation in rheumatic patients with hepatitis core antigen (HBV occult carriers) undergoing anti-tumor necrosis factor therapy. *Clin Exp Rheumatol* 2013; **31**: 118-121 [PMID: 23111095]
- 26 **Lee YH**, Bae SC, Song GG. Hepatitis B virus reactivation in HBsAg-positive patients with rheumatic diseases undergoing anti-tumor necrosis factor therapy or DMARDs. *Int J Rheum Dis* 2013; **16**: 527-531 [PMID: 24164839 DOI: 10.1111/1756-185x.12154]
- 27 **Jang JW**. Hepatitis B virus reactivation in patients with hepatocellular carcinoma undergoing anti-cancer therapy. *World J Gastroenterol* 2014; **20**: 7675-7685 [PMID: 24976705 DOI: 10.3748/wjg.v20.i24.7675]
- 28 **Liu F**, Dan J, Zhang Y, Chen M, Huang J, Xie R. [Hepatitis B reactivation after treatment for HBV-related hepatocellular carcinoma: comparative analysis of radiofrequency ablation versus hepatic resection]. *Zhonghua Ganzangbing Zazhi* 2014; **22**: 38-42 [PMID: 24721242 DOI: 10.3760/cma.j.issn.1007-3418.2014.01.009]
- 29 **von Weizsäcker F**, Blum HE. Out of control: hepatitis B reactivation by transarterial treatment of hepatocellular carcinoma. *J Hepatol* 2004; **41**: 482-484 [PMID: 15336452 DOI: 10.1016/j.jhep.2004.07.005]
- 30 **Liaw YF**, Kao JH, Piratvisuth T, Chan HL, Chien RN, Liu CJ, Gane E, Locarnini S, Lim SG, Han KH, Amarapurkar D, Cooksley G, Jafri W, Mohamed R, Hou JL, Chuang WL, Lesmana LA, Sollano JD, Suh DJ, Omata M. Asian-Pacific consensus statement on the management of chronic hepatitis B: a 2012 update. *Hepatol Int* 2012; **6**: 531-561 [PMID: 26201469 DOI: 10.1007/s12072-012-9365-4]
- 31 **Dan JQ**, Zhang YJ, Huang JT, Chen MS, Gao HJ, Peng ZW, Xu L, Lau WY. Hepatitis B virus reactivation after radiofrequency ablation or hepatic resection for HBV-related small hepatocellular carcinoma: a retrospective study. *Eur J Surg Oncol* 2013; **39**: 865-872 [PMID: 23597497 DOI: 10.1016/j.ejso.2013.03.020]
- 32 **Huang W**, Zhang W, Fan M, Lu Y, Zhang J, Li H, Li B. Risk factors for hepatitis B virus reactivation after conformal radiotherapy in patients with hepatocellular carcinoma. *Cancer Sci* 2014; **105**: 697-703 [PMID: 24654677 DOI: 10.1111/cas.12400]
- 33 **Gu HR**, Shin DY, Choi HS, Moon CH, Park SC, Kang HJ. HBV reactivation in a HBsAg-negative patient with multiple myeloma treated with prednisolone maintenance therapy after autologous HSCT. *Blood Res* 2015; **50**: 51-53 [PMID: 25830131 DOI: 10.5045/br.2015.50.1.51]
- 34 **Dyson JK**, Hudson M, McPherson S. Lesson of the month 2: Severe reactivation of hepatitis B after immunosuppressive chemotherapy. *Clin Med (Lond)* 2014; **14**: 551-555 [PMID: 25301924 DOI: 10.7861/clinmedicine.14-5-551]
- 35 **Tamori A**, Hino M, Kawamura E, Fujii H, Uchida-Kobayashi S, Morikawa H, Nakamae H, Enomoto M, Murakami Y, Kawada N. Prospective long-term study of hepatitis B virus reactivation in patients with hematologic malignancy. *J Gastroenterol Hepatol* 2014; **29**: 1715-1721 [PMID: 24730465 DOI: 10.1111/jgh.12604]
- 36 **Hsu C**, Tsou HH, Lin SJ, Wang MC, Yao M, Hwang WL, Kao WY, Chiu CF, Lin SF, Lin J, Chang CS, Tien HF, Liu TW, Chen PJ, Cheng AL. Chemotherapy-induced hepatitis B reactivation in lymphoma patients with resolved HBV infection: a prospective study. *Hepatology* 2014; **59**: 2092-2100 [PMID: 24002804 DOI: 10.1002/hep.26718]
- 37 **Yang Y**, Du Y, Luo WX, Li C, Chen Y, Cheng K, Ding J, Zhou Y, Ge J, Yang X, Liu JY. Hepatitis B virus reactivation and hepatitis in gastrointestinal cancer patients after chemotherapy. *Cancer Chemother Pharmacol* 2015; **75**: 783-790 [PMID: 25687988 DOI: 10.1007/s00280-015-2700-4]
- 38 **Mozessohn L**, Chan KK, Feld JJ, Hicks LK. Hepatitis B reactivation in HBsAg-negative/HBcAb-positive patients receiving rituximab for lymphoma: a meta-analysis. *J Viral Hepat* 2015; **22**: 842-849 [PMID: 25765930 DOI: 10.1111/jvh.12402]
- 39 **Civan J**, Hann HW. Giving rituximab in patients with occult or resolved hepatitis B virus infection: are the current guidelines good enough? *Expert Opin Drug Saf* 2015; **14**: 865-875 [PMID: 25826452 DOI: 10.1517/14740338.2015.1032243]
- 40 **Mikulska M**, Nicolini L, Signori A, Rivoli G, Del Bono V, Raiola AM, Di Grazia C, Dominietto A, Varaldo R, Ghiso A, Bacigalupo A, Viscoli C. Hepatitis B reactivation in HBsAg-negative/HBcAb-positive allogeneic haematopoietic stem cell transplant recipients: risk factors and outcome. *Clin Microbiol Infect* 2014; **20**: O694-O701 [PMID: 24575948 DOI: 10.1111/1469-0691.12611]
- 41 **Sampedro B**, Hernández-López C, Ferrandiz JR, Illaro A, Fàbrega E, Cuadrado A, Iruzubietta P, Menéndez S, Cabezas J, Crespo J. Computerized physician order entry-based system to prevent HBV reactivation in patients treated with biologic agents: the PRESCRIB project. *Hepatology* 2014; **60**: 106-113 [PMID: 24585503 DOI: 10.1002/hep.27103]
- 42 **Kusumoto S**, Tobinai K. Screening for and management of hepatitis B virus reactivation in patients treated with anti-B-cell therapy. *Hematology Am Soc Hematol Educ Program* 2014; **2014**: 576-583 [PMID: 25696914 DOI: 10.1182/asheducation-2014.1.576]
- 43 **Díez-Padrisa N**, Castellanos LG. Viral hepatitis in Latin America and the Caribbean: a public health challenge. *Rev Panam Salud Publica* 2013; **34**: 275-281 [PMID: 24301739]
- 44 **Sun WC**, Hsu PI, Yu HC, Lin KH, Tsay FW, Wang HM, Tsai TJ, Chen WC, Lai KH, Cheng JS. The compliance of doctors with viral hepatitis B screening and antiviral prophylaxis in cancer patients receiving cytotoxic chemotherapy using a hospital-based screening reminder system. *PLoS One* 2015; **10**: e0116978 [PMID: 25658926 DOI: 10.1371/journal.pone.0116978]
- 45 **Artz AS**, Somerfield MR, Feld JJ, Giusti AF, Kramer BS, Sabichi AL, Zon RT, Wong SL. American Society of Clinical Oncology provisional clinical opinion: chronic hepatitis B virus infection screening in patients receiving cytotoxic chemotherapy for treatment of malignant diseases. *J Clin Oncol* 2010; **28**: 3199-3202 [PMID: 20516452 DOI: 10.1200/jco.2010.30.0673]
- 46 **Lau GKK**. How do we handle the anti-HBc positive patient? (in highly endemic settings): The Anti-HBc positive patient. *Clinical Liver Disease* 2015; **5**: 29-31 [DOI: 10.1002/cld.399]
- 47 **Ludwig E**. HBV reactivation in immunosuppressed patients: prevention or containment? *Hepatology* 2014; **59**: 2062-2064



- [PMID: 24753022 DOI: 10.1002/hep.27056]
- 48 **Zheng Y**, Zhang S, Tan Grahn HM, Ye C, Gong Z, Zhang Q. Prophylactic Lamivudine to Improve the Outcome of Breast Cancer Patients With HBsAg Positive During Chemotherapy: A Meta-Analysis. *Hepat Mon* 2013; **13**: e6496 [PMID: 23805156 DOI: 10.5812/hepatmon.6496]
  - 49 **Terrault N**. Management strategies for hepatitis B-infected patients undergoing immunomodulatory therapy: Is lamivudine enough? *Clinical Liver Disease* 2015; **5**: 43-46 [DOI: 10.1002/cld.447]
  - 50 **Mo YQ**, Liang AQ, Ma JD, Chen LF, Zheng DH, Schumacher HR, Dai L. Discontinuation of antiviral prophylaxis correlates with high prevalence of hepatitis B virus (HBV) reactivation in rheumatoid arthritis patients with HBV carrier state: a real-world clinical practice. *BMC Musculoskelet Disord* 2014; **15**: 449 [PMID: 25532827 DOI: 10.1186/1471-2474-15-449]
  - 51 **Tuna N**, Karabay O. Hepatitis B reactivation and timing for prophylaxis. *World J Gastroenterol* 2015; **21**: 2263-2264 [PMID: 25717269 DOI: 10.3748/wjg.v21.i7.2263]
  - 52 **Abramson JS**, Chung RT. Optimal antiviral prophylaxis against hepatitis B reactivation in patients receiving rituximab-based chemotherapy for lymphoma. *JAMA* 2014; **312**: 2505-2507 [PMID: 25514300 DOI: 10.1001/jama.2014.16095]
  - 53 **Brost S**, Schnitzler P, Stremmel W, Eisenbach C. Entecavir as treatment for reactivation of hepatitis B in immunosuppressed patients. *World J Gastroenterol* 2010; **16**: 5447-5451 [PMID: 21086562]
  - 54 **Baang J**. Treatment to prevent hepatitis B virus reactivation in patients with lymphoma receiving chemotherapy. *JAMA* 2015; **313**: 1269-1270 [PMID: 25803354 DOI: 10.1001/jama.2015.1438]
  - 55 **Philips CA**, Sarin SK. Potent antiviral therapy improves survival in acute on chronic liver failure due to hepatitis B virus reactivation. *World J Gastroenterol* 2014; **20**: 16037-16052 [PMID: 25473156 DOI: 10.3748/wjg.v20.i43.16037]
  - 56 **Kim HY**, Kim W. Chemotherapy-related reactivation of hepatitis B infection: updates in 2013. *World J Gastroenterol* 2014; **20**: 14581-14588 [PMID: 25356022 DOI: 10.3748/wjg.v20.i40.14581]
  - 57 **Salpini R**, Colagrossi L, Bellocchi MC, Surdo M, Becker C, Alteri C, Aragri M, Ricciardi A, Armenia D, Pollicita M, Di Santo F, Carioti L, Louzoun Y, Mastroianni CM, Lichtner M, Paoloni M, Esposito M, D'Amore C, Marrone A, Marignani M, Sarrecchia C, Sarmati L, Andreoni M, Angelico M, Verheyen J, Perno CF, Svicher V. Hepatitis B surface antigen genetic elements critical for immune escape correlate with hepatitis B virus reactivation upon immunosuppression. *Hepatology* 2015; **61**: 823-833 [PMID: 25418031 DOI: 10.1002/hep.27604]

**P- Reviewer:** Chiang TA, Lee WC, Li J **S- Editor:** Gong XM

**L- Editor:** A **E- Editor:** Liu SQ



## Management of human factors engineering-associated hemochromatosis: A 2015 update

Menaka Sivakumar, Lawrie W Powell

Menaka Sivakumar, School of Medicine, the University of Queensland, Brisbane QLD 4029, Australia

Lawrie W Powell, Centre for the Advancement of Clinical Research, Royal Brisbane and Women's Hospital Campus, Brisbane QLD 4029, Australia

**Author contributions:** Both authors contributed equally writing the review.

**Conflict-of-interest statement:** Neither author has any conflict of interest to declare (including but not limited to commercial, personal, political, intellectual, or religious interests).

**Open-Access:** This article is an open-access article which was selected by an in-house editor and fully peer-reviewed by external reviewers. It is distributed in accordance with the Creative Commons Attribution Non Commercial (CC BY-NC 4.0) license, which permits others to distribute, remix, adapt, build upon this work non-commercially, and license their derivative works on different terms, provided the original work is properly cited and the use is non-commercial. See: <http://creativecommons.org/licenses/by-nc/4.0/>

**Correspondence to:** Lawrie W Powell, MD, PhD, Director, Professor, Centre for the Advancement of Clinical Research, Royal Brisbane and Women's Hospital Campus, Level 4, UQ Centre for Clinical Research, Building 71/918, Brisbane QLD 4029, Australia. [lawrie.powell@qimrberghofer.edu.au](mailto:lawrie.powell@qimrberghofer.edu.au)  
 Telephone: +61-7-36462352  
 Fax: +61-7-36462355

Received: August 7, 2015  
 Peer-review started: August 10, 2015  
 First decision: September 21, 2015  
 Revised: January 27, 2016  
 Accepted: March 7, 2016  
 Article in press: March 9, 2016  
 Published online: March 18, 2016

### Abstract

This review focuses on the management of iron meta-

bolism and iron overload experienced in the hereditary condition, human factors engineering (HFE)-associated hemochromatosis. Hemochromatosis refers to a group of genetic diseases that result in iron overload; the major one globally is HFE-associated hemochromatosis. The evolution in understanding of the most common form of hereditary hemochromatosis, being the substitution of cysteine to a tyrosine at position 282 in the *HFE* gene, has been extensively studied. Novel mutations in both *HFE* and non-*HFE* genes have been indicated in this disease which hold significance in its application for the Asia-Pacific region. In conditions with iron overload, the storage of excess iron in various body tissues leads to complications and toxic damage. The most common presenting complaint for this disease is malaise, lethargy and other non-specific symptoms. In order to diagnose hereditary hemochromatosis, there are biochemical, imaging and genetic testing options. Currently, cascade screening of affected families is preferred over population-level screening. The mainstay of treatment is venesection and the appropriate approach to treatment has been consolidated over the years. Recently, the indications for venesection therapy of hemochromatosis have been challenged and are the subject of ongoing research.

**Key words:** Human factors engineering; Iron storage diseases; Genetics; Venesections; Hemochromatosis

© **The Author(s) 2016.** Published by Baishideng Publishing Group Inc. All rights reserved.

**Core tip:** The concept of hemochromatosis as a single disease entity has changed to an iron storage disease resulting from several genetic disorders although the final common metabolic pathway is inappropriate iron absorption from the intestine and progressive tissue iron loading. The most common form of the disease is due to a mutation in the human factors engineering gene resulting in cysteine tyrosine substitution at position 282 in the molecule. This mutation is relatively common in populations of northern European extraction but is rare

in other populations. In contrast other rarer forms of hemochromatosis resulting from other mutations in the hepcidin pathway are quite ubiquitous. The main stay of treatment remains venesection although new oral iron-chelating agents show promise.

Sivakumar M, Powell LW. Management of human factors engineering-associated hemochromatosis: A 2015 update. *World J Hepatol* 2016; 8(8): 395-400 Available from: URL: <http://www.wjgnet.com/1948-5182/full/v8/i8/395.htm> DOI: <http://dx.doi.org/10.4254/wjh.v8.i8.395>

## INTRODUCTION

The clinical and molecular research surrounding the clinical syndrome of hemochromatosis has been substantial in the last two decades even though it has been recognized in its advanced state for more than 100 years<sup>[1]</sup>. A mutation in the human factors engineering (*HFE*) gene was identified as the cause for more than 90% of cases of classic hemochromatosis<sup>[2]</sup> in most countries except for the Mediterranean region where it is responsible for around 65% of the cases. The genetic cause for hemochromatosis is more common in individuals with a northern European ancestry; however, the clinical manifestation, or incidence of biochemical abnormalities and clinical disease, is not as common in these populations. Although mutations in the *HFE* gene are most common, there are other forms of iron overload caused by mutations in other iron regulatory molecules that present as distinct clinical diseases. Over time, population studies have served the purpose of outlining the risk to an individual with a genetic mutation and the clinical investigations available for assessment and monitoring have improved. The treatment of hemochromatosis is the one aspect of this condition that has evolved the least over the years with phlebotomy still being the main therapy available. However, the treatment has potential for change with increased research on new therapeutic agents under trial. Although the European Association of the Study of Liver (EASL) and the American Association for the Study of Liver Disease have outlined appropriate treatment regimens, recent research have challenged these guidelines suggesting there is a benefit in beginning treatment early for patients with even mildly elevated iron levels but with or without clinical manifestation. According to current guidelines, the threshold of serum ferritin at which to start treatment is currently taken as above the normal range where the normal range for serum ferritin in men is 24-336 µg/L and in women is 11-307 µg/L. The current clinical standard is to maintain the serum ferritin at 50-100 µg/L<sup>[3]</sup>.

## PATHOPHYSIOLOGY

### Iron homeostasis

The role of iron in the body is a crucial one from oxygen

transport in hemoglobin and oxidative phosphorylation to the production of red blood cells and other functions<sup>[4,5]</sup>. In situations with overload, there are consequences in disease and mortality to be discussed later in this paper however the extent of this risk is still debated<sup>[6-9]</sup>. Beginning with iron, when it is consumed, it can enter the body in two forms: Either heme or non-heme<sup>[10,11]</sup>. Heme is mostly commonly ingested as animal protein and non-heme is *via* vegetables. However, there is no mechanism for the excretion of iron which is toxic in overload. Uncontrolled loss (1-2 mg) in menses, bleeding and the sloughing of skin are the only methods for iron removal.

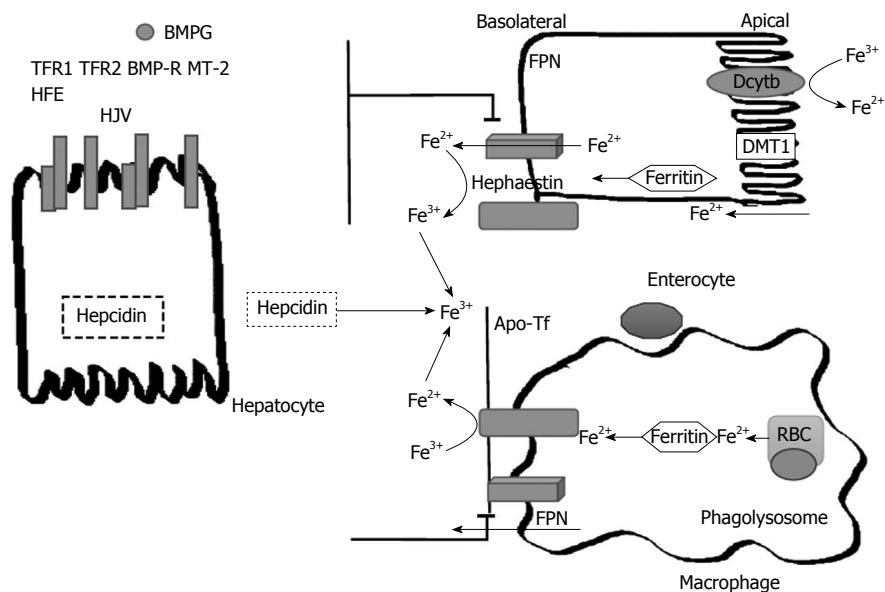
In order to understand iron homeostasis, a discussion regarding the pathway of iron is necessary. Iron is absorbed on the apical surface of enterocytes in the duodenum and proximal small bowel. Non-heme iron can be either ferrous ( $\text{Fe}^{2+}$ ) or ferric ( $\text{Fe}^{3+}$ )<sup>[4]</sup>. It is important to note that since ferrous iron is more soluble, it is necessary for ferric iron to be reduced to ferrous iron prior to absorption<sup>[12]</sup>. In order to reduce ferric iron found in non-heme iron to the ferrous state both gastric acidity and duodenal cytochrome B (DCyTB1) have been identified as well as other non-enzymatic pathways<sup>[13,14]</sup>. On the apical surface of enterocytes, the divalent metal transport 1 (DMT1) protein takes in ferrous iron<sup>[14]</sup>. The DMT1 protein also serves to transport manganese and copper (Figure 1).

From the enterocyte, iron uptake into tissue is mediated by transferrin receptors (TfR1 and TfR2). In transportation, iron is consistently bound to a molecule due to its ability to form free radicals. Transferrin, the carrier protein for iron binds to the TfR1 and is taken up by endosomes, where transferrin is cleaved and the receptor recycled back to the cell surface<sup>[15]</sup>. In the case of iron overload, excess iron is stored in complexes of hemosiderin or ferritin. Another form of iron storage is hemosiderin which is a by-product of ferritin degradation<sup>[13]</sup>.

On the basal surface of enterocytes, ferroportin (FPN1) is the sole expressed exporter in cells. Iron is released into circulation when FPN1 interacts with ferroxidase and hepcidin. Hephestin next acts to oxidize the iron and the iron is then immediately bound to the transport molecule transferrin (Tf)<sup>[4]</sup>. Another important regulator of iron homeostasis is ferroportin, a protein which acts to export stored iron from enterocytes and other intracellular stores. A small hepatic peptide, hepcidin, negatively regulates ferroportin<sup>[12]</sup> by causing the internalization and degradation of this protein thereby affecting the export of iron. In summary, hepcidin reduces iron uptake and serum iron<sup>[12,16]</sup>. There have been certain factors such as iron, inflammation and oxidative stress that have been demonstrated to have an inhibitory effect on the expression hepcidin. However, hepcidin regulation is not a topic that is completely understood.

### Genetics

Hereditary Hemochromatosis is caused by different



**Figure 1 Pathways of Iron transport and metabolism.** The pathway of iron in enterocytes and macrophages as effected by hepcidin. Dietary non-heme iron is taken into the enterocyte via the DMT1. In order for iron to move across the brush border of the enterocyte via DMT1, it must first be reduced from  $\text{Fe}^{3+}$  to  $\text{Fe}^{2+}$  by DcytB. Once inside of the cell, iron can be sequestered into storage as ferritin or continue along the pathway into circulation. In this process, the iron exporter FPN located on the basolateral surface of enterocytes is responsible for the transport of ferrous iron into circulation. Once iron is in circulation, hephaestin oxidizes the ferrous iron back into the ferric state and then it immediately binds to plasma transferrin. The iron is now able to travel to sites of iron storage or where iron is required. In macrophages, phagolysosomes containing senescent RBC release iron which is also then exported into circulation via ferroportin. Hepcidin, a protein derived from the liver, regulates iron transport in the body by causing the internalization and degradation of FPN transporters on macrophages and the basolateral surface of enterocytes. Hepcidin is regulated based on body iron requirements by signals produced from the interaction between different proteins on hepatocytes. The interaction of the HFE protein and transferrin receptors 1 and 2 (TFR1 and TFR2) and the interaction between bone morphogenic protein (BMP6), hemojuvelin (HJV) and the bone morphogenic protein receptor (BMP-R) and matriptase 2 (MT-2). RBC: Red blood cells; FPN: Ferroportin; DMT1: Divalent metal-ion transporter 1; DcytB: Duodenal cytochrome B; HFE: Human factors engineering.

**Table 1 Classification of iron overload and hemochromatosis**

Genetic iron overload (primary)
Type 1 HFE-associated hemochromatosis
C282Y homozygosity
C282Y/H63D compound heterozygosity
Type 2 juvenile hemochromatosis
2A hemojuvelin mutations
2B hepcidin mutations
Type 3 TFR2-related hemochromatosis
Transferrin receptor 2
Type 4 ferroportin disease
Loss of function mutations, also called type 4A or "M"
Hepcidin resistance mutations, also called type 4B or "H"
Aceruloplasminemia
Ceruloplasmin mutations
A(hypo)transferrinemia
Acquired iron overload (secondary)
Ineffective erythropoiesis
Thalassemia major
Sideroblastic anemia
Chronic hemolytic anemia
Dietary iron overload (African)
Parenteral iron overload (including transfusional overload)

HFE: Human factors engineering.

mutations that alter the regulatory proteins involved in iron homeostasis and hepcidin pathways. The genetic causes for hemochromatosis can be categorized into *HFE* gene mutations and non-*HFE* gene mutations (FPN, TFR HJV)<sup>[2]</sup>. While non-*HFE* gene mutations are not as

common as *HFE* gene mutations, there is an increased proportion of these mutations in non-Northern European populations<sup>[4]</sup>. Therefore, this information is of significance in Asia-Pacific populations<sup>[4]</sup>.

The knowledge and classification of hemochromatosis and other iron overload diseases has become more detailed in the last 2 decades (Table 1). Mutations in the genes encoding HFE, TFR2, hemojuvelin and hepcidin all lead to decreased hepcidin activity and increased iron absorption, resulting in the syndrome of hemochromatosis<sup>[5]</sup>. Mutations in *HFE*, *HJV*, *HAMP*, *TFR2* and *SLC40A1* have been linked to the various types of hemochromatosis<sup>[2,5]</sup>.

#### ***HFE-associated hereditary hemochromatosis***

In Northern European ancestry, an amino acid substitution specifically at position 282 of the HFE protein is the mutation most responsible for iron overload in this population<sup>[5]</sup>. The C282Y substitution is rare outside those of white ethnicity<sup>[17-19]</sup>. *HFE* is tightly linked to the HLA-A locus on chromosome 6p. Persons who are homozygous for the mutation are at increased risk of iron overload and account for 80% to 90% of clinical hereditary hemochromatosis in persons of northern European descent<sup>[6-9]</sup>. Pietrangelo suggest that between 10% and 33% of homozygous patients develop hereditary hemochromatosis<sup>[4,20]</sup>. This suggests that there are other genetic and non-genetic factors in the disease<sup>[21]</sup>.



There have been alternative mutations of HFE identified, primarily H63D and S65C; however, these mutations have not been proven to cause substantial iron overload<sup>[4]</sup>. In order to produce symptomatic disease, a heterozygous mutation is necessary. Since there is an increased prevalence of C282Y, and H63D is more relevant clinically, compound heterozygotes with symptomatic disease are usually C282Y/H63D<sup>[2,22-24]</sup>.

### **Non-HFE associated hereditary hemochromatosis**

Discussion regarding non-HFE associated hemochromatosis is beyond the scope of this paper.

## **CLINICAL MANIFESTATIONS**

Hereditary hemochromatosis is most commonly associated with liver disease including cirrhosis, but the clinical manifestations of iron overload are diverse and involve many other organs. Hemochromatosis is an overall underdiagnosed disease due to the idea that it is a rare condition and also associating diagnosis with clinical features seen in advanced disease such as cirrhosis, diabetes and skin pigmentation<sup>[3]</sup>. Genetic susceptibility for hemochromatosis is seen in approximately one in 250 Caucasians; however, fully expressed disease with end-organ manifestations is seen in fewer than 10% of these individuals<sup>[3]</sup>. Hemochromatosis patients mostly present with non-specific symptoms such as lethargy, arthralgia and weakness<sup>[25,26]</sup>. The other more commonly affected organ systems include liver, heart, pancreas, pituitary, skin and joints. Iron deposition in the conducting bundles and parenchyma of the heart result in cardiac arrhythmias and cardiomyopathy in 2%-19% of symptomatic patients<sup>[27,28]</sup>. Diabetes mellitus (DM) can be seen in up to 60% of symptomatic homozygotes but the rates of DM in asymptomatic patients are comparable to controls<sup>[7,29]</sup>. Endocrine dysfunction can occur as a result of iron deposition in pituitary and parathyroid glands<sup>[27,30]</sup>. Arthropathy is also observed in symptomatic and asymptomatic patients due to calcium pyrophosphate deposition in the articular cartilage, not iron sequestration and primarily involves the 2<sup>nd</sup> and 3<sup>rd</sup> metacarpophalangeal joints<sup>[25,31]</sup>.

## **MANAGEMENT AND TREATMENT**

Treatment for hemochromatosis with venesection (phlebotomy) has remained unchanged over the years<sup>[5]</sup>. Venesection as a treatment has two purposes: Directly reduce serum iron by depleting hemoglobin levels and to replace the depleted circulating serum iron by mobilizing iron stores from tissues. Early intervention, prior to the onset of symptoms, improves patient prognosis<sup>[32]</sup>. Furthermore, venesection in symptomatic individuals improves certain symptoms, such as skin pigmentation, while not having an effect on others such as cirrhosis and arthropathy<sup>[32]</sup>.

According to EASL clinical practice guidelines, the threshold of serum ferritin at which to start treatment is

currently taken as above the normal range. In regards to maintenance, the advocated standard practice is to maintain the serum ferritin at 50-100 µg/L and this is usually achieved with 3-6 mo of venesection<sup>[32]</sup>. It has been identified that the morbidity and mortality related to hereditary hemochromatosis can be greatly reduced by beginning treatment (phlebotomy) before the development of cirrhosis and/or diabetes. As a result of these findings, it is generally recommended that individuals at risk have prompt identification and pre-emptive treatment<sup>[32]</sup>. The pre-emptive treatment should be extended to involve those with homozygous HH that are asymptomatic and have markers of iron overload. Also, individuals with indications or evidence of increased level of hepatic iron should be treated. In summary, the American Association for the Study of Liver Disease recommends that in the absence of indicators suggestive of significant liver disease (alanine aminotransferase, aspartate transaminase elevation), C282Y homozygotes who have an elevated ferritin (but < 1000 µg/L) should proceed to prophylactic phlebotomy without a liver biopsy where target levels of phlebotomy should be a ferritin level of 50-100 µg/L<sup>[3,23,32]</sup>.

Traditionally, it was suggested that serum ferritin be maintained below 50 µg/L, but this has been updated to the range stated. Treatment guidelines also suggest yearly follow-up for the patients whose ferritin levels are at the normal range. This treatment strategy works for types 1-3 hereditary hemochromatosis but patients with type 4a may not tolerate venesection due to the irregular iron export from cells therefore treatment must be intermittent and is more complicated<sup>[32]</sup>.

Generally, 1 unit of blood is understood to contain approximately 200-250 mg of iron but the amount of iron that is removed each venesection can be variable<sup>[3]</sup>. It has been reported that on average, phlebotomy removes around 200-250 mg of iron per session<sup>[33]</sup>. Therefore, treatment must be provided on a personalized and case by case basis for each patient for appropriate venesection intervals and treatment regimens.

Although the treatment has remained the same for many years, there is still debate regarding the appropriate serum ferritin levels for maintenance of hemochromatosis. A recent study conducted by Bardou-Jacquet *et al*<sup>[6]</sup> found that early and sustained iron removal is beneficial as patients with serum ferritin levels between normal and 1000 µg/L, when treated, have reduced cardiovascular and extra-hepatic related mortality rates despite normal liver-related mortality rates. This study suggests that patients with even mild iron overload should be treated which builds on current management guidelines. However, this subject remains controversial.

## **CONCLUSION**

There is a continuing need to study the factors contributing to hemochromatosis due to the variable clinical penetrance of HFE mutations and the worldwide

prevalence of hemochromatosis in the absence of HFE mutations. Hemochromatosis has been divided into HFE-associated hemochromatosis related to mutations affecting iron transport and absorption and also HFE negative hemochromatosis or disease without HFE mutations. There is an incomplete understanding of the reasons for incomplete penetrance of disease phenotype in those with HFE mutations but recent research has revealed the presence of at least one other significant modifying genetic mutation<sup>[34]</sup>. Individuals at risk for hemochromatosis with genetic mutations and with or without symptomatic disease are recommended to pursue treatment at the earliest time possible and prior to any disease as this can help prevent further morbidity and mortality associated with hemochromatosis. Research advancement is opening doors for the management and treatment of iron overload as recent research has begun to develop the importance of treating mild iron overload due to its identified relation with reduced cardiovascular and extrahepatic related mortality rates.

## REFERENCES

- Von-Recklinghausen F.** Über haemochromatose. *Tageblatt Versammlung Deutsche Naturforscher Ärzte Heidelberg* 1889; **62**: 324-325
- Feder JN, Gnirke A, Thomas W, Tsuchihashi Z, Ruddy DA, Basava A, Dormishian F, Domingo R, Ellis MC, Fullan A, Hinton LM, Jones NL, Kimmel BE, Kronmal GS, Lauer P, Lee VK, Loeb DB, Mapa FA, McClelland E, Meyer NC, Mintier GA, Moeller N, Moore T, Morikang E, Prass CE, Quintana L, Starnes SM, Schatzman RC, Brunke KJ, Drayna DT, Risch NJ, Bacon BR, Wolff RK.** A novel MHC class I-like gene is mutated in patients with hereditary haemochromatosis. *Nat Genet* 1996; **13**: 399-408 [PMID: 8696333 DOI: 10.1038/ng0896-399]
- Bacon BR, Adams PC, Kowdley KV, Powell LW, Tavill AS.** Diagnosis and management of hemochromatosis: 2011 practice guideline by the American Association for the Study of Liver Diseases. *Hepatology* 2011; **54**: 328-343 [PMID: 21452290 DOI: 10.1002/hep.24330]
- Ekanayake D, Roddick C, Powell LW.** Recent advances in hemochromatosis: a 2015 update : a summary of proceedings of the 2014 conference held under the auspices of Hemochromatosis Australia. *Hepatol Int* 2015; **9**: 174-182 [PMID: 25788196 DOI: 10.1007/s12072-015-9608-2]
- Wood MJ, Skoien R, Powell LW.** The global burden of iron overload. *Hepatol Int* 2009; **3**: 434-444 [PMID: 19669241 DOI: 10.1007/s12072-009-9144-z]
- Bardou-Jacquet E, Morcet J, Manet G, Lainé F, Perrin M, Jouanolle AM, Guyader D, Moirand R, Viel JF, Deugnier Y.** Decreased cardiovascular and extrahepatic cancer-related mortality in treated patients with mild HFE hemochromatosis. *J Hepatol* 2015; **62**: 682-689 [PMID: 25450707 DOI: 10.1016/j.jhep.2014.10.025]
- Allen KJ, Gurrin LC, Constantine CC, Osborne NJ, Delatycki MB, Nicoll AJ, McLaren CE, Bahl M, Nisselle AE, Vulpe CD, Anderson GJ, Southey MC, Giles GG, English DR, Hopper JL, Olynyk JK, Powell LW, Gertig DM.** Iron-overload-related disease in HFE hereditary hemochromatosis. *N Engl J Med* 2008; **358**: 221-230 [PMID: 18199861 DOI: 10.1056/NEJMoa073286]
- Powell LW, Dixon JL, Ramm GA, Purdie DM, Lincoln DJ, Anderson GJ, Subramaniam VN, Hewett DG, Searle JW, Fletcher LM, Crawford DH, Rodgers H, Allen KJ, Cavanaugh JA, Bassett ML.** Screening for hemochromatosis in asymptomatic subjects with or without a family history. *Arch Intern Med* 2006; **166**: 294-301 [PMID: 16476869 DOI: 10.1001/archinte.166.3.294]
- Beutler E, Felitti VJ, Koziol JA, Ho NJ, Gelbart T.** Penetrance of 845G->A (C282Y) HFE hereditary haemochromatosis mutation in the USA. *Lancet* 2002; **359**: 211-218 [PMID: 11812557 DOI: 10.1016/S0140-6736(02)07447-0]
- Han O.** Molecular mechanism of intestinal iron absorption. *Metallomics* 2011; **3**: 103-109 [PMID: 21210059 DOI: 10.1039/c0mt00043d]
- Bourdon E, Kang DK, Ghosh MC, Drake SK, Wey J, Levine RL, Rouault TA.** The role of endogenous heme synthesis and degradation domain cysteines in cellular iron-dependent degradation of IRP2. *Blood Cells Mol Dis* 2003; **31**: 247-255 [PMID: 12972033 DOI: 10.1016/S1079-9796(03)00161-X]
- Ganz T.** Systemic iron homeostasis. *Physiol Rev* 2013; **93**: 1721-1741 [PMID: 24137020 DOI: 10.1152/physrev.00008.2013]
- Lawen A, Lane DJ.** Mammalian iron homeostasis in health and disease: uptake, storage, transport, and molecular mechanisms of action. *Antioxid Redox Signal* 2013; **18**: 2473-2507 [PMID: 23199217 DOI: 10.1089/ars.2011.4271]
- Gunshin H, Mackenzie B, Berger UV, Gunshin Y, Romero MF, Boron WF, Nussberger S, Gollan JL, Hediger MA.** Cloning and characterization of a mammalian proton-coupled metal-ion transporter. *Nature* 1997; **388**: 482-488 [PMID: 9242408 DOI: 10.1038/41343]
- Bartnikas TB.** Known and potential roles of transferrin in iron biology. *Biometals* 2012; **25**: 677-686 [PMID: 22294463 DOI: 10.1007/s10534-012-9520-3]
- Ganz T, Nemeth E.** Hepcidin and iron homeostasis. *Biochim Biophys Acta* 2012; **1823**: 1434-1443 [PMID: 22306005 DOI: 10.1016/j.bbamer.2012.01.014]
- Khusainova RI, Khusnutdinova NN, Khusnutdinova EK.** [Analysis of the hemochromatosis gene (HFE) mutations, C282Y and H63D, in the populations of Central Asia]. *Genetika* 2006; **42**: 421-426 [PMID: 16649670]
- Hayashi H, Wakusawa S, Motonishi S, Miyamoto K, Okada H, Inagaki Y, Ikeda T.** Genetic background of primary iron overload syndromes in Japan. *Intern Med* 2006; **45**: 1107-1111 [PMID: 17106152 DOI: 10.2169/internalmedicine.45.1876]
- Lee JY, Yoo KH, Hahn SH.** HFE gene mutation, C282Y causing hereditary hemochromatosis in Caucasian is extremely rare in Korean population. *J Korean Med Sci* 2000; **15**: 179-182 [PMID: 10803694 DOI: 10.3346/jkms.2000.15.2.179]
- Pietrangelo A.** Hereditary hemochromatosis: pathogenesis, diagnosis, and treatment. *Gastroenterology* 2010; **139**: 393-408, 408.e1-2 [PMID: 20542038 DOI: 10.1053/j.gastro.2010.06.013]
- Fracanzani AL, Piperno A, Valenti L, Fraquelli M, Coletti S, Maraschi A, Consonni D, Coviello E, Conte D, Fargion S.** Hemochromatosis in Italy in the last 30 years: role of genetic and acquired factors. *Hepatology* 2010; **51**: 501-510 [PMID: 20101754 DOI: 10.1002/hep.23333]
- Bassett ML, Hickman PE, Dahlstrom JE.** The changing role of liver biopsy in diagnosis and management of haemochromatosis. *Pathology* 2011; **43**: 433-439 [PMID: 21716156 DOI: 10.1097/PAT.0b013e3283490e04]
- Kanwar P, Kowdley KV.** Diagnosis and treatment of hereditary hemochromatosis: an update. *Expert Rev Gastroenterol Hepatol* 2013; **7**: 517-530 [PMID: 23985001 DOI: 10.1586/17474124.2013.816114]
- Pietrangelo A.** Hereditary hemochromatosis--a new look at an old disease. *N Engl J Med* 2004; **350**: 2383-2397 [PMID: 15175440 DOI: 10.1056/NEJMra031573]
- Cadet E, Capron D, Perez AS, Crépin SN, Arlot S, Ducroix JP, Dautréaux M, Fardellone P, Leflon P, Merryweather-Clarke AT, Livesey KJ, Pointon JJ, Rose P, Harcourt J, Emery J, Sueur JM, Feyt R, Robson KJ, Rochette J.** A targeted approach significantly increases the identification rate of patients with undiagnosed haemochromatosis. *J Intern Med* 2003; **253**: 217-224 [PMID: 12542563 DOI: 10.1046/j.1365-2796.2003.01094.x]
- Swinkels DW, Aalbers N, Elving LD, Bleijenberg G, Swanink CM, van der Meer JW.** Primary haemochromatosis: a missed cause of chronic fatigue syndrome? *Neth J Med* 2002; **60**: 429-433 [PMID: 12685490]
- Adams PC, Deugnier Y, Moirand R, Brissot P.** The relationship

- between iron overload, clinical symptoms, and age in 410 patients with genetic hemochromatosis. *Hepatology* 1997; **25**: 162-166 [PMID: 8985284 DOI: 10.1002/hep.510250130]
- 28 **Niederau C**, Fischer R, Pürschel A, Stremmel W, Häussinger D, Strohmeyer G. Long-term survival in patients with hereditary hemochromatosis. *Gastroenterology* 1996; **110**: 1107-1119 [PMID: 8613000 DOI: 10.1053/gast.1996.v110.pm8613000]
  - 29 **Adams PC**, Reboussin DM, Barton JC, McLaren CE, Eckfeldt JH, McLaren GD, Dawkins FW, Acton RT, Harris EL, Gordeuk VR, Leiendecker-Foster C, Speechley M, Snively BM, Holup JL, Thomson E, Sholinsky P. Hemochromatosis and iron-overload screening in a racially diverse population. *N Engl J Med* 2005; **352**: 1769-1778 [PMID: 15858186 DOI: 10.1056/NEJMoa041534]
  - 30 **Bacon BR**, Olynyk JK, Brunt EM, Britton RS, Wolff RK. HFE genotype in patients with hemochromatosis and other liver diseases. *Ann Intern Med* 1999; **130**: 953-962 [PMID: 10383365 DOI: 10.7326/0003-4819-130-12-199906150-00002]
  - 31 **Timms AE**, Sathananthan R, Bradbury L, Athanasou NA, Wordsworth BP, Brown MA. Genetic testing for haemochromatosis in patients with chondrocalcinosis. *Ann Rheum Dis* 2002; **61**: 745-747 [PMID: 12117686 DOI: 10.1136/ard.61.8.745]
  - 32 **European Association For The Study Of The Liver**. EASL clinical practice guidelines for HFE hemochromatosis. *J Hepatol* 2010; **53**: 3-22 [PMID: 20471131 DOI: 10.1016/j.jhep.2010.03.001]
  - 33 **Harrison SA**, Bacon BR. Hereditary hemochromatosis: update for 2003. *J Hepatol* 2003; **38** Suppl 1: S14-S23 [PMID: 12591183 DOI: 10.1016/S0168-8278(02)00428-2]
  - 34 **McLaren CE**, Emond MJ, Subramaniam VN, Phatak PD, Barton JC, Adams PC, Goh JB, McDonald CJ, Powell LW, Gurrin LC, Allen KJ, Nickerson DA, Louie T, Ramm GA, Anderson GJ, McLaren GD. Exome sequencing in HFE C282Y homozygous men with extreme phenotypes identifies a GNPAT variant associated with severe iron overload. *Hepatology* 2015; **62**: 429-439 [PMID: 25605615 DOI: 10.1002/hep.27711]

**P- Reviewer:** Bardou-Jacquet E, Castro JA, Musci G  
**S- Editor:** Qiu S **L- Editor:** A **E- Editor:** Liu SQ



Basic Study

# Role of interleukin-1 and its antagonism of hepatic stellate cell proliferation and liver fibrosis in the Abcb4<sup>-/-</sup> mouse model

Florian P Reiter, Ralf Wimmer, Lena Wottke, Renate Artmann, Jutta M Nagel, Manuel O Carranza, Doris Mayr, Christian Rust, Peter Fickert, Michael Trauner, Alexander L Gerbes, Simon Hohenester, Gerald U Denk

Florian P Reiter, Ralf Wimmer, Lena Wottke, Renate Artmann, Jutta M Nagel, Alexander L Gerbes, Simon Hohenester, Gerald U Denk, Department of Medicine II, Liver Center Munich, University of Munich, D-81377 Munich, Germany

Manuel O Carranza, Doris Mayr, Institute of Pathology, University of Munich, D-80337 Munich, Germany

Christian Rust, Department of Medicine I, Krankenhaus Barmherzige Brüder, D-80639 Munich, Germany

Peter Fickert, Research Unit for Experimental and Molecular Hepatology, Division of Gastroenterology and Hepatology, Department of Internal Medicine, A-8036 Graz, Austria

Michael Trauner, Hans Popper Laboratory of Molecular Hepatology, Division of Gastroenterology and Hepatology, Department of Internal Medicine III, Medical University of Vienna, A-1090 Vienna, Austria

Gerald U Denk, Transplant Center Munich of the University of Munich, D-81377 Munich, Germany

**Author contributions:** Reiter FP, Wimmer R, Rust C, Fickert P, Trauner M, Gerbes AL, Hohenester S and Denk GU designed the research; Wimmer R, Nagel JM, Wottke L and Artmann R performed the experiments; Carranza MO and Mayr D performed the histological examinations and imaging; Reiter FP, Wimmer R, Hohenester S and Denk GU analysed the data; Reiter FP, Hohenester S and Denk GU prepared the manuscript; all of the authors discussed and approved the manuscript.

**Supported by** The Münchener Medizinische Wochenschrift (MMW); B. Braun-Stiftung (to Reiter FP); the Deutsche Forschungsgemeinschaft (HO 4460/2-1 to Hohenester S and RU 742/6-1 to Rust C).

**Institutional review board statement:** This study includes no data or material from patients. We confirm that all of the required permissions for this study were obtained from our local authorities as mentioned in the Institutional animal care and use

committee statement.

**Institutional animal care and use committee statement:** We confirm that the animals for our studies were kept according to the local regulations. All procedures involving animals were reviewed and approved by the Institutional Animal Care and Use Committee of the Regierung von Oberbayern; protocol number No.: 55.2.1.54-2532-104-11. All of the institutional and national guidelines for the care and use of laboratory animals were followed.

**Conflict-of-interest statement:** All of the authors declare that they have no conflict of interest.

**Data sharing statement:** The technical appendix, statistical code, and dataset are available from the corresponding author at [florian.reiter@med.uni-muenchen.de](mailto:florian.reiter@med.uni-muenchen.de).

**Open-Access:** This article is an open-access article which was selected by an in-house editor and fully peer-reviewed by external reviewers. It is distributed in accordance with the Creative Commons Attribution Non Commercial (CC BY-NC 4.0) license, which permits others to distribute, remix, adapt, build upon this work non-commercially, and license their derivative works on different terms, provided the original work is properly cited and the use is non-commercial. See: <http://creativecommons.org/licenses/by-nc/4.0/>

**Correspondence to:** Florian P Reiter, MD, Department of Medicine II, Liver Center Munich, University of Munich, Marchioninstr. 15, D-81377 Munich, Germany. [florian.reiter@med.uni-muenchen.de](mailto:florian.reiter@med.uni-muenchen.de)  
Telephone: +49-89-440073129  
Fax: +49-89-440078864

**Received:** June 11, 2015

**Peer-review started:** June 11, 2015

**First decision:** September 18, 2015

**Revised:** January 7, 2016

**Accepted:** March 7, 2016

**Article in press:** March 9, 2016

**Published online:** March 18, 2016



## Abstract

**AIM:** To study the interleukin-1 (IL-1) pathway as a therapeutic target for liver fibrosis *in vitro* and *in vivo* using the ATP-binding cassette transporter b4<sup>-/-</sup> (Abcb4<sup>-/-</sup>) mouse model.

**METHODS:** Female and male Abcb4<sup>-/-</sup> mice from 6 to 13 mo of age were analysed for the degree of cholestasis (liver serum tests), extent of liver fibrosis (hydroxyproline content and Sirius red staining) and tissue-specific activation of signalling pathways such as the IL-1 pathway [quantitative polymerase chain reaction (qPCR)]. For *in vivo* experiments, murine hepatic stellate cells (HSCs) were isolated *via* pronase-collagenase perfusion followed by density gradient centrifugation using female mice. Murine HSCs were stimulated with up to 1 ng/mL IL-1 $\beta$  with or without 2.5  $\mu$ g/mL Anakinra, an IL-1 receptor antagonist, respectively. The proliferation of murine HSCs was assessed *via* the BrdU assay. The toxicity of Anakinra was evaluated *via* the fluorescein diacetate hydrolysis (FDH) assay. *In vivo* 8-wk-old Abcb4<sup>-/-</sup> mice with an already fully established hepatic phenotype were treated with Anakinra (1 mg/kg body-weight daily intraperitoneally) or vehicle and liver injury and liver fibrosis were evaluated *via* serum tests, qPCR, hydroxyproline content and Sirius red staining.

**RESULTS:** Liver fibrosis was less pronounced in males than in female Abcb4<sup>-/-</sup> animals as defined by a lower hydroxyproline content (274  $\pm$  64  $\mu$ g/g *vs* 436  $\pm$  80  $\mu$ g/g liver, respectively;  $n$  = 13-15;  $P$  < 0.001; Mann-Whitney  $U$ -test) and lower mRNA expression of the profibrogenic tissue inhibitor of metalloproteinase-1 (TIMP) (1  $\pm$  0.41 *vs* 0.66  $\pm$  0.33 fold, respectively;  $n$  = 13-15;  $P$  < 0.05; Mann-Whitney  $U$ -test). Reduced liver fibrosis was associated with significantly lower levels of F4/80 mRNA expression (1  $\pm$  0.28 *vs* 0.71  $\pm$  0.41 fold, respectively;  $n$  = 12-15;  $P$  < 0.05; Mann-Whitney  $U$ -test) and significantly lower IL-1 $\beta$  mRNA expression levels (1  $\pm$  0.38 *vs* 0.44  $\pm$  0.26 fold, respectively;  $n$  = 13-15;  $P$  < 0.001; Mann-Whitney  $U$ -test). No gender differences in the serum liver parameters [bilirubin; alanine aminotransferase (ALT); aspartate aminotransferase and alkaline phosphatase (AP)] were found. *In vitro*, the administration of IL-1 $\beta$  resulted in a significant increase in HSC proliferation [0.94  $\pm$  0.72 arbitrary units (A.U.) in untreated controls, 1.12  $\pm$  0.80 A.U. at an IL-1 $\beta$  concentration of 0.1 ng/mL and 1.18  $\pm$  0.73 A.U. at an IL-1 $\beta$  concentration of 1 ng/mL in samples from  $n$  = 6 donor animals;  $P$  < 0.001; analyses of variance (ANOVA)]. Proliferation was reduced significantly by the addition of 2.5  $\mu$ g/mL Anakinra (0.81  $\pm$  0.60 A.U. in untreated controls, 0.92  $\pm$  0.68 A.U. at an IL-1 $\beta$  concentration of 0.1 ng/mL, and 0.91  $\pm$  0.69 A.U. at an IL-1 $\beta$  concentration of 1 ng/mL; in samples from  $n$  = 6 donor animals;  $P$  < 0.001; ANOVA) suggesting an anti-proliferative effect of this clinically approved IL-1 receptor antagonist. The FDH assay showed this dose to be non-toxic in HSCs. *In vivo*, Anakinra had no effect on the hepatic hydroxyproline

content, liver serum tests (ALT and AP) and pro-fibrotic (collagen 1 $\alpha$ 1, collagen 1 $\alpha$ 2, transforming growth factor- $\beta$ , and TIMP-1) and anti-fibrotic [matrix metalloproteinase 2 (MMP2), MMP9 and MMP13] gene expression after 4 wk of treatment. Furthermore, the hepatic IL-1 $\beta$  and F4/80 mRNA expression levels were unaffected by Anakinra treatment.

**CONCLUSION:** IL-1 $\beta$  expression is associated with the degree of liver fibrosis in Abcb4<sup>-/-</sup> mice and promotes HSC proliferation. IL-1 antagonism shows antifibrotic effects *in vitro* but not in Abcb4<sup>-/-</sup> mice.

**Key words:** Cholestasis; Primary sclerosing cholangitis; The ATP-binding cassette transporter b4; Liver fibrosis; Interleukin-1

© **The Author(s) 2016.** Published by Baishideng Publishing Group Inc. All rights reserved.

**Core tip:** Interleukin-1 (IL-1) critically participates in hepatic stellate cells (HSCs) pathophysiology and in the progression of liver injury to fibrosis. We found that fibrosis was more pronounced in female than in male ATP-binding cassette transporter b4<sup>-/-</sup> animals. This fibrosis was associated with higher IL-1 $\beta$  mRNA expression levels. We showed that IL-1 $\beta$  promoted the proliferation of murine HSCs and described an antifibrotic effect of the clinically approved IL-1 receptor antagonist Anakinra *in vitro*. Despite the promising antifibrotic effects *in vitro*, Anakinra failed to improve liver fibrosis in this preclinical primary sclerosing cholangitis model. Its potency in other models of liver injury and fibrosis remains to be determined.

Reiter FP, Wimmer R, Wottke L, Artmann R, Nagel JM, Carranza MO, Mayr D, Rust C, Fickert P, Trauner M, Gerbes AL, Hohenester S, Denk GU. Role of interleukin-1 and its antagonism of hepatic stellate cell proliferation and liver fibrosis in the Abcb4<sup>-/-</sup> mouse model. *World J Hepatol* 2016; 8(8): 401-410 Available from: URL: <http://www.wjgnet.com/1948-5182/full/v8/i8/401.htm> DOI: <http://dx.doi.org/10.4254/wjh.v8.i8.401>

## INTRODUCTION

Primary sclerosing cholangitis (PSC) is a chronic cholestatic liver disease that is characterised by obliterative strictures of the intra- and extra-hepatic bile ducts. Because these strictures are associated with inflammation and fibrosis, PSC is supposed to be an immune-mediated liver disease. PSC primarily occurs in young adults and leads to liver cirrhosis with hepatic decompensation and portal hypertension and is frequently associated with malignancy of the biliary tract<sup>[1,2]</sup>. To date, there is no effective therapeutic option to halt disease progression. Thus, liver transplantation in end-stage liver disease is often required. The estimated median time for transplant-free survival may be as

short as 12 to 13 years at tertiary referral centres<sup>[1,3]</sup>. Therefore, new therapeutic targets need to be identified to establish an urgently required effective therapy for PSC.

PSC mainly affects the large bile ducts and causes periductal fibrosis<sup>[4]</sup>. This leads to obliteration of the bile ducts, resulting in impaired bile flow and cholestasis. During chronic cholestatic disease, toxic bile acids accumulate<sup>[5]</sup> and induce cholangio- and hepatocellular apoptosis by specific signalling pathways<sup>[6-8]</sup>. The clinical significance of cholangiocellular and hepatocellular apoptosis in patients with chronic cholestatic disease was recently supported by the detection of serum markers of liver cell apoptosis<sup>[9]</sup>.

Hepatocellular apoptosis is considered a trigger of liver fibrosis *via* the activation of hepatic stellate cells (HSCs)<sup>[10,11]</sup>. This results in the progression to liver fibrosis and cirrhosis in PSC.

HSCs are the major source of hepatic extracellular matrix deposition and crucially participate in the pathogenesis of liver fibrosis<sup>[12-14]</sup>. In addition to other factors, enhanced proliferation of this cell type is thought to be an important profibrotic mechanism<sup>[14]</sup>. In this regard, a recent study found that interleukin-1 $\beta$  (IL-1 $\beta$ ) induces the proliferation of rat HSCs<sup>[15]</sup>. Furthermore, IL-1 was identified as a factor in the progression of liver injury to fibrosis<sup>[16]</sup>. Therefore, we hypothesised that blocking the IL-1 pathway during liver fibrosis might be a therapeutic approach in chronic liver disease.

Anakinra is a clinically approved IL-1 receptor antagonist that is listed for the treatment of rheumatoid arthritis by the European Medicines Agency and the United States Food and Drug Administration. Its implication for the treatment of chronic liver disease and fibrosis has not been investigated thus far.

The ATP-binding cassette transporter b4<sup>-/-</sup> (Abcb4<sup>-/-</sup>) mouse is an established preclinical model for biliary fibrosis and PSC<sup>[17-19]</sup>. Therefore, this model is widely used to study therapeutic strategies for biliary fibrosis and PSC *in vivo*<sup>[20]</sup>.

Here, we tested the proliferative and pro-fibrotic properties of the IL-1 pathway *in vitro*, analysed its contribution to liver fibrosis in the Abcb4<sup>-/-</sup> model *in vivo* and tested the potential protective effects of the clinically approved IL-1 receptor antagonist Anakinra on the development of liver injury and fibrosis in this animal model.

## MATERIALS AND METHODS

### Animals

Animals were obtained from the Jackson Laboratory (United States) and Charles River (Germany). The animal protocol was designed to minimise pain or discomfort to the animals. The animals were housed at a 12/12 h light/dark cycle and were fed *ad libitum*. The animals were kept according to local regulations. The experiments were approved by local authorities. All

ethical, institutional and national guidelines for the care and use of laboratory animals were followed.

### Isolation and culture of primary murine HSCs

The isolation of primary murine HSC from female C57BL/6N wild-type animals was performed by pronase-collagenase perfusion followed by density gradient centrifugation in 13.2% Nycodenz<sup>®</sup> (Axis-Shield PoC, Norway)<sup>[21]</sup>. The cells were plated at a density of 25000 cells/cm<sup>2</sup>. The cells were kept in DMEM containing 10% fetal bovine serum and antibiotics (Sigma, Germany) in a humidified atmosphere with 5% CO<sub>2</sub> and 21% O<sub>2</sub> at 37 °C.

### Toxicity assay

To investigate the potential toxic effects of Anakinra on murine HSCs, we performed the fluorescein diacetate hydrolysis (FDH) assay according to the method of Jones *et al.*<sup>[22]</sup> after stimulation of murine HSCs for 24 h with 25 pg/mL to 2.5  $\mu$ g/mL Anakinra.

### Proliferation assay

The cells were stimulated with vehicle, 0.1 and 1 ng/mL IL-1 $\beta$  for 24 h at day three after isolation. Where indicated, the cells were co-incubated with 2.5  $\mu$ g/mL Anakinra. The proliferation of primary murine HSCs was measured using a BrdU-assay kit (Roche, Germany) according to the manufacturer's instructions.

### In vivo experiments

Available material from female and male Abcb4<sup>-/-</sup> mice was kindly provided by the Research Unit for Experimental and Molecular Hepatology, Graz, Austria (Fickert P and Trauner M). The material from 6- to 13-mo-old animals was studied.

Eight-week old female Abcb4<sup>-/-</sup> (FVB) mice received daily intraperitoneally injections of Anakinra (1 mg/kg body-weight, a dosage used previously for animal studies, corresponding to the recommended dose for the treatment of rheumatoid arthritis<sup>[23]</sup> or NaCl 0.9% as a control for 4 wk, a time period previously shown to be sufficient to identify the modulation of liver fibrosis in this model<sup>[20]</sup>. After narcotisation with isoflurane (Abbott GmbH, Germany), the animals were sacrificed by cervical dislocation.

### Quantitative real-time polymerase chain reaction

Quantitative real-time polymerase chain reaction was performed using a Sybr<sup>®</sup> green system. Glyceraldehyde-3-phosphate dehydrogenase or 18 s were used as housekeeping genes and were normalised against the means of the controls.

### Serum biochemistry

The levels of bilirubin, alkaline phosphatase (AP), aspartate aminotransferase (AST), and alanine aminotransferase (ALT) were analysed using the Cobas Integra 800 analyser (Roche Diagnostics, Germany) or the

Hitachi 917 analyser (Boehringer Mannheim, Germany).

### Quantification of hydroxyproline

The hydroxyproline content was determined according to the method of Edwards *et al.*<sup>[24]</sup>.

### Sirius-red staining

Liver samples were fixed using 4% formaldehyde. After embedding in paraffin, 4- $\mu$ m sections were stained with Sirius red.

### Immunohistochemistry

Ki-67 immunohistochemistry was performed using the polyclonal rabbit anti-Ki-67 antibody (Novocastra, Germany). The ABC system with AEC as a substrate was used for the detection of antibody antigen binding. The number of positively stained cells was counted per mouse in 20 randomly chosen fields at 40-fold magnification.

### Statistical analysis

Statistical calculations were performed using the SPSS 23 software package (IBM, United States). Where appropriate, the differences between groups were verified by the Mann-Whitney *U*-test.

Where appropriate, the analyses of variance (ANOVA) were calculated with the procedure UNIANOVA. The normality and homogeneity of the variances of the residuals were assessed by inspection of residual plots from the UNIANOVA procedure and P-P plots. Furthermore, Levene's test was used to assess the equality of error variances (for details, see also supplemental material). The results are reported as the means  $\pm$  SD. *P*-values less than 0.05 were considered to be statistically significant. The statistical analysis of this study was supported and reviewed by Christoph Glasmacher (Christoph Glasmacher - Biometrics and SAS-Programming for Clinical Research).

## RESULTS

### Gender differences in the liver disease of *Abcb4*<sup>-/-</sup> mice

Hepatic injury and liver fibrosis were evaluated in male and female *Abcb4*<sup>-/-</sup> animals from 6 to 13 mo of age. We found that the hepatic hydroxyproline levels were 37% lower in male animals than in female animals (Figure 1A; 274  $\pm$  64  $\mu$ g/g vs 436  $\pm$  80  $\mu$ g/g liver, respectively; *n* = 13-15; *P* < 0.001; Mann-Whitney *U*-test). Sirius red staining illustrated reduced collagen deposition in male animals (Figure 1B). In accordance with these findings, the livers of male animals showed 34% lower tissue inhibitor of metalloproteinase (TIMP-1) mRNA expression (Figure 1C; 1  $\pm$  0.41 vs 0.66  $\pm$  0.33 fold; *n* = 13-15; *P* < 0.05; Mann-Whitney *U*-test).

The mRNA expression of IL-1 $\beta$  and F4/80 as markers of hepatic-inflammation was 56% (Figure 1C; 1  $\pm$  0.38 vs 0.44  $\pm$  0.26 fold; *n* = 13-15; *P* < 0.001; Mann-Whitney *U*-test) and 29% lower (Figure 1C; 1  $\pm$  0.28 vs 0.71  $\pm$  0.41 fold; *n* = 12-15; *P* < 0.05; Mann-Whitney *U*-test) in the liver tissue of male animals than in the

liver tissue of female animals.

No gender differences were observed regarding the hepatic mRNA expression of collagen 1 $\alpha$ 1, cytokeratin 19 and monocyte chemotactic protein-1; *n* = 13-15; Mann-Whitney *U*-test).

Additionally, no gender differences in serum biochemistry were observed regarding the bilirubin, ALT, AST, and AP levels (data not shown; *n* = 17-21; Mann-Whitney *U*-test). Furthermore, there were no sex differences regarding hepatic mitotic activity in Ki-67 immunohistochemistry (data not shown; *n* = 15; Mann-Whitney *U*-test).

In summary, we identified a lower grade of liver fibrosis in male than in female animals as illustrated by lower hydroxyproline levels and lower hepatic mRNA expression levels of the profibrogenic gene TIMP-1. Furthermore, lower fibrosis in male animals was associated with the reduced mRNA expression of the pro-inflammatory genes IL-1 $\beta$  and F4/80. These findings may support a potential role of the IL-1 pathway in the progression of liver injury to liver fibrosis.

### IL-1 $\beta$ exerts proliferative effects in murine HSCs, while proliferation is reduced by the IL-1 receptor antagonist Anakinra *in vitro*

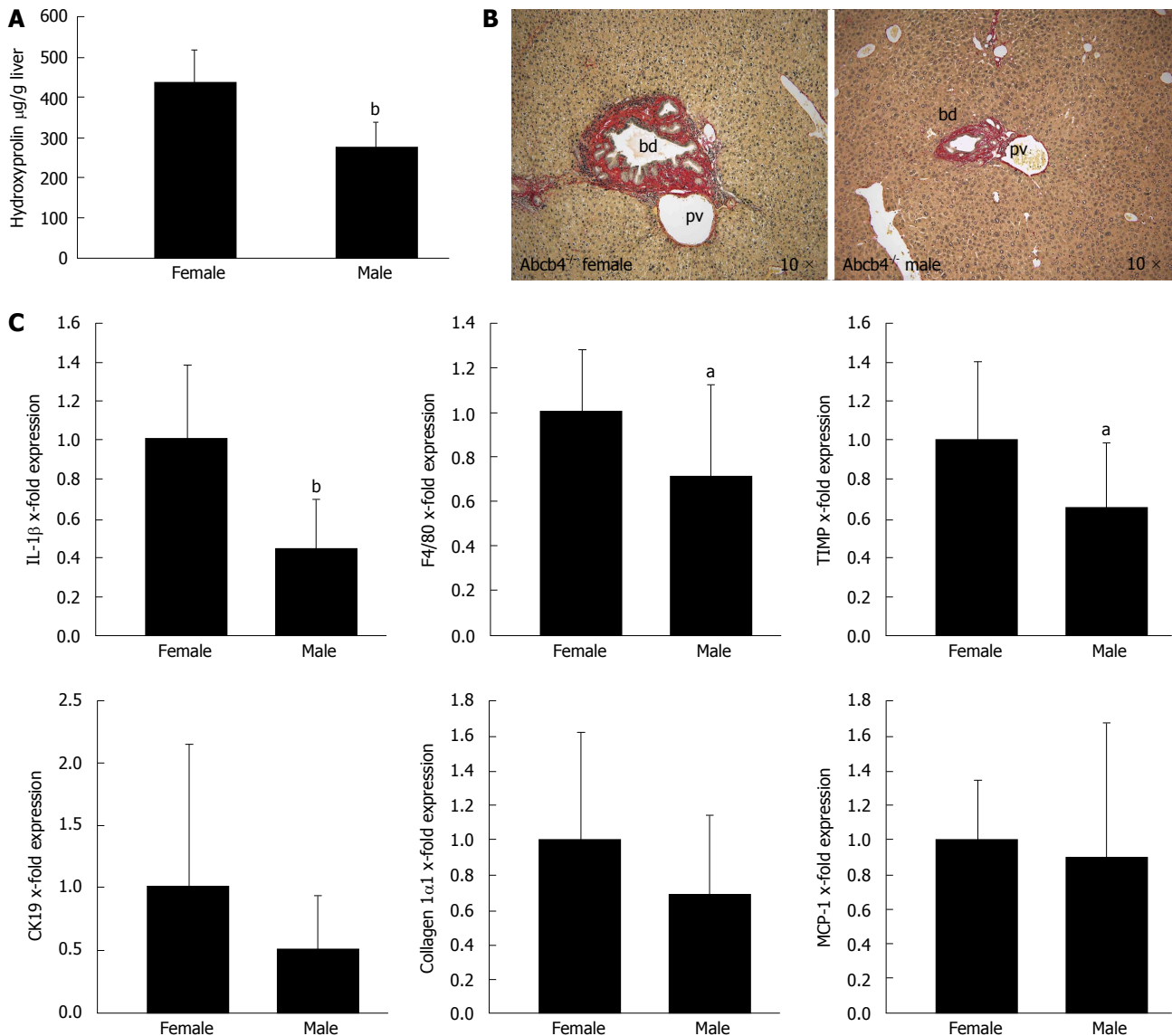
The importance of IL-1 $\beta$  in stellate cell proliferation was reported previously<sup>[15]</sup>. This work implicates inhibition of the IL-1 pathway as a potential target in the treatment of liver fibrosis. However, blockade of this target by the clinically available IL-1 receptor antagonist Anakinra has not been tested yet regarding HSC pathophysiology and liver fibrosis.

We addressed our *in vitro* experiments to investigate whether Anakinra could inhibit IL-1 $\beta$ -induced HSC proliferation.

In a first step, we evaluated the possible toxicity of Anakinra in primary murine HSCs using the FDH assay. This revealed no toxic effects of Anakinra at the tested doses, including the chosen dose of 2.5  $\mu$ g/mL (data not shown, *n* = 3).

Furthermore, we observed that IL-1 $\beta$  increased the proliferation of murine HSCs [Figure 2A; 0.94  $\pm$  0.72 (arbitrary units) A.U. in untreated controls, 1.12  $\pm$  0.80 A.U. at an IL-1 $\beta$  concentration of 0.1 ng/mL and 1.18  $\pm$  0.73 A.U. at an IL-1 $\beta$  concentration of 1 ng/mL in samples from *n* = 6 donor animals; general effect of IL-1 $\beta$  stimulation *P* < 0.001; control vs 0.1 ng/mL IL-1 $\beta$  *P* < 0.01; control vs 1 ng/mL IL-1 $\beta$  *P* < 0.001; ANOVA]. Due to the sufficient induction of HSC proliferation by IL-1 $\beta$ , the toxicity assay was not required for IL-1 $\beta$ .

Proliferation of murine HSCs was reduced significantly by treatment with 2.5  $\mu$ g/mL Anakinra (Figure 2B; 0.81  $\pm$  0.60 A.U. in untreated controls, 0.92  $\pm$  0.68 A.U. at an IL-1 $\beta$  concentration of 0.1 ng/mL, and 0.91  $\pm$  0.69 A.U. at an IL-1 $\beta$  concentration of 1 ng/mL; in sample from *n* = 6 donor animals; general effect of Anakinra: *P* < 0.001; effect of Anakinra without IL-1 $\beta$  stimulation: *P* < 0.01; effect of Anakinra with 0.1 ng/mL IL-1 $\beta$  stimulation: *P* < 0.01; effect of Anakinra with 1.0



**Figure 1** Gender differences in liver disease in ATP-binding cassette transporter *b4*<sup>-/-</sup> mice. Gender differences in liver fibrosis and liver inflammation were assessed with hydroxyproline measurement, Sirius red staining and quantitative real-time PCR in male and female *Abcb4*<sup>-/-</sup> mice between 6 and 13 mo of age. **A:** The hepatic hydroxyproline content of liver homogenates ( $\mu\text{g/g}$  liver) was lower in male animals than in female animals ( $n = 13-15$ ; <sup>b</sup> $P < 0.001$ ; Mann-Whitney *U*-test); **B:** Sirius-red staining illustrates the gender differences regarding fibrosis in *Abcb4*<sup>-/-</sup> mice. Images were taken from 9- to 10-mo-old animals (original magnification, 10 $\times$ ; bd: bile duct; pv: portal vein); **C:** Gene expression was assessed via quantitative real-time PCR and was normalised for 18 s as a housekeeping gene. Expressions were normalised against the means of female mice. The hepatic IL-1 $\beta$  and F4/80 mRNA expression levels as markers for hepatic inflammation were significantly lower in male *Abcb4*<sup>-/-</sup> mice than in female animals ( $n = 12-15$ ; <sup>b</sup> $P < 0.001$ ; <sup>a</sup> $P < 0.05$ ; Mann-Whitney *U*-test). The mRNA expression levels of the profibrotic gene TIMP-1 were also significantly lower in male *Abcb4*<sup>-/-</sup> mice than in female *Abcb4*<sup>-/-</sup> mice ( $n = 13-15$ ; <sup>a</sup> $P < 0.05$ ; Mann-Whitney *U*-test). PCR: Polymerase chain reaction; TIMP-1: Tissue inhibitor of metalloproteinase-1; *Abcb4*<sup>-/-</sup>: ATP-binding cassette transporter *b4*<sup>-/-</sup>; IL-1: Interleukin-1; CK19: Cytokeratin 19; MCP-1: Monocyte chemotactic protein-1.

ng/mL IL-1 $\beta$  stimulation:  $P < 0.001$ ; ANOVA), indicating a therapeutic effect of Anakinra on the proliferation of murine HSCs and, thereby, on liver fibrosis.

Taken together, Anakinra revealed promising anti-fibrotic effects *in vitro*.

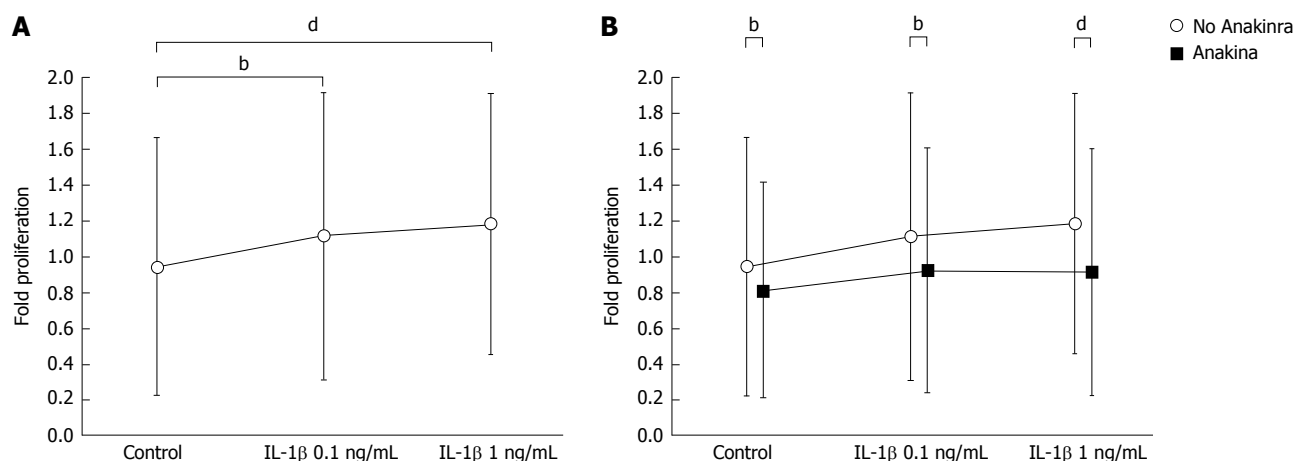
#### Anakinra has no therapeutic effects in *Abcb4*<sup>-/-</sup> mice

The association of the degree of liver fibrosis and IL-1 $\beta$  expression in *Abcb4*<sup>-/-</sup> mice together with our *in vitro* data suggest a therapeutic effect of IL-1 antagonism on liver fibrosis *in vivo*. Therefore, we tested the therapeutic effects of Anakinra, a clinically approved

IL-1 receptor antagonist, on biliary fibrosis and hepatic injury in female *Abcb4*<sup>-/-</sup> mice.

The hepatic hydroxyproline levels as a marker of liver fibrosis were lower in untreated Wt animals than in untreated *Abcb4*<sup>-/-</sup> mice (Figure 3A;  $n = 11$ ;  $82 \pm 30 \mu\text{g/g}$  vs  $227 \pm 55 \mu\text{g/g}$  liver;  $P < 0.01$ ; Mann-Whitney *U*-test) but were unaffected by Anakinra treatment (Figure 3A;  $n = 10-11$ ; Mann-Whitney *U*-test). In accordance with this, we found differences regarding the serum parameters ALT (Figure 3A;  $89 \pm 87 \text{ U/L}$  vs  $454 \pm 133 \text{ U/L}$ ;  $n = 8-10$ ;  $P < 0.01$ ; Mann-Whitney *U*-test) and AP (Figure 3A;  $92 \pm 17 \text{ U/L}$  vs  $530 \pm 133 \text{ U/L}$ ;  $n$





**Figure 2** Interleukin-1 $\beta$  exerts proliferative effects in primary murine hepatic stellate cells, while Anakinra reduces hepatic stellate cell proliferation *in vitro*. The effects of IL-1 $\beta$   $\pm$  the IL-1 receptor antagonist Anakinra on the proliferation of murine HSCs were tested *in vitro*. A and B: The effects on HSC proliferation were examined using the BrdU assay after stimulation of cells with vehicle, and IL-1 $\beta$  at 0.1 and 1 ng/mL in the presence and absence of Anakinra (2.5  $\mu$ g/mL), respectively (samples from  $n = 6$  donor animals, <sup>b</sup> $P < 0.01$ ; <sup>d</sup> $P < 0.001$ ; ANOVA). HSC: Hepatic stellate cells; IL-1: Interleukin-1; ANOVA: Analyses of variance.

= 8-10;  $P < 0.01$ ; Mann-Whitney  $U$ -test) between the untreated Wt animals and Abcb4<sup>-/-</sup> mice but no effects of the treatment with Anakinra were observed (Figure 3A;  $n = 10-11$ ; Mann-Whitney  $U$ -test).

In a next step, we performed genetic profiling of fibrosis-related genes. Here, we found no influence of Anakinra on the profile of the profibrotic genes collagen 1 $\alpha$ 1, collagen 1 $\alpha$ 2, tissue growth factor- $\beta$ , and TIMP-1 (Figure 3B;  $n = 10-11$ ; Mann-Whitney  $U$ -test) between the groups.

In line with this finding, Anakinra treatment did not influence the expression of genes encoding the matrix-degrading enzymes matrix metalloproteinases 2, 9, and 13 (Figure 3C;  $n = 10-11$ ; Mann-Whitney  $U$ -test).

The mRNA expression levels of IL-1 $\beta$  and F4/80 as indicators of hepatic inflammation were also unaffected by Anakinra treatment (Figure 3D;  $n = 10-11$ ; Mann-Whitney  $U$ -test).

These missing antifibrotic effects were illustrated by Sirius red staining revealing no differences regarding periportal fibrosis (Figure 3E).

In summary, the *in vivo* administration of Anakinra showed no therapeutic effects on established fibrosis and hepatic injury in Abcb4<sup>-/-</sup> mice.

## DISCUSSION

Few treatment options are available to prevent disease progression to liver fibrosis and cirrhosis in chronic cholestatic liver disease such as PSC. In PSC, the frequently applied bile acid ursodeoxycholic acid (UDCA) failed to demonstrate a positive effect on the clinical outcome<sup>[25]</sup>, despite the beneficial effects of UDCA on serum biochemistry. Consequently, the American Association for the Study of Liver Disease no longer recommends the use of UDCA in PSC<sup>[2]</sup>. The loss of this therapeutic hope aggravates the need for an effective drug to treat PSC.

In the present study, we identified differences in

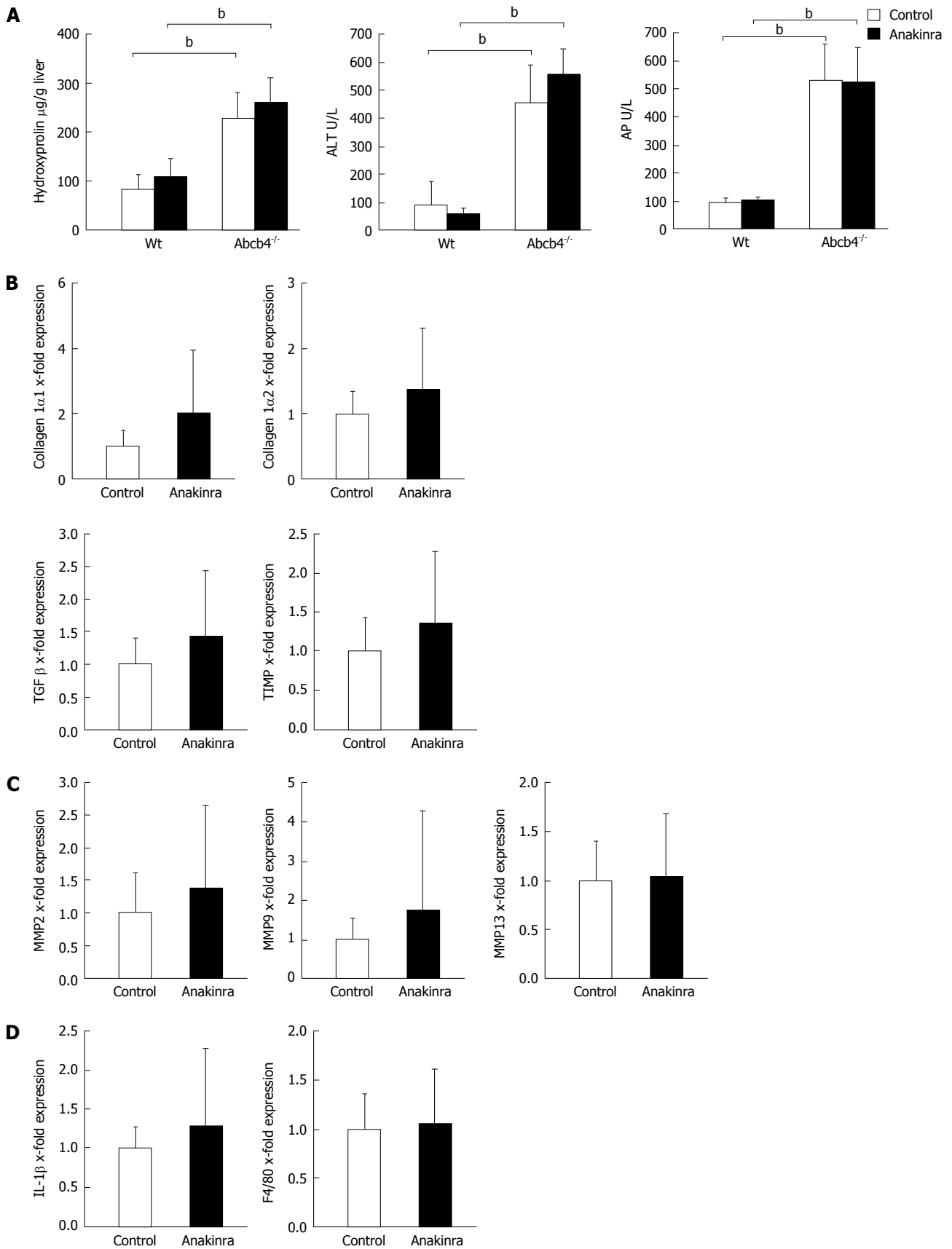
the levels of hepatic fibrosis between female and male Abcb4<sup>-/-</sup> mice. Hepatic fibrosis was more aggravated in female mice as assessed by the determination of the liver hydroxyproline content, a finding that is in line with that of previous studies, which identified a more severe histological phenotype in female animals<sup>[26]</sup>. Here, the pronounced phenotype in females was accompanied by higher mRNA expression levels of IL-1 $\beta$ , F4/80, and TIMP-1.

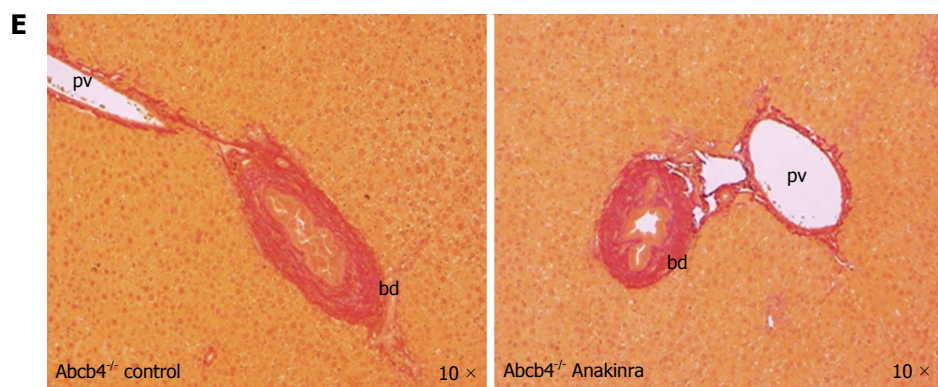
TIMP is a well-known profibrotic player in the regulation of matrix degradation during fibrogenesis and resolution *via* the inhibition of matrix metalloproteinases<sup>[27]</sup> but also *via* its anti-apoptotic effects on hepatic myofibroblasts<sup>[28,29]</sup>.

Therefore, the different TIMP levels might be a crucial factor for the observed gender differences in the degree of fibrosis. Hepatic inflammation, the role of chemokines, cytokines<sup>[30]</sup> and macrophages in the context of liver fibrosis are broadly discussed<sup>[31]</sup>. Macrophages may produce a wide spectrum of cytokines, including IL-1 $\beta$ , which are relevant for the pro-fibrogenic nature of HSCs<sup>[31-33]</sup>. Therefore, we hypothesised that the higher degree of fibrosis in female Abcb4<sup>-/-</sup> mice may be related to a more pronounced IL-1-driven hepatic inflammation and that the observed TIMP-1 alterations could reflect a consequence of inflammation. Thus, the IL-1 pathway might be a potential therapeutic target in PSC and fibrosis.

Supporting our hypothesis, we found that IL-1 $\beta$  stimulation exerts proliferative effects also on murine HSCs. These findings are in accordance with previously published data in rat HSCs<sup>[15]</sup>. Subsequently, we showed that the HSC proliferation was reduced by applying the clinically approved IL-1 receptor antagonist Anakinra. Because the proliferation of HSCs is a trigger of hepatic fibrosis<sup>[14]</sup>, these effects might be of consequence for disease progression *in vivo*.

In light of recently published data showing that IL-1 receptor antagonism ameliorates inflammasome-





**Figure 3** Anakinra does not reveal therapeutic effects on liver injury in ATP-binding cassette transporter b4<sup>-/-</sup> mice. Eight-week-old female Abcb4<sup>-/-</sup> animals were treated with daily intraperitoneal injections of saline (control) as vehicle or Anakinra (1 mg/kg body-weight) for 4 wk. A: The levels of hepatic hydroxyproline, alanine aminotransferase (ALT), and alkaline phosphatase (AP) were determined as described previously ( $n = 8-11$ ,  $^bP < 0.01$ ; Mann-Whitney *U*-test). Gene expression was assessed via quantitative real-time PCR using glyceraldehyde-3-phosphate dehydrogenase as the housekeeping gene. Data were normalised against the means of the controls (saline); B: No alterations in the profibrotic genes were found [ $n = 10-11$ ; not significant (n.s.); Mann-Whitney *U*-test]; C: No alterations in the antifibrotic genes were found ( $n = 10-11$ ; n.s.; Mann-Whitney *U*-test); D: Anakinra treatment did not result in a significant change in the mRNA expression of the pro-inflammatory gene IL-1 $\beta$  or F4/80 ( $n = 10-11$ , n.s., Mann-Whitney *U*-test); E: The Sirius-red staining illustrates the absence of antifibrotic effects (original magnification 10  $\times$ ). bd: Bile duct; pv: Portal-vein; PCR: Polymerase chain reaction; TIMP: Tissue inhibitor of metalloproteinase; Abcb4<sup>-/-</sup>: ATP-binding cassette transporter b4<sup>-/-</sup>; IL: Interleukin; MMP: Matrix metalloproteinase; TGF: Transforming growth factor.

dependent alcoholic steatohepatitis in mice<sup>[34]</sup>, our *in vitro* findings led us to test the efficacy of medical IL-1 receptor antagonism to prevent liver damage and fibrosis in the Abcb4<sup>-/-</sup> model.

We applied Anakinra at an established dose (1 mg/kg body-weight)<sup>[23]</sup> for 4 wk. This time span has been established to be sufficient to detect the therapeutic effects in the Abcb4<sup>-/-</sup> model<sup>[20,35]</sup>.

However, in the chosen setting, we found no effects on hepatic injury and fibrosis in this study. The serum markers of liver damage and cholestasis, as well as the analysis of liver tissue for fibrotic reaction, were unchanged.

This might be due to the distinctive pathophysiology of fibrosis in the Abcb4<sup>-/-</sup> model. The absence of phospholipids in Abcb4<sup>-/-</sup> mice results in a "toxic bile" constitution that leads to hepatic injury with scarring and obstruction of the biliary tree, finally causing cholestasis<sup>[36]</sup>. It is thought that portal myofibroblasts are primarily affected by the regurgitation of bile in this model<sup>[18]</sup>. These cells seem to rapidly acquire an activated phenotype in the early stages of biliary fibrosis<sup>[37]</sup> and might be the primary effectors of periportal fibrosis, which is the main type of fibrosis in the Abcb4<sup>-/-</sup> mouse<sup>[17,18]</sup>. This is also reflected by the previously observed increasing number in  $\alpha$ -SMA-positive cells per portal field of Abcb4<sup>-/-</sup> over time<sup>[18]</sup>. Our *in vitro* studies revealed the effects on HSCs, possibly might have different characteristics than portal myofibroblasts<sup>[37]</sup>. This could explain the missing transferability of the *in vitro* effects in HSCs on the *in vivo* situation in the Abcb4<sup>-/-</sup> model. Thus, it seems likely that the IL-1-dependent effects may be of pathophysiologic relevance in other types of hepatic fibrosis that are primarily caused by the activation and proliferation of perisinusoidal HSCs, a situation that might be different from cholestatic fibrosis. One might also suspect that

our results suggest that multiple pathways need to be considered for the therapeutic intervention of different types of liver fibrosis.

The observation that conventional immunosuppressive treatment has no therapeutic effect on PSC<sup>[2]</sup> is in accordance with the missing effects of our selective and putatively well-tolerable immunosuppressive approach by inhibition of the IL-1 pathway.

Taken together, this study demonstrated sex differences regarding hepatic inflammation and hepatic fibrosis in the Abcb4<sup>-/-</sup> model. Our *in vitro* experiments suggest the relevance of the IL-1 pathway in HSC proliferation and implicate the therapeutic potential of IL-1 antagonism. However, the treatment with the clinically approved IL-1 receptor antagonist Anakinra did not result in the amelioration of the hepatic phenotype in the Abcb4<sup>-/-</sup> model after 4 wk of treatment. Further studies might identify a therapeutic impact of this pathway in other types of liver fibrosis.

## ACKNOWLEDGMENTS

Parts of this work were presented at the annual meeting of the Bavarian Society for Gastroenterology 2015 in Garmisch-Partenkirchen. The statistical methods of this study were reviewed by Christoph Glasmacher, an external biostatistician (Christoph Glasmacher - Biometrics and SAS-Programming for Clinical Research).

## COMMENTS

### Background

Hepatic stellate cells (HSCs) are the major source of hepatic extracellular matrix deposition and crucially participate in the pathogenesis of liver fibrosis. In addition to other factors, enhanced proliferation of this cell type is thought to be an important profibrotic mechanism. In this regard, a recent study found that interleukin-1 $\beta$  (IL-1) $\beta$  induces the proliferation of rat HSCs. Furthermore, IL-1 was identified as a factor in the progression of liver injury to fibrosis.

Gender differences regarding hepatic injury in ATP-binding cassette transporter b4<sup>+</sup> (Abcb4<sup>+</sup>) mice were reported previously. However, differences in liver fibrosis were not evaluated in detail so far. In this study, the authors describe gender differences regard liver fibrosis in Abcb4<sup>+</sup> animals. Interestingly these findings are associated with coherent alterations of the IL-1 $\beta$  mRNA expression levels. Therefore, they hypothesised that the clinically approved IL-1 receptor antagonist Anakinra could reduce the proliferative effects of IL-1 $\beta$  in HSCs and improve fibrosis in Abcb4<sup>+</sup> mice. They also hypothesised that blocking the IL-1 pathway during liver fibrosis might be a therapeutic approach in this chronic cholestatic liver disease.

### Research frontiers

The proliferative effects of IL-1 $\beta$  on HSCs were described in former studies. However, a therapeutic approach *via* the clinically approved IL-1 receptor antagonist Anakinra was not investigated thus far regarding its efficacy in liver fibrosis.

### Innovations and breakthroughs

This is the first study to evaluate the efficacy of the clinically approved IL-1 receptor antagonist Anakinra on HSC proliferation *in vitro*. They report on the antiproliferative effects of this agent on HSC proliferation and identified a potential therapeutic approach. Furthermore, this study reported on gender differences regarding liver fibrosis in the Abcb4<sup>+</sup> mouse model.

### Applications

They *in vitro* findings support the importance of the IL-1 pathway in HSC proliferation. The effects of Anakinra on HSC proliferation suggest a therapeutic approach in liver fibrosis.

### Terminology

HSCs are the major source of hepatic extracellular matrix deposition and crucially participate in the pathogenesis of liver fibrosis. The Abcb4<sup>+</sup> mouse model is a preclinical model for primary sclerosing cholangitis and biliary liver fibrosis.

### Peer-review

This paper shows that the IL-1 signaling antagonist Anakinra can influence mouse HSC *in vitro* but not fibrosis in the Abcb4 mouse. Additional novel data is that female mice in this model are more affected than male mice.

## REFERENCES

- Farrant JM, Hayllar KM, Wilkinson ML, Karani J, Portmann BC, Westaby D, Williams R. Natural history and prognostic variables in primary sclerosing cholangitis. *Gastroenterology* 1991; **100**: 1710-1717 [PMID: 1850376]
- Chapman R, Fevery J, Kalloo A, Nagorney DM, Boberg KM, Shneider B, Gores GJ. Diagnosis and management of primary sclerosing cholangitis. *Hepatology* 2010; **51**: 660-678 [PMID: 20101749 DOI: 10.1002/hep.23294]
- Boonstra K, Weersma RK, van Erpecum KJ, Rauws EA, Spanier BW, Poen AC, van Nieuwkerk KM, Drenth JP, Witteman BJ, Tuynman HA, Naber AH, Kingma PJ, van Buuren HR, van Hoek B, Vleggaar FP, van Geloven N, Beuers U, Ponsioen CY. Population-based epidemiology, malignancy risk, and outcome of primary sclerosing cholangitis. *Hepatology* 2013; **58**: 2045-2055 [PMID: 23775876 DOI: 10.1002/hep.26565]
- Washington MK. Autoimmune liver disease: overlap and outliers. *Mod Pathol* 2007; **20** Suppl 1: S15-S30 [PMID: 17486048 DOI: 10.1038/modpathol.3800684]
- Dilger K, Hohenester S, Winkler-Budenhofer U, Bastiaansen BA, Schaap FG, Rust C, Beuers U. Effect of ursodeoxycholic acid on bile acid profiles and intestinal detoxification machinery in primary biliary cirrhosis and health. *J Hepatol* 2012; **57**: 133-140 [PMID: 22414767 DOI: 10.1016/j.jhep.2012.02.014]
- Hohenester S, Gates A, Wimmer R, Beuers U, Anwer MS, Rust C, Webster CR. Phosphatidylinositol-3-kinase p110 $\gamma$  contributes to bile salt-induced apoptosis in primary rat hepatocytes and human hepatoma cells. *J Hepatol* 2010; **53**: 918-926 [PMID: 20675006 DOI: 10.1016/j.jhep.2010.05.015]
- Hohenester S, Wenniger LM, Paulusma CC, van Vliet SJ, Jefferson DM, Elferink RP, Beuers U. A biliary HCO<sub>3</sub><sup>-</sup> umbrella constitutes a protective mechanism against bile acid-induced injury in human cholangiocytes. *Hepatology* 2012; **55**: 173-183 [PMID: 21932391 DOI: 10.1002/hep.24691]
- Rust C, Wild N, Bernt C, Vennegerts T, Wimmer R, Beuers U. Bile acid-induced apoptosis in hepatocytes is caspase-6-dependent. *J Biol Chem* 2009; **284**: 2908-2916 [PMID: 19017654 DOI: 10.1074/jbc.M804585200]
- Denk G, Omary AJ, Reiter FP, Hohenester S, Wimmer R, Holdenrieder S, Rust C. Soluble intracellular adhesion molecule, M30 and M65 as serum markers of disease activity and prognosis in cholestatic liver diseases. *Hepatol Res* 2014; **44**: 1286-1298 [PMID: 24451045 DOI: 10.1111/hepr.12304]
- Guicciardi ME, Gores GJ. Bile acid-mediated hepatocyte apoptosis and cholestatic liver disease. *Dig Liver Dis* 2002; **34**: 387-392 [PMID: 12132783]
- Canbay A, Taimr P, Torok N, Higuchi H, Friedman S, Gores GJ. Apoptotic body engulfment by a human stellate cell line is profibrogenic. *Lab Invest* 2003; **83**: 655-663 [PMID: 12746475]
- Friedman SL. Molecular regulation of hepatic fibrosis, an integrated cellular response to tissue injury. *J Biol Chem* 2000; **275**: 2247-2250 [PMID: 10644669]
- Friedman SL. Mechanisms of disease: Mechanisms of hepatic fibrosis and therapeutic implications. *Nat Clin Pract Gastroenterol Hepatol* 2004; **1**: 98-105 [PMID: 16265071]
- Lee UE, Friedman SL. Mechanisms of hepatic fibrogenesis. *Best Pract Res Clin Gastroenterol* 2011; **25**: 195-206 [PMID: 21497738 DOI: 10.1016/j.bpg.2011.02.005]
- Yaping Z, Ying W, Luqin D, Ning T, Xuemei A, Xixian Y. Mechanism of interleukin-1 $\beta$ -induced proliferation in rat hepatic stellate cells from different levels of signal transduction. *APMIS* 2014; **122**: 392-398 [PMID: 23992404 DOI: 10.1111/apm.12155]
- Gieling RG, Wallace K, Han YP. Interleukin-1 participates in the progression from liver injury to fibrosis. *Am J Physiol Gastrointest Liver Physiol* 2009; **296**: G1324-G1331 [PMID: 19342509 DOI: 10.1152/ajpgi.90564]
- Popov Y, Patsenker E, Fickert P, Trauner M, Schuppan D. Mdr2 (Abcb4)<sup>-/-</sup> mice spontaneously develop severe biliary fibrosis via massive dysregulation of pro- and antifibrogenic genes. *J Hepatol* 2005; **43**: 1045-1054 [PMID: 16223543]
- Fickert P, Fuchsbichler A, Wagner M, Zollner G, Kaser A, Tilg H, Krause R, Lammert F, Langner C, Zatloukal K, Marschall HU, Denk H, Trauner M. Regurgitation of bile acids from leaky bile ducts causes sclerosing cholangitis in Mdr2 (Abcb4) knockout mice. *Gastroenterology* 2004; **127**: 261-274 [PMID: 15236191]
- Mauad TH, van Nieuwkerk CM, Dingemans KP, Smit JJ, Schinkel AH, Notenboom RG, van den Bergh Weerman MA, Verkruijsen RP, Groen AK, Oude Elferink RP. Mice with homozygous disruption of the mdr2 P-glycoprotein gene. A novel animal model for studies of nonsuppurative inflammatory cholangitis and hepatocarcinogenesis. *Am J Pathol* 1994; **145**: 1237-1245 [PMID: 7977654]
- Fickert P, Wagner M, Marschall HU, Fuchsbichler A, Zollner G, Tsybrovskyy O, Zatloukal K, Liu J, Waalkes MP, Cover C, Denk H, Hofmann AF, Jaeschke H, Trauner M. 24-norUrsodeoxycholic acid is superior to ursodeoxycholic acid in the treatment of sclerosing cholangitis in Mdr2 (Abcb4) knockout mice. *Gastroenterology* 2006; **130**: 465-481 [PMID: 16472600]
- Friedman SL, Roll FJ. Isolation and culture of hepatic lipocytes, Kupffer cells, and sinusoidal endothelial cells by density gradient centrifugation with Stractan. *Anal Biochem* 1987; **161**: 207-218 [PMID: 3578783]
- Jones KH, Senft JA. An improved method to determine cell viability by simultaneous staining with fluorescein diacetate-propidium iodide. *J Histochem Cytochem* 1985; **33**: 77-79 [PMID: 2578146]
- Abbate A, Salloum FN, Vecile E, Das A, Hoke NN, Straino S, Biondi-Zoccai GG, Houser JE, Qureshi IZ, Ownby ED, Gustini E,



- Biasucci LM, Severino A, Capogrossi MC, Vetovec GW, Crea F, Baldi A, Kukreja RC, Dobrina A. Anakinra, a recombinant human interleukin-1 receptor antagonist, inhibits apoptosis in experimental acute myocardial infarction. *Circulation* 2008; **117**: 2670-2683 [PMID: 18474815]
- 24 **Edwards CA**, O'Brien WD. Modified assay for determination of hydroxyproline in a tissue hydrolyzate. *Clin Chim Acta* 1980; **104**: 161-167 [PMID: 7389130]
  - 25 **Ali AH**, Carey EJ, Lindor KD. Current research on the treatment of primary sclerosing cholangitis. *Intractable Rare Dis Res* 2015; **4**: 1-6 [PMID: 25674381 DOI: 10.5582/ir.2014.01018]
  - 26 **van Nieuwerck CM**, Groen AK, Ottenhoff R, van Wijland M, van den Bergh Weerman MA, Tytgat GN, Offerhaus JJ, Oude Elferink RP. The role of bile salt composition in liver pathology of mdr2 (-/-) mice: differences between males and females. *J Hepatol* 1997; **26**: 138-145 [PMID: 9148004]
  - 27 **Ramachandran P**, Iredale JP. Liver fibrosis: a bidirectional model of fibrogenesis and resolution. *QJM* 2012; **105**: 813-817 [PMID: 22647759 DOI: 10.1093/qjmed/hcs069]
  - 28 **Elsharkawy AM**, Oakley F, Mann DA. The role and regulation of hepatic stellate cell apoptosis in reversal of liver fibrosis. *Apoptosis* 2005; **10**: 927-939 [PMID: 16151628]
  - 29 **Ismail MH**, Pinzani M. Reversal of hepatic fibrosis: pathophysiological basis of antifibrotic therapies. *Hepat Med* 2011; **3**: 69-80 [PMID: 24367223 DOI: 10.2147/HMER.S9051]
  - 30 **Affo S**, Morales-Ibanez O, Rodrigo-Torres D, Altamirano J, Blaya D, Dapito DH, Millán C, Coll M, Caviglia JM, Arroyo V, Caballeria J, Schwabe RF, Ginès P, Bataller R, Sancho-Bru P. CCL20 mediates lipopolysaccharide induced liver injury and is a potential driver of inflammation and fibrosis in alcoholic hepatitis. *Gut* 2014; **63**: 1782-1792 [PMID: 24415562 DOI: 10.1136/gutjnl-2013-306098]
  - 31 **Wynn TA**, Barron L. Macrophages: master regulators of inflammation and fibrosis. *Semin Liver Dis* 2010; **30**: 245-257 [PMID: 20665377 DOI: 10.1055/s-0030-1255354]
  - 32 **Friedman SL**. Hepatic stellate cells: protean, multifunctional, and enigmatic cells of the liver. *Physiol Rev* 2008; **88**: 125-172 [PMID: 18195085 DOI: 10.1152/physrev.00013.2007]
  - 33 **Trautwein C**, Friedman SL, Schuppan D, Pinzani M. Hepatic fibrosis: Concept to treatment. *J Hepatol* 2015; **62**: S15-S24 [PMID: 25920084 DOI: 10.1016/j.jhep.2015.02.039]
  - 34 **Petrasek J**, Bala S, Csak T, Lippai D, Kodys K, Menashy V, Barrieau M, Min SY, Kurt-Jones EA, Szabo G. IL-1 receptor antagonist ameliorates inflammasome-dependent alcoholic steatohepatitis in mice. *J Clin Invest* 2012; **122**: 3476-3489 [PMID: 22945633 DOI: 10.1172/JCI60777]
  - 35 **Reiter FP**, Hohenester S, Nagel JM, Wimmer R, Artmann R, Wotke L, Makeschin MC, Mayr D, Rust C, Trauner M, Denk GU. 1,25-(OH)<sub>2</sub>-vitamin D<sub>3</sub> prevents activation of hepatic stellate cells in vitro and ameliorates inflammatory liver damage but not fibrosis in the Abcb4(-/-) model. *Biochem Biophys Res Commun* 2015; **459**: 227-233 [PMID: 25712522 DOI: 10.1016/j.bbrc.2015.02.074]
  - 36 **Trauner M**, Fickert P, Halilbasic E, Moustafa T. Lessons from the toxic bile concept for the pathogenesis and treatment of cholestatic liver diseases. *Wien Med Wochenschr* 2008; **158**: 542-548 [PMID: 18998069 DOI: 10.1007/s10354-008-0592-1]
  - 37 **Ramadori G**, Saile B. Portal tract fibrogenesis in the liver. *Lab Invest* 2004; **84**: 153-159 [PMID: 14688800]

**P- Reviewer:** Fan XM, Gorrell MD, Penkova-Radicheva MP, Xu J  
**S- Editor:** Qiu S **L- Editor:** A **E- Editor:** Liu SQ



Retrospective Study

## Retrocaval liver lifting maneuver and modifications of total hepatic vascular exclusion for liver tumor resection

Saiho Ko, Yuuki Kirihataya, Yayoi Matsumoto, Tadataka Takagi, Masanori Matsusaka, Tomohide Mukogawa, Hirofumi Ishikawa, Akihiko Watanabe

Saiho Ko, Yuuki Kirihataya, Yayoi Matsumoto, Tadataka Takagi, Masanori Matsusaka, Tomohide Mukogawa, Hirofumi Ishikawa, Akihiko Watanabe, Department of Surgery, Nara Prefecture General Medical Center, Nara 631-0846, Japan

**Author contributions:** Ko S conceived and designed the study, and wrote the manuscript; Kirihataya Y, Matsumoto Y and Takagi T acquired the data; Ko S, Matsusaka M and Mukogawa T analyzed and interpreted the data; Ishikawa H contributed to drafting of the manuscript; Watanabe A contributed to critical revision of the manuscript.

**Institutional review board statement:** The Institutional Ethical Committee of Nara Prefecture General Medical Center approved this retrospective clinical study.

**Informed consent statement:** Written informed consent was obtained from all patients for use of clinical data in research. The analysis is a retrospective study and the clinical data were anonymous.

**Conflict-of-interest statement:** None of the authors has any conflict of interest related to the publication of this manuscript.

**Data sharing statement:** There are no additional data available for this manuscript.

**Open-Access:** This article is an open-access article which was selected by an in-house editor and fully peer-reviewed by external reviewers. It is distributed in accordance with the Creative Commons Attribution Non Commercial (CC BY-NC 4.0) license, which permits others to distribute, remix, adapt, build upon this work non-commercially, and license their derivative works on different terms, provided the original work is properly cited and the use is non-commercial. See: <http://creativecommons.org/licenses/by-nc/4.0/>

**Correspondence to:** Dr. Saiho Ko, Director, Department of Surgery, Nara Prefecture General Medical Center, 1-30-1 Nara, Nara 631-0846, Japan. [saihoko@naramed-u.ac.jp](mailto:saihoko@naramed-u.ac.jp)  
 Telephone: +81-742-466001  
 Fax: +81-742-466011

Received: November 28, 2015  
 Peer-review started: November 29, 2015  
 First decision: January 4, 2016  
 Revised: January 13, 2016  
 Accepted: March 7, 2016  
 Article in press: March 9, 2016  
 Published online: March 18, 2016

### Abstract

**AIM:** To evaluate the efficacy of technical modifications of total hepatic vascular exclusion (THVE) for hepatectomy involving inferior vena cava (IVC).

**METHODS:** Of 301 patients who underwent hepatectomy during the immediate previous 5-year period, 8 (2.7%) required THVE or modified methods of IVC cross-clamping for resection of liver tumors with massive involvement of the IVC. Seven of the patients had diagnosis of colorectal liver metastases and 1 had diagnosis of hepatocellular carcinoma. All tumors involved the IVC, and THVE was unavoidable for combined resection of the IVC in all 8 of the patients. Technical modifications of THVE were applied to minimize the extent and duration of vascular occlusion, thereby reducing the risk of damage.

**RESULTS:** Broad dissection of the space behind the IVC coupled with lifting up of the liver from the retrocaval space was effective for controlling bleeding around the IVC before and during THVE. The procedures facilitate modification of the positioning of the cranial IVC cross-clamp. Switching the cranial IVC cross-clamp from supra- to retrohepatic IVC or to the confluence of hepatic vein decreased duration of the THVE while restoring hepatic blood flow or systemic circulation *via* the IVC. Oblique cranial IVC cross-clamping avoided ischemia of the remnant hemi-liver. With these technical

modifications, the mean duration of THVE was  $13.4 \pm 8.4$  min, which was extremely shorter than that previously reported in the literature. Recovery of liver function was smooth and uneventful for all 8 patients. There was no case of mortality, re-operation, or severe complication (*i.e.*, Clavien-Dindo grade of III or more).

**CONCLUSION:** The retrocaval liver lifting maneuver and modifications of cranial cross-clamping were useful for minimizing duration of THVE.

**Key words:** Total hepatic vascular exclusion; Retrocaval liver lifting maneuver; Oblique clamping; Switching the clamp; Hepatectomy

© **The Author(s) 2016.** Published by Baishideng Publishing Group Inc. All rights reserved.

**Core tip:** Total hepatic vascular exclusion (THVE) is needed for resection of liver tumors involving inferior vena cava (IVC). Because THVE has a high risk of morbidity, compared to inflow occlusion alone, its duration should be shortened. The technical modifications reported here minimized the risk of damage of THVE. Specifically, the procedures include the retrocaval liver lifting maneuver, switching of the cranial IVC cross-clamp, and oblique IVC cross-clamping. For the 8 patients retrospectively assessed, the duration of THVE was  $13.4 \pm 8.4$  min, which was remarkably shorter than that reported previously. Postoperative recovery was smooth for all patients, without severe complications.

Ko S, Kirihataya Y, Matsumoto Y, Takagi T, Matsusaka M, Mukogawa T, Ishikawa H, Watanabe A. Retrocaval liver lifting maneuver and modifications of total hepatic vascular exclusion for liver tumor resection. *World J Hepatol* 2016; 8(8): 411-420 Available from: URL: <http://www.wjgnet.com/1948-5182/full/v8/i8/411.htm> DOI: <http://dx.doi.org/10.4254/wjh.v8.i8.411>

## INTRODUCTION

Despite recent advances in liver surgery, resection for tumors involving inferior vena cava (IVC) is still challenging<sup>[1-4]</sup>. This situation requires total hepatic vascular exclusion (THVE) for combined resection of the IVC. The THVE method was developed to control bleeding during hepatic parenchymal transection<sup>[5,6]</sup>; however, it is technically complicated and may cause profound liver damage and circulatory instability, and as a result inflow occlusion *via* Pringle's maneuver is more frequently used to control bleeding during usual hepatectomy, rather than THVE<sup>[7]</sup>. While THVE can effectively limit blood loss during hepatic parenchymal transection, especially that from hepatic veins<sup>[8,9]</sup>, its related rates of morbidity and mortality after hepatectomy for tumors involving IVC have been quite high<sup>[10,11]</sup>. Novel strategies to reduce the risk of damage and complications of THVE will benefit clinical practice and

patient outcome.

Long occlusion time is one of the most significant hazards of operative morbidity and mortality after hepatectomy with THVE<sup>[2]</sup>. There is no doubt about the importance of minimizing duration of THVE to reduce ischemic damage of the liver. Different from the procedure of portal triad clamping applied alone, addition of THVE necessitates taking into account both hepatic ischemia and instability of systemic circulation, including renal congestion. Selective hepatic vascular exclusion with hepatic venous occlusion preserving IVC flow is an alternative of THVE in usual hepatectomy<sup>[12,13]</sup>, but the method cannot be used for tumors involving IVC. Reports describing technical modifications aimed at minimizing hazards of THVE are available in the publicly available literature, but they are small in number<sup>[8,14]</sup>. Herein, we describe some technical modifications of THVE that were applied to patients in our hospital and which were found by retrospective analysis to have successfully minimized the duration and the extent of vascular occlusion. The purpose of reporting these results is to share these methods with clinicians and researchers in the field of hepatology so as to help reduce the rates of disastrous events during hepatectomy requiring THVE.

## MATERIALS AND METHODS

### Patients

From January 2010 to April 2015, 301 patients underwent hepatectomy at our hospital. Patients who underwent hepatectomy with THVE or modified THVE with IVC cross-clamping were selected for retrospective analysis, and those patients who had required only a small portion of the IVC to be resected without cross-clamping of the IVC were excluded from the study. A total of 8 patients (2.7% of the 301 hepatectomized patients) fit the criteria for inclusion, namely tumors involving IVC and treatment by combined resection of the IVC.

### Preoperative evaluation for indication of THVE

For all 8 patients, tumor status had been evaluated using three-phase contrast-enhanced computed tomography (CT). Contrast-enhanced magnetic resonance imaging (MRI) and/or (<sup>18</sup>F)-fluoro-D-glucose positron emission tomography had been performed in addition as necessary. The indication of THVE during hepatectomy was massive tumor involvement of IVC or tumor involvement of major hepatic vein extending to its confluence on IVC. Tumors that had been deemed as necessitating resection by side clamping of the IVC were excluded from the indication of THVE. THVE was not used merely for controlling bleeding from the parenchymal transection plane.

### Standard THVE procedures

By dissecting the coronary ligament around the supra-hepatic IVC just below the diaphragm, the outer wall

Table 1 Surgical procedures

Case No.	Diagnosis	No. of tumor	Size of the largest tumor, cm	THVE and modifications	THVE duration, min	Hepatectomy	Vascular reconstruction procedures	Outcome
1	HCC	1	20.0	Standard with switching <sup>1</sup>	5	Extended right hepatectomy	Direct suture of IVC	Alive without disease, 60 mo postoperative
2	Liver metastasis	1	20.0	Standard with switching <sup>1</sup>	9	Extended right hepatectomy	IMV patch for HV, Direct suture of IVC	Alive with disease, 17 mo postoperative
3	Liver metastasis	2	9.0	Standard with switching <sup>1</sup>	23	Extended right hepatectomy	IMV patch for HV and IVC	Alive with disease, 10 mo postoperative
4	Liver metastasis	1	6.0	Oblique <sup>2</sup> (right)	26	Right hepatectomy	IMV patch graft for IVC	Died of disease, 27 mo postoperative
5	Liver metastasis	4	2.5	Oblique <sup>2</sup> (right)	20	Partial resection	IMV patch graft for IVC and HV	Alive without disease, 15 mo postoperative
6	Liver metastasis	10	18.0	Oblique <sup>2</sup> (right)	7	Right hepatectomy, partial resection	Direct suture of IVC	Died of disease, 8 mo postoperative
7	Liver metastasis	15	5.5	Oblique <sup>2</sup> (right)	7	Extended anterior sectionectomy, partial resection	Direct suture of IVC	Died of disease, 9 mo postoperative
8	Liver metastasis	9	5.5	Oblique <sup>2</sup> (left)	10	Segmentectomy, partial resection	Direct suture of IVC and HVs	Alive without disease, 13 mo postoperative

<sup>1</sup>Switching the cross-clamp; <sup>2</sup>Oblique cross-clamping. IMV: Inferior mesenteric vein; IVC: Inferior vena cava; HVs: Hepatic veins; THVE: Total hepatic vascular exclusion.

of the IVC was made visible. Ligation and division of infradiaphragmatic veins had been made as necessary. For all 8 patients, the attachment between the liver and diaphragm was dissected, and the dorsal space of the suprahepatic IVC was dissected. Subsequently, the suprahepatic IVC was encircled gently and taped in preparation for cranial cross-clamping of the IVC. The infrahepatic IVC was also dissected circumferentially and encircled in preparation for caudal cross-clamping. Principally, THVE was not applied before completion of hepatic parenchymal transection. The final step of resection involved clamping of the caudal and cranial IVC prior to the resection and reconstruction of the involved IVC *via* THVE.

#### Other surgical procedures

The abdomen was opened *via* J-shape incision that included upper median and right oblique incisions. Tumor status and the relation between the tumors and major intrahepatic vasculature were confirmed by intraoperative ultrasonography. The liver was mobilized to the extent necessary for the planned surgery. The hepatic parenchyma was transected using the clamp-crushing method. Thin vessel branches were burned by electrocautery or soft coagulation devices. Thicker branches were ligated and divided. Intermittent Pringle's maneuver was applied routinely during the hepatic parenchymal transection using a 15-min/5-min period of clamping and release.

#### Evaluation of operative morbidity and mortality

The recorded postoperative complications were classified according to severity by using the Clavien-Dindo criteria (grades I - V). Hepatic failure was defined as serum level of total bilirubin > 5.0 mg/dL (equal to 85.5  $\mu$ mol/L) at postoperative day 5 or later. Operative mortality was defined as all in-hospital deaths and death

within 90 d after surgery.

#### Follow-up schedule and adjuvant chemotherapy

Follow-up after discharge involved CT or MRI evaluation every 4-6 mo and blood testing and physical examination every 1-6 mo for a total period of 5 years after the last intervention.

#### Statistical analysis

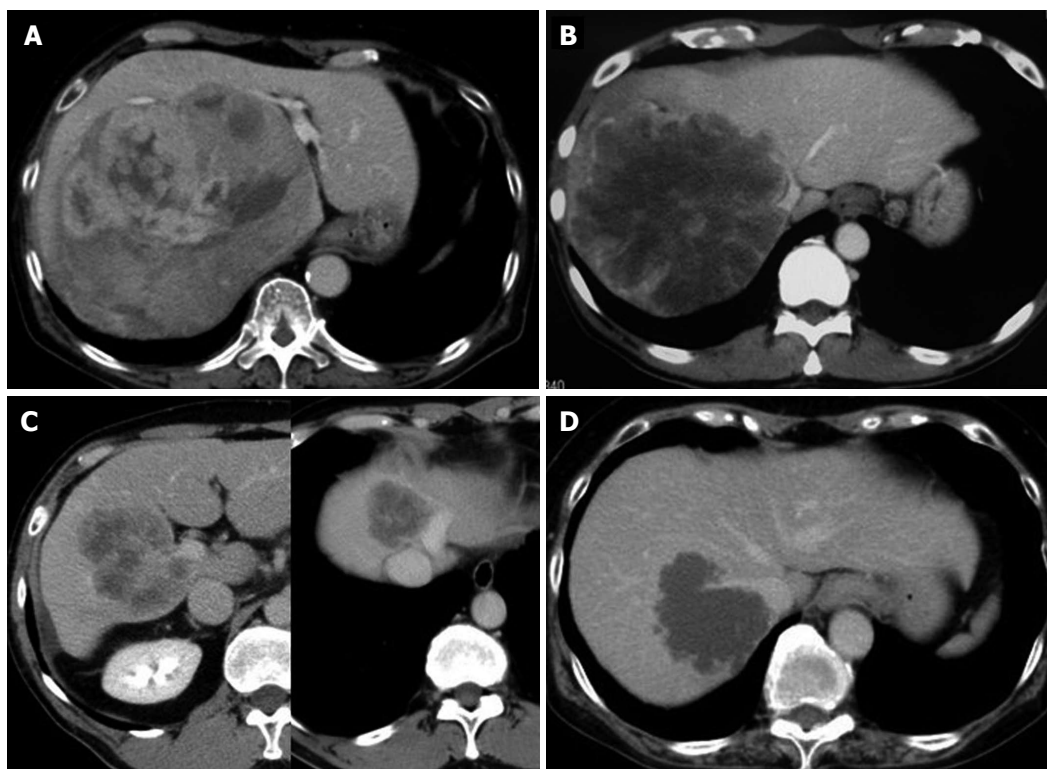
All numerical values were calculated as mean and SD or median and range.

## RESULTS

The 8 patients included in this analysis consisted of 6 men and 2 women, with median age of 72-years-old (range: 36-78 years). Seven of the patients had a diagnosis of colorectal liver metastases and 1 had a diagnosis of hepatocellular carcinoma (Table 1). The mean diameter of the total resected tumors was  $10.8 \pm 7.3$  cm. All patients had tumors involving the IVC, with or without confluence of the hepatic veins as shown in Figure 1.

The surgical procedures used for all 8 patients are listed in Table 1. For all, the initial surgical step was broad dissection of the space behind the IVC, after which the liver was lifted up by the surgeon's left hand to move it from the retrocaval space in order to control bleeding before and during THVE (retrocaval liver lifting maneuver). Standard THVE was applied to 3 patients (cases 1-3), for which the cranial cross-clamp for THVE was switched from the suprahepatic to retrohepatic levels or to the confluence of the major hepatic vein to shorten the duration of THVE (switching the cross-clamp). For the remaining 5 patients (cases 4-8), total ischemia of the whole liver was avoided by applying the





**Figure 1** Abdominal computed tomography scan images of cases 1-4. A: Case 1: Lumen of the IVC compressed by a huge right liver tumor with expansive growth; B: Case 2: A large right liver tumor involving the right aspect of the IVC and the confluence of middle and left hepatic veins; C: Case 3: Two tumors were present, a right liver tumor involving the right portal vein and the portal vein bifurcation, and another tumor occupying the cranial part of segments 4 and 8 and involving the left aspect of the trunk of the middle and left hepatic veins; D: Case 4: A tumor involving the right dorsal aspect of the IVC and its confluence of the right hepatic vein. IVC: Inferior vena cava.

cranial clamp obliquely to maintain the hepatic venous outflow of the liver remnant (oblique cross-clamping). Detailed descriptions of these techniques are provided below.

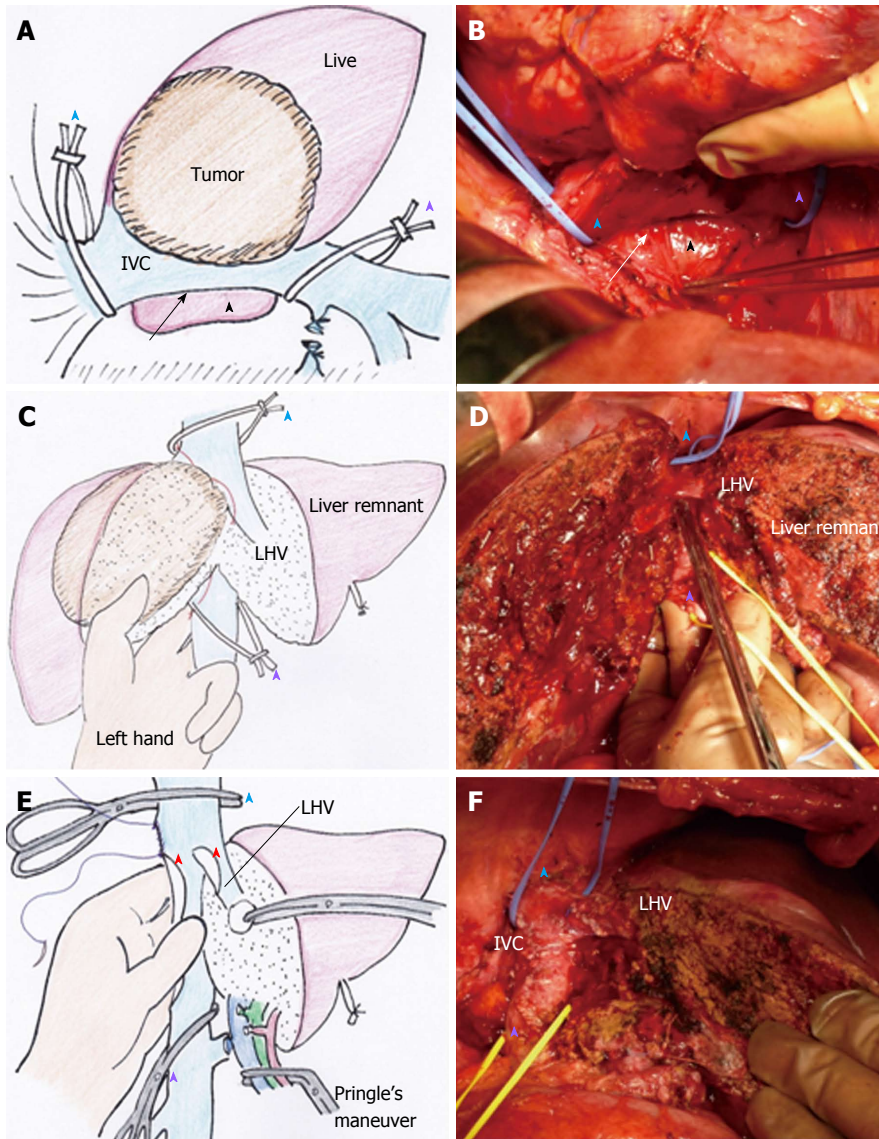
### Technical modifications for THVE

**Retrocaval liver lifting maneuver:** The liver cannot be detached from the IVC when the tumor involves the IVC. Instead, the retrocaval space behind the hepatic IVC should be dissected broadly to facilitate performance of standard or modified THVE (Figure 2A and B). In all 8 patients of this study, the IVC was compressed ventrally and the liver was lifted up from the retrocaval space by the surgeon's left hand (Figure 2C and D). This maneuver was quite useful for controlling bleeding during transection of the hepatic parenchyma near the IVC. With the help of this maneuver parenchymal transection can be completed safely before applying THVE, as shown in Figure 2D. The THVE procedure was applied at the last step of the combined resection and reconstruction of IVC, with the involved part of the IVC excised en-bloc with the liver specimen (Figure 2E). Theoretically, no bleeding should come from the IVC under THVE, but a significant amount of backflow bleeding often comes from the cut orifice of IVC during THVE. For all 8 patients in this study, compressing the IVC upward from the retrocaval space, by means of

the surgeon's left hand, was effective for controlling backflow bleeding from the cut orifice of the IVC under THVE (Figure 2E).

**Switching the cross-clamp:** Standard THVE cannot be avoided for combined resection of IVC involving the major hepatic vein of the liver remnant, as was performed in case 3 of this study (Figure 3A). After removal of the specimen and completion of the repair of the IVC under standard THVE, the position of the cranial IVC cross-clamp was switched from the suprahepatic IVC to the IVC confluence of the resected hepatic vein to be reconstructed (Figure 3C). Then, the IVC blood flow was restored to stabilize systemic hemodynamics.

Another surgical situation in this study involved switching of the cross-clamp of the suprahepatic IVC to the retrohepatic level, as performed in case 1. The tumor status is shown in Figure 1A. At the first step of this intervention, standard THVE was applied for resection of large hepatocellular carcinoma that involved retrohepatic IVC massively. Both the tumor and the involved wall of the IVC were resected under standard THVE. After repairing the IVC defect around the confluence of the hepatic vein, the suprahepatic IVC cross-clamp was switched to the level just below the hepatic vein confluence. Then, the portal triad occlusion was released to restore the blood flow of the liver remnant, after which



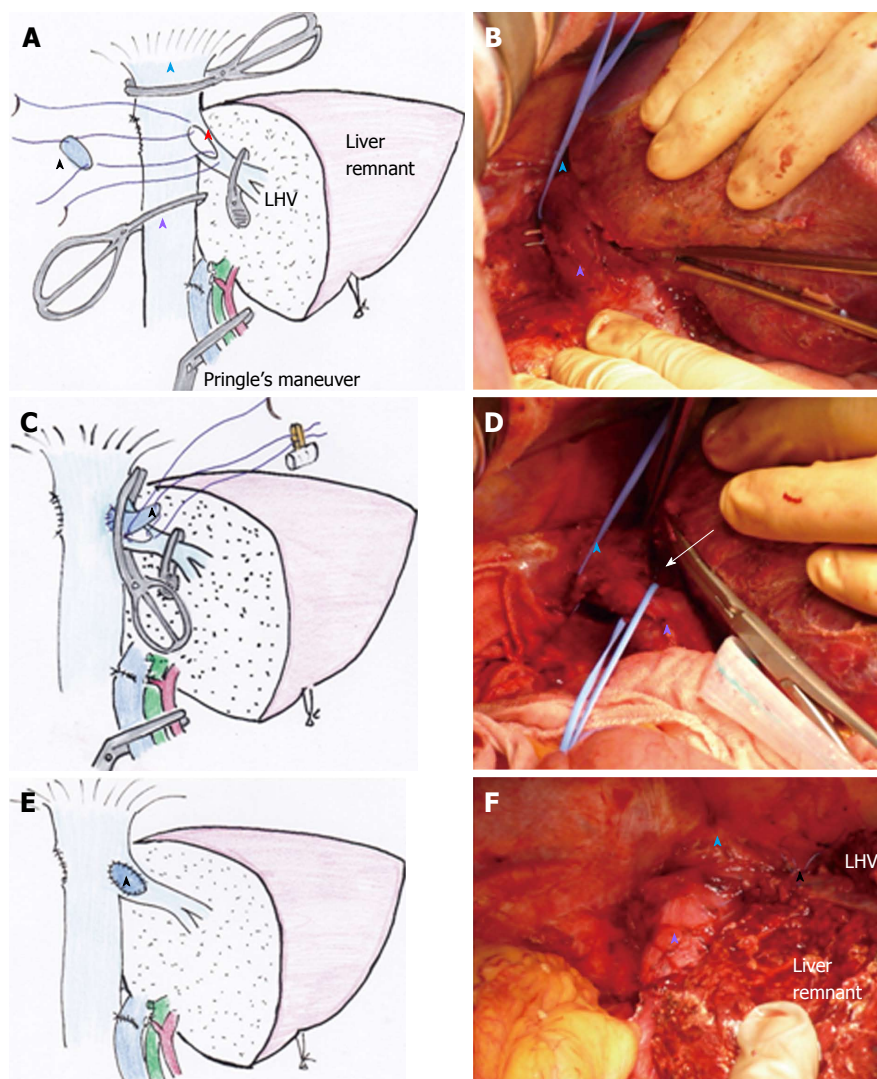
**Figure 2 Retrocaval liver lifting maneuver, performed in case 2.** A (illustration) and B (intraoperative image): The retrocaval space (arrow) was dissected broadly from the right lateral view toward the inner aspect of Spiegel's lobe (black arrowhead), after which the supra- and infrahepatic IVC were taped to prepare cross-clamping for THVE (blue arrowhead and purple arrowhead); C (illustration) and D (intraoperative image): The index and middle fingers of the surgeon's left hand were placed into the dissected retrocaval space, and the IVC was compressed ventrally to control bleeding around the IVC during deep parenchymal transection, after which the thumb finger of the surgeon's left hand was used to spread the transection plane of the liver (C, which also shows the tumor status); D: Hepatic parenchymal transection is completed, except for the IVC involved site, before applying THVE; E (illustration) and F (intraoperative image): The liver specimen was excised along with the involved IVC and LHV wall (red arrowheads), and the backflow bleeding from the cut orifice of IVC was controlled by pinching the IVC using the surgeon's left hand from its placement in the retrocaval space; F shows the view after reconstruction of IVC and LHV. See Figure 1B for tumor status. IVC: Inferior vena cava; LHV: Left hepatic vein; THVE: Total hepatic vascular exclusion.

the retrohepatic IVC was repaired without prolonging the ischemic time of the liver.

**Oblique cranial cross-clamping:** When the space between the right and middle hepatic veins is free from involvement, venous drainage of the residual liver can be preserved during vascular exclusion by applying the cranial cross-clamping obliquely (Figure 4A). For this purpose, the retrocaval space must be dissected sufficiently in advance, same as shown in Figure 2A. Prior to this step, hepatic parenchymal transection had been completed to facilitate visualization of the anterior aspect of the hepatic IVC (Figure 4A and B). In the next step,

the vascular clamp was inserted behind the IVC obliquely, preserving the outflow orifice of the hepatic vein of the liver remnant (Figure 4A and B). By applying this modification of the THVE procedure, ischemic damage was avoided, as was intestinal congestion. In patients of this study for whom the right liver tumor involved the IVC massively around the orifice of right hepatic vein (RHV) (as in cases 4-7), the cranial IVC cross-clamp was applied from the right cranial side to the left caudal side of the IVC to allow venous drainage of the trunk of middle and left hepatic veins (MHV + LHV) (Figure 4A). In patients of this study for whom the left liver tumor involved the trunk of MHV + LHV (as in case 8), the





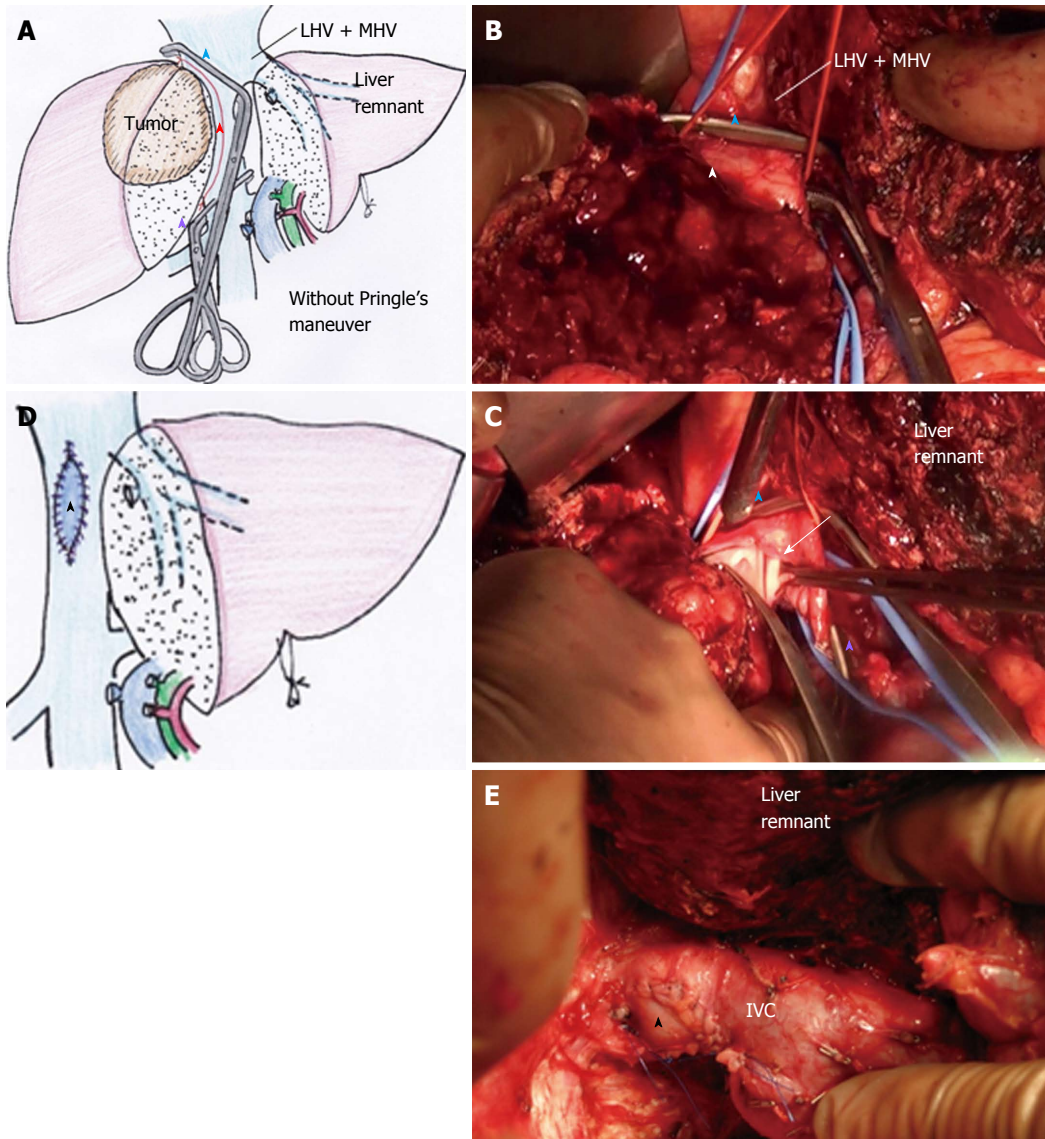
**Figure 3 Switching the cross-clamp, performed in case 3.** A (illustration) and B (intraoperative image): The right liver and involved right wall of the LHV and a part of the IVC wall had been resected en-bloc under standard THVE (red star indicates the orifice of resected IVC and LHV), before which the suprahepatic IVC was taped (blue arrowhead, blue tape), and the caudal cross-clamp was placed just under the confluence of LHV to the retrocaval space that had been already dissected (B). The defect of the confluence of the IVC and LHV was to be reconstructed by using an IMV patch graft (black arrowhead); C (illustration) and D (intraoperative image): After suturing the IMV patch graft to the IVC part of the defect, the IVC cross-clamps were removed and the clamp was switched to the confluence of the LHV to restore the systemic circulation *via* the IVC. The space for switching the clamp was spread by the caudal blue tape (white arrow in D); E (illustration) and F (intraoperative image): The view after reconstruction is shown. See Figure 1C for tumor status. IMV: Inferior mesenteric vein; IVC: Inferior vena cava; LHV: Left hepatic vein; THVE: Total hepatic vascular exclusion.

clamp was applied from the left cranial line to the right caudal line to preserve the outflow of the RHV. In the 5 patients who represented these two special situations, the THVE duration presented in Table 1 equates to the occlusion time of oblique cross-clamping of the IVC.

#### Operative parameters and postoperative course

The mean values of the operative parameters for the total 8 patients in this study are presented in Table 2. In no case did the THVE time exceed 30 min. Results from biochemical liver function tests and prothrombin time indicated the smooth recovery of liver function during the first postoperative week. In no case did the maximum serum total bilirubin level exceed 5 mg/mL, and no patient developed liver failure. For all of the

patients, the serum total bilirubin levels gradually decreased during the first postoperative week to below 2 mg/mL (equal to 34.2  $\mu$ mol/L) by day 7. No patient showed a prothrombin time less than 50% at any time during the postoperative period. In addition, no patient experienced a complication of Clavien-Dindo grade III or higher and there was no case of operative mortality. The postoperative complications that occurred included leg edema, pleural effusion, refractory ascites, and wound infection ( $n = 1$  each). No patient required reoperation, subsequent surgical or radiological interventions, or management in the intensive care unit, and all patients were discharged within a month after the surgery. All of the reconstructed vessels remained patent through the end of follow-up.



**Figure 4 Oblique cranial cross-clamping, performed in case 4.** A (illustration) and B (intraoperative image): The trunk of LHV + MHV was free from tumor involvement, while the right aspect of the IVC was involved extensively (red arrowhead). After completion of hepatic parenchymal transection, the cranial IVC cross-clamp (blue arrowhead) was applied obliquely between the tumor-involved IVC and the trunk of LHV + MHV preserving outflow of the LHV + MHV trunk, which was possible because the retrocaval space had been dissected sufficiently. Then, the involved IVC wall (white arrowhead in B) and the liver was resected *en-bloc* under modified THVE; C (intraoperative image): The involved IVC wall was cut away with scissors (arrow) between the oblique cranial (blue arrowhead) and caudal (purple arrowhead) cross-clamps; D (illustration) and E (intraoperative image): The large cut orifice of IVC was reconstructed with IMV patch graft (black arrowhead). See Figure 1D for tumor status. IMV: Inferior mesenteric vein; IVC: Inferior vena cava; LHV: Left hepatic vein; THVE: Total hepatic vascular exclusion.

### Survival

All patients returned to usual active life after discharge. The 1-year survival rate was 71%. Individual outcomes for each patient are presented in Table 1. At the date of this report, case 1 was alive without disease (5 years after surgery) and cases 6 and 7 presented with early multiple tumor recurrence in the liver remnant and died of rapid progression at 8 and 9 mo respectively.

### DISCUSSION

Liver tumors involving IVC or its junction of major hepatic veins represent situations in which THVE is needed for curative resection. Such surgery is fraught

with challenges, including unstable systemic circulation, ischemic damage of the liver and high risk of morbidity. Minimizing the duration and extent of exclusion is key to increasing the safety of THVE<sup>[2]</sup>. To this end, the present study highlights the feasibility of three technical modifications of THVE. The techniques include: (1) retrocaval liver lifting maneuver; (2) switching the cross-clamp; and (3) oblique cranial cross-clamping, which minimized duration of THVE and ischemic damage of the liver. It is noteworthy that application of these modified techniques minimized occlusion time; in addition, recovery of liver function was smooth, no severe complication developed, and operative mortality was not experienced. These operative results are quite favorable,



**Table 2** Operative parameters and postoperative course of 8 patients

Parameters	Values or number of patients
Operation time	482 ± 108 min
Blood loss	1778 ± 1233 mL
THVE duration	13.4 ± 8.4 min
Postoperative liver function	
TB (mg/dL)	
Maximum	2.01 (0.98-4.4)
POD7	1.08 (0.75-1.86)
AST (IU/L)	
Maximum	513 (238-1058)
POD7	30 (20-41)
ALT (IU/L)	
Maximum	319 (179-824)
POD7	64 (36-115)
PT (%)	
Minimum	64.4 (55.3-88.8)
POD7	88.1 (61.6-107.8)
Complications	
Clavien-Dindo classification	
I	2
II	1
≥ III	0
Operative mortality	0
Hospital stay (d)	15 (12-24)

AST: Aspartate amino transferase; PT: Prothrombin time; TB: Total bilirubin; ALT: Aspartate alanine aminotransferase; THVE: Total hepatic vascular exclusion.

particularly when compared to those reported by other studies<sup>[1-3,8,10,11]</sup>.

To date, only a limited number of studies of THVE for resection of liver tumors involving IVC are present in the publicly available literature, probably because the number of experiences in individual institutes has been small. The most distinctive features of the present study are the extremely short duration of THVE and favorable recovery after surgery. While the mean durations of THVE were 29 min to 78 min in the reports from very experienced institutes<sup>[1,2,7,8]</sup>, the mean THVE duration in the present study was only 13.4 ± 8.4 min. The mortality rates of hepatectomy with IVC resection were 4.5% to 25% in the previous reports<sup>[1-4,8,10,11,15]</sup>. In particular, the morbidity and mortality rates were quite high when standard THVE was applied frequently, even when hypothermic perfusion was used to attenuate the ischemic liver damage. In the previous reports, the major causes of mortality were liver failure and sepsis<sup>[1,3,4,8,11]</sup>, both of which are likely to be relevant to ischemic injury of the liver and intestinal congestion since they may facilitate bacterial translocation. Of course, simple comparison to the present case series is not possible due to the differences in severity of tumor status and underlying conditions. Nevertheless, minimized duration of THVE might have contributed to the favorable postoperative course in the present study.

Hand manipulation of the IVC from the broadly dissected retrocaval space is a unique method to decrease bleeding around the IVC. This procedure is also essential

as a preparation for modifying the THVE procedure to improve its safety. When the tumor involves the IVC, the liver cannot be freed from the IVC and Belghiti's liver hanging maneuver is not possible (and is rather a contraindication)<sup>[16]</sup>. In such a situation, wide dissection of the retrocaval space makes subsequent procedures safer. Lifting-up the liver by hand from the retrocaval space proved quite useful to control bleeding from the hepatic parenchyma near the IVC and backflow bleeding from the cut orifice of the IVC during THVE. Although no bleeding is supposed to come from the IVC under THVE theoretically, significant amount of backflow bleeding, which occurs frequently, serves to disrupt and complicate the vascular reconstruction procedure of IVC. Sources of such backflow bleeding are lumbar veins, short hepatic veins, or small venous branches that extend into the major hepatic veins. Even with portal triad occlusion by Pringle's maneuver, blood flow into the liver from the diaphragm or lesser omentum can exist. Compressing the IVC by hand, from the retrocaval space, was shown in the present study to be quite useful and the only way to control backflow bleeding during THVE.

The damage associated with THVE includes both systemic circulatory instability (due to absence of venous return *via* the IVC) and total cessation of hepatic blood flow. These conditions cause congestion of the kidney and intestine, which may explain why the damage and morbidity after THVE is much higher than that experienced after inflow occlusion alone<sup>[7]</sup>. In the current study, when the cranial IVC cross-clamp was switched from the supra- to the retrohepatic IVC (as performed in case 1), blood flow of the liver remnant was restored, thereby shortening the ischemic time of the liver remnant and intestine. When the clamp was switched to the confluence of hepatic vein of the liver remnant (as performed in case 3), IVC blood flow was restored, thereby resolving the systemic circulatory instability and renal congestion.

Oblique cranial IVC clamping is an option of standard THVE to avoid ischemic damage of the liver remnant as well as intestinal congestion; yet, this technique has not been precisely described in the literature. Even in the series of patients in this study with tumors with massive IVC involvement, the hepatic vein of the liver remnant side was free from involvement in many of the cases, and this is reported in other studies as well<sup>[1,8]</sup>. Such a situation is good indication for oblique cross-clamping. Sufficient dissection of the retrocaval space and completion of hepatic parenchymal transection in advance are essential for application of this method.

The timing of applying THVE may be one of the most important issues underlying its efficacy and safety. In most of the studies reported in the literature, THVE was applied during both parenchymal transection and combined resection/reconstruction of IVC<sup>[1,7,8]</sup>. This might be one of the reasons for the characteristic long occlusion time in the studies previous to ours. The primary policy of our hospital, however, is to make

every effort to minimize the duration of THVE. Because the retrocaval liver lifting maneuver makes it possible to complete the hepatic parenchymal transection without much bleeding, THVE was applied at the final step only for IVC resection and reconstruction. We believe that its success depends primarily on the procedures that had been applied prior to the application of THVE, including sufficient dissection of the retrocaval space and smooth completion of the hepatic parenchymal transection.

The small number of included patients may be a limitation of the present study. In general, the number of patients requiring THVE for hepatectomy with IVC reconstruction is rather small for a single institute, such as ours, as reflected in the previous studies<sup>[1-4,10,11,15]</sup>. The accumulated literature on this topic includes no reports that provide a definitive description of modified procedures of THVE, especially the retrocaval liver lifting maneuver and oblique cranial cross-clamping that are described here for the first time. These techniques can be strategies to decrease the risk of disastrous bleeding and ischemic liver damage. Sharing these data with other surgeons will serve to increase the safety and feasibility of surgery for liver tumors involving IVC.

In conclusion, the retrocaval liver lifting maneuver and modifications of IVC cross-clamping are useful to attenuate damage related to THVE. The knowledge and techniques that have arisen from the current analysis of our case series may help to improve the surgical techniques and outcomes for advanced liver tumors involving IVC.

## COMMENTS

### Background

Total hepatic vascular exclusion (THVE) is needed during hepatectomy for liver tumors involving inferior vena cava (IVC). However, THVE carries a much greater risk than inflow occlusion alone.

### Research frontiers

The authors performed technical modifications that shortened the duration of THVE, thereby reducing the risk of damage.

### Innovations and breakthroughs

The technical modifications described in this study for THVE included the retrocaval liver lifting maneuver, switching of the cranial IVC cross-clamp, and oblique cranial IVC cross-clamping. With these techniques, the mean duration of THVE was shortened remarkably, compared to that reported in the past literature. Moreover, postoperative recovery of liver function was smooth without any severe complications.

### Applications

The retrocaval liver lifting maneuver and modifications of cranial cross-clamping minimized the duration of THVE. Thus, these techniques might help to decrease risk of liver damage and increase likelihood of favorable postoperative courses in patients who undergo hepatectomy requiring THVE.

### Terminology

THVE is a method to control bleeding during hepatectomy by occluding both inflow and outflow of the liver. THVE is required especially for resection of liver tumors involving IVC.

## Peer-review

The authors suggest some technical modifications of the THVE. The study is clearly planned and correctly managed. The technical details of the three variations are clearly explained as well as the figures.

## REFERENCES

- 1 **Azoulay D**, Andreani P, Maggi U, Salloum C, Perdigao F, Sebah M, Lemoine A, Adam R, Castaing D. Combined liver resection and reconstruction of the supra-renal vena cava: the Paul Brousse experience. *Ann Surg* 2006; **244**: 80-88 [PMID: 16794392 DOI: 10.1097/01.sla.0000218092.83675.bc]
- 2 **Azoulay D**, Pascal G, Salloum C, Adam R, Castaing D, Tranecol N. Vascular reconstruction combined with liver resection for malignant tumours. *Br J Surg* 2013; **100**: 1764-1775 [PMID: 24227362 DOI: 10.1002/bjs.9295]
- 3 **Madariaga JR**, Fung J, Gutierrez J, Bueno J, Iwatsuki S. Liver resection combined with excision of vena cava. *J Am Coll Surg* 2000; **191**: 244-250 [PMID: 10989898 DOI: 10.1016/S1072-7515(00)00362-8]
- 4 **Hemming AW**, Mekeel KL, Zendejas I, Kim RD, Sicklick JK, Reed AI. Resection of the liver and inferior vena cava for hepatic malignancy. *J Am Coll Surg* 2013; **217**: 115-124; discussion 124-125 [PMID: 23376028 DOI: 10.1016/j.jamcollsurg.2012.12.003]
- 5 **Heaney JP**, Stanton WK, Halbert DS, Seidel J, Vice T. An improved technic for vascular isolation of the liver: experimental study and case reports. *Ann Surg* 1966; **163**: 237-241 [PMID: 4286023 DOI: 10.1097/00000658-196602000-00013]
- 6 **Huguet C**, Nordlinger B, Galopin JJ, Bloch P, Gallot D. Normo-thermic hepatic vascular exclusion for extensive hepatectomy. *Surg Gynecol Obstet* 1978; **147**: 689-693 [PMID: 715645]
- 7 **Belghiti J**, Noun R, Zante E, Ballet T, Sauvanet A. Portal triad clamping or hepatic vascular exclusion for major liver resection. A controlled study. *Ann Surg* 1996; **224**: 155-161 [PMID: 8757378 DOI: 10.1097/00000658-199608000-00007]
- 8 **Emre S**, Schwartz ME, Katz E, Miller CM. Liver resection under total vascular isolation. Variations on a theme. *Ann Surg* 1993; **217**: 15-19 [PMID: 8424696 DOI: 10.1097/00000658-199301000-00004]
- 9 **Smyrniotis VE**, Kostopanagiotou GG, Gamaletsos EL, Vassiliou JG, Voros DC, Fotopoulos AC, Contis JC. Total versus selective hepatic vascular exclusion in major liver resections. *Am J Surg* 2002; **183**: 173-178 [PMID: 11918884 DOI: 10.1016/S0002-9610(01)00864-9]
- 10 **Dubay D**, Gallinger S, Hawryluck L, Swallow C, McCluskey S, McGilvray I. In situ hypothermic liver preservation during radical liver resection with major vascular reconstruction. *Br J Surg* 2009; **96**: 1429-1436 [PMID: 19918862 DOI: 10.1002/bjs.6740]
- 11 **Malde DJ**, Khan A, Prasad KR, Toogood GJ, Lodge JP. Inferior vena cava resection with hepatectomy: challenging but justified. *HPB (Oxford)* 2011; **13**: 802-810 [PMID: 21999594 DOI: 10.1111/j.1477-2574.2011.00364.x]
- 12 **Fu SY**, Lai EC, Li AJ, Pan ZY, Yang Y, Sun YM, Lau WY, Wu MC, Zhou WP. Liver resection with selective hepatic vascular exclusion: a cohort study. *Ann Surg* 2009; **249**: 624-627 [PMID: 19300226 DOI: 10.1097/SLA.0b013e31819ed212]
- 13 **Cherqui D**, Malassagne B, Colau PI, Brunetti F, Rotman N, Fagniez PL. Hepatic vascular exclusion with preservation of the caval flow for liver resections. *Ann Surg* 1999; **230**: 24-30 [PMID: 10400032 DOI: 10.1097/00000658-199907000-00004]
- 14 **Azoulay D**, Maggi U, Lim C, Malek A, Compagnon P, Salloum C, Laurent A. Liver resection using total vascular exclusion of the liver preserving the caval flow, in situ hypothermic portal perfusion and temporary porta-caval shunt: a new technique for central tumors. *Hepatobiliary Surg Nutr* 2014; **3**: 149-153 [PMID: 25019076 DOI: 10.3978/j.issn.2304-3881.2014.05.02]
- 15 **Lodge JP**, Ammori BJ, Prasad KR, Bellamy MC. Ex vivo and in situ resection of inferior vena cava with hepatectomy for colorectal

metastases. *Ann Surg* 2000; **231**: 471-479 [PMID: 10749606 DOI: 10.1097/00000658-200004000-00004]

16 **Belghiti J**, Guevara OA, Noun R, Saldinger PF, Kianmanesh R.

Liver hanging maneuver: a safe approach to right hepatectomy without liver mobilization. *J Am Coll Surg* 2001; **193**: 109-111 [PMID: 11442247 DOI: 10.1016/S1072-7515(01)00909-7]

**P- Reviewer:** Aurello P **S- Editor:** Gong ZM

**L- Editor:** A **E- Editor:** Liu SQ





Published by **Baishideng Publishing Group Inc**

8226 Regency Drive, Pleasanton, CA 94588, USA

Telephone: +1-925-223-8242

Fax: +1-925-223-8243

E-mail: [bpgoffice@wjgnet.com](mailto:bpgoffice@wjgnet.com)

Help Desk: <http://www.wjgnet.com/esps/helpdesk.aspx>

<http://www.wjgnet.com>

