

World Journal of *Hepatology*

World J Hepatol 2019 March 27; 11(3): 250-334



**MINIREVIEWS**

- 250 Update on management of gastric varices
Vine LJ, Subhani M, Acevedo JG
- 261 Hepatocellular carcinoma recurrence after liver transplantation: Risk factors, screening and clinical presentation
Filgueira NA

ORIGINAL ARTICLE**Basic Study**

- 273 Protective action of glutamine in rats with severe acute liver failure
Schemitt EG, Hartmann RM, Colares JR, Licks F, Salvi JO, Marroni CA, Marroni NP

Retrospective Cohort Study

- 287 Extreme hyperbilirubinemia: An indicator of morbidity and mortality in sickle cell disease
Haydek JP, Taborda C, Shah R, Reshamwala PA, McLemore ML, Rassi FE, Chawla S

Observational Study

- 294 Angiogenesis of hepatocellular carcinoma: An immunohistochemistry study
Fodor D, Jung I, Turdean S, Satala C, Gurzu S

Randomized Clinical Trial

- 305 Preoperative immunonutrition in patients undergoing liver resection: A prospective randomized trial
Russell K, Zhang HG, Gillanders LK, Bartlett AS, Fisk HL, Calder PC, Swan PJ, Plank LD

CASE REPORT

- 318 Intraperitoneal rupture of the hydatid cyst: Four case reports and literature review
Akbulut S, Ozdemir F

LETTER TO THE EDITOR

- 330 Persistent elevation of fibrosis biomarker cartilage oligomeric matrix protein following hepatitis C virus eradication
Andréasson K, Jönsson G, Hesselstrand R, Norrgren H

ABOUT COVER

Editor-in-Chief of *World Journal of Hepatology*, Koo Jeong Kang, MD, PhD, Professor, Division of Hepatobiliary Pancreatic Surgery, Department of surgery, Keimyung University Dong-San Medical Center, Daegu 41931, South Korea

AIMS AND SCOPE

World Journal of Hepatology (*World J Hepatol*, *WJH*, online ISSN 1948-5182, DOI: 10.4254), is a peer-reviewed open access academic journal that aims to guide clinical practice and improve diagnostic and therapeutic skills of clinicians.

The *WJH* covers topics concerning liver biology/pathology, cirrhosis and its complications, liver fibrosis, liver failure, portal hypertension, hepatitis B and C and inflammatory disorders, steatohepatitis and metabolic liver disease, hepatocellular carcinoma, etc. Priority publication will be given to articles concerning diagnosis and treatment of hepatology diseases. The following aspects are covered: Clinical diagnosis, laboratory diagnosis, etc.

We encourage authors to submit their manuscripts to *WJH*. We will give priority to manuscripts that are supported by major national and international foundations and those that are of great basic and clinical significance.

INDEXING/ABSTRACTING

The *WJH* is now abstracted and indexed in PubMed, PubMed Central, Emerging Sources Citation Index (Web of Science), Scopus, China National Knowledge Infrastructure (CNKI), China Science and Technology Journal Database (CSTJ), and Superstar Journals Database.

RESPONSIBLE EDITORS FOR THIS ISSUE

Responsible Electronic Editor: Yan-Liang Zhang Proofing Editorial Office Director: Ya-Juan Ma

NAME OF JOURNAL

World Journal of Hepatology

ISSN

ISSN 1948-5182 (online)

LAUNCH DATE

October 31, 2009

FREQUENCY

Monthly

EDITORS-IN-CHIEF

Ke-Qin Hu, Koo Jeong Kang, Nikolaos Pyrsopoulos

EDITORIAL BOARD MEMBERS

<https://www.wjnet.com/1948-5182/editorialboard.htm>

EDITORIAL OFFICE

Ya-Juan Ma, Director

PUBLICATION DATE

March 27, 2019

COPYRIGHT

© 2019 Baishideng Publishing Group Inc

INSTRUCTIONS TO AUTHORS

<https://www.wjnet.com/bpg/gerinfo/204>

GUIDELINES FOR ETHICS DOCUMENTS

<https://www.wjnet.com/bpg/GerInfo/287>

GUIDELINES FOR NON-NATIVE SPEAKERS OF ENGLISH

<https://www.wjnet.com/bpg/gerinfo/240>

PUBLICATION MISCONDUCT

<https://www.wjnet.com/bpg/gerinfo/208>

ARTICLE PROCESSING CHARGE

<https://www.wjnet.com/bpg/gerinfo/242>

STEPS FOR SUBMITTING MANUSCRIPTS

<https://www.wjnet.com/bpg/GerInfo/239>

ONLINE SUBMISSION

<https://www.f6publishing.com>



Update on management of gastric varices

Louisa J Vine, Mohsan Subhani, Juan G Acevedo

ORCID number: Louisa J Vine (0000-0002-5036-3972); Mohsan Subhani (0000-0001-8739-7263); Juan G Acevedo (0000-0003-4507-2422).

Author contributions: All authors contributed to the literature review, analyses, drafting, and critical revision of the manuscript.

Conflict-of-interest statement: All the authors declare no conflict of interest related to this publication.

Open-Access: This article is an open-access article which was selected by an in-house editor and fully peer-reviewed by external reviewers. It is distributed in accordance with the Creative Commons Attribution Non Commercial (CC BY-NC 4.0) license, which permits others to distribute, remix, adapt, build upon this work non-commercially, and license their derivative works on different terms, provided the original work is properly cited and the use is non-commercial. See: <http://creativecommons.org/licenses/by-nc/4.0/>

Manuscript source: Invited manuscript

Received: November 28, 2018

Peer-review started: December 3, 2018

First decision: January 8, 2019

Revised: February 20, 2019

Accepted: February 26, 2019

Article in press: February 27, 2019

Published online: March 27, 2019

P-Reviewer: Hernanda PY, Kao JT, Konishi H, Lo GH, Pallav K, Rodríguez-Perálvarez M

S-Editor: Cui LJ

L-Editor: A

Louisa J Vine, Mohsan Subhani, Juan G Acevedo, South West Liver Unit, University Hospitals Plymouth NHS Trust, Plymouth, PL68DH, United Kingdom

Corresponding author: Juan G Acevedo, PhD, Doctor, South West Liver Unit, University Hospitals Plymouth NHS Trust, Derriford Road, Plymouth, PL68DH, United Kingdom.

jacevedo@nhs.net

Telephone: +44-17-52432723

Fax: +44-17-52517576

Abstract

Gastric varices (GV) have different physiology and clinical characteristics compared to oesophageal varices (OV). There is little information about the management of GV. Most part of the recommendations is extrapolated from studies where the majority of participants had OV. Thus, most recommendations lack of strong evidence. This is a comprehensive review on all aspects of management of GV, *i.e.*, primary, secondary prophylaxis and management of acute bleeding. The papers on which international societies' recommendations are based are scrutinised in this review and areas of research are identified.

Key words: Gastric varices; Oesophageal varices; Portal hypertension; Cirrhosis

©The Author(s) 2019. Published by Baishideng Publishing Group Inc. All rights reserved.

Core tip: This review focuses on an area in Hepatology which needs updating due to the recent contradictory recommendations from different international societies, *i.e.*, American Association for the Study of Liver Disease, Baveno-VI and United Kingdom guidelines. Contradiction arises from lack of strong evidence. This comprehensive review analyses critically the key papers on which recommendations are based, and it also detects areas needing urgent research. There are also graphs and information which would help clinicians in their decision-making process.

Citation: Vine LJ, Subhani M, Acevedo JG. Update on management of gastric varices. *World J Hepatol* 2019; 11(3): 250-260

URL: <https://www.wjgnet.com/1948-5182/full/v11/i3/250.htm>

DOI: <https://dx.doi.org/10.4254/wjh.v11.i3.250>

E-Editor: Zhang YL



INTRODUCTION

Gastric varices (GV) are present in around 20% of patients with cirrhosis, portal hypertension and varices detected in the endoscopy^[1]. GV are quite different from oesophageal varices (OV), they are supplied by the short gastric, left gastric and polar renal veins and thus, they have different venous afferents compared to OV. GV bleed less frequently, but they bleed more significantly than OV. Bleeding from GV is less directly related to the degree of portal hypertension and more related to the size of the varix and wall tension.

In one large study, including 568 patients, GV were present in 20% at initial endoscopy with 9% of patients developing GV over a medium follow up period of 24.6 ± 5.3 mo, however this was after eradication of OV's the authors reported a mortality rate of 45%^[1]. In comparison, a more recent study reported the six-week mortality of bleeding GV as being only 16.7%^[2].

Another study reviewing 117 patients with fundal GV who had never bled showed that the cumulative risk for GV bleeding at 1, 3, and 5 years was 16%, 36%, and 44%, respectively with a total of 34/117 patients bleeding^[3]; this was higher than a later study of 604 patients which showed a cumulative incidence of GV bleeding at 4.8%, 19.9%, and 23.2% at 1, 3, and 5 years respectively^[4].

Currently, there is much more information on management of OV than on GV. Hence, most recommendations are based on expert opinions and not on evidence-based medicine.

CLASSIFICATION OF GV

According to their development before or after endoscopic/surgical intervention

Primary GV are present at the time of the initial endoscopy and before any endoscopic/surgical intervention, and secondary GV are those which appear after endoscopic/surgical intervention.

According with their anatomical site

There are four types^[1] (Figure 1). Gastroesophageal varices (GOV)-1; gastro-OV type-1 are OV extending beneath the cardia through the lesser curvature. They are the most common type of GV, comprising around 75% of all GV. They are almost always associated with large OV (92%).

GOV-2; gastro-OV type-2 are OV extending beneath the cardias through the fundus. They comprise around 21% of all GV and are associated with the presence of large OV in 50% of cases.

Isolated gastric varices (IGV)-1; isolated GV type 1 are not connected with OV and they are located on the fundus. They are seen in only 1.6% of patients with GV.

IGV-2; isolated GV type 2 are not connected with OV and are present in the stomach but not in the fundus. They are seen in 4.2% of patients with GV. This type of varices usually develops during or after endoscopic obliteration of oesophageal or GV, around 85% of the cases. In the other 15% of the cases portal vein thrombosis with or without liver cirrhosis is found. Most of these cases (59%) have other types of GV associated. Only 6% of these patients bleed during a mean follow up of 3 years^[5].

A new type has been recently proposed by Singh, around 11% of patients with oesophageal and GV who cannot be classified in any of the other types, *i.e.*, having OV and GV in the body, pylorus or antrum^[6]. Clinical characteristic of this new type of GV has not been investigated yet.

According to their size

They are classified in small (< 5 mm), medium (5 to 10 mm) and large (> 10 mm). GV are more common in segmental portal hypertension caused by portal/splenic vein thrombosis, than in generalized portal hypertension due to cirrhosis^[7]. This is probably due to a more direct transmission of increased portal pressure to the short and posterior GV. Fundal varices, *i.e.*, IVG-1 and GOV-2 type varices, are developed by dilation of short and posterior gastric veins and large gastro-renal shunts are usually present.

DEFINITION OF HAEMORRHAGE FROM GV

Bleeding from GV is diagnosed when (1) active bleeding from a gastric varix is seen in endoscopy, (2) a clot or ulcer is seen over the gastric varix, (3) in the presence of large GV, absence of OV, and no other cause for upper gastrointestinal bleeding detected.

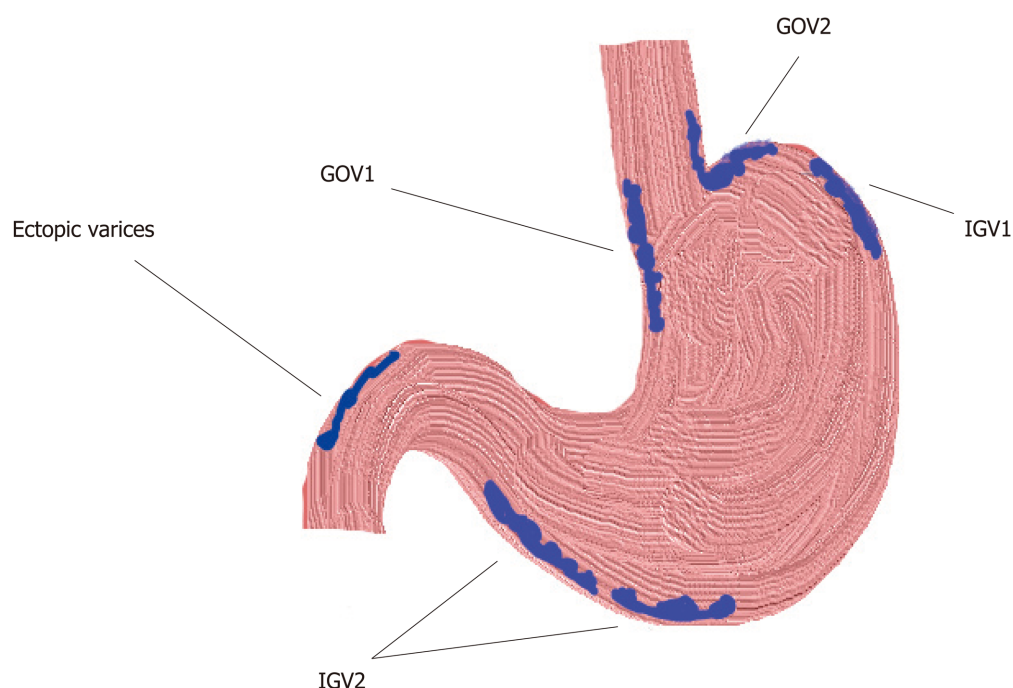


Figure 1 Classification of gastric varices according to their anatomical location within the stomach. GOV-1: Gastroesophageal varices type-1; GOV-2: Gastroesophageal varices type-2; IGV-1: Isolated gastric varices type-1; IGV-2: Isolated gastric varices type-2.

GOV2s bleed more frequently than GOV1s. Secondary GOV2s carry the worst prognosis, 38% of patients with this type of varices died of bleeding. IGV-1s bleed in a similar frequency as GOV2s, but are less frequently present^[1].

The main risk factors for bleeding are the degree of liver dysfunction, location, size, and presence of red spots on the varix^[3,8,9].

GV bleed less frequently than OV, but it seems GV bleed more severely than OV. The transfusion requirement is higher in gastric than in oesophageal variceal bleeding, 4.8 ± 0.6 vs 2.9 ± 0.3 transfusion unit/person, $P < 0.01$ ^[3].

PRIMARY PROPHYLAXIS

In view of the absence of data GOV1 should follow same guidelines as OV^[10] and thus, we are going to discuss the management of fundal varices only in this section.

There is only one trial assessing primary prophylaxis in patients with GV and it was a prospective study. Eighty-nine cirrhotic patients with high risk GV, *i.e.*, large (> 10 mm) and located in the fundus (GOV2/IGV1) were included. They had no history of gastrointestinal bleeding and no OV were present at diagnostic endoscopy. They were randomized to receive either cyanoacrylate injection until complete obliteration (Group I), or propranolol with a target heart rate of 55/min or maximal dose of 360 mg/d (Group II), or no treatment (Group III). The median follow-up period was 26 mo^[11,12] (Table 1).

This study showed that cyanoacrylate injection was superior to propranolol and to no therapy in preventing bleeding. Some experts recommend using non-selective beta-blockers (NSBB) as primary prophylaxis and avoiding cyanoacrylate injections because they consider this study very particular since it was conducted in a single expert centre and thus, it is considered not enough evidence to generalise its findings^[13,14]. Glue injection requires expertise which is not always available and the low complication rate in the study reflects the high skills of endoscopists who conducted the study, which is not widely reproducible. Moreover, data suggesting that carvedilol is more effective in reducing the hepatic venous pressure gradient (HVPG) may reduce the gap in efficacy between NSBB and cyanoacrylate injection. On the other hand, it is well known that bleeding from GV does not depend only on the HVPG, but also on the wall tension and size of the varix. Some experts refrain from issuing any recommendation in view of the lack of strong evidence^[10]. There is a clear need for research in this area.

Table 1 Risk of bleeding, mortality and complication rate according to treatment group^[11]

Characteristics	Cyanoacrylate Group I (n = 30)	Propranolol Group II (n = 29)	No treatment Group III (n = 30)	P value
GV bleed	10%	38%	53%	0.003
Bleed-related mortality	0	10%	24%	0.034
Overall mortality	7%	17%	26%	0.113
Complications	3%	3%	7%	1

SECONDARY PROPHYLAXIS

In view of the absence of data GOV1 should follow same guidelines as OV^[10] and thus, we are going to discuss management of fundal varices only in this section as well.

There is less evidence supporting prevention of re-bleeding in GV compared to OV. There have been trials testing NSBB, endoscopic injection of tissue adhesives, endoscopic band ligation (EBL), Transjugular Intrahepatic Portosystemic Shunt (TIPS), and Balloon-occluded Retrograde Transvenous Obliteration (BRTO). It is important to note that these studies included patients at the time of the index bleeding which could be confusing in terms of overlap with treatment of acute bleeding, but patients with uncontrolled bleeding were excluded. Therefore, all of participants had successful treatment of the acute bleeding.

Cyanoacrylate injection and beta-blockers

There are two prospective trials comparing NSBB versus glue injection alone and versus glue injection plus NSBB^[15,16].

The first study compared endoscopic injection of cyanoacrylate versus propranolol. Thirty-two patients were allocated in each group. All patients had portal hypertension secondary to liver cirrhosis and all had fundal varices, *i.e.*, GOV-2 with eradicated OV or patients with IGV-1, all of them were large, *i.e.*, at least 10mm in width. These types of GV have the highest risk of bleeding. Re-bleeding from GV was managed with TIPS or surgery in the cyanoacrylate group and with cyanoacrylate injection in the propranolol group. The fact that the two groups received different rescue therapies may be a bias affecting survival. Patients on the propranolol branch were monitored daily until the target dose was achieved. Afterwards, they were monitored every three months. Results showed that rate of re-bleeding and mortality were significantly lower in the cyanoacrylate group, 10% *vs* 44%, $P = 0.004$ and 3% *vs* 23%, $P = 0.023$ ^[15]. We must interpret these results with caution because all patients were enrolled shortly after GV bleeding but 77% of them did not receive endoscopic treatment to control the acute bleeding. Thus, an important part of the patients allocated to Beta-blocker group did not receive adequate endoscopic treatment for the episode of index bleeding while the patients allocated to the glue injection group did. This difference would be a disadvantage in the Beta-blocker group regarding re-bleeding rate.

The second study compared glue injection alone versus glue injection plus propranolol. Forty-eight and 47 patients were included in each group, respectively. The study showed similar re-bleeding rates between both groups, 54% *vs* 47%, $P = \text{NS}$. Mortality rate was also similar, 42% *vs* 47%, $P = \text{NS}$ ^[16]. Authors stated that these findings could be explained because portal hypertension may not be as critical as in OV^[17], and because most patients have segmental portal hypertension or gastro-renal portosystemic shunting. Patient in the beta-blocker group experienced more asthenia, 60% *vs* 23%, $P < 0.01$, but overall side effects were similar in both groups. Experts recommend eradication with cyanoacrylate injections as first line therapy^[14].

TIPS and histoacryl® injection

Histoacryl® is monomeric n-butyl-2-cyanoacrylate. One prospective study compared both treatments in patients with cirrhosis and gastric variceal bleeding. Participants were selected at the time of index bleeding from GV. Patients bleeding from OV were excluded. Patients with severe decompensation of cirrhosis were also excluded. Acute bleeding was treated with somatostatin and glue injection initially. Thirty-five patients were allocated to TIPS and 37 to cyanoacrylate injections. Re-bleeding from GV was lower in the TIPS group, 11% *vs* 38%, $P = 0.014$. Nevertheless, upper GI bleeding and 2-year survival were similar between both groups: 43% *vs* 59% and 70% *vs* 83%, respectively^[18]. The lack of impact on mortality may be attributed to the increased rate of hepatic encephalopathy and to liver dysfunction in the TIPS group, two of the patients in the TIPS group developed liver failure. According to the authors, there was some delay in elective treatment. In fact, two episodes of gastric variceal bleeding occurred between randomization and elective treatment. Moreover,

the high rate of re-bleeding in the Histoacryl® group could be related to the non-compliance of some patients and to the low dose injected at each session. Furthermore, some of the bleeding episodes attributed to GV were ulcers post glue injection and not to portal hypertension. Those patients were started on proton pump inhibitors only when an ulcer was diagnosed during endoscopic follow-up and not as standard prophylaxis. Finally, half of the patients included in this study had GOV1 which clinical characteristics are similar to OV and not to fundal varices (GOV2 and IGV1). There is a clear need of research in this area.

Thrombin injection and BRTO have been evaluated only in the acute bleeding setting, but no as prophylactic treatment.

MANAGEMENT OF ACTIVE BLEEDING

Multiple guidelines are available that discuss the management of active variceal bleeding, these include the American Association for the Study of Liver Disease 2016 guidelines^[13], the British Society of Gastroenterology (BSG) 2015 guidelines^[14], and the 2015 International consensus statement (Baveno VI)^[10].

The main stay of treatment for gastric variceal bleeding is initially similar to that of oesophageal variceal bleeding and is based on good fluid resuscitation, correction of coagulopathies, early pharmacological treatments with antibiotics and vasoactive medications and early endoscopic intervention. Radiological management, balloon tamponade and surgical management are typically reserved for those who fail to achieve haemostasis with endoscopic and pharmacological therapy; although the early use of interventional radiological procedures is likely to play a greater role in the management of gastric variceal bleeding^[10].

Restoration of circulating volume should be achieved whilst avoiding over transfusion to prevent a rebound of portal hypertension and precipitate re-bleeding. A recent study showed that a restrictive transfusion policy to a haemoglobin of 7-8 g/dL resulted in better outcomes and less complications^[19]. With regards to coagulopathies the BSG guidelines suggest a platelet transfusion if the count is below $< 50 \times 10^9/L$ and fresh frozen plasma to be used for patients with a fibrinogen level of $< 1 \text{ g/L}$ or clotting derangement > 1.5 times greater than normal^[14]. Although, in contrast, the Baveno Consensus statement feel that recommendations regarding coagulopathy and thrombocytopenia could not be made on the basis of currently available data^[10]. We would suggest that correction of coagulopathies be based on local guidelines and patient factors such as the severity of the bleeding and their comorbidities.

Pharmacological treatments for active gastric variceal bleeding

Initial management of GV bleed should include early use of pharmacological agents in the form of prophylactic antibiotics and vasoactive drugs and these should be initiated at an early stage^[10].

Antibiotics: Prophylactic antibiotics should be given to all patients with variceal bleeding to decrease the risk of bacterial infections and improve survival and is recommended in all of the prior mention guidelines and consensus. Antibiotics of choice are those that are active against enteric bacteria of which Cephalosporins are the most widely used and studied. Data was first published in 1985 showing prophylactic antibiotics reduced the rate of infections in patients with cirrhosis and variceal bleeding^[20] and multiple studies and meta-analysis since have confirmed this^[21]. Moreover, other studies showed that re-bleeding rates are lower after the use of prophylactic antibiotics^[22]. No studies have been published looking specifically at antibiotic therapy solely in GV haemorrhage but many studies discussed variceal bleeding without differentiating between OV and GV bleeding.

A 2011 meta-analysis of 12 trials including 1241 patients looked at antibiotic prophylaxis against placebo/no antibiotic prophylaxis in patients with cirrhosis and upper gastro intestinal bleeding and reported that antibiotic prophylaxis was associated with reduced mortality (RR 0.79, 95%CI: 0.63-0.98), reduced bacterial infections (RR 0.35, 95%CI: 0.26-0.47), reduced re-bleeding (RR 0.53, 95%CI: 0.38-0.74) and shorter length of stay (MD -1.91, 95%CI: -3.80-0.02)^[23]. No note was made of whether any of these trials looked purely at GV bleeding and in fact, some trials included non-variceal haemorrhage.

A current Cochrane review protocol has been published in November 2018 stating the aim of reviewing the role of antibiotics in patients with cirrhosis and variceal bleeding^[24].

The choice of antibiotics should be guided by local microbiology advice and guidelines and take into account the prevalence of local resistance, the prior use of

prophylactic antibiotics and other external facts, for example norfloxacin is no longer available in the United States nor in the United Kingdom.

Vasoactive medications: Vasoactive drugs decrease the portal venous blood flow. They include vasopressin and its analogue terlipressin, and somatostatin and its analogue octreotide. Their use is recommended in all major guidelines although again, it must be noted that no studies have looked purely at the use of vasoactive medication in GV bleeding^[10,13,14].

In 2012, a meta-analysis of 30 trials including 3111 patients showed that the use of vasoactive agents was associated with a significantly lower risk of 7-d mortality (RR 0.74; 95%CI: 0.57-0.95), an improvement in haemostasis (RR 1.21, 95%CI: 1.13-1.30), less transfusions requirement (pooled mean difference -0.70 units of blood transfused, 95%CI: -1.01 to -0.38;) and a shorter duration of hospitalisation (pooled mean difference -0.71 d; 95%CI: -1.23 to -0.19). They reported that studies comparing different vasoactive agents did not show a difference in efficacy, although the quality of evidence was very low^[25].

Terlipressin is a synthetic analogue of vasopressin that is administered as intermittent injections. In a meta-analysis it showed lower risk of complications compared to vasopressin^[26]. It is currently not licensed for use in the United States but is the preferred medication of choice outside of the United States. A Cochrane review in 2003 showed that terlipressin was the only medication to reduce mortality^[27].

Endoscopic management

Studies reviewing the endoscopic management of GV bleeding are limited compared to those related to OV bleeding interventions; however, endoscopy intervention is still the main stay of treatment and should be offered to all patients with suspected severe variceal bleed immediately after resuscitation or for more stable patients within 24 h^[14].

Tissue adhesives: Endoscopic therapies that have been studied include tissues adhesives mainly cyanoacrylate glues but also fibrin and thrombin therapy, EBL and sclerosants including alcohol; with the use of tissue adhesive being considered as first-choice treatment in most parts of the world.

Sclerosing agents including alcohol have been used with varying success in GV bleeding, often with high re-bleeding rates^[28] and the most current ASGE guidelines on sclerosing agents, whilst focusing mainly on their use in OV's, suggest their use should be limited but may be considered in some circumstances such as treating OGV combined with EBL^[29].

Only a small number of studies could be found looking at EBL for active GV bleeding and often with low numbers of participants. One study reported a series of 27 patients with GV, with active bleeding in 18 patients, EBL achieved haemostasis in 16 of the 18 patients (88.8%). However, recurrent bleeding was noted in five of the 27 patients (18.5%)^[30]. Another study reported 22 patients with active bleeding from GV treated with EBL; all patients achieved initial haemostasis and there was no immediate complication; however, four patients (18.2%) developed early re-bleeding^[31].

One randomised study looked at the use of tissue adhesive versus EBL for acute GV bleeding and whilst both interventions were as effective at controlling the initial bleed, the use of glue was associated with lower re-bleeding rates^[32].

A meta-analysis of tissue adhesive versus EBL for active GV bleeding, only including three suitable trials with 194 patients, reported that control of bleeding was achieved in 93.9% of patients treated with tissue adhesive versus 79.5% in the EBL groups ($P = 0.032$). Re-bleeding rate was comparable in GOV2 between the 2 interventions (35.7% *vs* 34.8%, $P = 0.895$), but cyanoacrylate use was superior at reducing re-bleeding rates in GOV1 and IGV1^[33]. They concluded that tissue adhesives were superior but that in places where it was not available EBL could still be a useful treatment option.

With regards to tissue adhesives cyanoacrylates glues are the commonest used and are a group of synthetic glues that solidify rapidly on contact with weak bases *i.e.*, water and blood. They are often mixed with lipiodol, any oily emulsion, to slow their rate of solidification thus reducing the chance of inadvertent adherence to the endoscope or catheter and also allowing imaging visualisation of the glue after injection in the case of complications and distal embolization.

ASGE reports that cyanoacrylates use has an initial haemostasis rates in the region of 80%-90% and that tissue adhesive is superior to sclerotherapy or EBL for control of GV haemorrhage^[34]. Higher rates of haemostasis have been reported in many studies ranging from 91%-100% with re-bleeding rates ranging from 7% to 28%^[35,36]. The Baveno consensus and the BSG guidelines recommend the use of tissue adhesives

such as N-butyl cyanoacrylate in the use of GV bleeding^[10,14].

Other tissues adhesives include thrombin which is a human or bovine protein that affects haemostasis by converting fibrinogen to a fibrin clot. There are no controlled trials looking at its use but one case series looked at 37 patients and reported that human thrombin was an effective treatment for active GV bleeding but re-bleeding occurred in 4 patients^[37]. Other case series would suggest its use is safe and effective with low side effect profile but with repeated interventions sometimes needed^[38,39].

Hemospray: TC-325 (Hemospray, Cook Medical, Winston-Salem, North Carolina, United States) is a haemostatic powder which becomes cohesive and adhesive when gets in contact with blood or tissue in the GI tract, forming an effective mechanical barrier covering the bleeding site and thus, achieving quick haemostasis. Its effect lasts approximately 24 hours, because the haemostatic layer sloughs off. Currently, it is only licensed for the treatment of non-variceal Upper GI bleed. However, two recent studies by Ibrahim *et al* have shown that Hemospray could be employed in active variceal bleeding as a bridge to a definitive treatment^[40,41].

The first study^[40] was a single arm prospective study on 38 patients admitted with acute variceal bleed from oesophageal or GV (GV were present in 10% and IGV2 were present in 6.6%). Gastroscopy was performed within 6 hours of admission after hemodynamic stabilization to confirm acute variceal bleeding and Hemospray was applied as primary measure. Clinical haemostasis was achieved in 29 of 30 (96.7%). Only 13 of 30 patients (43.4%) had active bleeding at the time of endoscopy. A follow up endoscopy was performed within 24 h for definitive treatment with either banding or cyanoacrylate injection.

The second study^[41] was a recent prospective, randomized study including 86 patients with active variceal bleeding from oesophageal or GV who were randomly allocated to early endoscopy (within 2 h) with application of hemospray plus pharmacological therapy or to a group who received pharmacological therapy alone. The authors showed higher haemostasis rate at the time of definitive endoscopy (within 12-24 h) and lower mortality rate in the intervention group. The authors concluded that hemospray could be employed as a bridge to definitive intervention in remote centres where the expertise to apply banding/glue injection is not easily available but the one to apply hemospray is. Probably, this recommendation is applicable to a minor proportion of centres. Moreover, their findings may suggest that earlier endoscopic intervention is better, regardless of the type of intervention, especially if the medical treatment is not the recommended first line option, they used octreotide instead of terlipressin.

There was also an anecdotic report employing Hemospray as a rescue therapy of actively bleeding gastric varix after failure of cyanoacrylate injection^[42]. Currently, there is still little evidence to support the routine use of Hemospray in the management of active variceal bleeding.

Rescue measures

Balloon tamponade: Balloon tamponade is an effective short-term measure to achieve control of bleeding; however, due to the observed complication rates and the high risk of re-bleeding once the balloon is deflated this measure should be considered a temporary measure until definitive control of the bleeding can be achieved.

The use of balloon tamponade was first described as early as 1930 by Westphal but was named as Sengstaken-Blakemore (SB) tube in after the Sengstaken and Blakemore paper in 1950. Three tubes are available, the SB tube, which has two balloons, gastric and oesophageal, and a gastric suction port, the Minnesota tube (a modified SB tube with the addition of an oesophageal suction port to try and prevent aspiration), and the Linton- Nachlas tube, which has a single gastric balloon, but of larger volume and a gastric suction port only. Their use has decreased over time as endoscopic and pharmacological measures improve outcomes and remove the need for balloon tamponade^[43].

Most studies regarding balloon tamponade relate to OV bleeding^[44] or do not differentiate between OV and GV bleeding, however one study found initial success rates of 88% with the use of balloon tamponade in GV (*vs* 91.5% in OV bleeding) whilst their reported complication rate was 10% and mainly related to aspiration^[45].

Complications of balloon tamponade relate normally to misplacement of the tube or pressure effects from over inflation or the balloon being inflated for too long. Complications include oesophageal ulceration, necrosis and rupture and aspiration pneumonia^[46] and consequently their use is recommended to be limited to temporary control until more definitive management can be put in place^[14].

TIPS: It is widely used as a salvage option for GV bleeding and is increasingly used as first line treatment, especially in the United States and Europe whilst BRTO remains

more commonly used in the Eastern countries.

TIPS was first shown to be successful for GV bleeding in a 1998 study that showed outcomes for TIPS in acute GV versus OV bleeding was equal with haemostasis being achieved in all but one patient. Re-bleeding occurred in 4/28 patients due to shunt thrombosis or occlusion, which the authors report was easily diagnosed and managed. The study therefore established the role of TIPS as a rescue procedure in management of uncontrolled GV^[47].

Investigating the role of TIPS in GV remains difficult as many studies do not distinguish OV from GV bleeding and some pivotal studies in TIPS exclude patients with isolated GV bleeding^[48]. Due to severe hepatic dysfunction often patients are not TIPS candidates and TIPS is not available in all centres thus the use of cyanoacrylate glue may be the only viable option for control of the haemorrhage.

A single centre study that showed in cyanoacrylate glue *vs* TIPS there was no difference in re-bleeding rates but noted that patients treated with glue therapy had significantly less long-term morbidity than the TIPS patients^[49] and this was again reported in a retrospective review in 2015 comparing cyanoacrylate glue with TIPS which noted no difference in re-bleeding rates and mortality^[50].

BRTO: BRTO is an interventional radiology technique which accessed the GV via a gastroduodenal shunt, which is occluded with a balloon while the sclerosant agent is injected in the GV. There has been a series of retrospective reports, but no prospective trial has been conducted so far. Early reports showed it was a feasible procedure^[51]. Technical success is high and it is an effective method when employed as prophylaxis^[52] and also in the acute setting^[53]. The main side effects include the development of new or progression of pre-existing OV, vascular damage or migration of the sclerosant agent when the balloon is inadvertently displaced. When BRTO is compared with TIPS it seems that BRTO is equally effective^[54] or even superior than TIPS^[55], but the evidence is based only on retrospective series of patients and thus, these results cannot be generalized. There has been a recent meta-analysis based on six studies comparing TIPS *vs* BRTO which showed a decrease in mortality rate in the BRTO compared to the TIPS group (RR 0.44, 95%CI: 0.35-0.56, $P < 0.01$). It also showed BRTO group had lower re-bleeding risk (RR 0.38, 95%CI: 0.24-0.59, $P < 0.01$) and lower encephalopathy risk (RR: 0.07, 95%CI: 0.03-0.16, $P < 0.01$)^[56].

The current recommendation for BRTO is to be applied as a rescue therapy when TIPS is contraindicated, such as in cases of advanced liver failure or hepatic encephalopathy. Nevertheless, a gastroduodenal shunt must be present to use BRTO.

Surgery: It is applicable only in highly specialised centres and consists of selective shunts in carefully selected patients, with well-preserved synthetic function, otherwise risk of complications is unacceptably high^[57]. In cases of segmental portal hypertension, splenectomy could be considered^[7] (Figure 2).

CONCLUSION

There is little literature regarding management of GV compared with the abundant quantity published on OV. Most recommendations for the management of acute bleeding are extrapolated from trials including mainly patients with OV bleeding and only a small proportion with GV. In fundal varices (*i.e.*, GOV2 and IGV1) management with cyanoacrylate injections is the preferred option leaving TIPS or BRTO as a rescue therapy. With regards to prophylaxis, there is not enough evidence on secondary prophylaxis and even less on primary prophylaxis to make strong recommendations. Probably, cyanoacrylate injection has a role in both primary and secondary prophylaxis, but most experts prefer to suggest NSBB in primary prophylaxis as they are less invasive and easily accessible. There is still a wide area for research in GV therapy.

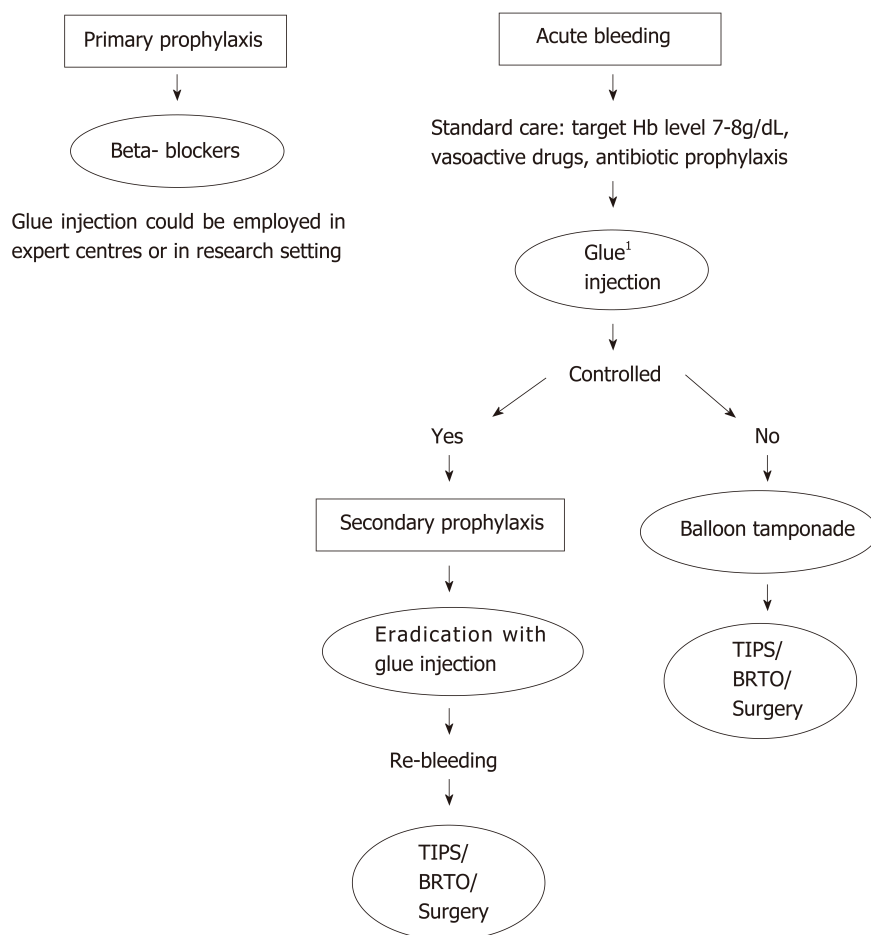


Figure 2 Algorithm of management of gastric varices: Primary prophylaxis, acute bleeding and secondary prophylaxis.¹Patients with gastroesophageal varices (GOV)-1 or GOV2 extending close to the cardias may be treated with endoscopic band ligation if the varix diameter is smaller than the diameter of the cap of the ligation device. Hb: Haemoglobin; TIPS: Transjugular intrahepatic portosystemic shunt; BRTO: Balloon-occluded retrograde transvenous obliteration.

REFERENCES

- 1 Sarin SK, Lahoti D, Saxena SP, Murthy NS, Makwana UK. Prevalence, classification and natural history of gastric varices: a long-term follow-up study in 568 portal hypertension patients. *Hepatology* 1992; **16**: 1343-1349 [PMID: 1446890 DOI: 10.1002/hep.1840160607]
- 2 Teng W, Chen WT, Ho YP, Jeng WJ, Huang CH, Chen YC, Lin SM, Chiu CT, Lin CY, Sheen IS. Predictors of mortality within 6 weeks after treatment of gastric variceal bleeding in cirrhotic patients. *Medicine (Baltimore)* 2014; **93**: e321 [PMID: 25546678 DOI: 10.1097/MD.0000000000000321]
- 3 Kim T, Shijo H, Kokawa H, Tokumitsu H, Kubara K, Ota K, Akiyoshi N, Iida T, Yokoyama M, Okumura M. Risk factors for hemorrhage from gastric fundal varices. *Hepatology* 1997; **25**: 307-312 [PMID: 9021939 DOI: 10.1053/jhep.1997.v25.pm0009021939]
- 4 Lee CH, Lee JH, Choi YS, Paik SW, Sinn DH, Lee CY, Koh KC, Gwak GY, Choi MS, Yoo BC. Natural history of gastric varices and risk factors for bleeding. *Korean J Hepatol* 2008; **14**: 331-341 [PMID: 18815456 DOI: 10.3350/kjhep.2008.14.3.331]
- 5 Sarin SK, Jain AK, Lamba GS, Gupta R, Chowdhary A. Isolated gastric varices: prevalence, clinical relevance and natural history. *Dig Surg* 2003; **20**: 42-47 [PMID: 12637804 DOI: 10.1159/000068865]
- 6 Verma N, Kumari S, Kumari P, De A, Singh V. New classification of gastric varices: a twenty-year experience. *J Hepatol* 2017; **66**: S543-S750 [DOI: 10.1016/S0168-8278(17)31540-4]
- 7 Madsen MS, Petersen TH, Sommer H. Segmental portal hypertension. *Ann Surg* 1986; **204**: 72-77 [PMID: 3729585]
- 8 Komori K, Kubokawa M, Ihara E, Akahoshi K, Nakamura K, Motomura K, Masumoto A. Prognostic factors associated with mortality in patients with gastric fundal variceal bleeding. *World J Gastroenterol* 2017; **23**: 496-504 [PMID: 28210086 DOI: 10.3748/wjg.v23.i3.496]
- 9 Triantafyllou M, Stanley AJ. Update on gastric varices. *World J Gastrointest Endosc* 2014; **6**: 168-175 [PMID: 24891929 DOI: 10.4253/wjge.v6.i5.168]
- 10 de Franchis R, Baveno VI Faculty. Expanding consensus in portal hypertension: Report of the Baveno VI Consensus Workshop: Stratifying risk and individualizing care for portal hypertension. *J Hepatol* 2015; **63**: 743-752 [PMID: 26047908 DOI: 10.1016/j.jhep.2015.05.022]
- 11 Mishra SR, Sharma BC, Kumar A, Sarin SK. Primary prophylaxis of gastric variceal bleeding comparing cyanoacrylate injection and beta-blockers: a randomized controlled trial. *J Hepatol* 2011; **54**: 1161-1167

- [PMID: 21145834 DOI: 10.1016/j.jhep.2010.09.031]
- 12 **Tripathi D.** Primary prophylaxis against gastric variceal bleeding: is there a sticky solution at last? *Hepatology* 2011; **54**: 1094-1096 [PMID: 22179988 DOI: 10.1002/hep.24499]
 - 13 **Garcia-Tsao G,** Abraldes JG, Berzigotti A, Bosch J. Portal hypertensive bleeding in cirrhosis: Risk stratification, diagnosis, and management: 2016 practice guidance by the American Association for the study of liver diseases. *Hepatology* 2017; **65**: 310-335 [PMID: 27786365 DOI: 10.1002/hep.28906]
 - 14 **Tripathi D,** Stanley AJ, Hayes PC, Patch D, Millson C, Mehrzad H, Austin A, Ferguson JW, Olliff SP, Hudson M, Christie JM; Clinical Services and Standards Committee of the British Society of Gastroenterology. U.K. guidelines on the management of variceal haemorrhage in cirrhotic patients. *Gut* 2015; **64**: 1680-1704 [PMID: 25887380 DOI: 10.1136/gutjnl-2015-309262]
 - 15 **Mishra SR,** Chander Sharma B, Kumar A, Sarin SK. Endoscopic cyanoacrylate injection versus beta-blocker for secondary prophylaxis of gastric variceal bleed: a randomised controlled trial. *Gut* 2010; **59**: 729-735 [PMID: 20551457 DOI: 10.1136/gut.2009.192039]
 - 16 **Hung HH,** Chang CJ, Hou MC, Liao WC, Chan CC, Huang HC, Lin HC, Lee FY, Lee SD. Efficacy of non-selective β -blockers as adjunct to endoscopic prophylactic treatment for gastric variceal bleeding: a randomized controlled trial. *J Hepatol* 2012; **56**: 1025-1032 [PMID: 22266602 DOI: 10.1016/j.jhep.2011.12.021]
 - 17 **Tripathi D,** Therapondos G, Jackson E, Redhead DN, Hayes PC. The role of the transjugular intrahepatic portosystemic stent shunt (TIPSS) in the management of bleeding gastric varices: clinical and haemodynamic correlations. *Gut* 2002; **51**: 270-274 [PMID: 12117893 DOI: 10.1136/gut.51.2.270]
 - 18 **Lo GH,** Liang HL, Chen WC, Chen MH, Lai KH, Hsu PI, Lin CK, Chan HH, Pan HB. A prospective, randomized controlled trial of transjugular intrahepatic portosystemic shunt versus cyanoacrylate injection in the prevention of gastric variceal rebleeding. *Endoscopy* 2007; **39**: 679-685 [PMID: 17661241 DOI: 10.1055/s-2007-966591]
 - 19 **Villanueva C,** Colomo A, Bosch A. Transfusion for acute upper gastrointestinal bleeding. *N Engl J Med* 2013; **368**: 1362-1363 [PMID: 23550677 DOI: 10.1056/NEJMoa1211801]
 - 20 **Rimola A,** Bory F, Teres J, Perez-Ayuso RM, Arroyo V, Rodes J. Oral, nonabsorbable antibiotics prevent infection in cirrhotics with gastrointestinal hemorrhage. *Hepatology* 1985; **5**: 463-467 [PMID: 3873389]
 - 21 **Fernández J,** Acevedo J. New antibiotic strategies in patients with cirrhosis and bacterial infection. *Expert Rev Gastroenterol Hepatol* 2015; **9**: 1495-1500 [PMID: 26465070 DOI: 10.1586/17474124.2015.1100075]
 - 22 **Hou MC,** Lin HC, Liu TT, Kuo BI, Lee FY, Chang FY, Lee SD. Antibiotic prophylaxis after endoscopic therapy prevents rebleeding in acute variceal hemorrhage: a randomized trial. *Hepatology* 2004; **39**: 746-753 [PMID: 14999693 DOI: 10.1002/hep.20126]
 - 23 **Chavez-Tapia NC,** Barrientos-Gutierrez T, Tellez-Avila FI, Soares-Weiser K, Uribe M. Antibiotic prophylaxis for cirrhotic patients with upper gastrointestinal bleeding. *Cochrane Database Syst Rev* 2010; CD002907 [PMID: 20824832 DOI: 10.1002/14651858.CD002907.pub2]
 - 24 **Sanchez-Jimenez B,** Chavez-Tapia NC, Jakobsen JC. Cochrane Database of Systematic Reviews. Antibiotic prophylaxis versus placebo or no intervention for people with cirrhosis and variceal bleeding Cochrane Systematic Review. [Accessed 08 November 2018] Intervention. Protocol Version [DOI: 10.1002/14651858.CD013214]
 - 25 **Wells M,** Chande N, Adams P, Beaton M, Levstik M, Boyce E, Mrkobrada M. Meta-analysis: vasoactive medications for the management of acute variceal bleeds. *Aliment Pharmacol Ther* 2012; **35**: 1267-1278 [PMID: 22486630 DOI: 10.1111/j.1365-2036.2012.05088.x]
 - 26 **Zhou X,** Tripathi D, Song T, Shao L, Han B, Zhu J, Han D, Liu F, Qi X. Terlipressin for the treatment of acute variceal bleeding: A systematic review and meta-analysis of randomized controlled trials. *Medicine (Baltimore)* 2018; **97**: e13437 [PMID: 30508958 DOI: 10.1097/MD.00000000000013437]
 - 27 **Ioannou G,** Doust J, Rockey DC. Terlipressin for acute esophageal variceal hemorrhage. *Cochrane Database Syst Rev* 2003; CD002147 [PMID: 12535432 DOI: 10.1002/14651858.CD002147]
 - 28 **Trudeau W,** Prindiville T. Endoscopic injection sclerosis in bleeding gastric varices. *Gastrointest Endosc* 1986; **32**: 264-268 [PMID: 3488937]
 - 29 **Hwang JH,** Shergill AK, Acosta RD, Chandrasekhara V, Chathadi KV, Decker GA, Early DS, Evans JA, Fanelli RD, Fisher DA, Foley KQ, Fonkalsrud L, Jue T, Khashab MA, Lightdale JR, Muthusamy VR, Pasha SF, Saltzman JR, Sharaf R, Cash BD; American Society for Gastrointestinal Endoscopy. The role of endoscopy in the management of variceal hemorrhage. *Gastrointest Endosc* 2014; **80**: 221-227 [PMID: 25034836 DOI: 10.1016/j.gie.2013.07.023]
 - 30 **Shiha G,** El-Sayed SS. Gastric variceal ligation: a new technique. *Gastrointest Endosc* 1999; **49**: 437-441 [PMID: 10202055]
 - 31 **Lee TH,** Shih LN. Clinical experience of endoscopic banding ligation for bleeding gastric varices. *Hepatogastroenterology* 2008; **55**: 766-769 [PMID: 18613450]
 - 32 **Tan PC,** Hou MC, Lin HC, Liu TT, Lee FY, Chang FY, Lee SD. A randomized trial of endoscopic treatment of acute gastric variceal hemorrhage: N-butyl-2-cyanoacrylate injection versus band ligation. *Hepatology* 2006; **43**: 690-697 [PMID: 16557539 DOI: 10.1002/hep.21145]
 - 33 **Qiao W,** Ren Y, Bai Y, Liu S, Zhang Q, Zhi F. Cyanoacrylate Injection Versus Band Ligation in the Endoscopic Management of Acute Gastric Variceal Bleeding: Meta-Analysis of Randomized, Controlled Studies Based on the PRISMA Statement. *Medicine (Baltimore)* 2015; **94**: e1725 [PMID: 26469912 DOI: 10.1097/MD.0000000000001725]
 - 34 **ASGE Technology Committee.** Bhat YM, Banerjee S, Barth BA, Chauhan SS, Gottlieb KT, Konda V, Maple JT, Murad FM, Pfau PR, Pleskow DK, Siddiqui UD, Tokar JL, Wang A, Rodriguez SA. Tissue adhesives: cyanoacrylate glue and fibrin sealant. *Gastrointest Endosc* 2013; **78**: 209-215 [PMID: 23867370 DOI: 10.1016/j.gie.2013.04.166]
 - 35 **Franco MC,** Gomes GF, Nakao FS, de Paulo GA, Ferrari AP, Libera ED. Efficacy and safety of endoscopic prophylactic treatment with undiluted cyanoacrylate for gastric varices. *World J Gastrointest Endosc* 2014; **6**: 254-259 [PMID: 24932378 DOI: 10.4253/wjge.v6.i6.254]
 - 36 **Kang EJ,** Jeong SW, Jang JY, Cho JY, Lee SH, Kim HG, Kim SG, Kim YS, Cheon YK, Cho YD, Kim HS, Kim BS. Long-term result of endoscopic Histoacryl (N-butyl-2-cyanoacrylate) injection for treatment of gastric varices. *World J Gastroenterol* 2011; **17**: 1494-1500 [PMID: 21472110 DOI: 10.3748/wjg.v17.i11.1494]
 - 37 **McAvoy NC,** Plevris JN, Hayes PC. Human thrombin for the treatment of gastric and ectopic varices. *World J Gastroenterol* 2012; **18**: 5912-5917 [PMID: 23139607 DOI: 10.3748/wjg.v18.i41.5912]
 - 38 **Ramesh J,** Limdi JK, Sharma V, Makin AJ. The use of thrombin injections in the management of bleeding

- gastric varices: a single-center experience. *Gastrointest Endosc* 2008; **68**: 877-882 [PMID: [18534583](#) DOI: [10.1016/j.gie.2008.02.065](#)]
- 39 **Jhajharia A**, Wanjari SJ, Ashdhir P, Pokharna R, Nijhawan S. Role and safety of human thrombin injection for the treatment of bleeding gastric varices. *Indian J Gastroenterol* 2018; **37**: 321-325 [PMID: [30196518](#) DOI: [10.1007/s12664-018-0877-2](#)]
 - 40 **Ibrahim M**, El-Mikkawy A, Abdalla H, Mostafa I, Devière J. Management of acute variceal bleeding using hemostatic powder. *United European Gastroenterol J* 2015; **3**: 277-283 [PMID: [26137303](#) DOI: [10.1177/2050640615570148](#)]
 - 41 **Ibrahim M**, El-Mikkawy A, Abdel Hamid M, Abdalla H, Lemmers A, Mostafa I, Devière J. Early application of haemostatic powder added to standard management for oesophagogastric variceal bleeding: a randomised trial. *Gut* 2018 [PMID: [29730601](#) DOI: [10.1136/gutjnl-2017-314653](#)]
 - 42 **Holster IL**, Poley JW, Kuipers EJ, Tjwa ET. Controlling gastric variceal bleeding with endoscopically applied hemostatic powder (Hemospray™). *J Hepatol* 2012; **57**: 1397-1398 [PMID: [22864337](#) DOI: [10.1016/j.jhep.2012.07.024](#)]
 - 43 **Carbonell N**, Pauwels A, Serfaty L, Fourdan O, Lévy VG, Poupon R. Improved survival after variceal bleeding in patients with cirrhosis over the past two decades. *Hepatology* 2004; **40**: 652-659 [PMID: [15349904](#) DOI: [10.1002/hep.20339](#)]
 - 44 **Sarin SK**, Nundy S. Balloon tamponade in the management of bleeding oesophageal varices. *Ann R Coll Surg Engl* 1984; **66**: 30-32 [PMID: [6607022](#)]
 - 45 **Panés J**, Terés J, Bosch J, Rodés J. Efficacy of balloon tamponade in treatment of bleeding gastric and esophageal varices. Results in 151 consecutive episodes. *Dig Dis Sci* 1988; **33**: 454-459 [PMID: [3280273](#)]
 - 46 **Cook D**, Laine L. Indications, technique, and complications of balloon tamponade for variceal gastrointestinal bleeding. *J Intensive Care Med* 1992; **7**: 212-218 [PMID: [10147943](#) DOI: [10.1177/088506669200700408](#)]
 - 47 **Chau TN**, Patch D, Chan YW, Nagral A, Dick R, Burroughs AK. "Salvage" transjugular intrahepatic portosystemic shunts: gastric fundal compared with esophageal variceal bleeding. *Gastroenterology* 1998; **114**: 981-987 [PMID: [9558287](#)]
 - 48 **García-Pagán JC**, Caca K, Bureau C, Laleman W, Appenrodt B, Luca A, Abraldes JG, Nevens F, Vinel JP, Mössner J, Bosch J; Early TIPS (Transjugular Intrahepatic Portosystemic Shunt) Cooperative Study Group. Early use of TIPS in patients with cirrhosis and variceal bleeding. *N Engl J Med* 2010; **362**: 2370-2379 [PMID: [20573925](#) DOI: [10.1056/NEJMoa0910102](#)]
 - 49 **Procaccini NJ**, Al-Osaimi AM, Northup P, Argo C, Caldwell SH. Endoscopic cyanoacrylate versus transjugular intrahepatic portosystemic shunt for gastric variceal bleeding: a single-center U.S. analysis. *Gastrointest Endosc* 2009; **70**: 881-887 [PMID: [19559425](#) DOI: [10.1016/j.gie.2009.03.1169](#)]
 - 50 **Kochhar GS**, Navaneethan U, Hartman J, Mari Parungao J, Lopez R, Gupta R, Kapoor B, Mehta P, Sanaka M. Comparative study of endoscopy vs. transjugular intrahepatic portosystemic shunt in the management of gastric variceal bleeding. *Gastroenterol Rep (Oxf)* 2015; **3**: 75-82 [PMID: [25673803](#) DOI: [10.1093/gastro/gou095](#)]
 - 51 **Choi YH**, Yoon CJ, Park JH, Chung JW, Kwon JW, Choi GM. Balloon-occluded retrograde transvenous obliteration for gastric variceal bleeding: its feasibility compared with transjugular intrahepatic portosystemic shunt. *Korean J Radiol* 2003; **4**: 109-116 [PMID: [12845306](#) DOI: [10.3348/kjr.2003.4.2.109](#)]
 - 52 **Katoh K**, Sone M, Hirose A, Inoue Y, Fujino Y, Onodera M. Balloon-occluded retrograde transvenous obliteration for gastric varices: the relationship between the clinical outcome and gastroduodenal shunt occlusion. *BMC Med Imaging* 2010; **10**: 2 [PMID: [20074342](#) DOI: [10.1186/1471-2342-10-2](#)]
 - 53 **Jang SY**, Kim GH, Park SY, Cho CM, Tak WY, Kim JH, Choe WH, Kwon SY, Lee JM, Kim SG, Kim DY, Kim YS, Lee SO, Min YW, Lee JH, Paik SW, Yoo BC, Lim JW, Kim HJ, Cho YK, Sohn JH, Jeong JY, Lee YH, Kim TY, Kweon YO. Clinical outcomes of balloon-occluded retrograde transvenous obliteration for the treatment of gastric variceal hemorrhage in Korean patients with liver cirrhosis: a retrospective multicenter study. *Clin Mol Hepatol* 2012; **18**: 368-374 [PMID: [23323252](#) DOI: [10.3350/cmh.2012.18.4.368](#)]
 - 54 **Kim SK**, Lee KA, Sauk S, Korenblat K. Comparison of Transjugular Intrahepatic Portosystemic Shunt with Covered Stent and Balloon-Occluded Retrograde Transvenous Obliteration in Managing Isolated Gastric Varices. *Korean J Radiol* 2017; **18**: 345-354 [PMID: [28246514](#) DOI: [10.3348/kjr.2017.18.2.345](#)]
 - 55 **Lee SJ**, Kim SU, Kim MD, Kim YH, Kim GM, Park SI, Won JY, Lee DY, Lee KH. Comparison of treatment outcomes between balloon-occluded retrograde transvenous obliteration and transjugular intrahepatic portosystemic shunt for gastric variceal bleeding hemostasis. *J Gastroenterol Hepatol* 2017; **32**: 1487-1494 [PMID: [28085232](#) DOI: [10.1111/jgh.13729](#)]
 - 56 **Hamdeh S**, Altayar O, Aziz M. Balloon-Occluded Retrograde Transvenous Obliteration (BRTO) versus Transjugular Intrahepatic Portosystemic Shunt (TIPS) in the management of gastric variceal bleeding: A systematic review and meta-analysis. *Hepatology* 2018; **68**:S475A
 - 57 **Orozco H**, Mercado MA. The evolution of portal hypertension surgery: lessons from 1000 operations and 50 Years' experience. *Arch Surg* 2000; **135**: 1389-93; discussion 1394 [PMID: [11115336](#) DOI: [10.1001/archsurg.135.12.1389](#)]



Hepatocellular carcinoma recurrence after liver transplantation: Risk factors, screening and clinical presentation

Norma Arteiro Filgueira

ORCID number: Norma Arteiro Filgueira (0000-0002-7549-9825).

Author contributions: Filgueira NA contribute to conception and design, literature review and writing of article.

Conflict-of-interest statement: No potential conflicts of interest, no financial support

Open-Access: This article is an open-access article which was selected by an in-house editor and fully peer-reviewed by external reviewers. It is distributed in accordance with the Creative Commons Attribution Non Commercial (CC BY-NC 4.0) license, which permits others to distribute, remix, adapt, build upon this work non-commercially, and license their derivative works on different terms, provided the original work is properly cited and the use is non-commercial. See: <http://creativecommons.org/licenses/by-nc/4.0/>

Manuscript source: Invited manuscript

Received: February 6, 2019

Peer-review started: February 6, 2019

First decision: March 5, 2019

Revised: March 6, 2019

Accepted: March 16, 2019

Article in press: March 16, 2019

Published online: March 27, 2019

P-Reviewer: Qin J, Tchilikidi KY

S-Editor: Cui LJ

L-Editor: A

E-Editor: Zhang YL

Norma Arteiro Filgueira, Department of Internal Medicine, Universidade Federal de Pernambuco, Recife, Pernambuco 50670-901, Brazil

Corresponding author: Norma A Filgueira, MD, PhD, Professor, Department of Internal Medicine, Universidade Federal de Pernambuco, Av. Prof. Moraes Rego, 1235, Cidade Universitária, Recife, Pernambuco 50670-901, Brazil. norma.arteiro@hotmail.com
Telephone: +55-81-9991416308

Abstract

Liver transplantation is the best treatment option for cirrhotic patients with early-stage hepatocellular carcinoma, but it faces the problem of scarcity of donors and the risk of tumor recurrence, which affects between 15% and 20% of the cases, despite the use of restrictive criteria. The risk of recurrence depends on a number of factors, related to the tumor, the patient, and the treatment, which are discussed in this review. Some of these factors are already well established, such as the histopathological characteristics of the tumor, Alpha-fetoprotein (AFP) levels, and waiting time. Other factors related to the biological behavior of the tumor and treatment should be recognized because they can be used in the refinement of the selection criteria of transplant candidates and in an attempt to reduce recurrence. This review also discusses the clinical presentation of recurrence and its prognosis, contributing to the identification of a subgroup of patients who may have better survival, if they are timely identified and treated. Development of recurrence after the first year, with AFP levels ≤ 100 ng/mL, and single site capable of locoregional therapy are associated with better survival after recurrence.

Key words: Hepatocellular carcinoma; Liver transplantation; Recurrence; Risk factors; Alpha-fetoprotein; Survival; Prognosis

©The Author(s) 2019. Published by Baishideng Publishing Group Inc. All rights reserved.

Core tip: Recurrence of hepatocellular carcinoma (HCC) after liver transplantation usually portends a poor prognosis with short survival. Besides well recognized risk factors for post-transplant HCC recurrence, as tumor staging and vascular invasion, this review discusses other factors strongly associated with the recurrence risk, such as alpha-fetoprotein levels, tumor uptake of FDG in Pet scan, response to locoregional therapy and post-transplant immunosuppression. We present proposals of a screening protocol for tumor recurrence after transplantation and of criteria to identify patients with good prognosis after recurrence, who might benefit from aggressive antitumor therapy.



Citation: Filgueira NA. Hepatocellular carcinoma recurrence after liver transplantation: Risk factors, screening and clinical presentation. *World J Hepatol* 2019; 11(3): 261-272
URL: <https://www.wjgnet.com/1948-5182/full/v11/i3/261.htm>
DOI: <https://dx.doi.org/10.4254/wjh.v11.i3.261>

INTRODUCTION

Liver transplantation (LT) is the treatment of choice for cirrhotic patients with early-stage hepatocellular carcinoma (HCC), because it concomitantly resects the tumor and the underlying liver disease, which is the main risk factor for the appearance of new tumors. The percentage of cases of HCC among patients waiting LT tripled from 2004 to 2015 in the United States, becoming the leading indication of LT in 2015 (23.9% of registrations)^[1]. However, the shortage of organs for transplantation limits the selection of this therapeutic modality for HCC.

Despite using morphologic criteria, such as the Milan criteria (MC) (single nodule smaller than 5 cm or two or three nodules of up to 3 cm)^[2], to select HCC patients for LT, tumor recurrence (TR) still occurs in 15% to 20% of cases, being associated with an unfavorable prognosis^[3-6]. Therefore, it is necessary to identify other risk factors for TR to refine patient selection and to identify modifiable factors that may reduce the incidence of TR.

RISK FACTORS FOR TUMOR RECURRENCE

There are numerous studies that have sought to identify the risk factors for HCC recurrence after LT. We shall classify these factors according to the tumor, the patient, or the treatment (Table 1).

Factors related to the tumor

Staging, number and size of the nodules: After 15 years of using the MC^[2] in clinical practice, a systematic review showed that with the compliance of these criteria, cases of well-differentiated tumors were selected, without vascular invasion and with similar 5-year survival rate to that of the transplanted patients for nontumor causes^[7].

The increased risk of TR with the higher number of nodules is not linear, because, from three nodules and above, the increase in risk tends to be attenuated^[8]. Another meta-analysis showed that the risk of TR was proportional to the diameter of the larger nodule, with no association with the number of nodules, probably because multiple nodules, however small, did not present higher frequency of vascular invasion^[9]. These findings were confirmed in a retrospective cohort study that showed an increase of 36% in the risk of TR for each extra centimeter in the diameter of the larger nodule, with no association with the number of nodules^[10].

Vascular invasion: Macrovascular tumoral invasion can be identified by imaging exams and is considered a contraindication to the realization of LT. In turn, microvascular invasion (mIV) can only be detected by the analysis of the explant, being, therefore, unavailable in the preoperative period.

However, mIV tends to be associated with tumor staging, being observed in 16.6% of the tumors within the MC, and in 50.2% of those beyond the Up-to-seven criteria group (sum of the diameter of the largest node with the number of nodules smaller than seven)^[8].

The mIV is a determining factor in the risk of TR and survival, doubling the risk of death^[8]. The presence of micro- and macrovascular invasion in the explant was associated with a significant increase in the TR [relative risk (RR), 2.42 and 7.82, respectively] and decreased 5-year recurrence-free survival (RFS) (44% and 13%, respectively, compared to 64% in patients without vascular invasion)^[11].

Degree of differentiation: Poorly differentiated tumors are found in 11% to 25% of patients who underwent LT^[8,11-13], and this frequency seems to increase as we expand the morphological selection criteria^[8]. Poorly differentiated tumors entail higher risk of TR (39.3% vs 13%) and reduction of RFS by 5 years (39.9% vs 57.7%)^[12]. However, a percutaneous biopsy presents low sensitivity (29%) and positive predictive value (35%) in the identification of poorly differentiated tumors, not improving the accuracy of the selection of candidates for LT, when associated to the MC^[14].

Table 1 Factors possibly associated with the recurrence of hepatocellular carcinoma after liver transplantation

Related to the tumor	Related to the patient	Related to the treatment
Tumor staging	Obesity	Pretransplantation:
Vascular invasion	Viral etiology	Percutaneous tumor biopsy
Differentiation's grade	HCV treatment	Waiting time
	NAFLD	Bridging therapy
		Peri-transplantation:
Alpha-fetoprotein		Donor's age
Neutrophil-lymphocyte ratio		Ischemia time
		Surgical technique
		Posttransplantation:
Enhanced uptake in PET scan		Immunosuppression
MRI findings with gadoxetic acid		Adjuvant sorafenib
Response to LRT		

MRI: Magnetic resonance imaging; LRT: Locoregional therapy; HCV: Hepatitis C virus; NAFLD: Non-alcoholic fatty liver disease.

Alpha-fetoprotein: Alpha-fetoprotein (AFP) levels are high in approximately 60% of the HCC cases^[15]. Although losing diagnostic value, its role in the prognosis of HCC is relevant. A retrospective analysis, based on the United Network for Sharing Organs (UNOS) data, observed an inverse relationship between the level of AFP (from 16 ng/mL) and survival post-LT^[16].

Duvoux *et al*^[17] have proposed a simple scoring system, associating the levels of AFP with the size and number of nodules. Using a cutoff value of two points to differentiate low- and high-risk patients, they found the following rates of TR: 8.8% and 50.6%, respectively, after LT.

A recent study reported that in patients with tumors within the MC, a monthly increase in the level of AFP greater than 7.5 ng/mL, in spite of locoregional therapy (LRT), was associated with the presence of mIV [odds ratio (OR) 6.8] and a greater risk of TR [(hazard ratio (HR), 3.9)]^[18].

Several authors have reported that the reduction of AFP levels after LRT is associated with a good prognosis^[16,17,19,20]. Merani *et al*^[21] showed that patients who achieved AFP levels below 400 ng/mL after LRT were less excluded by tumor progression and attained a higher survival rate than those who already had low values from the onset. Even patients with initial levels of AFP above 1000 ng/mL attained good survival, as long as the AFP levels were reduced with less than 400 ng/mL after LRT.

Some authors proposed the exclusion of patients with AFP levels higher than 1000 ng/mL from undergoing LT, found in 4.7% of the cases with tumors within the MC, which was strongly associated with mIV (OR, 6.8) and 5-year TR (47.3%)^[19]. A recent study, based on the UNOS database, included 407 patients with HCC who underwent LT with AFP levels > 1000 ng/mL, which corresponded to 3.8% of the total number of cases. Of these, 23.9% achieved a reduction of AFP to less than 500 ng/mL with LRT, which was associated with a marked reduction of TR (13.3% *vs* 35%) and 5-year mortality rate (33% *vs* 51, 2%)^[22].

Neutrophil-lymphocyte ratio: Some tumors induce an inflammatory response that induces the release of cytokines and inflammatory mediators, increasing the risk of metastasis by inhibition of apoptosis, promotion of angiogenesis, and DNA damage. The neutrophil-lymphocyte ratio (NLR) in the peripheral blood can be a marker of inflammatory response, and its association with the poor prognosis of various tumors has already been demonstrated^[23]. Some authors have studied the association between the NLR, calculated based on the immediate preoperative exams, and the risk of recurrence of HCC after LT. Halazun *et al*^[24] found NLR ≥ 5 in 9% of the individuals transplanted for HCC, who presented a 5-year RFS of only 25%. They proposed a score by associating the NLR to the diameter of the larger nodule and observed a median survival of only 3 mo in patients with NLR ≥ 5 and tumor diameter > 3 cm. A meta-analysis confirmed the association of the NLR with mIV, multifocality, size, poor tumor differentiation, and shorter survival^[25].

Enhanced uptake in positron emission tomography scan: The diagnostic sensitivity of positron emission tomography scan (Pet scan) for HCC is only 50%, since well-differentiated tumors have comparable glycolytic activity to that of nontumor liver cells. [18F] FDG uptake by the tumor has been used as a marker of HCC aggressiveness, based on the association with mIV and poor tumoral differentiation, greater risk of dropout, greater risk of TR, and lower RFS and overall 5-year survival^[26,27].

Findings from magnetic resonance imaging with gadoxetic acid: A recent publication described the development of significantly higher TR in patients with satellite nodules (HR, 3.97) and peritumoral hypointensity in the hepatobiliary phase (HR, 4.24). The positive predictive value of these findings in predicting mIV in the explant was 84%, and the difference in RFS over 3 years was significant (27.5% vs 84.6%)^[28].

LRT response: LRT response may be a marker of the biological behavior of the tumor. LRT can be used pretransplant in the following two scenarios: (1) in tumors beyond MC, with the goal of reducing tumor mass and thus enabling the inclusion criteria (downstaging), or (2) in patients with tumors within the MC, as neoadjuvant therapy [bridging therapy (BT)], to prevent the removal of the patient from the list due to tumor progression (dropout). The treatment modalities that can be performed for LRT are transarterial chemoembolization (TACE), radiofrequency ablation, alcoholization, and radioembolization, depending on the characteristics of the tumor and the patient^[29].

Otto *et al*^[30] observed that the response to TACE allows a better selection of candidates for LT than pathological data, such as tumor size, vascular invasion, and degree of differentiation. Patients who reached downstaging obtained a lower rate of TR (3.3%), while those who presented some degree of tumor progression presented a significantly lower 5-year RFS (22 vs 92%; RR, 21.7).

The University of California's group prospectively included patients with tumors beyond CM in a downstaging program provided they did not present macrovascular invasion and met one of the following criteria: (1) Single nodule less than or equal to 8 cm; (2) two or three nodules smaller than 5 cm, with a sum smaller than 8 cm; or (3) four to five nodules smaller than 3 cm with a sum smaller than 8 cm. About 65% of the cases achieved effective downstaging and were enrolled for LT after 3 mo. When compared to patients with MC tumors from the start, they had a greater 2-year dropout risk (34.2 vs 25.6%), but the RFS was similar^[31]. A recent meta-analysis confirmed the good results with the downstaging process^[32], so much so that the American Association for the Study of Liver Diseases (AASLD) recommends the inclusion of such patients in the LT list^[33].

Factors related to the patient

Obesity: In one sample, 25% of patients with HCC who underwent LT were obese and had twice the risk of death, a higher frequency of mIV, and tendency for a higher rate of TR, suggesting that the increased expression of vascular endothelial growth factor (VEGF) induced by the adipose tissue may stimulate tumor angiogenesis^[34]. Another group has confirmed the increased risk of TR, with smaller RFS among overweight patients, suggesting that obesity induces a pro-oncogenic state, via reduction of adiponectin and increase of leptin, which would stimulate HCC proliferation, migration, and invasion^[35].

Viral etiology: A study from Taiwan described a strong association between the failure of prophylactic therapy against reactivation of hepatitis B in the posttransplant period and the risk of TR, both of which are related to the presence of a specific mutation of the virus, which seems to induce a pro-carcinogenic state^[36]. Another study found a 2.45-fold higher risk of TR in patients with hepatitis B and viral load above 5 log, also finding an association between the reactivation of hepatitis B in the post-LT period and the risk of TR^[37].

There are controversial reports on the influence of hepatitis C on the risk of TR after LT due to HCC. Bozorgzadeh *et al*^[38] compared a small group of transplanted HCC patients with and without hepatitis C and reported an association of viral infection with lower 5-year RFS. A group from Taiwan, in turn, found lower RFS in the subgroup of hepatitis C patients who evolved with rapid development of liver fibrosis after living-donor LT^[39].

Hepatitis C virus treatment: There are few reports on the impact of HCV treatment in the post-LT period on the risk of TR. Small case series have suggested that treatment with interferon-based schemes could be associated with a lower risk of TR^[40].

Data on the use of direct-acting antivirals (DAAs) to treat HCV in patients with

HCC who underwent LT are still scarce. In the CUPILT cohort, 314 patients transplanted for HCC were treated with DAAs after ca. 67 mo of transplant, attaining 96.8% sustained virological response (SVR), with only 2.2% of TR^[41].

Some authors have reported preliminary results regarding antiviral treatment in patients with HCC during the waiting time for transplantation. Yang *et al*^[42] observed a tendency for a higher risk of TR in 18 patients treated with DAAs in pre-LT, who presented a surprisingly low rate of virologic response (50%), observing an association with histological features of poor prognosis, early TR, and extrahepatic metastases.

On the other hand, an Italian cohort achieved 94% SVR after treatment during the waiting time, with TR being observed in only 8.5% of them after 20 mo of follow-up^[43]. Another study compared patients treated or not with DAAs while awaiting transplantation, with no difference in dropout risk, characteristics of the explant, or TR^[44].

Non-alcoholic fatty liver disease: Recently, some authors have described a more indolent biological behavior in HCC associated to non-alcoholic fatty liver disease (NAFLD). Lewin *et al*^[45] analyzed the UNOS database and observed that the cases with HCC secondary to NAFLD presented a 32% lower rate of high-risk characteristics for TR. A study from the University of Toronto and University of San Francisco noted that among patients with tumors beyond MC, bearers of NAFLD showed a 80% lower rate of TR^[46].

Factors related to treatment

Percutaneous tumor biopsy: Although the current consensus allows the diagnosis of HCC by imaging methods in most of the cases, percutaneous biopsy may still be necessary in cases with atypical radiological pattern^[29,33]. In 2005, a Spanish group reported that the accomplishment of percutaneous biopsy was associated with a higher risk of TR, especially extrahepatic^[47]. Lopez *et al*^[48] studied patients with HCC who underwent biopsy and radiofrequency ablation before LT, finding no tumor implant in the needle path in patients who underwent the two procedures at the same time, while 16.7% of those who underwent radiofrequency after biopsy showed TR in the thoracic wall.

Time to transplantation: Studies based on the UNOS database reported an association between a short time to transplantation and increased risk of TR in the post-LT, with decreased survival. The authors suggested that the rigorous image monitoring during the waiting time could select the tumors with more favorable biological behavior^[49,50]. A multicenter study found a dropout rate of 3.2% and 12.4% when the time between HCC diagnosis and LT was greater than 6 and 18 mo, respectively, despite the completion of LRT. The risk of 5-year TR was greater in patients transplanted before 6 mo or after 18 mo of diagnosis of HCC^[51].

BT: There are controversial reports on the benefits of BT, but an international conference recommended it when the likely waiting time is longer than 6 mo^[52], and the AASLD suggests BT in patients with tumors within the MC^[33]. In their meta-analysis, Kulik *et al*^[32] found no significant reduction in the risk of dropout after LRT in patients within the MC, while no impact on the risk of TR and RFS was observed.

A multicenter study examined 3601 transplanted patients with HCC, of which 79.3% received LRT, and did not observe difference in TR and RFS compared to those without these therapies. However, a greater risk of TR in those who developed only partial necrosis of the nodule was seen when compared to those without LRT^[53].

Another group confirmed the similarity of TR rates in patients within the MC who underwent LRT or did not and the higher risk of TR in patients with partial necrosis of the tumor, when compared to those with complete necrosis and without necrosis. They also found an association between partial necrosis of the tumor and increased risk of lymph node metastases, demonstrating that the partial necrosis was accompanied by greater density of peritumoral lymphatic vessels and increased expression of VEGF. These authors raised the hypothesis that tumor necrosis stimulates the production of growth factors and neoangiogenesis, facilitating the progression and lymphatic dissemination of the remaining tumor cells^[54].

A recently published retrospective cohort study found a 64% reduction in the risk of TR in patients undergoing TACE when adjusted by the initial size of the lesion, not observing this association in patients who underwent radiofrequency, suggesting that the greatest benefits would be achieved in patients with tumors with a diameter greater than 4 cm^[10].

Donor's age: One study observed higher median age of the donor among patients who evolved with TR after LT, which remained significant after multivariate analysis,

which led them to speculate if older livers would have less tolerance to the preservation injury and increased susceptibility to cold ischemia^[55]. A similar result was observed in a survey of the UNOS database, in which a 70% higher risk of TR was found in patients who received grafts from donors older than 60 years, regardless of the etiology of liver disease^[56].

Ischemia time: Warm and cold ischemia times are related with the intensity of ischemia-reperfusion injury, which stimulates immune and inflammatory phenomena. Nagai *et al*^[57] observed a gradual increase in the risk of TR with the increase of the ischemia time, with a significant difference after 10 h of cold ischemia and 50 min of warm ischemia. A German group found an association between a warm ischemia time greater than 50 minutes and the risk of TR^[58]. It is speculated that ischemia-reperfusion injury can accelerate growth and implantation of HCC micrometastases present at the time of LT.

Surgical technique: The preservation of the vena cava in piggyback procedures reduces the hemodynamic instability and the warm ischemia time. On the other hand, the preservation of the cava theoretically could increase the risk of persistence of tumor-affected margins, and the greater manipulation of the patient's liver could increase the spread of tumor cells. Mangus *et al*^[59] found no difference in the frequency of TR nor RFS according to the technique of venous reconstruction, while a Polish study found a higher risk of TR in patients undergoing the conventional technique^[60].

The technique of living-donor LT implies piggyback anastomosis between the receiver and the partial graft of the donor. A meta-analysis reported ca. 60% greater RFS in patients who underwent cadaver LT than those who underwent living-donor LT^[61]. The possible explanations for the worse prognosis of living-donor LT in the treatment of HCC would be the following: (1) Shorter waiting list, which would prevent the identification of more aggressive tumors; (2) greater surgical manipulation, which could contribute to the spread of neoplastic cells; and (3) rapid hepatic regeneration after living-donor LT, which would release growth factors and cytokines that could contribute to the TR^[62].

Immunosuppression: In the transplantation scenario for the treatment of a neoplasia, a balance must be sought between immunological risks (graft rejection) and oncological risks (TR). The association between the serum level of tacrolimus in the first month after LT with the risk of TR has already been demonstrated, and it was observed that patients with a level above 10 ng/ml presented a 2.8-fold higher risk of TR^[63].

As mTOR inhibitors (sirolimus and everolimus) inhibit cell proliferation and angiogenesis, it has been postulated that these drugs could reduce the risk of TR after LT. A meta-analysis of five cohort studies found 70% lower risk of TR in patients who used sirolimus associated to a calcineurin inhibitor^[64]. Another meta-analysis including 42 studies showed a lower frequency of TR among patients treated with an mTOR inhibitor, although this difference was only significant among patients with tumors within the MC^[65]. However, both meta-analyses assumed that these studies were of low quality.

A randomized, prospective, multicenter trial (SILVER trial) included 525 patients transplanted for HCC, associating or not sirolimus, from 4 to 6 weeks of LT, with the traditional immunosuppression scheme of each participating center. Although the 5-year TR rate was similar between the groups, those treated with sirolimus showed a higher percentage of RFS in the first 4 years, and from the end of the first year, the risk of TR was 50% lower. When an analysis of subgroups was performed, the addition of sirolimus was beneficial in patients with tumors within the MC. In general, the addition of sirolimus to the immunosuppressive regimen was associated with a gain of 6.4 mo in the RFS^[66].

Another study using a historical control group evaluated the use of everolimus from the third week after LT on the risk of TR, with no significant difference between the groups^[67].

Adjuvant sorafenib: Sorafenib is a multiple tyrosine kinase inhibitor that exerts an antiangiogenic effect through the inhibition of VEGF and platelet-derived growth factor and was the first drug to provide increased survival for patients with advanced HCC^[68]. Its use as an adjuvant therapy after LT in order to reduce the risk of TR began to be described from 2010 in small case-control studies, with varying results, but at the expense of toxicity that required a reduction of dose in 75% to 82% of cases^[69-71].

MONITORING OF THE PATIENT AFTER LT FOR HCC

There is no consensus on the protocol for monitoring TR after LT, without definition on the modality of exams to be performed and frequency or duration of follow-up. Most authors monitored the patients with thoracic-abdominal computed tomography (CT) and AFP levels with 3- to 6-mo intervals in the first 2 or 3 years, increasing the interval between exams from that date. Bone scintigraphy is usually reserved for those cases that present with symptoms or TR. There is also no consensus on the duration of screening of TR^[5,6,72,73]. A consensus conference published a vague recommendation of a combination of imaging exams (CT or magnetic resonance imaging), and AFP every 6 to 12 mo^[54].

A multicenter study has proposed a protocol of postoperative monitoring, stratified according to the risk of TR, which would be estimated by the RETREAT score, calculated according to the following three simple data: AFP on the occasion of the LT, vascular invasion, and sum of diameter with the number of viable nodules (Table 2)^[74].

CLINICAL PRESENTATION OF HCC RECURRENCE AFTER LT

The recurrence of HCC after LT usually occurs early, with a median RFS of 12 to 16 mo. In most cases, TR is of poor prognosis with a median survival after recurrence of 7 to 16 mo^[4-6,72,73].

Approximately 75% of the TR occur during the first 2 years after the LT, and only 10% of them are detected after the fourth year^[6]. Most authors consider early TR the one that develops during the first year after LT. From a pathophysiological point of view, early TR occurs due to pretransplantation staging failure, which fails to identify existing metastases, or by implantation and growth of circulating tumor cells in another organ. On the other hand, late TR would arise as a result of late seeding of cells that remained latent and in less number for a long time after LT^[3].

The clinical course of TR after LT tends to be dramatic, because it involves tumoral dissemination in immunosuppressed patients. TR after LT must be considered a systemic event, because it is restricted to the graft in only 30% of cases^[75]. The organs most commonly involved in TR are the lungs, liver, bones, lymph nodes, and adrenal glands. Involvement of more than one organ is observed in more than 50% of the cases^[6].

RFS has a strong impact on survival after TR, since the early TR usually denotes greater tumor burden and more aggressive biological behavior^[5,6,73]. Other factors seem to impact survival after TR including the following: nutritional status on the occasion of the TR^[4], bone metastases^[6,72], level of AFP after TR^[4-6], lymphopenia^[4], the involvement of multiple organs^[76], and impossible treatment with curative intent of TR^[5].

The use of therapy with curative intention, such as surgical resection or ablation by radiofrequency, is usually possible in patients with TR with less aggressive behavior, represented by late TR, lower levels of AFP, lower number and size of tumor nodules, and single TR site, which is associated with a significantly higher survival rates (22 *vs* 9 mo)^[77].

A Euro-American study developed a prognostic score after TR, based on the presence of the following three signs of poor prognosis: TR during the first year after LT (HR, 1.6), AFP level higher than 100 ng/mL at TR (HR, 2.1), and tumor not susceptible to curative therapy (HR, 4.7). Patients without any of these poor prognostic factors achieved a 5-year survival rate of 50% (Table 3)^[5]. This score was recently validated in another multicenter study, which confirmed its usefulness in predicting survival after TR^[77].

CONCLUSION

LT is the best treatment option for cirrhotic patients with early-stage HCC, but it faces the problem of scarcity of donors and the risk of TR, which affects between 15% and 20% of the cases, probably because morphologic criteria do not predict the tumor biological behavior. Besides well recognized risk factors for HCC recurrence after LT, as tumor staging and vascular invasion, some other factors are strongly associated with the recurrence risk, such as AFP levels, tumor uptake of FDG in Pet scan and response to LRT. Some therapy-related risk factors may be modified to reduce recurrence risk, as waiting time and post-transplant immunosuppression. Tumor recurrence after transplantation usually portends a poor prognosis with a median

Table 2 RETREAT score to estimate the risk of tumor recurrence after liver transplantation in patients with tumors within the Milan criteria and proposed protocol for tumor recurrence screening^[74]

Risk factor	Score
Alpha-fetoprotein level before LT	
0–20 ng/mL	0
21–99 ng/mL	1
0–999 ng/mL	2
> 1000 ng/mL	3
Microvascular invasion	2
Sum of the diameter of the largest viable tumor and the number of viable nodules	
0	0
1.1–4.9	1
5.0–9.9	2
≥ 10	3
RETREAT Score	Screening Protocol
0 points	Screening not needed
1–3 points	Screening every 6/6 mo for 2 yr
4 points	Screening every 6/6 mo for 5 yr
≥5 points	Screening every 3–4 mo for 2 yr Exams every 6 mo between the 2nd and 5th year

TR: Tumor recurrence; LT: Liver transplantation.

survival of 7 to 16 mo. Although there are no structured studies on the treatment of HCC recurrence after LT, it is important to modify the paradigm that TR is always fatal. The implementation of a regular screening protocol may allow the establishment of diagnosis at an early stage, which might provide effective treatment for some patients, improving the dismal prognosis of this clinical condition.

Table 3 Prognostic score for the prediction of survival after hepatocellular carcinoma recurrence after liver transplantation^[77]

Poor prognostic variables		
Early tumor recurrence (during the first year after transplantation)		
AFP ≥ 100 ng/mL at the time of the TR		
Tumor not susceptible to curative therapy		
Score	Prognostic score	1st year survival after TR
No variable	Good prognosis	73%
1 or 2 variables	Moderate prognosis	55%
3 variables	Poor prognosis	17%

TR: Tumor recurrence.

REFERENCES

- 1 **Yang JD**, Larson JJ, Watt KD, Allen AM, Wiesner RH, Gores GJ, Roberts LR, Heimbach JA, Leise MD. Hepatocellular Carcinoma Is the Most Common Indication for Liver Transplantation and Placement on the Waitlist in the United States. *Clin Gastroenterol Hepatol* 2017; **15**: 767-775.e3 [PMID: [28013117](#) DOI: [10.1016/j.cgh.2016.11.034](#)]
- 2 **Mazzaferro V**, Regalia E, Doci R, Andreola S, Pulvirenti A, Bozzetti F, Montalto F, Ammatuna M, Morabito A, Gennari L. Liver transplantation for the treatment of small hepatocellular carcinomas in patients with cirrhosis. *N Engl J Med* 1996; **334**: 693-699 [PMID: [8594428](#) DOI: [10.1056/NEJM199603143341104](#)]
- 3 **de'Angelis N**, Landi F, Carra MC, Azoulay D. Managements of recurrent hepatocellular carcinoma after liver transplantation: A systematic review. *World J Gastroenterol* 2015; **21**: 11185-11198 [PMID: [26494973](#) DOI: [10.3748/wjg.v21.i39.11185](#)]
- 4 **Nagai S**, Mangus RS, Kubal CA, Ekser B, Fridell JA, Klingler KR, Maluccio MA, Tector AJ. Prognosis after recurrence of hepatocellular carcinoma in liver transplantation: predictors for successful treatment and survival. *Clin Transplant* 2015; **29**: 1156-1163 [PMID: [26458066](#) DOI: [10.1111/ctr.12644](#)]
- 5 **Sapisochin G**, Goldaracena N, Astete S, Laurence JM, Davidson D, Rafael E, Castells L, Sandroussi C, Bilbao I, Dopazo C, Grant DR, Lázaro JL, Caralt M, Ghanekar A, McGilvray ID, Lilly L, Cattral MS, Selzner M, Charco R, Greig PD. Benefit of Treating Hepatocellular Carcinoma Recurrence after Liver Transplantation and Analysis of Prognostic Factors for Survival in a Large Euro-American Series. *Ann Surg Oncol* 2015; **22**: 2286-2294 [PMID: [25472651](#) DOI: [10.1245/s10434-014-4273-6](#)]
- 6 **Bodzin AS**, Lunsford KE, Markovic D, Harlander-Locke MP, Busuttil RW, Agopian VG. Predicting Mortality in Patients Developing Recurrent Hepatocellular Carcinoma After Liver Transplantation: Impact of Treatment Modality and Recurrence Characteristics. *Ann Surg* 2017; **266**: 118-125 [PMID: [27433914](#) DOI: [10.1097/SLA.0000000000001894](#)]
- 7 **Mazzaferro V**, Bhoori S, Sposito C, Bongini M, Langer M, Miceli R, Mariani L. Milan criteria in liver transplantation for hepatocellular carcinoma: an evidence-based analysis of 15 years of experience. *Liver Transpl* 2011; **17** Suppl 2: S44-S57 [PMID: [21695773](#) DOI: [10.1002/lt.22365](#)]
- 8 **Mazzaferro V**, Llovet JM, Miceli R, Bhoori S, Schiavo M, Mariani L, Camerini T, Roayaie S, Schwartz ME, Grazi GL, Adam R, Neuhaus P, Salizzoni M, Bruix J, Forner A, De Carlis L, Cillo U, Burroughs AK, Troisi R, Rossi M, Gerunda GE, Lerut J, Belghiti J, Boin I, Gugenheim J, Rochling F, Van Hoek B, Majno P; Metroticket Investigator Study Group. Predicting survival after liver transplantation in patients with hepatocellular carcinoma beyond the Milan criteria: a retrospective, exploratory analysis. *Lancet Oncol* 2009; **10**: 35-43 [PMID: [19058754](#) DOI: [10.1016/S1470-2045\(08\)70284-5](#)]
- 9 **Germani G**, Gurusamy K, Garcovich M, Toso C, Fede G, Hemming A, Suh KS, Weber A, Burroughs AK. Which matters most: number of tumors, size of the largest tumor, or total tumor volume? *Liver Transpl* 2011; **17** Suppl 2: S58-S66 [PMID: [21584928](#) DOI: [10.1002/lt.22336](#)]
- 10 **Welling TH**, Eddinger K, Carrier K, Zhu D, Kleaveland T, Moore DE, Schaubel DE, Abt PL. Multicenter Study of Staging and Therapeutic Predictors of Hepatocellular Carcinoma Recurrence Following Transplantation. *Liver Transpl* 2018; **24**: 1233-1242 [PMID: [29729113](#) DOI: [10.1002/lt.25194](#)]
- 11 **Agopian VG**, Harlander-Locke M, Zarrinpar A, Kaldas FM, Farmer DG, Yersiz H, Finn RS, Tong M, Hiatt JR, Busuttil RW. A novel prognostic nomogram accurately predicts hepatocellular carcinoma recurrence after liver transplantation: analysis of 865 consecutive liver transplant recipients. *J Am Coll Surg* 2015; **220**: 416-427 [PMID: [25690672](#) DOI: [10.1016/j.jamcollsurg.2014.12.025](#)]
- 12 **Donat M**, Alonso S, Pereira F, Ferrero E, Carrión L, Acin-Gándara D, Moreno E. Impact of Histological Factors of Hepatocellular Carcinoma on the Outcome of Liver Transplantation. *Transplant Proc* 2016; **48**: 1968-1977 [PMID: [27569930](#) DOI: [10.1016/j.transproceed.2016.04.002](#)]
- 13 **Yao FY**, Ferrell L, Bass NM, Watson JJ, Bacchetti P, Venook A, Ascher NL, Roberts JP. Liver transplantation for hepatocellular carcinoma: expansion of the tumor size limits does not adversely impact survival. *Hepatology* 2001; **33**: 1394-1403 [PMID: [11391528](#) DOI: [10.1053/jhep.2001.24563](#)]
- 14 **Court CM**, Harlander-Locke MP, Markovic D, French SW, Naini BV, Lu DS, Raman SS, Kaldas FM, Zarrinpar A, Farmer DG, Finn RS, Sadeghi S, Tomlinson JS, Busuttil RW, Agopian VG. Determination of hepatocellular carcinoma grade by needle biopsy is unreliable for liver transplant candidate selection. *Liver Transpl* 2017; **23**: 1123-1132 [PMID: [28688158](#) DOI: [10.1002/lt.24811](#)]
- 15 **Vibert E**, Azoulay D, Hoti E, Iacopinelli S, Samuel D, Salloum C, Lemoine A, Bismuth H, Castaing D, Adam R. Progression of alpha-fetoprotein before liver transplantation for hepatocellular carcinoma in cirrhotic patients: a critical factor. *Am J Transplant* 2010; **10**: 129-137 [PMID: [20070666](#) DOI: [10.1111/j.1600-6143.2009.02750.x](#)]
- 16 **Berry K**, Ioannou GN. Serum alpha-fetoprotein level independently predicts posttransplant survival in patients with hepatocellular carcinoma. *Liver Transpl* 2013; **19**: 634-645 [PMID: [23536495](#) DOI: [10.1002/lt.23536](#)]

- 10.1002/lt.23652]
- 17 **Duvoux C**, Roudot-Thoraval F, Decaens T, Pessione F, Badran H, Piardi T, Francoz C, Compagnon P, Vanlemmens C, Dumortier J, Dharancy S, Gugenheim J, Bernard PH, Adam R, Radenne S, Muscari F, Conti F, Hardwigsen J, Pageaux GP, Chazouillères O, Salame E, Hilleret MN, Lebray P, Abergel A, Debette-Gratien M, Kluger MD, Mallat A, Azoulay D, Cherqui D; Liver Transplantation French Study Group. Liver transplantation for hepatocellular carcinoma: a model including α -fetoprotein improves the performance of Milan criteria. *Gastroenterology* 2012; **143**: 986-994.e3; quiz e14-15 [PMID: [22750200](#) DOI: [10.1053/j.gastro.2012.05.052](#)]
- 18 **Giard JM**, Mehta N, Dodge JL, Roberts JP, Yao FY. Alpha-Fetoprotein Slope; 7.5 ng/mL per Month Predicts Microvascular Invasion and Tumor Recurrence After Liver Transplantation for Hepatocellular Carcinoma. *Transplantation* 2018; **102**: 816-822 [PMID: [29505494](#) DOI: [10.1097/TP.0000000000002094](#)]
- 19 **Hameed B**, Mehta N, Sapisochin G, Roberts JP, Yao FY. Alpha-fetoprotein level; 1000 ng/mL as an exclusion criterion for liver transplantation in patients with hepatocellular carcinoma meeting the Milan criteria. *Liver Transpl* 2014; **20**: 945-951 [PMID: [24797281](#) DOI: [10.1002/lt.23904](#)]
- 20 **Toso C**, Meeberg G, Hernandez-Alejandro R, Dufour JF, Marotta P, Majno P, Kneteman NM. Total tumor volume and alpha-fetoprotein for selection of transplant candidates with hepatocellular carcinoma: A prospective validation. *Hepatology* 2015; **62**: 158-165 [PMID: [25777590](#) DOI: [10.1002/hep.27787](#)]
- 21 **Merani S**, Majno P, Kneteman NM, Berney T, Morel P, Mentha G, Toso C. The impact of waiting list alpha-fetoprotein changes on the outcome of liver transplant for hepatocellular carcinoma. *J Hepatol* 2011; **55**: 814-819 [PMID: [21334400](#) DOI: [10.1016/j.jhep.2010.12.040](#)]
- 22 **Mehta N**, Dodge JL, Roberts JP, Hirose R, Yao FY. Alpha-Fetoprotein Decrease from 1,000 to 500 ng/mL in Patients with Hepatocellular Carcinoma Leads to Improved Posttransplant Outcomes. *Hepatology* 2019; **69**: 1193-1205 [PMID: [30548884](#) DOI: [10.1002/hep.30413](#)]
- 23 **Templeton AJ**, McNamara MG, Šeruga B, Vera-Badillo FE, Aneja P, Ocaña A, Leibowitz-Amit R, Sonpavde G, Knox JJ, Tran B, Tannock IF, Amir E. Prognostic role of neutrophil-to-lymphocyte ratio in solid tumors: a systematic review and meta-analysis. *J Natl Cancer Inst* 2014; **106**: dju124 [PMID: [24875653](#) DOI: [10.1093/jnci/dju124](#)]
- 24 **Halazun KJ**, Hardy MA, Rana AA, Woodland DC 4th, Luyten EJ, Mahadev S, Witkowski P, Siegel AB, Brown RS Jr, Emond JC. Negative impact of neutrophil-lymphocyte ratio on outcome after liver transplantation for hepatocellular carcinoma. *Ann Surg* 2009; **250**: 141-151 [PMID: [19561458](#) DOI: [10.1097/SLA.0b013e3181a77e59](#)]
- 25 **Xiao WK**, Chen D, Li SQ, Fu SJ, Peng BG, Liang LJ. Prognostic significance of neutrophil-lymphocyte ratio in hepatocellular carcinoma: a meta-analysis. *BMC Cancer* 2014; **14**: 117 [PMID: [24559042](#) DOI: [10.1186/1471-207-14-117](#)]
- 26 **Kornberg A**, Küpper B, Tannapfel A, Büchler P, Krause B, Witt U, Gottschild D, Friess H. Patients with non-[18 F]fludeoxyglucose-avid advanced hepatocellular carcinoma on clinical staging may achieve long-term recurrence-free survival after liver transplantation. *Liver Transpl* 2012; **18**: 53-61 [PMID: [21850692](#) DOI: [10.1002/lt.22416](#)]
- 27 **Takada Y**, Kaido T, Shirabe K, Nagano H, Egawa H, Sugawara Y, Taketomi A, Takahara T, Wakabayashi G, Nakanishi C, Kawagishi N, Kenjo A, Gotoh M, Toyoki Y, Hakamada K, Ohtsuka M, Akamatsu N, Kokudo N, Takeda K, Endo I, Takamura H, Okajima H, Wada H, Kubo S, Kuramitsu K, Ku Y, Ishiyama K, Ohdan H, Ito E, Maehara Y, Honda M, Inomata Y, Furukawa H, Uemoto S, Yamaue H, Miyazaki M, Takada T; LTx-PET study group of the Japanese Society of Hepato-Biliary-Pancreatic Surgery and the Japanese Liver Transplantation Society. Significance of preoperative fluorodeoxyglucose-positron emission tomography in prediction of tumor recurrence after liver transplantation for hepatocellular carcinoma patients: a Japanese multicenter study. *J Hepatobiliary Pancreat Sci* 2017; **24**: 49-57 [PMID: [27806426](#) DOI: [10.1002/jhbp.412](#)]
- 28 **Kim AY**, Sinn DH, Jeong WK, Kim YK, Kang TW, Ha SY, Park CK, Choi GS, Kim JM, Kwon CHD, Joh JW, Kim MJ, Sohn I, Jung SH, Paik SW, Lee WJ. Hepatobiliary MRI as novel selection criteria in liver transplantation for hepatocellular carcinoma. *J Hepatol* 2018; **68**: 1144-1152 [PMID: [29410377](#) DOI: [10.1016/j.jhep.2018.01.024](#)]
- 29 **European Association for the Study of the Liver**. Electronic address: easloffice@easloffice.eu; European Association for the Study of the Liver. EASL Clinical Practice Guidelines: Management of hepatocellular carcinoma. *J Hepatol* 2018; **69**: 182-236 [PMID: [29628281](#) DOI: [10.1016/j.jhep.2018.03.019](#)]
- 30 **Otto G**, Schuchmann M, Hoppe-Lotichius M, Heise M, Weinmann A, Hansen T, Pitton MP. How to decide about liver transplantation in patients with hepatocellular carcinoma: size and number of lesions or response to TACE? *J Hepatol* 2013; **59**: 279-284 [PMID: [23587474](#) DOI: [10.1016/j.jhep.2013.04.006](#)]
- 31 **Yao FY**, Mehta N, Flemming J, Dodge J, Hameed B, Fix O, Hirose R, Fidelman N, Kerlan RK, Roberts JP. Downstaging of hepatocellular cancer before liver transplant: long-term outcome compared to tumors within Milan criteria. *Hepatology* 2015; **61**: 1968-1977 [PMID: [25689978](#) DOI: [10.1002/hep.27752](#)]
- 32 **Kulik L**, Heimbach JK, Zaïem F, Almasri J, Prokop LJ, Wang Z, Murad MH, Mohammed K. Therapies for patients with hepatocellular carcinoma awaiting liver transplantation: A systematic review and meta-analysis. *Hepatology* 2018; **67**: 381-400 [PMID: [28859222](#) DOI: [10.1002/hep.29485](#)]
- 33 **Heimbach JK**, Kulik LM, Finn RS, Sirlin CB, Abecassis MM, Roberts LR, Zhu AX, Murad MH, Marrero JA. AASLD guidelines for the treatment of hepatocellular carcinoma. *Hepatology* 2018; **67**: 358-380 [PMID: [28130846](#) DOI: [10.1002/hep.29086](#)]
- 34 **Siegel AB**, Lim EA, Wang S, Brubaker W, Rodriguez RD, Goyal A, Jacobson JS, Hershsman DL, Verna EC, Zaretsky J, Halazun K, Dove L, Brown RS, Neugut AI, Kato T, Remotti H, Coppleson YJ, Emond JC. Diabetes, body mass index, and outcomes in hepatocellular carcinoma patients undergoing liver transplantation. *Transplantation* 2012; **94**: 539-543 [PMID: [22864187](#) DOI: [10.1097/TP.0b013e31825c58ea](#)]
- 35 **Mathur A**, Franco ES, Leone JP, Osman-Mohamed H, Rojas H, Kemmer N, Neff GW, Rosemurgy AS, Alsina AE. Obesity portends increased morbidity and earlier recurrence following liver transplantation for hepatocellular carcinoma. *HPB (Oxford)* 2013; **15**: 504-510 [PMID: [23750492](#) DOI: [10.1111/j.1477-2574.2012.00602.x](#)]
- 36 **Wu TJ**, Chan KM, Chou HS, Lee CF, Wu TH, Chen TC, Yeh CT, Lee WC. Liver transplantation in patients with hepatitis B virus-related hepatocellular carcinoma: the influence of viral characteristics on clinical outcome. *Ann Surg Oncol* 2013; **20**: 3582-3590 [PMID: [23760589](#) DOI: [10.1245/s10434-013-3023-5](#)]
- 37 **Li MR**, Chen GH, Cai CJ, Wang GY, Zhao H. High hepatitis B virus DNA level in serum before liver

- transplantation increases the risk of hepatocellular carcinoma recurrence. *Digestion* 2011; **84**: 134-141 [PMID: 21502763 DOI: 10.1159/000324197]
- 38 **Bozorgzadeh A**, Orloff M, Abt P, Tsoulfas G, Younan D, Kashyap R, Jain A, Mantry P, Maliakkal B, Khorana A, Schwartz S. Survival outcomes in liver transplantation for hepatocellular carcinoma, comparing impact of hepatitis C versus other etiology of cirrhosis. *Liver Transpl* 2007; **13**: 807-813 [PMID: 17539001 DOI: 10.1002/lt.21054]
- 39 **Vasavada BB**, Chan CL. Rapid fibrosis and significant histologic recurrence of hepatitis C after liver transplant is associated with higher tumor recurrence rates in hepatocellular carcinomas associated with hepatitis C virus-related liver disease: a single center retrospective analysis. *Exp Clin Transplant* 2015; **13**: 46-50 [PMID: 25654412]
- 40 **Kohli V**, Singhal A, Elliott L, Jilil S. Antiviral therapy for recurrent hepatitis C reduces recurrence of hepatocellular carcinoma following liver transplantation. *Transpl Int* 2012; **25**: 192-200 [PMID: 22151471 DOI: 10.1111/j.1432-2277.2011.01396.x]
- 41 **ANRS collaborative study group on hepatocellular carcinoma (ANRS CO22 HEPATHER, CO12 CirVir and CO23 CUPILT cohorts)**. Lack of evidence of an effect of direct-acting antivirals on the recurrence of hepatocellular carcinoma: Data from three ANRS cohorts. *J Hepatol* 2016; **65**: 734-740 [PMID: 27288051 DOI: 10.1016/j.jhep.2016.05.045]
- 42 **Yang JD**, Aql BA, Pungpapong S, Gores GJ, Roberts LR, Leise MD. Direct acting antiviral therapy and tumor recurrence after liver transplantation for hepatitis C-associated hepatocellular carcinoma. *J Hepatol* 2016; **65**: 859-860 [PMID: 27392425 DOI: 10.1016/j.jhep.2016.06.023]
- 43 **Donato MF**, Invernizzi F, Rossi G IM. Interferon-free therapy of hepatitis C during wait list and post-transplant risk of hepatocellular recurrence. *J Hepatol* 2017; **67**: 1340-1357 [PMID: 28803950 DOI: 10.1016/j.jhep.2017.07.026]
- 44 **Zanetto A**, Shalaby S, Vitale A, Mescoli C, Ferrarese A, Gambato M, Franceschet E, Germani G, Senzolo M, Romano A, Angeli P, Rugge M, Farinati F, Forton DM, Cillo U, Burra P, Russo FP. Dropout rate from the liver transplant waiting list because of hepatocellular carcinoma progression in hepatitis C virus-infected patients treated with direct-acting antivirals. *Liver Transpl* 2017; **23**: 1103-1112 [PMID: 28544587 DOI: 10.1002/lt.24790]
- 45 **Lewin SM**, Mehta N, Kelley RK, Roberts JP, Yao FY, Brandman D. Liver transplantation recipients with nonalcoholic steatohepatitis have lower risk hepatocellular carcinoma. *Liver Transpl* 2017; **23**: 1015-1022 [PMID: 28340509 DOI: 10.1002/lt.24764]
- 46 **Sadler EM**, Mehta N, Bhat M, Ghanekar A, Greig PD, Grant DR, Yao F, Sapisochin G. Liver Transplantation for NASH-Related Hepatocellular Carcinoma Versus Non-NASH Etiologies of Hepatocellular Carcinoma. *Transplantation* 2018; **102**: 640-647 [PMID: 29319620 DOI: 10.1097/TP.0000000000002043]
- 47 **Saborido BP**, Diaz JC, de Los Galanes SJ, Seguro CL, de Usera MA, Garrido MD, Elola-Olaso AM, S  n RG, Romero CJ, Garcia Garc  a I, Gonz  lez EM. Does preoperative fine needle aspiration-biopsy produce tumor recurrence in patients following liver transplantation for hepatocellular carcinoma? *Transplant Proc* 2005; **37**: 3874-3877 [PMID: 16386569 DOI: 10.1016/j.transproceed.2005.09.169]
- 48 **Lopez KT**, Kuwada SK, Wong LL. Consequences of needle tract seeding of hepatocellular cancer after liver transplant. *Clin Transplant* 2013; **27**: E400-E406 [PMID: 23837571 DOI: 10.1111/ctr.12160]
- 49 **Samoylova ML**, Dodge JL, Yao FY, Roberts JP. Time to transplantation as a predictor of hepatocellular carcinoma recurrence after liver transplantation. *Liver Transpl* 2014; **20**: 937-944 [PMID: 24797145 DOI: 10.1002/lt.23502]
- 50 **Schlansky B**, Chen Y, Scott DL, Austin D, Naugler WE. Waiting time predicts survival after liver transplantation for hepatocellular carcinoma: a cohort study using the United Network for Organ Sharing registry. *Liver Transpl* 2014; **20**: 1045-1056 [PMID: 24838471 DOI: 10.1002/lt.23917]
- 51 **Mehta N**, Heimbach J, Lee D, Dodge JL, Harnois D, Burns J, Sanchez W, Roberts JP, Yao FY. Wait Time of Less Than 6 and Greater Than 18 Months Predicts Hepatocellular Carcinoma Recurrence After Liver Transplantation: Proposing a Wait Time "Sweet Spot". *Transplantation* 2017; **101**: 2071-2078 [PMID: 28353492 DOI: 10.1097/TP.0000000000001752]
- 52 **Clavien PA**, Lesurtel M, Bossuyt PM, Gores GJ, Langer B, Perrier A; OLT for HCC Consensus Group. Recommendations for liver transplantation for hepatocellular carcinoma: an international consensus conference report. *Lancet Oncol* 2012; **13**: e11-e22 [PMID: 22047762 DOI: 10.1016/S1470-2045(11)70175-9]
- 53 **Agopian VG**, Harlander-Locke MP, Ruiz RM, Klintmalm GB, Senguttuvan S, Florman SS, Haydel B, Hoteit M, Levine MH, Lee DD, Taner CB, Verna EC, Halazun KJ, Abdelmessih R, Tevar AD, Humar A, Aucejo F, Chapman WC, Vachharajani N, Nguyen MH, Melcher ML, Nydam TL, Mobley C, Ghobrial RM, Amundsen B, Markmann JF, Langnas AN, Carney CA, Berumen J, Hemming AW, Sudan DL, Hong JC, Kim J, Zimmerman MA, Rana A, Kuehl ML, Jones CM, Fishbein TM, Busuttil RW. Impact of Pretransplant Bridging Locoregional Therapy for Patients With Hepatocellular Carcinoma Within Milan Criteria Undergoing Liver Transplantation: Analysis of 3601 Patients From the US Multicenter HCC Transplant Consortium. *Ann Surg* 2017; **266**: 525-535 [PMID: 28654545 DOI: 10.1097/SLA.0000000000002381]
- 54 **Xu M**, Doyle MM, Banan B, Vachharajani N, Wang X, Saad N, Fowler K, Brunt EM, Lin Y, Chapman WC. Neoadjuvant Locoregional Therapy and Recurrent Hepatocellular Carcinoma after Liver Transplantation. *J Am Coll Surg* 2017; **225**: 28-40 [PMID: 28400300 DOI: 10.1016/j.jamcollsurg.2017.03.015]
- 55 **Sharma P**, Welch K, Hussain H, Pelletier SJ, Fontana RJ, Marrero J, Merion RM. Incidence and risk factors of hepatocellular carcinoma recurrence after liver transplantation in the MELD era. *Dig Dis Sci* 2012; **57**: 806-812 [PMID: 21953139 DOI: 10.1007/s10620-011-1910-9]
- 56 **Vagefi PA**, Dodge JL, Yao FY, Roberts JP. Potential role of the donor in hepatocellular carcinoma recurrence after liver transplantation. *Liver Transpl* 2015; **21**: 187-194 [PMID: 25371243 DOI: 10.1002/lt.24042]
- 57 **Nagai S**, Yoshida A, Facciuto M, Moonka D, Abouljoud MS, Schwartz ME, Florman SS. Ischemia time impacts recurrence of hepatocellular carcinoma after liver transplantation. *Hepatology* 2015; **61**: 895-904 [PMID: 25099130 DOI: 10.1002/hep.27358]
- 58 **Kornberg A**, Witt U, Kornberg J, Friess H, Thrum K. Extended Ischemia Times Promote Risk of HCC Recurrence in Liver Transplant Patients. *Dig Dis Sci* 2015; **60**: 2832-2839 [PMID: 25630421 DOI: 10.1007/s10620-015-3541-z]
- 59 **Mangus RS**, Fridell JA, Vianna RM, Cooper AB, Jones DT, Tector AJ. Use of the piggyback hepatectomy

- technique in liver transplant recipients with hepatocellular carcinoma. *Transplantation* 2008; **85**: 1496-1499 [PMID: [18497692](#) DOI: [10.1097/TP.0b013e31816feec0](#)]
- 60 **Grat M**, Kornasiewicz O, Lewandowski Z, Skalski M, Zieniewicz K, Pączek L, Krawczyk M. The impact of surgical technique on the results of liver transplantation in patients with hepatocellular carcinoma. *Ann Transplant* 2013; **18**: 448-459 [PMID: [24008493](#) DOI: [10.12659/AOT.884005](#)]
- 61 **Grant RC**, Sandhu L, Dixon PR, Greig PD, Grant DR, McGilvray ID. Living vs. deceased donor liver transplantation for hepatocellular carcinoma: a systematic review and meta-analysis. *Clin Transplant* 2013; **27**: 140-147 [PMID: [23157398](#) DOI: [10.1111/ctr.12031](#)]
- 62 **Park MS**, Lee KW, Suh SW, You T, Choi Y, Kim H, Hong G, Yi NJ, Kwon CH, Joh JW, Lee SK, Suh KS. Living-donor liver transplantation associated with higher incidence of hepatocellular carcinoma recurrence than deceased-donor liver transplantation. *Transplantation* 2014; **97**: 71-77 [PMID: [24056623](#) DOI: [10.1097/TP.0b013e3182a68953](#)]
- 63 **Rodríguez-Perálvarez M**, Tsochatzis E, Naveas MC, Pieri G, García-Caparrós C, O'Beirne J, Poyato-González A, Ferrín-Sánchez G, Montero-Álvarez JL, Patch D, Thorburn D, Briceño J, De la Mata M, Burroughs AK. Reduced exposure to calcineurin inhibitors early after liver transplantation prevents recurrence of hepatocellular carcinoma. *J Hepatol* 2013; **59**: 1193-1199 [PMID: [23867318](#) DOI: [10.1016/j.jhep.2013.07.012](#)]
- 64 **Menon KV**, Hakeem AR, Heaton ND. Meta-analysis: recurrence and survival following the use of sirolimus in liver transplantation for hepatocellular carcinoma. *Aliment Pharmacol Ther* 2013; **37**: 411-419 [PMID: [23278125](#) DOI: [10.1111/apt.12185](#)]
- 65 **Cholongitas E**, Mamou C, Rodríguez-Castro KI, Burra P. Mammalian target of rapamycin inhibitors are associated with lower rates of hepatocellular carcinoma recurrence after liver transplantation: a systematic review. *Transpl Int* 2014; **27**: 1039-1049 [PMID: [24943720](#) DOI: [10.1111/tri.12372](#)]
- 66 **Geissler EK**, Schnitzbauer AA, Zülke C, Lamby PE, Proneth A, Duvoux C, Burra P, Jauch KW, Rentsch M, Ganten TM, Schmidt J, Settmacher U, Heise M, Rossi G, Cillo U, Kneteman N, Adam R, van Hoek B, Bachellier P, Wolf P, Rostaing L, Bechstein WO, Rizell M, Powell J, Hidalgo E, Gugenheim J, Wolters H, Brockmann J, Roy A, Mutzbauer I, Schlitt A, Beckebaum S, Graeb C, Nadalin S, Valente U, Turrión VS, Jamieson N, Scholz T, Colledan M, Fändrich F, Becker T, Söderdahl G, Chazouillères O, Mäkitalo H, Pageaux GP, Steininger R, Soliman T, de Jong KP, Pirenne J, Margreiter R, Pratschke J, Pinna AD, Hauss J, Schreiber S, Strasser S, Klempnauer J, Troisi RI, Bhoori S, Lerut J, Bilbao I, Klein CG, Königsrainer A, Mirza DF, Otto G, Mazzaferro V, Neuhaus P, Schlitt HJ. Sirolimus Use in Liver Transplant Recipients With Hepatocellular Carcinoma: A Randomized, Multicenter, Open-Label Phase 3 Trial. *Transplantation* 2016; **100**: 116-125 [PMID: [26555945](#) DOI: [10.1097/TP.0000000000000965](#)]
- 67 **Rodríguez-Perálvarez M**, Guerrero M, Barrera L, Ferrín G, Álamo JM, Ayllón MD, Artacho GS, Montero JL, Briceño J, Bernal C, Padillo J, Marín-Gómez LM, Pascasio JM, Poyato A, Gómez-Bravo MA, De la Mata M. Impact of Early Initiated Everolimus on the Recurrence of Hepatocellular Carcinoma After Liver Transplantation. *Transplantation* 2018; **102**: 2056-2064 [PMID: [29757893](#) DOI: [10.1097/TP.0000000000002270](#)]
- 68 **Llovet JM**, Ricci S, Mazzaferro V, Hilgard P, Gane E, Blanc JF, de Oliveira AC, Santoro A, Raoul JL, Forner A, Schwartz M, Porta C, Zeuzem S, Bolondi L, Greten TF, Galle PR, Seitz JF, Borbath I, Häussinger D, Giannaris T, Shan M, Moscovici M, Voliotis D, Bruix J; SHARP Investigators Study Group. Sorafenib in advanced hepatocellular carcinoma. *N Engl J Med* 2008; **359**: 378-390 [PMID: [18650514](#) DOI: [10.1056/NEJMoa0708857](#)]
- 69 **Saab S**, McTigue M, Finn RS, Busuttil RW. Sorafenib as adjuvant therapy for high-risk hepatocellular carcinoma in liver transplant recipients: feasibility and efficacy. *Exp Clin Transplant* 2010; **8**: 307-313 [PMID: [21143097](#)]
- 70 **Teng CL**, Hwang WL, Chen YJ, Chang KH, Cheng SB. Sorafenib for hepatocellular carcinoma patients beyond Milan criteria after orthotopic liver transplantation: a case control study. *World J Surg Oncol* 2012; **10**: 41 [PMID: [22339891](#) DOI: [10.1186/1477-7819-10-41](#)]
- 71 **Satapathy SK**, Das K, Kocak M, Helmick RA, Eason JD, Nair SP, Vanatta JM. No apparent benefit of preemptive sorafenib therapy in liver transplant recipients with advanced hepatocellular carcinoma on explant. *Clin Transplant* 2018; **32**: e13246 [PMID: [29577449](#) DOI: [10.1111/ctr.13246](#)]
- 72 **Roayaie S**, Schwartz JD, Sung MW, Emre SH, Miller CM, Gondolesi GE, Krieger NR, Schwartz ME. Recurrence of hepatocellular carcinoma after liver transplant: patterns and prognosis. *Liver Transpl* 2004; **10**: 534-540 [PMID: [15048797](#) DOI: [10.1002/lt.20128](#)]
- 73 **Toso C**, Cader S, Mentha-Dugerdil A, Meeberg G, Majno P, Morard I, Giostra E, Berney T, Morel P, Mentha G, Kneteman NM. Factors predicting survival after post-transplant hepatocellular carcinoma recurrence. *J Hepatobiliary Pancreat Sci* 2013; **20**: 342-347 [PMID: [22710887](#) DOI: [10.1007/s00534-012-0528-4](#)]
- 74 **Mehta N**, Heimbach J, Harnois DM, Sapisochin G, Dodge JL, Lee D, Burns JM, Sanchez W, Greig PD, Grant DR, Roberts JP, Yao FY. Validation of a Risk Estimation of Tumor Recurrence After Transplant (RETREAT) Score for Hepatocellular Carcinoma Recurrence After Liver Transplant. *JAMA Oncol* 2017; **3**: 493-500 [PMID: [27838698](#) DOI: [10.1001/jamaoncol.2016.5116](#)]
- 75 **Guerrini GP**, Berretta M, Tarantino G, Magistri P, Pecchi A, Ballarin R, Di Benedetto F. Multimodal oncological approach in patients affected by recurrent hepatocellular carcinoma after liver transplantation. *Eur Rev Med Pharmacol Sci* 2017; **21**: 3421-3435 [PMID: [28829499](#)]
- 76 **Roh YN**, David Kwon CH, Song S, Shin M, Man Kim J, Kim S, Joh JW, Lee SK. The prognosis and treatment outcomes of patients with recurrent hepatocellular carcinoma after liver transplantation. *Clin Transplant* 2014; **28**: 141-148 [PMID: [24372624](#) DOI: [10.1111/ctr.12286](#)]
- 77 **Goldaracena N**, Mehta N, Scalera I, Sposito C, Atenafu EG, Yao FY, Muiresan P, Mazzaferro V, Sapisochin G. Multicenter validation of a score to predict prognosis after the development of HCC recurrence following liver transplantation. *HPB (Oxford)* 2018 [PMID: [30391218](#) DOI: [10.1016/j.hpb.2018.10.005](#)]

Basic Study

Protective action of glutamine in rats with severe acute liver failure

Elizângela G Schemitt, Renata M Hartmann, Josieli R Colares, Francielli Licks, Jéferson O Salvi, Cláudio A Marroni, Norma P Marroni

ORCID number: Elizângela G Schemitt (0000-0003-3015-0192); Renata M Hartmann (0000-0001-8667-517X); Josieli R Colares (0000-0002-0482-204X); Francielli Licks (0000-0002-3668-5879); Jéferson O Salvi (0000-0003-0954-412X); Cláudio A Marroni (0000-0002-1718-6548); Norma Possa Marroni (0000-0001-7856-7953).

Author contributions: Schemitt EG, Hartmann RM, Colares JR and Marroni NP contributed to study conception and design; Schemitt EG, Hartmann RM, Colares JR, Licks F and Salvi JO contributed to data acquisition, data analysis and interpretation, and writing of article; Schemitt EG, Marroni CA and Marroni NP contributed to editing and reviewing of article; all authors have read and approved of the final version of the article.

Supported by: FIPE/Hospital de Clínicas of Porto Alegre.

Institutional review board

statement: This study was conducted at the Animal Experimentation Unit and the Laboratory of Experimental Hepatology and Gastroenterology, Hospital de Clínicas of Porto Alegre, after approval from the Institutional Animal Care and Use Committee, No. CEUA 15-0175.

Conflict-of-interest statement: The authors have no conflicts of interest to disclose.

ARRIVE guidelines statement: The authors followed the ARRIVE checklist.

Elizângela G Schemitt, Renata M Hartmann, Josieli R Colares, Francielli Licks, Jéferson O Salvi, Cláudio A Marroni, Norma P Marroni, Laboratory of Experimental Hepatology and Gastroenterology, Hospital de Clínicas de Porto Alegre, Porto Alegre 90040060, Brazil

Elizângela G Schemitt, Renata M Hartmann, Josieli R Colares, Francielli Licks, Jéferson O Salvi, Norma P Marroni, Laboratory of Oxidative Stress and Antioxidants, Universidade Luterana do Brasil, Canoas 92425900, Brazil

Corresponding author: Claudio A Marroni, PhD, Professor, Laboratory of Experimental Hepatology and Gastroenterology, Hospital de Clínicas de Porto Alegre, Rua José Kanan Aranha 102, Porto Alegre 90040060, Brazil. nmarroni@terra.com.br
Telephone: +55-51-999638306

Abstract

BACKGROUND

Severe acute liver failure (SALF) is a rare, but high-mortality, rapidly evolving syndrome that leads to hepatocyte degeneration with impaired liver function. Thioacetamide (TAA) is a known xenobiotic, which promotes the increase of the formation of reactive oxygen species. Erythroid 2-related factor 2 (Nrf2) activates the antioxidant protection of cells. Studies have evidenced the involvement of inflammatory mediators in conditions of oxidative stress.

AIM

To evaluate the antioxidant effects of glutamine on Nrf2 activation and NFκB-mediated inflammation in rats with TAA-induced IHAG.

METHODS

Male Wistar rats ($n = 28$) were divided into four groups: control, control+glutamine, TAA, and TAA + glutamine. Two TAA doses (400 mg/kg) were administered intraperitoneally, 8 h apart. Glutamine (25 mg/kg) was administered at 30 min, 24 h, and 36 h. At 48 h, blood was collected for liver integrity analysis [aspartate aminotransferase (AST), alanine aminotransferase (ALT), and alkaline phosphatase (ALP)]. The liver was harvested for histology and assessment of oxidative stress [thiobarbituric acid-reactive substances (TBARS), catalase (CAT), glutathione peroxidase (GPx), glutathione S-transferase (GST), glutathione (GSH), Nrf2, Kelch-like ECH-associated protein 1 (Keap1), NADPH quinone oxidoreductase1 (NQO1), superoxide dismutase (SOD)] and inflammatory process.

RESULTS

TAA caused disruption of the hepatic parenchyma, with inflammatory

Open-Access: This article is an open-access article which was selected by an in-house editor and fully peer-reviewed by external reviewers. It is distributed in accordance with the Creative Commons Attribution Non Commercial (CC BY-NC 4.0) license, which permits others to distribute, remix, adapt, build upon this work non-commercially, and license their derivative works on different terms, provided the original work is properly cited and the use is non-commercial. See: <http://creativecommons.org/licenses/by-nc/4.0/>

Manuscript source: Unsolicited manuscript

Received: October 30, 2018

Peer-review started: October 30, 2018

First decision: December 21, 2018

Revised: January 29, 2019

Accepted: March 12, 2019

Article in press: March 12, 2019

Published online: March 27, 2019

P-Reviewer: El-Bendary M, Kao JT, Sridharan G

S-Editor: Cui LJ

L-Editor: A

E-Editor: Zhang YL



infiltration, massive necrosis, and ballooning degeneration. Glutamine mitigated this tissue damage, with visible regeneration of hepatic parenchyma; decreased TBARS ($P < 0.001$), GSH ($P < 0.01$), IL-1 β , IL6, and TNF α levels ($P < 0.01$) in hepatic tissue; and decreased blood levels of AST, ALT, and ALP ($P < 0.05$). In addition, CAT, GPx, and GST activities were restored in the glutamine group ($P < 0.01$, $P < 0.01$, and $P < 0.001$, respectively *vs* TAA alone). Glutamine increased expression of Nrf2 ($P < 0.05$), NQO1, and SOD ($P < 0.01$), as well as levels of IL-10 ($P < 0.001$), while decreasing expression of Keap1, TLR4, NF κ B ($P < 0.001$), COX-2 and iNOS, ($P < 0.01$), and reducing NO $_2$ and NO $_3$ levels ($P < 0.05$).

CONCLUSION

In the TAA experimental model of IHAG, glutamine activated the Nrf2 pathway, thus promoting antioxidant protection, and blunted the NF κ B-mediated pathway, reducing inflammation.

Key words: Thioacetamide; Cytokines; Oxidative stress; Inflammation; Liver failure; Chemical and drug induced liver injury; Glutamine

©The Author(s) 2019. Published by Baishideng Publishing Group Inc. All rights reserved.

Core tip: Severe acute liver failure (SALF) is a rare syndrome characterized by rapid deterioration of liver function, usually in patients without underlying liver disease; the only effective treatment is transplantation. In this study, we used thioacetamide (TAA), a known xenobiotic hepatotoxicant, to induce SALF in rats. This was followed by administration of glutamine in an attempt to activate antioxidative defenses *via* the erythroid 2-related factor 2 (Nrf2) pathway and mitigate liver injury. Glutamine successfully activated Nrf2 and inhibited TLR4/NF κ B-mediated inflammation, allowing restoration of parenchymal architecture and recovery of several parameters to near-control levels.

Citation: Schemitt EG, Hartmann RM, Colares JR, Licks F, Salvi JO, Marroni CA, Marroni NP. Protective action of glutamine in rats with severe acute liver failure. *World J Hepatol* 2019; 11(3): 273-286

URL: <https://www.wjgnet.com/1948-5182/full/v11/i3/273.htm>

DOI: <https://dx.doi.org/10.4254/wjh.v11.i3.273>

INTRODUCTION

Severe acute liver failure (SALF) is a complex and rare syndrome characterized by rapid deterioration of liver function, usually in patients without underlying liver disease^[1,2]. Management includes intensive and comprehensive supportive care, but the only effective treatment to date is liver transplantation^[3].

The xenobiotic thioacetamide (TAA) has been used to induce hepatic damage in animals, and constitutes an effective experimental model to study the mechanisms involved in the pathophysiology of SALF and investigate potential therapies thereof.

Several studies have implicated oxidative stress and inflammation as critical events involved in experimental SALF^[4-9].

Reactive oxygen species (ROS) are generated during the process of oxygen metabolism and play several important physiological roles, including signal transduction, defense against microbial pathogens, and gene expression to support cell growth or cell death signaling pathways^[5,10]. Reactive nitrogen species (RNS), in turn, are derived from nitric oxide (NO), which is produced *via* inducible nitric oxide synthase (iNOS) activity^[5,6]. Because of their unique chemical characteristics, ROS and RNS can trigger lipid peroxidation and cause DNA strand breaks and protein oxidation, resulting in cellular injury. Oxidative and nitrosative stress represents an imbalance in the production and elimination of these reactive species and a decrease in the production of antioxidants^[5,11,12].

The antioxidant defense system is essential for cell protection. Antioxidant enzymes such as superoxide dismutase (SOD), catalase (CAT), and glutathione peroxidase (GPx), as well as non-enzymatic electron receptors such as glutathione (GSH), are affected by oxidative stress conditions^[12,13]. The nuclear factor erythroid 2-related

factor 2 (Nrf2) is an important regulator of redox balance. Under physiological conditions, Nrf2 is stored in the cytoplasm in an inactivated form, bound to Kelch-like ECH-associated protein 1 (Keap1). Under stress conditions, Nrf2 dissociates Keap1 and is translocated to the nucleus, where it promotes expression of cytoprotective target genes, such as NADPH quinone oxidoreductase1 (NQO1), antioxidant enzymes, and phase-II detoxification enzymes such as glutathione S-transferase (GST)^[5,14-16].

Inflammation is a key component of several liver diseases. The inflammatory process leads to parenchymal damage, which progresses to fibrosis, liver cancer, and, occasionally, SALT^[17]. Metabolites of hepatotoxic drugs bind to a toll-like receptor 4 (TLR4) complex that activates nuclear factor kappa B (NFκB), triggering the production of pro-inflammatory cytokines, such as tumor necrosis factor-α (TNF-α), interleukin (IL)-1β, and IL-6, and modulation of anti-inflammatory cytokines such as IL-10^[12,14,17,18]. Furthermore, it can stimulate production of the enzymes cyclooxygenase-2 (COX-2) and iNOS, both of which act as inflammatory mediators^[19].

Many isolated compounds have been investigated for their potential to eliminate oxidative stress and mitigate the inflammatory process in liver diseases. Within this context, glutamine (Gln) has been investigated due to its important role in a wide range of metabolic pathways. It is indispensable for nucleotide, glucose, and protein synthesis. It is a precursor of GSH and plays a key role in the immune defense of the gut mucosal barrier, participating in immunoglobulin formation^[20,21]. Several studies in humans have shown that Gln modulates the expression of genes related to the activation of pathways involved in several disease states^[22-25]. Furthermore, studies conducted in different experimental models have demonstrated beneficial effects of Gln on the rat liver, bowel, and stomach^[21,26-30].

Within this context, the present study aimed to evaluate the effect of Gln as an antioxidant and its role in the inflammatory process in an experimental model of IHAG induced by TAA.

MATERIALS AND METHODS

Ethical considerations

This study was conducted at the Animal Experimentation Unit and the Laboratory of Experimental Hepatology and Gastroenterology, Hospital de Clínicas de Porto Alegre, after approval from the Institutional Animal Care and Use Committee (opinion no. CEUA 15-0175).

Animal handling followed the ethical principles for animal experimentation mandated by current Brazilian legislation (Law no. 11794/2008), the standards of the Brazilian Council for the Control of Animal Experimentation (CONCEA), the State Code for Animal Protection, and established local procedures for the care and use of animals in experimental research.

Experimental procedures

Twenty-eight male Wistar rats (mean weight 300 g) were used in this study. During the experiment, the animals were housed in boxes (47 cm × 34 cm × 18 cm) lined with wood shavings, in a 12-h light/dark cycle, and a controlled temperature of 18 to 22 °C. Water and feed were given *ad libitum*. The animals were randomized in four groups (*n* = 7 each): control (CO), control plus glutamine (CO + G), TAA, and TAA plus glutamine (TAA + G).

IHAG was induced by intraperitoneal administration of two doses of TAA, 400 mg/kg in normal saline solution (0.9% NaCl), with an 8-hour interval between doses^[8]. The glutamine-treated groups received intraperitoneal Gln (Sigma Chemical®, St. Louis, MO, United States), 25 mg/kg in 1 mL 0.9% NaCl. The first dose was administered 30 min after the last dose of TAA; the second and third doses of Gln were administered 24 and 36 h, respectively, after the start of the experiment.

At 48 h, the animals were weighed and anesthetized by intraperitoneal injection of a mixture of ketamine hydrochloride (95 mg/kg) and 2% xylazine hydrochloride (8 mg/kg). Blood was then collected from the retro-orbital plexus with a glass capillary tube and placed into a heparin-containing test tube to prevent coagulation.

After blood sampling, animals were euthanized by anesthetic overdose (three times the therapeutic dose, as per CONCEA guidelines)^[31]. Upon confirmation of death, the abdominal region was shaved and disinfected, a midline ventral laparotomy was performed, and the liver was removed in sections for storage and subsequent analysis. One liver fragment was submerged in 10% formaldehyde solution for 24 h for histological examination, while another fragment was frozen -80 °C for other analyses.

Histological examination of hepatic tissue

Tissue samples were fixed in 10% formalin and embedded in paraffin. The resulting paraffin blocks were then placed in a Leitz® 1512 microtome and cut into sections 3 µm thick. The slides were then dipped in hematoxylin and eosin (HE) for 5 min each and placed in a running water bath. For dehydration, the slides were run through a graded ethanol series, followed by two xylol baths. Finally, coverslips were mounted with Canada balsam. Slides were examined under a light microscope coupled to a digital camera. Images were captured using Image-Plus software (Media Cybernetics®, Bethesda, United States) at a magnification of 200×. Hallmarks of acute liver injury were scored on a scale of 0 to 3, where 0 = normal hepatic tissue; 1 = mild damage with scant inflammatory infiltration; 2 = moderate damage and infiltration; and 3 = severe damage with infiltration and loss of hepatic architecture.

Spectrophotometric analysis of biochemical parameters

Hepatic integrity was assessed by measurement of the liver enzymes aspartate aminotransferase (AST), alanine aminotransferase (ALT), and alkaline phosphatase (ALP) in plasma, using the commercially available Liquiform Labtest® kit (a kinetic spectrophotometric assay). Protein content in liver homogenate was determined by Bradford's method^[32]. Lipid peroxidation was investigated by the thiobarbituric acid-reactive substances (TBARS) method^[33]. Levels of GSH were evaluated^[34], as well as activity of the antioxidant enzymes catalase (CAT)^[35] and glutathione peroxidase (GPx)^[36] and of the phase-II detoxification enzyme glutathione S-transferase (GST)^[37]. Production of nitric oxide metabolites (NO₂/NO₃) was measured indirectly by the Griess reaction^[38].

Western blot analysis of protein expression

Cytoplasmic and nuclear extracts were prepared from liver homogenates^[39]. The supernatant fraction was collected, aliquoted, and stored at -80 °C. Protein content was determined by Bradford's method^[32]. Lysed proteins were separated by sodium dodecyl sulfate-polyacrylamide gel electrophoresis (SDS-PAGE) and transferred to polyvinylidene fluoride (PVDF) membranes^[40,41]. The membranes were then blocked with 5% skim milk in Tris buffer containing 0.05% Tween (TTBS) for 1 hour at room temperature and probed overnight at 4 °C with anti-Nrf2 (57 kDa), anti-Keap1 (69 kDa), anti-NQO1 (31 kDa), anti-SOD (32 kDa), anti-TLR4 (95 to 120 kDa), anti-NFκB (65 kDa), anti-COX-2 (21 kDa), and anti-iNOS (120 kDa) antibodies (Santa Cruz Biotechnology, Santa Cruz, CA, United States), diluted 1:200 to 1:1000 with TTBS in dehydrated milk at 5%. Primary antibodies were detected with HRP-conjugated anti-rat IgG, anti-rabbit IgG, or anti-goat IgG secondary antibodies (Santa Cruz Biotechnology, Santa Cruz, CA, United States). Protein detection was performed with a commercially available electrochemiluminescence kit (Amersham Pharmacia Biotech, Little Chalfont, Bucks, England)^[42]. Density of the specific bands was quantified with imaging densitometry software (Scion Image, Scion Corporation, Frederick, MA, United States).

Multiplex analysis

Levels of IL-1, IL-6, IL-10, and TNF-α were measured in hepatic tissue homogenates using a MILLIPLEX™ MAP Rat Cytokine bead-based multiplex assay kit (RCYTO-80K, Millipore, Billerica, MA, United States). The MILLIPLEX™ MAP method is based on Luminex® xMAP™ technology. All procedures were performed in accordance with manufacturer recommendations. Tissue specimens were diluted 1:5 in sample diluent and incubated in duplicate overnight with TNF-α, IL-1, IL-6, and IL-10 capture beads. The beads were subsequently washed and incubated for 2 h with biotin-conjugated detection antibody, and then for 30 min with streptavidin-phycoerythrin. Bead fluorescence was read in a Luminex 100 IS Multiplex BioAssay analyzer. Cytokine concentrations were determined from these readings using four standard curves. Results were expressed as pg/mL.

Statistical analysis

Quantitative data were expressed as mean ± SE. Groups were compared by one-way analysis of variance (ANOVA). Differences in means were located by the Student-Newman-Keuls procedure. Data were analyzed in program GraphPad Instat 3.1, and significance was accepted at *P* < 0.05. The statistical methods of this study were reviewed by Ceres Andréia Vieira Oliveira, from the Regional Statistical Council of Rio Grande do Sul and Santa Catarina, Brazil.

RESULTS

Histopathological analysis

On histological examination of H&E-stained slides at 200× magnification (Figure 1), disruption of the hepatic parenchyma was observed in the TAA group, with inflammatory infiltration, massive necrosis, and ballooning; none of these features occurred in the CO or CO + G groups. Photomicrographs of liver tissue from rats in the TAA + G group show regeneration of the hepatic parenchyma, with a decrease in inflammatory infiltration and a substantial reduction in ballooning and spotty necrosis.

Assessment of hepatic cellular integrity

Liver function tests (Table 1) showed increased levels of liver enzymes in TAA group animals, which decreased significantly when Gln was administered ($P < 0.05$).

Assessment of oxidative stress

Assessment of lipid peroxidation by the TBARS method (Figure 2) revealed a significant increase in the TAA group in relation to the CO and CO + G groups ($P < 0.001$). Again, significant reductions were observed in the TAA + G group (to which Gln was administered) as compared with the TAA group ($P < 0.001$).

Nuclear expression of Nrf2 (Figure 3A) was decreased in the TAA group as compared with the CO and CO + G groups ($P < 0.01$), and increased in the TAA + G group as compared with the TAA group ($P < 0.05$). Conversely, expression of the inhibitory cytoplasmic protein Keap1 (Figure 3B) was increased in the TAA group as compared to both control groups ($P < 0.001$) and significantly reduced in the TAA + G group when compared to the TAA group ($P < 0.01$).

Expression of both NQO1 (Figure 4A) and SOD (Figure 4B) was decreased in the TAA group compared to the CO and CO + G groups ($P < 0.001$ and $P < 0.05$, respectively) and increased in the TAA + G group as compared to the TAA group ($P < 0.01$).

GSH levels (Figure 5) were statistically lower in the TAA group than in both control groups ($P < 0.01$), but increased significantly in the TAA + G group ($P < 0.01$).

Table 2 shows the findings of analysis of activity of the antioxidant enzymes CAT and GPx and the detoxification enzyme GST. GPx enzyme activity was increased in the TAA group as compared with the CO and CO + G groups ($P < 0.001$), and decreased in the Gln-treated group as compared with the TAA group ($P < 0.01$). CAT activity exhibited the inverse behavior; it was lower in the TAA group than in the control groups ($P < 0.01$) and higher in the TAA + G group than in the TAA group ($P < 0.01$). GST activity increased in the TAA group ($P < 0.001$) and decreased in the Gln-treated group ($P < 0.001$), which is consistent with its detoxifying role.

Assessment of the inflammatory process

Cytoplasmic expression of TLR4 (Figure 6A) and nuclear expression of NFκB (Figure 6B) were significantly increased in the TAA group as compared with control groups ($P < 0.001$), and significantly decreased in the TAA + G group *vs* the TAA group ($P < 0.001$).

Levels of the proinflammatory cytokines IL-1β, IL-6, and TNFα (Table 3) were higher in the TAA group than in both control groups, CO and CO + G ($P < 0.001$). These levels decreased significantly in the TAA + G group *vs* the TAA group ($P < 0.01$). In contrast, levels of the anti-inflammatory cytokine IL-10 were decreased in the TAA group in relation to the CO and CO + G groups ($P < 0.001$) and increased in the TAA + G group *vs* the TAA group ($P < 0.001$).

Expression of both COX-2 (Figure 7A) and iNOS (Figure 7B) was increased in the TAA group compared to the CO and CO + G groups ($P < 0.001$) and decreased in the TAA + G group as compared to the TAA group ($P < 0.01$).

Assessment of NO levels through their metabolites (nitrites and nitrates) (Figure 8) revealed a significant increase in the TAA group *vs* the CO and CO + G groups ($P < 0.001$) and a significant decrease in the TAA + G group as compared with the TAA group ($P < 0.05$).

DISCUSSION

SALF is a syndrome that causes a marked decline in hepatocyte function, leading to multiple organ failure and leads to an extremely high mortality rate due to several etiologies: drug-induced liver injury (DILI), xenobiotics, viral hepatitis, diseases metabolic, vascular and autoimmune. In many situations the cause remains unknown. The therapeutic armamentarium available to prevent or treat SALF is still very limited^[18]. Studies using TAA as an inducer of tissue damage have shown that this xenobiotic leads to different degrees of liver injury depending on the dose and timing

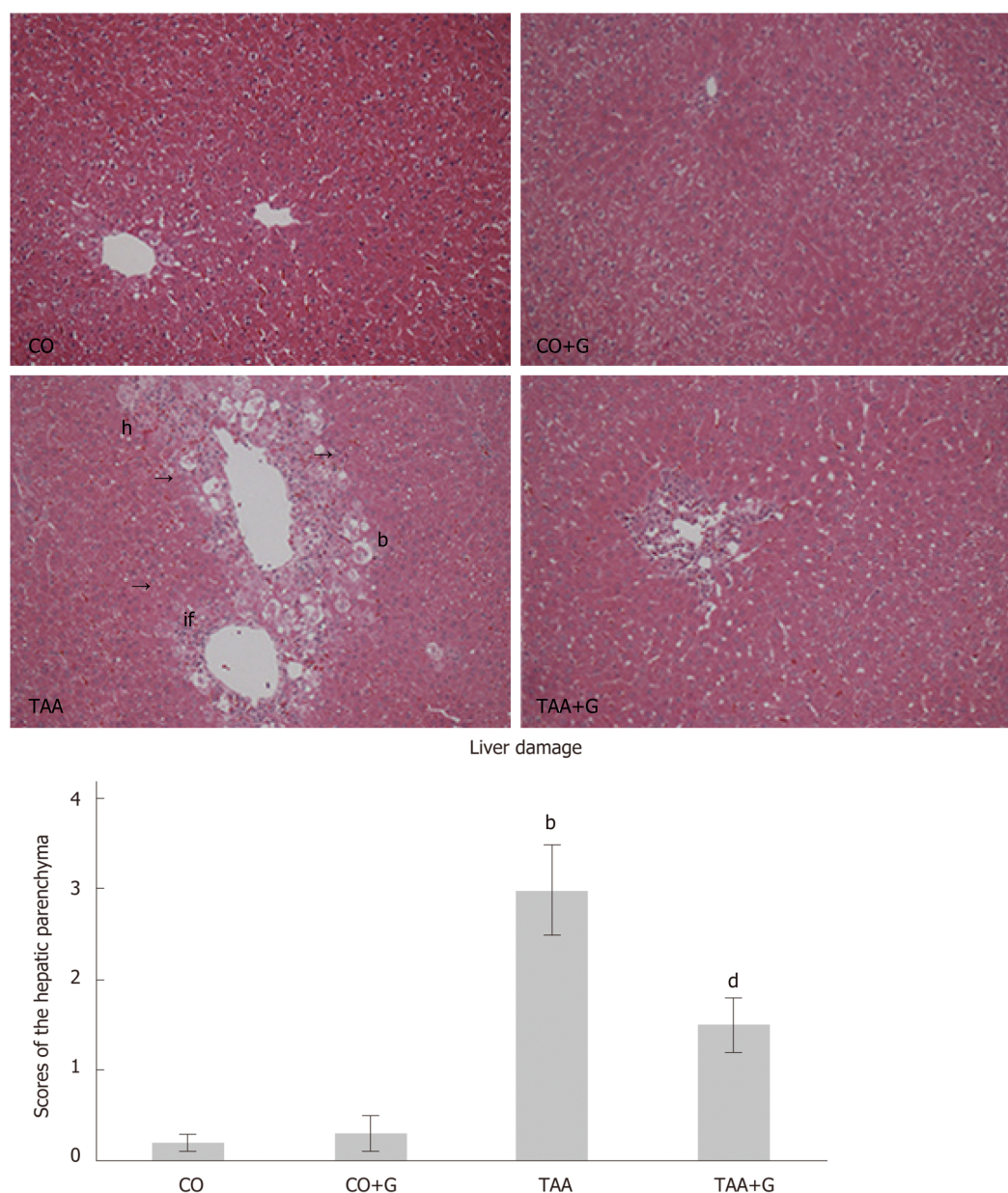


Figure 1 Effect of glutamine on liver injury in animals exposed to an experimental model of severe acute liver failure. Representative photomicrographs; original magnification, 200 ×. Hematoxylin and eosin (HE) stain. In the Thioacetamide (TAA) group, there is visible disruption of the hepatic parenchymal architecture, with inflammatory infiltration, hemorrhage, ballooning, and massive necrosis. The glutamine-treated group (TAA + G) exhibits a reduction of these parameters and restructuring of the hepatic parenchyma. There were no visible tissue changes in the CO and CO + G groups. CO: Control; G: Glutamine; TAA: Thioacetamide. If: Inflammatory infiltrate; h: Hemorrhage; b: Ballooning; n: Necrosis. Values expressed as mean ± SE. ^b $P < 0.001$, TAA group vs groups CO and CO + G; ^d $P < 0.01$, TAA + G group vs the TAA group.

of administration. This study aimed to evaluate the damage caused by acute administration of TAA in rats and assess the effects of Gln on the Nrf2-mediated antioxidant pathway and on chemical mediators of inflammation.

We observed extensive destruction of the hepatic parenchyma with necrosis, spotty hemorrhaging, leukocyte infiltration, and ballooning in the group of animals administered TAA. These findings are consistent with previous studies that reported hepatic tissue damage in experimental models using TAA^[43-45]. In the present study, Gln was able to mitigate changes in the parameters of interest, thus restoring the hepatic parenchyma. Sellmann *et al.* showed that Gln contributed to a reduction of inflammatory infiltration in the livers of mice with non-alcoholic steatohepatitis induced by a liquid Western-style diet (WSD)^[28]. Hartmann *et al.* found that Gln reduced hemorrhagic spots, necrosis, and inflammatory infiltration in the liver of rats subjected to intestinal ischemia–reperfusion injury^[21].

Similar results were found on analysis of hepatic cell integrity. Gln reduced serum

Table 1 Effect of glutamine on hepatic integrity levels in rats with severe acute liver failure

Enzyme	CO	CO + G	TAA	TAA + G
AST (U/L)	38.25 ± 5.82	44.96 ± 5.69	623.58 ± 51.66 ^a	269.38 ± 33.26 ^c
ALT (U/L)	29.65 ± 4.65	33.45 ± 3.12	326.27 ± 33.65 ^a	66.54 ± 9.49 ^c
ALP (U/L)	21.36 ± 2.69	19.64 ± 0.96	71.49 ± 4.22 ^a	29.64 ± 3.33 ^c

^aP < 0.05, TAA, CO *vs* CO + G;^cP < 0.05, TAA + G *vs* TAA. Values expressed as mean ± SE. CO: Control; G: Glutamine; TAA: Thioacetamide; AST: Aspartate aminotransferase; ALT: Alanine aminotransferase; ALP: Alkaline phosphatase.

levels of AST, ALT, and ALP, while significantly increased levels of these enzymes were found in animals in the TAA group, suggesting massive hepatic impairment after exposure to the xenobiotic. In other studies, Gln was also able to decrease serum levels of these enzymes, thus corroborating our findings^[7,14,46].

We also observed an increase in TBARS levels in the livers of animals in the TAA group, which is indicative of increased lipid peroxidation. Other authors found similar increases in TBARS in studies that used TAA to induce liver damage^[6,7,43]. Again, Gln administration was able to reduce these levels in our animals, corroborating the findings of several other studies that have demonstrated its protective effect in different experimental models^[21,26,47].

Cellular stress mediators activate Nrf2, which is translocated to the nucleus and binds to DNA through a region known as the antioxidant response element (ARE). This promotes expression of cytoprotective target genes, including antioxidant and detoxification enzymes^[5]. In the present study, Gln promoted increased nuclear expression of Nrf2, whereas cytoplasmic expression of its inhibitory protein Keap1 was downregulated. Gln also promoted increased expression of the NQO1 protein and the antioxidant enzyme SOD. Similar results were reported in a study that evaluated expression of the Nrf2/Keap1 antioxidant pathway, NQO1, and SOD in the liver of rats subjected to intestinal ischemia and reperfusion^[14].

GSH is considered an important marker of the antioxidant defenses of the cell. High doses of TAA lead to liver damage because it is biotransformed into a rapidly reacting metabolite that causes an imbalance of the glutathione redox cycle^[44]. In this study, Gln was able to increase GSH levels in liver tissue, demonstrating its protective role. Similar results were observed by Cruzat *et al.*, who studied the antioxidant effects of Gln in endotoxemic animals^[47].

The first line of antioxidant defense is represented by the antioxidative enzymes, such as CAT and SOD. In this study, CAT activity was decreased in the TAA group in relation to both control groups. This reduction may reflect the redox imbalance induced by stress resulting from xenobiotic administration. Conversely, CAT activity was increased in the group which received Gln treatment. Other studies using TAA-induced liver damage models have demonstrated increased CAT activity in animals treated with berberine and α-lipoic acid^[19,46].

GPx enzyme activity was increased in the TAA group and decreased in the Gln-treated group. The proper balance of antioxidative enzyme activity plays an important role in cellular protection against oxidative stress. GPx acts in an attempt to reduce molecules with oxidative potential, especially hydrogen peroxide and hydroperoxides, which may explain its increased activity in the group of animals that received TAA. Similar results regarding GPx activity were reported in other studies that used the experimental model of TAA-induced SALF and evaluated the antioxidant action of vitamin E and melatonin^[6,7].

GST is an important cellular detoxification enzyme that works in tandem with GSH to remove toxic metabolites. In this study, GST was increased in the TAA group, and Gln treatment was able to reduce its activity. Other authors have reported similar increases in GST in other hepatotoxicity models^[7,48]. The protective action of Gln in this experimental model may be due to the fact that it is a precursor for GSH synthesis.

The link between oxidative stress and inflammation has been recognized in many disease states, including those which affect the liver. ROS stimulate signaling molecules such as TLR4 to activate inflammatory mediators, including NFκB, which upregulates the production of inflammatory cytokines (such as IL-1β, IL-6, and TNFα) and other mediators of inflammation (such as iNOS and COX-2)^[46].

In this study, expression of TLR4 and NFκB in the TAA group was increased in relation to both control groups. Similar results were reported in another study that evaluated TLR4 signaling pathways in a model of TAA-induced hepatic fibrosis and

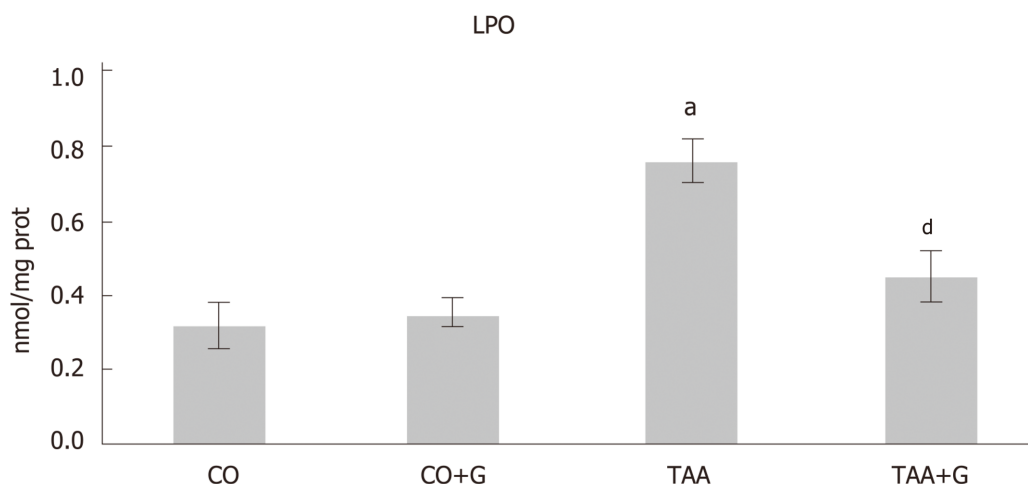


Figure 2 Assessment of lipid peroxidation in the liver of rats with severe acute liver failure. Values expressed as mean \pm standard error. ^a $P < 0.05$ TAA group vs groups CO and CO + G; ^d $P < 0.01$ TAA + G group vs the TAA group. CO: Control; G: Glutamine; TAA: Thioacetamide.

liver carcinogenesis^[49] and in a study that evaluated NF κ B activity in an LPS-induced model of SALF^[18]. Gln was able to reduce TLR4 and NF κ B expression, thus demonstrating its effectiveness in blunting the inflammatory process. A decrease in inflammatory modulators was also observed in other experimental studies that used allopurinol and Gln as treatments^[14,50,51].

In the present study, levels of the proinflammatory cytokines IL-1 β , IL-6, and TNF α increased while those of the anti-inflammatory cytokine IL-10 declined in animals that received TAA as a hepatotoxicant. Gln reversed the inflammatory process, as demonstrated by a decrease in levels of IL-1 β , IL-6, and TNF α and an increase in levels of IL-10 in liver tissue after its administration. A previous study using the TAA model of liver injury also demonstrated an increase in levels of proinflammatory cytokines in animals that developed TAA-induced liver damage^[46]. Another study reported a similar anti-inflammatory action of Gln in the liver of animals subjected to experimental endotoxemia^[47].

Activation of the TLR4/NF κ B pathway promotes COX-2 production. In this study, COX-2 expression was increased in the group that received TAA and decreased in the group that received TAA followed by Gln as treatment. In another study of TAA-induced hepatotoxicity, the authors observed a similar increase in COX-2 expression, followed by decreased expression after treatment with allopurinol^[50].

As a hepatotoxicant, TAA may induce production of iNOS and, consequently, NO synthesis, which further increases inflammation in the liver. In this study, we observed overexpression of iNOS and an increase in NO (as measured by levels of its nitrite and nitrate metabolites) in the liver of animals with TAA-induced SALF. Gln was able to reverse these parameters, reducing iNOS expression and nitrite and nitrate levels. In a study using the intestinal ischemia-reperfusion model, the authors observed a similar pattern of iNOS expression and NO levels in the liver of animals which Gln treatment^[14].

Gln is an essential amino acid for several cell types, including hepatocytes. The mechanisms underlying the protective effects promoted by Gln include the antioxidant of GSH, which is dependent on a supply of glutamate—this, in turn, is synthesized from Gln. In addition, its protective role in the inflammatory process has been widely reported^[47]. Gln can attenuate oxidative stress and inflammation, consequently protecting against a variety of mechanisms of cell and tissue injury. In humans, Gln supplementation has been used in clinical practice especially in diseases of the gastrointestinal tract with daily doses that can reach 20 g, being administered preferably parenterally.

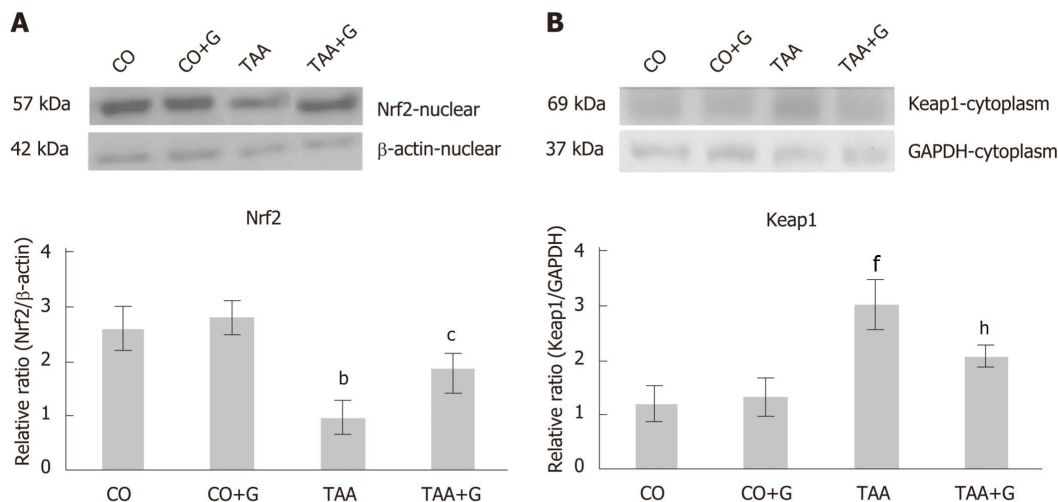
In conclusion, the results of this experimental study demonstrate that Gln administration had a protective role on the Nrf2-mediated antioxidant pathway and on inflammation activated by the TLR4/NF κ B pathway in rats with TAA-induced SALF. As the molecular pathways involved in the pathophysiology of SALF are manifold and complex, further experimental studies are warranted to investigate other potential mechanisms of Gln action in this setting.

Table 2 Effect of glutamine on enzyme activity of catalase, glutathione peroxidase, and glutathione S-transferase in rats with experimental severe acute liver failure

Enzyme	CO	CO + G	TAA	TAA + G
catalase (μmol/min/mg prot)	0.47 ± 0.04	0.51 ± 0.02	0.24 ± 0.06 ^b	0.38 ± 0.03 ^d
glutathione peroxidase (nmol/min/mg prot)	0.31 ± 0.05	0.36 ± 0.07	0.99 ± 0.11 ^c	0.72 ± 0.09 ^d
glutathione S-transferase (μmol/min/mg prot)	231.64 ± 11.25	249.65 ± 26.38	769.75 ± 55.69 ^c	326.81 ± 41.25 ^d

^b*P* < 0.01,^c*P* < 0.001, TAA, CO *vs* CO + G;^d*P* < 0.001, TAA + G *vs* TAA. Values expressed as mean ± SE. CO: Control; G: Glutamine; TAA: Thioacetamide.**Table 3** Effect of glutamine on levels of proinflammatory cytokines in the liver of rats with experimental severe acute liver failure

Cytokine	CO	CO + G	TAA	TAA + G
IL-1β (pg/mL)	61.10 ± 1.81	62.19 ± 1.32	465.96 ± 15.90 ^a	104.69 ± 8.57 ^b
IL-6 (pg/mL)	73.22 ± 0.98	78.21 ± 0.88	359.40 ± 12.62 ^a	155.93 ± 6.93 ^b
IL-10 (pg/mL)	145.69 ± 0.99	136.25 ± 1.23	58.28 ± 4.55 ^a	99.25 ± 3.11 ^b
TNF-α (pg/mL)	0.68 ± 0.23	0.71 ± 0.25	2.98 ± 0.64 ^a	1.45 ± 0.41 ^b

^b*P* < 0.001, TAA, CO *vs* CO + G; ^d*P* < 0.01, TAA + G *vs* TAA. Values expressed as mean ± SE. CO: Control; G: Glutamine; TAA: Thioacetamide.**Figure 3** Effect of glutamine in experimental severe acute liver failure. Western blot analysis of protein expression of (A) Nrf2 and (B) Keap1. Values expressed as mean ± standard error. ^b*P* < 0.01 TAA group *vs* groups CO and CO + G; ^c*P* < 0.05 TAA + G group *vs* the TAA group; ^d*P* < 0.001 TAA group *vs* groups CO and CO + G. ^h*P* < 0.01 TAA + G group *vs* the TAA group. CO: Control; G: Glutamine; TAA: Thioacetamide.

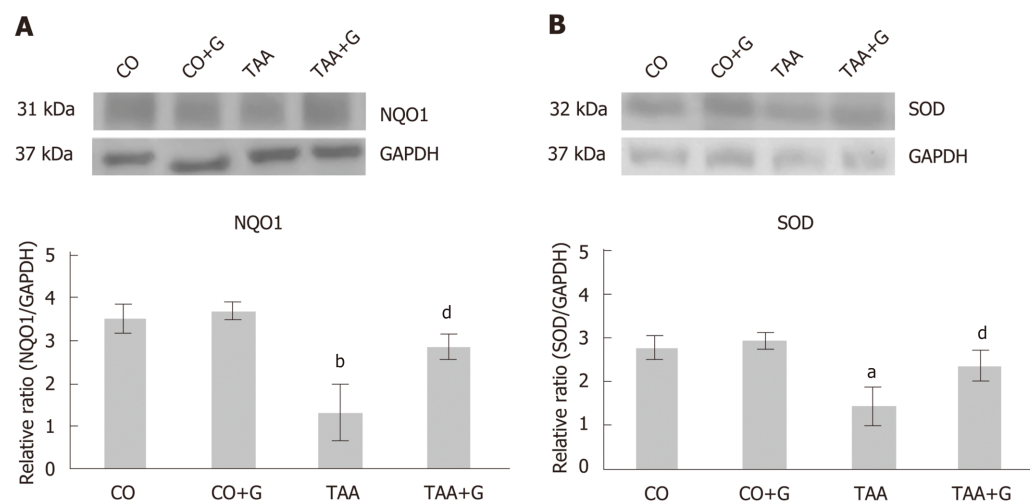


Figure 4 Effect of glutamine in experimental severe acute liver failure. Western blot analysis of protein expression of (A) NQO1 and (B) SOD. Values expressed as mean \pm SE. ^a $P < 0.05$ TAA group vs groups CO and CO + G. ^b $P < 0.01$ TAA group vs groups CO and CO + G; ^d $P < 0.01$ TAA + G group vs the TAA group. CO: Control; G: Glutamine; TAA: Thioacetamide.

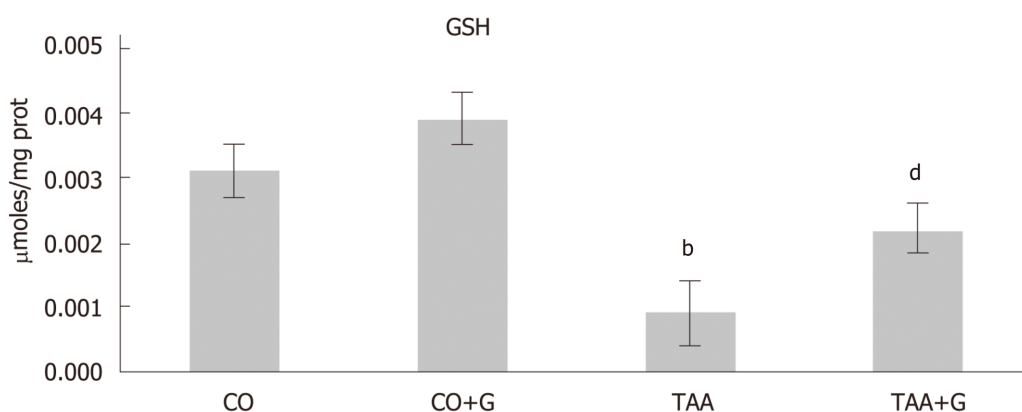


Figure 5 Assessment of glutathione (GSH) levels in the liver of rats treated with glutamine after induction of severe acute liver failure. Values expressed as mean \pm standard error. ^b $P < 0.001$ TAA group vs groups CO and CO + G; ^d $P < 0.01$ TAA + G group vs the TAA group. CO: Control; G: Glutamine; TAA: Thioacetamide.

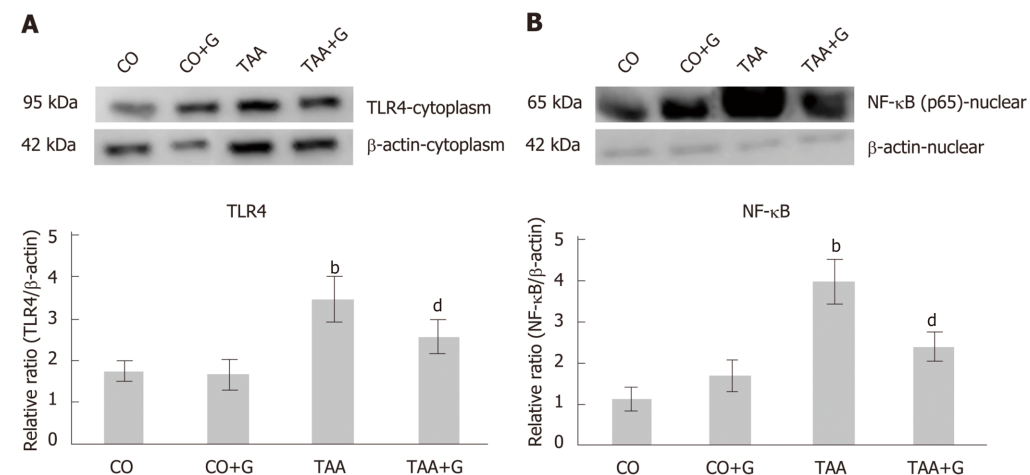


Figure 6 Effect of glutamine in experimental severe acute liver failure. Western blot analysis of protein expression of (A) TLR4 and (B) NFκB. Values expressed

as mean \pm SE. ^b $P < 0.001$ TAA group vs groups CO and CO + G; ^d $P < 0.001$ TAA + G group vs the TAA group. CO: Control; G: Glutamine; TAA: Thioacetamide.

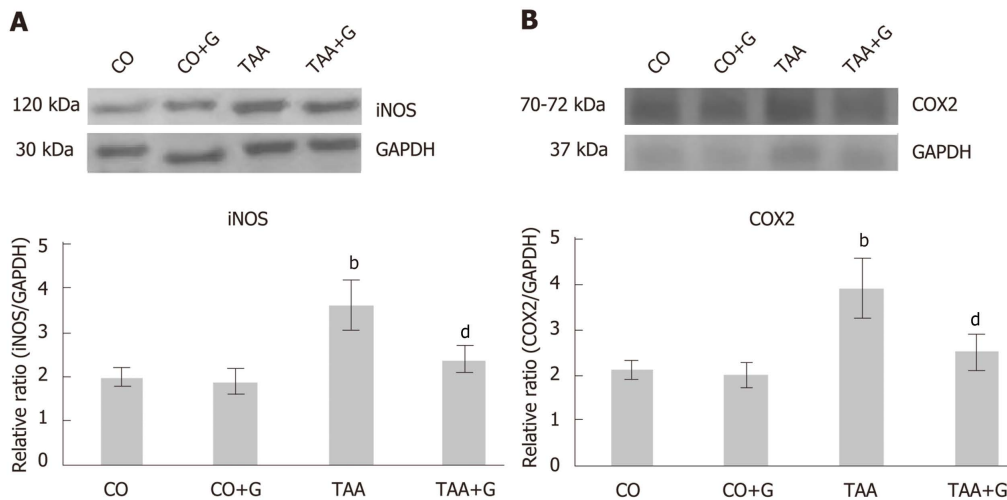


Figure 7 Effect of glutamine in experimental severe acute liver failure. Western blot analysis of protein expression of A: iNOS and B: COX-2. Values expressed as mean \pm SE. ^b $P < 0.001$ TAA group vs groups CO and CO + G; ^d $P < 0.01$ TAA + G group vs the TAA group. CO: Control; G: Glutamine; TAA: Thioacetamide.

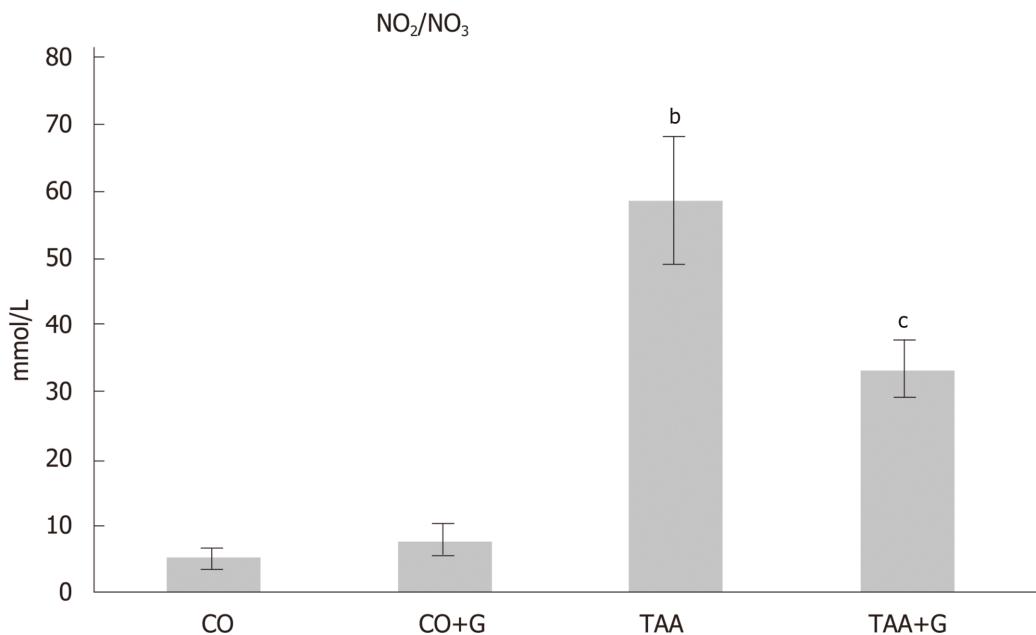


Figure 8 Effect of glutamine on levels of nitric oxide metabolites (nitrites and nitrates) in the liver of rats with severe acute liver failure. Values expressed as mean \pm SE. ^b $P < 0.001$, TAA group vs groups CO and CO + G; ^c $P < 0.05$, TAA + G group vs the TAA group. CO: Control; G: Glutamine; TAA: Thioacetamide.

ARTICLE HIGHLIGHTS

Research background

Severe acute liver failure (SALF) is a serious disease that does not have an effective treatment and liver transplantation is the only viable alternative. The mechanisms intrinsic to the pathophysiology of the disease are still not well understood and therefore, experimental studies are of fundamental importance in the attempt to elucidate the mechanisms and therapeutic agents. Glutamine is an amino acid used in the treatment of various diseases of the gastrointestinal tract and has been shown to be promising in previous studies of liver diseases.

Research motivation

In a previous study, the authors developed the experimental model of thioacetamide-induced SALF across different times. From the obtained data the best model to be studied was defined. It was evaluated the antioxidant action of glutamine that presented promising data. With the continuity of the research, we evaluated in this work the pathways of oxidative stress and inflammatory process at the molecular level, involved in the SALF. The results of this research are important indicators of the restorative role of glutamine in the SALF experimental model and will certainly provide a basis for a better understanding of the evaluated mechanisms contributing to the continuity of the studies.

Research objectives

The objective of this study was to investigate the action of glutamine on parameters of oxidative stress and inflammatory process in the experimental SALF. It is known that such parameters are implicated in the pathophysiology of various diseases. The understanding of the routes studied offers a basis for further studies that may evaluate other pathways involved in the disease, as well as the action of other therapeutic agents.

Research methods

To induce SALF in wistar rats the xenobiotic thioacetamide was used. The animals were randomized into different groups. In the treatment groups, the animals received doses of glutamine intraperitoneally. Blood tests were performed to evaluate hepatic integrity through a commercial kit. Liver portions were used for histopathological evaluation through hematoxylin and eosin staining. Techniques based on spectrophotometry were performed through protocols for the analysis of oxidative stress and inflammatory process. Protein expression was performed by Western Blot and cytokine analysis was done using multiplex technology based on magnetic beads through commercial kit.

Research results

Glutamine reduced hepatic integrity enzymes and restored the liver of the animals evidenced by decreased necrosis, ballooning and inflammation in the histopathological analysis. In addition, glutamine reduced lipid peroxidation and restored antioxidant enzyme activity. It was evidenced the decrease of the expression of proteins of the oxidative system and of the inflammatory process. Glutamine was able to increase the levels of interleukin 10, an important anti-inflammatory cytokine and also the expression of Nrf2, NQO1 and GSH levels, important proteins of the antioxidant protection system.

Research conclusions

When evaluating mechanisms implicated in the experimental SALF, studying parameters of oxidative stress and inflammatory process, it was possible to observe the protective action of glutamine in the liver of the animals. It is possible to confirm with this study that the oxidative stress and the inflammatory process play a primordial role in the progression of the disease, evidenced by the study of the molecular aspects. Glutamine has been shown to be effective by activating the antioxidant system and minimizing damage from the inflammatory process. Therefore, it presents as a viable alternative in the treatment of patients with severe hepatic insufficiency. Still, new studies confirming the efficacy of glutamine are needed so that in the future it may be part of the routine in the medical clinic.

Research perspectives

In this study the efficacy of the experimental model proposed by the authors in a previous study was confirmed. The pathophysiological mechanisms involved in SALF are diverse and complex. For further clarification of these mechanisms, other molecular routes should be investigated in an attempt to elucidate the aspects involved. We present the details of the involvement of the oxidative stress and the inflammatory process in this research and we hope that further studies can provide technical and theoretical data for the development of viable and effective strategies in the treatment of patients with SALF.

ACKNOWLEDGEMENTS

Funding was provided by Fundo de Incentivo à Pesquisa e Eventos (FIPE) do Hospital de Clínicas de Porto Alegre (HCPA); Universidade Federal do Rio Grande do Sul (UFRGS); Universidade Luterana do Brasil (ULBRA); the Coordination for the Improvement of Higher Education Personnel (CAPES); the National Council for Scientific and Technological Development (CNPq); and the Research Support Foundation of Rio Grande do Sul (FAPERGS). The authors thank Ceres Andréia Vieira Oliveira for her assistance with statistical analysis.

REFERENCES

- 1 **Cardoso LMDF**, Moreira LFP, Pinto MA, Henriques-Pons A, Alves LA. Domino Hepatocyte Transplantation: A Therapeutic Alternative for the Treatment of Acute Liver Failure. *Can J Gastroenterol Hepatol* 2018; **2018**: 2593745 [PMID: 30065914 DOI: 10.1155/2018/2593745]

- 2 **Scott TR**, Kronsten VT, Hughes RD, Shawcross DL. Pathophysiology of cerebral oedema in acute liver failure. *World J Gastroenterol* 2013; **19**: 9240-9255 [PMID: [24409052](#) DOI: [10.3748/wjg.v19.i48.9240](#)]
- 3 **Wu C**, Zhu Y, Yu M. Serum Metabonomics Analysis of Liver Failure Treated by Nonbioartificial Liver Support Systems. *Can J Gastroenterol Hepatol* 2018; **2018**: 2586052 [PMID: [30073154](#) DOI: [10.1155/2018/2586052](#)]
- 4 **Li AN**, Li S, Zhang YJ, Xu XR, Chen YM, Li HB. Resources and biological activities of natural polyphenols. *Nutrients* 2014; **6**: 6020-6047 [PMID: [25533011](#) DOI: [10.3390/nu6126020](#)]
- 5 **Li S**, Tan HY, Wang N, Zhang ZJ, Lao L, Wong CW, Feng Y. The Role of Oxidative Stress and Antioxidants in Liver Diseases. *Int J Mol Sci* 2015; **16**: 26087-26124 [PMID: [26540040](#) DOI: [10.3390/ijms161125942](#)]
- 6 **Miguel FM**, Schemitt EG, Colares JR, Hartmann RM, Morgan-Martins MI, Marroni NP. Action of Vitamin E on Experimental Severe Acute Liver Failure. *Arq Gastroenterol* 2017; **54**: 123-129 [PMID: [28198914](#) DOI: [10.1590/s0004-2803.201700000-03](#)]
- 7 **Salvi JO**, Schemitt EG, Colares JR, Hartmann RM, Marroni CA, Marroni NAP. Action of melatonin on severe acute liver failure in rats. *J Pharmacy Biol Sci* 2017; **12**: 62-75 [DOI: [10.9790/3008-1203036275](#)]
- 8 **Schemitt EG**, Colares JR, Hartmann RM, Morgan-Martins M, Marroni CA, Tunon MJ, Marroni NP. Effect of glutamine on oxidative stress and inflammation in a rat model of fulminant hepatic failure. *Nutricion hospitalaria* 2016; **33**: 92
- 9 **Shen Z**, Wang Y, Su Z, Kou R, Xie K, Song F. Activation of p62-keap1-Nrf2 antioxidant pathway in the early stage of acetaminophen-induced acute liver injury in mice. *Chem Biol Interact* 2018; **282**: 22-28 [PMID: [29331651](#) DOI: [10.1016/j.cbi.2018.01.008](#)]
- 10 **Finkel T**, Holbrook NJ. Oxidants, oxidative stress and the biology of ageing. *Nature* 2000; **408**: 239-247 [PMID: [11089981](#) DOI: [10.1038/35041687](#)]
- 11 **Cichoż-Lach H**, Michalak A. Oxidative stress as a crucial factor in liver diseases. *World J Gastroenterol* 2014; **20**: 8082-8091 [PMID: [25009380](#) DOI: [10.3748/wjg.v20.i25.8082](#)]
- 12 **Ajuwon OR**, Marnewick JL, Davids LM. l'-qRooibos (Aspalathus linearis) and its major flavonoids - Potential against oxidative stress-induced conditions. In: Gowder SJJ, ed. Basic principles and clinical significance of oxidative stress. *Intech* 2015; 171-218 [DOI: [10.5772/61614](#)]
- 13 **Valente MJ**, Carvalho F, Bastos Md, de Pinho PG, Carvalho M. Contribution of oxidative metabolism to cocaine-induced liver and kidney damage. *Curr Med Chem* 2012; **19**: 5601-5606 [PMID: [22856659](#) DOI: [10.2174/092986712803988938](#)]
- 14 **Hartmann RM**, Licks F, Schemitt EG, Colares JR, do Couto Soares M, Zabot GP, Fillmann HS, Marroni NP. Protective effect of glutamine on the main and adjacent organs damaged by ischemia-reperfusion in rats. *Protoplasma* 2017; **254**: 2155-2168 [PMID: [28382390](#) DOI: [10.1007/s00709-017-1102-3](#)]
- 15 **Wang H**, Chen X, Su Y, Pauksakon P, Hu W, Zhang MZ, Harris RC, Blackwell TS, Zent R, Pozzi A. p47(phox) contributes to albuminuria and kidney fibrosis in mice. *Kidney Int* 2015; **87**: 948-962 [PMID: [25565313](#) DOI: [10.1038/ki.2014.386](#)]
- 16 **Zhang YK**, Wu KC, Klaassen CD. Genetic activation of Nrf2 protects against fasting-induced oxidative stress in livers of mice. *PLoS One* 2013; **8**: e59122 [PMID: [23527105](#) DOI: [10.1371/journal.pone.0059122](#)]
- 17 **Ludwig JM**, Zhang Y, Chamulitrat W, Stremmel W, Pathil A. Anti-inflammatory properties of ursodeoxycholyl lysophosphatidylethanolamide in endotoxin-mediated inflammatory liver injury. *PLoS One* 2018; **13**: e0197836 [PMID: [29795632](#) DOI: [10.1371/journal.pone.0197836](#)]
- 18 **Yin X**, Gong X, Jiang R, Kuang G, Wang B, Zhang L, Xu G, Wan J. Emodin ameliorated lipopolysaccharide-induced fulminant hepatic failure by blockade of TLR4/MD2 complex expression in D-galactosamine-sensitized mice. *Int Immunopharmacol* 2014; **23**: 66-72 [PMID: [25173984](#) DOI: [10.1016/j.intimp.2014.08.018](#)]
- 19 **Xia X**, Su C, Fu J, Zhang P, Jiang X, Xu D, Hu L, Song E, Song Y. Role of α -lipoic acid in LPS/d-GalN induced fulminant hepatic failure in mice: studies on oxidative stress, inflammation and apoptosis. *Int Immunopharmacol* 2014; **22**: 293-302 [PMID: [25046589](#) DOI: [10.1016/j.intimp.2014.07.008](#)]
- 20 **Chen S**, Xia Y, Zhu G, Yan J, Tan C, Deng B, Deng J, Yin Y, Ren W. Glutamine supplementation improves intestinal cell proliferation and stem cell differentiation in weanling mice. *Food Nutr Res* 2018; **62** [PMID: [30083086](#) DOI: [10.29219/fnr.v62.1439](#)]
- 21 **Hartmann R**, Licks F, Schemitt EG, Colares JR, Da Silva J, Moura RM, Zabot GP, Fillmann HS, Marroni NP. Effect of glutamine on liver injuries induced by intestinal ischemia-reperfusion in rats. *Nutr Hosp* 2017; **34**: 548-554 [PMID: [28627188](#) DOI: [10.20960/nh.643](#)]
- 22 **Cruzat VF**, Petry ER, Trapegui J. Glutamine: biochemical, metabolic, molecular aspects and supplementation. *Revista Brasileira de Medicina do Esporte* 2009; **15**
- 23 **Curi R**, Lagranha CJ, Doi SQ, Sellitti DF, Procopio J, Pithon-Curi TC, Corless M, Newsholme P. Molecular mechanisms of glutamine action. *J Cell Physiol* 2005; **204**: 392-401 [PMID: [15795900](#) DOI: [10.1002/jcp.20339](#)]
- 24 **Liboni KC**, Li N, Scumpia PO, Neu J. Glutamine modulates LPS-induced IL-8 production through IkappaB/NF-kappaB in human fetal and adult intestinal epithelium. *J Nutr* 2005; **135**: 245-251 [PMID: [15671221](#) DOI: [10.1093/jn/135.2.245](#)]
- 25 **Ziegler TR**. Glutamine supplementation in cancer patients receiving bone marrow transplantation and high dose chemotherapy. *J Nutr* 2001; **131**: 2578S-84S; discussion 2590S [PMID: [11533316](#) DOI: [10.1093/jn/131.9.2578S](#)]
- 26 **Fillmann H**, Kretzmann NA, San-Miguel B, Llesuy S, Marroni N, González-Gallego J, Tuñón MJ. Glutamine inhibits over-expression of pro-inflammatory genes and down-regulates the nuclear factor kappaB pathway in an experimental model of colitis in the rat. *Toxicology* 2007; **236**: 217-226 [PMID: [17543437](#) DOI: [10.1016/j.tox.2007.04.012](#)]
- 27 **Kretzmann NA**, Fillmann H, Mauriz JL, Marroni CA, Marroni N, González-Gallego J, Tuñón MJ. Effects of glutamine on proinflammatory gene expression and activation of nuclear factor kappa B and signal transducers and activators of transcription in TNBS-induced colitis. *Inflamm Bowel Dis* 2008; **14**: 1504-1513 [PMID: [18623154](#) DOI: [10.1002/ibd.20543](#)]
- 28 **Sellmann C**, Baumann A, Brandt A, Jin CJ, Nier A, Bergheim I. Oral Supplementation of Glutamine Attenuates the Progression of Nonalcoholic Steatohepatitis in C57BL/6J Mice. *J Nutr* 2017; **147**: 2041-2049 [PMID: [28931589](#) DOI: [10.3945/jn.117.253815](#)]
- 29 **Ventura G**, Bortolotti M, Neveux N, Gusmini X, Nakib S, Sarfati G, Cynober L, De Bandt JP. Influence of an ω 3-fatty acid-enriched enteral diet with and without added glutamine on the metabolic response to injury in a rat model of prolonged acute catabolism. *Nutrition* 2017; **42**: 75-81 [PMID: [28870483](#) DOI: [10.1016/j.nut.2017.04.008](#)]

- 10.1016/j.nut.2017.06.001]
- 30 **Zabot GP**, Carvalhal GF, Marroni NP, Licks F, Hartmann RM, da Silva VD, Fillmann HS. Glutamine prevents oxidative stress in a model of portal hypertension. *World J Gastroenterol* 2017; **23**: 4529-4537 [PMID: 28740341 DOI: 10.3748/wjg.v23.i25.4529]
 - 31 **Brazil**. Ministério da Ciência, Tecnologia e Inovação. Resolução normativa nº 30, de 2 de fevereiro de 2016. Diretriz brasileira para o cuidado e a utilização de animais em atividades de ensino ou de pesquisa científica – DBCA. [Accessed 28 Sep 2018]. Available from: http://www3.icb.usp.br/corpoeditorial/ARQUIVOS/etica-animal/RESOLUCAO_NORMATIVA_N_%2030_DE_02_02_2016.pdf
 - 32 **Bradford MM**. A rapid and sensitive method for the quantitation of microgram quantities of protein utilizing the principle of protein-dye binding. *Anal Biochem* 1976; **72**: 248-254 [PMID: 942051]
 - 33 **Buege JA**, Aust SD. Microsomal lipid peroxidation. *Methods Enzymol* 1978; **52**: 302-310 [PMID: 672633]
 - 34 **Beutler E**, Duron O, Kelly BM. Improved method for the determination of blood glutathione. *J Lab Clin Med* 1963; **61**: 882-888 [PMID: 13967893]
 - 35 **Boveris A**, Chance B. The mitochondrial generation of hydrogen peroxide. General properties and effect of hyperbaric oxygen. *Biochem J* 1973; **134**: 707-716 [PMID: 4749271 DOI: 10.1042/bj1340707]
 - 36 **Guthenberg C**, Mannervik B. Glutathione S-transferase (transferase pi) from human placenta is identical or closely related to glutathione S-transferase (transferase rho) from erythrocytes. *Biochim Biophys Acta* 1981; **661**: 255-260 [PMID: 7295737]
 - 37 **Flohé L**, Günzler WA. Assays of glutathione peroxidase. *Methods Enzymol* 1984; **105**: 114-121 [PMID: 6727659]
 - 38 **Granger DL**, Anstey NM, Miller WC, Weinberg JB. Measuring nitric oxide production in human clinical studies. *Methods Enzymol* 1999; **301**: 49-61 [PMID: 9919553]
 - 39 **Tuñón MJ**, San Miguel B, Crespo I, Jorquera F, Santamaría E, Alvarez M, Prieto J, González-Gallego J. Melatonin attenuates apoptotic liver damage in fulminant hepatic failure induced by the rabbit hemorrhagic disease virus. *J Pineal Res* 2011; **50**: 38-45 [PMID: 20964705 DOI: 10.1111/j.1600-079X.2010.00807.x]
 - 40 **Mauriz JL**, Molpeceres V, Garcia-Mediavilla MV, González P, Barrio JP, González-Gallego J. Melatonin prevents oxidative stress and changes in antioxidant enzyme expression and activity in the liver of aging rats. *J Pineal Res* 2007; **42**: 222-230 [PMID: 17349019 DOI: 10.1111/j.1600-079X.2006.00409.x]
 - 41 **San-Miguel B**, Alvarez M, Culebras JM, González-Gallego J, Tuñón MJ. N-acetyl-cysteine protects liver from apoptotic death in an animal model of fulminant hepatic failure. *Apoptosis* 2006; **11**: 1945-1957 [PMID: 17021698 DOI: 10.1007/s10495-006-0090-0]
 - 42 **Tuñón MJ**, San-Miguel B, Crespo I, Laliena A, Vallejo D, Álvarez M, Prieto J, González-Gallego J. Melatonin treatment reduces endoplasmic reticulum stress and modulates the unfolded protein response in rabbits with lethal fulminant hepatitis of viral origin. *J Pineal Res* 2013; **55**: 221-228 [PMID: 23679826 DOI: 10.1111/jpi.12063]
 - 43 **Salama SM**, Abdulla MA, AlRashdi AS, Ismail S, Alkiyumi SS, Golbabapour S. Hepatoprotective effect of ethanolic extract of Curcuma longa on thioacetamide induced liver cirrhosis in rats. *BMC Complement Altern Med* 2013; **13**: 56 [PMID: 23496995 DOI: 10.1186/1472-6882-13-56]
 - 44 **Sukalingam K**, Ganesan K, Xu B. Protective Effect of Aqueous Extract from the Leaves of Justicia tranquebariensis against Thioacetamide-Induced Oxidative Stress and Hepatic Fibrosis in Rats. *Antioxidants (Basel)* 2018; **7** [PMID: 29932107 DOI: 10.3390/antiox7070078]
 - 45 **Wei DD**, Wang JS, Duan JA, Kong LY. Metabolomic Assessment of Acute Cholestatic Injuries Induced by Thioacetamide and by Bile Duct Ligation, and the Protective Effects of Huang-Lian-Jie-Du-Decoction. *Front Pharmacol* 2018; **9**: 458 [PMID: 29867467 DOI: 10.3389/fphar.2018.00458]
 - 46 **Eissa LA**, Kenawy HI, El-Karef A, Elsherbiny NM, El-Mihi KA. Antioxidant and anti-inflammatory activities of berberine attenuate hepatic fibrosis induced by thioacetamide injection in rats. *Chem Biol Interact* 2018; **294**: 91-100 [PMID: 30138605 DOI: 10.1016/j.cbi.2018.08.016]
 - 47 **Cruzat VF**, Bittencourt A, Scomazzon SP, Leite JS, de Bittencourt PI, Tirapegui J. Oral free and dipeptide forms of glutamine supplementation attenuate oxidative stress and inflammation induced by endotoxemia. *Nutrition* 2014; **30**: 602-611 [PMID: 24698353 DOI: 10.1016/j.nut.2013.10.019]
 - 48 **Zhang Z**, Lv Z, Shao Y, Qiu Q, Zhang W, Duan X, Li Y, Li C. Microsomal glutathione transferase 1 attenuated ROS-induced lipid peroxidation in *Apostichopus japonicus*. *Dev Comp Immunol* 2017; **73**: 79-87 [PMID: 28302499 DOI: 10.1016/j.dci.2017.03.011]
 - 49 **Seifert L**, Deutsch M, Alothman S, Alqunaibit D, Werba G, Pansari M, Pergamo M, Ochi A, Torres-Hernandez A, Levie E, Tippens D, Greco SH, Tiwari S, Ly NNG, Eisenthal A, van Heerden E, Avanzi A, Barilla R, Zambirinis CP, Rendon M, Daley D, Pachter HL, Hajdu C, Miller G. Dectin-1 Regulates Hepatic Fibrosis and Hepatocarcinogenesis by Suppressing TLR4 Signaling Pathways. *Cell Rep* 2015; **13**: 1909-1921 [PMID: 26655905 DOI: 10.1016/j.celrep.2015.10.058]
 - 50 **Demirel U**, Yalniz M, Aygün C, Orhan C, Tuzcu M, Sahin K, Ozercan IH, Bahçecioglu IH. Allopurinol ameliorates thioacetamide-induced acute liver failure by regulating cellular redox-sensitive transcription factors in rats. *Inflammation* 2012; **35**: 1549-1557 [PMID: 22535497 DOI: 10.1007/s10753-012-9470-5]
 - 51 **Raizel R**, Leite JS, Hypólito TM, Coqueiro AY, Newsholme P, Cruzat VF, Tirapegui J. Determination of the anti-inflammatory and cytoprotective effects of L-glutamine and L-alanine, or dipeptide, supplementation in rats submitted to resistance exercise. *Br J Nutr* 2016; **116**: 470-479 [PMID: 27215379 DOI: 10.1017/S0007114516001999]



Retrospective Cohort Study

Extreme hyperbilirubinemia: An indicator of morbidity and mortality in sickle cell disease

John Paul Haydek, Cesar Taborda, Rushikesh Shah, Preeti A Reshamwala, Morgan L McLemore, Fuad El Rassi, Saurabh Chawla

ORCID number: John Paul Haydek (0000-0003-2094-7181); Cesar Taborda (0000-0002-6612-5071); Rushikesh Shah (0000-0001-5472-9196); Preeti A Reshamwala (0000-0001-8620-9742); Morgan L McLemore (0000-0002-1107-1192); Fuad El Rassi (0000-0002-8583-0526); Saurabh Chawla (0000-0001-6841-4929).

Author contributions: Shah R, Reshamwala PA, McLemore ML, El Rassi F and Chawla S designed research; Haydek JP and Taborda C collected clinical data; Haydek JP and Shah R analyzed data; Haydek JP wrote the manuscript.

Institutional review board

statement: The study was reviewed and approved by the Emory Institutional Review Board under project number IRB00092809.

Informed consent statement: This study was retrospective in nature and was not associated with any clinical intervention and thus was exempt from informed consent per our institutional policies.

Conflict-of-interest statement: We have no financial relationships to disclose.

STROBE statement: The authors have read the STROBE statement and the manuscript was prepared and revised according to its checklist of items.

Open-Access: This article is an open-access article which was

John Paul Haydek, Department of Medicine, Emory University School of Medicine, Atlanta, GA 30322, United States

Cesar Taborda, Rushikesh Shah, Preeti A Reshamwala, Saurabh Chawla, Division of Digestive Diseases, Department of Medicine, Emory University School of Medicine, Atlanta, GA 30329, United States

Morgan L McLemore, Fuad El Rassi, Department of Hematology and Medical Oncology, Emory University School of Medicine, Atlanta, GA 30329, United States

Corresponding author: Saurabh Chawla, MD, FACP, Associate Professor, Division of Digestive Diseases, Department of Medicine, Emory University School of Medicine, 49 Jesse Hill Jr. Dr. SE, Suite 431, Atlanta, GA 30303, United States. saurabh.chawla@emory.edu
Telephone: +1-404-7781684
Fax: +1-404-7781681

Abstract

BACKGROUND

Sickle cell disease (SCD) is a disorder that results in increased hospitalizations and higher mortality. Advances in management have resulted in increases in life expectancy and led to increasing awareness of sickle cell hepatopathy (SCH). However, its impact in patients on the natural history and outcomes of SCD is not known. Our study aims to describe the prevalence of extreme hyperbilirubinemia (EH), one form of SCH, its effect on morbidity and mortality, and correlations between sickle cell genotype and SCH type. We hypothesize that EH is associated with higher morbidity and mortality.

AIM

To investigate the effects of EH on morbidity and mortality among patients with SCD.

METHODS

This retrospective cohort study was performed using a database of patients with SCD treated at Grady Memorial Hospital between May 2004 and January 2017. Patients with EH (defined as total bilirubin above 13.0 mg/dL) were identified. A control group was identified from the same database with patients with total serum bilirubin \leq 5.0 mg/dL. Electronic medical records were used to extract demographic information, laboratory values, radiology results, current medications, need for transfusions and mortality data. Two samples *T*-test, chi-

selected by an in-house editor and fully peer-reviewed by external reviewers. It is distributed in accordance with the Creative Commons Attribution Non Commercial (CC BY-NC 4.0) license, which permits others to distribute, remix, adapt, build upon this work non-commercially, and license their derivative works on different terms, provided the original work is properly cited and the use is non-commercial. See: <http://creativecommons.org/licenses/by-nc/4.0/>

Manuscript source: Invited manuscript

Received: November 25, 2018

Peer-review started: November 26, 2018

First decision: December 10, 2018

Revised: January 16, 2019

Accepted: January 28, 2019

Article in press: January 28, 2019

Published online: March 27, 2019

P-Reviewer: Morales-González JA, Rezaee-Zavareh MS

S-Editor: Yan JP

L-Editor: A

E-Editor: Zhang YL



squared test and Fisher's exact test were then used to compare the parameters between the two groups.

RESULTS

Out of the database, fifty-seven charts were found of patients with bilirubin > 13 mg/dL. Prevalence of severe SCH as defined by EH was 4.8% (57/1172). There were no demographic differences between patients with and without EH. Significant genotypic differences existed between the two groups, with hemoglobin SS SCD being much higher in the EH group ($P < 0.001$). Patients with severe EH had a significant elevations in alanine aminotransferase (157.0 ± 266.2 IU/L *vs* 19.8 ± 21.3 IU/L, $P < 0.001$), aspartate aminotransferase (256.5 ± 485.9 U/L *vs* 28.2 ± 14.7 U/L, $P < 0.001$) and alkaline phosphatase (218.0 ± 176.2 IU/L *vs* 85.9 ± 68.4 IU/L, $P < 0.001$). Patients with EH had significantly higher degree of end organ failure measured with quick Sequential Organ Failure Assessment scores (0.42 ± 0.68 *vs* 0.01 ± 0.12 , $P < 0.001$), increased need for blood products (63% *vs* 5%, $P < 0.001$), and exchange transfusions (10.5% *vs* 1.3%, $P = 0.022$).

CONCLUSION

Among patients with SCD, elevated levels of total bilirubin are rare, but indicative of elevated morbidity, mortality, and need for blood transfusions. Large differences in sickle cell genotype also exist, but the significance of this is unknown.

Key words: Sickle cell disease; Sickle cell hepatopathy; Liver diseases; Extreme hyperbilirubinemia; Mortality

©The Author(s) 2019. Published by Baishideng Publishing Group Inc. All rights reserved.

Core tip: Sickle cell hepatopathy is a rarely studied complication of sickle cell disease. Little is known about prognostic factors related to it. In our study, we identified patients with one indicator of sickle cell hepatopathy, extreme hyperbilirubinemia, and analyzed outcomes related to their clinical state. High levels of bilirubin are indicative of elevated morbidity and need for blood transfusion among patients with sickle cell disease.

Citation: Haydek JP, Taborda C, Shah R, Reshamwala PA, McLemore ML, Rassi FE, Chawla S. Extreme hyperbilirubinemia: An indicator of morbidity and mortality in sickle cell disease. *World J Hepatol* 2019; 11(3): 287-293

URL: <https://www.wjgnet.com/1948-5182/full/v11/i3/287.htm>

DOI: <https://dx.doi.org/10.4254/wjh.v11.i3.287>

INTRODUCTION

Sickle cell hepatopathy (SCH) encompasses a wide range of hepatic pathologies arising from variety of pathophysiologic insults^[1,2] in patients with sickle cell disease (SCD). The hepatobiliary manifestations are most commonly seen in patients with hemoglobin SS (Hb SS) anemia as compared to patients with sickle cell trait, hemoglobin SC disease and hemoglobin S-beta thalassemia. Multiple pathways contribute to the development of SCH and result in a myriad of different conditions including hepatic sequestration^[3,4], cholestasis and biliary obstruction^[2,5], and complications related to the transfusions that patients with SCD frequently receive^[6].

The impact of SCH on morbidity and mortality in SCD patients is often underrecognized. With evolving treatment strategies in SCD, improvements have been made in morbidity and mortality, resulting in higher longevity in SCD patients^[7]. As a result, some of the previously rare clinical scenarios, such as hepatobiliary complications of SCD, are more commonly encountered. Sickle cell related liver disease is associated with higher rates of morbidity. Previous studies have shown that factors such as hyperbilirubinemia, elevated ferritin, and alkaline phosphatemia are factors independently associated with mortality^[8]. However, several of these studies have been limited by small sample size. Mortality typically results due to complications related to sepsis or vascular complications. Some studies have estimated that acute liver failure was the primary cause of death for between 8%-

10.7% of patients with SCD^[9,10]. Despite this, liver failure and end stage liver disease are seldom identified as the immediate cause of death^[11-13].

Abnormal liver markers are frequently found in patients with SCD, but these are often limited to mild elevations in total bilirubin without rise in alanine aminotransferase (ALT) or aspartate aminotransferase (AST)^[14]. As compared to isolated rise in serum bilirubin, SCH has a variety of possible presentations and the absence of stable definitions of the individual conditions within the spectrum of SCH possesses a unique challenge in clinical management as well as research on SCH^[1].

Our study aims to describe the prevalence of extreme hyperbilirubinemia (EH), one of the key indicators of severe SCH and its effect on morbidity, mortality and healthcare expenditures related to SCH. We also want to better understand the risk factors related to it in a large cohort of patients with SCD seen at the Grady Memorial Hospital Sickle Cell Clinic. Third, we aim to identify whether there is any correlation between SCD genotype and severe SCH identified through EH.

MATERIALS AND METHODS

Identification of cases and controls

This retrospective cohort study was performed using a database of patients with SCD treated at Grady Memorial Hospital between May 2004 and January 2017. With institutional review board approval, the database was queried for patients with EH (defined as total bilirubin above 13.0 mg/dL). A control group was identified from the same database with patients with total serum bilirubin ≤ 5.0 mg/dL. Patient inclusion criteria included adults older than 18 years old, hemoglobin electrophoresis confirmation of SCD, and absence of biliary obstruction identified on abdominal ultrasound. Exclusion criteria also included patients with known infection with hepatitis A, B or C; diagnosis of autoimmune hepatitis; alcoholism; cirrhosis of different etiologies; follow-up less than one year and patients for whom a complete set of required data was unavailable.

Data analysis

Associations between laboratory results, hydroxyurea dosing, quick Sequential Organ Failure Assessment (qSOFA) score^[15] and rate of blood transfusions were assessed with two-sample *T*-tests. Chi-square testing was performed to compare the frequency of sickle cell genotypes. Fisher's exact test was used to compare rates of death within 1 year. Level of significance for all tests was set at 0.05. Patients were identified as having EH if total bilirubin was chronically elevated over the course of a hospitalization or for at least 6 wk as an outpatient to levels > 13.0 mg/dL with direct bilirubin $> 50\%$ of total bilirubin. This level of hyperbilirubinemia was selected because of previous usage in the literature and findings that published cases in the literature all had levels greater than 13.0 mg/dL^[16].

RESULTS

Patient populations

A total of 1172 patients with SCD were identified, out of which fifty-seven charts were found of patients with bilirubin greater than 13 mg/dL. 4.8% (57/1172) of patients were identified to have severe SCH as defined by EH. The control group consisted of 99 patients. There were no demographic differences between patients with and without EH (see [Table 1](#)). After data collection, 15 patients were removed from the case-arm due to inadequate patient records, leaving 42 patients.

Lab Abnormalities

Patients with severe EH had increased levels of ALT (157.0 ± 266.2 IU/L *vs* 19.8 ± 21.3 IU/L, $P < 0.001$), AST (256.5 ± 485.9 U/L *vs* 28.2 ± 14.7 U/L, $P < 0.001$) total bilirubin (18.41 ± 6.74 mg/dL *vs* 1.29 ± 0.19 mg/dL, $P < 0.001$) direct bilirubin (11.73 ± 6.03 mg/dL *vs* 0.28 ± 0.07 , $P < 0.001$) and alkaline phosphatase (AP; 218.0 ± 176.2 IU/L *vs* 85.9 ± 68.4 IU/L, $P < 0.001$) compared to controls (see [Table 2](#)). Given limited data, comparisons were not performed for prothrombin time or lactate dehydrogenase (LDH). There was insufficient data for comparison of prothrombin time or LDH.

Outcomes

Patients with EH had worse outcomes compared to the control group. They experienced higher rates of end organ failure measured with qSOFA scores ($0.42 \pm$

Table 1 Demographics differences in sickle cell disease patients with and without severe extreme hyperbilirubinemia

	SCD with EH	SCD without EH	P values
Gender: Male (percent)	21 (50%)	35 (35%)	0.11
Age in yr (mean \pm SD)	29.5 \pm 11.20	32.6 \pm 13.20	0.19
Race (African American)	41 (98%)	97 (98%)	0.89

SCD: Sickle cell disease; EH: Extreme hyperbilirubinemia.

0.68 *vs* 0.01 \pm 0.12, $P < 0.001$), increased need for blood products (63% *vs* 5%, $P < 0.001$), and exchange transfusions (10.5% *vs* 1.3%, $P = 0.022$). There were 2 deaths in the EH arm and 0 deaths in the control arm, so Fisher's exact test was used. While the results trended towards significance, they were not significantly different (4.7% *vs* 0%, $P = 0.09$). Two deaths occurred within the severe SCH group, and were due to acute chest syndrome and septic shock.

Hydroxyurea usage

Usage and dosage of hydroxyurea was analyzed between the two groups. Prescribing rates (34% *vs* 25%, $P = 0.27$) and average daily doses (278 \pm 469 mg *vs* 288 \pm 602 mg, $P = 0.95$) were not different between the two groups.

Sickle cell genotypes

There were significant differences among the genotype breakdown between those that experienced EH and the control groups. There were five types of genotypes identified: Hb SS, hemoglobin S beta thalassemia, hemoglobin S beta null thalassemia, hemoglobin SC and hemoglobin S beta thalassemia status undetermined (see Table 3). The EH group almost entirely consisted of Hb SS SCD, while the control group had a predominance of hemoglobin SC and sickle beta thalassemia. Fisher's exact test was done on the genotypes and showed significant differences between the two groups ($P < 0.0001$).

Correlations

There were weak correlations between total bilirubin levels and other liver enzymes. When plotted in relation to total bilirubin, Pearson coefficients were $r = 0.28$ for AP, $r = 0.24$ for ALT, $r = 0.29$ for AST, and $r = 0.23$ for LDH.

DISCUSSION

In this case-control study of sickle cell liver disease, we observed that patients with SCD who developed SCH as defined by EH had higher rates of other liver enzyme elevations as well as higher rates of morbidity, defined by end organ damage and need for blood transfusion. SCH is an under-diagnosed disease state, and one that will become more prominent in practice as patients with SCD live longer. It can often be difficult to diagnose because of the chronic hemolytic state that SCD patients are in, causing chronically elevated bilirubin levels and occasionally, mild elevations in transaminases. Previous studies^[16] have used a total bilirubin level of 13 mg/dL as a specific cutoff for a condition termed "EH" and used as a metric for SCH. We chose to use this same level as a definition of EH to maximize specificity, at the expense of potentially excluding milder cases of SCH.

These findings are consistent with our hypothesis that severe SCH, like other secondary complications of SCD, is associated with higher rates of morbidity. Mortality was higher in the EH group but was not statistically significant between the two samples given the absence of death among the control group and low number of deaths among the EH group. Surprisingly, there were no differences between the groups in regard to hydroxyurea usage or duration. While there are very limited studies evaluating hyperbilirubinemia or SCH as a predictor of mortality, our findings are consistent with other small analyses that showed associations between direct hyperbilirubinemia and increased mortality^[8,16]. Our mortality rates are lower than that seen in Feld *et al*^[8] although our length of follow-up was much shorter than used in their study. Additionally, Feld *et al*^[8] did not perform subgroup analysis on patients with very high levels of hyperbilirubinemia.

The differences in genotype identified between the two groups were a finding that was not expected originally. Although Hb SS disease is associated with more crises,

Table 2 Lab values and outcomes in sickle cell disease patients with and without severe sickle cell hepatopathy

	SCD with severe SCH	SCD without SCH	P values
Alkaline Phosphatase (IU/L; mean \pm SD)	218.0 \pm 176.2	85.9 \pm 68.4	< 0.001
Alanine Aminotransferase (IU/L; mean \pm SD)	157.0 \pm 266.2	19.8 \pm 21.3	< 0.001
Aspartate Aminotransferase (U/L; mean \pm SD)	256.5 \pm 485.9	28.2 \pm 14.7	< 0.001
Direct Bilirubin (mg/dL; mean \pm SD)	11.73 \pm 6.03	0.28 \pm 0.07	< 0.001
Total Bilirubin (mg/dL; mean \pm SD)	18.41 \pm 6.74	1.29 \pm 0.19	< 0.001
qSOFA (mean \pm SD)	0.42 \pm 0.68	0.01 \pm 0.12	< 0.001
Need for blood transfusion (number, percent)	24 (63%)	4 (5%)	< 0.001
Need for Exchange Transfusion (number, percent)	4 (10.5%)	1 (1.3%)	0.022
Mortality within 1 yr (number, percent)	2 (4.7%)	0 (0%)	0.09

SCD: Sickle cell disease; SCH: Sickle cell hepatopathy; qSOFA: Quick Sequential Organ Failure Assessment.

Hb SC disease is associated with higher rates of thromboembolic disease. The results may suggest that patients with *Hb SS* SCD are at increased risk for SCH. However, it may also indicate that patients with lesser variants of SCD, including *Hb SC* or sickle thalassemia, experience more mild variants of SCH and would not be identified using a relatively specific EH cutoff. Further study is needed to identify whether hepatic markers other than EH are reliable identifiers of SCH. Additionally, creation of a large database that also includes laboratory data prior to the onset of SCH may help in identifying predictive factors that aid in diagnosis.

Among patients with SCD, hydroxyurea is the only approved disease modifying therapy^[17]. A large randomized controlled study that prompted the drug's approval, the Multicenter Study of Hydroxyurea for Sickle Cell Anemia^[18], showed a significant reduction in rates of crises, rates of acute chest syndrome and need for blood transfusion. However, there was not a difference of rates of hepatic sequestration or hepatic failure between the groups, and it is unknown whether hydroxyurea use is protective against SCH. One case report showed improvement in chronic hepatic sequestration with long-term hydroxyurea use^[19], but there is little else published regarding hydroxyurea use and liver function. In our study, we did not see a difference in hydroxyurea use between the two groups but we could not reliably track the compliance of hydroxyurea use in our patients.

Our study has several limitations including small sample size, lack of analysis by genotype, and lack of exclusion of outpatient visits. The use of both inpatient and outpatient encounters did not allow us to accurately compare length of stay between the groups, which was hypothesized to be longer among the EH group. These limitations are balanced by the strengths of this study, including the novelty of data about SCH and the large database queried for this study.

In summary, our manuscript has identified SCH as a secondary complication of SCD that is associated with increased morbidity and higher healthcare utilization. Further study is needed to identify the longitudinal course of the disease, including whether there are predictive factors that precede the clinical presentation of SCH, whether sickle cell genotype is predictive of the likelihood of SCH, and whether there are protective factors that reduce the likelihood of developing SCH.

Table 3 Hemoglobin genotype breakdown between the extreme hyperbilirubinemia and control groups

	Hemoglobin SS (n)	Hemoglobin S Beta+ Thalassemia (n)	Hemoglobin S Beta null Thalassemia (n)	Hemoglobin S Beta (unknown) Thalassemia (n)	Hemoglobin SC (n)
Extreme hyperbilirubinemia	40	2	0	0	0
Control	33	11	2	2	51

EH: Extreme hyperbilirubinemia.

ARTICLE HIGHLIGHTS

Research background

Sickle cell hepatopathy is a category of pathologies that occur among patients with sickle cell disease, and has been rising in incidence as lifespan has increased. Additionally, based on autopsy studies, sickle cell hepatopathy is felt to be underreported and likely contributes to mortality in more cases than in realized. Previous studies have tried to identify risk factors associated with sickle cell hepatopathy but have been limited by small size.

Research motivation

With the increasing incidence of sickle cell hepatopathy, understanding risk factors and improving its recognition are important to its early diagnosis and treatment.

Research objectives

The main objectives of this study were to describe the prevalence of extreme hyperbilirubinemia, its effect on morbidity and mortality, and any association between sickle cell genotype and sickle cell hepatopathy.

Research methods

We used a retrospective observational cohort study to evaluate the epidemiology and outcomes behind extreme hyperbilirubinemia, a form of sickle cell hepatopathy. This was conducted at a hospital with a large population of patients with sickle cell disease.

Research results

About 5% of patients in our sickle cell disease database developed extreme hyperbilirubinemia. This cohort was associated with higher rates of systemic illness, measured by quick Sequential Organ Failure Assessment scores, higher rates of blood transfusions and higher rates of exchange transfusions. There was not a higher mortality rate in the extreme hyperbilirubinemia group. There were higher rates of patients with hemoglobin SS sickle cell disease among the extreme hyperbilirubinemia group compared to a control group, compared to other genotypes. Additionally, there were not significant differences in hydroxyurea use between groups.

Research conclusion

Our study highlights the increased morbidity and use of blood products seen among patients with extreme hyperbilirubinemia, a form of sickle cell hepatopathy. It also identifies different rates of sickle cell hepatopathy depending on the sickle cell genotype present. Finally, it shows that reported hydroxyurea doses did not have an effect on development of sickle cell hepatopathy.

Research perspective

Our study highlights the need for further study into types of sickle cell hepatopathy, whether strategies other than hydroxyurea can mitigate the risk of development of sickle cell hepatopathy, and whether there are any identifiable risk factors to increase rates of early diagnosis.

ACKNOWLEDGEMENTS

Special thanks are extended to Eugene Huang and Ziduo Zheng from the Emory Data Analytics and Biostatistics Core for assistance with statistical work.

REFERENCES

- 1 Banerjee S, Owen C, Chopra S. Sickle cell hepatopathy. *Hepatology* 2001; **33**: 1021-1028 [PMID: 11343226 DOI: 10.1053/jhep.2001.24114]
- 2 Shah R, Taborda C, Chawla S. Acute and chronic hepatobiliary manifestations of sickle cell disease: A

- review. *World J Gastrointest Pathophysiol* 2017; **8**: 108-116 [PMID: 28868180 DOI: 10.4291/wjgp.v8.i3.108]
- 3 **Ebert EC**, Nagar M, Hagspiel KD. Gastrointestinal and hepatic complications of sickle cell disease. *Clin Gastroenterol Hepatol* 2010; **8**: 483-9; quiz e70 [PMID: 20215064 DOI: 10.1016/j.cgh.2010.02.016]
- 4 **Issa H**, Al-Salem AH. Hepatobiliary Manifestations of Sickle Cell Anemia. *Gastroenterology Res* 2010; **3**: 1-8 [PMID: 27956978 DOI: 10.4021/gr2010.01.1332]
- 5 **Irizarry K**, Rossbach HC, Ignacio JR, Winesett MP, Kaiser GC, Kumar M, Gilbert-Barness E, Wilsey MJ. Sickle cell intrahepatic cholestasis with cholelithiasis. *Pediatr Hematol Oncol* 2006; **23**: 95-102 [PMID: 16651237 DOI: 10.1080/08880010500456964]
- 6 **Bauer TW**, Moore GW, Hutchins GM. The liver in sickle cell disease. A clinicopathologic study of 70 patients. *Am J Med* 1980; **69**: 833-837 [PMID: 7446549 DOI: 10.1016/S0002-9343(80)80008-8]
- 7 **Gardner K**, Douiri A, Drasar E, Allman M, Mwirigi A, Awogbade M, Thein SL. Survival in adults with sickle cell disease in a high-income setting. *Blood* 2016; **128**: 1436-1438 [PMID: 27439910 DOI: 10.1182/blood-2016-05-716910]
- 8 **Feld JJ**, Kato GJ, Koh C, Shields T, Hildesheim M, Kleiner DE, Taylor JG 6th, Sandler NG, Douek D, Haynes-Williams V, Nichols JS, Hoofnagle JH, Jake Liang T, Gladwin MT, Heller T. Liver injury is associated with mortality in sickle cell disease. *Aliment Pharmacol Ther* 2015; **42**: 912-921 [PMID: 26235444 DOI: 10.1111/apt.13347]
- 9 **Karacaoglu PK**, Asma S, Korur A, Solmaz S, Buyukkurt NT, Gereklioglu C, Kasar M, Ozbalcı D, Unal S, Kaya H, Gurkan E, Yeral M, Sariturk C, Boga C, Ozdogu H. East Mediterranean region sickle cell disease mortality trial: Retrospective multicenter cohort analysis of 735 patients. *Ann Hematol* 2016; **95**: 993-1000 [PMID: 27068408 DOI: 10.1007/s00277-016-2655-5]
- 10 **Manci EA**, Culberson DE, Yang YM, Gardner TM, Powell R, Haynes J, Shah AK, Mankad VN; Investigators of the Cooperative Study of Sickle Cell Disease. Causes of death in sickle cell disease: An autopsy study. *Br J Haematol* 2003; **123**: 359-365 [PMID: 14531921 DOI: 10.1046/j.1365-2141.2003.04594.x]
- 11 **Darbari DS**, Kple-Faget P, Kwagyan J, Rana S, Gordeuk VR, Castro O. Circumstances of death in adult sickle cell disease patients. *Am J Hematol* 2006; **81**: 858-863 [PMID: 16924640 DOI: 10.1002/ajh.20685]
- 12 **Platt OS**, Brambilla DJ, Rosse WF, Milner PF, Castro O, Steinberg MH, Klug PP. Mortality in sickle cell disease. Life expectancy and risk factors for early death. *N Engl J Med* 1994; **330**: 1639-1644 [PMID: 7993409 DOI: 10.1056/nejm199406093302303]
- 13 **Perronne V**, Roberts-Harewood M, Bachir D, Roudot-Thoraval F, Delord JM, Thuret I, Schaeffer A, Davies SC, Galactéros F, Godeau B. Patterns of mortality in sickle cell disease in adults in France and England. *Hematol J* 2002; **3**: 56-60 [PMID: 11960397 DOI: 10.1038/sj/thj/6200147]
- 14 **Johnson CS**, Omata M, Tong MJ, Simmons JF, Weiner J, Tatter D. Liver involvement in sickle cell disease. *Medicine (Baltimore)* 1985; **64**: 349-356 [PMID: 4033412 DOI: 10.1097/00005792-198509000-00007]
- 15 **Angus DC**, Seymour CW, Coopersmith CM, Deutschman CS, Klompas M, Levy MM, Martin GS, Osborn TM, Rhee C, Watson RS. A Framework for the Development and Interpretation of Different Sepsis Definitions and Clinical Criteria. *Crit Care Med* 2016; **44**: e113-e121 [PMID: 26901559 DOI: 10.1097/CCM.0000000000001730]
- 16 **Ahn H**, Li CS, Wang W. Sickle cell hepatopathy: Clinical presentation, treatment, and outcome in pediatric and adult patients. *Pediatr Blood Cancer* 2005; **45**: 184-190 [PMID: 15747337 DOI: 10.1002/pbc.20317]
- 17 **Lanzkron S**, Strouse JJ, Wilson R, Beach MC, Haywood C, Park H, Witkop C, Bass EB, Segal JB. Systematic review: Hydroxyurea for the treatment of adults with sickle cell disease. *Ann Intern Med* 2008; **148**: 939-955 [PMID: 18458272 DOI: 10.1001/jama.299.23.2795]
- 18 **Charache S**, Terrin ML, Moore RD, Dover GJ, Barton FB, Eckert SV, McMahon RP, Bonds DR. Effect of hydroxyurea on the frequency of painful crises in sickle cell anemia. Investigators of the Multicenter Study of Hydroxyurea in Sickle Cell Anemia. *N Engl J Med* 1995; **332**: 1317-1322 [PMID: 7715639 DOI: 10.1056/nejm199505183322001]
- 19 **Jeng MR**, Rieman MD, Naidu PE, Kaste SC, Jenkins JJ, Serjeant G, Wang WC. Resolution of chronic hepatic sequestration in a patient with homozygous sickle cell disease receiving hydroxyurea. *J Pediatr Hematol Oncol* 2003; **25**: 257-260 [PMID: 12621248 DOI: 10.1097/00043426-200303000-00015]



Observational Study

Angiogenesis of hepatocellular carcinoma: An immunohistochemistry study

Decebal Fodor, Ioan Jung, Sabin Turdean, Catalin Satala, Simona Gurzu

ORCID number: Decebal Fodor (0000-0001-5949-8278); Ioan Jung (0000-0001-6537-2807); Sabin Turdean (0000-0001-7085-4755); Catalin Satala (0000-0002-4466-6360); Simona Gurzu (0000-0003-3968-5118).

Author contributions: Fodor D drafted the article and contributed to the surgical interventions; Jung I contributed to the diagnosis and immunohistochemical assessment; Turdean S contributed to the conception of the paper, angiogenesis and statistical assessment; Satala C contributed to the statistical assessment; Gurzu S designed research and confer the final agreement for publication; Fodor D and Turdean S had equal contribution to the paper.

Institutional review board statement: The agreement of the Ethical Committee of University of Medicine and Pharmacy, Targu Mures, Romania, was obtained.

Conflict-of-interest statement: None declared.

Open-Access: This article is an open-access article which was selected by an in-house editor and fully peer-reviewed by external reviewers. It is distributed in accordance with the Creative Commons Attribution Non Commercial (CC BY-NC 4.0) license, which permits others to distribute, remix, adapt, build upon this work non-commercially, and license their derivative works on different terms, provided the original work is properly cited and the use is non-commercial. See: <http://creativecommons.org/licenses/by-nc/4.0/>

Decebal Fodor, Ioan Jung, Sabin Turdean, Catalin Satala, Simona Gurzu, Department of Pathology, University of Medicine, Pharmacy, Sciences and Technology, Targu Mures 530149, Romania

Simona Gurzu, Research Center (CCAMF), University of Medicine, Pharmacy, Sciences and Technology, Targu Mures 540139, Romania

Corresponding author: Simona Gurzu, MD, PhD, Professor, Department of Pathology, University of Medicine, Pharmacy, Sciences and Technology, 38 Gheorghe Marinescu Street, Targu Mures 530149, Romania. simona.gurzu@umftgm.ro

Telephone: +40-745-673550

Fax: +40-265-210407

Abstract

BACKGROUND

Although hepatocellular carcinoma (HCC) is one of the most vascular solid tumors, antiangiogenic therapy has not induced the expected results.

AIM

To uncover immunohistochemical (IHC) aspects of angiogenesis in HCC.

METHODS

A retrospective cohort study was performed and 50 cases of HCC were randomly selected. The angiogenesis particularities were evaluated based on the IHC markers Cyclooxygenase-2 (COX-2), vascular endothelial growth factor (VEGF) A and the endothelial area (EA) was counted using the antibodies CD31 and CD105.

RESULTS

The angiogenic phenotype evaluated with VEGF-A was more expressed in small tumors without vascular invasion (pT1), whereas COX-2 was rather expressed in dedifferentiated tumors developed in non-cirrhotic liver. The CD31-related EA value decreased in parallel with increasing COX-2 intensity but was higher in HCC cases developed in patients with cirrhosis. The CD105-related EA was higher in tumors developed in patients without associated hepatitis.

CONCLUSION

In patients with HCC developed in cirrhosis, the newly formed vessels are rather immature and their genesis is mediated *via* VEGF. In patients with non-cirrhotic liver, COX-2 intensity and number of mature neoformed vessels increases in parallel with HCC dedifferentiation.

ses/by-nc/4.0/

Manuscript source: Invited manuscript**Received:** December 28, 2018**Peer-review started:** December 29, 2018**First decision:** January 27, 2019**Revised:** January 27, 2019**Accepted:** March 12, 2019**Article in press:** March 12, 2019**Published online:** March 27, 2019**P-Reviewer:** Chen G, Gorrell MD, Xiao E, Zhang Y**S-Editor:** Cui LJ**L-Editor:** A**E-Editor:** Zhang YL**Key words:** Hepatocellular carcinoma; Angiogenesis; Endothelial area; Antiangiogenic therapy

©The Author(s) 2019. Published by Baishideng Publishing Group Inc. All rights reserved.

Core tip: In this paper we showed a possible role of morphological and immunohistochemical features of Hepatocellular carcinoma (HCC) in predicting the individualized antiangiogenic therapy of HCC. Based on the results and literature data, it seems that dedifferentiated HCCs developed in non-cirrhotic liver are predominantly driven *via* Cyclooxygenase-2 axis, whereas vascular endothelial growth factor-A induces hepatocarcinogenesis in patients with HCCs developed on the cirrhosis background.

Citation: Fodor D, Jung I, Turdean S, Satala C, Gurzu S. Angiogenesis of hepatocellular carcinoma: An immunohistochemistry study. *World J Hepatol* 2019; 11(3): 294-304**URL:** <https://www.wjgnet.com/1948-5182/full/v11/i3/294.htm>**DOI:** <https://dx.doi.org/10.4254/wjh.v11.i3.294>

INTRODUCTION

Hepatocellular carcinoma (HCC) is the most common type of hepatic primary malignant tumor (over 70% of cases) which globally ranks fifth in terms of cancer frequency and second in terms of cancer mortality^[1-3]. It is a well-vascularized tumor in which angiogenesis plays an important role in development, invasion and metastasis^[4]. HCC cells can synthesize angiogenic factors such as vascular endothelial growth factor (VEGF) A, Cyclooxygenase-2 (COX-2) and Basic Fibroblast Growth Factor (bFGF). At the same time, they might produce antiangiogenic factors such as angiostatin and endostatin. Thus, tumor angiogenesis depends on a local balance between these positive and negative regulators^[5].

Cyclooxygenase-2 (COX-2) is an enzyme encoded by the *PTGS2* gene, which belongs to the group of endogenous tumor factors that might stimulate genesis and progression of HCC^[6]. There are three isoforms: constitutive COX-1, inducible COX-2, and COX-3^[3,7]. If COX-1 is present in nearly all types of tissues, being responsible for the synthesis of prostaglandins in normal conditions, COX-2 is induced by cellular stress or tumor promoters, being responsible for the synthesis of prostaglandins involved in inflammation, cell growth, tumor development and progression^[3,6,8]. Although the therapeutic inhibition of COX enzymes and prostaglandins was supposed to be linked to lower risk and better survival of HCC^[9], the exact mechanism of inhibition and criteria of identification of those cases that can benefit by anti-COX therapy are still unknown.

VEGF is a glycoprotein with an important role in both physiological and pathological angiogenesis. It is located on the 6p chromosome, contains 8 exons^[10] and encodes five variants: VEGF-A, -B, -C, -D and PlGF (Placental Growth Factor)^[3]. VEGF is the key mediator of formation of new vessels from pre-existing vessels^[3].

Microvessel density (MVD) and endothelial area (EA) values are parameters used as prognostic factors in many tumors and can be assessed using immunohistochemical (IHC) markers such as CD31 and CD105^[11,12]. To determine the MVD, the number of vessels are counted, whereas EA can be semiautomatically quantified and take into account the area of endothelial cells versus total tissue area^[13].

CD31 or PECAM-1 (Platelet endothelial cell adhesion molecule-1) is a receptor expressed by cells of the hematopoietic system, such as platelets, monocytes, neutrophils and lymphocytes, but also by endothelial cells^[14]. In the liver, CD31 is diffusely expressed in sinusoids, as opposed to CD34 which is expressed only in hepatic periportal areas^[15]. CD31 marks neoformed and preexistent vessels^[16].

CD105 or endoglin is a co-receptor for TGF (transforming growth factor)- β 1 and - β 3^[16]. It is a marker of proliferating activated endothelial cells^[13,16-18].

As the antiangiogenic therapy did not show encouraging results in patients with HCC^[19], the aim of this paper was to perform an IHC study and try to identify those cases that might benefit by anti-VEGF-A or anti-COX-2 drugs therapy. The angiogenic phenotype of tumor cells was evaluated with VEGF-A and COX-2, and the value of EA was semiautomatically quantified with CD31 and CD105.

MATERIALS AND METHODS

Clinicopathological features

From 2004-2014, in a period of 11 years, all of the 113 cases of HCC were evaluated and 50 cases were randomly selected for angiogenesis quantification. The agreement of the Ethical Committee of University of Medicine and Pharmacy of Tirgu-Mures, Romania, was obtained for retrospective assessment of the cases.

The clinicopathological characteristics of the cases (Table 1) were correlated with the angiogenic parameters. We reassessed the microscopic slides in order to establish the tumor grade (G) and tumor stage (pT) according to AJCC Cancer Staging Manual, 8th Edition^[20]. No preoperative radiochemotherapy was done in any of the included cases.

Immunohistochemistry

The IHC stains, with antibodies used for examination of the angiogenic immunophenotype of tumor cells (VEGF-A and COX-2) and assessment of the endothelial area (CD31 and CD105), were performed using 5-μm thick sections from formalin-fixed paraffin-embedded tissues. For heat-induced antigen retrieval the sections were subjected to incubation with high-pH buffer (pH 9.0) for 30 min. The developing was performed with DAB solution (diaminobenzidine, Novocastra) and counterstaining was done with Mayer's hematoxylin (Novocastra). For negative controls, incubation was done with omission of specific antibodies. The characteristics of the antibodies are summarized in Table 2.

Immunohistochemistry assessment

For COX-2 and VEGF-A, the intensity of the IHC reaction was quantified in the cytoplasm of tumor cells, based on the cytoplasmic staining intensity and percentage of positive cells, as follows (Figure 1): negative (no stain or weak positivity < 5% of cells); score 1+ (weak diffuse cytoplasmic staining in 5%-10% of tumor cells); score 2+ (moderate positivity in 10%-70% of cells); score 3+ (strong positivity >70% of tumor cells)^[16]. Each slide was independently evaluated by three pathologists (SG, IJ and ST).

For the semiautomated assessment of endothelial area (EA), marked with CD31 and CD105, the "hot spot" method was used. Using Nikon E800 microscope, equipped with a digital camera, the areas with the highest vascular density were identified at a magnification of 100x. We discarded the areas with necrosis or rich in inflammatory infiltrate as well as those in which the antibodies have marked nonspecific other elements besides the endothelial cells. We digitally captured the images from "hot spot" areas at 400x high power fields, of intra- and peritumoral regions, performing 5 JPEG format photos per each region^[13,16].

The EA was quantified using NIH's ImageJ software. We manually selected the vessels, with or without lumen, that were marked positive, then the software automatically determined the EA, respectively the positive endothelial cells, with or without lumen, and reported it to the total tissue area^[13,16]. For statistical purposes, the median value of EA, using the 5 hot-spot pictures, was used.

Statistical analysis

The statistical assessment was done using the GraphPadInStat 3 statistical software (free access). We calculated the mean ± SD. A *P*-value < 0.05 with 95% confidence interval was considered statistically significant. We also turned to correlations, Fisher's Exact Test, using frequency tables for obtaining numerical data and percentage, as well as the ANOVA test and multivariate regressions.

RESULTS

Clinicopathological parameters

In a period of 11 years, 113 patients were diagnosed with HCC: 81 males and 32 females (M:F = 2.5:1). They showed a median age of 66.11 ± 9.98 years (ranging from 31 to 94 years), slightly lower (*P* = 0.05) in females (64.56 ± 11.18 years) than males (66.71 ± 9.47 years). All of the cases were diagnosed in stages pT1 (*n* = 52; 46.01%) or pT2 (*n* = 61; 53.99%). Regarding the tumor grade, 14 cases (12.38%) were diagnosed as G1, 64 (56.63%) as G2, 31 cases (27.43%) as G3, the other 4 cases (3.53%) being classified as G4 carcinomas. As for the associated hepatic lesions, we identified 47 cases (41.59%) developed in patients with cirrhosis, 39 patients (34.51%) had chronic persistent hepatitis, 23 (20.35%) showed Mallory bodies in absence of hepatitis, 34 (30.08%) were associated with steatosis, and 19 (16.81%) with cholestasis. From the

Table 1 Clinicopathological parameters of the cases used for quantification of angiogenesis

Variable	Number of cases (n = 50)	Percentage
Gender		
Male	36	72
Females	14	28
Age (mean \pm SD, yr)	64.66 \pm 9.6	
Age groups		
31-50 yr	2	4
51-60 yr	12	24
61-70 yr	21	42
71-80 yr	15	30
Tumor size (mean \pm SD, cm)	40.12 \pm 40.58	
Tumor aspect		
Single nodule	36	72
Multifocality	14	28
Tumor grade		
G1	8	16
G2	24	48
G3	17	34
G4	1	2
Tumor stage		
T1	23	46
T2	27	54
Cirrhosis		
Without	32	64
With	18	36
Mallory bodies		
Without	36	72
With	14	28
Hepatitis		
Without	26	52
With	24	48
Cholestasis		
Without	41	82
With	9	18
Steatosis		
Without	33	66
With	17	34

113 cases, 50 were randomly selected for angiogenesis assessment (Table 1).

Angiogenic immunophenotype

Evaluation of COX-2 and VEGF-A expression in the 50 cases with HCC, revealed that the angiogenic immunophenotype of tumor cells, independently by the used antibody, was not correlated with the gender or age of the patient (Table 3). More than half of the cases showed a moderate (score 2+) expression of VEGF-A but COX-2 intensity was distributed in a similar manner, each third part of the cases revealing 1+, 2+ or 3+ intensity. No negative cases were identified.

Regarding tumor stage, COX-2 intensity did not show correlation with tumor size or multifocal aspect (pT stage). In solitary tumors smaller than 2 cm (pT1), VEGF-A presented a higher intensity (20 of the 23 cases showed 2+ or 3+ score of VEGF-A) than tumors with vascular invasion or multifocal aspect (pT2) (Table 3).

On the other hand, VEGF-A intensity was not correlated with tumor grade or the associated hepatic lesions. In contrast, COX-2 high intensity (score 2+ and 3+) was rather observed in dedifferentiated carcinomas (G3+G4), whereas the G1+G2 cases showed an oscillating pattern of COX-2. The COX-2 expression was slightly elevated in patients that developed HCC in absence of premalignant lesions such hepatic

Table 2 Antibodies used for quantification of angiogenesis

Antibody	Clone	Company, town, country	Dilution	External control
COX-2	4H12	Novocastra, NewCastle Upon Tyne, United Kingdom	1:100	Brain-multipolar neurons; renal tubes
VEGF	VG1	LabVision, Fremont, CA, United States	1:50	Renal tubes
CD31	JC70A	DAKO,Glostrup, Denmark	1:40	Renal glomerules
CD105	SN6H	LabVision, Fremont, CA, United States	1:50	Tonsils

VEGF: Vascular endothelial growth factor; COX-2: Cyclooxygenase-2.

cirrhosis or Mallory bodies (Table 3 and Figure 1).

Endothelial area

Evaluation of EA showed that, independently of the antibody used for quantification of this angiogenic parameter (CD31 or CD105), it was not correlated with gender of patient, tumor stage or grade of differentiation (Table 4).

Regarding the associated lesions, a slightly elevated CD31-related EA was observed in tumors developed on the background of cirrhosis, whereas CD105-related EA was rather increased in cases without associated hepatitis (Table 4 and Figures 2 and 3).

COX-2 intensity increased in parallel with decreasing CD31-related EA. No correlation between CD105-EA value and CD31-EA, or COX-2 either VEGF-A intensity was observed (Table 5).

DISCUSSION

The stepwise process of angiogenesis consists of releasing proteases by the activated endothelial cells, basal membrane degradation of the existing vessel, migration of the endothelial cells into the interstitial space, endothelial cells proliferation, and lumen formation^[21]. However, the mechanism of formation of new vessels is still insufficiently known^[21].

In HCCs, the pro-angiogenic VEGF-A is supposed to influence proliferation of tumor cells and endothelial cells^[22-25]. At the same time, proliferated hepatocytes can release VEGF-A which binds to receptors (VEGF-R1/Flt-1, VEGF-R2/KDR, and VEGF-R3/Flt-4) that are localized within the tumor cells or on the surface of activated endothelial cells^[3,24]. Despite this supposed mechanism, the anti-VEGF drugs such as bevacizumab (anti-VEGF-A) and ramucirumab (anti-VEGF-R2) or multi-tyrosine inhibitors such as sorafenib, regorafenib, lenvatinib or tivantinib, did not show encouraging results in all cases of HCC^[18,19,26,27]. Morphological explanation of resistance is still unknown. It was recently supposed that angiogenesis might induce epithelial-mesenchymal transition of HCC cells^[26], as a possible explanation of resistance to antiangiogenic drugs^[19].

Regarding anti-COX therapy, in a meta-analysis published in 2018 it was shown that only 11 representative studies have been published about the controversial role of nonsteroidal anti-inflammatory drugs (NSAIDs) in the occurrence and prognosis of HCC^[9]. The conclusion of this meta-analysis was that NSAIDs decrease the risk of HCC occurrence and induce a better disease-free survival and overall survival, compared with non-NSAIDs users^[9]. There were not differences between aspirin and non-aspirin NSAIDs users^[9]. Moreover, in patients with HCC, aspirin did not increase the risk of bleeding^[9]. However, it would be useful to identify morphological criteria of HCC cells that might select patients that could benefit by anti-VEGF versus anti-COX therapy. The commonly used dose of aspirin was 100 mg/d, for at least 90 consecutive days^[9].

The morphological studies showed that, in peritumoral hepatocytes, both VEGF-A and COX-2 expression is higher than in tumor cells^[2,28]. In our material, an oscillating pattern of VEGF-A was found in the HCC, independently from the tumor grade. In smaller tumors and those without vascular invasion, we also proved high VEGF-A intensity. The intensity decreased in parallel with tumor size and was also lower in cases with multiple nodules. Although hepatitis C virus (HCV) can upregulate VEGF-A^[3], we did not find differences between VEGF expression in patients with or without hepatitis.

Regarding COX-2 expression, the literature data even indicates that COX-2 does not mediate the process of fibrosis^[6,29,30], or, contrary, COX-2 plays roles in fibrogenesis and hepatocarcinogenesis via metalloproteinases/mismatch repair proteins MMP-2 and MMP-9 or through activation of β -catenin^[3], one of the mediators of epithelial

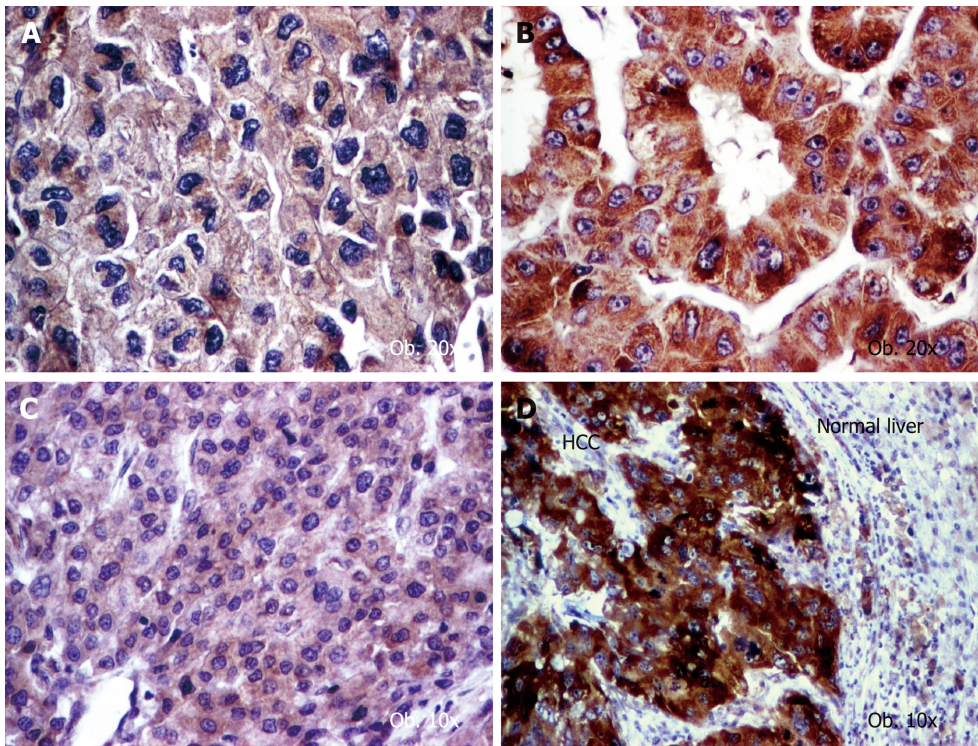


Figure 1 Angiogenic phenotype of hepatocellular carcinoma cells. A: Vascular endothelial growth factor (VEGF) A shows a low intensity (score 2+) in aggressive cases with vascular invasion; B: VEGF-A is well expressed (score 3+) in well differentiated carcinomas; C: Cyclooxygenase-2 (COX-2) presents low intensity (score 1+) in well-differentiated carcinomas; D: COX-2 becomes upregulated (score 3+) in dedifferentiated tumors.

mesenchymal transition^[19]. Although COX-2 stimulates HCV replication and HCV stimulates COX-2 expression via oxidative stress^[3], we did not find differences between COX-2 expression in patients with or without hepatitis. We proved that COX-2 induced tumor dedifferentiation in patients without cirrhosis and/or Mallory bodies.

The endothelial cells can be marked by CD31 but CD105 is more specific and marks only the activated cells. A high EA value is the expression of immature vessels, whereas predominance of mature vessels is quantified as a lower EA^[21].

In our cases, mature vessels (low CD31-related EA) were predominant in COX-2 positive dedifferentiated HCCs, except those cases developed on a background of cirrhosis, which mostly showed immature vessels, and respectively a higher EA value^[21]. In line to our data, it was experimentally shown that, although CD31 injection promotes migration of endothelial cells and HCC metastasis, it does influence intrahepatic metastases (pT stage)^[26]. CD31 expression is higher in patients with associated cirrhosis and is mostly seen in tumor-derived endothelial cells^[26]. CD31 reflects the rate of endothelialization of sinusoids and extent of capillarization, which are characteristic features of HCC^[31].

In contrast, the CD105-positive activated endothelial cells, mostly found in immature vessels^[32,33], were more frequent in HCCs developed in the absence of hepatitis. Lack of correlation of EA/MVD with cirrhosis and tumor grade has also been observed by other authors^[34]. As HCV might disturb angiogenesis pathways and promotes hepatocarcinogenesis^[3], it can be supposed that HCV might induce activation of endothelial cells and genesis of CD105 positive mature neoformed vessels.

As HCC is a heterogenous and frequent multifocal tumor, correlation with clinicopathological factors is difficult to be proved and literature data are controversial. Decreased MVD is supposed to be an indicator of poor prognosis^[35,36]. Similar to our study, a lower MVD, respectively predominance of mature vessels, was shown in dedifferentiated HCC^[37,38]. The idea is not agreed by all authors, in some studies being showed that MVD is increased in dedifferentiated tumors of large sizes and in those associated with cirrhosis^[39].

This study has some limitations. Firstly, the authors examined a small number of cases ($n = 50$). Although higher number of cases (but below 100) were analyzed in other studies^[26,31], they were mostly performed using tissue microarrays slides. We have analyzed the angiogenesis in classic (full) slides, that confers the reproducibility

Table 3 Assessment of COX-2 and VEGF-A expression in HCC

Parameter	COX-2 intensity			P value	VEGF-A intensity			P value
	1+	2+	3+		1+	2+	3+	
<i>n</i> (%)	14 (28)	18 (36)	18 (36)		12 (24)	28 (56)	10 (20)	
Gender								
Males	10	12	14	0.75	8	22	6	0.47
Females	4	6	4		4	6	4	
Age groups (yr)								
31-50	0	0	2	0.47	0	1	1	0.33
51-60	4	4	4		5	4	3	
61-70	5	10	6		4	12	5	
71-80	5	4	6		3	11	1	
Tumor grade								
G1+G2	13	7	12	0.006	6	19	7	0.50
G3+G4	1	11	6		6	9	3	
Tumor stage								
pT1	7	6	10	0.38	3	12	8	0.03
pT2	7	12	8		9	16	2	
Associated lesions								
With cirrhosis	8	3	7	0.05	5	9	4	0.81
Without cirrhosis	6	15	11		7	19	6	
With Mallory bodies	7	5	2	0.05	4	7	3	0.85
Without Mallory bodies	7	13	16		8	21	7	
With hepatitis	7	9	8	0.93	6	14	4	0.85
Without hepatitis	7	9	10		6	14	6	

VEGF: Vascular endothelial growth factor; COX-2: Cyclooxygenase-2.

character. Secondly, other cytokines and markers of epithelial mesenchymal transition^[19] have been reported to be associated with HCC. The interaction of angiogenesis with these biomarkers should be explored in future studies.

In conclusion, based on the literature data and the present study, we can affirm that, in HCC, angiogenesis has an oscillating pattern but some specific features can be emphasized. In patients with cirrhosis, the newly formed vessels are rather immature, are synthesized via VEGF, and COX-2 is downregulated. The VEGF-A expression is rather high in first steps of carcinogenesis, respectively in small tumors that do not show vascular invasion. VEGF-A intensity decreases in advanced stages. In dedifferentiated HCCs, which were developed in absence of cirrhosis, COX-2 overexpression and predominance of mature vessels is characteristic.

Table 4 Endothelial area assessment, using CD31 and CD105 antibodies in hepatocellular carcinoma

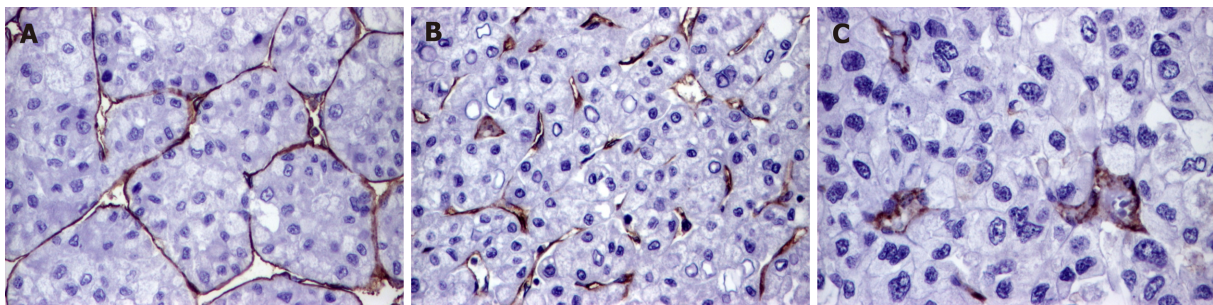
Parameter	Number of cases	CD31-EA (median and range values)	P value	CD105-EA (median and range values)	P value
Gender					
Males	36	7.35 ± 2.16 (2.57-11.18)	0.31	8.91 ± 2.64 (4.06-15.53)	0.44
Females	14	8.06 ± 2.30 (4.17-11.85)		9.59 ± 3.28 (4.23-15.56)	
Tumor grade					
G1+G2	32	7.69 ± 2.22 (2.57-11.69)	0.53	9.28 ± 2.64 (4.06-16.56)	0.55
G3+G4	18	7.29 ± 2.21 (3.34-11.85)		8.78 ± 3.17 (5.77-15.53)	
Tumor stage					
pT1	23	7.85 ± 2.33 (2.57-11.69)	0.59	9.47 ± 3.15 (4.06-16.56)	0.39
pT2	27	7.71 ± 2.11 (3.34-11.85)		8.79 ± 2.51 (5.47-14.91)	
Associated lesions					
With cirrhosis	18	8.29 ± 1.68 (5.64-11.85)	0.07	9.12 ± 2.51 (4.23-14.33)	0.97
Without cirrhosis	32	7.13 ± 2.37 (2.57-11.69)		9.09 ± 3.01 (4.06-16.56)	
With Mallory bodies	14	8.01 ± 1.39 (5.56-10.53)	0.36	9.86 ± 2.89 (5.85-15.53)	0.23
Without Mallory bodies	36	7.37 ± 2.44 (2.57-11.85)		8.81 ± 2.77 (4.06-16.56)	
With hepatitis	24	7.28 ± 1.99 (2.57-10.53)	0.40	8.26 ± 2.25 (4.23-12.28)	0.04
Without hepatitis	26	7.80 ± 2.39 (3.07-11.85)		9.88 ± 3.09 (4.06-16.56)	

EA: Endothelial area.

Table 5 Correlation of the angiogenic immunophenotype, quantified with VEGF-A and COX2, with endothelial area values

	COX-2 intensity			P value	VEGF-A intensity			P value
	1+	2+	3+		1+	2+	3+	
EA-CD31	8.66 ± 1.41	7.47 ± 2.29	6.76 ± 2.34	0.04	7.23 ± 1.52	7.53 ± 2.44	8.01 ± 2.32	0.72
EA-CD105	9.22 ± 1.83	9.58 ± 3.56	8.53 ± 2.64	0.53	8.45 ± 1.74	8.95 ± 3.02	10.31 ± 3.15	0.28

EA: Endothelial area; VEGF: Vascular endothelial growth factor; COX-2: Cyclooxygenase-2.

**Figure 2** Particular features of neoangiogenesis of hepatocellular carcinoma, revealed by CD31 stain. A: Endothelialization of the cirrhotic sinusoids; B: High endothelial area and immature vessels in the peri-cirrhotic tumor tissue; C: Rare mature vessels can be intratumorally seen, in cases developed in patients without cirrhosis. 20 x.

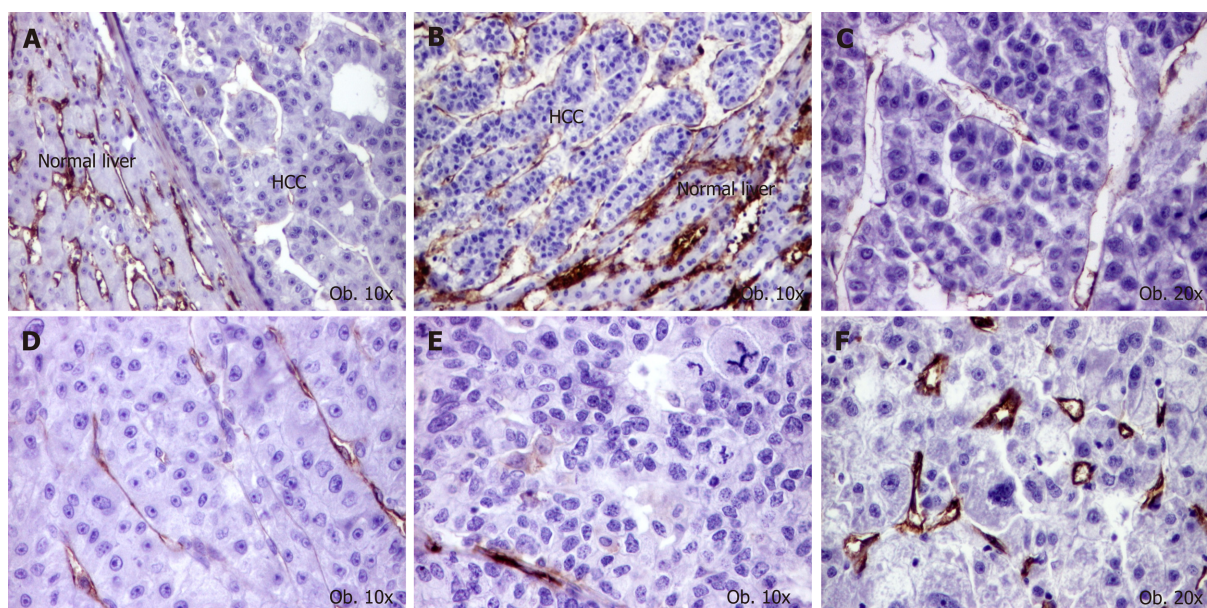


Figure 3 Particular features of neoangiogenesis of hepatocellular carcinoma, revealed by CD105 stain. A and B: High microvessels density of normal parenchyma, compared with tumor tissue; C: Mature activated neoformed vessels, in a G1 carcinoma; D: Mature vessels, in a G2 carcinoma; E: Low endothelial area, in a G3 carcinoma; F: Small neoformed vessels, in a case with high endothelial area.

ARTICLE HIGHLIGHTS

Research background

Although hepatocellular carcinoma (HCC) is one of the most vascular solid tumors, mechanisms of angiogenesis are still unknown. Moreover, angiogenesis is not properly inhibited by the currently used chemotherapies. For these reasons, new data are necessary to be published regarding the angiogenesis background.

Research motivation

The aim of the study was to perform a complex immunohistochemical assessment of angiogenic immunophenotype of HCC cells.

Research objectives

In this paper, we aimed to correlate the angiogenic immunophenotype of tumor cells with the values of endothelial area (EA). To reach the aim of the paper and understand the angiogenesis mechanisms, these two parameters were necessary to be examined.

Research methods

The angiogenic immunophenotype of tumor cells was examined with the immunohistochemically antibodies Cyclooxygenase-2 (COX-2), vascular endothelial growth factor (VEGF) A, whereas the values of EA were quantified using the antibodies CD31 and CD105. To increase the study reliability, the EA was digitally counted, using a semi automatically method.

Research results

The immunohistochemical study performed in this paper showed that the VEGF-A-related angiogenesis is more intense in small tumors, without vascular invasion, which were classified as pT1 HCCs. In the dedifferentiated and aggressive tumors, COX-2 was more expressed and CD31-related EA decreased, as result of proliferation of mature neoformed vessels. In patients with associated cirrhosis, CD31-related EA was higher, as result of proliferation of immature vessels. In patients without associated hepatitis, CD105-related EA was higher, as result of activated endothelial cells.

Research conclusions

The original data identified in the present study showed that the antiangiogenic therapy do not show the expected results for several reasons: angiogenesis has an oscillating pattern, the mechanisms of inducing angiogenesis depend on the tumor size and grade of differentiation and the EA is not always a reflection of the angiogenesis intensity. Based on these data, it can be concluded that a targeted antiangiogenic therapy should be considered in patients with HCC, based on the pathways of induction angiogenesis in specific cases.

Research perspectives

Before performing clinical trials with antiangiogenic/antityrosine-kinase drugs, the immunohistochemical and molecular background of the tumor tissue is mandatory to be

checked in any patient. It should be tested, in experimental study, the theory of predominance of VEGF-A-induced angiogenesis in small differentiated HCCs and COX-2 induced angiogenesis and vascular maturation in dedifferentiated cases.

REFERENCES

- 1 **Ferlay J**, Soerjomataram I, Ervik M, Dikshit R, Eser S, Mathers C, Rebelo M, Parkin DM, Forman D, Bray F. GLOBOCAN. 2012; IARC CancerBase No. 11 [Internet]. Lyon, France: International Agency for Research on Cancer; 2013 [accessed on 20/05/2016] Available from: <http://globocan.iarc.fr>
- 2 **Turdean S**, Gurzu S, Turcu M, Voidazan S, Sin A. Current data in clinicopathological characteristics of primary hepatic tumors. *Rom J Morphol Embryol* 2012; **53**: 719-724 [PMID: [23188430](#)]
- 3 **Mahmoudvand S**, Shokri S, Taherkhani R, Farshadpour F. Hepatitis C virus core protein modulates several signaling pathways involved in hepatocellular carcinoma. *World J Gastroenterol* 2019; **25**: 42-58 [PMID: [30643357](#) DOI: [10.3748/wjg.v25.i1.42](#)]
- 4 **Liu K**, Min XL, Peng J, Yang K, Yang L, Zhang XM. The Changes of HIF-1 α and VEGF Expression After TACE in Patients With Hepatocellular Carcinoma. *J Clin Med Res* 2016; **8**: 297-302 [PMID: [26985249](#) DOI: [10.14740/jocmr2496w](#)]
- 5 **Zhu B**, Lin N, Zhang M, Zhu Y, Cheng H, Chen S, Ling Y, Pan W, Xu R. Activated hepatic stellate cells promote angiogenesis via interleukin-8 in hepatocellular carcinoma. *J Transl Med* 2015; **13**: 365 [PMID: [26593962](#) DOI: [10.1186/s12967-015-0730-7](#)]
- 6 **Liang R**, Yan XX, Lin Y, Li Q, Yuan CL, Liu ZH, Li YQ. Functional polymorphisms of the cyclooxygenase-2 gene and prognosis of hepatocellular carcinoma-a cohort study in Chinese people. *Genet Mol Res* 2016; **15** [PMID: [27173352](#) DOI: [10.4238/gmr.15028093](#)]
- 7 **Martín-Sanz P**, Mayoral R, Casado M, Boscá L. COX-2 in liver, from regeneration to hepatocarcinogenesis: what we have learned from animal models? *World J Gastroenterol* 2010; **16**: 1430-1435 [PMID: [20333781](#)]
- 8 **Takasu S**, Tsukamoto T, Cao XY, Toyoda T, Hirata A, Ban H, Yamamoto M, Sakai H, Yanai T, Masegi T, Oshima M, Tatematsu M. Roles of cyclooxygenase-2 and microsomal prostaglandin E synthase-1 expression and beta-catenin activation in gastric carcinogenesis in N-methyl-N-nitrosourea-treated K19-C2mE transgenic mice. *Cancer Sci* 2008; **99**: 2356-2364 [PMID: [19018769](#) DOI: [10.1111/j.1349-7006.2008.00983.x](#)]
- 9 **Tao Y**, Li Y, Liu X, Deng Q, Yu Y, Yang Z. Nonsteroidal anti-inflammatory drugs, especially aspirin, are linked to lower risk and better survival of hepatocellular carcinoma: a meta-analysis. *Cancer Manag Res* 2018; **10**: 2695-2709 [PMID: [30147368](#) DOI: [10.2147/CMAR.S167560](#)]
- 10 **Mattei MG**, Borg JP, Rosnet O, Marmé D, Birnbaum D. Assignment of vascular endothelial growth factor (VEGF) and placenta growth factor (PLGF) genes to human chromosome 6p12-p21 and 14q24-q31 regions, respectively. *Genomics* 1996; **32**: 168-169 [PMID: [8786112](#)]
- 11 **Murakami K**, Kasajima A, Kawagishi N, Ohuchi N, Sasano H. Microvessel density in hepatocellular carcinoma: Prognostic significance and review of the previous published work. *Hepatol Res* 2015; **45**: 1185-1194 [PMID: [25594920](#) DOI: [10.1111/hepr.12487](#)]
- 12 **Li Y**, Ma X, Zhang J, Liu X, Liu L. Prognostic value of microvessel density in hepatocellular carcinoma patients: a meta-analysis. *Int J Biol Markers* 2014; **29**: e279-e287 [PMID: [24803279](#) DOI: [10.5301/ijbm.5000087](#)]
- 13 **Gurzu S**, Jung J, Azamfirei L, Mezei T, Cîmpean AM, Szentirmay Z. The angiogenesis in colorectal carcinomas with and without lymph node metastases. *Rom J Morphol Embryol* 2008; **49**: 149-152 [PMID: [18516319](#)]
- 14 **Privratsky JR**, Newman DK, Newman PJ. PECAM-1: conflicts of interest in inflammation. *Life Sci* 2010; **87**: 69-82 [PMID: [20541560](#) DOI: [10.1016/j.lfs.2010.06.001](#)]
- 15 **Pusztaszeri MP**, Seelentag W, Bosman FT. Immunohistochemical expression of endothelial markers CD31, CD34, von Willebrand factor, and Fli-1 in normal human tissues. *J Histochem Cytochem* 2006; **54**: 385-395 [PMID: [16234507](#)]
- 16 **Jung I**, Gurzu S, Raica M, Cîmpean AM, Szentirmay Z. The differences between the endothelial area marked with CD31 and CD105 in colorectal carcinomas by computer-assisted morphometrical analysis. *Rom J Morphol Embryol* 2009; **50**: 239-243 [PMID: [19434317](#)]
- 17 **Barriuso B**, Antolín P, Arias FJ, Girotti A, Jiménez P, Cordoba-Díaz M, Cordoba-Díaz D, Gírbés T. Anti-Human Endoglin (hCD105) Immunotoxin-Containing Recombinant Single Chain Ribosome-Inactivating Protein Musarmin 1. *Toxins (Basel)* 2016; **8** [PMID: [27294959](#) DOI: [10.3390/toxins8060184](#)]
- 18 **Kasprzak A**, Adamek A. Role of Endoglin (CD105) in the Progression of Hepatocellular Carcinoma and Anti-Angiogenic Therapy. *Int J Mol Sci* 2018; **19** [PMID: [30563158](#) DOI: [10.3390/ijms19123887](#)]
- 19 **Gurzu S**, Turdean S, Kovacs A, Contac AO, Jung I. Epithelial-mesenchymal, mesenchymal-epithelial, and endothelial-mesenchymal transitions in malignant tumors: An update. *World J Clin Cases* 2015; **3**: 393-404 [PMID: [25984514](#) DOI: [10.12998/wjcc.v3.i5.393](#)]
- 20 **Abou-Alfa GK**, Pawlik TM, Shindoh J, Vauthey JN. Liver. *AJCC Cancer Staging manual* 2017; 287-293
- 21 **Gurzu S**, Cîmpean AM, Kovacs J, Jung I. Counting of angiogenesis in colorectal carcinomas using double immunostain. *Tumori* 2012; **98**: 485-490 [PMID: [23052166](#) DOI: [10.1700/1146.12644](#)]
- 22 **Park YN**, Kim YB, Yang KM, Park C. Increased expression of vascular endothelial growth factor and angiogenesis in the early stage of multistep hepatocarcinogenesis. *Arch Pathol Lab Med* 2000; **124**: 1061-1065 [PMID: [10888784](#)]
- 23 **Lichtenberger BM**, Tan PK, Niederleithner H, Ferrara N, Petzelbauer P, Sibilia M. Autocrine VEGF signaling synergizes with EGFR in tumor cells to promote epithelial cancer development. *Cell* 2010; **140**: 268-279 [PMID: [20141840](#) DOI: [10.1016/j.cell.2009](#)]
- 24 **Shimizu H**, Miyazaki M, Wakabayashi Y, Mitsuhashi N, Kato A, Ito H, Nakagawa K, Yoshidome H, Kataoka M, Nakajima N. Vascular endothelial growth factor secreted by replicating hepatocytes induces sinusoidal endothelial cell proliferation during regeneration after partial hepatectomy in rats. *J Hepatol* 2001; **34**: 683-689 [PMID: [11434614](#)]
- 25 **Jain RK**, Tong RT, Munn LL. Effect of vascular normalization by antiangiogenic therapy on interstitial hypertension, peritumor edema, and lymphatic metastasis: insights from a mathematical model. *Cancer Res* 2007; **67**: 2729-2735 [PMID: [17363594](#)]
- 26 **Zhang YY**, Kong LQ, Zhu XD, Cai H, Wang CH, Shi WK, Cao MQ, Li XL, Li KS, Zhang SZ, Chai ZT,

- Ao JY, Ye BG, Sun HC. CD31 regulates metastasis by inducing epithelial-mesenchymal transition in hepatocellular carcinoma via the ITGB1-FAK-Akt signaling pathway. *Cancer Lett* 2018; **429**: 29-40 [PMID: 29746931 DOI: 10.1016/j.canlet.2018.05.004]
- 27 **Turkes F**, Chau I. Ramucirumab and its use in the treatment of hepatocellular carcinoma. *Future Oncol* 2019 [PMID: 30644314 DOI: 10.2217/fon-2018-0822]
- 28 **Zhu AX**, Duda DG, Sahani DV, Jain RK. HCC and angiogenesis: possible targets and future directions. *Nat Rev Clin Oncol* 2011; **8**: 292-301 [PMID: 21386818 DOI: 10.1038/nrclinonc.2011.30]
- 29 **Soslow RA**, Dannenberg AJ, Rush D, Woerner BM, Khan KN, Masferrer J, Koki AT. COX-2 is expressed in human pulmonary, colonic, and mammary tumors. *Cancer* 2000; **89**: 2637-2645 [PMID: 11135226]
- 30 **Yu J**, Wu CW, Chu ES, Hui AY, Cheng AS, Go MY, Ching AK, Chui YL, Chan HL, Sung JJ. Elucidation of the role of COX-2 in liver fibrogenesis using transgenic mice. *Biochem Biophys Res Commun* 2008; **372**: 571-577 [PMID: 18503750 DOI: 10.1016/j.bbrc.2008.05.069]
- 31 **Bösmüller H**, Pfefferle V, Bittar Z, Scheble V, Horger M, Sipos B, Fend F. Microvessel density and angiogenesis in primary hepatic malignancies: Differential expression of CD31 and VEGFR-2 in hepatocellular carcinoma and intrahepatic cholangiocarcinoma. *Pathol Res Pract* 2018; **214**: 1136-1141 [PMID: 29935812 DOI: 10.1016/j.prp.2018.06.011]
- 32 **Yu D**, Zhuang L, Sun X, Chen J, Yao Y, Meng K, Ding Y. Particular distribution and expression pattern of endoglin (CD105) in the liver of patients with hepatocellular carcinoma. *BMC Cancer* 2007; **7**: 122 [PMID: 17608955]
- 33 **Zhuang PY**, Wang JD, Tang ZH, Zhou XP, Quan ZW, Liu YB, Shen J. Higher proliferation of peritumoral endothelial cells to IL-6/sIL-6R than tumoral endothelial cells in hepatocellular carcinoma. *BMC Cancer* 2015; **15**: 830 [PMID: 26525581 DOI: 10.1186/s12885-015-1763-2]
- 34 **Yang LY**, Lu WQ, Huang GW, Wang W. Correlation between CD105 expression and postoperative recurrence and metastasis of hepatocellular carcinoma. *BMC Cancer* 2006; **6**: 110 [PMID: 16650286]
- 35 **Sun HC**, Tang ZY, Li XM, Zhou YN, Sun BR, Ma ZC. Microvessel density of hepatocellular carcinoma: its relationship with prognosis. *J Cancer Res Clin Oncol* 1999; **125**: 419-426 [PMID: 10394963]
- 36 **Nanashima A**, Nakayama T, Sumida Y, Abo T, Takeshita H, Shibata K, Hidaka S, Sawai T, Yasutake T, Nagayasu T. Relationship between microvessel count and post-hepatectomy survival in patients with hepatocellular carcinoma. *World J Gastroenterol* 2008; **14**: 4915-4922 [PMID: 18756600]
- 37 **Asayama Y**, Yoshimitsu K, Irie H, Nishihara Y, Aishima S, Tajima T, Hirakawa M, Ishigami K, Kakihara D, Taketomi A, Honda H. Poorly versus moderately differentiated hepatocellular carcinoma: vascularity assessment by computed tomographic hepatic angiography in correlation with histologically counted number of unpaired arteries. *J Comput Assist Tomogr* 2007; **31**: 188-192 [PMID: 17414751]
- 38 **Asayama Y**, Yoshimitsu K, Nishihara Y, Irie H, Aishima S, Taketomi A, Honda H. Arterial blood supply of hepatocellular carcinoma and histologic grading: radiologic-pathologic correlation. *AJR Am J Roentgenol* 2008; **190**: W28-W34 [PMID: 18094269]
- 39 **El-Assal ON**, Yamanoi A, Soda Y, Yamaguchi M, Igarashi M, Yamamoto A, Nabika T, Nagasue N. Clinical significance of microvessel density and vascular endothelial growth factor expression in hepatocellular carcinoma and surrounding liver: possible involvement of vascular endothelial growth factor in the angiogenesis of cirrhotic liver. *Hepatology* 1998; **27**: 1554-1562 [PMID: 9620326]



Randomized Clinical Trial

Preoperative immunonutrition in patients undergoing liver resection: A prospective randomized trial

Kylie Russell, Han-Guang Zhang, Lyn K Gillanders, Adam SJR Bartlett, Helena L Fisk, Philip C Calder, Peter J Swan, Lindsay D Plank

ORCID number: Kylie Russell (0000-0003-2766-4993); Han-Guang Zhang (0000-0003-2457-014X); Lyn K Gillanders (0000-0002-4144-6071); Adam SJR Bartlett (0000-0003-0055-8891); Helena L Fisk (0000-0002-9534-3246); Philip C Calder (0000-0002-6038-710X); Peter J Swan (0000-0001-6421-1358); Lindsay D Plank (0000-0003-2737-0151).

Author contributions: Russell K, Zhang HG, Gillanders LK, Bartlett AJSR and Plank LD designed the study; Russell K, Zhang HG, Fisk HL, and Plank LD acquired the data; Russell K, Zhang H-G and Plank LD analysed and interpreted the data; Gillanders LK, Bartlett AJSR, Calder PC and Swan PJ contributed to interpretation of the results; Russell K and Plank LD wrote the manuscript; Gillanders LK, Bartlett AJSR, Fisk HL, Calder PC and Swan PJ provided critical revisions of the manuscript; all authors read and approved the final version of the manuscript.

Supported by: Australasian Society for Parenteral and Enteral Nutrition Research Grant and A+ Trust Small Project Grant, No. 5576.

Institutional review board statement: The study was reviewed and approved by the New Zealand Health and Disability Ethics Northern A Committee (NTX/12/06/056).

Clinical trial registration statement: This study is registered with the Australian and New Zealand

Kylie Russell, Lyn K Gillanders, Nutrition Services, Auckland City Hospital, Auckland 1023, New Zealand

Han-Guang Zhang, Adam SJR Bartlett, Peter J Swan, Lindsay D Plank, Department of Surgery, University of Auckland, Auckland 1023, New Zealand

Adam SJR Bartlett, New Zealand Liver Transplant Unit, Auckland City Hospital, Auckland 1023, New Zealand

Helena L Fisk, Philip C Calder, Human Development and Health, Faculty of Medicine, University of Southampton, Southampton SO171BJ, United Kingdom

Philip C Calder, NIHR Southampton Biomedical Research Centre, University Hospital Southampton NHS Foundation Trust and University of Southampton, Southampton SO166YD, United Kingdom

Corresponding author: Lindsay D Plank, DPhil, Associate Professor, Department of Surgery, University of Auckland, 2 Park Road, Auckland 1023, New Zealand. l.plank@auckland.ac.nz
Telephone: +64-9-9236949
Fax: +64-9-3779656

Abstract

BACKGROUND

Preoperative supplementation with immunonutrients, including arginine and n-3 fatty acids, has been shown in a number of systematic reviews to reduce infectious complications in patients who have undergone gastrointestinal surgery. Limited information, however, is available on the benefits of nutritional supplementation enriched with arginine and n-3 fatty acids in patients undergoing liver resection.

AIM

To evaluate the effects of preoperative nutritional supplementation enriched with arginine and n-3 fatty acids on inflammatory and immunologic markers and clinical outcome in patients undergoing liver resection.

METHODS

Thirty-four patients undergoing liver resection were randomized to either five days of preoperative Impact® [1020 kcal/d, immunonutrition (IMN) group], or standard care [no supplementation, standard care (STD) group]. Nutritional status was measured at study entry by subjective global assessment (SGA).

Clinical Trials Registry
(ACTRN12612001151820).

Informed consent statement: All study participants provided written informed consent prior to study enrolment.

Conflict-of-interest statement: None of the authors has any conflicts of interest related to this study.

Data sharing statement: No additional data are available.

CONSORT 2010 statement: The authors have read the CONSORT 2010 Statement and the manuscript was prepared according to the CONSORT 2010 Statement.

Open-Access: This article is an open-access article which was selected by an in-house editor and fully peer-reviewed by external reviewers. It is distributed in accordance with the Creative Commons Attribution Non Commercial (CC BY-NC 4.0) license, which permits others to distribute, remix, adapt, build upon this work non-commercially, and license their derivative works on different terms, provided the original work is properly cited and the use is non-commercial. See: <http://creativecommons.org/licenses/by-nc/4.0/>

Manuscript source: Invited manuscript

Received: October 25, 2018

Peer-review started: October 26, 2018

First decision: December 19, 2018

Revised: February 22, 2019

Accepted: March 16, 2019

Article in press: March 16, 2019

Published online: March 27, 2019

P-Reviewer: Abdel-Salam OME, Aoki H, Frena A

S-Editor: Cui LJ

L-Editor: A

E-Editor: Zhang YL



Functional assessments (grip strength, fatigue and performance status) were carried out at study entry, on the day prior to surgery, and on postoperative day (POD) 7 and 30. Inflammatory and immune markers were measured at study entry, on the day prior to surgery, and POD 1, 3, 5, 7, 10 and 30. Postoperative complications were recorded prospectively until POD30.

RESULTS

A total of 32 patients (17 IMN and 15 STD) were analysed. All except four patients were SGA class A. The plasma ratio of (eicosapentaenoic acid plus docosahexaenoic acid) to arachidonic acid was higher in IMN patients on the day prior to surgery and POD 1, 3, 5 and 7 ($P < 0.05$). Plasma interleukin (IL)-6 concentrations were elevated in the IMN group ($P = 0.017$ for POD7). No treatment effect was detected for functional measures, immune response (white cell count and total lymphocytes) or markers of inflammation (C-reactive protein, tumour necrosis factor- α , IL-8, IL-10). There were 10 patients with infectious complications in the IMN group and 4 in the STD group ($P = 0.087$). Median hospital stay was 9 (range 4–49) d in the IMN group and 8 (3–34) d in the STD group ($P = 0.476$).

CONCLUSION

In well-nourished patients undergoing elective liver resection, this study failed to show any benefit of preoperative immunonutrition.

Key words: Liver cancer; Partial hepatectomy; Fish oil; Arginine; Nutritional status; Inflammation

©The Author(s) 2019. Published by Baishideng Publishing Group Inc. All rights reserved.

Core tip: Whether immunonutritional supplementation provided preoperatively to patients undergoing liver resection can reduce postoperative inflammation and improve clinical outcome compared to standard care remains unclear. We conducted a prospective randomized trial to clarify this. We found no significant suppression of postoperative inflammation or reduction in infectious complications or length of hospital stay post-surgery through providing preoperative immunonutrition.

Citation: Russell K, Zhang HG, Gillanders LK, Bartlett AS, Fisk HL, Calder PC, Swan PJ, Plank LD. Preoperative immunonutrition in patients undergoing liver resection: A prospective randomized trial. *World J Hepatol* 2019; 11(3): 305-317

URL: <https://www.wjgnet.com/1948-5182/full/v11/i3/305.htm>

DOI: <https://dx.doi.org/10.4254/wjh.v11.i3.305>

INTRODUCTION

Immunonutrition, the provision of specific nutrients in supra-physiological doses, is suggested to provide vital substrates that act to modulate immune and metabolic responses and improve clinical outcome^[1]. Nutrients that have been identified to offer immunological benefit include n-3 polyunsaturated fatty acids, arginine, glutamine and nucleotides. A number of systematic reviews have shown that immunonutrition provided as a preoperative supplement to patients undergoing elective gastrointestinal surgery leads to significant reductions in postoperative infectious complications^[2-5]. Benefit has been demonstrated in both malnourished^[6] and normally nourished patients^[7] and is thought to be due to the down regulation of the inflammatory responses to surgery and amelioration of the postoperative immune depression.

Despite the reported benefits of this therapy, we are aware of only two published randomized, prospective studies investigating the effect of preoperative immunonutrition on postoperative inflammation and clinical outcome in liver resection patients^[8,9]. Mikagi *et al*^[8] randomized 41 patients but only 26 were analysed. Some evidence for reduction of inflammation [interleukin-6 (IL-6)] on postoperative day (POD) 1 was seen and only one infectious complication was reported. Uno *et al*^[9] randomised 40 patients, 83% of whom had surgery for (presumably perihilar) bile

duct carcinoma, a relatively rare condition. Significant reductions in IL-6 on POD1, infectious complications and length of hospital stay were reported.

The primary objective of the present study was to investigate postoperative inflammatory and immunologic responses in patients undergoing liver resection who were randomized to either preoperative treatment with an immunonutritional supplement (IMN) or standard care (STD). Secondary objectives included clinical outcomes and physiological function.

MATERIALS AND METHODS

Patients

Patients over 16 years of age scheduled for non-laparoscopic elective hepatic resection for primary or secondary liver cancer between December 2012 and April 2014 were recruited from the hepaticopancreaticobiliary outpatient clinic at Auckland City Hospital. Exclusion criteria included immunosuppression, cirrhosis (biopsy proven or fibroscan result), chemotherapy within 3 wk prior to study entry, taking fish oil supplements, and pregnancy. Ethics approval was granted by the Northern A Ethics Committee. Each patient provided written informed consent.

Surgical procedure

Hepatic resection was performed by an open technique through a right subcostal incision. All patients received intra-theal opiate and general anaesthesia. Parenchymal resection was performed without inflow occlusion by anatomical dissection. Drains were routinely placed at completion and removed post-operatively depending upon volume and character of effluent. All patients received antibiotic prophylaxis (cefoxitin 1 g) given intravenously at induction of anaesthesia.

Study protocol

This was a prospective, randomized, assessor-blinded, clinical trial. At recruitment, patients were allocated to IMN or STD groups in a 1:1 ratio using opaque sealed envelopes prepared according to a computer-derived random sequence with variable block sizes. In addition to their usual intake, IMN patients were prescribed for each of the 5 consecutive days preceding surgery 3 x 237 mL tetra packs of IMPACT Advanced Recovery® (Nestle) providing 1020 kcal energy, 54 g protein, 12.6 g arginine, 1.3 g nucleotides, and 3.3 g eicosapentaenoic acid (EPA) + docosahexaenoic acid (DHA) per day. Patients were telephoned to remind them to commence taking the supplement and asked to keep a daily record of the timing and volume of Impact consumed, as well as all other oral intake over this period. Those randomized to the STD group were advised to continue with their usual oral intake. Patients in this group assessed as having malnutrition were provided with a standard nutritional supplement (Fortisip®, Nutricia) twice daily (providing 600 kcal energy, 24 g protein), in addition to their usual intake, for the period preceding and including 5 days prior to surgery. At recruitment, blood samples were taken for inflammatory and immune status markers and measurement of plasma fatty acids. These measurements were repeated on the day prior to surgery (D-1) and on POD 1, 3, 5 and 7. An additional C-reactive protein (CRP) measurement was taken on POD30. CRP and full blood count were determined by the hospital accredited laboratory. Remaining blood was centrifuged at 4 °C and plasma separated and frozen at -80 °C until analysis. Nutritional status was assessed at study entry and functional status at study entry and on D-1, POD7 and POD30.

Plasma phosphatidylcholine fatty acids

Using methods described in detail previously^[10], total lipids were extracted, phosphatidylcholine (PC), the major phospholipid in plasma, was isolated, and gas chromatography was performed to determine the fatty acid composition of PC.

Immune and inflammatory markers

An immunoturbidimetric method (Roche Diagnostics) was used for high-sensitivity CRP assay. Simultaneous quantification of plasma tumour necrosis factor (TNF)-α, IL-6, IL-8 and IL-10 was carried out using a high-sensitivity multiplex immunoassay kit (Milliplex®, Millipore Corp, Billerica, MA, United States) and a micro-beads system following the manufacturer's instructions (Luminex Corp., Austin, TX, United States).

Nutritional and functional status

Nutritional intake was assessed using the 24 hour diet recall technique^[11]. Body weight to the nearest 0.1 kg was measured using electronic scales and an estimated clothing weight was subtracted. Height was measured using a stadiometer. Subjective

global assessment (SGA) of nutritional status was performed as described by Detsky *et al*^[12]. The Christensen Fatigue Scale was used to quantify subjective feelings of fatigue^[13]. The Karnofsky Performance Scale was used to quantify general well-being and ability to complete activities of daily living^[14]. Physiological function was measured by maximum voluntary grip strength in the dominant hand as the best of three attempts using a spring loaded analogue dynamometer (model 78010, Lafayette Instrument Co., Lafayette, IN, United States).

Clinical outcome

Patients were assessed daily while in hospital for infectious and other complications. Clinical notes were reviewed post-discharge to ensure no complication was missed. Patients were monitored for 30 days for complications. Postoperative complications were assessed and graded according to the Clavien-Dindo system^[15]. A bacterial infection was defined by administration of antibiotics when signs and symptoms of sepsis were evident, indicating possible chest, urinary, line or wound infection. Infectious complications were categorised according to the Centers for Disease Control Classification System^[16]. The surgical team in charge of each patient had sole discretion over adjudication of complications and determination of date of hospital discharge and were blinded to group allocation.

Statistical analysis

Sample size calculations demonstrated that 15 patients per group would provide > 90% power for detecting a significant difference in plasma IL-6 concentrations on POD1, based on the results of Braga *et al*^[17] in gastrointestinal surgery patients.

Repeated measures data were analysed by the general linear mixed model. Inflammatory markers were log-transformed prior to analysis. Between-group comparisons used Student's *t* test or Mann-Whitney *U* test for normally distributed and non-normally distributed data respectively. Fisher's exact test was used for categorical data. Time-to-event data were compared between groups using the log-rank test. All analysis was performed on an intention-to-treat basis. Data are presented as mean \pm SE or median (range). *P* values of less than 0.05 were considered to indicate statistical significance. Statistical analyses were performed using SAS release 9.4 (SAS Institute, Cary, NC, United States).

RESULTS

Patients

Thirty-four patients were randomized to IMN or STD groups between November 2012 and April 2014 (Figure 1). Two STD patients were withdrawn after randomization, one undergoing laparoscopic instead of open surgery and the other did not proceed to resection because of unexpected disease at laparotomy. Baseline characteristics for the remaining 32 patients are summarised in Table 1.

Plasma phosphatidylcholine fatty acids

The ratio of EPA + DHA to arachidonic acid differed significantly between the groups over time ($P < 0.0001$; Figure 2). No difference was seen at baseline ($P = 0.36$) but the ratio was higher in the IMN group on D-1 ($P < 0.0001$) and on POD1 ($P < 0.0001$), POD3 ($P < 0.0001$), POD5 ($P = 0.003$) and POD7 ($P = 0.014$). In the IMN group, compared with the preoperative period, plasma PC EPA+DHA (as percent of total fatty acids) increased more than two-fold.

Functional status

Baseline dietary assessment showed no significant differences between the groups for consumption of energy ($P = 0.27$), carbohydrate ($P = 0.11$), protein ($P = 0.37$), total fat ($P = 0.93$), PUFAs ($P = 0.47$), MUFAs ($P = 0.88$), or fibre ($P = 0.12$). Compliance with the full preoperative course of immunonutrition was 100% in 16 out of 17 patients with one patient consuming one less tetra pack than prescribed. As shown in Table 2, changes over time did not differ between the groups for fatigue score ($P = 0.342$), performance status ($P = 0.810$) or grip strength ($P = 0.849$). Compared to D-1, patients were more fatigued on POD7 ($P < 0.0001$) and performance status ($P < 0.0001$) and grip strength ($P = 0.009$) deteriorated. Over the subsequent 3 weeks fatigue and performance improved ($P < 0.0001$) but no change in grip strength was seen ($P = 0.802$).

Immune and inflammatory markers

There were no differences in white cell count ($P = 0.201$) or total lymphocytes ($P = 0.575$) between the groups over the study period (Table 3). White cell count was

Table 1 Demographics and operative characteristics of patients who received either immunonutrition or standard care preoperatively

	Immunonutrition	Standard care
<i>n</i>	17	15
Male/Female	11/6	10/5
Age (yr)	61 (28–76)	63 (31–79)
SGA grade (A/B/C)	15/1/1	13/2/0
Indication for surgery		
Metastatic disease	15	13
Hepatocellular carcinoma	2	1
Granulomatous liver disease	0	1
Hepatectomy		
Major resection (≥ 3 segments)	14	10
Minor resection (< 3 segments)	3	5
ASA grade (I/II/III)	1/9/6	0/8/6
Tissue removed (g)	815 ± 123	610 ± 94
Duration of surgery (min)	173 (104–337)	155 (128–246)

Data are number of patients, mean ± SE or median (range). SGA: Subjective global assessment; ASA: American Society of Anaesthesiologists physical status classification.

elevated and lymphocyte count was depressed over the first 10 postoperative days before returning to preoperative levels by POD30. Plasma concentrations of CRP, TNF- α , IL-6, IL-8 and IL-10 to POD7 are shown in Figures 3 and 4 for the two groups. Except for IL-6 ($P = 0.034$), there were no significant differences between the groups for the profiles over time for these markers. Circulating IL-6 concentrations were higher in the IMN group on POD7 ($P = 0.017$) and tended to be higher on POD1 ($P = 0.087$) and POD5 ($P = 0.088$). In both groups on POD7, IL-6 concentrations were elevated ($P < 0.0001$) compared to baseline.

Clinical outcome

Postoperative complications are summarized in Table 4. Postoperative complications occurred in 12 patients in the IMN group and 11 patients in the STD group ($P = 0.598$). Ten patients in the IMN group and 4 in the STD group developed infectious complications ($P = 0.087$). The median length of hospital stay (LOS) was 9 (range 4–49) d in the IMN group and 8 (3–34) d in the STD group ($P = 0.476$). Seven patients in the IMN group developed a major postoperative complication (Clavien-Dindo grade \geq III) as did one patient in the STD group ($P = 0.047$). However, no association was seen between the severity of postoperative complications and whether the surgery was major or minor (Table 5).

DISCUSSION

In this study, preoperative nutritional supplementation enriched in n-3 fatty acids and arginine did not result in suppression of postoperative inflammation compared to standard care. The primary measure of inflammatory response was IL-6 and this marker was persistently elevated in the IMN group, significantly so on POD7, in comparison to the STD group. The pattern of changes for other markers of inflammation did not differ between the groups but also tended to be elevated in the IMN group on POD7. Similarly, there were no differences in immune markers between the groups. While the study was not powered for clinical outcome, the results for infectious complications and length of stay were consistent with a failure of preoperative immunonutrition to dampen the postoperative inflammatory response. The incidence of infectious complications was 59% and 27% in the IMN and STD groups, respectively. Notably, there was a higher incidence of major complications in the IMN group.

These results contrast with those in colorectal, pancreatic and gastric surgery where reductions of around 50% in infectious complication rates and 2–3 d in length of hospital stay were seen in meta-analyses of studies where supplementation with arginine and n-3 fatty acid based formulas were provided only preoperatively^[3–5]. Studies included in these meta-analyses that have examined inflammatory and

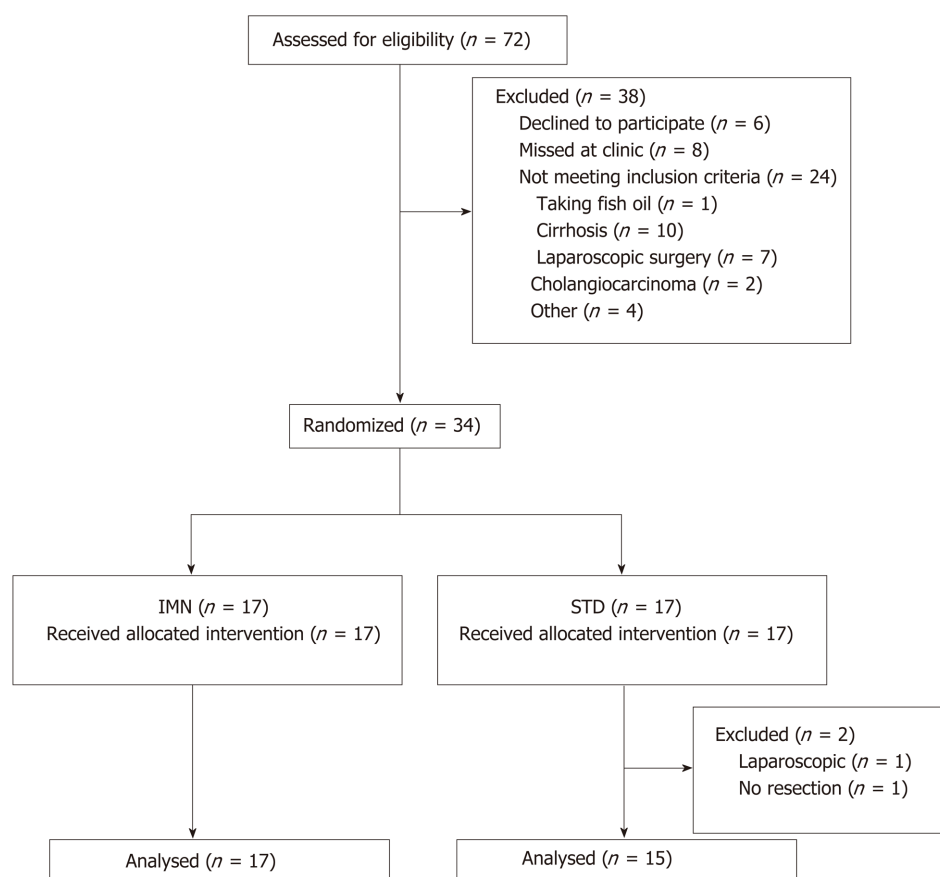


Figure 1 Disposition of patients in the study. IMN: Immunonutrition; STD: Standard care.

immune responses after preoperative feeding with IMN have reported reduced IL-6 concentrations on POD1^[17] and increased total lymphocyte numbers postoperatively^[18]. Limited published work is available in patients undergoing liver resection with only two published randomized trials of immunonutrition. Mikagi *et al*^[8] administered IMPACT at 750 kcal/d for 5 d preoperatively in the immunonutrition group. A drop-out rate of 37% was reported with no significant reductions in infectious complications, non-infectious complications or length of hospital stay in the 26 patients analysed. Uno *et al*^[9] carried out an intention to treat analysis on 40 patients and reported a significant reduction in infectious complications, no difference in non-infectious complications and a significant reduction in length of stay. However, case-mix differed markedly from the present study. Patients largely underwent surgery for bile duct carcinoma compared to metastatic colorectal cancer in the current study and the differing pathologies may have contributed to the contrasting results, as infectious complications in their control group were much higher (75%) than in the current study (27%).

Liver resections were included in recently published randomized trials from Hubner *et al*^[19] (28 of 145 patients) and Giger-Pabst *et al*^[20] (11 of 105 patients) but subgroup analyses were not conducted. In a non-randomized, propensity score matched case-control study^[21] of 49 patients receiving immunonutrition and 49 controls, most of whom were well nourished, IMPACT was provided preoperatively in the same dose as the current study (3 x 237 mL, 1020 kcal) for 7 d. Definition and grading of severity of complications were identical to the current study and the authors reported no significant difference in infectious complications (38.7% immunonutrition vs. 28.5% control) or median length of stay (10 d in both groups). This evident lack of benefit also extends to liver transplantation where perioperative administration of IMPACT did not result in improved clinical outcome^[22].

In contrast to the studies of Mikagi *et al*^[8] and Zacharias *et al*^[21], major hepatectomy was performed in 75% of our patients compared to 8% and 21% in the respective earlier studies. This may account, at least in part, for the higher incidence of major complications in our study (25%) compared to the Zacharias study (11%). The markedly higher number of non-infectious complications in the immunonutrition

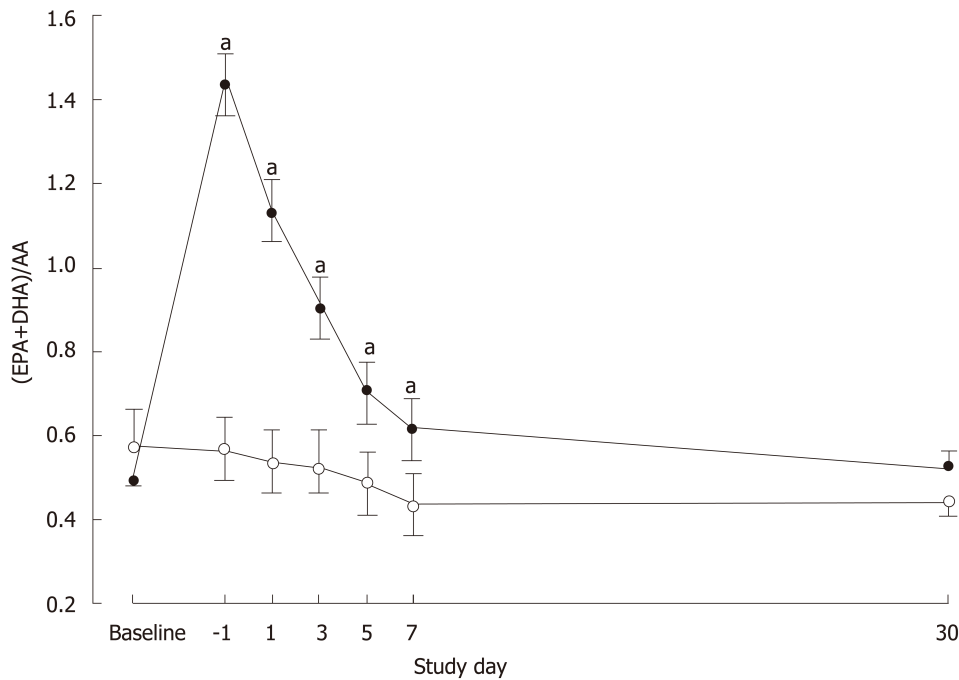


Figure 2 Ratio of eicosapentaenoic acid plus docosahexaenoic acid to arachidonic acid (mean \pm SE) measured at baseline, day prior to surgery (day-1) and on postoperative days 1, 3, 5, 7 and 30 in patients who received IMPACT preoperatively (solid symbols) compared with patients who received standard care (open symbols). ^a $P < 0.05$ vs standard care.

group in the current study may have been a chance effect rather than a result of the treatment. A larger study is required to confirm this. This finding however may have contributed to the greater and more sustained inflammatory response postoperatively in the immunonutrition group, predisposing those patients to infection. One patient in the IMN group contributed 3 of the 15 infectious and 10 of the 40 non-infectious complications observed in that group having suffered aspiration pneumonia and acute respiratory distress syndrome.

The majority of patients in the current study were well-nourished with two patients in each group assessed as malnourished preoperatively (SGA B + C). Malnourished patients experience significantly longer LOS and more major postoperative complications^[23], which are attributed to malnutrition associated immune depression^[24]. Consequently, it has been hypothesized that by providing immunonutrition containing key nutrients with the ability to minimise the early inflammatory response to surgery a more substantial benefit may be seen in malnourished patients^[25]. If this is the case it might explain, at least in part, the lack of any indication of improved clinical outcomes in the present study. Uno *et al*^[9] did not report nutritional status of their patients and a high prevalence of malnutrition in their cholangiocarcinoma patients may help explain the significant benefits seen with immunonutrition. To date, there are no published meta-analyses evaluating the impact of nutritional status on the treatment effect of immunonutrition. Published meta-analyses have pooled data from randomized trials that include both well-nourished and malnourished patients, with a number of studies not reporting on baseline nutritional status.

Dose and timing of preoperative immunonutrient supplementation are not well-defined. Our protocol conformed to the 500-1000 kcal/d recommended by Waitzberg *et al*^[2] and the consensus guidelines from ASPEN^[26] and ESPEN^[27]. Giger-Pabst *et al*^[20] investigated the effect of immunonutrition administered for only 3 days preoperatively based on the findings of a prior study suggesting that the anti-inflammatory effect of immunonutrition starts after only two days^[28]. However, 3 days of IMPACT supplementation preoperatively was insufficient to provide any benefit in terms of infectious complications or LOS. The authors concluded based on their own findings and review of the literature that at least five days of preoperative supplementation are required to achieve benefit.

Limitations of the current study include its small size, given it was focused on inflammatory and immune parameters rather than clinical outcome. It was also not placebo-controlled and double-blinded, the latter being less important for endpoints

Table 2 Fatigue score and performance status measured at study entry, Day-1, POD 7 and POD 30 and grip strength measured at Day-1, POD7 and POD30 in patients who received either immunonutrition or standard care preoperatively

	Study entry	Day -1	POD 7	POD 30	P value ¹		
					Group	Time	Group×Time
Fatigue score							
STD group	4.2 ± 0.8	4.0 ± 0.6	7.1 ± 0.5	5.4 ± 0.7	0.121	< 0.0001	0.342
IMN group	4.3 ± 0.6	2.7 ± 0.4	6.7 ± 0.5	3.5 ± 0.8			
Performance status							
STD group	84.0 ± 3.9	85.7 ± 2.8	59.3 ± 4.2	73.5 ± 3.9	0.867	< 0.0001	0.810
IMN group	81.9 ± 2.8	86.8 ± 3.1	57.7 ± 4.8	75.0 ± 6.9			
Grip strength (kg)							
STD group	-	37.8 ± 2.7	35.4 ± 2.6	33.8 ± 2.3	0.825	0.019	0.849
IMN group	-	38.9 ± 3.4	36.5 ± 3.3	33.2 ± 2.4			

¹Repeated measures analysis using the linear mixed model. Data are mean ± SE. POD: Postoperative day; IMN: Immunonutrition; STD: Standard care.

based on blood assays. However, there was potential for bias in the reporting of complications, most especially for those occurring after hospital discharge. In-hospital complications were assessed by clinicians who were blinded to the group allocation. After discharge, patients were contacted or assessed at clinic visits to monitor complications over the first postoperative month. However, not all complications may have been captured. Up to 25% of postoperative infections, which are largely surgical wound infections, may occur after discharge^[17]. We did not perform dietary assessments during or at the end of the period of nutritional supplementation so cannot comment on any difference in caloric load between the groups prior to surgery and impact on outcome.

Strengths of the study include: measurement of EPA and DHA plasma concentrations which support likely cell membrane incorporation^[29] and resultant biological effects^[30]; the near-perfect compliance with the immunonutrition product, verified by the EPA+DHA levels in plasma; hospital discharge determination by staff independent of the study; operations performed by the same surgeon using the same surgical technique in all except one patient; and assessment of inflammatory and immune markers in the very early postoperative period (from POD1).

In conclusion, this study failed to show any evidence for suppression of postoperative inflammation or improvement in clinical outcome through providing immunonutrition to well-nourished patients undergoing liver resection. There remains no large scale double-blind trial in liver resection on which to base more definitive conclusions and such a trial, particularly in patients having major resections, is warranted.

Table 3 Total lymphocyte and white cell counts over the pre-and postoperative periods in patients who received either immunonutrition or standard care preoperatively

	Preoperative		Postoperative					P value ¹		
	Study entry	Day-1	POD 1	POD 3	POD 5	POD 10	POD 30	Group	Time	Group×time
Total lymphocytes (x10 ⁹ /L)										
IMN group	1.41 ± 0.13	1.54 ± 0.12	0.93 ± 0.09	0.96 ± 0.10	0.95 ± 0.09	1.19 ± 0.09	1.47 ± 0.13	0.091	< 0.001	0.575
STD group	1.66 ± 0.16	1.78 ± 0.13	1.12 ± 0.15	1.21 ± 0.09	1.07 ± 0.13	1.38 ± 0.12	1.47 ± 0.10			
White cell count (x10 ⁹ /L)										
IMN group	5.80 ± 0.60	7.05 ± 0.78	12.78 ± 1.10	9.81 ± 1.29	7.40 ± 0.91	12.28 ± 2.27	6.80 ± 0.86	0.416	< 0.001	0.201
STD group	6.86 ± 0.83	6.75 ± 0.54	12.79 ± 1.32	8.99 ± 0.77	9.65 ± 0.98	13.53 ± 1.63	7.40 ± 0.68			

¹Repeated measures analysis using the linear mixed model. Data are mean ± SE. POD: Postoperative day; IMN: Immunonutrition; STD: Standard care.

Table 4 All complications in patients who received either immunonutrition or standard care preoperatively

	IMN	STD	P value ¹
Infectious complications			
Urinary tract	3	0	
Surgical site	2	2	
Blood stream	5	0	
Gastrointestinal	2	1	
Lower respiratory tract	3	3	
Non Infectious complications			
AF/Bradycardia/Tachycardia	3	2	
Acute kidney injury	3	0	
Aspiration pneumonia	1	0	
Acute respiratory distress syndrome	1	0	
Atelectasis	7	6	
Bowel obstruction	1	3	
Diarrhoea	1	0	
Electrolyte derangement	4	3	
Encephalopathy	1	0	
Hypotension	2	0	
Ileus	4	2	
Ischaemic optic neuropathy	1	0	
Leak	1	0	
Nausea and vomiting	1	2	
Pleural effusion	5	3	
Pain requiring epidural	2	0	
Pneumothorax	1	0	
Non infected collection	1	0	
Wound dehiscence	1	0	
Total infectious complications	15	6	
Total non-infectious complications	40	21	
Total complications	55	27	
Patients with an infectious complication	10	4	0.087
Patients with a non-infectious complication	11	11	0.445
Patients with any complication	12	11	0.598

Severity of complication			0.047
Patients with major complication (Clavien-Dindo Grade \geq III)	7	1	
Patients with minor complication (Clavien-Dindo Grade < III)	5	10	
Patients without any complication	5	4	

¹Fisher's exact test. AF: Atrial fibrillation; IMN: Immunonutrition; STD: Standard care.

Table 5 Severity of complications with major and minor surgery

	Severity of complication			P value ¹
	Major	Minor	No complication	
Major surgery	6	11	7	1.000
Minor surgery	2	4	2	

¹Fisher's exact test.

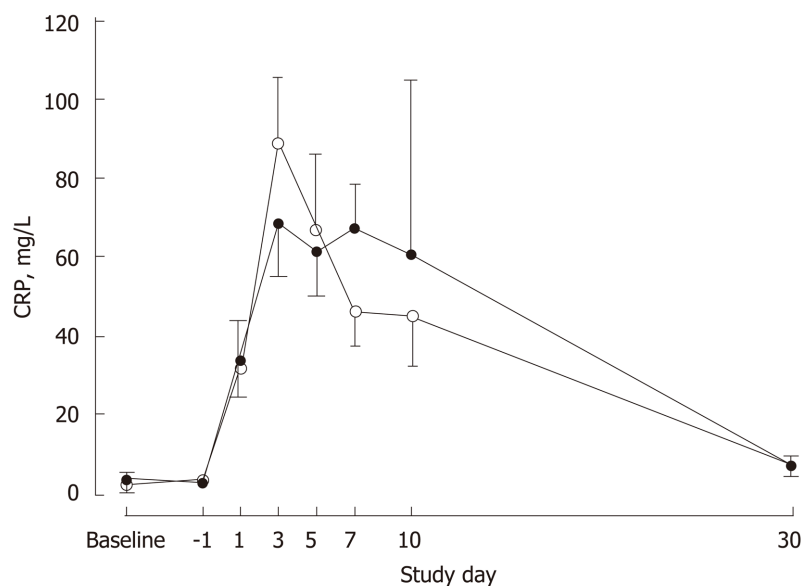


Figure 3 Plasma C-reactive protein concentrations (geometric mean \pm SE) measured at baseline, day prior to surgery (day-1) and on postoperative days 1, 3, 5, 7 and 30 in patients who received IMPACT preoperatively (solid symbols) compared with patients who received standard care (open symbols).

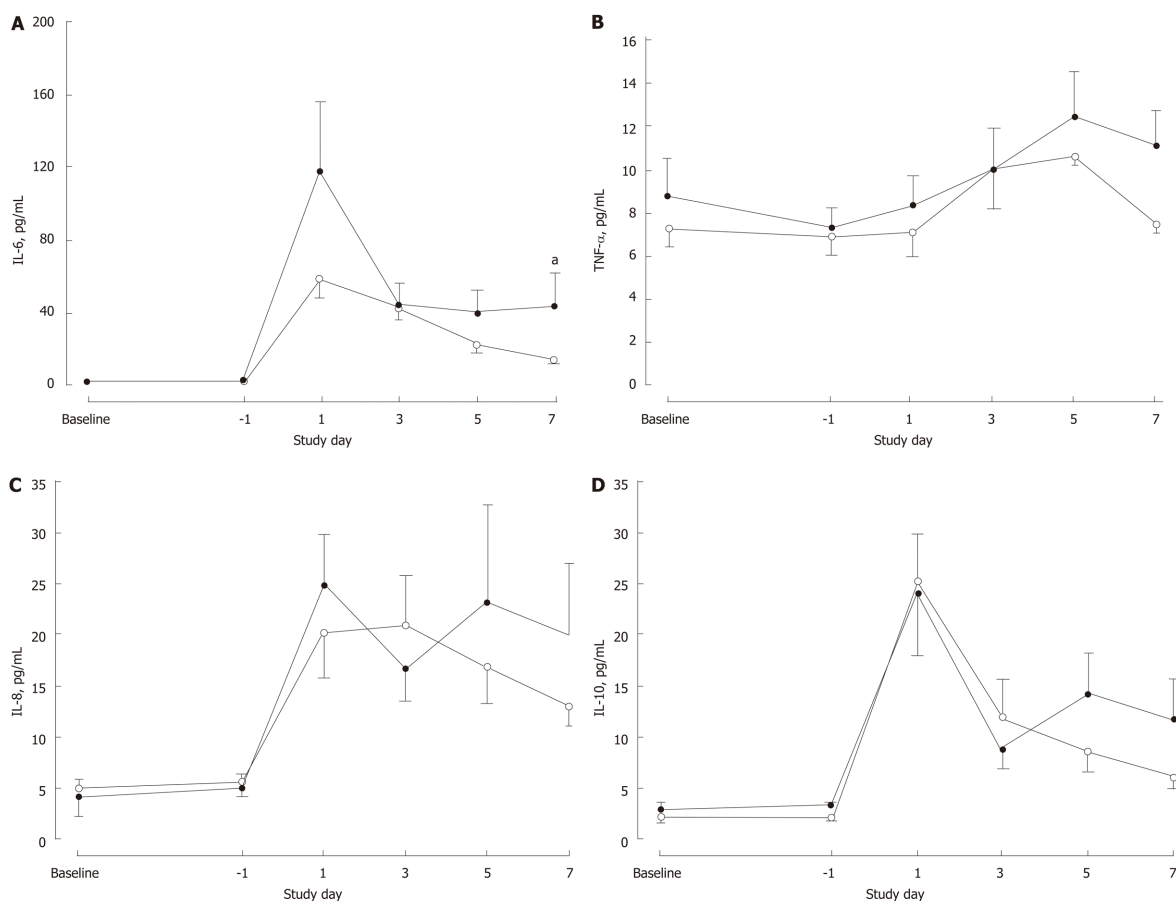


Figure 4 Plasma concentrations (geometric mean \pm SE) of interleukin-6 (IL-6) (A), TNF- α (B), IL-8 (C) and IL-10 (D) measured at baseline, day prior to surgery (day-1) and on postoperative days 1, 3, 5, and 7 in patients who received IMPACT preoperatively (solid symbols) compared with patients who received standard care (open symbols). ^a $P < 0.05$ vs standard care.

ARTICLE HIGHLIGHTS

Research background

Immunonutrients provided pre- and perioperatively to patients undergoing major gastrointestinal surgery have been shown in a number of studies to reduce postoperative morbidity. Nutritional supplementation enriched in n-3 long-chain fatty acids and arginine has been used in the majority of these studies and these nutrients are thought to modulate the inflammatory and immune responses to surgery leading to improved clinical outcome.

Research motivation

We were motivated to design and implement a randomized trial of immunonutrition in patients undergoing liver resection given that only one such prospective trial had previously been reported. That trial had a high dropout rate and we considered further work was needed.

Research objectives

The main objective of this study was to evaluate the effect of preoperative supplemental immunonutrition, enriched in n-3 fatty acids and arginine, on postoperative inflammatory and immune markers. A secondary objective was to examine effects on clinical outcome.

Research methods

Patients scheduled for non-laparoscopic elective hepatic resection for primary or secondary liver cancer were randomized in an assessor-blinded prospective trial to preoperative immunonutrition (IMPACT Advanced Recovery[®], 1020 kcal/d) for 5 consecutive days or to standard care. Blood samples were obtained at recruitment, on the day prior to surgery and on postoperative day (POD) 1, 3, 5 and 7 for measurement of plasma fatty acids and markers of inflammation and immune status. Patients were monitored for 30 POD for infectious and other complications.

Research results

Immune markers did not differ between the groups. Postoperative inflammatory response, as

assessed by interleukin-6 concentrations, was more pronounced in the immunonutrition group. Ten patients in the immunonutrition group and 4 in the standard care group developed infectious complications. Major postoperative complications were more common in the immunonutrition group.

Research conclusions

In this study, provision of a preoperative immunonutritional supplement was not associated with post-surgery suppression of inflammation nor with improved clinical outcomes. The higher incidence of major complications in the immunonutrition group may have contributed to these findings.

Research perspectives

Since completion of this study a similar preoperative immunonutrition regime was reported in a randomized trial demonstrating reduced postoperative inflammatory response and improved clinical outcome with immunonutrition. The majority of patients in that study had a relatively rare indication for liver resection. Future efforts should be directed at double-blind trials of immunonutritional formulae, in patients undergoing major liver resections for commonly seen indications, that are adequately powered to assess postoperative infectious complications.

REFERENCES

- 1 **Calder PC.** Immunonutrition in surgical and critically ill patients. *Br J Nutr* 2007; **98** Suppl 1: S133-S139 [PMID: 17922951 DOI: 10.1017/S0007114507832909]
- 2 **Waitzberg DL,** Saito H, Plank LD, Jamieson GG, Jagannath P, Hwang TL, Mijares JM, Bihari D. Postsurgical infections are reduced with specialized nutrition support. *World J Surg* 2006; **30**: 1592-1604 [PMID: 16794908 DOI: 10.1007/s00268-005-0657-x]
- 3 **Cerantola Y,** Hübner M, Grass F, Demartines N, Schäfer M. Immunonutrition in gastrointestinal surgery. *Br J Surg* 2011; **98**: 37-48 [PMID: 20931620 DOI: 10.1002/bjs.7273]
- 4 **Marimuthu K,** Varadhan KK, Ljungqvist O, Lobo DN. A meta-analysis of the effect of combinations of immune modulating nutrients on outcome in patients undergoing major open gastrointestinal surgery. *Ann Surg* 2012; **255**: 1060-1068 [PMID: 22549749 DOI: 10.1097/SLA.0b013e318252edf8]
- 5 **Zhang Y,** Gu Y, Guo T, Li Y, Cai H. Perioperative immunonutrition for gastrointestinal cancer: a systematic review of randomized controlled trials. *Surg Oncol* 2012; **21**: e87-e95 [PMID: 22317969 DOI: 10.1016/j.suronc.2012.01.002]
- 6 **Braga M,** Gianotti L, Nespoli L, Radaelli G, Di Carlo V. Nutritional approach in malnourished surgical patients: a prospective randomized study. *Arch Surg* 2002; **137**: 174-180 [PMID: 11822956 DOI: 10.1001/archsurg.137.2.174]
- 7 **Gianotti L,** Braga M, Nespoli L, Radaelli G, Beneduce A, Di Carlo V. A randomized controlled trial of preoperative oral supplementation with a specialized diet in patients with gastrointestinal cancer. *Gastroenterology* 2002; **122**: 1763-1770 [PMID: 12055582 DOI: 10.1053/gast.2002.33587]
- 8 **Mikagi K,** Kawahara R, Kinoshita H, Aoyagi S. Effect of preoperative immunonutrition in patients undergoing hepatectomy: a randomized controlled trial. *Kurume Med J* 2011; **58**: 1-8 [PMID: 22027191 DOI: 10.2739/kurumemedj.58.1]
- 9 **Uno H,** Furukawa K, Suzuki D, Shimizu H, Ohtsuka M, Kato A, Yoshitomi H, Miyazaki M. Immunonutrition suppresses acute inflammatory responses through modulation of resolvins E1 in patients undergoing major hepatobiliary resection. *Surgery* 2016; **160**: 228-236 [PMID: 26965712 DOI: 10.1016/j.surg.2016.01.019]
- 10 **Burdge GC,** Wright P, Jones AE, Wootton SA. A method for separation of phosphatidylcholine, triacylglycerol, non-esterified fatty acids and cholesterol esters from plasma by solid-phase extraction. *Br J Nutr* 2000; **84**: 781-787 [PMID: 11177194 DOI: 10.1017/S0007114500002154]
- 11 **Gibson RS,** Ferguson EL. *An interactive 24-hour recall for assessing the adequacy of iron and zinc intakes in developing countries. HarvestPlus Technical Monograph 8.* Washington D.C.: HarvestPlus 2008;
- 12 **Detsky AS,** McLaughlin JR, Baker JP, Johnston N, Whittaker S, Mendelson RA, Jeejeebhoy KN. What is subjective global assessment of nutritional status? *JPN J Parenter Enteral Nutr* 1987; **11**: 8-13 [PMID: 3820522 DOI: 10.1177/014860718701100108]
- 13 **Christensen T,** Bendix T, Kehlet H. Fatigue and cardiorespiratory function following abdominal surgery. *Br J Surg* 1982; **69**: 417-419 [PMID: 7104617 DOI: 10.1002/bjs.1800690721]
- 14 **Karnofsky DA,** Albelman WH, Craver LF, Burchenal JH. The use of the nitrogen mustards in the palliative treatment of carcinoma. *Cancer* 1948; **1**: 634-656 [DOI: 10.1002/1097-0142(194811)]
- 15 **Dindo D,** Demartines N, Clavien PA. Classification of surgical complications: a new proposal with evaluation in a cohort of 6336 patients and results of a survey. *Ann Surg* 2004; **240**: 205-213 [PMID: 15273542 DOI: 10.1097/01.sla.0000133083.54934.ae]
- 16 **Horan TC,** Andrus M, Dudeck MA. CDC/NHSN surveillance definition of health care-associated infection and criteria for specific types of infections in the acute care setting. *Am J Infect Control* 2008; **36**: 309-332 [PMID: 18538699 DOI: 10.1016/j.ajic.2008.03.002]
- 17 **Braga M,** Gianotti L, Vignali A, Carlo VD. Preoperative oral arginine and n-3 fatty acid supplementation improves the immunometabolic host response and outcome after colorectal resection for cancer. *Surgery* 2002; **132**: 805-814 [PMID: 12464864 DOI: 10.1067/msy.2002.128350]
- 18 **Okamoto Y,** Okano K, Izuishi K, Usuki H, Wakabayashi H, Suzuki Y. Attenuation of the systemic inflammatory response and infectious complications after gastrectomy with preoperative oral arginine and omega-3 fatty acids supplemented immunonutrition. *World J Surg* 2009; **33**: 1815-1821 [PMID: 19629583 DOI: 10.1007/s00268-009-0140-1]
- 19 **Hübner M,** Cerantola Y, Grass F, Bertrand PC, Schäfer M, Demartines N. Preoperative immunonutrition in patients at nutritional risk: results of a double-blinded randomized clinical trial. *Eur J Clin Nutr* 2012; **66**: 850-855 [PMID: 22617278 DOI: 10.1038/ejcn.2012.53]
- 20 **Giger-Pabst U,** Lange J, Maurer C, Bucher C, Schreiber V, Schlumpf R, Kocher T, Schweizer W,

- Krähenbühl S, Krähenbühl L. Short-term preoperative supplementation of an immunoenriched diet does not improve clinical outcome in well-nourished patients undergoing abdominal cancer surgery. *Nutrition* 2013; **29**: 724-729 [PMID: [23352174](#) DOI: [10.1016/j.nut.2012.10.007](#)]
- 21 **Zacharias T**, Ferreira N, Carin AJ. Preoperative immunonutrition in liver resection-a propensity score matched case-control analysis. *Eur J Clin Nutr* 2014; **68**: 964-969 [PMID: [24961546](#) DOI: [10.1038/ejcn.2014.113](#)]
- 22 **Plank LD**, Mathur S, Gane EJ, Peng SL, Gillanders LK, McIlroy K, Chavez CP, Calder PC, McCall JL. Perioperative immunonutrition in patients undergoing liver transplantation: a randomized double-blind trial. *Hepatology* 2015; **61**: 639-647 [PMID: [25212278](#) DOI: [10.1002/hep.27433](#)]
- 23 **Garth AK**, Newsome CM, Simmance N, Crowe TC. Nutritional status, nutrition practices and post-operative complications in patients with gastrointestinal cancer. *J Hum Nutr Diet* 2010; **23**: 393-401 [PMID: [20337847](#) DOI: [10.1111/j.1365-277X.2010.01058.x](#)]
- 24 **Krenitsky J**. Nutrition and the immune system. *AACN Clin Issues* 1996; **7**: 359-369 [PMID: [8826398](#) DOI: [10.1097/00044067-199608000-00004](#)]
- 25 **Barker LA**, Gray C, Wilson L, Thomson BN, Shedd S, Crowe TC. Preoperative immunonutrition and its effect on postoperative outcomes in well-nourished and malnourished gastrointestinal surgery patients: a randomised controlled trial. *Eur J Clin Nutr* 2013; **67**: 802-807 [PMID: [23801093](#) DOI: [10.1038/ejcn.2013.117](#)]
- 26 **Consensus recommendations from the US summit on immune-enhancing enteral therapy**. *JPEN J Parenter Enteral Nutr* 2001; **25**: S61-S63 [PMID: [11288926](#)]
- 27 **Weimann A**, Braga M, Harsanyi L, Laviano A, Ljungqvist O, Soeters P; DGEM (German Society for Nutritional Medicine), Jauch KW, Kemen M, Hiesmayr JM, Horbach T, Kuse ER, Vestweber KH; ESPEN (European Society for Parenteral and Enteral Nutrition). ESPEN Guidelines on Enteral Nutrition: Surgery including organ transplantation. *Clin Nutr* 2006; **25**: 224-244 [PMID: [16698152](#) DOI: [10.1016/j.clnu.2006.01.015](#)]
- 28 **Giger U**, Büchler M, Farhadi J, Berger D, Hüsler J, Schneider H, Krähenbühl S, Krähenbühl L. Preoperative immunonutrition suppresses perioperative inflammatory response in patients with major abdominal surgery-a randomized controlled pilot study. *Ann Surg Oncol* 2007; **14**: 2798-2806 [PMID: [17632760](#) DOI: [10.1245/s10434-007-9407-7](#)]
- 29 **Browning LM**, Walker CG, Mander AP, West AL, Madden J, Gambell JM, Young S, Wang L, Jebb SA, Calder PC. Incorporation of eicosapentaenoic and docosahexaenoic acids into lipid pools when given as supplements providing doses equivalent to typical intakes of oily fish. *Am J Clin Nutr* 2012; **96**: 748-758 [PMID: [22932281](#) DOI: [10.3945/ajcn.112.041343](#)]
- 30 **Calder PC**. Mechanisms of action of (n-3) fatty acids. *J Nutr* 2012; **142**: 592S-599S [PMID: [22279140](#) DOI: [10.3945/jn.111.155259](#)]

Intraperitoneal rupture of the hydatid cyst: Four case reports and literature review

Sami Akbulut, Fatih Ozdemir

ORCID number: Sami Akbulut (0000-0002-6864-7711); Fatih Ozdemir (0000-0003-0292-3602).

Author contributions: Akbulut S designed the report; Akbulut S and Ozdemir F collected the clinical data; Akbulut S and Ozdemir F analyzed the data and wrote the paper.

Informed consent statement: The patients involved in this study gave informed written consent prior to study enrollment, authorizing the use and disclosure of their protected health information.

Conflict-of-interest statement: The author declares no potential conflict of interest.

CARE Checklist (2016) statement: The authors have read the CARE Checklist (2013), and the manuscript was prepared and revised according to the CARE Checklist (2016).

Open-Access: This article is an open-access article that was selected by an in-house editor and fully peer-reviewed by external reviewers. It is distributed in accordance with the Creative Commons Attribution Non Commercial (CC BY-NC 4.0) license, which permits others to distribute, remix, adapt, build upon this work non-commercially, and license their derivative works on different terms, provided the original work is properly cited and the use is non-commercial. See: <http://creativecommons.org/licenses/by-nc/4.0/>

Sami Akbulut, Fatih Ozdemir, Department of Surgery and Liver Transplant Institute, Inonu University Faculty of Medicine, Malatya 44280, Turkey

Corresponding author: Sami Akbulut, MD, Associate Professor, FACS, Department of Surgery and Liver Transplant Institute, Inonu University Faculty of Medicine, Elazig Yolu 10. Km, Malatya 44280, Turkey. akbulutsami@gmail.com

Telephone: +90-422-3410660

Fax: +90-422-3410036

Abstract

BACKGROUND

Most patients with hydatid cysts are asymptomatic, and they are diagnosed incidentally during radiological evaluations performed for other reasons. However, some patients develop symptoms and complications due to cyst size, location, and the relationship between the cyst and adjacent structures. The most serious complications that can occur are rupture of the cysts into the biliary tract, vascular structures, hollow viscus, and peritoneal cavity. We aimed to describe the management of four cases of intraperitoneal rupture of hydatid cysts.

CASE SUMMARIES

Four patients aged between 27 and 44 years (two men and two women) were admitted to our clinic with sudden abdominal pain ($n = 4$), hypotension ($n = 3$), and anaphylaxis ($n = 2$). Three of the perforated cysts were located in the liver, and one was located in the spleen. Two patients developed cyst rupture after minor trauma, and the other two developed spontaneous rupture. Enzyme-linked immunosorbent assay IgG results were positive for two patients and negative for the other two. All patients received albendazole treatment after surgical intervention (range: 2-6 mo). Two patients developed hepatic abscesses requiring drainage; one of these patients also developed hydatid cyst recurrence during postoperative follow-up (range: 25-80 mo).

CONCLUSION

Intraperitoneal rupture is a life-threatening complication of hydatid cysts. It is important to manage patients with surgical intervention as soon as possible with aggressive medical treatment for anaphylactic reactions.

Key words: Hydatid cyst; Complication; Intraperitoneal rupture; Spontaneous rupture; Traumatic rupture; Anaphylactic reactions; Case report

©The Author(s) 2019. Published by Baishideng Publishing Group Inc. All rights reserved.

Manuscript source: Unsolicited manuscript

Received: November 29, 2018

Peer-review started: November 30, 2018

First decision: December 17, 2018

Revised: January 19, 2019

Accepted: January 29, 2019

Article in press: January 30, 2019

Published online: March 27, 2019

P-Reviewer: Farshadpour F, Jarcuska P

S-Editor: Ji FF

L-Editor: Filipodia

E-Editor: Zhang YL



Core tip: Spontaneous or traumatic intraperitoneal hydatid cyst rupture is a rare but life-threatening complication. Therefore, hydatid cyst rupture should be considered as a differential diagnosis in patients who have sudden onset abdominal pain and allergic reactions like urticaria, especially those in regions endemic to the disease. Deteriorated hemodynamic parameters due to anaphylactic reactions should be corrected quickly with subsequent emergent surgery for a life-saving procedure. Herein, we aimed to present the management algorithm of four patients diagnosed with intraperitoneal hydatid cyst rupture.

Citation: Akbulut S, Ozdemir F. Intraperitoneal rupture of the hydatid cyst: Four case reports and literature review. *World J Hepatol* 2019; 11(3): 318-329

URL: <https://www.wjgnet.com/1948-5182/full/v11/i3/318.htm>

DOI: <https://dx.doi.org/10.4254/wjh.v11.i3.318>

INTRODUCTION

Hydatid disease is a zoonotic disease caused by the echinococcus parasite, which is a member of the Taeniidae family. Most common echinococcus species that cause hydatid disease in humans are *Echinococcus granulosus* (cystic echinococcosis) and *Echinococcus multilocularis* (alveolar echinococcosis). Cystic echinococcosis, also known as hydatid cysts, constitute 95% of all hydatid diseases [1-3]. Hydatid diseases can develop in almost all organs and tissues of the human body, but the most frequently involved organs are the liver (50%-77%), lungs (15%-47%), spleen (0.5%-8%), and kidneys (2%-4%) [1-6]. Humans, who have no role in the biological life cycle of echinococcosis, can accidentally become intermediate hosts by ingesting tapeworm eggs [1,4]. Hydatid cysts can grow at an average of 10-50 mm/year depending on the location of the cyst, so most patients remain asymptomatic for years [3,7,8]. Usually, asymptomatic patients are diagnosed incidentally by radiological evaluations that are performed for other reasons. Nevertheless, some patients have signs and symptoms, including mild or severe abdominal pain, nausea, vomiting, jaundice due to size, location, and/or involvement of the adjacent structures and organs of the cystic lesions [1]. The most frequently reported complications are rupture (perforation), bacterial infection, anaphylactic reaction, compression of the vascular and biliary structures, and compression of the neighboring organs [4,5]. Hydatid cyst rupture can be internal (cysto-biliary fistula, rupture into the hollow viscus, broncho-biliary fistula, bronchopleural fistula, intrapericardial rupture, intrapleural rupture, intraperitoneal rupture) or more rarely, it can be external (cysto-cutaneous fistula) [3]. Intraperitoneal rupture is a rare but life-threatening, severe complication of hydatid cyst disease [3]. We aim to describe the cases of four patients who developed intraperitoneal rupture and review the medical literature.

CASE PRESENTATION

The summary information of the four cases described below is given in Table 1.

Case 1: Chief complaints

A 44-year-old man was admitted to the emergency department with sudden onset abdominal pain, skin flushing at some areas of the abdomen and hypotensive shock without any history of trauma.

History of present illness

The patient was diagnosed with obstructive jaundice complicated by a hydatid cyst approximately one month ago. The connection between the biliary tract and hydatid cyst was visualized by radiological examinations. Endoscopic retrograde cholangiopancreatography (ERCP) was performed to decompress the biliary tract before surgical intervention. Albendazole treatment was initiated before the surgery.

History of past illness

The patient had no medical disease other than the hydatid cyst.

Laboratory examinations

Table 1 Demographic and clinical characteristics of four patients with hydatid cyst perforation

Parameters	Case 1	Case 2	Case 3	Case 4
Age	44	37	27	40
Gender	Male	Male	Female	Female
Cause of perforation	Spontaneous	Trauma	Spontaneous	Trauma
Clinical presentation	Pain (sudden)	Pain (sudden)	Pain (sudden)	Pain (sudden)
	Hypotension	Hypotension	Hypotension	Anaphylaxis
	Anaphylaxis	Anaphylaxis		Not clear
Serology	ELISA IgG (+)	ELISA IgG (+)	Negative	Negative
History of HD	Known	Unknown	Unknown	Known
Cyst location	Liver (Bilobar)	Spleen	Liver (Bilobar)	Liver (Bilobar)
		Retroperitoneum		
		Retrovesical		
Perforated cyst location	Liver (VI)	Spleen	Liver (III)	Liver (II-VI)
Cysts size (mm)	165 × 100 × 80	50 × 45	80 × 75	110 × 85
	130 × 100 × 95	50 × 40	40 × 10	30 × 25
	85 × 70 × 65	60 × 50		
Preop antihelminthic	ALBZ (1 mo)	No	No	ALBZ (? mo)
Postop antihelminthic	ALBZ (6 mo)	ALBZ (2 mo)	ALBZ (2 mo)	ALBZ (2 mo)
Diagnostic tools	US + CT	US	US + CT	CT
Surgical approach	Partial Cystectomy+	Splenectomy+	Partial Cystectomy+	Partial Cystectomy+
	CBD exploration+	Retroperitoneal+	Omentopexy	Omentopexy
	T-tube insertion+	Retrovesical		
	Omentopexy	Cystectomy		
Recurrence	Yes	No	No	No
Postop complication	Liver abscess	Bleeding	No	Liver abscess
Follow up (mo)	80	34	25	36

HD: Hydatid disease; ALBZ: Albendazole; US: Ultrasonography; CT: Computed tomography; CBD: Common bile duct.

Complete blood count (CBC) was as follows: White blood cells (WBCs): 12900/mL, neutrophils: 80%, and eosinophils: 0.9%. Test results for biochemical analysis were as follows: Aspartate aminotransferase (AST), 152 (5-34 U/L); alanine aminotransferase (ALT), 58 (5-34 U/L); alkaline phosphatase (ALP), 260 (40-150 U/L); gamma-glutamyl transferase (GGT) 125, (12-64 U/L); and total bilirubin, 1.03 (0.2-1.2 mg/dL).

Imaging examinations

Abdominal ultrasonography (US) and contrast-enhanced abdominal computed tomography (CT) showed that multiple cystic lesions compatible with hydatid cyst disease (largest size 165 mm × 100 mm × 80 mm) were localized in the liver. CT scans also showed that the ruptured cystic lesion was localized in the VI segment of the liver (Figures 1 and 2).

FINAL DIAGNOSIS

The final diagnosis of the present case was intraperitoneal liver hydatid cyst rupture.

TREATMENT

Fluid resuscitation, antihistaminic, and corticosteroid treatment was initiated at the emergency department. Laparotomy was performed due to the patient's general condition. Intraoperatively, the cyst located in the liver ruptured, and 2500 mL of fluid containing cyst material was aspirated from the peritoneal cavity. The peritoneal cavity was washed with saline solution and partial cystectomy, omentoplasty, and common bile duct exploration with T-tube placement were performed.

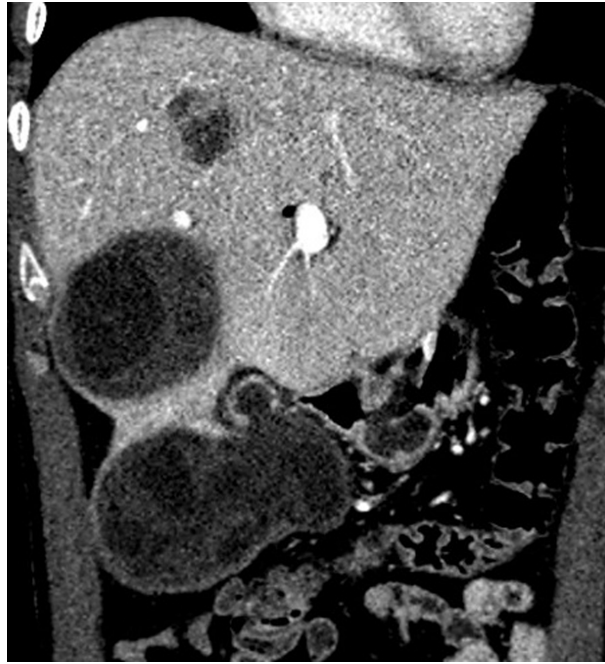

Figure 1 Coronal reformatted contrast-enhanced computed tomography shows that fluid collection and daughter vesicles adjacent to the hydatid cyst located in segment VI of the liver. This finding is consistent with a perforated hydatid cyst.

OUTCOME AND FOLLOW-UP

The patient developed an abscess that required drainage in the postoperative period. Six albendazole treatments with 3-wk cycles were administered as medical treatment. The T-tube was removed when normal biliary tract anatomy was visualized during cholangiography, approximately three weeks postoperative.

Case 2: Chief complaints

A 37-year-old man presented in our emergency unit with severe abdominal pain and anaphylactic shock signs/symptoms, such as hypotension and allergic reaction.

History of present illness

The patient suddenly felt sharp abdominal pain after playing with and tossing his nephew and simultaneously felt like something was leaking inside him. Subsequently, dizziness and diffuse flushing occurred.

Laboratory examinations

CBC analysis revealed leukocytosis (18800/mL), with predominant neutrophils (86.4%) and normal eosinophils (0.1%). Biochemical blood test results were within normal limits except for total bilirubin (1.5 mg/dL).

Imaging examinations

US showed massive intraabdominal fluid collections in the perihepatic and perisplenic area. Additionally, a ruptured and degenerated cyst with a germinative membrane collapse near the spleen was visualized.

FINAL DIAGNOSIS

The final diagnosis of the present case was intraperitoneal splenic hydatid cyst rupture.

TREATMENT

Fluid resuscitation, antihistaminic, and corticosteroid treatment was initiated at the emergency department. The patient was then taken to the operating room, and laparotomy was performed with a midline incision. An exophytic, ruptured hydatid

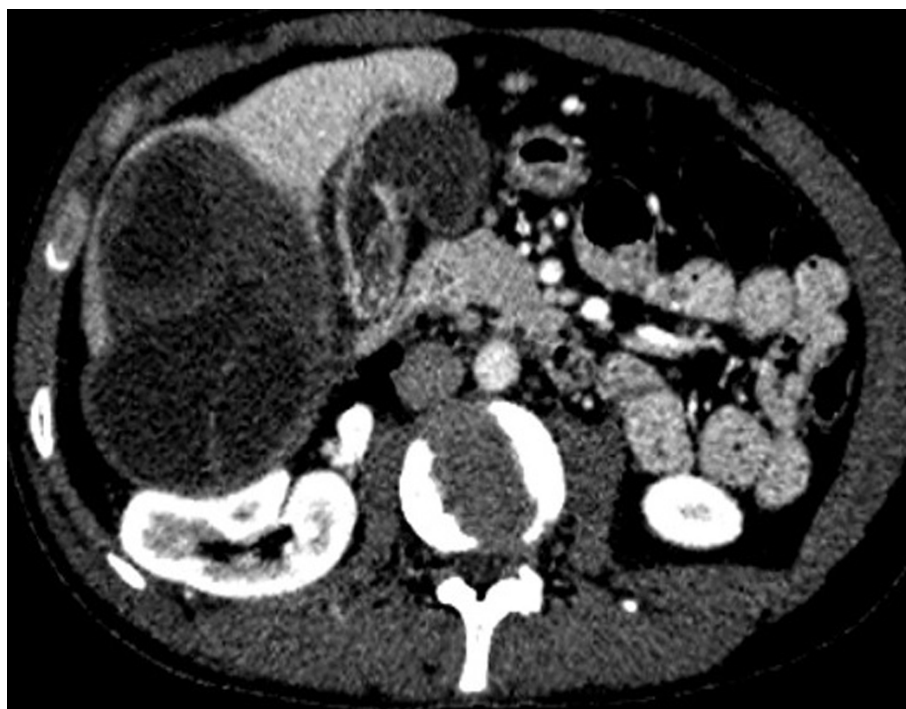

Figure 2 Axial plane computed tomography of the same patient shows exophytic extension of the giant hydatid cyst located in the right lobe of the liver.

cyst originating from the spleen, which had adhesions to adjacent structures, was identified. Total splenectomy was required (Figures 3 and 4). An iatrogenic left diaphragm injury due to intraabdominal adhesions occurred during surgery. A left-sided chest tube was inserted after the primary repair of the diaphragm. Additionally, other cystic lesions located at the posterior side of the urinary bladder (60 mm × 50 mm) and at the retroperitoneum (50 mm × 40 mm) were completely excised. A chest tube was removed postoperatively on the fourth day.

OUTCOME AND FOLLOW-UP

The patient had an uneventful postoperative clinical course. *Pneumococcus* vaccination was administered 14 d after surgery. Continuous albendazole treatment was administered for two months after surgery.

Case 3: Chief complaints

A 27-year-old woman experienced sudden onset abdominal pain at another medical center. She was diagnosed with a ruptured hydatid cyst and was referred to our medical center. She had hypotension during her first evaluation at the emergency unit.

History of present illness

She had no history of hydatid cyst.

Laboratory examinations

CBC analysis showed leukocytosis (24100/mL) with predominant neutrophils (94.5%) and normal eosinophils (0.2%). Biochemical blood tests were within normal limits.

Imaging examinations

Contrast-enhanced abdominal CT revealed that one lesion was compatible with a hydatid cyst in the anterior sector of the liver (80 mm × 75 mm × 70 mm) and another one at segment III (40 mm × 10 mm). Additionally, several daughter cystic lesions (largest diameter 130 mm × 60 mm × 50 mm) secondary to the rupture of the cystic lesion near segment III were observed in the pelvic cavity (Figure 5).

FINAL DIAGNOSIS

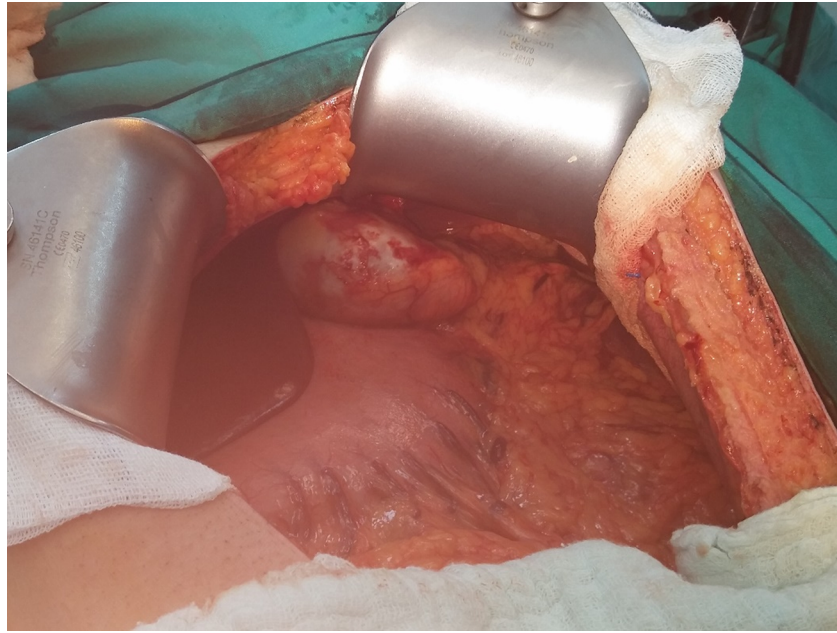


Figure 3 Intraoperative appearance of the hydatid cyst compatible lesion that originated and ruptured from the spleen. This image was taken after aspiration of the hydatid cyst fluid in the abdominal cavity.

The final diagnosis of the present case was an intraperitoneal liver hydatid cyst rupture.

TREATMENT

Fluid resuscitation was initiated at the emergency department. The patient was then taken to the operating room. The anterior wall of the cyst located in the anterior sector of the liver was excised, and the cystic components were completely evacuated. Three bile ducts that opened into the cystic cavity were closed with polypropylene sutures. Afterwards, the hydatid cyst wall localized next to segment III was excised, and the cyst components were completely evacuated. Cholecystectomy was performed to place high pressure saline solution into the common bile duct via cystic duct; there was no bile leak. Daughter vesicles located in the pelvic cavity were also removed, and the peritoneal cavity was washed with hypertonic saline solution.

OUTCOME AND FOLLOW-UP

The patient had an uneventful postoperative clinical course. Postoperative albendazole treatment was administered for two months.

Case 4: Chief complaints

A 40-year-old woman was suffering from abdominal pain for one month, and her pain became aggravated for two days prior to admission. Physical examination revealed widespread tenderness in all quadrants of the abdomen.

History of present illness

The patient stated that she had received antihelminthic medical treatment several times.

Laboratory examinations

CBC analysis showed leukocytosis (WBC: 23400/mm³, neutrophils: 90.6%, and eosinophils: 0.4%). Biochemical results were not altered except for ALP and GGT levels (AST: 18 U/L, ALT: 18 U/L, ALP: 197 U/L, GGT: 114 U/L, and total bilirubin 0.87 mg/dL).

Imaging examinations

Contrast-enhanced abdominal CT revealed several hydatid cysts (largest diameter 10 mm × 85 mm × 60 mm) in the left lobe of the liver. Cysts located in the left lobe of the

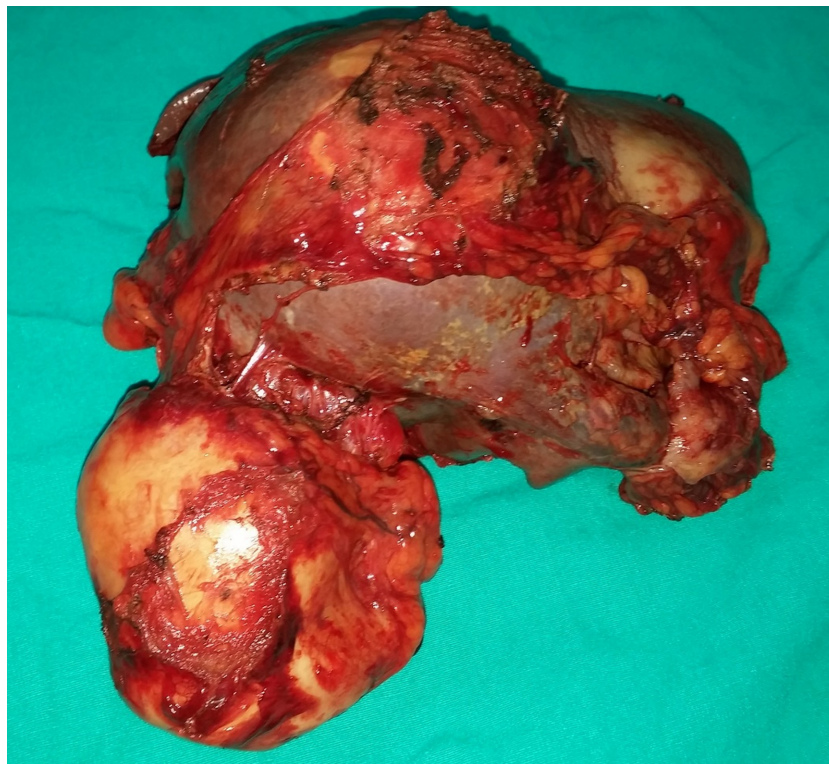

Figure 4 Appearance of the spleen and ruptured cyst specimens obtained from the same patient.

liver compressed the main bile duct, causing dilation of the intrahepatic bile ducts of the left liver lobe (Figure 6). Several cystic lesions were also observed in the pelvic cavity.

FINAL DIAGNOSIS

The final diagnosis of the present case was intraperitoneal liver hydatid cyst rupture.

TREATMENT

There were several adhesions secondary to the ruptured cyst, and they were diagnosed during laparotomy as sclerosing encapsulated peritonitis (Figure 7). After adhesiolysis, the perforated wall of the cyst was excised, and the cyst components were completely evacuated (Figure 8). Additionally, cystic components located in the pelvic cavity were removed.

OUTCOME AND FOLLOW-UP

The patient had an uneventful postoperative clinical course and was treated with continuous albendazole for two months. The patient developed left lobe liver abscess in the third postoperative year, which required percutaneous drainage.

DISCUSSION

About 5%-40% of the hydatid cysts located in the liver and other organs of the body may cause various complications. The most common complications related with hydatid cysts include superinfection, cysto-biliary fistula (obstructive jaundice, cholangitis), allergic reactions, rupture into the gastrointestinal system (duodenum, small intestine, colon), Budd Chiari syndrome, portal hypertension, gastric outlet obstruction, membranous glomerulonephritis, broncho-biliary fistula, bronchopleural fistula, intrapericardial rupture, intrapleural rupture, and intraperitoneal rupture^[1,3,7,9].

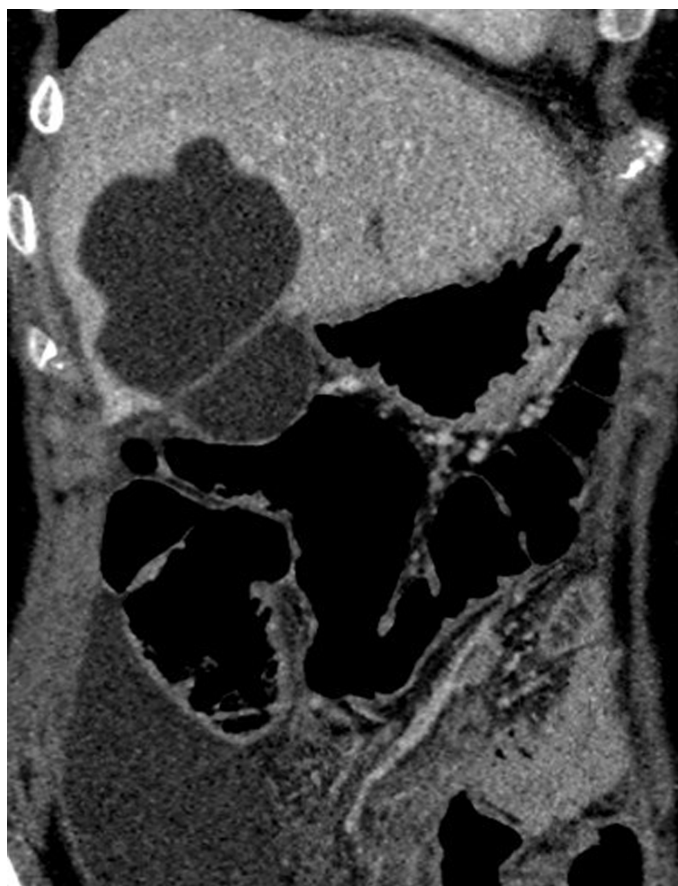

Figure 5 Coronal reformatted images of the venous phase of computed tomography shows perforated hydatid cyst located in segment V of the liver. This image also shows fluid collection in the right paracolic area.

Intraperitoneal hydatid cyst rupture may result from trauma or may spontaneously occur due to increased intracystic pressure [1,10,11]. Sometimes, iatrogenic hydatid cyst rupture may occur during elective surgery. Some studies have concluded that most intraperitoneal ruptures develop after trauma; nevertheless, other studies pointed out that spontaneous ruptures may develop more frequently [6,7,12].

Intraperitoneal rupture is the third most common complication (0.9%-16%) after intrabiliary rupture (5%-25%) and allergic reactions (1%-25%) [1,4,7]. Most studies regarding intraperitoneal hydatid cyst rupture have been published as case reports. To our knowledge, four or more cases were reported in a limited number of studies [4,6,9,13-22] (Table 2). Risk factors for rupture include young age, cyst diameter (> 10 cm), and superficial localization [1,4,7]. Hydatid cysts are more common in younger individuals because they are exposed to traffic accidents more often than older individuals. Intracystic pressure increases with increasing cyst dimension. When intracystic pressure increases to more than 50 cmH₂O, spontaneous or traumatic rupture risk also increases [6,10]. Most superficial cyst walls are not protected by the liver parenchyma. This is a facilitating factor for rupture of the cyst into peritoneal cavity or hollow gastrointestinal organs [1,4]. The aims of emergent surgical treatment include prevention or minimization of anaphylactic reactions in the early term and prevention of the development of long-term secondary peritoneal hydatidosis [4,7].

Clinical signs and symptoms of intraperitoneal cyst ruptures may vary widely among patients. The most frequent symptoms are mild or severe abdominal pain, vomiting, nausea, and some allergic reactions that span a wide range. If the content of the ruptured cyst is purulent or associated with the biliary tract, it may cause peritoneal irritation. Therefore, clinical signs of acute abdominal pain may occur [1,4]. A wide spectrum of life-threatening immunologic reactions, such as allergic reactions and/or anaphylactic shock, develop against the cyst content, which spread into the peritoneal cavity [1,4]. Therefore, some patients may have complaints such as hypotension, tachycardia, and respiratory distress [1].

While 16.7%-25% of patients with hydatid cyst rupture develop minor allergic reactions, such as urticaria and macular eruption, 1%-12.5% of patients develop more severe allergic reactions such as peripheral edema, syncope, and anaphylaxis [1,6]. The life-threatening anaphylactic shock incidence rate is approximately 1.4%. Allergic

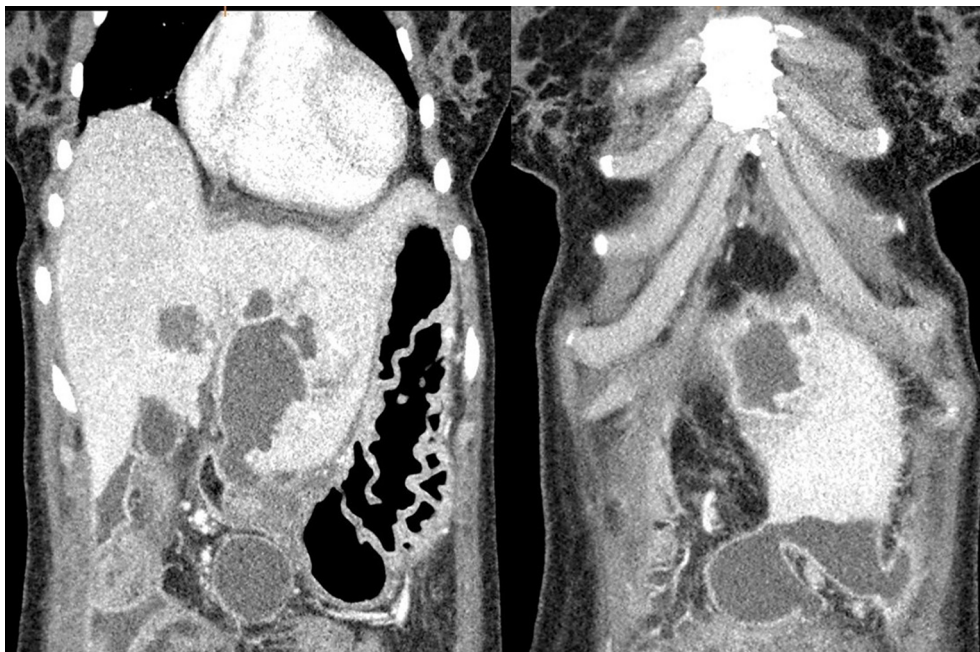


Figure 6 Two different coronal reformatted contrast-enhanced computed tomography images of the same patient show a perforated hydatid cyst located in segment III of the liver and fluid collection in the perihepatic/pelvic area.

reactions may develop in macroscopic ruptures or when the cyst contents pass into the biliary tract after trauma, iatrogenic interventions, or spontaneously. Even allergic reactions may occur after direct communication when the cyst contents enter systemic circulation [1]. Anaphylactic reactions during cyst hydatid surgery may develop in 0.2%-3.3% of patients who do not experience rupture [1].

Most patients who have intraperitoneal rupture are admitted to the emergency unit with symptoms such as severe abdominal pain, hypotension, tachycardia, and allergic reactions [1,10,11]. Therefore, US is the most common radiologic tool for diagnosis. If patients are hemodynamically stable, contrast-enhanced CT may be used. The sensitivity of US and CT is 85% and 100%, respectively [1,8,9].

Medical treatment should be initiated as soon as possible at the emergency unit after confirming the diagnosis of intraperitoneal rupture. Moreover, it should be continued during surgery. To minimize morbidity and mortality, patients should be hemodynamically stabilized before surgery, and they should undergo surgery as soon as possible. Medical treatment is aimed at stabilizing hemodynamic status with fluid resuscitation and treating anaphylactic reactions with corticosteroids, antihistaminic, and vasopressor drugs.

There is no consensus in the literature about surgical treatment options for intraperitoneal cyst rupture [7,12]. We suggest that each case should be evaluated separately in accordance with the general principles of hydatid cyst surgery. Simply summarized, hemodynamically stable patients should undergo either laparoscopic or open surgery as soon as possible, and hemodynamically unstable patients should undergo open surgery. Cyst contents that trigger anaphylactic reactions should be removed from the abdominal cavity as soon as possible [1,5-7]. The peritoneal cavity should be washed with scolicidal solutions such as formaldehyde, hypertonic saline (3%-10%-15%-30%), silver nitrate (0.5%), cetrimide, chlorhexidine, cetrimide plus chlorhexidine (1.5%/0.15%), hydrogen peroxide (1.5%-3%), povidone iodine (10%-50%), or ethyl alcohol (70%-95%). Each solution has a different time frame for possible scolicidal effects [1,5-7]. We prefer hypertonic saline or cetrimide plus chlorhexidine to wash the peritoneal cavity at least two times within 10 min for 10-15 min each [1]. Allergens that lead to anaphylactic reactions can be removed in this manner. Perforated cystic cavities should be carefully evaluated. Remaining cystic contents should also be evacuated, and the free edges of the cystic cavity should be widely excised. Perforated cysts that are located in the liver should be examined via a leakage test, which can be performed with a saline solution administered through the common bile duct/cystic duct to observe the relationship between the cyst and the biliary tract. Bile duct orificies that lead to bile leakage should be repaired with different suture materials. Common bile duct and T-tube placement for high flow output bile fistulas can be performed simultaneously. Sometimes, ERCP can be selected instead of T-tube application to complete the surgery as soon as possible. The

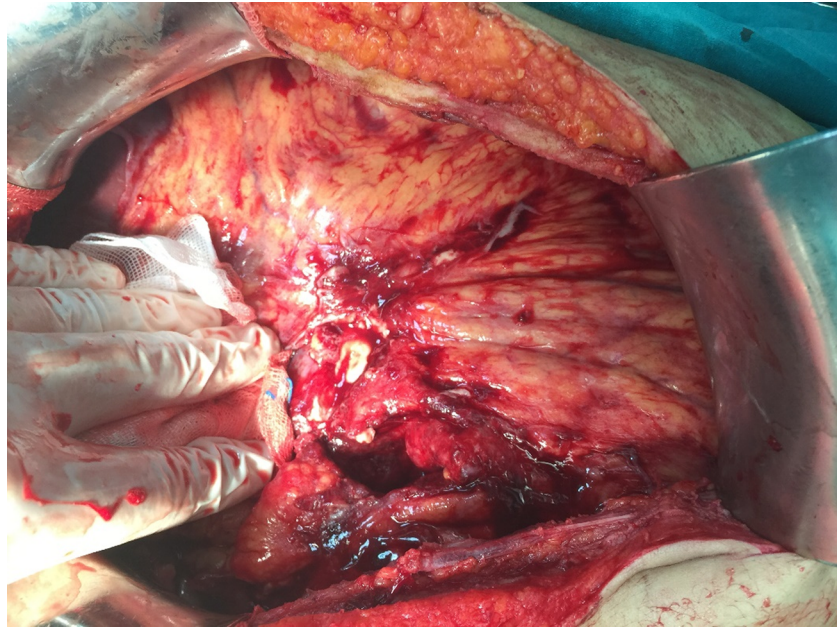


Figure 7 Intraoperative appearance of severe adhesions similar to sclerosing encapsulating peritonitis in the abdominal cavity secondary to hydatid cyst perforation.

biliary tract can be visualized via ERCP. If possible, spleen-preserving surgical interventions should be preferred [5]. Abdominal drains should be placed both into the cystic cavity and in the abdomen before surgery completion. Next, we would like to discuss the question “do we need any intervention for other unperforated cystic lesions identified during emergency surgery?”

Antihelminthic treatment should be administered as soon as possible for patients diagnosed with intraperitoneal rupture to prevent disease recurrence due to overlooked cystic contents during surgery. The most preferred antihelminthic agent is albendazole (10-15 mg/kg per day). According to the literature, the treatment period should last between 1 and 12 mo [1,4,6,8]. Patients diagnosed with intraperitoneal hydatid cyst rupture should be followed-up more frequently than patients without complications. Morbidity and mortality rates after intraperitoneal rupture are 10-35.3% and 0-23.5%, respectively [7,9]. Clinical follow-up should be performed monthly, especially during the early period after surgery and once a year in the long-term. US, echinococcus IgG enzyme-linked immunosorbent assay, indirect hemagglutination, and CT can be selected during follow-up. If there is no recurrence after five years, clinical follow-up can be terminated. The recurrence rate after intraperitoneal hydatid cyst rupture is reported between 0-28.6% [1,4,6,7,9]. There was only one case of recurrence in our series.

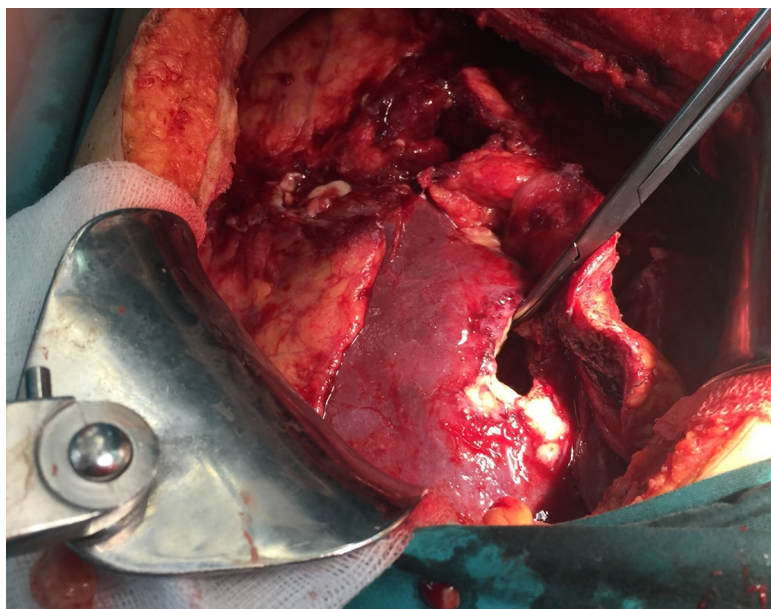
CONCLUSION

Intraperitoneal hydatid cyst rupture is a life-threatening complication because it causes serious hemodynamic instability and allergic reactions. Therefore, hydatid cyst rupture should be considered a differential diagnosis in patients who have sudden onset abdominal pain and allergic reactions, like urticaria, especially in regions endemic for the disease. Deteriorated hemodynamic parameters due to anaphylactic reactions should be quickly corrected so that emergent surgery can be life-saving.

Table 2 Short analysis of studies that published four or more cases of intraperitoneal hydatid cyst rupture

Authors	Years	Country	City	Study period	Perforated HC	Total HC surgery	Rate (%)
Toumi	2017	Tunisia	Monastir	1990-2015	12	1350	0,9
Sakcak	2015	Turkey	Ankara	1996-2013	16	756	2,1
Ozturk	2007	Turkey	Erzurum	1979-2004	20	653	3,1
Mouqait	2013	Morocco	Fes	2008-2012	14	306	4,6
Derici	2007	Turkey	Izmir	1988-2005	17	306	5,6
Unalp	2010	Turkey	Izmir	2000-2009	21	368	5,7
Kurt	2003	Turkey	Istanbul	1995-2001	7	99	7,1
Akcan	2010	Turkey	Kayseri	1990-2008	28	372	7,5
Bozdog	2016	Turkey	Diyarbakir	2005-2015	16	NA	NA
Ozturk	2016	Turkey	Izmir	2008-2012	13	NA	NA
Dirican	2010	Turkey	Malatya	2003-2008	10	NA	NA
Rami	2009	Morocco	Fes	NA	4	NA	NA
Gunay	1999	Turkey	Istanbul	1985-1997	16	NA	NA

NA: Not available; HC: hydatid cyst.

**Figure 8** Intraoperative image obtained after evacuating the cystic contents.

REFERENCES

- 1 **Yilmaz M**, Akbulut S, Kahraman A, Yilmaz S. Liver hydatid cyst rupture into the peritoneal cavity after abdominal trauma: case report and literature review. *Int Surg* 2012; **97**: 239-244 [PMID: [23113853](#) DOI: [10.9738/CC116.1](#)]
- 2 **Akbulut S**, Sogutcu N, Eris C. Hydatid disease of the spleen: single-center experience and a brief literature review. *J Gastrointest Surg* 2013; **17**: 1784-1795 [PMID: [23949423](#) DOI: [10.1007/s11605-013-2303-5](#)]
- 3 **Akbulut S**. Parietal complication of the hydatid disease: Comprehensive literature review. *Medicine (Baltimore)* 2018; **97**: e10671 [PMID: [29794743](#) DOI: [10.1097/MD.00000000000010671](#)]
- 4 **Toumi O**, Noomen F, Salem R, Rabeh H, Jabra SB, Korbi I, Bannani S, Nasr M, Zouari K, Mondher G, Hamdi A. Intraperitoneal rupture of hydatid cysts. *Eur J Trauma Emerg Surg* 2017; **43**: 387-391 [PMID: [27084544](#) DOI: [10.1007/s00068-016-0662-9](#)]
- 5 **Belli S**, Akbulut S, Erbay G, Koçer NE. Spontaneous giant splenic hydatid cyst rupture causing fatal anaphylactic shock: a case report and brief literature review. *Turk J Gastroenterol* 2014; **25**: 88-91 [PMID: [24918138](#) DOI: [10.5152/tjg.2014.3521](#)]
- 6 **Unalp HR**, Yilmaz Y, Durak E, Kamer E, Tarcan E. Rupture of liver hydatid cysts into the peritoneal cavity. A challenge in endemic regions. *Saudi Med J* 2010; **31**: 37-42 [PMID: [20062897](#) DOI: [10.1016/j.revmed.2009.02.027](#)]
- 7 **Tinsley B**, Abbara A, Kadaba R, Sheth H, Sandhu G. Spontaneous intraperitoneal rupture of a hepatic

- hydatid cyst with subsequent anaphylaxis: a case report. *Case Reports Hepatol* 2013; **2013**: 320418 [PMID: 25431702 DOI: 10.1155/2013/320418]
- 8 Sozuer E, Akyuz M, Akbulut S. Open surgery for hepatic hydatid disease. *Int Surg* 2014; **99**: 764-769 [PMID: 25437585 DOI: 10.9738/INTSURG-D-14-00069.1]
 - 9 Mouaqit O, Hibatallah A, Oussaden A, Maazaz K, Taleb KA. Acute intraperitoneal rupture of hydatid cysts: a surgical experience with 14 cases. *World J Emerg Surg* 2013; **8**: 28 [PMID: 23885766 DOI: 10.1186/1749-7922-8-28]
 - 10 Malik AA, Bari SU, Amin R, Jan M. Surgical management of complicated hydatid cysts of the liver. *World J Gastrointest Surg* 2010; **2**: 78-84 [PMID: 21160854 DOI: 10.4240/wjgs.v2.i3.78]
 - 11 Karakaya K. Spontaneous rupture of a hepatic hydatid cyst into the peritoneum causing only mild abdominal pain: a case report. *World J Gastroenterol* 2007; **13**: 806-808 [PMID: 17278209 DOI: 10.3748/wjg.v13.i5.806]
 - 12 Erel S, Kilicoglu B, Kismet K, Gollu A, Akkus MA. Peritoneal hydatid cyst perforation: a rare cause of emergency abdominal surgeries. *Adv Ther* 2008; **25**: 943-950 [PMID: 18758698 DOI: 10.1007/s12325-008-0088-9]
 - 13 Sakcak I, Erdogan A, Aydogan I, Ismail E, Doganay M, Akat Z. Long-term outcomes of ruptured intraperitoneal hydatid cysts. *J J Gastro Hepato* 2015; **2**: 18
 - 14 Ozturk S, Han I, Carti EB, Unver M, Ozturk BK, Kebapci E, Olmez M, Zalluhoglu N, Aydin C, Akbulut G. A Rare emergency intraperitoneal perforation of liver hydatid cysts. clinical presentation and surgical outcomes of double center experience. *J Surg Arts (Cer San D)* 2016; **2**: 61-66
 - 15 Ozturk G, Aydinli B, Yildirman MI, Basoglu M, Atamanalp SS, Polat KY, Alper F, Guvendi B, Akcay MN, Oren D. Posttraumatic free intraperitoneal rupture of liver cystic echinococcosis: a case series and review of literature. *Am J Surg* 2007; **194**: 313-316 [PMID: 17693274 DOI: 10.1016/j.amjsurg.2006.11.014]
 - 16 Derici H, Tansug T, Reyhan E, Bozdog AD, Nazli O. Acute intraperitoneal rupture of hydatid cysts. *World J Surg* 2006; **30**: 1879-1883 [PMID: 16847712 DOI: 10.1007/s00268-005-0699-0]
 - 17 Kurt N, Oncel M, Gulmez S, Ozkan Z, Uzun H. Spontaneous and traumatic intra-peritoneal perforations of hepatic hydatid cysts: a case series. *J Gastrointest Surg* 2003; **7**: 635-641 [PMID: 12850676 DOI: 10.1016/S1091-255X(02)00434-1]
 - 18 Akcan A, Sozuer E, Akyildiz H, Ozturk A, Atalay A, Yilmaz Z. Predisposing factors and surgical outcome of complicated liver hydatid cysts. *World J Gastroenterol* 2010; **16**: 3040-3048 [PMID: 20572308 DOI: 10.3748/wjg.v16.i24.3040]
 - 19 Bozdog Z, Turkoglu A, Yilmaz EE, Gul M. A rare reason for acute abdomen: Intraperitoneal liver hydatid cyst rupture. *Dig Liver Dis* 2016; **48**: 98-100 [PMID: 26598445 DOI: 10.1016/j.dld.2015.10.009]
 - 20 Dirican A, Yilmaz M, Unal B, Tatli F, Piskin T, Kayaalp C. Ruptured Hydatid Cysts into the peritoneum: A case series. *Eur J Trauma Emerg Surg* 2010; **36**: 375-379 [PMID: 26816043 DOI: 10.1007/s00068-009-9056-6]
 - 21 Rami M, Khattala K, Mahmoudi A, El Madi A. Ruptured hepatic hydatid cyst: Report of four cases. *Ann Pediatr Surg* 2009; **5**: 146-149
 - 22 Gunay K, Taviloglu K, Berber E, Ertekin C. Traumatic rupture of hydatid cysts: a 12-year experience from an endemic region. *J Trauma* 1999; **46**: 164-167 [PMID: 9932701]

Persistent elevation of fibrosis biomarker cartilage oligomeric matrix protein following hepatitis C virus eradication

Kristofer Andréasson, Göran Jönsson, Roger Hesselstrand, Hans Norrgren

ORCID number: Kristofer Andréasson (0000-0001-7021-2541); Göran Jönsson (0000-0002-4436-7977); Roger Hesselstrand (0000-0001-6794-2201); Hans Norrgren (0000-0001-5780-530X).

Author contributions: Andréasson K, Jönsson G, Hesselstrand R and Norrgren H designed the study and wrote this letter; Norrgren H is in charge of the patients and performed the Fibroscan analyses; Andréasson K made the statistical analyses.

Supported by: Bengt Ihre Foundation, No. SLS-594-301 and SLS-789091.

Conflict-of-interest statement: The authors declare that they do not have anything to disclose regarding funding or conflict of interest with respect to this manuscript.

Open-Access: This article is an open-access article which was selected by an in-house editor and fully peer-reviewed by external reviewers. It is distributed in accordance with the Creative Commons Attribution Non Commercial (CC BY-NC 4.0) license, which permits others to distribute, remix, adapt, build upon this work non-commercially, and license their derivative works on different terms, provided the original work is properly cited and the use is non-commercial. See: <http://creativecommons.org/licenses/by-nc/4.0/>

Manuscript source: Invited manuscript

Kristofer Andréasson, Roger Hesselstrand, Section of Rheumatology, Department of Clinical Sciences Lund, Lund University, Lund S-221 85, Sweden

Göran Jönsson, Hans Norrgren, Section of Infectious Diseases, Department of Clinical Sciences Lund, Lund University, Lund S-221 85, Sweden

Corresponding author: Kristofer Andréasson, MD, PhD, Reader (Associate Professor), Section of Rheumatology, Department of Clinical Sciences Lund, Lund University, Kioskgatan 3, Lund S-221 85, Sweden. kristofer.andreason@med.lu.se
Telephone: +46-46-171000
Fax: +46-46-128468

Abstract

Serum levels of cartilage oligomeric matrix protein (COMP) has been presented as a biomarker of liver fibrosis in several cross-sectional studies. COMP is also an essential mediator in carcinoma development and has also been associated with hepatocellular carcinoma. We present a prospective analysis of this biomarker in 38 patients with chronic hepatitis C who were subject to eradication therapy with direct acting antivirals. We confirm previous studies associating COMP elevation with liver cirrhosis. We also show how viral levels are correlated with COMP at baseline. In our prospective analysis, we report that successful eradication of hepatitis C results in improvement in liver stiffness and laboratory liver function tests at 1 year follow-up. In contrast, median COMP-levels remain unchanged during the study period. We conclude that the biomarker potential of COMP in the prospective evaluation of liver diseases, remains to be elucidated.

Key words: Hepatitis C; Chronic; Cartilage oligomeric matrix protein; Fibrosis

©The Author(s) 2019. Published by Baishideng Publishing Group Inc. All rights reserved.

Core tip: Cartilage oligomeric matrix protein (COMP) is a biomarker of fibrosis that has recently been introduced in the field of hepatology. COMP has also been associated with tumor development. This is the first prospective study of COMP in chronic liver disease. We confirm previous findings, relating S-COMP to liver cirrhosis. Eradication of hepatitis C was associated with improvements of liver function test and liver elasticity. In contrast, and unexpectedly, S-COMP remained unchanged in this cohort. We argue that the biomarker potential of COMP in chronic liver diseases needs further exploration, especially in reference to carcinoma development.

Received: January 13, 2019**Peer-review started:** January 14, 2019**First decision:** February 22, 2019**Revised:** February 27, 2019**Accepted:** March 16, 2019**Article in press:** March 16, 2019**Published online:** March 27, 2019**P-Reviewer:** Ferraioli G, Mizuguchi T, Zampino R, Zhu Y**S-Editor:** Cui LJ**L-Editor:** A**E-Editor:** Zhang YL**Citation:** Andréasson K, Jönsson G, Hesselstrand R, Norrgren H. Persistent elevation of fibrosis biomarker cartilage oligomeric matrix protein following hepatitis C virus eradication. *World J Hepatol* 2019; 11(3): 330-334**URL:** <https://www.wjgnet.com/1948-5182/full/v11/i3/330.htm>**DOI:** <https://dx.doi.org/10.4254/wjh.v11.i3.330>

TO THE EDITOR

Chronic hepatitis C (CHC) is a widespread disease caused by infection with hepatitis C virus (HCV). It is associated with significant mortality and morbidity due to liver cirrhosis, liver decompensation and hepatocellular carcinoma (HCC). During the last decade, direct acting antiviral agents (DAA) have been introduced for the eradication of HCV infection. These treatments are usually successful in eradication of the virus, resulting in sustained virologic response (SVR) in over 90% of the cases^[1]. SVR have been associated with improvements in liver stiffness and biomarkers of CHC, including fibrosis specific biomarkers such as hyaluronic acid and type IV collagen^[2], suggesting reversal of CHC induced inflammation and fibrosis.

Cartilage oligomeric matrix protein (COMP) is a pentameric molecule first identified in cartilage and later characterised in fibrotized tissues in tendons, skin and lung. It is readily measurable in serum with a commercially available ELISA. Increased levels have been associated with arthritis and fibrotic states including systemic sclerosis, wound healing, and Crohn's disease^[3,4]. COMP has also been associated with malignancies including breast, prostate and HCC^[5-7]. In *World Journal of Hepatology*, in 2015, Norman *et al*^[8] published the first report suggesting that S-COMP has biomarker potential in chronic liver diseases. S-COMP was associated with both cirrhosis and HCC development. They concluded that "The present exploratory study has provided intriguing results and may assist enhanced management of hepatic fibrosis, in particular the assessment of regression or progression of fibrosis before and after specific therapeutic treatments". In independent cross-sectional studies, we and others have confirmed that S-COMP is associated with fibrosis stage based on liver biopsy and liver elastography in CHC^[8-10]. These findings have been corroborated by experimental studies of liver fibrosis in which COMP originating from hepatocytes was essential for fibrosis development^[11].

In order to further explore the biomarker potential of S-COMP in liver fibrosis, we have conducted the first prospective study aimed to investigate the biomarker potential of S-COMP following successful therapy of CHC with DAA.

Consecutive patients with CHC infection eligible for antiviral therapy between August 2015 and April 2017 at the Infectious Clinic, Skåne University Hospital Lund, were included in this study. Patients with concomitant rheumatic disease, organ transplant recipients and patients with documented alcohol abuse were excluded.

Serum levels of COMP were measured with ELISA (Anamar, United Kingdom), together with aspartate aminotransferase (AST) and platelet levels at baseline, after 4 weeks of treatment, at end of treatment and 1-2 year post-treatment follow-up. Viral genotype and HCV-RNA levels before treatment start were noted. Liver stiffness was measured by transient elastography (TE) at baseline and at 1-2 years post-treatment follow-up. Liver cirrhosis was defined as TE > 12.5 kPa. Non-parametric statistics were consequently used including Wilcoxon signed rank test when comparing repeated measurements within the cohort, and median [interquartile range (IQR)] for descriptive measures. Figures were made with BoxPlotR^[12]. The study was approved by the Regional Ethics Board Lund (2017-471) and conducted in accordance with the declaration of Helsinki. All study participants gave informed consent.

This study comprised 38 subjects with CHC who were infected with the following viral subtypes; subtype 1 ($n = 24$), subtype 2 ($n = 3$), subtype 3 ($n = 11$). All received DAA including sofosbuvir ($n = 37$), ledipasvir ($n = 25$), ribavirin ($n = 7$), daclatasvir ($n = 5$), velpatasvir ($n = 1$), elbasvir ($n = 1$) and grazoprevir ($n = 1$). Baseline median (IQR) age, viral levels and liver stiffness were 58 (43-63) years, 2.0×10^6 (9.7×10^5 - 4.7×10^6) and 8.3 (6.9-11.1) kPa, respectively.

Six patients had a TE measurement indicating liver cirrhosis at baseline. These subjects had higher AST to platelet ratio index (APRI)-scores and S-COMP levels compared to the other patients (0.91 *vs* 0.55; $P = 0.008$ and 13 *vs* 9 U/L; $P = 0.036$, respectively). Median (IQR) treatment duration was 84 (60-95) days, and all study participants reached SVR. TE was performed at baseline and at follow up, 517 (468-639) days later. Liver stiffness decreased significantly during this period (from 8.3

(6.9–11.1) to 5.4 (4.4–6.6) kPa; $P < 0.001$; **Figure 1A**). Also, APRI decreased significantly, from 0.62 to 0.29; $P < 0.001$, **Figure 1B**. In contrast, S-COMP levels did not decrease from baseline 9.5 (8.0–13) versus 10.5 (9.8–13) U/L at follow up; $P = 0.14$. Similar levels of S-COMP were measured at 4 wk of treatment 9.0 (8.0–12) and at end of treatment 10 (6.8–12) U/L (**Figure 1C**). Furthermore, change in S-COMP over time was not associated with any disease characteristics (data not shown).

There was a significant relationship between baseline S-COMP and viral levels ($r_s = 0.45$, $P = 0.005$) at baseline. In contrast, there was no association between viral levels and liver stiffness or APRI at baseline. Baseline S-COMP was not associated with virus subtype, body mass index, and it was unable to predict change in liver stiffness (data not shown).

One patient developed HCC prior to the inclusion in this study. This patient had an estimated liver elasticity of 6.1 and liver function tests within reference range. This patient exhibited the highest (21 U/L) level of S-COMP in this study.

As previously described in this journal, we show that S-COMP is associated with liver cirrhosis. We also show that S-COMP correlates to viral levels in serum, an established risk factor for HCC development, which to our knowledge have not previously been described. In this prospective study, we also report how DAA induced SVR is associated with improvements in liver function as measured by TE and APRI, which is in agreement with previous studies. In contrast however, S-COMP remained unchanged during the study period.

Magdaleno *et al*^[11] have in detail explored the significance of COMP in the hepatocyte pathology of liver fibrosis, ultimately suggesting that COMP is a mediator of inflammation and fibrosis originating from the hepatocytes. In other diseases, S-COMP has been suggested to reflect a mixture of both synthesis and degradation of extracellular matrix^[3,4]. In malignant and premalignant diseases, COMP expression has been associated with tumor invasiveness. We suggest that the origin of elevated S-COMP in CHC to be multifactorial. The results from this study indicate that the biomarker potential of COMP in the longitudinal follow up of chronic liver diseases is yet to be determined. Further studies encompassing a larger number of patients are needed. In such studies, S-COMP should ideally be compared with other fibrotic biomarkers such as hyaluronic acid. Compared to currently available biomarkers of CHC, COMP correlates poorly with other surrogates of disease severity following DAA induced SVR. This finding does however not invalidate COMP's potential as a biomarker for HCC, as previously suggested in this journal^[7].

In conclusion, our study indicates that this biomarker's dynamics in the context of CHC and possibly also other chronic liver diseases, must be further explored if S-COMP is to be used in a prospective clinical setting^[13]. The role of S-COMP in relation to chronic liver disease and the risk of HCC development needs further investigation.

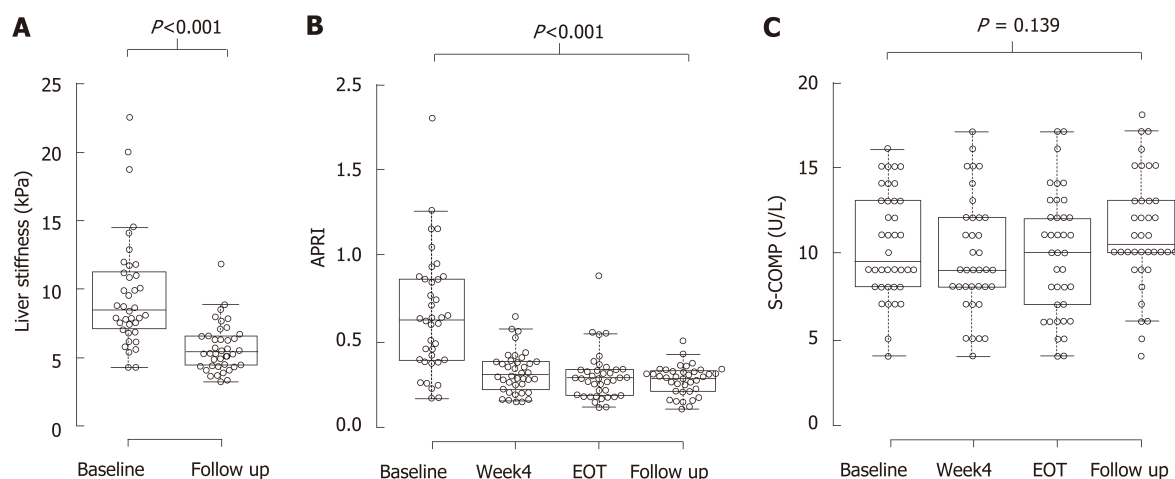


Figure 1 Direct acting antiviral agents-induced sustain viral response is associated with improvements in liver stiffness, aspartate aminotransferase platelet ratio index but not in S-cartilage oligomeric matrix protein. Box-plots on measurements of liver stiffness (A), aspartate aminotransferase platelet ratio index (B) and S-cartilage oligomeric matrix protein (C), made at baseline (A-C), 4 wk of treatment (B and C), at end of treatment (B and C) and at 1-2 years follow up (A-C). Center lines show the medians; box limits indicate the 25th and 75th percentiles as determined by R software^[12]; whiskers extend 1.5 times the interquartile range from the 25th and 75th percentiles, outliers are represented by dots; data points are plotted as open circles. $n = 38$ for all measurements. APRI: Aspartate aminotransferase platelet ratio index; COMP: Cartilage oligomeric matrix protein; EOT: End of treatment.

ACKNOWLEDGEMENTS

We appreciate the help of head nurse Ann Åkesson in organizing this study. We appreciate advice from professor Tore Saxne when planning and conducting this study. We appreciate the collaboration with Martin Olsson on conducting the COMP-analyses.

REFERENCES

- 1 Vermehren J, Park JS, Jacobson IM, Zeuzem S. Challenges and perspectives of direct antivirals for the treatment of hepatitis C virus infection. *J Hepatol* 2018; **69**: 1178-1187 [PMID: 30006068 DOI: 10.1016/j.jhep.2018.07.002]
- 2 Miyaki E, Imamura M, Hiraga N, Murakami E, Kawaoka T, Tsuge M, Hiramatsu A, Kawakami Y, Aikata H, Hayes CN, Chayama K. Daclatasvir and asunaprevir treatment improves liver function parameters and reduces liver fibrosis markers in chronic hepatitis C patients. *Hepatol Res* 2016; **46**: 758-764 [PMID: 26574180 DOI: 10.1111/hepr.12621]
- 3 Crnkic M, Månsson B, Larsson L, Geborek P, Heinegård D, Saxne T. Serum cartilage oligomeric matrix protein (COMP) decreases in rheumatoid arthritis patients treated with infliximab or etanercept. *Arthritis Res Ther* 2003; **5**: R181-R185 [PMID: 12823852 DOI: 10.1186/ar760]
- 4 Li M, Lu S, Liu X, Zhao J, Zhang H, Ling C. [Expression of endoglin in human non-small cell lung cancer and its clinical significance]. *Xi Bao Yu Fen Zi Mian Yi Xue Za Zhi* 2013; **29**: 581-584 [PMID: 23746240 DOI: 10.1242/jcs.180216]
- 5 Norman GL, Gatselis NK, Shums Z, Liaskos C, Bogdanos DP, Koukoulis GK, Dalekos GN. Cartilage oligomeric matrix protein: A novel non-invasive marker for assessing cirrhosis and risk of hepatocellular carcinoma. *World J Hepatol* 2015; **7**: 1875-1883 [PMID: 26207169 DOI: 10.4254/wjh.v7.i14.1875]
- 6 Xiao Y, Kleeff J, Guo J, Gazdhar A, Liao Q, Di Cesare PE, Büchler MW, Friess H. Cartilage oligomeric matrix protein expression in hepatocellular carcinoma and the cirrhotic liver. *J Gastroenterol Hepatol* 2004; **19**: 296-302 [PMID: 14748877 DOI: 10.1111/j.1440-1746.2003.03268.x]
- 7 Englund E, Bartoschek M, Reitsma B, Jacobsson L, Escudero-Esparza A, Orimo A, Leandersson K, Hagerling C, Aspberg A, Storm P, Okroj M, Mulder H, Jirstrom K, Pietras K, Blom AM. Cartilage oligomeric matrix protein contributes to the development and metastasis of breast cancer. *Oncogene* 2016; **35**: 5585-5596 [PMID: 27065333 DOI: 10.1038/onc.2016.98]
- 8 Zachou K, Gabeta S, Shums Z, Gatselis NK, Koukoulis GK, Norman GL, Dalekos GN. COMP serum levels: A new non-invasive biomarker of liver fibrosis in patients with chronic viral hepatitis. *Eur J Intern Med* 2017; **38**: 83-88 [PMID: 28100410 DOI: 10.1016/j.ejim.2017.01.007]
- 9 Andréasson K, Hesselstrand R, Saxne T, Holmberg A, Norrgren H, Jönsson G. Cartilage oligomeric matrix protein: a new promising biomarker of liver fibrosis in chronic hepatitis C. *Infect Dis (Lond)* 2015; **47**: 915-918 [PMID: 26269256 DOI: 10.3109/23744235.2015.1075659]
- 10 Andréasson K, Waldenström J, Westin J, Norrgren H, Jönsson G, Nyström K, Lagging M. Cartilage oligomeric matrix protein associates with hepatic inflammation and fibrosis in hepatitis C virus infection. *J Hepatol* 2017; **67**: 649-651 [PMID: 28527663 DOI: 10.1016/j.jhep.2017.03.043]
- 11 Magdaleno F, Arriazu E, Ruiz de Galarreta M, Chen Y, Ge X, Conde de la Rosa L, Nieto N. Cartilage oligomeric matrix protein participates in the pathogenesis of liver fibrosis. *J Hepatol* 2016; **65**: 963-971 [PMID: 27318326 DOI: 10.1016/j.jhep.2016.06.003]

- 12 **Spitzer M**, Wildenhain J, Rappsilber J, Tyers M. BoxPlotR: a web tool for generation of box plots. *Nat Methods* 2014; **11**: 121-122 [PMID: [24481215](#) DOI: [10.1038/nmeth.2811](#)]
- 13 **Huang R**, Xia J, Yan X, Liu Y, Wu C. Serum cartilage oligomeric matrix protein levels as a novel non-invasive biomarker for liver fibrosis in patients with chronic viral hepatitis? It is too early. *Eur J Intern Med* 2017; **42**: e24 [PMID: [28427803](#) DOI: [10.1016/j.ejim.2017.04.009](#)]



Published By Baishideng Publishing Group Inc
7041 Koll Center Parkway, Suite 160, Pleasanton, CA 94566, USA
Telephone: +1-925-2238242
Fax: +1-925-2238243
E-mail: bpgoffice@wjgnet.com
Help Desk: <https://www.f6publishing.com/helpdesk>
<https://www.wjgnet.com>

