

World Journal of *Hepatology*

World J Hepatol 2019 May 27; 11(5): 412-488



**OPINION REVIEW**

- 412** Roles of hepatic stellate cells in acute liver failure: From the perspective of inflammation and fibrosis
Li J, Zhao YR, Tian Z

REVIEW

- 421** Hepatitis C virus cure with direct acting antivirals: Clinical, economic, societal and patient value for China
Xie Q, Xuan JW, Tang H, Ye XG, Xu P, Lee IH, Hu SL

ORIGINAL ARTICLE**Basic Study**

- 442** Hepatitis C virus antigens enzyme immunoassay for one-step diagnosis of hepatitis C virus coinfection in human immunodeficiency virus infected individuals
Hu KQ, Cui W, Rouster SD, Sherman KE

SYSTEMATIC REVIEW

- 450** Expanding etiology of progressive familial intrahepatic cholestasis
Henkel SA, Squires JH, Ayers M, Ganoza A, Mckiernan P, Squires JE

META-ANALYSIS

- 464** Carvedilol *vs* endoscopic variceal ligation for primary and secondary prevention of variceal bleeding: Systematic review and meta-analysis
Dwinata M, Putera DD, Adda'i MF, Hidayat PN, Hasan I

CASE REPORT

- 477** Neonatal cholestasis and hepatosplenomegaly caused by congenital dyserythropoietic anemia type 1: A case report
Jaramillo C, Ermarth AK, Putnam AR, Deneau M
- 483** Successful treatment of noncirrhotic portal hypertension with eculizumab in paroxysmal nocturnal hemoglobinuria: A case report
Alexopoulou A, Mani I, Tiniakos DG, Kontopidou F, Tsironi I, Noutsou M, Pantelidaki H, Dourakis SP

ABOUT COVER

Associate Editor of *World Journal of Hepatology*, Yeong Yeh Lee, FACC, FACP, FRCP (C), MD, PhD, Doctor, Professor, Department of Medicine, School of Medical Sciences, Universiti Sains Malaysia, Kota Bahru 16150, Kelantan, Malaysia

AIMS AND SCOPE

World Journal of Hepatology (*World J Hepatol*, *WJH*, online ISSN 1948-5182, DOI: 10.4254), is a peer-reviewed open access academic journal that aims to guide clinical practice and improve diagnostic and therapeutic skills of clinicians.

The *WJH* covers topics concerning liver biology/pathology, cirrhosis and its complications, liver fibrosis, liver failure, portal hypertension, hepatitis B and C and inflammatory disorders, steatohepatitis and metabolic liver disease, hepatocellular carcinoma, etc. Priority publication will be given to articles concerning diagnosis and treatment of hepatology diseases. The following aspects are covered: Clinical diagnosis, laboratory diagnosis, etc.

We encourage authors to submit their manuscripts to *WJH*. We will give priority to manuscripts that are supported by major national and international foundations and those that are of great basic and clinical significance.

INDEXING/ABSTRACTING

The *WJH* is now abstracted and indexed in PubMed, PubMed Central, Emerging Sources Citation Index (Web of Science), Scopus, China National Knowledge Infrastructure (CNKI), China Science and Technology Journal Database (CSTJ), and Superstar Journals Database.

RESPONSIBLE EDITORS FOR THIS ISSUE

Responsible Electronic Editor: Yan-Liang Zhang Proofing Editorial Office Director: Ya-Juan Ma

NAME OF JOURNAL

World Journal of Hepatology

ISSN

ISSN 1948-5182 (online)

LAUNCH DATE

October 31, 2009

FREQUENCY

Monthly

EDITORS-IN-CHIEF

Ke-Qin Hu, Koo Jeong Kang, Nikolaos T Prysopoulos

EDITORIAL BOARD MEMBERS

<https://www.wjnet.com/1948-5182/editorialboard.htm>

EDITORIAL OFFICE

Ya-Juan Ma, Director

PUBLICATION DATE

May 27, 2019

COPYRIGHT

© 2019 Baishideng Publishing Group Inc

INSTRUCTIONS TO AUTHORS

<https://www.wjnet.com/bpg/gerinfo/204>

GUIDELINES FOR ETHICS DOCUMENTS

<https://www.wjnet.com/bpg/GerInfo/287>

GUIDELINES FOR NON-NATIVE SPEAKERS OF ENGLISH

<https://www.wjnet.com/bpg/gerinfo/240>

PUBLICATION MISCONDUCT

<https://www.wjnet.com/bpg/gerinfo/208>

ARTICLE PROCESSING CHARGE

<https://www.wjnet.com/bpg/gerinfo/242>

STEPS FOR SUBMITTING MANUSCRIPTS

<https://www.wjnet.com/bpg/GerInfo/239>

ONLINE SUBMISSION

<https://www.f6publishing.com>



Roles of hepatic stellate cells in acute liver failure: From the perspective of inflammation and fibrosis

Juan Li, Ying-Ren Zhao, Zhen Tian

ORCID number: Juan Li (0000-0002-8246-9798); Ying-Ren Zhao (0000-0001-6020-7028); Zhen Tian (0000-0001-7475-9472).

Author contributions: Li J contributed to literature search, manuscript drafting and final revision of the article; Zhao YR contributed to figure drawing and final revision of the article; Tian Z contributed to the study idea and design, manuscript drafting and final revision of the article.

Supported by: National Natural Science Foundation, No. 81800548.

Conflict-of-interest statement: No potential conflicts of interest relevant to this article were reported.

Open-Access: This is an open-access article that was selected by an in-house editor and fully peer-reviewed by external reviewers. It is distributed in accordance with the Creative Commons Attribution Non Commercial (CC BY-NC 4.0) license, which permits others to distribute, remix, adapt, build upon this work non-commercially, and license their derivative works on different terms, provided the original work is properly cited and the use is non-commercial. See: <http://creativecommons.org/licenses/by-nc/4.0/>

Manuscript source: Invited Manuscript

Received: February 23, 2019

Peer-review started: February 25, 2019

First decision: April 22, 2019

Revised: May 14, 2019

Juan Li, Ying-Ren Zhao, Zhen Tian, Department of Infectious Diseases, Institute of Hepatology, the First Affiliated Hospital of Xi'an Jiaotong University, Xi'an 710061, Shaanxi Province, China

Corresponding author: Zhen Tian, MD, PhD, Doctor, Department of Infectious Diseases, Institute of Hepatology, the First Affiliated Hospital of Xi'an Jiaotong University, No. 277 Yanta Road (w), Xi'an 710061, Shaanxi Province, China. tianzen1984@163.com

Telephone: +86-29-85323634

Fax: +86-29-85323634

Abstract

Acute liver failure (ALF) usually results in hepatocellular dysfunction and coagulopathy and carries a high mortality rate. Hepatic stellate cells (HSCs) are famous for their role in liver fibrosis. Although some recent studies revealed that HSCs might participate in the pathogenesis of ALF, the accurate mechanism is still not fully understood. This review focuses on the recent advances in understanding the functions of HSCs in ALF and revealed both protective and promotive roles during the pathogenesis of ALF: HSC activation participates in the maintenance of cell attachment and the architecture of liver tissue *via* extracellular matrix production and assists liver regeneration by producing growth factors; and HSC inflammation plays a role in relaying inflammation signaling from sinusoids to parenchyma *via* secretion of inflammatory cytokines. A better understanding of roles of HSCs in the pathogenesis of ALF may lead to improvements and novel strategies for treating ALF patients.

Key words: Acute liver failure; Hepatic stellate cells; Inflammation; Fibrosis

©The Author(s) 2019. Published by Baishideng Publishing Group Inc. All rights reserved.

Core tip: Acute liver failure (ALF) is a rare life-threatening disease with a high mortality rate and is characterized by massive hepatocyte death and overactivation of hepatic inflammation. Hepatic stellate cells (HSCs) play both protective and promotive roles during the pathogenesis of ALF: HSC activation participates in the maintenance of cell attachment and the architecture of liver tissue *via* extracellular matrix production and assists liver regeneration by producing growth factors; and HSC inflammation plays a role in relaying inflammation signaling from sinusoids to parenchyma *via* secretion of inflammatory cytokines. A better understanding of roles of HSCs in ALF will lead to improvements for treating ALF patients.

Accepted: May 21, 2019
Article in press: May 21, 2019
Published online: May 27, 2019

P-Reviewer: Alexopoulou A,
 Garbuzenko DV
S-Editor: Cui LJ
L-Editor: Filipodia
E-Editor: Zhang YL



Citation: Li J, Zhao YR, Tian Z. Roles of hepatic stellate cells in acute liver failure: From the perspective of inflammation and fibrosis. *World J Hepatol* 2019; 11(5): 412-420
URL: <https://www.wjgnet.com/1948-5182/full/v11/i5/412.htm>
DOI: <https://dx.doi.org/10.4254/wjh.v11.i5.412>

INTRODUCTION

Liver failure, including acute, chronic and acute-on-chronic liver failure, is a rare but dramatic clinical syndrome characterized by massive hepatocyte death and overactivation of hepatic inflammation^[1]. Acute liver failure (ALF), characterized by a rapid deterioration of liver function without pre-existing liver disease, usually results in hepatocellular dysfunction and coagulopathy and carries a high mortality rate. The main causes of ALF include viral hepatitis, ischemia and drug-induced toxicity^[2]. Currently, ALF continues to be a huge therapeutic challenge and apart from liver transplantation, few effective therapies are available.

Hepatic stellate cells (HSCs) are resident mesenchymal cells that have features of resident fibroblasts and pericytes and account for 15% of total resident cells in the normal human liver. HSCs are one of the key nonparenchymal components in the sinusoid with multiple functions in the liver and are known for their roles in fibrosis^[3]. Under physiological conditions, HSCs exhibit a quiescent state and contain numerous vitamin A lipid droplets. Upon liver injury, HSCs lose lipid-rich granules and transdifferentiate into active myofibroblast-like cells characterized by the expression of α -SMA, production of extracellular matrix (ECM) and release of cytokines^[4]. Although the involvement of HSCs in liver fibrosis is well recognized, few studies have examined their roles in ALF. Some recent studies have indicated that the blockade of fibrosis by depleting activated HSCs in an acetaminophen (APAP)-induced mouse ALF model resulted in significantly more severe liver damage and a lower survival rate^[5]. However, due to the dramatic clinical course of ALF, the role of HSC activation in the process of ALF is still unclear.

HSCs comprise approximately one-third of nonparenchymal cells and constitute the liver sinusoid together with sinusoidal endothelial cells and Kupffer cells (KCs). Upon stimulation by the gut microbiota and microbial byproducts in septic liver injury, KCs and sinusoidal endothelial cells produce inflammatory cytokines in the sinusoidal lumen and serve as the first gate against inflammatory stimuli in the portal circulation^[6]. Although the role of HSC activation in liver fibrosis has been widely accepted and attracts much attention, whether and how HSCs participate in hepatic inflammation have not been examined. Anatomically, HSCs seem to respond to inflammatory stimuli from the sinusoids. Recent studies have revealed that activated HSCs may release inflammatory cytokines such as interleukin (IL)-1 β and IL-18. HSCs from both humans and rodents produce inflammatory cytokines promoting hepatocellular carcinoma and immune-mediated hepatitis^[7-9]. However, how HSCs participate in hepatic inflammation, and whether and how HSC inflammation is involved in the pathogenesis of ALF are still unknown (Figure 1).

PATHOGENESIS OF ALF

To date, ALF remains a life-threatening syndrome with a high mortality rate, and is characterized by massive hepatocyte death and overactivation of hepatic inflammation.

Cell death and regeneration in ALF

Hepatocyte injury and subsequent cell death are important during the pathogenesis of ALF^[10]. Two different types of programmed cell death are thought to be involved in this process, including apoptosis and necrosis. Apoptosis is defined by chromatin condensation, nuclear fragmentation, cell shrinkage, blebbing of the plasma membrane, and the formation of apoptotic bodies that contain nuclear or cytoplasmic material; and necrosis, which is an alternative to apoptotic cell death and is considered to be a toxic process with the characteristics of cytoplasmic swelling, dilation of organelles, and mechanical rupture of the plasma membrane^[11]. The relative contribution of apoptosis and necrosis during liver failure remains controversial. Studies have shown that a variety of injurious stimuli induce apoptosis at low dose while the same stimuli may result in necrosis at higher dose. The etiology

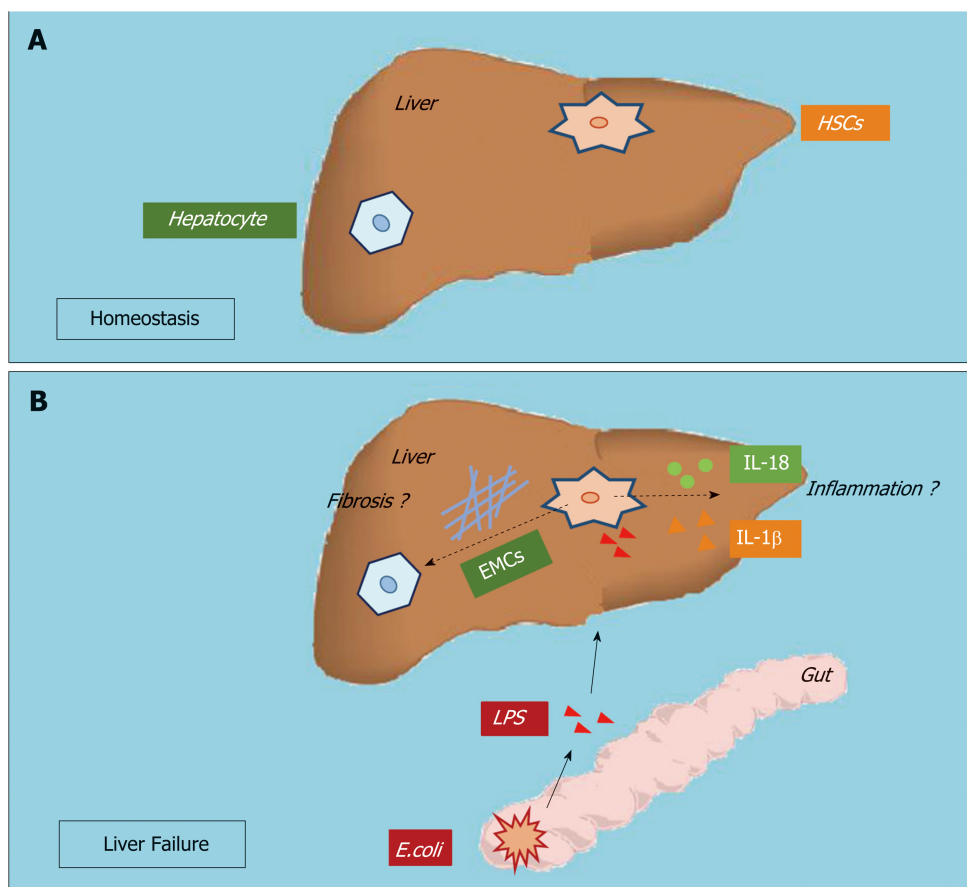


Figure 1 Hepatic stellate cell activation and inflammation participate in acute liver failure. A: At homeostasis; B: During acute liver failure, the roles of hepatic stellate cell activation and inflammation remain unclear.

may also alter the type of cell death in ALF: necrosis is considered a prominent death pathway of hepatocytes in drug-induced ALF, and apoptosis is always found in viral- and toxin-mediated liver failure^[12,13].

Clinicians have observed that some ALF patients may recover spontaneously and the clinical outcomes largely depend on the balance between hepatocyte loss and regeneration^[14]. Under mild conditions, lost cells can quickly be replaced by neighboring healthy hepatocytes *via* replication in an attempt to restore hepatic architecture and function. However, the regenerative capacity of the remaining hepatocytes may not be sufficient upon extensive injury and massive hepatocyte death, and the resident liver progenitor cells (LPCs) are then activated to take over the role of hepatocytes in hepatic regeneration^[15]. However, for many liver failure patients, even the regenerative process by LPCs is inadequate to match the rapid process of hepatocyte death and dramatic deterioration in liver function, which means that apart from liver transplantation, few effective therapies exist^[16]. To date, the mechanisms promoting hepatic cell death and the processes mediating liver regeneration are not fully understood.

Hepatic inflammation in ALF

Overactivation of hepatic inflammation is another important characteristic of ALF. Clinically, ALF shares many features with severe sepsis, including a systemic inflammatory response and progression to multi-organ failure^[17]. Patients with ALF often present with endotoxemia and increased serum lipopolysaccharide (LPS) levels due to increased gut permeability^[18]. LPS can cause the release of a wide variety of inflammatory mediators and contribute to the pathogenesis of various diseases, including ALF. Studies have also found elevated plasma inflammatory cytokines, such as IL-1β, IL-6, IL-8 and tumor necrosis factor (TNF)-α, in ALF patients^[19]. Moreover, approximately 60% of ALF patients fulfill the criteria for systemic inflammatory syndrome irrespective of the presence or absence of infection^[20]. Inflammasome activation serves as a double-edged sword, which contributes to both the protective antimicrobial response and cell death when excessively active during the pathogenesis of various diseases^[21]. Inflammation is a common element in the

pathogenesis of most liver diseases. ALF is now known as an inflammation-mediated hepatocellular injury process. During the disease process of ALF, inflammation first participates in the initiation and amplification steps leading to cell injury and hepatocyte death; these injured/dead hepatocytes then release damage-associated molecular patterns that can drive inflammasome activation, directly perpetuate further cell death, and mediate additional organ failure forming a vicious circle. Studies have shown that inhibition of hepatic inflammation can successfully delay/prevent the progression of ALF^[22,23]. However, the mechanisms promoting hepatic inflammation during ALF are still not fully understood.

LIVER FAILURE AND HSC ACTIVATION

Hepatic fibrosis and HSCs in ALF

Liver fibrosis is a highly conserved and coordinated wound-healing process aimed at maintaining organ integrity, which results from acute or chronic liver injury and is always associated with excess hepatocellular death^[24]. Chronic liver injury always accompanies progressive hepatocyte apoptosis and subsequent liver fibrogenesis. In chronic liver injury, fibrosis is widely acknowledged as a damaging process, which results in cirrhosis, portal hypertension and liver cancer^[25]. ALF is associated with massive short-term hepatocyte death by provoking excessive apoptosis and necrosis, and consequently, deterioration of liver function^[26]. When the disease is not fatal, the liver has a unique capacity to recover *via* proliferation and regeneration, and HSC activation has also been found to participate in the pathogenesis of ALF^[27]. However, data on the roles of fibrosis during the pathogenesis of ALF are still scarce.

HSC activation is the central step during liver fibrogenesis, and HSCs are known for their role in the initiation, progression and regression of hepatic fibrosis. A recent study has shown that fibrogenic cells, including HSCs and myofibroblasts, are activated early after acute/chronic liver injury to produce ECM components^[24]. The engulfment of hepatocyte-derived apoptotic bodies formed during liver failure was shown to promote the expression of fibrogenic genes in HSCs^[28]. Moreover, Dechêne *et al*^[29] found that ALF was accompanied by active hepatic fibrogenesis and revealed a positive correlation between liver stiffness, hepatocyte death and HSC activation, which suggests that fibrosis is an attempt to repair liver damage responding to ALF. Besides, a decrease of liver stiffness in the remission stage of the disease was also found in these ALF patients. Our previous data indicated that this short-term occurrence of fibrosis during the progression stage of ALF is a potentially beneficial response by the liver and serves as a scaffold to support the parenchyma and maintain hepatic integrity^[30]. Thus, liver fibrosis may play a protective role during ALF.

Clinical data have revealed that patients with chronic liver disease are not sensitive to the deleterious effects of toxic compounds due to elevated levels of fibrosis: patients with long-term elevated liver enzyme levels are less sensitive to the hepatotoxicity of statins^[31], and patients with chronic liver disease have shown increased tolerance to APAP compared to healthy individuals^[32]. Moreover, in experimental mouse models, Osawa *et al*^[33] showed that mice with bile duct-ligated-induced fibrosis were more resistant to the lethal effect of Fas. Acute and chronic injury can both induce HSC activation and subsequent ECM accumulation. In the pathogenesis of ALF, ECM has been shown to protect hepatocytes from death through the maintenance of cell attachment and the architecture of liver tissue^[30]. However, the mechanism by which ECM participates in protecting hepatocytes from death remains complex. In a recent study, collagen 1, the most abundant form of collagen in both normal and pathologic livers, has been shown to increase resistance to various injurious stimuli and protect hepatocytes from apoptotic or necrotic death *via* activation of the ERK1/2-MAPK signaling pathway^[27]. In addition, some adaptor molecules such as the integrins, focal adhesion kinase, integrin-like kinase, PINCH and others are also likely to contribute to hepatocyte survival^[34]. Matrix metalloproteinases are a family of proteinases that are capable of degrading all ECM proteins. A recent study revealed that IL-1 β induced the production of matrix metalloproteinases during liver failure, which provoked the collapse of sinusoids *via* ECM degradation and led to parenchymal cell death and loss of liver function in response to hepatic toxins^[35]. Taken together, HSC activation leads to hepatic fibrosis, which participates in the maintenance of cell attachment and the architecture of liver tissue and protects hepatocytes from injurious stimuli *via* ECM production.

Hepatic regeneration and HSCs in ALF

The liver is the main site of drug detoxification. It is exposed to numerous chemicals

in the body that may induce cell injury or even death, and the ability for regeneration is of importance to maintain liver homeostasis^[36]. It is known that the key strategy for the treatment of ALF is to reduce hepatocyte death and stimulate hepatocyte regeneration. Liver regeneration is the process by which the liver is able to replace lost liver tissue *via* growth from the remaining tissue. Liver regeneration driven by epithelial cell (including hepatocytes and LPCs) proliferation is a highly controlled process regulated by a complex signaling network and has important implications for stimulating hepatic recovery and improving survival during liver failure^[12,37]. The induction of liver regeneration depends on cross-talk between epithelial cells and nonparenchymal cells, especially HSCs.

HSCs are liver-specific mesenchymal cells that play vital roles in promoting liver fibrosis and maintaining hepatic homeostasis. There is growing evidence to show that HSCs have a profound impact on the proliferation, differentiation and morphogenesis of other hepatic cell types during liver development and regeneration^[38]. HSCs are in direct contact with hepatocytes and LPCs, and their close anatomic relationship in the space of Disse suggests that HSCs are part of the local “stem cell niche” for hepatocytes and LPCs. Activated HSCs have been shown to assist liver regeneration by producing growth factors, which can modulate the proliferation of both hepatocytes and LPCs around them. Conditioned medium collected from HSCs at an early stage of liver regeneration in a 2-acetylaminofluorene/partial hepatectomy injury model was found to contain high levels of hepatic growth factor and epidermal growth factor, which target and act primarily on epithelial cells^[39]. These factors may directly enhance the proliferation of hepatocytes and LPCs. It has also been shown that early-activated HSC-derived paracrine factors can evoke an enhanced liver protective response in APAP-induced ALF in mice by promoting LPCs proliferation^[40]. In addition, depletion of activated HSCs has been shown to correlate with severe liver damage and abnormal liver regeneration in APAP-induced acute liver injury in mice^[5]. We hypothesize that HSCs may assist liver regeneration during liver failure by producing growth factors.

LIVER FAILURE AND HSC INFLAMMATION

Hepatic inflammation and HSCs

Inflammation is one of the most characteristic features of chronic liver disease of viral, alcoholic, fatty and autoimmune origin^[41]. Inflammation has been shown to typically present in different disease stages and is associated with the pathogenesis of cirrhosis, hepatocellular carcinoma and ALF^[42]. Fibrosis is a highly conserved response to hepatic injury occurring in diseases with hepatocellular death. A number of studies have focused on explaining the links between inflammation and fibrosis.

Hepatocyte injury followed by inflammation and activation of the innate immune system leads to liver fibrosis mediated by HSC activation^[43]. HSCs are quiescent in the normal liver and upon activation by liver injury become activated. HSCs have been characterized as the main effector cells in liver fibrogenesis and receive a wide range of signals from injured/dead hepatocytes and liver immune cells, predominantly KCs. KC-derived transforming growth factor- β 1 activates HSCs and is the most potent fibrogenic agonist. KCs also enhance liver fibrosis by promoting activated HSC survival in a NF- κ B dependent manner. The cross-talk between KCs and HSCs have been shown to be mediated by inflammatory cytokines, including IL-1 β and TNF- α ^[44]. In addition, inhibition of IL-1 β significantly led to increased apoptosis of HSCs and decreased liver fibrosis^[45].

Studies have shown that inflammatory cytokines, such as IL-1 β and IL-6, are produced in activated HSCs. HSCs of murine or human origin are highly responsive to LPS and other pro-inflammatory cytokines, resulting in the activation of pro-inflammatory signaling pathways and the subsequent production of inflammatory chemokines/cytokines. This positive inflammatory feedback loop then maintains a sustained inflammatory process and ensures the survival and activation of HSCs^[46,47].

Hepatic inflammation and HSCs in ALF

ALF is characterized by elevated inflammation. ALF shares many features with severe sepsis, including a systemic inflammatory response and progression to multi-organ failure.

Two main mouse models are now used to study ALF, including the LPS/D-galactosamine and Concanavalin A (Con A) models. Intraperitoneal injection of LPS may activate immune cells located in the circulation and the sinusoids, and these activated cells produce large amounts of inflammatory cytokines and chemokines resulting in massive hemorrhagic liver injury or even hepatocyte death^[46]. D-

galactosamine is a hepatotoxic agent, which inhibits protein synthesis and is usually used together with LPS to create ALF mouse models^[48]. A recent study showed that compared to wild-type mice, HSC-depleted mice presented with decreased cytokine and chemokine expression and attenuated liver injury after LPS/D-galactosamine administration^[49]. Con A is a lectin, carbohydrate-binding protein, extracted from the jack-bean (*Canavalia ensiformis*). An intravenous injection of Con A constitutively activates intrahepatic and systemic immune cells resulting in excessive inflammatory cytokines and chemokines production^[50]. In a Con A-induced liver injury mouse model, inflammatory cytokines, including TNF- α and interferon- β , caused massive hepatocyte necrosis with dense infiltration of leukocytes. A recent study on a Con A-induced liver injury model showed that HSCs received inflammatory signals generated in the sinusoids and relayed them to the liver parenchyma^[8]. Thus, we hypothesize that HSCs have important roles in hepatic inflammation during the pathogenesis of ALF.

Our recent work showed that during the pathogenesis of ALF, reactive oxygen species activate the NLRP3 inflammasome and promote inflammation in HSCs. We also revealed that LPS treatment induced reactive oxygen species generation in HSCs *via* mitophagy inhibition^[51]. Studies have suggested that in hepatocytes, reactive oxygen species play important roles in the pathophysiology of diseases, including ALF. Injured/dead hepatocytes greatly increase oxidative stress during liver failure, which in turn contributes to inflammation, further hepatocyte loss and impedes regeneration^[52]. Taken together, these data suggest that HSC inflammation is involved in the pathogenesis of ALF by producing inflammatory cytokines upon stimulation and relaying inflammation signaling from the sinusoids to parenchyma (Figure 2).

CONCLUSION

ALF is a life-threatening disease, which has a high mortality rate. Hepatocyte death and overactivation of hepatic inflammation are two main characteristics of ALF. HSCs play both protective and promotive roles during the pathogenesis of ALF: first, HSC activation participates in the maintenance of cell attachment and the architecture of liver tissue *via* ECM production; second, HSC activation assists liver regeneration by producing growth factors; and third, HSC inflammation plays a role in relaying inflammation signaling from the sinusoids to parenchyma *via* the secretion of inflammatory cytokines. A better understanding of the roles of HSCs in the pathogenesis of ALF will lead to improvements and novel strategies for the treatment of patients with ALF.

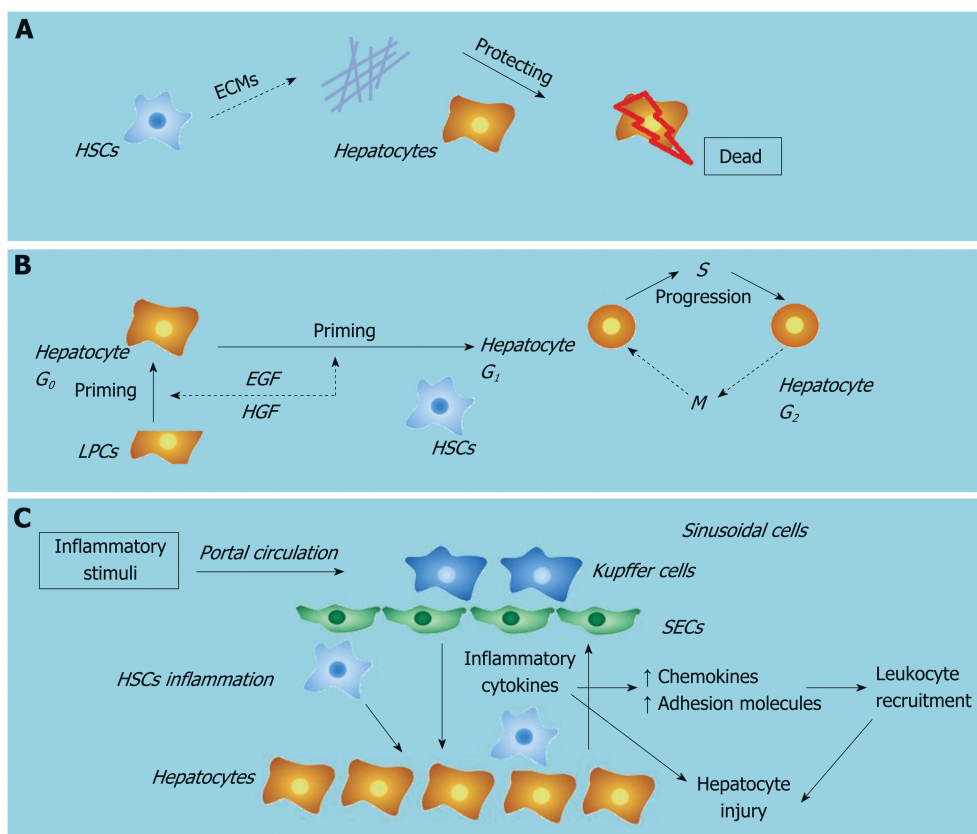


Figure 2 Roles of hepatic stellate cells in liver failure. A: Hepatic stellate cells protect hepatocytes by participating in the maintenance of cell attachment and the architecture of liver tissue via extracellular matrix production; B: Hepatic stellate cells assist liver regeneration by producing growth factors; C: Hepatic stellate cells play a role in relaying inflammation signaling from sinusoids to parenchyma via the secretion of inflammatory cytokines.

REFERENCES

- 1 **Liver Failure and Artificial Liver Group**; Chinese Society of Infectious Diseases; Chinese Medical Association; Severe Liver Disease and Artificial Liver Group; Chinese Society of Hepatology; Chinese Medical Association. Guideline for diagnosis and treatment of liver failure. *Zhonghua Gan Zang Bing Za Zhi* 2019; **27**: 18-26 [PMID: 30685919 DOI: 10.3760/cma.j.issn.1007-3418.2019.01.006]
- 2 **Bernal W**. Acute Liver Failure: Review and Update. *Int Anesthesiol Clin* 2017; **55**: 92-106 [PMID: 28288031 DOI: 10.1097/AIA.0000000000000141]
- 3 **Tsuchida T**, Friedman SL. Mechanisms of hepatic stellate cell activation. *Nat Rev Gastroenterol Hepatol* 2017; **14**: 397-411 [PMID: 28487545 DOI: 10.1038/nrgastro.2017.38]
- 4 **Schumacher JD**, Guo GL. Regulation of Hepatic Stellate Cells and Fibrogenesis by Fibroblast Growth Factors. *Biomed Res Int* 2016; **2016**: 8323747 [PMID: 27699175 DOI: 10.1155/2016/8323747]
- 5 **Shen K**, Chang W, Gao X, Wang H, Niu W, Song L, Qin X. Depletion of activated hepatic stellate cell correlates with severe liver damage and abnormal liver regeneration in acetaminophen-induced liver injury. *Acta Biochim Biophys Sin (Shanghai)* 2011; **43**: 307-315 [PMID: 21335335 DOI: 10.1093/abbs/gmr005]
- 6 **Fujita T**, Narumiya S. Roles of hepatic stellate cells in liver inflammation: a new perspective. *Inflamm Regen* 2016; **36**: 1 [PMID: 29259674 DOI: 10.1186/s41232-016-0005-6]
- 7 **Xiang DM**, Sun W, Ning BF, Zhou TF, Li XF, Zhong W, Cheng Z, Xia MY, Wang X, Deng X, Wang W, Li HY, Cui XL, Li SC, Wu B, Xie WF, Wang HY, Ding J. The HLF/IL-6/STAT3 feedforward circuit drives hepatic stellate cell activation to promote liver fibrosis. *Gut* 2018; **67**: 1704-1715 [PMID: 28754776 DOI: 10.1136/gutjnl-2016-313392]
- 8 **Fujita T**, Soonthrapa K, Ito Y, Iwaisako K, Moniaga CS, Asagiri M, Majima M, Narumiya S. Hepatic stellate cells relay inflammation signaling from sinusoids to parenchyma in mouse models of immune-mediated hepatitis. *Hepatology* 2016; **63**: 1325-1339 [PMID: 26248612 DOI: 10.1002/hep.28112]
- 9 **Harvey SA**, Dangi A, Tandon A, Gandhi CR. The transcriptomic response of rat hepatic stellate cells to endotoxin: implications for hepatic inflammation and immune regulation. *PLoS One* 2013; **8**: e82159 [PMID: 24349206 DOI: 10.1371/journal.pone.0082159]
- 10 **Sowa JP**, Gerken G, Canbay A. Acute Liver Failure - It's Just a Matter of Cell Death. *Dig Dis* 2016; **34**: 423-428 [PMID: 27170397 DOI: 10.1159/000444557]
- 11 **Bantel H**, Schulze-Osthoff K. Mechanisms of cell death in acute liver failure. *Front Physiol* 2012; **3**: 79 [PMID: 22485095 DOI: 10.3389/fphys.2012.00079]
- 12 **Weng HL**, Cai X, Yuan X, Liebe R, Dooley S, Li H, Wang TL. Two sides of one coin: massive hepatic necrosis and progenitor cell-mediated regeneration in acute liver failure. *Front Physiol* 2015; **6**: 178 [PMID: 26136687 DOI: 10.3389/fphys.2015.00178]
- 13 **Macdonald S**, Andreola F, Bachtiger P, Amoros A, Pavesi M, Mookerjee R, Zheng YB, Gronbaek H, Gerbes AL, Sola E, Caraceni P, Moreau R, Gines P, Arroyo V, Jalan R. Cell death markers in patients with

- cirrhosis and acute decompensation. *Hepatology* 2018; **67**: 989-1002 [PMID: [29023872](#) DOI: [10.1002/hep.29581](#)]
- 14 **Best J**, Dollé L, Manka P, Coombes J, van Grunsven LA, Syn WK. Role of liver progenitors in acute liver injury. *Front Physiol* 2013; **4**: 258 [PMID: [24133449](#) DOI: [10.3389/fphys.2013.00258](#)]
 - 15 **Preziosi ME**, Monga SP. Update on the Mechanisms of Liver Regeneration. *Semin Liver Dis* 2017; **37**: 141-151 [PMID: [28564722](#) DOI: [10.1055/s-0037-1601351](#)]
 - 16 **Sang JF**, Shi XL, Han B, Huang T, Huang X, Ren HZ, Ding YT. Intraportal mesenchymal stem cell transplantation prevents acute liver failure through promoting cell proliferation and inhibiting apoptosis. *Hepatobiliary Pancreat Dis Int* 2016; **15**: 602-611 [PMID: [27919849](#)]
 - 17 **CANONIC Study Investigators of the EASL-CLIF Consortium and the European Foundation for the Study of Chronic Liver Failure (EF-CLIF)**; Stauber RE, Coenraad MJ, Moreau R, Jalan R, Pavesi M, Titos E, Oettl K, Angeli P, Domenicali M, Alessandria C, Gerbes A, Wendon J, Nevens F, Trebicka J, Laleman W, Saliba F, Welzel TM, Albillos A, Gustot T, Bente D, Durand F, Bernardi M, Arroyo V, Clària J, Amorós A, Ginès P, Morales-Ruiz M, Alcaraz-Quiles J. Systemic inflammation in decompensated cirrhosis: Characterization and role in acute-on-chronic liver failure. *Hepatology* 2016; **64**: 1249-1264 [PMID: [27483394](#) DOI: [10.1002/hep.28740](#)]
 - 18 **Wang LK**, Wang LW, Li X, Han XQ, Gong ZJ. Ethyl pyruvate prevents inflammatory factors release and decreases intestinal permeability in rats with D-galactosamine-induced acute liver failure. *Hepatobiliary Pancreat Dis Int* 2013; **12**: 180-188 [PMID: [23558073](#)]
 - 19 **Zhong W**, Qian K, Xiong J, Ma K, Wang A, Zou Y. Curcumin alleviates lipopolysaccharide induced sepsis and liver failure by suppression of oxidative stress-related inflammation via PI3K/AKT and NF- κ B related signaling. *Biomed Pharmacother* 2016; **83**: 302-313 [PMID: [27393927](#) DOI: [10.1016/j.biopha.2016.06.036](#)]
 - 20 **Donnelly MC**, Hayes PC, Simpson KJ. Role of inflammation and infection in the pathogenesis of human acute liver failure: Clinical implications for monitoring and therapy. *World J Gastroenterol* 2016; **22**: 5958-5970 [PMID: [27468190](#) DOI: [10.3748/wjg.v22.i26.5958](#)]
 - 21 **Fischer J**, Silva TE, Soares E Silva PE, Colombo BS, Silva MC, Wildner LM, Bazzo ML, Rateke EC, Frode TS, Mello SV, Rosa JS, Dantas-Correa EB, Narciso-Schiavon JL, Schiavon LL. From stable disease to acute-on-chronic liver failure: Circulating cytokines are related to prognosis in different stages of cirrhosis. *Cytokine* 2017; **91**: 162-169 [PMID: [28082235](#) DOI: [10.1016/j.cyto.2016.12.017](#)]
 - 22 **Yang X**, Chen Y, Zhang J, Tang T, Kong Y, Ye F, Zhang X, Liu X, Lin S. Thymosin α 1 treatment reduces hepatic inflammation and inhibits hepatocyte apoptosis in rats with acute liver failure. *Exp Ther Med* 2018; **15**: 3231-3238 [PMID: [29545840](#) DOI: [10.3892/etm.2018.5843](#)]
 - 23 **Liang DY**, Liu LM, Ye CG, Zhao L, Yu FP, Gao DY, Wang YY, Yang ZW, Wang YY. Inhibition of UH1/UTR system relieves acute inflammation of liver through preventing activation of NF- κ B pathway in ALF mice. *PLoS One* 2013; **8**: e64895 [PMID: [23755157](#) DOI: [10.1371/journal.pone.0064895](#)]
 - 24 **Lee UE**, Friedman SL. Mechanisms of hepatic fibrogenesis. *Best Pract Res Clin Gastroenterol* 2011; **25**: 195-206 [PMID: [21497738](#) DOI: [10.1016/j.bpg.2011.02.005](#)]
 - 25 **Lunova M**, Goehring C, Kuscuglu D, Mueller K, Chen Y, Walther P, Deschemin JC, Vaulont S, Haybaeck J, Lackner C, Trautwein C, Strnad P. Hecpudin knockout mice fed with iron-rich diet develop chronic liver injury and liver fibrosis due to lysosomal iron overload. *J Hepatol* 2014; **61**: 633-641 [PMID: [24816174](#) DOI: [10.1016/j.jhep.2014.04.034](#)]
 - 26 **McGill MR**, Jaeschke H. Apoptosis or necrosis in acetaminophen-induced acute liver failure? New insights from mechanistic biomarkers. *Crit Care Med* 2013; **41**: 2653-2654 [PMID: [24162681](#) DOI: [10.1097/CCM.0b013e31829caf67](#)]
 - 27 **Bourbonnais E**, Raymond VA, Ethier C, Nguyen BN, El-Leil MS, Meloche S, Bilodeau M. Liver fibrosis protects mice from acute hepatocellular injury. *Gastroenterology* 2012; **142**: 130-139.e4 [PMID: [21945831](#) DOI: [10.1053/j.gastro.2011.09.033](#)]
 - 28 **Zhan SS**, Jiang JX, Wu J, Halsted C, Friedman SL, Zern MA, Torok NJ. Phagocytosis of apoptotic bodies by hepatic stellate cells induces NADPH oxidase and is associated with liver fibrosis in vivo. *Hepatology* 2006; **43**: 435-443 [PMID: [16496318](#) DOI: [10.1002/hep.21093](#)]
 - 29 **Dechêne A**, Sowa JP, Gieseler RK, Jochum C, Bechmann LP, El Fouly A, Schlattjan M, Saner F, Baba HA, Paul A, Dries V, Odenthal M, Gerken G, Friedman SL, Canbay A. Acute liver failure is associated with elevated liver stiffness and hepatic stellate cell activation. *Hepatology* 2010; **52**: 1008-1016 [PMID: [20684020](#) DOI: [10.1002/hep.23754](#)]
 - 30 **He Y**, Jin L, Wang J, Yan Z, Chen T, Zhao Y. Mechanisms of fibrosis in acute liver failure. *Liver Int* 2015; **35**: 1877-1885 [PMID: [25388426](#) DOI: [10.1111/liv.12731](#)]
 - 31 **Chalasani N**, Aljadhey H, Kesterson J, Murray MD, Hall SD. Patients with elevated liver enzymes are not at higher risk for statin hepatotoxicity. *Gastroenterology* 2004; **126**: 1287-1292 [PMID: [15131789](#)]
 - 32 **Teschke R**, Danan G. Drug-induced liver injury: Is chronic liver disease a risk factor and a clinical issue? *Expert Opin Drug Metab Toxicol* 2017; **13**: 425-438 [PMID: [27822971](#) DOI: [10.1080/17425255.2017.1252749](#)]
 - 33 **Osawa Y**, Hannun YA, Proia RL, Brenner DA. Roles of AKT and sphingosine kinase in the antiapoptotic effects of bile duct ligation in mouse liver. *Hepatology* 2005; **42**: 1320-1328 [PMID: [16317686](#) DOI: [10.1002/hep.20967](#)]
 - 34 **Gkretsi V**, Bowen WC, Yang Y, Wu C, Michalopoulos GK. Integrin-linked kinase is involved in matrix-induced hepatocyte differentiation. *Biochem Biophys Res Commun* 2007; **353**: 638-643 [PMID: [17194454](#) DOI: [10.1016/j.bbrc.2006.12.091](#)]
 - 35 **Yan C**, Zhou L, Han YP. Contribution of hepatic stellate cells and matrix metalloproteinase 9 in acute liver failure. *Liver Int* 2008; **28**: 959-971 [PMID: [18507761](#) DOI: [10.1111/j.1478-3231.2008.01775.x](#)]
 - 36 **Michalopoulos GK**. Advances in liver regeneration. *Expert Rev Gastroenterol Hepatol* 2014; **8**: 897-907 [PMID: [24964729](#) DOI: [10.1586/17474124.2014.934358](#)]
 - 37 **Kwon YJ**, Lee KG, Choi D. Clinical implications of advances in liver regeneration. *Clin Mol Hepatol* 2015; **21**: 7-13 [PMID: [25834796](#) DOI: [10.3350/cmh.2015.21.1.7](#)]
 - 38 **Yin C**, Evason KJ, Asahina K, Stainier DY. Hepatic stellate cells in liver development, regeneration, and cancer. *J Clin Invest* 2013; **123**: 1902-1910 [PMID: [23635788](#) DOI: [10.1172/JCI66369](#)]
 - 39 **Williams MJ**, Clouston AD, Forbes SJ. Links between hepatic fibrosis, ductular reaction, and progenitor cell expansion. *Gastroenterology* 2014; **146**: 349-356 [PMID: [24315991](#) DOI: [10.1053/j.gastro.2013.11.034](#)]
 - 40 **Chang W**, Song L, Chang X, Ji M, Wang H, Qin X, Niu W. Early activated hepatic stellate cell-derived paracrine molecules modulate acute liver injury and regeneration. *Lab Invest* 2017; **97**: 318-328 [PMID: [28564722](#) DOI: [10.1055/s-0037-1601351](#)]

- 27991908 DOI: [10.1038/labinvest.2016.130](https://doi.org/10.1038/labinvest.2016.130)]
- 41 **de Andrade KQ**, Moura FA, dos Santos JM, de Araújo OR, de Farias Santos JC, Goulart MO. Oxidative Stress and Inflammation in Hepatic Diseases: Therapeutic Possibilities of N-Acetylcysteine. *Int J Mol Sci* 2015; **16**: 30269-30308 [PMID: [26694382](https://pubmed.ncbi.nlm.nih.gov/26694382/) DOI: [10.3390/ijms161226225](https://doi.org/10.3390/ijms161226225)]
 - 42 **Alegre F**, Pelegrin P, Feldstein AE. Inflammasomes in Liver Fibrosis. *Semin Liver Dis* 2017; **37**: 119-127 [PMID: [28564720](https://pubmed.ncbi.nlm.nih.gov/28564720/) DOI: [10.1055/s-0037-1601350](https://doi.org/10.1055/s-0037-1601350)]
 - 43 **Wen YA**, Liu D, Zhou QY, Huang SF, Luo P, Xiang Y, Sun S, Luo D, Dong YF, Zhang LP. Biliary intervention aggravates cholestatic liver injury, and induces hepatic inflammation, proliferation and fibrogenesis in BDL mice. *Exp Toxicol Pathol* 2011; **63**: 277-284 [PMID: [20149605](https://pubmed.ncbi.nlm.nih.gov/20149605/) DOI: [10.1016/j.etp.2010.01.006](https://doi.org/10.1016/j.etp.2010.01.006)]
 - 44 **Robert S**, Gicquel T, Bodin A, Lagente V, Boichot E. Characterization of the MMP/TIMP Imbalance and Collagen Production Induced by IL-1 β or TNF- α Release from Human Hepatic Stellate Cells. *PLoS One* 2016; **11**: e0153118 [PMID: [27046197](https://pubmed.ncbi.nlm.nih.gov/27046197/) DOI: [10.1371/journal.pone.0153118](https://doi.org/10.1371/journal.pone.0153118)]
 - 45 **Masola V**, Carraro A, Granata S, Signorini L, Bellin G, Violi P, Lupo A, Tedeschi U, Onisto M, Gambaro G, Zaza G. In vitro effects of interleukin (IL)-1 beta inhibition on the epithelial-to-mesenchymal transition (EMT) of renal tubular and hepatic stellate cells. *J Transl Med* 2019; **17**: 12 [PMID: [30616602](https://pubmed.ncbi.nlm.nih.gov/30616602/) DOI: [10.1186/s12967-019-1770-1](https://doi.org/10.1186/s12967-019-1770-1)]
 - 46 **Hamesch K**, Borkham-Kamphorst E, Strnad P, Weiskirchen R. Lipopolysaccharide-induced inflammatory liver injury in mice. *Lab Anim* 2015; **49**: 37-46 [PMID: [25835737](https://pubmed.ncbi.nlm.nih.gov/25835737/) DOI: [10.1177/0023677215570087](https://doi.org/10.1177/0023677215570087)]
 - 47 **Chen Y**, Wu Z, Yuan B, Dong Y, Zhang L, Zeng Z. MicroRNA-146a-5p attenuates irradiation-induced and LPS-induced hepatic stellate cell activation and hepatocyte apoptosis through inhibition of TLR4 pathway. *Cell Death Dis* 2018; **9**: 22 [PMID: [29348414](https://pubmed.ncbi.nlm.nih.gov/29348414/) DOI: [10.1038/s41419-017-0038-z](https://doi.org/10.1038/s41419-017-0038-z)]
 - 48 **Wang W**, Wu L, Li Q, Zhang Z, Xu L, Lin C, Gao L, Zhao K, Liang F, Zhang Q, Zhou M, Jiang W. Madecassoside prevents acute liver failure in LPS/D-GalN-induced mice by inhibiting p38/NF- κ B and activating Nrf2/HO-1 signaling. *Biomed Pharmacother* 2018; **103**: 1137-1145 [PMID: [29715757](https://pubmed.ncbi.nlm.nih.gov/29715757/) DOI: [10.1016/j.biopha.2018.04.162](https://doi.org/10.1016/j.biopha.2018.04.162)]
 - 49 **Stewart RK**, Dangi A, Huang C, Murase N, Kimura S, Stolz DB, Wilson GC, Lentsch AB, Gandhi CR. A novel mouse model of depletion of stellate cells clarifies their role in ischemia/reperfusion- and endotoxin-induced acute liver injury. *J Hepatol* 2014; **60**: 298-305 [PMID: [24060854](https://pubmed.ncbi.nlm.nih.gov/24060854/) DOI: [10.1016/j.jhep.2013.09.013](https://doi.org/10.1016/j.jhep.2013.09.013)]
 - 50 **Fayad R**, Sennello JA, Kim SH, Pini M, Dinarello CA, Fantuzzi G. Induction of thymocyte apoptosis by systemic administration of concanavalin A in mice: role of TNF-alpha, IFN-gamma and glucocorticoids. *Eur J Immunol* 2005; **35**: 2304-2312 [PMID: [16047339](https://pubmed.ncbi.nlm.nih.gov/16047339/) DOI: [10.1002/eji.200526062](https://doi.org/10.1002/eji.200526062)]
 - 51 **Tian Z**, Chen Y, Yao N, Hu C, Wu Y, Guo D, Liu J, Yang Y, Chen T, Zhao Y, He Y. Role of mitophagy regulation by ROS in hepatic stellate cells during acute liver failure. *Am J Physiol Gastrointest Liver Physiol* 2018; **315**: G374-G384 [PMID: [29648877](https://pubmed.ncbi.nlm.nih.gov/29648877/) DOI: [10.1152/ajpgi.00032.2018](https://doi.org/10.1152/ajpgi.00032.2018)]
 - 52 **Gong X**, Yang Y, Huang L, Zhang Q, Wan RZ, Zhang P, Zhang B. Antioxidation, anti-inflammation and anti-apoptosis by paeonol in LPS/d-GalN-induced acute liver failure in mice. *Int Immunopharmacol* 2017; **46**: 124-132 [PMID: [28282576](https://pubmed.ncbi.nlm.nih.gov/28282576/) DOI: [10.1016/j.intimp.2017.03.003](https://doi.org/10.1016/j.intimp.2017.03.003)]

Hepatitis C virus cure with direct acting antivirals: Clinical, economic, societal and patient value for China

Qing Xie, Jian-Wei Xuan, Hong Tang, Xiao-Guang Ye, Peng Xu, I-Heng Lee, Shan-Lian Hu

ORCID number: Qing Xie (0000-0002-2582-8803); Jian-Wei Xuan (0000-0003-2918-1813); Hong Tang (0000-0003-0675-1860); Xiao-Guang Ye (0000-0002-7837-2360); Peng Xu (0000-0002-5702-2177); I-Heng Lee (0000-0001-9980-177X); Shan-Lian Hu (0000-0001-7295-0855).

Author contributions: All authors contributed to this paper with conception and design of the study, literature review and analysis, critical revision and editing, and final approval of the version to be published; all authors agree to be accountable for all aspects of the work in ensuring that questions related to the accuracy or integrity of any part of the work are appropriately investigated and resolved.

Conflict-of-interest statement: Xie Q served as adviser, speaker or advisory board member for F Hoffmann-La Roche, Bristol-Myers Squibb, Novartis Pharmaceutical, MSD, and Gilead Sciences; Xuan JW has no potential conflicts of interest; Tang H served as adviser, speaker or advisory board member for MSD, La Roche, Bristol-Myers Squibb, Novartis Pharmaceutical, and Gilead Sciences; Ye XG served as speaker or adviser for GSK, F Hoffmann-La Roche, Bristol-Myers Squibb, Novartis Pharmaceutical, MSD, and Gilead Sciences; Xu P employee of Gilead Sciences. Lee IH employee of Gilead Sciences; Hu SL served as speaker or adviser for Gilead Sciences.

Open-Access: This article is an open-access article which was selected by an in-house editor and

Qing Xie, Department of Infectious Diseases, Ruijin Hospital, Shanghai Jiaotong University School of Medicine, Shanghai 200025, China

Jian-Wei Xuan, Health Economic Research Institute, School of Pharmacy, Sun Yat-Sen University, Guangzhou 510006, Guangdong Province, China

Hong Tang, Center of Infectious Diseases, West China Hospital of Sichuan University, Chengdu 610041, Sichuan Province, China

Xiao-Guang Ye, Second Affiliated Hospital of Guangzhou Medical University, Guangzhou 510260, Guangdong Province, China

Peng Xu, Gilead Sciences Inc, Shanghai 200122, China

I-Heng Lee, Gilead Sciences Inc, Foster City, CA 94404, United States

Shan-Lian Hu, School of Public Health, Fudan University, Shanghai 200032, China

Shan-Lian Hu, Shanghai Health Development Research Center, Shanghai 200032, China

Corresponding author: Shan-Lian Hu, MD, MSc, Professor, School of Public Health, Fudan University, 130 Dong'an Road, Shanghai 200032, China. hushanlian@hotmail.com
Telephone: +86-21-65642222

Abstract

About 10 million people in China are infected with hepatitis C virus (HCV), with the seroprevalence of anti-HCV in the general population estimated at 0.6%. Delaying effective treatment of chronic hepatitis C (CHC) is associated with liver disease progression, cirrhosis, hepatocellular carcinoma, and liver-related mortality. The extrahepatic manifestations of CHC further add to the disease burden of patients. Managing CHC-related advanced liver diseases and systemic manifestations are costly for both the healthcare system and society. Loss of work productivity due to reduced well-being and quality of life in CHC patients further compounds the economic burden of the disease. Traditionally, pegylated-interferon plus ribavirin (PR) was the standard of care. However, a substantial number of patients are ineligible for PR treatment, and only 40%-75% achieved sustained virologic response. Furthermore, PR is associated with impairment of patient-reported outcomes (PROs), high rates of adverse events, and poor adherence. With the advent of direct acting antivirals (DAAs), the treatment of CHC patients has been revolutionized. DAAs have broader eligible patient populations, higher efficacy, better PRO profiles, fewer adverse events, and better adherence rates, thereby making it possible to cure a large proportion of all CHC

fully peer-reviewed by external reviewers. It is distributed in accordance with the Creative Commons Attribution Non Commercial (CC BY-NC 4.0) license, which permits others to distribute, remix, adapt, build upon this work non-commercially, and license their derivative works on different terms, provided the original work is properly cited and the use is non-commercial. See: <http://creativecommons.org/licenses/by-nc/4.0/>

Manuscript source: Unsolicited Manuscript

Received: December 28, 2018

Peer-review started: December 29, 2018

First decision: March 5, 2019

Revised: April 5, 2019

Accepted: April 19, 2019

Article in press: April 19, 2019

Published online: May 27, 2019

P-Reviewer: Campollo O, Farshadpour F, Hu KQ, Lin ZY, Shimizu Y, Tajiri K

S-Editor: Cui LJ

L-Editor: A

E-Editor: Zhang YL



patients. This article aims to provide a comprehensive evaluation on the value of effective, curative hepatitis C treatment from the clinical, economic, societal, and patient experience perspectives, with a focus on recent data from China, supplemented with other Asian and international experiences where China data are not available.

Key words: Hepatitis C; Value of cure; Sustained virologic response; End stage liver disease; Prevention of transmission; Cost-effectiveness; Productivity; Societal value; Patient-reported outcomes

©The Author(s) 2019. Published by Baishideng Publishing Group Inc. All rights reserved.

Core tip: Chronic hepatitis C is a systemic disease that manifests both hepatically and extrahepatically, leading to impaired patient-reported outcomes (PROs) and huge economic burden on the healthcare system and society. Direct acting antivirals are effective hepatitis C therapies that improve PROs and have broad eligible patient populations, good efficacy, few adverse events, and high adherence rates. Sustained virologic response is associated with improved clinical outcomes and increased work productivity. Curative therapies for hepatitis C was of substantial societal and economic value because they reduce productivity loss and avoid the management costs associated with advanced liver disease and extrahepatic manifestations.

Citation: Xie Q, Xuan JW, Tang H, Ye XG, Xu P, Lee IH, Hu SL. Hepatitis C virus cure with direct acting antivirals: Clinical, economic, societal and patient value for China. *World J Hepatol* 2019; 11(5): 421-441

URL: <https://www.wjgnet.com/1948-5182/full/v11/i5/421.htm>

DOI: <https://dx.doi.org/10.4254/wjh.v11.i5.421>

INTRODUCTION

In recent years, direct acting antiviral (DAA) treatments have replaced pegylated-interferon (PEG-IFN) and ribavirin (RBV) combination therapy (PR) as standard of care for patients with chronic hepatitis C (CHC) globally^[1-3]. DAAs are associated with over 90% rates of sustained virologic response (SVR), fewer side effects, shorter treatment durations, and improved adherence compared to PR therapy^[4].

Due to the substantial impact of hepatitis C virus (HCV) infection globally on patients, their families, and public health systems, the World Health Organization (WHO) has set HCV elimination goals that include reduction of HCV incidence by 80% and HCV-related mortality by 65% by 2030^[5]. As part of the strategy to achieve these goals, the WHO included DAA therapies in its 2017 edition of List of Essential Medicines^[6]. Specifically, the latest (2018) WHO guidelines for HCV treatment make an updated recommendation of using pan-genotypic regimens for treating adult patients with chronic HCV infection^[5]. Besides their proven high efficacy, pan-genotypic regimens enable cost saving and care pathway simplification by eliminating the need for pre-treatment genotyping, potentially reducing loss to follow up among patients. Furthermore, the recommended pan-genotypic regimens, such as sofosbuvir/velpatasvir (SOF/VEL), enable most HCV patients to be treated with simple treatment strategies regardless of patients' prior treatment experience or cirrhosis status, with minimal need for regimen adjustment or on-treatment monitoring^[5]. As reflected in this recommendation by the WHO, the value of high-impact, curative treatment for HCV infection is wide-ranging and goes beyond clinical efficacy.

In China, the number of individuals infected with HCV is estimated at 10 million, with a seroprevalence of anti-HCV antibodies of 0.6% among the general population^[7,8]. In addition to the large and growing number of HCV-infected individuals, there have been a diversification of HCV genotypes (GTs) and a broadening of the age spectrum among Chinese HCV patients; GT1b or GT2a HCV patients historically infected through blood transfusion are aging, while an increasing number of younger patients are becoming infected with GT3a, 3b and 6a HCV through injection drug use^[9-11]. The resulting healthcare expenditures, as well as reduction in quality of life and loss of work productivity among the Chinese CHC

population, are expected to have wide-ranging economic and societal implications.

In addition to the heavy disease burden, the management of the HCV epidemic has been compounded by a lag in adopting DAAs in China: up to early 2017, no DAA had been approved in China. To improve the availability of innovative treatments (including DAAs), China introduced policies that expedite the regulatory review process for drug registration. To date (March 2019), most of the mainstream DAA regimens used internationally have been approved in China, including daclatasvir plus asunaprevir (DCV + ASV), sofosbuvir plus simeprevir (SOF + SMV), SOF + DCV, the fixed-dose combination ombitasvir/paritaprevir/ritonavir with or without dasabuvir (O/P/r ± D), SOF/VEL, ledipasvir (LDV)/SOF, and elbasvir/grazoprevir (EBR/GZR). Glecaprevir/pibrentasvir (GLE/PIB) and SOF/VEL/voxilaprevir (VOX) are also pending approval.

While the rapid improvement in DAA availability is encouraging, China is still far from universal adoption of DAA-based therapies. In an initial step to address the issue of drug accessibility, the Chinese government included SOF/VEL in the latest (October 2018) National Essential Drug List as the first and only DAA treatment^[12]. Nevertheless, DAAs are not covered by the National Medical Insurance scheme for reimbursement, and thus much less affordable compared with IFN-based therapies. As such, a considerable number of patients, such as those in rural and less-developed areas and those with limited financial means, would still have to resort to IFN-based therapies.

In light of how IFN-free DAA regimens have revolutionized treatment for HCV-infected patients, many countries are now aiming for elimination of the disease^[13]; the introduction of DAA regimens in China therefore, also provides the opportunity for potential hepatitis C elimination. In the 2017–2020 National Viral Hepatitis Action Plan, the Chinese government emphasized the use of more efficacious treatment as part of the strategy to reduce the spread of HCV^[14]. The overarching Healthy China 2030 Plan also showed the Chinese government's commitment to establish public health as the foundation for future economic and societal development^[15]. In line with the country's strategic approach to healthcare and hepatitis management, this article aims to comprehensively evaluate the value of curative HCV therapies in the dimensions of clinical, patient, economic and societal benefits, in the hope of providing useful references for various stakeholders and policy makers in China. Where possible, data from China have been used, supplemented with data from other Asian countries and from around the world when Chinese data are unavailable.

CLINICAL BENEFITS OF CURING HCV INFECTION

Impact of HCV infection and treatment on the liver

The principal impact of HCV is on the liver, the predominant site of HCV replication. While initial HCV infection resolves spontaneously in around 15%–25% of cases, the majority of patients will develop CHC^[16]. The long-term outcomes of the liver inflammation caused by HCV infection include the development of fibrosis, compensated and decompensated cirrhosis, hepatocellular carcinoma (HCC), and end-stage liver disease (ESLD)^[16]. Progression of CHC typically occurs over many years; it is estimated that 10%–20% of patients will develop cirrhosis and the annual risk of HCC in patients with cirrhosis is approximately 1%–4%^[16]. If left untreated, CHC patients would progress to more advanced disease stages, which in turn are associated with accelerated disease progression, elevated risks of developing HCC, and consequently lower survival rates^[4]. A long-term retrospective cohort study in Japanese CHC patients showed that untreated F0/F1 patients have a 0.5% annual risk for HCC development, while this increased to 7.9% in F4 patients^[17]. A systematic review of CHC patients in Asia, including China, reported that the 5-year survival for cirrhotic CHC patients was 73.8%, but falls to 39.2% following progression to ESLD, wherein liver transplantation is required^[18].

China has an estimated annual incidence of 53593 cases (95%CI: 16144–92466) of HCV-related HCC^[19], with > 93000 cases of HCV-related liver cancer deaths recorded in 2005^[20]. The majority of Chinese HCV patients were infected through blood transfusion before 1993–1996, in whom age and duration of infection are significant risk factors for disease progression^[21]. As these patients grow older and enter their third or fourth decade of infection, the occurrence of decompensated cirrhosis (DCC), HCC and ELSD will rise. On the other hand, China has seen a recent increase in younger patients with GT3 HCV^[10,22]. A study in Shanghai reported evidence that GT3 patients undergo faster disease progression, with GT3 patients < 50 years of age showing significantly more advanced fibrosis than their non-GT3 counterparts^[22]. If left untreated, considerable numbers of liver sequelae will develop in these younger

GT3 patients in future.

Antiviral treatment and resultant SVR improve the long-term clinical outcome of HCV patients^[23-28]. The beneficial effects of IFN-based treatment and SVR on reducing cirrhosis progression, HCC, and mortality have been well documented, and this is reflected by the recently published results from two large-scale studies in Asia and two Chinese cohort studies^[29-32]. Similar clinical benefits have been observed with SVR to DAA-based treatment. In a large-scale, retrospective study in Japan, GT1 HCV patients who achieved SVR to all-oral DAA regimens had a lower cumulative incidence of HCC than non-SVR patients at 2 years post-treatment (**Figure 1**)^[27]. Furthermore, a recent Chinese prospective study in DAA-treated and case-matched PR-treated patients showed no difference in the risk of developing HCC post-SVR^[33]. DAA treatment was also associated with a 32% reduction in liver-related mortality relative to no treatment^[25], and DAA-mediated SVR conferred reductions in all-cause mortality relative to non-SVR in patients with or without advanced liver disease by 79% and 56%, respectively^[23,24].

A meta-analysis of 31 studies in predominantly GT1 HCV-infected patients (including Asian patients) showed that achieving SVR conferred survival benefit irrespective of patients' clinical characteristics, with difficult-to-treat populations such as cirrhotic patients experiencing the largest extent of reduction in 5-year mortality compared to no SVR^[34]. Nonetheless, the hepatic and survival benefits of achieving SVR are maximized by treating patients in earlier disease stages^[31,35]. For instance, for Asian cirrhotic patients who achieved SVR, despite a reduction in cumulative risk of HCC by 25.5 percentage points relative to cirrhotic patients without SVR, the associated risk of HCC was still higher than non-cirrhotic patients with SVR (0.54 *vs* 0.37)^[31]. Thus, the WHO guidelines recommend treating all HCV-infected patients without disease stage-based restriction or prioritization, with an emphasis on minimizing treatment delay after diagnosis^[5].

Although SVR to either IFN- or DAA-based treatment reduces liver disease progression, the impact of IFN-based treatment would be limited due to low SVR rates (40%–75%)^[4,36]. In a meta-analysis of 12 studies involving 25497 CHC patients on IFN-based therapy, although SVR achievement led to a 76% reduction in HCC risk, only 36% of patients achieved SVR^[37]. PR treatment also has numerous contraindications and side effects, such as RBV-induced hemolytic anemia and various neuropsychiatric, autoimmune, ischemic, and infectious disorders that may be caused or aggravated by IFN^[38,39]. In the nationwide CCgenos study, 56.7% of untreated Chinese HCV patients were IFN-ineligible^[40]. In contrast, DAA regimens confer high real-world SVR rates of 90%–100%, and extend HCV cure to patient populations that could not be effectively treated in the PR era, such as patients with DCC and/or liver transplant, and patients with concomitant renal impairment or psychiatric disorders (although the eligible patient populations and efficacy profiles do differ among DAA regimens)^[41]. As such, DAAs would have a greater impact than IFN-based therapy in significantly reducing HCV-related liver sequelae and deaths at the population level^[42]. Evidence for such populational benefits associated with expanded DAA use is emerging internationally, and various countries are promoting the use and reimbursement of DAAs as a key strategy towards the goal of HCV elimination. For example, in England, a national 40% scale-up of DAA provision in 2015 was followed by reductions in the incidence of HCV-related cirrhosis (42%), liver transplantations (32%), and deaths (8%)^[43]. In 2018, Canada is progressively removing the eligibility criterion of F2+ fibrosis for DAA reimbursement^[44].

In China, DAAs achieved high SVR rates in pivotal clinical studies (**Table 1**). Evaluated genotype-specific regimens (DCV + ASV, LDV/SOF, EBR/GZR, and O/P/r + D) all achieved SVR12 rates $\geq 92\%$ in GT1 or GT1b patients^[45-48]. Pan-genotypic regimens evaluated in clinical studies included SOF + RBV \pm PEG-IFN and SOF/VEL. For SOF + RBV \pm PEG-IFN, cirrhotic patients achieved lower SVR12 rates than non-cirrhotic patients (**Table 1**)^[49]. For SOF/VEL, the only patient population with an SVR12 rate below 90% was GT3b cirrhotic patients (**Table 1**), who also exhibited a high prevalence of baseline A30K + L31M substitutions^[50,51]. Due to the short period of DAA application, real-world efficacy data in China are only emerging. Majority of the early real-world studies focused on SOF-based regimens (reviewed by An *et al*^[52]); two examples are shown in **Table 1**, where SOF-based regimens demonstrated high efficacy in difficult-to-treat patients^[53,54].

Using China-specific SVR data where available, modeling studies predicted that compared to PR, DAA treatment would markedly reduce the HCV-associated long-term disease burden and mortality. A study simulating the national-level disease burden of CHC in China predicted that with no treatment, the prevalence of HCV would continue increasing and reach 28.1 million in 2050, with 2.4 million liver-related deaths, mostly attributable to DCC and HCC^[55]. The model predicted that using PR therapy would not be able to revert the trend of increase in HCV prevalence.

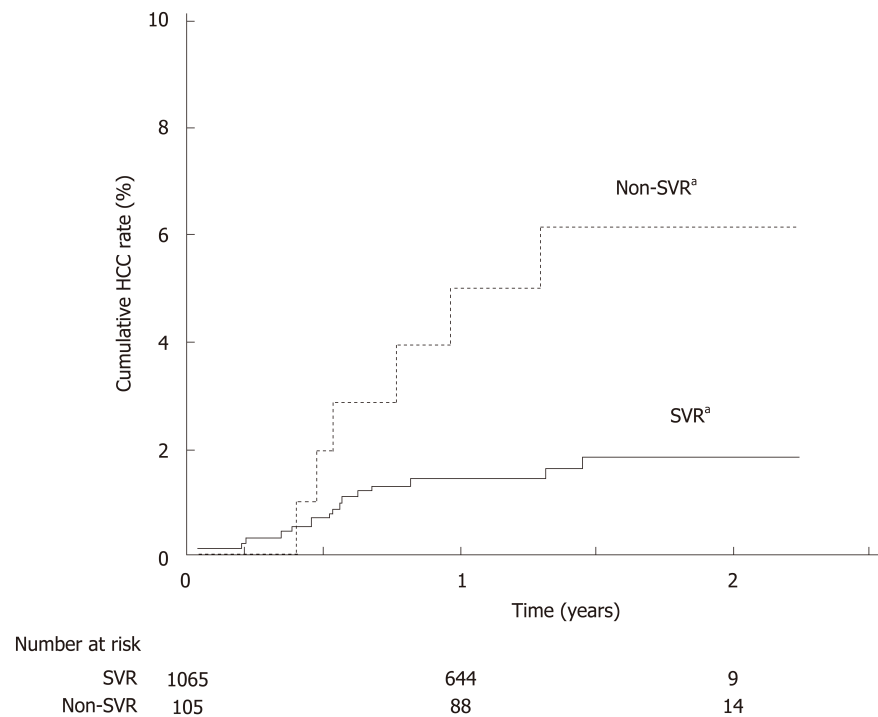


Figure 1 Viral elimination by all-oral direct acting antiviral treatment reduces rate of hepatocellular carcinoma in hepatitis C virus-infected patients. Japanese patients with GT1 hepatitis C virus infection initiating all-oral direct acting antiviral treatment between September 2014 and May 2016 were followed up for a range of 0.1–2.2 years (median follow-up period 1.3 years). The number of patients at risk is shown below each time point. Patients who achieved sustained virologic response had significantly lower incidence of hepatocellular carcinoma compared to patients without sustained virologic response. ^a $P = 0.007$, log-rank test. SVR: Sustained virologic response. Adapted with permission from Ogata *et al.*^[27], 2017.

In contrast, universal adoption of DAAs from 2021 onward would significantly reduce the HCV prevalence. Furthermore, compared to using PR therapy, universal DAA adoption would reduce the cases of incident DCC, HCC, liver transplants, and liver-related deaths by 61%, 45%, 50%, and 61%, respectively^[55]. Similarly, simulations of 10000 Chinese CHC patients over a lifetime horizon predicted that various DAA regimens would significantly reduce the incidence of HCV-related liver sequelae and mortality compared to PR therapy^[56,57]. These simulations took into consideration the composition of different HCV genotypes, treatment history and cirrhotic status of the patient population, thus, pan-genotypic regimens (SOF/VEL and GLE/PIB) were predicted to achieve higher overall SVR rates and greater reduction in disease progression than genotype-specific DAA regimens (Table 2)^[56,57].

Extrahepatic manifestations

Besides the direct impact on the liver, HCV-infected patients may experience liver-unrelated symptoms that, depending on epidemiological evidence, are considered extrahepatic manifestations (EHMs) associated or possibly associated with HCV infection^[58,59]. The most documented EHMs are mixed cryoglobulinemia/cryoglobulinemic vasculitis and B-cell non-Hodgkin's lymphoma. A diverse range of other conditions also occur at higher prevalence in HCV-infected patients, including type 2 diabetes mellitus, renal diseases, fatigue, cardiovascular disease, and lichen planus (LP), to name a few^[58]. EHMs can occur in > 70% of CHC patients, and can be present before advancement into ESLD^[59]. Underlining the impact of EHMs on HCV patients, a Taiwanese study reported a cumulative 18-year EHM-related mortality of 19.8% in patients with chronic HCV infection, much higher than the non-liver-related mortality in those without HCV infection (12.2%)^[60]. Published studies on EHMs in China are few, and there is currently a lack of clinical data on the prevalence and management of EHMs among Chinese patients^[61].

A recent meta-analysis investigated the extrahepatic benefit of antiviral treatment and SVR in HCV patients^[62]. Achieving SVR significantly reduced extrahepatic mortality (*vs* no SVR, OR 0.44, 95% CI: 0.28–0.67), was associated with improvements in cryoglobulinemic vasculitis and B-cell lymphoproliferative diseases, and reduced the incidence of insulin resistance and diabetes^[62]. Concordantly, IFN-based treatment

Table 1 Clinical efficacy of direct acting antiviral in major empirical studies in China

Study Information	Study regimen	SVR12	Ref.
Pivotal phase 3; TN patients; GT1b	DCV + ASV	Non-cirrhotic: 92% Cirrhotic: 94%	[45]
Pivotal phase 3b; TN and TE patients; GT1, 2, 3, 6	SOF + RBV ± PEG-IFN	Non-cirrhotic GT1/2/3/6: 96%/93%/97%/100% Cirrhotic GT1/2/3/6: 84%/88%/88%/50% (GT6 with cirrhosis: <i>n</i> = 2)	[49]
Pivotal phase 3b; TN and TE patients; GT1b	LDV/SOF	100%	[46]
Pivotal phase 3; TN and TE patients; GT1b, 2, 3, 6	SOF/VEL	GT1b/2/3/6: 100%/100%/83%/100% (Subgroup SVR12: GT3a: 91%; GT3b non- cirrhotic/cirrhotic: 96%/50%)	[50]
Pivotal phase 3; TN patients; GT1, 6	EBR/GZR	GT1/6: 97%/80% (GT1: 140/146 patients were GT1b; GT6: <i>n</i> = 5)	[48]
Pivotal phase 3; TN and TE patients; GT1b	O/P/r + D	99%–100%	[47]
Prospective cohort; TE; GT1b	SOF + DCV	100% (SVR24)	[53]
	LDV/SOF	100% (SVR24)	
	PEG-IFN + RBV	28% (SVR24)	
Real-world study; TN and TE HCV patients with DCC	SOF-containing regimens	90%; with significant improvement in hepatic function among SVR patients	[54]

ASV: Asunaprevir; DCC: Decompensated cirrhosis; DCV: Daclatasvir; EBR: Elbasvir; GT: Genotype; GZR: Grazoprevir; HCV: Hepatitis C virus; LDV: Ledipasvir; O/P/r + D: Ombitasvir/paritaprevir/ritonavir plus dasabuvir; PEG-IFN: Pegylated-interferon; RBV: Ribavirin; SOF: Sofosbuvir; SVR: Sustained virologic response; TE: Treatment experienced; TN: Treatment naïve; VEL: Velpatasvir.

induced favorable immunologic response in Chinese cryoglobulinemic patients with HCV infection, and IFN-based SVR reduced the risk for type 2 diabetes mellitus among Japanese HCV patients^[63,64]. Of note, IFN-based treatment may exacerbate symptoms of cryoglobulinemic vasculitis, likely due to the immune-stimulatory effects of IFN^[65,66]. IFN also induces lichenoid inflammation, and is thus contraindicated to LP^[66].

Emerging data support the extrahepatic benefit of successful DAA treatment for HCV patients^[67]. In two prospective studies on patients with HCV-related mixed cryoglobulinemia, SOF-based regimens conferred 100% SVR rates and clinical improvement or resolution of mixed cryoglobulinemia-associated vasculitis^[68,69]. In a retrospective study on 46 CHC patients with lymphoproliferative disorders, DAA treatment (mostly SOF-based) achieved an SVR rate of 98%, together with a lymphoproliferative disease response rate of 67% and survival benefit^[70]. In a prospective Japanese study, 7 patients with HCV-related oral LP all achieved resolution or improvement of oral LP lesions and cutaneous LP upon DAA-based SVR^[71].

In short, existing data on DAAs are in line with data from the IFN era, showing that SVR attainment aids the amelioration of HCV-associated EHMs. While further research is needed on the effect of DAAs on EHMs, the higher virologic efficacy, fewer side effects, and shorter treatment durations of DAAs would likely amplify the health benefit of reducing disease burden associated with extrahepatic complications^[67].

Prevention of HCV transmission

Effective treatment of diagnosed patients is an integral part of a comprehensive approach to preventing HCV transmission, which also requires public education to raise disease awareness and efficient screening and linkage to care^[72]. HCV prevention strategies also need to be aligned with the predominant mode of transmission^[72].

There is substantial regional variation in risk factors for HCV infection in China. In regions outside Southern China, blood transfusion is the major route of HCV transmission, accounting for 57.5%–69.3% of existing HCV-infected patients. Infection through surgery or dental treatment is more common in Northern China than in other areas, whereas HCV transmission *via* high-risk behavior such as intravenous drug abuse is more prevalent in Southern and Western China^[10]. Within each broad geographical region, the modes of HCV transmission may also show urban–rural

Table 2 Model predicted long-term clinical outcomes of using direct acting antivirals in China

Study Information	Regimens compared	Predicted reduction in liver sequelae relative to PR therapy			
		DCC	HCC	Liver transplant	Liver-related death
Simulating 10000 Chinese CHC patients over a lifetime horizon; GT1b, 2, 3, 6	GLE/PIB ^[57]	-95%	-90%	-95%	-92%
	SOF/VEL ^[56,57]	-96%	-91%	-96%	-93%
	DCV + ASV ^[56]	-51%	-48%	-51%	-49%
	O/P/r + D ^[56]	-59%	-55%	-59%	-57%
	EBR/GZR ^[56]	-59%	-55%	-59%	-57%

ASV: Asunaprevir; CHC: Chronic hepatitis C; DCC: Decompensated cirrhosis; DCV: Daclatasvir; EBR: Elbasvir; GT: Genotype; GZR: Grazoprevir; HCC: Hepatocellular carcinoma; O/P/r + D: Ombitasvir/paritaprevir/ritonavir plus dasabuvir; PR: Pegylated-interferon plus ribavirin; RBV: Ribavirin; SOF: Sofosbuvir; VEL: Velpatasvir.

differences. Current HCV prevention measures in China include screening of all blood donors, as well as harm reduction services for high-risk groups like injection drug users (IDUs)^[3,73].

In addition to existing prevention measures, treating HCV infection with highly effective therapy can function as a prevention strategy [treatment as prevention, TasP] by essentially removing individuals in key populations from the pool of transmitters. Numerous TasP modelling studies predicted that HCV treatment of sufficient effectiveness and accessibility would help reduce the incidence and chronic prevalence of HCV infection among IDUs, prisoners, and men who have sex with men (MSM)^[74]. For example, in Melbourne, with HCV prevalence among IDUs at 50%, increasing uptake of DAA treatment to 40 per 1000 IDUs annually is expected to halve HCV prevalence rates within 15 years; while scaling up treatment to 54 per 1000 IDUs annually could cut prevalence rates by as much as 75%^[75].

Empirical evidence verifying these positive projections are currently scarce, but some real-world programs are underway, reflecting confidence in the potential of HCV TasP. In Australia, a world-first HCV surveillance and treatment program assessing the use of SOF/VEL for HCV TasP in prisons is expected to be completed by 2019^[76]. Notably, high real-world efficacy of SOF/VEL has been demonstrated among HCV-infected, treatment-adherent IDUs with recent injection, lending confidence to the notion that treatment scale-up and adherence management would effectively control HCV transmission among IDUs^[77]. In 2016, Iceland (with a population of 340000) launched the nationwide program of Treatment as Prevention for Hepatitis C ("TraP Hep C"), offering universal access to DAAs for HCV-infected patients, with an emphasis on treating high-risk transmitters such as IDUs^[78]. International guidelines also recognized the benefit of reduced transmission with successful HCV treatment^[1,2,79]. Guidelines by the European Association for the Study of the Liver and the WHO further highlighted that HCV screening and treatment should be prioritized in individuals at high-risk of transmitting HCV such as IDUs^[2,79].

With the regional variations in HCV epidemiology in China, tailored strategies at the provincial or even district/city level will be necessary for HCV prevention and control^[80]. Suitable measures targeting specific modes of transmission will facilitate HCV 'micro-elimination' within certain populations: such is the strategy adopted by many countries for HCV elimination, and can form part of a realistic approach in China towards accomplishing the goals in the National Viral Hepatitis Action Plan^[14]. In particular, China has a documented IDU population of 2.95 million, among whom the estimated HCV prevalence is 50.4%^[81,82]. In this key population, efficacious HCV treatments, together with targeted education campaigns, continued harm reduction measures, and efficient diagnosis and linkage to care, would be required to reduce the prevalence and transmission of HCV^[14,15].

ECONOMIC AND SOCIETAL VALUE OF CURING HCV INFECTION

As illustrated in the WHO 2018 guidelines, HCV control strategies are formulated based on not only the clinical efficacy of treatment options, but also their cost-effectiveness and the broader value and benefits they bring to patients and society^[5]. Curing HCV infection can generate economic and societal value on many fronts, depending on the efficacy, safety, and other characteristics of the treatment options

used. **Figure 2** provides an overview of the main factors contributing to the economic and societal value of DAA- and IFN-based HCV treatment. It is challenging for any existing value assessment model to incorporate all the factors shown in **Figure 2**; the following sections seek to provide relevant information in these areas to enable a holistic discussion on the value of curing HCV infection.

Significance of economic and societal burden of CHC

Costing studies on the management of CHC generally found that more advanced disease stages are associated with higher medical costs, which constitute a financial burden to patients, healthcare systems, and society^[83,84]. Within the CHC population in China, nearly a quarter are hospitalized at least once per year with a median duration of 2 wk^[85]. Since later disease stages are costlier, treatment delay would lead to increased future costs associated with disease progression. A modelling study in China captured such a scenario and highlighted the impact of treatment delay on younger patients who, with a longer life expectancy, would incur higher life-time disease management costs than older patients with a similar initial disease state^[86]. With a 3-year treatment deferment, the projected cost for managing future ESLD in non-cirrhotic patients aged 40 increased from RMB 4407359 to RMB 7997253, while the corresponding cost increment for non-cirrhotic patients aged 70 was from RMB 2091499 to RMB 5565547^[86]. At the population level, more cases of cirrhosis and HCC would occur as CHC patients age, leading to higher healthcare costs in the future^[87]. China faces both an increasing population of younger, incident patients and an aging population of prevalent patients^[9-11]. Without effective treatment, it was predicted that over the next 15 years, 420000 new cases of HCV-related cirrhosis and 254000 new cases of HCV-related HCC would occur, leading to future treatment costs of 589 million and 611 million dollars respectively (**Figure 3**)^[8,88].

Besides the cost of managing liver-related morbidity of CHC, economic burden also arises from HCV-associated EHMs. In a meta-analysis of 102 studies conducted between 1996 and 2014, the annual medical costs of managing EHMs, in 2014 dollars, amounted to approximately \$1.5 billion^[89]. Therefore, curing HCV would also be expected to reduce the cost of managing EHMs as well as preventing expensive long-term liver morbidities.

In addition to direct costs related to CHC management, the growing involvement of younger, work age HCV patients in China also poses a broader societal issue^[11,84]. HCV patients may suffer from fatigue, low energy, and impaired general health; the resultant impairment of work productivity would have repercussions on the financial and psychological well-being of the HCV-infected young individuals and their families^[89]. Employers of HCV-infected individuals would also face reduced output and earnings due to loss of worker productivity, in the forms of absenteeism and presenteeism^[90]. Based on a modelling study in HCV GT1-infected Chinese patients, the monetized productivity losses resulting from non-treatment amount to RMB 37.78 billion per year^[91].

By effectively curing HCV infection, HCV therapeutic innovation would help alleviate the heavy economic and societal burdens caused by CHC, yet such innovation would require upfront investments. To determine which treatment strategy offers the best “value for money” (cost-effectiveness), health economic models are used to weigh the costs of different HCV treatment options against their long-term cost savings.

Cost-effectiveness considerations in HCV treatment

Health economic analysis in HCV predominantly focuses on the direct medical costs of managing HCV. As discussed previously, more advanced disease stages are associated with higher medical costs, and patients who achieve SVR have lower probabilities of progressing to the later, costlier disease stages. Thus, in theory, more effective HCV treatments should save more on long-term medical costs by avoiding disease progression in more patients. Health economic models evaluate the costs thus saved, along with the benefits of life extension and improved quality of life, against the upfront investments needed for implementing certain treatment methods. Currently, health economic research on HCV treatment in China is expanding rapidly. Emerging health economic analysis results from China will be introduced, together with analyses from countries with more experience using DAAs, to evaluate the potential costs and benefits associated with upfront investments in HCV treatment innovation.

In health economic analysis, the gain in patients’ quantity and quality of life achieved using a certain treatment is measured in quality-adjusted life years (QALYs), and the incremental cost-effectiveness ratio (ICER) measures the cost needed to achieve a unit gain in QALYs; if the ICER of a treatment is below the willingness-to-pay threshold, it is considered cost-effective. In a systematic review of health

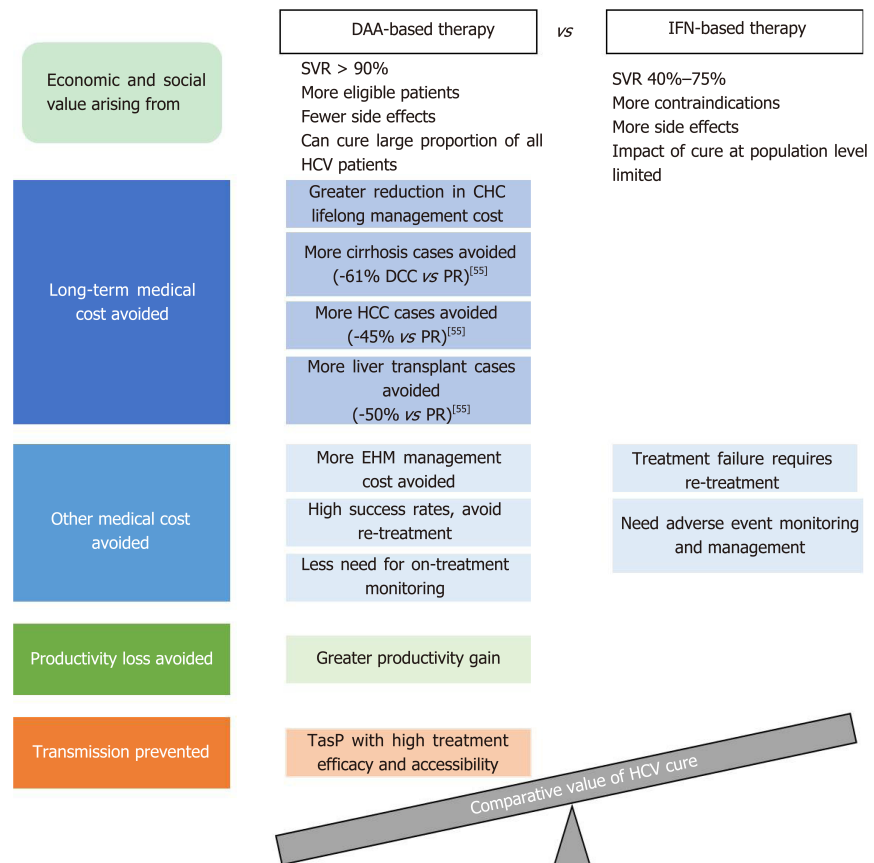


Figure 2 Main factors contributing to the comparative economic and societal value of direct acting antiviral- and interferon-based treatment for hepatitis C virus infection. Predicted relative percentage reductions in decompensated cirrhosis, hepatocellular carcinoma, and liver transplant: as reported in Wu *et al*^[55], 2019. CHC: Chronic hepatitis C; DAA: direct acting antiviral; DCC: Decompensated cirrhosis; EHM: Extrahepatic manifestation; HCC: Hepatocellular carcinoma; HCV: Hepatitis C virus; IFN: interferon; PR: Pegylated-interferon plus ribavirin; SVR: Sustained virologic response; TasP: Treatment as prevention.

economic studies in the United States, Europe, and Australia, second-generation DAAs, compared to first-generation DAAs, PR therapy, or non-treatment, were shown to be either cost-saving or cost-effective in the majority of the analyses as judged by the ICERs calculated^[92]. Furthermore, a modelling analysis in the United States compared various second-generation DAA regimens for treating GT1 patients; the results predicted that a treatment strategy of 8-wk LDV/SOF for GT1, treatment-naïve (TN), non-cirrhotic patients with a viral load less than 6 million copies, and SOF/VEL for all other GT1 patients was the most cost-effective strategy, resulting in 35% fewer cases of advanced liver disease events, with up to 57% reduction in cost per SVR relative to the other comparator regimens^[93].

Moving beyond the conventional methodology using ICERs, recent health economic studies devised other indicators to better elucidate the economic value of HCV therapies, by monetizing QALYs gained so that they can be directly compared against the costs of treatment. A United States economic model study in HCV GT1 patients predicted that all-oral therapies, in relation to PR therapy, improved health by 1.622 QALYs per patient, thereby leading to an overall decrease of 32730–500599 dollar in quality-adjusted cost of care, which was defined as the increase in the price of treatment minus the increase in the value of the patient's expected QALYs when valued at 50000–300000 dollar per QALY^[94].

Unlike the abovementioned counties and regions, China is still early in its transition from IFN to DAA-based regimens. Health economic studies in China are fast emerging, mostly focused on comparing DAA regimens with IFN-based treatments, reflecting an acute need for cost-effectiveness data to inform potential health technology assessment decisions at this stage. The DCV + ASV regimen was predicted to be more or comparably cost-effective relative to IFN- or RBV-containing regimens in GT1b patients in two analyses^[95,96]; an SMV-containing regimen was also predicted to be more cost-effective than PEG-IFN-based therapy in GT1 patients^[97].

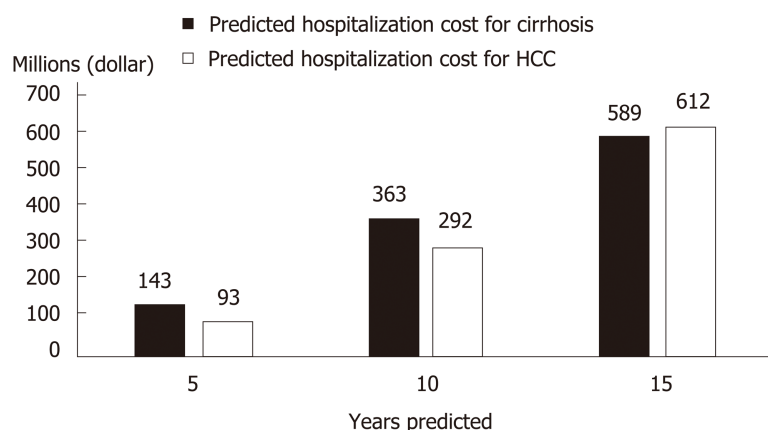


Figure 3 Projected chronic hepatitis C-related medical costs in China in the absence of effective hepatitis C virus treatment. Estimation based on annual data (2005–2013) of hepatitis C virus infection cases from the Chinese Center for Disease Control and Prevention; graph generated using data reported in Wei *et al*^[88], 2015. HCC: Hepatocellular carcinoma.

Another study predicted that compared to PR, O/P/r + D would be cost-saving in GT1b patients, and SOF + RBV cost-effective in GT2/3 patients and cost-saving in GT6 patients, respectively^[98]. One of the aforementioned studies simulating 10000 Chinese CHC patients with various HCV genotypes predicted that all the then-available second-generation DAA regimens (DCV + ASV, O/P/r + D, SOF/VEL, and EBR/GZR) would have cost-effectiveness advantages over PR therapy, with the pan-genotypic SOF/VEL conferring the greatest gain in QALYs (by 17%) and reduction in lifetime cost (by 49%) relative to PR^[56]. Among genotype-specific DAA regimens, one study predicted that for GT1b Chinese patients stratified by cirrhosis status and treatment history, EBR/GZR would be more cost-effective than DCV + ASV^[99].

Cost-effectiveness analyses derived from a real-world prospective cohort predicted that for Chinese GT1b cirrhotic, PR-experienced patients, 12-wk LDV/SOF and 12-wk SOF+DCV would be cost-saving and cost-effective, respectively, compared to repeated PR treatment for 72 wk^[53]. Analyzing real-world data from the PR era, a Taiwanese study reported that the costs per SVR for PR treatment were the highest in GT1/6 patients co-infected with HIV, due to low SVR rates in these populations; EBR/GZR, though more expensive than PR, would theoretically offer similar costs per SVR thanks to significantly higher SVR rates^[100]. These two studies highlight the value of DAAs for traditional difficult-to-treat patient populations, and illustrate how the benefit of short treatment durations and high efficacy can offset the impact of high drug price for DAAs to maintain favorable cost-effectiveness profiles. Furthermore, two budget impact studies, from Hong Kong and three cities in Mainland China respectively, both predicted that although subsidizing DAAs would incur additional short-term drug costs, the resultant gain in patients' health benefit and the avoidance of long-term disease management costs would be desirable^[101,102].

Besides the factor of avoiding disease progression-associated long-term costs of HCV sequelae, health economic models take into account additional factors contributing to cost of care^[94]. For PR therapy, such additional factors include the costs of monitoring and managing adverse events, and of re-treating patients who failed or discontinued the treatment^[4]. With a high incidence of adverse events and the need for frequent monitoring, PR treatment can negatively impact patients' quality of life (which will be discussed in a later section), resulting in lower QALY gains compared to DAA treatment. DAA therapy with its better safety and efficacy profiles can avoid such costs altogether if used as a first-line treatment. Indeed, one study predicted that for treatment-naïve Chinese GT1 patients, treatment with all-oral DAA regimens, either immediate or with a 1-year delay, would generate positive net monetary benefits of 6832 dollar and 3115 dollar, respectively, compared to immediate PEG-IFN-based treatment, at a willingness-to-pay threshold of 21209 dollar per SVR^[103]. On the other hand, certain DAA therapies may incur costs associated with genotype/subtype or baseline resistance testing; such costs could be avoided with the application of pan-genotypic DAA regimens and regimens with high resistance barrier. Further studies would be required to fully elucidate the costs and savings associated with different DAA regimens in this respect.

In summary, modelling analyses conducted in the United States, Europe, and high-

income Asian countries thus far have suggested that DAAs are likely to be cost effective compared to conventional IFN-based therapies; emerging health economic evidence in China is in line with these international findings. DAA regimens are easy to use, of shorter treatment duration, and requiring less monitoring than IFN-based therapy; the management cost thus saved, together with the long-term saving in CHC-related medical cost, would likely outweigh the upfront investment in DAAs. This is consistent with the WHO's recommendation, whereby treatment regimens with better tolerability and safety profiles that simplify the care pathway would be preferred by patients and policy makers, which may also facilitate care coverage expansion and equity in treatment access^[5].

Societal value of HCV treatment

The health economic analyses discussed above focus mostly on medical costs and do not capture the societal value of curing HCV. As will be discussed here, the additional potential benefits of curing HCV, such as improved productivity in Chinese workers and reduced HCV transmission, would further offset the upfront investment in HCV treatment.

Reduced productivity impairment has been predicted in Asian CHC patients with successful HCV treatment (Figure 4)^[104]. Hence, introduction of therapies with high SVR rates in China would likely improve work productivity among Chinese CHC patients, and in turn ameliorate the financial burden of HCV infection at an individual and family level. The resulting economic stability within a family unit owing to attainment of HCV cure could be of great benefit to China's societal fabric.

From the employer standpoint, improved worker productivity increases revenue generation^[104]. A modelling study in HCV GT1-infected Chinese patients showed that treatment with SOF/VEL would generate annual productivity gains equivalent to RMB 11.37 billion, mainly driven by reduced presenteeism (Figure 4C)^[91]. The consideration of presenteeism in addition to absenteeism in the model is a more accurate representation of the actual reduction in productivity impairment in the context of Asian culture that values stoic industriousness.

Besides work productivity, another aspect typically not captured in health economic analyses is the benefits of stopping onward transmission through effective HCV treatment in key populations. Based on projections from a modelling study in the UK, at 10%–100% treatment uptake among IDUs and cost of GBP 20000 per QALY, reduced HCV transmission with DAA therapy led to an additional net monetary benefit of GBP 24304–90559 per patient^[105]. One modelling study in China estimated the cost associated with HCV management in IDUs at RMB 21900 per patient per year^[82]. With a predicted 20-year cumulative HCV incidence in 48.28% of IDUs, effective TasP in IDUs in China would conceivably translate into considerable societal and economic values^[82].

In summary, effective HCV treatment can benefit society through improving working productivity and reducing HCV transmission. As reflected in the modelling studies above, such benefits would translate into tremendous value in addition to the economic benefit of reducing medical costs.

PATIENTS' EXPERIENCE WITH HCV TREATMENT

While SVR is the main clinical indicator of HCV treatment success, a patient's overall experience with the disease and the treatment process can be captured by patient reported outcomes (PROs). PROs are directly reported by patients without interpretation by HCPs and are used as proxy indicators of patients' overall wellbeing. As mentioned earlier, HCV patients often experience debilitating fatigue and impairment to work productivity and non-work activities^[89]. HCV infection also causes neuropsychiatric manifestations such as "brain fog", whereby patients suffer from difficulty in attention and memory, alongside other cognitive impairments^[106]. Clearly, HCV infection and its systemic manifestations negatively impact patients' health-related quality of life (HRQoL)^[89,106]. As such, the importance of assessing PROs in HCV management has gained considerable attention internationally over the past decade^[107,108]. PRO data can also contribute to informing healthcare policy making^[109]. Patients' demographic characteristics and cultural background may influence how they perceive and report their conditions; thus country-specific PRO data would be important for an accurate understanding of the impact of the disease^[4].

Multiple PRO instruments can be used to assess HCV patients' HRQoL, which typically assess patients' conditions in several aspects, or domains; the outcomes are reported using domain and summary scores (Supplementary Table 1).

HCV disease burden in China as reflected in PRO data

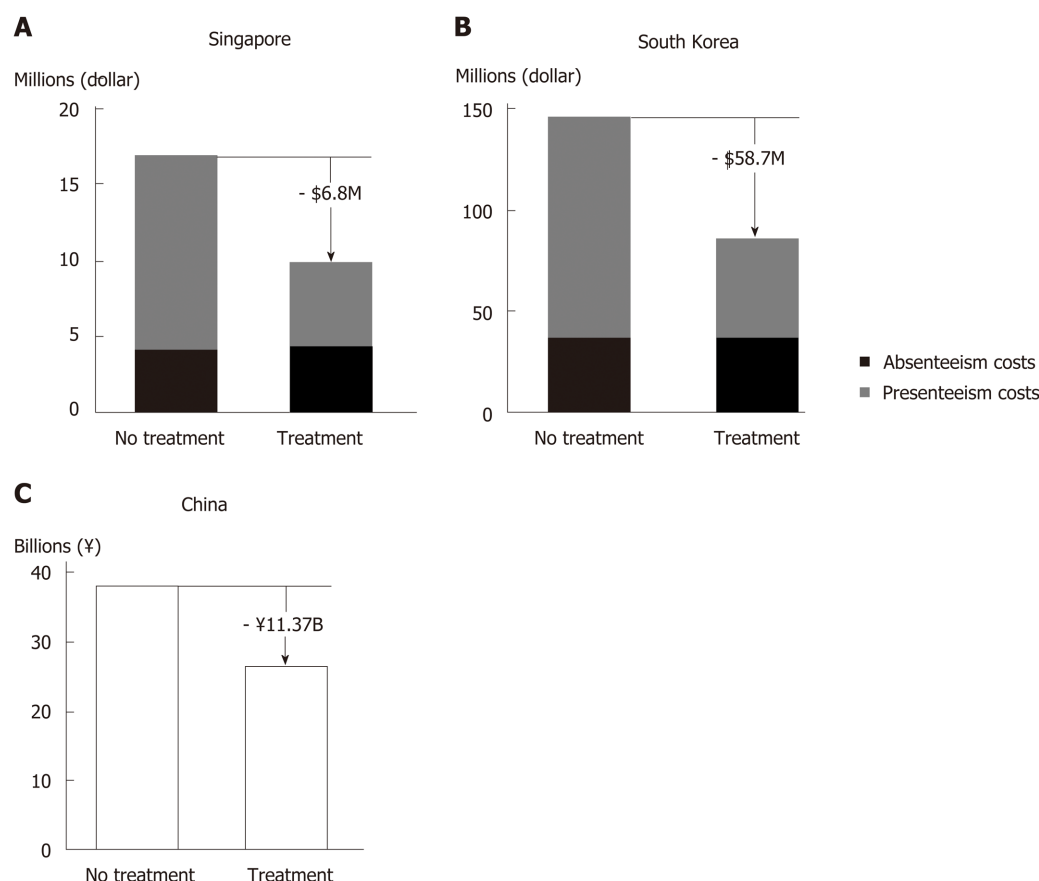


Figure 4 Predicted reduction in hepatitis C virus-related productivity loss with direct acting antiviral treatment. Compared to no treatment, direct acting antiviral treatment for GT1 hepatitis C virus patients was predicted to reduce productivity loss in Singapore, South Korea (A and B: Adapted with permission from Younossi *et al.*^[104], 2017) and China (C: Graph generated using data reported in Ye *et al.*^[91], 2018); modelling was over a one-year time horizon.

HCV infection negatively impacts patients' health and quality of life throughout the disease stages. Evidence indicates that there is already measurable damage to HRQoL in asymptomatic or undiagnosed patients with HCV infection^[110]. PRO measurements deteriorate further as the disease progresses to more severe and advanced stages, as reported by studies from Thailand and Japan^[111,112].

In China, studies on PROs in HCV patients have been scarce. Nevertheless, existing data showed that impairment in quality of life contributes to the disease burden of HCV infection. As part of the nationwide CCgenos study, cross-sectional data collected in 2011 from 997 untreated patients with chronic HCV infection reported a mean Euro-QoL 5 Dimensions descriptive score of 0.780/1^[113]. The percentage of patients reporting moderate or severe problems was about 34% for both the domains of pain/discomfort and anxiety/depression, and 7%–8% for the domains of mobility and usual activities^[113]. Similarly, results from local studies in rural Liaoning and Beijing using the Short Form-36 (SF-36) and/or the Chronic Liver Disease Questionnaire (CLDQ) scales revealed low quality of life among CHC patients^[114,115]. In a community-based survey of CHB and CHC patients in Shanghai using the Quality of Life Instruments for Chronic Disease-Chronic Hepatitis and the Family Burden Interview Schedule, multivariable analyses identified HCV infection and elevated serum alanine aminotransferase level as direct risk factors negatively impacting both the patients' quality of life and the burden on their caregivers^[116]. Clearly, the wellbeing and quality of life of Chinese HCV patients and caregivers are adversely affected by the disease, calling for closer attention to patient experience in HCV management.

Impact of different HCV treatment regimens on patient experience

To understand how treating and curing HCV infection can affect patients' experience and wellbeing, PROs are typically measured pre-treatment, at different time points during treatment, at the end of treatment (EoT), and 12 or 24 wk post-treatment.

Impact of PR therapy on PROs: PR therapy is known to cause on-treatment

deterioration in PROs due to side effects of and intolerance to the regime. A cross-sectional study in Taiwan reported that CHC patients on PR treatment ($n = 108$) scored significantly lower than untreated CHC patients on some of the SF-36 and CLDQ scales^[117]. Illustrating the on-treatment PRO impairment more clearly, another Taiwanese study involving 47 PR-treated CHC patients showed that by treatment week 12, the patients' mean scores for all 8 SF-36 domains decreased significantly from baseline^[118].

Upon PR treatment completion, PRO parameters would return to pre-treatment levels, or improve further upon treatment success. In the afore-mentioned study of 47 PR-treated patients, the SF-36 domain scores of those who achieved SVR ($n = 21$) improved significantly over baseline by week 24 post-treatment. In contrast, the domain scores of non-SVR patients ($n = 26$), though recovered from treatment week 12 to pre-treatment level by EoT, did not improve further post-treatment^[118]. A study in Guangzhou involving 72 CHC patients treated with PR reported that by EoT and similarly at week 24 post-treatment, patients' quality of life as measured by the Generic Quality of Life Inventory-74 questionnaire improved significantly over baseline, being significantly better than that of 30 untreated CHC patients at the same timepoints. This study did not report on-treatment QoL measurements or patients' SVR status^[119].

Impact of DAA regimens on PROs: Throughout the development of DAAs, various combination therapies have been studied and used, including DAA + IFN + RBV, DAA + RBV, and DAA-only regimens. For SOF-based regimens, PRO data collected from pivotal clinical studies in Western countries, Japan and other Asian regions (China, Hong Kong, Taiwan, South Korea and Vietnam) consistently demonstrated that for all three types of DAA combination therapy, achieving SVR12 was associated with post-treatment PRO improvement, although compared to PR-containing or IFN-free, RBV-containing regimens, DAA-only treatment offered better on-treatment patient experience^[120-124].

Specifically for HCV patients in China, pooled analysis of two phase 3 studies on SOF-based regimens showed that all three types of DAA combination therapy achieved high SVR12 rates (94.6%–100%)^[125]. Patients treated with SOF + IFN + RBV regimen showed marked HRQoL decrease from treatment week 2, and those treated with SOF + RBV experienced modest on-treatment HRQoL decline. For both groups, the HRQoL scores remained at trough level until EoT, before improving to and beyond pre-treatment levels^[125]. In contrast, the HRQoL scores of patients receiving DAA-only treatment (LDV/SOF) started to improve from treatment week 4, and continued improving during and after the treatment period^[125]. By week 12 post-treatment, the HRQoL scores of the LDV/SOF-treated group were significantly higher than those of the other two treatment groups^[125]. Considering the good safety profile and tolerability documented for SOF/VEL in clinical and real-world studies, SOF/VEL is likely to have beneficial effects on PROs, similar to LDV/SOF. Other non-SOF-based, DAA-only regimens have also generally been associated with stable on-treatment PRO profiles and PRO improvements at EoT or post-treatment^[126-130].

In summary, curing HCV infection is generally associated with improved patient experience and quality of life, irrespective of the therapy used. Again, the benefits availed by PR therapy are likely to be limited in the light of its low treatment success rate. In fact, poor adherence due to severe on-treatment HRQoL impairment is considered an important factor contributing to the low real-life SVR rates with PR therapy^[4]. IFN-containing DAA combination regimens can achieve high SVR rates, but like PR therapy, are associated with severe PRO impairment during treatment. IFN-free, RBV-containing DAA regimens lead to mild on-treatment PRO impairment. In contrast, DAA-only regimens can avoid such negative impact on patients, and can confer rapid, sustained improvements in PROs during and after treatment. In resource-limited settings or in difficult-to-treat patients, the use of IFN and/or RBV may be a pragmatic necessity. Nevertheless, the need to minimize on-treatment life quality deterioration and to optimize patient experience should be taken into consideration when choosing the appropriate treatment regimens for HCV patients, and DAA-only regimens have demonstrated added value in this respect.

REMAINING CHALLENGES AND FUTURE DIRECTIONS

Technical considerations in HCV management

In the DAA era, the goal of HCV elimination has become more realistic than ever. Nevertheless, there remain some challenges and important issues that deserve more attention in the management of HCV.

With existing pan-genotypic regimens, GT3 HCV tends to be more difficult to treat than the other genotypes. Both GLE/PIB and SOF + DCV require treatment duration extensions for certain subpopulations of GT3 patients, and SOF/VEL's drug label in China suggests the addition of RBV for GT3, cirrhotic patients^[5,131]. More research would be needed to optimize the treatment strategy for GT3 patients, especially in China where the proportion of GT3b subtype and the prevalence of baseline NS5A RASs are higher than in Western countries^[51,132].

Special attention needs to be paid to patients coinfecting with hepatitis B virus (HBV), which has a prevalence of 4.11% among HCV patients in China^[133]. HBV/HCV coinfecting patients not on active anti-HBV treatment should be monitored for potential HBV reactivation during and after DAA treatment^[5].

Patients who fail certain DAA regimens may develop treatment-emergent RASs, the transmission and accumulation of which could potentially cause public health issues. A study on HCV resistance in China by Huang *et al.*^[134] reported a significantly higher overall frequency of NS5A RASs in treatment-naïve GT1b patients in 2016 than in 2008 (42.0% *vs* 18.4%; *P* = 0.002). To minimize the risk of treatment-emergence RASs, it is important to select for initial treatment regimens with high resistance barriers (such as NS5B inhibitors), or to diligently conduct baseline RAS testing if planning to use regimens known to be prone to clinical resistance. SOF/VEL/VOX, the regimen reserved for rescue treatment of patients with DAA failures, is not yet available in China, but would likely be a valuable tool in the future as more and more Chinese patients undergo DAA treatments.

While DAAs offer high rates of virologic cure, the issue of HCV reinfection is coming increasingly into attention. High reinfection rates associated with high risk behaviors may hamper HCV elimination in key populations, such as IDUs and MSM. For patients prone to high-risk behavior, reinfection risk counseling and linkage to harm reduction services should be provided before and after HCV treatment, such as referring actively injecting IDUs to methadone substitution treatment or needle and syringe exchange programs, linking MSM to condom distribution programs, and other behavioral interventions where necessary^[135].

Besides curative therapies, another approach explored for facilitating HCV elimination is the development of prophylactic HCV vaccines. Faced with challenges ranging from the high genetic variability of HCV to a lack of appropriate animal model systems for efficacy evaluation, research in this area thus far has not met with success (for research progress on vaccine candidates, please refer to reviews by Ghasemi *et al.*^[136] and Yan *et al.*^[137]).

Value assessment and other considerations in healthcare policy making

In addition to the value aspects discussed in this article, there are other factors pertaining to curing HCV infection that, though not yet incorporated into value assessment models, obviously carry considerable importance for patients and society. For example, the hope of being cured and the removal of societal stigmatization would be valuable from individual patients' perspectives. Often, HCV patients are ostracized by the community and discriminated in the workplace. Individuals diagnosed with HCV infection may suffer from anxiety and fear, and some may feel hopeless and give up on seeking treatment. However, with the availability of highly effective DAA therapies, the possibility of achieving a complete cure with relatively short and well tolerated treatments would help alleviate the fear in many patients and contribute towards destigmatizing HCV infection. Another such example is the scientific "spill-over" effect, whereby introducing and investing in innovative treatment technology may stimulate future research for better understanding of HCV and advancement in HCV prevention and control. It could be worthwhile for Chinese researchers to explore how these aspects can be incorporated into novel value assessment models to better inform health technology assessment and public health policy making.

With the first DAA regimens approved in 2017 and the registration process expedited for innovative HCV medicines, China is undoubtedly shifting from the PR era towards that of DAAs for HCV treatment. In light of the principles set out in the 2017–2020 National Viral Hepatitis Action Plan and the goals of the Healthy China 2030 Plan, we would like to suggest that Chinese policy makers take further measures to improve the availability of, and enable large-scale access to, innovative HCV treatment, so as to capitalize fully on the value of effective HCV cure.

In order to maximize the benefits of highly effective HCV treatment, it would be essential to have as many HCV-infected patients as possible diagnosed and treated. The targets set out in the WHO Global Health Sector Strategy on viral hepatitis are that, by 2030, 90% of HCV-infected patients are diagnosed and 80% of those diagnosed receive HCV treatment^[5]. In this respect, efforts would be needed from Chinese policy makers and healthcare professionals to improve the public awareness

of HCV through continued education. Public health resources would also be needed to support the service coverage of HCV screening, diagnosis, and linkage to care. Specifically, targeted efforts and aids may be needed to ensure that the diagnosis and treatment needs are met in rural and less developed areas of China, and that HCV management capabilities can be enhanced in lower-tier hospitals and healthcare facilities.

CONCLUSION

The value of curing HCV infection extends far beyond the clinical endpoint of SVR. At patient level, achieving virologic cure improves the long-term health outcomes and quality of life. At society level, providing prompt and effective treatment can help avoid future HCV-related disease and financial burdens. As China stands on the threshold of the DAA era, it would be important for stakeholders and policy makers to consider, that when evaluated holistically, the long-term benefits associated with curing HCV infection would outweigh the initial investment needed for implementing effective HCV therapies.

ACKNOWLEDGEMENTS

The authors would like to thank Mei Kwan Chan, MSc and Bo Lyu, PhD (employees of Costello Medical, Singapore, funded by Gilead Sciences, Shanghai, China), for writing assistance and editorial support for the development of the manuscript. The authors are entirely responsible for the scientific content of this paper.

REFERENCES

- 1 **AASLD-IDSA.** Recommendations for testing, managing, and treating hepatitis C. 2017. Available from: https://www.hcvguidelines.org/sites/default/files/full-guidance-pdf/HCVGuidance_September_21_2017_e.pdf
- 2 **European Association for the Study of the Liver.** Electronic address: easloffice@easloffice.eu. EASL Recommendations on Treatment of Hepatitis C 2016. *J Hepatol* 2017; **66**: 153-194 [PMID: [27667367](#) DOI: [10.1016/j.jhep.2016.09.001](#)]
- 3 **Chinese Society of Hepatology, Chinese Medical Association.** Wei L; Chinese Society of Infectious Diseases, Chinese Medical Association, Hou JL. [The guideline of prevention and treatment for hepatitis C: a 2015 update]. *Zhonghua Gan Zang Bing Za Zhi* 2015; **23**: 906-923 [PMID: [26739465](#) DOI: [10.3760/cma.j.issn.1007-3418.2015.12.003](#)]
- 4 **Younossi ZM,** Tanaka A, Eguchi Y, Lim YS, Yu ML, Kawada N, Dan YY, Brooks-Rooney C, Negro F, Mondelli MU. The impact of hepatitis C virus outside the liver: Evidence from Asia. *Liver Int* 2017; **37**: 159-172 [PMID: [27748564](#) DOI: [10.1111/liv.13272](#)]
- 5 **World Health Organization.** Guidelines for the care and treatment of persons diagnosed with chronic hepatitis C virus infection. 2018. Available from: <https://www.who.int/hepatitis/publications/hepatitis-c-guidelines-2018/en/>
- 6 **World Health Organization.** WHO model list of essential medicines. 2017; Available from: http://www.who.int/medicines/publications/essentialmedicines/20th_EML2017_FINAL_amendedAug2017.pdf?ua=1
- 7 **Polaris Observatory HCV Collaborators.** Global prevalence and genotype distribution of hepatitis C virus infection in 2015: a modelling study. *Lancet Gastroenterol Hepatol* 2017; **2**: 161-176 [PMID: [28404132](#) DOI: [10.1016/s2468-1253\(16\)30181-9](#)]
- 8 **Chinese Foundation for Hepatitis Prevention and Control.** Report on the current status and prevention and treatment strategies for hepatitis C in China. Beijing: People's Medical Publishing House Co 2017; 3-5
- 9 **Duan Z,** Jia JD, Hou J, Lou L, Tobias H, Xu XY, Wei L, Zhuang H, Pan CQ. Current challenges and the management of chronic hepatitis C in mainland China. *J Clin Gastroenterol* 2014; **48**: 679-686 [PMID: [24921215](#) DOI: [10.1097/MCG.000000000000109](#)]
- 10 **Rao H,** Wei L, Lopez-Talavera JC, Shang J, Chen H, Li J, Xie Q, Gao Z, Wang L, Wei J, Jiang J, Sun Y, Yang R, Li H, Zhang H, Gong Z, Zhang L, Zhao L, Dou X, Niu J, You H, Chen Z, Ning Q, Gong G, Wu S, Ji W, Mao Q, Tang H, Li S, Wei S, Sun J, Jiang J, Lu L, Jia J, Zhuang H. Distribution and clinical correlates of viral and host genotypes in Chinese patients with chronic hepatitis C virus infection. *J Gastroenterol Hepatol* 2014; **29**: 545-553 [PMID: [24090188](#) DOI: [10.1111/jgh.12398](#)]
- 11 **Nie B,** Zhang K, Liu J, Guo Y, Tu Z. Prevalence of hepatitis C virus genotypes in China patients: a systematic review and meta-analysis. *Jiayuan Yixue Yu Linchuang* 2016; **13**: 2876-2881 [DOI: [10.3969/j.issn.1672-9455.2016.20.013](#)]
- 12 **National Health Commission of the People's Republic of China.** National essential drug list (2018). 2018; Available from: <http://www.gov.cn/fuwu/2018-10/30/5335721/files/e7473e46d9b24aad3eb25127f986.pdf>
- 13 **Lazarus JV,** Wiktor S, Colombo M, Thursz M; EASL International Liver Foundation. Micro-elimination - A path to global elimination of hepatitis C. *J Hepatol* 2017; **67**: 665-666 [PMID: [28760329](#) DOI: [10.1016/j.jhep.2017.06.033](#)]
- 14 **National Health Commission of the People's Republic of China.** Action plan for the prevention and treatment of viral hepatitis in China (2017-2020). 2017; Available from: <http://www.nhc.gov.cn/ewebeditor/uploadfile/2017/11/20171113134002475.pdf>

- 15 **CPC Central Committee, State Council of the People's Republic of China.** Healthy China 2030 blueprint. 2016; Available from: <http://www.nhc.gov.cn/zhuazhu/mtbd/201610/21d120c917284007ad9c7aa8e9634bb4.shtml>
- 16 **Chen SL, Morgan TR.** The natural history of hepatitis C virus (HCV) infection. *Int J Med Sci* 2006; **3**: 47-52 [PMID: 16614742]
- 17 **Yoshida H, Shiratori Y, Moriyama M, Arakawa Y, Ide T, Sata M, Inoue O, Yano M, Tanaka M, Fujiyama S, Nishiguchi S, Kuroki T, Imazeki F, Yokosuka O, Kinoyama S, Yamada G, Omata M.** Interferon therapy reduces the risk for hepatocellular carcinoma: national surveillance program of cirrhotic and noncirrhotic patients with chronic hepatitis C in Japan. IHIT Study Group. Inhibition of Hepatocarcinogenesis by Interferon Therapy. *Ann Intern Med* 1999; **131**: 174-181 [PMID: 10428733]
- 18 **Bennett H, Waser N, Johnston K, Kao JH, Lim YS, Duan ZP, Lee YJ, Wei L, Chen CJ, Sievert W, Yuan Y, Li H.** A review of the burden of hepatitis C virus infection in China, Japan, South Korea and Taiwan. *Hepatol Int* 2015; **9**: 378-390 [PMID: 26071238 DOI: 10.1007/s12072-015-9629-x]
- 19 **Baecker A, Liu X, La Vecchia C, Zhang ZF.** Worldwide incidence of hepatocellular carcinoma cases attributable to major risk factors. *Eur J Cancer Prev* 2018; **27**: 205-212 [PMID: 29489473 DOI: 10.1097/CEJ.0000000000000428]
- 20 **Fan JH, Wang JB, Jiang Y, Xiang W, Liang H, Wei WQ, Qiao YL, Boffetta P.** Attributable causes of liver cancer mortality and incidence in china. *Asian Pac J Cancer Prev* 2013; **14**: 7251-7256 [PMID: 24460283 DOI: 10.7314/APJCP.2013.14.12.7251]
- 21 **Pan YF, Zheng Y, Qin T, Feng L, Zhang Q, Ping XG, Pan YT, Wang XP, Bai L, Li HH.** Disease progression in Chinese patients with hepatitis C virus RNA-positive infection via blood transfusion. *Exp Ther Med* 2016; **12**: 3476-3484 [PMID: 27882182 DOI: 10.3892/etm.2016.3792]
- 22 **Lu J, Xiang X, Cao Z, Wang W, Zhao G, Tang W, Chen L, Guo S, Zhuang Y, Shi D, Chen L, Bao S, Cai W, Wang H, Zhou H, Xie Q.** Younger trend of cirrhosis incidence in genotype 3 HCV infected patients in Eastern China. *J Med Virol* 2017; **89**: 1973-1980 [PMID: 28671305 DOI: 10.1002/jmv.24894]
- 23 **Backus LI, Belperio PS, Shahoumian TA, Mole LA.** Impact of Sustained Virologic Response with Direct-Acting Antiviral Treatment on Mortality in Patients with Advanced Liver Disease. *Hepatology* 2019; **69**: 487-497 [PMID: 28749564 DOI: 10.1002/hep.29408]
- 24 **Backus LI, Belperio PS, Shahoumian TA, Mole LA.** Direct-acting antiviral sustained virologic response: Impact on mortality in patients without advanced liver disease. *Hepatology* 2018; **68**: 827-838 [PMID: 29377196 DOI: 10.1002/hep.29811]
- 25 **Carrat F.** First prospective evidence of decreased mortality after direct acting antivirals in the French ANRS CO22 HEPATHER cohort. *Hepatology* 2017; **66**: 1271A [DOI: 10.1002/hep.29634]
- 26 **Mangia A, Lawitz E, Gane E, Conway B, Ruane P, Abergel A, McNabb B, Osinusi A, Chen F, Dvory-Sobol H, Brainard D, Subramanian M, Leggett B, Panero JLC, Agarwal K, Younes ZH, Muir A.** Long-term follow-up of patients with chronic HCV infection and compensated or decompensated cirrhosis following treatment with sofosbuvir-based regimens. *J Hepatol* 2018; **68** Suppl 1: S67-S68 [DOI: 10.1016/S0168-8278(18)30356-8]
- 27 **Ogata F, Kobayashi M, Akuta N, Osawa M, Fujiyama S, Kawamura Y, Sezaki H, Hosaka T, Kobayashi M, Saitoh S, Suzuki Y, Suzuki F, Arase Y, Ikeda K, Kumada H.** Outcome of All-Oral Direct-Acting Antiviral Regimens on the Rate of Development of Hepatocellular Carcinoma in Patients with Hepatitis C Virus Genotype 1-Related Chronic Liver Disease. *Oncology* 2017; **93**: 92-98 [PMID: 28448999 DOI: 10.1159/000470910]
- 28 **Zhang CH, Xu GL, Jia WD, Li JS, Ma JL, Ge YS.** Effects of interferon treatment on development and progression of hepatocellular carcinoma in patients with chronic virus infection: a meta-analysis of randomized controlled trials. *Int J Cancer* 2011; **129**: 1254-1264 [PMID: 21710498 DOI: 10.1002/ijc.25767]
- 29 **Ji F, Dang S, Cai Z, Xue H, Huang N, Liu L, Zhang S, Guo Y, Jia X, Wang Y, Li Z, Deng H.** Antiviral treatment and long-term clinical outcome of decompensated cirrhotic patients with hepatitis C virus infection. *Zhonghua Gan Zang Bing Za Zhi* 2015; **23**: 647-652 [PMID: 26524356 DOI: 10.3760/cma.j.issn.1007-3418.2015.09.003]
- 30 **Xie ZW, Li JP, Guan YJ, Zhang XY, Guo FX, Chen BB, Pan CQ.** A clinical study of antiviral therapy for patients with compensated hepatitis C cirrhosis. *Zhonghua Gan Zang Bing Za Zhi* 2017; **25**: 827-833 [PMID: 29325276 DOI: 10.3760/cma.j.issn.1007-3418.2017.11.006]
- 31 **Lee MH, Huang CF, Lai HC, Lin CY, Dai CY, Liu CJ, Wang JH, Huang JF, Su WP, Yang HC, Kee KM, Yeh ML, Chuang PH, Hsu SJ, Huang CJ, Kao JT, Chen CC, Chen SH, Jeng WJ, Yang HI, Yuan Y, Lu SN, Sheen IS, Liu CH, Peng CY, Kao JH, Yu ML, Chuang WL, Chen CJ.** Clinical Efficacy and Post-Treatment Seromarkers Associated with the Risk of Hepatocellular Carcinoma among Chronic Hepatitis C Patients. *Sci Rep* 2017; **7**: 3718 [PMID: 28623331 DOI: 10.1038/s41598-017-02313-y]
- 32 **Lee SH, Jin YJ, Shin JY, Lee JW.** Assessment of hepatocellular carcinoma risk based on peg-interferon plus ribavirin treatment experience in this new era of highly effective oral antiviral drugs. *Medicine (Baltimore)* 2017; **96**: e5321 [PMID: 28072684 DOI: 10.1097/MD.00000000000005321]
- 33 **Ji D, Wang C, Shao Q, Li F, Li B, Wu V, Wong A, Wang YD, Chen J, Chen GF, Lau G.** No increase in the occurrence rate of hepatocellular carcinoma in Chinese treated by direct-acting antivirals compared to interferon after eradication of hepatitis C virus: a long-term follow-up. *J Hepatol* 2017; **66** Suppl 1: S23 [DOI: 10.1016/S0168-8278(17)30308-2]
- 34 **Simmons B, Saleem J, Heath K, Cooke GS, Hill A.** Long-Term Treatment Outcomes of Patients Infected With Hepatitis C Virus: A Systematic Review and Meta-analysis of the Survival Benefit of Achieving a Sustained Virological Response. *Clin Infect Dis* 2015; **61**: 730-740 [PMID: 25987643 DOI: 10.1093/cid/civ396]
- 35 **Ioannou GN, Green PK, Berry K.** HCV eradication induced by direct-acting antiviral agents reduces the risk of hepatocellular carcinoma. *J Hepatol* 2017 [PMID: 28887168 DOI: 10.1016/j.jhep.2017.08.030]
- 36 **Wei L, Lok AS.** Impact of new hepatitis C treatments in different regions of the world. *Gastroenterology* 2014; **146**: 1145-1150; e1-4 [PMID: 24662488 DOI: 10.1053/j.gastro.2014.03.008]
- 37 **Morgan RL, Baack B, Smith BD, Yartel A, Pitasi M, Falck-Ytter Y.** Eradication of hepatitis C virus infection and the development of hepatocellular carcinoma: a meta-analysis of observational studies. *Ann Intern Med* 2013; **158**: 329-337 [PMID: 23460056 DOI: 10.7326/0003-4819-158-5-201303050-00005]
- 38 **Pegasis® Prescribing Information.** South San Francisco, CA: Genentech United States, Inc., 2017
- 39 **Rebetol® Prescribing Information.** Whitehouse Station, NJ: Merck Sharp Cohme Corp, 2017
- 40 **Rao HY, Li H, Chen H, Shang J, Xie Q, Gao ZL, Li J, Sun Y, Jiang J, Wang L, Zhao L, Zhang L, Yang W, Niu J, Gong Z, Gong G, Yang R, Lee MH, Wei L.** Real-world treatment patterns and clinical outcomes

- of HCV treatment-naïve patients in China: an interim analysis from the CCgenos study. *J Gastroenterol Hepatol* 2017; **32**: 244-252 [PMID: 27289083 DOI: 10.1111/jgh.13467]
- 41 **Hu P**, Ren H. Current status of treatment of chronic hepatitis C and related challenges in the "Pre-DAA Era" in China. *Zhonghua Gan Zang Bing Za Zhi* 2016; **24**: 869-873 [PMID: 27978936 DOI: 10.3760/cma.j.issn.1007-3418.2016.11.015]
 - 42 **Nuño Solinis R**, Arratibel Ugarte P, Rojo A, Sanchez Gonzalez Y. Value of Treating All Stages of Chronic Hepatitis C: A Comprehensive Review of Clinical and Economic Evidence. *Infect Dis Ther* 2016; **5**: 491-508 [PMID: 27783223 DOI: 10.1007/s40121-016-0134-x]
 - 43 **Public Health England**. Hepatitis C in England: 2017 report. 2017. Available from: https://assets.publishing.service.gov.uk/government/uploads/system/uploads/attachment_data/file/599738/hepatitis_c_in_england_2017_report.pdf
 - 44 **Action Hepatitis Canada**. Treatment access update: Alberta, Saskatchewan, Manitoba, Yukon, and NIHB formularies all lift eligibility restrictions for hepatitis C treatment. 2018. Available from: <http://www.actionhepatitiscanada.ca/news.html>
 - 45 **Wei L**, Wang FS, Zhang MX, Jia JD, Yakovlev AA, Xie W, Burnevich E, Niu JQ, Jung YJ, Jiang XJ, Xu M, Chen XY, Xie Q, Li J, Hou JL, Tang H, Dou XG, Gandhi Y, Hu WH, McPhee F, Noviello S, Treitel M, Mo L, Deng J. Daclatasvir plus asunaprevir in treatment-naïve patients with hepatitis C virus genotype 1b infection. *World J Gastroenterol* 2018; **24**: 1361-1372 [PMID: 29599611 DOI: 10.3748/wjg.v24.i12.1361]
 - 46 **Wei L**, Xie Q, Hou JL, Tang H, Ning Q, Cheng J, Nan Y, Zhang L, Li J, Jiang J, McNabb B, Zhang F, Camus G, Mo H, Osinusi A, Brainard DM, Gong G, Mou Z, Wu S, Wang G, Hu P, Gao Y, Jia J, Duan Z. Ledipasvir/sofosbuvir for treatment-naïve and treatment-experienced Chinese patients with genotype 1 HCV: an open-label, phase 3b study. *Hepatol Int* 2018; **12**: 126-132 [PMID: 29637511 DOI: 10.1007/s12072-018-9856-z]
 - 47 **Wei L**, Cheng J, Luo J, Li ZP, Duan JL, Hou JD, Jia MX, Zhang Y, Huang Q, Xie GJ, Wang DL, Yang W, Zhao CY, Zhao G, Tang SM, Lin GZ, Gong JJ, Niu ZL, Gao JF, Sarah KB, Linda F, Niloufar M, Wang Y, Wang J. Efficacy and safety of paritaprevir/ritonavir/ombitasvir combined with dasabuvir in non-cirrhotic Asian adult patients with newly diagnosed and treated chronic HCV genotype 1b infection: a randomized, double-blind, placebo-controlled study - China data. *Zhonghua Gan Zang Bing Za Zhi* 2018; **26**: 359-364 [PMID: 29996204 DOI: 10.3760/cma.j.issn.1007-3418.2018.05.009]
 - 48 **Wei L**, Jia JD, Wang FS, Niu JQ, Zhao XM, Mu S, Liang LW, Wang Z, Hwang P, Robertson MN, Ingravallo P, Asante-Appiah E, Wei B, Evans B, Hanna GJ, Talwani R, Duan ZP, Zhdanov K, Cheng PN, Tanwadee T, Nguyen VK, Heo J, Isakov V, George J; C-CORAL Investigators. Efficacy and safety of elbasvir/grazoprevir in participants with hepatitis C virus genotype 1, 4, or 6 infection from the Asia-Pacific region and Russia: Final results from the randomized C-CORAL study. *J Gastroenterol Hepatol* 2019; **34**: 12-21 [PMID: 30311701 DOI: 10.1111/jgh.14509]
 - 49 **Wei L**, Xie Q, Hou JL, Jia J, Li W, Xu M, Li J, Wu S, Cheng J, Jiang J, Wang G, Yang Y, Mou Z, Gao ZL, Gong G, Niu JQ, Hu P, Tang H, Lin F, Dou X, Li L, Zhang LL, Nan Y, Massetto B, Yang JC, Knox SJ, Kersey K, German P, Mo H, Jiang D, Brainard DM, Jiang J, Ning Q, Duan Z. Sofosbuvir plus ribavirin with or without peginterferon for the treatment of hepatitis C virus: Results from a phase 3b study in China. *J Gastroenterol Hepatol* 2018; **33**: 1168-1176 [PMID: 29380415 DOI: 10.1111/jgh.14102]
 - 50 **Wei L**, Xie Q, Huang Y, Wu S, Xu M, Tang H, Cheng J, Gao Y, Mou Z, Dou X, Nan Y, Ning Q, Mao Y, Stamm L, Lu S, Dvory-Sobol H, Mo H, Brainard D, Yang Y, Wang G, Hu P, Zhang L, Gao Z, Lin F, Shang J, Gong G, Li J, Su M, Duan Z, Hou J, Jia J. Safety and Efficacy of sofosbuvir/velpatasvir in genotype 1-6 HCV-infected patients in China: Results from a phase 3 clinical trial. *Hepatology* 2018; **68** Suppl 1: 379A [DOI: 10.1002/hep.30257]
 - 51 **Wei L**, Lim SG, Xie Q, Văn KN, Piratvisuth T, Huang Y, Wu S, Xu M, Tang H, Cheng J, Le Manh H, Gao Y, Mou Z, Sobhonslidsuk A, Dou X, Thongsawat S, Nan Y, Tan CK, Ning Q, Tee HP, Mao Y, Stamm LM, Lu S, Dvory-Sobol H, Mo H, Brainard DM, Yang YF, Dao L, Wang GQ, Tanwadee T, Hu P, Tangkijvanich P, Zhang L, Gao ZL, Lin F, Le TTP, Shang J, Gong G, Li J, Su M, Duan Z, Mohamed R, Hou JL, Jia J. Sofosbuvir-velpatasvir for treatment of chronic hepatitis C virus infection in Asia: a single-arm, open-label, phase 3 trial. *Lancet Gastroenterol Hepatol* 2019; **4**: 127-134 [PMID: 3055048 DOI: 10.1016/s2468-1253(18)30343-1]
 - 52 **An Z**, Ding Y, Dou X. Selection and evaluation of treatment regimens with direct-acting antiviral agents for patients with chronic hepatitis C in the real world in China. *Linchuang Gan Dan Bing Za Zhi* 2018; **34**: 233-237 [DOI: 10.3969/j.issn.1001-5256.2018.02.003]
 - 53 **Ji D**, Chen GF, Wang C, Wang YD, Shao Q, Li B, Zhao J, You SL, Hu JH, Liu JL, Niu XX, Chen J, Lu L, Wu V, Lau G. Twelve-week ribavirin-free direct-acting antivirals for treatment-experienced Chinese with HCV genotype 1b infection including cirrhotic patients. *Hepatol Int* 2016; **10**: 789-798 [PMID: 27443347 DOI: 10.1007/s12072-016-9755-0]
 - 54 **Ji F**, Wang W, Dang S, Wang S, Li B, Bai D, Zhao W, Deng H, Tian C, Li Z. Outcomes after sofosbuvir-containing regimens for hepatitis C virus in patients with decompensated cirrhosis: a real-world study. *Infect Agent Cancer* 2017; **12**: 48 [PMID: 28924449 DOI: 10.1186/s13027-017-0158-1]
 - 55 **Wu J**, Zhou Y, Fu X, Deng M, Zheng Y, Tian G, Li Y, Wang C, Ding C, Ruan B, Yang S, Li L. The Burden of Chronic Hepatitis C in China From 2004 to 2050: An Individual-Based Modeling Study. *Hepatology* 2019; **69**: 1442-1452 [PMID: 30561833 DOI: 10.1002/hep.30476]
 - 56 **Tang H**, Wu J, Wu B, Xu X, Ye X, Zhang W. Long-term outcomes associated with sofosbuvir-based regimens for treatment of chronic hepatitis C in China. *Value Health* 2018; **21** Suppl 2: S65 [DOI: 10.1016/j.jval.2018.07.488]
 - 57 **Wu J**, Wu B, Xu X, Ye X, Zhang W. Long-term health outcomes of pan-genotypic direct-acting antiviral treatment of chronic hepatitis C in China. *Hepatol Int* 2019; **13** Suppl 1: S93 [DOI: 10.1007/s12072-019-09936-5]
 - 58 **Cacoub P**, Gragnani L, Comarmond C, Zignego AL. Extrahepatic manifestations of chronic hepatitis C virus infection. *Dig Liver Dis* 2014; **46** Suppl 5: S165-S173 [PMID: 25458776 DOI: 10.1016/j.dld.2014.10.005]
 - 59 **van der Meer AJ**. Association between antiviral treatment and extrahepatic outcomes in patients with hepatitis C virus infection. *Gut* 2015; **64**: 364-366 [PMID: 25601636 DOI: 10.1136/gutjnl-2014-308745]
 - 60 **Lee MH**, Yang HI, Lu SN, Jen CL, You SL, Wang LY, Wang CH, Chen WJ, Chen CJ; R. E. V. E. A. L. -HCV Study Group. Chronic hepatitis C virus infection increases mortality from hepatic and extrahepatic diseases: a community-based long-term prospective study. *J Infect Dis* 2012; **206**: 469-477 [PMID: 22811301 DOI: 10.1093/infdis/jis385]

- 61 **Wang W**, Yang Y, Dang S. Current status of research in extrahepatic manifestations of HCV infection. *Gan Zang* 2018; **23**: 6-8
- 62 **Cacoub P**, Desbois AC, Comarmond C, Saadoun D. Impact of sustained virological response on the extrahepatic manifestations of chronic hepatitis C: a meta-analysis. *Gut* 2018; **67**: 2025-2034 [PMID: 29703790 DOI: 10.1136/gutjnl-2018-316234]
- 63 **Zhang JJ**, Li XH, Su ZY, Cao CR. Changes of quality of life after antiviral therapy in patients with chronic hepatitis C and cryoglobulinemia. *Zhongguo Linchuang Yanjiu* 2016; **29**: 440-443 [DOI: 10.13429/j.cnki.cjcr.2016.04.003]
- 64 **Arase Y**, Suzuki F, Suzuki Y, Akuta N, Kobayashi M, Kawamura Y, Yatsuji H, Sezaki H, Hosaka T, Hirakawa M, Ikeda K, Kumada H. Sustained virological response reduces incidence of onset of type 2 diabetes in chronic hepatitis C. *Hepatology* 2009; **49**: 739-744 [PMID: 19127513 DOI: 10.1002/hep.22703]
- 65 **Calvaruso V**, Craxi A. Why do I treat my patients with mild hepatitis C? *Liver Int* 2016; **36** Suppl 1: 7-12 [PMID: 26725891 DOI: 10.1111/liv.13011]
- 66 **Zignego AL**, Ramos-Casals M, Ferri C, Saadoun D, Arcaini L, Roccatello D, Antonelli A, Desbois AC, Comarmond C, Gragnani L, Casato M, Lamprecht P, Mangia A, Tzioufas AG, Younossi ZM, Cacoub P; ISG-EHCV. International therapeutic guidelines for patients with HCV-related extrahepatic disorders. A multidisciplinary expert statement. *Autoimmun Rev* 2017; **16**: 523-541 [PMID: 28286108 DOI: 10.1016/j.autrev.2017.03.004]
- 67 **Polo ML**, Laufer N. Extrahepatic manifestations of HCV: the role of direct acting antivirals. *Expert Rev Anti Infect Ther* 2017; **15**: 737-746 [PMID: 28696154 DOI: 10.1080/14787210.2017.1354697]
- 68 **Gragnani L**, Visentini M, Fognani E, Urraro T, De Santis A, Petracchia L, Perez M, Ceccotti G, Colantuono S, Mitrevski M, Stasi C, Del Padre M, Monti M, Gianni E, Pulsoni A, Fiorilli M, Casato M, Zignego AL. Prospective study of guideline-tailored therapy with direct-acting antivirals for hepatitis C virus-associated mixed cryoglobulinemia. *Hepatology* 2016; **64**: 1473-1482 [PMID: 27483451 DOI: 10.1002/hep.28753]
- 69 **Saadoun D**, Pol S, Ferfar Y, Alric L, Hezode C, Si Ahmed SN, de Saint Martin L, Comarmond C, Bouyer AS, Musset L, Poynard T, Resche Rignon M, Cacoub P. Efficacy and Safety of Sofosbuvir Plus Daclatasvir for Treatment of HCV-Associated Cryoglobulinemia Vasculitis. *Gastroenterology* 2017; **153**: 49-52; e5 [PMID: 28288791 DOI: 10.1053/j.gastro.2017.03.006]
- 70 **Arcaini L**, Besson C, Frigeni M, Fontaine H, Goldaniga M, Casato M, Visentini M, Torres HA, Loustaud-Ratti V, Peveling-Oberhag J, Fabris P, Rossotti R, Zaja F, Rigacci L, Rattotti S, Bruno R, Merli M, Dorival C, Alric L, Jaccard A, Pol S, Carrat F, Ferretti VV, Visco C, Hermine O. Interferon-free antiviral treatment in B-cell lymphoproliferative disorders associated with hepatitis C virus infection. *Blood* 2016; **128**: 2527-2532 [PMID: 27605512 DOI: 10.1182/blood-2016-05-714667]
- 71 **Nagao Y**, Kimura K, Kawahigashi Y, Sata M. Successful Treatment of Hepatitis C Virus-associated Oral Lichen Planus by Interferon-free Therapy with Direct-acting Antivirals. *Clin Transl Gastroenterol* 2016; **7**: e179 [PMID: 27388424 DOI: 10.1038/ctg.2016.37]
- 72 **Hagan LM**, Schinazi RF. Best strategies for global HCV eradication. *Liver Int* 2013; **33** Suppl 1: 68-79 [PMID: 23286849 DOI: 10.1111/liv.12063]
- 73 **Li Y**, Pang L. The epidemiology, prevention, and treatment of hepatitis C among drug users. *Zhongguo Aizibing Xingbing* 2015; **21**: 652-652 [DOI: 10.13419/j.cnki.aids.2015.07.31]
- 74 **Martin NK**, Vickerman P, Dore GJ, Hickman M. The hepatitis C virus epidemics in key populations (including people who inject drugs, prisoners and MSM): the use of direct-acting antivirals as treatment for prevention. *Curr Opin HIV AIDS* 2015; **10**: 374-380 [PMID: 26248124 DOI: 10.1097/COH.0000000000000179]
- 75 **Martin NK**, Vickerman P, Grebely J, Hellard M, Hutchinson SJ, Lima VD, Foster GR, Dillon JF, Goldberg DJ, Dore GJ, Hickman M. Hepatitis C virus treatment for prevention among people who inject drugs: Modeling treatment scale-up in the age of direct-acting antivirals. *Hepatology* 2013; **58**: 1598-1609 [PMID: 23553643 DOI: 10.1002/hep.26431]
- 76 **UNSW Medicine-Kirby Institute**. Surveillance and treatment of prisoners with hepatitis C (StoP-C). 2018. Available from: <https://kirby.unsw.edu.au/project/stop-c>
- 77 **Grebely J**, Dalgard O, Conway B, Cunningham EB, Bruggmann P, Hajarizadeh B, Amin J, Bruneau J, Hellard M, Litwin AH, Marks P, Quiene S, Siriragavan S, Applegate TL, Swan T, Byrne J, Lacalamita M, Dunlop A, Matthews GV, Powis J, Shaw D, Thurnheer MC, Weltman M, Kronborg I, Cooper C, Feld JJ, Fraser C, Dillon JF, Read P, Gane E, Dore GJ. Sofosbuvir and velpatasvir for hepatitis C virus infection in people with recent injection drug use (SIMPLIFY): an open-label, single-arm, phase 4, multicentre trial. *Lancet Gastroenterol Hepatol* 2018; **3**: 153-161 [PMID: 29310928 DOI: 10.1016/s2468-1253(17)30404-1]
- 78 **Olafsson S**, Tyrfinngsson T, Runarsdottir V, Bergmann OM, Hansdottir I, Björnsson ES, Johannsson B, Sigurdardottir B, Fridriksdottir RH, Löve A, Hellard M, Löve TJ, Gudnason T, Heimisdottir M, Gottfredsson M. Treatment as Prevention for Hepatitis C (TraP Hep C) - a nationwide elimination programme in Iceland using direct-acting antiviral agents. *J Intern Med* 2018; **283**: 500-507 [PMID: 29512219 DOI: 10.1111/joim.12740]
- 79 **World Health Organization**. Guidelines for the screening, care and treatment of persons with chronic hepatitis C infection. 2016. Available from: <https://www.who.int/hepatitis/publications/hepatitis-c-guidelines-2016/en/>
- 80 **Zhu B**, Liu J, Fu Y, Zhang B, Mao Y. Spatio-Temporal Epidemiology of Viral Hepatitis in China (2003-2015): Implications for Prevention and Control Policies. *Int J Environ Res Public Health* 2018; **15** [PMID: 29614809 DOI: 10.3390/ijerph15040661]
- 81 **Wang H**, Yang J, Deng X, Xu K, Wang J, Zhang Y. HIV/HBV/HCV infection among drug users: a meta-analysis of data collected in Chinese mainland. *Zhonghua Jibing Kongzhi Zazhi* 2010; **14**: 300-304
- 82 **Jin Y**, Li M, Liu T, Jin Y, Lu Z, Jia Z. Evaluation of burden of infectious diseases among drug abusers. *Zhonghua Yiyuan Ganranxue Zazhi* 2017; **27**: 2125-2128 [DOI: 10.11816/cn.ni.2017-163654]
- 83 **Kieran JA**, Norris S, O'Leary A, Walsh C, Merriman R, Houlihan D, McCormick PA, McKiernan S, Bergin C, Barry M. Hepatitis C in the era of direct-acting antivirals: real-world costs of untreated chronic hepatitis C; a cross-sectional study. *BMC Infect Dis* 2015; **15**: 471 [PMID: 26503519 DOI: 10.1186/s12879-015-1208-1]
- 84 **Duan ZP**, Zhou HY, Duan C, Wang Z, Chen Y, Zheng SJ, Liu S, Tang A, Li H. Survey of Treatment Costs to Hepatitis C in China. *Value Health* 2014; **17**: A805 [PMID: 27203036 DOI: 10.1016/j.jval.2014.08.515]
- 85 **Sun YT**, Zhang YX, Tang H, Mao Q, Wang XZ, Zhang LY, Chen H, Zhong YN, Lin SM, Zhang DZ.

- Clinical characteristics and current management of hepatitis B and C in China. *World J Gastroenterol* 2014; **20**: 13582-13590 [PMID: 25309089 DOI: 10.3748/wjg.v20.i37.13582]
- 86 **Webster S**, Ward T, Bennett H, Wygant G, Wang F, Yan J, McEwan P. Chronic hepatitis C and the emergence of direct-acting antiviral regimens in China: treat now or later? *Hepatol Int* 2017; **11** Suppl 1: S1048 [PMID: 28155069 DOI: 10.1007/s12072-016-9783-9]
- 87 **Razavi H**, Elkhoury AC, Elbasha E, Estes C, Pasini K, Poynard T, Kumar R. Chronic hepatitis C virus (HCV) disease burden and cost in the United States. *Hepatology* 2013; **57**: 2164-2170 [PMID: 23280550 DOI: 10.1002/hep.26218]
- 88 **Wei L**, Kamae I, Lee MH, Li H. Hepatitis C viral infection disease burden in Asia. *Value and Outcomes Spotlight* 2015; **1**: 16-18
- 89 **Younossi Z**, Park H, Henry L, Adeyemi A, Stepanova M. Extrahepatic Manifestations of Hepatitis C: A Meta-analysis of Prevalence, Quality of Life, and Economic Burden. *Gastroenterology* 2016; **150**: 1599-1608 [PMID: 26924097 DOI: 10.1053/j.gastro.2016.02.039]
- 90 **Gosselin E**, Lemyre L, Corneil W. Presenteeism and absenteeism: differentiated understanding of related phenomena. *J Occup Health Psychol* 2013; **18**: 75-86 [PMID: 23276197 DOI: 10.1037/a0030932]
- 91 **Ye X**, Xu X, Xie Q, Tang H, Xuan J. Impact of sofosbuvir-based regimens for chronic hepatitis C infection: A work productivity model from mainland China. *Value Health* 2018; **21** Suppl 2: S6 [DOI: 10.1016/j.jval.2018.07.044]
- 92 **Chhatwal J**, He T, Hur C, Lopez-Olivo MA. Direct-Acting Antiviral Agents for Patients With Hepatitis C Virus Genotype 1 Infection Are Cost-Saving. *Clin Gastroenterol Hepatol* 2017; **15**: 827-837.e8 [PMID: 27650326 DOI: 10.1016/j.cgh.2016.09.015]
- 93 **Younossi ZM**, Gordon SC, Dieterich DT, Wong R, Brown KA, Kugelmas M, Saab S, Ahmed A. A decision analytic Markov model to evaluate the health outcomes of sofosbuvir/velpatasvir for patients with chronic hepatitis C virus genotype 1 infection in the US. *Hepatology* 2016; **64** Suppl 1: 421A-422A [DOI: 10.1002/hep.28798]
- 94 **Younossi ZM**, Park H, Dieterich D, Saab S, Ahmed A, Gordon SC. Assessment of cost of innovation versus the value of health gains associated with treatment of chronic hepatitis C in the United States: The quality-adjusted cost of care. *Medicine (Baltimore)* 2016; **95**: e5048 [PMID: 27741116 DOI: 10.1097/MD.0000000000005048]
- 95 **Liu Y**, Wang Z, Tobe RG, Lin H, Wu B. Cost Effectiveness of Daclatasvir Plus Asunaprevir Therapy for Chinese Patients with Chronic Hepatitis C Virus Genotype 1b. *Clin Drug Investig* 2018; **38**: 427-437 [PMID: 29417464 DOI: 10.1007/s40261-018-0621-9]
- 96 **Lu Y**, Jin X, Duan CA, Chang F. Cost-effectiveness of daclatasvir plus asunaprevir for chronic hepatitis C genotype 1b treatment-naïve patients in China. *PLoS One* 2018; **13**: e0195117 [PMID: 29634736 DOI: 10.1371/journal.pone.0195117]
- 97 **Chen H**, Chen J, Lu Z, Yu H, Chen F. Establish pharmacoeconomics model for treatment of chronic hepatitis C with Markov model. *Zhongguo Weisheng Tongji* 2016; **33**: 370-373
- 98 **Wu B**, Wang Z, Xie Q. Cost-effectiveness of novel regimens for Chinese patients with chronic hepatitis C. *Curr Med Res Opin* 2019; **35**: 847-857 [PMID: 30409038 DOI: 10.1080/03007995.2018.1546678]
- 99 **Chen P**, Ma A, Liu Q. Cost-Effectiveness of Elbasvir/Grazoprevir Versus Daclatasvir Plus Asunaprevir in Patients with Chronic Hepatitis C Virus Genotype 1b Infection in China. *Clin Drug Investig* 2018; **38**: 1031-1039 [PMID: 30194584 DOI: 10.1007/s40261-018-0702-9]
- 100 **Chen CP**, Cheng CY, Zou H, Cheng CH, Cheng SH, Chen CK, Chen CH, Bair MJ. Evaluation of cost-effectiveness of peginterferon plus ribavirin for chronic hepatitis C treatment and direct-acting antiviral agents among HIV-infected patients in the prison and community settings. *J Microbiol Immunol Infect* 2018 [PMID: 30360951 DOI: 10.1016/j.jmii.2018.10.002]
- 101 **Li X**, Chan NS, Tam AW, Hung IFN, Chan EW. Budget impact and cost-effectiveness analyses of direct-acting antivirals for chronic hepatitis C virus infection in Hong Kong. *Eur J Clin Microbiol Infect Dis* 2017; **36**: 1801-1809 [PMID: 28516201 DOI: 10.1007/s10096-017-2995-7]
- 102 **Cheng WD**, Zhang LY, Chen W. Budget impact analysis of direct-acting antiviral regimens for the treatment of hepatitis C virus infection. *Zhongguo Wei Sheng Zi Yuan* 2018; **21**: 500-505 [DOI: 10.13688/j.cnki.chr.2018.18271]
- 103 **Chen H**, Chen L. Estimating cost-effectiveness associated with all-oral regimen for chronic hepatitis C in China. *PLoS One* 2017; **12**: e0175189 [PMID: 28380022 DOI: 10.1371/journal.pone.0175189]
- 104 **Younossi ZM**, Chan HLY, Dan YY, Lee MH, Lim YS, Kruger E, Tan SC. Impact of ledipasvir/sofosbuvir on the work productivity of genotype 1 chronic hepatitis C patients in Asia. *J Viral Hepat* 2018; **25**: 228-235 [PMID: 29053909 DOI: 10.1111/jvh.12808]
- 105 **Bennett H**, Gordon J, Jones B, Ward T, Webster S, Kalsekar A, Yuan Y, Brenner M, McEwan P. Hepatitis C disease transmission and treatment uptake: impact on the cost-effectiveness of new direct-acting antiviral therapies. *Eur J Health Econ* 2017; **18**: 1001-1011 [PMID: 27803989 DOI: 10.1007/s10198-016-0844-8]
- 106 **Iriana S**, Curry MP, Afdhal NH. Neurologic Manifestations of Hepatitis C Virus Infection. *Clin Liver Dis* 2017; **21**: 535-542 [PMID: 28689591 DOI: 10.1016/j.cld.2017.03.008]
- 107 **Kallman J**, O'Neil MM, Larive B, Boparai N, Calabrese L, Younossi ZM. Fatigue and health-related quality of life (HRQL) in chronic hepatitis C virus infection. *Dig Dis Sci* 2007; **52**: 2531-2539 [PMID: 17406828 DOI: 10.1007/s10620-006-9708-x]
- 108 **Spiegel BM**, Younossi ZM, Hays RD, Revicki D, Robbins S, Kanwal F. Impact of hepatitis C on health related quality of life: a systematic review and quantitative assessment. *Hepatology* 2005; **41**: 790-800 [PMID: 15791608 DOI: 10.1002/hep.20659]
- 109 **Liu YY**, Chen RN, Yao JJ, Yuan CR. Research process in patient-reported outcomes at home and abroad. *Xiandai Yufang Yixue* 2013; **40**: 2268-2271
- 110 **Strauss E**, Porto-Ferreira FA, de Almeida-Neto C, Teixeira MC. Altered quality of life in the early stages of chronic hepatitis C is due to the virus itself. *Clin Res Hepatol Gastroenterol* 2014; **38**: 40-45 [PMID: 24239318 DOI: 10.1016/j.clinre.2013.08.008]
- 111 **Matsushita H**, Ikeda F, Iwasaki Y, Seki H, Nanba S, Takeuchi Y, Moritou Y, Yasunaka T, Onishi H, Miyake Y, Takaki A, Nouse K, Yamamoto K. Assessment of health-related quality of life and how it predicts the outcome of pegylated interferon and ribavirin therapy for chronic hepatitis C. *J Gastroenterol Hepatol* 2014; **29**: 337-343 [PMID: 23869873 DOI: 10.1111/jgh.12337]
- 112 **Sobhonslidsuk A**, Silpakit C, Kongsakon R, Satitpornkul P, Srietch C, Khanthavit A. Factors influencing health-related quality of life in chronic liver disease. *World J Gastroenterol* 2006; **12**: 7786-7791 [PMID: 17203521]

- 113 **Huang R**, Rao H, Shang J, Chen H, Li J, Xie Q, Gao Z, Wang L, Wei J, Jiang J, Sun J, Jiang J, Wei L. A cross-sectional assessment of health-related quality of life in Chinese patients with chronic hepatitis c virus infection with EQ-5D. *Health Qual Life Outcomes* 2018; **16**: 124 [PMID: 29903024 DOI: 10.1186/s12955-018-0941-8]
- 114 **Zhang HR**, Pan GW, Xu XG, Liu L, Ning Y, Ma L, Ren R. [Study on quality of life and its related factors among patients with chronic hepatitis C in rural area]. *Zhonghua Yu Fang Yi Xue Za Zhi* 2017; **51**: 853-855 [PMID: 28881554 DOI: 10.3760/cma.j.issn.0253-9624.2017.09.015]
- 115 **Jia Y**, Li X, Li L, Liang J, Kang Y, Lin F, Deng Z, Wang W, Zhang B, Xu J. Quality of life and its influential factors in outpatients with chronic hepatitis B or C. *Linchuang Gandanbing Zazhi* 2015; **31**: 1695-1698 [DOI: 10.3969/j.issn.1001-5256.2015.10.034]
- 116 **Ren H**, Shi Y, Meng W, Hu JY, Chen YH, Pan QC. Study of disease burden of chronic hepatitis B and C patients in Shanghai based on Bronfenbrenner's ecological systems theory: a community-based survey. *Zhonghua Liu Xing Bing Xue Za Zhi* 2017; **38**: 37-42 [PMID: 28100374 DOI: 10.3760/cma.j.issn.0254-6450.2017.01.007]
- 117 **Chang SC**, Yang SS, Chang CC, Lin CC, Chung YC, Li TC. Assessment of health-related quality of life in antiviral-treated Taiwanese chronic hepatitis C patients using SF-36 and CLDQ. *Health Qual Life Outcomes* 2014; **12**: 97 [PMID: 24941994 DOI: 10.1186/1477-7525-12-97]
- 118 **Kang SC**, Hwang SJ, Lee SH, Chang FY, Lee SD. Health-related quality of life and impact of antiviral treatment in Chinese patients with chronic hepatitis C in Taiwan. *World J Gastroenterol* 2005; **11**: 7494-7498 [PMID: 16437722]
- 119 **Liu J**, Lin CS, Hu SH, Liang ML, Zhao ZX, Gao ZL. [Quality of life in patients with chronic hepatitis C after PEG-Interferon a-2a therapy]. *Zhonghua Gan Zang Bing Xue Za Zhi* 2011; **19**: 890-893 [PMID: 22525499 DOI: 10.3760/cma.j.issn.1007-3418.2011.12.003.]
- 120 **Younossi ZM**, Stepanova M, Henry L, Han KH, Ahn SH, Lim YS, Chuang WL, Kao JH, Nguyen KV, Lai CL, Chan HL, Wei L. Sofosbuvir and ledipasvir are associated with high sustained virologic response and improvement of health-related quality of life in East Asian patients with hepatitis C virus infection. *J Viral Hepat* 2018; **25**: 1429-1437 [PMID: 29974665 DOI: 10.1111/jvh.12965]
- 121 **Younossi ZM**, Stepanova M, Henry L, Han KH, Ahn SH, Lim YS, Chuang WL, Kao JH, Kinh N, Lai CL, Yuen MF, Chan HL, Lai W. The effect of interferon-free regimens on health-related quality of life in East Asian patients with chronic hepatitis C. *Liver Int* 2018; **38**: 1179-1187 [PMID: 29197140 DOI: 10.1111/liv.13650]
- 122 **Younossi Z**, Stepanova M, Omata M, Mizokami M, Nader F, Hunt S. Fatigue in Japanese patients with chronic hepatitis C treated with ledipasvir and sofosbuvir with or without ribavirin. *Value Health* 2016; **19**: A316-A317 [DOI: 10.1016/j.jval.2016.03.966]
- 123 **Younossi ZM**, Stepanova M, Omata M, Mizokami M, Walters M, Hunt S. Quality of life of Japanese patients with chronic hepatitis C treated with ledipasvir and sofosbuvir. *Medicine (Baltimore)* 2016; **95**: e4243 [PMID: 27537553 DOI: 10.1097/MD.0000000000004243]
- 124 **Younossi ZM**, Stepanova M, Henry L, Nader F, Hunt S. An In-Depth Analysis of Patient-Reported Outcomes in Patients With Chronic Hepatitis C Treated With Different Anti-Viral Regimens. *Am J Gastroenterol* 2016; **111**: 808-816 [PMID: 27021197 DOI: 10.1038/ajg.2016.99]
- 125 **Younossi Z**, Stepanova M, Henry L, Duan ZP, Xie Q, Hou JL, Jia J, Wei L. High efficacy and substantial improvement of health-related quality of life (HRQL) in Chinese patients with hepatitis C virus (HCV) infection treated with ledipasvir and sofosbuvir (LDV/SOF). *Hepatol Int* 2018; **12** Suppl 2: S238 [PMID: 29516349 DOI: 10.1007/s12072-018-9852-3]
- 126 **Behl A**, Kumada H, Toyota J, Chayama K, Ishikawa H, Kalsekar A. Comparison of patient reported outcomes in a phase 3 study of all oral dual combination of daclatasvir plus asunaprevir (DCV + ASV) versus telaprevir plus peginterferon alfa ribavirin (TVR) in treatment naive Japanese patients chronically infected with HCV genotype 1b. *Hepatol Int* 2015; **9** Suppl 1: S55 [PMID: 25788430 DOI: 10.1007/s12072-015-9609-1]
- 127 **Wygant G**, Mo L, Treitel M, Zhao Y. Patient reported outcomes in IFN/ribavirin intolerant/ineligible Asian patients from Mainland China receiving daclatasvir +asunaprevir for the treatment of HCV genotype 1b infection. *Hepatol Int* 2017; **11** Suppl 1: S1001-S1002 [PMID: 28155069 DOI: 10.1007/s12072-016-9783-9]
- 128 **Wygant G**, Mo L, Treitel M, Zhao Y. Fatigue severity scores (FSS) and SF-36 patient-reported outcomes (PROs) in Asian interferon/ribavirin intolerant/ineligible patients from Mainland China who received daclatasvir + asunaprevir for the treatment of HCV genotype 1b infection. *Hepatol Int* 2017; **11** Suppl 1: S1001 [PMID: 28155069 DOI: 10.1007/s12072-016-9783-9]
- 129 **Cheng W**, Sobhonslidsuk A, Jia J, Lindore P, Liang L, Evans B, Ginanni J, Talwani R, Arduino JM, Thuy thi TP, Wang F-s, Lee Y-J, Chu C-j. Impact of a 12-week oral regimen of elbasvir/grazoprevir (EBR/GZR) on health-related quality of life (HRQOL) and fatigue in treatment-naïve patients with chronic hepatitis C virus (HCV) genotype (GT) 1, 4, or 6 infection: data from the C-CORAL study. *Hepatol Int* 2017; **11** Suppl 1: S298 [PMID: 28155069 DOI: 10.1007/s12072-016-9783-9]
- 130 **Kumada H**, Chayama K, Mehta D, Pinsky B. Impact of hepatitis C treatment with glecaprevir + pibrentasvir on patient's health related quality of life: Results from phase 3 CERTAIN trials. *Hepatology* 2017; **66** Suppl 1: 639A-640A [DOI: 10.1002/hep.29501]
- 131 **Epclusa® Prescribing Information**. Shanghai, China: Gilead Sciences, Shanghai, 2018
- 132 **Wei L**, Omata M, Lim YS, Chuang WL, Long D, Xie Q, Hou J, Jia J, Svarovskaia E, Martin R, Doehle B, Yang J, De-Oertel S, Massetto B, Kersey K, Brainard D, Mo H, Kinh N, Kao JH, Han KH, Mizokami M, Duan Z. Prevalence of pre-treatment NS5A and NS5B NI resistance associated substitutions in HCV infected patients enrolled in clinical trials in Asia. *Hepatol Int* 2017; **11** Suppl 1: S189 [PMID: 28155069 DOI: 10.1007/s12072-016-9783-9]
- 133 **Yan LB**, Rao HY, Ma YJ, Bai L, Chen EQ, Du LY, Yang RF, Wei L, Tang H; CCgenos Study Group. Hepatitis B virus infection in Chinese patients with hepatitis C virus infection: prevalence, clinical characteristics, viral interactions and host genotypes: a nationwide cross-sectional study. *BMJ Open* 2016; **6**: e012016 [PMID: 27733412 DOI: 10.1136/bmjopen-2016-012016]
- 134 **Huang W**, Wang M, Gong Q, Yu D, Chen P, Lin J, Han Y, Su Y, Qu L, Zhang X. Comparison of Naturally Occurring Resistance-Associated Substitutions Between 2008 and 2016 in Chinese Patients with Chronic Hepatitis C Virus Infection. *Microb Drug Resist* 2019 [PMID: 30702389 DOI: 10.1089/mdr.2018.0360]
- 135 **Falade-Nwulia O**, Sulkowski MS, Merkow A, Latkin C, Mehta SH. Understanding and addressing hepatitis C reinfection in the oral direct-acting antiviral era. *J Viral Hepat* 2018; **25**: 220-227 [PMID: 29903024 DOI: 10.1186/s12955-018-0941-8]

- 29316030 DOI: 10.1111/jvh.12859]
- 136 **Ghasemi F**, Rostami S, Meshkat Z. Progress in the development of vaccines for hepatitis C virus infection. *World J Gastroenterol* 2015; **21**: 11984-12002 [PMID: 26576087 DOI: 10.3748/wjg.v21.i42.11984]
- 137 **Yan Y**, Wang X, Huang Z, Zhong J. Demands, challenges and progresses of prophylactic hepatitis C virus vaccine development. *Zhongguo Xi Bao Sheng Wu Xue Xue Bao* 2018; **40**: 303-308 [DOI: 10.11844/cjcb.2018.03.9001]



Basic Study

Hepatitis C virus antigens enzyme immunoassay for one-step diagnosis of hepatitis C virus coinfection in human immunodeficiency virus infected individuals

Ke-Qin Hu, Wei Cui, Susan D Rouster, Kenneth E Sherman

ORCID number: Ke-Qin Hu (0000-0003-3377-6553); Wei Cui (0000-0003-3891-5516); Susan D Rouster (0000-0002-6457-4949); Kenneth E Sherman (0000-0002-0560-0019).

Author contributions: Hu KQ contributed to the study design, data collection and analysis, and writing and editing of the manuscript; Cui W contributed to experiment performance, data collection and analysis, and preparing the manuscript; Rouster S and Sherman K contributed to serum samples, data analysis, and preparing the manuscript.

Institutional review board statement: This research project has been approved by the University of California, Irvine, and University of Cincinnati College of Medicine Institutional Review Board.

Conflict-of-interest statement: All authors have no conflicts of interest related to this study.

Open-Access: This article is an open-access article that was selected by an in-house editor and fully peer-reviewed by external reviewers. It is distributed in accordance with the Creative Commons Attribution Non Commercial (CC BY-NC 4.0) license, which permits others to distribute, remix, adapt, build upon this work non-commercially, and license their derivative works on different terms, provided the original work is properly cited and

Ke-Qin Hu, Wei Cui, Division of GI/Hepatology, University of California, Irvine, School of Medicine, Orange, CA 92868, United States

Susan D Rouster, Kenneth E Sherman, Division of Digestive Diseases, University of Cincinnati College of Medicine, Cincinnati, OH 45267, United States

Corresponding author: Ke-Qin Hu, MD, FAASLD, Division of GI/Hepatology, University of California, Irvine, School of Medicine, 101 The City Drive, Building 56, Ste. 801, Orange, CA 92868, United States. kqhu@uci.edu

Telephone: +1-714-4566926

Fax: +1-714-4563283

Abstract

BACKGROUND

Current diagnosis of hepatitis C virus (HCV) infection requires two sequential steps: testing for anti-HCV followed by HCV RNA PCR to confirm viremia. We have developed a highly sensitive and specific HCV-antigens enzyme immunoassay (HCV-Ags EIA) for one-step diagnosis of viremic HCV infection.

AIM

To assess the clinical application of the HCV-Ags EIA in one-step diagnosis of viremic HCV infection in human immunodeficiency virus (HIV)-coinfected individuals.

METHODS

The study blindly tested HCV-Ags EIA for its performance in one-step diagnosing viremic HCV infection in 147 sera: 10 without HCV or HIV infection; 54 with viremic HCV mono-infection; 38 with viremic HCV/HIV coinfection; and 45 with viremic HCV and non-viremic HIV coinfection.

RESULTS

Upon decoding, it was 100% accordance of HCV-Ags EIA to HCV infection status by HCV RNA PCR test. In five sera with HCV infection, HCV RNA was as low as 50-59 IU/mL, and four out of five tested positive for HCV-Ags EIA. Likewise, it was also 100% accordance of HCV-Ags EIA to HCV infection status by HCV RNA PCR in 83 sera with HCV and HIV coinfection, regardless if HIV infection was active or not.

CONCLUSION

the use is non-commercial. See: <http://creativecommons.org/licenses/by-nc/4.0/>

Manuscript source: Unsolicited manuscript

Received: January 14, 2019

Peer-review started: February 13, 2019

First decision: March 8, 2019

Revised: May 8, 2019

Accepted: May 21, 2019

Article in press: May 21, 2019

Published online: May 27, 2019

P-Reviewer: Farshadpour F, Jin B, Quarleri J

S-Editor: Ma YJ

L-Editor: Filipodia

E-Editor: Zhang YL



The modified HCV-Ags EIA has a lower detection limit equivalent to serum HCV RNA levels of approximately 100 IU/mL. It is highly sensitive and specific in the setting of HIV coinfection, regardless of HIV infection status and CD4 count. These data support the clinical application of the HCV-Ags EIA in one-step diagnosis of HCV infection in HIV-infected individuals.

Key words: Hepatitis C virus; Hepatitis C virus antigens; Hepatitis C virus core antigen; Hepatitis C virus diagnostic test; Diagnostic assay; Enzyme immunoassay

©The Author(s) 2019. Published by Baishideng Publishing Group Inc. All rights reserved.

Core tip: We recently developed a novel and highly sensitive and specific hepatitis C virus antigens (HCV-Ags) enzyme immunoassay for one-step diagnosis of viremic HCV infection. The present study blindly tested this test's performance in 147 sera: 10 without HCV or human immunodeficiency virus (HIV) infection; 54 with viremic HCV monoinfection; 38 with viremic HCV/HIV coinfection; and 45 with viremic HCV and non-viremic HIV coinfection. Our results demonstrated that the HCV-Ags enzyme immunoassay is highly sensitive and specific in the setting of HIV coinfection, regardless of HIV infection status and CD4 count. These data support the clinical application of the HCV-Ags test in one-step diagnosis of HCV infection in HIV-infected individuals.

Citation: Hu KQ, Cui W, Rouster SD, Sherman KE. Hepatitis C virus antigens enzyme immunoassay for one-step diagnosis of hepatitis C virus coinfection in human immunodeficiency virus infected individuals. *World J Hepatol* 2019; 11(5): 442-449

URL: <https://www.wjgnet.com/1948-5182/full/v11/i5/442.htm>

DOI: <https://dx.doi.org/10.4254/wjh.v11.i5.442>

INTRODUCTION

Chronic hepatitis C virus (HCV) infection affects approximately 115 million individuals worldwide that can progress to chronic hepatitis C or cirrhosis, and it is associated with development of hepatocellular carcinoma^[1,2]. HCV infection is also common in human immunodeficiency virus (HIV)-infected individuals, as both infections share the same modes of transmission^[3]. The activity and progression of liver injury are more severe in HCV and HIV coinfecting individuals than those with HCV monoinfection^[4]. Research advances have resulted in clinical application of direct acting anti-viral treatment for HCV infection. All these treatment regimens are highly safe and effective and associated with > 95% sustained virologic response rates even in those with HCV/HIV coinfection^[5-8]. It is recommended that HIV and HCV coinfection should not be treated differently than HCV monoinfection^[7,8]. Successful eradication of HCV has been shown to improve the prognosis of HCV-induced liver disease and reduce the associated mortality^[9,10]. Both the World Health Organization and the United States of America Center for Disease Control have advocated eradicating HCV infection by 2030^[11,12]. These emphasize the essential need for effective HCV screening and diagnosis, including HIV-infected individuals, to link them to appropriate care.

However, the current two-step HCV test process represents one of the main barriers for effective HCV screening^[7,13,14], as it is suboptimal, costly, inconvenient, time consuming, and globally not widely available. Current anti-HCV tests, although highly specific and sensitive, cannot distinguish viremic HCV (V-HCV) infection from resolved HCV (R-HCV) infection^[15]. Thus, when anti-HCV is tested positive, an expensive HCV reverse transcription-polymerase chain reaction (RT-PCR) is mandatory to further test the presence or absence of viremia. Additionally, anti-HCV testing cannot be used for diagnosing acute HCV infection and may cause false negative results in immunocompromised patients, those receiving immunosuppressive therapy, or on hemodialysis^[16,17]. Although serum HCV RNA RT-PCR is a highly specific and sensitive test to detect V-HCV infection, the dependence on expensive equipment, high cost, and time-consuming nature limit its applicability, especially in developing countries and regions.

Several HCV core antigen (HCVcAg) assays have been reported^[18-29]. The detection

limit of the Ortho HCVcAg enzyme immunoassay (EIA) was reported to be 1.48 pg/mL, corresponding to HCV RNA of 9707 IU/mL. Hence, it is not a sensitive test. The detection threshold of the Abbott Architect HCVcAg assay is reported to be 3 fmol/L, equivalent to HCV-RNA between 1015-1045 IU/mL, which is in line with published data showing HCVcAg detection limits corresponding to serum HCV-RNA levels in the range of 428-2700 IU/mL^[30-32]. However, the sensitivity of the Abbott Architect HCVcAg assay was only 64.7% to 81.9% when serum HCV RNA was < 4 log IU/mL and 0.0% to 19.7% when serum HCV RNA was < 3 log IU/mL^[31,33]. Furthermore, a high false positive rate occurred in patients with R-HCV infection (*i.e.*, negative HCV RNA and positive anti-HCV results) when tested with the current HCVcAg assay^[32-34]. Currently available HCVcAg assays have limited clinical utility due to their low specificity and sensitivity. Recently, we developed a highly sensitive and specific HCV-Ags EIA that could be used for one-step diagnosis of V-HCV infection by testing serum or urine specimens^[35].

The goals of the present study were to further assess the sensitivity and specificity of the HCV-Ags EIA and its value for one-step diagnosis of viremic HCV infection in HCV monoinfected and HCV/HIV coinfecting individuals through a blinded way, *i.e.* obtaining serum samples from one lab (Kenneth E Sherman; KES) and performing HCV-Ags EIA in another lab (Ke-Qin Hu). Our results indicated that HCV-Ags EIA holds high specificity and sensitivity for detection of V-HCV infection in individuals with HCV monoinfection as well as HCV/HIV coinfection.

MATERIALS AND METHODS

HCV and HIV diagnosing criteria, serum specimen, and clinical data collection

Chronic V-HCV infection was defined as positive anti-HCV and HCV RNA tests for 6 mo. R-HCV (or past) infection was defined on the basis of a known history of prior HCV infection, a positive anti-HCV test, but negative HCV RNA RT-PCR performed at least twice. Chronic viremic HIV infection was diagnosed by positive tests for both anti-HIV and HIV RNA PCR. Whereas, non-viremic HIV infection was defined by history of HIV infection, on HIV treatment, and negative HIV RNA test.

The study was approved by Institutional Review Boards of both institutions. After obtaining informed consent, venous blood specimens were collected, and serum aliquots were prepared and stored at -80 °C. Quantitative HCV RNA RT-PCR and HIV RNA RT-PCR were performed on the same day in the clinical laboratory. The clinical records were also reviewed for details regarding clinical diagnosis and course.

Anti-HCV test was performed using the Architect Anti-HCV Assay, a chemiluminescent microparticle immunoassay (Abbott Laboratories, Abbott Park, IL, United States). Serum HCV RNA was quantitated using the Abbott Real Time HCV assay, which has a lower limit of quantification of 12 IU/mL (Abbott Laboratories, Abbott Park, IL, United States). Anti-HIV was performed using Abbott's Architect HIV Ag/Antibody Combo assay for the simultaneous detection of both HIV antigen and antibodies. HIV RNA test was performed by LabOne, Inc. using the Roche Diagnostics Amplicor HIV-1 Monitor test kit with a linear range of 400-750000 HIV-1 RNA copies/mL.

Serum specimens and study conduction

The present studies utilized a blind fashion to assess the performance of the HCV-Ags EIA that was recently reported highly sensitive and specific^[35] in sera with (1) HCV monoinfection and (2) HCV and HIV coinfection. For study enrollment, patients must have a full assessment for HCV and HIV infection as described above. Serum samples were collected from the KES lab, and divided into four groups without HCV and HIV infection, HCV monoinfection, and HCV and HIV coinfection with different HIV replication status as shown in Table 1.

All the serum specimens were blindly coded in the KES lab and sent to the Ke-Qin Hu lab to perform HCV-Ags EIA. The test results were then sent back to the KES lab for decoding and used for statistical analysis. The related clinical data, such as age, gender, and CD4 count, were collected in the KES lab.

HCV-Ags EIA

All coded serum samples underwent HCV-Ags EIA that was performed in the Ke-Qin Hu lab, as previously reported^[35]. Briefly, 96 microtiter plates were coated with HCV-Ags-specific capture antibodies followed by addition of HCV detection antibodies specific to HCV antigens (*i.e.*, HCVcAg and non-structural S3-S5 proteins) and HRP-conjugated secondary antibodies. Finally, a color reaction was produced using substrate solution, and optical density was measured using ELX 800 Universal

Table 1 Blinded 147 serum samples in four groups for hepatitis C virus antigens enzyme immunoassay

Group	Diagnosis	Cases	HCV infection	HIV infection
1	No HCV/HIV	10	No (anti-HCV -/HCV PCR -)	No (anti-HIV -)
2	HCV alone	54	Yes (anti-HCV +/HCV PCR +)	No (anti-HIV -)
3	HCV/viremic HIV	38	Yes (anti-HCV +/HCV PCR +)	Yes (anti-HIV +/HIV PCR +)
4	HCV/non-viremic HIV	45	Yes (anti-HCV +/HCV PCR +)	Yes (anti-HIV +/HIV PCR -)
Total		147		

HCV: Hepatitis C virus; HIV: Human immunodeficiency virus.

Microplate Reader. Results were expressed as optical density values.

Statistical analysis

The categorical data were presented as percentage, and continuous data were expressed as the mean and standard deviation. A 2 x 2 table was used to calculate the test sensitivity, specificity, positive, and negative predictive values. The *P* values less than 0.05 were considered statistically significant. SPSS software was used for statistical analysis.

RESULTS

Study groups, serologic and virologic data, and CD4 count

As summarized in Table 1, a total of 147 coded serum specimens were used in the present study in the following four groups. Group 1 included 10 sera without HCV or HIV infection (*i.e.*, negative anti-HCV, HCV RNA, anti-HIV, and HIV RNA tests); group 2 included 54 sera with HCV mono-infection (*i.e.*, positive HCV RNA, negative anti-HIV tests); group 3 included 38 sera with viremic HCV and HIV coinfection (*i.e.*, positive for both HCV RNA and HIV RNA tests), and group 4 included 45 sera with viremic HCV infection, but non-viremic HIV infection (*i.e.*, history of positive HCV RNA and anti-HIV, on HIV treatment, and currently negative HIV RNA tests).

In group 2, HCV genotype (GT) distribution was GT1 = 47, GT3 = 4, GT4 = 1, and GT mixed = 2, and the range of serum HCV RNA load was from $4.8 \times 2 \log$ to $2.6 \times 7 \log$ IU/mL. In group 3, HCV GT distribution was GT1 = 28 and GT4 = 10. The range of serum HCV RNA load was from $4.6 \times 5 \log$ to $7.8 \times 7 \log$ IU/mL. The range of serum HIV RNA load was from $4.7 \times 1 \log$ to $1.2 \times 6 \log$ copies/mL, and mean CD4 count was 482.3 (282-800). In group 4, HCV GT distribution was GT1 = 35, GT2 = 6, GT4 = 2, and ND = 2. The range of serum HCV RNA load was from $9.5 \times 3 \log$ to $2.1 \times 7 \log$ IU/mL. All were negative for HIV RNA, and mean CD4 count was 594 (174-1106).

Additionally, five sera with HCV mono-infection and HCV RNA load ranging from 50-59 IU/mL were tested by the HCV-Ags EIA.

Performance of HCV-Ags EIA in HCV mono-infection

As shown in Table 2, in ten sera without HCV and HIV infection, all (100%) tested negative for HCV-Ags EIA. All 54 (100%) sera with viremic HCV infection tested positive for HCV-Ags EIA regardless of serum HCV RNA level and GT. Thus, the test results of HCV-Ags EIA were in 100% accordance to HCV infection status by HCV RNA PCR. Statically, HCV-Ags EIA test was confirmed to have 100% sensitivity and specificity for HCV viremic infection. Additionally, in five sera with low viremic HCV infection (HCV RNA level ranged between 50-59 IU/mL), 4/5 were positive for HCV-Ags EIA.

Performance of HCV-Ags EIA in HCV/HIV coinfection

As shown in Table 3, in 38 sera with viremic HCV and HIV coinfection, all (100%) were positive for HCV-Ags EIA. In 45 sera with viremic HCV and non-viremic HIV coinfection, all (100%) were positive for HCV-Ags EIA. Thus, the test results of HCV-Ags EIA were in 100% accordance to HCV infection status by HCV RNA PCR, regardless if HIV infection was active and of the CD4 count.

DISCUSSION

HCV infection affects approximately 115 million people globally^[1]. Currently,

Table 2 The accordance of serum hepatitis C virus antigens enzyme immunoassay test results to hepatitis C virus RNA PCR in sera with hepatitis C virus mono-infection

Groups	Interpretation	Cases	Serum HCV-Ags EIA	
			Positive (%)	Negative (%)
1 (anti-HCV -/HCV RNA -)	No HCV infection	10	0 (0.0%)	10 (100.0%)
2 (anti-HCV +/HCV RNA +)	Chronic HCV infection	54	54 (100.0%)	0 (0.0%)
Subtotal		64	54	10

HCV: Hepatitis C virus; HCV-Ags EIA: HCV-antigens enzyme immunoassay.

diagnosis of HCV infection requires two sequential steps: testing anti-HCV to screen, followed by HCV RNA RT-PCR to confirm viremia^[7,13,14]. The latest anti-HCV tests are highly sensitive and specific, but they cannot differentiate acute HCV infection with V-HCV and R-HCV infection. Therefore, all positive anti-HCV test results need to be further tested by HCV RNA RT-PCR. Although HCV RNA RT-PCR tests are highly sensitive and specific for V-HCV infection, it is time consuming, costly, and not available and affordable in many developing countries and regions.

Recently, we developed a novel HCV-Ags test that is more sensitive and specific than traditional HCVcAg tests and holds potential for one-step serologic diagnosis of V-HCV infection^[35]. In the present study, we used a blinded fashion to further test the sensitivity and specificity of the HCV-Ags EIA in HCV sera with mono-infection and HCV/HIV coinfection. The serum samples were from one laboratory with coding, and HCV-Ags EIA were performed blindly in another laboratory, then decoded for data analysis.

In 64 sera, 10 without HCV and HIV infection and 54 with viremic HCV infection, it was in 100% accordance of HCV-Ags EIA test results to HCV infection status by HCV RNA PCR. This blinded study further confirmed our previous report that the HCV-Ags EIA is highly specific and sensitive in diagnosing viremic HCV infection in those with HCV mono-infection. In an additional five sera with viremic HCV infection as low as HCV RNA load ranging between 50-59 IU/mL, 4/5 were positive for HCV-Ags EIA, further confirming the lowest limits of detection of the HCV-Ags assay as previously reported^[35].

We then tested utility of HCV-Ags EIA in sera with HCV and HIV coinfection. In 38 sera with viremic HCV and HIV coinfection and 45 sera with viremic HCV and non-viremic HIV coinfection, it was in 100% accordance of HCV-Ags EIA test results to HCV infection status by HCV RNA PCR, regardless if HIV infection was active and of the CD4 count. These results confirmed that the HCV-Ags EIA is highly specific and sensitive in diagnosing viremic HCV infection in those with HCV and HIV coinfection, no matter if HIV infection was active or not. The present study confirmed the potential that HCV-Ags EIA may provide an equal and cost-effective way for one-step screening and diagnosing viremic HCV infection. As HCV infection is common in HIV-infected individuals, these results are very promising in further study on the clinical application of the HCV-Ags EIA in the population with risk for both HCV and HIV infection, an important addition to the World Health Organization and the Center for Disease Control's commitment of HCV elimination globally^[11,12].

It should be noted that the main advantage of the present study is the blinded fashion, but the sample size was small. Further larger, prospective studies are needed to assess the value of clinical application of the HCV-Ags EIA.

Table 3 Accordance of serum hepatitis C virus antigens enzyme immunoassay to hepatitis C virus PCR testing results in sera with hepatitis C virus/human immunodeficiency virus coinfection

Groups	HIV status	Cases	Serum HCV-Ags EIA	
			Positive (%)	Negative (%)
1 (anti-HCV +/HCV RNA +)	Viremic HIV infection	38	38 (100.0%)	0 (0.0%)
2 (anti-HCV +/HCV RNA +)	No viremic HIV infection	45	45 (100.0%)	0 (0.0%)
Subtotal		83	83	0

HIV: Human immunodeficiency virus; HCV: Hepatitis C virus; HCV-Ags EIA: HCV-antigens enzyme immunoassay.

ARTICLE HIGHLIGHTS

Research background

Current diagnosis of hepatitis C virus (HCV) infection requires two sequential steps: testing for anti-HCV followed by HCV RNA PCR to confirm viremic infection. We have developed a highly sensitive and specific HCV-antigens (Ags) enzyme immunoassay (EIA) for one-step diagnosis of viremic HCV infection. However, it has not been tested blindly and especially in those with HCV and human immunodeficiency virus (HIV) coinfection.

Research motivation

Although HCV RNA RT-PCR tests are highly sensitive and specific for viremic HCV infection, it is time consuming, costly, and not available and affordable in many developing countries and regions. Further confirming the sensitivity and specificity of HCV-Ags EIA will provide additional support of its clinical value for one-step screening and diagnosing HCV viremic infection.

Research objectives

The present study was aimed to blindly assess the clinical application of the HCV-Ags EIA in one-step diagnosis of viremic HCV infection in HCV-infected and HCV/HIV-coinfected individuals.

Research methods

The study blindly tested HCV-Ags EIA for its performance in one-step diagnosing viremic HCV infection in 147 sera, 10 without HCV or HIV infection; 54 with viremic HCV mono-infection; 38 with viremic HCV/HIV coinfection; and 45 with viremic HCV and non-viremic HIV coinfection.

Research results

The modified HCV-Ags EIA has a lower detection limit equivalent to serum HCV RNA levels of approximately 100 IU/mL. It is highly sensitive and specific in the setting of HIV coinfection, regardless of HIV infection status and CD4 count.

Research conclusions

These data support the clinical application of the HCV-Ags test in one-step diagnosis of HCV infection in HIV-infected individuals.

Research perspectives

The HCV-Ags EIA will be a novel addition to the current standard and is a more cost-effective one-step HCV screening and diagnosis method.

REFERENCES

- Shepard CW, Finelli L, Alter MJ. Global epidemiology of hepatitis C virus infection. *Lancet Infect Dis* 2005; **5**: 558-567 [PMID: 16122679 DOI: 10.1016/S1473-3099(05)70216-4]
- Nguyen DL, Hu KQ. Clinical Monitoring of Chronic Hepatitis C Based on its Natural History and Therapy. *N Am J Med Sci (Boston)* 2014; **7**: 21-27 [PMID: 25580186]
- Azevedo TC, Zwahlen M, Rauch A, Egger M, Wandeler G. Hepatitis C in HIV-infected individuals: a systematic review and meta-analysis of estimated prevalence in Africa. *J Int AIDS Soc* 2016; **19**: 20711 [PMID: 27293220 DOI: 10.7448/IAS.19.1.20711]
- Rosenthal E, Poirée M, Pradier C, Perronne C, Salmon-Ceron D, Geffray L, Myers RP, Morlat P, Pialoux G, Pol S, Cacoub P; GERMIVIC Joint Study Group. Mortality due to hepatitis C-related liver disease in HIV-infected patients in France (Mortavic 2001 study). *AIDS* 2003; **17**: 1803-1809 [PMID: 12891066 DOI: 10.1097/01.aids.0000072671.21517.44]
- Pearlman BL, Traub N. Sustained virologic response to antiviral therapy for chronic hepatitis C virus infection: a cure and so much more. *Clin Infect Dis* 2011; **52**: 889-900 [PMID: 21427396 DOI: 10.1093/cid/cir076]
- Gutierrez JA, Lawitz EJ, Poordad F. Interferon-free, direct-acting antiviral therapy for chronic hepatitis

- C. *J Viral Hepat* 2015; **22**: 861-870 [PMID: 26083155 DOI: 10.1111/jvh.12422]
- 7 AASLD-IDS. HCV Guidance: Recommendations for Testing, Managing, and Treating Hepatitis C. Last updated: September 21 2017; Available from: <https://www.hcvguidelines.org/>
- 8 Karageorgopoulos DE, Allen J, Bhagani S. Hepatitis C in human immunodeficiency virus co-infected individuals: Is this still a "special population"? *World J Hepatol* 2015; **7**: 1936-1952 [PMID: 26244068 DOI: 10.4254/wjh.v7.i15.1936]
- 9 Backus LI, Boothroyd DB, Phillips BR, Belperio P, Halloran J, Mole LA. A sustained virologic response reduces risk of all-cause mortality in patients with hepatitis C. *Clin Gastroenterol Hepatol* 2011; **9**: 509-516.e1 [PMID: 21397729 DOI: 10.1016/j.cgh.2011.03.004]
- 10 Morgan TR, Ghany MG, Kim HY, Snow KK, Shiffman ML, De Santo JL, Lee WM, Di Bisceglie AM, Bonkovsky HL, Dienstag JL, Morishima C, Lindsay KL, Lok AS; HALT-C Trial Group. Outcome of sustained virological responders with histologically advanced chronic hepatitis C. *Hepatology* 2010; **52**: 833-844 [PMID: 20564351 DOI: 10.1002/hep.23744]
- 11 WHO. Combating hepatitis B and C to reach elimination by 2030. Publication in May. 2016; Available from: <https://www.who.int/hepatitis/publications/hep-elimination-by-2030-brief/en>
- 12 The U. S. National Viral Hepatitis Action Plan for 2017-2020. Published in Jan 2017. Accessed online in Jan. 10 2019.
- 13 Ghany MG, Strader DB, Thomas DL, Seeff LB; American Association for the Study of Liver Diseases. Diagnosis, management, and treatment of hepatitis C: an update. *Hepatology* 2009; **49**: 1335-1374 [PMID: 19330875 DOI: 10.1002/hep.22759]
- 14 Centers for Disease Control and Prevention (CDC). Testing for HCV infection: an update of guidance for clinicians and laboratorians. *MMWR Morb Mortal Wkly Rep* 2013; **62**: 362-365 [PMID: 23657112]
- 15 Pawlotsky JM. Diagnostic tests for hepatitis C. *J Hepatol* 1999; **31** Suppl 1: 71-79 [PMID: 10622564 DOI: 10.1016/S0168-8278(99)80378-X]
- 16 Bahadi A, Maoujoud O, Zejjari Y, Alayoud A, Hassani K, Elkabbaj D, Benyahia M. [Diagnosis and evaluation of hepatitis C virus among haemodialysis patients]. *East Mediterr Health J* 2013; **19**: 192-199 [PMID: 23516832]
- 17 Hanuka N, Sikuler E, Tovbin D, Mostoslavsky M, Hausman M, Orgel M, Yaari A, Shemer-Avni Y. Hepatitis C virus infection in renal failure patients in the absence of anti-hepatitis C virus antibodies. *J Viral Hepat* 2002; **9**: 141-145 [PMID: 11876797 DOI: 10.1046/j.1365-2893.2002.00332.x]
- 18 Fabrizi F, Lunghi G, Aucella F, Mangano S, Barbisoni F, Bisegna S, Vigilante D, Limido A, Martin P. Novel assay using total hepatitis C virus (HCV) core antigen quantification for diagnosis of HCV infection in dialysis patients. *J Clin Microbiol* 2005; **43**: 414-420 [PMID: 15635003 DOI: 10.1128/JCM.43.1.414-420.2005]
- 19 Aoyagi K, Ohue C, Iida K, Kimura T, Tanaka E, Kiyosawa K, Yagi S. Development of a simple and highly sensitive enzyme immunoassay for hepatitis C virus core antigen. *J Clin Microbiol* 1999; **37**: 1802-1808 [PMID: 10325327]
- 20 Kaiser T, Damerow HC, Tenckhoff S, Finger A, Böttcher I, Hafer C, Schwarz A, Lüth JB, Schmidt Gürtler H, Colucci G, Manns MP, Wedemeyer H, Tillmann HL. Kinetics of hepatitis C viral RNA and HCV-antigen during dialysis sessions: evidence for differential viral load reduction on dialysis. *J Med Virol* 2008; **80**: 1195-1201 [PMID: 18461613 DOI: 10.1002/jmv.21190]
- 21 Schüttler CG, Thomas C, Discher T, Friesse G, Lohmeyer J, Schuster R, Schaefer S, Gerlich WH. Variable ratio of hepatitis C virus RNA to viral core antigen in patient sera. *J Clin Microbiol* 2004; **42**: 1977-1981 [PMID: 15131157 DOI: 10.]
- 22 Seme K, Poljak M, Babic DZ, Mocilnik T, Vince A. The role of core antigen detection in management of hepatitis C: a critical review. *J Clin Virol* 2005; **32**: 92-101 [PMID: 15653411 DOI: 10.1016/j.jcv.2004.10.005]
- 23 Bouvier-Alias M, Patel K, Dahari H, Beaucourt S, Larderie P, Blatt L, Hezode C, Picchio G, Dhumeaux D, Neumann AU, McHutchison JG, Pawlotsky JM. Clinical utility of total HCV core antigen quantification: a new indirect marker of HCV replication. *Hepatology* 2002; **36**: 211-218 [PMID: 12085367 DOI: 10.1053/jhep.2002.34130]
- 24 Dawson GJ. The potential role of HCV core antigen testing in diagnosing HCV infection. *Antivir Ther* 2012; **17**: 1431-1435 [PMID: 23322590 DOI: 10.3851/IMP2463]
- 25 Gaudy C, Thevenas C, Tichet J, Mariotte N, Goudeau A, Dubois F. Usefulness of the hepatitis C virus core antigen assay for screening of a population undergoing routine medical checkup. *J Clin Microbiol* 2005; **43**: 1722-1726 [PMID: 15814991 DOI: 10.1128/JCM.43.4.1722-1726.2005]
- 26 Tanaka E, Ohue C, Aoyagi K, Yamaguchi K, Yagi S, Kiyosawa K, Alter HJ. Evaluation of a new enzyme immunoassay for hepatitis C virus (HCV) core antigen with clinical sensitivity approximating that of genomic amplification of HCV RNA. *Hepatology* 2000; **32**: 388-393 [PMID: 10915747 DOI: 10.1053/jhep.2000.9112]
- 27 Zanetti AR, Romanò L, Brunetto M, Colombo M, Bellati G, Tackney C. Total HCV core antigen assay: a new marker of hepatitis C viremia for monitoring the progress of therapy. *J Med Virol* 2003; **70**: 27-30 [PMID: 12629640 DOI: 10.1002/jmv.10355]
- 28 Veillon P, Payan C, Picchio G, Maniez-Montreuil M, Guntz P, Lunel F. Comparative evaluation of the total hepatitis C virus core antigen, branched-DNA, and amplicor monitor assays in determining viremia for patients with chronic hepatitis C during interferon plus ribavirin combination therapy. *J Clin Microbiol* 2003; **41**: 3212-3220 [PMID: 12843066 DOI: 10.1128/JCM.41.7]
- 29 Tobler LH, Stramer SL, Lee SR, Baggett D, Wright D, Hirschhorn D, Walsh I, Busch MP. Performance of ORTHO HCV core antigen and trak-C assays for detection of viraemia in pre-seroconversion plasma and whole blood donors. *Vox Sang* 2005; **89**: 201-207 [PMID: 16262752 DOI: 10.1111/j.1423-0410.2005.00687]
- 30 Morota K, Fujinami R, Kinukawa H, Machida T, Ohno K, Saegusa H, Takeda K. A new sensitive and automated chemiluminescent microparticle immunoassay for quantitative determination of hepatitis C virus core antigen. *J Virol Methods* 2009; **157**: 8-14 [PMID: 19135481 DOI: 10.1016/j.jviromet.2008.12.009]
- 31 Medici MC, Furlini G, Rodella A, Fuertes A, Monachetti A, Calderaro A, Galli S, Terlenghi L, Olivares M, Bagnarelli P, Costantini A, De Conto F, Sainz M, Galli C, Manca N, Landini MP, Dettori G, Chezzi C. Hepatitis C virus core antigen: analytical performances, correlation with viremia and potential applications of a quantitative, automated immunoassay. *J Clin Virol* 2011; **51**: 264-269 [PMID: 21621454 DOI: 10.1016/j.jcv.2011.05.003]
- 32 Garbuglia AR, Monachetti A, Galli C, Sabatini R, Ferreri ML, Capobianchi MR, Bagnarelli P. HCV core

- antigen and HCV-RNA in HIV/HCV co-infected patients with different HCV genotypes. *BMC Infect Dis* 2014; **14**: 222 [PMID: [24758157](#) DOI: [10.1186/1471-2334-14-222](#)]
- 33 **Kuo YH**, Chang KC, Wang JH, Tsai PS, Hung SF, Hung CH, Chen CH, Lu SN. Is hepatitis C virus core antigen an adequate marker for community screening? *J Clin Microbiol* 2012; **50**: 1989-1993 [PMID: [22461676](#) DOI: [10.1128/JCM.05175-11](#)]
- 34 **Ottiger C**, Gygli N, Huber AR. Detection limit of architect hepatitis C core antigen assay in correlation with HCV RNA, and renewed confirmation algorithm for reactive anti-HCV samples. *J Clin Virol* 2013; **58**: 535-540 [PMID: [24041472](#) DOI: [10.1016/j.jcv.2013.08.028](#)]
- 35 **Hu KQ**, Cui W. A highly specific and sensitive hepatitis C virus antigen enzyme immunoassay for One-step diagnosis of viremic hepatitis C virus infection. *Hepatology* 2016; **64**: 415-424 [PMID: [27273268](#) DOI: [10.1002/hep.28663](#)]

Expanding etiology of progressive familial intrahepatic cholestasis

Sarah AF Henkel, Judy H Squires, Mary Ayers, Armando Ganoza, Patrick Mckiernan, James E Squires

ORCID number: Sarah AF Henkel (0000-0002-7189-8829); Judy H Squires (0000-0002-1237-3504); Mary Ayers (0000-0002-6937-5201); Armando Ganoza (0000-0002-2748-1962); Patrick Mckiernan (0000-0002-8466-8504); James E Squires (0000-0001-6979-8987).

Author contributions: Henkel SAF and Squires JE contributed equally to the work; Henkel SAF drafted the initial manuscript; Squires JH, Ayers M and Ganoza A helped conceptualize, design, and carry out the review; all authors reviewed and approved the final manuscript as submitted.

Conflict-of-interest statement: The authors declare that they do not have any conflict of interest to disclose.

PRISMA 2009 Checklist statement: The authors have read the PRISMA 2009 Checklist, and the manuscript was prepared and revised according to the PRISMA 2009 Checklist.

Open-Access: This article is an open-access article which was selected by an in-house editor and fully peer-reviewed by external reviewers. It is distributed in accordance with the Creative Commons Attribution Non Commercial (CC BY-NC 4.0) license, which permits others to distribute, remix, adapt, build upon this work non-commercially, and license their derivative works on different terms, provided the original work is properly cited and the use is non-commercial. See: <http://creativecommons.org/licenses/by-nc/4.0/>

Manuscript source: Invited

Sarah AF Henkel, Division of Gastroenterology, Hepatology, and Nutrition, Emory School of Medicine, Atlanta, GA 30322, United States

Judy H Squires, Department of Radiology, UPMC Children's Hospital of Pittsburgh, Pittsburgh, PA 15224, United States

Mary Ayers, Patrick Mckiernan, James E Squires, Division of Gastroenterology, Hepatology, and Nutrition, UPMC Children's Hospital of Pittsburgh, Pittsburgh, PA 15224, United States

Armando Ganoza, Division of Pediatric Transplantation, Department of Surgery, UPMC Children's Hospital of Pittsburgh, Pittsburgh, PA 15224, United States

Corresponding author: James E Squires, MD, MSc, Assistant Professor, Division of Gastroenterology, Hepatology, and Nutrition, UPMC Children's Hospital of Pittsburgh, 4401 Penn Avenue, Pittsburgh, PA 15224, United States. james.squires2@chp.edu

Telephone: +1-412-6925180

Fax: +1-412-6927355

Abstract

BACKGROUND

Progressive familial intrahepatic cholestasis (PFIC) refers to a disparate group of autosomal recessive disorders that are linked by the inability to appropriately form and excrete bile from hepatocytes, resulting in a hepatocellular form of cholestasis. While the diagnosis of such disorders had historically been based on pattern recognition of unremitting cholestasis without other identified molecular or anatomic cause, recent scientific advancements have uncovered multiple specific responsible proteins. The variety of identified defects has resulted in an ever-broadening phenotypic spectrum, ranging from traditional benign recurrent jaundice to progressive cholestasis and end-stage liver disease.

AIM

To review current data on defects in bile acid homeostasis, explore the expanding knowledge base of genetic based diseases in this field, and report disease characteristics and management.

METHODS

We conducted a systemic review according to PRISMA guidelines. We performed a Medline/PubMed search in February-March 2019 for relevant articles relating to the understanding, diagnosis, and management of bile acid homeostasis with a focus on the family of diseases collectively known as PFIC. English only articles were accessed in full. The manual search included references of retrieved articles. We extracted data on disease characteristics, associations with other diseases, and treatment. Data was summarized and presented in text, figure, and table format.

Manuscript

Received: March 12, 2019**Peer-review started:** March 12, 2019**First decision:** March 25, 2019**Revised:** April 19, 2019**Accepted:** April 26, 2019**Article in press:** April 27, 2019**Published online:** May 27, 2019**P-Reviewer:** Erginel B, Tan YW**S-Editor:** Cui LJ**L-Editor:** A**E-Editor:** Zhang YL**RESULTS**

Genetic-based liver disease resulting in the inability to properly form and secrete bile constitute an important cause of morbidity and mortality in children and increasingly in adults. A growing number of PFIC have been described based on an expanded understanding of biliary transport mechanism defects and the development of a common phenotype.

CONCLUSION

We present a summary of current advances made in a number of areas relevant to both the classically described FIC1 (*ATP8B1*), BSEP (*ABCB11*), and MDR3 (*ABCB4*) transporter deficiencies, as well as more recently described gene mutations -- TJP2 (*TJP2*), FXR (*NR1H4*), MYO5B (*MYO5B*), and others which expand the etiology and understanding of PFIC-related cholestatic diseases and bile transport.

Key words: Cholestasis; Progressive familial intrahepatic cholestasis; Benign recurrent intrahepatic cholestasis; Intrahepatic cholestasis of pregnancy; Drug induced cholestasis; Bile acids; Bile transport

©The Author(s) 2019. Published by Baishideng Publishing Group Inc. All rights reserved.

Core tip: Progressive familial intrahepatic cholestasis is a heterogeneous cohort of diseases that present both diagnostic and treatment challenges for clinicians. Significant advancement in the knowledge base related to the genetic underpinnings regulating bile acid transport physiology has enabled new diseases to be identified with a breadth of phenotypes from neonates to adults.

Citation: Henkel SA, Squires JH, Ayers M, Ganoza A, Mckiernan P, Squires JE. Expanding etiology of progressive familial intrahepatic cholestasis. *World J Hepatol* 2019; 11(5): 450-463

URL: <https://www.wjgnet.com/1948-5182/full/v11/i5/450.htm>

DOI: <https://dx.doi.org/10.4254/wjh.v11.i5.450>

INTRODUCTION

Progressive familial intrahepatic cholestasis (PFIC) refers to a heterogeneous group of autosomal recessive disorders that are linked by the inability to appropriately form and excrete bile from hepatocytes, resulting in a hepatocellular form of cholestasis. While the diagnosis of such disorders had historically been based on pattern recognition of unremitting cholestasis without other identified molecular or anatomic cause, recent scientific advancements have uncovered multiple specific responsible proteins. The variety of identified defects has resulted in an ever-broadening phenotypic spectrum, ranging from traditional benign recurrent jaundice to progressive cholestasis and end-stage liver disease.

Bile is a unique aqueous secretion of the liver that is formed by the hepatocyte and modified downstream by absorptive and secretory properties of the bile duct epithelium. It is a combination of lipids (mainly phosphatidylcholine), bile acids, cholesterol, bilirubin, and other substances that serve to move toxins and waste metabolites out of the liver and into the gut for excretion^[1]. Micellarized bile is then reabsorbed in the enterohepatic circulation in the distal small bowel *via* the apical sodium dependent bile transporter (ASBT; *SLC10A*)^[2]. Bile salts are synthesized in hepatocytes and transported across the canalicular membrane *via* the bile salt export pump (BSEP); the expression and trafficking of which is regulated by the farnesoid X receptor (FXR) and dependent upon MYO5B respectively^[3,4]. The stability of the canalicular membrane, in which the BSEP transporter lies, is dependent on the FIC1 ATPase that regulates the phospholipid balance and the ABC translocase MDR3 which moves phosphatidylcholine across the canalicular membrane to inactivate bile acids. The integrity of the system is in part dependent upon hepatocyte connections, such as the TJP2-anchored tight junctions, which protect hepatocytes from bile salt reflux and subsequent damage^[4] (Figure 1). Defects in these bile acid transport processes result in the accumulation of bile salts in the hepatic parenchyma, which are

toxic due to their detergent nature, and the phenotypic manifestations collectively known as PFIC.

MATERIALS AND METHODS

This systematic review was conducted according to the PRISMA guidelines. We searched Medline/PubMed in February–March 2019 for established cases of PFIC as well as reports of defects in PFIC-related genes contributing to morbidity in adult populations. English language only articles that were fully accessible were included in the review. Data was manually extracted on disease characteristics in established PFIC patients. Associated phenotypes with other diseases relating to specific genetic defects were also collected. Treatment strategies were summarized. Data was collated and presented in text, figure, and table format.

Statistical analysis

Descriptive statistics were utilized to present the data. The statistical methods of this study were reviewed by Suraj Nepal, lead data analyst from the UPMC Children's Hospital of Pittsburgh department of surgery.

RESULTS

A summary of currently understood protein mechanisms, whose functions are critical to bile acid homeostasis, and whose dysfunction results in a phenotype of PFIC is presented in [Figure 1](#). A gene-specific search identified 52 *ATP8B1*, 158 *ABCB11*, 250 *ABCB4*, 56 *TJP2*, 48 *MYO5B*, and 363 *NR1H4* articles. Manual review to identify association with liver disease in humans revealed reports summarized in the current manuscript. The three “Historical” PFIC diseases, the expanded phenotypes, and emerging data on contributing morbidity in non-pediatric populations relating to defects in PFIC-related genes are summarized.

Historical PFIC

***ATP8B1* (FIC1, PFIC1, Byler's disease):** The first reported PFIC, progressive familial intrahepatic cholestasis type 1, also called Byler's disease, was described 1969 in seven Amish children (from the original Byler kindred in Western Pennsylvania) as a progressive cholestatic disease with associated extrahepatic symptoms^[5]. The causative *ATP8B1* gene and corresponding FIC1 protein was identified by Bull *et al*^[6] in 1998 by analyzing the genetics of patients from the initial Amish cohort as well as patients from Northern Europe with benign recurrent intrahepatic cholestasis type 1 (BRIC1). Definitive FIC1 function remains ambiguous. Current understanding of its action as an aminophospholipid translocase which transports phospholipids from outside to inside the canalicular membrane is based on studies in *Atp8b1*-deficient mice^[7]. Additional modifiers of disease phenotype, such as mutation-specific effects on FIC1 trafficking from the endoplasmic reticulum to the canalicular membrane, have been proposed^[8]. Ultimately, without appropriate concentrations of intracellular phospholipids, bile acids accumulate intracellularly and are cytotoxic to the hepatocyte due to their detergent nature^[9].

Deficient or defective FIC1 results in a low gamma glutamyl (GGT) cholestasis that often presents in the neonatal period, though milder forms with transient jaundice may present later in life^[1,9,10]. Affected individuals have hyperbilirubinemia, mildly elevated transaminases, and elevated serum bile acids. Infants often present jaundiced, with pruritis and hepatosplenomegaly developing over the first months of life. Severe disease manifests with persistent, progressive cholestasis and the development of portal hypertension often in early childhood. Extrahepatic disease is also notable due to the broad distribution of FIC1, which can clinically distinguish FIC1 deficiency from other forms of intrahepatic cholestasis. Affected children frequently exhibit profound diarrhea, poor growth, short stature, pancreatic insufficiency, elevated sweat chloride, and sensorineural deafness^[4,10]. Histopathology demonstrates canalicular cholestasis with biliary plugs, giant cell transformation, ductular paucity, and lobular disarray^[11]. Visualized bile is termed as “bland” granular (Byler's) bile^[9,12].

Treatment for FIC1 deficiency, as with all PFIC diseases, is challenging with no definitive medical therapies available. Supportive measures are focused on improving nutritional deficiencies and managing complications of end stage liver disease. Patients should be treated with caloric, fat, and vitamin supplementation, with the majority of fat being medium chain triglycerides^[9]. Ursodeoxycholic (UDCA), a

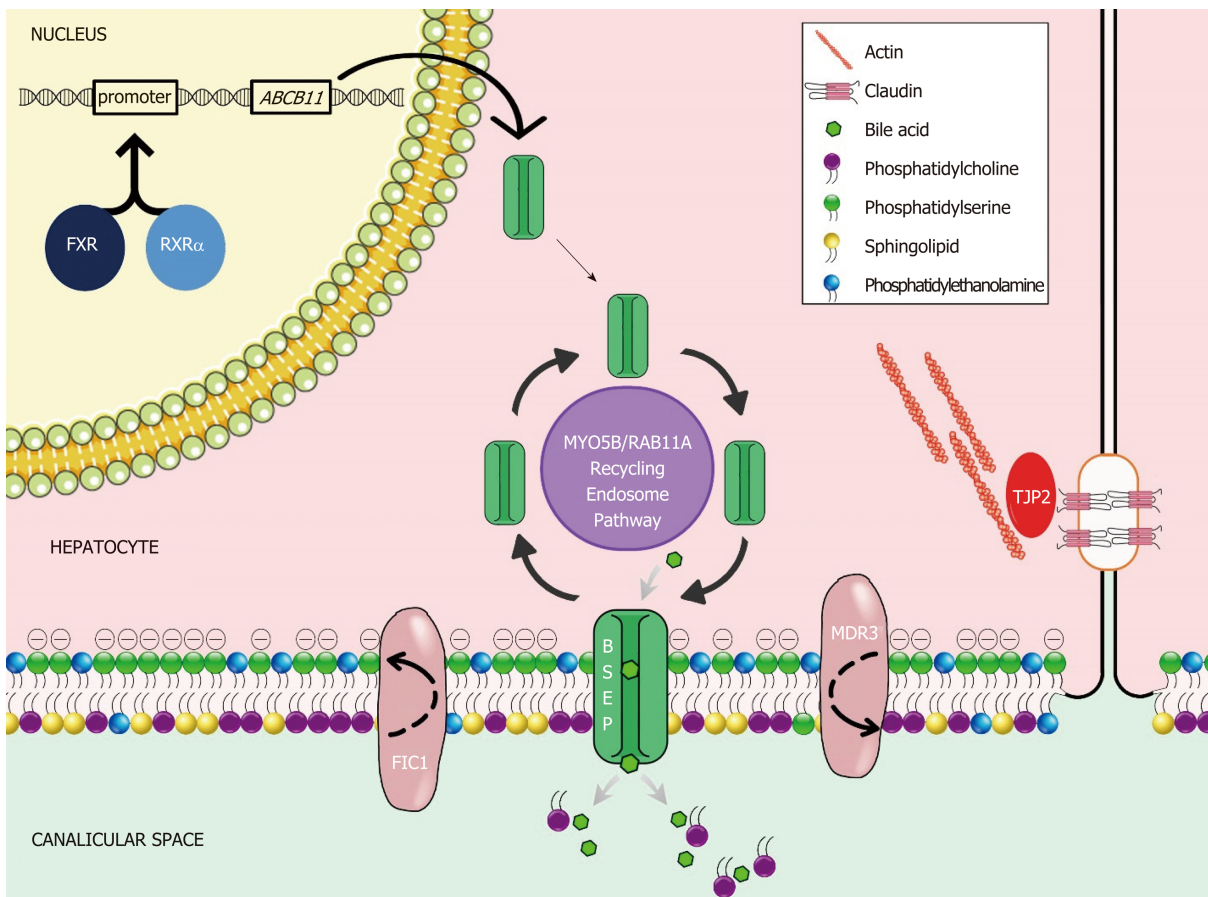


Figure 1 Molecular mechanisms of cholestasis at the apical hepatocellular membrane. FXR: Farnesoid X receptor; RXR: Retinoid x receptor alpha; ABCB11: ATP binding cassette subfamily B member 11; MYO5B: Myosin VB; RAB11A: Ras-related protein Rab11a; FIC1: Familial intrahepatic cholestasis 1; BSEP: Bile salt export pump; MDR3: Multidrug resistance 3; TJP2: Tight junction protein 2.

hydrophilic bile acid which replaces hydrophobic bile salts and may also induce BSEP and MDR3 expression, can improve pruritis and biochemical markers of cholestasis^[9]. Other antipruritic agents (Table 1) such as rifampin and cholestyramine may also be utilized but are often less helpful in FIC1 deficiency^[9,10]. Certain CFTR folding correctors have been shown to improve defective trafficking of FIC1 in cell culture^[13]; however, studies in human subjects are lacking.

When medical therapy is insufficient, surgical intervention may be considered with the goal of bypassing the enterohepatic circulation and/or decreasing reabsorption of bile salts (Figure 2). Procedures including partial external biliary diversion (PEBD), partial internal biliary diversion, and ileal exclusion have generally, though not uniformly, resulted in sustained clinical improvement in PFIC patients^[14-16]. A large surgical experience has been described in FIC1 deficiency^[14-16].

Early procedures including PEBD were first reported more than 20 years ago^[17]. PEBD utilizes an external stomal conduit (generally a cholecystojejunostomy) to enable partial, unregulated external bile flow, resulting in decreased bile acids in the enterohepatic circulation and reports of improved pruritis, growth, and possibly hepatic fibrosis^[14,17]. Remarkably, PEBD has been recognized to provide an alternative to transplant, with many patients surviving with their native liver. However, complications can occur including recurrent episodes of pruritis, possible need for biliary diversion revision, continued need for aggressive vitamin supplementation, or progressive disease necessitating liver transplant^[14,18,19].

An alternative to PEBD is the ileal bypass (IB, or ileal exclusion)^[20]. This technique bypasses the distal 15% of the ileum to avoid the major site of bile acid reabsorption and is particularly useful in patients without an intact gall bladder^[20]. Unfortunately, severe malabsorption can occur and refractory disease has been reported^[18,21,22].

More recently, partial internal biliary diversions (PIBD) has been described. The procedure may involve the creation of a neo-conduit between the gall bladder and the colon to prevent reabsorption of bile acids in the terminal ileum. This procedure may utilize a cholecystojejunocolonic, cholecystoileocolonic, cholecystocolostomy, or cholecystoappendicocolonic anastomosis technique^[22,23]. Reports in the literature

Table 1 Medical management of pruritus in children

Medicine	Dose	Mechanism of action
Cholestyramine	Initial dose: 2 g BID	Ion exchange resin which acts as BA binder in the intestine
	(max dose 24 g/d)	Decreased ileal BA absorption, Increased BA excretion (in feces)
Naltrexone	Initial dose: 0.25-5 mg/kg per day	Opioid antagonist
	(max dose 50 mg/d)	Block the permissive activity on pruritus neuronal signaling
Rifampicin	Initial dose: 5 mg/kg	PXR agonist
		Induces CYP3A4
	(max dose 20 mg/kg per day)	Increases metabolism and renal excretion of pruritogenic substances
Sertraline	Initial dose: 1 mg/kg per day	Serotonin reuptake inhibitor
	(max dose: 4 mg/kg per day)	Proposed mechanism includes increase in central serotonergic tone, which regulates pruritus
Ursodeoxycholic acid	600 mg/m ² per day	Tertiary BA
		Increases bile secretion
		Reduces ileal absorption of hydrophilic BAs

BA: Bile acid; PXR: Pregnane X receptor.

suggest patients experience not only improvement of intractable pruritis and sleeping difficulties, but also significant biochemical decrease in both bilirubin and plasma bile acids^[21-23]. Side effects described are most notable for diarrhea, which improved with cholestyramine^[21,23]. Notably, no single procedure has demonstrated definitive superiority with center-experience likely driving center-specific approaches. Newer therapeutics including inhibitors of the ileal apical-sodium dependent bile acid transporter (ASBT) which effectively act as a ‘chemical’ biliary diversion are currently under investigation (NCT03566238)^[24].

Liver transplant is indicated in those with a refractory course and in those who develop end stage disease. While hepatocellular carcinoma as an indication for transplant has been reported in other PFIC diseases, FIC1 deficiency is not known to associate with tumor development. However, mutations in *ATP8B1* have been found while sequencing hepatocellular carcinoma in patients without cholestatic disease^[25]. Importantly, patients should be counseled that the diarrhea associated with FIC1 deficiency may persist, or even worsen, following transplant. This phenomenon has been reported concomitant with the development of both allograft steatosis and fibrosis, which can progress requiring re-transplantation^[9,26]. In order to prevent damaging steatosis in the graft, ileal diversion at the time of transplant has sometimes been utilized^[27].

Notably, the recognition of variable disease courses and responses to therapy in individuals with identical *ATP8B1* mutations would suggest the presence of disease modifiers^[10,14]. While the majority of FIC1 deficiency presents in childhood, mutations in the *ATP8B1* gene may also lead to more mild manifestations of disease including BRIC1 and intrahepatic cholestasis of pregnancy type 1 (ICP1)^[28-30]. Dozens of mutations have been described, with missense mutations being more common in BRIC1 patients and nonsense or large deletions more common in severe FIC1 disease^[31].

ABCB11 (BSEP, PFIC2): Historical PFIC2 results from defects or deficiency in the BSEP encoded by *ABCB11*. The location of the defect was initially mapped to chromosome 2q24 to be positional match to BSEP, which had been cloned previously in the mouse genome and was shown soon after to export bile acids^[32,33]. This defect results in a severe hepatobiliary phenotype due to impairment of bile salt handling and subsequent damage to hepatocytes^[9]. As of this writing, more than 200 causative mutations have been identified^[34]. Affected infants initially present jaundiced, with pruritis developing around 4-5 mo of age and often progressing to the development of portal hypertension within the first year of life^[9,35,36]. Scleral icterus, hepatomegaly, excoriation of skin, and poor growth due to fat malabsorption and fat-soluble vitamin deficiency may also be apparent due to cholestasis, though extrahepatic symptoms are

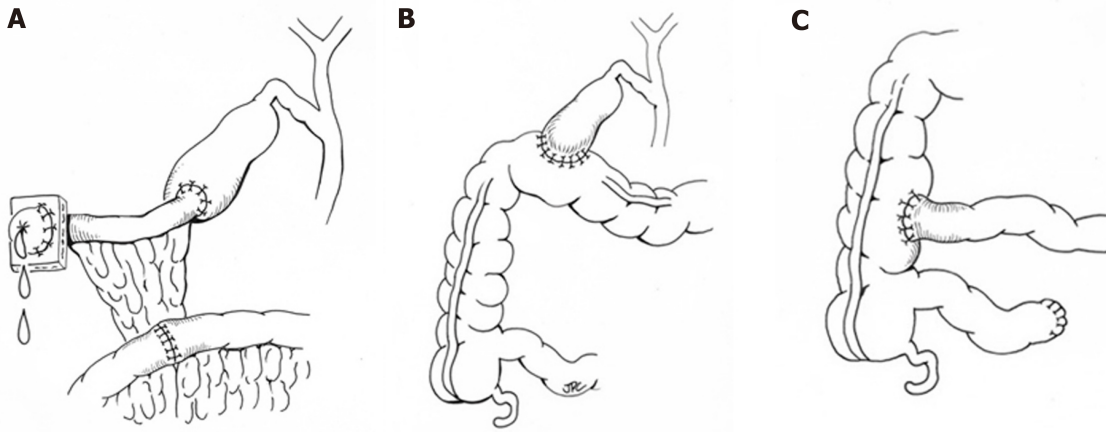


Figure 2 Representative surgical interventions for progressive familial cholestasis. A: Partial external biliary diversion; B: Partial internal biliary diversion using a cholecystocolostomy approach; C: Ileal bypass/exclusion.

less significant than in FIC1 deficiency^[4,9]. Laboratory findings demonstrate a low GGT cholestasis with transaminases typically more than twice the upper limit of normal^[36]. Similar to FIC1 deficiency, treatment is primarily supportive and focuses on nutritional supplementation and antipruritic agents. Zebrafish models of BSEP deficiency suggest a potential role for therapies aimed at promoting alternative transporters to excrete bile^[37] while reports in human subjects using cell surface BSEP-enhancer molecules (*i.e.*, 4-phenylbutyrate) alone^[38] or as part of a cocktail of medications^[39] have shown promise. Both approaches require more complete investigation, which may be facilitated through new disease models using patient-specific induced pluripotent stem cell-derived hepatocyte like cells^[40]. Surgical interruption of the enterohepatic circulation may improve pruritis but may not change the course of disease^[46]. Notably, the response to diversion has been shown to be dependent on the gene defect, with those who retain some residual protein function having better outcomes than those with mutations resulting in severely dysfunctional or absent protein^[41,42]. Pathology typically demonstrates canalicular cholestasis, hepatocellular disarray, and lobular and portal fibrosis^[9]. Importantly, there is up to 15% rate of malignancy (hepatocellular carcinoma and cholangiocarcinoma) that has been described in children as young as 13 mo^[43]. Therefore, patients with PFIC2 should be screened for malignancy with an alpha-fetoprotein (AFP) level and abdominal ultrasound every 6-12 mo^[9]. Liver transplant has been successfully used to treat severe BSEP disease and in those who develop tumor. While organ replacement has historically been considered a “cure”, patients can develop allo-reactive antibodies specific to the extracellular loop of the BSEP protein resulting in an immune mediated recurrence of their BSEP disease in the allograft^[44-46]. Monitoring for disease recurrence is critical as most disease will respond to increased immunosuppression. However, with refractory disease recurrence, more intensive management such as B-cell depleting antibody therapy^[47], allogeneic hematopoietic stem cell transplant^[48], and repeat solid organ transplant^[49] may be required.

Similar to *ATP8B1*, a phenotypic continuum has been recognized with *ABCB11* mutations. Transient neonatal cholestasis, benign recurrent intrahepatic cholestasis type 2 (BRIC2), intrahepatic cholestasis of pregnancy type 2 (ICP2), and drug induced cholestasis have all been associated with abnormalities in BSEP^[50,51]. Two mutations have been found that prognosticate a modified disease course of BSEP disease: D482G leads to a more slowly progressive disease with the development of cirrhosis at a later age, and E297G results in PFIC2 or BRIC2 that may be more responsive to medical therapy^[4,9]. Drug induced cholestasis is often associated with the V444A mutation, which leads to decreased BSEP expression, and specifically contraceptive induced cholestasis has been associated with the 1331T>C polymorphism^[52,53].

***ABCB4* (MDR3, PFIC3):** Also described as a cholangiopathy, PFIC3 is secondary to defects in the multidrug resistance class 3 (MDR3) glycoprotein, encoded by *ABCB4*^[54]. As a phospholipid translocator, MDR3 facilitates the incorporation of phosphatidylcholine into bile. Without phosphatidylcholine to neutralize bile acids, the imbalance of free bile acids damages cholangiocytes, and cholesterol crystallizes into liver-damaging stones^[9]. As with other PFIC diseases, there is a spectrum of disease that can be explained by the extent to which MDR3 is impaired by a particular genetic mutation^[55,56]. Those with a heterozygous mutation typically have a mild

disease course, including forms of transient neonatal cholestasis^[55,57]. Of the described defects in MDR3, the majority are missense mutations that result in defective processing or intracellular transport; while the minority have completely absent MDR3 expression secondary to early truncation or destruction of the protein^[9,55,57,58]. While presentation in the first months of life are reported, MDR3 deficiency more often presents in late adolescence or even adulthood^[59]. The phenotype of adults with *ABCB4* mutations can be varied, ranging from slowly progressive disease, cholelithiasis, ICP, drug induced cholestasis, and benign recurrent intrahepatic cholestasis^[58]. In children and adolescents, symptoms are typically few, and the first may be variceal bleeding secondary to portal hypertension^[9]. A retrospective review of 38 patients found that those diagnosed in childhood presented with pruritis around 1 year of age and most had hepatosplenomegaly, portal hypertension, and jaundice at the time of presentation^[58]. Pediatric disease has also been associated with growth restriction, reduced bone density, and learning disabilities^[58]. GGT is typically elevated at presentation, with relatively milder elevation of transaminases and bilirubin^[41,59]. Medical treatment should be initiated early in the disease course. Care is supportive including nutrition supplementation and antipruritic agents, though it is not clear if these therapies alter the disease course^[4,55]. In vitro studies have suggested that disease-associated mutations resulting in impaired *ABCB4* trafficking may be functionally rescued by chemical chaperones^[56]. Temporizing surgical interventions as described above are rarely successful due to the severity of disease when diagnosed and liver transplant remains the only definitive therapy^[4,59]. Histology typically demonstrates portal fibrosis and bile duct proliferation with mild giant cell hepatitis at disease onset with occasional intraductal cholelithiasis^[9]. MDR3 immunohistochemical staining will be absent, decreased, or potentially normal if there are functional protein defects^[9]. Carcinogenesis and the development of both cholangiocarcinoma and hepatocellular carcinoma have been reported^[9,60,61].

Expanded PFIC

TJP2 (TJP2): Recently, alternate proteins have been identified in whom mutations result in a phenotypic pattern that is similarly to “classic” PFIC disease, mainly cholestasis presenting in the neonatal period. The first of these identified stems from loss of function mutations in *TJP2* encoding the tight junction protein TJP2. TJP2 is one of the intracellular anchors for tight junctions that seal canaliculi and prevent damage from cytotoxic detergent bile salts^[4,59]. To date the largest case series consists of 12 infants from 8 families (most consanguineous) who presented ≤ 3 mo of age with severe liver disease^[62]. Though still exceedingly rare, advances in genetic understanding has enabled retrospective re-classification suggesting TJP2 deficiency may be more common than previously thought^[63]. The disease results from biallelic mutations in *TJP2* with extrahepatic manifestation in the respiratory and neurologic systems having been reported. The mechanism of injury is thought to relate to TJP2’s function maintaining junction integrity, the disturbance of which enables toxic molecules to reflux into the paracellular space; however, this is not clearly described^[62]. Though few samples are available, pathology demonstrates intracellular cholestasis and giant cell transformation, with absence of TJP2 specific staining^[4]. Several mutations have been noted specific to the families who manifested the disease, but it is not yet clear if some mutations pertain to less severe disease than others or if there is a milder form of disease that may be appreciated in adult patients. Hepatocellular carcinoma has been described at presentation in infants^[64,65]. Due to the severity of presentation, 9 of the initial 12 patients described underwent liver transplant; 2 have survived with portal hypertension, and one passed away of their disease^[62].

NR1H4 (FXR): PFIC phenotype can also result from mutations in *NR1H4*, which encodes the FXR, the nuclear receptor transcription factor which regulates BSEP expression *via* negative feedback loop and induces FGF19 to repress bile acid synthesis^[4,66]. Patients reported with these defects are extremely rare, with only 5 patients reported in the literature^[67,68]. Without appropriate regulation of BSEP, patients with this defect have presented in the neonatal period with normal GGT cholestasis, normal liver enzymes, elevated serum bile acids, extremely elevated AFP, and rapidly progressed to end stage liver disease with vitamin K independent coagulopathy and hyperammonemia^[67,68]. On native liver pathology, the patients were found to have intralobular cholestasis with ductular reaction, hepatocellular ballooning, giant cell transformation, and fibrosis with progression to micronodular cirrhosis. Three patients underwent liver transplant with 2 of 3 showing steatosis in the graft organ on follow up^[67].

MYO5B (MYO5B): Defects in *MYO5B*, on which BSEP depends to localize to the

canalicular hepatocellular membrane, usually cause microvillus inclusion disease but also may result in isolated liver disease^[4]. Without appropriate BSEP localization, secretion of bile acids is impaired and causes hepatocellular toxicity^[69]. This results in a clinical picture of low GGT cholestasis, hepatomegaly, normal or mildly elevated transaminases. Patients have preserved synthetic function but struggle with pruritis and present around 1 year of age, similar to FIC1 and BSEP disease^[69]. The hepatocellular damage results in a pathologic pattern of hepatocellular cholestasis with portal and lobular fibrosis and giant cell transformation. Present but abnormal BSEP and MDR3 staining suggest that these transporters are made but can't appropriately migrate to the canalicular membrane^[69].

Because MYO5B interacts with rab11 for appropriate functioning of polarized cells, extrahepatic manifestations can be present. MYO5B has previously been implicated in microvillous inclusion disease, thus some patients with genetic cholestasis have also had diarrheal manifestations of disease^[69]. Similarly, some patients also suffer short stature, though others have normal growth. Finally, some patients with this disease have neurologic findings, though it is not clear if these are related to the gene defect^[4,69]. In addition to supportive care for nutrition and diarrhea, patients have been treated with antipruritic and anticholestatic agents, including UDCA, rifampin, cholestyramine, traditional Chinese medicine^[4,69]. If pruritis is refractory to medical therapy, some success has been seen with PEBD. Finally, liver transplant has been undertaken if pruritis is refractory, though it does not address extrahepatic symptoms^[69]. At our institution, the association between MYO5B defects, intestinal failure, and isolated liver disease has made decisions regarding type of transplant (isolated bowel, liver bowel, multi-visceral, *etc*) challenging in patients with microvillus inclusion disease.

USP53 (USP53) and LSR (LSR): A recent report utilizing exome sequencing and positional mapping was able to identify 2 novel loci with defects associated with low-GGT cholestatic liver disease presenting in childhood^[70]. In the first case, 3 members of a family (2 sisters and a cousin) presented with low-ggt cholestasis, liver enzyme elevations, and pruritus. Defects in the USP53 protein, thought to colocalize with TJP2 and be part of the tight junction complex^[71], was identified. In the second case, a young boy who presented with hypocalcemic seizures, pruritus, liver enzyme elevation, and low-ggt cholestasis was found to have a mutation in lipolysis-stimulated lipoprotein receptor (LSR). Mechanisms by which LSR contributed to the liver disease were not reported, although LSRs role in animal models of liver development suggests an area for future research^[70].

Contributions beyond pediatrics

The traditional understanding of the PFIC-associated genes contributing to morbidity in adults mainly encompass the phenotypes of BRIC and ICP. The phenotype of BRIC is characterized by intermittent episodes of cholestasis with varying degrees of severity. Both *ATP8B1* and *ABCB11* mutations have been associated with the phenotype^[12,51]. While classic descriptions of BRIC note complete symptom resolution without progression, several cases have been reported to transition to more persistent, progressive disease^[72]. Treatment of cholestatic episodes with steroids, choleretic agents, and bile acid binders have generally been ineffective, although rifampicin has been shown to decrease pruritus and shorten exacerbations^[73,74]. ICP is a common condition affecting about 1% of all pregnancies^[75]. ICP manifests during pregnancy with pruritus, hepatic impairment, and cholestasis which usually resolves completely after delivery. While generally considered benign for the mother, adverse perinatal outcomes for the child, such as fetal distress, premature birth, and stillbirth, can occur^[75]. While rare, stillbirth has been shown to be associated with bile acid concentrations of ≥ 100 $\mu\text{mol/L}$ highlighting the importance of close monitoring^[76]. The use of ursodiol has been shown to symptomatically improve pruritus and decrease the risk of premature birth^[77,78]. An expanded understanding of the genetics associated with ICP has identified mutations in *ABCB4*, *ABCB11*, *ATP8B1*, *ABCC2* (associated with Dubin-Johnson), and *TJP2* contributing to disease^[79]. Additionally, variations in *NR1H4* may be implicated in ICP, possibly *via* downregulation of BSEP expression^[80]. Beyond BRIC and ICP, drug-induced injury has been historically been linked to PFIC gene associated polymorphisms^[52].

More recently, investigators have begun looking more broadly at the contributions that these genes may have on morbidity in adult populations (Table 2). Mutations in *ATP8B1*, *ABCB11*, *ABCB4*, and *TJP2* have been reported in adults with cryptogenic cirrhosis^[81] while *ABCB4* defects have been linked to the development of sclerosing cholangitis, biliary cirrhosis, and low-phospholipid cholelithiasis^[82,83]. Genetic sequencing of large cholestatic populations have revealed disease causing mutations in up to a third of patients, with common variants detected in a high number of those

without known disease-causing defects suggesting that they still may have a contributing role to the development of cholestasis^[83]. Importantly, several of the recently identified contributing genes, such as *NR1H4*, *MYO5B*, *USP53* and *LSR* were not tested for in these studies, suggesting the burden may still be higher.

DISCUSSION

PFIC is a heterogeneous cohort of diseases that present both diagnostic and treatment challenges for clinicians. While significant advancement in bile transport physiology has been made by studying these diseases, the breadth of phenotypes from neonates to adults demonstrates that there remains much more to be understood. In the future, precise molecular diagnosis may allow individualized therapy through gene replacement or protein augmentation therapies.

Table 2 Adult manifestations of progressive familial intrahepatic cholestasis gene mutations

Etiology	Genetic defect	Manifestations
FIC1 deficiency	<i>ATP8B1</i>	BRIC1 ICP1 and contraceptive-induced cholestasis Cryptogenic cirrhosis
BSEP deficiency	<i>ABCB11</i>	BRIC2 ICP2 and contraceptive-induced cholestasis DILI Cryptogenic cirrhosis
MDR3 deficiency	<i>ABCB4</i>	ICP3 and contraceptive-induced cholestasis Drug induced cholestasis Low phospholipid-associated cholestasis Cholesterol gallstone disease Biliary fibrosis or liver cirrhosis without cholestasis Cryptogenic cirrhosis
TJP2 deficiency	<i>TJP2</i>	Cryptogenic cirrhosis
FXR	<i>NR1H4</i>	ICP Drug induced cholestasis associated with propylthiouracil

BRIC: Benign recurrent intrahepatic cholestasis; BSEP: Bile salt export pump; ICP: Intrahepatic cholestasis of pregnancy; DILI: Drug induce liver injury.

ARTICLE HIGHLIGHTS

Research background

Progressive familial intrahepatic cholestasis (PFIC) is an umbrella term originally used to describe 3 classic genetic-based cholestatic diseases in children. Recent advancements in how genetic defects in proteins affect bile acid homeostasis and caused disease has led to an expanded list of syndromes categorized as PFIC and a growing understanding of how adults can be affected. In this report, we review the literature to summarize the understanding of 'classic' PFIC diseases and present up-to-date information the expanding list of genetic defects that are now known to contribute to the PFIC phenotype.

Research motivation

Bile acid metabolism, homeostasis, and transport is a complex physiologic process, the importance of which is underscored when defects in the system cause disease. While recent advancements have identified critical genes and protein products that, when defective, contribute to disease, phenotypic variability persists, and treatment remains mainly supportive. Furthermore, it is clearly that additional genes and proteins are likely to be identified as the field continues to evolve. In the future, better diagnostics and precise molecular defect identification may identify individualized therapy options that will improve the care provided to these patients.

Research objectives

The objectives of this work were to thoroughly review the current published literature and present an up-to-date summarization of both the "Classic" and "Expanded" PFIC diseases.

Research methods

A Medline/PubMed search was performed to identify established articles relating to PFIC as well as reports of defects in PFIC-related genes contributing to morbidity in adult and pediatric populations. Data was manually extracted on disease characteristics. Associated phenotypes with other diseases relating to specific genetic defects were also collected. Treatment strategies were summarized. Data was collated and presented in text, figure, and table format.

Research results

We present a comprehensive summary of the "Classic" PFIC disorders resulting from defects in *ATP8B1* (FIC1 protein), *ABCB11* (BSEP protein), and *ABCB4* (MDR3 protein). We further explore and summarize the "Expanded" PFIC disorders including those related to *TJP1* (TJP2 protein), *NR1H4* (FXR protein), *MYO5B* (MYO5B protein), *USP53* (USP53 protein), and *LSR* (LSR protein) defects. While many of these disorders have historically affected children, we also looked to present the growing literature related to the significant morbidity that these diseases cause in adults.

Research conclusions

In this review, we present a comprehensive summary of the current understanding and

management of PFIC-related disorders. The recent identification of the “Expanded” disorders underscores the importance of continued exploration of the genetic basis of bile acid homeostasis. However, idiopathic disease remains a considerable challenge to patients and healthcare professionals suggesting opportunities for further investigation. Future strategies to improve the treatment provided to patients affected by these devastating diseases are also critically needed.

Research perspectives

Since their first description in 1969, the last 50 years has brought dramatic advancements in both the understanding and management of PFIC-related diseases. Still, challenges remain. Continued idiopathic disease suggest improvement in diagnostic strategies are needed and treatment options remain frustratingly small. Variability in both phenotype and response to therapy opens the possibility that specific gene defects or modifiers can identify sub-populations where more personalized approaches can be more effective. Improved disease models, both *in vitro* and *in vivo*, are needed to better understand mechanisms and identify therapeutic strategies. Finally, the growing morbidity linked to defects in PFIC-related genes identified in adults highlights the urgency, but also the opportunity, for future investigation.

REFERENCES

- 1 Linton KJ. Lipid flopping in the liver. *Biochem Soc Trans* 2015; **43**: 1003-1010 [PMID: 26517915 DOI: 10.1042/BST20150132]
- 2 Dawson PA, Haywood J, Craddock AL, Wilson M, Tietjen M, Kluckman K, Maeda N, Parks JS. Targeted deletion of the ileal bile acid transporter eliminates enterohepatic cycling of bile acids in mice. *J Biol Chem* 2003; **278**: 33920-33927 [PMID: 12819193 DOI: 10.1074/jbc.M306370200]
- 3 Boyer JL. Bile formation and secretion. *Compr Physiol* 2013; **3**: 1035-1078 [PMID: 23897680 DOI: 10.1002/cphy.c120027]
- 4 Bull LN, Thompson RJ. Progressive Familial Intrahepatic Cholestasis. *Clin Liver Dis* 2018; **22**: 657-669 [PMID: 30266155 DOI: 10.1016/j.cld.2018.06.003]
- 5 Clayton RJ, Iber FL, Ruebner BH, McKusick VA. Byler disease. Fatal familial intrahepatic cholestasis in an Amish kindred. *Am J Dis Child* 1969; **117**: 112-124 [PMID: 5762004]
- 6 Bull LN, van Eijk MJ, Pawlikowska L, DeYoung JA, Juijn JA, Liao M, Klomp LW, Lomri N, Berger R, Scharschmidt BF, Knisely AS, Houwen RH, Freimer NB. A gene encoding a P-type ATPase mutated in two forms of hereditary cholestasis. *Nat Genet* 1998; **18**: 219-224 [PMID: 9500542 DOI: 10.1038/ng0398-219]
- 7 Paulusma CC, Groen A, Kunne C, Ho-Mok KS, Spijkerboer AL, Rudi de Waart D, Hoek FJ, Vreeling H, Hoebe KA, van Marle J, Pawlikowska L, Bull LN, Hofmann AF, Knisely AS, Oude Elferink RP. Atp8b1 deficiency in mice reduces resistance of the canalicular membrane to hydrophobic bile salts and impairs bile salt transport. *Hepatology* 2006; **44**: 195-204 [PMID: 16799980 DOI: 10.1002/hep.21212]
- 8 Folmer DE, van der Mark VA, Ho-Mok KS, Oude Elferink RP, Paulusma CC. Differential effects of progressive familial intrahepatic cholestasis type 1 and benign recurrent intrahepatic cholestasis type 1 mutations on canalicular localization of ATP8B1. *Hepatology* 2009; **50**: 1597-1605 [PMID: 19731236 DOI: 10.1002/hep.23158]
- 9 Srivastava A. Progressive familial intrahepatic cholestasis. *J Clin Exp Hepatol* 2014; **4**: 25-36 [PMID: 25755532 DOI: 10.1016/j.jceh.2013.10.005]
- 10 Davit-Spraul A, Fabre M, Branchereau S, Baussan C, Gonzales E, Stieger B, Bernard O, Jacquemin E. ATP8B1 and ABCB11 analysis in 62 children with normal gamma-glutamyl transferase progressive familial intrahepatic cholestasis (PFIC): phenotypic differences between PFIC1 and PFIC2 and natural history. *Hepatology* 2010; **51**: 1645-1655 [PMID: 20232290 DOI: 10.1002/hep.23539]
- 11 Alonso EM, Snover DC, Montag A, Freese DK, Whittington PF. Histologic pathology of the liver in progressive familial intrahepatic cholestasis. *J Pediatr Gastroenterol Nutr* 1994; **18**: 128-133 [PMID: 8014759]
- 12 Bull LN, Carlton VE, Stricker NL, Baharloo S, DeYoung JA, Freimer NB, Magid MS, Kahn E, Markowitz J, DiCarlo FJ, McLoughlin L, Boyle JT, Dahms BB, Faught PR, Fitzgerald JF, Piccoli DA, Witzleben CL, O'Connell NC, Setchell KD, Agostini RM, Kocoshis SA, Reyes J, Knisely AS. Genetic and morphological findings in progressive familial intrahepatic cholestasis (Byler disease [PFIC-1] and Byler syndrome): evidence for heterogeneity. *Hepatology* 1997; **26**: 155-164 [PMID: 9214465 DOI: 10.1002/hep.510260121]
- 13 van der Woerd WL, Wichers CG, Vestergaard AL, Andersen JP, Paulusma CC, Houwen RH, van de Graaf SF. Rescue of defective ATP8B1 trafficking by CFTR correctors as a therapeutic strategy for familial intrahepatic cholestasis. *J Hepatol* 2016; **64**: 1339-1347 [PMID: 26879107 DOI: 10.1016/j.jhep.2016.02.001]
- 14 Squires JE, Celik N, Morris A, Soltys K, Mazariegos G, Shneider B, Squires RH. Clinical Variability After Partial External Biliary Diversion in Familial Intrahepatic Cholestasis 1 Deficiency. *J Pediatr Gastroenterol Nutr* 2017; **64**: 425-430 [PMID: 28045770 DOI: 10.1097/MPG.0000000000001493]
- 15 Emond JC, Whittington PF. Selective surgical management of progressive familial intrahepatic cholestasis (Byler's disease). *J Pediatr Surg* 1995; **30**: 1635-1641 [PMID: 8749912]
- 16 Wang KS, Tiao G, Bass LM, Hertel PM, Mogul D, Kerkar N, Clifton M, Azen C, Bull L, Rosenthal P, Stewart D, Superina R, Arnon R, Bozic M, Brandt ML, Dillon PA, Fecteau A, Iyer K, Kamath B, Karpen S, Karrer F, Loomes KM, Mack C, Mattei P, Miethke A, Soltys K, Turmelle YP, West K, Zagory J, Goodhue C, Shneider BL; Childhood Liver Disease Research Network (ChILDRen). Analysis of surgical interruption of the enterohepatic circulation as a treatment for pediatric cholestasis. *Hepatology* 2017; **65**: 1645-1654 [PMID: 28027587 DOI: 10.1002/hep.29019]
- 17 Whittington PF, Whittington GL. Partial external diversion of bile for the treatment of intractable pruritus associated with intrahepatic cholestasis. *Gastroenterology* 1988; **95**: 130-136 [PMID: 3371608]
- 18 Kaliciński PJ, Ismail H, Jankowska I, Kamiński A, Pawłowska J, Drewniak T, Markiewicz M, Szymczak M. Surgical treatment of progressive familial intrahepatic cholestasis: comparison of partial external biliary diversion and ileal bypass. *Eur J Pediatr Surg* 2003; **13**: 307-311 [PMID: 14618520 DOI: 10.1007/s00381-003-0811-1]

- 10.1055/s-2003-43570]
- 19 **Ismail H**, Kaliciński P, Markiewicz M, Jankowska I, Pawłowska J, Kluge P, Eliadou E, Kamiński A, Szymczak M, Drewniak T, Revillon Y. Treatment of progressive familial intrahepatic cholestasis: liver transplantation or partial external biliary diversion. *Pediatr Transplant* 1999; **3**: 219-224 [PMID: 10487283]
 - 20 **Hollands CM**, Rivera-Pedrogo FJ, Gonzalez-Vallina R, Loret-de-Mola O, Nahmad M, Burnweit CA. Ileal exclusion for Byler's disease: an alternative surgical approach with promising early results for pruritus. *J Pediatr Surg* 1998; **33**: 220-224 [PMID: 9498390]
 - 21 **Gün F**, Erginel B, Durmaz O, Sökücü S, Salman T, Celik A. An outstanding non-transplant surgical intervention in progressive familial intrahepatic cholestasis: partial internal biliary diversion. *Pediatr Surg Int* 2010; **26**: 831-834 [PMID: 20563871 DOI: 10.1007/s00383-010-2638-x]
 - 22 **Gunaydin M**, Tander B, Demirel D, Caltepe G, Kalayci AG, Eren E, Bicakci U, Rizalar R, Ariturk E, Bernay F. Different techniques for biliary diversion in progressive familial intrahepatic cholestasis. *J Pediatr Surg* 2016; **51**: 386-389 [PMID: 26382286 DOI: 10.1016/j.jpedsurg.2015.08.011]
 - 23 **Bustorff-Silva J**, Sbraggia Neto L, Olimpio H, de Alcantara RV, Matsushima E, De Tommaso AM, Brandão MA, Hessel G. Partial internal biliary diversion through a cholecystojejunocolonic anastomosis--a novel surgical approach for patients with progressive familial intrahepatic cholestasis: a preliminary report. *J Pediatr Surg* 2007; **42**: 1337-1340 [PMID: 17706492 DOI: 10.1016/j.jpedsurg.2007.03.029]
 - 24 **Thébaud A**, Debray D, Gonzales E. An update on the physiopathology and therapeutic management of cholestatic pruritus in children. *Clin Res Hepatol Gastroenterol* 2018; **42**: 103-109 [PMID: 29031874 DOI: 10.1016/j.clinre.2017.08.007]
 - 25 **Meerzaman DM**, Yan C, Chen QR, Edmonson MN, Schaefer CF, Clifford RJ, Dunn BK, Dong L, Finney RP, Cultraro CM, Hu Y, Yang Z, Nguyen CV, Kelley JM, Cai S, Zhang H, Zhang J, Wilson R, Messmer L, Chung YH, Kim JA, Park NH, Lyu MS, Song IH, Komatsoulis G, Buetow KH. Genome-wide transcriptional sequencing identifies novel mutations in metabolic genes in human hepatocellular carcinoma. *Cancer Genomics Proteomics* 2014; **11**: 1-12 [PMID: 24633315]
 - 26 **Squires JE**. Protecting the allograft following liver transplantation for PFIC1. *Pediatr Transplant* 2016; **20**: 882-883 [PMID: 27566138 DOI: 10.1111/ptr.12787]
 - 27 **Mali VP**, Fukuda A, Shigeta T, Uchida H, Hirata Y, Rahayatri TH, Kanazawa H, Sasaki K, de Ville de Goyet J, Kasahara M. Total internal biliary diversion during liver transplantation for type 1 progressive familial intrahepatic cholestasis: a novel approach. *Pediatr Transplant* 2016; **20**: 981-986 [PMID: 27534385 DOI: 10.1111/ptr.12782]
 - 28 **Hsu YC**, Chen HL, Wu MZ, Liu YJ, Lee PH, Sheu JC, Chen CH. Adult progressive intrahepatic cholestasis associated with genetic variations in ATP8B1 and ABCB11. *Hepatol Res* 2009; **39**: 625-631 [PMID: 19260995]
 - 29 **Dixon PH**, Wadsworth CA, Chambers J, Donnelly J, Cooley S, Buckley R, Mannino R, Jarvis S, Syngelaki A, Geenes V, Paul P, Sothinathan M, Kubitz R, Lammert F, Tribe RM, Ch'ng CL, Marshall HU, Glantz A, Khan SA, Nicolaides K, Whittaker J, Geary M, Williamson C. A comprehensive analysis of common genetic variation around six candidate loci for intrahepatic cholestasis of pregnancy. *Am J Gastroenterol* 2014; **109**: 76-84 [PMID: 24366234 DOI: 10.1038/ajg.2013.406]
 - 30 **Müllenbach R**, Bennett A, Tetlow N, Patel N, Hamilton G, Cheng F, Chambers J, Howard R, Taylor-Robinson SD, Williamson C. ATP8B1 mutations in British cases with intrahepatic cholestasis of pregnancy. *Gut* 2005; **54**: 829-834 [PMID: 15888793 DOI: 10.1136/gut.2004.058115]
 - 31 **Klomp LW**, Vargas JC, van Mil SW, Pawlikowska L, Strautnieks SS, van Eijk MJ, Juijn JA, Pabón-Peña C, Smith LB, DeYoung JA, Byrne JA, Gombert J, van der Brugge G, Berger R, Jankowska I, Pawłowska J, Villa E, Knisely AS, Thompson RJ, Freimer NB, Houwen RH, Bull LN. Characterization of mutations in ATP8B1 associated with hereditary cholestasis. *Hepatology* 2004; **40**: 27-38 [PMID: 15239083 DOI: 10.1002/hep.20285]
 - 32 **Strautnieks SS**, Bull LN, Knisely AS, Kocoshis SA, Dahl N, Arnell H, Sokal E, Dahan K, Childs S, Ling V, Tanner MS, Kagalwalla AF, Németh A, Pawłowska J, Baker A, Mieli-Vergani G, Freimer NB, Gardiner RM, Thompson RJ. A gene encoding a liver-specific ABC transporter is mutated in progressive familial intrahepatic cholestasis. *Nat Genet* 1998; **20**: 233-238 [PMID: 9806540 DOI: 10.1038/3034]
 - 33 **Gerloff T**, Stieger B, Hagenbuch B, Madon J, Landmann L, Roth J, Hofmann AF, Meier PJ. The sister of P-glycoprotein represents the canalicular bile salt export pump of mammalian liver. *J Biol Chem* 1998; **273**: 10046-10050 [PMID: 9545351]
 - 34 **Imagawa K**, Hayashi H, Sabu Y, Tanikawa K, Fujishiro J, Kajikawa D, Wada H, Kudo T, Kage M, Kusuhashi H, Sumazaki R. Clinical phenotype and molecular analysis of a homozygous ABCB11 mutation responsible for progressive infantile cholestasis. *J Hum Genet* 2018; **63**: 569-577 [PMID: 29507376 DOI: 10.1038/s10038-018-0431-1]
 - 35 **Thompson R**, Strautnieks S. BSEP: function and role in progressive familial intrahepatic cholestasis. *Semin Liver Dis* 2001; **21**: 545-550 [PMID: 11745042]
 - 36 **Chen HL**, Chang PS, Hsu HC, Ni YH, Hsu HY, Lee JH, Jeng YM, Shau WY, Chang MH. FIC1 and BSEP defects in Taiwanese patients with chronic intrahepatic cholestasis with low gamma-glutamyltranspeptidase levels. *J Pediatr* 2002; **140**: 119-124 [PMID: 11815775 DOI: 10.1067/mpd.2002.119993]
 - 37 **Ellis JL**, Bove KE, Schuetz EG, Leino D, Valencia CA, Schuetz JD, Miethke A, Yin C. Zebrafish abcb11b mutant reveals strategies to restore bile excretion impaired by bile salt export pump deficiency. *Hepatology* 2018; **67**: 1531-1545 [PMID: 29091294 DOI: 10.1002/hep.29632]
 - 38 **Naio S**, Hayashi H, Inoue T, Tanikawa K, Igarashi K, Nagasaka H, Kage M, Takikawa H, Sugiyama Y, Inui A, Nagai T, Kusuhashi H. Improved liver function and relieved pruritus after 4-phenylbutyrate therapy in a patient with progressive familial intrahepatic cholestasis type 2. *J Pediatr* 2014; **164**: 1219-1227.e3 [PMID: 24530123 DOI: 10.1016/j.jpeds.2013.12.032]
 - 39 **Malatack JJ**, Doyle D. A Drug Regimen for Progressive Familial Cholestasis Type 2. *Pediatrics* 2018; **141** [PMID: 29284646 DOI: 10.1542/peds.2016-3877]
 - 40 **Imagawa K**, Takayama K, Isoyama S, Tanikawa K, Shinkai M, Harada K, Tachibana M, Sakurai F, Noguchi E, Hirata K, Kage M, Kawabata K, Sumazaki R, Mizuguchi H. Generation of a bile salt export pump deficiency model using patient-specific induced pluripotent stem cell-derived hepatocyte-like cells. *Sci Rep* 2017; **7**: 41806 [PMID: 28150711 DOI: 10.1038/srep41806]
 - 41 **Bull LN**, Pawlikowska L, Strautnieks S, Jankowska I, Czubkowski P, Dodge JL, Emerick K, Wanty C, Wali S, Blanchard S, Lacaille F, Byrne JA, van Eerde AM, Kolho KL, Houwen R, Lobritto S, Hupertz V, McClean P, Mieli-Vergani G, Sokal E, Rosenthal P, Whittington PF, Pawłowska J, Thompson RJ.

- Outcomes of surgical management of familial intrahepatic cholestasis 1 and bile salt export protein deficiencies. *Hepatol Commun* 2018; **2**: 515-528 [PMID: 29761168 DOI: 10.1002/hep4.1168]
- 42 **Ellinger P**, Stindt J, Dröge C, Sattler K, Stross C, Kluge S, Herebald D, Smits SHJ, Burdelski M, Schulz-Jürgensen S, Ballauff A, Schulte Am Esch J, Mayatepek E, Häussinger D, Kubitz R, Schmitt L. Partial external biliary diversion in bile salt export pump deficiency: Association between outcome and mutation. *World J Gastroenterol* 2017; **23**: 5295-5303 [PMID: 28839429 DOI: 10.3748/wjg.v23.i29.5295]
- 43 **Knisely AS**, Strautnieks SS, Meier Y, Stieger B, Byrne JA, Portmann BC, Bull LN, Pawlikowska L, Bilezikçi B, Özçay F, László A, Tiszlavicz L, Moore L, Raftos J, Arnell H, Fischler B, Németh A, Papadogiannakis N, Cielecka-Kuszyk J, Jankowska I, Pawłowska J, Melin-Aldana H, Emerick KM, Whittington PF, Mieli-Vergani G, Thompson RJ. Hepatocellular carcinoma in ten children under five years of age with bile salt export pump deficiency. *Hepatology* 2006; **44**: 478-486 [PMID: 16871584 DOI: 10.1002/hep.21287]
- 44 **Jara P**, Hierro L, Martínez-Fernández P, Alvarez-Doforno R, Yáñez F, Diaz MC, Camarena C, De la Vega A, Frauca E, Muñoz-Bartolo G, López-Santamaría M, Larrauri J, Alvarez L. Recurrence of bile salt export pump deficiency after liver transplantation. *N Engl J Med* 2009; **361**: 1359-1367 [PMID: 19797282 DOI: 10.1056/NEJMoa0901075]
- 45 **Siebold L**, Dick AA, Thompson R, Maggiore G, Jacquemin E, Jaffe R, Strautnieks S, Grammatikopoulos T, Horslen S, Whittington PF, Shneider BL. Recurrent low gamma-glutamyl transpeptidase cholestasis following liver transplantation for bile salt export pump (BSEP) disease (posttransplant recurrent BSEP disease). *Liver Transpl* 2010; **16**: 856-863 [PMID: 20583290 DOI: 10.1002/lt.22074]
- 46 **Stindt J**, Kluge S, Dröge C, Keitel V, Stross C, Baumann U, Brinkert F, Dhawan A, Engelmann G, Ganschow R, Gerner P, Grabhorn E, Knisely AS, Noli KA, Pukite I, Shepherd RW, Ueno T, Schmitt L, Wiek C, Hanenberg H, Häussinger D, Kubitz R. Bile salt export pump-reactive antibodies form a polyclonal, multi-inhibitory response in antibody-induced bile salt export pump deficiency. *Hepatology* 2016; **63**: 524-537 [PMID: 26516723 DOI: 10.1002/hep.28311]
- 47 **Lin HC**, Alvarez L, Laroche G, Melin-Aldana H, Pfeifer K, Schwarz K, Whittington PF, Alonso EM, Ekong UD. Rituximab as therapy for the recurrence of bile salt export pump deficiency after liver transplantation. *Liver Transpl* 2013; **19**: 1403-1410 [PMID: 24115678 DOI: 10.1002/lt.23754]
- 48 **Brinkert F**, Pukite I, Krebs-Schmitt D, Briem-Richter A, Stindt J, Häussinger D, Keitel V, Müller I, Grabhorn E. Allogeneic haematopoietic stem cell transplantation eliminates alloreactive inhibitory antibodies after liver transplantation for bile salt export pump deficiency. *J Hepatol* 2018; **69**: 961-965 [PMID: 29935200 DOI: 10.1016/j.jhep.2018.06.003]
- 49 **Krebs-Schmitt D**, Briem-Richter A, Brinkert F, Keitel V, Pukite I, Lenhartz H, Fischer L, Grabhorn E. Alloimmunity and Cholestasis After Liver Transplantation in Children With Progressive Familial Intrahepatic Cholestasis. *J Pediatr Gastroenterol Nutr* 2019; **68**: 169-174 [PMID: 30664572 DOI: 10.1097/MPG.0000000000002200]
- 50 **Kubitz R**, Dröge C, Stindt J, Weissenberger K, Häussinger D. The bile salt export pump (BSEP) in health and disease. *Clin Res Hepatol Gastroenterol* 2012; **36**: 536-553 [PMID: 22795478 DOI: 10.1016/j.clinre.2012.06.006]
- 51 **van Mil SW**, van der Woerd WL, van der Brugge G, Sturm E, Jansen PL, Bull LN, van den Berg IE, Berger R, Houwen RH, Klomp LW. Benign recurrent intrahepatic cholestasis type 2 is caused by mutations in ABCB11. *Gastroenterology* 2004; **127**: 379-384 [PMID: 15300568]
- 52 **Lang C**, Meier Y, Stieger B, Beuers U, Lang T, Kerb R, Kullak-Ublick GA, Meier PJ, Pauli-Magnus C. Mutations and polymorphisms in the bile salt export pump and the multidrug resistance protein 3 associated with drug-induced liver injury. *Pharmacogenet Genomics* 2007; **17**: 47-60 [PMID: 17264802 DOI: 10.1097/01.fpc.0000230418.28091.76]
- 53 **Meier Y**, Zordan T, Lang C, Zimmermann R, Kullak-Ublick GA, Meier PJ, Stieger B, Pauli-Magnus C. Increased susceptibility for intrahepatic cholestasis of pregnancy and contraceptive-induced cholestasis in carriers of the 1331T>C polymorphism in the bile salt export pump. *World J Gastroenterol* 2008; **14**: 38-45 [PMID: 18176959 DOI: 10.3748/wjg.14.38]
- 54 **Mauad TH**, van Nieuwkerk CM, Dingemans KP, Smit JJ, Schinkel AH, Notenboom RG, van den Bergh Weerman MA, Verkuisen RP, Groen AK, Oude Elferink RP. Mice with homozygous disruption of the *mdr2* P-glycoprotein gene. A novel animal model for studies of nonsuppurative inflammatory cholangitis and hepatocarcinogenesis. *Am J Pathol* 1994; **145**: 1237-1245 [PMID: 7977654]
- 55 **Davit-Spraul A**, Gonzales E, Baussan C, Jacquemin E. The spectrum of liver diseases related to ABCB4 gene mutations: pathophysiology and clinical aspects. *Semin Liver Dis* 2010; **30**: 134-146 [PMID: 20422496 DOI: 10.1055/s-0030-1253223]
- 56 **Gordo-Gilart R**, Andueza S, Hierro L, Jara P, Alvarez L. Functional Rescue of Trafficking-Impaired ABCB4 Mutants by Chemical Chaperones. *PLoS One* 2016; **11**: e0150098 [PMID: 26900700 DOI: 10.1371/journal.pone.0150098]
- 57 **Gonzales E**, Davit-Spraul A, Baussan C, Buffet C, Maurice M, Jacquemin E. Liver diseases related to MDR3 (ABCB4) gene deficiency. *Front Biosci (Landmark Ed.)* 2009; **14**: 4242-4256 [PMID: 19273348]
- 58 **Schatz SB**, Jüngst C, Keitel-Anselmo V, Kubitz R, Becker C, Gerner P, Pfister ED, Goldschmidt I, Junge N, Wenning D, Gehring S, Arens S, Bretschneider D, Grothues D, Engelmann G, Lammert F, Baumann U. Phenotypic spectrum and diagnostic pitfalls of ABCB4 deficiency depending on age of onset. *Hepatol Commun* 2018; **2**: 504-514 [PMID: 29761167 DOI: 10.1002/hep4.1149]
- 59 **Squires JE**, McKiernan P. Molecular Mechanisms in Pediatric Cholestasis. *Gastroenterol Clin North Am* 2018; **47**: 921-937 [PMID: 30337041 DOI: 10.1016/j.gtc.2018.07.014]
- 60 **Vij M**, Shanmugam NP, Reddy MS, Govil S, Rella M. Hepatocarcinogenesis in multidrug-resistant P-glycoprotein 3 deficiency. *Pediatr Transplant* 2017; **21** [PMID: 28127842 DOI: 10.1111/ptr.12889]
- 61 **Tougeron D**, Fotsing G, Barbu V, Beauchant M. ABCB4/MDR3 gene mutations and cholangiocarcinomas. *J Hepatol* 2012; **57**: 467-468 [PMID: 22387667 DOI: 10.1016/j.jhep.2012.01.025]
- 62 **Sambrotta M**, Strautnieks S, Papouli E, Rushton P, Clark BE, Parry DA, Logan CV, Newbury LJ, Kamath BM, Ling S, Grammatikopoulos T, Wagner BE, Magee JC, Sokol RJ, Mieli-Vergani G; University of Washington Center for Mendelian Genomics, Smith JD, Johnson CA, McClean P, Simpson MA, Knisely AS, Bull LN, Thompson RJ. Mutations in TJP2 cause progressive cholestatic liver disease. *Nat Genet* 2014; **46**: 326-328 [PMID: 24614073 DOI: 10.1038/ng.2918]
- 63 **Shagrani M**, Burkholder J, Broering D, Abouelhoda M, Faquih T, El-Kalioby M, Subhani SN, Goljan E, Albar R, Monies D, Mazhar N, AlAbdulaziz BS, Abdelrahman KA, Altassan N, Alkuraya FS. Genetic profiling of children with advanced cholestatic liver disease. *Clin Genet* 2017; **92**: 52-61 [PMID: 28039895 DOI: 10.1111/cge.12959]

- 64 **Vij M**, Shanmugam NP, Reddy MS, Sankaranarayanan S, Rela M. Paediatric hepatocellular carcinoma in tight junction protein 2 (TJP2) deficiency. *Virchows Arch* 2017; **471**: 679-683 [PMID: [28733884](#) DOI: [10.1007/s00428-017-2204-1](#)]
- 65 **Zhou S**, Hertel PM, Finegold MJ, Wang L, Kerkar N, Wang J, Wong LJ, Plon SE, Sambrotta M, Foscett P, Niu Z, Thompson RJ, Knisely AS. Hepatocellular carcinoma associated with tight-junction protein 2 deficiency. *Hepatology* 2015; **62**: 1914-1916 [PMID: [25921221](#) DOI: [10.1002/hep.27872](#)]
- 66 **Davit-Spraul A**, Gonzales E, Jacquemin E. NR1H4 analysis in patients with progressive familial intrahepatic cholestasis, drug-induced cholestasis or intrahepatic cholestasis of pregnancy unrelated to ATP8B1, ABCB11 and ABCB4 mutations. *Clin Res Hepatol Gastroenterol* 2012; **36**: 569-573 [PMID: [23142591](#) DOI: [10.1016/j.clinre.2012.08.008](#)]
- 67 **Gomez-Ospina N**, Potter CJ, Xiao R, Manickam K, Kim MS, Kim KH, Shneider BL, Picarsic JL, Jacobson TA, Zhang J, He W, Liu P, Knisely AS, Finegold MJ, Muzny DM, Boerwinkle E, Lupski JR, Plon SE, Gibbs RA, Eng CM, Yang Y, Washington GC, Porteus MH, Berquist WE, Kambham N, Singh RJ, Xia F, Enns GM, Moore DD. Mutations in the nuclear bile acid receptor FXR cause progressive familial intrahepatic cholestasis. *Nat Commun* 2016; **7**: 10713 [PMID: [26888176](#) DOI: [10.1038/ncomms10713](#)]
- 68 **Chen HL**, Li HY, Wu JF, Wu SH, Chen HL, Yang YH, Hsu YH, Liou BY, Chang MH, Ni YH. Panel-Based Next-Generation Sequencing for the Diagnosis of Cholestatic Genetic Liver Diseases: Clinical Utility and Challenges. *J Pediatr* 2019; **205**: 153-159.e6 [PMID: [30366773](#) DOI: [10.1016/j.jpeds.2018.09.028](#)]
- 69 **Gonzales E**, Taylor SA, Davit-Spraul A, Thébaut A, Thomassin N, Guettier C, Whittington PF, Jacquemin E. MYO5B mutations cause cholestasis with normal serum gamma-glutamyl transferase activity in children without microvillous inclusion disease. *Hepatology* 2017; **65**: 164-173 [PMID: [27532546](#) DOI: [10.1002/hep.28779](#)]
- 70 **Maddirevula S**, Alhebbi H, Alqahtani A, Algoufi T, Alsaif HS, Ibrahim N, Abdulwahab F, Barr M, Alzaidan H, Almehaideb A, AlSasi O, Alhashem A, Hussaini HA, Wali S, Alkuraya FS. Identification of novel loci for pediatric cholestatic liver disease defined by KIF12, PPM1F, USP53, LSR, and WDR83OS pathogenic variants. *Genet Med* 2018 [PMID: [30250217](#) DOI: [10.1038/s41436-018-0288-x](#)]
- 71 **Kazmierczak M**, Harris SL, Kazmierczak P, Shah P, Starovoytov V, Ohlemiller KK, Schwander M. Progressive Hearing Loss in Mice Carrying a Mutation in Usp53. *J Neurosci* 2015; **35**: 15582-15598 [PMID: [26609154](#) DOI: [10.1523/JNEUROSCI.1965-15.2015](#)]
- 72 **van Ooteghem NA**, Klomp LW, van Berge-Henegouwen GP, Houwen RH. Benign recurrent intrahepatic cholestasis progressing to progressive familial intrahepatic cholestasis: low GGT cholestasis is a clinical continuum. *J Hepatol* 2002; **36**: 439-443 [PMID: [11867191](#)]
- 73 **Beuers U**, Trauner M, Jansen P, Poupon R. New paradigms in the treatment of hepatic cholestasis: from UDCA to FXR, PXR and beyond. *J Hepatol* 2015; **62**: S25-S37 [PMID: [25920087](#) DOI: [10.1016/j.jhep.2015.02.023](#)]
- 74 **Sticova E**, Jirsa M, Pawlowska J. New Insights in Genetic Cholestasis: From Molecular Mechanisms to Clinical Implications. *Can J Gastroenterol Hepatol* 2018; **2018**: 2313675 [PMID: [30148122](#) DOI: [10.1155/2018/2313675](#)]
- 75 **Dixon PH**, Williamson C. The pathophysiology of intrahepatic cholestasis of pregnancy. *Clin Res Hepatol Gastroenterol* 2016; **40**: 141-153 [PMID: [26823041](#) DOI: [10.1016/j.clinre.2015.12.008](#)]
- 76 **Ovadia C**, Seed PT, Sklavounos A, Geenes V, Di Ilio C, Chambers J, Kohari K, Bacq Y, Bozkurt N, Brun-Furrer R, Bull L, Estiú MC, Grymowicz M, Gunaydin B, Hague WM, Haslinger C, Hu Y, Kawakita T, Kebapcilar AG, Kebapcilar L, Kondrackienė J, Koster MPH, Kowalska-Kańka A, Kupčinskis L, Lee RH, Locatelli A, Macias RIR, Marschall HU, Oudijk MA, Raz Y, Rimón E, Shan D, Shao Y, Tribe R, Tripodi V, Yayla Abide C, Yenidede I, Thornton JG, Chappell LC, Williamson C. Association of adverse perinatal outcomes of intrahepatic cholestasis of pregnancy with biochemical markers: results of aggregate and individual patient data meta-analyses. *Lancet* 2019; **393**: 899-909 [PMID: [30773280](#) DOI: [10.1016/S0140-6736\(18\)31877-4](#)]
- 77 **Binder T**, Salaj P, Zima T, Vitek L. Randomized prospective comparative study of ursodeoxycholic acid and S-adenosyl-L-methionine in the treatment of intrahepatic cholestasis of pregnancy. *J Perinat Med* 2006; **34**: 383-391 [PMID: [16965225](#) DOI: [10.1515/JPM.2006.077](#)]
- 78 **Glantz A**, Marschall HU, Lammert F, Mattsson LA. Intrahepatic cholestasis of pregnancy: a randomized controlled trial comparing dexamethasone and ursodeoxycholic acid. *Hepatology* 2005; **42**: 1399-1405 [PMID: [16317669](#) DOI: [10.1002/hep.20952](#)]
- 79 **Dixon PH**, Sambrotta M, Chambers J, Taylor-Harris P, Syngelaki A, Nicolaides K, Knisely AS, Thompson RJ, Williamson C. An expanded role for heterozygous mutations of ABCB4, ABCB11, ATP8B1, ABCB2 and TJP2 in intrahepatic cholestasis of pregnancy. *Sci Rep* 2017; **7**: 11823 [PMID: [28924228](#) DOI: [10.1038/s41598-017-11626-x](#)]
- 80 **Van Mil SW**, Milona A, Dixon PH, Mullenbach R, Geenes VL, Chambers J, Shevchuk V, Moore GE, Lammert F, Glantz AG, Mattsson LA, Whittaker J, Parker MG, White R, Williamson C. Functional variants of the central bile acid sensor FXR identified in intrahepatic cholestasis of pregnancy. *Gastroenterology* 2007; **133**: 507-516 [PMID: [17681172](#) DOI: [10.1053/j.gastro.2007.05.015](#)]
- 81 **Vitale G**, Gitto S, Raimondi F, Mattiaccio A, Mantovani V, Vukotic R, D'Errico A, Seri M, Russell RB, Andreone P. Cryptogenic cholestasis in young and adults: ATP8B1, ABCB11, ABCB4, and TJP2 gene variants analysis by high-throughput sequencing. *J Gastroenterol* 2018; **53**: 945-958 [PMID: [29238877](#) DOI: [10.1007/s00535-017-1423-1](#)]
- 82 **Andress EJ**, Nicolaou M, McGeoghan F, Linton KJ. ABCB4 missense mutations D243A, K435T, G535D, I490T, R545C, and S978P significantly impair the lipid floppase and likely predispose to secondary pathologies in the human population. *Cell Mol Life Sci* 2017; **74**: 2513-2524 [PMID: [28220208](#) DOI: [10.1007/s00018-017-2472-6](#)]
- 83 **Dröge C**, Bonus M, Baumann U, Klindt C, Lainka E, Kathemann S, Brinkert F, Grabhorn E, Pfister ED, Wenning D, Fichtner A, Gotthardt DN, Weiss KH, Mckiernan P, Puri RD, Verma IC, Kluge S, Gohlke H, Schmitt L, Kubitz R, Häussinger D, Keitel V. Sequencing of FIC1, BSEP and MDR3 in a large cohort of patients with cholestasis revealed a high number of different genetic variants. *J Hepatol* 2017; **67**: 1253-1264 [PMID: [28733223](#) DOI: [10.1016/j.jhep.2017.07.004](#)]

Carvedilol vs endoscopic variceal ligation for primary and secondary prevention of variceal bleeding: Systematic review and meta-analysis

Michael Dwinata, David Dwi Putera, Muhamad Fajri Adda'i, Putra Nur Hidayat, Irsan Hasan

ORCID number: Michael Dwinata (0000-0001-8483-6806); David Dwi Putera (0000-0002-9170-9941); Muhamad Fajri Adda'i (0000-0002-7645-2738); Putra Nur Hidayat (0000-0001-5772-1931); Irsan Hasan (0000-0001-6702-2659).

Author contributions: Dwinata M proposed the study; Dwinata M and Putera DD performed the literature search and wrote the research draft; Dwinata M and Putera DD collected and synthesized the data; Dwinata M, Putera DD, Hidayat PN, and Adda'i MF performed the data interpretation; Hasan I reviewed the manuscript and acted as an advisor.

Conflict-of-interest statement: No potential conflicts of interest.

PRISMA 2009 Checklist statement: The authors have read the PRISMA 2009 Checklist, and the manuscript was prepared and revised according to the PRISMA 2009 Checklist.

Open-Access: This article is an open-access article which was selected by an in-house editor and fully peer-reviewed by external reviewers. It is distributed in accordance with the Creative Commons Attribution Non Commercial (CC BY-NC 4.0) license, which permits others to distribute, remix, adapt, build upon this work non-commercially, and license their derivative works on different terms, provided the original work is properly cited and the use is non-commercial. See: <http://creativecommons.org/licenses/by-nc/4.0/>

Michael Dwinata, Department of Internal Medicine, Depati Hamzah General Hospital, Pangkalpinang 33684, Indonesia

David Dwi Putera, School of Medicine and Public Health, University of Sydney, Sydney 2006, Australia

Muhamad Fajri Adda'i, Faculty of Medicine, Public Health, and Nursing, Universitas Gadjah Mada, Yogyakarta 55281, Indonesia

Putra Nur Hidayat, Irsan Hasan, Hepatobiliary Division, Department of Internal Medicine, Faculty of Medicine Universitas Indonesia, Cipto Mangunkusumo National General Hospital, Jakarta 10430, Indonesia

Corresponding author: Michael Dwinata, MD, Staff Physician, Department of Internal Medicine, Depati Hamzah General Hospital, Soekarno Hatta Street, Pangkalpinang 33684, Indonesia. mdwinata@gmail.com

Telephone: +62-822-99066500

Abstract

BACKGROUND

Variceal hemorrhage is associated with high mortality and is the cause of death for 20–30% of patients with cirrhosis. Nonselective β blockers (NSBBs) or endoscopic variceal ligation (EVL) are recommended for primary prevention of variceal bleeding in patients with medium to large esophageal varices. Meanwhile, combination of EVL and NSBBs is the recommended approach for the secondary prevention. Carvedilol has greater efficacy than other NSBBs as it decreases intrahepatic resistance. We hypothesized that there was no difference between carvedilol and EVL intervention for primary and secondary prevention of variceal bleeding in cirrhosis patients.

AIM

To evaluate the efficacy of carvedilol compared to EVL for primary and secondary prevention of variceal bleeding in cirrhotic patients

METHODS

We searched relevant literatures in major journal databases (CENTRAL, MEDLINE, and EMBASE) from March to August 2018. Patients with cirrhosis and portal hypertension, regardless of aetiology and severity, with or without a history of variceal bleeding, and aged ≥ 18 years old were included in this review.

<http://creativecommons.org/licenses/by-nc/4.0/>

Manuscript source: Unsolicited Manuscript

Received: March 4, 2019

Peer-review started: March 5, 2019

First decision: March 25, 2019

Revised: April 8, 2019

Accepted: April 26, 2019

Article in press: April 28, 2019

Published online: May 27, 2019

P-Reviewer: Lan C, Maria Streba LLA

S-Editor: Cui LJ

L-Editor: A

E-Editor: Zhang YL



Only randomized controlled trials (RCTs) that compared the efficacy of carvedilol and that of EVL for primary and secondary prevention of variceal bleeding and mortality in patients with cirrhosis and portal hypertension were considered, irrespective of publication status, year of publication, and language.

RESULTS

Seven RCTs were included. In four trials assessing the primary prevention, no significant difference was found on the events of variceal bleeding (RR: 0.74, 95% CI: 0.37-1.49), all-cause mortality (RR: 1.10, 95% CI: 0.76-1.58), and bleeding-related mortality (RR: 1.02, 95% CI: 0.34-3.10) in patients who were treated with carvedilol compared to EVL. In three trials assessing secondary prevention, there was no difference between two interventions for the incidence of rebleeding (RR: 1.10, 95% CI: 0.75-1.61). The fixed-effect model showed that, compared to EVL, carvedilol decreased all-cause mortality by 49% (RR: 0.51, 95% CI: 0.33-0.79), with little or no evidence of heterogeneity.

CONCLUSION

Carvedilol had similar efficacy to EVL in preventing the first variceal bleeding in cirrhosis patients with esophageal varices. It was superior to EVL alone for secondary prevention of variceal bleeding in regard to all-cause mortality reduction.

Key words: Carvedilol; Liver cirrhosis; Variceal hemorrhage; Portal hypertension; Prophylaxis

©The Author(s) 2019. Published by Baishideng Publishing Group Inc. All rights reserved.

Core tip: This study was an updated meta-analysis of primary prevention and the first meta-analysis of secondary prevention of variceal bleeding in cirrhotic patients. Seven relevant randomized controlled trials were included. Based on the pooled analysis, carvedilol had similar efficacy to endoscopic variceal ligation (EVL) in preventing the first variceal hemorrhage in cirrhosis patients with esophageal varices. Carvedilol was superior to EVL for secondary prevention of variceal bleeding in regard to all-cause mortality reduction by 49% (RR: 0.51, 95% CI: 0.33–0.79).

Citation: Dwinata M, Putera DD, Adda'i MF, Hidayat PN, Hasan I. Carvedilol vs endoscopic variceal ligation for primary and secondary prevention of variceal bleeding: Systematic review and meta-analysis. *World J Hepatol* 2019; 11(5): 464-476

URL: <https://www.wjgnet.com/1948-5182/full/v11/i5/464.htm>

DOI: <https://dx.doi.org/10.4254/wjh.v11.i5.464>

INTRODUCTION

Variceal hemorrhage is associated with high mortality and is the cause of death for 20–30% of patients with cirrhosis^[1]. The use of nonselective β blockers (NSBBs) or endoscopic variceal ligation (EVL) is recommended to prevent primary variceal bleeding in patients with medium to large esophageal varices^[2]. Meanwhile, a combination of EVL and NSBBs (*i.e.*, propranolol or nadolol, with carvedilol as an alternative) is the standard approach to prevent rebleeding. Treatment selection is based on the availability of local resources and expertise, patient characteristics and preferences, contraindications, and side-effects^[3].

NSBBs reduce portal pressure by decreasing cardiac output (β -1 effect) and, more importantly, by initiating splanchnic vasoconstriction (β -2 effect), thus causing a reduction in portal vein pressure. A decrease in the hepatic venous pressure gradient of < 20% or even < 10% from baseline significantly minimizes the risk of the first variceal hemorrhage^[4,5].

Carvedilol, given its additional α -blocking component, has been reported to have higher efficacy than other NSBBs in reducing intrahepatic vascular resistance. A significant difference in overall mortality, bleeding-related mortality, and upper gastrointestinal bleeding between patients treated with carvedilol or EVL to prevent first variceal hemorrhage was not seen in a previous systematic review. However,

only two primary prevention studies were included in the review. On the other hand, until present, there is no systematic review or meta-analysis comparing carvedilol with EVL for the secondary prevention of variceal bleeding^[6-8].

We hypothesized that there was no difference between carvedilol and EVL intervention for primary and secondary prevention of variceal bleeding in cirrhosis patients. In many developing countries, EVL intervention is only available at specific secondary or tertiary healthcare centres. We presumed that carvedilol may be the best prevention strategy of variceal bleeding, especially in hospitals that are unable to offer EVL. Therefore, we performed this review with the inclusion of subsequent trials to summarize and update the evidence.

The study objective was to compare the efficacy of carvedilol and EVL for primary and secondary prevention of variceal bleeding in cirrhotic patients

MATERIALS AND METHODS

Study sample, design, and setting

Patients with cirrhosis and portal hypertension, regardless of aetiology and severity, with or without a history of variceal bleeding, and aged ≥ 18 years old were included in this systematic review and meta-analysis. Only randomized controlled trials (RCTs) that compared the efficacy of carvedilol and that of EVL for primary and secondary prevention of variceal bleeding and mortality in patients with cirrhosis and portal hypertension were considered, irrespective of publication status, year of publication, and language.

Treatment outcomes

A comparison of the primary outcome (bleeding events, all-cause mortality, and bleeding-related mortality) was made for patients with and without a history of variceal bleeding. A bleeding incident was defined as hematemesis or melena and was detected by endoscopic procedure or signs of hemorrhage. Bleeding from the band ligation was also counted. All-cause mortality meant death that occurred in each of the included studies and until follow-up completion.

Serious adverse events, non-serious adverse events, and compliance and treatment failure were secondary outcomes. An adverse event was considered be serious if it led to death, was life-threatening, or caused persistent disability.

Search strategy and literature review

Two independent reviewers searched the Medline, Cochrane Central Register of Controlled Trials (CENTRAL), and EMBASE journal databases from March to August 2018 (Table 1). The reference lists of the retrieved articles were perused for potentially relevant studies. Abstracts and other gray literatures were also included through a manual and electronic search of the clinical trial registries and electronic databases.

Selection of study

Relevant studies, screened based on the title and abstract, were selected after conducting an electronic search. Studies on animals and review articles were excluded. Disagreement was resolved through discussion, failing which a third reviewer was consulted. The study selection process was plotted using a Preferred Reporting Items for Systematic Reviews and Meta-Analyses (PRISMA) flow diagram. The relevant studies were independently appraised using an Oxford Centre for Evidence-Based Medicine critical appraisal tool.

Assessment of bias

Risk of bias was independently determined using the Cochrane risk-of-bias tool. The data were then included in a table. Risk of bias was classified as low, high, or unclear. Disagreement was resolved through discussion, failing which a third reviewer was consulted.

Statistical analysis

Risk ratios (RR) and 95%CI were used to calculate the dichotomous data. RRs with 95%CI were used as relevant effect measures for variceal bleeding, all-cause mortality, and bleeding-related mortality. Statistical analysis was performed according to the Cochrane Handbook for Systematic Reviews of Interventions and using Review Manager® version 5.3 guidelines.

A random-effects model was chosen a priori for the entire analysis. The χ^2 and I^2 statistics were calculated. $P < 0.10$ or I^2 of $> 60\%$ was considered to indicate substantial heterogeneity. I^2 of $> 40\%$ indicated moderate heterogeneity. Analysis was carried out using a fixed-effects model, in the absence of statistically significant heterogeneity,

Table 1 Search strategy

Journal database	Search Terms	Articles
CENTRAL	(Cirrhosis OR “esophageal varices” OR “oesophageal varices”) AND (carvedilol) AND (ligation OR “variceal band ligation” OR “endoscopic variceal ligation” OR VBL OR EVL)	20
MEDLINE	(Cirrhosis OR “esophageal varices” OR “oesophageal varices”) AND (carvedilol) AND (ligation or “variceal band ligation” OR “endoscopic variceal ligation” OR VBL OR EVL)	5
EMBASE <i>via</i> Ovid	Cirrhosis AND Carvedilol AND Ligation	3
A manual search of abstracts and citation index from identified paper's reference list and <i>via</i> https://library.sydney.edu.au/	“portal hypertension”, “cirrhosis”, “carvedilol”, “endoscopic variceal ligation”	54

and a random-effects model in the case of significant heterogeneity. For the subgroup analysis, $P < 0.05$ was considered to denote a difference that was statistically significant between the subgroups. We assessed the quality of evidence using Grading of Recommendations, Assessment, Development and Evaluation (GRADE) approach and created ‘Summary of findings’ table.

Our initial intention was to perform sensitivity analysis of heterogeneity found in the pooled studies through the exclusion of studies with low-quality results. However, this did not occur owing to a paucity of data. Subgroup analysis was conducted of the primary bleeding outcomes based on the grade of varices.

RESULTS

Five, twenty, and three relevant references were identified in the Medline, CENTRAL, and EMBASE *via* Ovid databases, respectively. Fifty-four of them were selected through a manual search of the references lists in the identified papers. Thirty-five studies were duplicates and were removed. The abstracts were also filtered, leading to the removal of a further 22 studies that met the exclusion criteria for various reasons; *i.e.*, carvedilol or EVL were not used as interventions, the study design was not an RCT, or the research had been withdrawn or was ongoing. Thirteen full-text studies were assessed for eligibility. Six of these were excluded, primarily because either EVL or carvedilol were not evaluated, or carvedilol was assessed but in combination with other drugs (Figure 1).

Seven RCTs were included in the current study. Primary prevention was assessed in four trials^[9-12], and secondary prevention was evaluated in three^[9-15] (Table 2). Three of the studies were deemed to be of fair quality, and the remaining one was determined to be of low quality when measured using the Cochrane risk-of-bias tool (Figures 2 and 3).

In the four studies that assessed primary prevention, 368 patients were randomised to carvedilol and 374 patients to EVL. The length of follow-up in the studies varied from 6–24 mo. The mean age of the participants was 47–52 years. Majority of study subjects in two of the trials were classified as Child class A (Child-Pugh Score) and as Child class C in one trial, while cirrhosis was not classified in the fourth research. Most of the trials included cirrhosis patients with medium to large varices (grade II or higher)^[10-12], but one study included patients with grade I and II esophageal varices^[13]. There was no difference for bleeding incidence (RR: 0.74, 95% CI: 0.37–1.49), all-cause mortality (RR of 1.10, 95% CI: 0.76–1.58), and bleeding-related mortality (RR: 1.02, 95% CI: 0.34–3.10) between carvedilol group and EVL (Figure 4 A-C). Subgroup analysis was conducted on participants with medium to large esophageal varices (grade II or larger), and the differences between the groups were also without statistical significance (RR: 0.89, 95% CI: 0.55–1.43). There was little to no evidence of subgroup differences between Grade I and Grade II varices or higher ($\chi^2 = 2.19$, degrees of freedom = 1, $P = 0.14$). The differences might be moderate ($I^2 = 54.4\%$) (Figure 4A).

During the follow-up, hypotension was seen to be the most common side-effect of carvedilol treatment, followed by bradycardia, and asthmatic attack^[11]. Following analysis of the primary prevention studies, a 4.18 times higher risk of treatment-related side-effects was attributed to the carvedilol group (95% CI: 2.19–7.95, $P \leq 0.001$) (Figure 5 A). By contrast, EVL was shown to be associated with serious adverse events

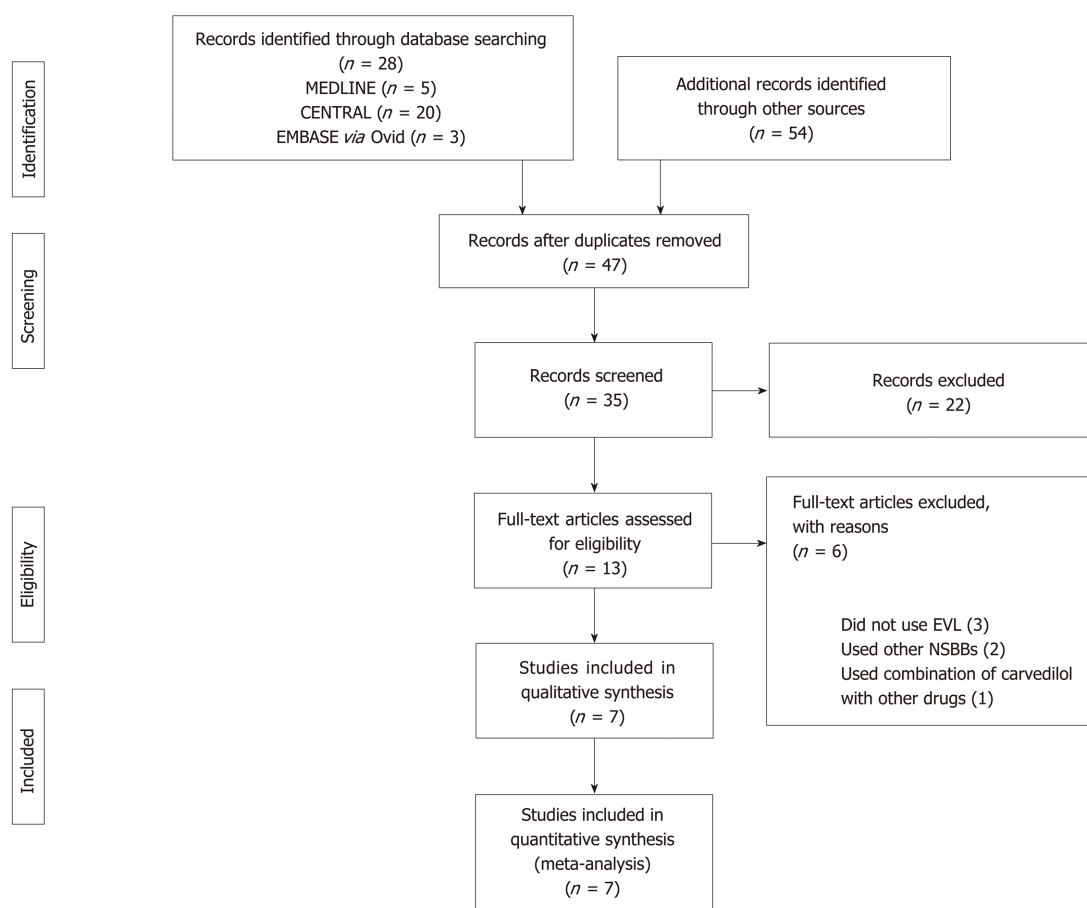


Figure 1 The results of the literature search process used in the current study, depicted using a Preferred Reporting Items for Systematic Reviews and Meta-Analyses flow diagram.

(i.e., chest pain that required medication) in 20% of the participants, compared to 0% of the patients in the carvedilol group ($P \leq 0.001$) in another study^[10]. However, subjects in the carvedilol group experienced more non-serious adverse events, including dyspnea and nausea ($P < 0.001$). Patient compliance with the treatment was similar between the two groups when the primary prevention studies were analyzed ($P = 0.32$) (Figure 5 B).

The randomization of 230 participants took place in the three trials in which secondary prevention was assessed. The mean age of the participants in the studies ranged from 44–52 years. A median Child-Pugh score of 9 was attained, with a mean follow-up period of 16–30 mo. There was no difference between the two interventions with respect to rebleeding incidence (RR: 1.10, 95%CI: 0.75–1.61) (Figure 6 A). The fixed-effects model showed that carvedilol decreased all-cause mortality by 49% (RR: 0.51, 95%CI: 0.33–0.79) (Figure 6 B) without significant heterogeneity ($\chi^2 = 0.04$, $P = 0.980$, $I^2 = 0\%$). Elsewhere, in a study on secondary prevention, Stanley *et al*^[14] reported a similar incidence of serious adverse events in both intervention groups ($P = 0.97$). However, Kumar *et al*^[13] noted considerably more side-effects (28%) due to carvedilol compared to EVL (2%) ($P \leq 0.05$).

DISCUSSION

In this study, we found no significant differences in the incidence of variceal bleeding, all-cause mortality, and bleeding-related mortality between carvedilol *vs* EVL for primary prevention strategy. This finding was consistent with the subsequent subgroup analysis of participants with medium to large esophageal varices (grade II or higher). This finding was also similar to that reported in a previous meta-analysis^[8], but the current study extended to an analysis of the side-effects that arose from the interventions and patient compliance with the medication.

To the best of our knowledge, this study is the first meta-analysis to have assessed the efficacy of carvedilol *vs* that of EVL for secondary prevention of variceal bleeding.

Table 2 Characteristic of included studies

Ref.	History of variceal bleeding	Treatment groups	Age (mean \pm SD, yr)	n	Dosage / method	Follow up(mo)
Tripathi <i>et al</i> ^[9]	No	Carvedilol	54.2 \pm 9.4	77	6.25 mg (starting dose) daily, with target dose of 12.5 mg daily	24
		EVL	54.5 \pm 11.1	75	Every two weeks until eradication	24
Shah <i>et al</i> ^[10]	No	Carvedilol	48.3 \pm 11.3	82	6.25 mg daily, with target dose of 6.25 mg twice a day	up to 24
		EVL	47.2 \pm 13.2	86	Every three weeks until eradication	up to 24
Khan <i>et al</i> ^[12]	No	Carvedilol	52.1 \pm 14.7	125	12.5 mg daily	6
		EVL	54.1 \pm 14.3	125	Not mentioned	6
Abd ElRahim <i>et al</i> ^[11]	No	Carvedilol	51.2 \pm 11.0	84	starting dosage of 6.25 mg daily, titrated up every 4 days to reach up to 12.5–50 mg	up to 12
		EVL	50.6 \pm 5.9	88	Every two weeks until eradication	up to 12
Smith <i>et al</i> ^[15]	Yes	Carvedilol	51 \pm 10.9	32	6.25 mg daily, with target dose 12.5 of mg daily	29
		EVL	50 \pm 13.0	31	Not mentioned	29
Stanley <i>et al</i> ^[14]	Yes	Carvedilol	51.4 \pm 10.8	33	6.25 mg daily, with target dose 12.5 of mg daily	up to 60
		EVL	49.6 \pm 12.87	31	Every two weeks until eradication	up to 60
Kumar <i>et al</i> ^[13]	Yes	Carvedilol	44.1 \pm 8.5 (overall)	47	Not mentioned	11.1 - 21.7
		EVL	44.1 \pm 8.5 (overall)	56	Not mentioned	11.1 - 21.7

EVL: Endoscopic variceal ligation.

Based on our pooled analysis, although there was no significant difference regarding incidence, carvedilol may be superior compared to EVL by significantly reducing all-cause mortality. Unfortunately, the relevant data needed to elucidate this finding were lacking in the review. In a study conducted by Stanley, most deaths in the carvedilol group were related to bleeding (15%), whereas only 3% of deaths were due to bleeding in the EVL group. None of the patients in the carvedilol group died of liver-related causes not due to bleeding, whereas the latter was responsible for the deaths of six of the 31 (19%) patients in the EVL group. It is assumed that this result can be explained by the systematic effect of carvedilol in reducing portal pressure in patients with cirrhosis.

Carvedilol, an NSBB with weak intrinsic anti- α 1-adrenergic activity, is known to effect a reduction in portal pressure with added vasodilatory α -adrenergic blocking activity. The α 1-adrenergic receptor located in the splanchnic vascular smooth muscles and vascular smooth muscle at other sites, such as the genitourinary tract. Blocking the α 1-adrenergic receptors leads to a reduction in intrahepatic vascular tone. Therefore, the α 1- and β -receptor-blocking properties of carvedilol can lead to superior reduction in portal pressure compared to conventional NSBBs (*i.e.*, propranolol or nadolol)^[16].

The current recommendation for the prevention of variceal rebleeding in cirrhosis patients is to use a combination of EVL and NSBBs (*i.e.*, propranolol or nadolol). This study revealed that carvedilol is superior to EVL alone for secondary prevention of variceal bleeding in regard to all-cause mortality reduction. Regarding this finding, we encourage that RCTs comparing efficacy of carvedilol *vs* combination therapy of EVL and NSBBs should be conducted to strengthen the evidence. This current study

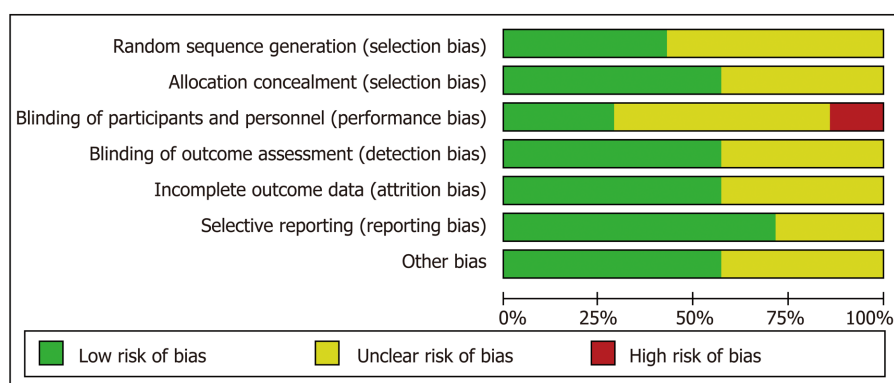


Figure 2 A risk of bias graph showing the researchers' opinions on each risk of bias item (presented as percentages across all the seven included studies).

finding may be of use to physicians working in rural areas or hospitals where an EVL intervention is unlikely^[17].

In the primary prevention studies, patient compliance was similar in both groups despite a greater number of side-effects being seen in the carvedilol group. This indicates that the side-effects were nevertheless tolerable to the participants. In the secondary prevention studies, the data on serious adverse events and side-effects of both interventions were still insufficient. Further studies are needed to comprehensively assess the side-effects of each intervention.

There are several limitations in this systematic review and meta-analysis that bear mentioning. First, we could not retrieve complete data from some included studies which hindered us to do some subgroup analysis, such as subgroup analysis of cirrhosis severity or numbers of EVL procedure performed. Most of the included studies also did not perform specific analysis regarding this particularly topic. Second, the numbers of available clinical trials are relatively limited which also hindered us to perform sensitivity analysis for this study.

The quality of evidence of primary prevention for variceal bleeding is low. The quality is reduced due to lack of blinding in the included studies. On the contrary, the quality of evidence for the all-cause mortality and the bleeding-related mortality in primary prevention is high as the included studies showed low risk of bias. The quality of evidence of secondary prevention for rebleeding is low, because some of the included studies showed unclear methods while conducting the studies (Table 3).

In conclusion, carvedilol had similar efficacy to EVL in preventing the first variceal bleeding in cirrhosis patients with esophageal varices. We considered that carvedilol was superior to EVL alone for secondary prevention of variceal bleeding in regard to all-cause mortality reduction.

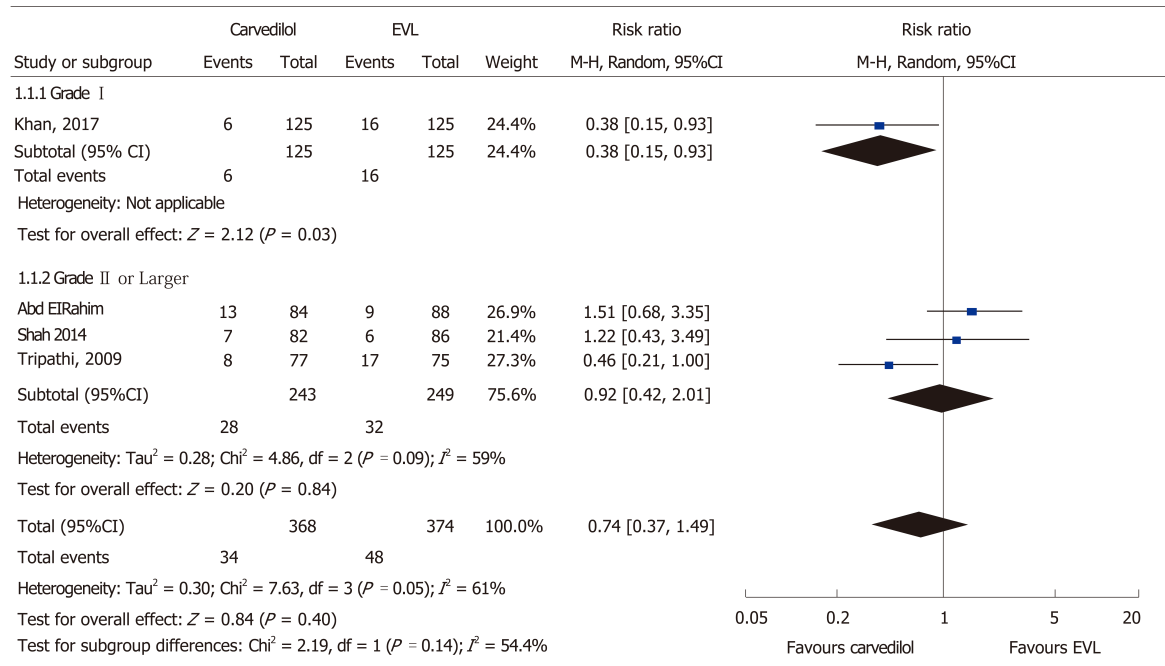
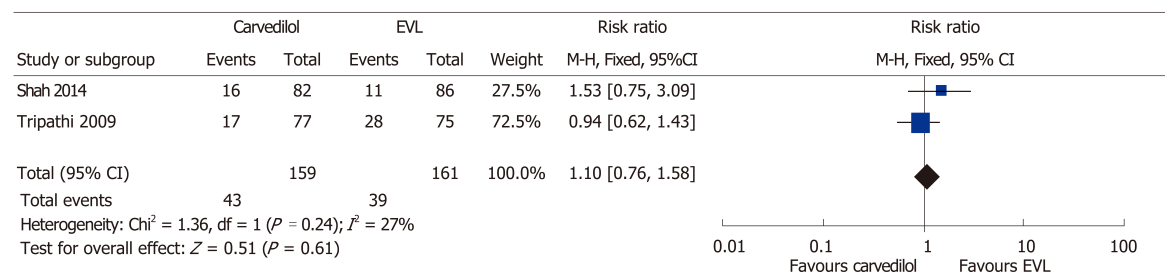
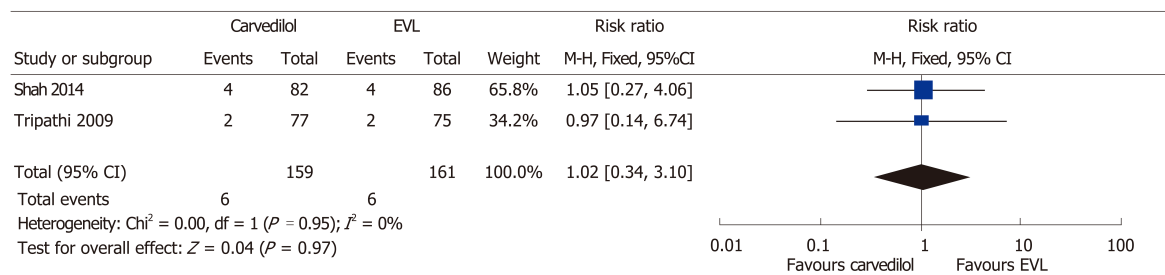
Table 3 Summary of findings for the main comparison

Outcomes	Relative effect (95%CI)	Participants (studies)	Quality of the evidence (GRADE)	Comments
Variceal bleed in primary prevention (Grade I)	RR 0.38 (0.15-0.93)	250 (1 Study)	++-- low	Benefit for Carvedilol group
Variceal bleed in primary prevention (Grade II)	RR 0.92 (0.42-2.41)	492 (3 Studies)	++++ moderate	
All-cause mortality in primary prevention	RR 1.10 (0.76-1.58)	320 (2 Studies)	++++ high	
Bleeding-related mortality in primary prevention	RR 1.02 (0.34-3.10)	320 (2 Studies)	++++ high	
Side effect of treatment in primary prevention	RR 4.18 (2.19-7.95)	276 (2 Studies)	+++- moderate	Benefit for EVL group
Compliance in primary prevention	RR 0.90 (0.73-1.11)	122 (2 Studies)	+++- low	
Rebleeding events in secondary prevention	RR 1.10 (0.75-1.61)	230 (3 Studies)	++-- low	Benefit for Carvedilol group
All-cause mortality in secondary prevention	RR 0.51 (0.33-0.79)	230 (3 Studies)	++-- low	

GRADE: Grading of Recommendations, Assessment, Development and Evaluation; Patient or population: Portal hypertension or cirrhosis patients; Comparison: Endoscopic variceal ligation; Settings: Secondary or tertiary hospital; Intervention: Carvedilol. GRADE Working Group grades of evidence. High quality: Further research is very unlikely to change our confidence in the estimate of effect; Moderate quality: Further research is likely to have an important impact on our confidence in the estimate of effect and may change the estimate; Low quality: Further research is very likely to have an important impact on our confidence in the estimate of effect and is likely to change the estimate; Very low quality: We are very uncertain about the estimate.

	Random sequence generation (selection bias)	Allocation concealment (selection bias)	Blinding of participants and personnel (performance bias)	Blinding of outcome assessment (detection bias)	Incomplete outcome data (attrition bias)	Selective reporting (reporting bias)	Other bias
Abd ElRahim 2017	?	+	?	+	+	+	+
Khan 2017	?	?	-	?	+	+	?
Kumar 2015	?	?	?	?	?	?	?
Shah 2014	+	+	+	+	+	+	+
Smith 2013	?	?	?	?	?	?	?
Stanley 2014	+	+	?	+	+	+	+
Tripathi 2009	+	+	+	+	?	+	+

Figure 3 A risk of bias summary showing the researchers' opinions on each risk of bias item for each of the seven included studies.

A**B****C****Figure 4** Meta-analysis forest plot of primary outcomes in primary prevention studies. A: Variceal bleeding; B: All-cause mortality; C: Bleeding-related mortality.

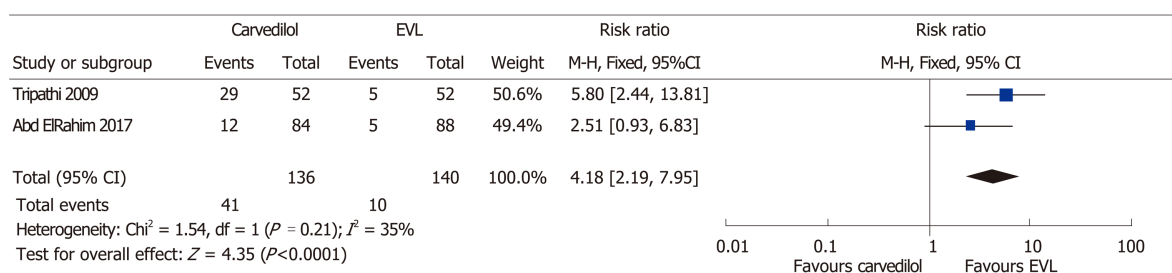
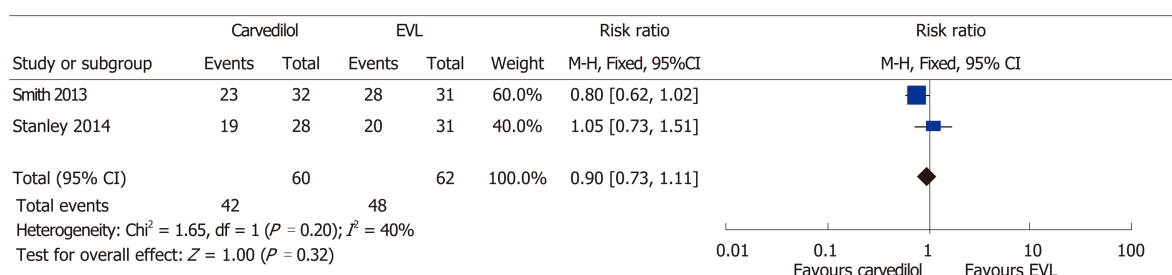
A**B**

Figure 5 Meta-analysis forest plot of secondary outcomes in primary prevention studies. A: Side-effects of treatment; B: Compliance.

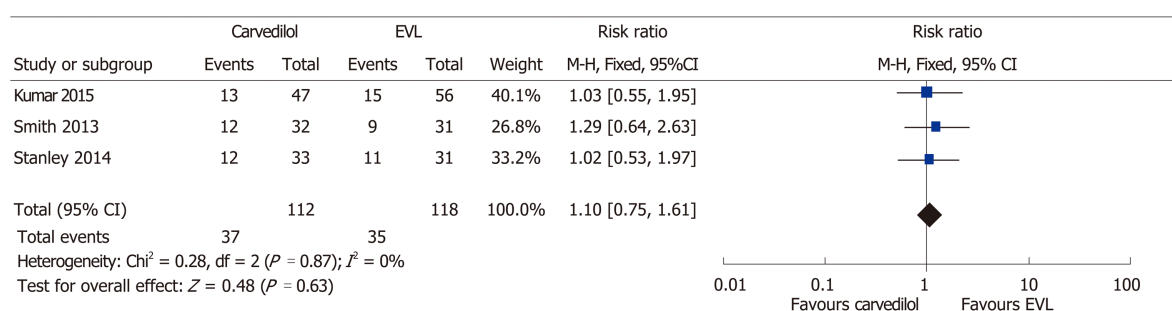
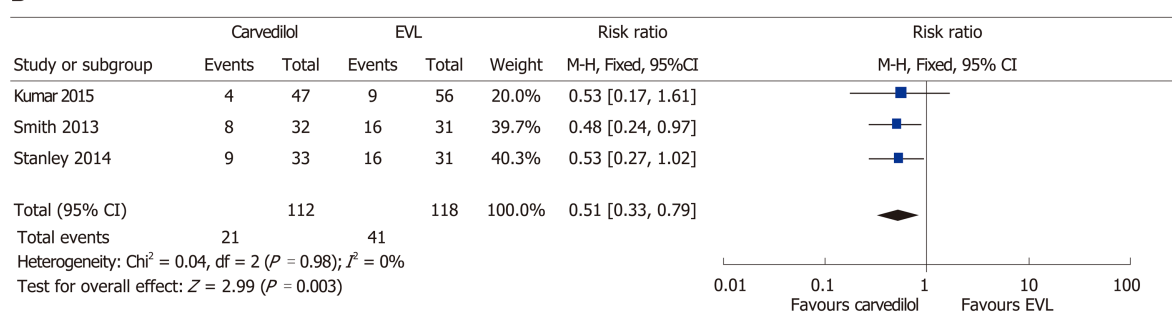
A**B**

Figure 6 Meta-analysis forest plot of primary outcomes in secondary prevention studies. A: Variceal rebleeding; B: All-cause mortality.

ARTICLE HIGHLIGHTS**Research background**

Variceal hemorrhage is associated with high mortality and is the cause of death for 20%–30% of patients with cirrhosis. Either traditional nonselective β blockers (NSBBs) (*i.e.* propranolol or nadolol), carvedilol, or endoscopic variceal ligation (EVL) is recommended for primary prevention of variceal bleeding in patients with medium to large esophageal varices. Meanwhile, combination of EVL and NSBBs is the recommended approach for the secondary prevention. Carvedilol has greater efficacy than other NSBBs as it decreases intrahepatic resistance. We

hypothesized that there was no difference between carvedilol and EVL intervention for primary and secondary prevention of variceal bleeding in cirrhosis patients.

Research motivation

Some of the major drawbacks of EVL are invasive, costly, and unavailable in many areas, especially in developing countries. A better understanding of the efficacy of carvedilol compared to EVL might provide less invasive and more accessible prevention strategy for variceal bleeding in cirrhosis patients.

Research objectives

We conducted this meta-analysis to evaluate the efficacy of carvedilol compared to EVL for primary and secondary prevention of variceal bleeding in cirrhotic patients with esophageal varices

Research methods

We searched relevant literatures in major journal databases (CENTRAL, MEDLINE, and EMBASE) from March to August 2018. Only randomized controlled trials (RCTs) that compared the efficacy of carvedilol and that of EVL for primary and secondary prevention of variceal bleeding and mortality in patients with cirrhosis and portal hypertension were considered, irrespective of publication status, year of publication, and language.

Research results

Seven RCTs were included in this meta-analysis. For primary prevention strategy, we found no significant difference between carvedilol and EVL on the events of variceal bleeding, all-cause mortality, and bleeding-related mortality. For secondary prevention strategy, we found no difference between two interventions for the incidence of rebleeding. Interestingly, compared to EVL, carvedilol decreased all-cause mortality by 49% (RR: 0.51, 95%CI: 0.33-0.79), with little or no evidence of heterogeneity.

Research conclusions

Carvedilol had similar efficacy to EVL in preventing the first variceal bleeding in cirrhosis patients with esophageal varices. In clinical practice, the use of carvedilol or EVL for prevention of first variceal bleeding may depends on physicians' and patients' preference. For prevention of rebleeding, we considered that carvedilol was superior to EVL alone in regard to all-cause mortality reduction.

Research perspectives

This study demonstrated significant benefit of using carvedilol for secondary prevention of variceal bleeding in cirrhosis patients. We highly suggest that future clinical trials should compare between carvedilol and combination of EVL and traditional NSBBs (*i.e.*, propranolol or nadolol) or carvedilol to enrich our understanding about efficacy of carvedilol for the prevention of esophageal varices rebleeding.

ACKNOWLEDGEMENTS

The authors are grateful to Jonathan Haposan at the Graduate School of Public Health, University of Pittsburgh, for his invaluable assistance in assisting with the statistical analysis and data interpretation.

REFERENCES

- 1 Kasper D, Fauci A, Hauser S, Longo D, Jameson J, Loscalzo J. Harrison's principles of internal medicine. 19th ed. New York: Mc Graw Hill 2015; 2062-2064
- 2 Garcia-Tsao G, Abraldes JG, Berzigotti A, Bosch J. Portal hypertensive bleeding in cirrhosis: Risk stratification, diagnosis, and management: 2016 practice guidance by the American Association for the study of liver diseases. *Hepatology* 2017; **65**: 310-335 [PMID: 27786365 DOI: 10.1002/hep.28906]
- 3 de Franchis R; Baveno V Faculty. Revising consensus in portal hypertension: report of the Baveno V consensus workshop on methodology of diagnosis and therapy in portal hypertension. *J Hepatol* 2010; **53**: 762-768 [PMID: 20638742 DOI: 10.1016/j.jhep.2010.06.004]
- 4 Turnes J, Garcia-Pagan JC, Abraldes JG, Hernandez-Guerra M, Dell'Era A, Bosch J. Pharmacological reduction of portal pressure and long-term risk of first variceal bleeding in patients with cirrhosis. *Am J Gastroenterol* 2006; **101**: 506-512 [PMID: 16542287 DOI: 10.1111/j.1572-0241.2006.00453.x]
- 5 Villanueva C, Aracil C, Colomo A, Hernández-Gea V, López-Balaguer JM, Alvarez-Urturi C, Torras X, Balanzó J, Guarner C. Acute hemodynamic response to beta-blockers and prediction of long-term outcome in primary prophylaxis of variceal bleeding. *Gastroenterology* 2009; **137**: 119-128 [PMID: 19344721 DOI: 10.1053/j.gastro.2009.03.048]
- 6 Sinagra E, Perricone G, D'Amico M, Tinè F, D'Amico G. Systematic review with meta-analysis: the haemodynamic effects of carvedilol compared with propranolol for portal hypertension in cirrhosis. *Aliment Pharmacol Ther* 2014; **39**: 557-568 [PMID: 24461301 DOI: 10.1111/apt.12634]
- 7 Gluud LL, Krag A. Banding ligation versus beta-blockers for primary prevention in oesophageal varices in adults. *Cochrane Database Syst Rev* 2012; CD004544 [PMID: 22895942 DOI: 10.1002/14651858.CD004544.pub2]

- 8 **Li T**, Ke W, Sun P, Chen X, Belgaumkar A, Huang Y, Xian W, Li J, Zheng Q. Carvedilol for portal hypertension in cirrhosis: systematic review with meta-analysis. *BMJ Open* 2016; **6**: e010902 [PMID: 27147389 DOI: 10.1136/bmjopen-2015-010902]
- 9 **Tripathi D**, Ferguson JW, Kochar N, Leithead JA, Therapondos G, McAvoy NC, Stanley AJ, Forrest EH, Hislop WS, Mills PR, Hayes PC. Randomized controlled trial of carvedilol versus variceal band ligation for the prevention of the first variceal bleed. *Hepatology* 2009; **50**: 825-833 [PMID: 19610055 DOI: 10.1002/hep.23045]
- 10 **Shah HA**, Azam Z, Rauf J, Abid S, Hamid S, Jafri W, Khalid A, Ismail FW, Parkash O, Subhan A, Munir SM. Carvedilol vs. esophageal variceal band ligation in the primary prophylaxis of variceal hemorrhage: a multicentre randomized controlled trial. *J Hepatol* 2014; **60**: 757-764 [PMID: 24291366 DOI: 10.1016/j.jhep.2013.11.019]
- 11 **Abd ElRahim AY**, Fouad R, Khairy M, Elsharkawy A, Fathalah W, Khatamish H, Khorshid O, Moussa M, Seyam M. Efficacy of carvedilol versus propranolol versus variceal band ligation for primary prevention of variceal bleeding. *Hepatol Int* 2018; **12**: 75-82 [PMID: 29185106 DOI: 10.1007/s12072-017-9835-9]
- 12 **Khan MS**, Majeed A, Ghauri F, Asghar U, Waheed I. Comparison of carvedilol and esophageal variceal band ligation for prevention of variceal bleed among cirrhotic patient. *Pak J Health Med Sci* 2017; **11**: 1046-1048
- 13 **Kumar P**, Kumar R, Saxena KN, Misra SP, Dwivedi, M. Secondary prophylaxis of variceal hemorrhage: a comparative study of band ligation, carvedilol, and propranolol plus isosorbide mononitrate. *Indian J Gastroenterol* 2015; **34**: 1-104 [DOI: 10.1007/s12664-015-0600-5]
- 14 **Stanley AJ**, Dickson S, Hayes PC, Forrest EH, Mills PR, Tripathi D, Leithead JA, MacBeth K, Smith L, Gaya DR, Suzuki H, Young D. Multicentre randomised controlled study comparing carvedilol with variceal band ligation in the prevention of variceal rebleeding. *J Hepatol* 2014; **61**: 1014-1019 [PMID: 24953021 DOI: 10.1016/j.jhep.2014.06.015]
- 15 **Smith LA**, Dickson S, Hayes PC, Tripathi D, Ferguson W, Forrest EH, Gaya DR, Mills PR, Suzuki H, Young D, Stanley AJ. Multicentre randomised controlled study comparing carvedilol with endoscopic band ligation in the prevention of variceal rebleeding. *Gut* 2013; **62**: A1-A2 [DOI: 10.1136/gutjnl-2013-304907.003]
- 16 **Karadsheh Z**, Allison H. Primary prevention of variceal bleeding: pharmacological therapy versus endoscopic banding. *N Am J Med Sci* 2013; **5**: 573-579 [PMID: 24350068 DOI: 10.4103/1947-2714.120791]
- 17 **Brunner F**, Berzigotti A, Bosch J. Prevention and treatment of variceal haemorrhage in 2017. *Liver Int* 2017; **37** Suppl 1: 104-115 [PMID: 28052623 DOI: 10.1111/liv.13277]

Neonatal cholestasis and hepatosplenomegaly caused by congenital dyserythropoietic anemia type 1: A case report

Catalina Jaramillo, Anna K Ermarth, Angelica R Putnam, Mark Deneau

ORCID number: Catalina Jaramillo (0000-0003-0708-8247); Anna K Ermarth (0000-0003-3688-5624); Angelica R Putnam (0000-0003-3983-5024); Mark Deneau (0000-0003-0459-9404).

Author contributions: Jaramillo C, Ermarth AK and Deneau M were the patient's gastroenterologists, reviewed the literature and contributed to manuscript drafting; Putnam AR reviewed the patient's pathology slides, electron microscopy images and contributed to manuscript drafting; All authors were responsible for the revision of the manuscript for important intellectual content and issued final approval for the version to be submitted.

Informed consent statement: Verbal informed consent was obtained from the patient's mother for publication of this report and any accompanying images.

Conflict-of-interest statement: The authors declare that they have no conflict of interest.

CARE Checklist (2016) statement: The authors have read the CARE Checklist (2016), and the manuscript was prepared and revised according to the CARE Checklist (2016).

Open-Access: This article is an open-access article that was selected by an in-house editor and fully peer-reviewed by external reviewers. It is distributed in accordance with the Creative Commons Attribution Non Commercial (CC BY-NC 4.0) license, which permits others to

Catalina Jaramillo, Anna K Ermarth, Mark Deneau, Department of Pediatrics, University of Utah, Salt Lake City, UT 84113, United States

Angelica R Putnam, Department of Pathology, University of Utah, Salt Lake City, UT 84113, United States

Corresponding author: Mark Deneau, MD, MS, Associate Professor, Department of Pediatrics, University of Utah, 81 Mario Capecchi Drive, Salt Lake City, UT 84113, United States.

mark.deneau@hsc.utah.edu

Telephone: +1-801-2137664

Abstract

BACKGROUND

Congenital dyserythropoietic anemia type 1 (CDA1) is an autosomal recessive disorder of ineffective erythropoiesis, resulting in increased iron storage. CDA1 is usually diagnosed in children and adolescents but can rarely present in the neonatal period with severe anemia at birth. There are no prior reports of neonatal liver histologic findings of CDA1. We report a case of CDA1 in a newborn presenting with severe anemia, cholestasis and liver failure, where liver biopsy helped confirm the diagnosis.

CASE SUMMARY

A term infant, born *via* emergency Cesarean section, presented with cholestasis, hepatosplenomegaly, multiorgan failure and severe anemia at birth. A prior pregnancy was significant for fetal demise at 35 wk without autopsy or known etiology for the fetal demise. Parents are both healthy and there is no history of consanguinity. On further evaluation, the patient was found to have severe ferritin elevation and pulmonary hypertension. An extensive infectious and metabolic work-up was negative. Salivary gland biopsy was negative for iron deposition. At 2 wk of age, a liver biopsy showed findings consistent with CDA1. A genome rapid sequencing panel revealed novel variants in the *CDAN1* gene. The patient's liver dysfunction, cholestasis and organomegaly resolved, however she remains transfusion-dependent.

CONCLUSION

We report liver pathology findings of CDA1 with a novel genetic mutation for the first time in a newborn.

Key words: Congenital dyserythropoietic anemia; Hemochromatosis; Pulmonary hypertension; Jaundice; Case report

distribute, remix, adapt, build upon this work non-commercially, and license their derivative works on different terms, provided the original work is properly cited and the use is non-commercial. See: <http://creativecommons.org/licenses/by-nc/4.0/>

Manuscript source: Invited manuscript

Received: March 11, 2019

Peer-review started: March 12, 2019

First decision: April 10, 2019

Revised: April 12, 2019

Accepted: April 19, 2019

Article in press: April 19, 2019

Published online: May 27, 2019

P-Reviewer: Karatza AA

S-Editor: Cui LJ

L-Editor: Filipodia

E-Editor: Zhang YL



©The Author(s) 2019. Published by Baishideng Publishing Group Inc. All rights reserved.

Core tip: Congenital dyserythropoietic anemia type 1 (commonly known as CDA1) is an autosomal recessive disorder of ineffective erythropoiesis, resulting in increased iron storage. We report a rare case of CDA1 with novel genetic mutations in a newborn presenting with severe anemia, cholestasis and liver failure. This case highlights how liver histology helped confirm the diagnosis.

Citation: Jaramillo C, Ermarth AK, Putnam AR, Deneau M. Neonatal cholestasis and hepatosplenomegaly caused by congenital dyserythropoietic anemia type 1: A case report. *World J Hepatol* 2019; 11(5): 477-482

URL: <https://www.wjgnet.com/1948-5182/full/v11/i5/477.htm>

DOI: <https://dx.doi.org/10.4254/wjh.v11.i5.477>

INTRODUCTION

Congenital dyserythropoietic anemia type 1 (CDA1) is an autosomal recessive disorder of ineffective erythropoiesis, resulting in increased iron storage, and considered a form of secondary hemochromatosis^[1]. Most CDA1 patients have a mutation in the CDAN1 gene^[2]. CDA1 is usually diagnosed in children and adolescents with moderate to severe macrocytic anemia. However, it can rarely present in the neonatal period with severe anemia at birth^[2]. Additional clinical findings include hepatosplenomegaly (HSM), jaundice, cholestasis, liver dysfunction, transient thrombocytopenia and persistent pulmonary hypertension of the newborn^[2]. The diagnosis is based on hematologic abnormalities and positive genetic testing^[3]. Bone marrow biopsy findings include spongy heterochromatin, enlargement of nuclear pores and invagination of cytoplasm into the nuclear area^[4].

Prior reports have described liver biopsy findings of extramedullary hematopoiesis and iron accumulation in autopsies and adult patients^[5-8]. There have been no prior reports of neonatal liver histologic findings of CDA1. We report a case of CDA1 in a newborn presenting with severe anemia, cholestasis and liver failure, where liver biopsy helped confirm the diagnosis.

CASE PRESENTATION

Chief complaints

This is a former 37 wk and 3 d old female transferred to our institution due to respiratory failure.

Birth history

The patient was delivered by emergency Cesarean section due to non-reassuring fetal heart rate tracings at an outside hospital to a 28-year-old, Caucasian, gravida 4, para 2, 0, 1, 2 with an unremarkable pregnancy. A prior pregnancy was significant for fetal demise at 35 wk without autopsy or known etiology for the fetal demise. Parents are both healthy and there is no history of consanguinity. Perinatal laboratory results included maternal blood type O (+) with negative antibody screen, negative venereal disease research laboratory, hepatitis B, and human immunodeficiency virus and rubella. Apgar scores were 7 and 8. Birth weight was 3070 g (21st percentile), length 18 inches (16th percentile), occipital frontal circumference 32.5 cm (3rd percentile).

Physical examination upon admission

At birth, this patient had no facial or limb dimorphism. She was started on supplemental oxygen due to duskiess 10 min after birth. Subsequently, she required endotracheal intubation and initiation of inhaled nitric oxide. She was then transferred to our institution due to respiratory failure on day of life (DOL) 1. On arrival, she was found to have HSM.

Laboratory examinations

On admission to our institution, she was found to have liver dysfunction with an International normalized ratio (commonly referred to as INR) of 2.1, total bilirubin of 9 mg/dL, direct bilirubin of 2.1 mg/dL, aspartate aminotransferase 655 U/L and

alanine aminotransferase 65 U/L. Partial thromboplastin time was within normal limits, with mildly low fibrinogen and elevated D-dimers. Anemia and thrombocytopenia were also present. The anemia was present since birth with a hemoglobin of 7.4 g/dL and hematocrit of 23.7%. Her platelets were initially normal but soon started to decline, with a nadir of 54 k/ μ L on DOL 1. She was also found to have pulmonary hypertension, right ventricular hypertrophy and required high frequency oscillator ventilation due to hypoxemic respiratory failure.

Additional laboratory work-up included serum ferritin of 40664 ng/mL and normal soluble interleukin 2 receptor. Initially her gamma-glutamyltransferase (commonly referred to as GGT) was normal and then peaked at 390 U/L on DOL 25. Infectious studies included negative herpes simplex virus, Epstein-Barr virus, cytomegalovirus, adenovirus, parvovirus, enterovirus, echovirus, parechovirus and human herpesvirus 6 PCR. Multiple blood cultures and urine cultures were also negative. She also had negative work-up for inborn errors of metabolism: normal serum plasma amino acids, urine organic acids, ammonia and very long/branched-chain fatty acids.

Imaging examinations

Imaging studies included an initial echocardiogram on DOL 1, which showed a large patent ductus arteriosus, small patent foramen ovale and dilated and hypertrophied right ventricle with suprasystemic pressures. An abdominal ultrasound showed HSM with minimal ascites, and a liver Doppler was normal.

Further diagnostic work-up

A salivary gland biopsy performed on DOL 5 did not show any evidence of iron deposition. On DOL 15, a liver biopsy was performed, which showed iron deposition (Figure 1) and erythroblasts with spongy appearance (Figure 2). Immunohistochemical staining for cytomegalovirus and HSV were negative. A genome rapid sequencing panel of over 4500 genes was performed (ARUP Laboratories, Salt Lake City, UT, United States) and revealed novel compound heterozygous variants in *CDAN1*, c.2174G>A (p.Arg725Gln) and c.1003C>T (p.Arg335Trp), each variant inherited from an asymptomatic parent.

FINAL DIAGNOSIS

The final diagnosis of the presented case is *CDAN1* resulting from c.2174G>A (p.Arg725Gln) and c.1003C>T (p.Arg335Trp) mutations.

TREATMENT

The infant remained on broad spectrum antibiotics, antivirals and required multiple packed red blood cell, fresh frozen plasma and platelet transfusions. She also received intravenous immunoglobulin. She was weaned off mechanical ventilation on DOL 16 and was discharged from the neonatal intensive care unit (known as the NICU) at DOL 43.

OUTCOME AND FOLLOW-UP

Her INR normalized by DOL 2. Her ferritin levels remained elevated but were declining with a level of 4133 ng/mL at NICU discharge. She had improving liver enzymes, bilirubin and thrombocytopenia throughout her NICU stay. At discharge, she was on nasal cannula and sildenafil for persistent pulmonary hypertension. By 7 wk of age, her bilirubin had normalized, and by 4 mo of age, her liver enzymes and GGT had normalized. At her first gastroenterology follow-up 4 wk after discharge, her organomegaly had resolved. At 1 year of age, her ferritin level had decreased to 1139 ng/mL and had 9.3 mg of iron/g of liver tissue determined by magnetic resonance hepatic iron quantification, still consistent with iron overload^[5]. She remains transfusion-dependent.

DISCUSSION

CDAN1 is a rare disorder of ineffective erythropoiesis that leads to severe anemia^[6]. It has been mainly described in European countries and in the Bedouin Israeli

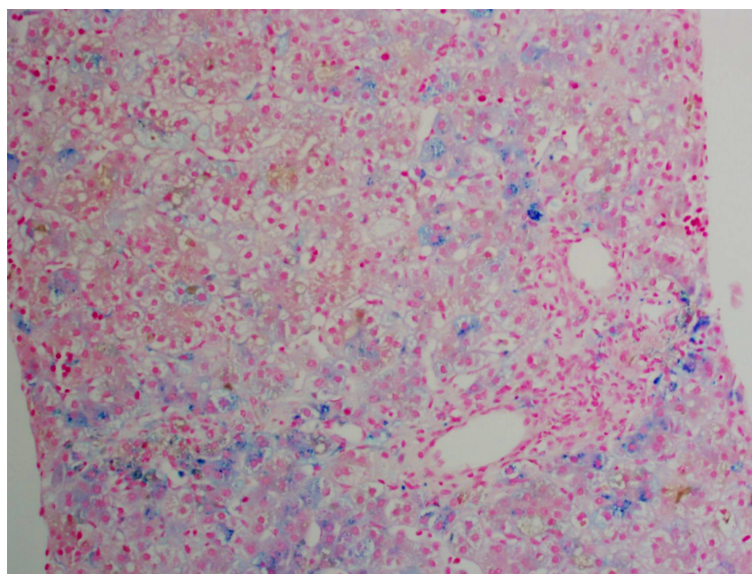


Figure 1 Approximately 10%-15% of the hepatocytes contained iron granules. Iron deposition was identified in all three zones of the liver.

population^[2]. The diagnosis is more commonly suspected in patients presenting with hematologic abnormalities such as moderate-severe macrocytic anemia (MCV > 90), inappropriately low reticulocytes for degree of anemia, macrocytosis, elliptocytes and basophilic stippling on peripheral blood smear, bone marrow aspirate findings of erythroid hyperplasia with interchromatic bridges on light microscopy and erythroblasts with spongy appearance of heterochromatin and invaginations of the nuclear membrane on electron microscopy^[3]. Other common findings may include jaundice, splenomegaly, limb dimorphism, hypoplastic nails and syndactyly^[3].

Diagnosis in the newborn period is rare^[2]. The patient described above presented with multiple clinical characteristics previously described in the literature. HSM and early jaundice are commonly encountered (65% and 53%, respectively). Neonates can also present with direct hyperbilirubinemia in up to 20% of cases. Thrombocytopenia has been described as transient, which is consistent with this patient's presentation^[2]. Persistent fetal circulation/pulmonary hypertension has also been reported in up to 15% of patients; the reported cases have had pulmonary hypertension without any underlying cardiopulmonary abnormalities requiring high pressure ventilation^[2,7]. It is also reported that patients who have clinical manifestations of CDA1 in the neonatal period have severe intrauterine anemia at birth, and there have been cases of hydrops fetalis^[8,9].

In this case, a liver biopsy supported evidence for the diagnosis of CDA1 before genetic testing was performed, with identification of typical siderosis and extramedullary hematopoiesis^[6,10]. Both of these findings are consistent with prior adult liver pathology reports. Most recently in 2016, Salihoglu *et al*^[10] reported a case of CDA1 in an adult in whom a liver biopsy was performed to exclude Wilson's disease and was found to have extramedullary hematopoiesis. Another case report describes a 28-year-old diagnosed with CDA1 with a liver biopsy that showed massive siderosis and early cirrhosis^[6]. Autopsy reports have also been described with findings of extramedullary hematopoiesis of the liver and spleen^[8].

The initial therapeutic modality for this disease is intermittent blood transfusions, however if patients become transfusion-dependent, there have been cases of successful treatment with interferon alpha^[6,11,12]. Up to 80% of affected neonates require blood transfusions in the first month of life, with reported transfusion independence by 4 mo of age in 88% of patients^[2]. There are also three reported cases of bone marrow transplantation in patients resistant to interferon therapy^[3,13]. Our patient is currently receiving intermittent blood transfusions approximately every 4 wk.

From a gastrointestinal and hepatology standpoint, CDA1 patients have a future risk of gallstones (reported in patients as young as 4 years of age)^[4] and secondary hemochromatosis; the latter develops with age due to increased iron absorption even in patients who are not chronically transfused^[3]. Hence, it is suggested that patients are periodically monitored (every 3 mo) for iron overload starting at age 10^[3].

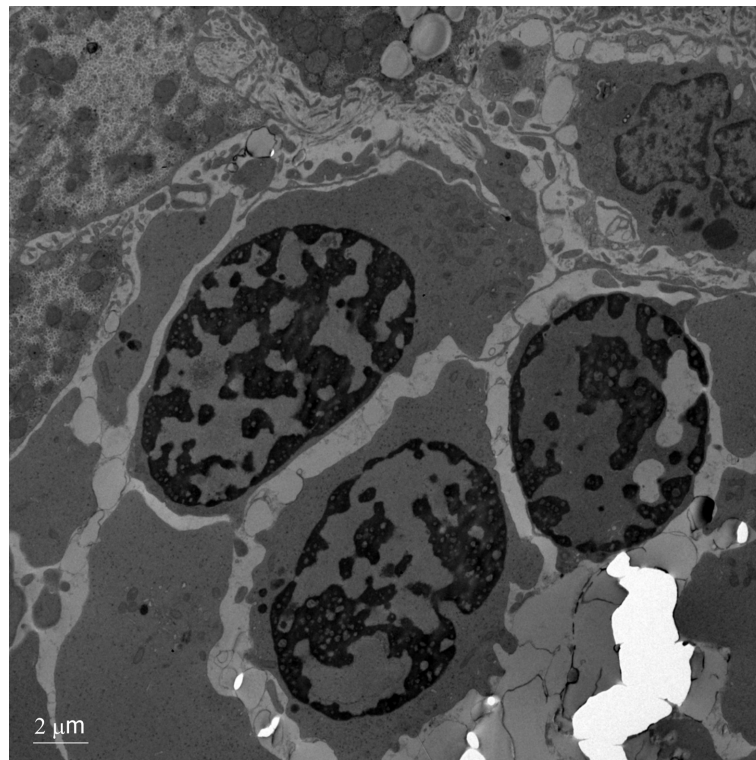


Figure 2 Electron microscopy showing erythroblasts with dense heterochromatin and translucent vacuoles. There is widening of the nuclear pores with invagination of cytoplasm.

CONCLUSION

Liver biopsy can be a helpful tool in the diagnosis of infants with unexplained liver dysfunction. This case report describes the liver histopathology and electron microscopy findings of CDA1 caused by a novel genetic mutation in the pediatric age group. CDA1 is in the differential diagnosis of infants with unexplained anemia, hyperbilirubinemia and HSM.

REFERENCES

1. Beutler E, Felitti V, Gelbart T, Ho N. Genetics of iron storage and hemochromatosis. *Drug Metab Dispos* 2001; **29**: 495-499 [PMID: [11259339](#)]
2. Shalev H, Kapelushnik J, Moser A, Dgany O, Krasnov T, Tamary H. A comprehensive study of the neonatal manifestations of congenital dyserythropoietic anemia type I. *J Pediatr Hematol Oncol* 2004; **26**: 746-748 [PMID: [15543010](#)]
3. Tamary H, Dgany O. *Congenital Dyserythropoietic Anemia Type I*. In: Adam MP, Ardinger HH, Pagon RA, Wallace SE, Bean LJH, Mefford HC, Stephens K, Amemiya A, Ledbetter N, editors. GeneReviews. Seattle, WA, United States 1993;
4. Bader-Meunier B, Leverger G, Tchernia G, Schischmanoff O, Cynober T, Bernaudin F, Leblanc T, Munzer M, Roda L, Soler C, Thuret I, Delaunay J. Clinical and laboratory manifestations of congenital dyserythropoietic anemia type I in a cohort of French children. *J Pediatr Hematol Oncol* 2005; **27**: 416-419 [PMID: [16096522](#)]
5. Sarigianni M, Liakos A, Vlachaki E, Paschos P, Athanasiadou E, Montori VM, Murad MH, Tsapas A. Accuracy of magnetic resonance imaging in diagnosis of liver iron overload: a systematic review and meta-analysis. *Clin Gastroenterol Hepatol* 2015; **13**: 55-63.e5 [PMID: [24993364](#) DOI: [10.1016/j.cgh.2014.05.027](#)]
6. Goede JS, Benz R, Fehr J, Schwarz K, Heimpel H. Congenital dyserythropoietic anemia type I with bone abnormalities, mutations of the CDAN I gene, and significant responsiveness to alpha-interferon therapy. *Ann Hematol* 2006; **85**: 591-595 [PMID: [16767397](#) DOI: [10.1007/s00277-006-0143-z](#)]
7. Shalev H, Moser A, Kapelushnik J, Karplus M, Zucker N, Yaniv I, Tamary H. Congenital dyserythropoietic anemia type I presenting as persistent pulmonary hypertension of the newborn. *J Pediatr* 2000; **136**: 553-555 [PMID: [10753260](#)]
8. Kato K, Sugitani M, Kawataki M, Ohyama M, Aida N, Koga N, Ijiri R, Imaizumi K, Kigasawa H, Tanaka Y, Itani Y. Congenital dyserythropoietic anemia type I with fetal onset of severe anemia. *J Pediatr Hematol Oncol* 2001; **23**: 63-66 [PMID: [11196275](#)]
9. Tekinalp G, Sarici SU, Erdinç AS, Göğüş S, Balci S, Gürgey A. Lethal hydrops fetalis due to congenital dyserythropoietic anemia in a newborn: association of a new skeletal abnormality. *Pediatr Hematol Oncol* 2001; **18**: 537-542 [PMID: [11764104](#) DOI: [10.1080/088800101753328510](#)]
10. Salihoglu A, Elverdi T, Eskazan AE, Eyice D, Bavunoglu I, Ar MC, Ongoren S, Guzel E, Baslar Z,

- Tunckale A, Tuzuner N, Soysal T. Congenital Dyserythropoietic Anemia Type 1: Report of One Patient and Analysis of Previously Reported Patients Treated with Interferon Alpha. *Indian J Hematol Blood Transfus* 2016; **32**: 272-277 [PMID: [27408411](#) DOI: [10.1007/s12288-015-0600-8](#)]
- 11 **Marwaha RK**, Bansal D, Trehan A, Garewal G. Interferon therapy in congenital dyserythropoietic anemia type I/II. *Pediatr Hematol Oncol* 2005; **22**: 133-138 [PMID: [15804998](#) DOI: [10.1080/08880010590907221](#)]
- 12 **Parez N**, Dommergues M, Zupan V, Chambost H, Fieschi JB, Delaunay J, Miélot F, Cramer EM, Dommergues JP, Wickramasinghe SN, Tchernia G. Severe congenital dyserythropoietic anaemia type I: prenatal management, transfusion support and alpha-interferon therapy. *Br J Haematol* 2000; **110**: 420-423 [PMID: [10971401](#)]
- 13 **Ayas M**, al-Jefri A, Baothman A, al-Mahr M, Mustafa MM, Khalil S, Karaoui M, Solh H. Transfusion-dependent congenital dyserythropoietic anemia type I successfully treated with allogeneic stem cell transplantation. *Bone Marrow Transplant* 2002; **29**: 681-682 [PMID: [12180113](#) DOI: [10.1038/sj.bmt.1703526](#)]

Successful treatment of noncirrhotic portal hypertension with eculizumab in paroxysmal nocturnal hemoglobinuria: A case report

Alexandra Alexopoulou, Iliana Mani, Dina G Tiniakos, Flora Kontopidou, Ioanna Tsironi, Marina Noutsou, Helen Pantelidaki, Spyros P Dourakis

ORCID number: Alexandra Alexopoulou (0000-0003-1991-7436); Iliana Mani (0000-0002-9971-5174); Dina G Tiniakos (0000-0003-4657-7780); Flora Kontopidou (0000-0001-7303-6635); Ioanna Tsironi (0000-0003-4275-847X); Marina Noutsou (0000-0002-8092-1023); Helen Pantelidaki (0000-0001-6449-3666); Spyros P Dourakis (0000-0003-1259-9199).

Author contributions: Alexopoulou A and Mani I reviewed the literature and contributed to manuscript drafting; Tiniakos DG analyzed and interpreted the histological findings and contributed to manuscript drafting; Kontopidou F performed the hematological consultation and contributed to manuscript drafting; Pantelidaki H, Noutsou M, and Tsironi I reviewed the literature and contributed to manuscript drafting; Dourakis SP was responsible for the revision of the manuscript for important intellectual content; all authors issued final approval for the version to be submitted.

Informed consent statement: Informed written consent was obtained from the patient for publication of this report and any accompanying images.

Conflict-of-interest statement: The authors declare that they have no conflict of interest.

CARE Checklist (2016) statement: The authors have read the CARE Checklist (2013), and the manuscript was prepared and

Alexandra Alexopoulou, Iliana Mani, Flora Kontopidou, Ioanna Tsironi, Marina Noutsou, Helen Pantelidaki, Spyros P Dourakis, 2nd Department of Medicine, Medical School, National and Kapodistrian University of Athens, Hippokration General Hospital, Athens 11527, Greece

Dina G Tiniakos, Institute of Cellular Medicine, Faculty of Medical Sciences, Newcastle University, Framlington Place, Newcastle NE2 4HH, United Kingdom

Dina G Tiniakos, Department of Pathology, Aretaieion Hospital, National and Kapodistrian University of Athens, Athens 11528, Greece

Corresponding author: Alexandra Alexopoulou, MD, PhD, Associate Professor, 2nd Department of Medicine, Medical School, National and Kapodistrian University of Athens, Hippokration General Hospital, 114 Vas Sophias St, Athens 11527, Greece. alexopou@ath.forthnet.gr

Telephone: +30-213-2088178

Fax: +30-210-7706871

Abstract

BACKGROUND

Idiopathic non-cirrhotic portal hypertension (INCPH) is mainly associated with thrombophilia in Western countries. Paroxysmal nocturnal hemoglobinuria (PNH) is a rare hematologic disease that manifests with hemolytic anemia, thrombosis, and peripheral blood cytopenias. Portal and hepatic venous thrombosis were reported in PNH. A rare case of INCPH complicating PNH is described.

CASE SUMMARY

A 63-year old woman with a 2-year past medical history of PNH without treatment was admitted because of jaundice and refractory ascites requiring large volume paracentesis. Liver histology revealed portal venopathy with portal fibrosis and sclerosis, nodular regenerative hyperplasia, parenchymal ischemic changes, and focal sinusoidal and perivenular fibrosis without bridging fibrosis or cirrhosis, all indicative of INCPH. The flow cytometry confirmed PNH diagnosis and eculizumab treatment was initiated. Her condition was improved gradually, bilirubin was normalized 6 months following initiation of eculizumab, and 1 year later diuretics were stopped.

CONCLUSION

Eculizumab improved intravascular hemolysis and reversed clinical manifestations of INCPH in a patient with paroxysmal nocturnal hemoglobinuria.

revised according to the CARE Checklist (2016).

Open-Access: This article is an open-access article that was selected by an in-house editor and fully peer-reviewed by external reviewers. It is distributed in accordance with the Creative Commons Attribution Non Commercial (CC BY-NC 4.0) license, which permits others to distribute, remix, adapt, build upon this work non-commercially, and license their derivative works on different terms, provided the original work is properly cited and the use is non-commercial. See: <http://creativecommons.org/licenses/by-nc/4.0/>

Manuscript source: Unsolicited Manuscript

Received: March 6, 2019

Peer-review started: March 7, 2019

First decision: April 11, 2019

Revised: April 25, 2019

Accepted: May 20, 2019

Article in press: May 20, 2019

Published online: May 27, 2019

P-Reviewer: Akbulut S, El-Razek AA, Ferraioli G, Garbuzenko DV

S-Editor: Cui LJ

L-Editor: Filipodia

E-Editor: Zhang YL



Key words: Paroxysmal nocturnal hemoglobinuria; Idiopathic non-cirrhotic portal hypertension; Eculizumab; Case report

©The Author(s) 2019. Published by Baishideng Publishing Group Inc. All rights reserved.

Core tip Idiopathic non-cirrhotic portal hypertension diagnosis is based on liver histology, the clinical signs of portal hypertension, and the exclusion of chronic liver diseases in the absence of portal and hepatic venous thrombosis. We describe a patient with paroxysmal nocturnal hemoglobinuria who presented with intravascular hemolysis, jaundice, and refractory ascites. Abdominal portosystemic collaterals were evident in imaging without varices in endoscopy. Liver histology demonstrated portal venopathy, features of nodular regenerative hyperplasia, and ischemic parenchymal changes without cirrhosis, all indicative of idiopathic non-cirrhotic portal hypertension. Eculizumab treatment achieved improvement of hemolysis and reversion of biochemical and clinical manifestations of liver disease.

Citation: Alexopoulou A, Mani I, Tiniakos DG, Kontopidou F, Tsironi I, Noutsou M, Pantelidaki H, Dourakis SP. Successful treatment of noncirrhotic portal hypertension with eculizumab in paroxysmal nocturnal hemoglobinuria: A case report. *World J Hepatol* 2019; 11(5): 483-488

URL: <https://www.wjgnet.com/1948-5182/full/v11/i5/483.htm>

DOI: <https://dx.doi.org/10.4254/wjh.v11.i5.483>

INTRODUCTION

Idiopathic non-cirrhotic portal hypertension (INCPH) is evidenced by the presence of an increased portal venous pressure gradient despite the absence of a known cause of chronic liver disease and portal vein thrombosis^[1]. In India, INCPH accounts for 23% of portal hypertension cases^[2], while in the Western world, it is very rare^[3]. The etiology is heterogeneous and varies according to the geographical area and the population studied^[4,5]. INCPH is often misdiagnosed as liver cirrhosis, so liver histology is required to differentiate between the two entities^[1]. Histological features in liver specimens from patients with INCPH include obliterative portal venopathy, hepatoportal sclerosis, nodular regenerative hyperplasia, and incomplete septal cirrhosis^[1]. It has been suggested that obliterative portal venopathy may represent an early stage while nodular regenerative hyperplasia is a late stage of the same disease currently termed porto-sinusoidal vascular disease^[6], which may lead to INCPH^[7]. Paroxysmal nocturnal hemoglobinuria (PNH) is a rare disease^[8] and has not been reported so far as a cause of INCPH. We herein describe a case of PNH complicated by INCPH, which was reversed clinically by the administration of eculizumab.

CASE PRESENTATION

Chief complaints

A 63-year old female patient was admitted to the hospital for fatigue, jaundice, and large-volume ascites.

History of present illness

PNH was diagnosed 2 years earlier when she was admitted for anemia, but she was lost to follow-up. Six weeks before current admission, portal vein thrombosis was diagnosed and enoxaparin 60 IU twice daily was initiated.

Physical examination

The abdomen was distended, and the liver was enlarged 4 cm below the right costal margin. The spleen was mildly enlarged.

Laboratory workup

Blood analysis revealed hemoglobin of 10.8 g/dL, white blood cell count $5.4 \times 10^9/L$, platelets $171 \times 10^9/L$, reticulocytes 6.5%, international normalized ratio 1.0, total bilirubin 4 mg/dL, direct bilirubin 2.6 mg/dL, aspartate transaminase 28 IU/L,

alanine transaminase 12 IU/L, alkaline phosphatase 456 IU/L, glutamyl transpeptidase 248 IU/L, total protein 6.6 g/dL, albumin 3.3 g/dL, lactate dehydrogenase (LDH) 650 U/L, serum haptoglobin < 7 mg/dL, creatinine 1.7 mg/dL, urea 81 mg/dL. Ascitic fluid had a serum-ascites albumin gradient of 1.7 g/dL (ascitic fluid total protein 3 g/dL, albumin 1.6 g/dL). Hepatitis B and C and human immunodeficiency virus serology was negative. Direct globulin test was negative.

Further work-up

In Doppler ultrasonography of splenoportal axis, recanalization of the portal vein and large abdominal portosystemic anastomoses were evident. Hepatic veins were patent. Magnetic resonance imaging showed hepatomegaly and confirmed the above findings. No esophageal or gastric varices were demonstrated in endoscopy. Ascites was refractory to diuretics and multiple large volume paracenteses were required. Due to the absence of a clear etiology of portal hypertension, a liver biopsy was performed.

Liver histology

Changes of portal venopathy with portal fibrosis and sclerosis and features of nodular regenerative hyperplasia were demonstrated. A spectrum of portal vein lesions was seen in interlobular portal tracts included in the biopsy, ranging from portal venule herniation in the periportal parenchyma, to slit-like stenosed portal venules and sclerosed portal tracts without a visible portal venule. In addition, parenchymal ischemic changes indicative of decreased venous outflow, mild focal sinusoidal and perivenular fibrosis, mild cholestasis, and mild secondary siderosis were noted. There was no bridging fibrosis or cirrhosis (Figure 1). The overall changes supported the diagnosis of INCPH.

Hematology work-up

The flow cytometry at this point revealed that 16.5% of her red blood cells were PNH, 4.1% were partially deficient for CD59, and 12.4% lacked CD59 completely; 63% of her granulocytes and 60% of monocytes were PNH.

FINAL DIAGNOSIS

INCPH complicating PNH was diagnosed.

COURSE OF THE DISEASE

Paroxysms of abdominal pain, debilitating fatigue, dyspnea, deepening of jaundice (total bilirubin 21 mg/dL, direct bilirubin 14.4 mg/dL), worsening of renal function (creatinine 2.2 mg/dL), anemia (Hb 7.6 g/dL), and thrombocytopenia ($80 \times 10^9/L$) developed over the next 8 weeks, and the patient became bedridden. Vaccination for *Neisseria meningitis* was performed as a prophylaxis for future therapy with eculizumab.

TREATMENT

Eculizumab was initiated at a regular dosing for patients with PNH (600 mg weekly for the first 5 weeks followed by 900 mg biweekly thereafter).

OUTCOME AND FOLLOW-UP

Three months following eculizumab initiation, no more therapeutic paracentesis of ascitic fluid was required and diuretics were administered. Serum bilirubin, LDH, hemoglobin, and reticulocyte count improved gradually (Figure 2). Renal function, serum bilirubin, LDH, and platelets normalized 6 months following initiation of eculizumab. One year later, diuretics were stopped without reappearance of the ascites. No direct antiglobulin test was evident during follow-up. Anticoagulation treatment with enoxaparin was continued during hospitalization and follow-up.

DISCUSSION

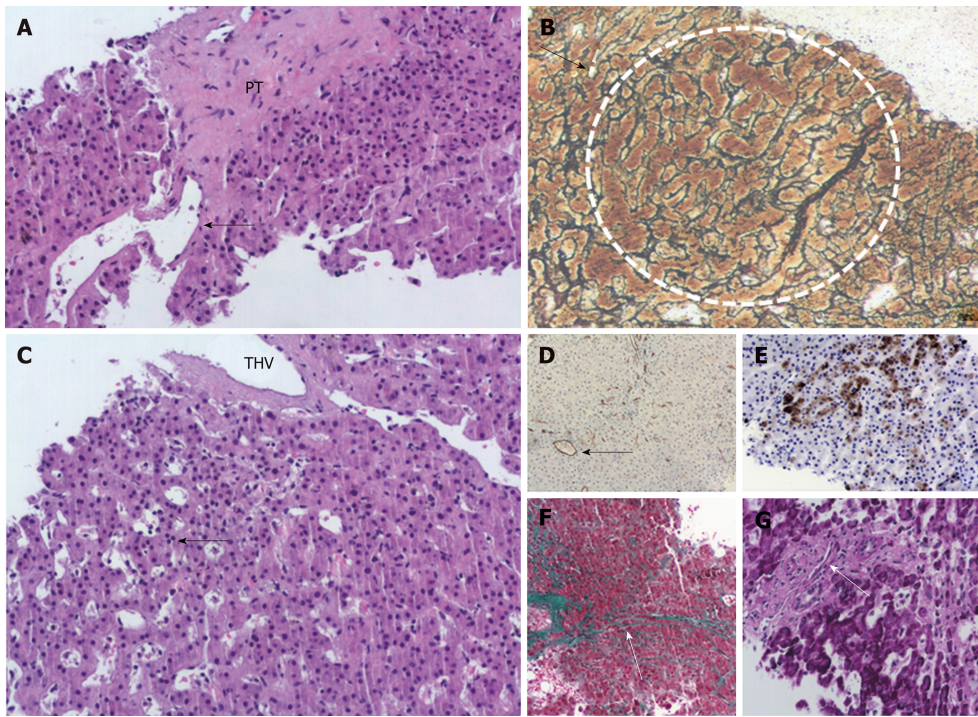


Figure 1 Selected images from the liver biopsy showing changes of portal venopathy and features of nodular regenerative hyperplasia. A: A sclerosed PT without a visible portal vein. Peripherally, a dilated portal vein radicle herniates into the adjacent hepatic parenchyma (HE, x 10); B: Nodular regenerative hyperplasia. White dotted line circumscribes a nodule of regenerating hepatocytes surrounded by atrophic hepatocyte trabeculae (arrow), reticulin stain, x 10; C: THV with perivenular sclerosis. Sinusoidal dilatation in zone 3 (arrow), (HE, x 10); D: Sinusoidal capillarization in ischemic areas highlighted by CD34 immunostain. Arrow points to a THV (brown CD 34-positive sinusoidal staining), x 10; E: Keratin 7-positive atrophic hepatocytes indicative of ischemia in zone 3 (brown staining), x 10; F: Sinusoidal zone 3 fibrosis in zone 3 (arrow) and perivenular fibrosis in midleft, Masson trichrome stain, x 10; G: A fibrosed portal tract with a slit-like portal venule (arrow), PAS stain, x 20. PT: Portal tract; THV: Terminal hepatic vein; HE: Hematoxylin & eosin.

Our patient fulfilled all the criteria for the diagnosis of INCPH, including the clinical signs of portal hypertension (ascites and portovenous collaterals in our case), the exclusion of cirrhosis on histology, the absence of chronic liver diseases causing cirrhosis or other conditions causing INCPH, and the patency of portal and hepatic veins^[1]. Although called idiopathic, INCPH has been associated with various conditions, including thrombophilia^[9], hematological malignancies^[10], infections^[11], medication and toxins^[12], genetic^[13] and immunological disorders^[14]. The main symptoms of patients with INCPH are upper gastrointestinal bleeding and splenomegaly^[2,15]. Ascites, as in the current case, was present in 50% of cases in a French^[16] and in 26% in a Spanish study^[17]. Prothrombotic disorders accounted for 48% in the former and 8% in the latter. Our case demonstrated the presence of large abdominal portosystemic collaterals. However, esophageal or gastric varices were not evident, probably due to the early stage of portal hypertension. Chronic ascites may be attributed both to portal hypertension and the concomitant renal failure in keeping with published literature^[1]. Kidney disease is a common manifestation of PNH and is a result of tubular damage caused by microvascular thrombosis and renal iron accumulation^[8].

From a pathophysiology point of view, in thrombophilia cases of INCPH, increased intrahepatic resistance ensuing from obliteration of the portal venous microcirculation may result in an increase in portal blood pressure^[7,18]. High levels of endothelin-1 might further increase vascular resistance and stimulate periportal collagen production^[19]. Another hypothesis is that the prothrombotic disorder affects the sinusoidal and portal vein wall causing fibrosis, obstruction, and secondary alterations in hepatic architecture^[10]. In the case of PNH, the accumulation of high levels of free hemoglobin, which is a potent nitric oxide scavenger^[20], may play a role in increasing vascular resistance. Nitric oxide maintains smooth muscle relaxation and inhibits platelet activation and aggregation^[21]. Its deficiency may contribute to smooth muscle tone increase and platelet activation.

In PNH, deficiency of the glycosyl phosphatidylinositol-anchored complement regulatory proteins CD55 and CD59 induces the intravascular hemolysis that is the main clinical manifestation of the disease^[22,23]. Thrombotic events occur in about 27% of patients with PNH and are the main cause of mortality, accounting for approximately 40% of deaths^[24]. Hepatic and portal veins are considered common

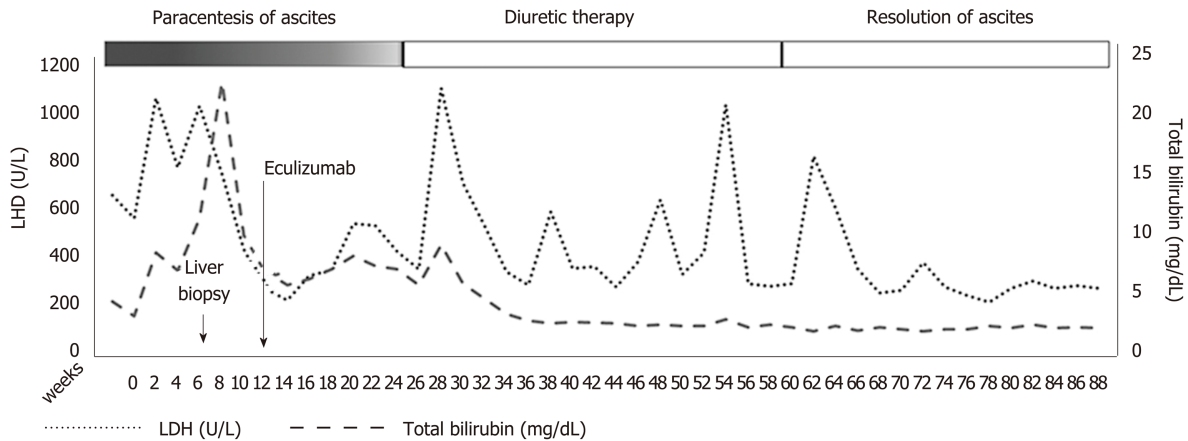


Figure 2 Clinical and laboratory course of the disease before and after treatment with eculizumab.

sites of thrombosis^[25]. Eculizumab is a monoclonal blocking antibody to complement protein C5, which inhibits cleavage to C5a and C5b and impedes terminal complement complex C5b-9^[26]. Trials with eculizumab demonstrated a reduction in hemolysis, stabilization of hemoglobin levels, and a reduction in transfusion requirements but also a protection against the complications of hemolytic PNH, such as deteriorating renal function, pulmonary hypertension, and thromboembolism^[27].

The patient presented has a large clone (> 50% PNH granulocytes and > 10% PNH red cells) combined with a notably increased LDH as evidence of intravascular hemolysis and a high reticulocyte count. In addition, platelet count was normal and anemia was mild without transfusion requirement, indicating an adequate bone marrow reserve. Thus, she had many chances to benefit from eculizumab treatment as the drug is highly effective in abrogating the intravascular hemolysis of PNH and reducing the risk of thrombosis but does not alleviate bone marrow failure if present^[28]. Eculizumab is expensive and should be administered indefinitely for achieving sustained response. It has been stated that the drug has changed the natural course of PNH^[29].

In our case, long-term treatment with eculizumab in combination with anticoagulation in a patient with PNH and INCPH resulted in improvement of the symptoms of liver disease, elimination of intravascular hemolysis, gradual resolution of kidney disease, and improvement of quality of life. The beneficial effect of the drug on liver microcirculation may be a result of the elimination of the prothrombotic disorder and the decrease of vascular resistance of the sinusoidal and portal venous walls.

CONCLUSION

Long-term administration of the monoclonal antibody eculizumab controlled the symptoms and life-threatening complications of PNH. More specifically, it reversed the complications of INCPH, as indicated by the elimination of large ascites and jaundice and normalization of liver function tests. Furthermore, it abrogated the intravascular hemolysis and improved dramatically the quality of life.

REFERENCES

- Schouten JN, Garcia-Pagan JC, Valla DC, Janssen HL. Idiopathic noncirrhotic portal hypertension. *Hepatology* 2011; **54**: 1071-1081 [PMID: 21574171 DOI: 10.1002/hep.24422]
- Sarin SK, Kumar A, Chawla YK, Baijal SS, Dhiman RK, Jafri W, Lesmana LA, Guha Mazumder D, Omata M, Qureshi H, Raza RM, Sahni P, Sakhuja P, Salih M, Santra A, Sharma BC, Sharma P, Shiha G, Sollano J; Members of the APASL Working Party on Portal Hypertension. Noncirrhotic portal fibrosis/idiopathic portal hypertension: APASL recommendations for diagnosis and treatment. *Hepatol Int* 2007; **1**: 398-413 [PMID: 19669336 DOI: 10.1007/s12072-007-9010-9]
- Wanless IR. Micronodular transformation (nodular regenerative hyperplasia) of the liver: a report of 64 cases among 2,500 autopsies and a new classification of benign hepatocellular nodules. *Hepatology* 1990; **11**: 787-797 [PMID: 2189821 DOI: 10.1002/hep.1840110512]
- Mazumder DN, Das Gupta J, Santra A, Pal A, Ghose A, Sarkar S. Chronic arsenic toxicity in west Bengal--the worst calamity in the world. *J Indian Med Assoc* 1998; **96**: 4-7, 18 [PMID: 9601181]

- 5 **Vispo E**, Moreno A, Maida I, Barreiro P, Cuevas A, Albertos S, Soriano V. Noncirrhotic portal hypertension in HIV-infected patients: unique clinical and pathological findings. *AIDS* 2010; **24**: 1171-1176 [PMID: [20299955](#) DOI: [10.1097/QAD.0b013e3283389e26](#)]
- 6 **De Gottardi A**, Rautou PE, Schouten J, Rubbia-Brandt L, Leebeek F, Trebicka J, Murad SD, Vilgrain V, Hernandez-Gea V, Nery F, Plessier A, Berzigotti A, Bioulac-Sage P, Primignani M, Semela D, Elkrif L, Bedossa P, Valla D, Garcia-Pagan JC; VALDIG group. Porto-sinusoidal vascular disease: proposal and description of a novel entity. *Lancet Gastroenterol Hepatol* 2019; **4**: 399-411 [PMID: [30957754](#) DOI: [10.1016/S2468-1253\(19\)30047-0](#)]
- 7 **Elkrif L**, Rautou PE. Idiopathic non-cirrhotic portal hypertension: the tip of the obliterative portal venopathies iceberg? *Liver Int* 2016; **36**: 325-327 [PMID: [26872111](#) DOI: [10.1111/liv.13048](#)]
- 8 **Brodsky RA**. Paroxysmal nocturnal hemoglobinuria. *Blood* 2014; **124**: 2804-2811 [PMID: [25237200](#) DOI: [10.1182/blood-2014-02-522128](#)]
- 9 **Khanna R**, Sarin SK. Idiopathic portal hypertension and extrahepatic portal venous obstruction. *Hepatol Int* 2018; **12**: 148-167 [PMID: [29464506](#) DOI: [10.1007/s12072-018-9844-3](#)]
- 10 **Schouten JN**, Verheij J, Seijo S. Idiopathic non-cirrhotic portal hypertension: a review. *Orphanet J Rare Dis* 2015; **10**: 67 [PMID: [26025214](#) DOI: [10.1186/s13023-015-0288-8](#)]
- 11 **Saifee S**, Joelson D, Braude J, Shrestha R, Johnson M, Sellers M, Galambos MR, Rubin RA. Noncirrhotic portal hypertension in patients with human immunodeficiency virus-1 infection. *Clin Gastroenterol Hepatol* 2008; **6**: 1167-1169 [PMID: [18639498](#) DOI: [10.1016/j.cgh.2008.04.023](#)]
- 12 **Maida I**, Garcia-Gasco P, Sotgiu G, Rios MJ, Vispo ME, Martin-Carbonero L, Barreiro P, Mura MS, Babudieri S, Albertos S, Garcia-Samaniego J, Soriano V. Antiretroviral-associated portal hypertension: a new clinical condition? Prevalence, predictors and outcome. *Antivir Ther* 2008; **13**: 103-107 [PMID: [18389904](#)]
- 13 **Roulot D**, Degott C, Chazouillères O, Oberti F, Calès P, Carbonell N, Benferhat S, Bresson-Hadni S, Valla D. Vascular involvement of the liver in Turner's syndrome. *Hepatology* 2004; **39**: 239-247 [PMID: [14752843](#) DOI: [10.1002/hep.20026](#)]
- 14 **Austin A**, Campbell E, Lane P, Elias E. Nodular regenerative hyperplasia of the liver and coeliac disease: potential role of IgA anticardiolipin antibody. *Gut* 2004; **53**: 1032-1034 [PMID: [15194657](#) DOI: [10.1136/gut.2003.036806](#)]
- 15 **Okuda K**, Kono K, Ohnishi K, Kimura K, Omata M, Koen H, Nakajima Y, Musha H, Hirashima T, Takashi M. Clinical study of eighty-six cases of idiopathic portal hypertension and comparison with cirrhosis with splenomegaly. *Gastroenterology* 1984; **86**: 600-610 [PMID: [6698361](#)]
- 16 **Hillaire S**, Bonte E, Denninger MH, Casadevall N, Cadranet JF, Lebre D, Valla D, Degott C. Idiopathic non-cirrhotic intrahepatic portal hypertension in the West: a re-evaluation in 28 patients. *Gut* 2002; **51**: 275-280 [PMID: [12117894](#) DOI: [10.1136/gut.51.2.275](#)]
- 17 **Siramoliwat S**, Seijo S, Miquel R, Berzigotti A, Garcia-Criado A, Darnell A, Turon F, Hernandez-Gea V, Bosch J, Garcia-Pagan JC. Idiopathic portal hypertension: natural history and long-term outcome. *Hepatology* 2014; **59**: 2276-2285 [PMID: [24155091](#) DOI: [10.1002/hep.26904](#)]
- 18 **Cazals-Hatem D**, Hillaire S, Rudler M, Plessier A, Paradis V, Condat B, Francoz C, Denninger MH, Durand F, Bedossa P, Valla DC. Obliterative portal venopathy: portal hypertension is not always present at diagnosis. *J Hepatol* 2011; **54**: 455-461 [PMID: [21087805](#) DOI: [10.1016/j.jhep.2010.07.038](#)]
- 19 **Kamath PS**, Carpenter HA, Lloyd RV, McKusick MA, Steers JL, Nagorney DM, Miller VM. Hepatic localization of endothelin-1 in patients with idiopathic portal hypertension and cirrhosis of the liver. *Liver Transpl* 2000; **6**: 596-602 [PMID: [10980059](#) DOI: [10.1053/jlts.2000.9735](#)]
- 20 **Rother RP**, Bell L, Hillmen P, Gladwin MT. The clinical sequelae of intravascular hemolysis and extracellular plasma hemoglobin: a novel mechanism of human disease. *JAMA* 2005; **293**: 1653-1662 [PMID: [15811985](#) DOI: [10.1001/jama.293.13.1653](#)]
- 21 **Ignarro LJ**. Endothelium-derived nitric oxide: actions and properties. *FASEB J* 1989; **3**: 31-36 [PMID: [2642868](#) DOI: [10.1096/fasebj.3.1.2642868](#)]
- 22 **Miyata T**, Yamada N, Iida Y, Nishimura J, Takeda J, Kitani T, Kinoshita T. Abnormalities of PIG-A transcripts in granulocytes from patients with paroxysmal nocturnal hemoglobinuria. *N Engl J Med* 1994; **330**: 249-255 [PMID: [8272086](#) DOI: [10.1056/nejm199401273300404](#)]
- 23 **Bessler M**, Mason PJ, Hillmen P, Miyata T, Yamada N, Takeda J, Luzzatto L, Kinoshita T. Paroxysmal nocturnal haemoglobinuria (PNH) is caused by somatic mutations in the PIG-A gene. *EMBO J* 1994; **13**: 110-117 [PMID: [8306954](#) DOI: [10.1002/j.1460-2075.1994.tb06240.x](#)]
- 24 **Devalet B**, Mullier F, Chatelain B, Dogné JM, Chatelain C. Pathophysiology, diagnosis, and treatment of paroxysmal nocturnal hemoglobinuria: a review. *Eur J Haematol* 2015; **95**: 190-198 [PMID: [25753400](#) DOI: [10.1111/ejh.12543](#)]
- 25 **Ziakas PD**, Poulou LS, Rokas GI, Bartzoudis D, Voulgarelis M. Thrombosis in paroxysmal nocturnal hemoglobinuria: sites, risks, outcome. An overview. *J Thromb Haemost* 2007; **5**: 642-645 [PMID: [17319910](#) DOI: [10.1111/j.1538-7836.2007.02379.x](#)]
- 26 **Hillmen P**, Young NS, Schubert J, Brodsky RA, Socié G, Muus P, Röth A, Szer J, Elebute MO, Nakamura R, Browne P, Risitano AM, Hill A, Schrezenmeier H, Fu CL, Maciejewski J, Rollins SA, Mojcik CF, Rother RP, Luzzatto L. The complement inhibitor eculizumab in paroxysmal nocturnal hemoglobinuria. *N Engl J Med* 2006; **355**: 1233-1243 [PMID: [16990386](#) DOI: [10.1056/NEJMoa061648](#)]
- 27 **Brodsky RA**, Young NS, Antonioli E, Risitano AM, Schrezenmeier H, Schubert J, Gaya A, Coyle L, de Castro C, Fu CL, Maciejewski JP, Bessler M, Kroon HA, Rother RP, Hillmen P. Multicenter phase 3 study of the complement inhibitor eculizumab for the treatment of patients with paroxysmal nocturnal hemoglobinuria. *Blood* 2008; **111**: 1840-1847 [PMID: [18055865](#) DOI: [10.1182/blood-2007-06-094136](#)]
- 28 **Kelly RJ**, Hill A, Arnold LM, Brooksbank GL, Richards SJ, Cullen M, Mitchell LD, Cohen DR, Gregory WM, Hillmen P. Long-term treatment with eculizumab in paroxysmal nocturnal hemoglobinuria: sustained efficacy and improved survival. *Blood* 2011; **117**: 6786-6792 [PMID: [21460245](#) DOI: [10.1182/blood-2011-02-333997](#)]
- 29 **Hillmen P**, Muus P, Röth A, Elebute MO, Risitano AM, Schrezenmeier H, Szer J, Browne P, Maciejewski JP, Schubert J, Urbano-Ispizua A, de Castro C, Socié G, Brodsky RA. Long-term safety and efficacy of sustained eculizumab treatment in patients with paroxysmal nocturnal haemoglobinuria. *Br J Haematol* 2013; **162**: 62-73 [PMID: [23617322](#) DOI: [10.1111/bjh.12347](#)]



Published By Baishideng Publishing Group Inc
7041 Koll Center Parkway, Suite 160, Pleasanton, CA 94566, USA
Telephone: +1-925-2238242
Fax: +1-925-2238243
E-mail: bpgoffice@wjgnet.com
Help Desk: <https://www.f6publishing.com/helpdesk>
<https://www.wjgnet.com>

