

# World Journal of *Hepatology*

*World J Hepatol* 2014 April 27; 6(4): 160-262





## Editorial Board

2014-2017

The *World Journal of Hepatology* Editorial Board consists of 469 members, representing a team of worldwide experts in hepatology. They are from 53 countries, including Algeria (1), Argentina (6), Armenia (1), Australia (1), Austria (4), Bangladesh (2), Belgium (3), Botswana (2), Brazil (13), Bulgaria (2), Canada (3), Chile (1), China (98), Czech Republic (1), Denmark (2), Egypt (12), France (6), Germany (19), Greece (11), Hungary (5), India (15), Indonesia (2), Iran (4), Israel (1), Italy (52), Japan (35), Jordan (1), Malaysia (2), Mexico (3), Moldova (1), Netherlands (3), Nigeria (1), Pakistan (1), Philippines (2), Poland (1), Portugal (2), Qatar (1), Romania (6), Russia (2), Saudi Arabia (4), Singapore (1), South Korea (11), Spain (20), Sri Lanka (1), Sudan (1), Sweden (1), Switzerland (1), Thailand (4), Turkey (21), Ukraine (3), United Kingdom (17), and United States (56).

### EDITORS-IN-CHIEF

Clara Balsano, Rome  
Wan-Long Chuang, Kaohsiung

### GUEST EDITORIAL BOARD MEMBERS

King-Wah Chiu, Kaohsiung  
Tai-An Chiang, Tainan  
Chi-Tan Hu, Hualien  
Sen-Yung Hsieh, Taoyuan  
Wenya Huang, Tainan  
Liang-Yi Hung, Tainan  
Jih RU Hwu, Hsinchu  
Jing-Yi Lee, Taipei  
Mei-Hsuan Lee, Taipei  
Chih-Wen Lin, Kaohsiung  
Chun-Che Lin, Taichung  
Wan-Yu Lin, Taichung  
Tai-Long Pan, Tao-Yuan  
Suh-Ching Yang, Taipei  
Chun-Yan Yeung, Taipei

### MEMBERS OF THE EDITORIAL BOARD



**Algeria**

Samir Rouabhia, Batna



**Argentina**

Fernando O Bessone, Rosario  
Maria C Carrillo, Rosario  
Melisa M Dirchwolf, Buenos Aires  
Bernardo Frider, Buenos Aires

Jorge Quarleri, Buenos Aires  
Adriana M Torres, Rosario



**Armenia**

Narina Sargsyants, Yerevan



**Australia**

Mark D Gorrell, Sydney



**Austria**

Harald Hofer, Vienna  
Gustav Paumgartner, Vienna  
Matthias Pinter, Vienna  
Thomas Reiberger, Vienna



**Bangladesh**

Shahinul Alam, Dhaka  
Mamun Al Mahtab, Dhaka



**Belgium**

Nicolas Lanthier, Brussels  
Philip Meuleman, Ghent  
Luisa Vonghia, Antwerp



**Botswana**

Francesca Cainelli, Gaborone

Sandro Vento, Gaborone



**Brazil**

Edson Abdala, Sao Paulo  
Ilka FSF Boin, Campinas  
Niels OS Camara, Sao Paulo  
Ana Carolina FN Cardoso, Rio de Janeiro  
Roberto J Carvalho-Filho, Sao Paulo  
Julio CU Coelho, Curitiba  
Flavio Henrique Ferreira Galvao, São Paulo  
Janaina L Narciso-Schiavon, Florianopolis  
Sílvia HC Sales-Peres, Bauru  
Leonardo L Schiavon, Florianópolis  
Luciana D Silva, Belo Horizonte  
Vanessa Souza-Mello, Rio de Janeiro  
Jaques Waisberg, Santo André



**Bulgaria**

Mariana P Penkova-Radicheva, Stara Zagora  
Marieta Simonova, Sofia



**Canada**

Runjan Chetty, Toronto  
Michele Molinari, Halifax  
Giada Sebastiani, Montreal



**Chile**

Luis A Videla, Santiago



## China

Guang-Wen Cao, Shanghai  
 En-Qiang Chen, Chengdu  
 Gong-Ying Chen, Hangzhou  
 Jin-lian Chen, Shanghai  
 Jun Chen, Changsha  
 Alfred Cheng, Hong Kong  
 Chun-Ping Cui, Beijing  
 Shuang-Suo Dang, Xi'an  
 Ming-Xing Ding, Jinhua  
 Zhi-Jun Duang, Dalian  
 He-Bin Fan, Wuhan  
 Xiao-Ming Fan, Shanghai  
 James Yan Yue Fung, Hong Kong  
 Yi Gao, Guangzhou  
 Zuo-Jiong Gong, Wuhan  
 Zhi-Yong Guo, Guangzhou  
 Shao-Liang Han, Wenzhou  
 Tao Han, Tianjin  
 Jin-Yang He, Guangzhou  
 Ming-Liang He, Hong Kong  
 Can-Hua Huang, Chengdu  
 Bo Jin, Beijing  
 Shan Jin, Hohhot  
 Hui-Qing Jiang, Shijiazhuang  
 Wan-Yee Joseph Lau, Hong Kong  
 Guo-Lin Li, Changsha  
 Jin-Jun Li, Shanghai  
 Qiang Li, Jinan  
 Sheng Li, Jinan  
 Zong-Fang Li, Xi'an  
 Xu Li, Guangzhou  
 Xue-Song Liang, Shanghai  
 En-Qi Liu, Xi'an  
 Pei Liu, Shenyang  
 Zhong-Hui Liu, Changchun  
 Guang-Hua Luo, Changzhou  
 Yi Lv, Xi'an  
 Guang-Dong Pan, Liuzhou  
 Wen-Sheng Pan, Hangzhou  
 Jian-Min Qin, Shanghai  
 Wai-Kay Seto, Hong Kong  
 Hong Shen, Changsha  
 Xiao Su, Shanghai  
 Li-Ping Sun, Beijing  
 Wei-Hao Sun, Nanjing  
 Xue-Ying Sun, Harbin  
 Hua Tang, Tianjin  
 Ling Tian, Shanghai  
 Eric Tse, Hong Kong  
 Guo-Ying Wang, Changzhou  
 Yue Wang, Beijing  
 Shu-Qiang Wang, Chengdu  
 Mary MY Wayne, Hong Kong  
 Hong-Shan Wei, Beijing  
 Danny Ka-Ho Wong, Hong Kong  
 Grace Lai-Hung Wong, Hong Kong  
 Bang-Fu Wu, Dongguan  
 Feng Wu, Chongqing  
 Xiong-Zhi Wu, Tianjin  
 Chun-Fang Xu, Suzhou  
 Rui-An Xu, Quanzhou  
 Rui-Yun Xu, Guangzhou  
 Wei-Li Xu, Shijiazhuang  
 Shi-Ying Xuan, Qingdao  
 Ming-Xian Yan, Jinan  
 Lv-Nan Yan, Chengdu  
 Jin Yang, Hangzhou  
 Ji-Hong Yao, Dalian  
 Winnie Yeo, Hong Kong

Zheng Zeng, Beijing  
 Qi Zhang, Hangzhou  
 Shi-Jun Zhang, Guangzhou  
 Xiao-Lan Zhang, Shijiazhuang  
 Xiao-Yong Zhang, Guangzhou  
 Xin-Chen Zhang, Harbin  
 Yong Zhang, Xi'an  
 Hong-Chuan Zhao, Hefei  
 Ming-Hua Zheng, Wenzhou  
 Yu-Bao Zheng, Guangzhou  
 Ren-Qian Zhong, Shanghai  
 Fan Zhu, Wuhan  
 Xiao Zhu, Dongguan



## Czech Republic

Kamil Vysloulzil, Olomouc



## Denmark

Henning Gronbaek, Aarhus  
 Christian Mortensen, Hvidovre



## Egypt

Ihab T Abdel-Raheem, Damanhour  
 NGB G Bader EL Din, Cairo  
 Hatem Elalfy, Mansoura  
 Mahmoud M El-Bendary, Mansoura  
 Mona El SH El-Raziky, Cairo  
 Mohammad El-Sayed, Cairo  
 Yasser M Fouad, Minia  
 Mohamed AA Metwally, Benha  
 Hany Shehab, Cairo  
 Mostafa M Sira, Shebin El-koom  
 Ashraf Taye, Minia  
 MA Ali Wahab, Mansoura



## France

Laurent Alric, Toulouse  
 Sophie Conchon, Nantes  
 Daniel J Felmlee, Strasbourg  
 Herve Lerat, Creteil  
 Dominique Salmon, Paris  
 Jean-Pierre Vartanian, Paris



## Germany

Laura E Buitrago-Molina, Hannover  
 Enrico N De Toni, Munich  
 Oliver Ebert, Muenchen  
 Rolf Gebhardt, Leipzig  
 Janine V Hartl, Regensburg  
 Sebastian Hinz, Kiel  
 Benjamin Juntermanns, Essen  
 Roland Kaufmann, Jena  
 Viola Knop, Frankfurt  
 Veronika Lukacs-Kornek, Homburg  
 Benjamin Maasoumy, Hannover  
 Jochen Mattner, Erlangen  
 Nadja M Meindl-Beinker, Mannheim  
 Ulf P Neumann, Aachen  
 Margarete Odenthal, Cologne  
 Yoshiaki Sunami, Munich

Christoph Roderburg, Aachen  
 Frank Tacke, Aachen  
 Yuchen Xia, Munich



## Greece

Alex P Betrosian, Athens  
 George N Dalekos, Larissa  
 Ioanna K Delladetsima, Athens  
 Nikolaos K Gatselis, Larissa  
 Stavros Gourgiotis, Athens  
 Christos G Savopoulos, Thessaloniki  
 Tania Siahaniidou, Athens  
 Emmanouil Sinakos, Thessaloniki  
 Nikolaos G Symeonidi, Thessaloniki  
 Konstantinos C Thomopoulos, Larissa  
 Konstantinos Tziomalos, Thessaloniki



## Hungary

Gabor Banhegyi, Budapest  
 Peter L Lakatos, Budapest  
 Maria Papp, Debrecen  
 Ferenc Sipos, Budapest  
 Zsolt J Tulassay, Budapest



## India

Deepak N Amarapurkar, Mumbai  
 Girish M Bhopale, Pune  
 Sibnarayan Datta, Tezpur  
 Nutan D Desai, Mumbai  
 Sorabh Kapoor, Mumbai  
 Jaswinder S Maras, New Delhi  
 Nabeen C Nayak, New Delhi  
 C Ganesh Pai, Manipal  
 Amit Pal, Chandigarh  
 K Rajeshwari, New Delhi  
 Anup Ramachandran, Vellore  
 D Nageshwar Reddy, Hyderabad  
 Shivaram P Singh, Cuttack  
 Ajith TA, Thrissur  
 Balasubramaniyan Vairappan, Pondicherry



## Indonesia

Cosmas RA Lesmana, Jakarta  
 Neneng Ratnasari, Yogyakarta



## Iran

Seyed M Jazayeri, Tehran  
 Sedigheh Kafi-Abad, Tehran  
 Iradj Maleki, Sari  
 Fakhraddin Naghibalhossaini, Shiraz



## Israel

Stephen DH Malnick, Rehovot



## Italy

Francesco Angelico, Rome

Alfonso W Avolio, *Rome*  
 Francesco Bellanti, *Foggia*  
 Marcello Bianchini, *Modena*  
 Guglielmo Borgia, *Naples*  
 Mauro Borzio, *Milano*  
 Enrico Brunetti, *Pavia*  
 Valeria Cento, *Roma*  
 Beatrice Conti, *Rome*  
 Francesco D'Amico, *Padova*  
 Samuele De Minicis, *Fermo*  
 Fabrizio De Ponti, *Bologna*  
 Giovan Giuseppe Di Costanzo, *Napoli*  
 Luca Fabris, *Padova*  
 Giovanna Ferraioli, *Pavia*  
 Andrea Galli, *Florence*  
 Matteo Garcovich, *Rome*  
 Edoardo G Giannini, *Genova*  
 Rossano Girometti, *Udine*  
 Alessandro Granito, *Bologna*  
 Alberto Grassi, *Rimini*  
 Alessandro Grasso, *Savona*  
 Salvatore Gruttadauria, *Palermo*  
 Francesca Guerrieri, *Rome*  
 Quirino Lai, *Aquila*  
 Andrea Lisotti, *Bologna*  
 Marcello F Maida, *Palermo*  
 Lucia Malaguarnera, *Catania*  
 Andrea Mancuso, *Palermo*  
 Luca Maroni, *Ancona*  
 Francesco Marotta, *Milano*  
 Pierluigi Marzuillo, *Naples*  
 Sara Montagnese, *Padova*  
 Giuseppe Nigri, *Rome*  
 Claudia Piccoli, *Foggia*  
 Camillo Porta, *Pavia*  
 Chiara Raggi, *Rozzano (MI)*  
 Maria Rendina, *Bari*  
 Maria Ripoli, *San Giovanni Rotondo*  
 Kryssia I Rodriguez-Castro, *Padua*  
 Raffaella Romeo, *Milan*  
 Amedeo Sciarra, *Milano*  
 Antonio Solinas, *Sassari*  
 Aurelio Sonzogni, *Bergamo*  
 Giovanni Squadrito, *Messina*  
 Salvatore Sutti, *Novara*  
 Valentina Svicher, *Rome*  
 Luca Toti, *Rome*  
 Elvira Verduci, *Milan*  
 Umberto Vespasiani-Gentilucci, *Rome*  
 Maria A Zocco, *Rome*



**Japan**

Yasuhiro Asahina, *Tokyo*  
 Nabil AS Eid, *Takatsuki*  
 Kenichi Ikejima, *Tokyo*  
 Shoji Ikuo, *Kobe*  
 Yoshihiro Ikura, *Takatsuki*  
 Shinichi Ikuta, *Nishinomiya*  
 Kazuaki Inoue, *Yokohama*  
 Toshiya Kamiyama, *Sapporo*  
 Takanobu Kato, *Tokyo*  
 Saiho Ko, *Nara*  
 Haruki Komatsu, *Sakura*  
 Masanori Matsuda, *Chuo-city*  
 Yasunobu Matsuda, *Niigata*  
 Yoshifumi Nakayama, *Kitakyushu*  
 Taichiro Nishikawa, *Kyoto*

Satoshi Oeda, *Saga*  
 Kenji Okumura, *Urayasu*  
 Michitaka Ozaki, *Sapporo*  
 Takahiro Sato, *Sapporo*  
 Junichi Shindoh, *Tokyo*  
 Ryo Sudo, *Yokohama*  
 Atsushi Suetsugu, *Gifu*  
 Haruhiko Sugimura, *Hamamatsu*  
 Reiji Sugita, *Sendai*  
 Koichi Takaguchi, *Takamatsu*  
 Shinji Takai, *Takatsuki*  
 Akinobu Takaki, *Okayama*  
 Yasuhito Tanaka, *Nagoya*  
 Takuji Tanaka, *Gifu City*  
 Atsunori Tsuchiya, *Niigata*  
 Koichi Watashi, *Tokyo*  
 Hiroshi Yagi, *Tokyo*  
 Taro Yamashita, *Kanazawa*  
 Shuhei Yoshida, *Chiba*  
 Hitoshi Yoshiji, *Kashiwara*



**Jordan**

Kamal E Bani-Hani, *Zarqa*



**Malaysia**

Peng Soon Koh, *Kuala Lumpur*  
 Yeong Yeh Lee, *Kota Bahru*



**Mexico**

Francisco J Bosques-Padilla, *Monterrey*  
 María de F Higuera-de la Tijera, *Mexico City*  
 José A Morales-Gonzalez, *México City*



**Moldova**

Angela Peltec, *Chishinev*



**Netherlands**

Wybrich R Cnossen, *Nijmegen*  
 Frank G Schaap, *Maastricht*  
 Fareeba Sheedfar, *Groningen*



**Nigeria**

CA Asabamaka Onyekwere, *Lagos*



**Pakistan**

Bikha Ram Devrajani, *Jamshoro*



**Philippines**

Janus P Ong, *Pasig*  
 JD Decena Sollano, *Manila*



**Poland**

Jacek Zielinski, *Gdansk*



**Portugal**

Rui T Marinho, *Lisboa*  
 Joao B Soares, *Braga*



**Qatar**

Reem Al Olaby, *Doha*



**Romania**

Bogdan Dorobantu, *Bucharest*  
 Liana Gheorghe, *Bucharest*  
 George S Gherlan, *Bucharest*  
 Romeo G Mihaila, *Sibiu*  
 Bogdan Procopet, *Cluj-Napoca*  
 Streba T Streba, *Craiova*



**Russia**

Anisa Gumerova, *Kazan*  
 Pavel G Tarazov, *St.Petersburg*



**Saudi Arabia**

Abdulrahman A Aljumah, *Riyadh*  
 Ihab MH Mahmoud, *Riyadh*  
 Ibrahim Masoodi, *Riyadh*  
 Mhoammad K Parvez, *Riyadh*



**Singapore**

Ser Yee Lee, *Singapore*



**South Korea**

Young-Hwa Chung, *Seoul*  
 Dae-Won Jun, *Seoul*  
 Bum-Joon Kim, *Seoul*  
 Do Young Kim, *Seoul*  
 Ji Won Kim, *Seoul*  
 Moon Young Kim, *Wonju*  
 Mi-Kyung Lee, *Suncheon*  
 Kwan-Kyu Park, *Daegu*  
 Young Nyun Park, *Seoul*  
 Jae-Hong Ryoo, *Seoul*  
 Jong Won Yun, *Kyungsan*



**Spain**

Ivan G Marina, *Madrid*  
 Juan G Acevedo, *Barcelona*  
 Javier Ampuero, *Sevilla*  
 Jaime Arias, *Madrid*  
 Andres Cardenas, *Barcelona*  
 Agustin Castiella, *Mendaro*  
 Israel Fernandez-Pineda, *Sevilla*  
 Rocio Gallego-Duran, *Sevilla*  
 Rita Garcia-Martinez, *Barcelona*



José M González-Navajas, *Alicante*  
 Juan C Laguna, *Barcelona*  
 Elba Llop, *Madrid*  
 Laura Ochoa-Callejero, *La Rioja*  
 Albert Pares, *Barcelona*  
 Sonia Ramos, *Madrid*  
 Francisco Rodríguez-Frias, *Córdoba*  
 Manuel L Rodríguez-Peralvarez, *Córdoba*  
 Marta R Romero, *Salamanca*  
 Carlos J Romero, *Madrid*  
 Maria Traperó-Marugán, *Madrid*



#### **Sri Lanka**

Niranga M Devanarayana, *Ragama*



#### **Sudan**

Hatim MY Mudawi, *Khartoum*



#### **Sweden**

Evangelos Kalaitzakis, *Lund*



#### **Switzerland**

Christoph A Maurer, *Liestal*



#### **Thailand**

Taned Chitapanarux, *Chiang mai*  
 Temduang Limpaboon, *Khon Kaen*  
 Sith Phongkitkarun, *Bangkok*  
 Yong Poovorawan, *Bangkok*



#### **Turkey**

Osman Abbasoglu, *Ankara*  
 Mesut Akarsu, *Izmir*  
 Umit Akyuz, *Istanbul*  
 Hakan Alagozlu, *Sivas*  
 Yasemin H Balaban, *Istanbul*  
 Bulent Baran, *Van*  
 Mehmet Celikbilek, *Yozgat*

Levent Doganay, *Istanbul*  
 Fatih Eren, *Istanbul*  
 Abdurrahman Kadayifci, *Gaziantep*  
 Ahmet Karaman, *Kayseri*  
 Muhsin Kaya, *Diyarbakir*  
 Ozgur Kemik, *Van*  
 Serdar Moralioglu, *Uskudar*  
 A Melih Ozel, *Gebze - Kocaeli*  
 Seren Ozenirler, *Ankara*  
 Ali Sazci, *Kocaeli*  
 Goktug Sirin, *Kocaeli*  
 Mustafa Sunbul, *Samsun*  
 Nazan Tuna, *Sakarya*  
 Ozlem Yonem, *Sivas*



#### **Ukraine**

Rostyslav V Bubnov, *Kyiv*  
 Nazarii K Kobylak, *Kyiv*  
 Igor N Skrypnyk, *Poltava*



#### **United Kingdom**

Safa Al-Shamma, *Bournemouth*  
 Jayantha Arnold, *Southall*  
 Marco Carbone, *Cambridge*  
 Rajeev Desai, *Birmingham*  
 Ashwin Dhanda, *Bristol*  
 Matthew Hoare, *Cambridge*  
 Stefan G Hubscher, *Birmingham*  
 Nikolaos Karidis, *London*  
 Lemonica J Koumbi, *London*  
 Patricia Lalor, *Birmingham*  
 Ji-Liang Li, *Oxford*  
 Evaggelia Liaskou, *Birmingham*  
 Rodrigo Liberal, *London*  
 Wei-Yu Lu, *Edinburgh*  
 Richie G Madden, *Truro*  
 Christian P Selinger, *Leeds*  
 Esther Una Cidon, *Bournemouth*



#### **United States**

Naim Alkhouri, *Cleveland*  
 Robert A Anders, *Baltimore*  
 Mohammed Sawkat Anwer, *North Grafton*  
 Kalyan Ram Bhamidimarri, *Miami*

Brian B Borg, *Jackson*  
 Ronald W Busuttill, *Los Angeles*  
 Andres F Carrion, *Miami*  
 Saurabh Chatterjee, *Columbia*  
 Disaya Chavalitdhamrong, *Gainesville*  
 Mark J Czaja, *Bronx*  
 Jonathan M Fenkel, *Philadelphia*  
 Catherine Frenette, *La Jolla*  
 Lorenzo Gallon, *Chicago*  
 Kalpana Ghoshal, *Columbus*  
 Grigoriy E Gurvits, *New York*  
 Hie-Won L Hann, *Philadelphia*  
 Shuang-Teng He, *Kansas City*  
 Wendong Huang, *Duarte*  
 Rachel Hudacko, *Suffern*  
 Lu-Yu Hwang, *Houston*  
 Ijaz S Jamall, *Sacramento*  
 Neil L Julie, *Bethesda*  
 Hetal Karsan, *Atlanta*  
 Ahmed O Kaseb, *Houston*  
 Zeid Kayali, *Pasadena*  
 Kusum K Kharbanda, *Omaha*  
 Timothy R Koch, *Washington*  
 Gursimran S Kochhar, *Cleveland*  
 Steven J Kovacs, *East Hanover*  
 Mary C Kuhns, *Abbott Park*  
 Jiang Liu, *Silver Spring*  
 Li Ma, *Stanford*  
 Francisco Igor Macedo, *Southfield*  
 Sandeep Mukherjee, *Omaha*  
 Natalia A Osna, *Omaha*  
 Jen-Jung Pan, *Houston*  
 Christine Pocha, *Minneapolis*  
 Yury Popov, *Boston*  
 Davide Povero, *La Jolla*  
 Phillip Ruiz, *Miami*  
 Takao Sakai, *Cleveland*  
 Nicola Santoro, *New Haven*  
 Eva Schmelzer, *Pittsburgh*  
 Zhongjie Shi, *Philadelphia*  
 Nathan J Shores, *New Orleans*  
 Siddharth Singh, *Rochester*  
 Veysel Tahan, *Iowa City*  
 Mehlika Toy, *Boston*  
 Hani M Wadei, *Jacksonville*  
 Gulam Waris, *North Chicago*  
 Ruliang Xu, *New York*  
 Jun Xu, *Los Angeles*  
 Matthew M Yeh, *Seattle*  
 Xuchen Zhang, *West Haven*  
 Lixin Zhu, *Buffalo*  
 Sasa Zivkovic, *Pittsburgh*



### EDITORIAL

- 160 Drug-induced autoimmune liver disease: A diagnostic dilemma of an increasingly reported disease  
*Castiella A, Zapata E, Lucena MI, Andrade RJ*

### REVIEW

- 169 Lipid lowering effects of iodothyronines: *In vivo* and *in vitro* studies on rat liver  
*Vergani L*
- 178 Update on inflammatory bowel disease in patients with primary sclerosing cholangitis  
*Tsaitas C, Semertzidou A, Sinakos E*
- 188 Effects of resveratrol in experimental and clinical non-alcoholic fatty liver disease  
*Heebøll S, Thomsen KL, Pedersen SB, Vilstrup H, George J, Grønbaek H*
- 199 Insulin sensitizers for the treatment of non-alcoholic fatty liver disease  
*Ozturk ZA, Kadayifci A*
- 207 Mechanisms of fibrogenesis in liver cirrhosis: The molecular aspects of epithelial-mesenchymal transition  
*Lee SJ, Kim KH, Park KK*

### MINIREVIEWS

- 217 Pediatric non-alcoholic fatty liver disease: New insights and future directions  
*Marzuillo P, Miraglia del Giudice E, Santoro N*
- 226 To treat or not to treat the "immunotolerant phase" of hepatitis B infection: A tunnel of controversy  
*Mekky MA*

### ORIGINAL ARTICLE

- 230 Melatonin attenuates cisplatin-induced HepG2 cell death *via* the regulation of mTOR and ERCC1 expressions  
*Bennukul K, Numkliang S, Leardkamolkarn V*

## BRIEF ARTICLE

- 243 Murine model to study brain, behavior and immunity during hepatic encephalopathy

*Gomides LF, Marques PE, Faleiros BE, Pereira RV, Amaral SS, Lage TR, Resende GHS, Guidine PAM, Foureaux G, Ribeiro FM, Martins FP, Fontes MAP, Ferreira AJ, Russo RC, Teixeira MM, Moraes MF, Teixeira AL, Menezes GB*

## CLINICAL PRACTICE

- 251 Nuclear medicine dynamic investigations in the diagnosis of Budd-Chiari syndrome

*Dragoteanu M, Balea IA, Piglesan CD*

## Contents

*World Journal of Hepatology*  
Volume 6 Number 4 April 27, 2014

**APPENDIX** I-V Instructions to authors

**ABOUT COVER** Editorial Board Member of *World Journal of Hepatology*, Kwan-Kyu Park, MD, PhD, Professor, Department of Pathology, Catholic University of Daegu, Daegu ASIIRIK-S002ITAEGU, South Korea

**AIM AND SCOPE** *World Journal of Hepatology* (*World J Hepatol*, *WJH*, online ISSN 1948-5182, DOI: 10.4254), is a peer-reviewed open access academic journal that aims to guide clinical practice and improve diagnostic and therapeutic skills of clinicians.

*WJH* covers topics concerning liver biology/pathology, cirrhosis and its complications, liver fibrosis, liver failure, portal hypertension, hepatitis B and C and inflammatory disorders, steatohepatitis and metabolic liver disease, hepatocellular carcinoma, biliary tract disease, autoimmune disease, cholestatic and biliary disease, transplantation, genetics, epidemiology, microbiology, molecular and cell biology, nutrition, geriatric and pediatric hepatology, diagnosis and screening, endoscopy, imaging, and advanced technology. Priority publication will be given to articles concerning diagnosis and treatment of hepatology diseases. The following aspects are covered: Clinical diagnosis, laboratory diagnosis, differential diagnosis, imaging tests, pathological diagnosis, molecular biological diagnosis, immunological diagnosis, genetic diagnosis, functional diagnostics, and physical diagnosis; and comprehensive therapy, drug therapy, surgical therapy, interventional treatment, minimally invasive therapy, and robot-assisted therapy.

We encourage authors to submit their manuscripts to *WJH*. We will give priority to manuscripts that are supported by major national and international foundations and those that are of great basic and clinical significance.

**INDEXING/ ABSTRACTING** *World Journal of Hepatology* is now indexed in PubMed Central, PubMed, Digital Object Identifier, Directory of Open Access Journals, and Scopus.

**FLYLEAF** I-IV Editorial Board

## EDITORS FOR THIS ISSUE

Responsible Assistant Editor: *Xiang Li*  
Responsible Electronic Editor: *Huan-Liang Wu*  
Proofing Editor-in-Chief: *Lian-Sheng Ma*

Responsible Science Editor: *Fang-Fang Ji*

**NAME OF JOURNAL**  
*World Journal of Hepatology*

**ISSN**  
ISSN 1948-5182 (online)

**LAUNCH DATE**  
October 31, 2009

**FREQUENCY**  
Monthly

**EDITORS-IN-CHIEF**  
**Clara Balsano, PhD, Professor**, Departement of Biomedicine, Institute of Molecular Biology and Pathology, Rome 00161, Italy

**Wan-Long Chuang, MD, PhD, Doctor, Professor**, Hepatobiliary Division, Department of Internal Medicine, Kaohsiung Medical University Hospital, Kaohsiung Medical University, Kaohsiung 807, Taiwan

**EDITORIAL OFFICE**  
Jin-Lei Wang, Director

Xiu-Xia Song, Vice Director  
*World Journal of Hepatology*  
Room 903, Building D, Ocean International Center,  
No. 62 Dongsihuan Zhonglu, Chaoyang District,  
Beijing 100025, China  
Telephone: +86-10-85381891  
Fax: +86-10-85381893  
E-mail: bpgoffice@wjgnet.com  
<http://www.wjgnet.com>

**PUBLISHER**  
Baishideng Publishing Group Co., Limited  
Flat C, 23/F, Lucky Plaza,  
315-321 Lockhart Road, Wan Chai,  
Hong Kong, China  
Fax: +852-65557188  
Telephone: +852-31779906  
E-mail: bpgoffice@wjgnet.com  
<http://www.wjgnet.com>

**PUBLICATION DATE**  
April 27, 2014

## COPYRIGHT

© 2014 Baishideng Publishing Group Co., Limited. Articles published by this Open Access journal are distributed under the terms of the Creative Commons Attribution Non-commercial License, which permits use, distribution, and reproduction in any medium, provided the original work is properly cited, the use is non commercial and is otherwise in compliance with the license.

## SPECIAL STATEMENT

All articles published in this journal represent the viewpoints of the authors except where indicated otherwise.

## INSTRUCTIONS TO AUTHORS

Full instructions are available online at [http://www.wjgnet.com/1948-5182/g\\_info\\_20100316080002.htm](http://www.wjgnet.com/1948-5182/g_info_20100316080002.htm)

## ONLINE SUBMISSION

<http://www.wjgnet.com/esps/>



## Drug-induced autoimmune liver disease: A diagnostic dilemma of an increasingly reported disease

Agustin Castiella, Eva Zapata, M Isabel Lucena, Raúl J Andrade

Agustin Castiella, Eva Zapata, Gastroenterology Service, Mendaro Hospital, Mendaro, 20850 Guipuzcoa, Spain

M Isabel Lucena, Clinical Pharmacology, Universidad de Málaga, Instituto de Investigación Biomédica de Málaga, University Hospital Virgen de la Victoria, 29010 Málaga, Spain

Raúl J Andrade, Liver Unit, Universidad de Málaga, Instituto de Investigación Biomédica de Málaga, University Hospital Virgen de la Victoria, 29010 Málaga, Spain

M Isabel Lucena, Raúl J Andrade, Centro de Investigación Biomédica en Red de Enfermedades Hepáticas y Digestivas, 08036 Barcelona, Spain

**Author contributions:** All the authors conceived and designed the study, wrote, revised and approved the manuscript.

**Correspondence to:** Agustin Castiella, PhD, MD, Gastroenterology Service, Mendaro Hospital, Barrio Mendarozabal, 20850 Mendaro, Spain. [agustincastiella@yahoo.es](mailto:agustincastiella@yahoo.es)

**Telephone:** +34-94-3032800 **Fax:** +34-94-3032836

**Received:** October 26, 2013 **Revised:** January 9, 2014

**Accepted:** April 3, 2014

**Published online:** April 27, 2014

### Abstract

The aetiology of autoimmune hepatitis (AIH) is uncertain but the disease can be triggered in susceptible patients by external factors such as viruses or drugs. AIH usually develops in individuals with a genetic background mainly consisting of some risk alleles of the major histocompatibility complex (HLA). Many drugs have been linked to AIH phenotypes, which sometimes persist after drug discontinuation, suggesting that they awaken latent autoimmunity. At least three clinical scenarios have been proposed that refers to drug-induced autoimmune liver disease (DIAILD): AIH with drug-induced liver injury (DILI); drug induced-AIH (DI-AIH); and immune mediated DILI (IM-DILI). In addition, there are instances showing mixed features of DI-AIH and IM-DILI, as well as DILI cases with positive autoantibodies. Histologically distinguishing DILI from AIH remains a challenge. Even more challenging is the differentiation of AIH from DI-AIH mainly relying in histological features; however, a detailed standard-

ised histologic evaluation of large cohorts of AIH and DI-AIH patients would probably render more subtle features that could be of help in the differential diagnosis between both entities. Growing information on the relationship of drugs and AIH is being available, being drugs like statins and biologic agents more frequently involved in cases of DIAILD. In addition, there is some evidence on the fact that patients diagnosed with DIAILD may have had a previous episode of hepatotoxicity. Further collaborative studies in DIAILD will strengthen the knowledge and understanding of this intriguing and complex disorder which might represent different phenotypes across the spectrum of disease

© 2014 Baishideng Publishing Group Co., Limited. All rights reserved.

**Key words:** Drug-induced liver injury; Autoimmune hepatitis; Drugs; Drug-induced autoimmune hepatitis; Drug-induced autoimmune liver disease

**Core tip:** Drug-induced autoimmune liver disease (DI-AILD) is a poorly defined and under-reported liver disorder, and, probably, a underestimated liver disease. A small number of drug-induced liver injury (DILI) cases exhibit features typical of autoimmune hepatitis (AIH). To differentiate between true AIH triggered by drugs (DI-AIH) and immune mediated DILI still remains a challenge. Patients diagnosed with DIAILD have frequently had a previous episode of hepatotoxicity. We consider that some basic requirements are needed to be considered before supporting a drug as a trigger of AIH and they should be taken into account by authors, reviewers and editors when cases are published and made available to the scientific community.

Castiella A, Zapata E, Lucena MI, Andrade RJ. Drug-induced autoimmune liver disease: A diagnostic dilemma of an increasingly reported disease. *World J Hepatol* 2014; 6(4): 160-168 Available from: URL: <http://www.wjgnet.com/1948-5182/full/v6/i4/160>.

## INTRODUCTION

The cause and pathogenesis of autoimmune hepatitis (AIH) is unknown<sup>[1]</sup>. AIH is characterised by the following clinical features: (1) presence of raised aminotransferases with normal or minimal elevations of alkaline phosphatase; (2) association with hypergammaglobulinemia and raised immunoglobulin G; (3) female gender preponderance; (4) high titres of a variety of autoantibodies; (5) immunogenetic background; (6) good response to immunosuppressive treatment; and (7) the presence of extrahepatic autoimmune manifestations<sup>[2,3]</sup>. In liver biopsy specimens, the presence of interface hepatitis is characteristic<sup>[3]</sup>. In 1999, an international group developed a diagnostic score system<sup>[4]</sup>, which was later on simplified in 2008<sup>[5]</sup>.

The aetiology of AIH is uncertain, but the disease can be triggered in susceptible persons by an external factor, such as viruses, drugs or herbal remedies<sup>[1,2]</sup>.

Many clinical observations suggest that drugs are potential triggers in some patients<sup>[6,7]</sup>. Several drugs have been identified to cause AIH that may persist after discontinuation, suggesting that they triggered true autoimmunity. These include oxyphenisatin, nitrofurantoin, minocycline, chlometacin and alpha-methyl dopa<sup>[3,8]</sup>. Other drugs have been infrequently reported to lead to AIH, making the association less probable. Recently, a growing number of drug-induced autoimmune liver disease (DIAILD) reports meeting the established international criteria<sup>[4,5]</sup> and showing clinical data (hypergammaglobulinemia, ANA/ASMA), typical liver biopsy findings and HLA-DR status, which allow to establish a causal relationship<sup>[6,9-11]</sup>.

For instance, Björnsson *et al*<sup>[12]</sup>, in a series of 261 patients with AIH, reported 9.2% (24 patients) of patients with drug-induced AIH. A French group<sup>[10]</sup> searched for a potential causative drug in a consecutive series of 65 patients with AIH, and identified that 12% of the cases were drug-induced, highlighting the frequency of this disorder. In this line, 5 out of 29 (17%) consecutive patients with AIH from Spain were diagnosed with drug-induced AIH<sup>[13]</sup>.

Very recently, Licata *et al*<sup>[14]</sup> reported 12 patients from a series of 136 drug-induced liver injury (DILI) subjects that were diagnosed as drug-induced AIH (8.8%). All were treated with corticosteroids and remission was achieved after six months in 10 of the cases (83%).

Although no particular drug has been definitively identified as a true aetiological trigger agent for AIH, it is interesting to note that drug-metabolizing enzymes of phase I and phase II are common targets of autoimmunity in idiopathic AIH and viral hepatitis<sup>[2]</sup>.

It is important to distinguish drugs as triggers of a self-perpetuating autoimmune liver disease from immune-mediated drug-induced liver injury (IM-DILI). Immune-mediated DILI nearly always resolves<sup>[2,12]</sup> or becomes

quiescent when drugs are withdrawn. Another possibility is that AIH was quiescent and remains undiagnosed until a drug triggered a new autoimmune process. Thus, to attempt to make a proper diagnosis of the type of immune process affecting the liver is challenging. Björnsson *et al*<sup>[12]</sup> reported 24 cases of drug-induced AIH (22 minocycline-nitrofurantoin cases, 11/11). Immunosuppressive therapy withdrawal was successful in all the 14 cases in which it was attempted. On the contrary of the AIH cases in this series 65% relapsed upon corticosteroid withdrawal. Heurgué *et al*<sup>[10]</sup>, observed one spontaneous remission, three relapses and four remissions without relapse in 8 patients out of 65 with drug-induced AIH.

In the Spanish DILI Registry, out of 742 DILI cases, 16 were diagnosed as DIAILD<sup>[9]</sup> and 25% of these cases had another autoimmune associated disease that may require persistent immunosuppressive treatment. Such cases may preclude the therapy to be discontinued and, therefore, one cannot ascertain the course of AIH upon immunosuppressive drug withdrawal. Therefore, to state that relapse after corticosteroid discontinuation might distinguish DIAILD from classical AIH is a very attractive conclusion, but far away from the complex reality of this disorder since in many cases the coexistence of other autoimmune disorders does not allow for stopping immunosuppressive therapy<sup>[15,16]</sup>. To further complicate the differentiation between AIH and DILI, we must underline the fact that there does not seem to be any specific histological features for either of the processes and the pathological features may show only subtle differences, pointing toward an immune-mediated liver disease versus hepatic toxicity<sup>[17]</sup>.

## CLASSIFICATION

There are several possible combinations of DILI and AIH (see Table 1). In 2002 Liu *et al*<sup>[2]</sup> distinguished 2 types: drugs as a potential triggers of drug-induced AIH (DI-AIH), which supposes a self-perpetuating liver disease, and immune-mediated DILI (IM-DILI), which is an acute or chronic process depending of the duration of the exposure of the liver to the hepatic insult (viruses, herbal remedies, drugs) and disappears or becomes quiescent when the drug is withdrawn<sup>[2]</sup>. In 2011, Weiler-Normann and Schramm<sup>[18]</sup> established a classification of DILI and AIH proposing possible connections with suggested diagnoses and clinical characteristics. First, AIH with DILI: The reactivation of a known AIH upon introduction of a new drug is possible, but it is very difficult to demonstrate a causal relationship, as it might be coincidental (chance by association) Often, there is advance fibrosis on histology (see Table 1). Second, DI-AIH, reveals a patient that has not been diagnosed before, or even just the predisposition to AIH that is awakened by DILI. An immune reaction in a genetically predisposed individual may lead to a chronic process, perpetuating the AIH in these patients, with a permanent need for immunosuppression. Usually, they have typical HLA-DR associated with true AIH (Table 1). Third, IM-DILI: acute

**Table 1** Classification of drug-induced autoimmune liver disease

|                                       |   |
|---------------------------------------|---|
| AIH with DILI                         | <p>Patients with known AIH</p> <p>AIH quiescent: the drug may be the trigger of a new bout</p> <p>AIH under IS or corticosteroids treatment: Reactivation of known AIH upon introduction of a new drug (very difficult to demonstrate a causal relationship as it might be coincidental)</p> <p>Often advanced fibrosis on histology</p>                          |
| DI-AIH                                | <p>Patients with a low grade disease not diagnosed before or predisposition to AIH</p> <p>Drug produce an immune reaction that lead to a chronic process:</p> <p>Perpetuating the AIH</p> <p>Permanent need of IS</p> <p>Habitually typical HLA-DR associated</p>   |
| IM-DILI (Autoimmune hypersensitivity) | <p>Fever, eosinophilia, lymphadenopathy, rash</p> <p>Indistinguishable from true AIH: Mandatory IS treatment</p> <p>Frequently spontaneous remission after drug cessation</p> <p>Usually complete response to treatment and sustained remission without relapse</p> <p>It is the most frequent drug-induced immune process in the liver attributable to drugs</p> |
| Mixed autoimmune type                 | <p>Patients with mixed clinical features of DI-AIH and IM-DILI</p> <p>Complete response to IS treatment but with chronic course after withdrawal</p> <p>Patients under IS treatment for another autoimmune disease. Withdraw IS drugs is not possible. Remission cannot be evaluated</p>  |
| DILI with positive autoantibodies     | <p>Patients with positive autoantibodies</p> <p>The probability of developing DIAILD increases in second DILI episodes independently of the causal agent</p>  |

AIH: Autoimmune hepatitis; DILI: Drug-induced liver injury; IS: Immunosuppressants; IM-DILI: Immunomediated DILI; DIAILD: Drug-induced autoimmune liver disease; HLA: Human leukocyte antigen.

or chronic liver injury (depending of the duration of the exposure to the drug), as has been explained by Liu and Kaplowicz<sup>[2]</sup>, that resolves or becomes quiescent with drug withdrawal. This scenario can be caused by a number of drugs, such as minocycline and nitrofurantoin<sup>[2,12]</sup>. These individuals may have spontaneous remission of acute hepatitis after drug cessation, or have a hepatocellular or mixed type of liver damage that does not improve after drug-withdrawal. Fever, eosinophilia, lymphadenopathy and rash may be present, but not always. In these situations, which are indistinguishable from true AIH, the immunosuppressive (IS) treatment is mandatory and may be life-saving. Most of these patients do not need IS forever as they usually have a complete response to treatment and a sustained remission without relapse<sup>[12,16,18,19]</sup>. This type of adverse drug reaction, which can be viewed as autoimmune hypersensitivity, is the most frequent drug-induced immune process in the liver that is attributable to drugs (see Table 1)<sup>[2,12]</sup>.

A second DILI episode (recurrent DILI) involving a different drug is a rare event, but if it happens, AIH or AIH-like DILI is frequent, and reported in up to 40% of cases in the series published from the Spanish DILI Registry<sup>[20]</sup>. Differentiating IM-DILI from DI-AIH in these cases is very difficult as the clinical presentation may be the same<sup>[20]</sup>.

Nevertheless, we think that a fourth type must be added: mixed autoimmune type. These patients have mixed clinical features that belong to DI-AIH and IM-DILI types. Thus, there are published cases of IM-DILI induced by minocycline which have a complete response to IS treatment, but experience a chronic course after drug withdrawal<sup>[15,21,22]</sup>. Therefore, the same drug can be DI-AIH or IM-DILI, depending on the clinical charac-

teristics and outcome of the episode. Another possibility is that the patient requires IS treatment for an autoimmune disease, different to AIH, in which case we cannot withdraw IS drugs. In these cases, we cannot differentiate DI-AIH or IM-DILI because the patient needs chronic IS treatment for another autoimmune disease. Therefore, one cannot ascertain the course of AIH upon IS drug withdrawal. For example, chronic uveitis has been associated with AIH<sup>[23,24]</sup>, and may require permanent IS treatment. In the Spanish DILI Registry<sup>[25]</sup>, 16 out of 742 DILI cases, were diagnosed as DIAILD<sup>[9]</sup>, 25% of these cases had another associated autoimmune disease, which may require persistent IS treatment. In a French series of eight patients<sup>[10]</sup>, 25% of them had another AI associated disease.

Finally, there are patients that present DILI with positive autoantibodies. However, its significance is unknown and requires further studies. In 2002, Ohmoto and Yamamoto studied 64 patients admitted to their hospital with DILI and identified 6 with positive ANA<sup>[26]</sup>. They found a higher prevalence of associated autoimmune diseases in the ANA positive group such as AIH, rheumatoid arthritis, Hashimoto's disease. The authors suggested that patients with DILI and ANA might also have autoimmune disease and should be followed over the long-term, even if liver function has recovered. On the other hand, Hinrichsen *et al*<sup>[27]</sup> reported a case of phenprocoumon-induced hepatitis with positive autoantibodies. After the drug was stopped, no clinical or laboratory features of autoimmune liver disease were present.

Recently, the Spanish-Latin American DILI Network has published a series of 73 DILI cases, in which 29% presented positive autoantibodies, mainly ANA. Six cases were DIAILD (AIH DILI) (8%) and 5 cases (7%) had

experienced a second DILI episode<sup>[28]</sup>.

Therefore, this analysis further support that the probability of presenting positive antibodies increases in second DILI episodes, as previously shown by Andrade *et al*<sup>[29]</sup>.

## HISTOLOGY

Liver histology shows apoptosis, necrosis and inflammatory infiltrates including mononuclear cells, neutrophils, eosinophils and lymphocytes, or cholestasis and paucity of bile ducts with moderate portal inflammation. Granulomas may also be seen<sup>[2]</sup>. Distinguishing DILI from AIH is challenging histologically. Recently, Suzuki *et al*<sup>[17]</sup> showed that while a histologic overlap exists for these pathologies, sufficient differences exist for pathologists and they can use the pattern of injury proposed by Suzuki *et al*<sup>[17]</sup> to suggest a correct diagnosis. Interface hepatitis, focal necrosis and portal inflammation were present in all of the evaluated cases but were more severe in AIH than in hepatocellular DILI. Portal and intra-acinar plasma cells, rosette formation, and emperipolesis were features that favoured AIH. All Ishak inflammation scores were more severe in AIH than in cholestatic DILI. They did not identify any histologic features differentiating AIH from DIAILD (DI-AIH) in a small subgroup analysis (7 cases), but it might still be possible that detailed standardised histologic evaluation using a larger cohort of DIAILD (DI-AIH) *vs* AIH can identify histologic features that can be helpful in the differential diagnosis. Björnsson *et al*<sup>[12]</sup>, in a recent work, revealed that similar histological grades and stages were present in patients with IM-DILI (DI-AIH) *vs* AIH. However, none of the IM-DILI (DI-AIH) patients had cirrhosis at baseline and it was present in 20% of the AIH patients. Czaja<sup>[16]</sup>, based on the referred work, confirmed that cirrhosis is a rare histologic feature in nitrofurantoin AIH cases at presentation, which may help to distinguish it from classical AIH (0 *vs* 13%). In a recent review of the histological patterns found in cases of DILI<sup>[30]</sup>, it was pointed out that, contrary to minocycline, significant fibrosis and cirrhosis occurs with nitrofurantoin. The French group<sup>[10,31]</sup> biopsied all of their cases (Minocycline *n* = 3; nitrofurantoin *n* = 2; atorvastatin *n* = 1; fenofibrate *n* = 1; isotretinoin *n* = 1), showing a fibrosis score F3-F4 in 57% *vs* 48% in the DIAILD (AIH-DILI) and AIH groups, respectively. Necroinflammatory activity A3, with Metavir, was revealed in 75% *vs* 65%. They concluded that the 2 groups showed similar histological lesions of fibrosis/cirrhosis. Recently, Licata *et al*<sup>[14]</sup> studied a series of 12 patients (4 nimesulide, 1 ketoprofen, 3 amoxicillin-calvulanate, 1 ceftriaxone, 1 epigallocatechin gallate and 1 hypericum perforatum-herbal drugs-, and dimethoate-toxic agent). All DIAILD patients were treated with corticosteroids and none developed cirrhosis. Appleyard *et al*<sup>[32]</sup> published a series of 3 cases, one of which had pre-cirrhosis/cirrhosis at diagnosis. The Spanish Registry of Hepatotoxicity<sup>[9]</sup> presented a case report of DIAILD that showed cirrhosis in the liver biopsy at presentation. Therefore, the absence of histological cirrhosis at presentation would not help to

discern between these two entities.

Ju *et al*<sup>[33]</sup> have studied the histological features of DILI patients in Korea, with special focus on relevancy of AIH. The study showed that characteristic histologic features of AIH, as interface hepatitis and lymphoplasmocytic infiltrates, were present in up to one third of DILI patients.

## FREQUENCY

Recently Czaja<sup>[16]</sup> stated that the best estimate of the frequency of drug-induced autoimmune-like hepatitis among patients with classical features of AIH is 9%<sup>[12]</sup>. There are other reports that show higher figures<sup>[15]</sup>. Heurgué *et al*<sup>[10]</sup>, in France, identified 8 cases (12%) with drug-induced AIH in a consecutive series of 65 patients with AIH, fulfilling all requirements recommended in the review to confirm the diagnosis (Table 2). In Gipuzkoa, Spain, from 1994 to 2009, 29 cases of AIH were diagnosed, 5 of which were considered AIH-DILI, which resulted in a 17% frequency<sup>[13]</sup>. We believe that these differences in frequencies may be explained by the fact that AIH-DILI is often misdiagnosed.

If we study patients diagnosed with DILI, Licata *et al*<sup>[14]</sup> reported 8.8% of the patients presenting features of DIAILD (DI-AIH). In the Spanish DILI Registry<sup>[9]</sup>, out of 742 recruited cases, 16 presented DIAILD criteria (2.15%).

### Why is there a growing number of case reports?

Indeed, the diagnosis of AIH is often made in the setting of a patient being treated with multiple drugs. If the diagnostic scale points out probable AIH, the possible role of the drug is generally underscored, and immunosuppressive treatment is started. On the other hand, if the AIH scale is not conclusive and/or histology findings are more consistent with DILI, the case is assumed to be a DILI case, particularly if the clinical symptoms resolve after discontinuation of the suspected drug (DIAILD may be a self-limiting process), and the possibility of unmasking AIH by the action of a drug is disregarded. To further complicate the differentiation between AIH and DILI we must underline the fact that there is no specific histological features of either process and the pathological features may show only subtle differences pointing to the immune-mediated liver disease versus hepatic toxicity<sup>[17]</sup>. These considerations lead us to suggest that DIAILD might be underreported nowadays.

When a patient is admitted to hospital because of acute hepatitis and the drug that is thought to be responsible is identified, treatment is stopped.

If transaminases decreased more than 50% in 1 week to 1 month, and the DILI case fulfils other Council for International Organizations of medical Science (CIOMS) criteria such as a favourable temporal sequence, alternative pharmacological and clinical conditions have been ruled out, dechallenge with the drug is followed by improvement, and rechallenge if present is positive, then the DILI case is probably related to the drug<sup>[34,35]</sup>. Sponta-



neous recovery supports this possibility and, generally, if autoantibodies have been solicited to the laboratory and are positive, we do not consider the possibility of a drug as a trigger of IM-DILI.

If aminotransferases remain permanently raised, suffer an increase during follow-up, and autoantibodies are positive, AIH is assumed; if the AIH-scale reveals a probable AIH, treatment with IS is begun as soon as possible. There is complete exclusion of the trigger paper of a drug treatment if it is present prior to acute hepatitis, or if the drug is retired but without giving its importance to it; if true, AIH may resolve spontaneously.

New drugs: the growing use of drugs such as statins and biologic agents, which have been related to DILI with autoimmune features, which has prompted an increase in the diagnosis of DIAILD<sup>[36-42]</sup>.

The diagnosis DIAILD represents a challenge to the clinician as there are neither histological, nor clinical features that are pathognomonic of true AIH, and HLA haplotypes do not convincingly distinguish between either entity. Indeed, as previously commented many cases of drug-induced AIH tend to be misdiagnosed as classical AIH cases. The CIOMS scale is unable to distinguish between AIH and DIAILD, as the scale fails to accommodate all relevant information for diagnosing DIAILD. Causality may also be challenged by the lack of spontaneous improvement after drug withdrawal in this form of DILI.

## PREDICTION OF AUTOIMMUNE HEPATITIS-RISK FACTORS

### Susceptibility

**Autoantibodies:** Many autoimmune diseases are chronic conditions that progress over the years, and are characterised by the presence of autoantibodies that may precede the overt disease by months or years<sup>[43]</sup>. In AIH, the hallmark is the presence of circulating autoantibodies. If ANAs are detected in female patients with DILI, the co-existence of an autoimmune disease is possible<sup>[26]</sup>.

**HLA genes and haplotypes:** Susceptibility to AIH, via a genetic predisposition, has been clearly associated with class II human leukocyte antigen (*HLA*) genes, more specifically to the DRB1 locus<sup>[44]</sup>. This is the major associated gene locus. Predisposition to AIH type I is associated with HLA-DRB1\*0301, DRB3\*0101, and DRB1\*0401 alleles in European and North-American Caucasoid, encoding the HLA-DR3, DR52 and DR4 molecules, respectively. Czaja *et al*<sup>[45]</sup> determined in 1993 the following class II HLA associations with AIH: 44% DR3, 32% DR4, 9% DR3-DR4, and 15% other antigens. The study of different geographical areas and ethnic groups revealed different results. In Japan and Argentinian Caucasoid adults, susceptibility was associated with HLA-DRB1\*1-0405 (DR4): Mexican adults presented DRB1\*0404 (DR4), and Caucasoid children and adults from Argentina presented DRB1\*1301 (DR13)<sup>[45-49]</sup>. In Brazil, the haplotype DRB1\*1301 is the most frequently

related to type 1-AIH<sup>[44]</sup>. A secondary association with HLA-DRB1\*0301 has been detected in this country<sup>[50]</sup>. Another haplotype, DRB1\*07, seems to produce susceptibility in German and Brazilian populations<sup>[51,52]</sup>. Type 2 AIH is associated with the haplotypes HLA-DRB1\*0301 and HLA-DRB1\*07<sup>[50]</sup>. Recently, Oliveira *et al*<sup>[50]</sup> searched for additional susceptibility factors in the extended MHC region. They have studied genes located in the MHC class III region, in addition to class I HLA-B and MICA genes, to verify if the specific haplotypes DRB1\*1301 or DRB1\*0301 could be involved in the susceptibility of paediatric patients in Brazil<sup>[53]</sup>. The ancestral haplotype comprising *TNFA*-308A, *TNFA*-238G, *LTA*+252G, *LTA*+80C, *NFKBIL1*-63A, *BAT1*-348C, *BAT1*-22C, *HLA-B*\*08 and *MICA*\*08 was more common in DRB1\*03 positive patients than in controls (40% *vs* 14%), showing a seven-fold increased risk of disease. Finally, a variety of class III haplotypes was also present in HLA-DRB1\*13 patients, without a predominant pattern. The most common of the 98 haplotypes present in patients were completely absent in controls. The extended haplotype analysis in this sample of AIH-1 patients highlighted not only the genetic diversity present in the Brazilian population, and was also in accordance with the previously documented microdiversity within the MHC region. The DRB1\*1501 allele may protect from disease<sup>[46]</sup>.

### Triggers

Triggers may induce AIH. AIH may be induced by drugs<sup>[12]</sup>, herbal remedies<sup>[11]</sup>, different viruses and bacteria<sup>[54-58]</sup> and vaccines<sup>[59,60]</sup>.

Exposure to all of these potential triggers may produce immune responses that especially target the liver, mainly in predisposed individuals, as we have seen previously; therefore, chronic hepatitis with autoimmune features might develop. If not recognised promptly and the responsible agent is not withdrawn, such responses can evolve to chronic hepatitis (resembling viral hepatitis) - alpha-metil dopa, halothane, hydralazine, minocycline, nitrofurantoin, and oxyphenisatin - or to a chronic non-suppurative cholangitis (resembling PBC) - chlorpromazine<sup>[1]</sup>.

Identification of these risk factors might help us to think about this disease and halt treatment with the offending trigger as soon as possible. Withdrawal of the offending agent may lead to a rapid resolution of the process.

**Genetic polymorphisms:** Several genetic polymorphisms of drug metabolising enzymes, particularly CYP, have been identified, which may produce reactive metabolites<sup>[2]</sup>. Differences in the metabolism of drugs genetically conditions may produce protein adducts and susceptibility to DI-AIH. The occurrence of more than one case within a family supports the theory that genetic factors are involved<sup>[61]</sup>. It has been shown that a familiar sensitivity to the toxic effect of the metabolites exists, which may produce an inherited defect in the defence of

**Table 2** Elements to be reported when a case of drug-induced autoimmune liver disease is suspected

|   |
|---|
| Previously obtained ANA                             |
| Evolution:  |
| During the treatment with the suspicious drug       |
| After drug withdrawal                               |
| Check for the presence of HLA-DR:                   |
| HLA-DRB1*0301,0401,07,1301                          |
| Drug type   |
| Time to onset from the beginning of the treatment   |
| AIH diagnosed:                                      |
| During the course of treatment                      |
| After withdrawal of the drug                        |
| AIH scales for diagnosis                            |
| International autoimmune hepatitis group report (4) |
| Simplified score (5)                                |
| Previous DILI episodes                              |
| Response to corticosteroids                         |
| Autoimmune titres evolution                         |
| IgG values evolution                                |

AIH: Autoimmune hepatitis; DILI: Drug-induced liver injury.

the liver from the injury produced by these toxic metabolites<sup>[2]</sup>. Anti-convulsants and sulphonamides have shown a familiar inheritance of *in vitro* lethal effects against the lymphocytes by their metabolites<sup>[62,63]</sup>.

### Sex

In AIH, there is a female sex predominance. Women are affected more frequently than men (sex ratio 3.6:1) and the disease is seen in all ethnic groups and across all age intervals<sup>[56]</sup>. Björnsson *et al*<sup>[12]</sup> published 78% (184/237) of females with AIH *vs* 92% in the DI-AIH (20/24); in the nitrofurantoin group the findings were 11/11, with numbers of 10/11 in the minocycline group. In the Spanish DILI Registry, sixteen cases out of the 742 cases (2.15%) of idiosyncratic DILI were identified<sup>[9]</sup>. There were 10/16 women. Heurgué *et al*<sup>[10]</sup> reported 8 patients with DI-AIH out of 65 AIH cases diagnosed consecutively. The female/male sex ratio was 87% *vs* 82%, revealing no statistically significant differences. Sugimoto *et al*<sup>[11]</sup> recently published a series of 7 patients with AIH that developed after a first DILI episode. Six out of the seven affected patients were women. In other smaller series, a female preponderance seems to be the general rule<sup>[32]</sup>. Czaja *et al*<sup>[16]</sup> reported that not only does DIAILD (DI-like AIH) occur almost exclusively in women, but that the drug injuries in the liver are more severe than in men<sup>[2,12,64,65]</sup>. Indeed, female sex has been found to be a risk factor for acute liver failure development after a DILI episode<sup>[25]</sup>.

### DILI

Multiple episodes of DILI in the same patient with drugs of similar structure or function as well as unrelated drugs may induce immune-related hepatotoxicity<sup>[20]</sup>. Between 1994 and 2009, Lucena *et al*<sup>[20]</sup> identified 9 patients out of 742 in the Spanish DILI Registry (1.21%), with evidence of two distinct DILI episodes produced by different drugs. In each individual, the type of injury was the same

in the two episodes, regardless of the causative drug. Second episodes were associated with features of AIH up to more than 40% (4/9) of cases, making it unclear whether this is drug-induced unmasking of true DI-AIH or IM-DILI (DILI with autoimmune features).

### Age

Elderly individuals have an increased risk of drug toxicity<sup>[16]</sup>. The risk of DILI increases with age for certain drugs, such as those that are implicated in autoimmune-like hepatitis (nitrofurantoin, halothane, and isoniazid).

### Association with other autoimmune diseases or induction by biologic agents

**Biologic agents:** Biologic agents are increasingly being used for rheumatological and systemic autoimmune diseases. The BIOGEAS project<sup>[39,40]</sup>, created by the Spanish Society of Internal medicine, has retrieved more than 800 cases of AI diseases secondary to biological therapies. In this study, 19 cases of AIH have been reported. Statins<sup>[36,37]</sup> have been reported to induce AI diseases, typically in patients with other AI diseases.

**Spontaneously:** AI diseases frequently appeared to be associated between them<sup>[36,37]</sup>. Multiple examples are published in the literature<sup>[66]</sup>.

### Drugs

Nowadays, more than 900 drugs, toxins and herbal remedies have been reported to cause liver injury. Recently, it has been reported that at least 24 drugs, probably more, have been associated with AI chronic hepatitis mimicking AIH<sup>[67]</sup>, but more and more new agents are being implicated<sup>[67-83]</sup>. With the appearance of new statins, biologic agents, and antibiotics, it will be quite normal to see more new agents being reported as being responsible for new drug-induced AIH cases (Table 3).

### Elements to be reported when a case of DIAILD is suspected

Some basic requirements are needed to consider a drug as a trigger of AIH. These basic requirements must be debated and consensuated prior to the publication of a suspected new case. The elements that we think that must be included in a suspected DIAILD case before publication are outlined in Table 2.

## CONCLUSION

DIAILD is still a poorly defined and under-reported liver disorder and is also a probably underestimated liver disorder. A small number of DILI cases exhibit features typical of AIH. To differentiate between true AIH triggered by drugs (DI-AIH) and IM-DILI still remains a challenge. Patients diagnosed with DIAILD have frequently had a previous episode of hepatotoxicity. The CIOMS scale has a limited value to ascertain causality in DIAILD. Hopefully, the collaborative efforts in DILI research will

**Table 3** Drugs and drug-induced autoimmune liver disease

|  |
|--|
| Well established drugs:  |
| Minocycline  |
| Nitrofurantoin   |
| Oxyphenisatin, alpha-methyl-dopa, clometacin.  |
| Emerging drugs:  |
| Statins  |
| Biologics agents:  |
| Infliximab   |
| Others: adalimumab, etanercept, efalizumab, ipilimumab   |
| Other drugs:   |
| Less compelling association (infrequent reports): atomoxetine, diclofenac, fenofibrate, pemoline, phenprocoumon, dihydralazine, tielinic acid, benzarone |

enhance our knowledge of this intriguing hepatic disease. We consider that some basic requirements are needed to be considered before supporting a drug as a trigger of AIH and they should be taken into account by authors, reviewers and editors when cases are published and made available to the scientific community.

## REFERENCES

- 1 **Watkins PB**, Seeff LB. Drug-induced liver injury: summary of a single topic clinical research conference. *Hepatology* 2006; **43**: 618-631 [PMID: 16496329 DOI: 10.1002/hep.21095]
- 2 **Liu ZX**, Kaplowitz N. Immune-mediated drug-induced liver disease. *Clin Liver Dis* 2002; **6**: 755-774 [PMID: 12362579 DOI: 10.1016/S1089-3261(02)00025-9]
- 3 **Seef LB**. Drug-induced autoimmune hepatitis; drugs potentially implicated. AASLD-FDA-NIH-PhRMA-Hepatotoxicity special interest group meeting. 2007 presentations. Available from: URL: <http://www.fda.gov/Drugs/ScienceResearch/ResearchAreas/ucm076641.htm>
- 4 **Alvarez F**, Berg PA, Bianchi FB, Burroughs AK, Cancado EL, Chapman RW, Cooksley WG, Czaja AJ, Desmet VJ, Donaldson PT, Eddleston AL, Fainboim L, Heathcote J, Homberg JC, Hoofnagle JH, Kakumu S, Krawitt EL, Mackay IR, MacSween RN, Maddrey WC, Manns MP, McFarlane IG, Meyer zum Büschenfelde KH, Zeniya M. International Autoimmune Hepatitis Group Report: review of criteria for diagnosis of autoimmune hepatitis. *J Hepatol* 1999; **31**: 929-938 [PMID: 10580593 DOI: 10.1016/S0168-8278(99)80297-9]
- 5 **Hennes EM**, Zeniya M, Czaja AJ, Parés A, Dalekos GN, Krawitt EL, Bittencourt PL, Porta G, Boberg KM, Hofer H, Bianchi FB, Shibata M, Schramm C, Eisenmann de Torres B, Galle PR, McFarlane I, Dienes HP, Lohse AW. Simplified criteria for the diagnosis of autoimmune hepatitis. *Hepatology* 2008; **48**: 169-176 [PMID: 18537184 DOI: 10.1002/hep.22322]
- 6 **Alla V**, Abraham J, Siddiqui J, Raina D, Wu GY, Chalasani NP, Bonkovsky HL. Autoimmune hepatitis triggered by statins. *J Clin Gastroenterol* 2006; **40**: 757-761 [PMID: 16940892 DOI: 10.1097/00004836-200609000-00018]
- 7 **Grasset L**, Guy C, Ollagnier M. Cycles and acne: pay attention to adverse drug reactions! A recent literature review. *Rev Med Interne* 2003; **24**: 305-316 [PMID: 12763176 DOI: 10.1016/S0248-8663(02)00017-6]
- 8 **Vierling JM**. Autoimmune hepatitis and drugs. AASLD-FDA-NIH-PhRMA-Hepatotoxicity special interest group meeting. 2007 presentations. Available from: URL: <http://www.fda.gov/Drugs/ScienceResearch/ResearchAreas/ucm076635.htm>
- 9 **Castiella A**, Zapata E, Lucena E. Hepatotoxicity with autoimmune features. Analysis of the cases included in the Spanish Dili registry. *Basic Clin Pharmacol Toxicol* 2011; **109** (Suppl 3): 53 (abstract)
- 10 **Heurgué A**, Bernard-Chabert B, Diebold M, Vitry F, Louvet H, Geoffroy P. Drug-induced autoimmune hepatitis: a frequent disorder. *Gut* 2007; **56** (Suppl III): A271
- 11 **Sugimoto K**, Ito T, Yamamoto N, Shiraki K. Seven cases of autoimmune hepatitis that developed after drug-induced liver injury. *Hepatology* 2011; **54**: 1892-1893 [PMID: 21725992 DOI: 10.1002/hep.24513]
- 12 **Björnsson E**, Talwalkar J, Treeprasertsuk S, Kamath PS, Takahashi N, Sanderson S, Neuhauser M, Lindor K. Drug-induced autoimmune hepatitis: clinical characteristics and prognosis. *Hepatology* 2010; **51**: 2040-2048 [PMID: 20512992 DOI: 10.1002/hep.23588]
- 13 **Zapata E**, Castiella A, Otazua P. Hepatitis autoimmune en Gipuzkoa, País Vasco: epidemiología, índices diagnósticos e impacto de la edad en la histología. *Rev Esp Enferm Digest* 2011; **103** (Suppl I): 137-138
- 14 **Licata A**, Butera G, Macaluso FS, Cabibi D, Craxi A, Almasio PL. Clinical features and outcomes of patients with drug-induced autoimmune hepatitis. *Dig Liver Dis* 2012; **44** (Suppl 1): S12 [DOI: 10.1016/S1590-8658(12)60035-8]
- 15 **Castiella A**, Lucena MI, Zapata EM, Otazua P, Andrade RJ. Drug-induced autoimmune-like hepatitis: a diagnostic challenge. *Dig Dis Sci* 2011; **56**: 2501-252; author reply 2501-2502 [PMID: 21674172 DOI: 10.1007/s10620-011-1787-7]
- 16 **Czaja AJ**. Drug-induced autoimmune-like hepatitis. *Dig Dis Sci* 2011; **56**: 958-976 [PMID: 21327704 DOI: 10.1007/s10620-011-1611-4]
- 17 **Suzuki A**, Brunt EM, Kleiner DE, Miquel R, Smyrk TC, Andrade RJ, Lucena MI, Castiella A, Lindor K, Björnsson E. The use of liver biopsy evaluation in discrimination of idiopathic autoimmune hepatitis versus drug-induced liver injury. *Hepatology* 2011; **54**: 931-939 [PMID: 21674554 DOI: 10.1002/hep.24481]
- 18 **Weiler-Normann C**, Schramm C. Drug induced liver injury and its relationship to autoimmune hepatitis. *J Hepatol* 2011; **55**: 747-749 [PMID: 21396413 DOI: 10.1016/j.jhep.2011.02.024]
- 19 **Lucena MI**, Molokhia M, Shen Y, Urban TJ, Aithal GP, Andrade RJ, Day CP, Ruiz-Cabello F, Donaldson PT, Stephens C, Pirmohamed M, Romero-Gomez M, Navarro JM, Fontana RJ, Miller M, Groome M, Bondon-Guitton E, Conforti A, Stricker BH, Carvajal A, Ibanez L, Yue QY, Eichelbaum M, Floratos A, Pe'er I, Daly MJ, Goldstein DB, Dillon JF, Nelson MR, Watkins PB, Daly AK. Susceptibility to amoxicillin-clavulanate-induced liver injury is influenced by multiple HLA class I and II alleles. *Gastroenterology* 2011; **141**: 338-347 [PMID: 21570397 DOI: 10.1053/j.gastro.2011.04.001]
- 20 **Lucena MI**, Kaplowitz N, Hallal H, Castiella A, García-Benagoechea M, Otazua P, Berenguer M, Fernandez MC, Planas R, Andrade RJ. Recurrent drug-induced liver injury (DILI) with different drugs in the Spanish Registry: the dilemma of the relationship to autoimmune hepatitis. *J Hepatol* 2011; **55**: 820-827 [PMID: 21338638 DOI: 10.1016/j.jhep.2010.12.041]
- 21 **Egiguren L**, Minondo L, Zapata E, Castiella A. [Patient with autoimmune hepatitis and idiopathic thrombocytopenic purpura after minocycline therapy]. *Gastroenterol Hepatol* 2007; **30**: 565-566 [PMID: 17980139]
- 22 **Heurgué-Berlot A**, Bernard-Chabert B, Diebold MD, Thiéfin G. Drug-induced autoimmune-like hepatitis: a case of chronic course after drug withdrawal. *Dig Dis Sci* 2011; **56**: 2504-2505; author reply 2505 [PMID: 21698369 DOI: 10.1007/s10620-011-1786-8]
- 23 **Maiz B**, Odriozola M, Blanco A, Fernández J, Castiella A. [Autoimmune hepatitis in a patient with uveitis]. *Gastroenterol Hepatol* 2005; **28**: 656-657 [PMID: 16373020 DOI: 10.1016/S0210-5705(05)71534-X]
- 24 **Romanelli RG**, Almerigogna F. Uveitis as a presenting feature of autoimmune hepatitis. *Am J Ophthalmol* 2009; **148**: 318-319; author reply 319-320 [PMID: 19619722 DOI: 10.1016/j.ajo.2009.05.002]



- 25 **Andrade RJ**, Lucena MI, Fernández MC, Pelaez G, Pachkoria K, García-Ruiz E, García-Muñoz B, González-Grande R, Pizarro A, Durán JA, Jiménez M, Rodrigo L, Romero-Gomez M, Navarro JM, Planas R, Costa J, Borrás A, Soler A, Salmerón J, Martín-Vivaldi R. Drug-induced liver injury: an analysis of 461 incidences submitted to the Spanish registry over a 10-year period. *Gastroenterology* 2005; **129**: 512-521 [PMID: 16083708]
- 26 **Ohmoto K**, Yamamoto S. Drug-induced liver injury associated with antinuclear antibodies. *Scand J Gastroenterol* 2002; **37**: 1345-1346 [PMID: 12465739 DOI: 10.1080/003655202761020687]
- 27 **Hinrichsen H**, Lüttges J, Klöppel G, Fölsch UR, Schmidt WE. Idiosyncratic drug allergic phenprocoumon-induced hepatitis with subacute liver failure initially misdiagnosed as autoimmune hepatitis. *Scand J Gastroenterol* 2001; **36**: 780-783 [PMID: 11444480 DOI: 10.1080/003655201300192076]
- 28 **Bessone F**, Hernandez N, Sanchez A. The Spanish-latin American DILI network: preliminary results from a collaborative strategic initiative. *J Hepatol* 2012; **58** (Suppl 1): S212-S213 [DOI: 10.1016/S0168-8278(13)60520-6]
- 29 **Andrade RJ**, Medina-Cáliz I, Stephens C. La hepatotoxicidad recurrente se asocia frecuentemente a manifestaciones de autoinmunidad. *Gastroenterol Hepatol* 2013; **36** (Espec Congre 1): 84
- 30 **Ramachandran R**, Kakar S. Histological patterns in drug-induced liver disease. *J Clin Pathol* 2009; **62**: 481-492 [PMID: 19474352 DOI: 10.1136/jcp.2008.058248]
- 31 **Heurgué A**, Vitry F, Diebold MD, Yaziji N, Bernard-Chabert B, Pennaforte JL, Picot R, Louvet H, Frémond L, Geoffroy P, Schmit JL, Cadiot G, Thiéfin G. Overlap syndrome of primary biliary cirrhosis and autoimmune hepatitis: a retrospective study of 115 cases of autoimmune liver disease. *Gastroenterol Clin Biol* 2007; **31**: 17-25 [PMID: 17273128 DOI: 10.1016/S0399-8320(07)89323-7]
- 32 **Appleyard S**, Saraswati R, Gorard DA. Autoimmune hepatitis triggered by nitrofurantoin: a case series. *J Med Case Rep* 2010; **4**: 311 [PMID: 20863377 DOI: 10.1186/1752-1947-4-311]
- 33 **Ju HY**, Jang JY, Jeong SW, Woo SA, Kong MG, Jang HY, Lee SH, Kim SG, Cha SW, Kim YS, Cho YD, Jin SY, Kim HS, Kim BS. The clinical features of drug-induced liver injury observed through liver biopsy: focus on relevancy to autoimmune hepatitis. *Clin Mol Hepatol* 2012; **18**: 213-218 [PMID: 22893872 DOI: 10.3350/cmh.2012.18.2.213]
- 34 **Danan G**, Benichou C. Causality assessment of adverse reactions to drugs--I. A novel method based on the conclusions of international consensus meetings: application to drug-induced liver injuries. *J Clin Epidemiol* 1993; **46**: 1323-1330 [PMID: 8229110 DOI: 10.1016/0895-4356(93)90101-6]
- 35 **Lucena MI**, Camargo R, Andrade RJ, Perez-Sanchez CJ, Sanchez De La Cuesta F. Comparison of two clinical scales for causality assessment in hepatotoxicity. *Hepatology* 2001; **33**: 123-130 [PMID: 11124828 DOI: 10.1053/jhep.2001.20645]
- 36 **Noël B**. Autoimmune disease and other potential side-effects of statins. *Lancet* 2004; **363**: 2000 [PMID: 15194268]
- 37 **Noël B**. Lupus erythematosus and other autoimmune diseases related to statin therapy: a systematic review. *J Eur Acad Dermatol Venereol* 2007; **21**: 17-24 [PMID: 17207162 DOI: 10.1111/j.1468-3083.2006.01838.x]
- 38 **Russo MW**, Scobey M, Bonkovsky HL. Drug-induced liver injury associated with statins. *Semin Liver Dis* 2009; **29**: 412-422 [PMID: 19826975 DOI: 10.1055/s-0029-1240010]
- 39 **Ramos-Casals M**, Roberto-Perez-Alvarez C, Cuadrado MJ, Khamashta MA. Autoimmune diseases induced by biological agents: a double-edged sword? *Autoimmun Rev* 2010; **9**: 188-193 [PMID: 19854301 DOI: 10.1016/j.autrev.2009.10.003]
- 40 **Ramos-Casals M**, Brito-Zerón P, Soto MJ, Cuadrado MJ, Khamashta MA. Autoimmune diseases induced by TNF-targeted therapies. *Best Pract Res Clin Rheumatol* 2008; **22**: 847-861 [PMID: 19028367 DOI: 10.1016/j.berh.2008.09.008]
- 41 **Thiéfin G**, Morelet A, Heurgué A, Diebold MD, Eschard JP. Infliximab-induced hepatitis: absence of cross-toxicity with etanercept. *Joint Bone Spine* 2008; **75**: 737-739 [PMID: 18693125 DOI: 10.1016/j.jbspin.2007.12.009]
- 42 **Toscano E**, Cotta J, Robles M, Lucena MA, Andrade RJ. [Hepatotoxicity induced by new immunosuppressants]. *Gastroenterol Hepatol* 2010; **33**: 54-65 [PMID: 19889479 DOI: 10.1016/j.gastrohep.2009.07.003]
- 43 **Harel M**, Shoenfeld Y. Predicting and preventing autoimmunity, myth or reality? *Ann N Y Acad Sci* 2006; **1069**: 322-345 [PMID: 16855160 DOI: 10.1196/annals.1351.031]
- 44 **Goldberg AC**, Bittencourt PL, Mougin B, Cançado EL, Porta G, Carrilho F, Kalil J. Analysis of HLA haplotypes in autoimmune hepatitis type 1: identifying the major susceptibility locus. *Hum Immunol* 2001; **62**: 165-169 [PMID: 11182227 DOI: 10.1016/S0198-8859(00)00234-2]
- 45 **Czaja AJ**, Carpenter HA, Santrach PJ, Moore SB. Genetic predispositions for the immunological features of chronic active hepatitis. *Hepatology* 1993; **18**: 816-822 [PMID: 8406354 DOI: 10.1002/hep.1840180411]
- 46 **Czaja AJ**, Strettell MD, Thomson LJ, Santrach PJ, Moore SB, Donaldson PT, Williams R. Associations between alleles of the major histocompatibility complex and type 1 autoimmune hepatitis. *Hepatology* 1997; **25**: 317-323 [PMID: 9021941 DOI: 10.1002/hep.510250211]
- 47 **Seki T**, Ota M, Furuta S, Fukushima H, Kondo T, Hino K, Mizuki N, Ando A, Tsuji K, Inoko H. HLA class II molecules and autoimmune hepatitis susceptibility in Japanese patients. *Gastroenterology* 1992; **103**: 1041-1047 [PMID: 1354193]
- 48 **Fainboim L**, Marcos Y, Pando M, Capucchio M, Reyes GB, Galoppo C, Badía I, Remondino G, Ciocca M, Ramonet M. Chronic active autoimmune hepatitis in children. Strong association with a particular HLA-DR6 (DRB1\*1301) haplotype. *Hum Immunol* 1994; **41**: 146-150 [PMID: 7860360 DOI: 10.1016/0198-8859(94)90008-6]
- 49 **Fainboim L**, Pando M, Larriba J. HLA and autoimmune hepatitis. In: Charron EDK (ed). Proceedings of the 12th IHWC "Genetic diversity of HLA: Functional and Medival implications". Paris, 1997
- 50 **Oliveira LC**, Porta G, Marin ML, Bittencourt PL, Kalil J, Goldberg AC. Autoimmune hepatitis, HLA and extended haplotypes. *Autoimmun Rev* 2011; **10**: 189-193 [PMID: 20933106 DOI: 10.1016/j.autrev.2010.09.024]
- 51 **Manns M**, Scheucher S, Jentzsch M. Genetics in autoimmune hepatitis type 2 (abstr). *Hepatology* 1991; **14**: 60
- 52 **Czaja AJ**, Kruger M, Santrach PJ, Moore SB, Manns MP. Genetic distinctions between types 1 and 2 autoimmune hepatitis. *Am J Gastroenterol* 1997; **92**: 2197-2200 [PMID: 9399751]
- 53 **Goldberg AC**, Bittencourt PL, Oliveira LC, Ramasawmy R, Marin ML, Palacios SA, Kalil J, Porta G. Autoimmune hepatitis in Brazil: an overview. *Scand J Immunol* 2007; **66**: 208-216 [PMID: 17635798 DOI: 10.1111/j.1365-3083.2007.01967.x]
- 54 **Huppertz HI**, Treichel U, Gassel AM, Jeschke R, Meyer zum Büschenfelde KH. Autoimmune hepatitis following hepatitis A virus infection. *J Hepatol* 1995; **23**: 204-208 [PMID: 7499793 DOI: 10.1016/0168-8278(95)80336-X]
- 55 **Laskus T**, Slusarczyk J. Autoimmune chronic active hepatitis developing after acute type B hepatitis. *Dig Dis Sci* 1989; **34**: 1294-1297 [PMID: 2752878 DOI: 10.1007/BF01537282]
- 56 **Vento S**, Guella L, Mirandola F, Cainelli F, Di Perri G, Solbiati M, Ferraro T, Concia E. Epstein-Barr virus as a trigger for autoimmune hepatitis in susceptible individuals. *Lancet* 1995; **346**: 608-609 [PMID: 7651006 DOI: 10.1016/S0140-6736(95)91438-2]
- 57 **Castellote J**, Güell E, Porta F. [Autoimmune hepatitis following cytomegalovirus infection]. *Med Clin (Barc)* 2001; **117**: 76 [PMID: 11446931 DOI: 10.1016/S0025-7753(01)72016-7]
- 58 **Kaech C**, Pache I, Raoult D, Greub G. Coxiella burnetii as a possible cause of autoimmune liver disease: a case report. *J Med Case Rep* 2009; **3**: 8870 [PMID: 19830243 DOI: 10.4076/1752-1947-3-8870]
- 59 **Della Corte C**, Carlucci A, Francalanci P, Alisi A, Nobili V.



- Autoimmune hepatitis type 2 following anti-papillomavirus vaccination in a 11-year-old girl. *Vaccine* 2011; **29**: 4654-4656 [PMID: 21596082 DOI: 10.1016/j.vaccine.2011.05.002]
- 60 **Perumalswami P**, Peng L, Odin JA. Vaccination as a triggering event for autoimmune hepatitis. *Semin Liver Dis* 2009; **29**: 331-334 [PMID: 19676005 DOI: 10.1055/s-0029-1233537]
  - 61 **Larrey D**, Pageaux GP. Genetic predisposition to drug-induced hepatotoxicity. *J Hepatol* 1997; **26** Suppl 2: 12-21 [PMID: 9204405 DOI: 10.1016/S0168-8278(97)80492-8]
  - 62 **Shear NH**, Spielberg SP. Anticonvulsant hypersensitivity syndrome. In vitro assessment of risk. *J Clin Invest* 1988; **82**: 1826-1832 [PMID: 3198757 DOI: 10.1172/JCI113798]
  - 63 **Rieder MJ**, Uetrecht J, Shear NH, Cannon M, Miller M, Spielberg SP. Diagnosis of sulfoamide hypersensitivity reactions by "in Vitro" rechallenge with hydroxylamine metabolites. *Ann Intern Med* 1989; **110**: 286-289 [PMID: 2913915 DOI: 10.7326/0003-4819-110-4-286]
  - 64 **Manns MP**, Czaja AJ, Gorham JD, Krawitt EL, Mieli-Vergani G, Vergani D, Vierling JM. Diagnosis and management of autoimmune hepatitis. *Hepatology* 2010; **51**: 2193-2213 [PMID: 20513004 DOI: 10.1002/hep.23584]
  - 65 **Chalasani N**, Björnsson E. Risk factors for idiosyncratic drug-induced liver injury. *Gastroenterology* 2010; **138**: 2246-2259 [PMID: 20394749 DOI: 10.1053/j.gastro.2010.04.001]
  - 66 **Mancini S**, Amorotti E, Vecchio S, Ponz de Leon M, Roncucci L. Infliximab-related hepatitis: discussion of a case and review of the literature. *Intern Emerg Med* 2010; **5**: 193-200 [PMID: 20107930 DOI: 10.1007/s11739-009-0342-4]
  - 67 **Etxagibel A**, Julià MR, Brotons A, Company MM, Dolz C. Drug-induced hepatitis superimposed on the presence of anti-SLA antibody: a case report. *J Med Case Rep* 2008; **2**: 25 [PMID: 18226219 DOI: 10.1186/1752-1947-2-25]
  - 68 **García-Cortés M**, Borraz Y, Lucena MI, Peláez G, Salmerón J, Diago M, Martínez-Sierra MC, Navarro JM, Planas R, Soria MJ, Bruguera M, Andrade RJ. Liver injury induced by "natural remedies": an analysis of cases submitted to the Spanish Liver Toxicity Registry. *Rev Esp Enferm Dig* 2008; **100**: 688-695 [PMID: 19159172]
  - 69 **Charier F**, Chagneau-Derrode C, Levillain P, Guilhot F, Silvain C. [Glivec induced autoimmune hepatitis]. *Gastroenterol Clin Biol* 2009; **33**: 982-984 [PMID: 19765927 DOI: 10.1016/j.gcb.2009.07.034]
  - 70 **Primo J**, Michavila J, Jiménez I. Efalizumab-induced autoimmune hepatitis. *Gastroenterol Hepatol* 2010; **33**: 69-70 [PMID: 19800148 DOI: 10.1016/j.gastrohep.2009.07.005]
  - 71 **Adar T**, Mizrahi M, Pappo O, Scheiman-Elazary A, Shibolet O. Adalimumab-induced autoimmune hepatitis. *J Clin Gastroenterol* 2010; **44**: e20-e22 [PMID: 19593165 DOI: 10.1097/MCG.0b013e3181a745e7]
  - 72 **Humayun F**, Shehab TM, Tworek JA, Fontana RJ. A fatal case of bupropion (Zyban) hepatotoxicity with autoimmune features: Case report. *J Med Case Rep* 2007; **1**: 88 [PMID: 17877816 DOI: 10.1186/1752-1947-1-88]
  - 73 **Harada K**, Akai Y, Koyama S, Ikenaka Y, Saito Y. A case of autoimmune hepatitis exacerbated by the administration of etanercept in the patient with rheumatoid arthritis. *Clin Rheumatol* 2008; **27**: 1063-1066 [PMID: 18563514 DOI: 10.1007/s10067-008-0885-1]
  - 74 **Fathalla BM**, Goldsmith DP, Pascasio JM, Baldrige A. Development of autoimmune hepatitis in a child with systemic-onset juvenile idiopathic arthritis during therapy with etanercept. *J Clin Rheumatol* 2008; **14**: 297-298 [PMID: 18824922 DOI: 10.1097/RHU.0b013e318188b1df]
  - 75 **Cueto R**, Valdivieso P, Lucena MI, Garcia-Arias C, Andrade RJ, Gonzalez-Santos P. Statins: hepatic disease and hepatotoxicity risk. *Open Gastroenterol J* 2008; **2**: 18-23 [DOI: 10.2174/1874259900802010018]
  - 76 **de Denus S**, Spinler SA, Miller K, Peterson AM. Statins and liver toxicity: a meta-analysis. *Pharmacotherapy* 2004; **24**: 584-591 [PMID: 15162892 DOI: 10.1592/phco.24.6.584.34738]
  - 77 **Cravo M**, Silva R, Serrano M. Autoimmune hepatitis induced by infliximab in a patient with Crohn's disease with no relapse after switching to adalimumab. *BioDrugs* 2010; **24** Suppl 1: 25-27 [PMID: 21175232 DOI: 10.2165/11586210-000000000-00000]
  - 78 **Carlsen KM**, Riis L, Madsen OR. Toxic hepatitis induced by infliximab in a patient with rheumatoid arthritis with no relapse after switching to etanercept. *Clin Rheumatol* 2009; **28**: 1001-1003 [PMID: 19370307 DOI: 10.1007/s10067-009-1179-y]
  - 79 **Khanna M**, Shirodkar MA, Gottlieb AB. Etanercept therapy in patients with autoimmunity and hepatitis C. *J Dermatolog Treat* 2003; **14**: 229-232 [PMID: 14660270 DOI: 10.1080/0954630310020470]
  - 80 **Goldenberg G**, Jorizzo JL. Use of etanercept in treatment of pyoderma gangrenosum in a patient with autoimmune hepatitis. *J Dermatolog Treat* 2005; **16**: 347-349 [PMID: 16428159 DOI: 10.1080/09546630500424722]
  - 81 **Kleiner DE**, Berman D. Pathologic changes in ipilimumab-related hepatitis in patients with metastatic melanoma. *Dig Dis Sci* 2012; **57**: 2233-2240 [PMID: 22434096 DOI: 10.1007/s10620-012-2140-5]
  - 82 **Efe C**. Drug induced autoimmune hepatitis and TNF- $\alpha$  blocking agents: is there a real relationship? *Autoimmun Rev* 2013; **12**: 337-339 [PMID: 22841985 DOI: 10.1016/j.autrev.2012.03.010]
  - 83 **Ghabril M**, Bonkovsky HL, Kum C, Davern T, Hayashi PH, Kleiner DE, Serrano J, Rochon J, Fontana RJ, Bonacini M. Liver injury from tumor necrosis factor- $\alpha$  antagonists: analysis of thirty-four cases. *Clin Gastroenterol Hepatol* 2013; **11**: 558-564.e3 [PMID: 23333219 DOI: 10.1016/j.cgh.2012.12.025]

P- Reviewers: Frider B, Komatsu H S- Editor: Ma YJ

L- Editor: A E- Editor: Wu HL



## Lipid lowering effects of iodothyronines: *In vivo* and *in vitro* studies on rat liver

Laura Vergani

Laura Vergani, Dipartimento di Scienze della Terra, dell'Ambiente e della Vita, Università degli Studi di Genova, 16132 Genova, Italy

Author contributions: Vergani L solely contributed to this paper. Correspondence to: Laura Vergani, PhD, Assistant Professor, Dipartimento di Scienze della Terra, dell'Ambiente e della Vita, Università degli Studi di Genova, DISTAV, Corso Europa 26, 16132 Genova, Italy. [laura.vergani@unige.it](mailto:laura.vergani@unige.it)

Telephone: +39-10-3538403 Fax: +39-10-3538403

Received: October 28, 2013 Revised: December 22, 2013

Accepted: January 17, 2014

Published online: April 27, 2014

### Abstract

Non-alcoholic fatty liver disease (NAFLD) is emerging as one of the most common liver diseases, leading to the increasing interest for new therapeutic approaches for its treatment. NAFLD primarily depends on a hypercaloric and/or unbalanced diet leading to overweight and obesity. The liver, in fact, plays a central role in lipid metabolism by importing free fatty acids from the blood and synthesizing, storing, oxidizing and exporting lipids. Furthermore, the liver is the target for the thyroid hormones, thyroxine (T<sub>4</sub>) and 3,3',5-triiodo-L-thyronine (T<sub>3</sub>), that stimulate the basal metabolic rate and lead to body weight loss. In the last decade, other iodothyronines have been shown to possess biological relevance and play some thyromimetic activities; in particular, 3,5-diiodo-L-thyronine (T<sub>2</sub>) gained large interest. The global effect of iodothyronines on liver lipid metabolism results from the balance between direct and indirect actions on the hepatocyte, leading to stimulation of lipid synthesis, oxidation and autophagy. In this review, the results so far obtained on both *in vivo* and *in vitro* models of hepatosteatosis are summarized in order to obtain an updated picture of the lipid-lowering effects of iodothyronines on mammalian liver.

© 2014 Baishideng Publishing Group Co., Limited. All rights reserved.

**Key words:** Iodothyronines; Liver steatosis; Lipid metabolism; Non-alcoholic fatty liver disease; Hepatocytes

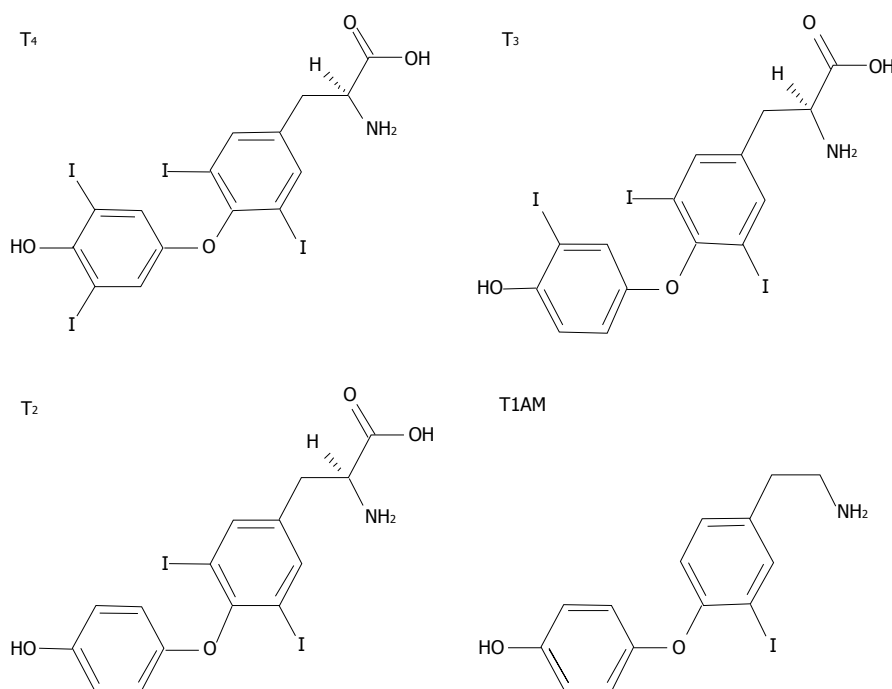
**Core tip:** This review summarizes the recent insights about the mechanisms underlying the lipid lowering action of iodothyronines. In the last decades, extensive studies investigated the possible use of iodothyronines in the treatment of obesity and dysmetabolic syndromes. Since the pharmacological use of thyroid hormones has found severe limitations because of their thyrotoxic effects, the identification of iodothyronines retaining anti-obesity and hypolipemic efficacies, while being devoid of thyrotoxicity, gained great interest. The review discusses the recent studies employing both *in vivo* and *in vitro* models of hepatosteatosis, with particular attention to the *in vitro* studies demonstrating the direct anti-steatotic effect of iodothyronines.

Vergani L. Lipid lowering effects of iodothyronines: *In vivo* and *in vitro* studies on rat liver. *World J Hepatol* 2014; 6(4): 169-177 Available from: URL: <http://www.wjgnet.com/1948-5182/full/v6/i4/169.htm> DOI: <http://dx.doi.org/10.4254/wjh.v6.i4.169>

### IODOTHYRONINES AND METABOLISM

Thyroid hormones (THs) secreted by the thyroid gland comprise two main iodothyronines: 3,5,3',5'-tetraiodo-thyronine (thyroxine or T<sub>4</sub>) and 3,5,3'-triiodo-L-thyronine (T<sub>3</sub>) (Figure 1). T<sub>4</sub> is the major form secreted by the thyroid and the most abundant TH in circulation, while T<sub>3</sub>, the active form, is mainly generated by peripheral deiodination of T<sub>4</sub>. T<sub>3</sub> may be further deiodinated to yield different diiodothyronines such as 3,5-diiodo-L-thyronine (T<sub>2</sub>) (Figure 1). In the past, T<sub>3</sub> was assumed to be the only active iodothyronine *in vivo*, but recent evidence suggested that other iodothyronines, such as 3',5',3-l-triiodo-thyronine (rT<sub>3</sub>) and T<sub>2</sub> may be of biological relevance<sup>[1,2]</sup>.

THs influence a large number of physiological pro-



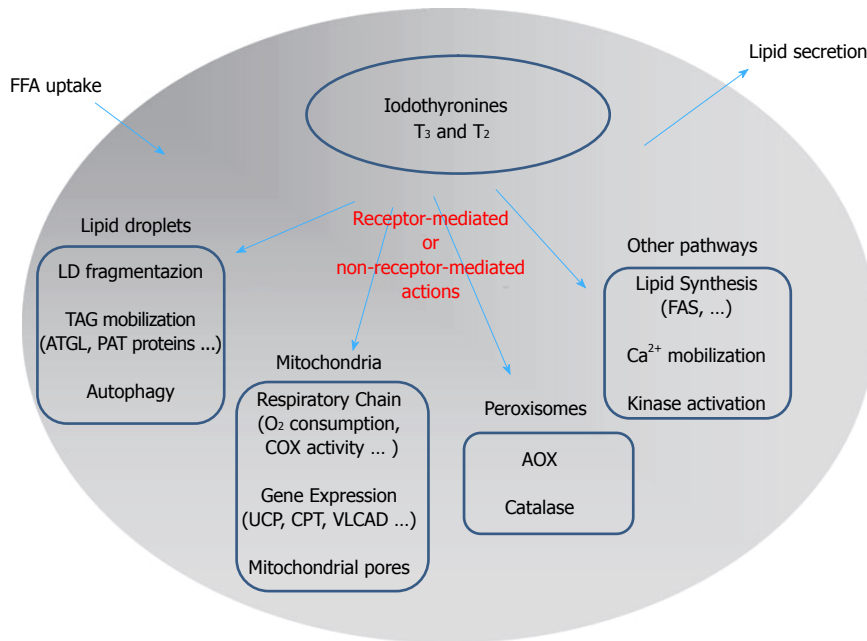
**Figure 1** The chemical structures of three biologically active iodothyronines and one derivative: thyroxine, 3,3',5-triiodothyronine, 3,5-diiodothyronine and 3-iodothyronamine. T<sub>4</sub>: Thyroxine; T<sub>3</sub>: 3,3',5-triiodothyronine; T<sub>2</sub>: 3,5-diiodothyronine; T<sub>1AM</sub>: 3-iodothyronamine.

cesses in vertebrates, including growth, development and differentiation. THs have stimulatory effects on metabolic activity, thus inducing thermogenesis (the so-called calorogenic effect) that represents a major component of the energy expenditure in endotherms. Of particular interest is the effect of THs on lipid metabolism resulting from the balance between stimulation of lipid synthesis and lipid oxidation (Figure 2). The liver represents one of the main target tissues of THs. At the hepatic level, T<sub>3</sub> stimulates cholesterol synthesis and its metabolism into bile acids<sup>[3]</sup> and cholesterol uptake<sup>[4]</sup>, and it induces lipogenic enzymes, including fatty acid synthase (FAS) and acetyl-CoA-carboxylase<sup>[5]</sup>. In addition to the lipogenic action, T<sub>3</sub> also leads to a general reduction in the hepatic triglyceride (TAG) content, likely through stimulation of lipolytic pathways<sup>[6]</sup>. Moreover, it has been suggested that TH-stimulated lipogenesis/lipolysis “futile” cycle may contribute to the calorogenic effect<sup>[7]</sup>.

The metabolic effects of iodothyronines have long been investigated because of their potential use as drugs to treat obesity and lipid metabolism disorders<sup>[8]</sup>. However, due to the simultaneous undesirable side effects, such as the induction of a thyrotoxic state (tachycardia, muscle wasting, bone loss), the employment of T<sub>3</sub> or T<sub>4</sub> to stimulate body weight loss or treat metabolic syndrome has been limited. At the same time, the development of TH agonists/analogs retaining lipid-lowering and anti-obesity efficacies, while being devoid of thyrotoxic effects, has received great interest as a potential therapeutic advancement. The research of the last years has identified several iodothyronines other than T<sub>3</sub> and T<sub>4</sub> that display some thyromimetic activities. Among them, T<sub>2</sub> assumed a great interest as it mimics several effects of T<sub>3</sub> on energy

metabolism<sup>[9-11]</sup> without inducing thyrotoxic effects<sup>[12]</sup>. A single dose of T<sub>2</sub> (25 µg/100 g body wt) stimulated the resting metabolic rate (RMR) of hypothyroid rats and increased the liver oxidative capacity to the same extent as the same dose of T<sub>3</sub><sup>[13]</sup>. Moreover, T<sub>2</sub> significantly reduced serum triglyceride and cholesterol levels and increased liver oxygen consumption<sup>[10]</sup>.

With regards to the calorogenic effects of THs, several cellular targets have been proposed but none has received universal acceptance. By virtue of their central role in the energy-transduction pathway, mitochondria are natural candidates to mediate the calorogenic activity of iodothyronines<sup>[14]</sup>. Single injections of T<sub>2</sub> or T<sub>3</sub> into hypothyroid rats stimulated RMR<sup>[15]</sup>, in association with an increase in oxygen consumption<sup>[16]</sup>. It is widely accepted that iodothyronines may exert two kinds of effects on mitochondria: (1) a rapid stimulation of respiration (within minutes/hours); and (2) a long term effect leading to mitochondrial biogenesis and mitochondrial mass increase. The calorogenic activity of THs has long been ascribed to uncoupling of mitochondrial oxidative phosphorylation, but the mode by which they promote mitochondrial proton leak is still unresolved. Harper *et al*<sup>[17]</sup> related the T<sub>3</sub>-induced increase in mitochondrial proton leak to an increased permeability of the phospholipid bilayer due to a change in the lipid composition of the inner mitochondrial membrane. On the other hand, T<sub>2</sub>, and to a lesser extent T<sub>3</sub>, was shown to bind the Va subunit of the cytochrome oxidase complex, thus abolishing the allosteric inhibition due to ATP binding and stimulating enzyme activity<sup>[18]</sup>. Recently, Yehuda-Shnaidman *et al*<sup>[19]</sup> reported that mitochondrial uncoupling by T<sub>3</sub> was transduced both *in vivo* (in rats) and *in vitro* (Jurkat cells) by gating of the



**Figure 2** Schematic representation of the mechanisms underlying the control of lipid metabolism by iodothyronines in the hepatic cell: A summary of the possible signaling pathways involved in iodothyronine actions is presented. The classic “receptor-mediated” pathway describes the action of iodothyronines through the thyroid hormone receptors (TR). The “non receptor-mediated” pathway occurs through the interaction of iodothyronines with different cellular targets. FFA: Free fatty acids; LD: Lipid droplet; AOX: Acyl-CoA oxidase; ATGL: Adipose triglyceride lipase; CPT: Carnitine palmitoyl-transferase 1; FAS: fatty acid synthase.

mitochondrial permeability transition pore.

Interestingly, T<sub>2</sub> administration has been demonstrated to be able to stimulate RMR and to also reduce body weight in humans. In a pilot study, two euthyroid subjects were treated with increasing doses of T<sub>2</sub> (from 100 to 900 mcg/d, three times a day for 8 d) and for a further 3 weeks with 3000 mcg/d. A reduction in body weight of -4% was observed without effects at the cardiac level<sup>[20]</sup>.

The pharmacological effects of some derivatives of thyronines called thyronamines have been also investigated. Scanlan *et al*<sup>[21]</sup> described the synthesis and biological properties of 3-iodothyronamine (T1AM), a novel thyronamine that was shown to be an endogenous component of biogenic amine extracts from rodents. T1AM has a carbon skeleton identical to that of T<sub>4</sub> and theoretically, it could be produced from T<sub>4</sub> by enzymatic decarboxylation and deiodination (Figure 1). T1AM treatment rapidly induced a hypometabolic state and hypothermia in rodents, with opposite effects compared with those typical of THs.

## MECHANISMS OF ACTION OF IODOTHYRONINES

In the past, it was a common notion that TH actions were mediated by specific nuclear thyroid hormone receptors (TRs) acting as ligand-dependent transcription factors binding the “thyroid hormone response elements” (TREs) on the promoter region of thyroid hormone-responsive genes<sup>[22]</sup>. In the early 1960s, Tata and co-workers provided the first evidence for a “receptor-mediated” mechanism of T<sub>3</sub> action on energy metabolism<sup>[23]</sup>. In the 1980s, two distinct genes, *THRA* and *THRB*, were iden-

tified in humans and rodents, each encoding a different TR isoform (TR $\alpha$  and TR $\beta$ , respectively). The *THRA* gene was originally identified in chicken<sup>[24]</sup>, while *THRB* was cloned from human and rat cDNA libraries<sup>[25]</sup>. Each isoform shows alternative splice variants (TR $\alpha$ 1, TR $\alpha$ 2, TR $\beta$ 1 and TR $\beta$ 2) with specific and distinct functions and tissue localization.

Although the “receptor-mediated” mechanism accounts for several actions of THs, other effects independent of TRs have been described, suggesting an alternative model for their action. Effects of iodothyronines that are not initiated by binding to TRs are termed ‘non-receptor-mediated’ mechanisms<sup>[26]</sup> and could involve a multiplicity of signaling pathways, such as phosphorylation of effector proteins<sup>[27]</sup>, binding to surface receptors<sup>[28]</sup>, Ca<sup>2+</sup> mobilization<sup>[29]</sup>, alteration of mRNA stability<sup>[30]</sup>, modification of membrane fluidity and permeability<sup>[2]</sup>. The possibility that TH action was mediated by interactions with membrane surface receptors was confirmed by using cell impermeant agarose-conjugated T<sub>3</sub>. The results clearly indicated that both free and conjugated hormones led to activation of extracellular signal-regulated kinase (ERK1/2s)<sup>[31]</sup> and affected Ca<sup>2+</sup> homeostasis<sup>[32]</sup>. Moreover, THs were shown to interact with the  $\alpha$ V $\beta$ 3 integrin receptor triggering the ERK1/2 pathway<sup>[33]</sup>. Although the “non-receptor mediated” effects are sometimes called “non-genomic”, this term is rather confusing as these pathways may also in turn affect gene transcription<sup>[34]</sup>.

In conclusion, it is now widely accepted that TH effects may result from a synergism between “receptor-mediated” and “non-receptor mediated” mechanisms. Moreover, we can distinguish between early and late effects of THs (also called “short-term” and “long-term” effects), the first being evident within minutes or a few



hours, whereas the second occurs over several hours or days<sup>[34,35]</sup>. However, the latency of a response is not sufficient to discriminate between “receptor-mediated” and “non-receptor” mediated effects.

## HEPATIC STEATOSIS: *IN VITRO* AND *IN VIVO* MODELS

With the rapidly growing prevalence of obesity throughout the Western countries, morbidity and mortality related to its complications are on the rise. Severe obesity is generally associated with TAG accumulation in non-adipose tissues like liver, muscle and pancreas and leads to a high risk of co-morbidities, including nonalcoholic fatty liver disease (NAFLD), cardiovascular disease and diabetes (for a review see<sup>[36]</sup>). NAFLD is a pathological condition associated with over-accumulation of TAGs in the liver and represents the most common of all hepatic disorders and the most frequent cause of chronic liver disease<sup>[37,38]</sup>. The earliest stage of NAFLD is hepatic steatosis characterized by the deposition of cytoplasmic TAGs as macro- and/or micro-vesicular lipid droplets in more than 5% of hepatocytes. Simple steatosis may progress to nonalcoholic steatohepatitis (NASH), cirrhosis and finally hepatocellular carcinoma<sup>[39]</sup>. NAFLD is now considered the hepatic manifestation of the metabolic syndrome and has insulin resistance as its hallmark. NAFLD is a syndrome with multifactorial etiology for which there is no effective treatment, although weight loss may halt disease progression and revert histological changes<sup>[36]</sup>.

In hepatocytes, steatosis results from an imbalance between lipid availability (deriving from circulating lipid uptake or *de novo* lipid synthesis) and lipid disposal (through FFA oxidation or TAG secretion)<sup>[40]</sup>. Typically, the main cause of steatosis is an overflow of free fatty acids (FFAs) into the liver that may eventually trigger lipoperoxidative stress and hepatic injury<sup>[39,41]</sup>. In the liver, FFAs are stored as TAGs through their esterification with glycerol or, alternatively, catabolized by oxidation to generate adenosine triphosphate (ATP). Excess TAGs are accumulated inside lipid droplets (LDs) that regulate storage and traffic of lipids (for a review see<sup>[42]</sup>). Typically, LDs are composed of a core of neutral lipids surrounded by phospholipids and proteins of the PAT protein family (acronym referring to the first members identified)<sup>[43]</sup>. The main PAT proteins are the adipocyte differentiation-related protein (ADRP, also called PLIN2), the oxidative tissue-enriched PAT protein (OXPAT or PLIN5) and the tail-interacting protein (TIP47 or PLIN3)<sup>[44]</sup>. ADRP expression is increased in rat models of NAFLD and in isolated hepatocytes<sup>[45]</sup>. PAT proteins are under the control of peroxisome proliferator-activated receptors (PPARs), a subfamily of lipid-activated transcription factors<sup>[46]</sup> consisting of three members, PPAR $\alpha$ , PPAR $\gamma$  and PPAR $\delta$ , with distinct functional roles<sup>[47,48]</sup>. In the liver, PPAR $\alpha$  enhances lipid catabolism and mobilization<sup>[49]</sup>, PPAR $\delta$  induces glycolysis/lipogenesis and PPAR $\gamma$  promotes lipid synthesis and LD formation<sup>[50]</sup>. In summary, PPAR $\alpha$  and

PPAR $\delta$  mainly act in energy burning, whereas PPAR $\gamma$  regulates energy storage, although an overlapping in their function has been described<sup>[40,51]</sup>. Moreover, PAT proteins regulate action of hepatic lipases that mobilize TAGs stored in LDs towards oxidation or secretion<sup>[52]</sup>, in particular, the adipose triglyceride lipase (ATGL) performs the first step in TAG hydrolysis.

### *In vivo models*

Steatosis and steatohepatitis can be modeled in rodents by two main dietary protocols: a methionine and choline deficient (MCD) diet or a high-fat diet (HFD). Different dietary approaches produce different disease severities and work by specific mechanisms<sup>[53]</sup>. In rodents, a MCD diet quickly induces (2-4 wk) hepatic steatosis (mainly macrovesicular) that may progress to inflammation and fibrosis. MCD diet-induced NASH is reversible by switching to a diet with methionine and choline. Rodents fed MCD diets lose weight (due to the lower caloric intake) and do not show insulin resistance. By contrast, HFD increases body weight, body fat and induces insulin resistance in rodent models. In general, HFD feeding induces only mild steatosis (mainly microvesicular) and does not produce liver fibrosis. The term “HFD” encompasses a wide variety of diet formulas but in all of them about 30%-75% of total calories is derived from saturated fatty acids. This diet closely resembles the pathological and molecular alterations found in humans with NAFLD<sup>[53]</sup>. It can be emphasized that fatty liver is typically characterized by altered lipid metabolism, increased oxidative stress and abnormal pattern of cytokine production.

### *In vitro models*

Hepatic steatosis in humans is typically associated with excess accumulation of oleic acid, a monounsaturated omega-9 fatty acid which represents the end product of *de novo* fatty acid synthesis. A number of studies using both primary cell cultures<sup>[54]</sup> and immortalized cell lines<sup>[55,56]</sup> proposed reliable cell models of hepatosteato-sis in which the steatosis severity might be modulated and the TAG content was exactly quantifiable. These *in vitro* models represent a simple experimental system to investigate the mechanisms underlying the steatosis progression and the hepatocyte alterations by excluding the interference from the matrix and other non-hepatocytic cells. Over the past decade, several cellular models of hepatosteato-sis have employed palmitate (C16:0) and oleate (C18:1) as exogenous fatty acids since these are common dietary long-chain FFAs and the most abundant FFAs in liver in both normal subjects and patients with NAFLD<sup>[57]</sup>. The human hepatoma cell line (HepG2) incubated with a mixture of oleate/palmitate (2:1 ratio) was used to study the cellular mechanisms involved in FFA-mediated lipotoxicity<sup>[55,58]</sup>. The same FFA mixture was used to induce steatosis in primary human hepatocytes<sup>[58]</sup>. In order to assess the different toxicity of saturated and unsaturated FFAs, primary mice hepatocytes and HepG2 cells were treated with various concentrations (0.05-0.5 mmol/L) of long

chain FFAs with different degrees of saturation; exposure to monounsaturated fatty acids resulted in lipid accumulation without changes in hepatocyte viability; in contrast, saturated fatty acids significantly decreased cell viability<sup>[59]</sup>. The effect of increasing concentrations of oleate alone (0.1-2.0 mmol/L) was also evaluated in order to clarify the pathophysiological changes associated with NAFLD<sup>[60]</sup>.

## LIPID-LOWERING EFFECTS OF IODOTHYRONINES ON *IN VIVO* MODELS OF HEPATOSTEATOSIS

In 1994, a first study reported that a daily intraperitoneal (*ip*) injection of T<sub>3</sub> (from 0 to 25 µg/100 g b.w.) to *ob/ob* mice decreased body weight and body fat and increased oxygen consumption and oxidative metabolism<sup>[61]</sup>. About ten years later, Goglia and coworkers described similar effects for T<sub>2</sub><sup>[10]</sup>. They showed that a daily *ip* injection of T<sub>2</sub> (25 µg/100 g b.w.) to rats simultaneously receiving HFD reduced both adiposity (about -50%) and body weight gain (about -13%) when compared with rats receiving HFD alone. Moreover, T<sub>2</sub> administration resulted in an almost complete disappearance of fat accumulation in the liver, a reduction in serum TAG and cholesterol levels (-52% and -18%, respectively), and a stimulation (about +42%) of FFA oxidation rate without inducing thyrotoxicity<sup>[10]</sup>. The effects of T<sub>2</sub> on liver metabolism seemed to involve mitochondria, even although peroxisomes are the main site for fat oxidation. In fact, long chain FFAs enter mitochondria through the activity of carnitine palmitoyl-transferase 1 (CPT1) that was stimulated by HFD and further increased by T<sub>2</sub><sup>[10]</sup>.

Interestingly, dietary administration of T<sub>3</sub> was also able to both prevent and reverse hepatic steatosis in rats<sup>[62]</sup>. In fact, concurrent dietary administration of T<sub>3</sub> and MCD diet resulted in prevention of fatty liver and decrease in lipid peroxidation in rats fed a MCD diet for 10 weeks and then co-fed T<sub>3</sub> for 1 week. Similar effects were observed using the potent TR selective agonist GC-1<sup>[62]</sup>.

The hepatic effects of T<sub>2</sub> administration to HFD rats were investigated in more detail by Grasselli *et al*<sup>[63,64]</sup>. HFD feeding resulted in hepatic lipid accumulation under the form of numerous LDs, a condition resembling the microvesicular steatosis typical of NAFLD. Fat accumulation was associated with increased transcription of PPAR $\alpha$ , a regulator for a number of genes involved in FFA catabolism, and of ATGL, a lipase mobilizing fat from LDs, together with a stimulation of anti-oxidant agents such as catalase and metallothioneins, in line with the increased production of reactive oxygen species (ROS) from mitochondria and peroxisomes as a consequence of fat accumulation<sup>[65]</sup>. In the liver of HFD rats, concomitant T<sub>2</sub> administration was able to prevent lipid accumulation, but also oxidative stress conditions associated with the diet<sup>[63]</sup>. Moreover, T<sub>2</sub> prevented the HFD-induced up-regulation of both PPAR $\alpha$  and ATGL and stimulated - (AOX) expression, indicating a stimulation of peroxisomal FFA oxidation<sup>[64]</sup>.

In addition to the above described reports demonstrating the ability of T<sub>2</sub> to prevent liver steatosis when administered simultaneously to HFD, other studies demonstrated that T<sub>2</sub> was also able to reverse hepatic steatosis after its induction through long term HFD and these effects were associated with a stimulation of mitochondrial uncoupling and a reduction in mitochondrial oxidative stress<sup>[66]</sup>.

A recent paper investigated the changes in the rat liver proteome induced by T<sub>2</sub> treatment. The proteomic approach allowed identification of which proteins were differentially expressed in the liver of HFD rats as a function of T<sub>2</sub> treatment<sup>[67]</sup>. Upon T<sub>2</sub> administration, the rat liver proteome resembled that typical of a non-steatotic condition. In particular, high-fat feeding led to changes in the expressions of enzymes involved in a multiplicity of pathways (*i.e.*, lipid metabolism, antioxidant defense, respiratory chain, oxidative metabolism). Mitochondria, in particular, appeared as the major target for the metabolic/energy adaptations induced by lipid overload in the liver and showed the more marked changes in terms of proteome as a response to T<sub>2</sub> treatment. In mitochondria from HFD rats, enhanced activities of complexes I and V and reduced activities of complexes II and IV were detected, even although the protein levels for all the complexes were increased. T<sub>2</sub>-treatment stimulated complexes I and II and normalized complex IV activity. On this basis, the authors suggest that the T<sub>2</sub>-induced enhancement of oxidative capacity may actually be based on a stimulation of the individual respiratory chain complexes (I, II and IV)<sup>[67]</sup>.

## LIPID LOWERING EFFECTS OF IODOTHYRONINES ON *IN VITRO* MODELS OF HEPATOSTEATOSIS

The above described *in vivo* studies could not distinguish between the direct antisteatotic effects of THs on the liver and their secondary effects due to upstream changes in endocrine or metabolic pathways. The employment of isolated hepatocytes allowed overcoming these problems.

Grasselli *et al*<sup>[51]</sup> assessed *in vitro* the direct effects of T<sub>2</sub> and T<sub>3</sub> (10<sup>-7</sup>-10<sup>-5</sup> mol/L doses for 24 h) using primary cultures of rat hepatocytes overloaded of lipids ("steatotic" hepatocytes) by exposure to the classical oleate/palmitate (2:1 ratio) mixture. The use of supraphysiological doses of iodothyronines depends on both their rapid metabolism *in vitro* and on their binding to the high concentration (1%) of albumin present in the culture medium. In accordance with reports showing altered expression of PPARs in murine models developing fatty livers<sup>[47]</sup>, isolated "steatotic" hepatocytes exhibited increased expression of both PPAR- $\gamma$  and PPAR- $\delta$ , as well as of ADRP, a PPAR-regulated PAT protein. As in liver of HFD rats<sup>[64]</sup>, also in isolated "steatotic" hepatocytes an increased activity of AOX, the enzyme catalyzing peroxisomal  $\beta$ -oxidation, as well as of SOD and catalase, two antioxidant enzymes protecting cells from the higher ROS production associ-

ated with FFA catabolism, was described. A reduction in the number and average sizes of LDs was observed after treatment with T<sub>2</sub> or T<sub>3</sub>, suggesting that iodothyronines lead to dispersion/fragmentation of LDs, thus making the stored TAGs more accessible to enzymes acting on catabolism/secretion of FFAs. Moreover, both T<sub>2</sub> and T<sub>3</sub> were able to reduce the FFA-induced up-regulation of PPAR $\gamma$  and PPAR $\delta$ , the stimulation of AOX, SOD and catalase activities. These results clearly indicate the lipid-lowering effect of iodothyronines mainly depends on a direct action on the hepatic cell<sup>[51]</sup>.

The use of primary rat hepatocytes allowed verification that the lipid-lowering effect of iodothyronines was a direct action on the hepatocyte but the involvement of thyroid hormone receptors in mediating this action remained to be elucidated. To this end, the same experiments were repeated using the FaO rat hepatoma cell line defective for functional TRs. FaO cells were exposed to the classical oleate/palmitate (2:1) mixture and then treated with T<sub>2</sub> or T<sub>3</sub> for 24 h (10<sup>-7</sup>-10<sup>-5</sup> mol/L doses). In FaO cells, TAG accumulation was associated with an increase in number and size of LDs and in PPAR $\gamma$  mRNA expression. The addition of T<sub>2</sub> or T<sub>3</sub> to “steatotic” cells reduced both the TAG content and the number and size of LDs and down-regulated expression of PPAR $\alpha$  and PPAR $\gamma$ . Moreover, iodothyronines stimulated the fuel-induced O<sub>2</sub> consumption. Since iodothyronines prevented the ADP-induced transient stimulation of O<sub>2</sub> consumption, this indicated a mitochondrial uncoupling action. In conclusion, this study demonstrated that the lipid-lowering actions of both T<sub>2</sub> and T<sub>3</sub> on the hepatocyte occur *via* “non-receptor-mediated” mechanisms and involve a short-term action by stimulation of mitochondrial O<sub>2</sub> consumption<sup>[68]</sup>.

## IODOTHYRONINES AND AUTOPHAGY OF LIPID DROPLETS

Despite the advances in the understanding of the effects of THs on cellular metabolism, little is known about the mechanisms by which THs regulate energy consumption within the cell. This is particularly true for the events involved in the delivery of FFAs to mitochondria, a necessary step in converting stored intracellular triglyceride fuel into ATP.

Autophagy is a stress-induced catabolic process involving lysosome fusion that is conserved in almost all eukaryotes. Autophagy of lipid droplets, termed “lipophagy”, has been shown to be a major pathway of lipid mobilization in hepatocytes<sup>[69]</sup> and its inhibition has been linked to development of fatty liver and insulin resistance<sup>[70]</sup>. The regulation of autophagy also appears to be important in the context of metabolic diseases, such as obesity. In a recent paper, Sinha *et al.*<sup>[71]</sup> showed that T<sub>3</sub> induced both lipophagy in cultured liver cell lines and hepatic autophagy in the mouse liver. The authors observed that the T<sub>3</sub>-stimulated autophagy of LDs depends on the presence of functional TRs and occurred before any

stimulation of hepatic lipases or oxidation enzyme<sup>[71]</sup>. Moreover, in animals with impaired autophagy, the effect of THs on FFA oxidation was abolished. Therefore, they propose that T<sub>3</sub> may increase the delivery of FFAs to mitochondria for  $\beta$ -oxidation through induction of autophagy of LDs. In this light, T<sub>3</sub> or its analogs, through their proautophagic action, may be useful in the treatment or prevention of NAFLD and its associated complications.

## CONCLUSION

In the last decades, extensive studies investigated the possible use of iodothyronines as pharmacological tools in the treatment of obesity, hyperlipidemia and dysmetabolic syndromes. The possible pharmacological use of the thyroid hormones T<sub>3</sub> or T<sub>4</sub> to stimulate body weight loss has found severe limitations because of the thyrotoxic effects associated with their long-term administration. For this reason, the identification of TH agonists/analogues retaining anti-obesity and hypolipemic efficacies, while being devoid of thyrotoxic effects, would represent a potential therapeutic advance.

Recent *in vivo* and *in vitro* studies have accumulated evidence on the lipid-lowering action of iodothyronines in the liver (Figure 2). The first studies showed that systemic administration of iodothyronines to rats receiving HFD resulted in a significant reduction in body weight gain and in the serum levels of triglycerides and cholesterol. At the organ level, the effects on the liver were very interesting, where iodothyronines could lower the excess lipid accumulation associated with HFD. These studies prosecuted by investigating the mechanisms of iodothyronine action. The development of *in vitro* models of hepatosteatosis using both primary cultures of rat hepatocytes and rat hepatoma cell lines allowed demonstration that the lipid lowering effects of iodothyronines depend on a direct interaction with the hepatic cell and is not mediated by thyroid hormone receptors. In conclusion, all the data summarized in this review clearly indicates that T<sub>2</sub> is able to reduce the lipid content of “steatotic hepatocytes”, thus supporting the possible utilization of T<sub>2</sub> as a pharmacological tool in the treatment of dysmetabolic syndromes, such as NAFLD, and also in the light of its lack of thyrotoxic effects.

Although a preliminary study on humans has been published, clinical trials are needed to translate these effects to the treatment of human obesity. If reproduced in humans, these results may offer an interesting perspective on the possible pharmacological approaches to the above mentioned lifestyle-related dysfunctions.

## ACKNOWLEDGMENTS

The author wishes to thank Elena Grasselli, Fernando Goglia, Adriana Voci, Laura Canesi and Gabriella Gallo for valuable discussion and their contributions are cited in the article.



## REFERENCES

- 1 **Goglia F.** Biological effects of 3,5-diiodothyronine (T(2)). *Biochemistry* (Mosc) 2005; **70**: 164-172 [PMID: 15807655]
- 2 **Hulbert AJ.** Thyroid hormones and their effects: a new perspective. *Biol Rev Camb Philos Soc* 2000; **75**: 519-631 [PMID: 11117200]
- 3 **Ness GC, Lopez D.** Transcriptional regulation of rat hepatic low-density lipoprotein receptor and cholesterol 7 alpha hydroxylase by thyroid hormone. *Arch Biochem Biophys* 1995; **323**: 404-408 [PMID: 7487105 DOI: 10.1006/abbi.1995.0061]
- 4 **Lopez D, Abisambra Socarrás JF, Bedi M, Ness GC.** Activation of the hepatic LDL receptor promoter by thyroid hormone. *Biochim Biophys Acta* 2007; **1771**: 1216-1225 [PMID: 17572141 DOI: 10.1016/j.bbali.2007.05.001]
- 5 **Cunningham BA, Moncur JT, Huntington JT, Kinlaw WB.** "Spot 14" protein: a metabolic integrator in normal and neoplastic cells. *Thyroid* 1998; **8**: 815-825 [PMID: 9777755 DOI: 10.1089/thy.1998.8.815]
- 6 **Jackson-Hayes L, Song S, Lavrentyev EN, Jansen MS, Hillgartner FB, Tian L, Wood PA, Cook GA, Park EA.** A thyroid hormone response unit formed between the promoter and first intron of the carnitine palmitoyltransferase-1alpha gene mediates the liver-specific induction by thyroid hormone. *J Biol Chem* 2003; **278**: 7964-7972 [PMID: 12493735]
- 7 **Oppenheimer JH, Schwartz HL, Lane JT, Thompson MP.** Functional relationship of thyroid hormone-induced lipogenesis, lipolysis, and thermogenesis in the rat. *J Clin Invest* 1991; **87**: 125-132 [PMID: 1985090 DOI: 10.1172/JCI114961]
- 8 **Pucci E, Chiovato L, Pinchera A.** Thyroid and lipid metabolism. *Int J Obes Relat Metab Disord* 2000; **24** Suppl 2: S109-S112 [PMID: 10997623 DOI: 10.1038/sj.ijo.0801292]
- 9 **Horst C, Rokos H, Seitz HJ.** Rapid stimulation of hepatic oxygen consumption by 3,5-di-iodo-L-thyronine. *Biochem J* 1989; **261**: 945-950 [PMID: 2803254]
- 10 **Lanni A, Moreno M, Lombardi A, de Lange P, Silvestri E, Ragni M, Farina P, Baccari GC, Fallahi P, Antonelli A, Goglia F.** 3,5-diiodo-L-thyronine powerfully reduces adiposity in rats by increasing the burning of fats. *FASEB J* 2005; **19**: 1552-1554 [PMID: 16014396 DOI: 10.1096/fj.05-3977fje]
- 11 **O'Reilly I, Murphy MP.** Treatment of hypothyroid rats with T2 (3,5-di-iodo-L-thyronine) rapidly stimulates respiration in subsequently isolated mitochondria. *Biochem Soc Trans* 1992; **20**: 59S [PMID: 1633981]
- 12 **Cimmino M, Mion F, Goglia F, Minaire Y, Geloën A.** Demonstration of in vivo metabolic effects of 3,5-di-iodothyronine. *J Endocrinol* 1996; **149**: 319-325 [PMID: 8708544 DOI: 10.1677/joe.0.1490319]
- 13 **Lanni A, Moreno M, Cioffi M, Goglia F.** Effect of 3,3'-diiodothyronine and 3,5-diiodothyronine on rat liver oxidative capacity. *Mol Cell Endocrinol* 1992; **86**: 143-148 [PMID: 1324858]
- 14 **Harper ME, Seifert EL.** Thyroid hormone effects on mitochondrial energetics. *Thyroid* 2008; **18**: 145-156 [PMID: 18279015 DOI: 10.1089/thy.2007.0250]
- 15 **Lanni A, Moreno M, Lombardi A, Goglia F.** Calorigenic effect of diiodothyronines in the rat. *J Physiol* 1996; **494** (Pt 3): 831-837 [PMID: 8865078]
- 16 **Kvetny J.** 3,5-T2 stimulates oxygen consumption, but not glucose uptake in human mononuclear blood cells. *Horm Metab Res* 1992; **24**: 322-325 [PMID: 1516887 DOI: 10.1055/s-2007-1003323]
- 17 **Harper ME, Brand MD.** The quantitative contributions of mitochondrial proton leak and ATP turnover reactions to the changed respiration rates of hepatocytes from rats of different thyroid status. *J Biol Chem* 1993; **268**: 14850-14860 [PMID: 8392060]
- 18 **Arnold S, Goglia F, Kadenbach B.** 3,5-Diiodothyronine binds to subunit Va of cytochrome-c oxidase and abolishes the allosteric inhibition of respiration by ATP. *Eur J Biochem* 1998; **252**: 325-330 [PMID: 9523704 DOI: 10.1046/j.1432-1327.1998.2520325.x]
- 19 **Yehuda-Shnaidman E, Kalderon B, Azazmeh N, Bar-Tana J.** Gating of the mitochondrial permeability transition pore by thyroid hormone. *FASEB J* 2010; **24**: 93-104 [PMID: 19723706 DOI: 10.1096/fj.09-133538]
- 20 **Antonelli A, Fallahi P, Ferrari SM, Di Domenicantonio A, Moreno M, Lanni A, Goglia F.** 3,5-diiodo-L-thyronine increases resting metabolic rate and reduces body weight without undesirable side effects. *J Biol Regul Homeost Agents* 2011; **25**: 655-660 [PMID: 22217997]
- 21 **Scanlan TS, Suchland KL, Hart ME, Chiellini G, Huang Y, Kruzich PJ, Frascarelli S, Crossley DA, Bunzow JR, Ronca-Testoni S, Lin ET, Hatton D, Zucchi R, Grandy DK.** 3-Iodothyronamine is an endogenous and rapid-acting derivative of thyroid hormone. *Nat Med* 2004; **10**: 638-642 [PMID: 15146179 DOI: 10.1038/nm1051]
- 22 **Bassett JH, Harvey CB, Williams GR.** Mechanisms of thyroid hormone receptor-specific nuclear and extra nuclear actions. *Mol Cell Endocrinol* 2003; **213**: 1-11 [PMID: 15062569 DOI: 10.1016/j.mce.2003.10.033]
- 23 **Tata JR, ERNSTER L, LINDBERG O, ARRHENIUS E, PEDERSEN S, HEDMAN R.** The action of thyroid hormones at the cell level. *Biochem J* 1963; **86**: 408-428 [PMID: 13993432]
- 24 **Sap J, Muñoz A, Damm K, Goldberg Y, Ghysdael J, Leutz A, Beug H, Vennström B.** The c-erb-A protein is a high-affinity receptor for thyroid hormone. *Nature* 1986; **324**: 635-640 [PMID: 2879242]
- 25 **Weinberger C, Thompson CC, Ong ES, Lebo R, Gruol DJ, Evans RM.** The c-erb-A gene encodes a thyroid hormone receptor. *Nature* 1986; **324**: 641-646 [PMID: 2879243]
- 26 **Cheng SY, Leonard JL, Davis PJ.** Molecular aspects of thyroid hormone actions. *Endocr Rev* 2010; **31**: 139-170 [PMID: 20051527 DOI: 10.1210/er.2009-0007]
- 27 **Shih A, Zhang S, Cao HJ, Tang HY, Davis FB, Davis PJ, Lin HY.** Disparate effects of thyroid hormone on actions of epidermal growth factor and transforming growth factor-alpha are mediated by 3',5'-cyclic adenosine 5'-monophosphate-dependent protein kinase II. *Endocrinology* 2004; **145**: 1708-1717 [PMID: 14691008 DOI: 10.1210/en.2003-0742]
- 28 **Davis PJ, Davis FB, Cody V.** Membrane receptors mediating thyroid hormone action. *Trends Endocrinol Metab* 2005; **16**: 429-435 [PMID: 16214361 DOI: 10.1016/j.tem.2005.09.007]
- 29 **Del Viscovo A, Secondo A, Esposito A, Goglia F, Moreno M, Canzoniero LM.** Intracellular and plasma membrane-initiated pathways involved in the [Ca2+]i elevations induced by iodothyronines (T3 and T2) in pituitary GH3 cells. *Am J Physiol Endocrinol Metab* 2012; **302**: E1419-E1430 [PMID: 22414808 DOI: 10.1152/ajpendo.00389.2011]
- 30 **Serrano-Nascimento C, Calil-Silveira J, Nunes MT.** Posttranscriptional regulation of sodium-iodide symporter mRNA expression in the rat thyroid gland by acute iodide administration. *Am J Physiol Cell Physiol* 2010; **298**: C893-C899 [PMID: 20107044 DOI: 10.1152/ajpcell.00224.2009]
- 31 **Lin HY, Davis FB, Gordinier JK, Martino LJ, Davis PJ.** Thyroid hormone induces activation of mitogen-activated protein kinase in cultured cells. *Am J Physiol* 1999; **276**: C1014-C1024 [PMID: 10329948]
- 32 **Hummerich H, Soboll S.** Rapid stimulation of calcium uptake into rat liver by L-tri-iodothyronine. *Biochem J* 1989; **258**: 363-367 [PMID: 2705987]
- 33 **Plow EF, Haas TA, Zhang L, Loftus J, Smith JW.** Ligand binding to integrins. *J Biol Chem* 2000; **275**: 21785-21788 [PMID: 10801897 DOI: 10.1074/jbc.R000003200]
- 34 **Davis PJ, Davis FB.** Nongenomic actions of thyroid hormone on the heart. *Thyroid* 2002; **12**: 459-466 [PMID: 12165107 DOI: 10.1089/10507250260143827]
- 35 **Soboll S.** Thyroid hormone action on mitochondrial energy transfer. *Biochim Biophys Acta* 1993; **1144**: 1-16 [PMID: 8347656]
- 36 **Mirza MS.** Obesity, Visceral Fat, and NAFLD: Querying the Role of Adipokines in the Progression of Nonalcoholic Fatty

- Liver Disease. *ISRN Gastroenterol* 2011; **2011**: 592404 [PMID: 21991518 DOI: 10.5402/2011/592404]
- 37 **Youssef WI**, McCullough AJ. Steatohepatitis in obese individuals. *Best Pract Res Clin Gastroenterol* 2002; **16**: 733-747 [PMID: 12406442 DOI: 10.1053/bega.2002.0334]
- 38 **Adams LA**, Angulo P. Recent concepts in non-alcoholic fatty liver disease. *Diabet Med* 2005; **22**: 1129-1133 [PMID: 16108837 DOI: 10.1111/j.1464-5491.2005.01748.x]
- 39 **Bradbury MW**. Lipid metabolism and liver inflammation. I. Hepatic fatty acid uptake: possible role in steatosis. *Am J Physiol Gastrointest Liver Physiol* 2006; **290**: G194-G198 [PMID: 16407588 DOI: 10.1152/ajpgi.00413.2005]
- 40 **Musso G**, Gambino R, Cassader M. Recent insights into hepatic lipid metabolism in non-alcoholic fatty liver disease (NAFLD). *Prog Lipid Res* 2009; **48**: 1-26 [PMID: 18824034 DOI: 10.1016/j.plipres.2008.08.001]
- 41 **Donnelly KL**, Smith CI, Schwarzenberg SJ, Jessurun J, Boldt MD, Parks EJ. Sources of fatty acids stored in liver and secreted via lipoproteins in patients with nonalcoholic fatty liver disease. *J Clin Invest* 2005; **115**: 1343-1351 [PMID: 15864352 DOI: 10.1172/JCI23621]
- 42 **Olofsson SO**, Boström P, Andersson L, Rutberg M, Perman J, Borén J. Lipid droplets as dynamic organelles connecting storage and efflux of lipids. *Biochim Biophys Acta* 2009; **1791**: 448-458 [PMID: 18775796 DOI: 10.1016/j.bbalip.2008.08.001]
- 43 **Bickel PE**, Tansey JT, Welte MA. PAT proteins, an ancient family of lipid droplet proteins that regulate cellular lipid stores. *Biochim Biophys Acta* 2009; **1791**: 419-440 [PMID: 19375517 DOI: 10.1016/j.bbalip.2009.04.002]
- 44 **Kimmel AR**, Brasaemle DL, McAndrews-Hill M, Sztalryd C, Londos C. Adoption of PERILIPIN as a unifying nomenclature for the mammalian PAT-family of intracellular lipid storage droplet proteins. *J Lipid Res* 2010; **51**: 468-471 [PMID: 19638644 DOI: 10.1194/jlr.R000034]
- 45 **Grasselli E**, Voci A, Pesce C, Canesi L, Fugassa E, Gallo G, Vergani L. PAT protein mRNA expression in primary rat hepatocytes: Effects of exposure to fatty acids. *Int J Mol Med* 2010; **25**: 505-512 [PMID: 20198297 DOI: 10.3892/ijmm.00000370]
- 46 **Motomura W**, Inoue M, Ohtake T, Takahashi N, Nagamine M, Tanno S, Kohgo Y, Okumura T. Up-regulation of ADRP in fatty liver in human and liver steatosis in mice fed with high fat diet. *Biochem Biophys Res Commun* 2006; **340**: 1111-1118 [PMID: 16403437 DOI: 10.1016/j.bbrc.2005.12.121]
- 47 **Everett L**, Galli A, Crabb D. The role of hepatic peroxisome proliferator-activated receptors (PPARs) in health and disease. *Liver* 2000; **20**: 191-199 [PMID: 10902968 DOI: 10.1034/j.1600-0676.2000.020003191.x]
- 48 **Patsouris D**, Reddy JK, Müller M, Kersten S. Peroxisome proliferator-activated receptor alpha mediates the effects of high-fat diet on hepatic gene expression. *Endocrinology* 2006; **147**: 1508-1516 [PMID: 16357043 DOI: 10.1210/en.2005-1132]
- 49 **Pyper SR**, Viswakarma N, Yu S, Reddy JK. PPARalpha: energy combustion, hypolipidemia, inflammation and cancer. *Nucl Recept Signal* 2010; **8**: e002 [PMID: 20414453 DOI: 10.1621/nrs.08002]
- 50 **Evans RM**, Barish GD, Wang YX. PPARs and the complex journey to obesity. *Nat Med* 2004; **10**: 355-361 [PMID: 15057233 DOI: 10.1038/nm1025]
- 51 **Grasselli E**, Voci A, Canesi L, De Matteis R, Goglia F, Cioffi F, Fugassa E, Gallo G, Vergani L. Direct effects of iodothyronines on excess fat storage in rat hepatocytes. *J Hepatol* 2011; **54**: 1230-1236 [PMID: 21145833 DOI: 10.1016/j.jhep.2010.09.027]
- 52 **Zimmermann R**, Lass A, Haemmerle G, Zechner R. Fate of fat: the role of adipose triglyceride lipase in lipolysis. *Biochim Biophys Acta* 2009; **1791**: 494-500 [PMID: 19010445 DOI: 10.1016/j.bbalip.2008]
- 53 **Kanuri G**, Bergheim I. In Vitro and in Vivo Models of Non-Alcoholic Fatty Liver Disease (NAFLD). *Int J Mol Sci* 2013; **14**: 11963-11980 [PMID: 23739675 DOI: 10.3390/ijms140611963]
- 54 **Vinciguerra M**, Sgroi A, Veyrat-Durebex C, Rubbia-Brandt L, Buhler LH, Foti M. Unsaturated fatty acids inhibit the expression of tumor suppressor phosphatase and tensin homolog (PTEN) via microRNA-21 up-regulation in hepatocytes. *Hepatology* 2009; **49**: 1176-1184 [PMID: 19072831 DOI: 10.1002/hep.22737]
- 55 **Feldstein AE**, Werneburg NW, Canbay A, Guicciardi ME, Bronk SF, Rydzewski R, Burgart LJ, Gores GJ. Free fatty acids promote hepatic lipotoxicity by stimulating TNF-alpha expression via a lysosomal pathway. *Hepatology* 2004; **40**: 185-194 [PMID: 15239102 DOI: 10.1002/hep.20283]
- 56 **Giudetti AM**, Leo M, Geelen MJ, Gnoni GV. Short-term stimulation of lipogenesis by 3,5-L-diiodothyronine in cultured rat hepatocytes. *Endocrinology* 2005; **146**: 3959-3966 [PMID: 15932927 DOI: 10.1210/en.2005-0345]
- 57 **Araya J**, Rodrigo R, Videla LA, Thielemann L, Orellana M, Pettinelli P, Ponichik J. Increase in long-chain polyunsaturated fatty acid n - 6/n - 3 ratio in relation to hepatic steatosis in patients with non-alcoholic fatty liver disease. *Clin Sci (Lond)* 2004; **106**: 635-643 [PMID: 14720121 DOI: 10.1042/CS20030326]
- 58 **Gómez-Lechón MJ**, Donato MT, Martínez-Romero A, Jiménez N, Castell JV, O'Connor JE. A human hepatocellular in vitro model to investigate steatosis. *Chem Biol Interact* 2007; **165**: 106-116 [PMID: 17188672 DOI: 10.1016/j.cbi.2006.11.004]
- 59 **Li ZZ**, Berk M, McIntyre TM, Feldstein AE. Hepatic lipid partitioning and liver damage in nonalcoholic fatty liver disease: role of stearoyl-CoA desaturase. *J Biol Chem* 2009; **284**: 5637-5644 [PMID: 19119140 DOI: 10.1074/jbc.M807612001]
- 60 **Cui W**, Chen SL, Hu KQ. Quantification and mechanisms of oleic acid-induced steatosis in HepG2 cells. *Am J Transl Res* 2010; **2**: 95-104 [PMID: 20182586]
- 61 **Oh SS**, Kaplan ML. Early treatment of obese (ob/ob) mice with triiodothyronine increases oxygen consumption and temperature and decreases body fat content. *Proc Soc Exp Biol Med* 1994; **207**: 260-267 [PMID: 7800681]
- 62 **Perra A**, Simbula G, Simbula M, Pibiri M, Kowalik MA, Sulas P, Cocco MT, Ledda-Columbano GM, Columbano A. Thyroid hormone (T3) and TRbeta agonist GC-1 inhibit/reverse nonalcoholic fatty liver in rats. *FASEB J* 2008; **22**: 2981-2989 [PMID: 18434432 DOI: 10.1096/fj.08-108464]
- 63 **Grasselli E**, Canesi L, Voci A, De Matteis R, Demori I, Fugassa E, Vergani L. Effects of 3,5-diiodo-L-thyronine administration on the liver of high fat diet-fed rats. *Exp Biol Med* (Maywood) 2008; **233**: 549-557 [PMID: 18375830 DOI: 10.3181/0710-RM-266]
- 64 **Grasselli E**, Voci A, Demori I, Canesi L, De Matteis R, Goglia F, Lanni A, Gallo G, Vergani L. 3,5-Diiodo-L-thyronine modulates the expression of genes of lipid metabolism in a rat model of fatty liver. *J Endocrinol* 2012; **212**: 149-158 [PMID: 22107956 DOI: 10.1530/JOE-11-0288]
- 65 **Reddy JK**, Rao MS. Lipid metabolism and liver inflammation. II. Fatty liver disease and fatty acid oxidation. *Am J Physiol Gastrointest Liver Physiol* 2006; **290**: G852-G858 [PMID: 16603729 DOI: 10.1152/ajpgi.00521.2005]
- 66 **Mollica MP**, Lionetti L, Moreno M, Lombardi A, De Lange P, Antonelli A, Lanni A, Cavaliere G, Barletta A, Goglia F. 3,5-diiodo-L-thyronine, by modulating mitochondrial functions, reverses hepatic fat accumulation in rats fed a high-fat diet. *J Hepatol* 2009; **51**: 363-370 [PMID: 19464748 DOI: 10.1016/j.jhep.2009.03.023]
- 67 **Silvestri E**, Cioffi F, Glinni D, Ceccarelli M, Lombardi A, de Lange P, Chambery A, Severino V, Lanni A, Goglia F, Moreno M. Pathways affected by 3,5-diiodo-L-thyronine in liver of high fat-fed rats: evidence from two-dimensional electrophoresis, blue-native PAGE, and mass spectrometry. *Mol Biosyst* 2010; **6**: 2256-2271 [PMID: 20844788 DOI: 10.1039/c0mb00040j]
- 68 **Grasselli E**, Voci A, Canesi L, Goglia F, Ravera S, Panfoli I,



- Gallo G, Vergani L. Non-receptor-mediated actions are responsible for the lipid-lowering effects of iodothyronines in FaO rat hepatoma cells. *J Endocrinol* 2011; **210**: 59-69 [PMID: 21508094 DOI: 10.1530/JOE-11-0074]
- 69 **Singh R**, Kaushik S, Wang Y, Xiang Y, Novak I, Komatsu M, Tanaka K, Cuervo AM, Czaja MJ. Autophagy regulates lipid metabolism. *Nature* 2009; **458**: 1131-1135 [PMID: 19339967 DOI: 10.1038/nature07976]
- 70 **Yang L**, Li P, Fu S, Calay ES, Hotamisligil GS. Defective hepatic autophagy in obesity promotes ER stress and causes insulin resistance. *Cell Metab* 2010; **11**: 467-478 [PMID: 20519119 DOI: 10.1016/j.cmet.2010.04.005]
- 71 **Sinha RA**, You SH, Zhou J, Siddique MM, Bay BH, Zhu X, Privalsky ML, Cheng SY, Stevens RD, Summers SA, Newgard CB, Lazar MA, Yen PM. Thyroid hormone stimulates hepatic lipid catabolism via activation of autophagy. *J Clin Invest* 2012; **122**: 2428-2438 [PMID: 22684107 DOI: 10.1172/JCI60580]

**P- Reviewers:** Goglia F, Hutz RJ, Kim JB **S- Editor:** Song XX  
**L- Editor:** Roemmele A **E- Editor:** Wu HL



## Update on inflammatory bowel disease in patients with primary sclerosing cholangitis

Christos Tsaitas, Anyisia Semertzidou, Emmanouil Sinakos

Christos Tsaitas, Anyisia Semertzidou, Emmanouil Sinakos, 4<sup>th</sup> Internal Medicine Unit, University Hospital of Thessaloniki, Thessaloniki 54642, Greece

**Author contributions:** Tsaitas C and Semertzidou A drafted the manuscript; Sinakos E revised the manuscript critically for important intellectual content.

**Correspondence to:** Emmanouil Sinakos, MD, 4<sup>th</sup> Internal Medicine Unit, University Hospital of Thessaloniki, 11A, Perdika Str, Pilea, 55535, Thessaloniki 54642, Greece. [em\\_sinakos@yahoo.com](mailto:em_sinakos@yahoo.com)

Telephone: +30-2310-950680 Fax: +30-2310-950680

Received: October 28, 2013 Revised: March 5, 2014

Accepted: March 13, 2014

Published online: April 27, 2014

### Abstract

Patients with primary sclerosing cholangitis (PSC) complicated by inflammatory bowel disease (IBD) represent a distinct subset of patients with unique characteristics, which have serious clinical implications. The aim of this literature review was to shed light to the obscure clinical and molecular aspects of the two diseases combined utilizing current data available and putting issues of diagnosis and treatment into perspective. The prevalence of IBD, mainly ulcerative colitis in PSC patients is estimated to be 21%-80%, dependent on screening programs and nationality. PSC-associated colitis is likely to be extensive, characterized by rectal sparing, backwash ileitis, and generally mild symptoms. It is also more likely to progress to colorectal malignancy, making it imperative for clinicians to maintain a high level of suspicion when tackling PSC patients. There is no optimal surveillance strategy but current guidelines advocate that colonoscopy is necessary at the time of PSC diagnosis with annual endoscopic follow-up. Random biopsies have been criticized and a shift towards targeted biopsies using chromoendoscopy, laser endomicroscopy and narrow-band imaging has been noted. Techniques directed towards genetic mutations instead of histological abnormalities hold promise for easier,

more accurate diagnosis of dysplastic lesions. Chemo-preventive measures against colorectal cancer have been sought in these patients. Ursodeoxycholic acid seemed promising at first but subsequent studies yielded conflicting results showing anticarcinogenic effects in low doses (8-15 mg/kg per day) and carcinogenic properties in high doses (15-30 mg/kg per day).

© 2014 Baishideng Publishing Group Co., Limited. All rights reserved.

**Key words:** Primary sclerosing cholangitis; Inflammatory bowel disease; Ulcerative colitis; Crohn's disease

**Core tip:** Combination of primary sclerosing cholangitis (PSC) and inflammatory bowel disease (IBD) has recently arisen as a challenging research field. Recent data highlight the specific clinical and genetic traits that differentiate PSC-IBD from the two diseases individually. We reviewed the literature on colorectal neoplastic susceptibility in this subset of patients and the underlying pathogenetic mechanisms. We also emphasize the technological advances that have provided novel diagnostic tools for more accurate detection of dysplastic lesions. Finally, we present current guidelines on follow-up as well as all evidence available as to whether ursodeoxycholic acid should be used prophylactically against colorectal cancer.

Tsaitas C, Semertzidou A, Sinakos E. Update on inflammatory bowel disease in patients with primary sclerosing cholangitis. *World J Hepatol* 2014; 6(4): 178-187 Available from: URL: <http://www.wjgnet.com/1948-5182/full/v6/i4/178.htm> DOI: <http://dx.doi.org/10.4254/wjh.v6.i4.178>

### INTRODUCTION

Primary sclerosing cholangitis (PSC) is a chronic progressive disease characterized by inflammation and fibrosis of

medium size and large ducts in the intrahepatic and extrahepatic biliary tree<sup>[1,2]</sup>. This disorder results in multifocal intrahepatic and extrahepatic biliary strictures, leading to cholestasis, liver cirrhosis, portal hypertension, and ultimately, premature death from liver failure. It was first reported in the German literature in 1867 by Hoffman, but was described in more detail in the 1920s by two French surgeons, Delbet and Lafourcade. The term sclerosing cholangitis was first used in 1954 by Castleman and later by Schwartz and Dale in their review article<sup>[3]</sup>. Its etiology remains largely unknown, although it is strongly believed that autoimmunity is the main culprit. The differential diagnosis of PSC includes congenital diseases (*e.g.*, Caroli disease and choledochal cysts) and secondary cholangiopathy, as observed in patients with collagen vascular diseases (*e.g.*, systemic lupus erythematosus, rheumatoid arthritis, and systemic sclerosis) and in those with infiltrative diseases (*e.g.*, mediastinal fibrosis, Riedel thyroiditis, eosinophilic cholangitis, and histiocytosis X). Parasitic, fungal, viral or bacterial infections or recurrent cholangitis itself, especially in patients who are immunocompromised, can cause multifocal liver abscesses that lead to a PSC-like appearance of the bile duct. This disease is associated with many cancers including cholangiocarcinoma, gallbladder cancer, hepatocellular carcinoma and colorectal cancer (CRC), thus establishing a link between chronic inflammation and carcinogenesis.

## THE PSC-INFLAMMATORY BOWEL DISEASE INTERPLAY

The overwhelming majority of PSC cases have underlying inflammatory bowel disease (IBD). IBD is defined as a chronic condition characterized by immune-mediated inflammation of the gastrointestinal system. The prevalence ranges from 21% to 80%, with the higher rates seen in settings where screening programs are more intense and rectal and sigmoid biopsies are routinely obtained. A geographical variation also exists, with northern European and American societies exhibiting higher rates of PSC-IBD than southern regions and Asia. About 85%-90% of patients with PSC and IBD are comprised of ulcerative colitis (UC) patients and the remainder involves patients with Crohn's colitis or Crohn's ileocolitis<sup>[4]</sup>. The association of PSC and Crohn's disease (CD) was first described by Atkinson and Carroll in 1964<sup>[5]</sup>. A year later, Smith and Loe described an association between PSC and UC<sup>[6]</sup>. Conversely, it has been estimated that PSC occurs in about 5% of UC patients and 3% of CD patients<sup>[7]</sup>.

IBD may be diagnosed at any time during the course of PSC. Until recently, the diagnosis of IBD more frequently preceded that of PSC, even by several years<sup>[8-11]</sup>. Nowadays, there has been a shift in the timing of diagnosis of IBD and PSC. PSC is most commonly diagnosed first, or at least there is a concomitant diagnosis of the two diseases. It is intriguing that *de novo* IBD may present after liver transplantation for PSC<sup>[12]</sup>, and PSC may present several years after proctocolectomy for IBD. The

altered trend in diagnostic timing can be attributed to two factors. First, the advent of noninvasive imaging techniques such as magnetic resonance cholangiography has enabled early diagnosis of pathological liver biochemistry. Second, the increasing awareness among physicians of the PSC-IBD association has led to early routine endoscopic screening in patients diagnosed with PSC, even in the absence of symptomatic colitis. A study comparing the interval from PSC to IBD diagnosis in 1993-1997 and 2003-2007 showed a decrease from 9 to 7 mo respectively<sup>[13]</sup>.

The genetic factors for PSC development are still poorly understood. There is an obvious geographic clustering with high prevalence in northern countries compared to Southern Europe and Asia. It has been shown that first-degree relatives of PSC patients have a disease prevalence of 0.7%, representing a nearly 100-fold increased risk of developing PSC compared to that in the general population<sup>[14]</sup>. In siblings the prevalence even reaches 1.5%<sup>[15]</sup>. Taken together, these epidemiologic data and heritability studies have revealed a strong genetic background for PSC. Genome-wide association studies have shed some light on the subcellular maze of PSC and its overlap with IBD. Human leucocyte antigen (HLA) and non-HLA haplotypes have been identified. The HLA-A1 allele<sup>[16]</sup>, HLA-C7<sup>[17]</sup>, major histocompatibility complex class I chain-related A (MICA)\*002 and 008/5.1 alleles<sup>[18,19]</sup>, as well as the tumor necrosis factor (TNF) $\alpha$  promoter -308 A allele<sup>[20]</sup> were identified as risk loci for PSC susceptibility. Data from five different European countries (United Kingdom, Italy, Norway, Spain and Sweden) demonstrate that PSC is positively associated with three different HLA class II haplotypes: DRB1\*03, DQA1\*0501, DQB1\*02 (which confers the highest relative risk for PSC development); DRB1\*15, DQA1\*0102, DQB1\*0602; and the DRB1\*13, DQA1\*0103, DQB1\*0603<sup>[21]</sup>. However, non-HLA associations have also been confirmed. Of note, MMEL1 and TNFRS14 on chromosome 1p36 encoding a membrane metallo-endopeptidase-like protein of unknown function and a receptor for cytokines and membrane-bound ligands, respectively, have been identified as risk loci for PSC<sup>[22]</sup>. The risk of PSC has also been associated with the *FUT2* gene encoding fucosyltransferase<sup>[22]</sup>, which is an enzyme that regulates expression of the ABO blood group antigens on the surface of epithelial cells. To date, there is scarcity of molecular evidence regarding the shared susceptibility loci between PSC and IBD. A Scandinavian study comparing PSC with UC patients showed distinct HLA associations<sup>[23]</sup>. No significant differences were noted between PSC patients with concurrent UC and PSC patients without IBD. This study provides genetic evidence that UC in PSC patients follows a distinct course and demonstrates phenotypic uniqueness compared with UC in isolation. More recently, *REL*, *IL-2* and *CARD9* have been identified as genetic links between the two diseases<sup>[24]</sup>.

Taking into consideration its associations with HLA haplotypes, autoimmune diseases and the presence of IBD in the majority of PSC patients, immunopathoge-

**Table 1** Characteristics of inflammatory bowel disease associated with primary sclerosing cholangitis

|  |
|--|
| Extensive colitis (with right-sided predominance)  |
| Rectal sparing   |
| Backwash ileitis   |
| Mild or quiescent course   |
| Increased risk of colorectal cancer  |
| Increased risk of pouchitis in patients undergoing proctocolectomy with ileal pouch anal anastomosis |
| Increased risk of peristomal varices in patients undergoing proctocolectomy with ileostomy           |

netic mechanisms have been sought in PSC pathogenesis. In this regard, two theories have been proposed: the leaky gut hypothesis and the gut lymphocyte homing hypothesis. According to the leaky gut hypothesis, bacteria or bacterial products enter the portal-venous system due to the increased intestinal permeability resulting from inflammation, and translocate to the liver. Bacteria trigger the release of cytokines by Kupffer cells and macrophages in the liver and lead to periductal fibrosis<sup>[8]</sup>. The gut lymphocyte homing hypothesis supports the notion that T lymphocytes primed in the inflamed gut may persist as long-lived memory cells, undergo enterohepatic circulation, and trigger portal inflammation in PSC *via* aberrantly expressed adhesion molecules in the liver and gut<sup>[25]</sup>.

## IBD IN PSC: A UNIQUE PHENOTYPIC EXPRESSION

There are many clinical and endoscopic features that differentiate patients with IBD and concomitant PSC and those with IBD in isolation (Table 1). Loftus *et al*<sup>[10]</sup> compared 71 patients with PSC who had IBD with a matched group of 142 patients with UC. Among the PSC patients, 86% had UC, 7% had CD, and 7% had indeterminate colitis. The PSC patients more frequently had pancolitis (87% *vs* 54%), rectal sparing (52% *vs* 6%), and backwash ileitis (51% *vs* 7%) than the control group. It is now commonly believed that the colitis associated with PSC is frequently extensive and characterized by rectal sparing and backwash ileitis<sup>[26,27]</sup>. These special traits impede the definitive classification of IBD. For instance, the presence of rectal sparing or ileitis may be misinterpreted for CD or indeterminate colitis, rather than UC. In addition, PSC-associated colitis runs a milder, quiescent course, sometimes with absent clinical manifestations, thus delaying diagnosis<sup>[28]</sup>. Another intriguing trait in PSC-IBD patients is the higher rate of colorectal neoplasia, which tends to be proximal, is diagnosed at a later stage and has a worse prognosis. The colorectal neoplastic potential in these patients will be discussed later.

Of note, PSC patients who have an ileal pouch anal anastomosis (IPAA) after colectomy have an increased risk of pouchitis compared to patients with UC without PSC<sup>[29,30]</sup>. The underlying mechanism for this complica-

tion remains obscure. There is also one report suggesting that patients with PSC and IPAA run an increased risk of development of dysplasia in the ileal pouch mucosa compared with UC patients without PSC, and that these patients consequently should be under intensive surveillance<sup>[31]</sup>. However, more studies are required to substantiate these claims. Interestingly, it has been suggested that PSC-IBD patients undergoing proctocolectomy with ileostomy develop peristomal varices more frequently than IBD patients without evidence of hepatobiliary disease<sup>[32]</sup>. Bleeding from these often is recurrent and is challenging to treat. This complication can be controlled with a portosystemic shunt or transjugular intrahepatic portosystemic shunt, but liver transplantation may be considered.

PSC in patients with IBD does not seem to run a different course when compared to patients without IBD. Nevertheless, one study has demonstrated that PSC in patients with concomitant IBD has a predilection for men, is more likely to manifest itself for the first time with abnormal liver biochemistry, and has intrahepatic and extrahepatic biliary tree strictures<sup>[33]</sup>. Proctocolectomy, as a surgical treatment for UC, has no effect on liver function tests, histology or survival of patients with PSC<sup>[34]</sup>.

## COLORECTAL NEOPLASTIC POTENTIAL IN PSC-IBD PATIENTS

The increased occurrence of CRC in IBD patients has been well documented since 1925, when it was first described by Crohn and Rosenberg<sup>[35]</sup>. The cancer risk involves both UC and CD<sup>[36-39]</sup>, and has been linked with prolonged duration and extent of disease, associated PSC and active inflammation<sup>[40,41]</sup>. Data on the relative risk of CRC in IBD are not in agreement in different studies. The cumulative risk varies from 1.4% after 18 years<sup>[42]</sup> to 34% after 25 years from onset of disease<sup>[43]</sup>. Some studies even advocate that the risk is not increased at all<sup>[44]</sup>.

Recent investigations have unveiled another relationship, that of PSC-IBD patients and CRC. The concept that PSC is associated with an increased risk of colorectal neoplasia in patients with UC was proposed by Broomé *et al*<sup>[45]</sup> in 1992. In a study of 17 patients with UC who were found to have dysplasia, carcinoma, and/or DNA aneuploidy, 28% had coexistent PSC. This led to the hypothesis that PSC is an independent risk factor for the development of colorectal neoplasia in patients with existing UC. There has been a wealth of studies since then reporting the connection of PSC-IBD and CRC, particularly highlighting the compounding neoplastic risk when the two disorders coexist as opposed to patients with IBD alone<sup>[46-53]</sup> (Table 2). Soetikno *et al*<sup>[54]</sup> performed a meta-analysis of 11 studies and described an odds ratio (OR) of 4.79 (95%CI: 2.89-5.76) when comparing patients with UC and PSC to UC patients without PSC. However, two studies (both from the Mayo Clinic but using different groups of patients) have yielded contradictory results rejecting the hy-



**Table 2** Summary of studies evaluating primary sclerosing cholangitis as a risk factor for colorectal neoplasia in chronic ulcerative colitis

| Ref.                                   | UC case group (No) | Centre                     | End point (No)       | Matched controls | Colectomy rate | Is PSC a risk factor? |
|--|--------------------|----------------------------|----------------------|------------------|----------------|-----------------------|
| Broomé <i>et al</i> <sup>[45]</sup>    | Dys (17)           | Hudding, Sweden            | PSC (5)              | Yes              | 0%             | Yes                   |
| D'Haens <i>et al</i> <sup>[46]</sup>   | Dys (29)           | Chicago, United States     | Cholestasis/PSC (10) | Yes              | 0%             | Yes                   |
| Broomé <i>et al</i> <sup>[47]</sup>    | PSC (40)           | Hudding, Sweden            | CRC/Dys (15)         | Yes              | 30%            | Yes                   |
| Brentnall <i>et al</i> <sup>[48]</sup> | PSC (20)           | Seattle, United States     | Dys (9)              | No               | 0%             | Yes                   |
| Leidenius <i>et al</i> <sup>[49]</sup> | PSC (45)           | Helsinki, Finland          | CRC/Dys (13)         | Yes              | 29%            | Yes                   |
| Marchesa <i>et al</i> <sup>[50]</sup>  | PSC (27)           | Cleveland, United States   | CRC (4)/Dys (14)     | Yes              | All postop     | Yes                   |
| Shetty <i>et al</i> <sup>[51]</sup>    | PSC (132)          | Cleveland, United States   | CRC (17)/Dys (16)    | No               | 0%             | Yes                   |
| Loftus <i>et al</i> <sup>[52]</sup>    | PSC (143)          | Mayo Clinic, United States | CRC (8)              | No               | 37%            | No                    |
| Nuako <i>et al</i> <sup>[53]</sup>     | CRC (171)          | Mayo Clinic, United States | PSC (30)             | Yes              | 14%            | No                    |

CRC: Colorectal cancer; CRN: Colorectal neoplasia; Dys: Dysplasia; PSC: Primary sclerosing cholangitis.

pothesis that there is an increased risk for CRC in PSC-IBD patients<sup>[52,53]</sup>. In general, the increased neoplastic potential in PSC-IBD patients could be ascribed to late diagnosis due to the subclinical course of colitis and the conservative treatment of mild flare-ups as opposed to colectomy, thereby increasing the duration and extent of colitis.

CRCs associated with PSC display a number of characteristics. They appear to have a more proximal localization with up to 76% right-sided distribution. A full colonoscopy is therefore mandatory for surveillance purposes. CRCs in this subset of patients are diagnosed at a more advanced stage and tend to be fatal. In a recent study, PSC patients with IBD and CRC were found to be younger at onset of IBD than patients who had IBD and CRC without PSC (19 *vs* 29 years;  $P = 0.04$ ). The time interval from onset of colitis until diagnosis of CRC was, however, similar in the two groups (17 *vs* 20 years;  $P = 0.02$ )<sup>[55]</sup>.

## PATHOGENETIC MECHANISMS OF CRC IN PSC

The mechanisms underlying the pathogenesis of CRC in IBD patients have been rigorously investigated and many differences in comparison with sporadic CRC have been addressed<sup>[56,57]</sup>. Even though IBD-CRC usually follows a dysplasia-cancer pattern, as in sporadic cancer, molecular and genetic events seem to occur in an unconventional sequence. Alterations to the *p53* tumor suppressor gene occur earlier in colitis-related CRC<sup>[58]</sup>, whereas adenomatous polyposis coli (*APC*) gene alteration is usually a later event<sup>[59]</sup>. The reverse applies to sporadic CRC. It is also noteworthy that *p53* mutations can be present in nondysplastic mucosa in IBD-CRC, but only in dysplastic areas in sporadic cancer<sup>[60]</sup>. Another noteworthy difference is that low-grade dysplasia is often in flat lesions in CRC-IBD, which are difficult to detect endoscopically, whereas such dysplasia occurs within raised polyps in sporadic cancer. The role of microsatellite instability, hypermethylation, chromosomal instability, interleukin (IL)-23/IL-17 signaling and E-cadherin (CDH1) has been addressed in studies but is not yet fully understood<sup>[61-64]</sup>. Polymorphisms of the mismatch repair genes *MLH1* and *MSH2*

have been incriminated for the pathogenesis of IBD and related malignancy<sup>[65,66]</sup>.

The direct impact of PSC on colorectal carcinogenesis has not yet been delineated. Another theory highlights the significance of the cholestasis-associated secondary bile salt pool in the colon<sup>[67]</sup>. Bile acids such as deoxycholic acid and lithocholic acid (LCA) are thought to contribute to tumorigenesis through disruption of the balance between colorectal crypt cell proliferation, differentiation and apoptosis<sup>[68-71]</sup>. Mucosa in carcinoma displayed an increased frequency of bile acid receptors compared with normal tissue<sup>[72]</sup>. A higher fecal bile acid concentration was found in patients with UC who developed neoplasia compared with those without UC<sup>[73]</sup>. Folate deficiency has also been implicated in the pathogenesis of CRC in IBD patients. Folate deficiency arises from sulfasalazine use to treat UC, which is a competitive inhibitor of folate absorption. Folate supplementation was associated with a 62% reduction in the incidence of neoplasia in patients with pancolonic UC compared with placebo<sup>[74]</sup>. This theory, however, contradicts epidemiological reports according to which maintenance therapy in UC reduces risk of carcinogenesis<sup>[75]</sup>.

## SURVEILLANCE RECOMMENDATIONS

Periodic surveillance colonoscopy is the milestone of cancer prevention in IBD<sup>[76,77]</sup>. PSC in combination with IBD further enhances the risk for CRC as described above and necessitates increased alertness. That along with the fact that IBD in PSC patients usually follows an asymptomatic, subclinical course raises the need for routine colonoscopy at the time of PSC diagnosis, which should be repeated on an annual basis<sup>[78]</sup>. However, a recent study by Imam *et al*<sup>[79]</sup> showed a low risk of colonic neoplasia in young patients with a combined diagnosis of PSC and IBD, with an estimated prevalence of 1.3% and an incidence of 0.4% per year. This finding raises the question whether annual surveillance is unnecessary in this selected group of patients.

Three categories of dysplasia have been identified according to the IBD Dysplasia Morphology Study Group<sup>[80]</sup>: (1) negative for dysplasia; (2) indefinite for dysplasia; and (3) positive for dysplasia, which is further subdivided into low-grade dysplasia (LGD) and high-grade



dysplasia (HGD). Each of these categories necessitates a different approach. A finding of indefinite dysplasia dictates a repeat colonoscopy in 3-6 mo. The management of LGD is debatable with no clear evidence of optimal approach. St Mark's Hospital<sup>[81]</sup> demonstrated a 54% cumulative probability of LGD progressing to HGD or CRC. Mayo Clinic reported a 33% 5-year progression<sup>[82]</sup>, while other studies described an even lower rate<sup>[83,84]</sup>. Thus, in the case of LGD different options should be discussed with patients and informed consent for conservative or operative management should be obtained. Patients with multifocal flat LGD in one screening or unifocal LGD in more than one screening should prompt prophylactic total proctocolectomy. HGD, however, needs unquestionable referral for total proctocolectomy due to the increased risk of concurrent or subsequent malignancy<sup>[85]</sup>.

There has been increased skepticism in the medical community about the random biopsies used for surveillance purposes. New methods enable targeted biopsies to be obtained from identifiable lesions. Chromoendoscopy, confocal laser endomicroscopy and narrow-band imaging (NBI) are new promising techniques that are likely to replace old-fashioned random biopsies that have proven their inadequacy in many studies<sup>[86,87]</sup>. Chromoendoscopy uses the application of indigo carmine or methylene blue to stain dysplastic areas on the colonic mucosa. Hurlstone *et al*<sup>[88]</sup> examined 700 patients in a prospective case-control trial and diagnosed 69 dysplastic lesions with chromoendoscopy and only 24 with random biopsies ( $P < 0.001$ )<sup>[88]</sup>. Confocal laser endomicroscopy enables the histological visualization of the mucosa in real time. It is easily inferred that this technique requires specialized training for histological interpretation. A randomized controlled trial was conducted by Kiesslich *et al*<sup>[89]</sup> showing an increase of 4.75 times in yield of neoplasia when using endomicroscopy ( $P = 0.005$ ). NBI uses optical fibers to enable a clear visualization of vessels, pit pattern and soft tissue structures. A study showed that NBI cannot be recommended as a chromoendoscopy substitute because it detected fewer lesions than chromoendoscopy in chronic colitis, although most were not dysplastic<sup>[90]</sup>.

Newer techniques that target genetic alterations rather than histological abnormalities have been proposed to increase detection efficacy. Deletions and point mutations of tumor-suppressor genes such as *p53*, *Rb*, *APC*, *mc* and the Sialosyl-Tn antigen have been found in dysplastic lesions and could be a useful tool for early diagnosis<sup>[91,92]</sup>. DNA evaluation by flow cytometry could reveal aneuploidy and predict suspicious areas likely to progress to CRC. The main drawback is that aneuploidy is not always a prerequisite for cancer occurrence and its presence does not always lead to malignancy.

## CHEMOPREVENTION

Many studies have investigated the potential protective effects of different drug agents against malignancy in patients with UC. Pinczowski *et al*<sup>[93]</sup> was the first to report

that CRC risk is diminished by therapy with 5-aminosalicylic acid (5-ASA) in 1994. Ever since, studies have failed to demonstrate a clear relationship between 5-ASA therapy and CRC, rendering its potential protective effect presumptive rather than definitive. Azathioprine and mercaptopurine have not been shown to have a beneficial effect with regards to CRC in IBD<sup>[85]</sup>. Likewise, research has yielded inconclusive results regarding the use of corticosteroids, nonsteroidal anti-inflammatory drugs or folates for chemopreventive purposes.

Ursodeoxycholic acid (UDCA) is a drug commonly used in PSC patients due to its safe profile and favorable effects on the biochemical parameters of the disease. *In vitro* and animal studies have revealed a chemoprophylactic effect of UDCA. UDCA appears to arrest proliferation of colon cancer cell lines *in vitro*<sup>[94]</sup>. CRC induced by N-methylnitrosourea<sup>[95]</sup> and azoxymethane<sup>[96,97]</sup> in rats appeared to respond to UDCA therapy with a decrease in size. UDCA also decreased fecal concentrations of deoxycholic acid in animals, suggesting a potential protective effect through control of bile acid concentration in colon<sup>[98]</sup>. Several molecular mechanisms have been proposed to explain the chemoprophylactic effect of UDCA, including downregulation of cyclo-oxygenase-2 expression<sup>[97]</sup>, prevention of carcinogen-induced changes in protein kinase C isoforms<sup>[99]</sup>, suppression of epidermal growth factor receptor<sup>[100]</sup>, cell cycle modulation by inhibiting the expression of cyclin D1 and promoting that of E-cadherin<sup>[101]</sup>, and stabilization of mitochondrial membranes against damaging free radicals<sup>[102]</sup>. These results triggered a number of investigations in humans in order to shed light on the real effect of UDCA. Two studies have confirmed the protective effect of the drug. Tung *et al*<sup>[103]</sup> conducted a retrospective review of 59 patients showing a reduced OR of 0.18 (95%CI: 0.05-0.61) of colonic dysplasia after ursodiol use. Pardi *et al*<sup>[104]</sup> also performed a randomized placebo controlled study evaluating the effect of UDCA in the subgroup of UC patients with concomitant PSC. Patients who received a low dose of UDCA (13-15 mg/kg per day) showed a relative risk of 0.26 for developing CRC or dysplasia. Wolf *et al*<sup>[105]</sup> showed in a retrospective study of 120 patients that there was no reduction of CRC or dysplasia in the UDCA group. A hallmark study by Eaton *et al*<sup>[106]</sup> has recently reversed the long-standing conviction that UDCA has a place in CRC prevention in PSC-IBD patients. Using high doses of UDCA (28-30 mg/kg per day), they showed an increased risk of CRC in the UDCA group. The majority of patients developed colorectal neoplasia after > 2 years of use. This association remained significant after adjusting for smoking history and UC duration. High-dose UDCA also resulted in an increased risk of liver transplantation and/or death<sup>[107]</sup>. The discrepancy between different studies can be attributed to their inherent limitations and their failure to adjust for confounding factors such as age at onset of colitis, extent of colitis, family history of CRC, cigarette smoking, use of other drugs such as 5-ASA and folate, and use of the same criteria for dysplasia classification.

There has been speculation with regard to mechanisms underlying the toxic and carcinogenic UDCA properties. The most prevalent theory implicates the alteration of colonic bile acid milieu when high doses are used. An increase in serum UDCA and LCA levels in the treatment group has been reported<sup>[108]</sup>. That combined with results from *in vitro* studies stating that bile acids stimulate cell invasion in a dose-dependent fashion and reduce apoptosis could possibly provide a plausible explanation of the differing effects when low and high UDCA doses are used<sup>[109-111]</sup>. It is therefore prudent to recommend UDCA chemoprevention only to a high-risk subset of patients, including those with a personal or family history of CRC, and those with long-standing extensive colitis. This rationale has been incorporated to recent European guidelines<sup>[112]</sup>.

In conclusion, PSC-IBD patients represent an important public health concern. Significant steps have been made towards the elucidation of the pathogenetic mechanisms underlying this complex disease. HLA and non-HLA susceptibility genes have been thoroughly studied and proven their association with PSC-IBD. Further investigations are warranted to reveal PSC- and IBD-specific genes and clarify their real impact on the disease. Genome-wide association studies could be invaluable in this direction but are severely undermined by the rarity of the disease and therefore the limited number of PSC patients that can be recruited. In terms of diagnosis, biomarkers currently in use are liver function tests and histology. A couple of new methods have been introduced to facilitate the evaluation of PSC patients. Fibroscan and a breath test assessing the elasticity and metabolic capacity of the liver respectively have paved the way for rapid, non-invasive diagnosis. Their diagnostic accuracy in PSC, however, remains under scrutiny.

CRC is a well-established risk for PSC-IBD patients. Aggressive colonoscopic surveillance is therefore imperative, even in those who have undergone liver transplantation<sup>[113]</sup>. In an attempt to relieve the socioeconomic and medical burden that PSC-IBD poses, many studies have explored potential pharmaceutical agents that may retard disease progression and protect against colorectal neoplasia. Antibiotics, immunomodulators, UDCA and antifibrotic agents have attracted the attention of researchers but their full potential has not yet been unraveled. Recent meta-analyses have demonstrated that UDCA in low to medium doses seems to have a chemoprophylactic effect, whereas high doses are carcinogenic<sup>[114,115]</sup>. Further investigations are required to test the efficacy of existing drug agents and promote the development of new ones. Understanding and harnessing molecular events seems a pivotal step towards this direction.

## REFERENCES

- 1 Wiesner RH, LaRusso NF. Clinicopathologic features of the syndrome of primary sclerosing cholangitis. *Gastroenterology* 1980; **79**: 200-206 [PMID: 7399227]
- 2 Thompson HH, Pitt HA, Tompkins RK, Longmire WP. Primary sclerosing cholangitis: a heterogenous disease. *Ann Surg* 1982; **196**: 127-136 [PMID: 7092362 DOI: 10.1097/00000658-198208000-00003]
- 3 Schwartz SI, Dale WA. Primary sclerosing cholangitis; review and report of six cases. *AMA Arch Surg* 1958; **77**: 439-451 [PMID: 13572239 DOI: 10.1001/archsurg.1958.01290030139016]
- 4 Olsson R, Danielsson A, Järnerot G, Lindström E, Lööf L, Rolny P, Rydén BO, Tysk C, Wallerstedt S. Prevalence of primary sclerosing cholangitis in patients with ulcerative colitis. *Gastroenterology* 1991; **100**: 1319-1323 [PMID: 2013375]
- 5 Atkinson AJ, Carroll WW. Sclerosing cholangitis. association with regional enteritis. *JAMA* 1964; **188**: 183-184 [PMID: 14107248 DOI: 10.1001/jama.1964.03060280085023]
- 6 Smith MP, Loe RH. Sclerosing cholangitis; review of recent case reports and associated diseases and four new cases. *Am J Surg* 1965; **110**: 239-246 [PMID: 14313190 DOI: 10.1016/0002-9610(65)90018-8]
- 7 Lee YM, Kaplan MM. Primary sclerosing cholangitis. *N Engl J Med* 1995; **332**: 924-933 [PMID: 7877651 DOI: 10.1056/NEJM199504063321406]
- 8 Fausa O, Schrumpf E, Elgjo K. Relationship of inflammatory bowel disease and primary sclerosing cholangitis. *Semin Liver Dis* 1991; **11**: 31-39 [PMID: 2047887 DOI: 10.1055/s-2008-1040420]
- 9 Chapman RW, Arborgh BA, Rhodes JM, Summerfield JA, Dick R, Scheuer PJ, Sherlock S. Primary sclerosing cholangitis: a review of its clinical features, cholangiography, and hepatic histology. *Gut* 1980; **21**: 870-877 [PMID: 7439807 DOI: 10.1136/gut.21.10.870]
- 10 Loftus EV, Harewood GC, Loftus CG, Tremaine WJ, Harmsen WS, Zinsmeister AR, Jewell DA, Sandborn WJ. PSC-IBD: a unique form of inflammatory bowel disease associated with primary sclerosing cholangitis. *Gut* 2005; **54**: 91-96 [PMID: 15591511 DOI: 10.1136/gut.2004.046615]
- 11 Aadland E, Schrumpf E, Fausa O, Elgjo K, Heilo A, Aakhus T, Gjone E. Primary sclerosing cholangitis: a long-term follow-up study. *Scand J Gastroenterol* 1987; **22**: 655-664 [PMID: 3659828 DOI: 10.3109/00365528709011139]
- 12 Verdonk RC, Dijkstra G, Haagsma EB, Shostrom VK, Van den Berg AP, Kleibeuker JH, Langnas AN, Sudan DL. Inflammatory bowel disease after liver transplantation: risk factors for recurrence and de novo disease. *Am J Transplant* 2006; **6**: 1422-1429 [PMID: 16686766 DOI: 10.1111/j.1600-6143.2006.01333.x]
- 13 Sinakos E, Samuel S, Enders F, Loftus EV, Sandborn WJ, Lindor KD. Inflammatory bowel disease in primary sclerosing cholangitis: a robust yet changing relationship. *Inflamm Bowel Dis* 2013; **19**: 1004-1009 [PMID: 23502353 DOI: 10.1097/MIB.0b013e3182802893]
- 14 Bergquist A, Lindberg G, Saarinen S, Broomé U. Increased prevalence of primary sclerosing cholangitis among first-degree relatives. *J Hepatol* 2005; **42**: 252-256 [PMID: 15664252 DOI: 10.1016/j.jhep.2004.10.011]
- 15 Bergquist A, Montgomery SM, Bahmanyar S, Olsson R, Danielsson A, Lindgren S, Prytz H, Hultcrantz R, Lööf LA, Sandberg-Gertzén H, Almer S, Askling J, Ehlin A, Ekbom A. Increased risk of primary sclerosing cholangitis and ulcerative colitis in first-degree relatives of patients with primary sclerosing cholangitis. *Clin Gastroenterol Hepatol* 2008; **6**: 939-943 [PMID: 18674735 DOI: 10.1016/j.cgh.2008.03.016]
- 16 Donaldson PT. Genetics of liver disease: immunogenetics and disease pathogenesis. *Gut* 2004; **53**: 599-608 [PMID: 15016758 DOI: 10.1136/gut.2003.031732]
- 17 Moloney MM, Thomson LJ, Strettell MJ, Williams R, Donaldson PT. Human leukocyte antigen-C genes and susceptibility to primary sclerosing cholangitis. *Hepatology* 1998; **28**: 660-662 [PMID: 9731555 DOI: 10.1002/hep.510280309]
- 18 Norris S, Kondeatis E, Collins R, Satsangi J, Clare M, Chapman R, Stephens H, Harrison P, Vaughan R, Donaldson P. Mapping MHC-encoded susceptibility and resistance in

- primary sclerosing cholangitis: the role of MICA polymorphism. *Gastroenterology* 2001; **120**: 1475-1482 [PMID: 11313318 DOI: 10.1053/gast.2001.24041]
- 19 **Wiencke K**, Spurkland A, Schrumpf E, Boberg KM. Primary sclerosing cholangitis is associated to an extended B8-DR3 haplotype including particular MICA and MICB alleles. *Hepatology* 2001; **34**: 625-630 [PMID: 11584356 DOI: 10.1053/jhep.2001.27543]
  - 20 **Mitchell SA**, Grove J, Spurkland A, Boberg KM, Fleming KA, Day CP, Schrumpf E, Chapman RW. Association of the tumour necrosis factor alpha -308 but not the interleukin 10 -627 promoter polymorphism with genetic susceptibility to primary sclerosing cholangitis. *Gut* 2001; **49**: 288-294 [PMID: 11454808 DOI: 10.1136/gut.49.2.288]
  - 21 **Spurkland A**, Saarinen S, Boberg KM, Mitchell S, Broome U, Caballeria L, Ciusani E, Chapman R, Ercilla G, Fausa O, Knutsen I, Pares A, Rosina F, Olerup O, Thorsby E, Schrumpf E. HLA class II haplotypes in primary sclerosing cholangitis patients from five European populations. *Tissue Antigens* 1999; **53**: 459-469 [PMID: 10372541 DOI: 10.1034/j.1399-0039.1999.530502.x]
  - 22 **Folseraas T**, Melum E, Rausch P, Juran BD, Ellinghaus E, Shiryayev A, Laerdahl JK, Ellinghaus D, Schramm C, Weismüller TJ, Gotthardt DN, Hov JR, Clausen OP, Weersma RK, Janse M, Boberg KM, Björnsson E, Marschall HU, Cleynen I, Rosentiel P, Holm K, Teufel A, Rust C, Gieger C, Wichmann HE, Bergquist A, Ryu E, Ponsioen CY, Runz H, Sterneck M, Vermeire S, Beuers U, Wijmenga C, Schrumpf E, Manns MP, Lazaridis KN, Schreiber S, Baines JF, Franke A, Karlsen TH. Extended analysis of a genome-wide association study in primary sclerosing cholangitis detects multiple novel risk loci. *J Hepatol* 2012; **57**: 366-375 [PMID: 22521342 DOI: 10.1016/j.jhep.2012.03.031]
  - 23 **Karlsen TH**, Boberg KM, Vatn M, Bergquist A, Hampe J, Schrumpf E, Thorsby E, Schreiber S, Lie BA. Different HLA class II associations in ulcerative colitis patients with and without primary sclerosing cholangitis. *Genes Immun* 2007; **8**: 275-278 [PMID: 17301827 DOI: 10.1038/sj.gene.6364377]
  - 24 **Janse M**, Lamberts LE, Franke L, Raychaudhuri S, Ellinghaus E, Muri Boberg K, Melum E, Folseraas T, Schrumpf E, Bergquist A, Björnsson E, Fu J, Jan Westra H, Groen HJ, Fehrmann RS, Smolonska J, van den Berg LH, Ophoff RA, Porte RJ, Weismüller TJ, Wedemeyer J, Schramm C, Sterneck M, Günther R, Braun F, Vermeire S, Henckaerts L, Wijmenga C, Ponsioen CY, Schreiber S, Karlsen TH, Franke A, Weersma RK. Three ulcerative colitis susceptibility loci are associated with primary sclerosing cholangitis and indicate a role for IL2, REL, and CARD9. *Hepatology* 2011; **53**: 1977-1985 [PMID: 21425313 DOI: 10.1002/hep.24307]
  - 25 **Grant AJ**, Lalor PF, Salmi M, Jalkanen S, Adams DH. Homing of mucosal lymphocytes to the liver in the pathogenesis of hepatic complications of inflammatory bowel disease. *Lancet* 2002; **359**: 150-157 [PMID: 11809275 DOI: 10.1016/S0140-6736(02)07374-9]
  - 26 **Broomé U**, Bergquist A. Primary sclerosing cholangitis, inflammatory bowel disease, and colon cancer. *Semin Liver Dis* 2006; **26**: 31-41 [PMID: 16496231 DOI: 10.1055/s-2006-933561]
  - 27 **Schrumpf E**, Elgjo K, Fausa O, Gjone E, Kolmannskog F, Ritland S. Sclerosing cholangitis in ulcerative colitis. *Scand J Gastroenterol* 1980; **15**: 689-697 [PMID: 7209379 DOI: 10.3109/00365528009181516]
  - 28 **Lundqvist K**, Broomé U. Differences in colonic disease activity in patients with ulcerative colitis with and without primary sclerosing cholangitis: a case control study. *Dis Colon Rectum* 1997; **40**: 451-456 [PMID: 9106695 DOI: 10.1007/BF02258391]
  - 29 **Kartheuser AH**, Dozois RR, LaRusso NF, Wiesner RH, Ilstrup DM, Schleck CD. Comparison of surgical treatment of ulcerative colitis associated with primary sclerosing cholangitis: ileal pouch-anal anastomosis versus Brooke ileostomy. *Mayo Clin Proc* 1996; **71**: 748-756 [PMID: 8691895]
  - 30 **Penna C**, Dozois R, Tremaine W, Sandborn W, LaRusso N, Schleck C, Ilstrup D. Pouchitis after ileal pouch-anal anastomosis for ulcerative colitis occurs with increased frequency in patients with associated primary sclerosing cholangitis. *Gut* 1996; **38**: 234-239 [PMID: 8801203 DOI: 10.1136/gut.38.2.234]
  - 31 **Ståhlberg D**, Veress B, Tribukait B, Broomé U. Atrophy and neoplastic transformation of the ileal pouch mucosa in patients with ulcerative colitis and primary sclerosing cholangitis: a case control study. *Dis Colon Rectum* 2003; **46**: 770-778 [PMID: 12794579 DOI: 10.1007/s10350-004-6655-5]
  - 32 **Wiesner RH**, LaRusso NF, Dozois RR, Beaver SJ. Peristomal varices after proctocolectomy in patients with primary sclerosing cholangitis. *Gastroenterology* 1986; **90**: 316-322 [PMID: 2934290]
  - 33 **Rabinovitz M**, Gavaler JS, Schade RR, Dindzans VJ, Chien MC, Van Thiel DH. Does primary sclerosing cholangitis occurring in association with inflammatory bowel disease differ from that occurring in the absence of inflammatory bowel disease? A study of sixty-six subjects. *Hepatology* 1990; **11**: 7-11 [PMID: 2295474 DOI: 10.1002/hep.1840110103]
  - 34 **Saich R**, Chapman R. Primary sclerosing cholangitis, autoimmune hepatitis and overlap syndromes in inflammatory bowel disease. *World J Gastroenterol* 2008; **14**: 331-337 [PMID: 18200656 DOI: 10.3748/wjg.14.331]
  - 35 **Crohn BB**, Rosenberg H. The sigmoidoscopic picture of chronic ulcerative colitis (non-specific). *Am J Med Sci* 1925; **170**: 220-227 [DOI: 10.1097/00000441-192508010-00006]
  - 36 **Bernstein CN**, Blanchard JF, Kliever E, Wajda A. Cancer risk in patients with inflammatory bowel disease: a population-based study. *Cancer* 2001; **91**: 854-862 [PMID: 11241255]
  - 37 **Eaden JA**, Abrams KR, Mayberry JF. The risk of colorectal cancer in ulcerative colitis: a meta-analysis. *Gut* 2001; **48**: 526-535 [PMID: 11247898 DOI: 10.1136/gut.48.4.526]
  - 38 **Gillen CD**, Andrews HA, Prior P, Allan RN. Crohn's disease and colorectal cancer. *Gut* 1994; **35**: 651-655 [PMID: 8200559]
  - 39 **Jess T**, Rungoe C, Peyrin-Biroulet L. Risk of colorectal cancer in patients with ulcerative colitis: a meta-analysis of population-based cohort studies. *Clin Gastroenterol Hepatol* 2012; **10**: 639-645 [PMID: 22289873 DOI: 10.1016/j.cgh.2012.01.010]
  - 40 **Gupta RB**, Harpaz N, Itzkowitz S, Hossain S, Matula S, Kornbluth A, Bodian C, Ullman T. Histologic inflammation is a risk factor for progression to colorectal neoplasia in ulcerative colitis: a cohort study. *Gastroenterology* 2007; **133**: 1099-1105; quiz 1340-1341 [PMID: 17919486 DOI: 10.1053/j.gastro.2007.08.001]
  - 41 **Jess T**, Loftus EV, Velayos FS, Winther KV, Tremaine WJ, Zinsmeister AR, Scott Harmsen W, Langholz E, Binder V, Munkholm P, Sandborn WJ. Risk factors for colorectal neoplasia in inflammatory bowel disease: a nested case-control study from Copenhagen county, Denmark and Olmsted county, Minnesota. *Am J Gastroenterol* 2007; **102**: 829-836 [PMID: 17222314 DOI: 10.1111/j.1572-0241.2007.01070.x]
  - 42 **Hendriksen C**, Kreiner S, Binder V. Long term prognosis in ulcerative colitis--based on results from a regional patient group from the county of Copenhagen. *Gut* 1985; **26**: 158-163 [PMID: 3967834 DOI: 10.1136/gut.26.2.158]
  - 43 **Kewenter J**, Ahlman H, Hultén L. Cancer risk in extensive ulcerative colitis. *Ann Surg* 1978; **188**: 824-828 [PMID: 736660 DOI: 10.1097/00000658-197812000-00018]
  - 44 **Jess T**, Simonsen J, Jørgensen KT, Pedersen BV, Nielsen NM, Frisch M. Decreasing risk of colorectal cancer in patients with inflammatory bowel disease over 30 years. *Gastroenterology* 2012; **143**: 375-381.e1; quiz e13-14 [PMID: 22522090 DOI: 10.1053/j.gastro.2012.04.016]
  - 45 **Broomé U**, Lindberg G, Löfberg R. Primary sclerosing cholangitis in ulcerative colitis--a risk factor for the development of dysplasia and DNA aneuploidy? *Gastroenterology* 1992; **102**: 1877-1880 [PMID: 1587406]



- 46 **D'Haens GR**, Lashner BA, Hanauer SB. Pericholangitis and sclerosing cholangitis are risk factors for dysplasia and cancer in ulcerative colitis. *Am J Gastroenterol* 1993; **88**: 1174-1178 [PMID: 8338083]
- 47 **Broomé U**, Löfberg R, Veress B, Eriksson LS. Primary sclerosing cholangitis and ulcerative colitis: evidence for increased neoplastic potential. *Hepatology* 1995; **22**: 1404-1408 [PMID: 7590655]
- 48 **Brentnall TA**, Haggitt RC, Rabinovitch PS, Kimmey MB, Bronner MP, Levine DS, Kowdley KV, Stevens AC, Crispin DA, Emond M, Rubin CE. Risk and natural history of colonic neoplasia in patients with primary sclerosing cholangitis and ulcerative colitis. *Gastroenterology* 1996; **110**: 331-338 [PMID: 8566577 DOI: 10.1053/gast.1996.v110.pm8566577]
- 49 **Leidenius MH**, Färkkilä MA, Kärkkäinen P, Taskinen EI, Kellokumpu IH, Höckerstedt KA. Colorectal dysplasia and carcinoma in patients with ulcerative colitis and primary sclerosing cholangitis. *Scand J Gastroenterol* 1997; **32**: 706-711 [PMID: 9246712 DOI: 10.3109/00365529708996522]
- 50 **Marchesa P**, Lashner BA, Lavery IC, Milsom J, Hull TL, Strong SA, Church JM, Navarro G, Fazio VW. The risk of cancer and dysplasia among ulcerative colitis patients with primary sclerosing cholangitis. *Am J Gastroenterol* 1997; **92**: 1285-1288 [PMID: 9260790]
- 51 **Shetty K**, Rybicki L, Brzezinski A, Carey WD, Lashner BA. The risk for cancer or dysplasia in ulcerative colitis patients with primary sclerosing cholangitis. *Am J Gastroenterol* 1999; **94**: 1643-1649 [PMID: 10364038 DOI: 10.1111/j.1572-0241.1999.01156.x]
- 52 **Loftus EV**, Sandborn WJ, Tremaine WJ, Mahoney DW, Zinsmeister AR, Offord KP, Melton LJ. Risk of colorectal neoplasia in patients with primary sclerosing cholangitis. *Gastroenterology* 1996; **110**: 432-440 [PMID: 8566590 DOI: 10.1053/gast.1996.v110.pm8566590]
- 53 **Nuako KW**, Ahlquist DA, Sandborn WJ, Mahoney DW, Siems DM, Zinsmeister AR. Primary sclerosing cholangitis and colorectal carcinoma in patients with chronic ulcerative colitis: a case-control study. *Cancer* 1998; **82**: 822-826 [PMID: 9486569]
- 54 **Soetikno RM**, Lin OS, Heidenreich PA, Young HS, Blackstone MO. Increased risk of colorectal neoplasia in patients with primary sclerosing cholangitis and ulcerative colitis: a meta-analysis. *Gastrointest Endosc* 2002; **56**: 48-54 [PMID: 12085034 DOI: 10.1067/mge.2002.125367]
- 55 **Brackmann S**, Andersen SN, Aamodt G, Langmark F, Clausen OP, Aadland E, Fausa O, Rydning A, Vatn MH. Relationship between clinical parameters and the colitis-colorectal cancer interval in a cohort of patients with colorectal cancer in inflammatory bowel disease. *Scand J Gastroenterol* 2009; **44**: 46-55 [PMID: 18609187 DOI: 10.1080/00365520801977568]
- 56 **Itzkowitz SH**. Inflammatory bowel disease and cancer. *Gastroenterol Clin North Am* 1997; **26**: 129-139 [PMID: 9119437 DOI: 10.1016/S0889-8553(05)70287-9]
- 57 **Sandborn WJ**. Inflammatory bowel disease and hereditary nonpolyposis colorectal cancer: is there a genetic link? *Gastroenterology* 1998; **114**: 608-609 [PMID: 9496956 DOI: 10.1016/S0016-5085(98)70548-7]
- 58 **Yin J**, Harpaz N, Tong Y, Huang Y, Laurin J, Greenwald BD, Hontanosas M, Newkirk C, Meltzer SJ. p53 point mutations in dysplastic and cancerous ulcerative colitis lesions. *Gastroenterology* 1993; **104**: 1633-1639 [PMID: 8500720]
- 59 **Redston MS**, Papadopoulos N, Caldas C, Kinzler KW, Kern SE. Common occurrence of APC and K-ras gene mutations in the spectrum of colitis-associated neoplasias. *Gastroenterology* 1995; **108**: 383-392 [PMID: 7835579 DOI: 10.1016/0016-5085(95)90064-0]
- 60 **Xie J**, Itzkowitz SH. Cancer in inflammatory bowel disease. *World J Gastroenterol* 2008; **14**: 378-389 [PMID: 18200660]
- 61 **Lees CW**, Barrett JC, Parkes M, Satsangi J. New IBD genetics: common pathways with other diseases. *Gut* 2011; **60**: 1739-1753 [PMID: 21300624 DOI: 10.1136/gut.2009.199679]
- 62 **Muise AM**, Walters TD, Glowacka WK, Griffiths AM, Ngan BY, Lan H, Xu W, Silverberg MS, Rotin D. Polymorphisms in E-cadherin (CDH1) result in a mis-localised cytoplasmic protein that is associated with Crohn's disease. *Gut* 2009; **58**: 1121-1127 [PMID: 19398441 DOI: 10.1136/gut.2008.175117]
- 63 **van Dieren JM**, Wink JC, Vissers KJ, van Marion R, Hoogmans MM, Dinjens WN, Schouten WR, Tanke HJ, Szuhai K, Kuipers EJ, van der Woude CJ, van Dekken H. Chromosomal and microsatellite instability of adenocarcinomas and dysplastic lesions (DALM) in ulcerative colitis. *Diagn Mol Pathol* 2006; **15**: 216-222 [PMID: 17122649 DOI: 10.1097/01.pdm.0000213470.92925.18]
- 64 **Tahara T**, Inoue N, Hisamatsu T, Kashiwagi K, Takaishi H, Kanai T, Watanabe M, Ishii H, Hibi T. Clinical significance of microsatellite instability in the inflamed mucosa for the prediction of colonic neoplasms in patients with ulcerative colitis. *J Gastroenterol Hepatol* 2005; **20**: 710-715 [PMID: 15853983 DOI: 10.1111/j.1440-1746.2005.03803.x]
- 65 **Pokorny RM**, Hofmeister A, Galandiuk S, Dietz AB, Cohen ND, Neiberghs HL. Crohn's disease and ulcerative colitis are associated with the DNA repair gene MLH1. *Ann Surg* 1997; **225**: 718-723; discussion 723-725 [PMID: 9230812 DOI: 10.1097/00000658-199706000-00009]
- 66 **Brentnall TA**, Rubin CE, Crispin DA, Stevens A, Batchelor RH, Haggitt RC, Bronner MP, Evans JP, McCahill LE, Bilir N. A germline substitution in the human MSH2 gene is associated with high-grade dysplasia and cancer in ulcerative colitis. *Gastroenterology* 1995; **109**: 151-155 [PMID: 7797014 DOI: 10.1016/0016-5085(95)90280-5]
- 67 **Nagengast FM**, Grubben MJ, van Munster IP. Role of bile acids in colorectal carcinogenesis. *Eur J Cancer* 1995; **31A**: 1067-1070 [PMID: 7576993 DOI: 10.1016/0959-8049(95)00216-6]
- 68 **Suzuki K**, Bruce WR. Increase by deoxycholic acid of the colonic nuclear damage induced by known carcinogens in C57BL/6J mice. *J Natl Cancer Inst* 1986; **76**: 1129-1132 [PMID: 3458949]
- 69 **Ochsenkühn T**, Bayerdörffer E, Meining A, Schinkel M, Thiede C, Nüssler V, Sackmann M, Hatz R, Neubauer A, Paumgartner G. Colonic mucosal proliferation is related to serum deoxycholic acid levels. *Cancer* 1999; **85**: 1664-1669 [PMID: 10223558]
- 70 **Bayerdörffer E**, Mannes GA, Richter WO, Ochsenkühn T, Wiebecke B, Köpcke W, Paumgartner G. Increased serum deoxycholic acid levels in men with colorectal adenomas. *Gastroenterology* 1993; **104**: 145-151 [PMID: 8419237]
- 71 **Qiao D**, Chen W, Stratagoules ED, Martinez JD. Bile acid-induced activation of activator protein-1 requires both extracellular signal-regulated kinase and protein kinase C signaling. *J Biol Chem* 2000; **275**: 15090-15098 [PMID: 10748108 DOI: 10.1074/jbc.M908890199]
- 72 **Summerton J**, Flynn M, Cooke T, Taylor I. Bile acid receptors in colorectal cancer. *Br J Surg* 1983; **70**: 549-551 [PMID: 6311314 DOI: 10.1002/bjs.1800700914]
- 73 **Hill MJ**, Melville DM, Lennard-Jones JE, Neale K, Ritchie JK. Faecal bile acids, dysplasia, and carcinoma in ulcerative colitis. *Lancet* 1987; **2**: 185-186 [PMID: 2885641 DOI: 10.1016/S0140-6736(87)90766-5]
- 74 **Lashner BA**, Heidenreich PA, Su GL, Kane SV, Hanauer SB. Effect of folate supplementation on the incidence of dysplasia and cancer in chronic ulcerative colitis. A case-control study. *Gastroenterology* 1989; **97**: 255-259 [PMID: 2568304]
- 75 **Moody GA**, Jayanthi V, Probert CS, Mac Kay H, Mayberry JF. Long-term therapy with sulphasalazine protects against colorectal cancer risk and compliance with treatment in Leicestershire. *Eur J Gastroenterol Hepatol* 1996; **8**: 1179-1183 [PMID: 8980937]
- 76 **Biancone L**, Michetti P, Travis S, Escher JC, Moser G, Forbes A, Hoffmann JC, Dignass A, Gionchetti P, Jantschek G,



- Kiesslich R, Kolacek S, Mitchell R, Panes J, Soderholm J, Vucelic B, Stange E. European evidence-based Consensus on the management of ulcerative colitis: Special situations. *J Crohns Colitis* 2008; **2**: 63-92 [PMID: 21172196 DOI: 10.1016/j.crohns.2007.12.001]
- 77 **Farraye FA**, Odze RD, Eaden J, Itzkowitz SH, McCabe RP, Dassopoulos T, Lewis JD, Ullman TA, James T, McLeod R, Burgart LJ, Allen J, Brill JV. AGA medical position statement on the diagnosis and management of colorectal neoplasia in inflammatory bowel disease. *Gastroenterology* 2010; **138**: 738-745 [PMID: 20141808 DOI: 10.1053/j.gastro.2009.12.037]
- 78 **Kitiyakara T**, Chapman RW. Chemoprevention and screening in primary sclerosing cholangitis. *Postgrad Med J* 2008; **84**: 228-237 [PMID: 18508979 DOI: 10.1136/pgmj.2007.064592]
- 79 **Imam MH**, Thackeray EW, Lindor KD. Colonic neoplasia in young patients with inflammatory bowel disease and primary sclerosing cholangitis. *Colorectal Dis* 2013; **15**: 198-203 [PMID: 22712545 DOI: 10.1111/j.1463-1318.2012.03133.x]
- 80 **Riddell RH**, Goldman R, Ransohoff DF, Appelman HD, Fenoglio CM, Haggitt RC, Ahren C, Correa P, Hamilton SR, Morson BC. Dysplasia in inflammatory bowel disease: standardized classification with provisional clinical applications. *Hum Pathol* 1983; **14**: 931-968 [PMID: 6629368 DOI: 10.1016/S0046-8177(83)80175-0]
- 81 **Connell WR**, Lennard-Jones JE, Williams CB, Talbot IC, Price AB, Wilkinson KH. Factors affecting the outcome of endoscopic surveillance for cancer in ulcerative colitis. *Gastroenterology* 1994; **107**: 934-944 [PMID: 7926483]
- 82 **Ullman TA**, Loftus EV, Kakar S, Burgart LJ, Sandborn WJ, Tremaine WJ. The fate of low grade dysplasia in ulcerative colitis. *Am J Gastroenterol* 2002; **97**: 922-927 [PMID: 12008669 DOI: 10.1111/j.1572-0241.2002.05610.x]
- 83 **Befrits R**, Ljung T, Jaramillo E, Rubio C. Low-grade dysplasia in extensive, long-standing inflammatory bowel disease: a follow-up study. *Dis Colon Rectum* 2002; **45**: 615-620 [PMID: 12004210 DOI: 10.1007/s10350-004-6255-4]
- 84 **Lim CH**, Dixon MF, Vail A, Forman D, Lynch DA, Axon AT. Ten year follow up of ulcerative colitis patients with and without low grade dysplasia. *Gut* 2003; **52**: 1127-1132 [PMID: 12865270 DOI: 10.1136/gut.52.8.1127]
- 85 **Zisman TL**, Rubin DT. Colorectal cancer and dysplasia in inflammatory bowel disease. *World J Gastroenterol* 2008; **14**: 2662-2669 [PMID: 18461651 DOI: 10.3748/wjg.14.2662]
- 86 **Bernstein CN**, Weinstein WM, Levine DS, Shanahan F. Physicians' perceptions of dysplasia and approaches to surveillance colonoscopy in ulcerative colitis. *Am J Gastroenterol* 1995; **90**: 2106-2114 [PMID: 8540497]
- 87 **Eaden JA**, Ward BA, Mayberry JF. How gastroenterologists screen for colonic cancer in ulcerative colitis: an analysis of performance. *Gastrointest Endosc* 2000; **51**: 123-128 [PMID: 10650251 DOI: 10.1016/S0016-5107(00)70405-6]
- 88 **Hurlstone DP**, Sanders DS, Lobo AJ, McAlindon ME, Cross SS. Indigo carmine-assisted high-magnification chromoscopic colonoscopy for the detection and characterisation of intraepithelial neoplasia in ulcerative colitis: a prospective evaluation. *Endoscopy* 2005; **37**: 1186-1192 [PMID: 16329015 DOI: 10.1055/s-2005-921032]
- 89 **Kiesslich R**, Hoffman A, Neurath MF. Colonoscopy, tumors, and inflammatory bowel disease - new diagnostic methods. *Endoscopy* 2006; **38**: 5-10 [PMID: 16429347 DOI: 10.1055/s-2005-921122]
- 90 **Efthymiou M**, Allen PB, Taylor AC, Desmond PV, Jayasakera C, De Cruz P, Kamm MA. Chromoendoscopy versus narrow band imaging for colonic surveillance in inflammatory bowel disease. *Inflamm Bowel Dis* 2013; **19**: 2132-2138 [PMID: 23899540 DOI: 10.1097/MIB.0b013e31829637b9]
- 91 **Itzkowitz SH**, Young E, Dubois D, Harpaz N, Bodian C, Chen A, Sachar DB. Sialosyl-Tn antigen is prevalent and precedes dysplasia in ulcerative colitis: a retrospective case-control study. *Gastroenterology* 1996; **110**: 694-704 [PMID: 8608878 DOI: 10.1053/gast.1996.v110.pm8608878]
- 92 **Greenwald BD**, Harpaz N, Yin J, Huang Y, Tong Y, Brown VL, McDaniel T, Newkirk C, Resau JH, Meltzer SJ. Loss of heterozygosity affecting the p53, Rb, and mcc/apc tumor suppressor gene loci in dysplastic and cancerous ulcerative colitis. *Cancer Res* 1992; **52**: 741-745 [PMID: 1346256]
- 93 **Pinczowski D**, Ekblom A, Baron J, Yuen J, Adami HO. Risk factors for colorectal cancer in patients with ulcerative colitis: a case-control study. *Gastroenterology* 1994; **107**: 117-120 [PMID: 7912678]
- 94 **Martinez JD**, Stratagoules ED, LaRue JM, Powell AA, Gause PR, Craven MT, Payne CM, Powell MB, Gerner EW, Earnest DL. Different bile acids exhibit distinct biological effects: the tumor promoter deoxycholic acid induces apoptosis and the chemopreventive agent ursodeoxycholic acid inhibits cell proliferation. *Nutr Cancer* 1998; **31**: 111-118 [PMID: 9770722 DOI: 10.1080/01635589809514689]
- 95 **Narisawa T**, Fukaura Y, Terada K, Sekiguchi H. Prevention of N-methylnitrosourea-induced colon tumorigenesis by ursodeoxycholic acid in F344 rats. *Jpn J Cancer Res* 1998; **89**: 1009-1013 [PMID: 9849578 DOI: 10.1111/j.1349-7006.1998.tb00489.x]
- 96 **Earnest DL**, Holubec H, Wali RK, Jolley CS, Bissonette M, Bhattacharyya AK, Roy H, Khare S, Brasitus TA. Chemoprevention of azoxymethane-induced colonic carcinogenesis by supplemental dietary ursodeoxycholic acid. *Cancer Res* 1994; **54**: 5071-5074 [PMID: 7923119]
- 97 **Ikegami T**, Matsuzaki Y, Shoda J, Kano M, Hirabayashi N, Tanaka N. The chemopreventive role of ursodeoxycholic acid in azoxymethane-treated rats: suppressive effects on enhanced group II phospholipase A2 expression in colonic tissue. *Cancer Lett* 1998; **134**: 129-139 [PMID: 10025872 DOI: 10.1016/S0304-3835(98)00248-1]
- 98 **Batta AK**, Salen G, Holubec H, Brasitus TA, Alberts D, Earnest DL. Enrichment of the more hydrophilic bile acid ursodeoxycholic acid in the fecal water-soluble fraction after feeding to rats with colon polyps. *Cancer Res* 1998; **58**: 1684-1687 [PMID: 9563483]
- 99 **Wali RK**, Frawley BP, Hartmann S, Roy HK, Khare S, Scaglione-Sewell BA, Earnest DL, Sitrin MD, Brasitus TA, Bissonnette M. Mechanism of action of chemoprotective ursodeoxycholate in the azoxymethane model of rat colonic carcinogenesis: potential roles of protein kinase C- $\alpha$ , - $\beta$  II, and - $\zeta$ . *Cancer Res* 1995; **55**: 5257-5264 [PMID: 7585585]
- 100 **Im E**, Martinez JD. Ursodeoxycholic acid (UDCA) can inhibit deoxycholic acid (DCA)-induced apoptosis via modulation of EGFR/Raf-1/ERK signaling in human colon cancer cells. *J Nutr* 2004; **134**: 483-486 [PMID: 14747693]
- 101 **Wali RK**, Khare S, Tretiakova M, Cohen G, Nguyen L, Hart J, Wang J, Wen M, Ramaswamy A, Joseph L, Sitrin M, Brasitus T, Bissonnette M. Ursodeoxycholic acid and F(6)-D(3) inhibit aberrant crypt proliferation in the rat azoxymethane model of colon cancer: roles of cyclin D1 and E-cadherin. *Cancer Epidemiol Biomarkers Prev* 2002; **11**: 1653-1662 [PMID: 12496057]
- 102 **Mitsuyoshi H**, Nakashima T, Sumida Y, Yoh T, Nakajima Y, Ishikawa H, Inaba K, Sakamoto Y, Okanoue T, Kashima K. Ursodeoxycholic acid protects hepatocytes against oxidative injury via induction of antioxidants. *Biochem Biophys Res Commun* 1999; **263**: 537-542 [PMID: 10491327 DOI: 10.1006/bbrc.1999.1403]
- 103 **Tung BY**, Emond MJ, Haggitt RC, Bronner MP, Kimmey MB, Kowdley KV, Brentnall TA. Ursodiol use is associated with lower prevalence of colonic neoplasia in patients with ulcerative colitis and primary sclerosing cholangitis. *Ann Intern Med* 2001; **134**: 89-95 [PMID: 11177311 DOI: 10.7326/0003-4819-134-2-200101160-00008]
- 104 **Pardi DS**, Loftus EV, Kremers WK, Keach J, Lindor KD. Ursodeoxycholic acid as a chemopreventive agent in patients with ulcerative colitis and primary sclerosing cholangitis. *Gastroenterology* 2003; **124**: 889-893 [PMID: 12671884 DOI: 10.1053/gast.2003.42888]

- 10.1053/gast.2003.50156]
- 105 **Wolf JM**, Rybicki LA, Lashner BA. The impact of ursodeoxycholic acid on cancer, dysplasia and mortality in ulcerative colitis patients with primary sclerosing cholangitis. *Aliment Pharmacol Ther* 2005; **22**: 783-788 [PMID: 16225486 DOI: 10.1111/j.1365-2036.2005.02650.x]
  - 106 **Eaton JE**, Silveira MG, Pardi DS, Sinakos E, Kowdley KV, Luketic VA, Harrison ME, McCashland T, Befeler AS, Harnois D, Jorgensen R, Petz J, Lindor KD. High-dose ursodeoxycholic acid is associated with the development of colorectal neoplasia in patients with ulcerative colitis and primary sclerosing cholangitis. *Am J Gastroenterol* 2011; **106**: 1638-1645 [PMID: 21556038 DOI: 10.1038/ajg.2011.156]
  - 107 **Lindor KD**. Ursodiol for primary sclerosing cholangitis. Mayo Primary Sclerosing Cholangitis-Ursodeoxycholic Acid Study Group. *N Engl J Med* 1997; **336**: 691-695 [PMID: 9041099 DOI: 10.1056/NEJM199703063361003]
  - 108 **Sinakos E**, Marschall HU, Kowdley KV, Befeler A, Keach J, Lindor K. Bile acid changes after high-dose ursodeoxycholic acid treatment in primary sclerosing cholangitis: Relation to disease progression. *Hepatology* 2010; **52**: 197-203 [PMID: 20564380 DOI: 10.1002/hep.23631]
  - 109 **Debruyne PR**, Bruyneel EA, Karaguni IM, Li X, Flatau G, Müller O, Zimmer A, Gespach C, Mareel MM. Bile acids stimulate invasion and haptotaxis in human colorectal cancer cells through activation of multiple oncogenic signaling pathways. *Oncogene* 2002; **21**: 6740-6750 [PMID: 12360401 DOI: 10.1038/sj.onc.1205729]
  - 110 **Baek MK**, Park JS, Park JH, Kim MH, Kim HD, Bae WK, Chung IJ, Shin BA, Jung YD. Lithocholic acid upregulates uPAR and cell invasiveness via MAPK and AP-1 signaling in colon cancer cells. *Cancer Lett* 2010; **290**: 123-128 [PMID: 19782465 DOI: 10.1016/j.canlet.2009.08.030]
  - 111 **McMillan L**, Butcher S, Wallis Y, Neoptolemos JP, Lord JM. Bile acids reduce the apoptosis-inducing effects of sodium butyrate on human colon adenoma (AA/C1) cells: implications for colon carcinogenesis. *Biochem Biophys Res Commun* 2000; **273**: 45-49 [PMID: 10873561 DOI: 10.1006/bbrc.2000.2899]
  - 112 **Chapman R**, Fevery J, Kalloo A, Nagorney DM, Boberg KM, Shneider B, Gores GJ. Diagnosis and management of primary sclerosing cholangitis. *Hepatology* 2010; **51**: 660-678 [PMID: 20101749]
  - 113 **Singh S**, Varayil JE, Loftus EV, Talwalkar JA. Incidence of colorectal cancer after liver transplantation for primary sclerosing cholangitis: a systematic review and meta-analysis. *Liver Transpl* 2013; **19**: 1361-1369 [PMID: 24019127]
  - 114 **Hansen JD**, Kumar S, Lo WK, Poulsen DM, Halai UA, Tater KC. Ursodiol and colorectal cancer or dysplasia risk in primary sclerosing cholangitis and inflammatory bowel disease: a meta-analysis. *Dig Dis Sci* 2013; **58**: 3079-3087 [PMID: 23896754 DOI: 10.1007/s10620-013-2772-0]
  - 115 **Singh S**, Khanna S, Pardi DS, Loftus EV, Talwalkar JA. Effect of ursodeoxycholic acid use on the risk of colorectal neoplasia in patients with primary sclerosing cholangitis and inflammatory bowel disease: a systematic review and meta-analysis. *Inflamm Bowel Dis* 2013; **19**: 1631-1638 [PMID: 23665966 DOI: 10.1097/MIB.0b013e318286fa61]

**P- Reviewer:** Liu ZJ **S- Editor:** Song XX **L- Editor:** Kerr C  
**E- Editor:** Wu HL



## Effects of resveratrol in experimental and clinical non-alcoholic fatty liver disease

Sara Heebøll, Karen Louise Thomsen, Steen B Pedersen, Hendrik Vilstrup, Jacob George, Henning Grønbaek

Sara Heebøll, Karen Louise Thomsen, Hendrik Vilstrup, Henning Grønbaek, Department of Hepatology and Gastroenterology, Aarhus University Hospital, 8000 Aarhus C, Denmark  
Steen B Pedersen, Department of Endocrinology, Aarhus University Hospital, 8000 Aarhus C, Denmark

Jacob George, Storr Liver Unit, Westmead Millennium Institute, Westmead Hospital and University of Sydney, Westmead, NSW 2145, Australia

**Author contributions:** Heebøll S searched the literature; Heebøll S and Grønbaek H prepared the manuscript; the remaining authors revised the manuscript and gave intellectual and editorial input; all authors approved the final version of submitted manuscript.

**Supported by** Aarhus University and the Danish Council for Independent Research, Medical Sciences, No. 11-107912; The Danish Strategic Research Council has supported the LIRMOI study on RSV effects in NAFLD and metabolic diseases, No. 10-093499; The NOVO Nordisk Foundation has supported Grønbaek H by a research grant; George J was supported by the Robert W; Storr Bequest to the Sydney Medical; Foundation, University of Sydney; a National Health and Medical Research Council of Australia (NHMRC) Program Grant No. 1053206 and Project grants 632630 and 1049857

**Correspondence to:** Henning Grønbaek, MD, PhD, Professor of Experimental Hepatology, Department of Hepatology and Gastroenterology, Aarhus University Hospital, Nørrebrogade 44, 8000 Aarhus C, Denmark. [henning.gronbaek@aarhus.rm.dk](mailto:henning.gronbaek@aarhus.rm.dk)  
Telephone: +45-7846-1546 Fax: +45-7846-2860

Received: October 30, 2013 Revised: January 22, 2014

Accepted: February 20, 2014

Published online: April 27, 2014

RSV has known anti-oxidant and anti-inflammatory effects. Here, we review the current evidence for RSV-mediated effects on NAFLD and address the different aspects of NAFLD and non-alcoholic steatohepatitis (NASH) pathogenesis with respect to free fatty acid (FFA) flux from adipose tissue, hepatic *de novo* lipogenesis, inadequate FFA  $\beta$ -oxidation and additional intra- and extrahepatic inflammatory and oxidant hits. We review the *in vivo* evidence from animal studies and clinical trials. The abundance of animal studies reports a decrease in hepatic triglyceride accumulation, liver weight and a general improvement in histological fatty liver changes, along with a reduction in circulating insulin, glucose and lipid levels. Some studies document AMPK or SIRT1 activation, and modulation of relevant markers of hepatic lipogenesis, inflammation and oxidation status. However, AMPK/SIRT1-independent actions are also likely. Clinical trials are scarce and have primarily been performed with a focus on overweight/obese participants without a focus on NAFLD/NASH and histological liver changes. Future clinical studies with appropriate design are needed to clarify the true impact of RSV treatment in NAFLD/NASH patients.

© 2014 Baishideng Publishing Group Co., Limited. All rights reserved.

**Key words:** Non-alcoholic fatty liver disease; Non-alcoholic steatohepatitis; Steatosis; Resveratrol; AMP-activated protein kinase; Silent information regulation-2 homolog 1; Anti-oxidants; Anti-inflammatory agents; Animal studies; Clinical trial

### Abstract

The prevalence of obesity and related conditions like non-alcoholic fatty liver disease (NAFLD) is increasing worldwide and therapeutic options are limited. Alternative treatment options are therefore intensively sought after. An interesting candidate is the natural polyphenol resveratrol (RSV) that activates adenosinmonophosphate-activated protein kinase (AMPK) and silent information regulation-2 homolog 1 (SIRT1). In addition,

**Core tip:** The prevalence of obesity and related conditions like non-alcoholic fatty liver disease (NAFLD) is increasing. Therapeutic options are limited and alternative treatment options are sought after. An interesting candidate is resveratrol (RSV), a known AMP-activated protein kinase and silent information regulation-2 homolog 1 activator with anti-oxidant and anti-inflammatory properties. Here, we review the current evidence

for RSV-mediated effects and address the different aspects of NAFLD and non-alcoholic steatohepatitis pathogenesis. We review the *in vivo* evidence from animal studies and clinical trials. Uniformly, animal studies report a decrease in hepatic triglyceride accumulation and improvements in histological fatty liver changes, whereas results from the few clinical trials are equivocal.

Heebøll S, Thomsen KL, Pedersen SB, Vilstrup H, George J, Grønbæk H. Effects of resveratrol in experimental and clinical non-alcoholic fatty liver disease. *World J Hepatol* 2014; 6(4): 188-198 Available from: URL: <http://www.wjg-net.com/1948-5182/full/v6/i4/188.htm> DOI: <http://dx.doi.org/10.4254/wjh.v6.i4.188>

## INTRODUCTION

The prevalence of obesity is increasing worldwide and consequently related conditions like non-alcoholic fatty liver disease (NAFLD) have increased. NAFLD now affects up to one-third of adults and a growing number of children in developed countries<sup>[1-3]</sup>. Early stages of NAFLD involve pathological accumulation of triglyceride (TG) in the liver, a fairly benign condition. However, some individuals elicit an inflammatory response that can progress to cirrhosis, cirrhosis complications and an increased risk of liver cancer<sup>[4]</sup>. NAFLD is now the third leading cause of liver transplantation in the United States<sup>[5]</sup>. Thus, NAFLD and especially the subtype non-alcoholic steatohepatitis (NASH) are thought to become a major health issue in the United States and throughout the world<sup>[6]</sup>.

Therapeutic options are limited and include weight loss, which is hard to obtain and sustain<sup>[7]</sup>, bariatric surgery, Vitamin E and glitazone treatment, especially the latter with a risk of significant side effects<sup>[8-11]</sup>. Alternative treatment options are therefore warranted and intensively sought after<sup>[12-15]</sup>.

A potential new therapeutic option is the polyphenol resveratrol (RSV). RSV is found in a number of plants, although in low concentrations. It is known as an activator of AMP-activated protein kinase (AMPK) and silent information regulation 2 homolog 1 (SIRT1), thereby mimicking a condition of caloric restriction *in vivo*. In addition, RSV has anti-oxidant and anti-inflammatory properties. All of these effects could in theory be beneficial for the treatment of NAFLD and a number of experimental and clinical studies have been performed.

The aim of the present review is to provide a comprehensive description of the rationale for RSV treatment for NAFLD and to review the present evidence from RSV intervention in experimental and clinical NAFLD studies.

## RSV ACTIONS

RSV is primarily recognized as an AMPK and SIRT1

activator<sup>[16-18]</sup>. AMPK and SIRT1 are both central in the metabolism of many different cell types, rendering RSV with pleiotropic effects in various tissues. To date, studies have been unable to determine if RSV activates AMPK, SIRT1 or both, directly or indirectly<sup>[19]</sup>, a matter of ongoing debate<sup>[20]</sup>. Regardless, the effects of the enzymes are closely interdependent. Recently, Park *et al*<sup>[21]</sup> proposed a mechanism involving a direct RSV-mediated inhibition of cAMP-specific phosphodiesterases and identified the cAMP effector protein Epac1 as a key mediator, which may lead to activation of first AMPK<sup>[21]</sup> and then SIRT1 through the up-regulation of NAD<sup>+</sup><sup>[20]</sup>. Furthermore, RSV may also act independently of AMPK/SIRT1; however, the mechanisms are not clarified.

Through the activation of AMPK, SIRT1 and alternative routes including anti-inflammatory and anti-oxidant actions, RSV may inhibit the development or progression of steatosis and steatohepatitis. Former attempts to use the AMPK activator metformin in the treatment of NAFLD have largely been abandoned because clinical studies showed no effect on histological NASH changes, despite a general decrease in hepatic steatosis and transaminase levels<sup>[22-24]</sup>.

### AMPK

The AMPK pathway regulates energy homeostasis, both intracellularly and at the whole-body level. Through the action of upstream kinases, AMPK responds to changes in the AMP/ATP ratio and thus serves as an intracellular sensor of energy levels, *e.g.*, in the situation of fasting, calorie restriction or accelerated ATP consumption<sup>[25]</sup>.

AMPK activation in the liver shuts down anabolic processes like cholesterol and TG biosynthesis by reducing the activities of, *e.g.*, sterol regulatory element-binding protein-1c (SREBP-1c) and fatty acid synthase (FAS). AMPK activation also promotes catabolic processes, *e.g.*, fatty acid (FA)  $\beta$ -oxidation by inactivation of acetyl-CoA carboxylase (ACC) and promotion of carnitine palmitoyltransferase-1 (CPT-1) activity<sup>[26-28]</sup>. *In vivo*, it has been shown that chronic AMPK activation limits TG accumulation in both high-fat and control diet fed rats<sup>[29]</sup>. These AMPK-mediated effects have been shown in *in vitro* and *in vivo* studies, using RSV as an AMPK activator<sup>[28]</sup>. As an example, RSV treatment of HepG2 cells in high glucose media dose-dependently attenuated enhanced FAS expression, increased ACC activity and elevated TG accumulation<sup>[30]</sup>.

In adipose tissue, the AMPK effects are similar, impairing lipolysis and promoting mitochondrial  $\beta$ -oxidation, thereby decreasing the level of circulating FFAs and the FFA load on the liver<sup>[26]</sup>. Both hepatic and peripheral insulin sensitivity is augmented.

### SIRT1

SIRT1 is a member of the sirtuin family and a NAD<sup>+</sup>-dependent deacetylase that acts as a master metabolic sensor of NAD<sup>+</sup>. Thus, it adapts gene expression and metabolic activity in response to the intracellular energy state. SIRT1 is mainly found in the nucleus, where it functions



as a transcriptional repressor through histone, transcription factor, co-factor and enzyme deacetylation<sup>[31]</sup>. Following the SIRT1 metabolic effects, the molecule is thought to link calorie restriction and healthy aging and/or longevity. A number of studies have confirmed this *in vivo* and *in vitro*<sup>[32-34]</sup>, while few have disputed it<sup>[35]</sup>.

In the liver, SIRT1 is implicated in the control of energy metabolism through deacetylation and activation of especially peroxisome proliferator-activated receptor gamma coactivator 1-alpha (PGC-1 $\alpha$ ) and the lipid-sensing transcription factor peroxisome proliferator-activated receptor (PPAR $\alpha$ ), resulting in increased FA  $\beta$ -oxidation<sup>[36]</sup>. PGC-1 $\alpha$  stimulates mitochondrial biogenesis, thereby increasing the mitochondrial content in hepatocytes<sup>[37]</sup>. In unison with AMPK, SIRT1 deacetylates and regulates SREBP-1c and liver X receptor (LXR), which govern lipid and cholesterol metabolism<sup>[38-41]</sup>. Adenovirus-mediated overexpression of SIRT1 specifically in mouse liver has been shown to reduce liver fat by down-regulation of SREBP-1c and FAS and up-regulation of expression of genes that control FA  $\beta$ -oxidation<sup>[42]</sup>.

SIRT1 is an inhibitor of inflammation, repressing especially NF- $\kappa$ B transcription and activation as shown in liver and adipose tissue<sup>[31,36,43]</sup>. Anti-inflammatory effects of RSV have also been demonstrated in *in vitro* and *in vivo* studies, however, better documented in adipose tissue<sup>[44-48]</sup> than in hepatic cells or tissue<sup>[18,49-52]</sup>.

Targeting SIRT1 activation for treatment of NAFLD has been suggested<sup>[53]</sup> as SIRT1 expression is decreased in dietary NAFLD models and NAFLD patients<sup>[54-56]</sup> and moderate SIRT1 overexpression protects mice from developing NAFLD<sup>[57]</sup>.

## NAFLD PATHOGENESIS

The pathogenesis of NAFLD and NASH is far from clarified and especially the factors that drive disease progression towards a more progressive, inflammatory phenotype are not fully characterized. Recently, a “multiple parallel hit hypothesis” has been proposed by Tilg and Moschen. Here, TG accumulation is viewed as an “innocent bystander”, while a number of different parallel hits lead to NASH development<sup>[58]</sup>. Thus, it appears that there are 3 types of NAFLD patients: the “Good Fat Storer” (the NAFLD patient with a benign course); “the Bad Fat Storer” (the patient who develops immediate NASH); and the “Unfortunate Good Fat Storer” (the NAFLD patient that experiences additional hits and becomes a NASH patient)<sup>[59]</sup>. Only the latter two may require pharmacological treatment however, bearing in mind that NAFLD may be an independent risk factor for type 2 diabetes<sup>[60,61]</sup>.

## STEATOSIS

Hepatic steatosis occurs most often in the setting of obesity and metabolic syndrome and is the result of lipid overload, primarily with increased free fatty acid (FFA)

flux and TG accumulation. Several mechanisms are involved<sup>[58,62]</sup> and some may be targeted directly or indirectly by RSV treatment. An illustration of the proposed RVS effects on NAFLD pathogenesis is shown in Figure 1.

### Increased FFA supply due to increased lipolysis from adipose tissue

Insulin resistance (IR) results in increased lipolysis of TG in adipose tissue, resulting in elevated levels of circulating FFAs. Hepatic uptake of both diet- and lipolysis-derived FFAs is unregulated with limitless hepatocyte uptake *via* fatty acid transporters (*e.g.*, CD36). The bulk of hepatic TG (two-thirds) is derived from circulating FFA from lipolysis<sup>[62]</sup>. RSV may decrease lipolysis in adipose tissue through improvement of peripheral insulin sensitivity, as documented in several studies<sup>[63,64]</sup>. Furthermore, RSV may favorably modulate the expression of fatty acid transporters<sup>[65-67]</sup>.

### Overnutrition

Dietary fat contributes approximately 15% to the overall FFA load on the liver<sup>[62]</sup>. Increased fat intake increases circulating FFA, whereas elevated carbohydrate intake, especially in the form of fructose, increases *de novo* lipogenesis<sup>[68]</sup>.

### Increased *de novo* hepatic lipogenesis from dietary carbohydrates and amino acids

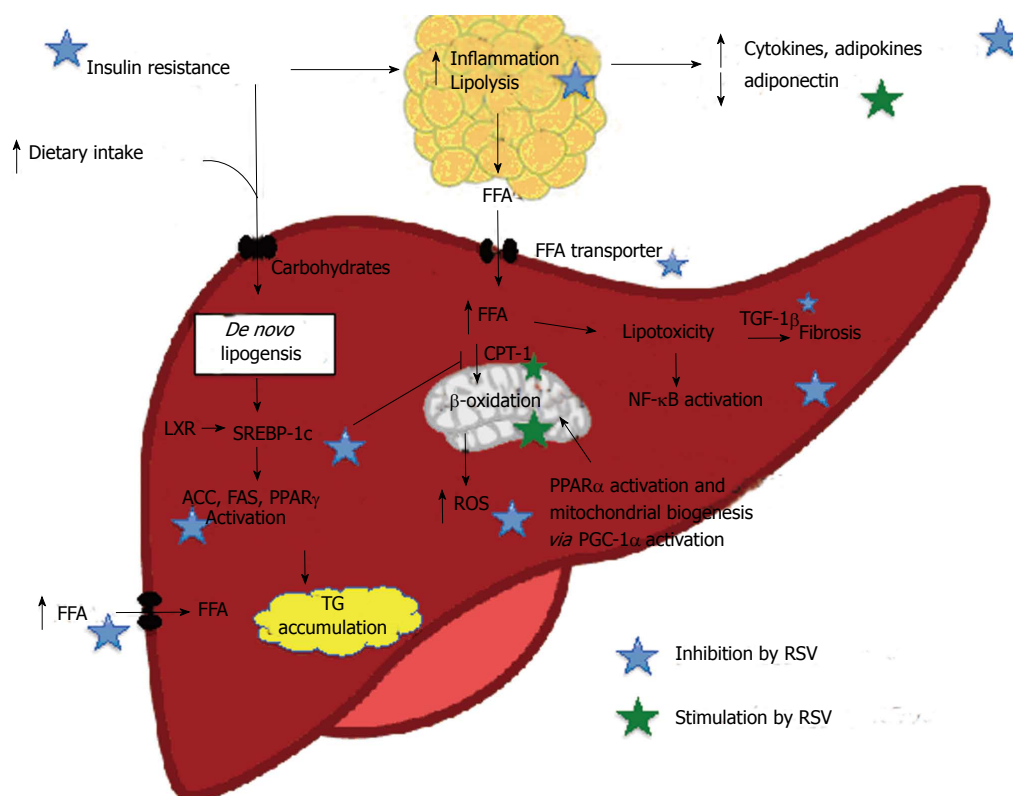
Normally, *de novo* synthesis accounts for 5% of hepatic fat content. However, in subjects with NASH, up to 25% of the hepatic fat content may be caused by *de novo* lipogenesis<sup>[62]</sup>. The process is regulated independently by insulin and glucose. In the postprandial and in the IR state, insulin stimulates the transcription factor SREBP-1c that promotes transcription of all genes involved in lipogenesis, among them ACC, FAS and peroxisome proliferator-activated receptor (PPAR $\gamma$ )<sup>[69,70]</sup>. Glucose stimulates lipogenesis through stimulation of the transcription factor carbohydrate response element binding protein (ChREBP)<sup>[71]</sup>. An upstream activator of both SREBP-1c and ChREBP is LXR, which is a transcription factor governing lipid and cholesterol metabolism<sup>[72,73]</sup>.

Results from *in vitro* and *in vivo* studies show that RSV inhibits hepatic lipogenesis by AMPK/SIRT1-mediated inhibition of SREBP-1c, ACC and FAS activity<sup>[27,28,37,44,74]</sup>.

### Inadequate fatty acid oxidation

Under normal physiological conditions, the mitochondria handle FFA by  $\beta$ -oxidation. Inadequate  $\beta$ -oxidation may be involved in NAFLD development due to the increased FFA flux through the liver<sup>[62,68]</sup> and both *de*- and increased  $\beta$ -oxidation rates are reported<sup>[75]</sup>. Regardless, SREBP-1c inhibits FA oxidation by indirect inhibition of CPT-1.

RSV may increase FA  $\beta$ -oxidation by stimulating mitochondrial biogenesis through PGC-1 $\alpha$  activation<sup>[37]</sup>, increasing mitochondrial number<sup>[37,76]</sup>, increasing uncoupling protein 2 expression<sup>[76]</sup> and by increasing CPT-1 expression and activity<sup>[27,77]</sup>.



**Figure 1** Proposed resveratrol effects on nonalcoholic fatty liver disease pathogenesis, AMP-activated protein kinase and silent information regulation-2 homolog 1 dependent and non-dependent mechanisms. Evidence of *in vivo* effect demonstrated especially a RSV-mediated inhibition of adipose tissue lipolysis, inhibition of hepatic de novo lipogenesis and an increase in FA  $\beta$ -oxidation. ACC: Acetyl-CoA carboxylase; CPT-1: Carnitine palmitoyltransferase-1; FAS: Fatty acid synthase; FFA: Free fatty acids; NAFLD: Non-alcoholic fatty liver disease; PGC-1 $\alpha$ : Peroxisome proliferator-activated receptor gamma coactivator 1  $\alpha$ ; PPAR $\gamma/\alpha$ : Peroxisome proliferator-activated receptor  $\gamma/\alpha$ ; ROS: Reactive oxygen species; SREBP-1c: Sterol regulatory element-binding protein-1c; TG: Triglyceride; TGF-1 $\beta$ : Tumor growth factor 1 $\beta$ .

## STEATOHEPATITIS

Hepatic inflammation is the hallmark of NASH and the inflammation is driven by several inflammatory hits that may include both intra- and extrahepatic factors<sup>[58]</sup>.

Among the intrahepatic factors are the excess cholesterol, FFA and lipotoxic intermediates, which elicit a number of damaging effects, collectively named “lipotoxicity”<sup>[78]</sup>. This is recently reviewed in comprehensive reviews<sup>[78,79]</sup>. Converging the harmful factors is the NF- $\kappa$ B pathway in immune cells, hepatocytes and hepatic stellate cells (HSC), resulting in an inflammatory, pro-fibrogenetic and pro-apoptotic hepatic environment. NF- $\kappa$ B activation enhances transcription of pro-inflammatory cytokines<sup>[80,81]</sup>, with increased hepatic transcription of interleukin-6 (IL-6), tumor necrosis factor- $\alpha$  (TNF- $\alpha$ ) and the TNF $\alpha$  receptor, as shown in NASH patients<sup>[82]</sup>. Kupffer cells and damaged hepatocytes release, *e.g.*, transforming growth factor 1 $\beta$  (TGF-1 $\beta$ ) that acts on quiescent HSC, inducing an activated state and thereby fibrosis. In addition, extracellular molecules, endotoxins, such as lipopolysaccharide (LPS) (*via* toll-like receptor 4), TNF $\alpha$ , IL-1, IL-6 and reactive oxygen species, can induce NF- $\kappa$ B-mediated activation of the HSCs.

The anti-inflammatory effects of RSV are also documented in the liver. Animal studies have shown reduced hepatic macrophage infiltration<sup>[51]</sup> and TNF $\alpha$  levels<sup>[49,52,83]</sup>,

as well as inhibition of the NF- $\kappa$ B pathway<sup>[50,52,83]</sup>. Only one study has focused on NASH-like fibrosis<sup>[52]</sup>, probably due to the lack of appropriate animal models. However, other hepatic fibrosis models have shown RSV-mediated mitigating effects on markers of hepatic fibrosis<sup>[84-87]</sup> and HSC activation<sup>[86,88,89]</sup>.

A number of studies report endoplasmic reticulum stress, lipid peroxidation and oxidative stress as causative or early events in NASH pathogenesis<sup>[90-93]</sup>. RSV is a known anti-oxidant compound and has been shown to lower hepatic oxidative stress in rodent diabetes and NAFLD models<sup>[49,51,94-98]</sup>. One potential mechanism is interference in the Keap1/Nrf2 pathway, leading to up-regulation of anti-oxidant enzymes<sup>[99,100]</sup>.

The extrahepatic inflammatory factors include dietary factors (*e.g.*, trans-fatty acids and fructose), gut-derived factors (*e.g.*, microbiota composition and bacterial byproducts) and adipose tissue-derived factors (*e.g.*, hypo adiponectinemia, adipo and cytokines, namely leptin, resistin, IL-6, TNF- $\alpha$  and monocyte chemotactic protein-1 (MCP-1)), that induce a state of whole-body low-grade inflammation in obesity<sup>[101]</sup>. Several lines of evidence document the anti-inflammatory effects of RSV in adipose tissue, especially by inhibiting NF- $\kappa$ B activation<sup>[46,102,103]</sup>, lowering IL-6 levels<sup>[47,104]</sup> and macrophage infiltration<sup>[103]</sup>, and modulating circulating cytokines and adipokines<sup>[45,50,103,105]</sup>. RSV-mediated reduction of LPS-

induced liver pathology and oxidative stress has also been reported<sup>[106,107]</sup>.

In summary, RSV has AMPK/SIRT1 activating, anti-inflammatory and anti-oxidant effects that may act in unison, combating the different hits in the pathogenesis of NAFLD and NASH development.

## RESVERATROL *IN VIVO*

Animal studies of RSV effects on NAFLD are numerous and span a wide variety of models, intervention periods and RSV doses. The studies can be divided into low-dose [RSV doses 7-45 mg/kg bodyweight (BW) daily] and high-dose studies (RSV 45-300 mg/kg BW daily). Some of the studies have hepatic steatosis as the primary endpoint, others as secondary. The RSV treatment is generally started from the beginning of the study and therefore most of the studies concentrate on the preventive effect of RSV and not the therapeutic effect. Almost uniformly, the studies report beneficial effects of RSV treatment on NAFLD pathology. In addition, RSV treatment in experimental models generally reduce circulating insulin and glucose levels<sup>[18,37,45,46,50-52,63,105,108-110]</sup> and, in some instances, weight<sup>[50,52,110-113]</sup>, circulating transaminases<sup>[44,52,77,110]</sup> and lipids<sup>[45,50,65,96,108,111,112]</sup>.

In Table 1 we present a list of published RSV animal studies with hepatic histological NAFLD/NASH data.

## MOUSE STUDIES

In 2006, Baur *et al.*<sup>[37]</sup> published a much-cited study on the effect of RSV on the health and survival of mice on a high-fat diet (HFD). HFD and low-dose RSV (10 mg/d) were fed to the mice from senescence to death. Besides increased survival and a number of beneficial metabolic effects, the study showed RSV-mediated hepatic AMPK activation, ACC inhibition, decreased FAS transcription and increased mitochondrial number. RSV also decreased liver weight and the degree of steatosis. This study triggered a number of other mouse studies, often using C57BL/6J diet-induced obese (DIO) mice.

Regarding NAFLD data, the studies report a decrease in hepatic TG<sup>[45,50,65,96,111,114]</sup> and/or cholesterol accumulation<sup>[45,108,111-113]</sup> and liver weight<sup>[37,65,112]</sup>, along with improvement in histological fatty liver changes<sup>[37,46,51,52,65,96,108,111,113-115]</sup>. Only a few studies report NASH changes in the histological specimens. Ahn *et al.*<sup>[65]</sup> and Li *et al.*<sup>[52]</sup> find that RSV supplementation represses development of histological steatosis and steatohepatitis and also fibrosis in the latter study. Tauriainen *et al.*<sup>[115]</sup> find that high-dose RSV represses steatosis and hepatocyte ballooning in a model with minimal hepatic inflammation.

Although tested in a few studies, only two mouse studies are able to verify RSV-mediated AMPK activation in liver tissue<sup>[105,114]</sup>. Also, no subsequent mouse studies have investigated hepatic PGC-1 $\alpha$  deacetylation as a marker of SIRT1 activation. However, other markers of AMPK/SIRT1 activation have been documented in several mouse studies, among them inhibition of FAS expression

and activation<sup>[65,109,111]</sup>, inhibition of ACC activation<sup>[97,114]</sup>, augmentation of FA  $\beta$ -oxidation<sup>[111]</sup>, inhibition of PPAR $\gamma$  and SREBP-1c expression and stimulation of PPAR $\alpha$  expression<sup>[52,65]</sup>. In mouse models, RSV treatment inhibits NF- $\kappa$ B activation<sup>[50,52]</sup> and lowers hepatic expression of inflammation markers<sup>[52]</sup>. Furthermore, oxidative stress is alleviated by RSV treatment in a number of mouse models<sup>[51,52,97]</sup>.

In a long-term study of high-dose RSV treatment alone and in combination with another polyphenolic compound, namely quercetin, transcriptomic and metabolomic data demonstrated that combination therapy results in a significant restoration of gene sets in functional pathways of glucose and lipid metabolism (glycolysis and FA  $\beta$ -oxidation), inflammation/immunity, liver function and the cardiovascular system, which were altered by HFD feeding<sup>[108]</sup>.

Also, in mutant Werner syndrome mice (showing premature signs of aging, *e.g.*, fatty liver), RSV treatment reversed liver steatosis and lipid peroxidation<sup>[109]</sup>. Microarray and biological enrichment analyses on liver tissues suggested that RSV mainly decreases lipogenesis and increases genes involved in the insulin signaling pathway and glutathione metabolism. The authors also observed a lower prevalence of hepatocellular carcinoma, however, an increase in lymphomas and other solid tumors was observed.

## RAT AND HAMSTER STUDIES

Numerous different rat models of NAFLD report on RSV effects on NAFLD relevant endpoints, along with a single hamster study. Similar to the mouse studies, the conclusions are positive overall. The studies show a decrease in liver weight<sup>[67,74,77]</sup>, hepatic TG<sup>[27,44,66,67,74,76,77]</sup> and/or cholesterol accumulation<sup>[66,67]</sup>, and histological fatty liver<sup>[49,66,67,74,76,77]</sup>.

The first to describe RSV effects on NAFLD in rats was Shang *et al.*<sup>[74]</sup>, using a HFD rat model in which the HFD was started 6 wk prior to the high-dose RSV treatment (100 mg/kg BW daily). This study therefore focused on the therapeutic effects of RSV. Besides alleviating NAFLD changes, it demonstrated that high-dose RSV treatment promotes phosphorylation and activation of AMPK and suppresses expression of FAS and SREBP-1c. This is backed by a recent study in which the HFD was added to a high amount of sucrose. Alberdi *et al.*<sup>[27]</sup> found that low-dose RSV treatment for 6 wk activates AMPK and PGC-1 $\alpha$ , increases CPT-1 and decreases ACC activities with no change in the mRNA expression of SREBP-1c, PPAR $\alpha$ , SIRT1 and PGC-1 $\alpha$ . Yet, not all rat studies find AMPK activation either. At variance, our group found no increase in AMPK phosphorylation or expression of related genes in spite of improvement in fatty liver changes, along with an increase in the hepatic mitochondrial content<sup>[76]</sup>.

Obese Zucker rats have been used in low-dose RSV studies<sup>[44,77]</sup>, with a reduction in hepatic lipid content and alanine aminotransferase levels, along with activation of

**Table 1** Rodent resveratrol studies with histological liver data

| Ref.  | Focus  | Model                              | RSV dose                             | RSV exposure (wk)           | Histology/LW             | TG/CH content | Liver AMPK activation | Suggested RSV actions/mechanisms   |
|---|--|------------------------------------|--------------------------------------|-----------------------------|--------------------------|---------------|-----------------------|--|
| Baur <i>et al</i> <sup>[37]</sup> (2006)          | Longevity                                      | Middle-aged DIO mice               | 22.4 mg/kg BW = 0.04% in diet        | 27                          | +/+                      | ND            | +                     | Elevated PGC-1 $\alpha$ deacetylation as marker of enzymatic SIRT1 activity. Phosphorylation of ACC                          |
| Ahn <i>et al</i> <sup>[65]</sup> (2008)           | NAFLD/NASH                                     | DIO mice (1% CH in diet)           | 1.25 g/kg diet                       | 8                           | +/+<br>Decrease in NASH  | +/-           | ND                    | Reduced hepatic expression of FAS, PPAR $\gamma$ , CD36. Increased PPAR $\alpha$ expression                                  |
| Kang <i>et al</i> <sup>[46]</sup> (2010)          | Insulin signaling                              | DIO mice                           | 30 mg/kg BW                          | 2                           | +/ND                     | ND            | -                     | Increased Akt phosphorylation, improving insulin signaling   |
| Labbé <i>et al</i> <sup>[109]</sup> (2011)        | NAFLD, metabolic profile, longevity            | Werner syndrome mice               | 0.04% RSV in diet                    | Life-long ( $\leq$ 22.5 mo) | +/ND                     | ND            | -                     | Decreased FAS expression<br>Decreased HCC prevalence   |
| Tauriainen <i>et al</i> <sup>[115]</sup> (2011)   | Obesity, NAFLD                                 | DIO mice                           | 2 or 4 g/kg diet                     | 15                          | +/ND                     | ND            | ND                    | Increased SIRT1 expression in liver tissue. High-dose most effective   |
| Cho <i>et al</i> <sup>[111]</sup> (2012)          | NAFLD  | DIO mice (1% CH in diet)           | 7 mg/kg BW or 30 mg/kg BW            | 10                          | +/ND                     | +/+           | ND                    | Suppressed FAS activity. Activation of FA $\beta$ -oxidation in liver. The lower dose is more efficient than the higher dose |
| Zhou <i>et al</i> <sup>[108]</sup> (2012)         | Overall transcriptomic and metabolic profiling | DIO mice                           | 0.04% or 0.02% RSV + quercetin 0.02% | 26                          | +/ND                     | -/+           | ND                    | Modulation of inflammation and FA $\beta$ -oxidation. Combination with quercetin was more effective than RSV alone           |
| Jeon <i>et al</i> <sup>[51]</sup> (2012)          | Cognitive deficit                              | DIO mice                           | 200 mg/kg BW                         | 20                          | +/ND                     | ND            | ND                    | Attenuation of hepatic lipid peroxidation and macrophage infiltration  |
| Shiozaki <i>et al</i> <sup>[97]</sup> (2012)      | Longevity                                      | SAMP10 mice                        | 0.04% RSV                            | 20                          | +/ND                     | ND            | ND                    | Inhibition of ACC. Improved mitochondrial number, redox status and activity  |
| Gao <i>et al</i> <sup>[114]</sup> (2013)          | NAFLD  | T0901317-treated mice              | 200 mg/kg BW                         | < 1                         | +/+                      | +/ND          | +                     | Inhibition of ACC. Unchanged expression SREBP-1c and related genes   |
| Li <i>et al</i> <sup>[52]</sup> (2013)            | NAFLD  | HFS mice                           | 50 mg/kg BW                          | 3                           | +/ND<br>Decrease in NASH | ND            | ND                    | Inhibition of NF- $\kappa$ B-induced inflammation and MDA-induced oxidative stress. Protection against NASH fibrosis         |
| Bujanda <i>et al</i> <sup>[49]</sup> (2008)       | NAFLD  | Fasting/feeding special diet, rats | 10 mg daily                          | 4                           | +/-                      | ND            | ND                    | Hepatic TNF- $\alpha$ decrease. Improved oxidant/antioxidant markers (MDA, NOS, SOD, <i>e.g.</i> , catalase)                 |
| Shang <i>et al</i> <sup>[74]</sup> (2008)         | NAFLD  | HFD rats                           | 100 mg/kg BW                         | 10                          | +/+                      | +/-           | +                     | Suppressed SREBP-1c and FAS gene expression  |
| Poulsen <i>et al</i> <sup>[76]</sup> (2012)       | NAFLD  | HFD rats                           | 100 mg daily                         | 8                           | +/-                      | +/ND          | -                     | Increased UCP2 expression<br>Increased mitochondrial number  |
| Gomez-Zorita <i>et al</i> <sup>[103]</sup> (2012) | NAFLD  | Obese Zucker rats                  | 15 mg/kg BW or 45 mg/kg BW           | 6                           | +/+                      | +/?           | ND                    | Increased CPT-1 $\alpha$ and ACO<br>No effect on activity of lipogenic enzymes   |
| Bagul <i>et al</i> <sup>[94]</sup> (2012)         | Oxidative stress                               | High fructose fed rats             | 10 mg/kg BW                          | 8                           | +/ND                     | ND            | ND                    | Attenuation of hepatic oxidative stress, <i>e.g.</i> , with increased level of NRF2  |
| Franco <i>et al</i> <sup>[96]</sup> (2013)        | Oxidative stress and NAFLD                     | Obese 'early weaned' rats          | 30 mg/kg BW                          | 4                           | +/ND                     | +/ND          | ND                    | Decreased markers of oxidative stress  |
| Xin <i>et al</i> <sup>[66]</sup> (2013)           | NAFLD  | HFS rats                           | 50 or 100 mg/kg BW                   | 13                          | +/ND                     | +/+           | ND                    | Decreased hepatic LDLr and SRB1 mRNA and protein express   |
| Cho <i>et al</i> <sup>[67]</sup> (2008)           | Hyperlipidemia                                 | HFD hamsters                       | 0.25 g/kg diet                       | 8                           | +/+                      | +/+           | ND                    | Decreased HMG-CoA expression and modulated lipoprotein expression  |
| Burgess <i>et al</i> <sup>[110]</sup> (2011)      | Metabolic syndrome                             | HFD mini-swine                     | 100 mg/kg daily                      | 11                          | (+)/ND                   | ND            | ND                    | Improved insulin sensitivity   |

+ positive finding; - negative finding; ND: Not determined. LW: Liver weight; BW: Body weight; TG: Triglyceride; CH: Cholesterol; AMPK: AMP-activated protein kinase; PGC-1 $\alpha$ : Peroxisome proliferator-activated receptor gamma coactivator 1  $\alpha$ ; SIRT1: Silent information regulation 2 homolog 1; ACC: Acetyl-CoA carboxylase; NAFLD/NASH: Nonalcoholic fatty liver disease/nonalcoholic steatohepatitis; DIO: Diet induced obesity; FAS: Fatty acid synthase; PPAR $\gamma$ / $\alpha$ : Peroxisome proliferator-activated receptor  $\gamma$ / $\alpha$ ; SAMP10: Senescence-accelerated mouse P10; HCC: Hepatocellular carcinoma; FA: Fatty acids; SREBP-1c: Sterol regulatory element-binding protein-1c; TNF- $\alpha$ : Tumor necrosis factor- $\alpha$ ; MDA: Malondialdehyde; NOS: Nitric oxide synthase; SOD: Superoxide dismutase; HFD: High fat diet; UCP2: Uncoupling protein 2; CPT-1 $\alpha$ : Carnitine palmitoyl transferase-1 $\alpha$ ; ACO: Acyl-coenzyme A oxidase; NRF2: Nuclear factor-like 2; HFS: High fat/sucrose diet; LDLr: Low-density lipoprotein receptor; SRB1: Scavenger receptor class B member 1; HMG-CoA: 3-hydroxy-3-methylglutaryl-coenzyme A.

AMPK and increased CPT-1 activity, which is important for the rate of FA  $\beta$ -oxidation. Resveratrol treatment also

improved the inflammatory status of visceral adipose tissue<sup>[44]</sup> and reduced liver oxidative stress<sup>[77]</sup>. Here, the ef-



fect on lipogenetic enzyme activity was equivocal.

Similar results on inflammatory and oxidative status was found by Bujanda *et al.*<sup>[49]</sup> in a model in which cycles of fasting and feeding with a high carbohydrate-fat free diet induced steatosis. Low dose RSV for 4 wk lowered hepatic TNF $\alpha$  levels and reduced markers of lipid peroxidation and hepatic oxidative stress.

To our knowledge, only one study reports no RSV effect on hepatic lipid levels. Andersen *et al.*<sup>[116]</sup> used a dietary rat model and high-dose RSV treatment for 8 wk, yet found no decrease in liver TG, FFA or cholesterol content. Also, they found no effect on liver SIRT1 protein expression.

Taken together, the current evidence shows that RSV prevents NAFLD-like hepatic steatosis in rodent NAFLD models. This may be caused by inhibition of adipose tissue lipolysis, inhibition of hepatic *de novo* lipogenesis and an increase in FA  $\beta$ -oxidation. A graphic illustration of the proposed RSV effects on NAFLD pathology is shown in Figure 1. Development of steatohepatitis may be attenuated by an inhibition of adipose tissue and hepatic inflammation and reduction of oxidative stress. However, few studies have used appropriate animal NASH models and there is only one study documenting an alleviating effect on NASH fibrosis. RSV could exert some of these effects through AMPK activation but AMPK activation is not found in all studies. Also, hepatic SIRT1 activation has not been verified in an experimental NAFLD model. Studies focusing on the therapeutic effect as opposed to the preventive effect of RSV on NAFLD and especially NASH are few but warranted.

## OTHER ANIMAL MODELS

In a porcine model of metabolic syndrome, Burgess *et al.*<sup>[110]</sup> found that high-dose RSV treatment had mitigating effects on insulin resistance and transaminase levels. Oil red O staining showed a decrease in hepatic lipid accumulation. However, a HE stain found no difference in histology between the control, HFD and HFD with RSV groups, signifying that steatosis was not sufficiently induced in this model.

## CLINICAL TRIALS

So far, only a few clinical RSV trials on efficacy outcomes have been concluded and none of these studies have focused on fatty liver disease *per se*. Two studies on obese but otherwise healthy male participants report liver data. In the study by Timmers *et al.*<sup>[117]</sup>, 11 participants received a daily dose of 150 mg RSV or placebo for 30 days in a double-blind, cross-over design. Results suggest a number of beneficial metabolic effects, among these a reduction of liver transaminases and liver fat by magnetic resonance (MR) spectroscopy. In another study, 24 participants received a dose of 1.5 g RSV or placebo daily for 4 wk<sup>[118]</sup> and there was no effect on liver fat content (MR spectroscopy) or transaminase levels. This is consistent with another study in 45 non-obese postmenopausal

women receiving a dose of 75 mg for 12 wk where no effect on liver fat (MR spectroscopy) or any other physiological parameter could be demonstrated<sup>[119]</sup>.

Future clinical studies should focus on patients with biopsy verified NAFLD and NASH to determine any efficacy of RSV treatment in this setting.

## CONCLUSION

So far, clinical studies of RSV effects on steatosis are scarce and the overall positive effects seen in rodent studies are still missing. None of the studies have included verified NAFLD patients or histological data and the studies differ significantly in the RSV dose used. New clinical studies should focus on the RSV effects in patients rather than healthy or near-healthy individuals<sup>[120]</sup>, in this case, histologically verified NAFLD/NASH patients. In this setting, the focus should be on the therapeutic effects of RSV and not its preventive effects, as reported in the majority of animal studies.

## REFERENCES

- 1 **Vernon G**, Baranova A, Younossi ZM. Systematic review: the epidemiology and natural history of non-alcoholic fatty liver disease and non-alcoholic steatohepatitis in adults. *Aliment Pharmacol Ther* 2011; **34**: 274-285 [PMID: 21623852 DOI: 10.1111/j.1365-2036.2011.04724.x]
- 2 **Welsh JA**, Karpen S, Vos MB. Increasing prevalence of non-alcoholic fatty liver disease among United States adolescents, 1988-1994 to 2007-2010. *J Pediatr* 2013; **162**: 496-500.e1 [PMID: 23084707 DOI: 10.1016/j.jpeds.2012.08.043]
- 3 **Bloomgarden ZT**. Nonalcoholic fatty liver disease and insulin resistance in youth. *Diabetes Care* 2007; **30**: 1663-1669 [PMID: 17526824 DOI: 10.2337/dc07-zb06]
- 4 **Kopec KL**, Burns D. Nonalcoholic fatty liver disease: a review of the spectrum of disease, diagnosis, and therapy. *Nutr Clin Pract* 2011; **26**: 565-576 [PMID: 21947639 DOI: 10.1177/0884533611419668]
- 5 **Charlton MR**, Burns JM, Pedersen RA, Watt KD, Heimbach JK, Dierkhising RA. Frequency and outcomes of liver transplantation for nonalcoholic steatohepatitis in the United States. *Gastroenterology* 2011; **141**: 1249-1253 [PMID: 21726509 DOI: 10.1053/j.gastro.2011.06.061]
- 6 **Schuppan D**, Gorrell MD, Klein T, Mark M, Afdhal NH. The challenge of developing novel pharmacological therapies for non-alcoholic steatohepatitis. *Liver Int* 2010; **30**: 795-808 [PMID: 20624207 DOI: 10.1111/j.1478-3231.2010.02264.x]
- 7 **Wing RR**, Phelan S. Long-term weight loss maintenance. *Am J Clin Nutr* 2005; **82**: 222S-225S [PMID: 16002825]
- 8 **Tanner BD**, Allen JW. Complications of bariatric surgery: implications for the covering physician. *Am Surg* 2009; **75**: 103-112 [PMID: 19280802]
- 9 **Klein EA**, Thompson IM, Tangen CM, Crowley JJ, Lucia MS, Goodman PJ, Minasian LM, Ford LG, Parnes HL, Gaziano JM, Karp DD, Lieber MM, Walther PJ, Klotz L, Parsons JK, Chin JL, Darke AK, Lippman SM, Goodman GE, Meyskens FL, Baker LH. Vitamin E and the risk of prostate cancer: the Selenium and Vitamin E Cancer Prevention Trial (SELECT). *JAMA* 2011; **306**: 1549-1556 [PMID: 21990298 DOI: 10.1001/jama.2011.1437]
- 10 **Bjelakovic G**, Nikolova D, Gluud LL, Simonetti RG, Gluud C. Antioxidant supplements for prevention of mortality in healthy participants and patients with various diseases. *Cochrane Database Syst Rev* 2012; **3**: CD007176 [PMID: 22419320 DOI: 10.1002/14651858.CD007176.pub2]

- 11 **Kung J**, Henry RR. Thiazolidinedione safety. *Expert Opin Drug Saf* 2012; **11**: 565-579 [PMID: 22616948 DOI: 10.1517/14740338.2012.691963]
- 12 **Kostapanos MS**, Kei A, Elisaf MS. Current role of fenofibrate in the prevention and management of non-alcoholic fatty liver disease. *World J Hepatol* 2013; **5**: 470-478 [PMID: 24073298 DOI: 10.4254/wjh.v5.i9.470]
- 13 **Hatzis G**, Ziakas P, Kavantzis N, Triantafyllou A, Sigalas P, Andreadou I, Ioannidis K, Chatzis S, Filis K, Papalampros A, Sigala F. Melatonin attenuates high fat diet-induced fatty liver disease in rats. *World J Hepatol* 2013; **5**: 160-169 [PMID: 23671720 DOI: 10.4254/wjh.v5.i4.160]
- 14 **Kelishadi R**, Farajian S, Mirlohi M. Probiotics as a novel treatment for non-alcoholic fatty liver disease; a systematic review on the current evidences. *Hepat Mon* 2013; **13**: e7233 [PMID: 23885277 DOI: 10.5812/hepatmon.7233]
- 15 **Tomeno W**, Yoneda M, Imajo K, Ogawa Y, Kessoku T, Saito S, Eguchi Y, Nakajima A. Emerging drugs for non-alcoholic steatohepatitis. *Expert Opin Emerg Drugs* 2013; **18**: 279-290 [PMID: 23848366 DOI: 10.1517/14728214.2013.811232]
- 16 **Howitz KT**, Bitterman KJ, Cohen HY, Lamming DW, Lavu S, Wood JG, Zipkin RE, Chung P, Kisielewski A, Zhang LL, Scherer B, Sinclair DA. Small molecule activators of sirtuins extend *Saccharomyces cerevisiae* lifespan. *Nature* 2003; **425**: 191-196 [PMID: 12939617 DOI: 10.1038/nature01960]
- 17 **Zang M**, Xu S, Maitland-Toolan KA, Zuccollo A, Hou X, Jiang B, Wierzbicki M, Verbeuren TJ, Cohen RA. Polyphenols stimulate AMP-activated protein kinase, lower lipids, and inhibit accelerated atherosclerosis in diabetic LDL receptor-deficient mice. *Diabetes* 2006; **55**: 2180-2191 [PMID: 16873680 DOI: 10.2337/db05-1188]
- 18 **Smith JJ**, Kenney RD, Gagne DJ, Frushour BP, Ladd W, Galonek HL, Israelian K, Song J, Razvadauskaite G, Lynch AV, Carney DP, Johnson RJ, Lavu S, Iffland A, Elliott PJ, Lambert PD, Elliston KO, Jirousek MR, Milne JC, Boss O. Small molecule activators of SIRT1 replicate signaling pathways triggered by calorie restriction in vivo. *BMC Syst Biol* 2009; **3**: 31 [PMID: 19284563 DOI: 10.1186/1752-0509-3-31]
- 19 **Price NL**, Gomes AP, Ling AJ, Duarte FV, Martin-Montalvo A, North BJ, Agarwal B, Ye L, Ramadori G, Teodoro JS, Hubbard BP, Varela AT, Davis JG, Varamini B, Hafner A, Moaddel R, Rolo AP, Coppari R, Palmeira CM, de Cabo R, Baur JA, Sinclair DA. SIRT1 is required for AMPK activation and the beneficial effects of resveratrol on mitochondrial function. *Cell Metab* 2012; **15**: 675-690 [PMID: 22560220 DOI: 10.1016/j.cmet.2012.04.003]
- 20 **Um JH**, Park SJ, Kang H, Yang S, Foretz M, McBurney MW, Kim MK, Viollet B, Chung JH. AMP-activated protein kinase-deficient mice are resistant to the metabolic effects of resveratrol. *Diabetes* 2010; **59**: 554-563 [PMID: 19934007 DOI: 10.2337/db09-0482]
- 21 **Park SJ**, Ahmad F, Philp A, Baar K, Williams T, Luo H, Ke H, Rehmann H, Taussig R, Brown AL, Kim MK, Beaven MA, Burgin AB, Manganiello V, Chung JH. Resveratrol ameliorates aging-related metabolic phenotypes by inhibiting cAMP phosphodiesterases. *Cell* 2012; **148**: 421-433 [PMID: 22304913 DOI: 10.1016/j.cell.2012.01.017]
- 22 **Haukeland JW**, Konopski Z, Eggesbø HB, von Volkmann HL, Raschpichler G, Bjørø K, Haaland T, Løberg EM, Birke-land K. Metformin in patients with non-alcoholic fatty liver disease: a randomized, controlled trial. *Scand J Gastroenterol* 2009; **44**: 853-860 [PMID: 19811343 DOI: 10.1080/00365520902845268]
- 23 **Omer Z**, Cetinkalp S, Akyildiz M, Yilmaz F, Batur Y, Yilmaz C, Akarca U. Efficacy of insulin-sensitizing agents in nonalcoholic fatty liver disease. *Eur J Gastroenterol Hepatol* 2010; **22**: 18-23 [PMID: 19667999 DOI: 10.1097/MEG.0b013e3283282baf]
- 24 **Musso G**, Gambino R, Cassader M, Pagano G. A meta-analysis of randomized trials for the treatment of nonalcoholic fatty liver disease. *Hepatology* 2010; **52**: 79-104 [PMID: 20578268 DOI: 10.1002/hep.23623]
- 25 **Yang YM**, Han CY, Kim YJ, Kim SG. AMPK-associated signaling to bridge the gap between fuel metabolism and hepatocyte viability. *World J Gastroenterol* 2010; **16**: 3731-3742 [PMID: 20698033 DOI: 10.3748/wjg.v16.i30.3731]
- 26 **Viollet B**, Athea Y, Mounier R, Guigas B, Zarrinpashneh E, Horman S, Lantier L, Hebrard S, Devin-Leclerc J, Beauloye C, Foretz M, Andreelli F, Ventura-Clapier R, Bertrand L. AMPK: Lessons from transgenic and knockout animals. *Front Biosci (Landmark Ed)* 2009; **14**: 19-44 [PMID: 19273052]
- 27 **Alberdi G**, Rodríguez VM, Macarulla MT, Miranda J, Churruga I, Portillo MP. Hepatic lipid metabolic pathways modified by resveratrol in rats fed an obesogenic diet. *Nutrition* 2013; **29**: 562-567 [PMID: 23274094 DOI: 10.1016/j.nut.2012.09.011]
- 28 **Li Y**, Xu S, Mihaylova MM, Zheng B, Hou X, Jiang B, Park O, Luo Z, Lefai E, Shyy JY, Gao B, Wierzbicki M, Verbeuren TJ, Shaw RJ, Cohen RA, Zang M. AMPK phosphorylates and inhibits SREBP activity to attenuate hepatic steatosis and atherosclerosis in diet-induced insulin-resistant mice. *Cell Metab* 2011; **13**: 376-388 [PMID: 21459323 DOI: 10.1016/j.cmet.2011.03.009]
- 29 **Henriksen BS**, Curtis ME, Fillmore N, Cardon BR, Thomson DM, Hancock CR. The effects of chronic AMPK activation on hepatic triglyceride accumulation and glycerol 3-phosphate acyltransferase activity with high fat feeding. *Diabetol Metab Syndr* 2013; **5**: 29 [PMID: 23725555 DOI: 10.1186/1758-5996-5-29]
- 30 **Hou X**, Xu S, Maitland-Toolan KA, Sato K, Jiang B, Ido Y, Lan F, Walsh K, Wierzbicki M, Verbeuren TJ, Cohen RA, Zang M. SIRT1 regulates hepatocyte lipid metabolism through activating AMP-activated protein kinase. *J Biol Chem* 2008; **283**: 20015-20026 [PMID: 18482975]
- 31 **Schug TT**, Li X. Sirtuin 1 in lipid metabolism and obesity. *Ann Med* 2011; **43**: 198-211 [PMID: 21345154 DOI: 10.3109/07853890.2010.547211]
- 32 **Kaerberlein M**, McVey M, Guarente L. The SIR2/3/4 complex and SIR2 alone promote longevity in *Saccharomyces cerevisiae* by two different mechanisms. *Genes Dev* 1999; **13**: 2570-2580 [PMID: 10521401]
- 33 **Tissenbaum HA**, Guarente L. Increased dosage of a sir-2 gene extends lifespan in *Caenorhabditis elegans*. *Nature* 2001; **410**: 227-230 [PMID: 11242085 DOI: 10.1038/35065638]
- 34 **Rogina B**, Helfand SL. Sir2 mediates longevity in the fly through a pathway related to calorie restriction. *Proc Natl Acad Sci USA* 2004; **101**: 15998-16003 [PMID: 15520384 DOI: 10.1073/pnas.0404184101]
- 35 **Herranz D**, Serrano M. Impact of Sirt1 on mammalian aging. *Aging (Albany NY)* 2010; **2**: 315-316 [PMID: 20562473]
- 36 **Purushotham A**, Schug TT, Xu Q, Surapureddi S, Guo X, Li X. Hepatocyte-specific deletion of SIRT1 alters fatty acid metabolism and results in hepatic steatosis and inflammation. *Cell Metab* 2009; **9**: 327-338 [PMID: 19356714 DOI: 10.1016/j.cmet.2009.02.006]
- 37 **Baur JA**, Pearson KJ, Price NL, Jamieson HA, Lerin C, Kalra A, Prabhu VV, Allard JS, Lopez-Lluch G, Lewis K, Pistell PJ, Poosala S, Becker KG, Boss O, Gwinn D, Wang M, Ramaswamy S, Fishbein KW, Spencer RG, Lakatta EG, Le Couteur D, Shaw RJ, Navas P, Puigserver P, Ingram DK, de Cabo R, Sinclair DA. Resveratrol improves health and survival of mice on a high-calorie diet. *Nature* 2006; **444**: 337-342 [PMID: 17086191 DOI: 10.1038/nature05354]
- 38 **Li X**, Zhang S, Blander G, Tse JG, Krieger M, Guarente L. SIRT1 deacetylates and positively regulates the nuclear receptor LXR. *Mol Cell* 2007; **28**: 91-106 [PMID: 17936707 DOI: 10.1016/j.molcel.2007.07.032]
- 39 **Kemper JK**, Xiao Z, Ponugoti B, Miao J, Fang S, Kanamalluru D, Tsang S, Wu SY, Chiang CM, Veenstra TD. FXR acetylation is normally dynamically regulated by p300 and SIRT1

- but constitutively elevated in metabolic disease states. *Cell Metab* 2009; **10**: 392-404 [PMID: 19883617 DOI: 10.1016/j.cmet.2009.09.009]
- 40 **Ponugoti B**, Kim DH, Xiao Z, Smith Z, Miao J, Zang M, Wu SY, Chiang CM, Veenstra TD, Kemper JK. SIRT1 deacetylates and inhibits SREBP-1C activity in regulation of hepatic lipid metabolism. *J Biol Chem* 2010; **285**: 33959-33970 [PMID: 20817729 DOI: 10.1074/jbc.M110.122978]
  - 41 **Walker AK**, Yang F, Jiang K, Ji JY, Watts JL, Purushotham A, Boss O, Hirsch ML, Ribich S, Smith JJ, Israelian K, Westphal CH, Rodgers JT, Shioda T, Elson SL, Mulligan P, Najafi-Shoushtari H, Black JC, Thakur JK, Kadyk LC, Whetstone JR, Mostoslavsky R, Puigserver P, Li X, Dyson NJ, Hart AC, Näär AM. Conserved role of SIRT1 orthologs in fasting-dependent inhibition of the lipid/cholesterol regulator SREBP. *Genes Dev* 2010; **24**: 1403-1417 [PMID: 20595232 DOI: 10.1101/gad.1901210]
  - 42 **Rodgers JT**, Puigserver P. Fasting-dependent glucose and lipid metabolic response through hepatic sirtuin 1. *Proc Natl Acad Sci USA* 2007; **104**: 12861-12866 [PMID: 17646659 DOI: 10.1073/pnas.0702509104]
  - 43 **Xie J**, Zhang X, Zhang L. Negative regulation of inflammation by SIRT1. *Pharmacol Res* 2013; **67**: 60-67 [PMID: 23098819 DOI: 10.1016/j.phrs.2012.10.010]
  - 44 **Rivera L**, Morón R, Zarzuelo A, Galisteo M. Long-term resveratrol administration reduces metabolic disturbances and lowers blood pressure in obese Zucker rats. *Biochem Pharmacol* 2009; **77**: 1053-1063 [PMID: 19100718 DOI: 10.1016/j.bcp.2008.11.027]
  - 45 **Kim S**, Jin Y, Choi Y, Park T. Resveratrol exerts anti-obesity effects via mechanisms involving down-regulation of adipogenic and inflammatory processes in mice. *Biochem Pharmacol* 2011; **81**: 1343-1351 [PMID: 21439945 DOI: 10.1016/j.bcp.2011.03.012]
  - 46 **Kang W**, Hong HJ, Guan J, Kim DG, Yang EJ, Koh G, Park D, Han CH, Lee YJ, Lee DH. Resveratrol improves insulin signaling in a tissue-specific manner under insulin-resistant conditions only: in vitro and in vivo experiments in rodents. *Metabolism* 2012; **61**: 424-433 [PMID: 21945106 DOI: 10.1016/j.metabol.2011.08.003]
  - 47 **Cullberg KB**, Olholm J, Paulsen SK, Foldager CB, Lind M, Richelsen B, Pedersen SB. Resveratrol has inhibitory effects on the hypoxia-induced inflammation and angiogenesis in human adipose tissue in vitro. *Eur J Pharm Sci* 2013; **49**: 251-257 [PMID: 23466666 DOI: 10.1016/j.ejps.2013.02.014]
  - 48 **Gonzales AM**, Orlando RA. Curcumin and resveratrol inhibit nuclear factor-kappaB-mediated cytokine expression in adipocytes. *Nutr Metab (Lond)* 2008; **5**: 17 [PMID: 18549505 DOI: 10.1186/1743-7075-5-17]
  - 49 **Bujanda L**, Hijona E, Larzabal M, Beraza M, Aldazabal P, García-Urkia N, Sarasqueta C, Cosme A, Irastorza B, González A, Arenas JI. Resveratrol inhibits nonalcoholic fatty liver disease in rats. *BMC Gastroenterol* 2008; **8**: 40 [PMID: 18782455 DOI: 10.1186/1471-230X-8-40]
  - 50 **Do GM**, Jung UJ, Park HJ, Kwon EY, Jeon SM, McGregor RA, Choi MS. Resveratrol ameliorates diabetes-related metabolic changes via activation of AMP-activated protein kinase and its downstream targets in db/db mice. *Mol Nutr Food Res* 2012; **56**: 1282-1291 [PMID: 22715031 DOI: 10.1002/mnfr.201200067]
  - 51 **Jeon BT**, Jeong EA, Shin HJ, Lee Y, Lee DH, Kim HJ, Kang SS, Cho GJ, Choi WS, Roh GS. Resveratrol attenuates obesity-associated peripheral and central inflammation and improves memory deficit in mice fed a high-fat diet. *Diabetes* 2012; **61**: 1444-1454 [PMID: 22362175 DOI: 10.2337/db11-1498]
  - 52 **Li L**, Hai J, Li Z, Zhang Y, Peng H, Li K, Weng X. Resveratrol modulates autophagy and NF- $\kappa$ B activity in a murine model for treating non-alcoholic fatty liver disease. *Food Chem Toxicol* 2014; **63**: 166-173 [PMID: 23978414 DOI: 10.1016/j.fct.2013.08.036]
  - 53 **Colak Y**, Ozturk O, Senates E, Tuncer I, Yorulmaz E, Adali G, Doganay L, Enc FY. SIRT1 as a potential therapeutic target for treatment of nonalcoholic fatty liver disease. *Med Sci Monit* 2011; **17**: HY5-HY9 [PMID: 21525818]
  - 54 **Deng XQ**, Chen LL, Li NX. The expression of SIRT1 in non-alcoholic fatty liver disease induced by high-fat diet in rats. *Liver Int* 2007; **27**: 708-715 [PMID: 17498258 DOI: 10.1111/j.1478-3231.2007.01497.x]
  - 55 **Chen LL**, Deng XQ, Li NX. [Effects of calorie restriction on SIRT1 expression in liver of nonalcoholic fatty liver disease: experiment with rats]. *Zhonghua Yixue Zazhi* 2007; **87**: 1434-1437 [PMID: 17785073]
  - 56 **Costa Cdos S**, Hammes TO, Rohden F, Margis R, Bortolotto JW, Padoin AV, Mottin CC, Guaragna RM. SIRT1 transcription is decreased in visceral adipose tissue of morbidly obese patients with severe hepatic steatosis. *Obes Surg* 2010; **20**: 633-639 [PMID: 20033348 DOI: 10.1007/s11695-009-0052-z]
  - 57 **Herranz D**, Muñoz-Martin M, Cañamero M, Mulero F, Martinez-Pastor B, Fernandez-Capetillo O, Serrano M. Sirt1 improves healthy ageing and protects from metabolic syndrome-associated cancer. *Nat Commun* 2010; **1**: 3 [PMID: 20975665 DOI: 10.1038/ncomms1001]
  - 58 **Tilg H**, Moschen AR. Evolution of inflammation in nonalcoholic fatty liver disease: the multiple parallel hits hypothesis. *Hepatology* 2010; **52**: 1836-1846 [PMID: 21038418 DOI: 10.1002/hep.24001]
  - 59 **Fujii H**, Kawada N. Inflammation and fibrogenesis in steatohepatitis. *J Gastroenterol* 2012; **47**: 215-225 [PMID: 22310735 DOI: 10.1007/s00535-012-0527-x]
  - 60 **Kim CH**, Park JY, Lee KU, Kim JH, Kim HK. Fatty liver is an independent risk factor for the development of Type 2 diabetes in Korean adults. *Diabet Med* 2008; **25**: 476-481 [PMID: 18346164 DOI: 10.1111/j.1464-5491.2008.02410.x]
  - 61 **Sung KC**, Jeong WS, Wild SH, Byrne CD. Combined influence of insulin resistance, overweight/obesity, and fatty liver as risk factors for type 2 diabetes. *Diabetes Care* 2012; **35**: 717-722 [PMID: 22338098 DOI: 10.2337/dc11-1853]
  - 62 **Donnelly KL**, Smith CI, Schwarzenberg SJ, Jessurun J, Boldt MD, Parks EJ. Sources of fatty acids stored in liver and secreted via lipoproteins in patients with nonalcoholic fatty liver disease. *J Clin Invest* 2005; **115**: 1343-1351 [PMID: 15864352 DOI: 10.1172/JCI23621]
  - 63 **Lagouge M**, Argmann C, Gerhart-Hines Z, Meziane H, Lerin C, Daussin F, Messadeq N, Milne J, Lambert P, Elliott P, Geny B, Laakso M, Puigserver P, Auwerx J. Resveratrol improves mitochondrial function and protects against metabolic disease by activating SIRT1 and PGC-1 $\alpha$ . *Cell* 2006; **127**: 1109-1122 [PMID: 17112576 DOI: 10.1016/j.cell.2006.11.013]
  - 64 **Szkudelski T**, Szkudelska K. Anti-diabetic effects of resveratrol. *Ann N Y Acad Sci* 2011; **1215**: 34-39 [PMID: 21261639 DOI: 10.1111/j.1749-6632.2010.05844.x]
  - 65 **Ahn J**, Cho I, Kim S, Kwon D, Ha T. Dietary resveratrol alters lipid metabolism-related gene expression of mice on an atherogenic diet. *J Hepatol* 2008; **49**: 1019-1028 [PMID: 18930334 DOI: 10.1016/j.jhep.2008.08.012]
  - 66 **Xin P**, Han H, Gao D, Cui W, Yang X, Ying C, Sun X, Hao L. Alleviative effects of resveratrol on nonalcoholic fatty liver disease are associated with up regulation of hepatic low density lipoprotein receptor and scavenger receptor class B type I gene expressions in rats. *Food Chem Toxicol* 2013; **52**: 12-18 [PMID: 23127599 DOI: 10.1016/j.fct.2012.10.026]
  - 67 **Cho JJ**, Ahn JY, Kim S, Choi MS, Ha TY. Resveratrol attenuates the expression of HMG-CoA reductase mRNA in hamsters. *Biochem Biophys Res Commun* 2008; **367**: 190-194 [PMID: 18166149 DOI: 10.1016/j.bbrc.2007.12.140]
  - 68 **Neuschwander-Tetri BA**. Hepatic lipotoxicity and the pathogenesis of nonalcoholic steatohepatitis: the central role of nontriglyceride fatty acid metabolites. *Hepatology* 2010; **52**: 774-788 [PMID: 20683968 DOI: 10.1002/hep.23719]



- 69 **Foretz M**, Guichard C, Ferré P, Foulle F. Sterol regulatory element binding protein-1c is a major mediator of insulin action on the hepatic expression of glucokinase and lipogenesis-related genes. *Proc Natl Acad Sci USA* 1999; **96**: 12737-12742 [PMID: 10535992]
- 70 **Shimomura I**, Bashmakov Y, Ikemoto S, Horton JD, Brown MS, Goldstein JL. Insulin selectively increases SREBP-1c mRNA in the livers of rats with streptozotocin-induced diabetes. *Proc Natl Acad Sci USA* 1999; **96**: 13656-13661 [PMID: 10570128]
- 71 **Yamashita H**, Takenoshita M, Sakurai M, Bruick RK, Henzel WJ, Shillinglaw W, Arnot D, Uyeda K. A glucose-responsive transcription factor that regulates carbohydrate metabolism in the liver. *Proc Natl Acad Sci U S A* 2001; **98**: 9116-9121 [PMID: 11470916 DOI: 10.1073/pnas.161284298]
- 72 **Joseph SB**, Laffitte BA, Patel PH, Watson MA, Matsukuma KE, Walczak R, Collins JL, Osborne TF, Tontonoz P. Direct and indirect mechanisms for regulation of fatty acid synthase gene expression by liver X receptors. *J Biol Chem* 2002; **277**: 11019-11025 [PMID: 11790787 DOI: 10.1074/jbc.M111041200]
- 73 **Repa JJ**, Liang G, Ou J, Bashmakov Y, Lobaccaro JM, Shimomura I, Shan B, Brown MS, Goldstein JL, Mangelsdorf DJ. Regulation of mouse sterol regulatory element-binding protein-1c gene (SREBP-1c) by oxysterol receptors, LXRalpha and LXRbeta. *Genes Dev* 2000; **14**: 2819-2830 [PMID: 11090130 DOI: 10.1101/gad.844900]
- 74 **Shang J**, Chen LL, Xiao FX, Sun H, Ding HC, Xiao H. Resveratrol improves non-alcoholic fatty liver disease by activating AMP-activated protein kinase. *Acta Pharmacol Sin* 2008; **29**: 698-706 [PMID: 18501116 DOI: 10.1111/j.1745-7254.2008.00807.x]
- 75 **Degli Esposti D**, Hamelin J, Bosselut N, Saffroy R, Sebah M, Pommier A, Martel C, Lemoine A. Mitochondrial roles and cytoprotection in chronic liver injury. *Biochem Res Int* 2012; **2012**: 387626 [PMID: 22745910 DOI: 10.1155/2012/387626]
- 76 **Poulsen MM**, Larsen JØ, Hamilton-Dutoit S, Clasen BF, Jessen N, Paulsen SK, Kjær TN, Richelsen B, Pedersen SB. Resveratrol up-regulates hepatic uncoupling protein 2 and prevents development of nonalcoholic fatty liver disease in rats fed a high-fat diet. *Nutr Res* 2012; **32**: 701-708 [PMID: 23084643 DOI: 10.1016/j.nutres.2012.08.004]
- 77 **Gómez-Zorita S**, Fernández-Quintela A, Macarulla MT, Aguirre L, Hijona E, Bujanda L, Milagro F, Martínez JA, Portillo MP. Resveratrol attenuates steatosis in obese Zucker rats by decreasing fatty acid availability and reducing oxidative stress. *Br J Nutr* 2012; **107**: 202-210 [PMID: 21733326 DOI: 10.1017/S0007114511002753]
- 78 **Malhi H**, Gores GJ. Molecular mechanisms of lipotoxicity in nonalcoholic fatty liver disease. *Semin Liver Dis* 2008; **28**: 360-369 [PMID: 18956292 DOI: 10.1055/s-0028-1091980]
- 79 **Alkhouiri N**, Dixon LJ, Feldstein AE. Lipotoxicity in nonalcoholic fatty liver disease: not all lipids are created equal. *Expert Rev Gastroenterol Hepatol* 2009; **3**: 445-451 [PMID: 19673631 DOI: 10.1586/egh.09.32]
- 80 **Gordon S**. Alternative activation of macrophages. *Nat Rev Immunol* 2003; **3**: 23-35 [PMID: 12511873 DOI: 10.1038/nri978]
- 81 **Tacke F**, Luedde T, Trautwein C. Inflammatory pathways in liver homeostasis and liver injury. *Clin Rev Allergy Immunol* 2009; **36**: 4-12 [PMID: 18600481 DOI: 10.1007/s12016-008-8091-0]
- 82 **Bertola A**, Bonnafous S, Anty R, Patouraux S, Saint-Paul MC, Iannelli A, Gugenheim J, Barr J, Mato JM, Le Marchand-Brustel Y, Tran A, Gual P. Hepatic expression patterns of inflammatory and immune response genes associated with obesity and NASH in morbidly obese patients. *PLoS One* 2010; **5**: e13577 [PMID: 21042596 DOI: 10.1371/journal.pone.0013577]
- 83 **Chang CC**, Chang CY, Huang JP, Hung LM. Effect of resveratrol on oxidative and inflammatory stress in liver and spleen of streptozotocin-induced type 1 diabetic rats. *Chin J Physiol* 2012; **55**: 192-201 [PMID: 22784284 DOI: 10.4077/CJP.2011.BAA012]
- 84 **Lee ES**, Shin MO, Yoon S, Moon JO. Resveratrol inhibits dimethylnitrosamine-induced hepatic fibrosis in rats. *Arch Pharm Res* 2010; **33**: 925-932 [PMID: 20607498 DOI: 10.1007/s12272-010-0616-4]
- 85 **Chávez E**, Reyes-Gordillo K, Segovia J, Shibayama M, Tsutsumi V, Vergara P, Moreno MG, Muriel P. Resveratrol prevents fibrosis, NF-kappaB activation and TGF-beta increases induced by chronic CCl4 treatment in rats. *J Appl Toxicol* 2008; **28**: 35-43 [PMID: 17429801 DOI: 10.1002/jat.1249]
- 86 **Di Pascoli M**, Diví M, Rodríguez-Vilarrupla A, Rosado E, Gracia-Sancho J, Vilaseca M, Bosch J, García-Pagán JC. Resveratrol improves intrahepatic endothelial dysfunction and reduces hepatic fibrosis and portal pressure in cirrhotic rats. *J Hepatol* 2013; **58**: 904-910 [PMID: 23262250 DOI: 10.1016/j.jhep.2012.12.012]
- 87 **Bishayee A**, Darvesh AS, Politis T, McGory R. Resveratrol and liver disease: from bench to bedside and community. *Liver Int* 2010; **30**: 1103-1114 [PMID: 20557453 DOI: 10.1111/j.1478-3231.2010.02295.x]
- 88 **Godichaud S**, Krisa S, Couronné B, Dubuisson L, Mérillon JM, Desmoulière A, Rosenbaum J. Deactivation of cultured human liver myofibroblasts by trans-resveratrol, a grapevine-derived polyphenol. *Hepatology* 2000; **31**: 922-931 [PMID: 10733549 DOI: 10.1053/he.2000.5848]
- 89 **Souza IC**, Martins LA, Coelho BP, Grivicich I, Guaragna RM, Gottfried C, Borojevic R, Guma FC. Resveratrol inhibits cell growth by inducing cell cycle arrest in activated hepatic stellate cells. *Mol Cell Biochem* 2008; **315**: 1-7 [PMID: 18454344 DOI: 10.1007/s11010-008-9781-x]
- 90 **Caldwell SH**, Chang CY, Nakamoto RK, Krugner-Higby L. Mitochondria in nonalcoholic fatty liver disease. *Clin Liver Dis* 2004; **8**: 595-617, x [PMID: 15331066 DOI: 10.1016/j.cld.2004.04.009]
- 91 **Serviddio G**, Bellanti F, Vendemiale G, Altomare E. Mitochondrial dysfunction in nonalcoholic steatohepatitis. *Expert Rev Gastroenterol Hepatol* 2011; **5**: 233-244 [PMID: 21476918 DOI: 10.1586/egh.11.11]
- 92 **Koek GH**, Liedorp PR, Bast A. The role of oxidative stress in non-alcoholic steatohepatitis. *Clin Chim Acta* 2011; **412**: 1297-1305 [PMID: 21514287 DOI: 10.1016/j.cca.2011.04.013]
- 93 **Pagliassotti MJ**. Endoplasmic reticulum stress in nonalcoholic fatty liver disease. *Annu Rev Nutr* 2012; **32**: 17-33 [PMID: 22809102 DOI: 10.1146/annurev-nutr-071811-150644]
- 94 **Bagul PK**, Middela H, Matapally S, Padiya R, Bastia T, Madhusudana K, Reddy BR, Chakravarty S, Banerjee SK. Attenuation of insulin resistance, metabolic syndrome and hepatic oxidative stress by resveratrol in fructose-fed rats. *Pharmacol Res* 2012; **66**: 260-268 [PMID: 22627169 DOI: 10.1016/j.phrs.2012.05.003]
- 95 **Rocha KK**, Souza GA, Ebaid GX, Seiva FR, Cataneo AC, Novelli EL. Resveratrol toxicity: effects on risk factors for atherosclerosis and hepatic oxidative stress in standard and high-fat diets. *Food Chem Toxicol* 2009; **47**: 1362-1367 [PMID: 19298841 DOI: 10.1016/j.fct.2009.03.010]
- 96 **Franco JG**, Lisboa PC, Lima NS, Amaral TA, Peixoto-Silva N, Resende AC, Oliveira E, Passos MC, Moura EG. Resveratrol attenuates oxidative stress and prevents steatosis and hypertension in obese rats programmed by early weaning. *J Nutr Biochem* 2013; **24**: 960-966 [PMID: 22959054 DOI: 10.1016/j.jnubio.2012.06.019]
- 97 **Shiozaki M**, Hayakawa N, Shibata M, Koike M, Uchiyama Y, Gotow T. Closer association of mitochondria with lipid droplets in hepatocytes and activation of Kupffer cells in resveratrol-treated senescence-accelerated mice. *Histochem Cell Biol* 2011; **136**: 475-489 [PMID: 21818579 DOI: 10.1007/s00418-011-0847-6]
- 98 **Palsamy P**, Sivakumar S, Subramanian S. Resveratrol attenuates hyperglycemia-mediated oxidative stress, proinflammatory



- matory cytokines and protects hepatocytes ultrastructure in streptozotocin-nicotinamide-induced experimental diabetic rats. *Chem Biol Interact* 2010; **186**: 200-210 [PMID: 20307516 DOI: 10.1016/j.cbi.2010.03.028]
- 99 **Palsamy P**, Subramanian S. Resveratrol protects diabetic kidney by attenuating hyperglycemia-mediated oxidative stress and renal inflammatory cytokines via Nrf2-Keap1 signaling. *Biochim Biophys Acta* 2011; **1812**: 719-731 [PMID: 21439372 DOI: 10.1016/j.bbdis.2011.03.008]
- 100 **Ungvari Z**, Bagi Z, Feher A, Recchia FA, Sonntag WE, Pearson K, de Cabo R, Csiszar A. Resveratrol confers endothelial protection via activation of the antioxidant transcription factor Nrf2. *Am J Physiol Heart Circ Physiol* 2010; **299**: H18-H24 [PMID: 20418481 DOI: 10.1152/ajpheart.00260.2010]
- 101 **Odegaard JI**, Chawla A. Mechanisms of macrophage activation in obesity-induced insulin resistance. *Nat Clin Pract Endocrinol Metab* 2008; **4**: 619-626 [PMID: 18838972 DOI: 10.1038/ncpendmet0976]
- 102 **Zagotta I**, Dimova EY, Funcke JB, Wabitsch M, Kietzmann T, Fischer-Posovszky P. Resveratrol suppresses PAI-1 gene expression in a human in vitro model of inflamed adipose tissue. *Oxid Med Cell Longev* 2013; **2013**: 793525 [PMID: 23819014 DOI: 10.1155/2013/793525]
- 103 **Gómez-Zorita S**, Fernández-Quintela A, Lasa A, Hijona E, Bujanda L, Portillo MP. Effects of resveratrol on obesity-related inflammation markers in adipose tissue of genetically obese rats. *Nutrition* 2013; **29**: 1374-1380 [PMID: 24012391 DOI: 10.1016/j.nut.2013.04.014]
- 104 **Olholm J**, Paulsen SK, Cullberg KB, Richelsen B, Pedersen SB. Anti-inflammatory effect of resveratrol on adipokine expression and secretion in human adipose tissue explants. *Int J Obes (Lond)* 2010; **34**: 1546-1553 [PMID: 20531350 DOI: 10.1038/ijo.2010.98]
- 105 **Chen S**, Li J, Zhang Z, Li W, Sun Y, Zhang Q, Feng X, Zhu W. Effects of resveratrol on the amelioration of insulin resistance in KKAY mice. *Can J Physiol Pharmacol* 2012; **90**: 237-242 [PMID: 22309033 DOI: 10.1139/y11-123]
- 106 **Sebai H**, Sani M, Yacoubi MT, Aouani E, Ghanem-Boughanmi N, Ben-Attia M. Resveratrol, a red wine polyphenol, attenuates lipopolysaccharide-induced oxidative stress in rat liver. *Ecotoxicol Environ Saf* 2010; **73**: 1078-1083 [PMID: 20089305 DOI: 10.1016/j.ecoenv.2009.12.031]
- 107 **Farghali H**, Cerný D, Kameníková L, Martínek J, Horínek A, Kmoníková E, Zidek Z. Resveratrol attenuates lipopolysaccharide-induced hepatitis in D-galactosamine sensitized rats: role of nitric oxide synthase 2 and heme oxygenase-1. *Nitric Oxide* 2009; **21**: 216-225 [PMID: 19796704 DOI: 10.1016/j.niox.2009.09.004]
- 108 **Zhou M**, Wang S, Zhao A, Wang K, Fan Z, Yang H, Liao W, Bao S, Zhao L, Zhang Y, Yang Y, Qiu Y, Xie G, Li H, Jia W. Transcriptomic and metabonomic profiling reveal synergistic effects of quercetin and resveratrol supplementation in high fat diet fed mice. *J Proteome Res* 2012; **11**: 4961-4971 [PMID: 22916952 DOI: 10.1021/pr3004826]
- 109 **Labbé A**, Garand C, Cogger VC, Paquet ER, Desbiens M, Le Couteur DG, Lebel M. Resveratrol improves insulin resistance hyperglycemia and hepatosteatosis but not hypertriglyceridemia, inflammation, and life span in a mouse model for Werner syndrome. *J Gerontol A Biol Sci Med Sci* 2011; **66**: 264-278 [PMID: 20974729 DOI: 10.1093/gerona/glq184]
- 110 **Burgess TA**, Robich MP, Chu LM, Bianchi C, Sellke FW. Improving glucose metabolism with resveratrol in a swine model of metabolic syndrome through alteration of signaling pathways in the liver and skeletal muscle. *Arch Surg* 2011; **146**: 556-564 [PMID: 21739664]
- 111 **Cho SJ**, Jung UJ, Choi MS. Differential effects of low-dose resveratrol on adiposity and hepatic steatosis in diet-induced obese mice. *Br J Nutr* 2012; **108**: 2166-2175 [PMID: 22414733 DOI: 10.1017/S0007114512000347]
- 112 **Chen Q**, Wang E, Ma L, Zhai P. Dietary resveratrol increases the expression of hepatic 7 $\alpha$ -hydroxylase and ameliorates hypercholesterolemia in high-fat fed C57BL/6J mice. *Lipids Health Dis* 2012; **11**: 56 [PMID: 22607622 DOI: 10.1186/1476-511X-11-56]
- 113 **Bai Y**, Mao QQ, Qin J, Zheng XY, Wang YB, Yang K, Shen HF, Xie LP. Resveratrol induces apoptosis and cell cycle arrest of human T24 bladder cancer cells in vitro and inhibits tumor growth in vivo. *Cancer Sci* 2010; **101**: 488-493 [PMID: 20028382 DOI: 10.1111/j.1349-7006.2009.01415.x]
- 114 **Gao M**, Liu D. Resveratrol suppresses T0901317-induced hepatic fat accumulation in mice. *AAPS J* 2013; **15**: 744-752 [PMID: 23591747 DOI: 10.1208/s12248-013-9473-7]
- 115 **Tauriainen E**, Luostarinen M, Martonen E, Finckenberg P, Kovalainen M, Huotari A, Herzig KH, Lecklin A, Mervaala E. Distinct effects of calorie restriction and resveratrol on diet-induced obesity and Fatty liver formation. *J Nutr Metab* 2011; **2011**: 525094 [PMID: 21977315 DOI: 10.1155/2011/525094]
- 116 **Andersen G**, Burkon A, Sulzmaier FJ, Walker JM, Leckband G, Fuhst R, Erbersdobler HF, Somoza V. High dose of dietary resveratrol enhances insulin sensitivity in healthy rats but does not lead to metabolite concentrations effective for SIRT1 expression. *Mol Nutr Food Res* 2011; **55**: 1197-1206 [PMID: 21732533 DOI: 10.1002/mnfr.201100292]
- 117 **Timmers S**, Konings E, Bilet L, Houtkooper RH, van de Weijer T, Goossens GH, Hoeks J, van der Krieken S, Ryu D, Kersten S, Moonen-Kornips E, Hesselink MK, Kunz I, Schrauwen-Hinderling VB, Blaak EE, Auwerx J, Schrauwen P. Calorie restriction-like effects of 30 days of resveratrol supplementation on energy metabolism and metabolic profile in obese humans. *Cell Metab* 2011; **14**: 612-622 [PMID: 22055504 DOI: 10.1016/j.cmet.2011.10.002]
- 118 **Poulsen MM**, Vestergaard PF, Clasen BF, Radko Y, Christensen LP, Stødkilde-Jørgensen H, Møller N, Jessen N, Pedersen SB, Jørgensen JO. High-dose resveratrol supplementation in obese men: an investigator-initiated, randomized, placebo-controlled clinical trial of substrate metabolism, insulin sensitivity, and body composition. *Diabetes* 2013; **62**: 1186-1195 [PMID: 23193181 DOI: 10.2337/db12-0975]
- 119 **Yoshino J**, Conte C, Fontana L, Mittendorfer B, Imai S, Schechtman KB, Gu C, Kunz I, Rossi Fanelli F, Patterson BW, Klein S. Resveratrol supplementation does not improve metabolic function in nonobese women with normal glucose tolerance. *Cell Metab* 2012; **16**: 658-664 [PMID: 23102619 DOI: 10.1016/j.cmet.2012.09.015]
- 120 **Smoliga JM**, Colombo ES, Campen MJ. A healthier approach to clinical trials evaluating resveratrol for primary prevention of age-related diseases in healthy populations. *Aging (Albany NY)* 2013; **5**: 495-506 [PMID: 24073437]

P- Reviewer: Fink MP S- Editor: Song XX

L- Editor: Roemmele A E- Editor: Wu HL



## Insulin sensitizers for the treatment of non-alcoholic fatty liver disease

Zeynel Abidin Ozturk, Abdurrahman Kadayifci

Zeynel Abidin Ozturk, Department of Internal Medicine, Faculty of Medicine, University of Gaziantep, 27000 Gaziantep, Turkey  
Abdurrahman Kadayifci, Division of Gastroenterology, Faculty of Medicine, University of Gaziantep, 27000 Gaziantep, Turkey  
Abdurrahman Kadayifci, Division of Gastroenterology, Massachusetts General Hospital, Boston, MA 02114, United States  
Author contributions: Ozturk ZA and Kadayifci A both contributed to this paper.

Correspondence to: Dr. Abdurrahman Kadayifci, MD, 3-H GI Associates, Zero Emerson Place, Blossom St. Massachusetts General Hospital, 100 Blossom Street, Boston, MA 02114, United States. [akadayifci@mgh.harvard.edu](mailto:akadayifci@mgh.harvard.edu)  
Telephone: +1-857-9199934 Fax: +1-617-7245997  
Received: October 28, 2013 Revised: February 27, 2014  
Accepted: March 11, 2014  
Published online: April 27, 2014

### Abstract

Non-alcoholic fatty liver disease (NAFLD) is the leading cause of liver disease in the Western world and is closely associated with metabolic syndrome, which includes hypertension, central obesity, dyslipidemia and insulin resistance. NAFLD includes a wide spectrum of liver alterations, ranging from simple hepatic steatosis to variable degrees of fibrosis, cirrhosis and even hepatocellular carcinoma. Although the etiology and progression of the disorder remain poorly understood, insulin resistance is considered to play a pivotal role in the pathogenesis. Insulin sensitizers such as biguanides, thiazolidinediones (TZDs), glucagon-like peptide-1 receptor agonists and dipeptidyl peptidase 4 inhibitors have been studied as therapeutic approaches for NAFLD in recent years. Metformin improves insulin sensitivity and serum alanine transaminase and aspartate transaminase (ALT/AST) levels in the majority of subjects; however, it has no significant effect on liver histology. TZDs improve insulin sensitivity, serum ALT/AST levels and histology in some cases, but there are some concerns about the safety of long-term therapy. Selection of appropriate patients for avoiding side effects and the treatment of underlying disease are the

main points. These drugs are the best choice for the treatment of NAFLD in patients with type 2 DM who are also candidates for treatment with an insulin sensitizer. The present review provides an overview of insulin sensitizers in the treatment of NAFLD.

© 2014 Baishideng Publishing Group Co., Limited. All rights reserved.

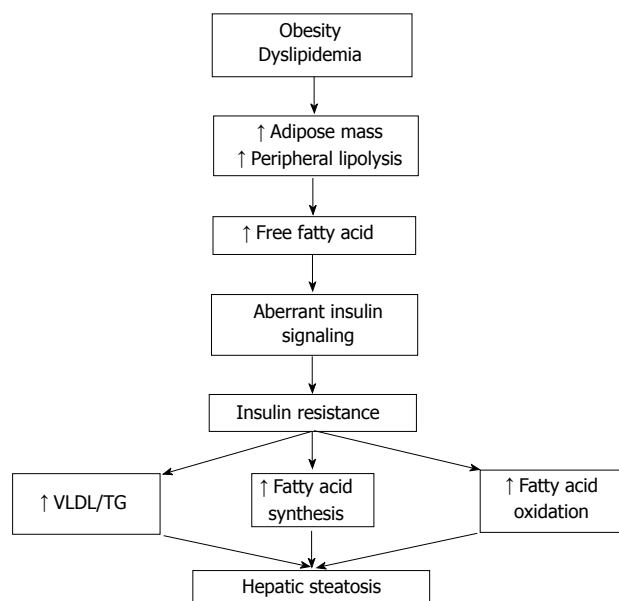
**Key words:** Insulin sensitizers; Metformin; Non-alcoholic fatty liver disease; Non-alcoholic steatohepatitis; Thiazolidinediones

**Core tip:** Non-alcoholic fatty liver disease (NAFLD) is increasing significantly due to the obesity epidemic. Insulin resistance, mainly caused by obesity, plays a primary role in NAFLD pathogenesis. Medications that improve insulin sensitivity are theorized to be useful in the treatment of NAFLD. Therefore, recent studies have explored the role of insulin sensitizers to improve biochemical and histological features of NAFLD.

Ozturk ZA, Kadayifci A. Insulin sensitizers for the treatment of non-alcoholic fatty liver disease. *World J Hepatol* 2014; 6(4): 199-206 Available from: URL: <http://www.wjgnet.com/1948-5182/full/v6/i4/199.htm> DOI: <http://dx.doi.org/10.4254/wjh.v6.i4.199>

### INTRODUCTION

Non-alcoholic fatty liver disease (NAFLD) was first described by Ludwig *et al*<sup>[1]</sup> as a liver disease that mimicked alcoholic hepatitis in histopathological features, but without a history of excessive drinking. A recent definition of NAFLD consists of evidence of hepatic steatosis either by imaging or by histology and no secondary hepatic fat accumulation from causes such as alcohol consumption, hereditary disorders and steatogenic medication<sup>[2]</sup>. The



**Figure 1** The relationship between obesity, insulin resistance and hepatic steatosis. VLDL: Very low-density lipoprotein; TG: Triglyceride.

spectrum of the disease reaches from simple hepatic steatosis to lobular inflammation (non-alcoholic steatohepatitis or NASH), fibrosis, cirrhosis and hepatocellular carcinoma<sup>[3,4]</sup>. It is the most common cause of chronic liver disease in all industrialized regions of the world<sup>[5-7]</sup>.

## BACKGROUND

The estimated prevalence of NAFLD varies in a wide range depending on the population studied and methods used for diagnosis. The disease has been reported in up to 10%-15% of normal weight individuals and 90% of obese persons<sup>[8-10]</sup>. The prevalence of NAFLD in patients with type 2 diabetes mellitus and hyperlipidemia is approximately 70% and 50%, respectively<sup>[11]</sup>. Ageing, male gender and ethnicity, such as being Hispanic, are associated factors that increase the prevalence of NAFLD. Elevated liver enzymes, histopathology of liver biopsy and imaging techniques such as ultrasound and magnetic resonance spectroscopy are different methods used for definition.

Previous studies have shown that 40% of patients with NAFLD may go on to develop NASH. The most common cause of cryptogenic cirrhosis is NASH and it progresses to advanced fibrosis in 32% to 37% of patients<sup>[12]</sup>. The patients with advanced fibrosis and cirrhosis also have higher risk of hepatocellular carcinoma<sup>[13-15]</sup>. Patients with NAFLD and NASH have increased cardiovascular mortality as well as liver-related mortality<sup>[16-18]</sup>. This is due to increased pericardial fat, increased carotid intima thickness and abnormal electrocardiogram changes<sup>[19-21]</sup>. Ramilli *et al.*<sup>[22]</sup> showed that the prevalence of carotid plaques was close to 60% in patients with NAFLD, while it was 38% in patients without NAFLD.

Type 2 DM, obesity and the associated insulin re-

sistance have been shown as independent factors for fibrosis progression<sup>[23]</sup>. Although a lot of risk factors have been defined, the major underlying mechanisms of the disease progression have not been clearly understood. The pathogenesis of NAFLD is closely related to obesity that leads to insulin resistance and significant metabolic alterations in liver occur in the setting of insulin resistance<sup>[24]</sup> (Figure 1). The prevailing hypothesis for explaining the pathway and involved mechanisms is the so-called two hit model<sup>[25,26]</sup>. At the first hit, hepatic steatosis develops due to insulin resistance and liver fat accumulation induced by excessive free fatty acid production, increased fatty acid oxidation and decreased hepatic triglyceride export. Following this step, the second hit includes increased oxidative stress which is characterized by excessive reactive oxygen species (ROS) in the liver. Progression from NAFLD to NASH is promoted by ROS through lipid peroxidation, cytochrome P450 activation and pro-inflammatory cytokine production<sup>[27]</sup>. Considering the complexity and unexpected progression of the disease, environmental and genetic factors are approved as contributors of a third hit.

Insulin resistance is the most specific metabolic risk and pathophysiological feature of NAFLD, with most patients having insulin resistance. In diabetic patients, a correlation between the severity of insulin resistance and grade of hepatic steatosis has also been shown<sup>[28]</sup>. On the basis of these data, studies of NAFLD treatment are mostly focused on improving insulin resistance and a pharmacological approach targeting improving insulin resistance are the more promising therapeutic candidates among categories that include antioxidants, lipid-lowering agents and anti-obesity drugs.

## INSULIN-SENSITIZING MEDICATIONS

### Metformin

Metformin was first used in medical practice in the 1950s and has been considered the first-line treatment of type 2 diabetes after receiving approval by the United States Food and Drug Administration (FDA) in 1994. Metformin belongs to a class of insulin-sensitizer drugs and acts through reducing hepatic glucose output, increasing insulin-stimulated glucose uptake in peripheral tissue and stimulating fatty acid oxidation in adipose tissue<sup>[29]</sup>. Adenosine monophosphate-activated protein kinase is the main player in mediating metformin effects.

Animal studies demonstrated that metformin reverses aminotransferase abnormalities, steatosis and inflammation in mouse models of NAFLD and NASH<sup>[30,31]</sup>. During last decade, many clinical trials have evaluated the useful effects of metformin on patients with NAFLD and NASH<sup>[32-41]</sup> (Table 1). Only a few of these studies were randomized and the results are conflicting.

The first nonrandomized study was carried out by Marchesini in 2001 and it included 20 biopsy proven NASH patients. For 4 mo the patients were treated with 1.5 g/d metformin and they observed a decrease in ami-

**Table 1** Summary of metformin trials in adult patients with non-alcoholic fatty liver disease/non-alcoholic steatohepatitis

| Ref.                                      | Study type             | Subject number | Therapy           | Compared with  | Duration | NAFLD vs NASH | Liver enzymes        | Histology       |
|---|------------------------|----------------|-------------------|----------------|----------|---------------|----------------------|-----------------|
| Marchesini <i>et al</i> <sup>[32]</sup>   | Open label, single arm | 20             | Metformin         | Baseline       | 4 mo     | NASH          | Improved             | Not assessed    |
| Nair <i>et al</i> <sup>[33]</sup>         | Open label, Single arm | 15             | Metformin         | Baseline       | 48 wk    | NAFLD         | Transiently improved | Mildly improved |
| Uygun <i>et al</i> <sup>[34]</sup>        | Open label, RCT        | 36             | Metformin         | Diet/Exercise  | 6 mo     | NASH          | Improved             | Not improved    |
| Bugianesi <i>et al</i> <sup>[35]</sup>    | Open label, RCT        | 110            | Metformin         | Vitamin E/Diet | 12 mo    | NAFLD         | Improved             | Improved        |
| Duseja <i>et al</i> <sup>[36]</sup>       | Open label, RCT        | 50             | Metformin         | Diet           | 6 mo     | NAFLD         | Improved             | Not assessed    |
| de Oliveira <i>et al</i> <sup>[37]</sup>  | Open label, Single arm | 20             | Metformin and NAC | Baseline       | 12 mo    | NASH          | Improved             | Improved        |
| Loomba <i>et al</i> <sup>[38]</sup>       | Open label, Single arm | 28             | Metformin         | Baseline       | 48 wk    | NASH          | Improved             | Improved        |
| Haukeland <i>et al</i> <sup>[39]</sup>    | Open label, RCT        | 48             | Metformin         | Diet/Exercise  | 6 mo     | NAFLD         | Improved             | Not improved    |
| Garinis <i>et al</i> <sup>[40]</sup>      | Open label, RCT        | 50             | Metformin         | Diet           | 6 mo     | NAFLD         | Improved             | Not assessed    |
| Shargorodsky <i>et al</i> <sup>[41]</sup> | Open label, RCT        | 63             | Metformin         | Placebo        | 12 mo    | NAFLD         | Not improved         | Not assessed    |

NAFLD: Non-alcoholic fatty liver disease; NASH: Non-alcoholic steatohepatitis; RCT: Randomized controlled trials.

notransferase levels<sup>[32]</sup>. The limitation of the study was the lack of histological evaluation and a control group. In 2004, Uygun *et al*<sup>[34]</sup> conducted the first randomized control trial comparing dietary modification to dietary modification plus metformin for six months. Aminotransferase levels and insulin sensitivity improved in the metformin treated group but there was no significant differences in necroinflammatory activity or fibrosis between groups. Bugianesi *et al*<sup>[35]</sup> presented an open label trial consisting of 110 patients who were randomized to receive either metformin 2 g/d (55 patients), vitamin E 800 IU/d (28 patients) or dietary-induced weight loss (27) patients for 12 mo. Liver transaminase levels were significantly decreased in the metformin group and there was also a histological improvement in hepatic steatosis, inflammation and fibrosis in the subset of 17 patients taking metformin. Haukeland *et al*<sup>[39]</sup> demonstrated that treatment with metformin for 6 mo was no better than placebo in terms of improvement in liver histology in patients with NAFLD. Another recent randomized control trial showed that metformin only transiently improved aminotransferase levels in patients with NASH<sup>[41]</sup>. A meta-analysis including five randomized controlled trials (RCT) concluded that metformin did not improve steatosis, lobular inflammation, hepatocellular ballooning and fibrosis in patients with NASH<sup>[42]</sup>. These results were independent of drug dose, treatment duration or diabetic state. Therewithal, a recent guideline indicates that metformin has no significant effect on liver histology and therefore it is not recommended as a specific treatment for liver disease in adults with NASH<sup>[2]</sup>. The largest RCT, “The Treatment of NAFLD in Children” (TONIC), investigated the effects of metformin in a pediatric population. The results of this study demonstrated that metformin was not associated with improvement in histology and reduction in serum alanine transaminase (ALT) levels<sup>[43]</sup>. On the basis of all these data, the AASLD guideline for the diagnosis and treatment of NAFLD concluded that metformin has no significant effect on liver histology and is not recommended as a specific treatment of NASH.

A position statement on NAFLD/NASH based on an EASL special conference has not recommended metformin for specific liver-directed therapy of NASH<sup>[44]</sup>.

Some studies demonstrated that high insulin and IGF levels have important roles in hepatic fibrosis and hepatocellular carcinoma<sup>[45,46]</sup>. An inverse association between cancer risk and long term metformin therapy has been found in previous studies. A recent meta-analysis showed that metformin was associated with an estimated 62% reduction in the risk of liver cancer among patients with type 2 diabetes<sup>[47]</sup>. Chen *et al*<sup>[48]</sup> demonstrated that each incremental year increase in metformin use results in 7% reduction in the risk of hepatocellular cancer. While the main anti-tumor effect of metformin is not clear in reducing lipogenesis and lipogenic expression, inhibition of hepatocyte proliferation and induction cell cycle arrest at G<sub>0</sub>/G<sub>1</sub> phase *via* adenosine monophosphate (AMP)-activated protein kinase, reduction endogenous reactive oxygen species are possible estimated mechanisms.

In summary, metformin improves insulin sensitivity and serum ALT and aspartate transaminase levels in the majority of subjects; however, it has no significant effect on liver histology. The precise dose and duration of treatment is unknown and the beneficial effects on serum ALT only continued during treatment. Metformin has no apparent increase in the risk of lactic acidosis<sup>[49]</sup> and unlike the thiazolidinediones, it is not encumbered by weight gain or potential hepatotoxicity. According to current data, it cannot be suggested for the specific treatment of NAFLD or NASH but can be given in patients with both NAFLD/NASH and type 2 DM.

### Thiazolidinediones

Thiazolidinediones (TZDs) are a class of oral anti-diabetic drugs that induce a nuclear transcription factor, peroxisome proliferator activated receptor- $\gamma$  (PPAR- $\gamma$ ), by binding selective ligands<sup>[50]</sup>. PPAR- $\gamma$  is predominantly expressed in adipose tissue and leads to decreased hepatic fat content and improves glycemic control with insulin sensitivity. TZDs also increase plasma adiponectin levels,



**Table 2** Summary of thiazolidinedione trials in adult patients with non-alcoholic fatty liver disease/non-alcoholic steatohepatitis

| Ref.  | Study type             | Subject number | Therapy                  | Compared with                     | Duration | NAFLD vs NASH | Liver enzymes | Histology       |
|---|------------------------|----------------|--------------------------|-----------------------------------|----------|---------------|---------------|-----------------|
| Caldwell <i>et al</i> <sup>[53]</sup>           | Open label, single arm | 10             | Troglitazone             | Baseline                          | < 6 mo   | NASH          | Improved      | Mildly improved |
| Neuschwander-Tetri <i>et al</i> <sup>[54]</sup> | Open label, single arm | 30             | Rosiglitazone            | Baseline                          | 48 wk    | NASH          | Improved      | Improved        |
| Promrat <i>et al</i> <sup>[55]</sup>            | Open label, single arm | 18             | Pioglitazone             | Baseline                          | 48 wk    | NASH          | Improved      | Improved        |
| Sanyal <i>et al</i> <sup>[56]</sup>             | Open label, RCT        | 20             | Pioglitazone + vitamin E | Vitamin E                         | 6 mo     | NASH          | Improved      | Improved        |
| Belfort <i>et al</i> <sup>[57]</sup>            | Blinded, RCT           | 55             | Pioglitazone             | Placebo                           | 6 mo     | NASH          | Improved      | Improved        |
| Idilman <i>et al</i> <sup>[58]</sup>            | Open label, RCT        | 74             | Rosiglitazone            | Metformin/life style modification | 48 wk    | NASH          | Improved      | Improved        |
| Ratziu <i>et al</i> <sup>[59]</sup>             | Blinded, RCT           | 63             | Rosiglitazone            | Placebo                           | 12 mo    | NASH          | Improved      | Improved        |
| Omer <i>et al</i> <sup>[60]</sup>               | Open label, RCT        | 64             | Rosiglitazone            | Metformin                         | 12 mo    | NAFLD         | Improved      | Improved        |
| Sanyal <i>et al</i> <sup>[61]</sup>             | Blinded, RCT           | 274            | Pioglitazone             | Placebo and vitamin E             | 24 mo    | NASH          | Improved      | Improved        |

NAFLD: Non-alcoholic fatty liver disease; NASH: Non-alcoholic steatohepatitis; RCT: Randomized controlled trials.

activate AMP-activated protein kinase and induce fatty acid stimulation<sup>[51]</sup>.

A lot of human and animal studies have investigated the effect of TZDs on liver enzymes and histology to date. In rat models, pioglitazone and rosiglitazone prevented activation of hepatic stellate cells *in vitro* and improved hepatic steatosis and fibrosis *in vivo*<sup>[52]</sup>.

The first human study was conducted by Caldwell in 2001<sup>[53]</sup>. Troglitazone was studied in 10 patients who had biopsy-proven NASH and the results were associated with improved aminotransferase levels. There was no change in histology and the drug was withdrawn from clinical use due to severe idiosyncratic hepatotoxicity. Neuschwander-Tetri *et al*<sup>[54]</sup> showed that rosiglitazone (4 mg twice daily for 48 wk) significantly decreased liver enzymes and improved steatosis, ballooning and inflammation scores in 30 patients who had biopsy-proven NASH. In addition to no change in fibrosis, the liver enzymes levels reverted to pretreatment values 6 mo after withdrawal of the drug. Clinical trials evaluating the effect of thiazolidinediones on patients with NAFLD and NASH are summarized in Table 2<sup>[53-61]</sup>. Omer *et al*<sup>[60]</sup> conducted an open label RCT including biopsy-proven NAFLD individuals to compare rosiglitazone with metformin. After 12 mo treatment, study results reported that rosiglitazone was more effective in metabolic control and histological improvement but fibrosis did not change significantly.

An early study with pioglitazone in 18 patients who had biopsy-proven NASH resulted in a decrease in aminotransferase levels with histological improvement<sup>[55]</sup>. The first double-blind, placebo-controlled trial using pioglitazone compared with placebo included 55 patients with NASH for 6 mo<sup>[57]</sup>. Insulin sensitivity, serum ALT levels, steatosis and necroinflammation, except fibrosis, were significantly ameliorated in the pioglitazone group.

In the largest trial completed to date for evaluation of the role of pioglitazone, 247 subjects with biopsy proven NASH were randomized to vitamin E, pioglitazone

or placebo for 96 wk<sup>[61]</sup>. Compared with placebo, both agents, pioglitazone and vitamin E, were associated with reductions in liver steatosis, lobular inflammation, hepatocellular ballooning and improvement in insulin resistance and serum aminotransferase levels. However, there was no improvement in fibrosis scores in the pioglitazone treated group. The “Fatty Liver Improvement with Rosiglitazone Therapy” (FLIRT) trial compared rosiglitazone with placebo in 63 patients<sup>[59]</sup>. Rosiglitazone improved serum aminotransferase levels, insulin sensitivity and hepatic steatosis. The two year extended trial (FLIRT2) demonstrated that improvement in liver enzyme levels continued but there was no further improvement in liver histology<sup>[62]</sup>.

A meta-analysis including six trials demonstrated reduction in steatosis and hepatocyte ballooning but no improvement in inflammation or fibrosis compared with control<sup>[63]</sup>. In contrast to this study, Mahady *et al*<sup>[64]</sup> found improvement in inflammation and fibrosis in addition to reduction in steatosis and hepatocyte ballooning in a meta-analysis including seven randomized trials.

The largest meta-analysis that included 11 RCTs (862 participants, 38% diabetic) showed that TZDs improve steatosis, hepatocellular ballooning and necroinflammation, delay fibrosis progression and ameliorate hepatic, muscle and adipose tissue insulin resistance with more consistent cardiovascular benefits with pioglitazone<sup>[42]</sup>.

Although the results of studies suggest some benefits from TZDs, a major problem also emerges: safety of long-term therapy and adverse effects. The use of rosiglitazone has been highly restricted in the United States and prohibited in Europe due to the increased risk of coronary events. On the other hand, pioglitazone is associated with adverse events such as bladder cancer, bone loss, weight gain, painful swollen legs and congestive heart failure. After evaluation of the overall results, it would be a good choice to use TZDs for the treatment of NAFLD only in patients with type 2 DM who are also candidates

for treatment with a TZD. The AASLD guideline recommended that pioglitazone can be used to treat only patients with biopsy-proven NASH; however, it also raised the concern about its long term safety and efficacy in patients with NASH<sup>[2]</sup>. The guideline also stressed that most of the clinical studies had been done in non-diabetic patients and thus the effect of TZDs on NASH of diabetic patients was not established. The position statement of a special EASL conference has recommended that pharmacological therapy of NASH could be a 1-2 year course of therapy with glitazone<sup>[44]</sup>.

### Dipeptidyl peptidase 4 inhibitors

Dipeptidyl peptidase 4 (DPP4) inhibitors are a new class of drugs and include sitagliptin, vildagliptin and saxagliptin. DPP4 is a membrane associated peptidase with a widespread organ distribution and deactivates a variety of bioactive peptides such as glucagon like peptide-1 (GLP-1). Inactivation of GLP-1 causes glucose intolerance, diabetes mellitus and hepatic steatosis. In a study including 31 NASH patients, Balaban *et al.*<sup>[65]</sup> reported that serum DPP-4 levels were higher in patients with NASH compared to controls. Furthermore, the serum DPP-4 activity and staining intensity in liver were correlated with histopathological grade of NASH and hepatosteatosis.

In rat models, DPP-4 inhibitors improve hepatic steatosis by increasing insulin sensitivity and decreasing hepatic triglyceride levels<sup>[66,67]</sup>. To date, there is no published controlled trial with these agents in humans.

GLP-1, a hormone excreted by intestinal L cells, regulates blood glucose by stimulation of glucose-dependent insulin release. GLP-1 has a direct effect on hepatocytes by inducing genes responsible for fatty acid oxidation and insulin sensitivity<sup>[68]</sup>. GLP-1 analogs (exenatide, liraglutide) have been approved by the FDA for treatment of patients with type 2 diabetes mellitus. Ding *et al.*<sup>[69]</sup> demonstrated that exenatide improves insulin sensitivity and reduces hepatosteatosis in rats with fatty liver. In another animal study liraglutide treatment reduced hepatic steatosis<sup>[70]</sup>. A case series including 8 patients with type 2 diabetes and biopsy-proven NAFLD showed that exenatide improves serum liver enzyme levels but has no effect on histopathology<sup>[71]</sup>. A recent meta-analysis including 4442 patients indicated that liraglutide decreased aminotransferase levels and that this effect was dose-dependent<sup>[72]</sup>. However, controlled studies are needed to show the efficacy of GLP-1 analogs in NAFLD and NASH treatment.

### CONCLUSION

NAFLD is a complex, multifactorial and major public health problem with an increasing prevalence worldwide. Insulin resistance is very common in this disease and the goal of the therapy should include improving insulin sensitivity. Insulin sensitizing agents could be convenient drugs to reach this target. Metformin has been accepted to have no significant effect on liver histology and is not recommended as a specific treatment for liver disease in

adults with NAFLD. TZDs have been most extensively evaluated in published trials to date and they have modest effects on liver histology. The long term safety and efficacy of TZDs in patients with NAFLD is lacking. Selection of appropriate patients to avoid side effects and treatment of the underlying disease causing insulin resistance, such as obesity, are crucial main points. NAFLD patients with metabolic syndrome and obesity are likely to be the best candidates to be treated with TZDs. According to current data, unfortunately insulin sensitizers do not satisfy expectations for the treatment of NAFLD. Future RCTs with adequate size and duration are still needed to assess the clinical outcomes in patients with NAFLD.

### REFERENCES

- 1 Ludwig J, Viggiano TR, McGill DB, Oh BJ. Nonalcoholic steatohepatitis: Mayo Clinic experiences with a hitherto unnamed disease. *Mayo Clin Proc* 1980; **55**: 434-438 [PMID: 7382552]
- 2 Chalasani N, Younossi Z, Lavine JE, Diehl AM, Brunt EM, Cusi K, Charlton M, Sanyal AJ. The diagnosis and management of non-alcoholic fatty liver disease: practice Guideline by the American Association for the Study of Liver Diseases, American College of Gastroenterology, and the American Gastroenterological Association. *Hepatology* 2012; **55**: 2005-2023 [PMID: 22488764 DOI: 10.1002/hep.25762]
- 3 Caldwell S, Argo C. The natural history of non-alcoholic fatty liver disease. *Dig Dis* 2010; **28**: 162-168 [PMID: 20460906 DOI: 10.1159/000282081]
- 4 Day CP. Genetic and environmental susceptibility to non-alcoholic fatty liver disease. *Dig Dis* 2010; **28**: 255-260 [PMID: 20460920 DOI: 10.1159/000282098]
- 5 Amarapurkar DN, Hashimoto E, Lesmana LA, Sollano JD, Chen PJ, Goh KL. How common is non-alcoholic fatty liver disease in the Asia-Pacific region and are there local differences? *J Gastroenterol Hepatol* 2007; **22**: 788-793 [PMID: 17565631 DOI: 10.1111/j.1440-1746.2007.05042.x]
- 6 Farrell GC, Larter CZ. Nonalcoholic fatty liver disease: from steatosis to cirrhosis. *Hepatology* 2006; **43**: S99-S112 [PMID: 16447287 DOI: 10.1002/hep.20973]
- 7 Larter CZ, Chitturi S, Heydet D, Farrell GC. A fresh look at NASH pathogenesis. Part 1: the metabolic movers. *J Gastroenterol Hepatol* 2010; **25**: 672-690 [PMID: 20492324 DOI: 10.1111/j.1440-1746.2010.06253.x]
- 8 Vernon G, Baranova A, Younossi ZM. Systematic review: the epidemiology and natural history of non-alcoholic fatty liver disease and non-alcoholic steatohepatitis in adults. *Aliment Pharmacol Ther* 2011; **34**: 274-285 [PMID: 21623852 DOI: 10.1111/j.1365-2036.2011.04724.x]
- 9 Boza C, Riquelme A, Ibañez L, Duarte I, Norero E, Viviani P, Soza A, Fernandez JL, Raddatz A, Guzman S, Arrese M. Predictors of nonalcoholic steatohepatitis (NASH) in obese patients undergoing gastric bypass. *Obes Surg* 2005; **15**: 1148-1153 [PMID: 16197788 DOI: 10.1381/0960892055002347]
- 10 Haentjens P, Massaad D, Reynaert H, Peeters E, Van Meerhaeghe A, Vinken S, Poppe K, Velkeniers B. Identifying non-alcoholic fatty liver disease among asymptomatic overweight and obese individuals by clinical and biochemical characteristics. *Acta Clin Belg* 2009; **64**: 483-493 [PMID: 20101871]
- 11 Leite NC, Salles GF, Araujo AL, Villela-Nogueira CA, Cardoso CR. Prevalence and associated factors of non-alcoholic fatty liver disease in patients with type-2 diabetes mellitus. *Liver Int* 2009; **29**: 113-119 [PMID: 18384521 DOI: 10.1111/j.1478-3231.2008.01718.x]
- 12 Grattagliano I, Portincasa P, Palmieri VO, Palasciano G.

- Managing nonalcoholic fatty liver disease: recommendations for family physicians. *Can Fam Physician* 2007; **53**: 857-863 [PMID: 17872748]
- 13 **Bugianesi E**, Leone N, Vanni E, Marchesini G, Brunello F, Carucci P, Musso A, De Paolis P, Capussotti L, Salizzoni M, Rizzetto M. Expanding the natural history of nonalcoholic steatohepatitis: from cryptogenic cirrhosis to hepatocellular carcinoma. *Gastroenterology* 2002; **123**: 134-140 [PMID: 12105842]
  - 14 **Hashimoto E**, Yatsuji S, Tobari M, Taniai M, Torii N, Tokushige K, Shiratori K. Hepatocellular carcinoma in patients with nonalcoholic steatohepatitis. *J Gastroenterol* 2009; **44** Suppl 19: 89-95 [PMID: 19148800 DOI: 10.1007/s00535-008-2262-x]
  - 15 **Smedile A**, Bugianesi E. Steatosis and hepatocellular carcinoma risk. *Eur Rev Med Pharmacol Sci* 2005; **9**: 291-293 [PMID: 16231592]
  - 16 **Targher G**, Bertolini L, Poli F, Rodella S, Scala L, Tessari R, Zenari L, Falezza G. Nonalcoholic fatty liver disease and risk of future cardiovascular events among type 2 diabetic patients. *Diabetes* 2005; **54**: 3541-3546 [PMID: 16306373]
  - 17 **Hamaguchi M**, Kojima T, Takeda N, Nagata C, Takeda J, Sarui H, Kawahito Y, Yoshida N, Suetsugu A, Kato T, Okuda J, Ida K, Yoshikawa T. Nonalcoholic fatty liver disease is a novel predictor of cardiovascular disease. *World J Gastroenterol* 2007; **13**: 1579-1584 [PMID: 17461452]
  - 18 **Targher G**. Non-alcoholic fatty liver disease, the metabolic syndrome and the risk of cardiovascular disease: the plot thickens. *Diabet Med* 2007; **24**: 1-6 [PMID: 17227317 DOI: 10.1111/j.1464-5491.2007.02025.x]
  - 19 **Bellentani S**, Bedogni G, Tiribelli C. Liver and heart: a new link? *J Hepatol* 2008; **49**: 300-302 [PMID: 18554746 DOI: 10.1016/j.jhep.2008.05.003]
  - 20 **Yu JH**, Lee KS, Lee SY, Hong AR, Park YS. The association of cardiovascular risk factors with nonalcoholic fatty liver disease in health checkup examinees. *J Prev Med Public Health* 2008; **41**: 407-412 [PMID: 19037170 DOI: 10.3961/jpmph.2008.41.6.407]
  - 21 **Fracanzani AL**, Burdick L, Raselli S, Pedotti P, Grigore L, Santorelli G, Valenti L, Maraschi A, Catapano A, Fargion S. Carotid artery intima-media thickness in nonalcoholic fatty liver disease. *Am J Med* 2008; **121**: 72-78 [PMID: 18187076 DOI: 10.1016/j.amjmed.2007.08.041]
  - 22 **Ramilli S**, Pretolani S, Muscari A, Pacelli B, Arienti V. Carotid lesions in outpatients with nonalcoholic fatty liver disease. *World J Gastroenterol* 2009; **15**: 4770-4774 [PMID: 19824109]
  - 23 **Angulo P**, Keach JC, Batts KP, Lindor KD. Independent predictors of liver fibrosis in patients with nonalcoholic steatohepatitis. *Hepatology* 1999; **30**: 1356-1362 [PMID: 10573511 DOI: 10.1002/hep.510300604]
  - 24 **Choudhury J**, Sanyal AJ. Insulin resistance in NASH. *Front Biosci* 2005; **10**: 1520-1533 [PMID: 15769642]
  - 25 **Day CP**. Non-alcoholic steatohepatitis (NASH): where are we now and where are we going? *Gut* 2002; **50**: 585-588 [PMID: 11950797]
  - 26 **Day CP**, James OF. Steatohepatitis: a tale of two "hits"? *Gastroenterology* 1998; **114**: 842-845 [PMID: 9547102]
  - 27 **Chitturi S**, Farrell GC. Etiopathogenesis of nonalcoholic steatohepatitis. *Semin Liver Dis* 2001; **21**: 27-41 [PMID: 11296694]
  - 28 **Matteoni CA**, Younossi ZM, Gramlich T, Boparai N, Liu YC, McCullough AJ. Nonalcoholic fatty liver disease: a spectrum of clinical and pathological severity. *Gastroenterology* 1999; **116**: 1413-1419 [PMID: 10348825]
  - 29 **Stumvoll M**, Nurjhan N, Perriello G, Dailey G, Gerich JE. Metabolic effects of metformin in non-insulin-dependent diabetes mellitus. *N Engl J Med* 1995; **333**: 550-554 [PMID: 7623903 DOI: 10.1056/NEJM199508313330903]
  - 30 **Lin HZ**, Yang SQ, Chuckaree C, Kuhajda F, Ronnet G, Diehl AM. Metformin reverses fatty liver disease in obese, leptin-deficient mice. *Nat Med* 2000; **6**: 998-1003 [PMID: 10973319 DOI: 10.1038/79697]
  - 31 **Kita Y**, Takamura T, Misu H, Ota T, Kurita S, Takeshita Y, Uno M, Matsuzawa-Nagata N, Kato K, Ando H, Fujimura A, Hayashi K, Kimura T, Ni Y, Ootoda T, Miyamoto K, Zen Y, Nakanuma Y, Kaneko S. Metformin prevents and reverses inflammation in a non-diabetic mouse model of nonalcoholic steatohepatitis. *PLoS One* 2012; **7**: e43056 [PMID: 23028442 DOI: 10.1371/journal.pone.0043056]
  - 32 **Marchesini G**, Brizi M, Bianchi G, Tomassetti S, Zoli M, Melchionda N. Metformin in non-alcoholic steatohepatitis. *Lancet* 2001; **358**: 893-894 [PMID: 11567710]
  - 33 **Nair S**, Diehl AM, Wiseman M, Farr GH, Perrillo RP. Metformin in the treatment of non-alcoholic steatohepatitis: a pilot open label trial. *Aliment Pharmacol Ther* 2004; **20**: 23-28 [PMID: 15225167 DOI: 10.1111/j.1365-2036.2004.02025.x]
  - 34 **Uygun A**, Kadayifci A, Isik AT, Ozgurtas T, Devci S, Tuzun A, Yesilova Z, Gulsen M, Dagalp K. Metformin in the treatment of patients with non-alcoholic steatohepatitis. *Aliment Pharmacol Ther* 2004; **19**: 537-544 [PMID: 14987322]
  - 35 **Bugianesi E**, Gentilcore E, Manini R, Natale S, Vanni E, Villanova N, David E, Rizzetto M, Marchesini G. A randomized controlled trial of metformin versus vitamin E or prescriptive diet in nonalcoholic fatty liver disease. *Am J Gastroenterol* 2005; **100**: 1082-1090 [PMID: 15842582 DOI: 10.1111/j.1572-0241.2005.41583.x]
  - 36 **Duseja A**, Das A, Dhiman RK, Chawla YK, Thumbaru KT, Bhadada S, Bhansali A. Metformin is effective in achieving biochemical response in patients with nonalcoholic fatty liver disease (NAFLD) not responding to lifestyle interventions. *Ann Hepatol* 2007; **6**: 222-226 [PMID: 18007551]
  - 37 **de Oliveira CP**, Stefano JT, de Siqueira ER, Silva LS, de Campos Mazo DF, Lima VM, Furuya CK, Mello ES, Souza FG, Rabello F, Santos TE, Nogueira MA, Caldwell SH, Alves VA, Carrilho FJ. Combination of N-acetylcysteine and metformin improves histological steatosis and fibrosis in patients with non-alcoholic steatohepatitis. *Hepatol Res* 2008; **38**: 159-165 [PMID: 18197877 DOI: 10.1111/j.1872-034X.2007.00215.x]
  - 38 **Loomba R**, Lutchman G, Kleiner DE, Ricks M, Feld JJ, Borg BB, Modi A, Nagabhyru P, Sumner AE, Liang TJ, Hoofnagle JH. Clinical trial: pilot study of metformin for the treatment of non-alcoholic steatohepatitis. *Aliment Pharmacol Ther* 2009; **29**: 172-182 [PMID: 18945255 DOI: 10.1111/j.1365-2036.2008.03869.x]
  - 39 **Haukeland JW**, Konopski Z, Eggesbø HB, von Volkmann HL, Raschpichler G, Bjørø K, Haaland T, Løberg EM, Birke-land K. Metformin in patients with non-alcoholic fatty liver disease: a randomized, controlled trial. *Scand J Gastroenterol* 2009; **44**: 853-860 [PMID: 19811343]
  - 40 **Garinis GA**, Fruci B, Mazza A, De Siena M, Abenavoli S, Gulletta E, Ventura V, Greco M, Abenavoli L, Belfiore A. Metformin versus dietary treatment in nonalcoholic hepatic steatosis: a randomized study. *Int J Obes (Lond)* 2010; **34**: 1255-1264 [PMID: 20179669 DOI: 10.1038/ijo.2010.40]
  - 41 **Shargorodsky M**, Omelchenko E, Matas Z, Boaz M, Gavish D. Relation between augmentation index and adiponectin during one-year metformin treatment for nonalcoholic steatohepatosis: effects beyond glucose lowering? *Cardiovasc Diabetol* 2012; **11**: 61 [PMID: 22676459 DOI: 10.1186/1475-2840-11-61]
  - 42 **Musso G**, Cassader M, Rosina F, Gambino R. Impact of current treatments on liver disease, glucose metabolism and cardiovascular risk in non-alcoholic fatty liver disease (NAFLD): a systematic review and meta-analysis of randomised trials. *Diabetologia* 2012; **55**: 885-904 [PMID: 22278337 DOI: 10.1007/s00125-011-2446-4]
  - 43 **Lavine JE**, Schwimmer JB, Van Natta ML, Molleston JP, Murray KF, Rosenthal P, Abrams SH, Scheimann AO, Sanyal AJ, Chalasani N, Tonascia J, Ünalp A, Clark JM, Brunt EM, Kleiner DE, Hoofnagle JH, Robuck PR. Effect of vitamin E or metformin for treatment of nonalcoholic fatty liver disease in



- children and adolescents: the TONIC randomized controlled trial. *JAMA* 2011; **305**: 1659-1668 [PMID: 21521847 DOI: 10.1001/jama.2011.520]
- 44 **Ratzliff V**, Bellentani S, Cortez-Pinto H, Day C, Marchesini G. A position statement on NAFLD/NASH based on the EASL 2009 special conference. *J Hepatol* 2010; **53**: 372-384 [PMID: 20494470 DOI: 10.1016/j.jhep.2010.04.008]
  - 45 **Hung CH**, Wang JH, Hu TH, Chen CH, Chang KC, Yen YH, Kuo YH, Tsai MC, Lu SN, Lee CM. Insulin resistance is associated with hepatocellular carcinoma in chronic hepatitis C infection. *World J Gastroenterol* 2010; **16**: 2265-2271 [PMID: 20458764]
  - 46 **Fartoux L**, Poujol-Robert A, Guécho J, Wendum D, Poupon R, Serfaty L. Insulin resistance is a cause of steatosis and fibrosis progression in chronic hepatitis C. *Gut* 2005; **54**: 1003-1008 [PMID: 15951550 DOI: 10.1136/gut.2004.050302]
  - 47 **Zhang ZJ**, Zheng ZJ, Shi R, Su Q, Jiang Q, Kip KE. Metformin for liver cancer prevention in patients with type 2 diabetes: a systematic review and meta-analysis. *J Clin Endocrinol Metab* 2012; **97**: 2347-2353 [PMID: 22523334 DOI: 10.1210/jc.2012-1267]
  - 48 **Chen HP**, Shieh JJ, Chang CC, Chen TT, Lin JT, Wu MS, Lin JH, Wu CY. Metformin decreases hepatocellular carcinoma risk in a dose-dependent manner: population-based and in vitro studies. *Gut* 2013; **62**: 606-615 [PMID: 22773548 DOI: 10.1136/gutjnl-2011-301708]
  - 49 **Kadayifçi A**. Nonalcoholic steatohepatitis: role of leptin in pathogenesis and benefits of metformin in treatment. *Am J Gastroenterol* 2003; **98**: 2330; author reply 2330-2331 [PMID: 14572592 DOI: 10.1111/j.1572-0241.2003.07736.x]
  - 50 **Yki-Järvinen H**. Thiazolidinediones. *N Engl J Med* 2004; **351**: 1106-1118 [PMID: 15356308 DOI: 10.1056/NEJMra041001]
  - 51 **Ahmed MH**, Byrne CD. Current treatment of non-alcoholic fatty liver disease. *Diabetes Obes Metab* 2009; **11**: 188-195 [PMID: 18564173 DOI: 10.1111/j.1463-1326.2008.00926.x]
  - 52 **Duvnjak M**, Tomasic V, Gomercic M, Smircic Duvnjak L, Barsic N, Lerotic I. Therapy of nonalcoholic fatty liver disease: current status. *J Physiol Pharmacol* 2009; **60** Suppl 7: 57-66 [PMID: 20388946]
  - 53 **Caldwell SH**, Hespdenheide EE, Redick JA, Iezzoni JC, Battle EH, Sheppard BL. A pilot study of a thiazolidinedione, troglitazone, in nonalcoholic steatohepatitis. *Am J Gastroenterol* 2001; **96**: 519-525 [PMID: 11232700 DOI: 10.1111/j.1572-0241.2001.03553.x]
  - 54 **Neuschwander-Tetri BA**, Brunt EM, Wehmeier KR, Oliver D, Bacon BR. Improved nonalcoholic steatohepatitis after 48 weeks of treatment with the PPAR-gamma ligand rosiglitazone. *Hepatology* 2003; **38**: 1008-1017 [PMID: 14512888 DOI: 10.1053/jhep.2003.50420]
  - 55 **Promrat K**, Lutchman G, Uwaifo GI, Freedman RJ, Soza A, Heller T, Doo E, Ghany M, Premkumar A, Park Y, Liang TJ, Yanovski JA, Kleiner DE, Hoofnagle JH. A pilot study of pioglitazone treatment for nonalcoholic steatohepatitis. *Hepatology* 2004; **39**: 188-196 [PMID: 14752837 DOI: 10.1002/hep.20012]
  - 56 **Sanyal AJ**, Mofrad PS, Contos MJ, Sargeant C, Luketic VA, Sterling RK, Stravitz RT, Shiffman ML, Clore J, Mills AS. A pilot study of vitamin E versus vitamin E and pioglitazone for the treatment of nonalcoholic steatohepatitis. *Clin Gastroenterol Hepatol* 2004; **2**: 1107-1115 [PMID: 15625656]
  - 57 **Belfort R**, Harrison SA, Brown K, Darland C, Finch J, Hardies J, Balas B, Gastaldelli A, Tio F, Pulcini J, Berria R, Ma JZ, Dwivedi S, Havranek R, Fincke C, DeFronzo R, Bannayan GA, Schenker S, Cusi K. A placebo-controlled trial of pioglitazone in subjects with nonalcoholic steatohepatitis. *N Engl J Med* 2006; **355**: 2297-2307 [PMID: 17135584 DOI: 10.1056/NEJMoa060326]
  - 58 **Idilman R**, Mizrak D, Corapcioglu D, Bektas M, Doganay B, Sayki M, Coban S, Erden E, Soykan I, Emral R, Uysal AR, Özden A. Clinical trial: insulin-sensitizing agents may reduce consequences of insulin resistance in individuals with non-alcoholic steatohepatitis. *Aliment Pharmacol Ther* 2008; **28**: 200-208 [PMID: 18445142 DOI: 10.1111/j.1365-2036.2008.03723.x]
  - 59 **Ratzliff V**, Giral P, Jacqueminet S, Charlotte F, Hartemann-Heurtier A, Serfaty L, Podevin P, Lacorte JM, Bernhardt C, Bruckert E, Grimaldi A, Poynard T. Rosiglitazone for nonalcoholic steatohepatitis: one-year results of the randomized placebo-controlled Fatty Liver Improvement with Rosiglitazone Therapy (FLIRT) Trial. *Gastroenterology* 2008; **135**: 100-110 [PMID: 18503774 DOI: 10.1053/j.gastro.2008.03.078]
  - 60 **Omer Z**, Cetinkalp S, Akyildiz M, Yilmaz F, Batur Y, Yilmaz C, Akarca U. Efficacy of insulin-sensitizing agents in nonalcoholic fatty liver disease. *Eur J Gastroenterol Hepatol* 2010; **22**: 18-23 [PMID: 19667999 DOI: 10.1097/MEG.0b013e32832e2baf]
  - 61 **Sanyal AJ**, Chalasani N, Kowdley KV, McCullough A, Diehl AM, Bass NM, Neuschwander-Tetri BA, Lavine JE, Tonascia J, Unalp A, Van Natta M, Clark J, Brunt EM, Kleiner DE, Hoofnagle JH, Robuck PR. Pioglitazone, vitamin E, or placebo for nonalcoholic steatohepatitis. *N Engl J Med* 2010; **362**: 1675-1685 [PMID: 20427778 DOI: 10.1056/NEJMoa0907929]
  - 62 **Ratzliff V**, Charlotte F, Bernhardt C, Giral P, Halbron M, Lenaour G, Hartmann-Heurtier A, Bruckert E, Poynard T. Long-term efficacy of rosiglitazone in nonalcoholic steatohepatitis: results of the fatty liver improvement by rosiglitazone therapy (FLIRT 2) extension trial. *Hepatology* 2010; **51**: 445-453 [PMID: 19877169 DOI: 10.1002/hep.23270]
  - 63 **Rakoski MO**, Singal AG, Rogers MA, Conjeevaram H. Meta-analysis: insulin sensitizers for the treatment of non-alcoholic steatohepatitis. *Aliment Pharmacol Ther* 2010; **32**: 1211-1221 [PMID: 20955440 DOI: 10.1111/j.1365-2036.2010.04467.x]
  - 64 **Mahady SE**, Webster AC, Walker S, Sanyal A, George J. The role of thiazolidinediones in non-alcoholic steatohepatitis - a systematic review and meta analysis. *J Hepatol* 2011; **55**: 1383-1390 [PMID: 21703200 DOI: 10.1016/j.jhep.2011.03.016]
  - 65 **Balaban YH**, Korkusuz P, Simsek H, Gokcan H, Gedikoglu G, Pinar A, Hascelik G, Asan E, Hamaloglu E, Tatar G. Dipeptidyl peptidase IV (DDP IV) in NASH patients. *Ann Hepatol* 2007; **6**: 242-250 [PMID: 18007554]
  - 66 **Akaslan SB**, Degertekin CK, Yilmaz G, Kadir N, Arslan M, Toruner FB. Effects of sitagliptin on nonalcoholic fatty liver disease in diet-induced obese rats. *Metab Syndr Relat Disord* 2013; **11**: 243-250 [PMID: 23544853 DOI: 10.1089/met.2012.0128]
  - 67 **Shirakawa J**, Fujii H, Ohnuma K, Sato K, Ito Y, Kaji M, Sakamoto E, Koganei M, Sasaki H, Nagashima Y, Amo K, Aoki K, Morimoto C, Takeda E, Terauchi Y. Diet-induced adipose tissue inflammation and liver steatosis are prevented by DPP-4 inhibition in diabetic mice. *Diabetes* 2011; **60**: 1246-1257 [PMID: 21330637 DOI: 10.2337/db10-1338]
  - 68 **Svegliati-Baroni G**, Saccomanno S, Rychlicki C, Agostinelli L, De Minicis S, Candelaresi C, Faraci G, Pacetti D, Vivarelli M, Nicolini D, Garelli P, Casini A, Manco M, Mingrone G, Risaliti A, Frega GN, Benedetti A, Gastaldelli A. Glucagon-like peptide-1 receptor activation stimulates hepatic lipid oxidation and restores hepatic signalling alteration induced by a high-fat diet in nonalcoholic steatohepatitis. *Liver Int* 2011; **31**: 1285-1297 [PMID: 21745271 DOI: 10.1111/j.1478-3231.2011.02462.x]
  - 69 **Ding X**, Saxena NK, Lin S, Gupta NA, Anania FA. Exendin-4, a glucagon-like protein-1 (GLP-1) receptor agonist, reverses hepatic steatosis in ob/ob mice. *Hepatology* 2006; **43**: 173-181 [PMID: 16374859 DOI: 10.1002/hep.21006]
  - 70 **Sharma S**, Mells JE, Fu PP, Saxena NK, Anania FA. GLP-1 analogs reduce hepatocyte steatosis and improve survival by enhancing the unfolded protein response and promoting macroautophagy. *PLoS One* 2011; **6**: e25269 [PMID: 21957486 DOI: 10.1371/journal.pone.0025269]
  - 71 **Kenny PR**, Brady DE, Torres DM, Ragozzino L, Chalasani N, Harrison SA. Exenatide in the treatment of diabetic patients with non-alcoholic steatohepatitis: a case series. *Am J Gastro-*



*enterol* 2010; **105**: 2707-2709 [PMID: 21131943 DOI: 10.1038/ajg.2010.363]

- 72 **Armstrong MJ**, Houlihan DD, Rowe IA, Clausen WH, Elbrønd B, Gough SC, Tomlinson JW, Newsome PN. Safety

and efficacy of liraglutide in patients with type 2 diabetes and elevated liver enzymes: individual patient data meta-analysis of the LEAD program. *Aliment Pharmacol Ther* 2013; **37**: 234-242 [PMID: 23163663 DOI: 10.1111/apt.12149]

**P- Reviewers:** Carvalho-Filho RJ, Ido Y, Masaki T, Zhao D  
**S- Editor:** Song XX **L- Editor:** Roemmele A **E- Editor:** Wu HL



## Mechanisms of fibrogenesis in liver cirrhosis: The molecular aspects of epithelial-mesenchymal transition

Sun-Jae Lee, Kyung-Hyun Kim, Kwan-Kyu Park

Sun-Jae Lee, Kyung-Hyun Kim, Kwan-Kyu Park, Department of Pathology, Catholic University of Daegu, College of Medicine, Daegu, 705-718, South Korea

**Author contributions:** Lee SJ and Park KK designed research; Lee SJ and Kim KH analyzed data; Lee SJ and Park KK wrote the paper; Lee SJ and Park KK contributed equally to this work.

**Supported by** The National Research Foundation of Korea Grant funded by the Korean Government, No. 2012R1A1A401015639

**Correspondence to:** Kwan-Kyu Park, MD, PhD, Department of Pathology, Catholic University of Daegu, College of Medicine, 3056-6 Daemyung 4-Dong, Nam-Gu, Daegu, 705-718, South Korea. [kkpark@cu.ac.kr](mailto:kkpark@cu.ac.kr)

Telephone: +82-53-6504149 Fax: +82-53-6504834

Received: October 28, 2013 Revised: January 9, 2014

Accepted: March 3, 2014

Published online: April 27, 2014

© 2014 Baishideng Publishing Group Co., Limited. All rights reserved.

**Key words:** Epithelial-mesenchymal transition; Liver; Fibrosis; Transforming growth factor-beta1; Biological markers

**Core tip:** The cause of fibrosis and diminished regeneration, especially in liver cirrhosis, is still unknown. Epithelial-mesenchymal transition (EMT) has been found to be associated with liver fibrosis. The possibility that EMT could contribute to hepatic fibrogenesis reinforced the concept that activated hepatic stellate cells are not the only key players in the hepatic fibrogenic process. The aim of this article is to describe how EMT participates to hepatic fibrosis and discuss the evidence of supporting this possibility in order to reach reasonable and useful conclusions.

### Abstract

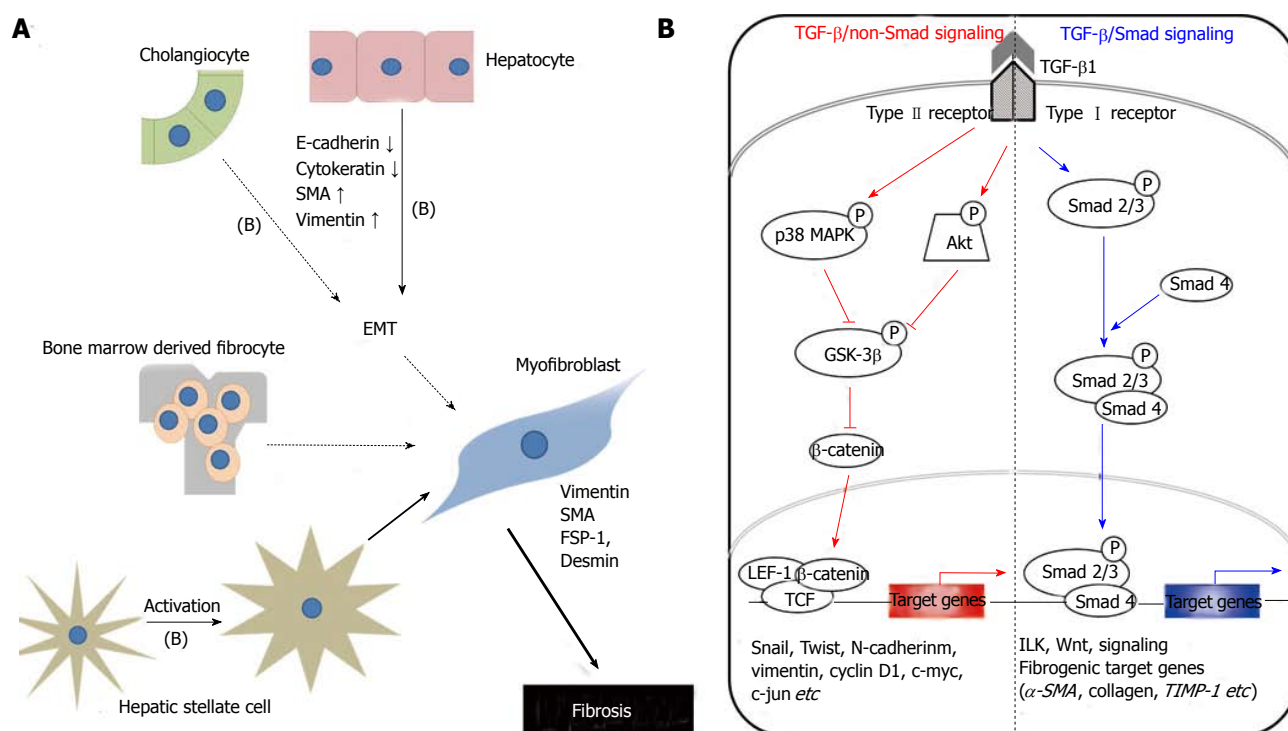
Liver injuries are repaired by fibrosis and regeneration. The cause of fibrosis and diminished regeneration, especially in liver cirrhosis, is still unknown. Epithelial-mesenchymal transition (EMT) has been found to be associated with liver fibrosis. The possibility that EMT could contribute to hepatic fibrogenesis reinforced the concept that activated hepatic stellate cells are not the only key players in the hepatic fibrogenic process and that other cell types, either hepatic or bone marrow-derived cells could contribute to this process. Following an initial enthusiasm for the discovery of this novel pathway in fibrogenesis, more recent research has started to cast serious doubts upon the real relevance of this phenomenon in human fibrogenetic disorders. The debate on the authenticity of EMT or on its contribution to the fibrogenic process has become very animated. The overall result is a general confusion on the meaning and on the definition of several key aspects. The aim of this article is to describe how EMT participates to hepatic fibrosis and discuss the evidence of supporting this possibility in order to reach reasonable and useful conclusions.

Lee SJ, Kim KH, Park KK. Mechanisms of fibrogenesis in liver cirrhosis: The molecular aspects of epithelial-mesenchymal transition. *World J Hepatol* 2014; 6(4): 207-216 Available from: URL: <http://www.wjgnet.com/1948-5182/full/v6/i4/207.htm> DOI: <http://dx.doi.org/10.4254/wjh.v6.i4.207>

### INTRODUCTION

Chronic liver damage can be triggered by different mechanisms (*e.g.*, viral hepatitis, metabolic liver diseases, or chronic alcohol consumption)<sup>[1]</sup> and are accompanied by changes in several key biochemical pathways involved in hepatic tissue homeostasis. One of the most important alterations is hepatic fibrosis, which is characterized by deposition of extracellular matrix (ECM) components around the sinusoidal layer in the space of Disse, together with molecular reorganization of the matrix components resulting in an altered composition<sup>[2]</sup>.

Fibrosis is comparable with a wound-healing response



**Figure 1 Mechanisms of hepatic fibrogenesis.** A: The proposed sources of hepatic myofibroblasts: Resident cells (hepatic stellate cells and portal fibroblasts); bone marrow-derived mesenchymal cells, and EMT from hepatocytes and cholangiocytes. Different insults initiate inflammation and then cause hepatocyte stellate cells activation and hepatocyte and biliary cell damage, necrosis and EMT. Continuous insults will shift those EMT-like cells to complete EMT cells and finally myofibroblasts, the main producer of extracellular matrix, which may be one of the main causes of an early loss of regenerative capacity. A similar process also occurs in biliary cells. Some cytokines play an important role to affect the adjacent cells and promote EMTs, such as TGF- $\beta$ 1 (B); B: Schematic presentation of the major intracellular signal transduction pathways of TGF- $\beta$ 1 in liver fibrosis. TGF- $\beta$ 1 is a chief inducer of the EMT process, and p-Smad2/3, p38 MAPK and ILK function as mediators of the intracellular signaling pathway. TGF- $\beta$ 1 signals via heteromeric transmembrane complexes of type I and type II receptors that are endowed with intrinsic serine/threonine kinase activity (ALK activin receptor-like kinase). Upon type-II-mediated phosphorylation of the type I receptor, the activated type I receptor initiates intracellular signalling by phosphorylating receptor regulated-Smad2 and Smad3. Activated Smads form heteromeric complexes with Smad4 and these complexes accumulate in the nucleus where they mediate transcriptional responses. p-Smad2/3: Phosphorylated-Smad2/3; MAPK: Mitogen-activated protein kinase; GSK-3 $\beta$ : Glycogen synthase kinase-3 $\beta$ ; ILK: Integrin-linked kinase; TCF/LEF-1 complex: T cell factor/lymphoid enhancer-binding factor-1 complex; EMT: Epithelial-mesenchymal transition; TGF: Transforming growth factor.

being out of control. Repair mechanisms aim at the replacement of injured cells. However, contrary to the pure regeneration of tissue in fibroplasia, connective tissue substitutes normal parenchyma<sup>[3]</sup>. The ultimate result is organ failure. In the liver, the final common pathway is cirrhosis, characterized by accumulation of ECM. In human beings liver fibrosis is associated with dysregulated growth of hepatocytes and results in the formation of regenerative nodules, dysplastic nodules, and hepatocellular carcinomas<sup>[4]</sup>. At present, no therapeutic concepts have been developed to treat and reverse fibrosis<sup>[5]</sup>.

Striking increases in our understanding of the pathogenesis of liver fibrosis include the identification of the main cellular effectors, key cytokines regulating the EMT process, and determinants of ECM turnover<sup>[3]</sup>.

## FIBROGENESIS OF HEPATIC STELLATE CELLS, MYOFIBROBLASTS AND HEPATOCYTES IN LIVER CIRRHOSIS

Recent work regarding liver fibrosis centers on the myofibroblast as a pivotal cell type due to its contractile nature and synthesis repertoire<sup>[6]</sup>. The sources of myofibroblasts

are still matters of discussion. Undisputedly, a “myofibroblast” phenotype is observed with hepatic stellate cell (HSC) after exposure to profibrogenic cytokines<sup>[3]</sup>.

Liver myofibroblasts stand for a wide repertoire of functions that emphasize the dynamic nature of the wound-healing response, including synthesis of fibrillar collagens, contractile and migratory activities, secretion of chemotactic and vasoactive factors, and the secretion of matrix metalloproteinases (MMPs) and tissue inhibitor of metalloproteinases (TIMPs)<sup>[3]</sup>. The origin of myofibroblasts in the injured liver is now under scrutiny, although evidence hints at HSCs as a major source<sup>[3]</sup>. Myofibroblasts can be derived from local mesenchymal cells recruited from the bone marrow or could derive from other cellular sources by EMT, a physiologic process in embryogenesis and of relevance for cancerous cell transformation<sup>[7]</sup> (Figure 1A).

Studies with animals and human tissue indicate that bone marrow stem cells infiltrate the liver and contribute to the myofibroblast population after damage. This may occur directly or through an intermediary cell, such as quiescent HSCs or CD45<sup>+</sup> fibrocytes<sup>[8,9]</sup>. Several studies have indicated that bone marrow-derived mesenchymal stem cells could be a source of multi-lineage cells for

various organs. They have the capacity to differentiate into hepatocytes, biliary epithelial cells, sinusoidal endothelial cells and even Kupffer cells in the presence of a suitable hepatic microenvironment<sup>[10,11]</sup>. There is growing evidence to suggest that bone marrow-derived stem cells are recruited during both progression and regression of liver fibrosis<sup>[8,12-16]</sup>.

Most studies in the past decade have focused on HSCs and analyzed characteristic features like plasticity and transdifferentiation to myofibroblasts, a phenotype that can be readily recapitulated in tissue culture<sup>[3]</sup>. Current concepts envision activated HSCs as a crucial pro-fibrogenic source, while the majority of hepatocytes are believed to undergo necrosis or apoptosis, thereby providing space for proliferating cells. Besides the resident hepatic cells, infiltrating neutrophils, macrophages, T and B cells, and eosinophils participate in the inflammatory response and may perpetuate the damage, whereby activated macrophages and neutrophils clean up tissue debris, dead cells, and invading organisms<sup>[17]</sup>.

HSCs are located in the space of Disse of hepatic sinusoids between hepatocytes and sinusoidal endothelial cells<sup>[1]</sup> as liver-specific pericytes interposed by sparse connective tissue and closely adhering to sinusoidal endothelial cells<sup>[18]</sup>. They also directly face hepatocytes and maintain a quiescent phenotype with the main function to store vitamin A<sup>[19]</sup>. During liver injury, HSCs lose their vitamin A content<sup>[20]</sup> and undergo activation triggered by exposure to cytokines and growth factors, such as platelet-derived growth factor (PDGF) and transforming growth factor (TGF)- $\beta$ 1, which derive from activated Kupffer cells and damaged hepatocytes. During activation, HSCs transform into a myofibroblast-like phenotype<sup>[21-23]</sup> losing their typical star-shape<sup>[20]</sup>, characterized by the expression of  $\alpha$ -smooth muscle actin (SMA)<sup>[24]</sup>, by the production of ECM and matrix degrading enzymes, such as MMPs<sup>[21-23]</sup> and TIMPs<sup>[25,26]</sup>. Activated HSCs are thought to migrate from the sinusoids into necrotic areas and produce a variety of ECM<sup>[19]</sup>.

Some authors<sup>[27]</sup> have proposed that HSC could be transitional cells derived from epithelial cells that have undergone partial EMT<sup>[28]</sup> or even a particular type of oval cell/hepatocyte precursor<sup>[29]</sup>. This hypothesis was based, at least in part, on the finding of an adult sub-population of primary rat HSC expressing the progenitor cell marker CD133 and differentiating into either myofibroblasts or hepatocytes when cultured under different *in vitro* conditions<sup>[30]</sup>.

Another source of myofibroblast may be portal fibroblasts that are described in fibrotic diseases with a portal component (*e.g.*, viral hepatitis and autoimmune conditions)<sup>[31]</sup>. In coherence with experimental data on hepatocytes, TGF- $\beta$ 1 is required for myofibroblast transdifferentiation of this cell type<sup>[32]</sup>. The portal connective tissue in healthy liver is surrounded by quiescent portal fibroblasts, which constitute a second population of liver cells implicated in portal fibrosis<sup>[33]</sup>. Derived from small portal vessels, they express markers distinct from HSC (*e.g.*, elastin)<sup>[32]</sup>. Proliferation of biliary cells is often accompanied

by proliferation of portal fibroblasts, which form onion-like configurations around biliary structures and acquire a myofibroblast phenotype, and are thus implied in the early deposition of ECM in portal zones<sup>[34]</sup>. It is generally believed that substantial signaling from biliary epithelial cells leads to portal fibroblast activation, although the key factors remain to be identified<sup>[20]</sup>. In complex studies employing the "lineage tracing" methodological approach have documented, in different animal models of liver fibrogenesis, that some hepatocytes or cholangiocytes acquire "mesenchymal markers" implicated in cell motility and survival, but are not involved in active fibrillar ECM deposition and, therefore, cannot be considered pro-fibrogenic cells<sup>[35]</sup>.

Dooley *et al*<sup>[3]</sup> have provided *in vitro* and *in vivo* evidence that profibrogenic TGF- $\beta$ 1 functions during liver damage are directed toward hepatocytes. A TGF- $\beta$ 1-induced gene expression profiling of hepatocytes indicates a minor role of apoptosis and induction of fibrogenesis- and EMT-related genes. While the definite occurrence of EMT in this cell type *in vivo* needs further investigation (*e.g.*, by double-transgenic animals expressing fluorescent proteins under the control of hepatocyte- and myofibroblast-specific promoters), their results suggest that hepatocytes and TGF- $\beta$ 1 signaling in this cell type play a prominent role for fibrogenesis. In patients with chronic hepatitis B virus (HBV) infection, the activation of the TGF- $\beta$ 1 pathway was also shown by the accumulation of phosphorylated Smad2 in hepatocyte nuclei. Furthermore, the induction of Snail, a transcription factor known to repress E-cadherin expression, and the co-expression of type I collagen and transferrin in HBV livers, indicated that hepatocyte EMT was a feature of human liver fibrosis<sup>[36]</sup>. Therefore, the hepatocytes may be a contributor to hepatic fibrosis, especially when they are chronically injured<sup>[4]</sup>.

## TGF- $\beta$ /SMAD AND NON-SMAD SIGNALLING PATHWAY IN LIVER FIBROSIS

TGF- $\beta$ 1 is recognized as a major profibrogenic cytokine and is a potent inducer of HSC proliferation and collagen production<sup>[37]</sup>. Furthermore, TGF- $\beta$ 1 expression is also associated with morphologic alterations like EMT in fetal<sup>[38]</sup> and adult hepatocytes<sup>[39]</sup>, and changes in survival signaling pathways<sup>[40]</sup>.

TGF- $\beta$ 1 binds to TGF- $\beta$ 1 receptor type II (TbR-II), and it recruits the TGF- $\beta$ 1 receptor type I (TbR-I)<sup>[41]</sup>. TbR-I subsequently phosphorylates Smad2 and Smad3, which form hetero-oligomers with Smad4. They translocate from the cytoplasm to the nucleus, where they regulate transcription of target genes<sup>[42]</sup> (Figure 1B). R-Smad signaling is limited by the inhibitory effects of inhibitory Smad6 and 7<sup>[3]</sup>.

Dysregulated TGF- $\beta$ 1 signaling is implicated in multiple developmental disorders and various human diseases, including cancer and autoimmune illnesses<sup>[43]</sup>. Its



over-expression is linked to liver fibrosis in diverse animal models<sup>[44]</sup> and in human patients with chronic liver diseases<sup>[45]</sup>. TGF- $\beta$ 1 crucially regulates ECM deposition by controlling the expression of ECM network components such as fibrillar collagens and fibronectin, ECM-degrading protease inhibitors, such as plasminogen activator inhibitor (PAI)-1 and TIMPs. Its activity is strongly induced during chronic liver damage with links between TGF- $\beta$ 1 and connective tissue growth factor in the HSC activation process<sup>[46]</sup>, which in turn acquire myofibroblastic features and produce ECM proteins.

Epithelial cell transdifferentiation comprises alterations in cellular morphology characterized by changes in cell polarity and loss of adhesion protein expression<sup>[3]</sup>. TGF- $\beta$ 1 can initiate and maintain this process in a variety of biological systems and pathophysiological contexts by activating major signaling pathways and transcriptional regulators integrated in extensive cellular networks<sup>[47]</sup>. In MDCKII cells, claudin-1, claudin-2, occludin and E-cadherin disappear within 72 h of exposure to TGF- $\beta$ 1. It is suggested that this expression loss occurs through a Smad-independent mechanism, involving mitogen-activated protein kinase kinase and phosphatidylinositol 3-kinase pathways with expression of Snail. On the other hand, a complete loss of E-cadherin and transition to the mesenchymal phenotype additionally requires Smad signaling, which results in formation of  $\beta$ -catenin/lymphoid enhancer factor-1 complexes that induce EMT<sup>[48]</sup>. Participation of TGF- $\beta$ 1 in the regulation of Notch signaling has been reported previously at the onset of EMT in epithelial cells from mammary gland, kidney tubules, and epidermis<sup>[49]</sup>. A set of the previously mentioned genes and others described to be involved in EMT, including Snail and Notch2, were identified as TGF- $\beta$ 1 target genes in hepatocytes. Some studies<sup>[39,50]</sup> have suggested on hepatocyte plasticity showing up-regulation of  $\alpha$ 1(I) collagen mRNA expression and type I collagen deposition in mouse hepatocytes and  $\alpha$  (alpha) mouse liver 12 cells as a result of Smad2/3/4-dependent induction of Snail-1.

## EMT IN HEPATIC FIBROGENESIS

EMT is a process that is normally evident in embryonic stages of development and recently has been investigated as a mechanism of cancer cell migration and metastasis<sup>[51,52]</sup>. A classification of EMT has been recently proposed to distinguish between these different types of EMT<sup>[53]</sup>. It is characterized by the loss of epithelial characteristics (E-cadherin) and the acquisition of a mesenchymal phenotype (vimentin and fibronectin)<sup>[54,55]</sup>. According to the functional consequences and biological context, EMT is divided into three subtypes<sup>[53,55,56]</sup>: Type I EMT occurs during embryogenesis, in which it produces motile cells but does not lead to ECM deposition or intravascular invasion. Type II EMT induces a morphogenetic change during organ fibrosis or wound healing, which is associated with ECM production and muscle-like characteristics. Type III EMT is involved in carcinoma-metastatic transition.

Evidence of EMT in fibrosis was first demonstrated in the kidney. *In vitro*, adult renal tubular epithelial cells were shown to undergo EMT<sup>[57,58]</sup>. Thereafter, induction of renal fibrosis in mice by unilateral ureteral obstruction (UUO) showed that epithelial marker expression (*i.e.*, E-cadherin) was lost in tubular epithelial cells, while the mesenchymal marker  $\alpha$ -SMA expression was increased<sup>[59]</sup>. A cell tracing method later established that mice submitted to UUO display EMT-derived fibroblasts that contribute to the fibroblastic population<sup>[60]</sup>.

Because the liver is an organ prone to fibrosis and because the origin of fibroblastic cells in fibrotic liver is still debated, the possibility that liver epithelial cells participate to fibrosis by EMT is appealing. Such hypothesis was strengthened by the observation that HSC lines express E-cadherin, while hepatic epithelial progenitor cells are positive for  $\alpha$ -SMA<sup>[61]</sup>. Kaimori *et al.*<sup>[39]</sup> then demonstrated that freshly isolated hepatocytes were able to convert to mesenchymal cells *in vitro*. Hepatocyte EMT, characterized by a decrease in E-cadherin expression and concomitant acquisition of mesenchymal markers (vimentin and type I collagen), was observed when cells were incubated with the profibrogenic cytokine, TGF- $\beta$ 1<sup>[39]</sup>. Zeisberg and co-workers were the first to report *in vivo* evidence for hepatocyte EMT<sup>[50]</sup>. They demonstrated that hepatocyte EMT was observed in CCl<sub>4</sub> induced liver fibrosis by developing transgenic mice specifically expressing a molecular tag in hepatocytes (*i.e.*,  $\beta$ -galactosidase). In these mice challenged with CCl<sub>4</sub>, 45% of the cells expressing the mesenchymal marker fibroblast-specific protein-1 (FSP-1) were also positive for  $\beta$ -galactosidase expression. Furthermore, the inhibition of the TGF- $\beta$ 1 pathway limited the extent of liver fibrosis in the CCl<sub>4</sub>-injected mice<sup>[50]</sup>. *In vitro* TGF- $\beta$ 1 treatment induced higher vimentin expression in cirrhotic liver-derived hepatocytes than in normal liver-derived hepatocytes<sup>[4]</sup>. Taken together, these results suggest that hepatocyte EMT is triggered by TGF- $\beta$ 1 and contributes to liver fibrosis. Some studies have proposed that EMT leads to myofibroblast accumulation through a two-stage process. In the first stage, epithelial cells adopt a mesenchymal phenotype, whereas in the second stage these mesenchymal cells further transition to myofibroblasts as part of what has been termed an epithelial-to-myofibroblast transition (EMyT)<sup>[62-64]</sup>.

Substantial experimental evidence supports the occurrence of EMT in embryonic development and tumor metastasis, processes in which the motility phenotype of the transitioned cells is essential<sup>[56,65,66]</sup>. For tissue fibrosis, however, there are conflicting data on whether or not EMT occurs<sup>[67]</sup>. Many studies of EMT in fibrosis have failed to define EMT rigorously or to differentiate between the transition to a mesenchymal (EMT) *vs* a myofibroblast (EMyT) phenotype. Type I collagen expression is the most direct measure of fibrogenesis, and the literature suggests that  $\alpha$ -SMA-positive cells are the primary effectors of fibrogenesis<sup>[55,62,68,69]</sup>. Nevertheless, surrogate fibroblast markers have often been used to identify EMT, most notably FSP-1, despite some data suggesting that it is nonspecific<sup>[68,70,71]</sup>.

Mendez *et al.*<sup>[72]</sup> examined the expression of four different mesenchymal markers, including FSP-1, vimentin,  $\alpha$ -SMA, and procollagen I. Their lack of colocalization with yellow fluorescent protein (YFP) in the setting of fibrosis supports the conclusion that in these models EMT does not contribute to fibrosis. The complete absence of its colocalization with YFP in their study suggests that liver epithelial cells do not transition to either mesenchymal cells or myofibroblasts in the mouse models examined.

The hypothesis of hepatocyte EMT contributing to liver fibrosis has been also challenged by a cell lineage strategy in mice<sup>[67]</sup>. A lineage tracing study in which  $\beta$ -galactosidase was expressed under the control of the hepatocyte marker albumin in transgenic mice expressing a collagen marker provided strong evidence against hepatocyte EMT in the CCl<sub>4</sub> model of fibrosis<sup>[73]</sup>. Triple transgenic mice with permanent cell labeling were produced to track hepatocyte-derived cells and type I collagen-expressing cells. Hepatocytes isolated from these triple transgenic mice were able to undergo EMT in culture when incubated with TGF- $\beta$ 1. However, in mice challenged by CCl<sub>4</sub>, no cells exhibited a double labeling specific for both hepatocytes and collagen expressing cells<sup>[73]</sup>. These observations also suggest that hepatocytes may not undergo EMT *in vivo*, while the observed transition *in vitro* might be an experimental artifact.

## EMT IN CHOLANGIOCYTES

The assumption that liver epithelial cells undergo EMT in liver fibrosis cannot however be ruled out for biliary epithelial cells. Indeed, biliary epithelial cell EMT could represent a cellular mechanism supporting histological observations<sup>[70]</sup>. For instance, primary biliary cirrhosis (PBC), a prototypical biliary-type liver disease, is characterized by both the loss of biliary epithelial cells and the concomitant development of periportal fibrosis.

The bile duct basement membranes undergo degradation in fibrogenic liver diseases and that cholangiocytes, the other major hepatic epithelial cell type, assume fibroblast-like, non-cuboidal shapes. Therefore, it became obvious that the next step was to investigate whether or not biliary cells could undergo EMT in chronic liver disease<sup>[27]</sup>. It is well established that proliferating cholangiocytes within the so-called “ductular reaction” (*i.e.*, “reactive cholangiocytes”), detectable in all types of chronic liver disease, express a variety of pro-fibrogenic growth factors and cytokines and are likely to contribute to fibrosis and inflammation by promoting activation, proliferation, and collagen synthesis in the surrounding pro-fibrogenic cells<sup>[74-80]</sup>. Nevertheless, the possibility of a direct contribution of cholangiocytes to fibrosis *via* EMT was suggested by Omenetti and his colleagues<sup>[81]</sup> showing *in vitro* a complete EMT in an immature cholangiocyte cell line treated with activated HSC conditioned medium.

Biliary epithelial cell EMT was confirmed by another study analyzing liver of patients with PBC, primary sclerosing cholangitis or alcoholic liver disease. Irrespective

of the underlying etiology, biliary epithelial cells from ducts associated with the ductular reaction were positive for FSP-1 and vimentin<sup>[82]</sup>. In biliary atresia, a disease defined by a destructive inflammatory obliterative cholangiopathy with portal tract fibrosis and ductular proliferation<sup>[83]</sup>, biliary epithelial cells were shown to express FSP-1 and vimentin, while hepatocytes were not. Moreover, the authors of this study show that the expression of mesenchymal markers in biliary epithelial cells is observed in all liver disease with a ductular proliferation component<sup>[84]</sup>. The common bile duct ligation (BDL) is an experimental liver fibrosis model that induces strong ductular reaction. In mice submitted to BDL, biliary epithelial cells undergo EMT as shown by  $\alpha$ -SMA and type I collagen expression<sup>[85]</sup>.

Evidence of cholangiocyte EMT was recently challenged with the lineage-tracing methodology previously used for the investigation of hepatocyte EMT<sup>[27]</sup>. Along these lines, Scholten and the colleagues<sup>[86]</sup> employed the Cre-Lox technology for lineage tracing and studied several mouse strains expressing Cre under cholangiocyte-, HSC-, or FSP-1-specific promoters in two established models of liver fibrosis, *i.e.*, chronic CCl<sub>4</sub> intoxication and common BDL. In this case the fundamental experiment was tracing the fate of cells expressing K19, a bile ductular cell-specific marker, after permanent genetic Cre-mediated labeling of cholangiocytes. The key result of this study was that, although myofibroblast markers were often found in the close proximity of the K19+ progeny of cholangiocytes, the two signals never overlapped in either CCl<sub>4</sub> or BDL fibrosis. Based on these and other observations reported in the paper, the authors concluded that cholangiocyte EMT does not occur in their experimental models.

It may be that in human livers EMT occurs in cirrhosis, a state not well modeled in rodents, and may require a florid ductular reaction, which is also poorly mimicked by rodent models. Alternatively, this discrepancy may reflect the limitations of immunohistochemistry-based lineage-tracing methodology<sup>[67]</sup>. Future work should focus on better understanding the direct contribution of dysfunctional epithelial cells to liver fibrosis, as well as determining the mechanistic relationships between fibrogenesis and the progenitor cell activation characteristic of the ductular reaction. This will ultimately require the development of animal models of biliary fibrosis that better reflect human disease<sup>[67]</sup>.

## SPECIFIC CELLULAR MARKERS IN EMT

The most widely used marker identifying myofibroblasts is the cytoskeletal protein  $\alpha$ -SMA that is a part of the contractile machinery and is involved in cell motility<sup>[27]</sup>. In adult normal tissue,  $\alpha$ -SMA expression is mostly restricted to vascular smooth muscle cells, but in most chronic inflammatory and fibrogenic disease states, it is often found in myofibroblasts of different derivation, and this expression is interpreted as an active involvement of these cells in fibrogenesis (*i.e.*, “activated myofibroblast”).

**Table 1 Useful biomarkers for identifying epithelial-mesenchymal transition**

| Biomarkers                 | Myofibroblast | Hepatic stellate cell | Hepatocyte | Cholangiocyte |
|----------------------------|---------------|-----------------------|------------|---------------|
| $\alpha$ -SMA <sup>1</sup> | +             | +                     | -          | -             |
| Vimentin <sup>1</sup>      | +             | +                     | -          | -             |
| Desmin <sup>1</sup>        | +             | +                     | -          | -             |
| ICAM-1                     | +             | +                     | -          | -             |
| Collagen type IV           | +             | +                     | -          | -             |
| Fibronectin                | +             | +                     | -          | -             |
| Fibulin-2                  | +             | -                     | -          | -             |
| IL-6 mRNA                  | +             | -                     | -          | -             |
| NCAM                       | +             | -                     | -          | -             |
| Synaptophysin              | +             | -                     | -          | -             |
| Neurotrophin               | +             | -                     | -          | -             |
| Neural growth factor       | +             | -                     | -          | -             |
| $\alpha$ B-crystalline     | +             | -                     | -          | -             |
| Tyrosine kinase            | +             | -                     | -          | -             |
| FSP-1 <sup>1</sup>         | +             | -                     | -          | -             |
| HSP47 <sup>1</sup>         | +             | -                     | -          | -             |
| CD95L                      | -             | +                     | -          | -             |
| $\alpha$ 2-macroglobulin   | -             | +                     | -          | -             |
| P100                       | -             | +                     | -          | -             |
| Reelin                     | -             | +                     | -          | -             |
| Fascin                     | -             | +                     | -          | -             |
| E-cadherin                 | -             | -                     | +          | +             |
| Cytokeratin                | -             | -                     | +          | +             |
| K19                        | -             | -                     | -          | +             |
| Albumin                    | -             | -                     | +          | -             |
| Slug <sup>1</sup>          | +             | ?                     | -          | -             |
| Twist <sup>1</sup>         | +             | ?                     | -          | -             |
| Snail <sup>1</sup>         | +             | ?                     | -          | -             |

<sup>1</sup>Previously proven markers associated with epithelial-mesenchymal transition.  $\alpha$ -SMA:  $\alpha$ -smooth muscle actin; ICAM-1: Intercellular adhesion molecule-1; IL-6: Interleukin-6; NCAM: Neural cell adhesion molecule; FSP-1: Fibroblast-specific protein-1.

Accordingly,  $\alpha$ -SMA cannot be a good lineage marker since its expression is activated by disease states and, in addition, does not denote function. Regardless of this, there is supportive evidence that epithelial cells express intermediate filaments such as  $\alpha$ -SMA and vimentin following tissue injury<sup>[4,87]</sup>.

A multitude of studies have shown that epithelial cells, including hepatocytes, when cultured *in vitro* retain epithelial features including polarity and specific protein expression (*i.e.*, albumin for hepatocytes), but when chronically stimulated with TGF- $\beta$ 1 or serum factors acquire a pattern of gene expression that is somehow typical of myofibroblasts *in vivo* and in the mesenchyme during development<sup>[39,88-91]</sup>. These genes are often represented by Slug, Twist, Snail,  $\alpha$ -SMA, vimentin, desmin, FSP-1, and discoidin domain receptor tyrosine kinase 2. Some of these markers have been used to identify epithelial cells that are in the midst of undergoing an EMT associated with chronic inflammation. These cells continue to exhibit epithelial-specific morphology and molecular markers, such as cytokeratin and E-cadherin, but often show the concomitant expression of the FSP-1 and  $\alpha$ -SMA. These aspects have been proposed to represent the intermediate stages of EMT, when epithelial markers

continue to be expressed but new mesenchymal markers have already been acquired, and, overall, these observations have led to the notion of the so-called “partial EMT”<sup>[53]</sup>.

Previous work has demonstrated in a model of fetal hepatocytes that TGF- $\beta$ 1 treatment induces EMT-like morphologic changes in 50%-60% of the hepatocyte population, whereas the remaining hepatocytes undergo apoptosis<sup>[38,40]</sup>. This means that EMT can be elicited by several oncogenic pathways (Src, Ras, integrin, Wnt/ $\beta$ -catenin and Notch)<sup>[27,92]</sup>. In particular, Ras-MAPK has been shown to activate two related transcription factors known as Snail and Slug<sup>[93]</sup>. Both of these proteins are transcriptional repressors of E-cadherin and their expression induces EMT.

Chronic liver damage leads to fibrotic degeneration of parenchyma, characterized by the formation of fibrotic septa. Except for HSCs, portal myofibroblasts can produce collagen in the liver<sup>[94]</sup>. Although both cell types show similar expression patterns of intercellular adhesion molecule-1, desmin, vimentin, collagen type IV, fibronectin, and  $\alpha$ -SMA, several differences between them have also been observed<sup>[94]</sup>. For instance, cultured portal myofibroblasts are positive for fibulin-2 and interleukin-6 mRNA, whereas CD95L,  $\alpha$ 2-macroglobulin, P100, and reelin are exclusively expressed by activated HSCs<sup>[94-100]</sup>. In addition, neural cell adhesion molecule, synaptophysin, neurotrophin, neural growth factor,  $\alpha$ B-crystallin, and tyrosine kinases are markers that distinguish HSCs from portal myofibroblasts<sup>[99,101]</sup>. Experiments using these markers have shown that myofibroblastic cells in fibrotic septa strongly resemble portal myofibroblasts, that they may originate and migrate from the portal tract, and that they are different from sinusoidal HSCs<sup>[19]</sup>.

Uyama *et al.*<sup>[19]</sup> found that fascin is present in intra-lobular sinusoidal areas, but not in the periportal areas or fibrotic septa of the human liver. In addition, the localization of fascin in the sinusoidal area is similar to that of vimentin. They concluded that fascin was localized in human HSCs, but not in (myo)fibroblasts of the periportal area or fibrotic septa.

Evidence favoring biliary EMT comes largely from immunohistochemical studies of fibrotic human and rodent livers that identified cholangiocytes coexpressing epithelial markers (especially the cholangiocyte marker K19) and mesenchymal markers (*i.e.*, FSP-1, vimentin, and HSP47)<sup>[64]</sup>. Table 1 shows the summary of useful biomarkers for identifying EMT.

## CONCLUSION

The pathogenesis of liver fibrosis is now better understood than ever before. It is increasingly recognized that the fibrogenic cells in the liver are heterogeneous in both their formation and their behaviour.

EMT is an established process in embryo development and plays an important role in liver fibrosis. Discussions now arise on the involvement of EMT in organ



fibrosis. The possibility that EMT could contribute to hepatic fibrogenesis in chronic liver diseases reinforced the concept that activated HSCs are not the only key players in the hepatic fibrogenic process and that other cell types, either hepatic or extrahepatic (bone marrow-derived cells and circulating fibrocytes) could contribute to this process. The presence of cells expressing both epithelial and mesenchymal markers suggests that EMT is a feature of liver fibrosis, however the ability of these cells to produce ECM *in vivo* has not yet been documented.

Therefore, the knowledge relative to the interpretation of what is defined as EMT in chronic fibrogenic disorders of the liver represents a scientific treasure that has prompted discussion, animated debates and has ultimately provided further maturity in this field of research. Definitely, there is now need for a more insightful analysis of the real pathophysiological meaning of these observations beyond their morphologic and biological features. Nevertheless, the future holds great promise for EMT as a viable therapeutic target.

EMT research in the next few years promises to be exciting, as new mouse models and molecular probes are identified to address the identities of the EMT-inducing microenvironmental signals, the nature of the cellular response of such signals and signaling machinery within epithelial cells.

Future research will surely be required on uncovering the origin of all fibrogenic cells within the liver and the molecular similarities and differences among the EMT programs.

## REFERENCES

- Friedman SL. Mechanisms of hepatic fibrogenesis. *Gastroenterology* 2008; **134**: 1655-1669 [PMID: 18471545 DOI: 10.1053/j.gastro.2008.03.003]
- Marsillach J, Ferré N, Camps J, Rull A, Beltran R, Joven J. Changes in the expression of genes related to apoptosis and fibrosis pathways in CCl<sub>4</sub>-treated rats. *Mol Cell Biochem* 2008; **308**: 101-109 [PMID: 17938867 DOI: 10.1007/s11010-007-9617-0]
- Dooley S, Hamzavi J, Ciucan L, Godoy P, Ilkavets I, Ehnert S, Ueberham E, Gebhardt R, Kanzler S, Geier A, Breitkopf K, Weng H, Mertens PR. Hepatocyte-specific Smad7 expression attenuates TGF-beta-mediated fibrogenesis and protects against liver damage. *Gastroenterology* 2008; **135**: 642-659 [PMID: 18602923 DOI: 10.1053/j.gastro.2008.04.038]
- Nitta T, Kim JS, Mohuczy D, Behrns KE. Murine cirrhosis induces hepatocyte epithelial mesenchymal transition and alterations in survival signaling pathways. *Hepatology* 2008; **48**: 909-919 [PMID: 18712785 DOI: 10.1002/hep.22397]
- Giebler A, Boeschoten MV, Klein C, Borowiak M, Birmeier C, Gassler N, Wasmuth HE, Müller M, Trautwein C, Streetz KL. c-Met confers protection against chronic liver tissue damage and fibrosis progression after bile duct ligation in mice. *Gastroenterology* 2009; **137**: 297-308, 308.e1-4 [PMID: 19208365 DOI: 10.1053/j.gastro.2009.01.068]
- Hinz B, Phan SH, Thannickal VJ, Galli A, Bochaton-Piallat ML, Gabbiani G. The myofibroblast: one function, multiple origins. *Am J Pathol* 2007; **170**: 1807-1816 [PMID: 17525249 DOI: 10.2353/ajpath.2007.070112]
- Kalluri R, Neilson EG. Epithelial-mesenchymal transition and its implications for fibrosis. *J Clin Invest* 2003; **112**: 1776-1784 [PMID: 14679171 DOI: 10.1172/JCI20530]
- Russo FP, Alison MR, Bigger BW, Amofah E, Florou A, Amin F, Bou-Gharios G, Jeffery R, Iredale JP, Forbes SJ. The bone marrow functionally contributes to liver fibrosis. *Gastroenterology* 2006; **130**: 1807-1821 [PMID: 16697743 DOI: 10.1053/j.gastro.2006.01.036]
- Forbes SJ, Russo FP, Rey V, Burra P, Rugge M, Wright NA, Alison MR. A significant proportion of myofibroblasts are of bone marrow origin in human liver fibrosis. *Gastroenterology* 2004; **126**: 955-963 [PMID: 15057733]
- Gao Z, McAlister VC, Williams GM. Repopulation of liver endothelium by bone-marrow-derived cells. *Lancet* 2001; **357**: 932-933 [PMID: 11289353]
- Fujii H, Hirose T, Oe S, Yasuchika K, Azuma H, Fujikawa T, Nagao M, Yamaoka Y. Contribution of bone marrow cells to liver regeneration after partial hepatectomy in mice. *J Hepatol* 2002; **36**: 653-659 [PMID: 11983449]
- Chang YJ, Liu JW, Lin PC, Sun LY, Peng CW, Luo GH, Chen TM, Lee RP, Lin SZ, Harn HJ, Chiou TW. Mesenchymal stem cells facilitate recovery from chemically induced liver damage and decrease liver fibrosis. *Life Sci* 2009; **85**: 517-525 [PMID: 19686763 DOI: 10.1016/j.lfs.2009.08.003]
- Kisseleva T, Uchinami H, Feirt N, Quintana-Bustamante O, Segovia JC, Schwabe RF, Brenner DA. Bone marrow-derived fibrocytes participate in pathogenesis of liver fibrosis. *J Hepatol* 2006; **45**: 429-438 [PMID: 16846660 DOI: 10.1016/j.jhep.2006.04.014]
- Roderfeld M, Rath T, Voswinckel R, Dierkes C, Dietrich H, Zahner D, Graf J, Roeb E. Bone marrow transplantation demonstrates medullar origin of CD34+ fibrocytes and ameliorates hepatic fibrosis in Abcb4-/- mice. *Hepatology* 2010; **51**: 267-276 [PMID: 19827165 DOI: 10.1002/hep.23274]
- Higashiyama R, Inagaki Y, Hong YY, Kushida M, Nakao S, Niioka M, Watanabe T, Okano H, Matsuzaki Y, Shiota G, Okazaki I. Bone marrow-derived cells express matrix metalloproteinases and contribute to regression of liver fibrosis in mice. *Hepatology* 2007; **45**: 213-222 [PMID: 17187438 DOI: 10.1002/hep.21477]
- Bird TG, Lorenzini S, Forbes SJ. Activation of stem cells in hepatic diseases. *Cell Tissue Res* 2008; **331**: 283-300 [PMID: 18046579 DOI: 10.1007/s00441-007-0542-z]
- Iredale JP. Models of liver fibrosis: exploring the dynamic nature of inflammation and repair in a solid organ. *J Clin Invest* 2007; **117**: 539-548 [PMID: 17332881 DOI: 10.1172/JCI30542]
- Wake K. Perisinusoidal stellate cells (fat-storing cells, interstitial cells, lipocytes), their related structure in and around the liver sinusoids, and vitamin A-storing cells in extrahepatic organs. *Int Rev Cytol* 1980; **66**: 303-353 [PMID: 6993411]
- Uyama N, Iimuro Y, Kawada N, Reynaert H, Suzumura K, Hirano T, Kuroda N, Fujimoto J. Fascin, a novel marker of human hepatic stellate cells, may regulate their proliferation, migration, and collagen gene expression through the FAK-PI3K-Akt pathway. *Lab Invest* 2012; **92**: 57-71 [PMID: 22005766 DOI: 10.1038/labinvest.2011.150]
- Mormone E, George J, Nieto N. Molecular pathogenesis of hepatic fibrosis and current therapeutic approaches. *Chem Biol Interact* 2011; **193**: 225-231 [PMID: 21803030 DOI: 10.1016/j.cbi.2011.07.001]
- Friedman SL. Seminars in medicine of the Beth Israel Hospital, Boston. The cellular basis of hepatic fibrosis. Mechanisms and treatment strategies. *N Engl J Med* 1993; **328**: 1828-1835 [PMID: 8502273 DOI: 10.1056/NEJM199306243282508]
- Pinzani M. Novel insights into the biology and physiology of the Ito cell. *Pharmacol Ther* 1995; **66**: 387-412 [PMID: 7667403]
- Gressner AM. Cytokines and cellular crosstalk involved in the activation of fat-storing cells. *J Hepatol* 1995; **22**: 28-36 [PMID: 7665846]
- Ramadori G, Veit T, Schwöglar S, Dienes HP, Knittel T, Rieder H, Meyer zum Büschenfelde KH. Expression of the gene



- of the alpha-smooth muscle-actin isoform in rat liver and in rat fat-storing (ITO) cells. *Virchows Arch B Cell Pathol Incl Mol Pathol* 1990; **59**: 349-357 [PMID: 1705733]
- 25 **Iredale JP**, Benyon RC, Arthur MJ, Ferris WF, Alcolado R, Winwood PJ, Clark N, Murphy G. Tissue inhibitor of metalloproteinase-1 messenger RNA expression is enhanced relative to interstitial collagenase messenger RNA in experimental liver injury and fibrosis. *Hepatology* 1996; **24**: 176-184 [PMID: 8707259 DOI: 10.1002/hep.510240129]
- 26 **Théret N**, Musso O, L'Helgoualc'h A, Clément B. Activation of matrix metalloproteinase-2 from hepatic stellate cells requires interactions with hepatocytes. *Am J Pathol* 1997; **150**: 51-58 [PMID: 9006321]
- 27 **Pinzani M**. Epithelial-mesenchymal transition in chronic liver disease: fibrogenesis or escape from death? *J Hepatol* 2011; **55**: 459-465 [PMID: 21320559 DOI: 10.1016/j.jhep.2011.02.001]
- 28 **Choi SS**, Diehl AM. Epithelial-to-mesenchymal transitions in the liver. *Hepatology* 2009; **50**: 2007-2013 [PMID: 19824076 DOI: 10.1002/hep.23196]
- 29 **Yang L**, Jung Y, Omenetti A, Witek RP, Choi S, Vandongen HM, Huang J, Alpini GD, Diehl AM. Fate-mapping evidence that hepatic stellate cells are epithelial progenitors in adult mouse livers. *Stem Cells* 2008; **26**: 2104-2113 [PMID: 18511600 DOI: 10.1634/stemcells.2008-0115]
- 30 **Kordes C**, Sawitz A, Müller-Marbach A, Ale-Agha N, Keitel V, Klonowski-Stumpe H, Häussinger D. CD133+ hepatic stellate cells are progenitor cells. *Biochem Biophys Res Commun* 2007; **352**: 410-417 [PMID: 17118341 DOI: 10.1016/j.bbrc.2006.11.029]
- 31 **Kinnman N**, Housset C. Peribiliary myofibroblasts in biliary type liver fibrosis. *Front Biosci* 2002; **7**: d496-d503 [PMID: 11815289]
- 32 **Li Z**, Dranoff JA, Chan EP, Uemura M, Sévigny J, Wells RG. Transforming growth factor-beta and substrate stiffness regulate portal fibroblast activation in culture. *Hepatology* 2007; **46**: 1246-1256 [PMID: 17625791 DOI: 10.1002/hep.21792]
- 33 **Tuchweber B**, Desmoulière A, Bochaton-Piallat ML, Rubbia-Brandt L, Gabbiani G. Proliferation and phenotypic modulation of portal fibroblasts in the early stages of cholestatic fibrosis in the rat. *Lab Invest* 1996; **74**: 265-278 [PMID: 8569191]
- 34 **Desmoulière A**, Darby I, Costa AM, Raccurt M, Tuchweber B, Sommer P, Gabbiani G. Extracellular matrix deposition, lysyl oxidase expression, and myofibroblastic differentiation during the initial stages of cholestatic fibrosis in the rat. *Lab Invest* 1997; **76**: 765-778 [PMID: 9194853]
- 35 **Firincieli D**, Boissan M, Chignard N. Epithelial-mesenchymal transition in the liver. *Gastroenterol Clin Biol* 2010; **34**: 523-528 [PMID: 20615641 DOI: 10.1016/j.gcb.2010.04.017]
- 36 **Carnona-Cuenca I**, Herrera B, Ventura JJ, Roncero C, Fernández M, Fabregat I. EGF blocks NADPH oxidase activation by TGF-beta in fetal rat hepatocytes, impairing oxidative stress, and cell death. *J Cell Physiol* 2006; **207**: 322-330 [PMID: 16331683 DOI: 10.1002/jcp.20568]
- 37 **Eghbali-Fatourechi G**, Sieck GC, Prakash YS, Maercklein P, Gores GJ, Fitzpatrick LA. Type I procollagen production and cell proliferation is mediated by transforming growth factor-beta in a model of hepatic fibrosis. *Endocrinology* 1996; **137**: 1894-1903 [PMID: 8612529]
- 38 **Valdés F**, Alvarez AM, Locascio A, Vega S, Herrera B, Fernández M, Benito M, Nieto MA, Fabregat I. The epithelial mesenchymal transition confers resistance to the apoptotic effects of transforming growth factor Beta in fetal rat hepatocytes. *Mol Cancer Res* 2002; **1**: 68-78 [PMID: 12496370]
- 39 **Kaimori A**, Potter J, Kaimori JY, Wang C, Mezey E, Koteish A. Transforming growth factor-beta1 induces an epithelial-to-mesenchymal transition state in mouse hepatocytes in vitro. *J Biol Chem* 2007; **282**: 22089-22101 [PMID: 17513865 DOI: 10.1074/jbc.M700998200]
- 40 **Del Castillo G**, Murillo MM, Alvarez-Barrientos A, Bertran E, Fernández M, Sánchez A, Fabregat I. Autocrine production of TGF-beta confers resistance to apoptosis after an epithelial-mesenchymal transition process in hepatocytes: Role of EGF receptor ligands. *Exp Cell Res* 2006; **312**: 2860-2871 [PMID: 16828470 DOI: 10.1016/j.yexcr.2006.05.017]
- 41 **Kitao A**, Sato Y, Sawada-Kitamura S, Harada K, Sasaki M, Morikawa H, Shiomi S, Honda M, Matsui O, Nakanuma Y. Endothelial to mesenchymal transition via transforming growth factor-beta1/Smad activation is associated with portal venous stenosis in idiopathic portal hypertension. *Am J Pathol* 2009; **175**: 616-626 [PMID: 19608867 DOI: 10.2353/ajpath.2009.081061]
- 42 **Inagaki Y**, Okazaki I. Emerging insights into Transforming growth factor beta Smad signal in hepatic fibrogenesis. *Gut* 2007; **56**: 284-292 [PMID: 17303605 DOI: 10.1136/gut.2005.088690]
- 43 **Rubtsov YP**, Rudensky AY. TGFbeta signalling in control of T-cell-mediated self-reactivity. *Nat Rev Immunol* 2007; **7**: 443-453 [PMID: 17525753 DOI: 10.1038/nri2095]
- 44 **Gressner AM**, Weiskirchen R, Breitkopf K, Dooley S. Roles of TGF-beta in hepatic fibrosis. *Front Biosci* 2002; **7**: d793-d807 [PMID: 11897555]
- 45 **Annoni G**, Weiner FR, Zern MA. Increased transforming growth factor-beta 1 gene expression in human liver disease. *J Hepatol* 1992; **14**: 259-264 [PMID: 1380023]
- 46 **Leask A**, Abraham DJ. TGF-beta signaling and the fibrotic response. *FASEB J* 2004; **18**: 816-827 [PMID: 15117886 DOI: 10.1096/fj.03-1273rev]
- 47 **Zavadil J**, Böttinger EP. TGF-beta and epithelial-to-mesenchymal transitions. *Oncogene* 2005; **24**: 5764-5774 [PMID: 16123809 DOI: 10.1038/sj.onc.1208927]
- 48 **Medici D**, Hay ED, Goodenough DA. Cooperation between snail and LEF-1 transcription factors is essential for TGF-beta1-induced epithelial-mesenchymal transition. *Mol Biol Cell* 2006; **17**: 1871-1879 [PMID: 16467384 DOI: 10.1091/mbc.E05-08-0767]
- 49 **Zavadil J**, Cermak L, Soto-Nieves N, Böttinger EP. Integration of TGF-beta/Smad and Jagged1/Notch signalling in epithelial-to-mesenchymal transition. *EMBO J* 2004; **23**: 1155-1165 [PMID: 14976548 DOI: 10.1038/sj.emboj.7600069]
- 50 **Zeisberg M**, Yang C, Martino M, Duncan MB, Rieder F, Tanjore H, Kalluri R. Fibroblasts derive from hepatocytes in liver fibrosis via epithelial to mesenchymal transition. *J Biol Chem* 2007; **282**: 23337-23347 [PMID: 17562716 DOI: 10.1074/jbc.M700194200]
- 51 **Thompson EW**, Newgreen DF, Tarin D. Carcinoma invasion and metastasis: a role for epithelial-mesenchymal transition? *Cancer Res* 2005; **65**: 5991-5995; discussion 5995 [PMID: 16024595 DOI: 10.1158/0008-5472.CAN-05-0616]
- 52 **Tarin D**, Thompson EW, Newgreen DF. The fallacy of epithelial mesenchymal transition in neoplasia. *Cancer Res* 2005; **65**: 5996-6000; discussion 6000-1 [PMID: 16024596 DOI: 10.1158/0008-5472.CAN-05-0699]
- 53 **Kalluri R**, Weinberg RA. The basics of epithelial-mesenchymal transition. *J Clin Invest* 2009; **119**: 1420-1428 [PMID: 19487818 DOI: 10.1172/JCI39104]
- 54 **Liu Y**. Epithelial to mesenchymal transition in renal fibrogenesis: pathologic significance, molecular mechanism, and therapeutic intervention. *J Am Soc Nephrol* 2004; **15**: 1-12 [PMID: 14694152]
- 55 **Zeisberg M**, Neilson EG. Biomarkers for epithelial-mesenchymal transitions. *J Clin Invest* 2009; **119**: 1429-1437 [PMID: 19487819 DOI: 10.1172/JCI36183]
- 56 **Acloque H**, Adams MS, Fishwick K, Bronner-Fraser M, Nieto MA. Epithelial-mesenchymal transitions: the importance of changing cell state in development and disease. *J Clin Invest* 2009; **119**: 1438-1449 [PMID: 19487820 DOI: 10.1172/JCI38019]
- 57 **Okada H**, Danoff TM, Kalluri R, Neilson EG. Early role of Fsp1 in epithelial-mesenchymal transformation. *Am J Physiol* 1997; **273**: F563-F574 [PMID: 9362334]
- 58 **Strutz F**, Okada H, Lo CW, Danoff T, Carone RL, Tomasze-

- wski JE, Neilson EG. Identification and characterization of a fibroblast marker: FSP1. *J Cell Biol* 1995; **130**: 393-405 [PMID: 7615639]
- 59 **Yang J**, Liu Y. Dissection of key events in tubular epithelial to myofibroblast transition and its implications in renal interstitial fibrosis. *Am J Pathol* 2001; **159**: 1465-1475 [PMID: 11583974 DOI: 10.1016/S0002-9440(10)62533-3]
- 60 **Iwano M**, Plieth D, Danoff TM, Xue C, Okada H, Neilson EG. Evidence that fibroblasts derive from epithelium during tissue fibrosis. *J Clin Invest* 2002; **110**: 341-350 [PMID: 12163453 DOI: 10.1172/JCI15518]
- 61 **Sicklick JK**, Choi SS, Bustamante M, McCall SJ, Pérez EH, Huang J, Li YX, Rojkind M, Diehl AM. Evidence for epithelial-mesenchymal transitions in adult liver cells. *Am J Physiol Gastrointest Liver Physiol* 2006; **291**: G575-G583 [PMID: 16710052 DOI: 10.1152/ajpgi.00102.2006]
- 62 **Masszi A**, Speight P, Charbonney E, Lodyga M, Nakano H, Szászi K, Kapus A. Fate-determining mechanisms in epithelial-myofibroblast transition: major inhibitory role for Smad3. *J Cell Biol* 2010; **188**: 383-399 [PMID: 20123992 DOI: 10.1083/jcb.200906155]
- 63 **Fan L**, Sebe A, Péterfi Z, Masszi A, Thirone AC, Rotstein OD, Nakano H, McCulloch CA, Szászi K, Mucsi I, Kapus A. Cell contact-dependent regulation of epithelial-myofibroblast transition via the rho-rho kinase-phospho-myosin pathway. *Mol Biol Cell* 2007; **18**: 1083-1097 [PMID: 17215519 DOI: 10.1091/mbc.E06-07-0602]
- 64 **Masszi A**, Fan L, Rosivall L, McCulloch CA, Rotstein OD, Mucsi I, Kapus A. Integrity of cell-cell contacts is a critical regulator of TGF-beta 1-induced epithelial-to-myofibroblast transition: role for beta-catenin. *Am J Pathol* 2004; **165**: 1955-1967 [PMID: 15579439]
- 65 **Hay ED**, Zuk A. Transformations between epithelium and mesenchyme: normal, pathological, and experimentally induced. *Am J Kidney Dis* 1995; **26**: 678-690 [PMID: 7573028]
- 66 **Xu J**, Lamouille S, Derynck R. TGF-beta-induced epithelial to mesenchymal transition. *Cell Res* 2009; **19**: 156-172 [PMID: 19153598 DOI: 10.1038/cr.2009.5]
- 67 **Chu AS**, Diaz R, Hui JJ, Yanger K, Zong Y, Alpini G, Stanger BZ, Wells RG. Lineage tracing demonstrates no evidence of cholangiocyte epithelial-to-mesenchymal transition in murine models of hepatic fibrosis. *Hepatology* 2011; **53**: 1685-1695 [PMID: 21520179 DOI: 10.1002/hep.24206]
- 68 **Lin SL**, Kisseleva T, Brenner DA, Duffield JS. Pericytes and perivascular fibroblasts are the primary source of collagen-producing cells in obstructive fibrosis of the kidney. *Am J Pathol* 2008; **173**: 1617-1627 [PMID: 19008372 DOI: 10.2353/ajpath.2008.080433]
- 69 **Yamaoka K**, Nouchi T, Marumo F, Sato C. Alpha-smooth-muscle actin expression in normal and fibrotic human livers. *Dig Dis Sci* 1993; **38**: 1473-1479 [PMID: 8344103]
- 70 **Wells RG**. The epithelial-to-mesenchymal transition in liver fibrosis: here today, gone tomorrow? *Hepatology* 2010; **51**: 737-740 [PMID: 20198628 DOI: 10.1002/hep.23529]
- 71 **Le Hir M**, Hegyi I, Cueni-Loffing D, Loffing J, Kaissling B. Characterization of renal interstitial fibroblast-specific protein 1/S100A4-positive cells in healthy and inflamed rodent kidneys. *Histochem Cell Biol* 2005; **123**: 335-346 [PMID: 15856273 DOI: 10.1007/s00418-005-0788-z]
- 72 **Mendez MG**, Kojima S, Goldman RD. Vimentin induces changes in cell shape, motility, and adhesion during the epithelial to mesenchymal transition. *FASEB J* 2010; **24**: 1838-1851 [PMID: 20097873 DOI: 10.1096/fj.09-151639]
- 73 **Taura K**, Miura K, Iwaisako K, Osterreicher CH, Kodama Y, Penz-Osterreicher M, Brenner DA. Hepatocytes do not undergo epithelial-mesenchymal transition in liver fibrosis in mice. *Hepatology* 2010; **51**: 1027-1036 [PMID: 20052656 DOI: 10.1002/hep.23368]
- 74 **Milani S**, Herbst H, Schuppan D, Stein H, Surrenti C. Transforming growth factors beta 1 and beta 2 are differentially expressed in fibrotic liver disease. *Am J Pathol* 1991; **139**: 1221-1229 [PMID: 1750499]
- 75 **Pinzani M**, Milani S, Herbst H, DeFranco R, Grappone C, Gentilini A, Caligiuri A, Pellegrini G, Ngo DV, Romanelli RG, Gentilini P. Expression of platelet-derived growth factor and its receptors in normal human liver and during active hepatic fibrogenesis. *Am J Pathol* 1996; **148**: 785-800 [PMID: 8774134]
- 76 **Grappone C**, Pinzani M, Parola M, Pellegrini G, Caligiuri A, DeFranco R, Marra F, Herbst H, Alpini G, Milani S. Expression of platelet-derived growth factor in newly formed cholangiocytes during experimental biliary fibrosis in rats. *J Hepatol* 1999; **31**: 100-109 [PMID: 10424289]
- 77 **Kinnman N**, Hultcrantz R, Barbu V, Rey C, Wendum D, Poupon R, Housset C. PDGF-mediated chemoattraction of hepatic stellate cells by bile duct segments in cholestatic liver injury. *Lab Invest* 2000; **80**: 697-707 [PMID: 10830780]
- 78 **Pinzani M**, Milani S, De Franco R, Grappone C, Caligiuri A, Gentilini A, Tosti-Guerra C, Maggi M, Failli P, Ruocco C, Gentilini P. Endothelin 1 is overexpressed in human cirrhotic liver and exerts multiple effects on activated hepatic stellate cells. *Gastroenterology* 1996; **110**: 534-548 [PMID: 8566602]
- 79 **Caligiuri A**, Glaser S, Rodgers RE, Phinzy JL, Robertson W, Papa E, Pinzani M, Alpini G. Endothelin-1 inhibits secretin-stimulated ductal secretion by interacting with ETA receptors on large cholangiocytes. *Am J Physiol* 1998; **275**: G835-G846 [PMID: 9756516]
- 80 **Marra F**, DeFranco R, Grappone C, Milani S, Pastacaldi S, Pinzani M, Romanelli RG, Laffi G, Gentilini P. Increased expression of monocyte chemotactic protein-1 during active hepatic fibrogenesis: correlation with monocyte infiltration. *Am J Pathol* 1998; **152**: 423-430 [PMID: 9466568]
- 81 **Omenetti A**, Porrello A, Jung Y, Yang L, Popov Y, Choi SS, Witek RP, Alpini G, Venter J, Vandongen HM, Syn WK, Baroni GS, Benedetti A, Schuppan D, Diehl AM. Hedgehog signaling regulates epithelial-mesenchymal transition during biliary fibrosis in rodents and humans. *J Clin Invest* 2008; **118**: 3331-3342 [PMID: 18802480 DOI: 10.1172/JCI35875]
- 82 **Rygiel KA**, Robertson H, Marshall HL, Pekalski M, Zhao L, Booth TA, Jones DE, Burt AD, Kirby JA. Epithelial-mesenchymal transition contributes to portal tract fibrogenesis during human chronic liver disease. *Lab Invest* 2008; **88**: 112-123 [PMID: 18059363 DOI: 10.1038/labinvest.3700704]
- 83 **Hartley JL**, Davenport M, Kelly DA. Biliary atresia. *Lancet* 2009; **374**: 1704-1713 [PMID: 19914515 DOI: 10.1016/S0140-6736(09)60946-6]
- 84 **Diaz R**, Kim JW, Hui JJ, Li Z, Swain GP, Fong KS, Csiszar K, Russo PA, Rand EB, Furth EE, Wells RG. Evidence for the epithelial to mesenchymal transition in biliary atresia fibrosis. *Hum Pathol* 2008; **39**: 102-115 [PMID: 17900655 DOI: 10.1016/j.humpath.2007.05.021]
- 85 **Xia JL**, Dai C, Michalopoulos GK, Liu Y. Hepatocyte growth factor attenuates liver fibrosis induced by bile duct ligation. *Am J Pathol* 2006; **168**: 1500-1512 [PMID: 16651617 DOI: 10.2353/ajpath.2006.050747]
- 86 **Scholten D**, Osterreicher CH, Scholten A, Iwaisako K, Gu G, Brenner DA, Kisseleva T. Genetic labeling does not detect epithelial-to-mesenchymal transition of cholangiocytes in liver fibrosis in mice. *Gastroenterology* 2010; **139**: 987-998 [PMID: 20546735 DOI: 10.1053/j.gastro.2010.05.005]
- 87 **Ng YY**, Fan JM, Mu W, Nikolic-Paterson DJ, Yang WC, Huang TP, Atkins RC, Lan HY. Glomerular epithelial-myofibroblast transdifferentiation in the evolution of glomerular crescent formation. *Nephrol Dial Transplant* 1999; **14**: 2860-2872 [PMID: 10570089]
- 88 **Fan JM**, Ng YY, Hill PA, Nikolic-Paterson DJ, Mu W, Atkins RC, Lan HY. Transforming growth factor-beta regulates tubular epithelial-myofibroblast transdifferentiation in vitro. *Kidney Int* 1999; **56**: 1455-1467 [PMID: 10504497 DOI: 10.1046/j.1523-1755.1999.00656.x]
- 89 **Gershengorn MC**, Hardikar AA, Wei C, Geras-Raaka E,

- Marcus-Samuels B, Raaka BM. Epithelial-to-mesenchymal transition generates proliferative human islet precursor cells. *Science* 2004; **306**: 2261-2264 [PMID: 15564314 DOI: 10.1126/science.1101968]
- 90 **Russ HA**, Ravassard P, Kerr-Conte J, Pattou F, Efrat S. Epithelial-mesenchymal transition in cells expanded in vitro from lineage-traced adult human pancreatic beta cells. *PLoS One* 2009; **4**: e6417 [PMID: 19641613 DOI: 10.1371/journal.pone.0006417]
- 91 **Godoy P**, Hengstler JG, Ilkavets I, Meyer C, Bachmann A, Müller A, Tuschl G, Mueller SO, Dooley S. Extracellular matrix modulates sensitivity of hepatocytes to fibroblastoid de-differentiation and transforming growth factor beta-induced apoptosis. *Hepatology* 2009; **49**: 2031-2043 [PMID: 19274752 DOI: 10.1002/hep.22880]
- 92 **Guarino M**, Rubino B, Ballabio G. The role of epithelial-mesenchymal transition in cancer pathology. *Pathology* 2007; **39**: 305-318 [PMID: 17558857 DOI: 10.1080/00313020701329914]
- 93 **Zhou BP**, Deng J, Xia W, Xu J, Li YM, Gunduz M, Hung MC. Dual regulation of Snail by GSK-3beta-mediated phosphorylation in control of epithelial-mesenchymal transition. *Nat Cell Biol* 2004; **6**: 931-940 [PMID: 15448698 DOI: 10.1038/ncb1173]
- 94 **Ramadori G**, Saile B. Portal tract fibrogenesis in the liver. *Lab Invest* 2004; **84**: 153-159 [PMID: 14688800 DOI: 10.1038/labinvest.3700030]
- 95 **Dubuisson L**, Lepreux S, Bioulac-Sage P, Balabaud C, Costa AM, Rosenbaum J, Desmoulière A. Expression and cellular localization of fibrillin-1 in normal and pathological human liver. *J Hepatol* 2001; **34**: 514-522 [PMID: 11394650]
- 96 **Saile B**, Matthes N, Neubauer K, Eisenbach C, El-Armouche H, Dudas J, Ramadori G. Rat liver myofibroblasts and hepatic stellate cells differ in CD95-mediated apoptosis and response to TNF-alpha. *Am J Physiol Gastrointest Liver Physiol* 2002; **283**: G435-G444 [PMID: 12121892 DOI: 10.1152/ajpgi.00441.2001]
- 97 **Knittel T**, Kobold D, Saile B, Grundmann A, Neubauer K, Piscaglia F, Ramadori G. Rat liver myofibroblasts and hepatic stellate cells: different cell populations of the fibroblast lineage with fibrogenic potential. *Gastroenterology* 1999; **117**: 1205-1221 [PMID: 10535885]
- 98 **Kobold D**, Grundmann A, Piscaglia F, Eisenbach C, Neubauer K, Steffgen J, Ramadori G, Knittel T. Expression of reelin in hepatic stellate cells and during hepatic tissue repair: a novel marker for the differentiation of HSC from other liver myofibroblasts. *J Hepatol* 2002; **36**: 607-613 [PMID: 11983443]
- 99 **Cassiman D**, Libbrecht L, Desmet V, Denef C, Roskams T. Hepatic stellate cell/myofibroblast subpopulations in fibrotic human and rat livers. *J Hepatol* 2002; **36**: 200-209 [PMID: 11830331]
- 100 **Dranoff JA**, Kruglov EA, Robson SC, Braun N, Zimmermann H, Sévigny J. The ecto-nucleoside triphosphate diphosphohydrolase NTPDase2/CD39L1 is expressed in a novel functional compartment within the liver. *Hepatology* 2002; **36**: 1135-1144 [PMID: 12395323 DOI: 10.1053/jhep.2002.36823]
- 101 **Nakatani K**, Seki S, Kawada N, Kobayashi K, Kaneda K. Expression of neural cell adhesion molecule (N-CAM) in perisinusoidal stellate cells of the human liver. *Cell Tissue Res* 1996; **283**: 159-165 [PMID: 8581955]

**P- Reviewers:** Anand BS, Kravos M **S- Editor:** Song XX

**L- Editor:** A **E- Editor:** Wu HL



## Pediatric non-alcoholic fatty liver disease: New insights and future directions

Pierluigi Marzuillo, Emanuele Miraglia del Giudice, Nicola Santoro

Pierluigi Marzuillo, Emanuele Miraglia del Giudice, Department of women and children and General and Specialized Surgery, Seconda Università degli Studi di Napoli, 80138 Naples, Italy

Nicola Santoro, Department of Pediatrics, Yale University School of Medicine, New Haven, CT 06520, United States

**Author contributions:** All the authors conceived and wrote the manuscript.

**Supported by** The American Heart Association (AHA), No. 13SDG14640038; 2012 Yale Center for Clinical Investigation (YCCI) scholar award to Santoro N; CTSA Grant Number UL1 RR024139 from the National Center for Advancing Translational Science (NCATS), a component of the National Institutes of Health (NIH), and NIH roadmap for Medical Research

**Correspondence to:** Nicola Santoro, MD, PhD, Department of Pediatrics, Yale University School of Medicine, 330 Cedar Street, P.O. Box 208064, New Haven, CT 06520, United States. [nicola.santoro@yale.edu](mailto:nicola.santoro@yale.edu)

Telephone: +1-203-7376356 Fax: +1-203-7856421

Received: October 17, 2013 Revised: February 25, 2014

Accepted: March 17, 2014

Published online: April 27, 2014

with NAFLD severity progression. Evidence that not all of the obese patients develop NAFLD suggests that the disease progression is likely to depend on complex interplay between environmental factors and genetic predisposition. Recently, a non-synonymous SNP (rs738409), characterized by a C to G substitution encoding an isoleucine to methionine substitution at the amino acid position 148 in the patatin like phospholipase containing domain 3 gene (*PNPLA3*), has been associated with hepatic steatosis in a multi-ethnic cohort of adults as well as in children. Another important polymorphisms that acts with *PNPLA3* to convey susceptibility to fatty liver in obese youths is the rs1260326 polymorphism in the glucokinase regulatory protein. The pharmacological approach in NAFLD children poorly adherent to or being unresponsive/partially responsive to lifestyle changes, is aimed at acting upon specific targets involved in the pathogenesis. There are some therapeutic approaches that are being studied in children. This article reviews the current knowledge regarding the pediatric fatty liver disease, the new insights and the future directions.

© 2014 Baishideng Publishing Group Co., Limited. All rights reserved.

**Key words:** Non alcoholic fatty liver disease; *PNPLA3*; Obesity; Insulin resistance; Glucokinase regulatory protein; Fructose

### Abstract

One of the most common complications of childhood obesity is the non-alcoholic fatty liver disease (NAFLD), which is the most common form of liver disease in children. NAFLD is defined by hepatic fat infiltration > 5% hepatocytes, as assessed by liver biopsy, in the absence of excessive alcohol intake, viral, autoimmune and drug-induced liver disease. It encompasses a wide spectrum of liver diseases ranging from simple steatosis to non-alcoholic steatohepatitis, which, in turn, can evolve into cirrhosis and end stage liver disease. Obesity and insulin resistance are the main risk factors for pediatric NAFLD. In fact, NAFLD is strongly associated with the clinical features of insulin resistance especially the metabolic syndrome, prediabetes and type 2 diabetes mellitus (T2D). In particular, it has been clearly shown in obese youth that the prevalence of metabolic syndrome, pre-diabetes and type 2 diabetes increases

**Core tip:** The prevalence of hepatic steatosis is increased in the last three decades concomitantly with the increased prevalence of pediatric obesity. Non-alcoholic fatty liver disease (NAFLD) is the most common form of liver disease in children. The *PNPLA3* rs738409 and the glucokinase regulatory protein rs1260326 are the strongest variants associated with fatty liver in paediatrics. Important risk factors are obesity, insulin resistance, gender, ethnicity and excessive dietetic intake of n-6 polyunsaturated fatty acids and fructose. New pharmacological approaches are object of study, in NAFLD children poorly adherent to or being unrespon-



sive/partially responsive to lifestyle changes.

Marzuillo P, Miraglia del Giudice E, Santoro N. Pediatric non-alcoholic fatty liver disease: New insights and future directions. *World J Hepatol* 2014; 6(4): 217-225 Available from: URL: <http://www.wjgnet.com/1948-5182/full/v6/i4/217.htm> DOI: <http://dx.doi.org/10.4254/wjh.v6.i4.217>

## INTRODUCTION

In the last three decades with the increased prevalence of childhood obesity, there has been an increase also of the obesity complications in paediatrics. One of the most common complications of childhood obesity is the non-alcoholic fatty liver disease (NAFLD), which is the most common form of liver disease in children<sup>[1]</sup>.

NAFLD is defined by hepatic fat infiltration > 5% hepatocytes, as assessed by liver biopsy, in the absence of excessive alcohol intake, viral, autoimmune and drug-induced liver disease<sup>[2,3]</sup>. It encompasses a wide spectrum of liver diseases ranging from simple steatosis to non-alcoholic steatohepatitis (NASH), which, in turn, can evolve into cirrhosis and end stage liver disease<sup>[3,4]</sup>.

The prevalence of NAFLD has more than doubled over the past 20 years. According to a landmark study by Schwimmer *et al*<sup>[1]</sup> based on autopsic data obtained in 1138 children and adolescents of the San Diego county (CA), its prevalence in the general pediatric population is estimated to be nearly 13%, while among obese and overweight children and, particularly, adolescents it rises up to 46%<sup>[1]</sup>. Nevertheless, other studies report quite a wide range of steatosis prevalence, likely due to the different diagnostic methods used. In fact, although liver histology is important for NAFLD evaluation, performing biopsies is not always indispensable from a clinical point of view; therefore, surrogate markers are often used in epidemiological and clinical studies. One of the marker most commonly used is liver aminotransferase [aspartate aminotransferase, and alanine aminotransferase (ALT)] evaluation. Children with NAFLD typically have elevated liver enzymes values<sup>[5]</sup>, which is why elevated serum levels of liver enzymes, even though may misrepresent the entity of intrahepatic damage, are used as a non-invasive test to screen for pediatric NAFLD<sup>[6]</sup>.

## RISK FACTORS FOR THE DEVELOPMENT OF PEDIATRIC NAFLD

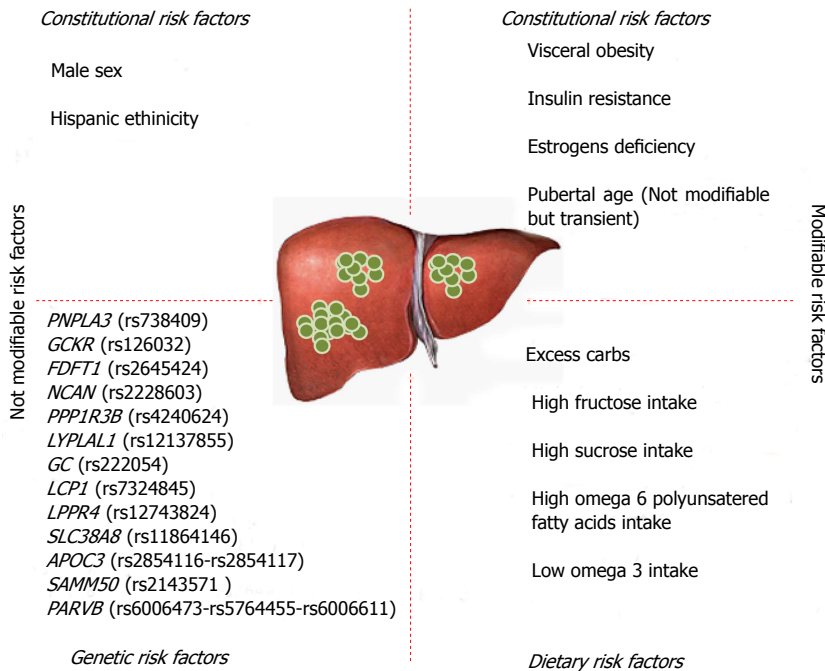
Obesity and insulin resistance are the main risk factors for pediatric NAFLD<sup>[1,7,8]</sup>. In fact, NAFLD is strongly associated with the clinical features of insulin resistance especially the metabolic syndrome (MS), prediabetes and type 2 diabetes mellitus (T2D)<sup>[9-11]</sup>. In particular, it has been clearly shown in obese youth that the prevalence of metabolic syndrome, pre-diabetes and type 2 diabetes increases with progression of NAFLD severity<sup>[12]</sup>.

This picture is strongly contributed by pubertal insulin resistance, a physiologic state characterized by an increased insulin resistance during the adolescence and resolving at the end of the pubertal development and probably consequent to the increase in growth hormone action during this stage of life<sup>[8,13]</sup>. In fact, although obesity is the most important cause of NAFLD among obese and adolescents, it is important to note that a transient insulin resistant state occurs during puberty<sup>[14]</sup>, and that this state worsens the insulin resistance present in obese children in turn accelerating the progression to MS and type 2 diabetes. In healthy individuals this phenomenon is balanced by an increased insulin secretion by the beta cell, but in obese individuals the co-occurrence of obesity and puberty represents the perfect storm causing such a high degree of insulin resistance that the beta cell is not always able to produce enough insulin to maintain the glycemic control<sup>[15-17]</sup>.

Two other critical risk factors for NAFLD development are represented by the gender and the ethnic background. In fact, NAFLD is more common in boys than in girls<sup>[15]</sup> with a male to female ratio of 2:1. This has been explained by the liver-protective role of estrogens, as well as by the potentially negative role of androgens in aggravating NASH<sup>[18,19]</sup>. The beneficial effects of estrogens on liver could be mediated by the beneficial effect on insulin action. Studies showed that insulin sensitivity is greater in premenopausal women compared with age-matched men, and metabolic-related cardiovascular diseases and type 2 diabetes are less frequent in premenopausal women<sup>[20,21]</sup>. Also, estrogens deficiency leads to increased fat mass and body weight in postmenopausal women, which has been associated with increased intraabdominal fat<sup>[22]</sup>. Moreover, Camporez *et al*<sup>[23]</sup> showed that, in mice, endogenous estrogens are important to protect against high-fat diet induced skeletal muscle insulin resistance, whereas E2 treatment in estrogen-deprived mice increased insulin sensitivity in both liver and skeletal muscle. Also, the estrogens effect is important in turn preventing diet-induced ectopic lipid deposition and hepatic and muscle insulin resistance.

The risk linked to the ethnic background has been investigated in large multiethnic populations. A cornerstone article by Browning *et al*<sup>[15]</sup> described for the first time that the prevalence of NAFLD is the highest in the American Hispanic population (45%) and the lowest among African Americans (24%), with the Caucasians showing an intermediate prevalence (33%). Ethnic differences could possibly be due to different degree of insulin resistance, and of visceral adiposity at equivalent body mass index, but may also be a result of genetics as well as socio-economic factors, including type of diet, exercise choice and living location<sup>[24]</sup>.

The accumulation of fat, as triacylglycerol (TAG), in the hepatocyte is the fingerprint of fatty liver. The TAG accumulated in the liver mostly derive from adipose tissue lipolysis (60%) and hepatic de novo lipogenesis (26%) whereas only a small amount directly derives from the diet as chylomicron remnants (14%)<sup>[25]</sup>. A large body of



**Figure 1 Risk factors for non-alcoholic fatty liver disease development.** In this figure, all risk factors for non-alcoholic fatty liver disease (NAFLD) are summarized. We divided the risk factors in modifiable and not modifiable. Among not modifiable risk factors we listed *PNPLA3* rs738409, but as underlined in the text, the weight loss can modify the capacity of *PNPLA3* polymorphism to lead to hepatic steatosis. *PNPLA3*: Patatin like phospholipase 3 gene; *GSKR*: Glucokinase regulatory protein; *FDFT1*: Farnesyl-diphosphate farnesyltransferase 1; *NCAN*: Neurocan; *PPP1R3B*: Protein phosphatase 1 regulatory subunit 3B; *LYPLAL1*: Lysophospholipase-like 1; *GC*: Group-specific component; *LCP1*: Lymphocyte cytosolic protein-1; *LPPR4*: Lipid phosphate phosphatase-related protein type 4; *SLC38A8*: Solute carrier family 38 member 8; *APOC3*: Apolipoprotein C3 gene; *SAMM50*: Sorting and assembly machinery component; *PARVB*: Parvin beta.

evidence suggests that not only the amount, but also the quality of dietary fat plays a role in NAFLD development<sup>[26]</sup>. In particular, recently published literature provides clues that the dietary imbalance between omega-6 (n-6) and omega-3 (n-3) polyunsaturated fatty acids (PUFAs) leads to development of an adverse cardiovascular and metabolic profile, thus contributing to the pathogenesis of NAFLD<sup>[27]</sup>. N-6 and n-3 are essential fatty acids; this means that they are not synthesized by human body. N-6 species are mainly represented by linoleic acid while n-3 are represented by alpha-linolenic acid, mainly found in plants and limited sets of seeds and nuts<sup>[28]</sup>. N-6 is readily converted by the body into other species such as omega-9 and so incorporated into triglycerides, or converted into arachidonic acid, which is the parent molecule of the main regulators of the inflammatory response including prostaglandins (cyclooxygenase pathway), leukotrienes (lipoxygenase pathway) and thromboxane<sup>[28]</sup>. It has been demonstrated that individuals with NAFLD have a lower dietary intake of n-3 PUFAs than healthy controls<sup>[29]</sup> and an increased n-6/n-3 PUFA ratio consumed in the diet<sup>[29,30]</sup>. Consistent with these data, lipidomic studies have shown that the intrahepatic fat in subjects with steatohepatitis is composed by an excess n-6 PUFA<sup>[31]</sup>. In particular, studying the three groups of subjects-NAFLD, NASH and healthy controls- it has been observed a progressive increase in the n-6/n-3 ratio from controls to NASH subjects<sup>[31]</sup>.

Another dietary risk factor contributing to the development of NAFLD is the fructose. Nowadays, the majority of fructose consumption comes from the added sugars in the beverages more than from the fruit<sup>[32]</sup>. Strong evidence exists that high in fructose intake results in increased de novo lipogenesis (DNL), dyslipidemia, insulin resistance, and obesity in humans<sup>[33]</sup>. Stanhope *et al.*<sup>[33]</sup>, studying the effect of consumption of glucose- or fructose-sweetened beverages providing 25% of energy requirements for 10

wk in overweight and obese subjects, provided the evidence that the consumption of fructose, instead of glucose, specifically increases DNL, promotes dyslipidemia, decreases insulin sensitivity, and increases visceral adiposity in overweight/obese adults.

### Progression from NAFLD to NASH

A recent study demonstrated that NAFLD in children is a progressive disease<sup>[34]</sup>. In that study the authors showed that 6% of subjects with early onset NAFLD develop cirrhosis and end-stage liver disease with the consequent need of liver transplantation.

The oxidative stress seems to explain the progression to NASH and liver fibrosis. Reactive oxygen species (ROS) can induce hepatocellular injury by the inhibition of the mitochondrial respiratory chain enzymes, the inactivation of glyceraldehyde-3-phosphate dehydrogenase and the inactivation of membrane sodium channels. ROS further cause lipid peroxidation, cytokine production, and induce Fas ligand, contributing to hepatocellular injury and fibrosis<sup>[12]</sup>. The risk of progression varies by ethnicity, in fact, as recently demonstrated, the African American obese children and adolescents show a lower degree of liver damage than Caucasians and Hispanics, independent of the degree of hepatic fat accumulation and insulin resistance. These data suggest that African Americans are protected from hepatic damage even in presence of high degree of hepatic fat accumulation and insulin resistance<sup>[35]</sup>.

### GENETIC PREDISPOSITION

Evidence that not all of the obese patients develop NAFLD suggests that disease progression is likely to depend on complex interplay between environmental factors and genetic predisposition (Figure 1).

Recently, a non-synonymous SNP (rs738409), char-

**Table 1** Current and future non-alcoholic fatty liver disease treatment strategies

| Present                          | Under development           |  |
|----------------------------------|-----------------------------|--|
| Weight loss                      | Vitamin E                   | Pentoxifylline   |
| Physical activity                | Metformin                   | Farnesoid X receptor agonists  |
| Reduced dietary sucrose intake   | Probiotics                  | Toll-like receptors modifiers  |
| Reduced dietary fructose intake  | Oral treatment with omega 3 | Glucagon-like peptid-1 receptor agonists resistant to DPP-4 mediated degradation |
| Reduced dietary omega 6 intake   |                             | DPP-4 inhibitors   |
| Increased dietary omega 3 intake |                             |  |

DPP-4: Dipeptidyl peptidase-4.

acterized by a C to G substitution encoding an isoleucine to methionine substitution at the amino acid position 148 in the patatin like phospholipase 3 gene (*PNPLA3*), has been associated with hepatic steatosis in a multiethnic cohort of adults<sup>[36]</sup> as well as in children<sup>[37,38]</sup>. *PNPLA3* encodes for a triglyceride hydrolase expressed in the liver and adipose tissue<sup>[39]</sup>. Metabolic studies in transgenic mice revealed that high level expression of *PNPLA3*<sup>I148M</sup> in the liver, but not in adipose tissue, affected both hepatic triacylglycerol (TAG) synthesis and catabolism. A surprising finding was that the *PNPLA3*<sup>I148M</sup> transgenic mice have significantly increased fatty acid synthesis and an altered spectrum of TAG-fatty acids in the liver, with no evidence of insulin resistance<sup>[40]</sup>. It is interesting that *PNPLA3*<sup>I148M</sup> transgenic mice develop steatosis on a sucrose diet but not on a high-fat diet. Ingestion of sucrose stimulates de novo synthesis of fatty acids<sup>[41]</sup>, whereas most of the hepatic fatty acids in livers of fat-fed mice are derived from circulating non esterified fatty acids (NEFAs). Perhaps *PNPLA3* in hepatocytes is exposed preferentially to newly synthesized TAG and is shielded from fatty acids that enter the liver in lipoproteins or are synthesized from circulating NEFAs<sup>[40]</sup>. Alternatively, *PNPLA3* may function specifically under conditions of insulin-stimulated lipid anabolism. The finding that *PNPLA3* is virtually absent from livers of fasting animals and is strongly upregulated both transcriptionally<sup>[42-45]</sup> and post-translationally<sup>[39]</sup> by carbohydrate refeeding is consistent with the latter hypothesis.

Moreover, purified recombinant *PNPLA3* has been found to have 5 enzymatic activities: triacylglycerol, diacylglycerol, and monoacylglycerol hydrolysis<sup>[42,46]</sup> as well as acyl-CoA thioesterase<sup>[42]</sup> and lysophosphatidic acid acyltransferase activity<sup>[47]</sup>. These different activities are not equally affected by the I148M substitution. In vitro assays, the I148M substitution results in a substantial loss of triacylglycerol, monoacylglycerols, and diacylglycerols hydrolytic activity<sup>[33]</sup>; a modest reduction in acyl-CoA thioesterase activity<sup>[33]</sup>; and an increase in lysophosphatidic acid acyltransferase activity<sup>[47]</sup>. None of these activities alone can explain all of the changes in TAG metabolism observed in the *PNPLA3* I148M transgenic mice. Therefore, some of the metabolic changes observed in these

animals are likely to be secondary rather than direct consequences of altered *PNPLA3* activity.

The effect of this polymorphism on liver damage seems to be driven by the size of abdominal fat, expressed as waist to height ratio (W/Hr)<sup>[38]</sup>. More recently it has been demonstrated that weight loss reduce the effect of this polymorphism in obese children<sup>[48]</sup>.

Other findings suggest also that the influence of *PNPLA3* on hepatic fat in obese children and adolescents might be modulated by dietary factors such as n-6/n-3 polyunsaturated fatty acids (PUFA) intake<sup>[49]</sup>. Finally, the rs738409 *PNPLA3* polymorphism is considered, regardless of metabolic profile, a risk factor for liver disease. In fact, in a recent study, in a hepatitis C-infected population, the *PNPLA3* polymorphism influenced the development of liver steatosis<sup>[50]</sup>. Moreover, it was also demonstrated as a novel genetic marker associated with progressive ALD (alcoholic liver disease)<sup>[51]</sup>.

Another polymorphism that acts along with the *PNPLA3* gene variant to convey susceptibility to fatty liver in obese youths is the rs1260326 polymorphism in the glucokinase regulatory protein (*GCKR*). This polymorphism is associated with hepatic fat accumulation along with large VLDL and triglyceride levels<sup>[52]</sup>.

Speliotes *et al*<sup>[53]</sup>, in addition to *GCKR*, identified variants in novel loci *NCAN* and *LYPLAL1* associated with both increasing computer tomography (CT) hepatic steatosis and histological NAFLD and identified variants in another locus, protein phosphatase 1 regulatory subunit 3B (*PPP1R3B*), associated with CT steatosis but not histologic NAFLD<sup>[53]</sup>. Recently Kitamoto *et al*<sup>[54]</sup> found that *PNPLA3*, *SAMM50* sorting and assembly machinery component (*SAMM50*), parvin beta (*PARVB*) genetic regions was significantly associated with NAFLD in the Japanese population. Adams *et al*<sup>[55]</sup> showed that SNPs in two genes expressed in liver were associated with NAFLD in adolescents: group-specific component (*GC*) and lymphocyte cytosolic protein-1 (*LCP1*). SNPs in two genes expressed in neurons were also associated with NAFLD: lipid phosphate phosphatase-related protein type 4 (*LPPR4*) and solute carrier family 38 member 8 (*SLC38A8*)<sup>[55]</sup>.

## TREATMENTS

### Diet and lifestyle changes

The goal of lifestyle interventions is a gradual and controlled weight loss achieved by diet and physical exercise (Table 1). This aim is difficult to achieve and only a small percentage of individuals is able to steadily lose weight and exercise regularly<sup>[56]</sup>. Weight loss in NAFLD patients improves hepatic insulin sensitivity by reducing hepatic NEFAs supply, improves extra-hepatic insulin sensitivity through better glucose utilization and reduces ROS generation and adipose tissue inflammation<sup>[56]</sup>.

Currently, there are no evidence-based guidelines establishing the optimal intervention. The only effective interventions are physical activity and dietary changes. In fact, reduction in sugar/sucrose and in soft drinks



rich in fructose, most probably not only acts through a reduction in IR and lipogenesis, but also counteracts the recently evidenced hepatic pro-inflammatory/fibrogenetic role of fructose<sup>[57]</sup>. It should be taken in mind that diet in childhood must be balanced to allow a healthy and harmonic growth, including wellness of bone structures. To intervene on dietary changes does not only mean to reduce the caloric intake, but also the single components of the diet (Table 1). In fact, also diet composition plays an important role in the development of NAFLD, as an increased dietary intake of monounsaturated and polyunsaturated fatty acids (mainly omega 3 PUFA) has been associated with a reduction of hepatic fat content, representing a reasonable intervention especially in the pediatric population<sup>[58]</sup>.

### Pharmacological interventions for NAFLD

The pharmacological approach, in NAFLD children poorly adherent to or being unresponsive/partially responsive to lifestyle changes, is aimed at acting upon specific targets involved in etiopathogenesis (Table 1).

Antioxidants, by reducing oxidative stress, protect susceptible components of biological membranes from lipid peroxidation, and may, therefore, prevent the progression of simple steatosis to NASH. The most studied antioxidant in children with NAFLD is alpha tocopherol (vitamin E) and warrants consideration in obesity-related liver dysfunction for children unable to adhere to low-calorie diets<sup>[59]</sup>. Sanyal *et al.*<sup>[60]</sup> showed that vitamin E therapy, as compared with placebo, was associated with a significantly higher rate of improvement in NASH (43% *vs* 19%, *P* = 0.001) in adults without diabetes. There was no benefit of pioglitazone over placebo for improvement of NASH but serum alanine and aspartate aminotransferase levels were reduced as well as with vitamin E.

For its pathogenic role, insulin resistance appears as an adequate therapeutic target. Metformin is the only insulin-sensitizing agent evaluated in children.

Lavine *et al.*<sup>[61]</sup> in a more recent large, multicenter, randomised double-blind placebo-controlled trial (TONIC study), evaluated the effect of daily dosing of 800 IU of vitamin E (58 patients), 1000 mg of metformin (57 patients) or placebo (58 patients) for 96 wk of NAFLD course. The patients (aged 8-17 years) with biopsy-confirmed NAFLD and persistently elevated levels of ALT, without diabetes or cirrhosis, were randomly assigned to 1 of 3 groups. At 96 wk neither vitamin E nor metformin was superior to placebo in attaining the primary outcome of sustained reduction in ALT level in pediatric NAFLD; vitamin E and metformin groups, however, showed an improvement in histological hepatocellular ballooning in NAFLD and NASH.

Another, single-arm, open-label, small pilot study on metformin (500 mg twice daily for 24 wk), conducted in 10 non-diabetic children with biopsy proven NASH and elevated ALT levels showed reduction of hepatic steatosis, as evaluated with Magnetic Resonance Spectroscopy (MRS) and low serum ALT levels<sup>[62]</sup>.

## FUTURE DIRECTIONS

A growing body of evidence<sup>[63]</sup> shows that the gut microbiota controls obesity and visceral fat storage. Specific variations in gut microbiota in early life may determine a major risk factor of obesity and its complications later in life<sup>[64]</sup>. Small intestinal bacterial overgrowth (SIBO) (a frequent condition in obese individuals, mainly prompted by slowing of the oro-coecal transit time) may promote NAFLD progression to non-alcoholic steatohepatitis by enhancing intestinal permeability and by favouring absorption of endotoxins with pro-inflammatory and pro-fibrogenetic effects on the liver<sup>[65]</sup>.

Probiotics are live microorganisms which when consumed in adequate amounts, confer a healthy benefit to the host<sup>[66]</sup>. Gut microbiota manipulation with probiotics in rodents with fatty liver reduces intestinal inflammation and improves the epithelial barrier function<sup>[67,68]</sup>. Therefore, probiotics could represent a new effective treatment also in NAFLD human patients (Table 1). Loguericio and colleagues have shown that probiotics may reduce NAFLD liver injury and may improve liver function tests<sup>[69]</sup>.

Moreover, recent pharmacological studies in NAFLD animal models and in adult humans focusing on the effect of oral treatment with n-3 fatty acids, demonstrate that they have both anti-inflammatory and insulin sensitizing properties, suggesting a potential role in treatment of NAFLD<sup>[70]</sup>. In NAFLD children n-3-docosahexaenoic acid (DHA) treatment for 6 months improved ultrasonographic fatty liver and insulin sensitivity<sup>[71]</sup>. Because this treatment is well tolerated in pediatric population, DHA deserve further studies in the management of children with NAFLD.

A series of other interesting approaches, hitherto explored only in NAFLD animal models or in few pilot studies in adults will possibly become in future the object of study in pediatric population (Table 1), as well: (1) tumor necrosis factor- $\alpha$  (TNF- $\alpha$ ) and other adipocytokines produced by adipose tissue are involved in NAFLD progression. Pentoxifylline, a phosphodiesterase inhibitor, exerts immunomodulatory functions by antagonizing the TNF- $\alpha$  pathway. In adults with NASH, pentoxifylline treatment showed good tolerability and could decrease serum ALT levels and improve histological features<sup>[72]</sup>; (2) the nuclear bile acid receptor, Farnesoid X receptor (FXR), strongly expressed in bowel and liver, is probably involved in NAFLD pathogenesis, by mediating control of lipids and glucose homeostasis, and controlling bacterial flora growth. Altogether, these effects may induce reduction of hepatic inflammation and fibrogenesis, through different mechanisms. Therefore, recently developed FXR agonists have a potential role in the pharmacological therapy of NAFLD/NASH<sup>[73]</sup>; (3) toll-like receptors (TLRs) are receptors sensing microbial components of gut microbiota. A number of recent evidences suggests the role of SIBO and increased intestinal permeability in NAFLD, by exposing *via* portal vein the liver to an high load of intestinal noxae including lipo-



polysaccharide and other pathogen-associated molecular patterns<sup>[74]</sup>. Furthermore, TLRs stimulation causes downstream activation of the inflammatory response. Pro-inflammatory patterns result in production of cytokines and chemokines implicated in progression from simple steatosis to steatohepatitis and fibro-cirrhosis; so therapeutic manipulation of innate immune system through TLRs modifiers, formerly evaluated for autoimmune diseases<sup>[75]</sup>, might be a new potential therapeutic target for pediatric NAFLD, but further studies are necessary; and (4) glucagon-like peptid-1 (GLP-1) is an incretin secreted in response to food intake, allotted to multiple functions, including, the stimulation of glucose-dependent insulin secretion and inhibition of glucagon release. The enzyme dipeptidyl peptidase-4 (DPP-4) rapidly degrades circulating GLP-1 (half-life: 1-2 min). Recent animal model and NAFLD adults studies showed an effective role of GLP-1 receptor agonists resistant to DPP-4 (such as exenatide and liraglutide) or DPP-4 inhibitors (*e.g.*, some gliptins) as a promising new therapy in NAFLD for their ability in modulating fatty acid oxidation, decreasing lipogenesis, and improving hepatic glucose metabolism<sup>[76]</sup>.

## CONCLUSION

Non-alcoholic fatty liver disease, because of the rise in the prevalence of childhood obesity, is becoming one of the most important chronic liver disease among children. Evidence that only a sub-group of obese patients develop NAFLD suggests that disease progression is likely to depend on complex interplay between environmental factors and genetic predisposition (Figure 1). Recent researches led us to understand the genetic basis predisposing to NAFLD. Many genes have been identified and many other will be identified and, actually, the most important it appears to be *PNPLA3* gene. Probably, all the genetic polymorphisms implicated in NAFLD development could have a summarizing effect. In fact, if more predisposing NAFLD polymorphisms coexist in the same subject, the risk to develop NAFLD and to develop it more severely could increase. Other important findings are related to the diet. For example, strong evidence exists that high in fructose intake, usually present in beverages, results in increased de novo lipogenesis and then in increased risk of NAFLD. Moreover, also high n-6/n-3 PUFA ratio consumed in the diet could predispose the NAFLD development. All these findings must drive the clinical practice: the diet is the first and important approach for the NAFLD prevention and treatment. In fact, there is the striking evidence that the weight loss can reduce the effect of I148M polymorphisms on determining hepatic steatosis. In addition to weight loss, to reduce the fructose intake through the beverages and increasing the n-3 fatty acids dietary intake could be also useful in contrasting the NAFLD.

In conclusion, waiting the new approaches, the dear and old diet is always a fundamental and irreplaceable NAFLD therapy.

## REFERENCES

- 1 **Schwimmer JB**, Deutsch R, Kahen T, Lavine JE, Stanley C, Behling C. Prevalence of fatty liver in children and adolescents. *Pediatrics* 2006; **118**: 1388-1393 [PMID: 17015527]
- 2 **Aly FZ**, Kleiner DE. Update on fatty liver disease and steatohepatitis. *Adv Anat Pathol* 2011; **18**: 294-300 [PMID: 21654360 DOI: 10.1097/PAP.0b013e318220f59b]
- 3 **Brunt EM**. Pathology of nonalcoholic fatty liver disease. *Nat Rev Gastroenterol Hepatol* 2010; **7**: 195-203 [PMID: 20195271 DOI: 10.1038/nrgastro.2010.21]
- 4 **Day CP**. Non-alcoholic fatty liver disease: a massive problem. *Clin Med* 2011; **11**: 176-178 [PMID: 21526706]
- 5 **Nobili V**, Reale A, Alisi A, Morino G, Trenta I, Pisani M, Marcellini M, Raucchi U. Elevated serum ALT in children presenting to the emergency unit: Relationship with NAFLD. *Dig Liver Dis* 2009; **41**: 749-752 [PMID: 19362523 DOI: 10.1016/j.dld.2009.02.048]
- 6 **Rodríguez G**, Gallego S, Breidenassel C, Moreno LA, Gottrand F. Is liver transaminases assessment an appropriate tool for the screening of non-alcoholic fatty liver disease in at risk obese children and adolescents? *Nutr Hosp* 2010; **25**: 712-717 [PMID: 21336425]
- 7 **Tominaga K**, Kurata JH, Chen YK, Fujimoto E, Miyagawa S, Abe I, Kusano Y. Prevalence of fatty liver in Japanese children and relationship to obesity. An epidemiological ultrasonographic survey. *Dig Dis Sci* 1995; **40**: 2002-2009 [PMID: 7555456]
- 8 **Pacifico L**, Poggiogalle E, Cantisani V, Menichini G, Ricci P, Ferraro F, Chiesa C. Pediatric nonalcoholic fatty liver disease: A clinical and laboratory challenge. *World J Hepatol* 2010; **2**: 275-288 [PMID: 21161009 DOI: 10.4254/wjh.v2.i7.275]
- 9 **Nadeau KJ**, Klingensmith G, Zeitler P. Type 2 diabetes in children is frequently associated with elevated alanine aminotransferase. *J Pediatr Gastroenterol Nutr* 2005; **41**: 94-98 [PMID: 15990637]
- 10 **Manco M**, Marcellini M, Devito R, Comparcola D, Sartorelli MR, Nobili V. Metabolic syndrome and liver histology in paediatric non-alcoholic steatohepatitis. *Int J Obes (Lond)* 2008; **32**: 381-387 [PMID: 18087267]
- 11 **Sundaram SS**, Zeitler P, Nadeau K. The metabolic syndrome and nonalcoholic fatty liver disease in children. *Curr Opin Pediatr* 2009; **21**: 529-535 [PMID: 19444112 DOI: 10.1097/MOP.0b013e32832cb16f]
- 12 **Giorgio V**, Prono F, Graziano F, Nobili V. Pediatric non alcoholic fatty liver disease: old and new concepts on development, progression, metabolic insight and potential treatment targets. *BMC Pediatr* 2013; **13**: 40 [PMID: 23530957 DOI: 10.1186/1471-2431-13-40]
- 13 **Barshop NJ**, Sirlin CB, Schwimmer JB, Lavine JE. Review article: epidemiology, pathogenesis and potential treatments of paediatric non-alcoholic fatty liver disease. *Aliment Pharmacol Ther* 2008; **28**: 13-24 [PMID: 18397387 DOI: 10.1111/j.1365-2036.2008.03703.x]
- 14 **Spiteller G**. Linoleic acid peroxidation--the dominant lipid peroxidation process in low density lipoprotein--and its relationship to chronic diseases. *Chem Phys Lipids* 1998; **95**: 105-162 [PMID: 9853364]
- 15 **Browning JD**, Szczepaniak LS, Dobbins R, Nuremberg P, Horton JD, Cohen JC, Grundy SM, Hobbs HH. Prevalence of hepatic steatosis in an urban population in the United States: impact of ethnicity. *Hepatology* 2004; **40**: 1387-1395 [PMID: 15565570]
- 16 **Poustchi H**, George J, Esmaili S, Esna-Ashari F, Ardalan G, Sepanlou SG, Alavian SM. Gender differences in healthy ranges for serum alanine aminotransferase levels in adolescence. *PLoS One* 2011; **6**: e21178 [PMID: 21738618 DOI: 10.1371/journal.pone.0021178]
- 17 **Loomba R**, Sirlin CB, Schwimmer JB, Lavine JE. Advances in pediatric nonalcoholic fatty liver disease. *Hepatology* 2009; **50**:

- 1282-1293 [PMID: 19637286 DOI: 10.1002/hep.23119]
- 18 **Lobanova YS**, Scherbakov AM, Shatskaya VA, Evteev VA, Krasil'nikov MA. NF-kappaB suppression provokes the sensitization of hormone-resistant breast cancer cells to estrogen apoptosis. *Mol Cell Biochem* 2009; **324**: 65-71 [PMID: 19096761 DOI: 10.1007/s11010-008-9985-0]
  - 19 **Xu JW**, Gong J, Chang XM, Luo JY, Dong L, Jia A, Xu GP. Effects of estradiol on liver estrogen receptor-alpha and its mRNA expression in hepatic fibrosis in rats. *World J Gastroenterol* 2004; **10**: 250-254 [PMID: 14716833]
  - 20 **Nuutila P**, Knuuti MJ, Mäki M, Laine H, Ruotsalainen U, Teräs M, Haaparanta M, Solin O, Yki-Järvinen H. Gender and insulin sensitivity in the heart and in skeletal muscles. Studies using positron emission tomography. *Diabetes* 1995; **44**: 31-36 [PMID: 7813811]
  - 21 **Donahue RP**, Bean JA, Donahue RA, Goldberg RB, Prineas RJ. Insulin response in a triethnic population: effects of sex, ethnic origin, and body fat. Miami Community Health Study. *Diabetes Care* 1997; **20**: 1670-1676 [PMID: 9353606]
  - 22 **Lovejoy JC**, Champagne CM, de Jonge L, Xie H, Smith SR. Increased visceral fat and decreased energy expenditure during the menopausal transition. *Int J Obes (Lond)* 2008; **32**: 949-958 [PMID: 18332882 DOI: 10.1038/ijo.2008.25]
  - 23 **Camporez JP**, Jornayvaz FR, Lee HY, Kanda S, Guigni BA, Kahn M, Samuel VT, Carvalho CR, Petersen KF, Jurczak MJ, Shulman GI. Cellular mechanism by which estradiol protects female ovariectomized mice from high-fat diet-induced hepatic and muscle insulin resistance. *Endocrinology* 2013; **154**: 1021-1028 [PMID: 23364948 DOI: 10.1210/en.2012-1989]
  - 24 **Graham RC**, Burke A, Stettler N. Ethnic and sex differences in the association between metabolic syndrome and suspected nonalcoholic fatty liver disease in a nationally representative sample of US adolescents. *J Pediatr Gastroenterol Nutr* 2009; **49**: 442-449 [PMID: 19644391 DOI: 10.1097/MPG.0b013e31819f73b4]
  - 25 **Donnelly KL**, Smith CI, Schwarzenberg SJ, Jessurun J, Boldt MD, Parks EJ. Sources of fatty acids stored in liver and secreted via lipoproteins in patients with nonalcoholic fatty liver disease. *J Clin Invest* 2005; **115**: 1343-1351 [PMID: 15864352]
  - 26 **Cortez-Pinto H**, Jesus L, Barros H, Lopes C, Moura MC, Camilo ME. How different is the dietary pattern in non-alcoholic steatohepatitis patients? *Clin Nutr* 2006; **25**: 816-823 [PMID: 16677739]
  - 27 **Toshimitsu K**, Matsuura B, Ohkubo I, Niiya T, Furukawa S, Hiasa Y, Kawamura M, Ebihara K, Onji M. Dietary habits and nutrient intake in non-alcoholic steatohepatitis. *Nutrition* 2007; **23**: 46-52 [PMID: 17140767]
  - 28 **Mozaffarian D**, Wu JH. Omega-3 fatty acids and cardiovascular disease: effects on risk factors, molecular pathways, and clinical events. *J Am Coll Cardiol* 2011; **58**: 2047-2067 [PMID: 22051327 DOI: 10.1016/j.jacc.2011.06.063]
  - 29 **Li Y**, Chen D. The optimal dose of omega-3 supplementation for non-alcoholic fatty liver disease. *J Hepatol* 2012; **57**: 468-469; author reply 468-469; [PMID: 22433603 DOI: 10.1016/j.jhep.2012.01.028]
  - 30 **Araya J**, Rodrigo R, Videla LA, Thielemann L, Orellana M, Pettinelli P, Poniachik J. Increase in long-chain polyunsaturated fatty acid n - 6/n - 3 ratio in relation to hepatic steatosis in patients with non-alcoholic fatty liver disease. *Clin Sci (Lond)* 2004; **106**: 635-643 [PMID: 14720121]
  - 31 **Puri P**, Baillie RA, Wiest MM, Mirshahi F, Choudhury J, Cheung O, Sargeant C, Contos MJ, Sanyal AJ. A lipidomic analysis of nonalcoholic fatty liver disease. *Hepatology* 2007; **46**: 1081-1090 [PMID: 17654743]
  - 32 **Vos MB**, Kimmons JE, Gillespie C, Welsh J, Blanck HM. Dietary fructose consumption among US children and adults: the Third National Health and Nutrition Examination Survey. *Medscape J Med* 2008; **10**: 160 [PMID: 18769702]
  - 33 **Stanhope KL**, Schwarz JM, Keim NL, Griffen SC, Bremer AA, Graham JL, Hatcher B, Cox CL, Dyachenko A, Zhang W, McGahan JP, Seibert A, Krauss RM, Chiu S, Schaefer EJ, Ai M, Otokoza S, Nakajima K, Nakano T, Beyesen C, Hellerstein MK, Berglund L, Havel PJ. Consuming fructose-sweetened, not glucose-sweetened, beverages increases visceral adiposity and lipids and decreases insulin sensitivity in overweight/obese humans. *J Clin Invest* 2009; **119**: 1322-1334 [PMID: 19381015 DOI: 10.1172/JCI37385]
  - 34 **Feldstein AE**, Charatcharoenwitthaya P, Treeprasertsuk S, Benson JT, Enders FB, Angulo P. The natural history of non-alcoholic fatty liver disease in children: a follow-up study for up to 20 years. *Gut* 2009; **58**: 1538-1544 [PMID: 19625277 DOI: 10.1136/gut.2008.171280]
  - 35 **Santoro N**, Feldstein AE, Enoksson E, Pierpont B, Kursawe R, Kim G, Caprio S. The association between hepatic fat content and liver injury in obese children and adolescents: effects of ethnicity, insulin resistance, and common gene variants. *Diabetes Care* 2013; **36**: 1353-1360 [PMID: 23275357 DOI: 10.2337/dc12-1791]
  - 36 **Romeo S**, Kozlitina J, Xing C, Pertsemlidis A, Cox D, Pennacchio LA, Boerwinkle E, Cohen JC, Hobbs HH. Genetic variation in PNPLA3 confers susceptibility to nonalcoholic fatty liver disease. *Nat Genet* 2008; **40**: 1461-1465 [PMID: 18820647 DOI: 10.1038/ng.257]
  - 37 **Santoro N**, Kursawe R, D'Adamo E, Dykas DJ, Zhang CK, Bale AE, Calí AM, Narayan D, Shaw MM, Pierpont B, Savoye M, Lartaud D, Eldrich S, Cushman SW, Zhao H, Shulman GI, Caprio S. A common variant in the patatin-like phospholipase 3 gene (PNPLA3) is associated with fatty liver disease in obese children and adolescents. *Hepatology* 2010; **52**: 1281-1290 [PMID: 20803499 DOI: 10.1002/hep.23832]
  - 38 **Giudice EM**, Grandone A, Cirillo G, Santoro N, Amato A, Brienza C, Savarese P, Marzuillo P, Perrone L. The association of PNPLA3 variants with liver enzymes in childhood obesity is driven by the interaction with abdominal fat. *PLoS One* 2011; **6**: e27933 [PMID: 22140488 DOI: 10.1371/journal.pone.0027933]
  - 39 **Huang Y**, He S, Li JZ, Seo YK, Osborne TF, Cohen JC, Hobbs HH. A feed-forward loop amplifies nutritional regulation of PNPLA3. *Proc Natl Acad Sci USA* 2010; **107**: 7892-7897 [PMID: 20385813 DOI: 10.1073/pnas.1003585107]
  - 40 **Li JZ**, Huang Y, Karaman R, Ivanova PT, Brown HA, Roddy T, Castro-Perez J, Cohen JC, Hobbs HH. Chronic overexpression of PNPLA3I148M in mouse liver causes hepatic steatosis. *J Clin Invest* 2012; **122**: 4130-4144 [PMID: 23023705]
  - 41 **Cohen AM**, Teitelbaum A. Effect of glucose, fructose, sucrose and starch on lipogenesis in rats. *Life Sci* 1968; **7**: 23-29 [PMID: 5638917]
  - 42 **Huang Y**, Cohen JC, Hobbs HH. Expression and characterization of a PNPLA3 protein isoform (I148M) associated with nonalcoholic fatty liver disease. *J Biol Chem* 2011; **286**: 37085-37093 [PMID: 21878620 DOI: 10.1074/jbc.M111.290114]
  - 43 **Lake AC**, Sun Y, Li JL, Kim JE, Johnson JW, Li D, Revett T, Shih HH, Liu W, Paulsen JE, Gimeno RE. Expression, regulation, and triglyceride hydrolase activity of Adiponutrin family members. *J Lipid Res* 2005; **46**: 2477-2487 [PMID: 16150821]
  - 44 **Polson DA**, Thompson MP. Adiponutrin mRNA expression in white adipose tissue is rapidly induced by meal-feeding a high-sucrose diet. *Biochem Biophys Res Commun* 2003; **301**: 261-266 [PMID: 12565853]
  - 45 **Kershaw EE**, Hamm JK, Verhagen LA, Peroni O, Katic M, Flier JS. Adipose triglyceride lipase: function, regulation by insulin, and comparison with adiponutrin. *Diabetes* 2006; **55**: 148-157 [PMID: 16380488]
  - 46 **Jenkins CM**, Mancuso DJ, Yan W, Sims HF, Gibson B, Gross RW. Identification, cloning, expression, and purification of three novel human calcium-independent phospholipase A2 family members possessing triacylglycerol lipase and acylglycerol transacylase activities. *J Biol Chem* 2004; **279**: 48968-48975 [PMID: 15364929]

- 47 **Kumari M**, Schoiswohl G, Chitruju C, Paar M, Cornaciu I, Rangrez AY, Wongsiriroj N, Nagy HM, Ivanova PT, Scott SA, Knittelfelder O, Rechberger GN, Birner-Gruenberger R, Eder S, Brown HA, Haemmerle G, Oberer M, Lass A, Kershaw EE, Zimmermann R, Zechner R. Adiponutrin functions as a nutritionally regulated lysophosphatidic acid acyltransferase. *Cell Metab* 2012; **15**: 691-702 [PMID: 22560221 DOI: 10.1016/j.cmet.2012.04.008]
- 48 **Marzuillo P**, Grandone A, Perrone L, del Giudice EM. Weight loss allows the dissection of the interaction between abdominal fat and PNPLA3 (adiponutrin) in the liver damage of obese children. *J Hepatol* 2013; **59**: 1143-1144 [PMID: 23845393]
- 49 **Santoro N**, Savoye M, Kim G, Marotto K, Shaw MM, Pierpont B, Caprio S. Hepatic fat accumulation is modulated by the interaction between the rs738409 variant in the PNPLA3 gene and the dietary omega6/omega3 PUFA intake. *PLoS One* 2012; **7**: e37827 [PMID: 22629460 DOI: 10.1371/journal.pone.0037827]
- 50 **Zampino R**, Coppola N, Cirillo G, Boemio A, Pisaturo M, Marrone A, Macera M, Sagnelli E, Perrone L, Adinolfi LE, Miraglia del Giudice E. Abdominal fat interacts with PNPLA3 I148M, but not with the APOC3 variant in the pathogenesis of liver steatosis in chronic hepatitis C. *J Viral Hepat* 2013; **20**: 517-523 [PMID: 23808989 DOI: 10.1111/jvh.12053]
- 51 **Dubuquoy C**, Burnol AF, Moldes M, PNPLA3, a genetic marker of progressive liver disease, still hiding its metabolic function? *Clin Res Hepatol Gastroenterol* 2013; **37**: 30-35 [PMID: 22884299 DOI: 10.1016/j.clinre.2012.06.014]
- 52 **Santoro N**, Zhang CK, Zhao H, Pakstis AJ, Kim G, Kursawe R, Dykas DJ, Bale AE, Giannini C, Pierpont B, Shaw MM, Groop L, Caprio S. Variant in the glucokinase regulatory protein (GCKR) gene is associated with fatty liver in obese children and adolescents. *Hepatology* 2012; **55**: 781-789 [PMID: 22105854 DOI: 10.1002/hep.24806]
- 53 **Speliotes EK**, Yerges-Armstrong LM, Wu J, Hernaez R, Kim LJ, Palmer CD, Gudnason V, Eiriksdottir G, Garcia ME, Launer LJ, Nalls MA, Clark JM, Mitchell BD, Shuldiner AR, Butler JL, Tomas M, Hoffmann U, Hwang SJ, Massaro JM, O'Donnell CJ, Sahani DV, Salomaa V, Schadt EE, Schwartz SM, Siscovick DS, Voight BF, Carr JJ, Feitosa MF, Harris TB, Fox CS, Smith AV, Kao WH, Hirschhorn JN, Borecki IB. Genome-wide association analysis identifies variants associated with nonalcoholic fatty liver disease that have distinct effects on metabolic traits. *PLoS Genet* 2011; **7**: e1001324 [PMID: 21423719]
- 54 **Kitamoto T**, Kitamoto A, Yoneda M, Hyogo H, Ochi H, Nakamura T, Teranishi H, Mizusawa S, Ueno T, Chayama K, Nakajima A, Nakao K, Sekine A, Hotta K. Genome-wide scan revealed that polymorphisms in the PNPLA3, SAMM50, and PARVB genes are associated with development and progression of nonalcoholic fatty liver disease in Japan. *Hum Genet* 2013; **132**: 783-792 [PMID: 23535911 DOI: 10.1007/s00439-013-1294-3]
- 55 **Adams LA**, White SW, Marsh JA, Lye SJ, Connor KL, Manganga R, Ayonrinde OT, Olynyk JK, Mori TA, Beilin LJ, Palmer LJ, Hamdorf JM, Pennell CE. Association between liver-specific gene polymorphisms and their expression levels with nonalcoholic fatty liver disease. *Hepatology* 2013; **57**: 590-600 [PMID: 23213074 DOI: 10.1002/hep.26184]
- 56 **Nobili V**, Alisi A, Raponi M. Pediatric non-alcoholic fatty liver disease: preventive and therapeutic value of lifestyle intervention. *World J Gastroenterol* 2009; **15**: 6017-6022 [PMID: 20027672]
- 57 **Vos MB**, Lavine JE. Dietary fructose in nonalcoholic fatty liver disease. *Hepatology* 2013; **57**: 2525-2531 [PMID: 23390127 DOI: 10.1002/hep.26299]
- 58 **Zelber-Sagi S**, Ratzin V, Oren R. Nutrition and physical activity in NAFLD: an overview of the epidemiological evidence. *World J Gastroenterol* 2011; **17**: 3377-3389 [PMID: 21876630 DOI: 10.3748/wjg.v17.i29.3377]
- 59 **Vajro P**, Mandato C, Franzese A, Ciccimarra E, Lucariello S, Savoia M, Capuano G, Migliaro F. Vitamin E treatment in pediatric obesity-related liver disease: a randomized study. *J Pediatr Gastroenterol Nutr* 2004; **38**: 48-55 [PMID: 14676594]
- 60 **Sanyal AJ**, Chalasani N, Kowdley KV, McCullough A, Diehl AM, Bass NM, Neuschwander-Tetri BA, Lavine JE, Tonascia J, Unalp A, Van Natta M, Clark J, Brunt EM, Kleiner DE, Hoofnagle JH, Robuck PR. Pioglitazone, vitamin E, or placebo for nonalcoholic steatohepatitis. *N Engl J Med* 2010; **362**: 1675-1685 [PMID: 20427778 DOI: 10.1056/NEJMoa0907929]
- 61 **Lavine JE**, Schwimmer JB, Van Natta ML, Molleston JP, Murray KF, Rosenthal P, Abrams SH, Scheimann AO, Sanyal AJ, Chalasani N, Tonascia J, Unalp A, Clark JM, Brunt EM, Kleiner DE, Hoofnagle JH, Robuck PR. Effect of vitamin E or metformin for treatment of nonalcoholic fatty liver disease in children and adolescents: the TONIC randomized controlled trial. *JAMA* 2011; **305**: 1659-1668 [PMID: 21521847 DOI: 10.1001/jama.2011.520]
- 62 **Schwimmer JB**, Middleton MS, Deutsch R, Lavine JE. A phase 2 clinical trial of metformin as a treatment for non-diabetic paediatric non-alcoholic steatohepatitis. *Aliment Pharmacol Ther* 2005; **21**: 871-879 [PMID: 15801922]
- 63 **Musso G**, Gambino R, Cassader M. Gut microbiota as a regulator of energy homeostasis and ectopic fat deposition: mechanisms and implications for metabolic disorders. *Curr Opin Lipidol* 2010; **21**: 76-83 [PMID: 19915460 DOI: 10.1097/MOL.0b013e3283347ebb]
- 64 **Kootte RS**, Vrieze A, Holleman F, Dallinga-Thie GM, Zoetendal EG, de Vos WM, Groen AK, Hoekstra JB, Stoes ES, Nieuwdorp M. The therapeutic potential of manipulating gut microbiota in obesity and type 2 diabetes mellitus. *Diabetes Obes Metab* 2012; **14**: 112-120 [PMID: 21812894 DOI: 10.1111/j.1463-1326.2011.01483.x]
- 65 **Wigg AJ**, Roberts-Thomson IC, Dymock RB, McCarthy PJ, Grose RH, Cummins AG. The role of small intestinal bacterial overgrowth, intestinal permeability, endotoxaemia, and tumour necrosis factor alpha in the pathogenesis of non-alcoholic steatohepatitis. *Gut* 2001; **48**: 206-211 [PMID: 11156641]
- 66 **Schrezenmeir J**, de Vrese M. Probiotics, prebiotics, and synbiotics—approaching a definition. *Am J Clin Nutr* 2001; **73**: 361S-364S [PMID: 11157342]
- 67 **Canli PD**, Bibiloni R, Knauf C, Waget A, Neyrinck AM, Delzenne NM, Burcelin R. Changes in gut microbiota control metabolic endotoxemia-induced inflammation in high-fat diet-induced obesity and diabetes in mice. *Diabetes* 2008; **57**: 1470-1481 [PMID: 18305141 DOI: 10.2337/db07-1403]
- 68 **Esposito E**, Iacono A, Bianco G, Autore G, Cuzzocrea S, Vajro P, Canani RB, Calignano A, Raso GM, Meli R. Probiotics reduce the inflammatory response induced by a high-fat diet in the liver of young rats. *J Nutr* 2009; **139**: 905-911 [PMID: 19321579 DOI: 10.3945/jn.108.101808]
- 69 **Loguercio C**, Federico A, Tuccillo C, Terracciano F, D'Auria MV, De Simone C, Del Vecchio Blanco C. Beneficial effects of a probiotic VSL#3 on parameters of liver dysfunction in chronic liver diseases. *J Clin Gastroenterol* 2005; **39**: 540-543 [PMID: 15942443]
- 70 **Masterton GS**, Plevris JN, Hayes PC. Review article: omega-3 fatty acids - a promising novel therapy for non-alcoholic fatty liver disease. *Aliment Pharmacol Ther* 2010; **31**: 679-692 [PMID: 20415840 DOI: 10.1111/j.1365-2036.2010.04230.x]
- 71 **Huang JS**, Barlow SE, Quiros-Tejiera RE, Scheimann A, Skelton J, Suskind D, Tsai P, Uko V, Warolin JP, Xanthakos SA. Childhood obesity for pediatric gastroenterologists. *J Pediatr Gastroenterol Nutr* 2013; **56**: 99-109 [PMID: 23282941]
- 72 **Li W**, Zheng L, Sheng C, Cheng X, Qing L, Qu S. Systematic review on the treatment of pentoxifylline in patients with non-alcoholic fatty liver disease. *Lipids Health Dis* 2011; **10**: 49 [PMID: 21477300 DOI: 10.1186/1476-511X-10-49]
- 73 **Fuchs M**. Non-alcoholic Fatty liver disease: the bile Acid-

- activated farnesoid x receptor as an emerging treatment target. *J Lipids* 2012; **2012**: 934396 [PMID: 22187656 DOI: 10.1155/2012/934396]
- 74 **Miura K**, Seki E, Ohnishi H, Brenner DA. Role of toll-like receptors and their downstream molecules in the development of nonalcoholic Fatty liver disease. *Gastroenterol Res Pract* 2010; **2010**: 362847 [PMID: 21274430 DOI: 10.1155/2010/362847]
- 75 **Kanzler H**, Barrat FJ, Hessel EM, Coffman RL. Therapeutic targeting of innate immunity with Toll-like receptor agonists and antagonists. *Nat Med* 2007; **13**: 552-559 [PMID: 17479101]
- 76 **Lee J**, Hong SW, Rhee EJ, Lee WY. GLP-1 Receptor Agonist and Non-Alcoholic Fatty Liver Disease. *Diabetes Metab J* 2012; **36**: 262-267 [PMID: 22950055 DOI: 10.4093/dmj.2012.36.4.262]

**P- Reviewers:** Borzio M, Celikbilek M, Gatselis NK, Izumi N  
**S- Editor:** Zhai HH **L- Editor:** A **E- Editor:** Wu HL





## To treat or not to treat the "immunotolerant phase" of hepatitis B infection: A tunnel of controversy

Mohamed A Mekky

Mohamed A Mekky, Department of Tropical Medicine and Gastroenterology, Assiut University Hospital, Assiut 71111, Egypt  
Author contributions: Mekky MA designed the work and wrote the paper.

Correspondence to: Mohamed A Mekky, MD, PhD, Department of Tropical Medicine and Gastroenterology, Assiut University Hospital, Assiut 71111, Egypt. doc\_mekky0000@yahoo.com  
Telephone: +2-88-4710955 Fax: +2-88-2343308

Received: September 15, 2013 Revised: December 8, 2013

Accepted: February 20, 2014

Published online: April 27, 2014

A thorough review of the updated published reports was carried out and a merge of the various management options, with a special point of view of the author, is stated.

Mekky MA. To treat or not to treat the "immunotolerant phase" of hepatitis B infection: A tunnel of controversy. *World J Hepatol* 2014; 6(4): 226-229 Available from: URL: <http://www.wjgnet.com/1948-5182/full/v6/i4/226.htm> DOI: <http://dx.doi.org/10.4254/wjh.v6.i4.226>

### Abstract

Hepatitis B virus (HBV) infection is a global public health problem, with an estimated 350 million people worldwide chronically infected and approximately 500000 who die annually from HBV-related liver diseases. Management of chronic HBV is challenging and waves of guidelines emerge every year. One of the hottest topics and a matter of debate is the management of patients in their early immunotolerant phase of infection. With the lack of evidence, dealing with this particular subset of patients creates a great conflict with opposing views. In this review, the author highlights the pros and cons of these views and proposes a reasonable solution to resolve this dilemma.

© 2014 Baishideng Publishing Group Co., Limited. All rights reserved.

**Key words:** Liver biopsy; Hepatitis B Virus; Immunotolerant phase; Polymerase chain reaction; Nucleotide analogue

**Core tip:** In this mini review, the author discusses the management dilemma of this peculiar subset of patients suffering from chronic hepatitis B in the immunotolerant phase. As already known, the immunotolerant phase of hepatitis B virus may last for a long period and hence there may be a potential for subtle liver damage.

### INTRODUCTION

Hepatitis B virus (HBV) infection is a global public health problem, with an estimated 350 million people chronically infected worldwide. Fifteen to forty percent of these individuals will develop serious sequelae during their lifetime, with greater evolution to cirrhosis or hepatocellular carcinoma (HCC). The estimated 5-year rate of progression from chronic hepatitis B (CHB) to cirrhosis was estimated to be 12%-20% and the 5-year cumulative risk of developing HCC was also estimated to be between 10%-17% in patients with cirrhosis. These figures vary from country to country according to the disease endemicity and prevalence<sup>[1-3]</sup>. The natural history of CHB is complex and described to run through different immunological phases that may overlap. In its early phases, HBV infection is characterized by minimal liver damage on liver biopsy, a high level of HBV replication and positivity for HBe-antigen (HBeAg). These patients are asymptomatic and have normal levels of serum alanine aminotransferase (ALT). This phase is described as the "immunotolerant phase"<sup>[3,4]</sup>.

Managing these patients creates a great conflict with two opposing views. One view is optimistic, conservative and relies upon the long-term course of benignity of the disease. They adopt the view of "leave the patient alone on close follow up". On the other hand, the other view is

pessimistic and relies upon the great risk of cancer development, even without cirrhosis. This latter view adopts the view of “to treat the patient and why wait”. Between these two views, there are no real evidence based guidelines.

In this review, an extensive online research for English reviews and articles that tackle this subject by using the key words “immunotolerant”, “HBV” and “management” was carried out. The author highlights the pros and cons of all views regarding the management strategies of this subject and makes a reasonable proposed solution for this dilemma.

## IMMUNOTOLERANT PHASE: CHARACTERISTICS AND IMMUNOLOGICAL INSIGHT

The natural history of HBV infection is perplexing and its net result is an interplay between the viral replication and the host immune response. After primary infection, an immunotolerant phase characterized by a very high rate of viral replication but without liver injury takes place. The mechanism of this tolerance is not yet fully understood<sup>[5]</sup>. These patients are infected early in life through vertical or early horizontal infection. Such infection most often occurs in areas with high rates of endemic infection, low rates of maternal screening, and lack of widely available neonatal prophylaxis with HBV vaccine and hepatitis B immunoglobulin<sup>[6,7]</sup>.

It is believed that before birth, HBeAg acts as a “tolerogen viral protein” in the fetus, and thus virus specific T-cells undergo deletion. This phase lasts from weeks to years, depending on the age at acquisition. After years/decades, this tolerance is somehow ruptured and the immune attack against infected hepatocytes to clear them begins, causing liver damage. During this “immune clearance phase”, ALT levels increase and HBV DNA levels begin to decrease. Immune attacks of infected hepatocytes result in HBeAg seroconversion and this seroconversion is usually associated with sustained remission of liver disease. Selection pressures for the virus come from either competition between viral variants, which are different in their replicative efficiency, and the host immune activity<sup>[8-10]</sup>.

It was found that the majority of young children who presented in the immunotolerant phase have either minimal chronic hepatitis or, more commonly, non-specific reactive hepatitis, in spite of persistently normal ALT activity<sup>[11-13]</sup>.

Wang *et al*<sup>[14]</sup> studied seven patients (age range between 7-25 years) by follow up for at least 17 years with serial sampling for ALT activity and viral load. They concluded that the interplay between viral replication and host immunity explains the pattern of HBV dynamics within the host during the early stages of infection. That is, without immune selection, competition between peers increases the viral load and decreases the nucleotide diversity; in contrast, host immunity accelerates viral evolu-

tion and decreases copy numbers but increases diversity. The fully infected liver can yield between  $10^9$  to  $10^{10}$  viruses per milliliter of serum, a level of production that would be expected to persist if infection were benign and the host were truly immunotolerant. Virus titers in adolescent and young adult carriers in the immunotolerant phase of infection tend to be lower, ranging from  $10^7$  to  $10^9$  copies per milliliter<sup>[15,16]</sup>. Some studies explain the declining of virus titers during the time in the immunotolerant phase by a low but persistent immune destruction of infected cells by the cytotoxic T-cell, leading to an adaptive immune response over time<sup>[14]</sup>.

## IMMUNOTOLERANT PHASE: MANAGEMENT OPTIONS AND DEBATES

Of particular concern is the fact that until now there is no drug therapy that is actually effective in achieving a sustained response against HBV in the immunotolerant phase<sup>[17]</sup>.

The currently approved treatment options for chronic HBV infection are interferon and nucleoside analogues (NA). Interferon acts primarily as an immunomodulatory agent, while NAs have essentially antiviral effects. According to current consensus and guideline statements, treatment candidates are patients with active liver disease characterized by persistently elevated ALT levels and detectable HBV DNA ( $10^5$  copy/mL) by most commercial assays, irrespective of their HBeAg/Ab status. These statements also concluded that HBeAg-negative inactive carriers do not need any treatment because of the absence of viral replication and liver injury. Also, patients in the immunotolerant phase should be followed up without treatment<sup>[18,19]</sup>.

However, and in the light of the Risk Evaluation of Viremia Elevation and Associated Liver Disease study, a baseline high HBV DNA level was associated with a significant risk of hepatocellular carcinoma<sup>[20]</sup>. These results led to the debate on whether a HBV infected person with normal liver enzymes, unremarkable liver histology, but with a detectable level of HBV DNA (high or low regardless the cutoff), should be treated with antiviral drugs or not<sup>[20,21]</sup>.

As a rule, most of the current guidelines recommend that patients with moderate/severe inflammation or bridging fibrosis/cirrhosis must be treated. Also, they recommend liver biopsy for the grey zone of patients who do not meet the typical criteria, have a detectable level of HBV DNA and/or fluctuating or persistently elevated ALT. The presence of significant inflammation or bridging fibrosis/cirrhosis is an indication for treatment<sup>[22,23]</sup>.

Hence, and in the light of the previous statements, we can assume that there are two options regarding the management of the immunotolerant phase; the “why wait” view and the “close follow up” view.

The “why wait” view adopts the option to treat all patients with a persistently high level of viral replication regardless of the phase of infection and relying only on the presence of detectable DNA levels. They rely on the

high risk of cancer/cirrhosis development, considering the infection as not totally benign<sup>[24]</sup>. Therefore, earlier treatment intervention may be beneficial in preventing disease progression. A recently published study aimed to break this tolerance in children by treating a group of HBV-infected children in the immunotolerant phase with lamivudine and interferon and comparing them to an untreated group. They reported a cure rate in more than one-fifth of the studied cohort, a figure that is still primitive and not high<sup>[25]</sup>.

On the opposing side, another strong option exists and adopts the view of “wait and observe”. This view relies on some evidence. The first is the evidence of the benign long term course of the immunotolerant phase<sup>[26]</sup>. The second is the pooled results of poor response to antiviral therapy in this unique phase, which hardly reaches 19%<sup>[27]</sup>. The third is the proved emerging resistance on long term therapy<sup>[28]</sup>. The last is a heavy cost burden of treatment.

Wong *et al*<sup>[29]</sup> studied the risk of liver fibrosis progression in HBeAg-positive patients at different phases by recruiting two hundred and forty-seven HBeAg-positive patients without advanced fibrosis at baseline. They found that liver fibrosis progression is uncommon in HBeAg-positive patients and hence their results enforce the follow-up strategy.

As is known, the degree of fibrosis or inflammation on liver biopsy cannot be predicted by the level of HBV-DNA and ALT is also considered an imperfect surrogate marker for liver disease<sup>[30]</sup>. Therefore, without evidence of normal liver histology, the definition of immunotolerant disease depends mainly on the persistence of a normal ALT level as a major determinant. Nevertheless and unfortunately, the definition of a “normal” ALT level has been redefined several times and was subjected to a strong debate. The study of Prati *et al*<sup>[31]</sup> modified the normal upper limit for ALT to be 30 IU/mL for men and 19 IU/mL for women. Re-introducing these relatively low figures will endorse many more patients under the umbrella of raised ALT levels.

The most appropriate way to make this miss clear cut is to perform a liver biopsy. However, there are still some unanswered questions; *e.g.*, what is the optimal timing of liver biopsy during the natural history of this phase, how many times and at what intervals should it be done, which drug is the best to start with, *etc.*

The use of therapeutic vaccines may also help to break the tolerance. In spite of its preliminary application, the published results of the study of Buchmann *et al*<sup>[32]</sup> carry a great hope for a wide future applicability. They evaluated the potential use of a novel vaccine formulation, comprising particulate hepatitis B surface and core antigen and the saponin-based adjuvant, for its ability to stimulate T and B cell responses in C57BL/6 mice. Their results were promising and future intense research in this subject is deemed to be mandatory.

## CONCLUSION

The immunotolerant phase of chronic HBV is a chal-

lenging problem, with an increasing awareness of its occurrence, especially in endemic areas. More intense studies are required for a better delineation of the pathogenesis and whether it is better to break the tolerance or to wait for the natural clearance. Until then, the most suitable solution is to perform liver biopsy to stand on solid ground in choosing the best option, to wait or to interfere.

## ACKNOWLEDGMENTS

We are thankful to Dr. Helal F Hetta, (PhD), Department of Internal Medicine, Division of Digestive Diseases, University of Cincinnati, 231 Albert B. Sabin Way, Cincinnati, OH, for his assistance with manuscript preparation and English language editing.

## REFERENCES

- 1 Lee WM. Hepatitis B virus infection. *N Engl J Med* 1997; **337**: 1733-1745 [PMID: 9392700]
- 2 Beasley RP. Hepatitis B virus. The major etiology of hepatocellular carcinoma. *Cancer* 1988; **61**: 1942-1956 [PMID: 2834034]
- 3 Shao J, Wei L, Wang H, Sun Y, Zhang LF, Li J, Dong JQ. Relationship between hepatitis B virus DNA levels and liver histology in patients with chronic hepatitis B. *World J Gastroenterol* 2007; **13**: 2104-2107 [PMID: 17465456]
- 4 Daniels G. A century of human blood groups. *Wien Klin Wochenschr* 2001; **113**: 781-786 [PMID: 11732113]
- 5 Ganem D, Prince AM. Hepatitis B virus infection--natural history and clinical consequences. *N Engl J Med* 2004; **350**: 1118-1129 [PMID: 15014185]
- 6 McMahon BJ. The natural history of chronic hepatitis B virus infection. *Hepatology* 2009; **49**: S45-S55 [PMID: 19399792 DOI: 10.1002/hep.22898]
- 7 Dienstag JL. Hepatitis B virus infection. *N Engl J Med* 2008; **359**: 1486-1500 [PMID: 18832247 DOI: 10.1056/NEJM-ra0801644]
- 8 Hsu HY, Chang MH, Hsieh KH, Lee CY, Lin HH, Hwang LH, Chen PJ, Chen DS. Cellular immune response to HBeAg in mother-to-infant transmission of hepatitis B virus. *Hepatology* 1992; **15**: 770-776 [PMID: 1568717]
- 9 Hadziyannis SJ, Vassilopoulos D. Hepatitis B e antigen-negative chronic hepatitis B. *Hepatology* 2001; **34**: 617-624 [PMID: 11584355]
- 10 Farci P, Quinzi I, Farci S, Alter HJ, Strazzera R, Palomba E, Coiana A, Cao D, Casadei AM, Ledda R, Iorio R, Vegnente A, Diaz G, Tovo PA. Evolution of hepatitis C viral quasiespecies and hepatic injury in perinatally infected children followed prospectively. *Proc Natl Acad Sci USA* 2006; **103**: 8475-8480 [PMID: 16707577]
- 11 Chang MH, Hwang LY, Hsu HC, Lee CY, Beasley RP. Prospective study of asymptomatic HBsAg carrier children infected in the perinatal period: clinical and liver histologic studies. *Hepatology* 1988; **8**: 374-377 [PMID: 3356419]
- 12 Chen DS. Natural history of chronic hepatitis B virus infection: new light on an old story. *J Gastroenterol Hepatol* 1993; **8**: 470-475 [PMID: 8218997]
- 13 Hsu HC, Lin YH, Chang MH, Su IJ, Chen DS. Pathology of chronic hepatitis B virus infection in children: with special reference to the intrahepatic expression of hepatitis B virus antigens. *Hepatology* 1988; **8**: 378-382 [PMID: 3356420]
- 14 Wang HY, Chien MH, Huang HP, Chang HC, Wu CC, Chen PJ, Chang MH, Chen DS. Distinct hepatitis B virus dynamics in the immunotolerant and early immunoclearance phases. *J Virol* 2010; **84**: 3454-3463 [PMID: 20089644 DOI: 10.1128/

- JVI.02164-09.]
- 15 **Lai M**, Hyatt BJ, Nasser I, Curry M, Afdhal NH. The clinical significance of persistently normal ALT in chronic hepatitis B infection. *J Hepatol* 2007; **47**: 760-767 [PMID: 17928090]
  - 16 **Carey I**, D'Antiga L, Bansal S, Longhi MS, Ma Y, Mesa IR, Mieli-Vergani G, Vergani D. Immune and viral profile from tolerance to hepatitis B surface antigen clearance: a longitudinal study of vertically hepatitis B virus-infected children on combined therapy. *J Virol* 2011; **85**: 2416-2428 [PMID: 21147914 DOI: 10.1128/JVI.01449-10]
  - 17 **Yalcin K**, Degertekin H, Yildiz F, Celik Y. Markers of disease activity in chronic hepatitis B virus infection. *Clin Invest Med* 2003; **26**: 27-34 [PMID: 12659467]
  - 18 **European Association For The Study Of The Liver**. EASL clinical practice guidelines: Management of chronic hepatitis B virus infection. *J Hepatol* 2012; **57**: 167-185 [PMID: 22436845 DOI: 10.1016/j.jhep.2012.02.010]
  - 19 **Liaw YF**, Leung N, Kao JH, Piratvisuth T, Gane E, Han KH, Guan R, Lau GK, Locarnini S; Chronic Hepatitis B Guideline Working Party of the Asian-Pacific Association for the Study of the Liver.. Asian-Pacific consensus statement on the management of chronic hepatitis B: a 2008 update. *Hepatol Int* 2008; **2**: 263-283 [PMID: 19669255 DOI: 10.1007/s12072-008-9080-3]
  - 20 **Chen CJ**, Yang HI, Su J, Jen CL, You SL, Lu SN, Huang GT, Iloeje UH. Risk of hepatocellular carcinoma across a biological gradient of serum hepatitis B virus DNA level. *JAMA* 2006; **295**: 65-73 [PMID: 16391218]
  - 21 **Chen CJ**, Yang HI, Iloeje UH. Hepatitis B virus DNA levels and outcomes in chronic hepatitis B. *Hepatology* 2009; **49**: S72-S84 [PMID: 19399801 DOI: 10.1002/hep.22884]
  - 22 **Iloeje UH**, Yang HI, Jen CL, Su J, Wang LY, You SL, Chen CJ. Risk and predictors of mortality associated with chronic hepatitis B infection. *Clin Gastroenterol Hepatol* 2007; **5**: 921-931 [PMID: 17678844]
  - 23 **Sanai FM**, Babatin MA, Bzeizi KI, Alsohaibani F, Al-Hamoudi W, Alsaad KO, Al Mana H, Handoo FA, Al-Ashgar H, Alghamdi H, Ibrahim A, Aljumah A, Alalwan A, Altraif IH, Al-Hussaini H, Myers RP, Abdo AA. Accuracy of international guidelines for identifying significant fibrosis in hepatitis B e antigen-negative patients with chronic hepatitis. *Clin Gastroenterol Hepatol* 2013; **11**: 1493-1499.e2 [PMID: 23811251 DOI: 10.1016/j.cgh.2013.05.038]
  - 24 **Zoulim F**, Mason WS. Reasons to consider earlier treatment of chronic HBV infections. *Gut* 2012; **61**: 333-336 [PMID: 22147510 DOI: 10.1136/gutjnl-2011-300937]
  - 25 **Poddar U**, Yachha SK, Agarwal J, Krishnani N. Cure for immune-tolerant hepatitis B in children: is it an achievable target with sequential combo therapy with lamivudine and interferon? *J Viral Hepat* 2013; **20**: 311-316 [PMID: 23565612 DOI: 10.1111/jvh.12007]
  - 26 **Dienstag JL**, Perrillo RP, Schiff ER, Bartholomew M, Vicary C, Rubin M. A preliminary trial of lamivudine for chronic hepatitis B infection. *N Engl J Med* 1995; **333**: 1657-1661 [PMID: 7477217]
  - 27 **Lok AS**, Lai CL, Wu PC, Leung EK, Lam TS. Spontaneous hepatitis B e antigen to antibody seroconversion and reversion in Chinese patients with chronic hepatitis B virus infection. *Gastroenterology* 1987; **92**: 1839-1843 [PMID: 3569757]
  - 28 **Hongthanakorn C**, Chotiyaputta W, Oberhelman K, Fontana RJ, Marrero JA, Licari T, Lok AS. Virological breakthrough and resistance in patients with chronic hepatitis B receiving nucleos(t)ide analogues in clinical practice. *Hepatology* 2011; **53**: 1854-1863 [PMID: 21618260 DOI: 10.1002/hep.24318]
  - 29 **Wong GL**, Chan HL, Yu Z, Chan HY, Tse CH, Wong VW. Liver fibrosis progression in chronic hepatitis B patients positive for hepatitis B e antigen: a prospective cohort study with paired transient elastography examination. *J Gastroenterol Hepatol* 2013; **28**: 1762-1769 [PMID: 23808759 DOI: 10.1111/jgh.12312]
  - 30 **Hu KQ**, Schiff ER, Kowdley KV, Min AD, Shiffman ML, Lee WM, Goodman ZD, Dau LO, Peschell KJ, Fagan EA, Flaherty JF. Histologic evidence of active liver injury in chronic hepatitis B patients with normal range or minimally elevated alanine aminotransferase levels. *J Clin Gastroenterol* 2010; **44**: 510-516 [PMID: 20179614 DOI: 10.1097/MCG.0b013e3181d34c65]
  - 31 **Prati D**, Taioli E, Zanella A, Della Torre E, Butelli S, Del Vecchio E, Vianello L, Zanuso F, Mozzi F, Milani S, Conte D, Colombo M, Sirchia G. Updated definitions of healthy ranges for serum alanine aminotransferase levels. *Ann Intern Med* 2002; **137**: 1-10 [PMID: 12093239]
  - 32 **Buchmann P**, Dembek C, Kuklick L, Jäger C, Tedjokusumo R, von Freyend MJ, Drebber U, Janowicz Z, Melber K, Protzer U. A novel therapeutic hepatitis B vaccine induces cellular and humoral immune responses and breaks tolerance in hepatitis B virus (HBV) transgenic mice. *Vaccine* 2013; **31**: 1197-1203 [PMID: 23306359 DOI: 10.1016/j.vaccine.2012.12.074]

**P- Reviewers:** Alavian SM, Quarleri J **S- Editor:** Gou SX  
**L- Editor:** Roemmele A **E- Editor:** Wu HL





## Melatonin attenuates cisplatin-induced HepG2 cell death *via* the regulation of mTOR and ERCC1 expressions

Kangsadarn Bennukul, Sucha Numkliang, Vijittra Leardkamolkarn

Kangsadarn Bennukul, Sucha Numkliang, Toxicology Graduate Programme, Faculty of Science, Mahidol University, Bangkok 10400, Thailand

Vijittra Leardkamolkarn, Department of Anatomy, Faculty of Science, Mahidol University, Bangkok 10400, Thailand

Vijittra Leardkamolkarn, Center of Excellence on Environmental Health and Toxicology, Mahidol University, Bangkok 10400, Thailand

Author contributions: Bennukul K and Leardkamolkarn V contributed to experimental design, coordinate the study, interpret the data, writing and revising the manuscript; Numkliang S performed an immunocytochemistry experiment.

Supported by Center of Excellence on Environmental Health and Toxicology, Science and Technology Postgraduate Education and Research Development Office, Thailand Ministry of Education

Correspondence to: Vijittra Leardkamolkarn, PhD, Associate Professor, Department of Anatomy, Faculty of Science, Mahidol University, Rama VI Road, Bangkok 10400, Thailand. [vijittra.lea@mahidol.ac.th](mailto:vijittra.lea@mahidol.ac.th)

Telephone: +66-2-2015402 Fax: +66-2-3547168

Received: October 25, 2013 Revised: January 9, 2014

Accepted: April 3, 2014

Published online: April 27, 2014

### Abstract

**AIM:** To elucidate the effects of melatonin on cisplatin-induced hepatocellular carcinoma (HepG2) cell death and to identify potential cross-talk pathways.

**METHODS:** Hepatocellular carcinoma HepG2 cells were treated with melatonin and/or cisplatin for 24 to 48 h. Cell viability and the 50% cytotoxic concentration (CC<sub>50</sub>) were calculated by MTT assays. The effects and intracellular events induced by the selected concentrations of melatonin (1 mmol/L) and cisplatin (20 μmol/L) were investigated. Cell death and survival detection were primarily evaluated using a fluorescence microscope to assess 4',6 diamideno-2-phenylindol DNA staining and acridine orange lysosome staining and then further analyzed with immunocytochemistry using an anti-LC3 antibody. The potential molecular

responses mediated by melatonin against cisplatin after the combined treatment were investigated by reverse transcription-polymerase chains reaction and Western blot analyses of the genes and proteins associated with cell survival and death. A cell cycle analysis was performed using a flow cytometry assay.

**RESULTS:** Melatonin had a concentration-dependent effect on HepG2 cell viability. At 1 mmol/L, melatonin significantly increased the cell viability percentage and decreased reactive oxygen species production due to cisplatin. Melatonin reduced cisplatin-induced cell death, decreasing phosphorylated p53 apoptotic protein, cleaved caspase 3 and Bax levels but increasing anti-apoptotic *Bcl-2* gene and protein expression. When combined with cisplatin, melatonin induced S phase (DNA synthesis) cell cycle arrest and promoted autophagic events in HepG2 cells. Melatonin also had a concentration-dependent effect on Beclin-1 and its autophagic regulator mammalian target of rapamycin (mTOR) as well as the DNA excision repair cross complementary 1 (ERCC1) protein. The expression levels of these proteins were altered in HepG2 cells during cisplatin or melatonin treatment alone. In the combination treatment, melatonin reversed the effects of cisplatin by suppressing the over-expression of mTOR and ERCC 1 and enhancing the expression levels of Beclin-1 and microtubule-associated protein-light chain3-II, leading to intracellular autophagosome progression.

**CONCLUSION:** Melatonin attenuated cisplatin-induced cell death in HepG2 cells *via* a counter-balance between the roles of apoptotic- and autophagy-related proteins.

© 2014 Baishideng Publishing Group Co., Limited. All rights reserved.

**Key words:** Melatonin; Cisplatin; Hepatocellular carcinoma; Excision repair cross complementary 1; Mammalian target of rapamycin; Autophagy

**Core tip:** Melatonin has anti-oxidative stress and anti-

proliferative effects on cisplatin-treated hepatocellular carcinoma cells through a counter-balance between the roles of apoptosis and autophagy proteins. Melatonin also reduced cisplatin-induced DNA damage by decreasing the activation of excision repair cross complementary 1 in the DNA repair system. Thus, co-treatment with melatonin to ameliorate cisplatin adverse effects might be beneficial for Hepatocellular carcinoma therapy.

Bennukul K, Numkliang S, Leardkamolkarn V. Melatonin attenuates cisplatin-induced HepG2 cell death *via* the regulation of mTOR and ERCC1 expressions. *World J Hepatol* 2014; 6(4): 230-242 Available from: URL: <http://www.wjgnet.com/1948-5182/full/v6/i4/230.htm> DOI: <http://dx.doi.org/10.4254/wjh.v6.i4.230>

## INTRODUCTION

Hepatocellular carcinoma (HCC) is one of the leading causes of human death worldwide. Aberrant gene expression and mutations induced by any genotoxic agents that can cause DNA damage contribute to its development. Effective treatment for HCC is not yet available because all anticancer strategies have limitations associated with the tumor grade and stage of the disease. For example, chemotherapy is limited by the side effects of cytotoxic drugs that also kill normal cells and by the long-term side effects of these drugs, which are carcinogenic and can cause secondary cancers<sup>[1]</sup>. Moreover, the mechanisms controlling the responses of pro-oncogenes and tumor suppressor genes in the effected cells are not well defined. In cancer research, the human hepatocellular carcinoma (HepG2) cell line has been used as a model system for studies of hepatocarcinogenesis because it is a permanent cell line derived from a well-differentiated hepatocellular carcinoma patient. The HepG2 cell line has also been used as an *in vitro* model for studying liver metabolism and in drug targeting assays<sup>[2]</sup>.

To date, several anticancer drugs have been used clinically. Cisplatin, a platinum-based drug that has a known molecular mechanism of action, is a drug of choice that has been widely chosen for the treatment of solid cancers<sup>[3,4]</sup>. Cisplatin platinum can form complexes with DNA, inducing DNA adducts and damage<sup>[5]</sup>. Once produced, the complex mediates a series of intracellular responses that lead to apoptosis and also activates the DNA repair system, which is capable of inducing recovery of the damaged DNA and participates in the restoration of normal cell systems. However, if the damage is too extensive, the repair mechanism fails, and the cell undergoing apoptosis dies<sup>[6]</sup>. Through this pathway, cisplatin has no selective effects on cancers or normal cells. When receiving chemotherapy with cisplatin, some individuals respond by showing excessive side effects, and some cancers develop resistance to cisplatin by mechanisms that are only partially known. To improve chemothera-

peutic efficiency, investigators have emphasized the need to search for new drugs. An example would be to study the potency of cisplatin at low concentrations, which can protect against hepatotoxicity, and to study drug resistance mechanisms to identify a new drug to replace cisplatin.

Melatonin is a hormone that is produced in the pineal gland and has several normal physiological functions in the human body. Its known properties include circadian rhythm regulation<sup>[7]</sup>, sleep induction<sup>[8]</sup>, immunomodulation<sup>[9]</sup>, neuroprotection<sup>[10]</sup>, bone differentiation<sup>[11]</sup>, and anti-microbial<sup>[12]</sup> and anti-oxidative effects<sup>[13]</sup>. Previous investigations have demonstrated that melatonin also possesses anti-proliferative effects, especially in cell lines derived from various malignancies such as lymphoma<sup>[14]</sup>, prostate cancer<sup>[15]</sup>, melanoma<sup>[16]</sup> and hepatocellular carcinoma<sup>[17]</sup>. Although most of the biological effects of melatonin are produced through the activation of melatonin receptors, some are due to its status as a powerful antioxidant that plays roles in the protection of nuclear and mitochondrial DNA<sup>[18]</sup>. The anti-proliferative effect of the human osteosarcoma cell line MG-63 was shown to be activated by melatonin if the concentration of melatonin reached an optimal value, which was a high concentration of 4-10 mol/L<sup>[19]</sup>. Further data have suggested that melatonin could be used as an adjuvant to increase responses to anticancer drugs and to ameliorate their side effects<sup>[20-22]</sup>. However, the effectiveness of melatonin as an adjuvant of chemotherapy most likely differs among cancer types, and the mechanisms of the action of melatonin are still unclear. Due to the selective effects of melatonin, the current oncology research aiming to enhance the apoptosis effect of cisplatin combined with melatonin has extended to alternative pathways in treated cells.

It is well accepted that cells under oxidative stress or exposed to DNA damage, hypoxia, nutrient deprivation, and intracellular pathogens can survive through an autophagy pathway<sup>[23]</sup>. This pathway involves the lysosomal degradation of cytoplasmic organelles or cytosolic components, allowing cells to eliminate damaged or harmful components and also to recycle the released amino acids and energy to maintain cellular homeostasis<sup>[24]</sup>. In mammalian cells, the pathway is regulated through a serine/threonine protein kinase called mammalian target of rapamycin (mTOR)<sup>[25]</sup>. Normally, mTOR is activated under nutrient-rich conditions and inhibits autophagy<sup>[26]</sup>. However, under stress conditions, mTOR plays a role in autophagy activation *via* an effector Beclin-1 that initiates core nucleation for autophagy formation<sup>[27]</sup>. Under the normal condition, Beclin-1 is inhibited by an interaction with the Bcl-2/Bcl-xL complex, but when p53 binds to Bcl-2, it frees Beclin-1, leading to autophagy<sup>[28]</sup>. In addition to losing collaborative proto-oncogenes and tumor-suppressor genes during DNA damage, the cells expressed several efficient DNA repair systems, such as the nucleotide excision repair (NER) pathway, to prevent cancer formation<sup>[29]</sup>. NER can eradicate a broad spectrum

of DNA damage lesions through the action of a specific endonuclease enzyme named excision repair cross complementary 1 (ERCC1), which functions at the incision step of the NER pathway. ERCC1 cleaves damaged DNA at upstream sites, leading to DNA re-synthesis and ligation to return the damaged DNA to its native state and configuration<sup>[30]</sup>. Therefore, increased or decreased levels of ERCC1 expression should indicate efficiency of the DNA repair system.

In this study, we hypothesized that autophagy is an important pathway that plays roles in the outcome of cell death or survival in HepG2 cell during cisplatin and melatonin chemotherapy. We explored the expression of genes and proteins that regulate autophagy processes and lead to cell death and also identified the possible mechanism or cross-talk pathways mediated by melatonin and cisplatin.

## MATERIALS AND METHODS

### Cell culture

A HepG2 cell line was purchased from the American Type Culture Collection (Rockville, MD, United States). The cells were cultured at 37 °C in a humidified 5% CO<sub>2</sub> incubator and maintained in DMEM supplemented with 10% (v/v) fetal bovine serum, 1% (v/v) non-essential amino acids, 1% (v/v) sodium pyruvate, and 100 Units/mL penicillin-streptomycin were purchased from Thermo Fisher Scientific (Waltham, MA, United States).

### Cell viability assay

HepG2 cells were seeded onto 96-well plates (2 × 10<sup>4</sup> cells/well) for 24 h and then treated with 0.5-5.0 mmol/L melatonin (Merck, Frankfurter, Germany), 2.5-80.0 μmol/L cisplatin (Sigma Aldrich, St. Louis, MO, United States), or the combination of both for 24 and 48 h. In the combination treatment, the selected concentration was based on the minimal concentration that induced the anti-proliferative effect of melatonin and the most tolerable concentration that induced the cytotoxic effect of cisplatin. Cell viability was measured using an MTT colorimetric assay; MTT (3-(4,5-dimethylthiazol-2-yl)-2,5-diphenyltetrazolium bromide) was purchased from Sigma Aldrich (St. Louis, MO, United States), a working solution was added to each well and incubated at 37 °C for 2 h. The optical density of each well was measured using a microplate reader at 570 nm and the reference wavelength of 690 nm. Cell viability was calculated as the percentage of viable cells in the drug-treated group versus the untreated control group. The concentration of the compound that decreased cell viability by 50% cytotoxic concentrations (CC50) was calculated. Each experiment was performed in triplicate, and each result was presented as the mean ± SE.

### Measurement of intracellular reactive oxygen species production

HepG2 cells were seeded onto 96-well black, flat, clear-bottom plates (2 × 10<sup>4</sup> cells/well). After treatment, the

intracellular levels of ROS were measured by staining the treated and untreated cells with 50 μmol/L 2',7'-dichlorodihydrofluorescein diacetate (DCFH-DA) that was purchased from Sigma Aldrich (St. Louis, MO, United States) after incubation in the dark at 37 °C for 30 min. The fluorescence intensity was quantified by the relative percentage of untreated cells using a fluorescence microplate reader and used 500 μmol/L H<sub>2</sub>O<sub>2</sub>-treated cells as the positive control. Each experiment was performed in triplicate, and each result was presented as the mean ± SE.

### 4',6 diamideno-2-phenylindol DNA stain and acridine orange lysosome stain

HepG2 cells were seeded onto 24-well plates (2 × 10<sup>4</sup> cells/well) for 24 h and then treated with 1 mmol/L melatonin, 20 μmol/L cisplatin, or both for 24 and 48 h.

**DNA stain:** Treated cells were fixed with cold methanol, air dried, and stained with 4'-6-diamidino-2-phenylindole, (DAPI) (Boehringer, Ingelheim, Germany) at 37 °C for 30 min. The primary signs of apoptosis induction, namely, chromatin condensation, fragmented DNA, and/or apoptotic body formation, were evaluated under an inverted fluorescent microscope.

**Acridine orange stain:** Treated cells were stained with 5 μg/mL acridine orange (Sigma Aldrich, St. Louis, MO, United States) in serum-free medium at 37 °C for 15 min. The cells were examined under an inverted fluorescence microscope. Positive acidic vacuoles or stained lysosomes were observed as orange or red foci in the cytoplasm, and DNA bound-acridine orange was detected as a green signal.

### Immunocytochemistry

To determine an autophagic event, treated cells grown on coverslips were fixed in 4% paraformaldehyde for 5 min, permeabilized with methanol, and blocked with 3% bovine serum albumin in phosphate buffer saline (PBS) for 1 h at room temperature. The cells were then incubated with an indicator of autophagy, an anti-LC3 antibody was purchased from Cell Signaling Technology (Danvers, MA, United States) and was diluted 1:400 in PBS, overnight at 4 °C. After incubation, the cells were washed with PBS and incubated with an Alexa Fluor 555-conjugated secondary antibody (Cell Signaling Technology, Danvers, MA, United States) for 2 h at room temperature, washed with PBS, and counter-stained with DAPI. The immunofluorescently labeled cells were visualized under a confocal laser-scanning microscope (Olympus, Tokyo, Japan).

### Semi-quantitative analysis (RT-PCR) of genes controlling apoptosis and autophagy

HepG2 cells were seeded onto 6-well plates (4 × 10<sup>5</sup> cells/well). After treatment with 1 mM melatonin, 20 μmol/L cisplatin, or both for 24 h, total RNA was extracted with TRI Reagent (Molecular Research Center Inc; Cincinnati, OH, United States). cDNAs were synthesized by RevertAid™ M-MuLV Reverse Transcriptase and amplified by polymerase chain reaction (PCR) with



**Table 1** Genes of interests and the primer pairs for polymerase chain reaction

| Genes        | Function              | Primers sequence (5'-3')                                | Size (bp) |
|--------------|-----------------------|---|-----------|
| <i>Bax</i>   | Pro-apoptosis         | F- AAAGCTAGCGAGTGTCTCAAGCGC<br>R-TCCCGCCACAAAGATGGTCACG | 366       |
| <i>Bcl-2</i> | Anti-apoptosis        | F-TTGIGGCCCTTCTTTGAGTTCG<br>R-TACIGCTTTAGTGAACCTTTT     | 332       |
| <i>mTOR</i>  | Autophagic inhibition | F-TCTCATGGGCTTCGGAACAA<br>R-GTGAAGGCAGAAGGTCGGAA        | 318       |
| <i>ERCC1</i> | DNA repair            | F-CCCTGGGAATTTGGCGACGTAA<br>R-CTCCAGGTACCGCCAGCTTCC     | 273       |
| <i>GAPDH</i> | House keeping         | F-CATCACCATCTTCCAGGAGC<br>R-CATGAGTCCTTCCACGATACC       | 307       |

mTOR: Mammalian target of rapamycin; ERCC1: Excision repair cross complementary 1; GAPDH: Glyceraldehyde-3-phosphate dehydrogenase.

specific primer pairs, as indicated in Table 1, using a High Fidelity PCR kit (Thermo Fisher Scientific, Waltham, MA, United States). The PCR cycles were adjusted accordingly to primer annealing. The PCR products were analyzed by 1.5% agarose gel electrophoresis and gel staining with ethidium bromide for 30 min. The gels were photographed using gel documentation (UVP Bio-imaging System, United States). The experiments were performed in triplicate, and the relative band densities of cDNA from the treated cells were compared to the untreated cells.

#### Western blot analysis of proteins associated with apoptosis and autophagy

The treated cells were lysed in RIPA buffer (25 mmol/L Tris-HCl pH 7.6, 150 mmol/L NaCl, 1% NP-40, 1% sodium deoxycholate, 0.1% sodium dodecyl sulfate (SDS), and protease inhibitor cocktail were purchased from Merck (Frankfurter, Germany) on ice for 30 min. The samples were then centrifuged at 24000 *g* at 4 °C for 15 min. The cell lysates were collected, and the total protein concentrations were determined by a BCA assay (Merck, Frankfurter, Germany). Equal amounts of protein (30 µg) from each sample were separated by 8%-15% SDS-polyacrylamide gel electrophoresis at 100 V and transferred onto nitrocellulose membranes (GE Healthcare, Buckinghamshire, United Kingdom). The membranes were blocked with 3% w/v bovine serum albumin (Sigma Aldrich, St. Louis, MO, United States) in Tris-buffered saline containing 0.1% Tween-20 for 2 h at room temperature. Then, the membranes were incubated with a 1:1000 dilution of primary antibodies against Bax (Santa Cruz, CA, United States), p53, phospho-p53, Bcl-2, procaspase3, cleaved-caspase3, p-mTOR, ERCC1, Beclin-1 or LC3 (Cell Signaling Technology, Danvers, MA, United States) overnight at 4 °C, followed by two extensive washings with TBST. The membranes were incubated with a 1:2000 dilution of horseradish peroxidase-conjugated secondary antibody for 2 h. The specific bands corresponding to the investigated proteins were visualized using enhanced chemiluminescence (ECL reagents, GE

Healthcare, Buckinghamshire, United Kingdom). The signal intensities were determined by densitometry using Image-J software (National Institutes of Health, Bethesda, MD, United States). After stripping off the first probe, each membrane was re-probed with a β-actin antibody (Santa Cruz, CA, United States) to confirm the equal loading of protein in each experiment. The levels of protein expression were presented in relation to β-actin.

#### Flow cytometry analysis of DNA synthesis and cell cycle activity

HepG2 cells were seeded onto 6-well plates ( $4 \times 10^5$  cells/well). After treatment with 1 mmol/L melatonin, 20 µmol/L cisplatin, or a combination of both for 24 h, the cells were trypsinized, centrifuged, washed twice with cold PBS, and fixed overnight with 70% ethanol at -20 °C. The cells were resuspended in staining buffer containing 50 µg/mL propidium iodide (Merck, Frankfurter, Germany), 3.8 mmol/L sodium citrate, and 50 µg/mL RNase A (Sigma Aldrich, St. Louis, MO, United States) and incubated in the dark at 37 °C for 30 min. The stained cell suspensions were processed for flow cytometry analysis to determine the amount of DNA at different phases of the cell cycle using a FACScanto apparatus (BD Pharmingen, San Diego, CA, United States) with the loaded software. A total of 30000 cells from each sample were collected for evaluation of each data file.

#### Statistical analysis

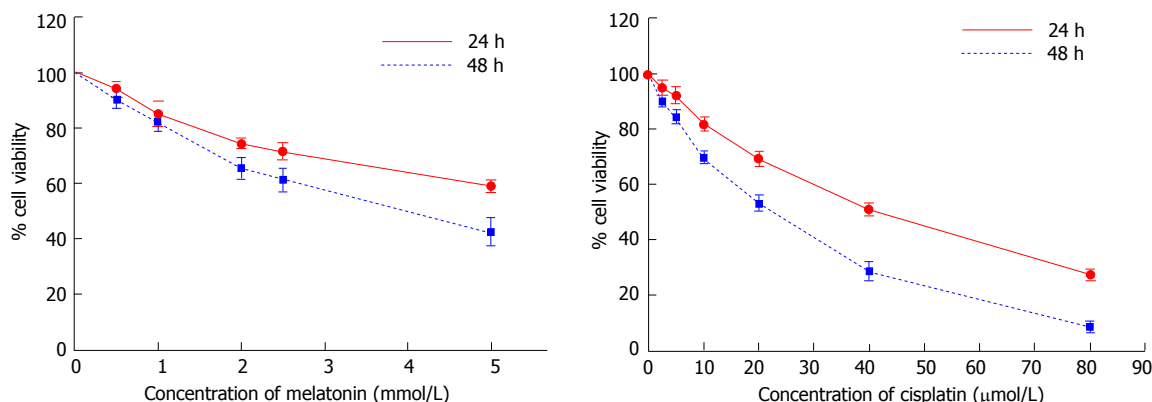
All experiments were performed in triplicate ( $n = 3$ ). Data are presented as the mean  $\pm$  SE for each group, and these were compared for significant differences using a one-way analysis of variance test, followed by a post-hoc analysis (Tukey's multiple comparison test) using Prism 5 (GraphPad Software Inc; San Diego, CA, United States).

## RESULTS

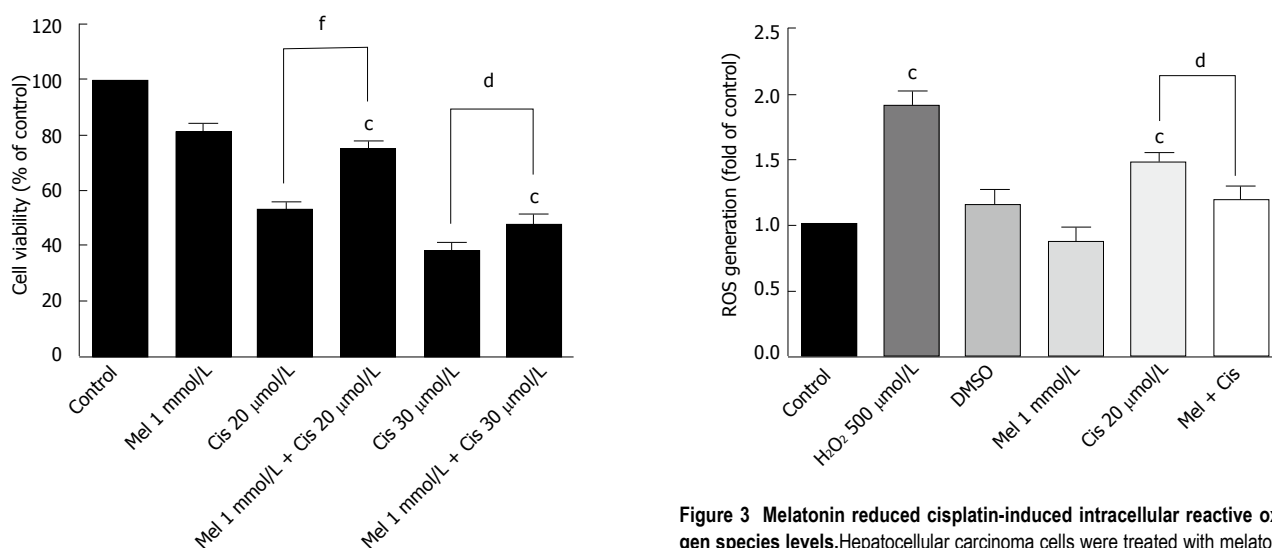
#### Effect of melatonin and cisplatin on HepG2 cell viability

As shown in Figure 1, melatonin (concentration 0.5-5 mmol/L) and cisplatin (concentration 2.5-80 µmol/L) reduced the viability of HepG2 cells in a time-concentration dependent manner. The 50% CC<sub>50</sub> of melatonin were 6.25 mmol/L and 3.74 mmol/L and of cisplatin were 38.53 µmol/L and 17.53 µmol/L, at 24 h and 48 h, respectively. The concentrations of melatonin and cisplatin used in the combination treatment were selected from the minimal anti-proliferative effect of melatonin, which significantly decreased percent cell viability, and the most tolerable cytotoxic effect of cisplatin, which induced cell death at a rate below 50%. Therefore, 1 mmol/L melatonin was used in combination with 20 and 30 µmol/L cisplatin for 48 h. Melatonin increased the viability of HepG2 cells compared with cisplatin treatment alone. The combined treatment significantly reduced cell viability compared with the control and significantly increased cell viability compared with the cisplatin treatment alone





**Figure 1** Effect of melatonin and cisplatin on cell viability analyzed using an MTT assay. Hepatocellular carcinoma (HepG2) cells were treated with various concentrations of melatonin and cisplatin for 24 h and 48 h. Both melatonin and cisplatin reduced the percent viability of HepG2 cells in a time and concentration-dependent manner ( $P < 0.001$ ). The experiments were performed in triplicate, and the results are presented as the means  $\pm$  SE.



**Figure 2** Effect of the combined treatment of melatonin and cisplatin on cell viability. Hepatocellular carcinoma cells were treated with melatonin (1 mmol/L) and/or cisplatin (20 and 30 μmol/L) for 48 h and then analyzed by an MTT assay. Melatonin reduced the cisplatin cytotoxic effect at 20 μmol/L cisplatin. The results are presented as the mean  $\pm$  SE. ( $^aP < 0.001$  compared with the control group,  $^bP < 0.05$ ,  $^cP < 0.001$  compared with cisplatin-treated group).

**Figure 3** Melatonin reduced cisplatin-induced intracellular reactive oxygen species levels. Hepatocellular carcinoma cells were treated with melatonin (1 mmol/L) and/or cisplatin (20 μmol/L) for 24 h. The results are presented as the means  $\pm$  SE. ( $^aP < 0.001$  compared with the control group,  $^bP < 0.05$  compared with the cisplatin-treated group).

(Figure 2).

### Potential mechanisms and pathways of the melatonin-mediated attenuation of cisplatin-induced cell death

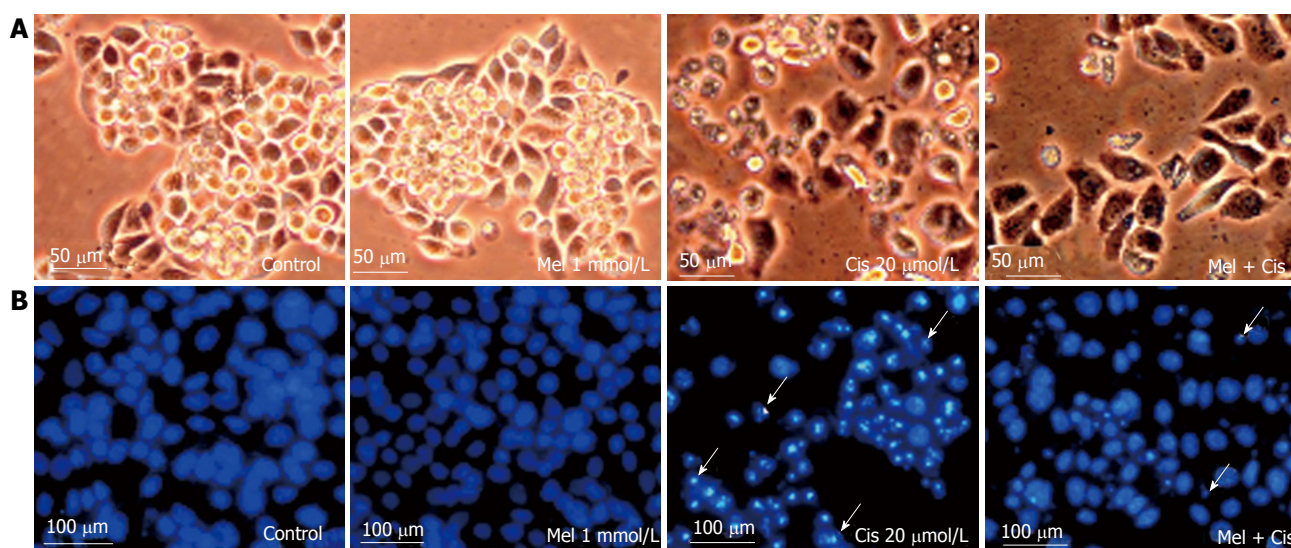
**Anti-ROS production:** To determine whether melatonin reduced the ROS production due to cisplatin, the biochemical basis of intracellular ROS was explored using a fluorescein-labeled dye, DCFH-DA. The results showed significantly increased intracellular ROS in cisplatin-treated cells. However, the combined treatment with melatonin (1 mmol/L) reduced the intracellular ROS level (Figure 3).

**Reduction of cellular damage and apoptosis formation:** The combined effect of melatonin and cisplatin

was evaluated in unstained in HepG2 cells under an inverted light microscope (Figure 4A) and in HepG2 cells stained with DAPI under a fluorescence microscope (Figure 4B). Melatonin treatment resulted in no morphological changes and the absence of apoptotic nuclei. Cisplatin treatment induced intense morphological changes, with cell shrinkage and typical apoptotic nuclear features, such as nuclear condensation and apoptotic bodies. The combined melatonin and cisplatin treatment revealed unchanged cell morphology and a reduction of apoptotic bodies.

### Regulation of apoptosis vs anti-apoptosis genes and protein expression:

To determine apoptotic events in cells, the expression of the genes and proteins involved in apoptosis were analyzed. As shown in Figure 5, Western blotting results indicated that melatonin (1 mmol/L) had no significant effect on proteins associated with apoptosis (p53, p-p53, pro-caspase3 and cleaved-caspase3), whereas cisplatin significantly increased p53 and p-p53 levels.



**Figure 4 Histological changes.** Hepatocellular carcinoma cells were treated with melatonin (1 mmol/L) and/or cisplatin (20 μmol/L) for 48 h. The cells were stained with DAPI for fragmented DNA (apoptotic bodies) and observed under an inverted microscope. A: Morphological changes showing vacuoles in the cytoplasm of cisplatin-treated cells (scale bar = 50 μm); B: DAPI staining showing nuclear condensation and apoptotic bodies (white arrows) in cisplatin-treated cells. The combined treatment showed less apoptotic effects (scale bar = 100 μm).

Gene and protein expression analyses of pro-apoptosis Bax and anti-apoptosis Bcl-2 levels revealed slight decreases in the Bax/Bcl-2 ratio with melatonin treatment while resulting in a significantly increased Bax/Bcl-2 ratio with cisplatin treatment. In the combined treatment, melatonin significantly ameliorated the pro-apoptotic effects of cisplatin.

**Cell cycle regulation:** To determine the effects of the treatments on HepG2 cell cycle control, DNA accumulation was measured by flow cytometry at different phases of the cell cycle. The phases of cell cycle arrest were determined at G<sub>0</sub>/G<sub>1</sub> by melatonin and at subG<sub>0</sub>, G<sub>0</sub>/G<sub>1</sub>, and S by cisplatin. In the combined treatment, melatonin reduced cisplatin cell cycle arrest at the subG<sub>0</sub> through G<sub>0</sub>/G<sub>1</sub> phases but significantly increased cell cycle arrest at the S phase (Figure 6).

**Autophagy regulation:** The combined effect of melatonin and cisplatin in HepG2-treated cells was evaluated for lysosomal staining with acridine orange dye and observation under an inverted microscope to measure fluorescence. Both melatonin and cisplatin caused slight increases in the acidic lysosomal compartments; an increase in acridine orange intensity was highly apparent in the combined treatment (Figure 7A). In the immunofluorescence assay with the anti-LC3 antibody, melatonin and cisplatin treatment alone induced minor autophagy events in HepG2 cells compared with the control. However, the combination of melatonin and cisplatin treatment significantly enhanced autophagy, as indicated by the fluorescence intensity of LC3 scattered throughout the cytoplasm (Figure 7B).

**Alteration of autophagy regulators and the DNA repair system:** To explore the potential pathways of melatonin and cisplatin effects on autophagy regulation and DNA repair process in HepG2-treated cells, the relationship between the proteins Beclin-1, mTOR and ERCC1 were analyzed.

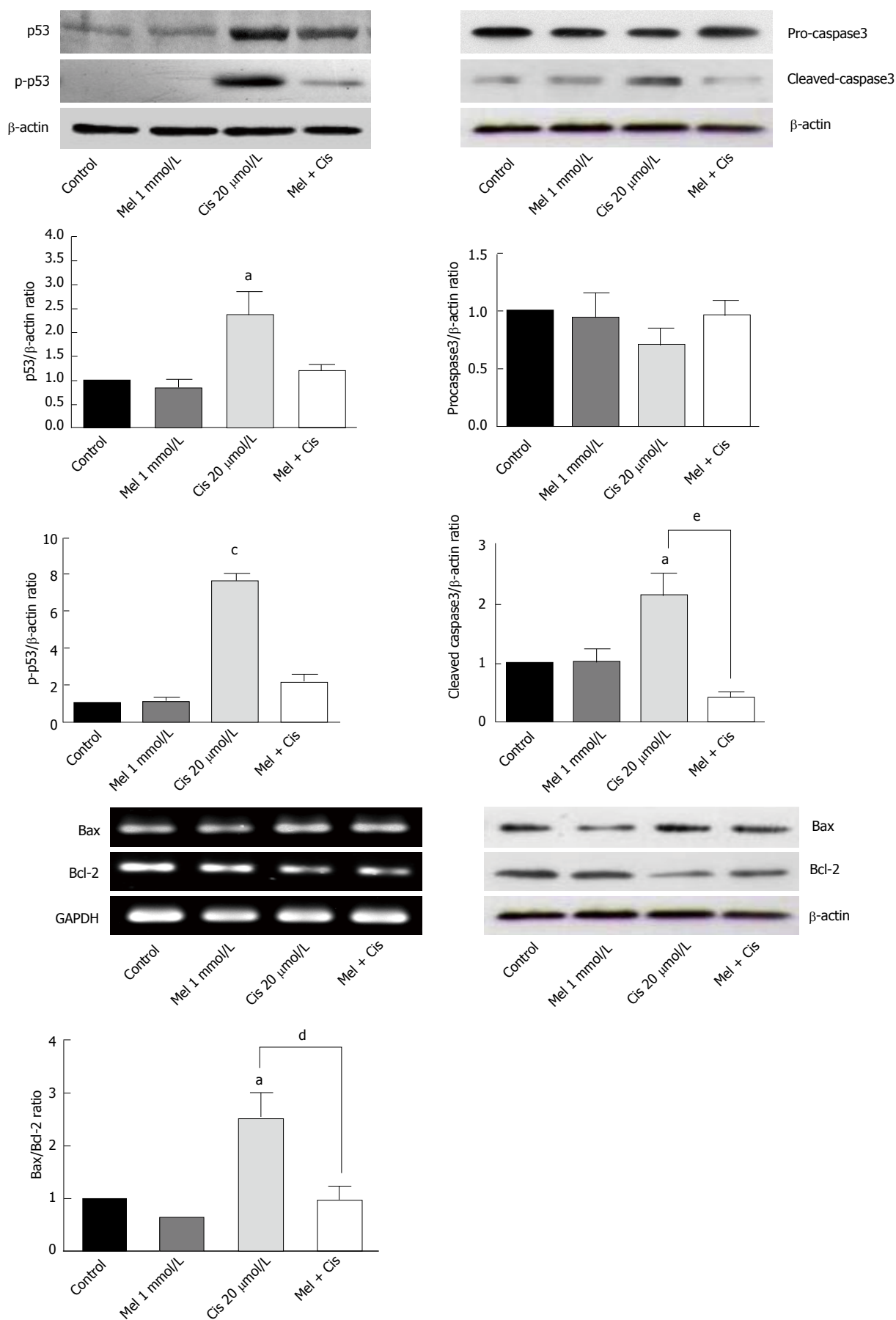
Melatonin (0.5 and 1 mmol/L) increased Beclin-1, p-mTOR, and ERCC1 in a concentration-dependent manner (Figure 8). Conversely, cisplatin (10 and 20 μmol/L) decreased Beclin-1, p-mTOR, and ERCC1 in a concentration-dependent manner. At the selected concentrations (1 mmol/L melatonin and 20 μmol/L cisplatin), melatonin significantly increased p-mTOR and ERCC1 from the basal levels, whereas cisplatin decreased Beclin-1 and increased p-mTOR and ERCC1 from the basal levels.

Evaluation of the autophagy process in melatonin- and cisplatin-treated HepG2 cells showed changes in Beclin-1 (an initiator of autophagy) and LC3-II (a mature marker of autophagy). Melatonin (1 mmol/L) treatment alone slightly increased both Beclin-1 and LC3-II, but cisplatin (20 μmol/L) treatment alone decreased Beclin-1 and slightly increased LC3-II (Figure 9). The combined treatment showed that melatonin prevented cisplatin from affecting the level of Beclin-1 but significantly increased the effect of cisplatin on the LC3-II level.

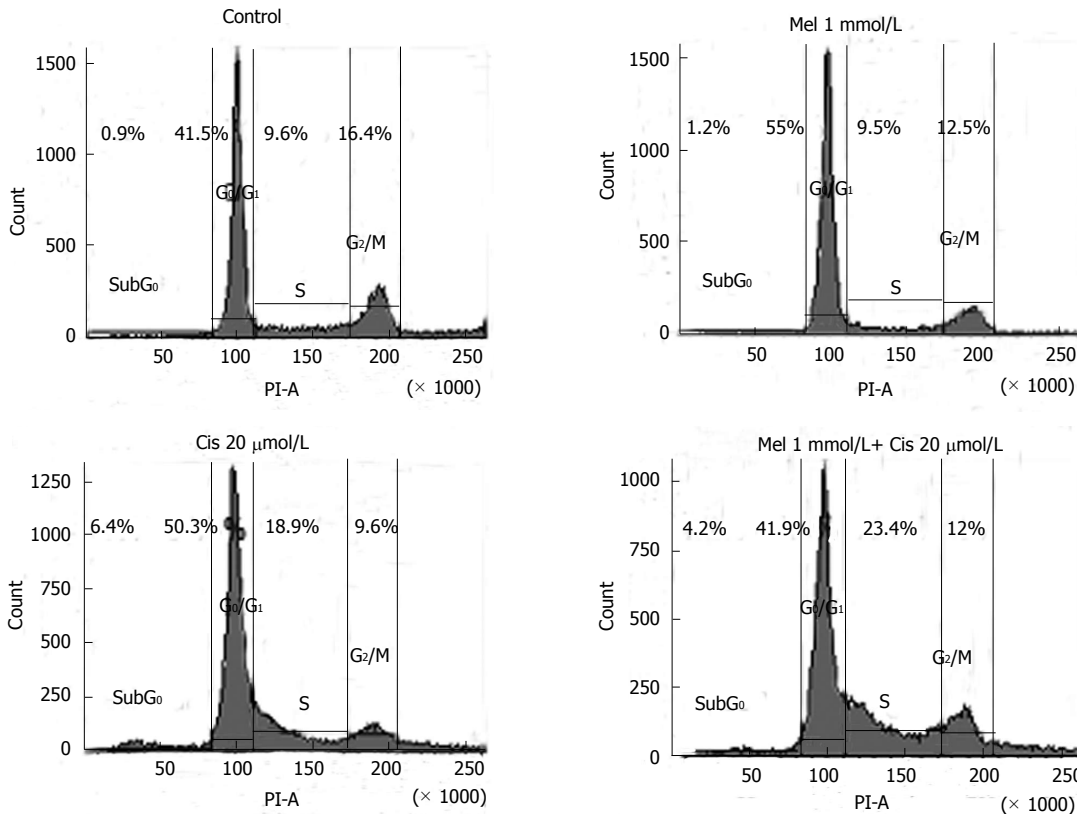
The analysis of mTOR and ERCC1 mRNA and protein expression in the treated HepG2 cells revealed that melatonin (1 mmol/L) or cisplatin (20 μmol/L) treatment alone significantly increased p-mTOR and ERCC1 from the basal levels. However, the combined treatment resulted in the suppression of both p-mTOR and ERCC1 compared with the basal cellular levels (Figure 10). (See a schematic overview of the results in Figure 11)

## DISCUSSION

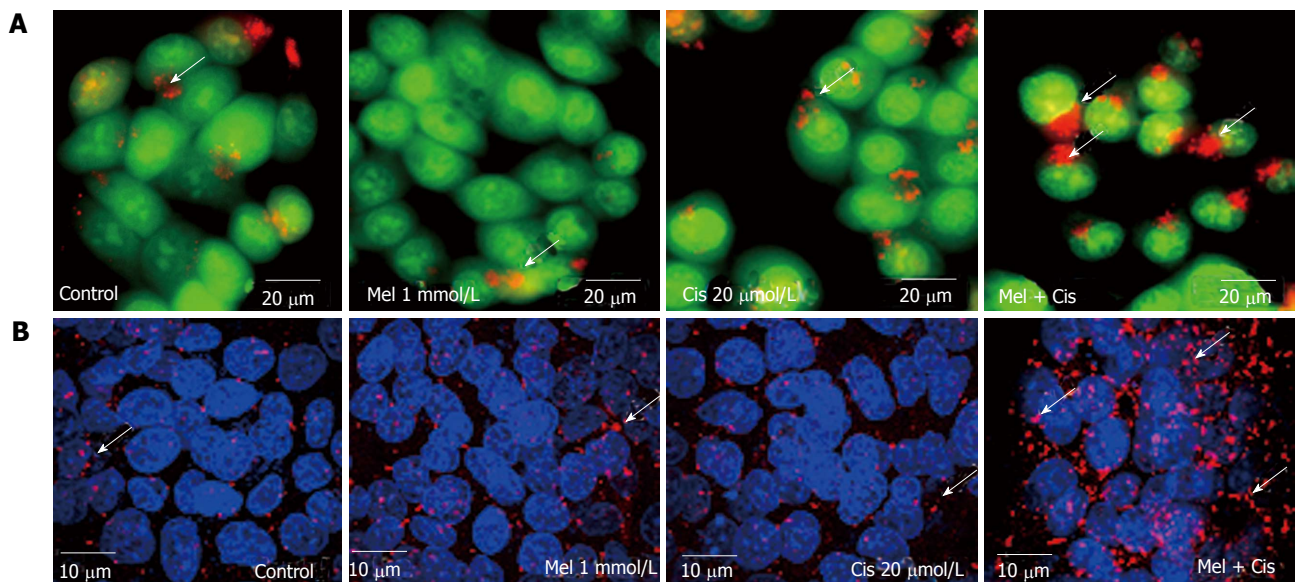
Cisplatin chemotherapy has been used to kill several solid cancer cells with satisfactory results. However, due to



**Figure 5** Reverse transcription-polymerase chain reaction and Western blot analyses of apoptosis regulators in treated hepatocellular carcinoma cells. Melatonin had minor effects on all apoptosis markers, whereas cisplatin significantly increased apoptosis via the activation of p53 and caspase3 and the Bax/Bcl-2 ratio. Melatonin reduced cisplatin effects in the combined treatment. (<sup>a</sup>P < 0.05, <sup>b</sup>P < 0.001 compared with the control group, <sup>c</sup>P < 0.05, <sup>d</sup>P < 0.01 compared with the cisplatin-treated group).



**Figure 6** Effects of melatonin and cisplatin on the cell cycle, as evaluated using flow cytometric analysis. Hepatocellular carcinoma (HepG2) cells were treated with melatonin (1 mmol/L) and/or cisplatin (20 μmol/L) for 24 h. Melatonin induced DNA accumulation in the HepG2 cells at the G<sub>0</sub>/G<sub>1</sub> phase, whereas cisplatin affected cell cycle arrest at the sub-G<sub>0</sub>, G<sub>0</sub>/G<sub>1</sub>, and S phases. In the combined treatment, melatonin decreased the cisplatin effect on cell cycle arrest at the sub-G<sub>0</sub> through G<sub>0</sub>/G<sub>1</sub> phases but significantly increased S phase cell cycle arrest.

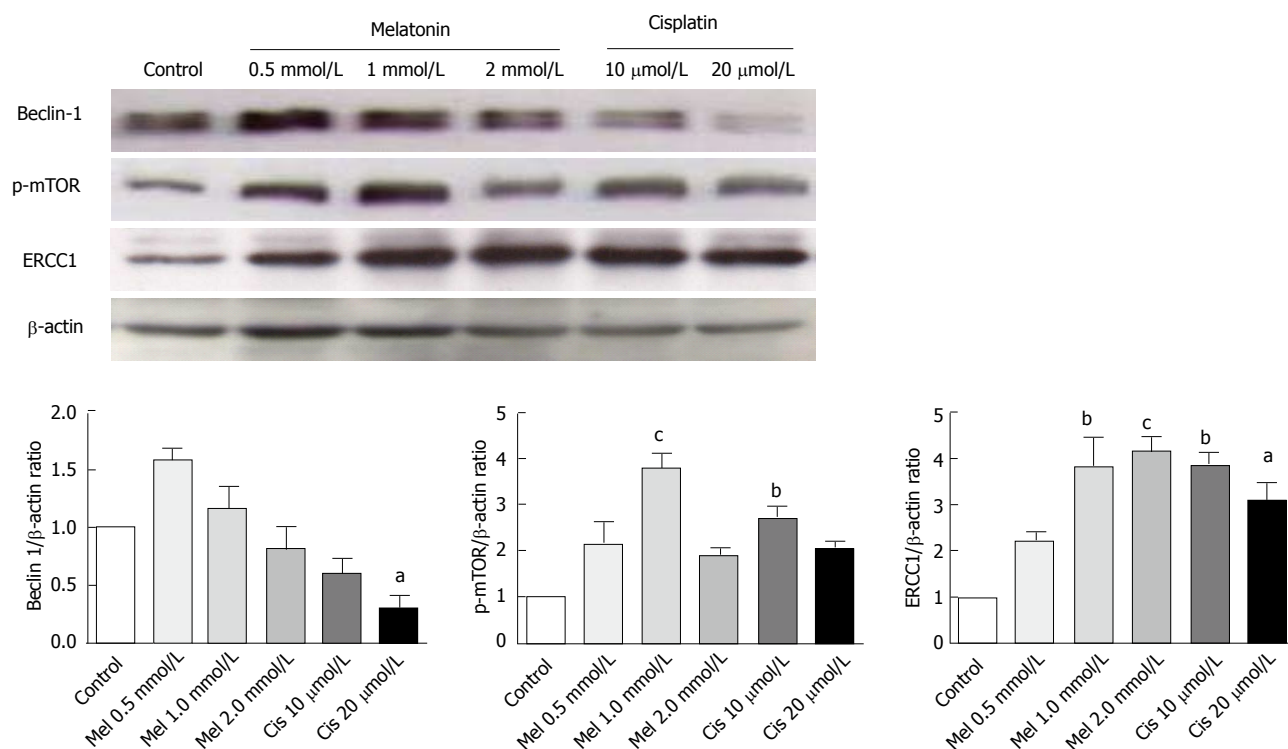


**Figure 7** Autophagic detection by acridine orange staining and immunofluorescence. Hepatocellular carcinoma (HepG2) cells were treated with 1 mmol/L melatonin and/or 20 μmol/L cisplatin for 24 h and evaluated for autophagy formation. The experiments were performed in triplicate, and representative micrographs are shown. A: Acridine orange staining showed lysosomal (red or orange) staining in the cells of all treatments. The increased acidic lysosomes in the combination treatment suggests potential lysosomal activation (scale bar = 20 μm); B: Confocal immunofluorescence micrographs of representative treated-HepG2 cells immunolabeled with the anti-LC3 antibody (scale bar = 10 μm). Melatonin and cisplatin treatment alone induced some fluorescent immunoreactivity in the cytoplasm, but the combined treatment induced intense immunoreactivity.

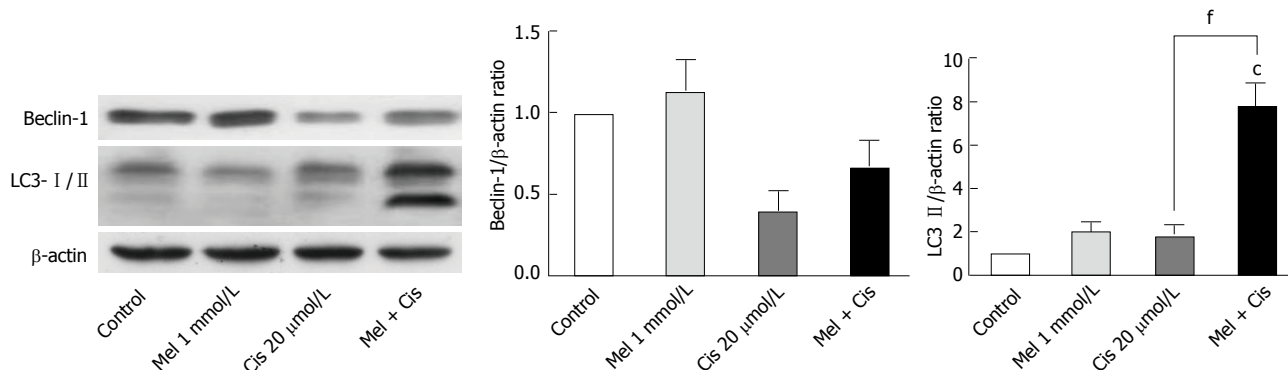
its efficient cytotoxic effects, cisplatin produces adverse drug effects and chemo-resistance. Therefore, adjuvant

therapy with melatonin has been proposed, and extensive studies were performed, with variable outcomes<sup>[22]</sup>. In the





**Figure 8 Analysis of autophagy and DNA repair-related proteins.** Hepatocellular carcinoma cells were treated with various concentrations of melatonin and cisplatin. At the selected concentrations, 1 mmol/L melatonin and 20  $\mu$ mol/L cisplatin have a similar effect by significantly increasing p-mTOR and ERCC 1 from the basal levels. However, the effect on Beclin-1 was the opposite, with melatonin increasing Beclin-1 and cisplatin decreasing Beclin-1 from the basal level. The results are presented as the mean  $\pm$  SE. (<sup>a</sup> $P$  < 0.05, <sup>b</sup> $P$  < 0.01, <sup>c</sup> $P$  < 0.001 compared with the control group). ERCC1: Excision repair cross complementary-1.

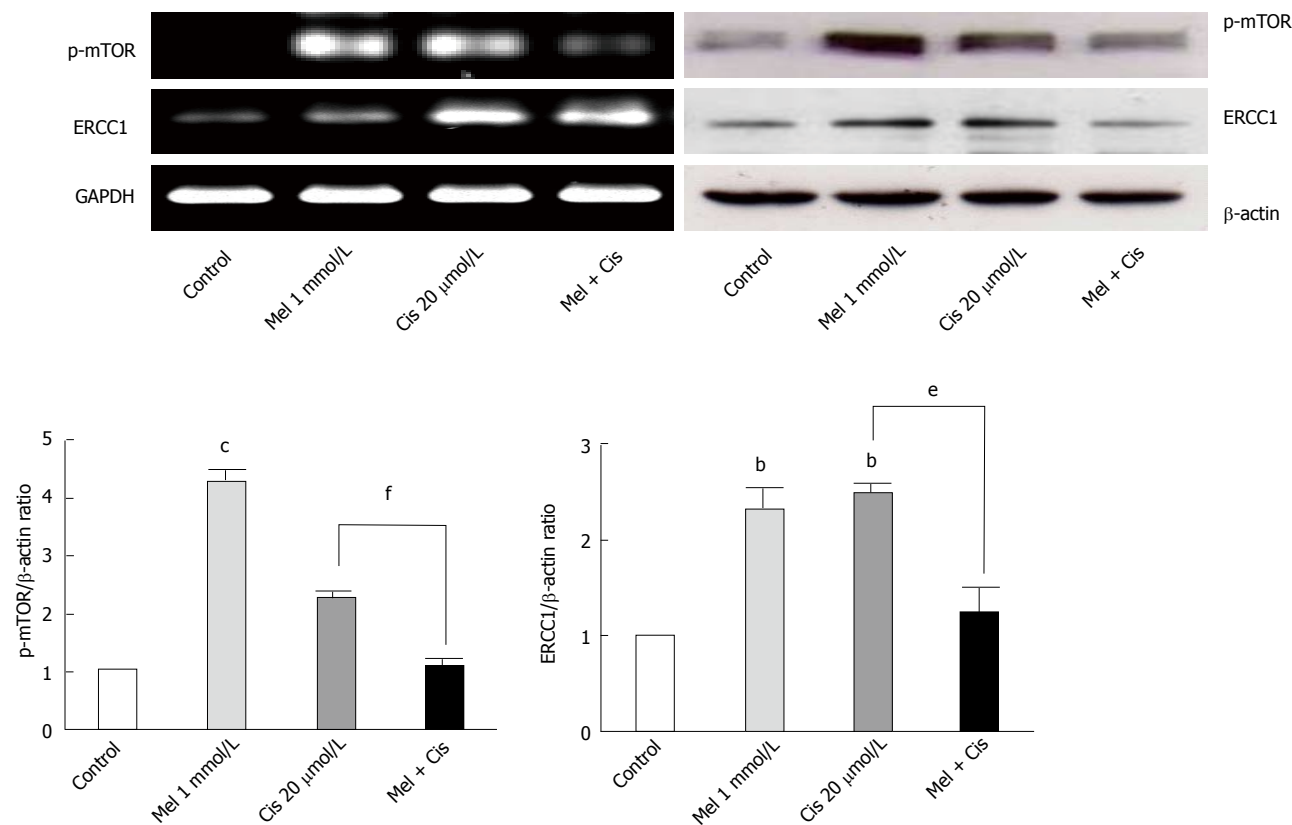


**Figure 9 Alteration of autophagy-forming proteins.** Hepatocellular carcinoma cells were treated with melatonin and/or cisplatin for 24 h. Melatonin slightly increased Beclin-1 and LC3-II, whereas cisplatin significantly decreased Beclin-1 and slightly increased LC3-II. Melatonin inhibited the cisplatin effect on Beclin-1 but increased LC3-II in the combined treatment. (<sup>a</sup> $P$  < 0.001 compared with the control group, <sup>b</sup> $P$  < 0.001 compared with the cisplatin-treated group).

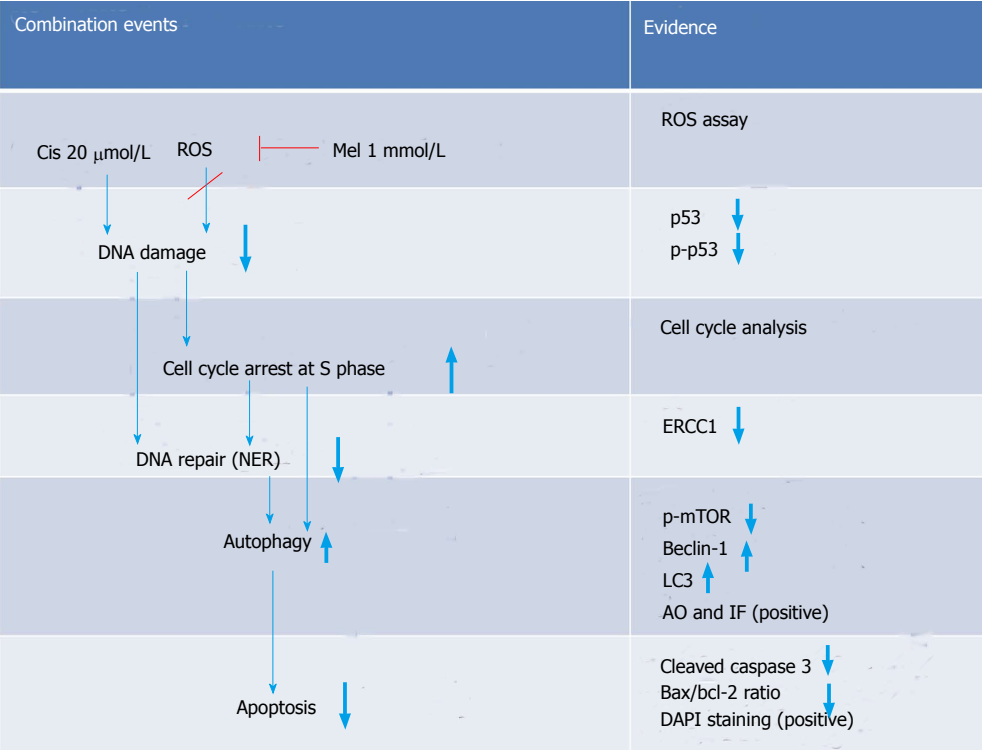
present study, we set out to determine whether melatonin could mediate a protective effect against cisplatin-induced apoptosis using HepG2 cells and attempted to identify the potential molecular pathways of melatonin action. The results demonstrated that the overall effect of this adjuvant in chemotherapy depends on a number of melatonin effects on cells. When melatonin was combined with cisplatin in the HepG2 cell line, the expression of the apoptosis mediators phosphorylated p53, cleaved caspase 3, and Bax decreased, whereas anti-apoptotic Bcl-2 increased. These biochemical results correlated well with decreases in the intracellular ROS level and the recovery of cell morphology. The results indicated the anti-

oxidative stress property of melatonin, which directly scavenges reactive oxygen species induced by cisplatin anticancer drugs<sup>[31,32]</sup>, thus reducing adverse cisplatin drug effects in hepatocytes.

In addition to the extended results from the alteration of the anti-apoptotic Bcl-2 level, we found that melatonin decreased the expression ratio of Bax/Bcl-2, which was affected by cisplatin. Thus, an apoptosis event in the combined treatment was switched to cell survival. The expression of p53 protein was also subjected to a switch by the melatonin and cisplatin combination, suggesting a direct effect of both on the cell cycle. The pro-death effect of cisplatin, which was mostly mediated by p53, indicated



**Figure 10** RT-PCR and Western blot analyses of autophagy regulators. Both melatonin and cisplatin increased p-mTOR and ERCC 1 levels in the HepG2 cells, but the combined treatment resulted in the suppression of both proteins. (<sup>b</sup>*P* < 0.01, <sup>c</sup>*P* < 0.001 compared with the control group, <sup>e</sup>*P* < 0.01, <sup>f</sup>*P* < 0.001 compared with the cisplatin-treated group). ERCC1: Excision repair cross complementary-1.



**Figure 11** Schematic overview of the major findings in the combination group.

that the cell cycle specificity of cisplatin in HepG2 cells affected G<sub>0</sub>/G<sub>1</sub> phase. In the combined treatment, the cell

cycle arrest was changed to the S and G<sub>2</sub>/M phases. Therefore, melatonin must have increased the cisplatin effect on cell cycle arrest through inhibition at the S (DNA synthesis) and M (mitosis) phases. These are considered the most anti-proliferative (oncostatic) effects of melatonin. However, the cell cycle arrest by melatonin in the treated cells could also be mediated by other cell cycle control proteins, such as the calcium/calmodulin pathway<sup>[33]</sup> and autophagy regulation pathway. Both pathways are related to the anti-proliferation of cells and pro-survival.

In our study, DNA damage may have been induced in HepG2 cells by the cisplatin genotoxic chemical and ROS by-products of cell metabolism<sup>[34]</sup>. The subsequent response reactions include the activation of a DNA damage checkpoint, which arrests cell cycle progression and leads to apoptosis<sup>[35]</sup>. We demonstrated that there was a survival switch from cisplatin-induced apoptosis to autophagy in the combination treatment with melatonin. The indicators included acridine orange staining, an immunohistochemistry assay for autophagy, and the measurement of mRNA and proteins associated with autophagy [*i.e.*, mTOR, Beclin-1, and chain3- II (LC3-II)]. Compared with cisplatin treatment alone, the combination treatment showed a high intensity of positive fluorescence staining in the lysosomal compartment of the cell, suggesting increased autophagy activity. Cisplatin acted on p53 and Bcl-2 to induce apoptosis, but in the combined treatment, Bcl-2 was decreased to an extent lower than the basal level. This could occur through reduced binding between the Bcl-2/Bcl-xL complex and Beclin-1, followed by a release of Beclin-1 to initiate autophagy formation. Thus, the combined treatment could change apoptosis to autophagy.

The basal levels of Beclin-1 and mTOR, major regulators of autophagy, were evaluated in HepG2 cells. Cisplatin treatment alone up-regulated mTOR and down-regulated Beclin-1 expression compared with the basal levels, thus decreasing autophagy and promoting the apoptosis pathway. Melatonin treatment alone up-regulated both mTOR and Beclin-1 expression compared with the basal levels, and this up-regulation by melatonin played a significant role in the survival of HepG2 cells. In the combined treatment, melatonin caused autophagy through the final formation of the autophagosome and was shown by an increased microtubule-associated protein-light LC3- II level via the up-regulation of p-mTOR and Beclin-1. This changed the apoptotic signal caused by cisplatin. Overall, melatonin attenuated cisplatin-induced HepG2 cell death by inducing an autophagy survival signal<sup>[36]</sup>.

A novel autophagy regulation mediated by melatonin was identified in this study. Both melatonin and cisplatin exhibited concentration-dependent effects on mTOR, Beclin-1, and DNA ERCC1. ERCC1 is a marker of DNA repair, whereby ERCC1 is the rate-limiting enzyme in the NER system, a pathway known to remove cisplatin lesions from DNA<sup>[37]</sup>. The analysis of protein expression in this study revealed that increases in ERCC1 from the basal levels in HepG2 cells by each

treatment were associated with an increase in mTOR expression, suggesting a tight relationship between DNA repair and autophagy. We also found that both mTOR and ERCC1 were significantly decreased by melatonin induction in the co-treatment group compared with the cisplatin-treated group. However, the only slight reduction in ERCC1 in our assay using rapamycin as an inhibitor of mTOR demonstrated that the melatonin effect on ERCC1 was not directly to the mTOR activation pathway (data not included). Therefore, melatonin reduced cisplatin-induced DNA damage, resulting in decreased activation of the DNA repair capacity and might be involved in transcriptional regulation or an epigenetic mechanism. As previously shown, p-p53 is a transcription factor for apoptotic gene expression and also plays a role in DNA repair via the subsequent up-regulation of genes in the NER pathway<sup>[38-40]</sup>. AP-1 is a transcription factor for autophagy and ERCC1 regulation in DNA damage pathways<sup>[41]</sup>. In the combined treatment, melatonin and cisplatin may encounter transcription inactivation. That is, after cisplatin treatment, DNA damage occurs, and ERCC1 is induced. An increased level and activation of mTOR induced by melatonin counter-balances the role of p-p53 in the DNA damage and repair process induced by cisplatin. This finding is the first report that melatonin can activate ERCC1 in a concentration-dependent manner.

Interestingly, significant decreases in both mTOR and ERCC1 compared with the basal levels were identified in the combined treatment, suggesting a positive response of the cells. The expression level of ERCC1 has been previously suggested to be a prognostic marker of cancers, and ERCC1 over-expression has been associated with to cisplatin resistance<sup>[42]</sup>. In our research, ERCC1 decreased compared with the cisplatin-treated group, indicating an improvement in cancer prognosis.

In conclusion, melatonin exerted an oncostatic effect on cisplatin-treated hepatocellular carcinoma cells via a counter-balance between the roles of apoptosis-related p53 and Bcl-2 and autophagy proteins. The alteration of Beclin-1, mTOR, and ERCC1 levels determined the pro-death and pro-survival effects of treatment in this cancer cell line. Therefore, during cisplatin treatment of hepatocellular carcinoma, the administration of a high dose of melatonin as an adjuvant in cancer therapy should ameliorate the adverse effects of cisplatin.

## ACKNOWLEDGMENTS

We thank the Core Instrument Facilities, Faculty of Science, Mahidol University for providing access to the laboratory instruments and facilities. Special thanks are extended to Dr. Peter Hanna for his help in the English correction of the manuscript.

## COMMENTS

### Background

Liver cancer is one of the major causes of death in humans worldwide due to

the limitation of drugs for treatment. Frequently, chemotherapy with platinum-based cisplatin is provided during the late stage of the disease. This drug causes excessive side effects and sometimes induces cancer drug resistance.

### Research frontiers

Melatonin is a hormone produced in our body to maintain several normal physiological functions, which may be altered during the course of cancer. To reduce cisplatin side effects and still maintain the drug's efficacy, we treated human hepatocellular carcinoma (HepG2) cells with cisplatin and a high concentration of melatonin. The results showed that melatonin could reduce the oxidative stress effects of cisplatin by altering the stages of cell cycle arrest and apoptosis mediators such as p53. Melatonin switched cisplatin-induced apoptosis in HepG2 cell to autophagy-induced survival via Bcl-2, Beclin-1 and mTOR. In addition, melatonin reduced cisplatin-induced DNA damage by decreasing the activation of excision repair cross complementary-1 (ERCC1) in the DNA repair system.

### Innovations and breakthroughs

Melatonin can activate DNA ERCC1 in a concentration-dependent manner. An analysis of protein expression in this study revealed that increases in ERCC1 from the basal levels in HepG2 cells by each treatment were associated with an increase in mTOR expression, suggesting a tight relationship between DNA repair and autophagy. In the combined treatment, melatonin and cisplatin may result in transcriptional inactivation between mTOR and ERCC1.

### Applications

During cisplatin treatment of hepatocellular carcinoma, the administration of melatonin as an adjuvant in cancer therapy should ameliorate the adverse cisplatin effects while maintaining the drug's efficacy.

### Terminology

ERCC1 is the rate-limiting endonuclease in the nucleotide excision repair (NER) pathway, which is the major pathway for removing cisplatin from the DNA strand. ERCC1 is a good predictive biomarker for cancer treatment with cisplatin. ERCC1-negative tumor patients were associated with a higher survival rate than ERCC1-positive tumor patients treated with adjuvant platinum-based regimens.

### Peer review

This study has a good structure and is easy to read despite many abbreviations, even for inexperienced readers in this field. It is a very important and up-to-date subject. The work is interesting, technically correct, and well written and describes an important role for melatonin as an adjuvant to cisplatin, a therapy known to cause severe toxicity in the body. The studies were well-designed, clearly presented, highly mechanistic, and demonstrated novel pathways regulated by melatonin to improve health outcomes associated with hepatic cancer and cisplatin-induced hepatotoxicity. This study will open up new research areas in this field. The authors used myriad techniques and approaches to tackle this deadly disease.

## REFERENCES

- 1 Arslan C, Ozdemir E, Dogan E, Ozisik Y, Altundag K. Secondary hematological malignancies after treatment of non-metastatic breast cancer. *J BUON* 2011; **16**: 744-750 [PMID: 22331732]
- 2 Gerets HH, Tilmant K, Gerin B, Chanteux H, Depelchin BO, Dhalluin S, Atienzar FA. Characterization of primary human hepatocytes, HepG2 cells, and HepaRG cells at the mRNA level and CYP activity in response to inducers and their predictivity for the detection of human hepatotoxins. *Cell Biol Toxicol* 2012; **28**: 69-87 [PMID: 22258563 DOI: 10.1007/s10565-011-9208-4]
- 3 Varan A, Batu A, Cila A, Soylemezoğlu F, Balci S, Akalan N, Zorlu F, Akyüz C, Kutluk T, Büyükpamukçu M. Optic glioma in children: a retrospective analysis of 101 cases. *Am J Clin Oncol* 2013; **36**: 287-292 [PMID: 22547006 DOI: 10.1097/COC.0b013e3182467efa]
- 4 Noguchi K, Yokoo H, Nakanishi K, Kakisaka T, Tsuruga Y, Kamachi H, Matsushita M, Kamiyama T. A long-term survival case of adult undifferentiated embryonal sarcoma of liver. *World J Surg Oncol* 2012; **10**: 65 [PMID: 22540346 DOI: 10.1186/1477-7819-10-65]
- 5 Jordan P, Carmo-Fonseca M. Molecular mechanisms involved in cisplatin cytotoxicity. *Cell Mol Life Sci* 2000; **57**: 1229-1235 [PMID: 11028915]
- 6 Wang D, Lippard SJ. Cellular processing of platinum anticancer drugs. *Nat Rev Drug Discov* 2005; **4**: 307-320 [PMID: 15789122 DOI: 10.1038/nrd1691]
- 7 Cassone VM. Effects of melatonin on vertebrate circadian systems. *Trends Neurosci* 1990; **13**: 457-464 [PMID: 1701579]
- 8 Shochat T, Haimov I, Lavie P. Melatonin--the key to the gate of sleep. *Ann Med* 1998; **30**: 109-114 [PMID: 9556097]
- 9 Carrillo-Vico A, Guerrero JM, Lardone PJ, Reiter RJ. A review of the multiple actions of melatonin on the immune system. *Endocrine* 2005; **27**: 189-200 [PMID: 16217132]
- 10 Cheung RT. The utility of melatonin in reducing cerebral damage resulting from ischemia and reperfusion. *J Pineal Res* 2003; **34**: 153-160 [PMID: 12614473 DOI: 10.1034/j.1600-079X.2003.00034.x]
- 11 Park KH, Kang JW, Lee EM, Kim JS, Rhee YH, Kim M, Jeong SJ, Park YG, Kim SH. Melatonin promotes osteoblastic differentiation through the BMP/ERK/Wnt signaling pathways. *J Pineal Res* 2011; **51**: 187-194 [PMID: 21470302 DOI: 10.1111/j.1600-079X.2011.00875.x]
- 12 Tekbas OF, Ogur R, Korkmaz A, Kilic A, Reiter RJ. Melatonin as an antibiotic: new insights into the actions of this ubiquitous molecule. *J Pineal Res* 2008; **44**: 222-226 [PMID: 18289175 DOI: 10.1111/j.1600-079X.2007.00516.x]
- 13 Korkmaz A, Reiter RJ, Topal T, Manchester LC, Oter S, Tan DX. Melatonin: an established antioxidant worthy of use in clinical trials. *Mol Med* 2009; **15**: 43-50 [PMID: 19011689 DOI: 10.2119/molmed.2008.00117]
- 14 Sánchez-Hidalgo M, Lee M, de la Lastra CA, Guerrero JM, Packham G. Melatonin inhibits cell proliferation and induces caspase activation and apoptosis in human malignant lymphoid cell lines. *J Pineal Res* 2012; **53**: 366-373 [PMID: 22582944 DOI: 10.1111/j.1600-079X.2012.01006.x]
- 15 Shiu SY, Leung WY, Tam CW, Liu VW, Yao KM. Melatonin MT1 receptor-induced transcriptional up-regulation of p27(Kip1) in prostate cancer antiproliferation is mediated via inhibition of constitutively active nuclear factor kappa B (NF-κB): potential implications on prostate cancer chemoprevention and therapy. *J Pineal Res* 2013; **54**: 69-79 [PMID: 22856547 DOI: 10.1111/j.1600-079X.2012.01026.x]
- 16 Cabrera J, Negrín G, Estévez F, Loro J, Reiter RJ, Quintana J. Melatonin decreases cell proliferation and induces melanogenesis in human melanoma SK-MEL-1 cells. *J Pineal Res* 2010; **49**: 45-54 [PMID: 20459460 DOI: 10.1111/j.1600-079X.2010.00765.x]
- 17 Martín-Renedo J, Mauriz JL, Jorquera F, Ruiz-Andrés O, González P, González-Gallego J. Melatonin induces cell cycle arrest and apoptosis in hepatocarcinoma HepG2 cell line. *J Pineal Res* 2008; **45**: 532-540 [PMID: 19012662 DOI: 10.1111/j.1600-079X.2008.00641.x]
- 18 Jou MJ, Peng TI, Yu PZ, Jou SB, Reiter RJ, Chen JY, Wu HY, Chen CC, Hsu LF. Melatonin protects against common deletion of mitochondrial DNA-augmented mitochondrial oxidative stress and apoptosis. *J Pineal Res* 2007; **43**: 389-403 [PMID: 17910608 DOI: 10.1111/j.1600-079X.2007.00490.x]
- 19 Liu L, Xu Y, Reiter RJ. Melatonin inhibits the proliferation of human osteosarcoma cell line MG-63. *Bone* 2013; **55**: 432-438 [PMID: 23470834 DOI: 10.1016/j.bone.2013.02.021]
- 20 Sanchez-Barcelo EJ, Mediavilla MD, Alonso-Gonzalez C, Reiter RJ. Melatonin uses in oncology: breast cancer prevention and reduction of the side effects of chemotherapy and radiation. *Expert Opin Investig Drugs* 2012; **21**: 819-831 [PMID: 22500582 DOI: 10.1517/13543784.2012.681045]
- 21 Wang YM, Jin BZ, Ai F, Duan CH, Lu YZ, Dong TF, Fu QL. The efficacy and safety of melatonin in concurrent chemotherapy or radiotherapy for solid tumors: a meta-analysis of randomized controlled trials. *Cancer Chemother Pharmacol* 2012; **69**: 1213-1220 [PMID: 22271210 DOI: 10.1007/s00280-012-1828-8]
- 22 Seely D, Wu P, Fritz H, Kennedy DA, Tsui T, Seely AJ, Mills E. Melatonin as adjuvant cancer care with and without chemotherapy: a systematic review and meta-analysis of



- randomized trials. *Integr Cancer Ther* 2012; **11**: 293-303 [PMID: 22019490 DOI: 10.1177/1534735411425484]
- 23 **Kroemer G**, Mariño G, Levine B. Autophagy and the integrated stress response. *Mol Cell* 2010; **40**: 280-293 [PMID: 20965422 DOI: 10.1016/j.molcel.2010.09.023]
- 24 **Hubbard VM**, Valdor R, Macian F, Cuervo AM. Selective autophagy in the maintenance of cellular homeostasis in aging organisms. *Biogerontology* 2012; **13**: 21-35 [PMID: 21461872 DOI: 10.1007/s10522-011-9331-x]
- 25 **Jung CH**, Ro SH, Cao J, Otto NM, Kim DH. mTOR regulation of autophagy. *FEBS Lett* 2010; **584**: 1287-1295 [PMID: 20083114 DOI: 10.1016/j.febslet.2010.01.017]
- 26 **Ramírez-Valle F**, Braunstein S, Zavadil J, Formenti SC, Schneider RJ. eIF4G links nutrient sensing by mTOR to cell proliferation and inhibition of autophagy. *J Cell Biol* 2008; **181**: 293-307 [PMID: 18426977 DOI: 10.1083/jcb.200710215]
- 27 **Pattingre S**, Espert L, Biard-Piechaczyk M, Codogno P. Regulation of macroautophagy by mTOR and Beclin 1 complexes. *Biochimie* 2008; **90**: 313-323 [PMID: 17928127 DOI: 10.1016/j.biochi.2007.08.014]
- 28 **Lorin S**, Pierron G, Ryan KM, Codogno P, Djavaheri-Mergny M. Evidence for the interplay between JNK and p53-DRAM signalling pathways in the regulation of autophagy. *Autophagy* 2010; **6**: 153-154 [PMID: 19949306 DOI: 10.4161/auto.6.1.10537]
- 29 **Hoeijmakers JH**. Genome maintenance mechanisms are critical for preventing cancer as well as other aging-associated diseases. *Mech Ageing Dev* 2007; **128**: 460-462 [PMID: 17588642 DOI: 10.1016/j.mad.2007.05.002]
- 30 **Friedberg EC**. How nucleotide excision repair protects against cancer. *Nat Rev Cancer* 2001; **1**: 22-33 [PMID: 11900249 DOI: 10.1038/35094000]
- 31 **Mayo JC**, Sainz RM, Antolí I, Herrera F, Martín V, Rodríguez C. Melatonin regulation of antioxidant enzyme gene expression. *Cell Mol Life Sci* 2002; **59**: 1706-1713 [PMID: 12475181 DOI: 10.1007/PL00012498]
- 32 **Rodríguez C**, Mayo JC, Sainz RM, Antolí I, Herrera F, Martín V, Reiter RJ. Regulation of antioxidant enzymes: a significant role for melatonin. *J Pineal Res* 2004; **36**: 1-9 [PMID: 14675124 DOI: 10.1046/j.1600-079X.2003.00092.x]
- 33 **Blask DE**, Sauer LA, Dauchy RT. Melatonin as a chronobiotic/anticancer agent: cellular, biochemical, and molecular mechanisms of action and their implications for circadian-based cancer therapy. *Curr Top Med Chem* 2002; **2**: 113-132 [PMID: 11899096 DOI: 10.2174/1568026023394407]
- 34 **Rodríguez-Rocha H**, García-García A, Panayiotidis MI, Franco R. DNA damage and autophagy. *Mutat Res* 2011; **711**: 158-166 [PMID: 21419786 DOI: 10.1016/j.mrfmmm.2011.03.007]
- 35 **Sancar A**, Lindsey-Boltz LA, Unsal-Kaçmaz K, Linn S. Molecular mechanisms of mammalian DNA repair and the DNA damage checkpoints. *Annu Rev Biochem* 2004; **73**: 39-85 [PMID: 15189136 DOI: 10.1146/annurev.biochem.73.011303.073723]
- 36 **Ding WX**, Li M, Chen X, Ni HM, Lin CW, Gao W, Lu B, Stolz DB, Clemens DL, Yin XM. Autophagy reduces acute ethanol-induced hepatotoxicity and steatosis in mice. *Gastroenterology* 2010; **139**: 1740-1752 [PMID: 20659474 DOI: 10.1053/j.gastro.2010.07.041]
- 37 **Bowden NA**, Ashton KA, Avery-Kiejda KA, Zhang XD, Hersey P, Scott RJ. Nucleotide excision repair gene expression after Cisplatin treatment in melanoma. *Cancer Res* 2010; **70**: 7918-7926 [PMID: 20807809 DOI: 10.1158/0008-5472.CAN-10-0161]
- 38 **Slee EA**, O'Connor DJ, Lu X. To die or not to die: how does p53 decide? *Oncogene* 2004; **23**: 2809-2818 [PMID: 15077144 DOI: 10.1038/sj.onc.1207516]
- 39 **Sengupta S**, Harris CC. p53: traffic cop at the crossroads of DNA repair and recombination. *Nat Rev Mol Cell Biol* 2005; **6**: 44-55 [PMID: 15688066 DOI: 10.1038/nrm1546]
- 40 **Seo YR**, Jung HJ. The potential roles of p53 tumor suppressor in nucleotide excision repair (NER) and base excision repair (BER). *Exp Mol Med* 2004; **36**: 505-509 [PMID: 15665582 DOI: 10.1038/emmm.2004.64]
- 41 **Andrieux LO**, Fautrel A, Bessard A, Guillouzo A, Baffet G, Langouët S. GATA-1 is essential in EGF-mediated induction of nucleotide excision repair activity and ERCC1 expression through ERK2 in human hepatoma cells. *Cancer Res* 2007; **67**: 2114-2123 [PMID: 17332341 DOI: 10.1158/0008-5472.CAN-06-3821]
- 42 **Steffensen KD**, Waldstrøm M, Jakobsen A. The relationship of platinum resistance and ERCC1 protein expression in epithelial ovarian cancer. *Int J Gynecol Cancer* 2009; **19**: 820-825 [PMID: 19574766 DOI: 10.1111/IGC.0b013e3181a12e09]

**P- Reviewers:** Guglielmo R, Sanchez-Barcelo EJ, Witt-Enderby PA  
**S- Editor:** Ma YJ **L- Editor:** A **E- Editor:** Wu HL



## Murine model to study brain, behavior and immunity during hepatic encephalopathy

Lindisley Ferreira Gomides, Pedro Elias Marques, Bruno Engler Faleiros, Rafaela Vaz Pereira, Sylvia Stella Amaral, Thais Reis Lage, Gustavo Henrique Souza Resende, Patricia Alves Maia Guidine, Giselle Foureaux, Fabíola Mara Ribeiro, Fabiana Paiva Martins, Marco Antônio Peliky Fontes, Anderson José Ferreira, Remo Castro Russo, Mauro Martins Teixeira, Márcio Flávio Moraes, Antonio Lúcio Teixeira, Gustavo Batista Menezes

Lindisley Ferreira Gomides, Pedro Elias Marques, Rafaela Vaz Pereira, Sylvia Stella Amaral, Thais Reis Lage, Gustavo Batista Menezes, Laboratório de Imunobiofotônica, Department of Morphology, ICB, UFMG, Belo Horizonte 31270-901, Brazil  
Bruno Engler Faleiros, Fabiana Paiva Martins, Antonio Lúcio Teixeira, School of Medicine, UFMG, Belo Horizonte 31270-901, Brazil

Gustavo Henrique Souza Resende, Patricia Alves Maia Guidine, Marco Antônio Peliky Fontes, Remo Castro Russo, Márcio Flávio Moraes, Department of Physiology, ICB, UFMG, Belo Horizonte 31270-901, Brazil

Giselle Foureaux, Anderson José Ferreira, Department of Morphology, UFMG, Belo Horizonte 31270-901, Brazil

Fabíola Mara Ribeiro, Mauro Martins Teixeira, Department of Biochemistry and Immunology, UFMG, Belo Horizonte 31270-901, Brazil

**Author contributions:** Gomides LF, Marques PE, Faleiros BE, Pereira RV, Amaral SS, Lage TR, Resende GHS, Guidine PAM, Foureaux G, Ribeiro FM and Martins FP performed the majority of experiments and analyzed data; Fontes MAP, Ferreira AJ, Russo RC, Teixeira MM, Moraes MF and Teixeira AL performed experiments and interpreted results; Menezes GB designed the study and wrote the manuscript; Gomides LF, Marques PE and Menezes GB revised the manuscript; all authors approved the final version to be published.

**Correspondence to:** Gustavo Batista Menezes, PhD, Laboratório de Imunobiofotônica, Department of Morphology, ICB, UFMG, Av. Antonio Carlos, 6627 - Pampulha, Belo Horizonte 31270-901, Brazil. [menezesgb@ufmg.br](mailto:menezesgb@ufmg.br)

Telephone: +55-31-34093015 Fax: +55-31-34093015

Received: November 21, 2013 Revised: January 17, 2014

Accepted: February 16, 2014

Published online: April 27, 2014

**METHODS:** Mice received two consecutive intraperitoneal injections of thioacetamide (TAA) at low dosage (300 mg/kg). Liver injury was assessed by serum transaminase levels (ALT) and liver histology (hematoxylin and eosin). Neutrophil infiltration was estimated by confocal liver intravital microscopy. Coagulopathy was evaluated using prolonged prothrombin and partial thromboplastin time. Hemodynamic parameters were measured through tail cuff. Ammonia levels were quantified in serum and brain samples. Electroencephalography (EEG) and psychomotor activity score were performed to show brain function. Brain edema was evaluated using magnetic resonance imaging.

**RESULTS:** Mice submitted to the TAA regime developed massive liver injury, as shown by elevation of serum ALT levels and a high degree of liver necrosis. An intense hepatic neutrophil accumulation occurred in response to TAA-induced liver injury. This led to mice mortality and weight loss, which was associated with severe coagulopathy. Furthermore, TAA-treated mice presented with increased serum and cerebral levels of ammonia, in parallel with alterations in EEG spectrum and discrete brain edema, as shown by magnetic resonance imaging. In agreement with this, neuropsychomotor abnormalities ensued 36 h after TAA, fulfilling several HE features observed in humans. In this context of liver injury and neurological dysfunction, we observed lung inflammation and alterations in blood pressure and heart rate that were indicative of multiple organ dysfunction syndrome.

**CONCLUSION:** In summary, we describe a new murine model of hepatic encephalopathy comprising multiple features of the disease in humans, which may provide new insights for treatment.

© 2014 Baishideng Publishing Group Co., Limited. All rights reserved.

### Abstract

**AIM:** To propose an alternative model of hepatic encephalopathy (HE) in mice, resembling the human features of the disease.

reserved.

**Key words:** Hepatic encephalopathy; Liver injury; Thioacetamide; Neurological dysfunction; Neuropsychomotor abnormalities; Intracranial hypertension; Cerebral herniation

**Core tip:** The study of hepatic encephalopathy is crucial for development of new therapies but has been dampened by the absence of murine models resembling the disease in patients. We showed that sequential thioacetamide injections cause extensive liver injury in mice, leading to increased ammonia levels, electroencephalography alterations and brain edema. In line with this, mice presented with poor psychomotor activity and survival rate. Liver injury and brain function impairment by thioacetamide resulted in systemic alterations such as coagulopathy, hemodynamic instability and lung inflammation, consistent with multiple organ failure. Therefore, this alternative model may provide tools for new therapeutic insights for hepatic encephalopathy.

Gomides LF, Marques PE, Faleiros BE, Pereira RV, Amaral SS, Lage TR, Resende GHS, Guidine PAM, Foureaux G, Ribeiro FM, Martins FP, Fontes MAP, Ferreira AJ, Russo RC, Teixeira MM, Moraes MF, Teixeira AL, Menezes GB. Murine model to study brain, behavior and immunity during hepatic encephalopathy. *World J Hepatol* 2014; 6(4): 243-250 Available from: URL: <http://www.wjgnet.com/1948-5182/full/v6/i4/243.htm> DOI: <http://dx.doi.org/10.4254/wjh.v6.i4.243>

## INTRODUCTION

Acute liver failure (ALF) is a rare but severe clinical syndrome. It is typically characterized by jaundice, coagulopathy and encephalopathy resulting from sudden hepatic dysfunction without preexisting liver disease<sup>[1]</sup>. Drug-induced liver injury (DILI) is the main cause of ALF in the United States and Europe<sup>[2]</sup>, whereas in developing countries viral hepatitis is the most important etiology. Although liver injuries may result from a wide range of situations, drug overdose may become the most important etiology of ALF worldwide in a few years<sup>[2]</sup> as life expectancy increases and the medicalization of the older population tends to increase<sup>[3]</sup>. Moreover, the worldwide cause of ALF tends towards DILI due to increasing public health measures (*e.g.*, vaccination)<sup>[1]</sup>, making it an emergent widespread problem. ALF has a high mortality rate of approximately 30% due to multiple organ dysfunction, hepatic encephalopathy and sepsis. Unfortunately, therapeutic options are very limited since liver transplantation is the only definitive therapy available. Besides that, patients are kept under clinical management and supportive care until spontaneous liver recovery<sup>[1,4]</sup>.

Hepatic encephalopathy (HE) is one of the major complications in ALF because of rapid brain edema, intracranial hypertension and cerebral herniation<sup>[5]</sup>. Clinically, HE is a neuropsychiatric syndrome that comprises

a wide range of signs and symptoms from subtle altered mental status to stupor and coma<sup>[6]</sup>. The severity of HE has prognostic implications since patient outcome worsens as HE progresses. There is a chance of 65%-70% of spontaneous liver recovery in mild HE and less than 20% in severe HE<sup>[7]</sup>. Moreover, patients with ALF who manifest increased intracranial pressure during the course of illness are more likely to develop sepsis<sup>[8]</sup>. Hence, understanding HE pathophysiology is crucial for development of new and specific therapies that would slow down its progression and increase chances of better outcomes.

In this sense, a murine model that reproduces features of HE in humans would be key to improve our understanding in HE pathophysiology and may also be useful for drug testing and development. Here, we propose an alternative murine model of HE using sequential systemic thioacetamide (TAA) injections in a lower dosage instead of a single higher dose administration.

## MATERIALS AND METHODS

### TAA induced liver failure and hepatic encephalopathy

Female C57BL/6 mice and Lysm-eGFP (eGFP-expressing neutrophils) had free access to food and water. TAA-induced liver injury protocol was based on two consecutive days of treatment with thioacetamide (300 mg/kg) administered intraperitoneally. Treated groups received the first dose in time zero and an additional dose after 24 h. Controls received vehicle following the same chronogram. Mice were sacrificed after 24 or 48 h and liver, lung, blood and brain samples were collected for further analysis. All mice received glucose replacement (12/12 h; 5%; *s.c.*) and glycemia was monitored (12/12 h) with commercially available reactive strips and a glucometer (Accu-Chek, Performa). Body temperature was maintained at 37 °C by a thermal pad. Psychomotor activity was graded following an adapted clinical score, in which 0 = normal behavior; 1 = mild lethargy; 2 = decreased motor activity, poor gesture control, diminished pain perception; 3 = Severe ataxia, no spontaneous righting reflex; 4 = no righting reflex, no reaction to pain stimuli; and 5 = death<sup>[9]</sup>. All procedures were approved by Animal Care and Use Committee in UFMG (CEBIO n°051/2011). The investigation conformed to the standards of Guide for the Care and Use of Laboratory Animals (National Institutes of Health publication 85-23, 1996 revision). In a separate set of experiments, the liver was imaged using confocal intravital microscopy as described previously<sup>[10]</sup>. Lysm-eGFP mice received propidium iodide (200 µL of a 100 µmol/L stock solution; *i.v.*) prior to the surgical procedure in order to visualize necrotic cells.

### Serum and cerebral ammonia determination

Immediately after decapitation, the brain was rapidly removed from the cranial cavity and fast-frozen in liquid nitrogen. Subsequently, brain samples were macerated using a pestle in perchloric acid (ice-cold; 1mol/L) and centrifuged at 10000 *g* for 10 min at 4 °C. The supernatant was collected for immediate dosage. Also, blood

samples were centrifuged for 7 min (7000 *g*) and plasma was collected. Ammonia concentration was estimated using Ammonia Assay kit (Sigma, United States) following manufacturer instructions.

### **Alanine aminotransferase**

The alanine aminotransferase enzyme is present in the cytoplasm of hepatocytes and is highly specific for the liver. The measurement of serum alanine aminotransferase (ALT) is a gold-standard marker of liver damage. To determine the activity of ALT, blood samples were centrifuged and the serum was collected and dosed using a kinetic kit (Bioclin, Brazil).

### **Hemodynamic measurements using tail cuff method**

Mean arterial pressure (MAP) and heart rate (HR) were evaluated by a volume pressure recording sensor and an occlusion tail-cuff, which measures mice blood pressure and HR noninvasively (Kent Scientific Corporation, Torrington, CT, United States)<sup>[11]</sup>. Mice were acclimated to the restraint and tail cuff inflation for two days before the beginning of the experiments. The restraint platform was maintained at 36–38 °C. In each session, mice were placed in an acrylic box restraint, and the tail was inserted into a compression cuff that measured the blood pressure 10 times. Following the measurement cycle, the average of these values was considered for each mouse. MAP and HR were evaluated at 0, 24 and 48 h after TAA administration.

### **Procedures for electroencephalography recording**

**Surgery procedures:** Mice ( $n = 8$ ) were anesthetized using a mixture of ketamine (100 mg/kg) and xylazine (10 mg/kg). Prophylactic treatment with antibiotics (enrofloxacin; 10 mg/kg; *s.c.*) was done in order to prevent post-surgical infections. The animals were submitted to surgery for electroencephalography (EEG) electrode implantation in the right and left parietal cortices. The electrodes for superficial EEG recordings were made with surgical screws (Fine Science Tools; model 19010-00; Foster City, CA, United States) previously soldered to Teflon-coated stainless-steel wires (A&M Systems; model 7916; Carlsborg, WA, United States) and introduced bilaterally in the parietal bones. A reference electrode, also made with surgical screws, was inserted in the nasal bone. All the electrodes were soldered to a common pin connector and anchored to the cranium with dental acrylic. Following surgery, animals were allowed to recover for at least 4 days before EEG recordings.

**Experimental protocol:** Mice were injected with thioacetamide in the same regime ( $n = 5$ ) or saline ( $n = 3$ ). Each mouse was recorded in three consecutive days, namely: day 1, before drug injection; days 2 and 3, after first and second drug injections, respectively. Mice were recorded for a period of 10 min each day. Bioelectrical activity was recorded with a video-EEG recording system (8:00–11:00 am). The EEG signal from both parietal cortices was amplified (1000 × gain) and filtered (1 Hz High

pass, 500 Hz Low pass) by a signal conditioner (Aisha4 - Kananda® Ltda). Data were sampled at 1 kHz (12 bit DI-148U A/D converter - DATAQ® Instruments) and recorded in a computer hard disk for offline analyses. Spectral analysis and 3D rendering of EEG spectrum were done using MatLab® scripts.

### **Magnetic resonance imaging: Acquisition and analysis**

MR image experiments were acquired using 4.7T NMR system (Oxford Systems) controlled by a UNITY Inova-200 imaging console (Varian). The imaging protocol consisted of coronal T2-weighted (TR = 3000 ms, TE = 50 ms) spin echo multislice scans, 16 contiguous 1 mm thick slices. Mice ( $n = 12$ ) were anesthetized with halothane (4% induction, 1.5% maintenance) and oxygen (1.5 l/min) delivered by a facemask in a head holder to minimize artifact movements. Animals anesthetized for the duration of an imaging experiment (50 min) recovered with no apparent difficulty and could be used for subsequent imaging studies. Each mouse was imaged in three consecutive days, namely: day 1, before drug injection; days 2 and 3, after first and second drug injections, respectively. Brain masks, based on the anatomical scans, were done using a tablet driver (Bamboo Tablet Driver, V5.2.5 WIN, WACOM Technology Corporation, United States) and MeVisLab software (MeVis Medical Solutions AG, Fraunhofer). Additionally, densitometry analysis was done using MatLab® scripts and repeated measures. ANOVA was used to compare densitometry values on different days.

### **Statistical analysis**

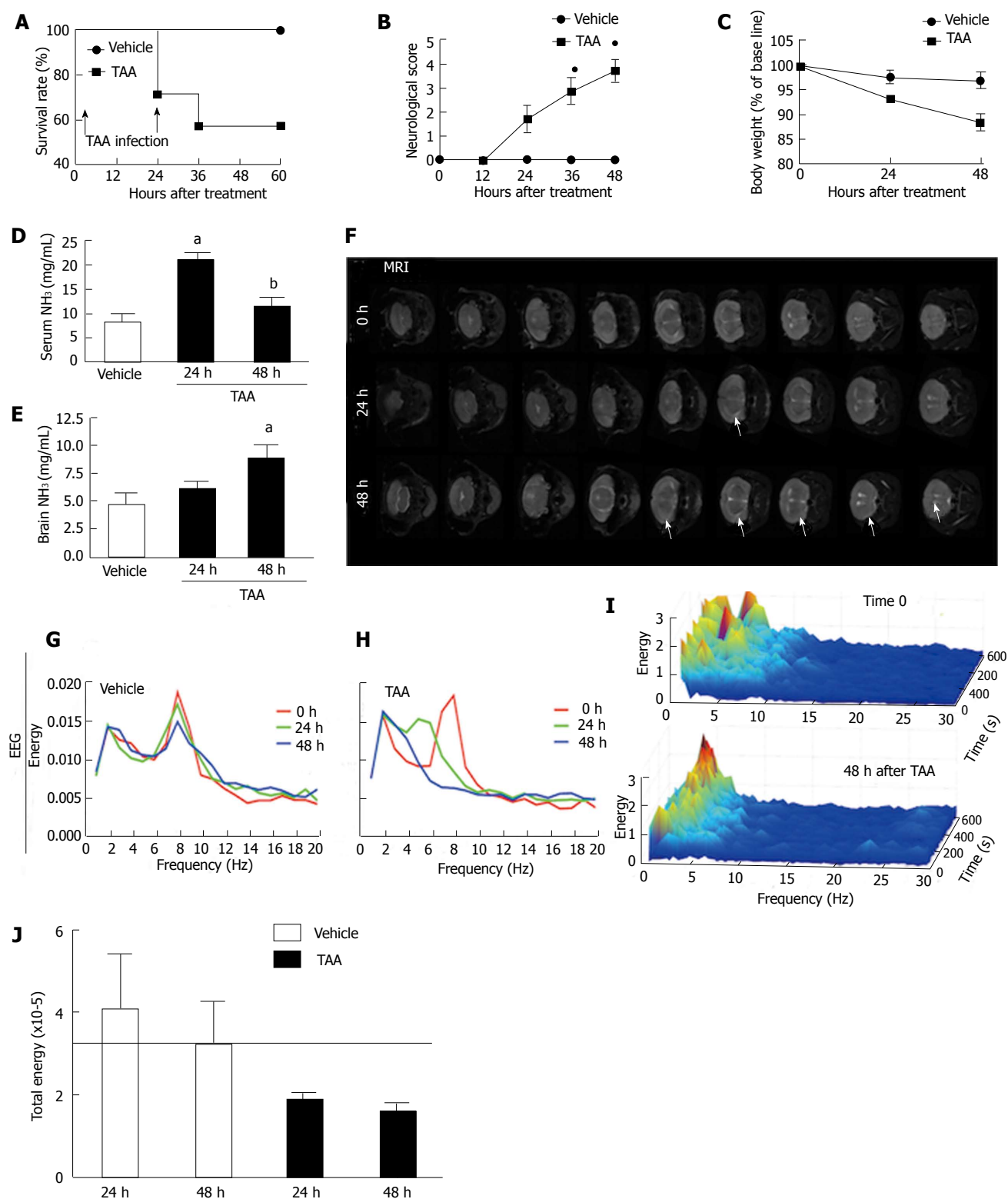
Statistical analyzes were performed using one-way ANOVA (Tukey's post test) and Student's *t* test. *P* values less than 0.05 were considered statistically significant. All data are presented as mean ± SE.

## **RESULTS**

### **Repeated TAA injections caused neuropsychomotor changes, brain edema and hyperammonemia, with EEG spectrum suggestive of metabolic encephalopathy**

As shown in Figure 1A, around 30% of mice treated with a single dose of TAA died after 24 h and more than 40% succumbed due to a second TAA administration. Also, a progressive increase in neurological score (reflecting a decreased neuropsychomotor activity) was observed (Figure 1B) and, probably due to such reduced mobility, TAA-treated mice presented with a significant weight loss in comparison to controls throughout the experiment (Figure 1C). In addition, TAA treatment caused serum hyperammonemia after 24 h (Figure 1D), which was also detected in the brain in later timepoints (48 h; Figure 1E). Taking into account the edematogenic effects of cerebral ammonia accumulation, we imaged mice brains using magnetic resonance (MR) to investigate potential morphological alterations, including suggestive areas of fluid accumulation. MR revealed a discrete but diffuse brain edema in TAA-treated mice, which was not observed in





**Figure 1** Thioacetamide treatment triggered neuropsychomotor changes, diffuse brain edema and hyperammonemia, with electroencephalography spectrum compatible with of encephalopathy. **A**: Survival rate following repeated TAA injections (arrows); **B**: Neurological score was assessed through all experimental procedure. Neuropsychomotor deficit increases as higher is the score average, with 1 = normal and 5 = death; **C**: Mice treated with TAA also presented with significant weight loss in comparison to controls; **D**, **E**: Serum ammonemia was detected following 24 h of TAA injection, while brain ammonia concentration increased gradually, reaching significant higher values after 48 h (**E**); **F**: In agreement, MRI from TAA-treated mice brains showed discrete, but diffuse edema as pointed by arrow heads. **G**, **H**: EEG analysis revealed that while controls had coincident EEG records during the experimental protocol (**G**), brain waves spectrum of TAA-treated mice (**H**) was compatible with metabolic encephalopathy; **I**: 3D rendering of 60 minutes EEG record (Z axis) plotted comparing energy (in Y axis) with frequency (X axis). Note the increase in higher frequencies waves (theta and alpha; 4-8 and 8-13 Hz, respectively) with a concomitant increase of lower frequency ones (mainly delta; up to 4 Hz). Best case results were depicted here;  $N = 8$  for each group; **J**: Total EEG energy was also reduced in TAA-treated group.  $\square$  indicates statistical significance in comparison to controls and bin comparison to 24 h group.  $P < 0.05$ , analysis of variance (Tukey's post test).  $N \geq 5$  for each group. TAA: Thioacetamide; EEG: Electroencephalography.

controls (Figure 1F). Increased fluid accumulation was more evident following 48 h of TAA treatment; however, such a feature was not prominent. In fact, no significant differences were observed in brain densitometry during analysis of MRI images (data not shown), suggesting that a mild brain edema was occurring in this model. To further dissect the neurological effects of TAA poisoning, we submitted mice to daily EEG registration throughout the experimental protocol. Analysis of the EEG spectrum revealed that while untreated mice had coincident EEG records during all experimental protocol (Figure 1G), TAA administration caused a progressive decrease in higher frequencies waves (*theta* and *alpha*; 4-8 and 8-13 Hz, respectively) with a concomitant increase of lower frequency ones (mainly *delta*; up to 4 Hz; Figure 1H-I). Such an EEG profile, with concentration of energy mainly in *delta* waves region and significant reduction in total energy (Figure 1J), confirmed that repeated TAA administration led to a diffuse brain lesion and metabolic encephalopathy.

#### **Severe liver necrosis and inflammation triggered metabolic encephalopathy, coagulopathy and remote lung injury**

It is well established that impaired liver function caused by extensive hepatocyte death leads to a general deficiency in metabolism, including ammonia depuration and synthesis of coagulation cascade factors<sup>[3]</sup>. Liver intravital microscopy revealed a marked increase in necrotic cells (stained by propidium iodide; in red) following TAA exposure (Figure 2A), which was also confirmed by histology analysis (Figure 2B). Also, we observed an exuberant neutrophil accumulation in liver necrotic areas, which increased throughout TAA intoxication process (Figure 2A; eGFP-expressing cells). Macroscopically, livers from TAA treated mice displayed extensive areas of necrosis (Figure 2C), which became more obvious after repeated TAA administration (48 h). Significantly higher serum levels of alanine aminotransferase (ALT) also indicated massive liver injury, which was sustained during the whole experimental period (Figure 2D). In fact, a complete lack of hemostatic function also confirmed hepatotoxicity and organ failure, suggesting that synthesis of liver-derived coagulation factors was seriously impaired. While controls had normal hemostatic parameters (MAP and HR), TAA-treated mice had a prolonged (undetermined) prothrombin and partial thromboplastin time (Figure 2E, F). Moreover, while control mice had normal hemodynamic parameters, the TAA-treated group had a significant drop in MAP (approximately 35%) with concomitant tachycardia, suggesting that mice might be evolving to a hemodynamic shock (Figure 2G, H). In this direction, we hypothesized that in our model TAA might also cause multiple organ failure and remote injury.

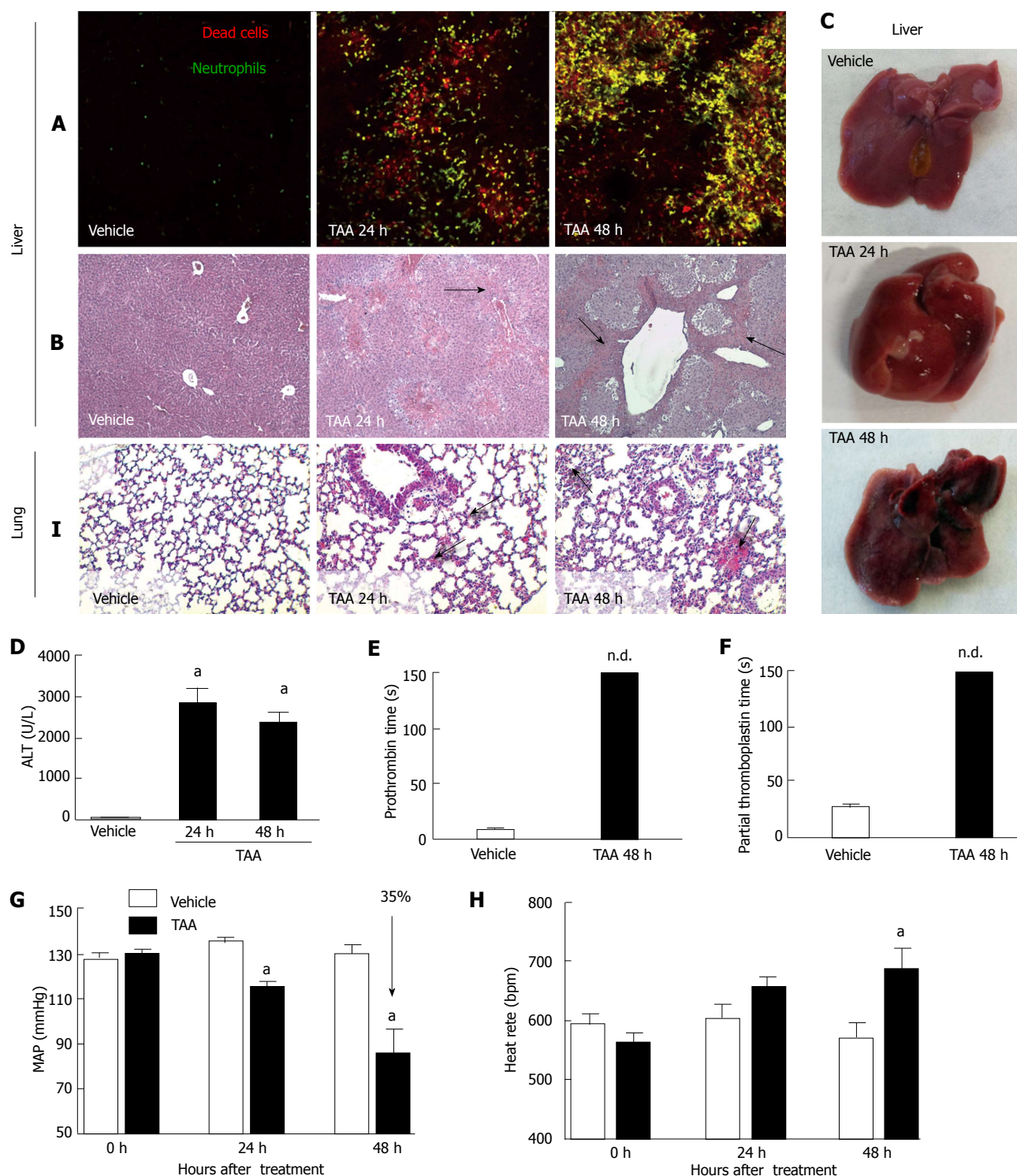
We have previously shown that necrosis-derived products may reach systemic circulation and trigger remote inflammatory responses in organs including the lungs<sup>[12]</sup>. Here, we evaluated the potential of TAA in induction of

lung inflammation. Histopathological analysis showed that TAA-induced liver injury also caused pulmonary injury. After 24 h, lungs from mice had increased cellularity in lung parenchyma, alveolar edema and hemorrhage in comparison to controls (Figure 1I; arrows). Those observations were found to be more pronounced after 48 h, showing increased tissue damage, alveolar hemorrhage and lung architecture disruption, suggesting that lethality induced by TAA can also be due to exacerbation of lung inflammatory response in this model.

## **DISCUSSION**

The hepatotoxic ability of TAA is well described in the literature and this drug has been extensively used in rat models of ALF and HE in sequential repeated dose administration<sup>[9,13-16]</sup>. Once in circulation, TAA is absorbed and bioactivated by hepatocytes. This metabolite will finally modify aminolipids and proteins, causing cell damage and death<sup>[17]</sup>. In mice, acute TAA poisoning causes centrilobular necrosis and an increase in plasma transaminases and bilirubin. We have shown that following two daily TAA injections, mice developed a massive and progressive liver damage and failure, with hyperammonemia in serum and brain, with discrete signals of cerebral edema.

Hyperammonemia is a hallmark of HE pathophysiology. In patients with ALF, the arterial ammonia level is directly related to severity of HE and development of intracranial hypertension<sup>[18]</sup>. Also, persistent hyperammonemia seems to be more important than a transient increase in the ammonia level regarding the occurrence of intracranial hypertension<sup>[19]</sup>. Most studies in mice used a single dose of a hepatotoxic drug which caused a briefer period of illness<sup>[20-22]</sup>. To supersede this, we developed a novel protocol using a lower TAA dose (300 mg/kg) and repeated administration (2 daily doses), trying to mimic a more realistic scenario closer to severe HE. We found that under these conditions, mice progressively presented with neuropsychomotor deficiencies (as assessed by neurological score)<sup>[23]</sup>, which was accompanied by persistent liver injury and failure. Interestingly, serum ammonia concentration peaked after the first TAA administration, decreasing at 48 h. However, cerebral ammonia gradually increased throughout the experimental protocol, reaching significantly higher levels 48 h after TAA, suggesting that probably excessive serum levels of ammonia might be transferred to the brain due to deficient liver ammonia clearance. The mechanisms responsible for ammonia-mediated encephalopathy and brain edema are still under debate; however, it is accepted that increased blood-derived ammonia intensifies glutamine synthesis via amidation of glutamate, generating a hyperosmotic environment within brain cells (mainly astrocytes)<sup>[24]</sup>. Consequently, cerebral liquid accumulation leads to intracranial hypertension, herniation and coma. In agreement with this, magnetic resonance imaging from mice treated with TAA revealed a discrete, but crescent-shaped and diffuse



**Figure 2** Thioacetamide caused severe liver necrosis and inflammation, which may explain mice metabolic encephalopathy, coagulopathy and remote lung injury. **A**: Liver intravital microscopy showing crescent number of necrotic cells (in red, propidium iodide) with concomitant neutrophil infiltration (in green, Lysm-eGFP mice); **B**: Liver sections stained by hematoxylin and eosin (4 × increase). Arrows indicate necrotic areas; **C**, **D**: Liver macroscopic analysis confirmed extensive and diffuse necrosis, which is also reflected by elevated serum transaminase activity (**D**); **E**, **F**: Liver failure was confirmed by prolonged prothrombin and partial thromboplastin times; **G**, **H**: Also, significant drop in mean arterial pressure (MAP; **G**) and increased heart rate (**H**), as assessed by tail cuff method, suggested that TAA-treated mice also evolved to hemodynamic shock; **I**: After TAA treatment hours, lungs from mice had increased cellularity in lung parenchyma, alveolar edema and hemorrhage in comparison to controls (arrows, 4 × increase) alndicates statistical significance in comparison to controls. \* $P < 0.05$ , ANOVA (Tukey's post test).  $N \geq 5$  for each group. TAA: Thioacetamide.

brain edema<sup>[25]</sup>. In addition, through analysis of the EEG spectrum we found diffuse a brain lesion compatible with metabolic encephalopathy<sup>[26]</sup>, suggesting that our DILI

model reproduces some of the main clinical manifestations of HE<sup>[27]</sup>. In conjunct, our data suggest that this model may be suitable for further studies involving ALF,



hyperammonemia and brain edema.

We also investigated the mechanisms involved in liver damage triggered by TAA in mice. Intravital microscopy revealed that large areas of liver necrosis were infiltrated by neutrophils and such sterile inflammation has been described as a key factor for injury amplification<sup>[12]</sup>. Furthermore, we also observed repercussions in hemodynamic functions and inflammatory infiltration in the lungs. In this sense, the innate immune response triggered by necrosis-derived products may add to direct TAA-mediated hepatotoxicity to establish not only ALF, but also remote organ injury. Accordingly, TAA-treated mice displayed a severe impairment in hemostatic function compatible with an end-stage liver failure, with coagulopathy, hypovolemic shock and possible multiple organ failure. Thus, these factors should be also evaluated in future studies primarily dedicated to the liver or central nervous system.

In conclusion, we have shown that repeated lower doses of TAA might constitute as a novel murine model of HE and ALF, which reproduce several features of human disease. Also, we provided read-outs for disease grade and severity that comprise behavioral changes, brain edema and ammonemia, hemodynamic parameters and inflammatory response.

## ACKNOWLEDGMENTS

We would like to thank CNPq, Fapemig, PRONEX and CAPES for financial support.

## COMMENTS

### Background

Acute liver failure (ALF) is a rare but severe clinical syndrome. ALF is the result of massive liver injury, which can be caused mostly by drugs or viruses. During the disease, patients may suffer hepatic encephalopathy, multiple organ dysfunction and sepsis, leading to a high mortality rate. The incidence of ALF is increasing worldwide and liver transplantation and supportive medical care are the only therapies available for ALF.

### Research frontiers

Hepatic encephalopathy (HE) is one of the major complications in ALF because of rapidly progressing brain edema and hypertension. Hence, understanding HE pathophysiology is crucial for development of new and specific therapies that would slow down its progression and increase chances of better outcomes. In this sense, a murine model that reproduces most features of HE in humans would be key to improve our understanding of HE pathophysiology and may also be useful for drug testing and development.

### Innovations and breakthroughs

This study provided a new model to study hepatic encephalopathy and acute liver failure in mice. In this model, mice are treated twice with a low dose thioacetamide, causing extensive liver injury and characteristic complications of human HE, including high ammonia levels, altered electroencephalography (EEG), brain edema and poor neuropsychomotor function. In addition, mice presented with a systemic response similar to multiple organ failure syndrome, where lung inflammation, coagulopathy and hemodynamic alterations were observed.

### Applications

This is a new model to study ALF and HE in mice, the most used animal model. Also, this is the first animal model to present such similar symptoms to the human disease, making it a more useful research tool for this biomedical area.

### Terminology

The most important terms in this article are: ALF, HE and thioacetamide.

### Peer review

The authors describe a murine model of acute hepatic failure to study hepatic

encephalopathy by sequential administration of thioacetamide intraperitoneally. The hypothesis is convenient, the methodology for acute hepatic failure was suitable, the evaluation of hepatic encephalopathy was convenient and sophisticated, the results were interesting and the discussion appropriate.

## REFERENCES

- 1 Bernal W, Auzinger G, Dhawan A, Wendon J. Acute liver failure. *Lancet* 2010; **376**: 190-201 [PMID: 20638564 DOI: 10.1016/S0140-6736(10)60274-7S0140-6736(10)60274-7]
- 2 Ichai P, Samuel D. Epidemiology of liver failure. *Clin Res Hepatol Gastroenterol* 2011; **35**: 610-617 [PMID: 21550329 DOI: 10.1016/j.clinre.2011.03.010S2210-7401(11)00122-7]
- 3 Bernal W, Hyyrylainen A, Gera A, Audimoolam VK, McPhail MJ, Auzinger G, Rela M, Heaton N, O'Grady JG, Wendon J, Williams R. Lessons from look-back in acute liver failure? A single centre experience of 3300 patients. *J Hepatol* 2013; **59**: 74-80 [PMID: 23439263]
- 4 Lee WM. Acute liver failure. *Semin Respir Crit Care Med* 2012; **33**: 36-45 [PMID: 22447259 DOI: 10.1055/s-0032-1301733]
- 5 Vaquero J, Chung C, Blei AT. Brain edema in acute liver failure. A window to the pathogenesis of hepatic encephalopathy. *Ann Hepatol* 2003; **2**: 12-22 [PMID: 15094701]
- 6 Shawcross DL, Wendon JA. The neurological manifestations of acute liver failure. *Neurochem Int* 2012; **60**: 662-671 [PMID: 22067133 DOI: 10.1016/j.neuint.2011.10.006]
- 7 O'Grady JG, Alexander GJ, Hayllar KM, Williams R. Early indicators of prognosis in fulminant hepatic failure. *Gastroenterology* 1989; **97**: 439-445 [PMID: 2490426]
- 8 Rolando N, Wade J, Davalos M, Wendon J, Philpott-Howard J, Williams R. The systemic inflammatory response syndrome in acute liver failure. *Hepatology* 2000; **32**: 734-739 [PMID: 11003617]
- 9 Farjam M, Dehdab P, Abbassnia F, Mehrabani D, Tanideh N, Pakbaz S, Imanieh MH. Thioacetamide-induced acute hepatic encephalopathy in rat: behavioral, biochemical and histological changes. *Iran Red Crescent Med J* 2012; **14**: 164-170 [PMID: 22737573]
- 10 McDonald B, Pittman K, Menezes GB, Hirota SA, Slaba I, Waterhouse CC, Beck PL, Muruve DA, Kubes P. Intravascular danger signals guide neutrophils to sites of sterile inflammation. *Science* 2010; **330**: 362-366 [PMID: 20947763 DOI: 10.1126/science.1195491]
- 11 Hartman RE, Kamper JE, Goyal R, Stewart JM, Longo LD. Motor and cognitive deficits in mice bred to have low or high blood pressure. *Physiol Behav* 2012; **105**: 1092-1097 [PMID: 22154805 DOI: 10.1016/j.physbeh.2011.11.022]
- 12 Marques PE, Amaral SS, Pires DA, Nogueira LL, Soriani FM, Lima BH, Lopes GA, Russo RC, Avila TV, Melgaço JG, Oliveira AG, Pinto MA, Lima CX, De Paula AM, Cara DC, Leite MF, Teixeira MM, Menezes GB. Chemokines and mitochondrial products activate neutrophils to amplify organ injury during mouse acute liver failure. *Hepatology* 2012; **56**: 1971-1982 [PMID: 22532075 DOI: 10.1002/hep.25801]
- 13 Norton NS, McConnell JR, Rodriguez-Sierra JF. Behavioral and physiological sex differences observed in an animal model of fulminant hepatic encephalopathy in the rat. *Physiol Behav* 1997; **62**: 1113-1124 [PMID: 9333208]
- 14 Chen TM, Subeq YM, Lee RP, Chiou TW, Hsu BG. Single dose intravenous thioacetamide administration as a model of acute liver damage in rats. *Int J Exp Pathol* 2008; **89**: 223-231 [PMID: 18422601 DOI: 10.1111/j.1365-2613.2008.00576.x]
- 15 Ashworth CT, Werner DJ, Glass MD, Arnold NJ. Spectrum of fine structural changes in hepatocellular injury due to thioacetamide. *Am J Pathol* 1965; **47**: 917-951 [PMID: 5844383]
- 16 Mangipudy RS, Chanda S, Mehendale HM. Tissue repair response as a function of dose in thioacetamide hepatotoxicity. *Environ Health Perspect* 1995; **103**: 260-267 [PMID: 7768227]



- 17 **Hajovsky H**, Hu G, Koen Y, Sarma D, Cui W, Moore DS, Staudinger JL, Hanzlik RP. Metabolism and toxicity of thioacetamide and thioacetamide S-oxide in rat hepatocytes. *Chem Res Toxicol* 2012; **25**: 1955-1963 [PMID: 22867114 DOI: 10.1021/tx3002719]
- 18 **Bhatia V**, Singh R, Acharya SK. Predictive value of arterial ammonia for complications and outcome in acute liver failure. *Gut* 2006; **55**: 98-104 [PMID: 16024550]
- 19 **Tofteng F**, Hauerberg J, Hansen BA, Pedersen CB, Jørgensen L, Larsen FS. Persistent arterial hyperammonemia increases the concentration of glutamine and alanine in the brain and correlates with intracranial pressure in patients with fulminant hepatic failure. *J Cereb Blood Flow Metab* 2006; **26**: 21-27 [PMID: 15959460]
- 20 **Avraham Y**, Grigoriadis N, Poutahidis T, Vorobiev L, Magen I, Ilan Y, Mechoulam R, Berry E. Cannabidiol improves brain and liver function in a fulminant hepatic failure-induced model of hepatic encephalopathy in mice. *Br J Pharmacol* 2011; **162**: 1650-1658 [PMID: 21182490 DOI: 10.1111/j.1476-5381.2010.01179.x]
- 21 **Bélanger M**, Côté J, Butterworth RF. Neurobiological characterization of an azoxymethane mouse model of acute liver failure. *Neurochem Int* 2006; **48**: 434-440 [PMID: 16563565]
- 22 **Miranda AS**, Rodrigues DH, Vieira LB, Lima CX, Rachid MA, Vidigal PV, Gomez MV, Reis HJ, Guatimosim C, Teixeira AL. A thioacetamide-induced hepatic encephalopathy model in C57BL/6 mice: a behavioral and neurochemical study. *Arq Neuropsiquiatr* 2010; **68**: 597-602 [PMID: 20730316]
- 23 **Norenberg MD**. Astroglial dysfunction in hepatic encephalopathy. *Metab Brain Dis* 1998; **13**: 319-335 [PMID: 10206824]
- 24 **Butterworth RF**. Pathophysiology of hepatic encephalopathy: a new look at ammonia. *Metab Brain Dis* 2002; **17**: 221-227 [PMID: 12602499]
- 25 **Bozza FA**, Garteiser P, Oliveira MF, Doblaz S, Cranford R, Saunders D, Jones I, Towner RA, Castro-Faria-Neto HC. Sepsis-associated encephalopathy: a magnetic resonance imaging and spectroscopy study. *J Cereb Blood Flow Metab* 2010; **30**: 440-448 [PMID: 19844239 DOI: 10.1038/jcbfm.2009.215]
- 26 **Kaplan PW**. The EEG in metabolic encephalopathy and coma. *J Clin Neurophysiol* 2004; **21**: 307-318 [PMID: 15592005]
- 27 **Butterworth RF**, Norenberg MD, Felipo V, Ferenci P, Albrecht J, Blei AT. Experimental models of hepatic encephalopathy: ISHEN guidelines. *Liver Int* 2009; **29**: 783-788 [PMID: 19638106 DOI: 10.1111/j.1478-3231.2009.02034.x]

**P- Reviewers:** Galvao FHF, Naglaa A, Yamasaki T  
**S- Editor:** Song XX **L- Editor:** Roemmele A **E-Editor:** Wu HL



## Nuclear medicine dynamic investigations in the diagnosis of Budd-Chiari syndrome

Mircea Dragoteanu, Ioan-Adrian Balea, Cecilia-Diana Piglesan

Mircea Dragoteanu, Ioan-Adrian Balea, Cecilia-Diana Piglesan, Department of Nuclear Medicine, Regional Institute for Gastroenterology and Hepatology, Prof. Dr. Octavian Fodor, 400162 Cluj-Napoca, Romania

**Author contributions:** Dragoteanu M was the leader of the research team, coordinated the practical procedures, developed the method of using per-rectal portal scintigraphy and liver angioscintigraphy to investigate the liver hemodynamics, conducted the analysis of data and wrote the paper; Balea IA contributed to the data analysis and writing of the paper; Piglesan CD performed the practical procedures of the patients and acquisition of data.

**Correspondence to:** Dr. Mircea Dragoteanu, MD, PhD, Head of Nuclear Medicine Department, Institute for Gastroenterology and Hepatology, Prof. Dr. Octavian Fodor, Croitorilor Str. 19-21, 400162 Cluj-Napoca, Romania. [dragoteanu@yahoo.co.uk](mailto:dragoteanu@yahoo.co.uk)

Telephone: +40-722-381851 Fax: +40-722-381851

Received: October 28, 2013 Revised: January 10, 2014

Accepted: February 20, 2014

Published online: April 27, 2014

### Abstract

**AIM:** To investigate the hepatic hemodynamics in the Budd-Chiari syndrome (BCS) using per-rectal portal scintigraphy (PRPS) and liver angioscintigraphy (LAS).

**METHODS:** Fourteen consecutive patients with BCS were evaluated by PRPS between 2003 and 2012. Ten of them underwent LAS and liver scan (LS) with Tc-99m colloid. Eleven patients had clinical manifestations and three were asymptomatic, incidentally diagnosed at PRPS. The control group included 15 healthy subjects. We used new parameters at PRPS, the liver transit time of portal inflow and the blood circulation time between the right heart and liver. PRPS offered information on the hepatic areas missing venous outflow or portal inflow, length and extent of the lesions, open portosystemic shunts (PSS), involvement of the caudate lobe (CL) as an intrahepatic shunt and flow reversal in the splenic vein. LAS was useful in the differential diagnosis between the BCS and portal obstructions, highlighting

the hepatic artery buffer response and reversed portal flow. LS offered complementary data, especially on the CL.

**RESULTS:** We described three hemodynamic categories of the BCS with several subtypes and stages, based on the finding that perfusion changes depend on the initial number and succession in time of the hepatic veins (HVs) obstructions. Obstruction of one hepatic vein (HV) did not cause opening of PSS. The BCS debuted by common obstruction of two HVs had different hemodynamic aspects in acute and chronic stages after subsequent obstruction of the third HV. In chronic stages, obstruction of two HVs resulted in opening of PSS. The BCS, determined by thrombosis of the terminal part of the inferior vena cava, presented in the acute stage with open PSS with low speed flow. At least several weeks are required in the obstructions of two or three HVs for the spontaneous opening of dynamically efficient PSS. The CL seems to have only a transient important role of intrahepatic shunt in several types of the BCS.

**CONCLUSION:** Dynamic nuclear medicine investigations assess the extent and length of hepatic venous obstructions, open collaterals, areas without portal inflow, hemodynamic function of the CL and reverse venous flow.

© 2014 Baishideng Publishing Group Co., Limited. All rights reserved.

**Key words:** Budd-Chiari syndrome; Per-rectal portal scintigraphy; Liver angioscintigraphy; Caudate lobe; Hepatic veins

**Core tip:** Per-rectal portal scintigraphy (PRPS) and liver angioscintigraphy (LAS) are reliable investigations of the liver hemodynamics in the Budd-Chiari syndrome (BCS). Diagnosis of the number, length and succession in time of hepatic vein obstructions allows identification

of hemodynamic varieties and stages of the BCS. Our new PRPS parameters, liver transit time and right heart to liver time, are used to diagnose obstructed hepatic veins, areas missing venous outflow or portal inflow, open collaterals, reverse splenic vein flow and hemodynamic role of the caudate lobe. LAS is useful in the differential diagnosis with portal occlusions, highlighting arterial-venous shunts and reverse portal flow.

Dragoteanu M, Balea IA, Piglesan CD. Nuclear medicine dynamic investigations in the diagnosis of Budd-Chiari syndrome. *World J Hepatol* 2014; 6(4): 251-262 Available from: URL: <http://www.wjgnet.com/1948-5182/full/v6/i4/251.htm> DOI: <http://dx.doi.org/10.4254/wjh.v6.i4.251>

## INTRODUCTION

The Budd-Chiari syndrome (BCS) is determined by hepatic venous obstruction localized from the small hepatic veins (HVs) to the terminal part of the inferior vena cava (IVC), resulting in increased sinusoidal pressure, hepatic congestion and portal hypertension (PHT)<sup>[1]</sup>. The natural outcome is poor in many cases, with a three year survival rate of about 10%<sup>[2,3]</sup>. Clinical manifestations are extremely varied and include ascites, jaundice, hepatomegaly, splenomegaly, collateral veins and upper right abdominal quadrant pain<sup>[4]</sup>. Ascites fluid has a characteristic high protein concentration (> 2.5 g/dL).

A widely accepted classification is based on etiology, site of obstruction, manifestations and duration of the disease<sup>[5]</sup>. Primary BCS is produced by thrombosis, its sequels or web obstruction<sup>[6]</sup>. Secondary forms are determined by malignant or parasitic obstruction of the lumen or by extrinsic compression, commonly produced by tumors<sup>[7]</sup>. The site involved by the obstruction and the affected HVs are commonly diagnosed through non-invasive imaging [ultrasound (US), magnetic resonance imaging (MRI), computed tomography (CT)] or by using venography<sup>[8]</sup>.

Clinical approach accounts for the severity of disease (fulminant/non-fulminant) and its duration (acute, subacute or chronic). Subacute forms show signs or symptoms for less than six months and no evidence of liver cirrhosis. Chronic evolution is characterized by onset over six months, with evidence of PHT and cirrhosis<sup>[9]</sup>. However, the severity of liver damage may be inconsistent with apparent symptomatology. Recent clinical onset may be discordant with advanced liver fibrosis, suggesting a long course without clinical symptoms. Asymptomatic disease (10%-15% of cases) is usually associated with the obstruction of only one HV but also with spontaneous development of dynamically efficient intrahepatic collaterals and extrahepatic portosystemic shunts (PSS), incidentally diagnosed by imaging at surgery or necropsy<sup>[10]</sup>. For the patients with acute clinical onset but with advanced histological damage, a recent hepatic venous obstruction added to older obstructions of other

HVs has to be suspected. In acute forms, the liver area without physiological outflow is hypertrophied and PHT occurs. Because of the higher pressure (35 mmHg) in the hepatic artery (HA) than in the portal vein (PV) branches (3-6 mmHg), the portal flow may be reversed.

Chronic alterations include parenchyma atrophy and extended fibrosis, gaining a cirrhotic appearance and considerably reducing both portal and arterial inflow. Splenomegaly is found in a third of patients<sup>[11]</sup>.

Thrombosis is the usual cause for the occlusion of large HVs, while the obstructions of the IVC or of the small HVs are rarely thrombotic<sup>[12]</sup>.

The anatomical varieties of the HVs have to be accounted for, both for the diagnosis and surgical treatment. A common opening into the IVC of the left hepatic vein (LHV) and middle hepatic vein (MHV) was reported in around 55%-60% of cases<sup>[13]</sup>. Other varieties, such as a common trunk of the MHV and right hepatic vein (RHV), separate opening of the three HVs into the IVC or the existence of an accessory RHV, were identified in various percentages<sup>[14-16]</sup>. The caudate lobe (CL) hemodynamic status is important as it may be an anastomosis between the obstructed HVs and the IVC. CL hypertrophy is described in 65%-75% of cases, with good sensitivity but not specificity<sup>[17]</sup>. A caliber of the CL vein higher than 3 mm is considered diagnostic for the BCS<sup>[18]</sup>.

US usually demonstrates altered HVs and hypertrophy of the CL<sup>[19]</sup>. Duplex Doppler sonography is widely used, offering a good assessment of the blood flow through the HVs<sup>[20,21]</sup>. Color Doppler sonography allows a more reliable identification of abnormalities of the HVs than conventional sonography and detects collateral vessels not visible with other techniques. The lack of flow signals in the HVs, intrahepatic and extrahepatic collaterals, together with reverse, slow or turbulent portal flow, are characteristic findings. US techniques should be the first line investigations, due to a low cost and a diagnostic sensitivity of more than 75%. There are, however, cases where the occlusion of HVs is difficult to demonstrate by US, even by color Doppler imaging<sup>[22]</sup>.

CT scans offer a good assessment of thrombosis of the HVs or IVC, global liver enlargement, abnormalities of liver structure, size and direction of the venous flow. The contrast-enhanced helical CT allows a good dynamic visualization of HVs<sup>[23]</sup>. MRI provides useful images of the hepatic venous outflow and thrombosis of HVs, as second line investigations together with CT<sup>[24,25]</sup>. It can be difficult to diagnose spontaneous intrahepatic anastomoses and prominent azygos and hemiazygos veins (especially in IVC thrombosis) on MRI<sup>[26]</sup>. The liver biopsy has limited value due to the inhomogeneous distribution of liver lesions in the BCS<sup>[27]</sup>.

Per-rectal portal scintigraphy (PRPS) was used over the last decades to investigate PHT and PSS in chronic liver disease (CLD) by evaluating a per-rectal portal shunt index<sup>[28,29]</sup>. Detailed information may be acquired about liver hemodynamics by using the parameters introduced by us in the interpretation of PRPS dynamic curves - liver transit time (LTT) and right heart to liver

time (RHLT)<sup>[30]</sup>.

Liver angioscintigraphy (LAS) evaluates the contribution of arterial inflow to the total liver perfusion. It is especially useful in the differential diagnosis between the BCS and obstructions of the portal branches. Liver areas missing portal inflow have compensatory increased arterial inflow due to the hepatic artery buffer response (HABR)<sup>[31]</sup> and a characteristic pattern at LAS, with abrupt arterial entry and a flattened portal segment.

Liver scan (LS) with Tc-99m labeled colloid performed after LAS may show changes in radiotracer capture by liver, spleen and spine. Increased radioactivity on the CL area is considered a characteristic finding in the BCS<sup>[32]</sup>.

The aim of this study is to underline the diagnostic possibilities in the BCS of the PRPS and LAS, with auxiliary use of the LS. The goals are assessment of liver areas missing venous drainage, length and order of the appearance of lesions, arterial and portal perfusion changes, existence of dynamically efficient collaterals and of supplementary drainage through the CL.

## MATERIALS AND METHODS

We evaluated 14 consecutive patients with the BCS between 2003 and 2012, 9 females and 5 males, between 20 and 63 years old. Eleven patients had clinically manifested BCS and 3 were asymptomatic, incidentally identified at PRPS among over 400 patients explored for chronic liver disease (CLD) staging. The control group included 15 healthy subjects from the laboratory casework, 7 men and 8 women, between 19 and 67 years old. All 14 patients with BCS underwent PRPS. LAS and LS were performed in 10 of them. Anonymity of the patients was respected. All persons gave their informed consent prior to the investigations, accepting inclusion in research studies. The study was realized as part of routine clinical practice.

All the investigations were performed by using a single photon emission computed tomography (SPECT) Orbiter Siemens gamma-camera with high resolution, low-energy, parallel collimator, connected to a Power Macintosh computer, using ICON dedicated software. We used Tc-99m sodium pertechnetate, eluted from Dryden generators (General Electric, Amersham, United Kingdom) and Fyton colloid (Institute of Isotopes, Budapest, Hungary).

PRPS was performed using the method developed by Shiomi *et al.*<sup>[33]</sup>. A solution containing 2 mL (296-370 MBq/8-10 mCi) of Tc-99m sodium pertechnetate was instilled at PRPS into the upper part of the rectum through a Nelaton tube, followed by 15 mL of air under pressure. Serial scintigrams were recorded every 2 s for 5 min. Radioactivity curves were built thereafter by computer on liver and heart areas to analyze the dynamics of the radiotracer absorbed from the rectum. The patients were told to fast from the evening preceding the test. Two enemas were performed in each patient, the first the previous evening and the second one 2 h prior to the PRPS. The patients were placed in a supine position, with

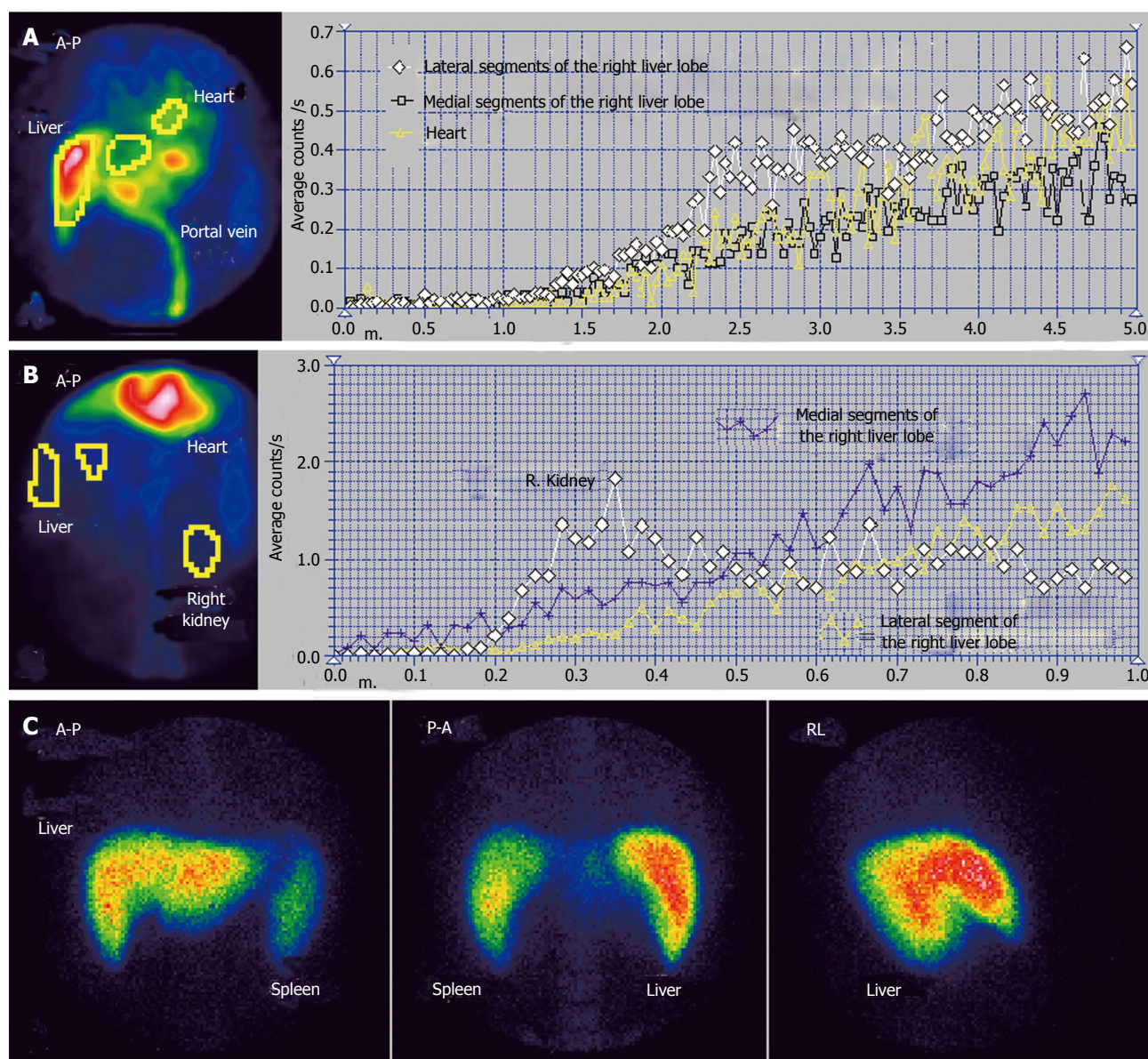
the camera detector in the anterior view, including in the field the liver and heart areas.

LTT and RHLT allow detailed assessment of liver hemodynamics in the BCS. These time parameters can be assessed for particular hepatic areas or for the whole liver. The portal inflow is missing in those areas where the tracer arrives (through the HA) with a delay equal to RHLT after entering into the right heart (RH). LTT increased between 25-40 s shows a higher resistance opposed to the portal inflow. Values over 50 s of the time interval between the entering of tracer into the liver and its arrival to the RH may occur in the acute stage of the BCS produced by obstruction of the terminal part of the IVC. This high delay is determined by the slow flow through the PSS open to the superior vena cava. LTT between 15-23 s reflects a decrease of the resistance opposed by the liver to the portal inflow due to the enlargement of intrahepatic small size shunts between terminal portal branches and small HVs. Open extrahepatic PSS of high flow are emphasized at PRPS by arrival of the portal tracer to the RH before entering into the liver. PRPS also detects alterations of portal and arterial perfusion in the liver areas which maintain their physiological venous outflow, highlighting the changes determined by the redistribution of flow from the affected areas.

The arterial upward inflexion (AUI) of the PRPS curve on a liver area is placed at a time interval equal to RHLT after the moment when the tracer entered into the RH. The beginning of the AUI segment on our figures is noted HA, marking the arrival of tracer to the liver through the HA. The moments when the portal tracer enters into the different areas of the liver are noted as Co, Lo, Mo and Ro. The entering of tracer into the RH is noted as Ho. The slope of the AUI gives information about the amplitude of arterial inflow. The portal segment of the PRPS curve (before the AUI) offers information about the portal inflow and the dynamic resistance encountered. Summed images at PRPS resulting from the overlapping of all the sequential images may highlight the normal aspect, increased accumulation or low quantity of tracer in a liver area. The presence of the spleen on the summed image highlights reverse flow in the splenic vein.

LAS was performed by rapid bolus injection of 8 to 15 mCi (300-450 MBq) of Tc-99m labeled colloid in a volume smaller than 0.5 mL, followed by computer dynamic recording of sequential images during 1 min at a 1 s rate. The detector's area included the heart, liver and kidneys. Six patients underwent LAS in the posterior-anterior view (P-A) and four in the anterior-posterior view (A-P). Patients were asked to fast 12 h before the LAS. Dynamic time-radioactivity curves for the liver, spleen and left or right kidney were built by computer. The moment of the peak of the kidney curve corresponds on the liver curve to the upward inflection point when the portal inflow of tracer adds to the arterial inflow. The interval of 8 s on the liver curve before the kidney curve's peak corresponds to the arterial segment, while the 8 s interval after the peak represents the portal segment<sup>[34]</sup>.





**Figure 1** Budd-Chiari syndrome with obstruction of the middle hepatic vein. A: Per-rectal portal scintigraphy; B: Liver angioscintigraphy; C: Liver scan.

The shape of the LAS curve built on a liver area may highlight amplitude changes of the arterial flow, a higher resistance opposed to the blood flow or open arterial-venous shunts. Hepatic perfusion index (HPI) calculated at LAS is used to estimate the ratio between the arterial inflow and total liver perfusion<sup>[35]</sup>. HPI > 45% on an area of the right liver lobe (RLL) without tumors diagnoses a decrease in portal inflow, with reactive increase in the arterial flow determined by the HABR<sup>[36]</sup>. HPI > 100% emphasizes reverse flow in the portal vein. HPI can be accounted for the RLL only, as the left liver lobe (LLL) normally has an increased arterial inflow.

LS images were acquired beginning at least 15 min after the LAS, based on the same administration of Tc-99m labeled colloid. P-A, A-P and right lateral (RL) views were used. Time consuming SPECT was not considered to bring significantly more information on hemodynamic status than planar LS and was not performed.

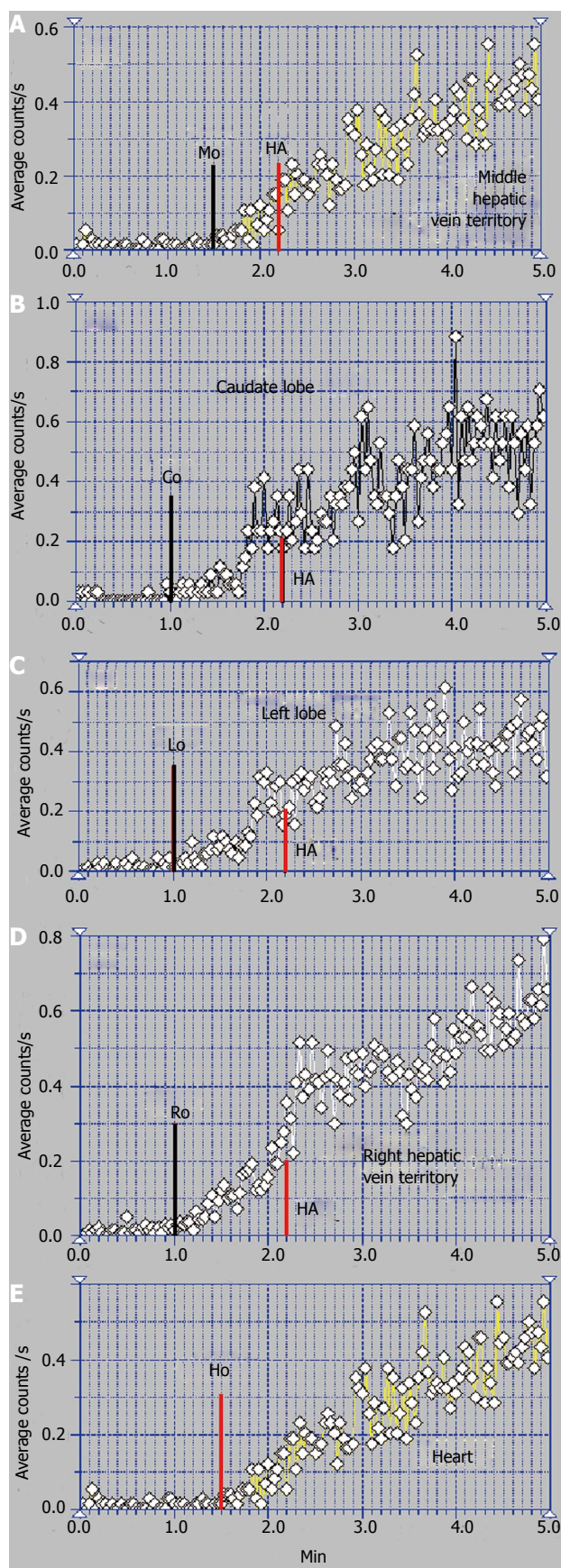
## RESULTS

We highlighted three hemodynamic categories of the BCS using PRPS and LAS: (1) BCS debuted by obstruction of one HV: asymptomatic, incidentally diagnosed and old obstruction of one HV followed by recent obstruction of the other two HVs; (2) BCS started by obstruction of two HVs: old obstruction of two HVs, followed by recent obstruction of the third HV, and old obstruction of two HVs, also followed by old obstruction of the third HV; and (3) BCS with acute onset due to simultaneous obstruction of all three HVs caused by obstruction of the terminal part of the IVC.

### **BCS with one obstructed HV, asymptomatic, incidentally diagnosed**

We had three cases of asymptomatic BCS in our study, two with obstruction of the MHV and one with obstruc-





**Figure 2** Per-rectal portal scintigraphy in Budd-Chiari syndrome with obstruction of the middle hepatic vein. A: Curve on the territory drained by the middle hepatic vein; B: Caudate lobe curve; C: Left lobe curve; D: Curve on the territory drained by the right hepatic vein; E: Heart curve.

tion of the RHV. All three were incidentally identified at PRPS.

The case presented in Figures 1 and 2 had MHV obstruction. The patient was a 36-year-old male, known to have chronic alcoholic hepatitis. US described inhomogeneous liver with regenerative nodules and dilated portal branches.

Summed image at PRPS (Figure 1A) reveals a decreased amount of radiotracer in the medial part of the RLL. The dynamic PRPS curves built on the RLL show highly different slopes on the medial and lateral segments. The arrival of portal tracer to the medial area was delayed about 30 s after the entrance into the lateral segments. Initial segment of the PRPS curve built on the medial area of the RLL has a slow slope, denoting moderately increased resistance opposed to the portal inflow (Figure 2A). The PRPS curve built on the lateral part of the RLL has an increased slope, showing a rise of its portal inflow (Figure 2D). The dynamic curve built on the CL has a low initial slope, indicating that the portal flow blocked due to the obstruction of the MHV was not drained through the CL. The LLL has a simultaneous entry of tracer as the CL and as the lateral area of the RLL, with a normal initial slope of the PRPS curve.

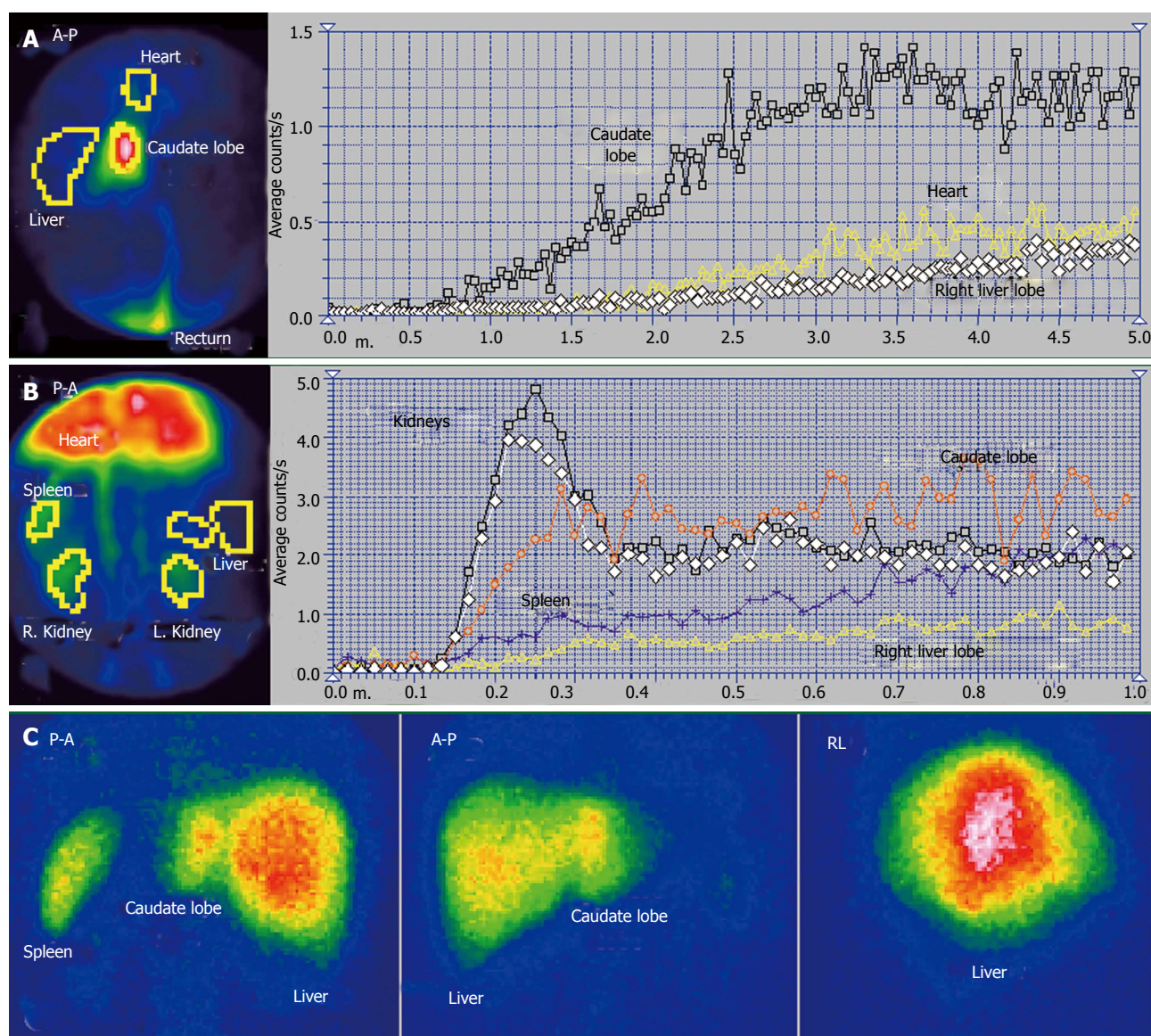
LTT is prolonged to 30 s, most likely due to the subadjacent CLD, with increased resistance opposed to the portal inflow. The LS images confirm the diagnosis of alcoholic CLD, showing splenomegaly and hypertrophy of the LLL, with a normal aspect of the spine. Normal LS aspect of the medial area of the RLL suggests a subacute stage of the BCS, without cirrhotic changes of the affected parenchyma. PSS were not open, as the tracer arrived at the RH by passing through the liver. The LAS curve on the medial segments of the RLL is significant for arterial-venous shunts. The differential diagnosis accounted for the value of LTT and missing of the HABR, excluding a portal branch obstruction.

### **BCS with old obstruction of one HV and recent obstruction of the other two HVs**

The patient presented in Figures 3 and 4 was a 32-year-old male, without a previous diagnosis of CLD. The patient complained of flatulence, vomiting and severe abdominal pain which had started several weeks earlier. US highlighted ascites and venous dilations. No blood flow in the HVs and no portal thrombosis were observed at the US, while numerous intrahepatic arterial-venous and venous-venous collaterals were described. Esophageal varices and gastric injuries were not seen on endoscopy.

The summed image at PRPS presents a sharply increased radioactivity on the CL area (Figure 3A). The LLL only has arterial inflow, receiving tracer after the RH with a delay equal to RHLT (Figure 4B). This suggests an old obstruction of the LHV, with chronic alteration of perfusion of the LLL. The clinical onset in this case resulted from a recent obstruction of the RHV and MHV, while the LHV had been obstructed for a long time. The PRPS curve on the RLL has low slopes on





**Figure 3** Budd-Chiari syndrome with old obstruction of the left hepatic vein and recent obstruction of the middle and right hepatic veins. A: Per-rectal portal scintigraphy; B: Liver angioscintigraphy; C: Liver scan.

the initial portal segment and on the AUI, showing that its portal and arterial inflows were decreased. The differential diagnosis excluded portal obstruction, accounting for small arterial inflow of the two liver lobes and missing the HABR.

Arrival of tracer to the RH at 30 s after entering into the CL shows that PSS were not open due to the earlier obstruction of one HV and the recent obstruction of the other two HVs (Figure 4). The tracer was detected in the RLL about 12 s after the CL, a slow portal inflow to the RLL being maintained.

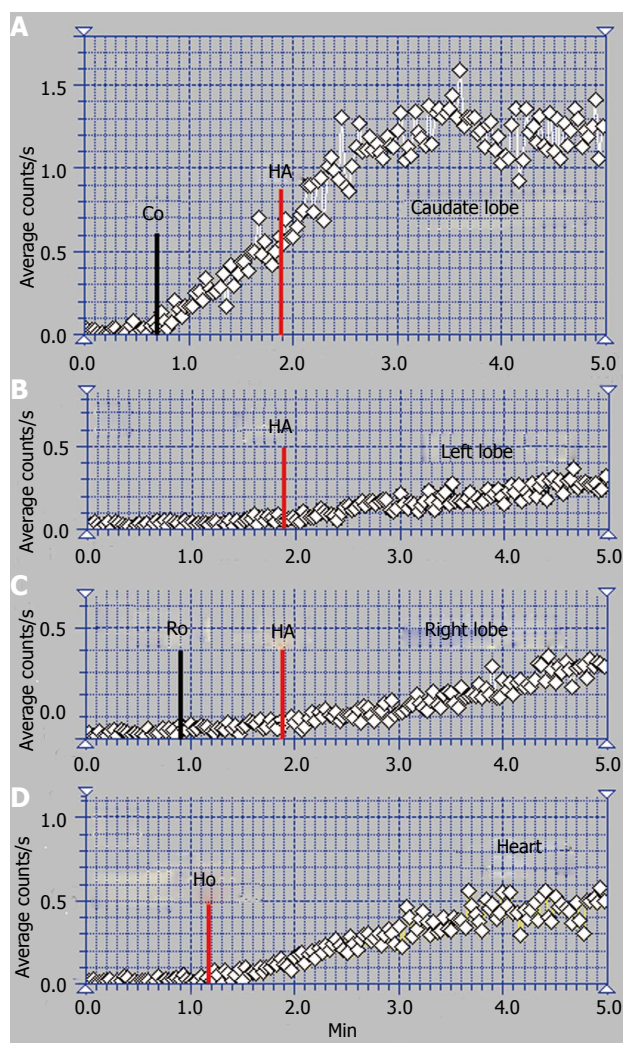
Altered flow of the RLL was highlighted at the LAS (Figure 3B). After a short initial interval of about 1 s with normal arterial input, the LAS curve flattens on the rest of the arterial segment and has a low slope on the portal segment. The flattened curve on the RLL highlights the higher dynamic resistance encountered by the arterial inflow.

The ASH curve of the CL has an initial abrupt and

high segment, due to the increased arterial inflow, followed by a flat portal segment and then by fluctuations of amplitude suggesting arterial-venous shunts (Figure 3B). The CL has a very high entering of portal tracer at the PRPS (Figure 4A). LTT on the CL is increased to 30 s due to the dynamic resistance opposed by the supplementary arterial and portal flows redirected from the RLL and LLL. The high amplitude of the PRPS curve on the CL was determined by the increased and slowed portal inflow. LS (Figure 3C) revealed increased radioactivity in the CL, inhomogeneous liver parenchyma and slightly increased radioactivity in the spleen.

The perfusion changes in the LLL and RLL suggest a subacute stage of the BCS. We underline that the old obstruction of the LLL together with more recent occlusion of the other two HVs did not open PSS. The arterial and portal blood flow of the whole liver was drained to the IVC through the CL.





**Figure 4** Per-rectal portal scintigraphy in Budd-Chiari syndrome with old obstruction of the left hepatic vein and recent obstruction of the middle and right hepatic veins. A: Caudate lobe curve; B: Left lobe curve; C: Right lobe curve; D: Heart curve.

### **BCS started by the common obstruction of two HVs, also followed by old obstruction of the third HV**

The scintigraphy investigations in a patient with BCS with an old obstruction of the MHV and RHV and subsequent but also old obstruction of the LHV are presented in Figures 5 and 6. This 20 year old woman, a user of an oral contraceptive, was hospitalized with an impaired general condition and abdominal pain. The first symptoms appeared two and a half years earlier when the BCS was diagnosed. US at admission showed abundant ascites and PV dilation to 15 mm. Doppler US could not detect flow in the HVs.

The RLL received tracer at PRPS at a time interval equal to RHLT after the RH, emphasizing that the portal inflow was missing and the blood supply of the RLL came from the HA only (Figures 6C, D).

The tracer entered the LLL and the CL (Figure 6A, B) at about 25 s after reaching the RH, showing that their perfusion was mainly (but not completely) arterial. The

initial low slopes of the CL and LLL curves were caused by increased resistance opposed to the portal inflow. The high slope of the AUI on the CL and LLL curves was determined by the large quantity of tracer that arrived through the HA. The slope of the AUI is smaller on the RLL than on the LLL and CL curves with about 50% (Figure 6C). Due to the older impairment of the RLL, its arterial perfusion per unit of area became lower than for the LLL and CL.

PSS were open, allowing the tracer absorbed from rectum to arrive faster to the RH than to the liver. The presence of the IVC on the summed PRPS image suggests the existence of open per-rectal PSS.

The ASH curve on the CL has a steep and biphasic entrance during the arterial segment. The portal phase has a drop in amplitude and subsequent fluctuations (Figure 5B). Increased arterial perfusion and existence of arterial-venous shunts are highlighted in the CL. The high arterial inflow suggests that the CL maintained part of its role of intrahepatic shunt to the IVC for the arterial inflow redirected from the rest of the liver. The ASH curve on the RLL shows increased arterial perfusion and reverse portal flow, with HPI = 115%.

The CL is visible on the LS, contrasting to the low colloid capture in the RLL (Figure 5C). The normal LS aspect of the spine and spleen argues against alcoholic or viral cirrhosis.

### **BCS with old obstruction of two HVs followed by recent obstruction of the third HV**

We encountered one case of the BCS syndrome with old RHV and MHV obstruction and very recent occlusion of the LHV. One of these patients was a 32-year-old woman, an oral contraceptive user, with ascites in high quantity, increasing abdominal girth and without viral or alcoholic cirrhosis.

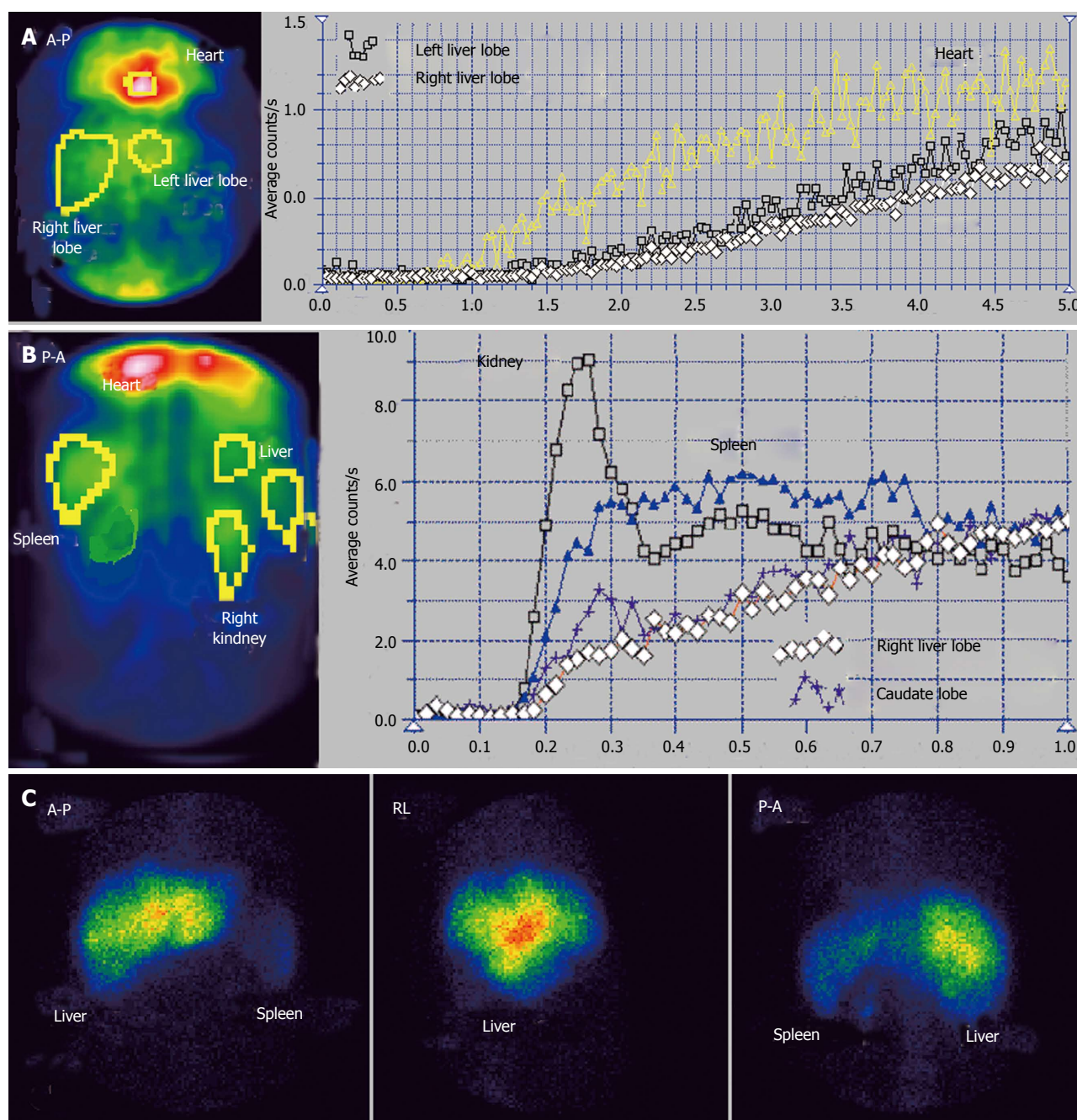
The time interval at PRPS (Figure 7) between the dynamic curves built on the heart and on the whole liver is equal to RHLT, showing that both the LLL and RLL missed portal inflow and the extrahepatic PSS of high flow were open. The high initial slope of the PRPS curve on the heart confirms that the PSS were hemodynamically efficient.

The highly increased radioactivity in the congested LLL on the summed PRPS image suggests that its deprivation of physiological venous drainage was very recent, while the obstruction of the MHV and RHV was old. The CL cannot be specifically distinguished on the PRPS summed image or by building dynamic curves on its area, therefore not playing a specific hemodynamic role. The image of the spleen on the summed PRPS image suggests inversion of flow in the splenic vein, while presence of the IVC suggests open per-rectal shunts.

### **BCS with acute onset by simultaneous obstruction of all three HVs (occlusion of terminal portion of the IVC)**

Two of the BCS patients in our study had fulminant symptoms. US and CT scans argued for obstruction of





**Figure 5** Budd-Chiari syndrome with old obstruction of the middle and right hepatic veins also followed by old obstruction of the left hepatic vein. A: Perirectal portal scintigraphy; B: Liver angioscintigraphy; C: Liver scan.

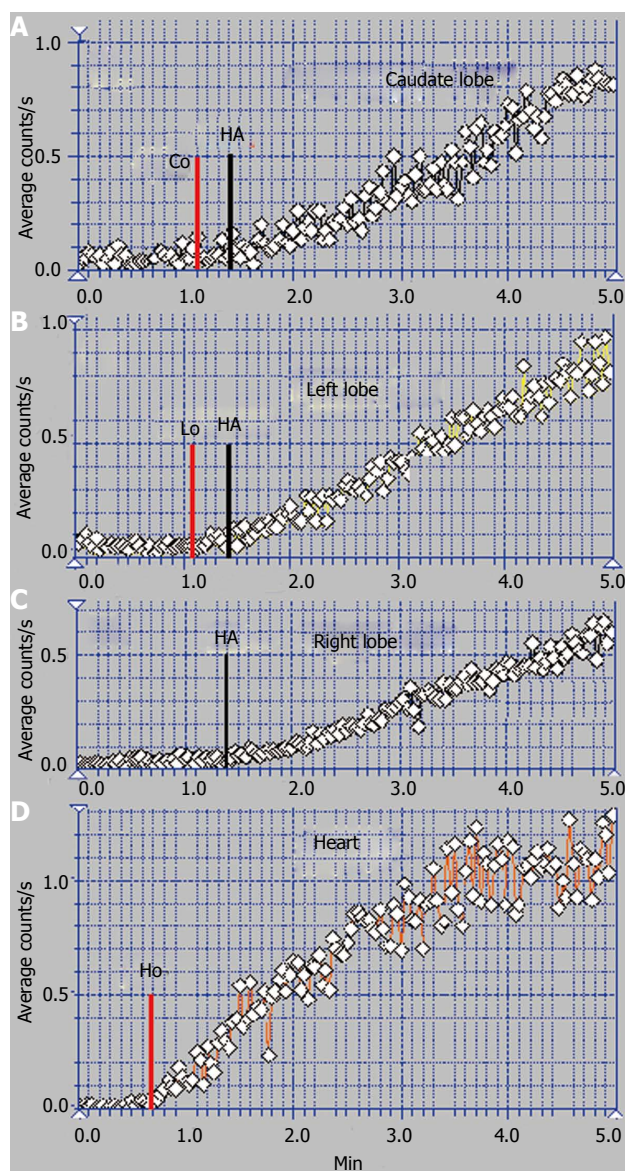
the terminal portion of the IVC in both of them. The data shown in Figure 8 belong to a 39-year-old woman with myeloproliferative disease, admitted for recently appeared severe pain in the upper right abdominal quadrant, with vomiting and encephalopathy signs. US and CT scans showed abundant ascites and significant dilation of the HVs.

PRPS highlights a sharp increase of the transit time of the tracer from entering into the liver to reaching the RH, up to values over 50 s. The amount of tracer passing through the heart during the first 30 s after its arrival was very low, with a flattened PRPS cardiac curve. The normal slope of the PRPS curves built on the liver lobes

show that the dynamic resistance encountered by the portal flow was not significantly increased. The very late arrival to the RH of a small quantity of tracer was determined by the slow transit through the PSS open to the superior vena cava. PRPS highlights the completely blocked venous outflow on the physiological pathway between the liver and the RH, involving all the HVs. The slow flow through the PSS suggested that the obstruction of the terminal portion of the IVC had been recently installed.

## DISCUSSION

We propose a new method to assess the liver hemodynamics



**Figure 6** Per-rectal portal scintigraphy in Budd-Chiari syndrome with old obstruction of the middle and right hepatic veins also followed by old obstruction of the left hepatic vein. A: Caudate lobe curve; B: Left lobe curve; C: Right lobe curve; D: Heart curve.

in the BCS by performing the PRPS and LAS, with auxiliary use of the LS. PRPS is the main investigation, based on the parameters introduced by us, LTT and RHLT, offering information about the portal and arterial flows and the effects of the venous outflow obstruction.

The liver areas missing portal inflow with only arterial perfusion are highlighted at PRPS based on the time interval equal to RHLT between the origins of cardiac and liver curves. The increased arterial perfusion of a liver area causes a high slope of the AUI at PRPS and HPI > 45% at LAS. In old obstructions of the HVs, PRPS shows decreased portal and arterial flows of the parenchyma without venous outflow. In recent obstructions of the HVs, PRPS detects small or inverted portal flow, increased arterial inflow and accumulation of radioactivity on the summed image in the affected area. A high quanti-

ty of radiotracer appears on the summed PRPS image in the CL of the patients with recent common occlusion of two HVs. Inverted flow in the splenic vein is suggested by a visible spleen on the summed PRPS image.

ASH is useful in the differential diagnosis between the BCS and portal obstructions and also in highlighting arterial-venous shunts and increased resistance opposed to the arterial flow. Reverse portal flow is emphasized by HPI > 100%. LS was performed after ASH, showing increased radioactivity in the CL in particular types of BCS. LS aspect of the liver lobes, spleen and spine is useful when viral or alcoholic CLD is suspected.

Several hemodynamic varieties and stages of the BCS were described by using PRPS and LAS. Liver perfusion status is closely related to the initial number of obstructed HVs and to the lengths of occlusions. The category of the BCS debuted by obstruction of one HV included the patients actually affected by one obstructed HV and the patients affected by an old obstruction of one HV followed by recent obstruction of the other two HVs. For the BCS started by obstruction of two HVs we found different perfusion patterns in acute and chronic stages after the obstruction of the third HV. The BCS with acute onset due to the simultaneous obstruction of all the three HVs is commonly caused by obstruction of the terminal part of the IVC and specifically presents in the acute stage highly prolonged LTT at PRPS. Different hemodynamic patterns of the liver flows related to various types of hepatic venous occlusions underline the autonomous regulation of the perfusion of the two liver lobes.

It is important to know in all the varieties and stages of the BCS if PSS are open. PRPS highlighted that PSS were not open in patients with occlusion of one HV. The CL did not play a significant hemodynamic role in the subacute stage of such patients, suggesting that the blood flow redirected from the area without physiological venous outflow was drained through the unaffected HVs. PSS were not open even in the acute stage after common obstruction of two HVs following an old obstruction of the other HV.

Open PSS were emphasized in our cases with old obstruction of two HVs. This finding suggests that the outflow of two HVs is too high to be redirected in chronic stages only through the unaffected HV and through the CL, with having to leave the liver through extrahepatic PSS.

In acute stages after the occlusion of terminal part of the IVC, the PSS draining the blood to the superior vena cava allowed only a low speed flow. Our data suggest that spontaneous effective drainage through PSS requires at least several weeks to open after the obstruction of two or three HVs.

Hypertrophy of the CL is currently underlined in the diagnosis of the BCS. However, the hemodynamic role of the CL looks to be unimportant or transient in several varieties and stages of the BCS. The CL was not involved as an intrahepatic shunt in asymptomatic pa-



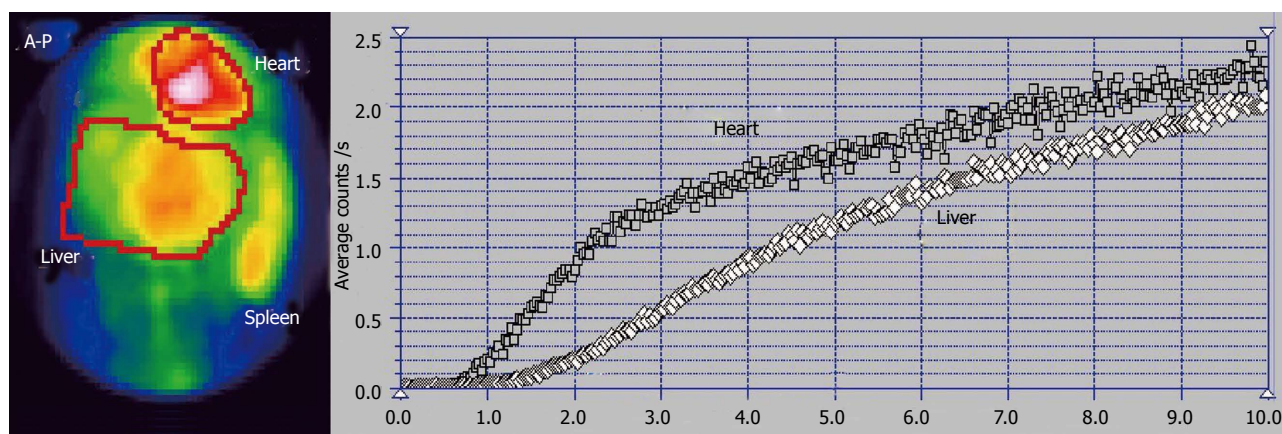


Figure 7 Per-rectal portal scintigraphy of a patient with Budd-Chiari syndrome with old obstruction of the middle and right hepatic veins and recent obstruction of the left hepatic vein.

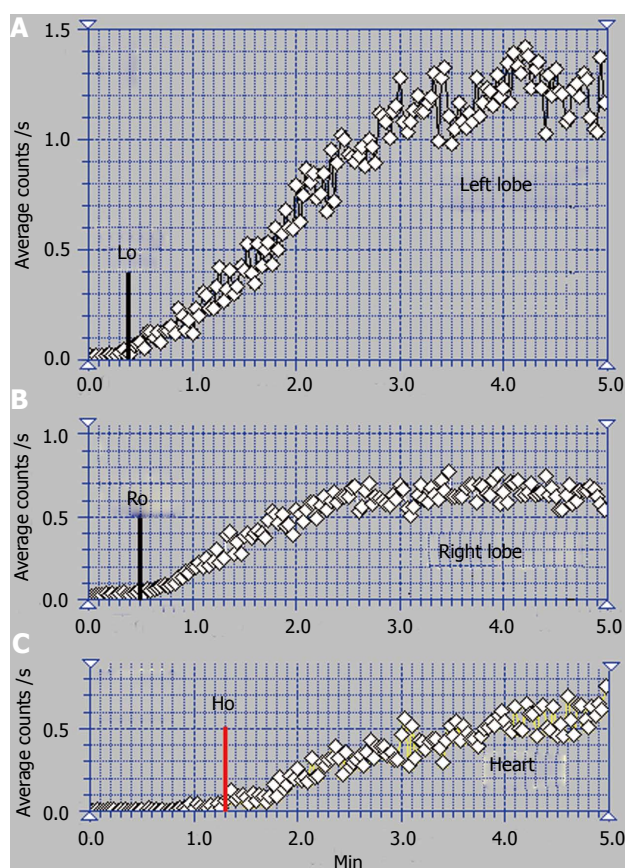


Figure 8 Per-rectal portal scintigraphy in Budd-Chiari syndrome with obstruction of the terminal part of the inferior vena cava. A: Left lobe curve; B: Right lobe curve; C: Heart curve.

tients with obstruction of one HV and in IVC obstructions. In the patients with chronic obstruction of two HVs, the CL had a reduced role of a hemodynamic shunt for part of the arterial flow redistributed from affected areas, presenting arterial-venous collaterals. The CL was highly active in the subacute stage after the obstruction of two HVs following an old occlusion of the third HV. Our study suggests that the CL usually plays an efficient hemodynamic role of intrahepatic shunt to the IVC in

acute or subacute stages and in particular varieties of the BCS. The importance in each case of the caliber and morphology of the CL venous drainage for its functioning as hemodynamic shunt has also to be accounted for.

Due to the rarity of the disease, we did not explore several other theoretical varieties of the BCS so our classification will have to be detailed. Common obstruction of the LHV and MHV, acute stage after the debut of the BCS by obstruction of one or two HVs, and chronic stage after the occlusion of the terminal part of the IVC may bring more information about the opening of PSS and the role of the CL in draining the redirected flows.

To conclude, PRPS associated with LAS are able to play a useful role as second line investigations in the BCS, adding important data to the US, CT or MRI findings. These scintigraphic procedures have reliable costs, are non-invasive and easily reproducible. The accuracy of the method, however, is dependent on the operator's expertise.

## ACKNOWLEDGMENTS

We are grateful to Professors Sabin Cotul and Doru Dejica, to Dr. Liliana Dina and Crina Briciu for their contribution to the development of PRPS and ASH investigations in our laboratory. We are also grateful to the colleagues from the 3<sup>rd</sup> Medical and Surgical Clinics of Cluj-Napoca and especially to the Ultrasound department for their diagnosis in the BCS patients.

## COMMENTS

### Background

Impaired liver perfusion in the Budd-Chiari syndrome is determined by the obstruction of the hepatic blood outflow. Portal and arterial altered flows may be properly explored by combined use of two nuclear medicine dynamic investigations, per-rectal portal scintigraphy and liver angioscintigraphy. Radioisotope techniques allow a more precise diagnosis in different types and stages of the Budd-Chiari syndrome and highlight the changes of perfusion patterns during evolution of the disease.

### Research frontiers

Scintigraphy investigations proposed by us to explore the Budd-Chiari syndrome highlight open portosystemic shunts, liver areas without portal inflow, hemodynamic involvement of the caudate lobe, inverted flow in the splenic or



portal vein and length of the obstructions of the hepatic veins or the terminal portion of the inferior vena cava. The authors described three hemodynamic categories of the Budd-Chiari syndrome with several subtypes and stages, based on the finding that perfusion changes depend on the initial number and succession in time of the hepatic veins obstructions.

### Related publications

The authors previously described the use of dynamic nuclear medicine investigations to evaluate portal hypertension and portosystemic shunts in chronic liver disease. Clinical applications of the liver angioscintigraphy are commonly related to hepatic tumors evaluation.

### Innovations and breakthroughs

The authors introduced a new method of interpretation for the per-rectal portal scintigraphy by proposing two new parameters, the transit time of the portal inflow through the liver and the transit time of the blood from the right heart to the liver. These time parameters allow an accurate description of hepatic hemodynamic changes determined by venous obstructions. The authors used liver angioscintigraphy in the differential diagnosis between the Budd-Chiari syndrome and portal obstructions, highlighting the absence of the hepatic artery buffer response in the Budd-Chiari syndrome. The authors showed that portosystemic shunts are not open after the obstruction of one hepatic vein, while at least several weeks are required in the obstructions of two or three hepatic veins for the spontaneous opening of dynamically efficient portosystemic shunts.

### Applications

The hemodynamic data offered by per-rectal portal scintigraphy and angioscintigraphy of the liver are especially important for surgery and TIPS mounting. Diagnosis of the number, length and succession in time of hepatic veins obstructions allow identification of hemodynamic varieties and stages of the Budd-Chiari syndrome and support an adequate therapeutic approach.

### Terminology

Per-rectal portal scintigraphy is a dynamic procedure performed by instillation into the rectum of a small quantity of radioactive tracer followed by recording its dynamics through the portal vein, liver and heart areas. Liver angioscintigraphy is performed by rapid antecubital intravenous bolus injection of a small quantity of radiotracer followed by recording its entrance into the liver through the hepatic artery and portal vein, allowing the assessment of an arterial to total liver perfusion (arterial plus portal) ratio. The Budd-Chiari syndrome is a vascular liver disease determined by hepatic venous obstruction localized from the small hepatic veins to the terminal part of the inferior vena cava, resulting in increased sinusoidal pressure, hepatic congestion and portal hypertension.

### Peer review

This is a well thought and comprehensive manuscript on the relevance of using PRPS and liver angioscintigraphy techniques to investigate the liver hemodynamics in Budd-Chiari syndrome. The manuscript provides useful and interesting information. It also has potential for clinical application.

## REFERENCES

- Mukund A, Gamanagatti S. Imaging and interventions in Budd-Chiari syndrome. *World J Radiol* 2011; **3**: 169-177 [PMID: 21860712 DOI: 10.4329/wjr.v3.i7.169]
- Plessier A, Valla DC. Budd-Chiari syndrome. *Semin Liver Dis* 2008; **28**: 259-269 [PMID: 18814079 DOI: 10.1055/s-0028-1085094]
- Orloff MJ, Daily PO, Orloff SL, Girard B, Orloff MS. A 27-year experience with surgical treatment of Budd-Chiari syndrome. *Ann Surg* 2000; **232**: 340-352 [PMID: 10973384 DOI: 10.1097/0000658-200009000-00006]
- Darwish Murad S, Plessier A, Hernandez-Guerra M, Fabris F, Eapen CE, Bahr MJ, Trebicka J, Morard I, Lasser L, Heller J, Hadengue A, Langlet P, Miranda H, Primignani M, Elias E, Leebeek FW, Rosendaal FR, Garcia-Pagan JC, Valla DC, Janssen HL; EN-Vie (European Network for Vascular Disorders of the Liver). Etiology, management, and outcome of the Budd-Chiari syndrome. *Ann Intern Med* 2009; **151**: 167-175 [PMID: 19652186 DOI: 10.7326/0003-4819-151-3-200908040-0004]
- Janssen HL, Garcia-Pagan JC, Elias E, Mentha G, Hadengue A, Valla DC. Budd-Chiari syndrome: a review by an expert panel. *J Hepatol* 2003; **38**: 364-371 [PMID: 12586305 DOI: 10.1016/S0168-8278(02)00434-8]
- Valla DC. Primary Budd-Chiari syndrome. *J Hepatol* 2009; **50**: 195-203 [PMID: 19012988 DOI: 10.1016/j.jhep.2008.10.007]
- De Stefano V, Za T, Ciminello A, Betti S, Rossi E. Causes of adult splanchnic vein thrombosis in the mediterranean area. *Mediterr J Hematol Infect Dis* 2011; **3**: e2011063 [PMID: 22220260 DOI: 10.4084/MJHID.2011.063]
- Virman V, Khandelwal N, Kang M, Gulati M, Chawla Y. MDCT venography in the evaluation of inferior vena cava in Budd-Chiari syndrome. *Indian J Gastroenterol* 2009; **28**: 17-23 [PMID: 19529897 DOI: 10.1007/s12664-009-0004-5]
- Loomes DE, Chang A, Webber D, Scudamore CH, Yoshida EM. Acute Budd-Chiari syndrome. *Can J Gastroenterol* 2011; **25**: 302-303 [PMID: 21766087]
- Hadengue A, Poliquin M, Vilgrain V, Belghiti J, Degott C, Erlinger S, Benhamou JP. The changing scene of hepatic vein thrombosis: recognition of asymptomatic cases. *Gastroenterology* 1994; **106**: 1042-1047 [PMID: 8143970]
- Powell-Jackson PR, Ede RJ, Williams R. Budd-Chiari syndrome presenting as fulminant hepatic failure. *Gut* 1986; **27**: 1101-1105 [PMID: 3758822 DOI: 10.1136/gut.27.9.1101]
- Ludwig J, Hashimoto E, McGill DB, van Heerden JA. Classification of hepatic venous outflow obstruction: ambiguous terminology of the Budd-Chiari syndrome. *Mayo Clin Proc* 1990; **65**: 51-55 [PMID: 2296212 DOI: 10.1016/S0025-6196(12)62109-0]
- Fang CH, You JH, Lau WY, Lai EC, Fan YF, Zhong SZ, Li KX, Chen ZX, Su ZH, Bao SS. Anatomical variations of hepatic veins: three-dimensional computed tomography scans of 200 subjects. *World J Surg* 2012; **36**: 120-124 [PMID: 21976007 DOI: 10.1007/s00268-011-1297-y]
- Buhe S, Miyaki T, Saito T, Sawuti A, Terayama H, Naito M, Yi SQ, Itoh M. A study of the accessory hepatic vein to segments VI and VII with a morphological reconsideration of the human liver. *Surg Radiol Anat* 2008; **30**: 201-207 [PMID: 18270648 DOI: 10.1007/s00276-008-0315-8]
- Kamel IR, Lawler LP, Fishman EK. Variations in anatomy of the middle hepatic vein and their impact on formal right hepatectomy. *Abdom Imaging* 2003; **28**: 668-674 [PMID: 14628873 DOI: 10.1007/s00261-002-0088-1]
- Ming YZ, Niu Y, Shao MJ, She XG, Ye QF. Hepatic veins anatomy and piggy-back liver transplantation. *Hepatobiliary Pancreat Dis Int* 2012; **11**: 429-433 [PMID: 22893472 DOI: 10.1016/S1499-3872(12)60203-3]
- Abdalla EK, Vauthey JN, Couinaud C. The caudate lobe of the liver: implications of embryology and anatomy for surgery. *Surg Oncol Clin N Am* 2002; **11**: 835-848 [PMID: 12607574 DOI: 10.1016/S1055-3207(02)00035-2]
- Bargalló X, Gilabert R, Nicolau C, García-Pagán JC, Bosch J, Brú C. Sonography of the caudate vein: value in diagnosing Budd-Chiari syndrome. *AJR Am J Roentgenol* 2003; **181**: 1641-1645 [PMID: 14627589 DOI: 10.2214/ajr.181.6.1811641]
- Boozari B, Bahr MJ, Kubicka S, Klempnauer J, Manns MP, Gebel M. Ultrasonography in patients with Budd-Chiari syndrome: diagnostic signs and prognostic implications. *J Hepatol* 2008; **49**: 572-580 [PMID: 18619699 DOI: 10.1016/j.jhep.2008.04.025]
- Chawla Y, Kumar S, Dhiman RK, Suri S, Dilawari JB. Duplex Doppler sonography in patients with Budd-Chiari syndrome. *J Gastroenterol Hepatol* 1999; **14**: 904-907 [PMID: 10535473 DOI: 10.1046/j.1440-1746.1999.01969.x]
- Zwiebel WJ. Sonographic diagnosis of hepatic vascular disorders. *Semin Ultrasound CT MR* 1995; **16**: 34-48 [PMID: 7718281 DOI: 10.1016/0887-2171(95)90013-6]
- Ralls PW, Johnson MB, Radin DR, Boswell WD, Lee KP, Halls JM. Budd-Chiari syndrome: detection with color Doppler sonography. *AJR Am J Roentgenol* 1992; **159**: 113-116 [PMID: 1609684 DOI: 10.2214/ajr.159.1.1609684]
- Mathieu D, Vasile N, Menu Y, Van Beers B, Lorphelin JM,

- Pringot J. Budd-Chiari syndrome: dynamic CT. *Radiology* 1987; **165**: 409-413 [PMID: 3659365]
- 24 **Wang L**, Lu JP, Wang F, Liu Q, Wang J. Diagnosis of Budd-Chiari syndrome: three-dimensional dynamic contrast enhanced magnetic resonance angiography. *Abdom Imaging* 2011; **36**: 399-406 [PMID: 21399974 DOI: 10.1007/s00261-011-9724-y]
- 25 **Kane R**, Eustace S. Diagnosis of Budd-Chiari syndrome: comparison between sonography and MR angiography. *Radiology* 1995; **195**: 117-121 [PMID: 7892450]
- 26 **Soyer P**, Rabenandrasana A, Barge J, Laissy JP, Zeitoun G, Hay JM, Levesque M. MRI of Budd-Chiari syndrome. *Abdom Imaging* 1994; **19**: 325-329 [PMID: 8075555 DOI: 10.1007/BF00198189]
- 27 **Tang TJ**, Batts KP, de Groen PC, van Hoek B, Haagsma EB, Hop WC, Janssen HL. The prognostic value of histology in the assessment of patients with Budd-Chiari syndrome. *J Hepatol* 2001; **35**: 338-343 [PMID: 11592594 DOI: 10.1016/S0168-8278(01)00131-3]
- 28 **Shiomi S**, Sasaki N, Habu D, Takeda T, Nishiguchi S, Kuroki T, Tanaka T, Ochi H. Natural course of portal hemodynamics in patients with chronic liver diseases, evaluated by per-rectal portal scintigraphy with Tc-99m pertechnetate. *J Gastroenterol* 1998; **33**: 517-522 [PMID: 9719235 DOI: 10.1007/s005350050125]
- 29 **Dragoteanu M**, Cotul SO, Tamas S, Piglesan C. Nuclear medicine dynamic investigations of diffuse chronic liver diseases and portal hypertension. *Rom J Gastroenterol* 2004; **13**: 351-357 [PMID: 15624036]
- 30 **Dragoteanu M**, Balea IA, Dina LA, Piglesan CD, Grigorescu I, Tamas S, Cotul SO. Staging of portal hypertension and portosystemic shunts using dynamic nuclear medicine investigations. *World J Gastroenterol* 2008; **14**: 3841-3848 [PMID: 18609707 DOI: 10.3748/wjg.14.3841]
- 31 **Dragoteanu M**, Cotul SO, Piglesan C, Tamas S. Liver angioscintigraphy: clinical applications. *Rom J Gastroenterol* 2004; **13**: 55-63 [PMID: 15054528]
- 32 **Gupta S**, Barter S, Phillips GW, Gibson RN, Hodgson HJ. Comparison of ultrasonography, computed tomography and 99mTc liver scan in diagnosis of Budd-Chiari syndrome. *Gut* 1987; **28**: 242-247 [PMID: 3552905 DOI: 10.1136/gut.28.3.242]
- 33 **Shiomi S**, Kuroki T, Ueda T, Takeda T, Ikeoka N, Nishiguchi S, Nakajima S, Kobayashi K, Ochi H. Clinical usefulness of evaluation of portal circulation by per rectal portal scintigraphy with technetium-99m pertechnetate. *Am J Gastroenterol* 1995; **90**: 460-465 [PMID: 7872286]
- 34 **Bouvard G**, Bouvard N, Dao T, el Fadel S, Fernandez Y. Value of hepatic angioscintigraphy combined to pulsed Echo-Doppler: application to the study of portal hypertension of cirrhotic patients. Apropos of 148 cases. *Ann Radiol (Paris)* 1991; **34**: 362-368 [PMID: 1822659]
- 35 **Leveson SH**, Wiggins PA, Giles GR, Parkin A, Robinson PJ. Deranged liver blood flow patterns in the detection of liver metastases. *Br J Surg* 1985; **72**: 128-130 [PMID: 3971119 DOI: 10.1002/bjs.1800720220]
- 36 **Lautt WW**. Hepatic Circulation in Health and Disease. NY: Raven Press, 1981: 210-212

**P- Reviewers:** Das UN, Verma S, Yu HP **S- Editor:** Song XX

**L- Editor:** Roemmele A **E- Editor:** Wu HL





## INSTRUCTIONS TO AUTHORS

### GENERAL INFORMATION

*World Journal of Hepatology* (*World J Hepatol*, *WJH*, online ISSN 1948-5182, DOI: 10.4254) is a peer-reviewed open access (OA) academic journal that aims to guide clinical practice and improve diagnostic and therapeutic skills of clinicians.

#### Aim and scope

*WJH* covers topics concerning arrhythmia, heart failure, vascular disease, stroke, hypertension, prevention and epidemiology, dyslipidemia and metabolic disorders, cardiac imaging, pediatrics, nursing, and health promotion. Priority publication will be given to articles concerning diagnosis and treatment of hepatology diseases. The following aspects are covered: Clinical diagnosis, laboratory diagnosis, differential diagnosis, imaging tests, pathological diagnosis, molecular biological diagnosis, immunological diagnosis, genetic diagnosis, functional diagnostics, and physical diagnosis; and comprehensive therapy, drug therapy, surgical therapy, interventional treatment, minimally invasive therapy, and robot-assisted therapy.

We encourage authors to submit their manuscripts to *WJH*. We will give priority to manuscripts that are supported by major national and international foundations and those that are of great basic and clinical significance.

*WJH* is edited and published by Baishideng Publishing Group (BPG). BPG has a strong professional editorial team composed of science editors, language editors and electronic editors. BPG currently publishes 42 OA clinical medical journals, including 41 in English, has a total of 15471 editorial board members or peer reviewers, and is a world first-class publisher.

#### Columns

The columns in the issues of *WJH* will include: (1) Editorial: The editorial board members are invited to make comments on an important topic in their field in terms of its current research status and future directions to lead the development of this discipline; (2) Frontier: The editorial board members are invited to select a highly cited cutting-edge original paper of his/her own to summarize major findings, the problems that have been resolved and remain to be resolved, and future research directions to help readers understand his/her important academic point of view and future research directions in the field; (3) Diagnostic Advances: The editorial board members are invited to write high-quality diagnostic advances in their field to improve the diagnostic skills of readers. The topic covers general clinical diagnosis, differential diagnosis, pathological diagnosis, laboratory diagnosis, imaging diagnosis, endoscopic diagnosis, biotechnological diagnosis, functional diagnosis, and physical diagnosis; (4) Therapeutics Advances: The editorial board members are invited to write high-quality therapeutic advances in their field to help improve the therapeutic skills of readers. The topic covers medication therapy, psychotherapy, physical therapy, replacement therapy, interventional therapy, minimally invasive therapy, endoscopic therapy, transplantation therapy, and surgical therapy; (5) Field of Vision: The editorial board members are invited to write commentaries on classic articles, hot topic articles, or latest articles to keep readers at the forefront of research and increase their levels of clinical research. Classic articles refer to papers that are included in Web of Knowledge and have received a large number of citations (ranking in the top 1%) after being published for more than years, reflecting the quality and impact of papers. Hot topic articles refer to papers that are included in Web of Knowledge and have received a large number of citations after being

published for no more than 2 years, reflecting cutting-edge trends in scientific research. Latest articles refer to the latest published high-quality papers that are included in PubMed, reflecting the latest research trends. These commentary articles should focus on the status quo of research, the most important research topics, the problems that have now been resolved and remain to be resolved, and future research directions. Basic information about the article to be commented (including authors, article title, journal name, year, volume, and inclusive page numbers); (6) Minireviews: The editorial board members are invited to write short reviews on recent advances and trends in research of molecular biology, genomics, and related cutting-edge technologies to provide readers with the latest knowledge and help improve their diagnostic and therapeutic skills; (7) Review: To make a systematic review to focus on the status quo of research, the most important research topics, the problems that have now been resolved and remain to be resolved, and future research directions; (8) Topic Highlight: The editorial board members are invited to write a series of articles (7-10 articles) to comment and discuss a hot topic to help improve the diagnostic and therapeutic skills of readers; (9) Medical Ethics: The editorial board members are invited to write articles about medical ethics to increase readers' knowledge of medical ethics. The topic covers international ethics guidelines, animal studies, clinical trials, organ transplantation, etc.; (10) Clinical Case Conference or Clinicopathological Conference: The editorial board members are invited to contribute high-quality clinical case conference; (11) Original Articles: To report innovative and original findings in hepatology; (12) Brief Articles: To briefly report the novel and innovative findings in hepatology; (13) Meta-Analysis: Covers the systematic review, mixed treatment comparison, meta-regression, and overview of reviews, in order to summarize a given quantitative effect, e.g., the clinical effectiveness and safety of clinical treatments by combining data from two or more randomized controlled trials, thereby providing more precise and externally valid estimates than those which would stem from each individual dataset if analyzed separately from the others; (14) Case Report: To report a rare or typical case; (15) Letters to the Editor: To discuss and make reply to the contributions published in *WJH*, or to introduce and comment on a controversial issue of general interest; (16) Book Reviews: To introduce and comment on quality monographs of hepatology; and (17) Autobiography: The editorial board members are invited to write their autobiography to provide readers with stories of success or failure in their scientific research career. The topic covers their basic personal information and information about when they started doing research work, where and how they did research work, what they have achieved, and their lessons from success or failure.

#### Name of journal

*World Journal of Hepatology*

#### ISSN

ISSN 1948-5182 (online)

#### Launch date

October 31, 2009

#### Frequency

Monthly

#### Editor-in-Chief

Clara Balsano, PhD, Professor, Departement of Biomedicine,



## Instructions to authors

Institute of Molecular Biology and Pathology, Rome 00161, Italy

**Wan-Long Chuang, MD, PhD, Doctor, Professor,** Hepatobiliary Division, Department of Internal Medicine, Kaohsiung Medical University Hospital, Kaohsiung Medical University, Kaohsiung 807, Taiwan

### Editorial office

Jin-Lei Wang, Director  
Xiu-Xia Song, Vice Director  
*World Journal of Hepatology*  
Room 903, Building D, Ocean International Center,  
No. 62 Dongsihuan Zhonglu, Chaoyang District,  
Beijing 100025, China  
Telephone: +86-10-85381891  
Fax: +86-10-85381893  
E-mail: bpgoffice@wjgnet.com  
<http://www.wjgnet.com>

### Publisher

Baishideng Publishing Group Co., Limited  
Flat C, 23/F, Lucky Plaza,  
315-321 Lockhart Road, Wan Chai, Hong Kong, China  
Fax: +852-65557188  
Telephone: +852-31779906  
E-mail: bpgoffice@wjgnet.com  
<http://www.wjgnet.com>

### Production center

Beijing Baishideng BioMed Scientific Co., Limited  
Room 903, Building D, Ocean International Center,  
No. 62 Dongsihuan Zhonglu, Chaoyang District,  
Beijing 100025, China  
Telephone: +86-10-85381892  
Fax: +86-10-85381893

### Representative office

USA Office  
8226 Regency Drive,  
Pleasanton, CA 94588-3144, United States

### Instructions to authors

Full instructions are available online at [http://www.wjgnet.com/1948-5182/g\\_info\\_20100316080002.htm](http://www.wjgnet.com/1948-5182/g_info_20100316080002.htm).

### Indexed and Abstracted in

PubMed Central, PubMed, Digital Object Identifier, Directory of Open Access Journals, and Scopus.

## SPECIAL STATEMENT

All articles published in this journal represent the viewpoints of the authors except where indicated otherwise.

### Biostatistical editing

Statistical review is performed after peer review. We invite an expert in Biomedical Statistics to evaluate the statistical method used in the paper, including *t*-test (group or paired comparisons), chi-squared test, Ridit, probit, logit, regression (linear, curvilinear, or stepwise), correlation, analysis of variance, analysis of covariance, *etc.* The reviewing points include: (1) Statistical methods should be described when they are used to verify the results; (2) Whether the statistical techniques are suitable or correct; (3) Only homogeneous data can be averaged. Standard deviations are preferred to standard errors. Give the number of observations and subjects (*n*). Losses in observations, such as drop-outs from the study should be reported; (4) Values such as ED50, LD50, IC50 should have their 95% confidence limits calculated and compared by weighted probit analysis (Bliss and Finney); and (5) The word 'significantly' should be replaced by its synonyms (if it indicates extent) or the *P* value (if it indicates statistical significance).

### Conflict-of-interest statement

In the interests of transparency and to help reviewers assess any potential bias, *WJH* requires authors of all papers to declare any competing commercial, personal, political, intellectual, or religious interests in relation to the submitted work. Referees are also asked to indicate any potential conflict they might have reviewing a particular paper. Before submitting, authors are suggested to read "Uniform Requirements for Manuscripts Submitted to Biomedical Journals: Ethical Considerations in the Conduct and Reporting of Research: Conflicts of Interest" from International Committee of Medical Journal Editors (ICMJE), which is available at: [http://www.icmje.org/ethical\\_4conflicts.html](http://www.icmje.org/ethical_4conflicts.html).

Sample wording: [Name of individual] has received fees for serving as a speaker, a consultant and an advisory board member for [names of organizations], and has received research funding from [names of organization]. [Name of individual] is an employee of [name of organization]. [Name of individual] owns stocks and shares in [name of organization]. [Name of individual] owns patent [patent identification and brief description].

### Statement of informed consent

Manuscripts should contain a statement to the effect that all human studies have been reviewed by the appropriate ethics committee or it should be stated clearly in the text that all persons gave their informed consent prior to their inclusion in the study. Details that might disclose the identity of the subjects under study should be omitted. Authors should also draw attention to the Code of Ethics of the World Medical Association (Declaration of Helsinki, 1964, as revised in 2004).

### Statement of human and animal rights

When reporting the results from experiments, authors should follow the highest standards and the trial should conform to Good Clinical Practice (for example, US Food and Drug Administration Good Clinical Practice in FDA-Regulated Clinical Trials; UK Medicines Research Council Guidelines for Good Clinical Practice in Clinical Trials) and/or the World Medical Association Declaration of Helsinki. Generally, we suggest authors follow the lead investigator's national standard. If doubt exists whether the research was conducted in accordance with the above standards, the authors must explain the rationale for their approach and demonstrate that the institutional review body explicitly approved the doubtful aspects of the study.

Before submitting, authors should make their study approved by the relevant research ethics committee or institutional review board. If human participants were involved, manuscripts must be accompanied by a statement that the experiments were undertaken with the understanding and appropriate informed consent of each. Any personal item or information will not be published without explicit consents from the involved patients. If experimental animals were used, the materials and methods (experimental procedures) section must clearly indicate that appropriate measures were taken to minimize pain or discomfort, and details of animal care should be provided.

## SUBMISSION OF MANUSCRIPTS

Manuscripts should be typed in 1.5 line spacing and 12 pt. Book Antiqua with ample margins. Number all pages consecutively, and start each of the following sections on a new page: Title Page, Abstract, Introduction, Materials and Methods, Results, Discussion, Acknowledgements, References, Tables, Figures, and Figure Legends. Neither the editors nor the publisher are responsible for the opinions expressed by contributors. Manuscripts formally accepted for publication become the permanent property of Baishideng Publishing Group Co., Limited, and may not be reproduced by any means, in whole or in part, without the written permission of both the authors and the publisher. We reserve the right to copy-edit and put onto our website accepted manuscripts. Authors should follow the relevant guidelines for the care and use of laboratory animals of their institution or national animal welfare committee. For the sake of transparency in regard to the performance and reporting of clinical trials, we endorse the policy of the ICMJE to refuse to publish papers on clinical trial results if the trial was not recorded in a publicly-accessible registry at its outset. The only register now

available, to our knowledge, is <http://www.clinicaltrials.gov> sponsored by the United States National Library of Medicine and we encourage all potential contributors to register with it. However, in the case that other registers become available you will be duly notified. A letter of recommendation from each author's organization should be provided with the contributed article to ensure the privacy and secrecy of research is protected.

Authors should retain one copy of the text, tables, photographs and illustrations because rejected manuscripts will not be returned to the author(s) and the editors will not be responsible for loss or damage to photographs and illustrations sustained during mailing.

### Online submissions

Manuscripts should be submitted through the Online Submission System at: <http://www.wjnet.com/esps/>. Authors are highly recommended to consult the ONLINE INSTRUCTIONS TO AUTHORS ([http://www.wjnet.com/1948-5182/g\\_info\\_20100316080002.htm](http://www.wjnet.com/1948-5182/g_info_20100316080002.htm)) before attempting to submit online. For assistance, authors encountering problems with the Online Submission System may send an email describing the problem to [bpgoffice@wjnet.com](mailto:bpgoffice@wjnet.com), or by telephone: +86-10-85381892. If you submit your manuscript online, do not make a postal contribution. Repeated online submission for the same manuscript is strictly prohibited.

## MANUSCRIPT PREPARATION

All contributions should be written in English. All articles must be submitted using word-processing software. All submissions must be typed in 1.5 line spacing and 12 pt. Book Antiqua with ample margins. Style should conform to our house format. Required information for each of the manuscript sections is as follows:

### Title page

**Title:** Title should be less than 12 words.

**Running title:** A short running title of less than 6 words should be provided.

**Authorship:** Authorship credit should be in accordance with the standard proposed by ICMJE, based on (1) substantial contributions to conception and design, acquisition of data, or analysis and interpretation of data; (2) drafting the article or revising it critically for important intellectual content; and (3) final approval of the version to be published. Authors should meet conditions 1, 2, and 3.

**Institution:** Author names should be given first, then the complete name of institution, city, province and postcode. For example, Xu-Chen Zhang, Li-Xin Mei, Department of Pathology, Chengde Medical College, Chengde 067000, Hebei Province, China. One author may be represented from two institutions, for example, George Sgourakis, Department of General, Visceral, and Transplantation Surgery, Essen 45122, Germany; George Sgourakis, 2nd Surgical Department, Korgialenio-Benakio Red Cross Hospital, Athens 15451, Greece

**Author contributions:** The format of this section should be: Author contributions: Wang CL and Liang L contributed equally to this work; Wang CL, Liang L, Fu JF, Zou CC, Hong F and Wu XM designed the research; Wang CL, Zou CC, Hong F and Wu XM performed the research; Xue JZ and Lu JR contributed new reagents/analytic tools; Wang CL, Liang L and Fu JF analyzed the data; and Wang CL, Liang L and Fu JF wrote the paper.

**Supportive foundations:** The complete name and number of supportive foundations should be provided, e.g. Supported by National Natural Science Foundation of China, No. 30224801

**Correspondence to:** Only one corresponding address should be provided. Author names should be given first, then author title, affiliation, the complete name of institution, city, postcode, province,

country, and email. All the letters in the email should be in lower case. A space interval should be inserted between country name and email address. For example, Montgomery Bissell, MD, Professor of Medicine, Chief, Liver Center, Gastroenterology Division, University of California, Box 0538, San Francisco, CA 94143, United States. [montgomery.bissell@ucsf.edu](mailto:montgomery.bissell@ucsf.edu)

**Telephone and fax:** Telephone and fax should consist of +, country number, district number and telephone or fax number, e.g. Telephone: +86-10-85381892 Fax: +86-10-85381893

**Peer reviewers:** All articles received are subject to peer review. Normally, three experts are invited for each article. Decision on acceptance is made only when at least two experts recommend publication of an article. All peer-reviewers are acknowledged on Express Submission and Peer-review System website.

### Abstract

There are unstructured abstracts (no less than 200 words) and structured abstracts. The specific requirements for structured abstracts are as follows:

An informative, structured abstract should accompany each manuscript. Abstracts of original contributions should be structured into the following sections: AIM (no more than 20 words; Only the purpose of the study should be included. Please write the Aim in the form of "To investigate/study/..."), METHODS (no less than 140 words for Original Articles; and no less than 80 words for Brief Articles), RESULTS (no less than 150 words for Original Articles and no less than 120 words for Brief Articles; You should present *P* values where appropriate and must provide relevant data to illustrate how they were obtained, e.g.,  $6.92 \pm 3.86$  vs  $3.61 \pm 1.67$ ,  $P < 0.001$ ), and CONCLUSION (no more than 26 words).

### Key words

Please list 5-10 key words, selected mainly from *Index Medicus*, which reflect the content of the study.

### Core tip

Please write a summary of less than 100 words to outline the most innovative and important arguments and core contents in your paper to attract readers.

### Text

For articles of these sections, original articles and brief articles, the main text should be structured into the following sections: INTRODUCTION, MATERIALS AND METHODS, RESULTS and DISCUSSION, and should include appropriate Figures and Tables. Data should be presented in the main text or in Figures and Tables, but not in both.

### Illustrations

Figures should be numbered as 1, 2, 3, etc., and mentioned clearly in the main text. Provide a brief title for each figure on a separate page. Detailed legends should not be provided under the figures. This part should be added into the text where the figures are applicable. Keeping all elements compiled is necessary in line-art image. Scale bars should be used rather than magnification factors, with the length of the bar defined in the legend rather than on the bar itself. File names should identify the figure and panel. Avoid layering type directly over shaded or textured areas. Please use uniform legends for the same subjects. For example: Figure 1 Pathological changes in atrophic gastritis after treatment. A: ...; B: ...; C: ...; D: ...; E: ...; F: ...; G: ... etc. It is our principle to publish high resolution-figures for the E-versions.

### Tables

Three-line tables should be numbered 1, 2, 3, etc., and mentioned clearly in the main text. Provide a brief title for each table. Detailed legends should not be included under tables, but rather added into the text where applicable. The information should complement, but not duplicate the text. Use one horizontal line under the title, a

## Instructions to authors

second under column heads, and a third below the Table, above any footnotes. Vertical and italic lines should be omitted.

### Notes in tables and illustrations

Data that are not statistically significant should not be noted. <sup>a</sup> $P < 0.05$ , <sup>b</sup> $P < 0.01$  should be noted ( $P > 0.05$  should not be noted). If there are other series of  $P$  values, <sup>c</sup> $P < 0.05$  and <sup>d</sup> $P < 0.01$  are used. A third series of  $P$  values can be expressed as <sup>e</sup> $P < 0.05$  and <sup>f</sup> $P < 0.01$ . Other notes in tables or under illustrations should be expressed as <sup>1</sup>F, <sup>2</sup>F, <sup>3</sup>F; or sometimes as other symbols with a superscript (Arabic numerals) in the upper left corner. In a multi-curve illustration, each curve should be labeled with ●, ○, ■, □, ▲, △, etc., in a certain sequence.

### Acknowledgments

Brief acknowledgments of persons who have made genuine contributions to the manuscript and who endorse the data and conclusions should be included. Authors are responsible for obtaining written permission to use any copyrighted text and/or illustrations.

## REFERENCES

### Coding system

The author should number the references in Arabic numerals according to the citation order in the text. Put reference numbers in square brackets in superscript at the end of citation content or after the cited author's name. For citation content which is part of the narration, the coding number and square brackets should be typeset normally. For example, "Crohn's disease (CD) is associated with increased intestinal permeability<sup>[1,2]</sup>". If references are cited directly in the text, they should be put together within the text, for example, "From references<sup>[19,22-24]</sup>, we know that..."

When the authors write the references, please ensure that the order in text is the same as in the references section, and also ensure the spelling accuracy of the first author's name. Do not list the same citation twice.

### PMID and DOI

Please provide PubMed citation numbers to the reference list, e.g. PMID and DOI, which can be found at <http://www.ncbi.nlm.nih.gov/sites/entrez?db=pubmed> and <http://www.crossref.org/SimpleTextQuery/>, respectively. The numbers will be used in E-version of this journal.

### Style for journal references

Authors: the name of the first author should be typed in bold-faced letters. The family name of all authors should be typed with the initial letter capitalized, followed by their abbreviated first and middle initials. (For example, Lian-Sheng Ma is abbreviated as Ma LS, Bo-Rong Pan as Pan BR). The title of the cited article and italicized journal title (journal title should be in its abbreviated form as shown in PubMed), publication date, volume number (in black), start page, and end page [PMID: 11819634 DOI: 10.3748/wjg.13.5396].

### Style for book references

Authors: the name of the first author should be typed in bold-faced letters. The surname of all authors should be typed with the initial letter capitalized, followed by their abbreviated middle and first initials. (For example, Lian-Sheng Ma is abbreviated as Ma LS, Bo-Rong Pan as Pan BR) Book title. Publication number. Publication place: Publication press, Year: start page and end page.

### Format

#### Journals

English journal article (list all authors and include the PMID where applicable)

- 1 **Jung EM**, Clevert DA, Schreyer AG, Schmitt S, Rennert J, Kubale R, Feuerbach S, Jung F. Evaluation of quantitative contrast harmonic imaging to assess malignancy of liver tumors: A prospective controlled two-center study. *World J Gastroenterol* 2007; **13**: 6356-6364 [PMID: 18081224 DOI: 10.3748/wjg.13.6356]

Chinese journal article (list all authors and include the PMID where applicable)

- 2 **Lin GZ**, Wang XZ, Wang P, Lin J, Yang FD. Immunologic effect of Jianpi Yishen decoction in treatment of Pixu-diarrhoea. *Shijie Huaren Xiaobua Zazhi* 1999; **7**: 285-287

In press

- 3 **Tian D**, Araki H, Stahl E, Bergelson J, Kreitman M. Signature of balancing selection in Arabidopsis. *Proc Natl Acad Sci USA* 2006; In press

Organization as author

- 4 **Diabetes Prevention Program Research Group**. Hypertension, insulin, and proinsulin in participants with impaired glucose tolerance. *Hypertension* 2002; **40**: 679-686 [PMID: 12411462 PMID:2516377 DOI:10.1161/01.HYP.0000035706.28494.09]

Both personal authors and an organization as author

- 5 **Vallancien G**, Emberton M, Harving N, van Moorselaar RJ; Alf-One Study Group. Sexual dysfunction in 1, 274 European men suffering from lower urinary tract symptoms. *J Urol* 2003; **169**: 2257-2261 [PMID: 12771764 DOI:10.1097/01.ju.0000067940.76090.73]

No author given

- 6 21st century heart solution may have a sting in the tail. *BMJ* 2002; **325**: 184 [PMID: 12142303 DOI:10.1136/bmj.325.7357.184]

Volume with supplement

- 7 **Geraud G**, Spierings EL, Keywood C. Tolerability and safety of frovatriptan with short- and long-term use for treatment of migraine and in comparison with sumatriptan. *Headache* 2002; **42** Suppl 2: S93-99 [PMID: 12028325 DOI:10.1046/j.1526-4610.42.s2.7.x]

Issue with no volume

- 8 **Banit DM**, Kaufer H, Hartford JM. Intraoperative frozen section analysis in revision total joint arthroplasty. *Clin Orthop Relat Res* 2002; **(401)**: 230-238 [PMID: 12151900 DOI:10.1097/00003086-200208000-00026]

No volume or issue

- 9 Outreach: Bringing HIV-positive individuals into care. *HRS-A Careaction* 2002; 1-6 [PMID: 12154804]

### Books

Personal author(s)

- 10 **Sherlock S**, Dooley J. Diseases of the liver and biliary system. 9th ed. Oxford: Blackwell Sci Pub, 1993: 258-296

Chapter in a book (list all authors)

- 11 **Lam SK**. Academic investigator's perspectives of medical treatment for peptic ulcer. In: Swabb EA, Azabo S. Ulcer disease: investigation and basis for therapy. New York: Marcel Dekker, 1991: 431-450

Author(s) and editor(s)

- 12 **Breedlove GK**, Schorfheide AM. Adolescent pregnancy. 2nd ed. Wiczorek RR, editor. White Plains (NY): March of Dimes Education Services, 2001: 20-34

Conference proceedings

- 13 **Harnden P**, Joffe JK, Jones WG, editors. Germ cell tumours V. Proceedings of the 5th Germ cell tumours Conference; 2001 Sep 13-15; Leeds, UK. New York: Springer, 2002: 30-56

Conference paper

- 14 **Christensen S**, Oppacher F. An analysis of Koza's computational effort statistic for genetic programming. In: Foster JA, Lutton E, Miller J, Ryan C, Tettamanzi AG, editors. Genetic programming. EuroGP 2002: Proceedings of the 5th European Conference on Genetic Programming; 2002 Apr 3-5; Kinsdale, Ireland. Berlin: Springer, 2002: 182-191

Electronic journal (list all authors)

- 15 Morse SS. Factors in the emergence of infectious diseases. Emerg Infect Dis serial online, 1995-01-03, cited 1996-06-05; 1(1): 24 screens. Available from: URL: <http://www.cdc.gov/ncidod/eid/index.htm>

Patent (list all authors)

- 16 **Pagedas AC**, inventor; Ancel Surgical R&D Inc., assignee. Flexible endoscopic grasping and cutting device and positioning tool assembly. United States patent US 20020103498. 2002 Aug 1



**Statistical data**

Write as mean  $\pm$  SD or mean  $\pm$  SE.

**Statistical expression**

Express *t* test as *t* (in italics), *F* test as *F* (in italics), chi square test as  $\chi^2$  (in Greek), related coefficient as *r* (in italics), degree of freedom as *ν* (in Greek), sample number as *n* (in italics), and probability as *P* (in italics).

**Units**

Use SI units. For example: body mass, *m* (B) = 78 kg; blood pressure, *p* (B) = 16.2/12.3 kPa; incubation time, *t* (incubation) = 96 h, blood glucose concentration, *c* (glucose)  $6.4 \pm 2.1$  mmol/L; blood CEA mass concentration, *p* (CEA) = 8.6  $24.5 \mu\text{g/L}$ ; CO<sub>2</sub> volume fraction, 50 mL/L CO<sub>2</sub>, not 5% CO<sub>2</sub>; likewise for 40 g/L formaldehyde, not 10% formalin; and mass fraction, 8 ng/g, *etc.* Arabic numerals such as 23, 243, 641 should be read 23243641.

The format for how to accurately write common units and quantum numbers can be found at: [http://www.wjgnet.com/1948-5182/g\\_info\\_20100107115140.htm](http://www.wjgnet.com/1948-5182/g_info_20100107115140.htm).

**Abbreviations**

Standard abbreviations should be defined in the abstract and on first mention in the text. In general, terms should not be abbreviated unless they are used repeatedly and the abbreviation is helpful to the reader. Permissible abbreviations are listed in Units, Symbols and Abbreviations: A Guide for Biological and Medical Editors and Authors (Ed. Baron DN, 1988) published by The Royal Society of Medicine, London. Certain commonly used abbreviations, such as DNA, RNA, HIV, LD50, PCR, HBV, ECG, WBC, RBC, CT, ESR, CSF, IgG, ELISA, PBS, ATP, EDTA, mAb, can be used directly without further explanation.

**Italics**

Quantities: *t* time or temperature, *c* concentration, *A* area, *l* length, *m* mass, *V* volume.

Genotypes: *gyrA*, *arg 1*, *c myc*, *c fos*, *etc.*

Restriction enzymes: *EcoRI*, *HindI*, *BamHI*, *Kho I*, *Kpn I*, *etc.*

Biology: *H. pylori*, *E. coli*, *etc.*

**Examples for paper writing**

All types of articles' writing style and requirement will be found in the link: <http://www.wjgnet.com/esps/NavigationInfo.aspx?id=15>

## RESUBMISSION OF THE REVISED MANUSCRIPTS

Authors must revise their manuscript carefully according to the

revision policies of Baishideng Publishing Group Co., Limited. The revised version, along with the signed copyright transfer agreement, responses to the reviewers, and English language Grade A certificate (for non-native speakers of English), should be submitted to the online system *via* the link contained in the e-mail sent by the editor. If you have any questions about the revision, please send e-mail to [esps@wjgnet.com](mailto:esps@wjgnet.com).

**Language evaluation**

The language of a manuscript will be graded before it is sent for revision. (1) Grade A: priority publishing; (2) Grade B: minor language polishing; (3) Grade C: a great deal of language polishing needed; and (4) Grade D: rejected. Revised articles should reach Grade A.

**Copyright assignment form**

Please download a Copyright assignment form from [http://www.wjgnet.com/1948-5182/g\\_info\\_20100107114726.htm](http://www.wjgnet.com/1948-5182/g_info_20100107114726.htm).

**Responses to reviewers**

Please revise your article according to the comments/suggestions provided by the reviewers. The format for responses to the reviewers' comments can be found at: [http://www.wjgnet.com/1948-5182/g\\_info\\_20100107114601.htm](http://www.wjgnet.com/1948-5182/g_info_20100107114601.htm).

**Proof of financial support**

For papers supported by a foundation, authors should provide a copy of the approval document and serial number of the foundation.

## STATEMENT ABOUT ANONYMOUS PUBLICATION OF THE PEER REVIEWERS' COMMENTS

In order to increase the quality of peer review, push authors to carefully revise their manuscripts based on the peer reviewers' comments, and promote academic interactions among peer reviewers, authors and readers, we decide to anonymously publish the reviewers' comments and author's responses at the same time the manuscript is published online.

**PUBLICATION FEE**

*WJH* is an international, peer-reviewed, OA online journal. Articles published by this journal are distributed under the terms of the Creative Commons Attribution Non-commercial License, which permits use, distribution, and reproduction in any medium and format, provided the original work is properly cited. The use is non-commercial and is otherwise in compliance with the license. Authors of accepted articles must pay a publication fee. Publication fee: 698 USD per article. All invited articles are published free of charge.



百世登  
**Baishideng**®

Published by **Baishideng Publishing Group Co., Limited**

Flat C, 23/F., Lucky Plaza,

315-321 Lockhart Road, Wan Chai, Hong Kong, China

Fax: +852-65557188

Telephone: +852-31779906

E-mail: [bpgoffice@wjgnet.com](mailto:bpgoffice@wjgnet.com)

<http://www.wjgnet.com>

