

# World Journal of *Hepatology*

*World J Hepatol* 2018 March 27; 10(3): 352-401



**REVIEW**

- 352 Reactivation of hepatitis B after liver transplantation: Current knowledge, molecular mechanisms and implications in management

*Chauhan R, Lingala S, Gadiparthi C, Lahiri N, Mohanty SR, Wu J, Michalak TI, Satapathy SK*

**MINIREVIEWS**

- 371 Metabolomics: From liver chiromancy to personalized precision medicine in advanced chronic liver disease

*Procopet B, Fischer P, Farcau O, Stefanescu H*

**ORIGINAL ARTICLE****Observational Study**

- 379 Management of restless legs syndrome in chronic liver disease: A challenge for the correct diagnosis and therapy

*Moretti R, Caruso P, Tecchiolli M, Gazzin S, Tiribelli C*

**CASE REPORT**

- 388 *Clostridium paraputrificum* septicemia and liver abscess

*Kwon YK, Cheema FA, Maneckshana BT, Rochon C, Sheiner PA*

- 396 Liver failure caused by prolonged state of malnutrition following bariatric surgery

*Lammers WJ, van Tilburg AJP, Apers JA, Wiebolt J*

**LETTERS TO THE EDITOR**

- 400 Do Ayurveda drugs induce liver injury?

*Ruknuddin G*

**ABOUT COVER**

Editorial Board Member of *World Journal of Hepatology*, Jong Won Yun, PhD, Professor, Department of Biotechnology, Daegu University, Kyungsan 712-714, South Korea

**AIM AND SCOPE**

*World Journal of Hepatology* (*World J Hepatol*, *WJH*, online ISSN 1948-5182, DOI: 10.4254), is a peer-reviewed open access academic journal that aims to guide clinical practice and improve diagnostic and therapeutic skills of clinicians.

*WJH* covers topics concerning liver biology/pathology, cirrhosis and its complications, liver fibrosis, liver failure, portal hypertension, hepatitis B and C and inflammatory disorders, steatohepatitis and metabolic liver disease, hepatocellular carcinoma, biliary tract disease, autoimmune disease, cholestatic and biliary disease, transplantation, genetics, epidemiology, microbiology, molecular and cell biology, nutrition, geriatric and pediatric hepatology, diagnosis and screening, endoscopy, imaging, and advanced technology. Priority publication will be given to articles concerning diagnosis and treatment of hepatology diseases. The following aspects are covered: Clinical diagnosis, laboratory diagnosis, differential diagnosis, imaging tests, pathological diagnosis, molecular biological diagnosis, immunological diagnosis, genetic diagnosis, functional diagnostics, and physical diagnosis; and comprehensive therapy, drug therapy, surgical therapy, interventional treatment, minimally invasive therapy, and robot-assisted therapy.

We encourage authors to submit their manuscripts to *WJH*. We will give priority to manuscripts that are supported by major national and international foundations and those that are of great basic and clinical significance.

**INDEXING/ABSTRACTING**

*World Journal of Hepatology* is now indexed in Emerging Sources Citation Index (Web of Science), PubMed, PubMed Central, and Scopus.

**EDITORS FOR THIS ISSUE**

Responsible Assistant Editor: *Xiang Li*  
Responsible Electronic Editor: *Xiu-Xia Song*  
Proofing Editor-in-Chief: *Lian-Sheng Ma*

Responsible Science Editor: *Li-Jun Cui*  
Proofing Editorial Office Director: *Ze-Mao Gong*

**NAME OF JOURNAL**  
*World Journal of Hepatology*

**ISSN**  
ISSN 1948-5182 (online)

**LAUNCH DATE**  
October 31, 2009

**FREQUENCY**  
Monthly

**EDITOR-IN-CHIEF**  
**Wan-Long Chuang, MD, PhD, Doctor, Professor,**  
Hepatobiliary Division, Department of Internal Medicine, Kaohsiung Medical University Hospital, Kaohsiung Medical University, Kaohsiung 807, Taiwan

**EDITORIAL BOARD MEMBERS**  
All editorial board members resources online at <http://www.wjgnet.com/1948-5182/editorialboard.htm>

**EDITORIAL OFFICE**  
Xiu-Xia Song, Director

*World Journal of Hepatology*  
Baishideng Publishing Group Inc  
7901 Stoneridge Drive, Suite 501,  
Pleasanton, CA 94588, USA  
Telephone: +1-925-2238242  
Fax: +1-925-2238243  
E-mail: [editorialoffice@wjgnet.com](mailto:editorialoffice@wjgnet.com)  
Help Desk: <http://www.f6publishing.com/helpdesk>  
<http://www.wjgnet.com>

**PUBLISHER**  
Baishideng Publishing Group Inc  
7901 Stoneridge Drive, Suite 501,  
Pleasanton, CA 94588, USA  
Telephone: +1-925-2238242  
Fax: +1-925-2238243  
E-mail: [bpgoffice@wjgnet.com](mailto:bpgoffice@wjgnet.com)  
Help Desk: <http://www.f6publishing.com/helpdesk>  
<http://www.wjgnet.com>

**PUBLICATION DATE**  
March 27, 2018

**COPYRIGHT**

© 2018 Baishideng Publishing Group Inc. Articles published by this Open Access journal are distributed under the terms of the Creative Commons Attribution Non-commercial License, which permits use, distribution, and reproduction in any medium, provided the original work is properly cited, the use is non commercial and is otherwise in compliance with the license.

**SPECIAL STATEMENT**

All articles published in journals owned by the Baishideng Publishing Group (BPG) represent the views and opinions of their authors, and not the views, opinions or policies of the BPG, except where otherwise explicitly indicated.

**INSTRUCTIONS TO AUTHORS**

<http://www.wjgnet.com/bpg/gerinfo/204>

**ONLINE SUBMISSION**

<http://www.f6publishing.com>

## Reactivation of hepatitis B after liver transplantation: Current knowledge, molecular mechanisms and implications in management

Ranjit Chauhan, Shilpa Lingala, Chiranjeevi Gadiparthi, Nivedita Lahiri, Smruti R Mohanty, Jian Wu, Tomasz I Michalak, Sanjaya K Satapathy

Ranjit Chauhan, Tomasz I Michalak, Molecular Virology and Hepatology Research Group, Division of BioMedical Sciences, Health Sciences Centre, Memorial University, St. John's, NL A1B 3V6, Canada

Shilpa Lingala, Chiranjeevi Gadiparthi, Sanjaya K Satapathy, Division of Transplant Surgery, Methodist University Hospital Transplant Institute, University of Tennessee Health Sciences Center, Memphis, TN 38104, United States

Nivedita Lahiri, Division of Rheumatology, Immunology and Allergy, Brigham Women's Hospital, Harvard Medical School, Boston, MA 02115, United States

Smruti R Mohanty, Division of Gastroenterology and Hepatobiliary Disease, New York-Presbyterian Brooklyn Methodist Hospital, Brooklyn, NY 11215, United States

Jian Wu, Department of Medical Microbiology, Key Laboratory of Molecular Virology, Fudan University School of Basic Medical Sciences, Shanghai 200032, China

ORCID number: Ranjit Chauhan (0000-0003-1682-0460); Shilpa Lingala (0000-0001-8219-2971); Chiranjeevi Gadiparthi (0000-0002-8905-6742); Nivedita Lahiri (0000-0002-7103-0202); Smruti R Mohanty (0000-0003-4887-5837); Jian Wu (0000-0001-9933-7364); Tomasz I Michalak (0000-0003-1438-0588); Sanjaya K Satapathy (0000-0003-0153-2829).

**Author contributions:** Chauhan R, Lingala S and Gadiparthi C wrote the first draft; Chauhan R, Lingala S and Satapathy SK revised the manuscript with intellectual input from Lahiri N, Mohanty SR, Wu J and Michalak TI; all authors participated in additional discussions and revision of the manuscript.

**Conflict-of-interest statement:** All authors declare no potential conflicts of interest related to this manuscript. This manuscript is not supported by any grants/funding.

**Open-Access:** This article is an open-access article which was selected by an in-house editor and fully peer-reviewed by external reviewers. It is distributed in accordance with the Creative

Commons Attribution Non Commercial (CC BY-NC 4.0) license, which permits others to distribute, remix, adapt, build upon this work non-commercially, and license their derivative works on different terms, provided the original work is properly cited and the use is non-commercial. See: <http://creativecommons.org/licenses/by-nc/4.0/>

**Manuscript source:** Invited manuscript

**Correspondence to:** Sanjaya K Satapathy, MBBS, MD, DM, FACP, FASGE, AGAF, Associate Professor, Division of Transplant Surgery, Methodist University Hospital, University of Tennessee Health Sciences Center, 1211 Union Avenue, Suite #340, Memphis, TN 38104, United States. [ssatapat@uthsc.edu](mailto:ssatapat@uthsc.edu)  
**Telephone:** +1-901-5160929  
**Fax:** +1-901-5168994

**Received:** October 16, 2017

**Peer-review started:** November 2, 2017

**First decision:** November 27, 2017

**Revised:** January 27, 2018

**Accepted:** February 9, 2018

**Article in press:** February 9, 2018

**Published online:** March 27, 2018

### Abstract

Chronic hepatitis B (CHB) is a major global health problem affecting an estimated 350 million people with more than 786000 individuals dying annually due to complications, such as cirrhosis, liver failure and hepatocellular carcinoma (HCC). Liver transplantation (LT) is considered gold standard for treatment of hepatitis B virus (HBV)-related liver failure and HCC. However, post-transplant viral reactivation can be detrimental to allograft function, leading to poor survival. Prophylaxis with high-dose hepatitis B immunoglobulin (HBIG) and anti-viral drugs have achieved remarkable progress in LT by suppressing

viral replication and improving long-term survival. The combination of lamivudine (LAM) plus HBIG has been for many years the most widely used. However, life-long HBIG use is both cumbersome and costly, whereas long-term use of LAM results in resistant virus. Recently, in an effort to develop HBIG-free protocols, high potency nucleos(t)ide analogues, such as Entecavir or Tenofovir, have been tried either as monotherapy or in combination with low-dose HBIG with excellent results. Current focus is on novel antiviral targets, especially for covalently closed circular DNA (cccDNA), in an effort to eradicate HBV infection instead of viral suppression. However, there are several other molecular mechanisms through which HBV may reactivate and need equal attention. The purpose of this review is to address post-LT HBV reactivation, its risk factors, underlying molecular mechanisms, and recent advancements and future of anti-viral therapy.

**Key words:** Hepatitis B virus; Liver transplantation; Reactivation; Hepatitis B immunoglobulin; Recurrence; Prophylaxis; Antivirals

© **The Author(s) 2018.** Published by Baishideng Publishing Group Inc. All rights reserved.

**Core tip:** Aim of this review is to summarize the current concepts and management of hepatitis B after liver transplantation (LT). There are no clear guidelines regarding hepatitis B therapy after transplantation. Hepatitis B immunoglobulin (HBIG) is expensive and cumbersome to administer and there is no definite time point for discontinuation of HBIG after LT. Here we summarize the indications and duration of hepatitis B immunoglobulin and nucleoside analogs. This review also addresses key molecular mechanisms and the risk factors which are associated with hepatitis B virus reactivation post LT. This review provides up-to-date information not only for the liver transplant specialists but also for the virologists and scientists working in this field.

Chauhan R, Lingala S, Gadiparthi C, Lahiri N, Mohanty SR, Wu J, Michalak TI, Satapathy SK. Reactivation of hepatitis B after liver transplantation: Current knowledge, molecular mechanisms and implications in management. *World J Hepatol* 2018; 10(3): 352-370 Available from: URL: <http://www.wjgnet.com/1948-5182/full/v10/i3/352.htm> DOI: <http://dx.doi.org/10.4254/wjh.v10.i3.352>

## INTRODUCTION

Chronic hepatitis B (CHB) caused by hepatitis B virus (HBV) infection remains a major global health problem affecting an estimated 350 million people worldwide with more than 786000 individuals dying annually due to complications of CHB, including cirrhosis and liver cancer. CHB is the leading cause of hepatocellular carcinoma (HCC) accounting for at least 50% of

newly diagnosed cases<sup>[1]</sup>. Furthermore, HCC is the third leading cause of cancer-related mortality in the world<sup>[2]</sup> with a dismal 5 year survival and the fastest growing rate of cancer death in North America<sup>[3]</sup>. Liver transplantation (LT) is the most effective treatment in patients with CHB-related liver failure, cirrhosis and HCC. However, HBV reactivation following LT emerges as a major clinical challenge<sup>[4]</sup>.

Over the past decade, a substantial advancement has been made in the treatment of CHB, and to date several potent antiviral medications are available for the treatment of HBV infection, mainly gaining long-term viral suppression<sup>[5,6]</sup>. However, despite of having strong suppressive antiviral therapy for chronically HBV-infected patients, some patients still develop HCC possibly due to the presence of minimal residual viremia (MRV) and irreversible HBV DNA integration into liver genome. MRV is a consequence of persistent, low-level virus replication in the liver and at the extrahepatic sites, particularly in peripheral blood mononuclear cells (PBMC), coinciding with circulation of virus traces<sup>[7-10]</sup>. Despite long-term antiviral treatment with suppression of viral DNA, MRV commonly persist<sup>[7,11]</sup>. One of the major sources of MRV is supercoiled HBV covalently closed circular DNA (cccDNA) and its persistence is mainly responsible for recurrent HBV infection post-LT<sup>[12,13]</sup>. Prior to introduction of hepatitis B immunoglobulin (HBIG) in 1990s, HBV recurrence in LT was as high as 75% to 89% of patients with 3-year survival rate in 54%<sup>[14,15]</sup>. The introduction of viral suppression strategy using combination of HBIG and more potent nucleos(t)ide analogs (NAs) has significantly decreased the HBV recurrence in vast majority of these patients improving their long-term survival<sup>[16]</sup>. However, this strategy does not completely eradicate HBV and, therefore, does not protect against future recurrence of symptomatic HBV infection. It also requires monitoring of LT patients for life, thus significantly increasing the economic burden and manpower engagement.

Evaluating the risk of HBV recurrence is crucial in devising effective strategy against post-LT reactivation. The factors associated with high rates of HBV reactivation are high viral load prior to the transplant, HBV e antigen (HBeAg) reactivity, co-infection with human immunodeficiency virus type 1 (HIV), non-compliance with drug therapy, HCC at the time of LT, and anti-viral drug resistance. On the other hand, low viral load, anti-HBe positivity and anti-HBs presence are factors with lower risk of HBV reactivation<sup>[15,17-21]</sup>.

## MOLECULAR MECHANISMS OF HEPATITIS B REACTIVATION IN LIVER TRANSPLANTATION

### cccDNA and its role in HBV reactivation

Although HBV is a DNA virus, it replicates by reverse transcription intermediate<sup>[22]</sup>. Establishment of cccDNA is crucial in the HBV life cycle. This nuclear cccDNA

minichromosomal acts as the powerhouse of HBV transcriptional machinery and constitutes a molecular basis for virus reactivation<sup>[12]</sup>. HBV cccDNA chronically exists throughout the natural history of HBV infection<sup>[23]</sup> and it is not yet possible to eradicate this HBV molecule even with current potent anti-viral therapies, such as Entecavir (ETV) or Tenofovir disoproxil fumarate (TDF)<sup>[24]</sup>. A recent study by Papatheodoritis *et al*<sup>[25]</sup> showed that despite of the anti-HBV therapy, HCC develops in the context of the cccDNA presence and, thus, MRV and reactivation cannot be ruled out.

When recipients receive transplantation with liver from donors with previous history of HBV infection, but with negative serum HBsAg and HBV DNA, intrahepatic cccDNA could still be detected after LT<sup>[4,26]</sup>. Notably, detection of anti-HBc alone in the absence of HBsAg and HBV DNA in a donor should be treated as an indicator of occult infection and a low-level virus replication in the liver, which could be reactivated post-LT<sup>[18,27,28]</sup>. On the other hand, patients with undetectable HBV viremia at LT and no evidence of cccDNA and intrahepatic HBV DNA on repeat examinations -may be safely withdrawn from long-term prophylaxis<sup>[29]</sup>. However, safe withdrawal also depends on the level of the sensitivity of the assays used for detecting HBV viremia, HBV cccDNA in the liver and the existence of HBV replication at the extrahepatic sites [e.g., peripheral blood mononuclear cells (PBMC)], which in occult cases may be missed even using ultrasensitive tests.

### Genotype-specific recurrence of HBV

Ten different HBV genotypes have been identified which are scattered in an ethno-geographically specific manner. Ample of evidence suggested the role of HBV genotypes in disease progression, mode of transmission, disease severity, HCC risk, and response to therapy<sup>[30]</sup>. Compared to genotype D, HBV genotype A responds well to the interferon therapy<sup>[31]</sup>. Numerous reports across the globe documented association of HBV genotype B and C with severe liver disease including development of HCC<sup>[32]</sup>, while HBV genotype C has higher risk for mother to child transmission<sup>[33]</sup>. Since virus evolves within the host, study of HBV genotype is important prior to LT, especially in genotypes, which are associated with the occult HBV infection<sup>[34,35]</sup>. A study by Devarbhavi *et al*<sup>[34]</sup> demonstrated that patients with HBV genotype D have the highest risk of HBV recurrence and mortality compared to genotype A. In our recent study, we demonstrated that viral genotypes fluctuate while patient is on the Tenofovir therapy, revealing two important phenomena, first, there is mixture of viral populations present in HBV infected patient and secondly, at a given time, only one of the viral strain is inhibited/exhibits<sup>[36]</sup>. Although, not with regard to the HBV genotypes, but from the point of HBV quasi-species an elegant study by Buti *et al*<sup>[37]</sup> identified HBV quasi-species evolution after LT in patients under long-term lamivudine prophylaxis with or without HBIG

and there was low transient viremia detected even in the absence of serum HBsAg, showing importance of continuing HBV prophylaxis. In the same context, a recent case study by Mina *et al*<sup>[38]</sup> showed that HBV genotypes fluctuates after LT, which could possibly be the main reason behind the HBV reactivation in liver transplant settings. Since, in diagnostic assays, the possible source of HBV reactivation is negated, it is an open question, if extrahepatic tissues should be tested to find the origin of such reactivation. Studies focusing on HBV recurrence based on genotype are summarized in Table 1. It would be worthwhile to consider HBV genotyping in both donor and recipient so that each viral strain is tracked in case of the mixed genotype infections, which are emerging as important hidden source for reactivation.

### Co-existing hepatitis D virus infection and HBV reactivation

Hepatitis delta virus (HDV) consists of a single-stranded RNA molecule enveloped by hepatitis B surface antigen (HBsAg)<sup>[39]</sup>. One of the risk factors of HBV recurrence in LT patients is the co-infection with hepatitis delta virus (HDV)<sup>[40]</sup>. Fulminant hepatitis B reactivation in co-infected patients has been reported<sup>[40,41]</sup>. HBsAg-positive liver grafts in HBsAg-positive recipients with HDV co-infection has been reported to result in virological recurrence and rapid development of liver cirrhosis, and need for re-transplant<sup>[42,43]</sup>. HDV is a RNA pathogenic virus that requires presence of HBV for its survival<sup>[44]</sup>. Studies on post-LT patients suggest that the absence of HBV prophylaxis or lack of proper function of HBIG leads to higher incidence of both HBV and HDV reinfection<sup>[43,45,46]</sup>.

The co-existence or co-infection of HBV and HDV is very commonly observed, obviously due to the dependence of HDV infection on HBV. For instance, 11.9% of HBV-positive patients were also positive for HDV in an Italian liver patient cohort, with a higher incident in patients older than 50 years<sup>[47]</sup>. It also appears to have a geographical connection, as co-infection HBV-HDV in LT patients was found to be low in Japan<sup>[48]</sup>, possibly due to the differential geographical distribution of HDV genotypes I and II between other parts of the world and Asian countries, respectively<sup>[49]</sup>. The helper functions of HBV provide the support to HDV for cell entry, replication, virion assembly and export<sup>[50]</sup>. The interactions between HBV-HDV occur in two phases, the first phase of active HDV replication occurs with the suppression of HBV, followed by reactivation of HBV and reduction in HDV in the second phase<sup>[51]</sup>. Due to this nature of HDV and HBV interactions, early recurrence of HDV has been detected in many patients in the absence of HBV recurrence<sup>[52]</sup>. Studies also imply that HDV could be a cause for many subclinical infections and symptoms develop rapidly upon recurrence of HBV<sup>[45]</sup>. HBV recurrence has been shown to cause atypical reappearance of HBV infection and HDV relapse in the

**Table 1** Recurrence of hepatitis B virus in different genotypes

HBV genotype	No. of patients	Median follow-up (mo)	HBV recurrence number (%)	Mortality number (%)
Girlanda <i>et al</i> <sup>[175]</sup> , 2004				
A	15	56	4 (27)	2 (13)
D	13	67	7 (54)	5 (38)
A/D	12	43	4 (33)	2 (17)
A/C	2	66	1 (50)	0
E	2	45	1 (50)	1 (50)
C	1	106	1 (100)	0
Devarbhavi <i>et al</i> <sup>[134]</sup> , 2002				
A	10	56	3 (30)	1 (10)
C	6	22.5	3 (50)	1 (10)
D	5	15	3 (60)	1 (10)
E	1	1	0	Lost follow-up
Gaglio <i>et al</i> <sup>[176]</sup> , 2008				
A	28	24	3 (10.7)	3 (10.7)
B	8	24	1 (12.5)	1 (12.5)
C	18	24	1 (5.5)	5 (5.5)
D	6	24	0	0
Lo <i>et al</i> <sup>[177]</sup> , 2005				
B	43	36	4 (2)	7 (17)
C	74	36	21 (15)	7.5 (11)

HBV: Hepatitis B virus.

allographs<sup>[53]</sup>. Additionally, the recurrence of HBV-HDV post-LT is the cause of death for many LT patients, prompting need for more research on this subject<sup>[45,54]</sup>. In a recent study, recurrence rate of HBV after LT was not different from the recurrence rate of HBV-HDV co-infection on long-term low-dose HBIG prophylaxis along with TDF<sup>[55]</sup>.

#### Genetic variations of host genetic makeup in predicting HBV reactivation

Genetic variations of host genetic makeup may play some role in increased/reduced risk of HBV reactivation after LT. Single-nucleotide polymorphisms (SNP) of two-gene locus cytotoxic T lymphocyte antigen-4 (CTLA-4) +49 and CD86 +1057 were previously reported to influence the outcome of LT with respect to allograft acceptance<sup>[56,57]</sup>. Homozygosity for CTLA-4 +49 (G/G genotype) was reported to be associated with reduced risk of HBV recurrence in post-LT Chinese patients<sup>[56]</sup>. CD86 and CTLA-4 are known to stimulate and inhibit T cell activation, respectively.

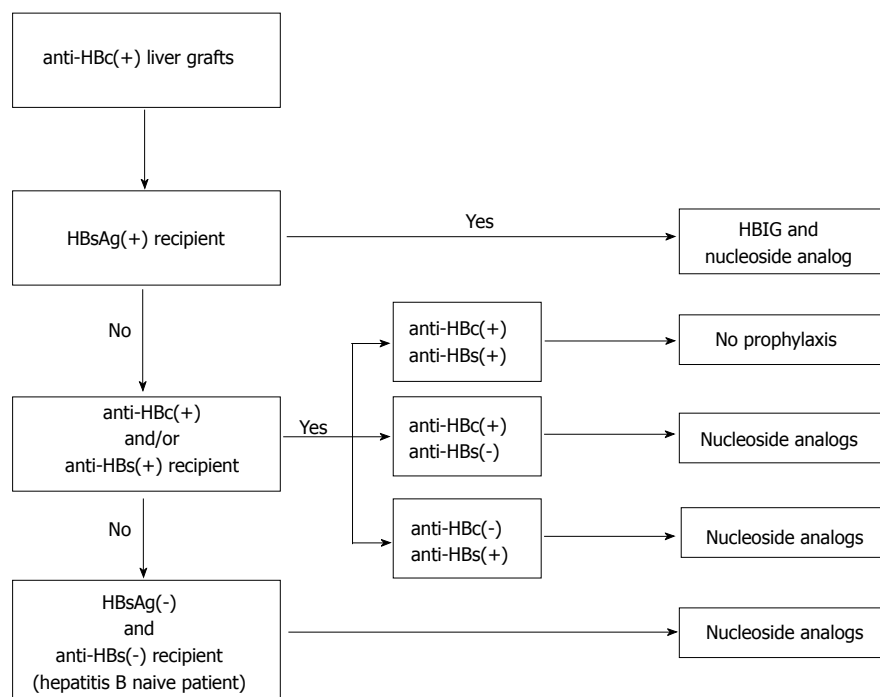
#### Role of superinfection in HBV reactivation

Superinfection is defined as the infection with a second virus or a different strain of virus at a later time point, after the establishment of persistent infection of the first virus<sup>[51,58]</sup>.

Superinfection with HDV of an individual chronically infected with HBV may have deleterious consequences<sup>[59]</sup>. This pattern of infection causes a severe acute hepatitis that may be self-limited but that in most cases (up to 80%) progresses to chronicity<sup>[60]</sup>. The resultant chronic HDV infection usually exacerbates the preexisting CHB<sup>[60]</sup>. It is to be noted that HBV replication is usually suppressed by HDV, and this suppression

becomes persistent in the case of a chronic HDV infection<sup>[61,62]</sup>. Due to concern for HDV superinfection in post-LT setting, it is of utmost importance to prevent HBV recurrence after LT. Nonetheless, patients chronically co-infected with HDV are less at risk of HBV recurrence and have a better survival rate than patients infected with HBV alone. Patients co-infected with HDV generally do not require pre-transplant antiviral therapy due to HBV suppression and low viral load. Although potent HBV DNA-polymerase inhibitors can control HBV replication, reappearance of HBsAg and/or the persistence of HBV DNA in serum, liver, or PBMC might have deleterious consequences in the setting of HBV-HDV co-infection as they may provide the biologic substrate to the reactivation of HDV<sup>[40]</sup>. No effective antiviral drug is available for the treatment of graft infection with HDV, and potentially the best approach is to keep them on long-term potent antiviral therapy along with low dose of HBIG (Figure 1).

As mentioned before, HBV has ten genotypes named A-J, and they influence the disease outcome and treatment to antiviral therapy<sup>[63]</sup>. Depending on the geographical location, patients may have one or mixed genotypes of HBV in infected patients and consequences of which possibly have the recombinant HBV genotypes<sup>[64-66]</sup>. The genotype C of HBV was observed in majority of the HBV-infected patients with acute exacerbation<sup>[67]</sup>. An earlier published review reported that HBV genotypes D and C are associated with a lower rate of favorable response to alpha-interferon and pegylated-interferon alpha-2b therapy than genotypes A and B<sup>[68]</sup>. The rate of resistance to lamivudine (LAM) was higher in patients with genotype A infection than in patients infected by genotype D, whereas no difference in the risk of LAM resistance is found between patients



**Figure 1 Stepwise approach of anti-hepatitis B core positive grafts allocated to recipients based on their hepatitis B serology.** In chronic hepatitis B patients with HBsAg positive and who receive Anti-HBc positive liver grafts should be treated with HBIG and nucleoside analogs. If the recipient is HBsAg negative and Anti-HBc positive and/or anti HBs positive, NA is used for prophylaxis based on anti HBc and anti HBs serologies. No prophylaxis is recommended for anti-HBc positive and anti-HBs positive liver in LT recipient without HBsAg positive serology. These patients should be followed with periodic HBV DNA level guided by ALT to monitor for any relapse. In Hepatitis B naïve patients, NA is recommended for prophylaxis. HBIG: Hepatitis B Immunoglobulin; HBsAg: Hepatitis B surface antigen; Anti-HBs: Hepatitis B surface antibody; Anti-HBc: Hepatitis B core antibody.

with genotype B and patients with genotype C<sup>[68]</sup>. Later studies using potent nucleotide analogue have shown no genotype specific differences in treatment responses<sup>[69]</sup>. Another challenge with HBV is the generation of HBV variants through splicing. These variants may get activated with the disease progression post-LT leading to undesirable clinical outcomes as well as the development of drug resistance<sup>[70]</sup>.

#### Role of HBV integration in HBV reactivation after LT

The role of HBV DNA integration in the genome of host liver cells has been studied from the early 1980s and it had long been postulated to have implications for the antiviral therapy for HBV<sup>[71,72]</sup>. Recent study demonstrated that HBV can integrate into the host genome immediately after its invasion<sup>[73]</sup>. HBV DNA integration has been detected in all the stages of HBV infection including occult HBV infection<sup>[74]</sup>. The potential for oncogenicity has been proven in the woodchuck model with occult WHV infection<sup>[75]</sup>. In a study from Japan, eighty-two consecutive Japanese patients with cirrhosis, who were negative for serum HBsAg and antibody to hepatitis C virus (anti-HCV) were observed for a median of 5.8 years<sup>[76]</sup>. The HCC development rates in the patients HBV DNA-positive and HBV DNA-negative were 27.0% and 11.8% at the end of the 5<sup>th</sup> year, and 100% and 17.6% at the 10<sup>th</sup> year, respectively.

The clinical significance of occult HBV infection has not been well studied in LT recipients. A recent study investigated the prevalence of occult HBV infection in

cirrhotic patients undergoing LT in a Brazilian referral center<sup>[77]</sup>. Liver samples from 68 adults were analyzed using a nested polymerase chain reaction assay for HBV DNA and occult HBV infection was diagnosed in three (4.4%) patients. Markers of previous HBV infection were available in two patients with occult HBV infection and were negative in both. Clinical impact of occult HBV infection in immunosuppressed individuals has been recently reviewed<sup>[78]</sup>. These results suggest potential for HBV reactivation post-LT from occult HBV infection. In fact, a recent study with 43 patients with alcoholic cirrhosis, who were negative for serum HBsAg before LT, detectable HBV DNA in the explanted liver was evident in 41.9%<sup>[79]</sup>. *De novo* HBV infection occurred in 18.6% (8/43) of the recipients at a median of 10 mo after LT.

#### Extrahepatic replication of HBV and its role in HBV reactivation

Numerous reports demonstrated the presence of HBV DNA, virus genome replicative intermediates and viral proteins in hepatic tissue, and HBV DNA and HBsAg in serum of HBV-infected persons, but the existence of extrahepatic sites of HBV replication are not as well recognized. Nonetheless, the accumulated data indicate that PBMC and different immune cell types can support HBV replication<sup>[27,80-83]</sup>. Stronger evidence came from the woodchuck model of HBV infection<sup>[27,75,84-87]</sup>. There are also occasional observations that endothelial cells, epithelial cells, neurons, macrophages and polymorphonuclear leukocytes could be permissive to

HBV infection in humans<sup>[88]</sup>. HBV replication was also demonstrated in *in vitro* bone marrow cultures and lymphatic tissues of patients with CHB<sup>[89-91]</sup>. In the woodchuck model of hepatitis B, extrahepatic replication of the woodchuck hepatitis virus and infectivity of the virus derived from lymphoid cells were clearly delineated<sup>[75,87]</sup>. Interestingly, in some situations, the lymphatic (immune) system might be the only site of virus replication in this model<sup>[75,86,87,92]</sup>.

In one of the xenotransplantation study in patients with baboon liver transplants, Lanford *et al.*<sup>[93]</sup> demonstrated the persistence of HBV DNA in several extrahepatic tissues after HBV replication halted in the liver. In the woodchuck model, the mothers with resident hepadnaviral infection cells transmit the infection to their offspring which is predominantly restricted to their lymphatic system<sup>[84]</sup>. These observations suggest that the attachment preferences of HBV to cellular receptors on diverse cell types might be responsible for the quasispecies specific compartmentalization of HBV<sup>[94]</sup>. Studies related to genetic variability, drug resistance and potential immune evasion mechanisms of virus in plasma and PBMC of patients with CHB have also been investigated<sup>[95,96]</sup>. Because of the diverse nature of the HBV in hepatic and extrahepatic tissues, the response to therapy has been shown to be different in PBMC-restricted HBV compared to hepatic HBV<sup>[95]</sup>. In these studies, liver, plasma as well as PBMC samples were evaluated using ultrasensitive assays for the quasispecies compatibility in LT patients under long term prophylaxis. The authors inferred that extrahepatic HBV is always detectable in the serum, liver, and PBMC of almost all patients despite prophylaxis, supporting continuation of anti-HBV therapy<sup>[95,96]</sup>. However, there is not a study yet that demonstrated that reactivation can solely originate from extrahepatic sites.

## THE RISK OF HBV REACTIVATION IN LIVER TRANSPLANT PATIENTS UNDERGOING IMMUNOSUPPRESSION THERAPY

Upon HBV entry, the level at which HBV persists depends on the interplay between the viral replication rate and the host immune response. LT patients with prior HBV infection could experience a reactivation of HBV following LT due to immunosuppressive therapy, potentially leading to deleterious consequences, including graft failure and death<sup>[97-99]</sup>.

### HBV reactivation in immunosuppressed patients

**Immune mechanism:** HBV cccDNA and low levels of HBV DNA and RNA remain detectable in host hepatocytes even in patients exposed to HBV who have developed anti-HBs after apparent complete clearance of serum HBsAg and HBV DNA from a recent infection<sup>[87,100]</sup>. Hence, there seems to be a balance between host HBV-specific T cell and

innate immune responses and virus replication that maintains the latency of the viral infection<sup>[80,101,102]</sup>. Immunosuppressive therapy or cancer chemotherapy may lead to induce imbalance of these mechanisms which causes HBV reactivation<sup>[101,103]</sup>.

**Non-immune mechanism:** HBV infection can also be flared by steroids<sup>[104]</sup>. This may include stimulation of a glucocorticoid-responsive element (GRE) in the HBV genome which leads to up regulation of HBV gene expression<sup>[105]</sup>. In addition, mechanistic target of rapamycin (mTOR) inhibitors, like rapamycin, that are used as immunosuppressive drugs in LT patients and certain cancers, are reported to enhance HBV reactivation in patients<sup>[106]</sup>. It is also shown that maintaining an immunosuppressive regimen using mTOR-inhibitors post-LT commonly reactivate HBV infection, along with infections with other viruses, such as HCV, cytomegalovirus (CMV), HIV-1, human papilloma virus (HPV), Epstein Barr virus (EBV) and herpes simplex virus (HSV) as well<sup>[107]</sup>.

### HCC recurrence after LT

In a Chinese registry study, patients undergoing LT due to HBV-related HCC vs HCV-related HCC demonstrated recurrence of HCC at a significantly higher rate in HBV-HCC cohort (26.39%) compared to that in HCV-HCC cohort (9.07%) ( $P < 0.001$ )<sup>[108]</sup>. The risk factors for HCC recurrence were: elevated serum alpha fetoprotein, large tumor volume, microvascular invasion, high serum HBV DNA and HBsAg levels, and immunosuppression<sup>[109,110]</sup>.

Younger age has been suggested as a significant risk factor for HBV infection-related HCC recurrence after LT. It has been proposed that this could be due to the vertical transmission of HBV from the occult HBV infection harboring mother and HBV immune tolerant state of the younger patients, triggering HCC recurrence<sup>[111,112]</sup>.

## PROPHYLAXIS FOR HBV REACTIVATION AFTER LT

### HBsAg-positive patients

Introduction of HBIG in prevention of HBV reactivation following LT was a major milestone. HBIG is pooled polyclonal antibody against HBsAg. Although its mechanism of action remains incompletely understood, it is believed that it prohibits binding of virions to hepatocytes or promotes lysis of infected hepatocytes<sup>[113]</sup>. In the initial days, prophylaxis for recurrent HBV infection was administered to HBsAg-positive patients using HBIG or LAM monotherapy. This strategy showed significant reduction in re-infection and improvement of graft survival after LT<sup>[14,15,114]</sup>. Although graft survival was largely improved with either HBIG or LAM monotherapy, the re-infection rates were continued to be 30%-40% of patients<sup>[15,19,115]</sup>. Furthermore, LAM monotherapy

resulted in development of HBV reverse transcriptase mutations that lead to antiviral drug resistance. When LT patients were on only HBIG prophylactic therapy, their chance of developing HBV escape mutations was significantly higher<sup>[116]</sup>, and this lead to *de novo* HBV infection in some patients after LT<sup>[17,117]</sup>. First described in 1998, combination therapies of HBIG with NA were successful in controlling HBV infection in most of the patients. None of the 59 patients undergoing LT for HBV-related liver failure who received high dose of HBIG intra- and post-operatively in combination with LAM as prophylaxis, showed detectable HBV DNA after 459 days of treatment<sup>[118]</sup>. By combining LAM with HBIG, the HBV recurrence rate further dropped to less than 5%. The success of this combination regimen led it to become the most favored antiviral prophylactic regimen in ILT centers worldwide. Despite being effective, HBIG was very expensive and unavailable to a significant percentage of the patient population, and it requires regular parental injections and monitoring. In view of this, lower-dose HBIG in combination with LAM was evaluated and was found to be equally effective<sup>[119-121]</sup>. However, this combination approach of HBIG with an oral antiviral medication is of historical value only and neither alone was sufficient in preventing HBV reactivation or recurrence. With the availability of newer and more potent oral NA, there has been a shift from HBIG combination therapy to NA alone. A systematic review by Cholongitas *et al.*<sup>[122]</sup> noted a higher recurrence rate with combination of HBIG plus LAM compared to HBIG plus ETV/TDF (6.1% vs 1%,  $P = 0.004$ ). A meta-analysis has shown that compared to high dose HBIG-LAM combination, low dose HBIG and potent NAs (TDF or ETV) demonstrated significantly lesser HBV recurrence<sup>[123]</sup>. Both ETV and TDF have been associated with resistance rate of less than 2% after 5 years in patients with HBV infection<sup>[124]</sup>. Several earlier studies have demonstrated usefulness of long term HBIG, and more recent studies have demonstrated safe withdrawal of HBIG with continuation of oral antiviral therapies alone by adopting a limited duration of HBIG use in the protocol<sup>[119,121,125-138]</sup> (Tables 2 and 3).

#### **Hepatitis B core antibody-positive liver donor**

LT from hepatitis B core antibody (anti-HBc)-positive donors is being increasingly used due to the shortage of organs. However, due to immunosuppressive therapy, the risk of HBV reactivation is higher after LT in these patients<sup>[139]</sup>. In a systematic review of 39 studies involving 903 LT patients, Cholongitas *et al.*<sup>[139]</sup> evaluated the risk of HBV recurrence after LT with grafts from anti-HBc-positive donors and effect of anti-HBV prophylaxis. HBV recurrence was found to be 11% in HBsAg-positive LT patients who received anti-HBc-positive grafts compared to anti-HBc-negative grafts, but overall survival was same in both groups. They also noted that *de novo* HBV infection occurred in 19% of HBsAg-negative patients receiving anti-HBc-positive grafts. Without prophylaxis, HBV re-activation

was 15% in anti-HBc/anti-HBs-positive recipients and 48% in HBV naïve patients. However, prophylaxis using HBIG, LAM or a combination decreased re-infection rate significantly. Similarly, *de novo* HBV infection rates in HBsAg-negative patients decreased to 19%, 2.6% and 2.8% using HBIG, LAM and combination, respectively.

This study suggests that anti-HBc positive grafts can be donated safely to HBsAg-positive and anti-HBc/anti-HBs-positive sub groups, and antiviral prophylaxis decreases post-LT reactivation significantly. Due to high risk of reactivation in HBV-naïve patients, anti-HBc-positive grafts should only be considered if other two sub-group recipients are not available<sup>[140]</sup>. Figure 2 shows stepwise approach in allocating anti-HBc-positive grafts based on recipients HBV serology and prophylaxis after LT.

#### **Anti-HBs and Anti- HBc-positive recipients**

*De novo* HBV infection is substantially lower in anti-HBc and/or anti-HBs-positive compared to HBV-naïve recipients<sup>[141]</sup>. The presence of anti-HBs seems to protect from *de novo* HBV infection and both anti-HBc and anti-HBs-positive recipients represent a group that can safely receive anti-HBc-positive liver grafts without any post-transplant HBV prophylaxis (probability of *de novo* HBV infection < 2%)<sup>[142-151]</sup>. These patients should however be followed with periodic HBV DNA level guided by ALT to monitor for any relapse. Despite this low risk, many centers prefer to continue with NA without HBIG in this subgroup of patients, and future studies will further clarify this concept (author's personal communication). Figure 3 shows stepwise approach in allocating anti-HBc-positive grafts based on recipients HBV serology and prophylaxis after LT.

#### **Duration of HBIG administration**

Currently, there is no consensus regarding the duration of use and dose of HBIG as a component of prophylaxis, and many experts believe in an individualized approach to use of HBIG in prophylaxis<sup>[152-154]</sup>. A recent study has demonstrated that in HBV-infected patients undergoing LT, who have HBV DNA levels less than 100 U/L and an absence of co-infection with HIV or HDV, a very short course of HBIG in combination with long-term antiviral therapy is highly effective in preventing HBV recurrence<sup>[130]</sup>. Chen *et al.*<sup>[131]</sup> has shown infusion of two high doses of HBIG during surgery in combination with ETV significantly prevented HBV recurrence and improved the 3-year survival after LY. Another, potential cost saving approach could be combination of ETV plus low-dose on-demand HBIG<sup>[155]</sup>. Additionally, HBIG-free approach has recently been advocated and is discussed in the later part of this review.

#### **HBIG-free prophylaxis and treatment options**

Advent of newer and more-potent NAs with high genetic barrier for resistance such as ETV and TDF, have shown great therapeutic potential as prophylactic agents, and achieved a stronger viral suppression,

**Table 2** The results of combination therapy of low-dose hepatitis B immunoglobulin and nucleos(t)ide analogues and the effects of withdrawal of hepatitis B immunoglobulin from combination therapy

Ref.	NA	HBIG protocol	Median follow-up (mo)	HBV recurrence
Angus <i>et al</i> <sup>[119]</sup> , 2000	32 LAM	400 IU or 800 IU/d for 1 wk from LT followed by 400 IU or 800 IU/monthly thereafter	18.4	3.1% HBsAg + and 0% HBV DNA+
Gane <i>et al</i> <sup>[121]</sup> , 2007	147 LAM	400 IU or 800 IU/d for 1 wk followed by 400 IU or 800 IU/monthly thereafter	62	1% at 1 yr and 4% at 5 yr. Baseline HBV DNA was associated with HBV recurrence
Karademir <i>et al</i> <sup>[125]</sup> , 2006	33 LAM, 2 LAM + ADV	All patients received 4000 IU of intramuscular HBIG during surgery, 2000 IU intramuscular daily thereafter, until the HBsAb titer > 200 IU/mL and the HBsAg was seronegative, followed by lifelong 1200 to 2000 IU HBIG on-demand if HBsAb titer fell below 100 IU/mL	16	5.7% (2 of 35 patients) had HBV DNA recurrence. They were LAM resistant
Iacob <i>et al</i> <sup>[126]</sup> , 2008	42 LAM	10000 IU within anhepatic phase and daily within the first postoperative week, followed by 2500 IU on demand	21.6	HBV recurrence rate was 4.8% after a median of 1.8 yr
Jiang <i>et al</i> <sup>[127]</sup> , 2010	254 LAM	2000 IU in anhepatic phase, followed by 800 IU/d for first day then weekly for the rest of 3 wk in the first post-operative month, then 800 IU monthly	41.2	1-, 3- and 5-yr HBV recurrence rates were 2.3%, 6.2% and 8.2%, respectively 5 cases have YVDD mutations
Nath <i>et al</i> <sup>[128]</sup> , 2006	14 LAM + ADV	1000 IU HBIG in anhepatic phase 1000 IU/daily for week 1, then HBIG withdrawn, replaced with oral ADV	14.1	7.1%
Saab <i>et al</i> <sup>[129]</sup> , 2011	18 LAM + HBIG, 16 LAM to LAM + ADV	Randomized trial Patients treated with low dose HBIG + LAM ≥ 1-yr post LT 18 patients continued HBIG 16 patients discontinued HBIG and ADV added	21	0% in HBIG + LMV 6.1% in LMV + ADV Recurrent case: HBsAg + /HBV DNA (-)
Saab <i>et al</i> <sup>[129]</sup> , 2011	19 LAM to LAM + ADV, 41 LAM to LAM + TDF, 1 ETV to ETV + ADV	All patients treated with low dose HBIG + LAM ≥ 1-yr post-LT. All patients discontinued HBIG	15	3.3% recurrent cases: HBsAg (+)/HBV DNA (-)
Radhakrishnan <i>et al</i> <sup>[130]</sup> , 2017	42 (ETV (12%), TDF (83%), or TDF/FTC (5%))	HBIG 5000 IU given in anhepatic phase and daily for 5 d together with nucleos(t)ide analogues after LT and then continued indefinitely.	36	1- and 3-year cumulative incidences of recurrence, defined by positive serum HBsAg of 2.9%
Chen <i>et al</i> <sup>[131]</sup> , 2015	50 (ETV before and after LT)	Two doses of HBIG-First dose anhepatic phase (10000 IU) and other dose (10000 IU) during surgery (additional doses as needed to maintain HBIG level > 300 IU/mL from 6 wk to 12 mo)	36	0% recurrence at 3 years defined as reappearance of HBsAg and HBV DNA level
Cholangitis <i>et al</i> <sup>[132]</sup> , 2016	34 (LAM = 2, AFV = 1, ETV = 9, TDF = 12)	HBIG 1000-10000 IU bolus during anhepatic phase, followed by daily × 7 d, and then monthly 1000-2000 IU intramuscularly for 6-12 mo post-LT and then discontinued NA were continued indefinitely	28	5.8% recurrence defined as reappearance of serum HDV in LT recipients with detectable serum HBsAg and/or HBV DNA
Wesdorp <i>et al</i> <sup>[133]</sup> , 2013	17 (15 of 17 converted from LAM/ADV to TDF/FTC)	All received HBIG ± (10000 IU given during anhepatic phase followed by a 4-7 d course of 10000 IU of IV HBIG daily, and then monthly intramuscularly for > 6 mo and then switched to TDF/FTC	24	No recurrence defined by HBsAg and HBV-DNA positivity. However, 6.7% had isolated HBsAg recurrence
Stravitz <i>et al</i> <sup>[134]</sup> , 2012	21 (Patients were initially on LAM = 11, ETV = 4, AFV = 2, LAM + ADV = 2, LAM + ADV = 2. All patients were converted to TDF/FTC)	HBIG ± nucleos(t)ide > 6 mo, then substituted with TDF/FTC	31	0% recurrence of HBV DNA after switching to TDF/FTC
Taperman <i>et al</i> <sup>[135]</sup> , 2013	37 patients were randomized to TDF/FTC plus HBIG ( <i>n</i> = 19) or receive (TDF/FTC) alone ( <i>n</i> = 18)	HBIG ± nucleos(t)ide for 24 wk, then randomized to TDF/FTC plus HBIG ( <i>n</i> = 19) or receive TDF/FTC alone ( <i>n</i> = 18) for an additional 72 wk	72	0% recurrence of HBV DNA in both arms

Gane <i>et al</i> <sup>[136]</sup> , 2013	20 patients with initial HBIG for 7 d and then switched to LAM+ ADV	HBIG 800 intramuscularly given immediately after LT and the daily for 7 d and then switched to LAM/ADV	57	0% recurrence defined as reappearance of HBsAg and HBV DNA
McGonigal <i>et al</i> <sup>[137,141]</sup> , 2013	4 (ETV = 2, LAM = 1, TDF = 1)	HBIG + NA for more than one year and switched to TDF/FTC	15	0% recurrence of HBsAg and HBV DNA
Angus <i>et al</i> <sup>[138]</sup> , 2008	34 patients randomized after 12 mo of HBIG + LAM to ADV ( <i>n</i> = 16) with and without HBIG ( <i>n</i> = 18)	Low dose HBIG × 12 mo along with LAM	4.4 yr for the LAM/ADV and 4.6 yr for the HBIG/LAM group	1 of 15 (6%) in the LAM/ADV and 0 of 15 (0%) in the HBIG/LAM group had HBsAg positive at last follow up

HBIG: Hepatitis B immunoglobulin; HBV: Hepatitis B virus; HBsAg: Hepatitis B surface antigen; HCC: Hepatocellular carcinoma; HIV: Human immunodeficiency virus; HDV: Hepatitis delta virus; LAM: Lamivudine; LT: Liver transplantation; ETV: Entecavir; TDF: Tenofovir.

**Table 3** Hepatitis B immunoglobulin-free regimens in preventing recurrence of hepatitis B virus infection after liver transplantation

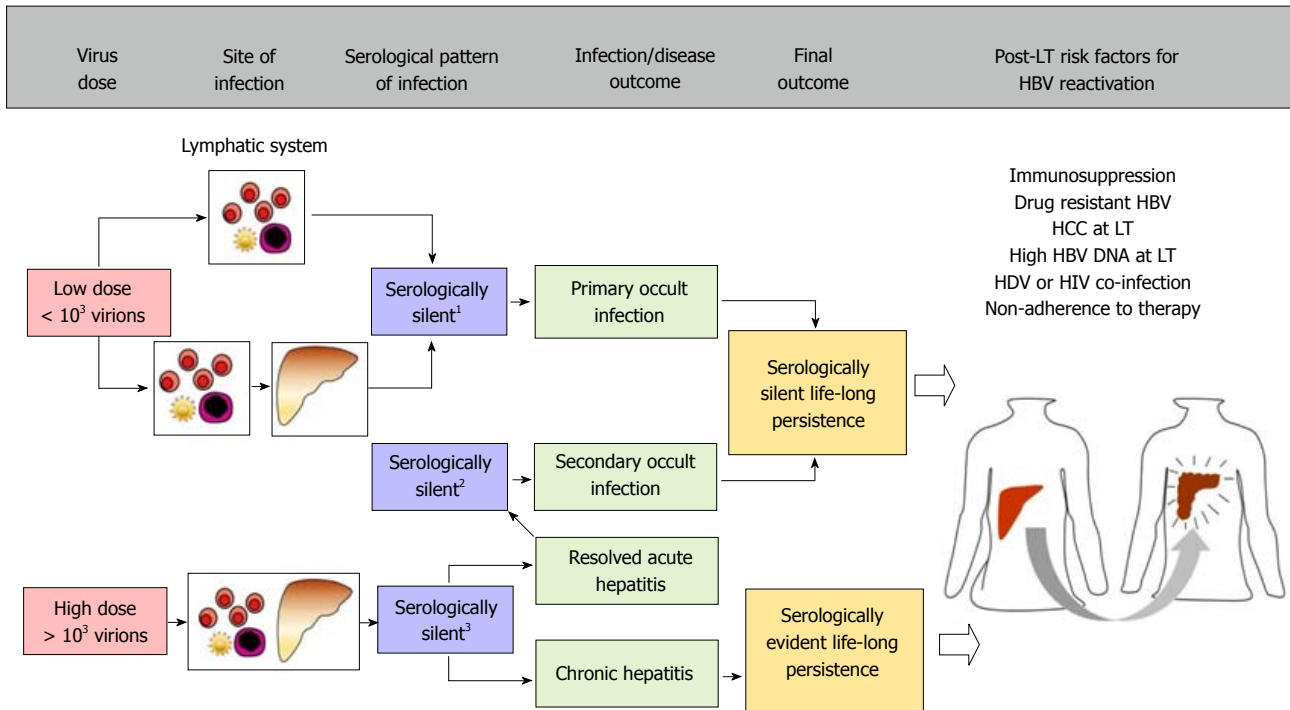
Ref.	No. of patients	Median duration of follow-up (mo)	Therapy	HBsAg loss	Undetectable HBV DNA
Fung <i>et al</i> <sup>[161]</sup> , 2017	265	59	ETV	At 1, 3, 5, and 8 yr of follow up, 85%, 88%, 87.0%, and 92% were negative for HBsAg, respectively	At 1, 3, 5 and 8 yr of follow up, 95%, 99%, 100%, and 100% had undetectable HBV DNA, respectively
Fung <i>et al</i> <sup>[158]</sup> , 2013	362	53	LAM = 176 (49%), ETV = 142 (39%), and 44 (12%) were on combination therapy (Either LAM or ETV) plus nucleotide analog (either ADV or TDF)	HBsAg seronegativity at 1, 3, 5 and 8 yr was 80%, 82%, 82% and 88%	HBV DNA suppression to undetectable levels at 1, 3, 5 and 8 yr was 94%, 96%, 96%, and 98%. Rate of HBV DNA suppression for LAM, combination therapy, and ETV at 1 yr was 97%, 94%, and 95%, respectively
Fung <i>et al</i> <sup>[159]</sup> , 2011	80	26	ETV	The cumulative rate of HBsAg loss was 86% and 91% after 1 and 2 yr, respectively	95% with undetectable HBV DNA and 5% had low level viremia
Wadhawan <i>et al</i> <sup>[157]</sup> , 2013	75	21	19 patients received a combination of LAM+ADV, 42 received entecavir, 12 received TDF, and 2 received a combination of ETV + TDF	The cumulative probabilities of clearing HBsAg were 90% and 92% at 1 and 2 yr after transplantation, respectively	Nine patients were HBsAg-positive with undetectable DNA at the last follow-up. The recurrence rate in our series was 8% (6/75)

HBV: Hepatitis B virus; HBsAg: Hepatitis B surface antigen; LAM: Lamivudine; ETV: Entecavir; TDF: Tenofovir.

paving the way for a HBIG free regimen for antiviral prophylaxis<sup>[13,156]</sup>. In a multicenter trial by Gane *et al*<sup>[136]</sup>, no HBV recurrence was detected in 28 HBV patients who received a combination of LAM and ADV after a median follow-up of 22 mo when the pre-transplant HBV-DNA level was below 3 log(10) IU/mL. In a later study of 75 HBV patients who received different oral antiviral treatment after LT (19 received a combination of LAM and ADV, 42 ETV, 12 TDF, and 2 received a combination of ETV and TDF), the HBV recurrence rate was merely 8% at a median follow-up of 21 mo and there was no mortality related to HBV recurrence<sup>[157]</sup>. There was no significant difference in HBsAg clearance and HBV-DNA suppression between those on LAM, combination treatment, or ETV, but virological relapse rate at 3 years was 17%, 7%, and 0%, respectively (*P* < 0.001).

Fung *et al*<sup>[158]</sup> evaluated monotherapy with NAs (LAM, ETV or LAM plus ADV) without HBIG in a large, long-term cohort study involving 362 LT patients with CHB. At the end of 8 years of follow-up, 98%

showed undetectable HBV DNA in serum by clinical assay. Overall 8-year survival rate was 83% with no difference between these three treatment groups and, importantly, no mortality was observed due to HBV recurrence in any of the 362 patients. This study showed that at least in low risk patients, HBIG-free regimen with high potency NAs was safe and effective in preventing post-LT HBV reactivation. For patients without preexisting LAM-resistant mutation, the use of ETV as a standalone treatment remains an ideal choice given its lack of nephrotoxicity. In a study of 80 CHB patients undergoing LT where ETV was used alone in a completely HBIG-free regimen with a median follow-up of 26 mo a high HBsAg seroclearance rate of 86 and 91% after 1 and 2 years respectively was observed<sup>[159]</sup>. Thirteen percent of patients had HBsAg positivity either from reappearance of HBsAg after initial seroclearance or from persistence of HBsAg-positive status after transplantation. It is important to note that there was no incidence of virological rebound or

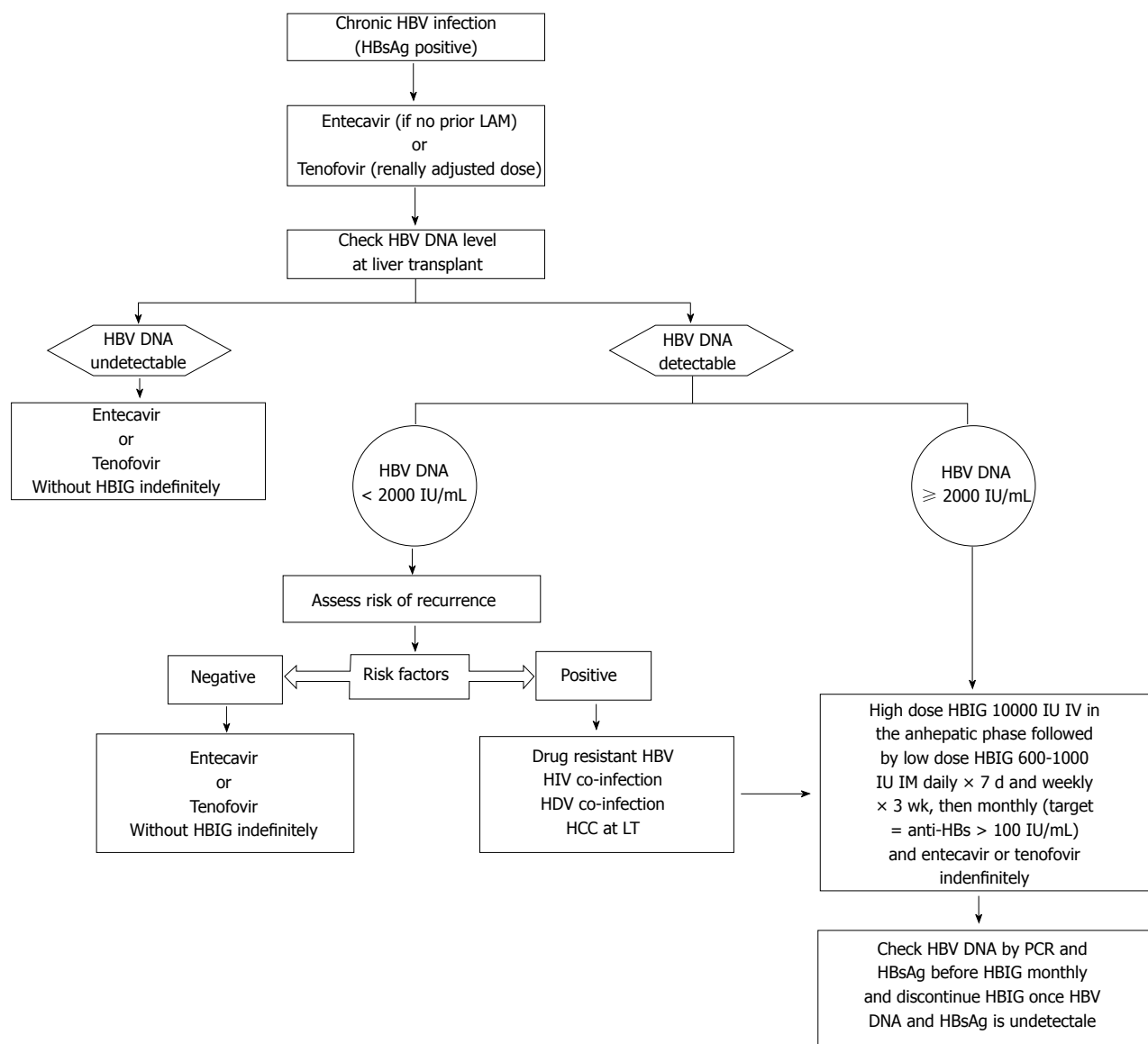


**Figure 2** Generalized concept of overt and occult hepatitis B virus infections based on the data from the woodchuck model of hepatitis B, their long-term outcomes, and associated risk factors for hepatitis B virus reactivation following liver transplant. Based on experimental infection in the woodchuck model (Mulrooney-Cousins PM, Michalak TI, 2015<sup>[92]</sup>). <sup>1</sup>Serologically silent infection: HBsAg, anti-HBc and anti-HBs negative; HBV DNA positive; <sup>2</sup>Serologically silent infection: HBsAg negative, anti-HBc positive, anti-HBs positive or negative; HBV DNA positive; <sup>3</sup>Serologically evident infection: HBsAg and anti-HBc positive, anti-HBs negative. HBV DNA positive. SOI: Secondary occult infection; POI: Primary occult infection; LT: Liver transplant; HCC: Hepatocellular carcinoma; HBV: Hepatitis B virus; HDV: Hepatitis D virus; HBsAg: HBV surface antigen; anti-HBc: Antibodies to HBV core antigen; anti-HBs: Antibodies to HBV surface antigen.

resistance, nor any HBV-related graft hepatitis, graft loss, or mortality. The same group later also followed histological outcomes of CHB patients treated with an HBIG-free regimen, 42 patients were treated with ETV monotherapy who underwent liver biopsies after LT at a median time of 10 mo. Of these, 9 were serum HBsAg-positive at the time of biopsy. All patients were serum HBV DNA-negative- at the time of biopsy. None of these patients had histological evidence of HBV-related graft hepatitis and positive immunohistochemical staining for HBsAg<sup>[160]</sup>. Fung *et al*<sup>[161]</sup> also shown the long-term efficacy of using ETV monotherapy in a study involving 165 LT recipients with HBV. The study demonstrated that ETV monotherapy is highly effective at preventing HBV reactivation after LT for CHB, with a durable HBsAg seroclearance rate of 92%, an undetectable HBV DNA rate of 100% at 8 years, and excellent long-term survival of 85% at 9 years.

This approach has been supported by another recent study by Chongitas *et al*<sup>[132]</sup>. They have shown that maintenance therapy with NAs prophylaxis after HBIG discontinuation was effective against HBV/HDV recurrence, but it seems that a longer period of HBIG administration might be needed before it is withdrawn after LT. Another large study from Asia has shown long-term ETV monotherapy (without HBIG) is highly effective at preventing HBV reactivation after LT for CHB, with a durable HBsAg seroclearance rate of 92%, an undetectable HBV DNA rate of 100% at 8 years, and

excellent long-term survival of 85% at 9 years. The positive outcomes with the use of ETV monotherapy without HBIG has challenged the need for HBIG post-LT<sup>[161]</sup>. A recent network metanalysis has shown that ETV resulted with the highest probability (31%) as the best prophylactic option on reducing the risk of HBV recurrence. ETV is the preferred oral NAs treatment compared to other five different prophylactic regimens (LAM, TDF, ADV, LAM plus ADV, LAM plus TDF) in the prevention of HBV recurrence after LT<sup>[162]</sup>. With currently preferred antivirals, namely, those with high barrier to resistance, more patients are likely to have low or undetectable viral load at the time of transplantation and an HBIG-free regimen will more likely be acceptable in the vast majority (Figures 2 and 4). On the other hand, HBIG is still an integral part of prophylaxis in high-risk patients with high pre-transplant HBV DNA level, presence of HCC at LT, co-infection with HIV and HDV, presence of drug-resistance and non-compliance with therapy<sup>[152]</sup>. However, duration of HBIG in such patients can be guided by testing of serial serum HBV DNA level, and HBsAg status (Figures 2 and 4). A recent study however has challenged this notion, and noted that oral antiviral therapy alone without HBIG is highly effective in preventing reactivation of HBV infection and graft loss from recurrent hepatitis B after LT in patients with preexisting HBV LAM resistance<sup>[163]</sup>. The cumulative rate of HBsAg seroclearance at 1, 5, and 10 years was 82%, 88%, and 91%, respectively. At the time



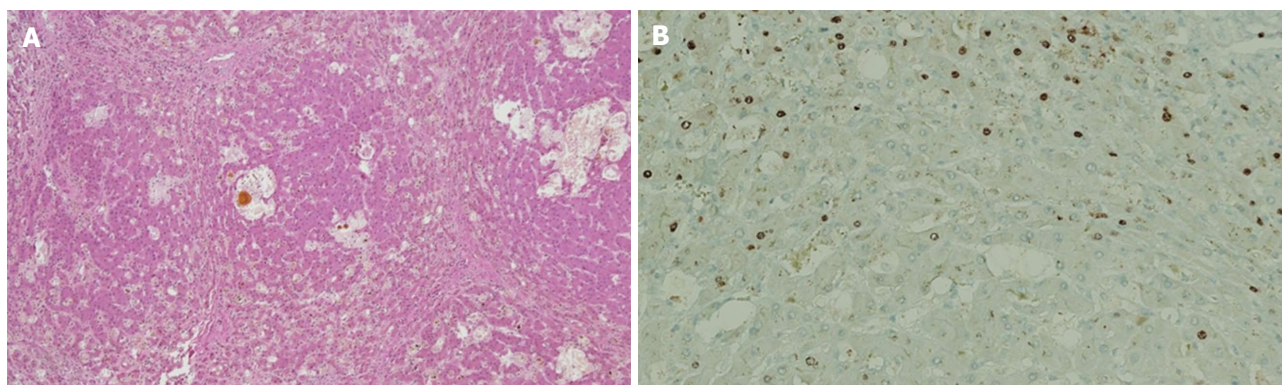
**Figure 3 Proposed algorithm for hepatitis B prophylaxis in liver transplant patients.** In chronic hepatitis B patients Entecavir (if no prior Lamivudine therapy) or Tenofovir (adjusted to renal function) is recommended as the first line therapy. Based on HBV DNA level at the time of transplant and risk factors, HBIG should be initiated, if associated risk factors for HBV recurrence post LT. High risk patients include drug resistant HBV, HIV co-infection, HDV co-infection, HCC. This group of patients receive high dose IV HBIG 10000 IU given during the anhepatic phase followed by low dose HBIG to achieve target anti HBs > 100 IU/mL along with NAs. HBIG is discontinued once HBV DNA is undetectable and loss of HBsAg is achieved. HBIG: Hepatitis B immunoglobulin; HBV: Hepatitis B virus; HBsAg: Hepatitis B surface antigen; HCC: Hepatocellular carcinoma; HIV: Human immunodeficiency virus; HDV: Hepatitis delta virus; LAM: Lamivudine; LT: Liver transplantation.

of transplantation, 39 (72%) patients had detectable HBV DNA, with a median of 4.5 log copies/mL. The cumulative rate of HBV undetectability was 91% at 1 year, increasing to 100% by 5 years. After 1 year of LT, over 90% of the patients had undetectable HBV DNA, and from 8 years onward, 100% had undetectable HBV DNA in serum. The long-term outcome was excellent, with survival of 87% at 12 years after transplantation, without any mortality related to HBV reactivation. However, HBIG does provide additional benefits beyond preventing HBV recurrence in LT recipients such as its association with reduced rates of rejection<sup>[164,165]</sup>, and modifying risk of developing HCC post-LT<sup>[166]</sup>. Another important consideration is the potential for preventing graft reinfection such that subsequent discontinuation

of all immunoprophylaxis can be considered<sup>[167]</sup>. The proposed algorithm for HBV prophylaxis for CHB patients undergoing LT is summarized in Figures 1 and 3.

### Complete discontinuation of all prophylaxis

Based on the previous data and clinical studies, lifelong prophylaxis is currently advocated to LT patients to prevent HBV recurrence. Lenci *et al.*<sup>[167]</sup> investigated the safety of withdrawal of prophylactic measures in selected LT patients using a stepwise protocol. The LT patients underwent liver biopsies after receiving a HBIG-LAM combination therapy. It was shown that careful withdrawal of HBIG was safe in patients with undetectable HBV viremia at transplantation and no evidence of total and intrahepatic cccDNA.



**Figure 4 Immunostaining.** A: Recurrent hepatitis B virus infection leading to cirrhosis in a post-liver transplantation patient. Figure shows cirrhotic nodules with cholestasis but no appreciable inflammation; B: Immunostaining for hepatitis B core antigen shows strong nuclear accumulation of antigen in a small proportion of hepatocytes indicating active virus propagation.

More recent study showed that complete prophylaxis withdrawal is safe in patients transplanted for HBV-related disease at low risk of recurrence and is often followed by spontaneous anti-HBs seroconversion<sup>[168]</sup>. However, based on previous studies many centers continue prophylaxis indefinitely as low level HBV viremia is known to persist even after many years of therapy<sup>[167,169]</sup>, and complete discontinuation of all preventative therapy cannot be recommended at this time and should only be performed in the setting of a clinical trial<sup>[170]</sup>.

#### **HBV vaccination and active immunity**

Although there is no effective clearance, to ensure a maximum suppression of HBV in LT patients and avoidance of escape mutations caused by long-term administration of HBIG or NAs, it is crucial to develop a strong and long lasting immune response against HBV. Several trials have noted an increase in anti-HBs titer in up to 65% of patients who received HBV vaccination after LT following HBIG withdrawal<sup>[141]</sup>. More recent study looking at active immunization in *de novo* HBV infection after LT with a HBV core antigen-positive graft have shown that active immunization is effective in preventing *de novo* infection if the post-transplant anti-HBs level is maintained above 100 IU/L with vaccination and antiviral prophylaxis. Prophylaxis can be safely discontinued in this group of patients who obtain this immunity<sup>[171]</sup>.

#### **Emerging therapies and the future of HBV treatment**

Current HBV prophylaxis and treatment modalities can only suppress but do not eradicate HBV infection completely; therefore there is a lifelong need for the therapy. Recently, there is a renewed interest to target various stages HBV replication cycle and its interaction with the host.

DAA and host-targeting agents (HTA) are the two major categories that are being developed and are at various phases of clinical trials<sup>[2,13]</sup>. Among these, DAAs act by inhibiting viral enzymatic activities or protein function, and generally have excellent safety

profile, therefore present an attractive option for drug manufacturers. Major HBV target-specific classes of DAAs that are being developed are inhibitors of cccDNA (e.g., CRISPR/Cas9, sirt1/2, MC2792), hepatocyte entry receptor inhibitors (*via* NTCP; *i.e.*, mycludex, ezetimibe), HBV DNA polymerase inhibitors (HB pol; e.g., GS-7340, besifovir), siRNA target (ARC-520/521), core allosteric modulators (CpAM; e.g., NVR 3-778), immune modulators (e.g., GS9620, nivolumab, pidilizumab), and therapeutic vaccines (e.g., TG-1050)<sup>[2,172-177]</sup>. These drugs are at various stages of clinical trials and they indicate a promising future for HBV prophylaxis and treatment.

## **CONCLUSION**

With the advent of LT is currently regarded as the ultimate option for treatment for liver cirrhosis, liver failure and HCC associated with chronic HBV infection. Phenomenal success in allograft survival has been achieved by use of HBIG and oral antiviral medications. Prophylaxis with low dose HBIG and oral anti-HBV nucleotides is universally accepted as an effective option to reduce post-transplant viral reactivation. Availability of newer oral anti-HBV nucleos(t)ide analogs (NA), such as ETV and TDF, with higher barriers to resistance and better knowledge of risk factors associated with post-LT HBV reactivation have allowed incorporating these newer NA as part of the antiviral regimen after LT for CHB patients. The use of combination HBIG and lamivudine remains only of historical interest at this time as neither alone was sufficient to prevent HBV recurrence. ETV with its excellent safety profile, low nephrotoxicity, remains the agent of choice for patients without prior lamivudine resistance. For those with prior resistance, the addition of TDF is likely the best treatment option. LT with anti-HBc-positive donors is now possible due to better understanding of the balance between recurrence risk and availability of individualized prophylaxis strategies, and has expanded the pool of donor in an era with high demand for cadaveric donor with scarce supply. Current treatment regimen for

HBV can only control HBV replication, but cannot fully eradicate. As such, efficacy of HBV prophylaxis should be measured by its ability to prevent graft hepatitis and loss secondary to HBV infection, and not in terms of achieving a cure. With currently available potent NA we can achieve substantial suppression of HBV replication, but we are far from achieving viral eradication, although newer antiviral treatments approaches are in development. Hence, a positive HBsAg in post-LT period does not necessarily means HBV recurrence, as the patient has never achieved a virological cure. It is for the same reason we can argue that continuation of HBIG to achieve seroclearance of HBsAg does not achieve any clinical utility as long as viral suppression is achieved with NA. By administering HBIG to keep the antibody titers above a certain arbitrary level, serum HBsAg logically becomes undetectable because of the formation of immune complexes, which evades detection. However, this does not equate to complete eradication, nor the reappearance of serum HBsAg upon stopping HBIG signifies reactivation. In fact, hepatitis B core antigen remains detectable in the liver throughout HBIG administration despite serum HBsAg negativity. As such, long-term prophylaxis with HBIG does not serve any clinical utility and early discontinuation of this practice should be considered as long as complete viral suppression is achieved.

Emerging therapies are now focusing on newer targets of HBV replication and virus-host interaction with an ambitious goal of eradicating HBV infection in the near future rather than mere viral suppression.

## ACKNOWLEDGMENTS

Ranjit Chauhan and Tomasz I Michalak thanks the Canadian Cancer Society, Environment-Cancer Fund and the Canadian Institutes of Health Research for operating research grant support. Photomicrographs courtesy of Dr. Ian Clark, Department of Pathology and Laboratory Medicine, UTHSC Memphis TN.

## REFERENCES

- 1 **El-Serag HB.** Epidemiology of viral hepatitis and hepatocellular carcinoma. *Gastroenterology* 2012; **142**: 1264-1273.e1 [PMID: 22537432 DOI: 10.1053/j.gastro.2011.12.061]
- 2 **Durantel D, Zoulim F.** New antiviral targets for innovative treatment concepts for hepatitis B virus and hepatitis delta virus. *J Hepatol* 2016; **64**: S117-S131 [PMID: 27084032 DOI: 10.1016/j.jhep.2016.02.016]
- 3 **Ryerson AB, Ehemann CR, Altekruse SF, Ward JW, Jemal A, Sherman RL, Henley SJ, Holtzman D, Lake A, Noone AM, Anderson RN, Ma J, Ly KN, Cronin KA, Penberthy L, Kohler BA.** Annual Report to the Nation on the Status of Cancer, 1975-2012, featuring the increasing incidence of liver cancer. *Cancer* 2016; **122**: 1312-1337 [PMID: 26959385 DOI: 10.1002/cncr.29936]
- 4 **Song GW, Ahn CS, Lee SG, Hwang S, Kim KH, Moon DB, Ha TY, Jung DH, Park GC, Kang SH, Jung BH, Kim N.** Correlation between risk of hepatitis B virus recurrence and tissue expression of covalently closed circular DNA in living donor liver transplant recipients treated with high-dose hepatitis B immunoglobulin. *Transplant Proc* 2014; **46**: 3548-3553 [PMID: 25498087 DOI: 10.1016/j.transproceed.2014.06.074]
- 5 **Wu D, Ning Q.** Toward a Cure for Hepatitis B Virus Infection: Combination Therapy Involving Viral Suppression and Immune Modulation and Long-term Outcome. *J Infect Dis* 2017; **216**: S771-S777 [PMID: 29156046 DOI: 10.1093/infdis/jix355]
- 6 **Sarin SK, Kumar M, Lau GK, Abbas Z, Chan HL, Chen CJ, Chen DS, Chen HL, Chen PJ, Chien RN, Dokmeci AK, Gane E, Hou JL, Jafri W, Jia J, Kim JH, Lai CL, Lee HC, Lim SG, Liu CJ, Locarnini S, Al Mahtab M, Mohamed R, Omata M, Park J, Piratvisuth T, Sharma BC, Sollano J, Wang FS, Wei L, Yuen MF, Zheng SS, Kao JH.** Asian-Pacific clinical practice guidelines on the management of hepatitis B: a 2015 update. *Hepatol Int* 2016; **10**: 1-98 [PMID: 26563120 DOI: 10.1007/s12072-015-9675-4]
- 7 **Geipel A, Seiz PL, Niekamp H, Neumann-Fraune M, Zhang K, Kaiser R, Protzer U, Gerlich WH, Glebe D; HOPE Consortium.** Entecavir allows an unexpectedly high residual replication of HBV mutants resistant to lamivudine. *Antivir Ther* 2015; **20**: 779-787 [PMID: 25560463 DOI: 10.3851/IMP2928]
- 8 **Hiramatsu N, Yamada R, Takehara T.** The suppressive effect of nucleos(t)ide analogue treatment on the incidence of hepatocellular carcinoma in chronic hepatitis B patients. *J Gastroenterol Hepatol* 2016; **31**: 546-552 [PMID: 26574149 DOI: 10.1111/jgh.13229]
- 9 **Michalak TI.** Occult persistence and lymphotropism of hepadnaviral infection: insights from the woodchuck viral hepatitis model. *Immunol Rev* 2000; **174**: 98-111 [PMID: 10807510]
- 10 **Maier M, Liebert UG, Wittekind C, Kaiser T, Berg T, Wiegand J.** Clinical Relevance of Minimal Residual Viremia during Long-Term Therapy with Nucleos(t)ide Analogues in Patients with Chronic Hepatitis B. *PLoS One* 2013; **8**: e67481 [PMID: 23826307 DOI: 10.1371/journal.pone.0067481]
- 11 **Moraleda G, Saputelli J, Aldrich CE, Averett D, Condreay L, Mason WS.** Lack of effect of antiviral therapy in nondividing hepatocyte cultures on the closed circular DNA of woodchuck hepatitis virus. *J Virol* 1997; **71**: 9392-9399 [PMID: 9371599]
- 12 **Nassal M.** HBV cccDNA: viral persistence reservoir and key obstacle for a cure of chronic hepatitis B. *Gut* 2015; **64**: 1972-1984 [PMID: 26048673 DOI: 10.1136/gutjnl-2015-309809]
- 13 **Zoulim F, Durantel D.** Antiviral therapies and prospects for a cure of chronic hepatitis B. *Cold Spring Harb Perspect Med* 2015; **5**: pii: a021501 [PMID: 25833942 DOI: 10.1101/cshperspect.a021501]
- 14 **Samuel D, Bismuth A, Mathieu D, Arulnaden JL, Reynes M, Benhamou JP, Brechot C, Bismuth H.** Passive immunoprophylaxis after liver transplantation in HBsAg-positive patients. *Lancet* 1991; **337**: 813-815 [PMID: 1672913]
- 15 **Samuel D, Muller R, Alexander G, Fassati L, Ducot B, Benhamou JP, Bismuth H.** Liver transplantation in European patients with the hepatitis B surface antigen. *N Engl J Med* 1993; **329**: 1842-1847 [PMID: 8247035 DOI: 10.1056/nejm199312163292503]
- 16 **Sawyer RG, McGory RW, Gaffey MJ, McCullough CC, Shephard BL, Houlgrave CW, Ryan TS, Kuhns M, McNamara A, Caldwell SH, Abdulkareem A, Pruett TL.** Improved clinical outcomes with liver transplantation for hepatitis B-induced chronic liver failure using passive immunization. *Ann Surg* 1998; **227**: 841-850 [PMID: 9637547]
- 17 **Faria LC, Gigou M, Roque-Afonso AM, Sebah M, Roche B, Fallot G, Ferrari TC, Guettier C, Dussaix E, Castaing D, Brechot C, Samuel D.** Hepatocellular carcinoma is associated with an increased risk of hepatitis B virus recurrence after liver transplantation. *Gastroenterology* 2008; **134**: 1890-1899; quiz 2155 [PMID: 18424269 DOI: 10.1053/j.gastro.2008.02.064]
- 18 **Marzano A, Gaia S, Ghisetti V, Carenzi S, Premoli A, Debernardi-Venon W, Alessandria C, Franchello A, Salizzoni M, Rizzetto M.** Viral load at the time of liver transplantation and risk of hepatitis B virus recurrence. *Liver Transpl* 2005; **11**: 402-409 [PMID: 15776431 DOI: 10.1002/lt.20402]
- 19 **Mutimer D, Pillay D, Dragon E, Tang H, Ahmed M, O'Donnell K, Shaw J, Burroughs N, Rand D, Cane P, Martin B, Buchan S, Boxall E, Barmat S, Gutekunst K, McMaster P, Elias E.** High pre-treatment serum hepatitis B virus titre predicts failure

- of lamivudine prophylaxis and graft re-infection after liver transplantation. *J Hepatol* 1999; **30**: 715-721 [PMID: 10207815]
- 20 Coffin CS, Shaheen AA, Burak KW, Myers RP. Pregnancy outcomes among liver transplant recipients in the United States: a nationwide case-control analysis. *Liver Transpl* 2010; **16**: 56-63 [PMID: 20035524 DOI: 10.1002/lt.21906]
  - 21 Sarin SK, Satapathy SK, Chauhan R. Hepatitis B e-antigen negative chronic hepatitis B. *J Gastroenterol Hepatol* 2002; **17** Suppl 3: S311-S321 [PMID: 12472956]
  - 22 Will H, Reiser W, Weimer T, Pfaff E, Büscher M, Sprengel R, Cattaneo R, Schaller H. Replication strategy of human hepatitis B virus. *J Virol* 1987; **61**: 904-911 [PMID: 3806799]
  - 23 Werle-Lapostolle B, Bowden S, Locarnini S, Wursthorn K, Petersen J, Lau G, Trepo C, Marcellin P, Goodman Z, Delaney WE 4th, Xiong S, Brosgart CL, Chen SS, Gibbs CS, Zoulim F. Persistence of cccDNA during the natural history of chronic hepatitis B and decline during adefovir dipivoxil therapy. *Gastroenterology* 2004; **126**: 1750-1758 [PMID: 15188170]
  - 24 Wong DK, Seto WK, Fung J, Ip P, Huang FY, Lai CL, Yuen MF. Reduction of hepatitis B surface antigen and covalently closed circular DNA by nucleos(t)ide analogues of different potency. *Clin Gastroenterol Hepatol* 2013; **11**: 1004-10.e1 [PMID: 23376799 DOI: 10.1016/j.cgh.2013.01.026]
  - 25 Papatheodoridis GV, Manolakopoulos S, Touloumi G, Vourli G, Raptopoulou-Gigi M, Vafiadis-Zoumbouli I, Vasiliadis T, Mimidis K, Gogos C, Ketikoglou I, Manesis EK; HEPNET. Greece Cohort Study Group. Virological suppression does not prevent the development of hepatocellular carcinoma in HBeAg-negative chronic hepatitis B patients with cirrhosis receiving oral antiviral(s) starting with lamivudine monotherapy: results of the nationwide HEPNET. Greece cohort study. *Gut* 2011; **60**: 1109-1116 [PMID: 21270118 DOI: 10.1136/gut.2010.221846]
  - 26 Cheung CK, Lo CM, Man K, Lau GK. Occult hepatitis B virus infection of donor and recipient origin after liver transplantation despite nucleoside analogue prophylaxis. *Liver Transpl* 2010; **16**: 1314-1323 [PMID: 21031547 DOI: 10.1002/lt.22169]
  - 27 Coffin CS, Pham TN, Mulrooney PM, Churchill ND, Michalak TI. Persistence of isolated antibodies to woodchuck hepatitis virus core antigen is indicative of occult infection. *Hepatology* 2004; **40**: 1053-1061 [PMID: 15382154 DOI: 10.1002/hep.20419]
  - 28 Hoofnagle JH, Seeff LB, Bales ZB, Zimmerman HJ. Type B hepatitis after transfusion with blood containing antibody to hepatitis B core antigen. *N Engl J Med* 1978; **298**: 1379-1383 [PMID: 652005 DOI: 10.1056/NEJM197806222982502]
  - 29 Shouval D. The search for a new endpoint for antiviral prophylaxis in hepatitis B virus transplanted patients. *Dig Liver Dis* 2010; **42**: 537-538 [PMID: 20619822 DOI: 10.1016/j.dld.2010.06.006]
  - 30 Kay A, Zoulim F. Hepatitis B virus genetic variability and evolution. *Virus Res* 2007; **127**: 164-176 [PMID: 17383765 DOI: 10.1016/j.virusres.2007.02.021]
  - 31 Tian Q, Jia J. Hepatitis B virus genotypes: epidemiological and clinical relevance in Asia. *Hepatol Int* 2016; **10**: 854-860 [PMID: 27300749 DOI: 10.1007/s12072-016-9745-2]
  - 32 Tanwar S, Dusheiko G. Is there any value to hepatitis B virus genotype analysis? *Curr Gastroenterol Rep* 2012; **14**: 37-46 [PMID: 22105466 DOI: 10.1007/s11894-011-0233-5]
  - 33 Wen WH, Chen HL, Ni YH, Hsu HY, Kao JH, Hu FC, Chang MH. Secular trend of the viral genotype distribution in children with chronic hepatitis B virus infection after universal infant immunization. *Hepatology* 2011; **53**: 429-436 [PMID: 21274864 DOI: 10.1002/hep.24061]
  - 34 Devarbhavi HC, Cohen AJ, Patel R, Wiesner RH, Dickson RC, Ishitani MB. Preliminary results: outcome of liver transplantation for hepatitis B virus varies by hepatitis B virus genotype. *Liver Transpl* 2002; **8**: 550-555 [PMID: 12037787 DOI: 10.1053/jlts.2002.33483]
  - 35 Zöllner B, Feucht HH, Sterneck M, Schäfer H, Rogiers X, Fischer L. Clinical reactivation after liver transplantation with an unusual minor strain of hepatitis B virus in an occult carrier. *Liver Transpl* 2006; **12**: 1283-1289 [PMID: 16868945 DOI: 10.1002/lt.20858]
  - 36 Chauhan R, Singh AK, Rooze S, Varshney A, Kumar M, Sarin SK. Analysis of hepatitis B virus genotype changes in patients with chronic hepatitis B infection on tenofovir therapy. *J Med Virol* 2016; **88**: 1364-1375 [PMID: 26858138 DOI: 10.1002/jmv.24489]
  - 37 Buti M, Tabernero D, Mas A, Homs M, Prieto M, Rodríguez-Frias F, Casafont F, Casillas R, González A, Miras M, Herrero JL, Castells L, Esteban R. Hepatitis B virus quasispecies evolution after liver transplantation in patients under long-term lamivudine prophylaxis with or without hepatitis B immune globulin. *Transpl Infect Dis* 2015; **17**: 208-220 [PMID: 25641570 DOI: 10.1111/tid.12360]
  - 38 Mina T, Amini-Bavil-Olyae S, Dekervel J, Verslype C, Nevens F, Maes P, Tacke F, Van Ranst M, Pourkarim MR. A rare case of HBV genotype fluctuation (shifting and reversion) after liver transplantation. *J Clin Virol* 2015; **71**: 93-97 [PMID: 26342803 DOI: 10.1016/j.jcv.2015.08.010]
  - 39 Lin JH, Chang MF, Baker SC, Govindarajan S, Lai MM. Characterization of hepatitis delta antigen: specific binding to hepatitis delta virus RNA. *J Virol* 1990; **64**: 4051-4058 [PMID: 2200884]
  - 40 Roche B, Samuel D. Liver transplantation in delta virus infection. *Semin Liver Dis* 2012; **32**: 245-255 [PMID: 22932973 DOI: 10.1055/s-0032-1323630]
  - 41 Marsman WA, Wiesner RH, Batts KP, Poterucha JJ, Porayko MK, Niesters HG, Zondervan PE, Krom RA. Fulminant hepatitis B virus: recurrence after liver transplantation in two patients also infected with hepatitis delta virus. *Hepatology* 1997; **25**: 434-438 [PMID: 9021960 DOI: 10.1002/hep.510250230]
  - 42 Bahde R, Hölzen JP, Wolters HH, Schmidt HH, Bock CT, Lügering A, Spieker T, Senninger N, Brockmann JG. Course of a HBsAg positive liver transplantation in a hepatitis B and D virus coinfecting recipient. *Ann Hepatol* 2011; **10**: 355-360 [PMID: 21677340]
  - 43 Franchello A, Ghisetti V, Marzano A, Romagnoli R, Salizzoni M. Transplantation of hepatitis B surface antigen-positive livers into hepatitis B virus-positive recipients and the role of hepatitis delta coinfection. *Liver Transpl* 2005; **11**: 922-928 [PMID: 16035057 DOI: 10.1002/lt.20471]
  - 44 Lempp FA, Urban S. Hepatitis Delta Virus: Replication Strategy and Upcoming Therapeutic Options for a Neglected Human Pathogen. *Viruses* 2017; **9**: pii: E172 [PMID: 28677645 DOI: 10.3390/v9070172]
  - 45 Ottobrelli A, Marzano A, Smedile A, Recchia S, Salizzoni M, Cornu C, Lamy ME, Otte JB, De Hemptinne B, Geubel A. Patterns of hepatitis delta virus reinfection and disease in liver transplantation. *Gastroenterology* 1991; **101**: 1649-1655 [PMID: 1955130]
  - 46 Smedile A, Casey JL, Cote PJ, Durazzo M, Lavezzo B, Purcell RH, Rizzetto M, Gerin JL. Hepatitis D viremia following orthotopic liver transplantation involves a typical HDV virion with a hepatitis B surface antigen envelope. *Hepatology* 1998; **27**: 1723-1729 [PMID: 9620349 DOI: 10.1002/hep.510270636]
  - 47 Stroffolini T, Sagnelli E, Sagnelli C, Russello M, De Luca M, Rosina F, Cacopardo B, Brancaccio G, Furlan C, Gaeta GB, Licata A, Almasio PL; behalf of EPACRON study group. Hepatitis delta infection in Italian patients: towards the end of the story? *Infection* 2017; **45**: 277-281 [PMID: 27817147 DOI: 10.1007/s15010-016-0956-1]
  - 48 Miyaaki H, Tamada Y, Hayashi K, Taura N, Miuma S, Shibata H, Soyama A, Hidaka M, Takatsuki M, Eguchi S, Nakao K. Recurrent Hepatitis B and D Virus Infection in a Liver Transplant Recipient. *Transplant Proc* 2017; **49**: 175-177 [PMID: 28104130 DOI: 10.1016/j.transproceed.2016.11.010]
  - 49 Handa H, Yamaguchi Y. Hepatitis Delta Virus. New York: Springer US, 2007
  - 50 Taylor JM. Host RNA circles and the origin of hepatitis delta virus. *World J Gastroenterol* 2014; **20**: 2971-2978 [PMID: 24659888 DOI: 10.3748/wjg.v20.i11.2971]
  - 51 Negro F. Hepatitis D Virus Coinfection and Superinfection. *Cold Spring Harb Perspect Med* 2014; **4**: a021550 [PMID: 25368018 DOI: 10.1101/cshperspect.a021550]

- 52 **Mederacke I**, Filmann N, Yurdaydin C, Bremer B, Puls F, Zacher BJ, Heidrich B, Tillmann HL, Rosenau J, Bock CT, Savas B, Helfritz F, Lehner F, Strassburg CP, Klempnauer J, Wursthorn K, Lehmann U, Manns MP, Herrmann E, Wedemeyer H. Rapid early HDV RNA decline in the peripheral blood but prolonged intrahepatic hepatitis delta antigen persistence after liver transplantation. *J Hepatol* 2012; **56**: 115-122 [PMID: 21762665 DOI: 10.1016/j.jhep.2011.06.016]
- 53 **David E**, Rahier J, Pucci A, Camby P, Scevens M, Salizzoni M, Otte JB, Galmarini D, Marinucci G, Ottobrelli A. Recurrence of hepatitis D (delta) in liver transplants: histopathological aspects. *Gastroenterology* 1993; **104**: 1122-1128 [PMID: 8462801]
- 54 **Lucey MR**, Graham DM, Martin P, Di Bisceglie A, Rosenthal S, Waggoner JG, Merion RM, Campbell DA, Nostrant TT, Appelman HD. Recurrence of hepatitis B and delta hepatitis after orthotopic liver transplantation. *Gut* 1992; **33**: 1390-1396 [PMID: 1446866]
- 55 **Adil B**, Fatih O, Volkan I, Bora B, Veysel E, Koray K, Cemalettin K, Burak I, Sezai Y. Hepatitis B Virus and Hepatitis D Virus Recurrence in Patients Undergoing Liver Transplantation for Hepatitis B Virus and Hepatitis B Virus Plus Hepatitis D Virus. *Transplant Proc* 2016; **48**: 2119-2123 [PMID: 27569956 DOI: 10.1016/j.transproceed.2016.02.076]
- 56 **Jiang Z**, Feng X, Zhang W, Gao F, Ling Q, Zhou L, Xie H, Chen Q, Zheng S. Recipient cytotoxic T lymphocyte antigen -4+ 49 G/G genotype is associated with reduced incidence of hepatitis B virus recurrence after liver transplantation among Chinese patients. *Liver Int* 2007; **27**: 1202-1208 [PMID: 17919231 DOI: 10.1111/j.1478-3231.2007.01553.x]
- 57 **Thio CL**, Mosbruger TL, Kaslow RA, Karp CL, Strathdee SA, Vlahov D, O'Brien SJ, Astemborski J, Thomas DL. Cytotoxic T-lymphocyte antigen 4 gene and recovery from hepatitis B virus infection. *J Virol* 2004; **78**: 11258-11262 [PMID: 15452244 DOI: 10.1128/JVI.78.20.11258-11262.2004]
- 58 **Liaw YF**, Yeh CT, Tsai SL. Impact of acute hepatitis B virus superinfection on chronic hepatitis C virus infection. *Am J Gastroenterol* 2000; **95**: 2978-2980 [PMID: 11051381 DOI: 10.1111/j.1572-0241.2000.02337.x]
- 59 **Couto I**, Victoria M, Veloso VG, Rodrigues L, Grinsztejn B, Lacerda M, Victoria F, Perazzo H. Prevalence and predictors for compensated Advanced Chronic Liver Disease (c-ACLD) in patients with chronic Hepatitis Delta Virus (HDV) infection. *PLoS One* 2017; **12**: e0174453 [PMID: 28329027 DOI: 10.1371/journal.pone.0174453]
- 60 **Smedile A**, Farci P, Verme G, Caredda F, Cargnel A, Caporaso N, Dentico P, Trepo C, Opolon P, Gimson A, Vergani D, Williams R, Rizzetto M. Influence of delta infection on severity of hepatitis B. *Lancet* 1982; **2**: 945-947 [PMID: 6127458]
- 61 **Krogsgaard K**, Kryger P, Aldershvile J, Andersson P, Sørensen TI, Nielsen JO. Delta-infection and suppression of hepatitis B virus replication in chronic HBsAg carriers. *Hepatology* 1987; **7**: 42-45 [PMID: 3804204]
- 62 **Farci P**, Karayiannis P, Lai ME, Marongiu F, Orgiana G, Balestrieri A, Thomas HC. Acute and chronic hepatitis delta virus infection: direct or indirect effect on hepatitis B virus replication? *J Med Virol* 1988; **26**: 279-288 [PMID: 3204366]
- 63 **Rajoriya N**, Combet C, Zoulim F, Janssen HLA. How viral genetic variants and genotypes influence disease and treatment outcome of chronic hepatitis B. Time for an individualised approach? *J Hepatol* 2017; **67**: 1281-1297 [PMID: 28736138 DOI: 10.1016/j.jhep.2017.07.011]
- 64 **Araujo NM**. Hepatitis B virus intergenotypic recombinants worldwide: an overview. *Infect Genet Evol* 2015; **36**: 500-510 [PMID: 26299884 DOI: 10.1016/j.meegid.2015.08.024]
- 65 **Sy BT**, Nguyen HM, Toan NL, Song LH, Tong HV, Wolboldt C, Binh VQ, Kremsner PG, Velavan TP, Bock CT. Identification of a natural intergenotypic recombinant hepatitis delta virus genotype 1 and 2 in Vietnamese HBsAg-positive patients. *J Viral Hepat* 2015; **22**: 55-63 [PMID: 24548489 DOI: 10.1111/jvh.12228]
- 66 **Chauhan R**, Kazim SN, Kumar M, Bhattacharjee J, Krishnamoorthy N, Sarin SK. Identification and characterization of genotype A and D recombinant hepatitis B virus from Indian chronic HBV isolates. *World J Gastroenterol* 2008; **14**: 6228-6236 [PMID: 18985816 DOI: 10.3748/wjg.14.6228]
- 67 **Kao JH**, Chen PJ, Lai MY, Chen DS. Acute exacerbations of chronic hepatitis B are rarely associated with superinfection of hepatitis B virus. *Hepatology* 2001; **34**: 817-823 [PMID: 11584381 DOI: 10.1053/jhep.2001.28188]
- 68 **Palumbo E**. Hepatitis B genotypes and response to antiviral therapy: a review. *Am J Ther* 2007; **14**: 306-309 [PMID: 17515708 DOI: 10.1097/01.pap.0000249927.67907.eb]
- 69 **Kim DY**, Kim HJ, Lee CK, Suh JH, Kim DH, Cho YS, Won SY, Park BK, Park IS. Efficacy of adefovir dipivoxil in the treatment of lamivudine-resistant hepatitis B virus genotype C infection. *Liver Int* 2007; **27**: 47-53 [PMID: 17241380 DOI: 10.1111/j.1478-3231.2006.01407.x]
- 70 **Betz-Stablein B**, Töpfer A, Littlejohn M, Yuen L, Colledge D, Sozzi V, Angus P, Thompson A, Revill P, Beerenwinkel N. Single-molecule sequencing reveals complex genome variation of hepatitis B virus during 15 years of chronic infection following liver transplantation. *J Virol* 2016; **90**: 7171-7183 [PMID: 27252524 DOI: 10.1128/JVI.00243-16]
- 71 **Brechot C**, Pourcel C, Louise A, Rain B, Tiollais P. Presence of integrated hepatitis B virus DNA sequences in cellular DNA of human hepatocellular carcinoma. *Nature* 1980; **286**: 533-535 [PMID: 6250074]
- 72 **Bréchet C**, Hadchouel M, Scotto J, Fonck M, Potet F, Vyas GN, Tiollais P. State of hepatitis B virus DNA in hepatocytes of patients with hepatitis B surface antigen-positive and -negative liver diseases. *Proc Natl Acad Sci USA* 1981; **78**: 3906-3910 [PMID: 6267609]
- 73 **Chauhan R**, Churchill ND, Mulrooney-Cousins PM, Michalak TI. Initial sites of hepadnavirus integration into host genome in human hepatocytes and in the woodchuck model of hepatitis B-associated hepatocellular carcinoma. *Oncogenesis* 2017; **6**: e317 [PMID: 28414318 DOI: 10.1038/oncsis.2017.22]
- 74 **Saitta C**, Tripodi G, Barbera A, Bertuccio A, Smedile A, Ciancio A, Raffa G, Sangiovanni A, Navarra G, Raimondo G, Pollicino T. Hepatitis B virus (HBV) DNA integration in patients with occult HBV infection and hepatocellular carcinoma. *Liver Int* 2015; **35**: 2311-2317 [PMID: 25677098 DOI: 10.1111/liv.12807]
- 75 **Mulrooney-Cousins PM**, Chauhan R, Churchill ND, Michalak TI. Primary seronegative but molecularly evident hepadnaviral infection engages liver and induces hepatocarcinoma in the woodchuck model of hepatitis B. *PLoS Pathog* 2014; **10**: e1004332 [PMID: 25165821 DOI: 10.1371/journal.ppat.1004332]
- 76 **Ikeda K**, Kobayashi M, Someya T, Saitoh S, Hosaka T, Akuta N, Suzuki F, Suzuki Y, Arase Y, Kumada H. Occult hepatitis B virus infection increases hepatocellular carcinogenesis by eight times in patients with non-B, non-C liver cirrhosis: a cohort study. *J Viral Hepat* 2009; **16**: 437-443 [PMID: 19226331 DOI: 10.1111/j.1365-2893.2009.01085.x]
- 77 **Ferrari TC**, Xavier MA, Vidigal PV, Amaral NS, Diniz PA, Resende AP, Miranda DM, Faria AC, Lima AS, Faria LC. Occult hepatitis B virus infection in liver transplant patients in a Brazilian referral center. *Braz J Med Biol Res* 2014; **47**: 990-994 [PMID: 25296362]
- 78 **Sagnelli E**, Pisaturo M, Martini S, Filippini P, Sagnelli C, Coppola N. Clinical impact of occult hepatitis B virus infection in immunosuppressed patients. *World J Hepatol* 2014; **6**: 384-393 [PMID: 25018849 DOI: 10.4254/wjh.v6.i6.384]
- 79 **Xie M**, Rao W, Yang T, Deng Y, Zheng H, Pan C, Liu Y, Shen Z, Jia J. Occult hepatitis B virus infection predicts de novo hepatitis B infection in patients with alcoholic cirrhosis after liver transplantation. *Liver Int* 2015; **35**: 897-904 [PMID: 24750566 DOI: 10.1111/liv.12567]
- 80 **Marusawa H**, Uemoto S, Hijikata M, Ueda Y, Tanaka K, Shimotohno K, Chiba T. Latent hepatitis B virus infection in healthy individuals with antibodies to hepatitis B core antigen. *Hepatology* 2000; **31**: 488-495 [PMID: 10655275 DOI: 10.1002/hep.510310232]

- 81 **Pontisso P**, Poon MC, Tiollais P, Brechot C. Detection of hepatitis B virus DNA in mononuclear blood cells. *Br Med J (Clin Res Ed)* 1984; **288**: 1563-1566 [PMID: 6426645]
- 82 **Bouffard P**, Lamelin JP, Zoulim F, Pichoud C, Trepo C. Different forms of hepatitis B virus DNA and expression of HBV antigens in peripheral blood mononuclear cells in chronic hepatitis B. *J Med Virol* 1990; **31**: 312-317 [PMID: 2269882]
- 83 **Mason A**, Wick M, White H, Perrillo R. Hepatitis B virus replication in diverse cell types during chronic hepatitis B virus infection. *Hepatology* 1993; **18**: 781-789 [PMID: 8406351]
- 84 **Coffin CS**, Michalak TI. Persistence of infectious hepadnavirus in the offspring of woodchuck mothers recovered from viral hepatitis. *J Clin Invest* 1999; **104**: 203-212 [PMID: 10411550 DOI: 10.1172/JCI5048]
- 85 **Michalak TI**, Pardoe IU, Coffin CS, Churchill ND, Freake DS, Smith P, Trelogan CL. Occult lifelong persistence of infectious hepadnavirus and residual liver inflammation in woodchucks convalescent from acute viral hepatitis. *Hepatology* 1999; **29**: 928-938 [PMID: 10051500 DOI: 10.1002/hep.510290329]
- 86 **Michalak TI**, Mulrooney PM, Coffin CS. Low doses of hepadnavirus induce infection of the lymphatic system that does not engage the liver. *J Virol* 2004; **78**: 1730-1738 [PMID: 14747538]
- 87 **Ogston CW**, Schechter EM, Humes CA, Prankoff MB. Extrahepatic replication of woodchuck hepatitis virus in chronic infection. *Virology* 1989; **169**: 9-14 [PMID: 2922930]
- 88 **Dejean A**, Lugassy C, Zafrani S, Tiollais P, Brechot C. Detection of hepatitis B virus DNA in pancreas, kidney and skin of two human carriers of the virus. *J Gen Virol* 1984; **65** (Pt 3): 651-655 [PMID: 6699625 DOI: 10.1099/0022-1317-65-3-651]
- 89 **Romet-Lemonne JL**, McLane MF, Elfassi E, Haseltine WA, Azocar J, Essex M. Hepatitis B virus infection in cultured human lymphoblastoid cells. *Science* 1983; **221**: 667-669 [PMID: 6867736]
- 90 **Elfassi E**, Romet-Lemonne JL, Essex M, Frances-McLane M, Haseltine WA. Evidence of extrachromosomal forms of hepatitis B viral DNA in a bone marrow culture obtained from a patient recently infected with hepatitis B virus. *Proc Natl Acad Sci USA* 1984; **81**: 3526-3528 [PMID: 6587366]
- 91 **Umeda M**, Marusawa H, Seno H, Katsurada A, Nabeshima M, Egawa H, Uemoto S, Inomata Y, Tanaka K, Chiba T. Hepatitis B virus infection in lymphatic tissues in inactive hepatitis B carriers. *J Hepatol* 2005; **42**: 806-812 [PMID: 15885350 DOI: 10.1016/j.jhep.2005.01.016]
- 92 **Mulrooney-Cousins PM**, Michalak TI. Asymptomatic Hepadnaviral Persistence and Its Consequences in the Woodchuck Model of Occult Hepatitis B Virus Infection. *J Clin Transl Hepatol* 2015; **3**: 211-219 [PMID: 26623268 DOI: 10.14218/JCTH.2015.00020]
- 93 **Lanford RE**, Michaels MG, Chavez D, Brasky K, Fung J, Starzl TE. Persistence of extrahepatic hepatitis B virus DNA in the absence of detectable hepatic replication in patients with baboon liver transplants. *J Med Virol* 1995; **46**: 207-212 [PMID: 7561791]
- 94 **Gao S**, Duan ZP, Chen Y, van der Meer F, Lee SS, Osiowy C, van Marle G, Coffin CS. Compartmental HBV evolution and replication in liver and extrahepatic sites after nucleos(tide) analogue therapy in chronic hepatitis B carriers. *J Clin Virol* 2017; **94**: 8-14 [PMID: 28709006 DOI: 10.1016/j.jcv.2017.06.009]
- 95 **Coffin CS**, Mulrooney-Cousins PM, Peters MG, van Marle G, Roberts JP, Michalak TI, Terrault NA. Molecular characterization of intrahepatic and extrahepatic hepatitis B virus (HBV) reservoirs in patients on suppressive antiviral therapy. *J Viral Hepat* 2011; **18**: 415-423 [PMID: 20626626 DOI: 10.1111/j.1365-2893.2010.01321.x]
- 96 **Coffin CS**, Mulrooney-Cousins PM, van Marle G, Roberts JP, Michalak TI, Terrault NA. Hepatitis B virus quasispecies in hepatic and extrahepatic viral reservoirs in liver transplant recipients on prophylactic therapy. *Liver Transpl* 2011; **17**: 955-962 [PMID: 21462295 DOI: 10.1002/lt.22312]
- 97 **Gish RG**, McCashland T. Hepatitis B in liver transplant recipients. *Liver Transpl* 2006; **12**: S54-S64 [PMID: 17051551 DOI: 10.1002/lt.20950]
- 98 **Kubo S**, Nishiguchi S, Hamba H, Hirohashi K, Tanaka H, Shuto T, Kinoshita H, Kuroki T. Reactivation of viral replication after liver resection in patients infected with hepatitis B virus. *Ann Surg* 2001; **233**: 139-145 [PMID: 11141236]
- 99 **Perrillo RP**, Gish R, Falck-Ytter YT. American Gastroenterological Association Institute technical review on prevention and treatment of hepatitis B virus reactivation during immunosuppressive drug therapy. *Gastroenterology* 2015; **148**: 221-244.e3 [PMID: 25447852 DOI: 10.1053/j.gastro.2014.10.038]
- 100 **Yang HC**, Kao JH. Persistence of hepatitis B virus covalently closed circular DNA in hepatocytes: molecular mechanisms and clinical significance. *Emerg Microbes Infect* 2014; **3**: e64 [PMID: 26038757 DOI: 10.1038/emi.2014.64]
- 101 **Raimondo G**, Allain JP, Brunetto MR, Buendia MA, Chen DS, Colombo M, Craxi A, Donato F, Ferrari C, Gaeta GB, Gerlich WH, Levvero M, Locarnini S, Michalak T, Mondelli MU, Pawlotsky JM, Pollicino T, Prati D, Puoti M, Samuel D, Shouval D, Smedile A, Squadrito G, Trépo C, Villa E, Will H, Zanetti AR, Zoulim F. Statements from the Taormina expert meeting on occult hepatitis B virus infection. *J Hepatol* 2008; **49**: 652-657 [PMID: 18715666 DOI: 10.1016/j.jhep.2008.07.014]
- 102 **Michalak TI**, Pasquinelli C, Guilhot S, Chisari FV. Hepatitis B virus persistence after recovery from acute viral hepatitis. *J Clin Invest* 1994; **94**: 907 [PMID: 8040346]
- 103 **Oh MJ**, Lee HJ. A study of hepatitis B virus reactivation associated with rituximab therapy in real-world clinical practice: a single-center experience. *Clin Mol Hepatol* 2013; **19**: 51-59 [PMID: 23593610 DOI: 10.3350/cmh.2013.19.1.51]
- 104 **Jhuang HJ**, Hsu WH, Lin KT, Hsu SL, Wang FS, Chou CK, Lee KH, Tsou AP, Lai JM, Yeh SF, Huang CY. Gluconeogenesis, lipogenesis, and HBV replication are commonly regulated by PGC-1 $\alpha$ -dependent pathway. *Oncotarget* 2015; **6**: 7788-7803 [PMID: 25762623 DOI: 10.18632/oncotarget.3050]
- 105 **Tur-Kaspa R**, Shaul Y, Moore DD, Burk RD, Okret S, Poellinger L, Shafritz DA. The glucocorticoid receptor recognizes a specific nucleotide sequence in hepatitis B virus DNA causing increased activity of the HBV enhancer. *Virology* 1988; **167**: 630-633 [PMID: 3201757]
- 106 **Huang W**, Zhao F, Huang Y, Li X, Zhu S, Hu Q, Chen W. Rapamycin enhances HBV production by inducing cellular autophagy. *Hepat Mon* 2014; **14**: e20719 [PMID: 25419217 DOI: 10.5812/hepatmon.20719]
- 107 **Brennan DC**, Aguado JM, Potena L, Jardine AG, Legendre C, Säemann MD, Mueller NJ, Merville P, Emery V, Nashan B. Effect of maintenance immunosuppressive drugs on virus pathobiology: evidence and potential mechanisms. *Rev Med Virol* 2013; **23**: 97-125 [PMID: 23165654 DOI: 10.1002/rmv.1733]
- 108 **Hu Z**, Zhou J, Wang H, Zhang M, Li S, Huang Y, Wu J, Li Z, Zhou L, Zheng S. Survival in liver transplant recipients with hepatitis B- or hepatitis C-associated hepatocellular carcinoma: the Chinese experience from 1999 to 2010. *PLoS One* 2013; **8**: e61620 [PMID: 23613886 DOI: 10.1371/journal.pone.0061620]
- 109 **Huang G**, Lau WY, Zhou WP, Shen F, Pan ZY, Yuan SX, Wu MC. Prediction of Hepatocellular Carcinoma Recurrence in Patients With Low Hepatitis B Virus DNA Levels and High Preoperative Hepatitis B Surface Antigen Levels. *JAMA Surg* 2014; **149**: 519-527 [PMID: 24696192 DOI: 10.1001/jamasurg.2013.4648]
- 110 **Marelli L**, Grasso A, Pleguezuelo M, Martinez H, Stigliano R, Dhillon AP, Patch D, Davidson BR, Sharma D, Rolles K, Burroughs AK. Tumour size and differentiation in predicting recurrence of hepatocellular carcinoma after liver transplantation: external validation of a new prognostic score. *Ann Surg Oncol* 2008; **15**: 3503-3511 [PMID: 18777193 DOI: 10.1245/s10434-008-0128-3]
- 111 **Wai CT**, Woon WA, Tan YM, Lee KH, Tan KC. Younger age and presence of macrovascular invasion were independent significant factors associated with poor disease-free survival in hepatocellular carcinoma patients undergoing living donor liver transplantation. *Transplant Proc* 2012; **44**: 516-519 [PMID: 22410059 DOI: 10.1016/j.transproceed.2012.01.032]
- 112 **Bertuzzo VR**, Cescon M, Ravaioli M, Grazi GL, Ercolani G, Del Gaudio M, Cucchetti A, D'Errico-Grigioni A, Golfieri R, Pinna

- AD. Analysis of factors affecting recurrence of hepatocellular carcinoma after liver transplantation with a special focus on inflammation markers. *Transplantation* 2011; **91**: 1279-1285 [PMID: 21617590 DOI: 10.1097/TP.0b013e3182187cf0]
- 113 **Celis E**, Abraham KG, Miller RW. Modulation of the immunological response to hepatitis B virus by antibodies. *Hepatology* 1987; **7**: 563-568 [PMID: 3494654]
- 114 **Müller R**, Gubernatis G, Farle M, Niehoff G, Klein H, Wittekind C, Tusch G, Lautz HU, Böker K, Stangel W. Liver transplantation in HBs antigen (HBsAg) carriers. Prevention of hepatitis B virus (HBV) recurrence by passive immunization. *J Hepatol* 1991; **13**: 90-96 [PMID: 1918881]
- 115 **Perrillo RP**, Wright T, Rakela J, Levy G, Schiff E, Gish R, Martin P, Dienstag J, Adams P, Dickson R, Anschuetz G, Bell S, Condreay L, Brown N; Lamivudine North American Transplant Group. A multicenter United States-Canadian trial to assess lamivudine monotherapy before and after liver transplantation for chronic hepatitis B. *Hepatology* 2001; **33**: 424-432 [PMID: 11172345 DOI: 10.1053/jhep.2001.21554]
- 116 **Roche B**, Roque-Afonso AM, Sebagh M, Delvart V, Duclos-Vallée JC, Castaing D, Samuel D. Escape hepatitis B virus mutations in recipients of antibody to hepatitis B core antigen-positive liver grafts receiving hepatitis B immunoglobulins. *Liver Transpl* 2010; **16**: 885-894 [PMID: 20583085 DOI: 10.1002/lt.22084]
- 117 **Ueda Y**, Marusawa H, Egawa H, Okamoto S, Ogura Y, Oike F, Nishijima N, Takada Y, Uemoto S, Chiba T. De novo activation of HBV with escape mutations from hepatitis B surface antibody after living donor liver transplantation. *Antivir Ther* 2011; **16**: 479-487 [PMID: 21685535 DOI: 10.3851/imp1771]
- 118 **Lok AS**. Prevention of recurrent hepatitis B post-liver transplantation. *Liver Transpl* 2002; **8**: S67-S73 [PMID: 12362302 DOI: 10.1053/jlts.2002.35780]
- 119 **Angus PW**, McCaughan GW, Gane EJ, Crawford DH, Harley H. Combination low-dose hepatitis B immune globulin and lamivudine therapy provides effective prophylaxis against posttransplantation hepatitis B. *Liver Transpl* 2000; **6**: 429-433 [PMID: 10915163 DOI: 10.1053/jlts.2000.8310]
- 120 **Markowitz JS**, Martin P, Conrad AJ, Markmann JF, Seu P, Yersiz H, Goss JA, Schmidt P, Pakrasi A, Artinian L, Murray NG, Imagawa DK, Holt C, Goldstein LI, Stribling R, Busuttil RW. Prophylaxis against hepatitis B recurrence following liver transplantation using combination lamivudine and hepatitis B immune globulin. *Hepatology* 1998; **28**: 585-589 [PMID: 9696028 DOI: 10.1002/hep.510280241]
- 121 **Gane EJ**, Angus PW, Strasser S, Crawford DH, Ring J, Jeffrey GP, McCaughan GW; Australasian Liver Transplant Study Group. Lamivudine plus low-dose hepatitis B immunoglobulin to prevent recurrent hepatitis B following liver transplantation. *Gastroenterology* 2007; **132**: 931-937 [PMID: 17383422 DOI: 10.1053/j.gastro.2007.01.005]
- 122 **Cholongitas E**, Papatheodoridis GV. High genetic barrier nucleos(t)ide analogue(s) for prophylaxis from hepatitis B virus recurrence after liver transplantation: a systematic review. *Am J Transplant* 2013; **13**: 353-362 [PMID: 23137006 DOI: 10.1111/j.1600-6143.2012.04315.x]
- 123 **Katz LH**, Paul M, Guy DG, Tur-Kaspa R. Prevention of recurrent hepatitis B virus infection after liver transplantation: hepatitis B immunoglobulin, antiviral drugs, or both? Systematic review and meta-analysis. *Transpl Infect Dis* 2010; **12**: 292-308 [PMID: 20002355 DOI: 10.1111/j.1399-3062.2009.00470.x]
- 124 **Chang TT**, Lai CL, Kew Yoon S, Lee SS, Coelho HS, Carrilho FJ, Poordad F, Halota W, Horsmans Y, Tsai N, Zhang H, Tenney DJ, Tamez R, Illoeje U. Entecavir treatment for up to 5 years in patients with hepatitis B e antigen-positive chronic hepatitis B. *Hepatology* 2010; **51**: 422-430 [PMID: 20049753 DOI: 10.1002/hep.23327]
- 125 **Karademir S**, Astarcioglu H, Akarsu M, Ozkardesler S, Ozzeybek D, Sayiner A, Akan M, Tankurt E, Astarcioglu I. Prophylactic use of low-dose, on-demand, intramuscular hepatitis B immunoglobulin and lamivudine after liver transplantation. *Transplant Proc* 2006; **38**: 579-583 [PMID: 16549180 DOI: 10.1016/j.transproceed.2005.12.063]
- 126 **Iacob S**, Hrehoret D, Matei E, Dorobantu B, Gangone E, Gheorghe L, Popescu I. Costs and efficacy of "on demand" low-dose immunoprophylaxis in HBV transplanted patients: experience in the Romanian program of liver transplantation. *J Gastrointest Liver Dis* 2008; **17**: 383-388 [PMID: 19104697]
- 127 **Jiang L**, Yan L, Li B, Wen T, Zhao J, Jiang L, Cheng N, Wei Y, Yang J, Xu M, Wang W. Prophylaxis against hepatitis B recurrence posttransplantation using lamivudine and individualized low-dose hepatitis B immunoglobulin. *Am J Transplant* 2010; **10**: 1861-1869 [PMID: 20659092 DOI: 10.1111/j.1600-6143.2010.03208.x]
- 128 **Nath DS**, Kalis A, Nelson S, Payne WD, Lake JR, Humar A. Hepatitis B prophylaxis post-liver transplant without maintenance hepatitis B immunoglobulin therapy. *Clin Transplant* 2006; **20**: 206-210 [PMID: 16640528 DOI: 10.1111/j.1399-0012.2005.00467.x]
- 129 **Saab S**, Desai S, Tsaoi D, Durazo F, Han S, McClune A, Holt C, Farmer D, Goldstein L, Busuttil RW. Posttransplantation hepatitis B prophylaxis with combination oral nucleoside and nucleotide analog therapy. *Am J Transplant* 2011; **11**: 511-517 [PMID: 21299826 DOI: 10.1111/j.1600-6143.2010.03416.x]
- 130 **Radhakrishnan K**, Chi A, Quan DJ, Roberts JP, Terrault NA. Short Course of Postoperative Hepatitis B Immunoglobulin Plus Antivirals Prevents Reinfection of Liver Transplant Recipients. *Transplantation* 2017; **101**: 2079-2082 [PMID: 28880197 DOI: 10.1097/TP.0000000000001786]
- 131 **Chen G**, Liu H, Hu ZQ, Bai JH, Liu QY, Zhao YP, Gan XM, Wang F, Wang DD, Ma LJ, Li L. A new scheme with infusion of hepatitis B immunoglobulin combined with entecavir for prophylaxis of hepatitis B virus recurrence among liver transplant recipients. *Eur J Gastroenterol Hepatol* 2015; **27**: 901-906 [PMID: 26011237 DOI: 10.1097/meg.0000000000000388]
- 132 **Cholongitas E**, Goulis I, Antoniadis N, Fouzas I, Imvrios G, Giakoustidis D, Gioulema O, Papanikolaou V, Akriviadis E, Vasiliadis T. Nucleos(t)ide analog(s) prophylaxis after hepatitis B immunoglobulin withdrawal against hepatitis B and D recurrence after liver transplantation. *Transpl Infect Dis* 2016; **18**: 667-673 [PMID: 27421122 DOI: 10.1111/tid.12575]
- 133 **Wesdorp DJ**, Knoester M, Braat AE, Coenraad MJ, Vossen AC, Claas EC, van Hoek B. Nucleoside plus nucleotide analogs and cessation of hepatitis B immunoglobulin after liver transplantation in chronic hepatitis B is safe and effective. *J Clin Virol* 2013; **58**: 67-73 [PMID: 23880162 DOI: 10.1016/j.jcv.2013.06.035]
- 134 **Stravitz RT**, Shiffman ML, Kimmel M, Puri P, Luketic VA, Sterling RK, Sanyal AJ, Cotterell AH, Posner MP, Fisher RA. Substitution of tenofovir/emtricitabine for Hepatitis B immune globulin prevents recurrence of Hepatitis B after liver transplantation. *Liver Int* 2012; **32**: 1138-1145 [PMID: 22348467 DOI: 10.1111/j.1478-3231.2012.02770.x]
- 135 **Teperman LW**, Poordad F, Bzowej N, Martin P, Pungpaong S, Schiano T, Flaherty J, Dinh P, Rossi S, Subramanian GM, Spivey J. Randomized trial of emtricitabine/tenofovir disoproxil fumarate after hepatitis B immunoglobulin withdrawal after liver transplantation. *Liver Transpl* 2013; **19**: 594-601 [PMID: 23447407 DOI: 10.1002/lt.23628]
- 136 **Gane EJ**, Patterson S, Strasser SI, McCaughan GW, Angus PW. Combination of lamivudine and adefovir without hepatitis B immune globulin is safe and effective prophylaxis against hepatitis B virus recurrence in hepatitis B surface antigen-positive liver transplant candidates. *Liver Transpl* 2013; **19**: 268-274 [PMID: 23447403 DOI: 10.1002/lt.23600]
- 137 **McGonigal KH**, Bajjoka IE, Abouljoud MS. Tenofovir-emtricitabine therapy for the prevention of hepatitis B recurrence in four patients after liver transplantation. *Pharmacotherapy* 2013; **33**: e170-e176 [PMID: 23744810 DOI: 10.1002/phar.1306]
- 138 **Angus PW**, Patterson SJ, Strasser SI, McCaughan GW, Gane E. A randomized study of adefovir dipivoxil in place of HBIG in combination with lamivudine as post-liver transplantation hepatitis B prophylaxis. *Hepatology* 2008; **48**: 1460-1466 [PMID: 18925641 DOI: 10.1002/hep.22524]
- 139 **Cholongitas E**, Papatheodoridis GV, Burroughs AK. Liver grafts

- from anti-hepatitis B core positive donors: a systematic review. *J Hepatol* 2010; **52**: 272-279 [PMID: 20034693 DOI: 10.1016/j.jhep.2009.11.009]
- 140 **Cholongitas E**, Papatheodoridis GV. Review of the pharmacological management of hepatitis B viral infection before and after liver transplantation. *World J Gastroenterol* 2013; **19**: 9189-9197 [PMID: 24409047 DOI: 10.3748/wjg.v19.i48.9189]
- 141 **Tahara H**, Tanaka Y, Ishiyama K, Ide K, Shishida M, Irei T, Ushitora Y, Ohira M, Banshodani M, Tashiro H, Itamoto T, Asahara T, Imamura M, Takahashi S, Chayama K, Ohdan H. Successful hepatitis B vaccination in liver transplant recipients with donor-specific hyporesponsiveness. *Transpl Int* 2009; **22**: 805-813 [PMID: 19490542 DOI: 10.1111/j.1432-2277.2009.00864.x]
- 142 **Prieto M**, Gómez MD, Berenguer M, Córdoba J, Rayón JM, Pastor M, García-Herola A, Nicolás D, Carrasco D, Orbis JF, Mir J, Berenguer J. De novo hepatitis B after liver transplantation from hepatitis B core antibody-positive donors in an area with high prevalence of anti-HBc positivity in the donor population. *Liver Transpl* 2001; **7**: 51-58 [PMID: 11150423 DOI: 10.1053/jlts.2001.20786]
- 143 **Manzarbeitia C**, Reich DJ, Ortiz JA, Rothstein KD, Araya VR, Munoz SJ. Safe use of livers from donors with positive hepatitis B core antibody. *Liver Transpl* 2002; **8**: 556-561 [PMID: 12037788 DOI: 10.1053/jlts.2002.33451]
- 144 **Chen YS**, Wang CC, de Villa VH, Wang SH, Cheng YF, Huang TL, Jawan B, Chiu KW, Chen CL. Prevention of de novo hepatitis B virus infection in living donor liver transplantation using hepatitis B core antibody positive donors. *Clin Transplant* 2002; **16**: 405-409 [PMID: 12437618]
- 145 **Nery JR**, Nery-Avila C, Reddy KR, Cirocco R, Weppeler D, Levi DM, Nishida S, Madariaga J, Kato T, Ruiz P, Schiff E, Tzakis AG. Use of liver grafts from donors positive for antihepatitis B-core antibody (anti-HBc) in the era of prophylaxis with hepatitis-B immunoglobulin and lamivudine. *Transplantation* 2003; **75**: 1179-1186 [PMID: 12717200 DOI: 10.1097/01.TP.0000065283.98275.FE]
- 146 **Erlebi Kobak A**, Karasu Z, Kilic M, Ozacar T, Tekin F, Gunsar F, Ersoz G, Yuzer Y, Tokat Y. Living donor liver transplantation from hepatitis B core antibody positive donors. *Transplant Proc* 2007; **39**: 1488-1490 [PMID: 17580169 DOI: 10.1016/j.transproceed.2006.11.015]
- 147 **De Feo TM**, Poli F, Mozzi F, Moretti MP, Scalapomagna M; Collaborative Kidney, Liver and Heart North Italy Transplant Program Study Groups. Risk of transmission of hepatitis B virus from anti-HBc positive cadaveric organ donors: a collaborative study. *Transplant Proc* 2005; **37**: 1238-1239 [PMID: 15848681 DOI: 10.1016/j.transproceed.2004.12.041]
- 148 **Suehiro T**, Shimada M, Kishikawa K, Shimura T, Soejima Y, Yoshizumi T, Hashimoto K, Mochida Y, Maehara Y, Kuwano H. Prevention of hepatitis B virus infection from hepatitis B core antibody-positive donor graft using hepatitis B immune globulin and lamivudine in living donor liver transplantation. *Liver Int* 2005; **25**: 1169-1174 [PMID: 16343068 DOI: 10.1111/j.1478-3231.2005.01165.x]
- 149 **Dodson SF**, Issa S, Araya V, Gayowski T, Pinna A, Eghtesad B, Iwatsuki S, Montalvo E, Rakela J, Fung JJ. Infectivity of hepatic allografts with antibodies to hepatitis B virus. *Transplantation* 1997; **64**: 1582-1584 [PMID: 9415560]
- 150 **Takemura N**, Sugawara Y, Tamura S, Makuuchi M. Liver transplantation using hepatitis B core antibody-positive grafts: review and university of Tokyo experience. *Dig Dis Sci* 2007; **52**: 2472-2477 [PMID: 17805972 DOI: 10.1007/s10620-006-9656-5]
- 151 **Bárcena Marugán R**, García-Hoz F, Vázquez Romero M, Nash R, Mateos M, González Alonso R, García González M, García Plaza A. Prevention of de novo hepatitis B infection in liver allograft recipients with previous hepatitis B infection or hepatitis B vaccination. *Am J Gastroenterol* 2002; **97**: 2398-2401 [PMID: 12358263 DOI: 10.1111/j.1572-0241.2002.05994.x]
- 152 **Fox AN**, Terrault NA. The option of HBIG-free prophylaxis against recurrent HBV. *J Hepatol* 2012; **56**: 1189-1197 [PMID: 22274310 DOI: 10.1016/j.jhep.2011.08.026]
- 153 **Ishigami M**, Ogura Y, Hirooka Y, Goto H. Change of strategies and future perspectives against hepatitis B virus recurrence after liver transplantation. *World J Gastroenterol* 2015; **21**: 10290-10298 [PMID: 26420956 DOI: 10.3748/wjg.v21.i36.10290]
- 154 **Roche B**, Roque-Afonso AM, Nevens F, Samuel D. Rational Basis for Optimizing Short and Long-term Hepatitis B Virus Prophylaxis Post Liver Transplantation: Role of Hepatitis B Immune Globulin. *Transplantation* 2015; **99**: 1321-1334 [PMID: 26038873 DOI: 10.1097/TP.0000000000000777]
- 155 **Hu TH**, Chen CL, Lin CC, Wang CC, Chiu KW, Yong CC, Liu YW, Eng HL. Section 14. Combination of entecavir plus low-dose on-demand hepatitis B immunoglobulin is effective with very low hepatitis B recurrence after liver transplantation. *Transplantation* 2014; **97** Suppl 8: S53-S59 [PMID: 24849836 DOI: 10.1097/01.tp.0000446278.43804.f9]
- 156 **Gish RG**, Given BD, Lai CL, Locarnini SA, Lau JY, Lewis DL, Schluep T. Chronic hepatitis B: Virology, natural history, current management and a glimpse at future opportunities. *Antiviral Res* 2015; **121**: 47-58 [PMID: 26092643 DOI: 10.1016/j.antiviral.2015.06.008]
- 157 **Wadhawan M**, Gupta S, Goyal N, Taneja S, Kumar A. Living related liver transplantation for hepatitis B-related liver disease without hepatitis B immune globulin prophylaxis. *Liver Transpl* 2013; **19**: 1030-1035 [PMID: 23788470 DOI: 10.1002/lt.23692]
- 158 **Fung J**, Chan SC, Cheung C, Yuen MF, Chok KS, Sharr W, Chan AC, Cheung TT, Seto WK, Fan ST, Lai CL, Lo CM. Oral nucleoside/nucleotide analogs without hepatitis B immune globulin after liver transplantation for hepatitis B. *Am J Gastroenterol* 2013; **108**: 942-948 [PMID: 23629601 DOI: 10.1038/ajg.2013.111]
- 159 **Fung J**, Cheung C, Chan SC, Yuen MF, Chok KS, Sharr W, Dai WC, Chan AC, Cheung TT, Tsang S, Lam B, Lai CL, Lo CM. Entecavir monotherapy is effective in suppressing hepatitis B virus after liver transplantation. *Gastroenterology* 2011; **141**: 1212-1219 [PMID: 21762659 DOI: 10.1053/j.gastro.2011.06.083]
- 160 **Fung J**, Lo R, Chan SC, Chok K, Wong T, Sharr W, Cheung TT, Chan AC, Dai WC, Sin SL, Ng I, Lai CL, Yuen MF, Lo CM. Outcomes including liver histology after liver transplantation for chronic hepatitis B using oral antiviral therapy alone. *Liver Transpl* 2015; **21**: 1504-1510 [PMID: 26194746 DOI: 10.1002/lt.24218]
- 161 **Fung J**, Wong T, Chok K, Chan A, Cheung TT, Dai JW, Sin SL, Ma KW, Ng K, Ng KT, Seto WK, Lai CL, Yuen MF, Lo CM. Long-term outcomes of entecavir monotherapy for chronic hepatitis B after liver transplantation: Results up to 8 years. *Hepatology* 2017; **66**: 1036-1044 [PMID: 28370215 DOI: 10.1002/hep.29191]
- 162 **Zheng JN**, Zou TT, Zou H, Zhu GQ, Ruan LY, Cheng Z, Van Poucke S, Zheng MH. Comparative efficacy of oral nucleotide analogues for the prophylaxis of hepatitis B virus recurrence after liver transplantation: a network meta-analysis. *Expert Rev Anti Infect Ther* 2016; **14**: 979-987 [PMID: 27491868 DOI: 10.1080/14787210.2016.1220831]
- 163 **Fung J**, Wong T, Chok K, Chan A, Sin SL, Cheung TT, Dai WC, Ng K, Ng K, Man K, Seto WK, Lai CL, Yuen MF, Lo CM. Oral Nucleos(t)ide Analogs Alone After Liver Transplantation in Chronic Hepatitis B With Preexisting rt204 Mutation. *Transplantation* 2017; **101**: 2391-2398 [PMID: 28731907 DOI: 10.1097/tp.0000000000001883]
- 164 **Couto CA**, Bittencourt PL, Farias AQ, Lalle MP, Cançado EL, Massarollo PC, Mies S. Human polyclonal anti-hepatitis B surface antigen immunoglobulin reduces the frequency of acute rejection after liver transplantation for chronic hepatitis B. *Rev Inst Med Trop Sao Paulo* 2001; **43**: 335-337 [PMID: 11781604]
- 165 **Wong SY**, Levitsky J. Chronic rejection related to hepatitis B immunoglobulin discontinuation in a liver transplant recipient. *Transpl Int* 2011; **24**: e104-e106 [PMID: 21902731 DOI: 10.1111/j.1432-2277.2011.01334.x]
- 166 **Lee EC**, Kim SH, Lee SD, Park H, Lee SA, Park SJ. High-dose hepatitis B immunoglobulin therapy in hepatocellular carcinoma with hepatitis B virus-DNA/hepatitis B e antigen-positive patients after living donor liver transplantation. *World J Gastroenterol*

- 2016; **22**: 3803-3812 [PMID: 27076765 DOI: 10.3748/wjg.v22.i14.3803]
- 167 **Lenci I**, Tisone G, Di Paolo D, Marcuccilli F, Tariciotti L, Ciotti M, Svicher V, Perno CF, Angelico M. Safety of complete and sustained prophylaxis withdrawal in patients liver-transplanted for HBV-related cirrhosis at low risk of HBV recurrence. *J Hepatol* 2011; **55**: 587-593 [PMID: 21251938 DOI: 10.1016/j.jhep.2010.12.036]
- 168 **Lenci I**, Baiocchi L, Tariciotti L, Di Paolo D, Milana M, Santopaolo F, Manzia TM, Toti L, Svicher V, Tisone G, Perno CF, Angelico M. Complete hepatitis B virus prophylaxis withdrawal in hepatitis B surface antigen-positive liver transplant recipients after longterm minimal immunosuppression. *Liver Transpl* 2016; **22**: 1205-1213 [PMID: 27272189 DOI: 10.1002/lt.24493]
- 169 **Roche B**, Feray C, Gigou M, Roque-Afonso AM, Arulnaden JL, Delvart V, Dussaix E, Guettier C, Bismuth H, Samuel D. HBV DNA persistence 10 years after liver transplantation despite successful anti-HBS passive immunoprophylaxis. *Hepatology* 2003; **38**: 86-95 [PMID: 12829990 DOI: 10.1053/jhep.2003.50294]
- 170 **Kasraianfard A**, Watt KD, Lindberg L, Alexopoulos S, Rezaei N. HBIG Remains Significant in the Era of New Potent Nucleoside Analogues for Prophylaxis Against Hepatitis B Recurrence After Liver Transplantation. *Int Rev Immunol* 2016; **35**: 312-324 [PMID: 24911598 DOI: 10.3109/08830185.2014.921160]
- 171 **Wang SH**, Loh PY, Lin TL, Lin LM, Li WF, Lin YH, Lin CC, Chen CL. Active immunization for prevention of De novo hepatitis B virus infection after adult living donor liver transplantation with a hepatitis B core antigen-positive graft. *Liver Transpl* 2017; **23**: 1266-1272 [PMID: 28691231 DOI: 10.1002/lt.24814]
- 172 **Cai D**, Mills C, Yu W, Yan R, Aldrich CE, Saputelli JR, Mason WS, Xu X, Guo JT, Block TM, Cuconati A, Guo H. Identification of disubstituted sulfonamide compounds as specific inhibitors of hepatitis B virus covalently closed circular DNA formation. *Antimicrob Agents Chemother* 2012; **56**: 4277-4288 [PMID: 22644022 DOI: 10.1128/aac.00473-12]
- 173 **Petersen J**, Dandri M, Mier W, Lütgehetmann M, Volz T, von Weizsäcker F, Haberkorn U, Fischer L, Pollok JM, Erbes B, Seitz S, Urban S. Prevention of hepatitis B virus infection in vivo by entry inhibitors derived from the large envelope protein. *Nat Biotechnol* 2008; **26**: 335-341 [PMID: 18297057 DOI: 10.1038/nbt1389]
- 174 **Volz T**, Allweiss L, Ben MBarek M, Warlich M, Lohse AW, Pollok JM, Alexandrov A, Urban S, Petersen J, Lütgehetmann M, Dandri M. The entry inhibitor Myrcludex-B efficiently blocks intrahepatic virus spreading in humanized mice previously infected with hepatitis B virus. *J Hepatol* 2013; **58**: 861-867 [PMID: 23246506 DOI: 10.1016/j.jhep.2012.12.008]
- 175 **Girlanda R**, Mohsen AH, Smith H, Sablon E, Yuen MF, O'Grady J, Muiesan P, Rela M, Heaton N, Norris S. Hepatitis B virus genotype A and D and clinical outcomes of liver transplantation for HBV-related disease. *Liver Transpl* 2004; **10**: 58-64 [PMID: 14755779 DOI: 10.1002/lt.20004]
- 176 **Gaglio P**, Singh S, Degertekin B, Ishitani M, Hussain M, Perrillo R, Lok AS; National Institutes of Health Hepatitis B Virus-Orthotopic Liver Transplantation Study Group. Impact of the hepatitis B virus genotype on pre- and post-liver transplantation outcomes. *Liver Transpl* 2008; **14**: 1420-1427 [PMID: 18825703 DOI: 10.1002/lt.21563]
- 177 **Lo CM**, Cheung CK, Lau GK, Yuen MF, Liu CL, Chan SC, Fan ST, Wong J. Significance of hepatitis B virus genotype in liver transplantation for chronic hepatitis B. *Am J Transplant* 2005; **5**: 1893-1900 [PMID: 15996236 DOI: 10.1111/j.1600-6143.2005.00952.x]

**P- Reviewer:** Cao GW, Gonzalez-Reimers E, Sergi CM, Sugawara Y  
**S- Editor:** Song XX **L- Editor:** A **E- Editor:** Li D



## Metabolomics: From liver chiromancy to personalized precision medicine in advanced chronic liver disease

Bogdan Procopet, Petra Fischer, Oana Farcau, Horia Stefanescu

Bogdan Procopet, Petra Fischer, Oana Farcau, 3<sup>rd</sup> Medical Clinic, University of Medicine and Pharmacy, Cluj 400162, Romania

Bogdan Procopet, Horia Stefanescu, Hepatology Unit, Regional Institute of Gastroenterology and Hepatology, Cluj 400162, Romania

ORCID number: Bogdan Procopet (0000-0001-8118-1760); Petra Fischer (0000-0002-3605-8007); Oana Farcau (0000-0002-4468-2053); Horia Stefanescu (0000-0002-4034-5471).

**Author contributions:** Procopet B and Stefanescu H designed the study; Fischer P and Farcau O drafted the first version of the manuscript; all authors reviewed the manuscript and approved the final version of the paper.

**Supported by** Romanian Agency for Scientific Research, No. PN-II-RU-TE-2014-4-0356 (awarded to Stefanescu H), and No. PN-II-RU-TE-2014-4-0709 (awarded to Procopet B).

**Conflict-of-interest statement:** None.

**Open-Access:** This article is an open-access article which was selected by an in-house editor and fully peer-reviewed by external reviewers. It is distributed in accordance with the Creative Commons Attribution Non Commercial (CC BY-NC 4.0) license, which permits others to distribute, remix, adapt, build upon this work non-commercially, and license their derivative works on different terms, provided the original work is properly cited and the use is non-commercial. See: <http://creativecommons.org/licenses/by-nc/4.0/>

**Manuscript source:** Invited manuscript

**Correspondence to:** Horia Stefanescu, MSc, MD, PhD, Doctor, Staff Physician, Hepatology Unit, Regional Institute of Gastroenterology and Hepatology, 19-21 Croitorilor Str., Cluj 400162, Romania. [horia.stefanescu@irgh.ro](mailto:horia.stefanescu@irgh.ro)  
Telephone: +4-766-318283

Received: October 28, 2017

Peer-review started: October 29, 2017

First decision: November 28, 2017

Revised: January 19, 2018

Accepted: January 29, 2018

Article in press: January 29, 2018

Published online: March 27, 2018

### Abstract

Currently there is a lack of accurate biomarkers for diagnosis and prognosis in advanced liver diseases. Either the occurrence of first decompensation, or diagnosis of acute on chronic liver failure, severe alcoholic hepatitis, or hepatocellular carcinoma (HCC), none of the available biomarkers are satisfactory. Metabolomics is the newest of omics, being much closer than the others to the actual phenotype and pathologic changes that characterizes a certain condition. It deals with a much wider spectrum of low molecular weight bio-compounds providing a powerful platform for discovering novel biomarkers and biochemical pathways to improve diagnostic, prognostication and therapy. Until now metabolomics was applied in a wide spectrum of liver conditions, but the findings were contradictory. This review proposes a synthesis of the existing evidences of metabolomics use in advanced chronic liver diseases, decompensated liver cirrhosis, severe alcoholic hepatitis and HCC.

**Key words:** Metabolomics; Biomarker; Prediction; Advanced chronic liver disease; Decompensation; Alcoholic hepatitis; Hepatocellular carcinoma

© **The Author(s) 2018.** Published by Baishideng Publishing Group Inc. All rights reserved.

**Core tip:** Currently there is a lack of accurate biomarkers for diagnosis and prognosis in advanced liver diseases. Either the occurrence of first decompensation, or diagnosis of acute on chronic liver failure, severe alcoholic hepatitis, or hepatocellular carcinoma (HCC), none of the available biomarkers are satisfactory. This review proposes a synthesis of the existing evidences

of metabolomics use in advanced chronic liver diseases, decompensated liver cirrhosis, severe alcoholic hepatitis and HCC.

Procopet B, Fischer P, Farcau O, Stefanescu H. Metabolomics: From liver chiromancy to personalized precision medicine in advanced chronic liver disease. *World J Hepatol* 2018; 10(3): 371-378 Available from: URL: <http://www.wjgnet.com/1948-5182/full/v10/i3/371.htm> DOI: <http://dx.doi.org/10.4254/wjh.v10.i3.371>

## INTRODUCTION

Hepatic fibrosis is a dynamic process that may progress to liver cirrhosis in the context of an active etiological factor. In compensated stages, physical exam by itself cannot distinguish between severe fibrosis and constituted liver cirrhosis. This is why in recent years the term compensated advanced chronic liver disease (cACLD) was introduced<sup>[1]</sup>. In this stage it is essential to establish the risk of decompensation and the best method to do it is by measuring hepatic venous pressure gradient (HVPG)<sup>[2]</sup>. However, HVPG measurement is not widely available and it is considered invasive<sup>[3]</sup>. Therefore, in the last years huge efforts were done to find new biomarkers or non-invasive methods to assess prognosis.

The occurrence of decompensation, with its various manifestations (ascites and variceal bleeding most often) is in direct relation with the increase in portal pressure, namely clinically significant portal hypertension, which represent an HVPG > 10 mmHg<sup>[4]</sup>. The life expectancy of these patients without liver transplantation is significantly lower than in compensated stages<sup>[5]</sup>.

Acute decompensation associated with organ failures and increased short-term mortality is defined by the concept of acute on chronic liver failure (ACLF) syndrome, which was recently defined<sup>[6]</sup>. The most frequent precipitating factors for ACLF are bacterial infections, acute flares in viral B advanced liver disease and alcohol consumption but the clinical features are identical regardless the precipitating factor<sup>[7]</sup>. There are some clinical situations where making a therapeutic decision based on the available non-invasive diagnostic tools proves to be difficult. Thus, without liver biopsy it is impossible to differentiate between severe alcoholic hepatitis and decompensated cirrhosis, which is essential for the indication of cortisone treatment<sup>[8]</sup>. Moreover, around one third of decompensated patients are infected at presentation<sup>[9,10]</sup> and without routine cultures the clinical suspicion and diagnosis of bacterial infections is very difficult. To reduce in hospital-morbidity and mortality, early initiation of empiric antibiotherapy can be crucial, but bacterial cultures last long, and infection markers represented by CRP, leucocyte count, procalcitonin are of limited

value in cirrhosis<sup>[11]</sup>. Therefore, in these specific clinical scenarios new biomarkers for diagnosis and prognosis are also needed.

Apart from acute decompensation, the prognosis of patients with cACLD is deeply influenced by hepatocellular carcinoma (HCC) occurrence<sup>[12]</sup>. The high mortality rate of HCC is owed partly to the absence of adequate monitoring in high-risk populations, and partly to insufficient diagnostic resources - especially for early tumor identification, which could still allow curative interventions. Serum alpha-fetoprotein (AFP) - which has been widely and commonly used as biomarker, either as a screening tool for early HCC detection or as a prognostic tool for tumor recurrence and patient survival, has a poor sensitivity since up to 40% of HCC and cirrhosis patients have normal AFP levels and only 10%-20% of patients with early-stage HCC have elevated AFP levels<sup>[13]</sup>. Therefore, more sensitive markers of disease are needed, particularly for the early detection of HCC disease and for HCC recurrence after curative treatment.

Given the reserved prognosis and the difficulty of management, this review proposes a synthesis of the existing evidences of metabolomics use in cACLD, decompensated liver cirrhosis, severe alcoholic hepatitis and HCC.

## METABOLOMICS - NEW OPPORTUNITY FOR BIOMARKERS DISCOVERY

Although its recognition as a distinct scientific area is much more recent than the other "omics" such as genomics, transcriptomics, or proteomics, metabolomics provides a powerful platform for discovering novel biomarkers and biochemical pathways to improve diagnostic, prognostication, and therapy (Figure 1)<sup>[14,15]</sup>. It has the advantage of being much closer to the actual phenotype than the other omics, but the number of possible compounds is much higher. In contrast to genomics, transcriptomics, and proteomics, which address macromolecules with similar chemical properties, such as DNA, RNA, and proteins, metabolomics deals with diverse properties of low molecular weight bio-compounds<sup>[16]</sup>.

Metabolomics allows small metabolites, usually with a molecular weight under 1 kDa, and metabolic processes to be studied using nuclear magnetic resonance (NMR) spectroscopy, gas chromatography mass spectrometry (GC-MS), and liquid chromatography mass spectrometry (LC-MS)<sup>[17]</sup>. Given the nonvolatile character of biological materials (serum, urine, tissue or faeces) the most commonly used technique in clinical trials is LC-MS. The common pattern recognition methods of metabolomics include unsupervised and supervised ones: Principal component analysis (PCA) for the former and partial least squares-discriminant analysis (PLS-DA) for the latter group.

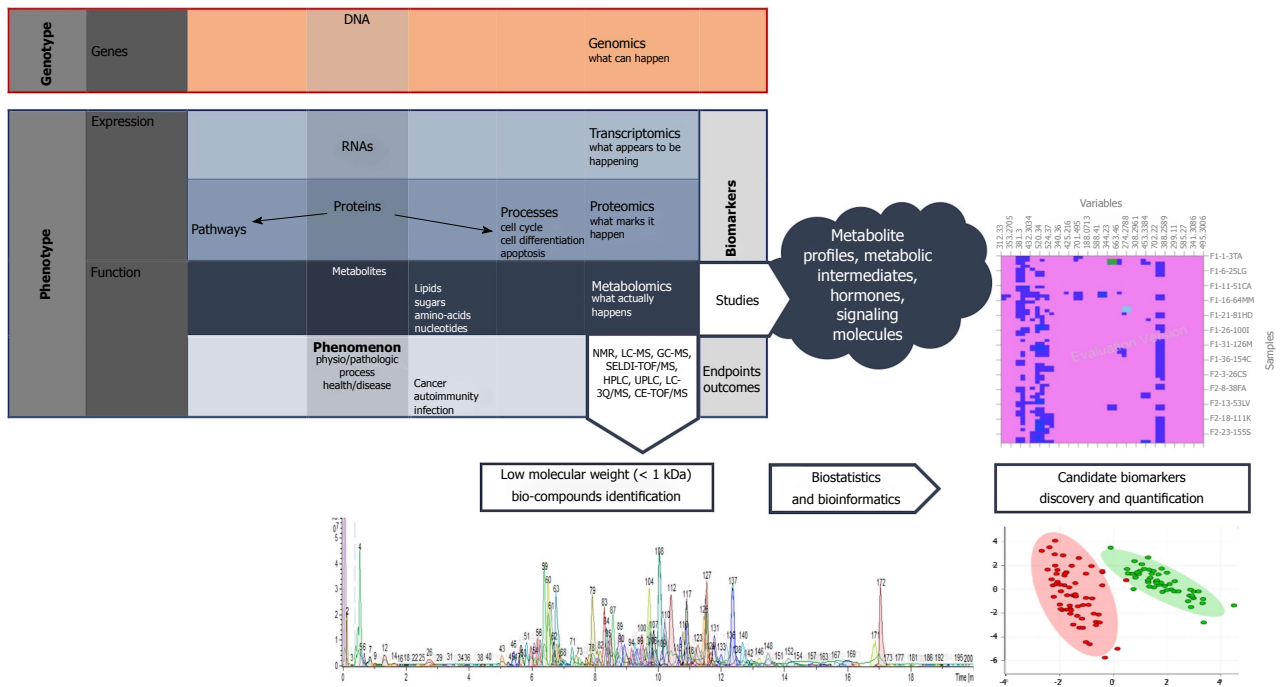


Figure 1 Integration of metabolites into the "omics" pathway and basic principles of metabolomics.

## METABOLOMICS AND ADVANCED CHRONIC LIVER DISEASE

Once the cACLD patients develop decompensation the progression of the disease is very clear. The annual transition rate from compensated to decompensated stage is the highest in HBV cirrhosis, around 10% per year, being lower in HCV and alcoholic etiologies<sup>[18,19]</sup>. However, without HVPg measurement, the most difficult task is to identify the patients at risk of decompensation or to accurately identify the precipitating factor.

It seems that with the progression of chronic liver diseases the core metabolic phenotype is characterized by a decrease in phosphatidylcholines (PC) and increase in serum biliary acids<sup>[20]</sup>. This core metabolic phenotype appears early in the natural history of chronic liver diseases, regardless the etiology, and remains stable in the evolution, including different stages of cirrhosis or hepatic tumors, either cholangio or HCC.

When comparing the metabolic profile of patients infected with HCV without fibrosis with HCV cirrhosis, along with this core metabolic phenotype, there are other several disorders involving lipid, carbohydrate, protein, and energetic metabolism<sup>[21]</sup>. The HDL cholesterol and choline levels were lower in patients with cirrhosis compared to those without fibrosis. The perturbations of glucose metabolism are caused, firstly, by impaired tricarboxylic acid cycle activity due to mitochondrial dysfunction, and possibly on the second hand by insulin resistance that characterizes HCV infection, leading to increased serum glucose and citrate levels in the cirrhotic group. As a response to the relative carbohydrate deficiency, ketone bodies

(hydroxybutyrate and acetoacetate) are used as preferential energy sources in the mitochondria, explaining their lower serum levels with the evolution of hepatic disease.

Regarding protein metabolism, there is an imbalance in the ratio of aromatic amino acids and branched chain amino acids in cirrhosis. In fact, only phenylalanine was founded elevated in serum of patients with cirrhosis, probably because disturbances of the gut microbiota in this situation<sup>[22]</sup>.

Jimenez *et al.*<sup>[23]</sup> has attempted to identify by NMR spectroscopy the metabolic profile of cirrhotic patients with minimal hepatic encephalopathy (MHE) vs cirrhotic patients without encephalopathy. MHE patients displayed increased serum concentrations of glucose, lactate, methionine and glycerol, as well as decreased levels of choline, branched chain amino acids, alanine, glycine, acetoacetate, and lipid moieties.

When serum metabolic profile by NMR spectroscopy of patients in different stages of chronic liver failure (CLF) according to the MELD score was analyzed, there is an evolutionary trend involving the representatives of the metabolism of lipids, carbohydrates and proteins<sup>[24]</sup>. Thus, there is a decrease in HDL cholesterol, choline and phosphatidylcholine, which are the more expressed in higher MELD patients. The glucose, lactic acid, butyrate, pyruvate and citrate levels increase in severe CLF and the protein metabolism is modified because increased skeletal muscle catabolism, expressed by increased levels of free amino acids (leucine, isoleucine, glutamine, methionine and valine) in parallel with the severity of liver disease.

Recently, it was proved that phosphatidylcholine and lysophosphatidylcholine may have also prognosis

**Table 1** Principal metabolic changes in advanced liver diseases

Condition	Lipids	Bile acids	Carbo-hydrates	Energy and oxidative stress	Proteins and Aminoacids
ACLD	↓ HDL cholesterol ↓ Choline ↓ Phosphatidylcholine ↓ Lipid moieties		↑ Glucose ↑ Glycerol	↓ OH-butyrate ↓ Aceto-acetate ↑ Lactate ↑ Pyruvate ↑ Citrate	↑ Phe ↓ Gli, Ala ↓ Branched AA ↑ Leu, Iso-Leu, Val, Glu ↑ Methionine ↑ Aromatic AA
ACLF	↓ HDL cholesterol			↑ Lactate ↑ Pyruvate	
ALD	↓ Lyso-phosphatidilcholine ↑ Eico/doco -sapentaenoate ↑ Tetra/hexa/octa-decanedioate	↑ Sulphated bile acids	↑ Fumarate, succinate, malate, citrate ↑ Xylionate	↑ Indole 3-acetic acid (u) ↑ Betaine ↑ Citruline	↓ Val, Iso-Leu
HCC	↓ Lysophosphatidilcholine ↑ Oleamide ↑ Stearoyl-coa desaturase ↓ 3-Hydroxybutyrate ↓ Choline	↓ (Lito)cholic, (cheno)deoxy-cholic acids ↓ GCA, GDCA, GCDCA, TCA, TCDA	↑ Glucose, glycerol	↓ OH-butyrate ↓ Xantine ↑ Canavanino succinate	↓ BCAAs: Leu, Iso-Leu and Val ↑ AAAs: Phe, Trp, Tyr, His ↑ Methionine, hydroxy-methyldeoxyuridine, dimethyl-guanosine, uric acid ↑ Methylhistidine

ACLF: Acute on chronic liver failure; ACLD: Advanced chronic liver disease; ALD: Alcoholic liver disease; HCC: Hepatocellular carcinoma; AA: Aminoacids; AAA: Aromatic AA; BCAA: Branched chain AA; Ala: Alanine; Arg: Arginine; Gli: Glicine; Glu: Glutamate; His: Histidine; Phe: Phenylalanine; Leu: Leucine; Val: Valine; Trp: Tryptofan; Tyr: Tyrosine; CA: Cholic acid; GCA: Glyco CA; GDCA: Glycodeoxy CA; GCDCA: Glycochenodeoxy CA; TCA: Tauro CA; TCDA: Tauro cheno deoxy CA; u: Urinary.

relevance in decompensated liver cirrhosis, serum levels of these compounds being negatively correlated with survival<sup>[25]</sup>.

Therefore, there is no single biomarker for the different stages of advanced chronic liver disease, but a complex of biomarkers, a so-called metabolic fingerprint. This implies, regardless of the etiology of liver disease, progressive changes of the same classes of compounds in parallel with disease evolution.

## METABOLOMICS AND ACUTE-ON-CHRONIC LIVER FAILURE

ACLF is a distinct syndrome that can occur in approximately one third of patients with decompensated liver cirrhosis<sup>[6]</sup>. The most common causes are bacterial infections, alcohol consumption and digestive bleeding, although in a large percentage of cases a precipitating factor cannot be identified<sup>[7]</sup>.

Amathieu *et al.*<sup>[26]</sup> compared the metabolic profile of patients with ACLF with the one of patients with decompensated liver cirrhosis who do not meet the criteria for ACLF. The patients with ACLF had decreased HDL cholesterol, increased lactic acid, pyruvate, and aromatic amino acids but these changes are rather the expression of the severity of liver disease.

Because indirect infection markers have limited value in cirrhotic patients and bacteriological studies last long, identifying bacterial infections in a patient with decompensated liver cirrhosis or ACLF could be difficult. Although there is a strong need for new biomarkers in infection, there are no publications

regarding the metabolic profile of the infected cirrhotic patients.

In severe sepsis and septic shock in non-cirrhotic patients it was identified a urinary metabolic profile with prognostic value, characterized by higher levels of ethanol, glucose, hippurate, but lower levels of methionine, glutamine, arginine and phenylalanine in patients with lower survival<sup>[27]</sup>. A retrospective multicenter study in Greece and Germany, which enrolled a large number of patients proposed as a primary endpoint to differentiate the metabolic profile of patients with SIRS from patients with sepsis and as a secondary endpoint, to identify specific biomarkers for the different types of infections<sup>[28]</sup>. A regression model combining the sphingolipid SM C22:3 and the glycerophospholipid lysoPCaC24:0 was created for sepsis diagnosis with a sensitivity of 84.1% and specificity of 85.7%. The glycerophospholipid lysoPCaC26:1 was characteristic for patients with community-acquired pneumonia complicated with severe sepsis or septic shock. For the other types of infection, no biomarker or significant metabolic profile was found.

For diagnosis of sepsis in emergency department, one study identified a panel of 6 metabolites, represented by myristic acid, citric acid, isoleucine, norleucine, pyruvic acid and a phosphocholine like derivative, to have very good sensitivity (95%) and specificity (90%)<sup>[29]</sup>.

It is to be demonstrated if all these metabolic markers of infection may be applied in the context of decompensated cirrhosis or ACLF.

## METABOLOMICS AND ALCOHOLIC LIVER DISEASE

Alcohol liver disease encompasses a spectrum of injury ranging from simple steatosis to frank cirrhosis and alcohol consumption may represent a precipitating factor for decompensation or ACLF<sup>[8]</sup>. Because most cases of alcoholic hepatitis occur in patients with established cirrhosis, most of the times it is impossible to differentiate between severe alcoholic hepatitis and decompensated cirrhosis without liver biopsy<sup>[8]</sup>. Accordingly, new biomarkers capable to differentiate between severe alcoholic hepatitis and decompensated cirrhosis as well as markers capable to predict early the response to corticosteroid therapy, would be of great help in clinical practice.

Urinary indole-3-acetic acid has been identified as a potential biomarker for early alcoholic liver disease on animal model, by two studies performed by LC-MS<sup>[30,31]</sup>. Our group, in a pilot study, proved that lysophosphatidylcholine (LPC) 16:1 and 20:4 decrease progressively with the severity of alcoholic liver disease and this is correlated with survival and the occurrence of liver related events<sup>[32]</sup>. However, if these metabolic changes are rather general in ACLD or specific to alcoholic liver disease remains to be proved.

There are only few small studies in the literature regarding the metabolic profile of the patient with severe alcoholic hepatitis. Enhanced adipose tissue lipolysis with increased fatty acid supply to the liver is a phenomenon observed in severe alcoholic hepatitis<sup>[33]</sup>. In severe alcoholic hepatitis, there is an impaired long-chain fatty acid beta-oxidation in the liver, first because of the oversaturation of hepatic metabolic capacity due to excessive fatty acid supply and second because of impaired mitochondrial function. Eicosapentaenoate (EPA; 20:5n3) and docosapentaenoate (DPA; 22:5n6), 2 long chain essential fatty acids, have been identified as potential biomarkers for severe alcoholic hepatitis by Rachakonda *et al.*<sup>[33,34]</sup>, capable to differentiate severe alcoholic hepatitis from compensated alcoholic liver cirrhosis.

As a consequence of faulty beta-oxidation, the same study demonstrated a relative transition to lipid omega-oxidation in severe alcoholic hepatitis, with the increase of dicarboxylic acids such as tetradecanedioate, hexadecanedioate, octadecanedioate, which are endogenous ligands of the peroxisome proliferator activated receptor (PPAR) alpha, mechanism at least partially responsible for the developing of severe steatosis in alcoholic hepatitis<sup>[34]</sup>. Severe alcoholic hepatitis is characterized by intrahepatic cholestasis. An increase in sulphated bile acids has been demonstrated in the serum of patients with severe alcoholic hepatitis, with a decrease in bile acids from intestinal bacterial origin, reflecting probably gut microbiota disturbances<sup>[34]</sup>. Carbohydrate metabolism is also impaired and implicates mainly the dysfunction

of the Krebs cycle activity, with an increase in serum concentrations of the intermediates of the cycle, like fumarate, succinate, malate, citrate. Glucose is poorly used in severe alcoholic hepatitis, and there is a shunting from glycolysis to the pentose phosphor pathway, the end product of this, xylurate, being an important biomarker for severe alcoholic hepatitis.

Branched chain amino acids originating in skeletal muscles appear to be an important energy substitute in severe alcoholic hepatitis, as their serum levels (valine and isoleucine) are reduced in parallel with the increase of their metabolites<sup>[34]</sup>.

Ascha *et al.*<sup>[35]</sup> identified two compounds, betaine and citrulline, as important biomarkers for the differentiation of severe alcoholic hepatitis from decompensated liver cirrhosis. Betaine is a methylating agent involved in preserving the integrity of the hepatic cell, while citrulline has intestinal origin and appears to be elevated alongside NO, secondary to an excessive nitric oxide synthase activity in the context of significant portal hypertension in alcoholic hepatitis<sup>[35]</sup>.

## METABOLOMICS AND HCC

LPC is an important signaling molecule, involved in regulating cellular proliferation, cancer cell invasion, and inflammation<sup>[36]</sup> and it has been reported to be significantly decreased in the sera of HCC patients<sup>[37,38]</sup>. In a recent study, lower levels of LPC and PC, such as LPC (16:0), LPC (18:0), PC (16:0), and PC (18:0) were observed in HCC and liver cirrhosis samples compared with healthy controls<sup>[37]</sup>. Low levels of LPCs imply an anti-inflammatory status in HCC patients, and markedly low levels of LPCs represent a severe immune suppression status in cirrhotic patients. Similar LPC trends have also been found in other malignant diseases, such as renal cell carcinoma<sup>[39]</sup>.

Other serum lipid compounds found to be discriminative between HCC and healthy controls are Free Fatty Acids (FFA). Amongst them, oleamide (cis-9, 10-octadecenoamide), the amide of FFA C18:1 (oleic acid), may represent a specific marker for HCC<sup>[36,40]</sup>. Gao *et al.*<sup>[41]</sup> reported a gradual up-regulation of the ratio of FFA C16:1 to C16:0 and FFA C18:1 to C18:0 during hepatocarcinogenesis as a result of significantly increased level of stearoyl-CoA desaturase 1 (SCD1), due to the increased demand for lipid synthesis in HCC.

Bile acids are synthesized in the liver and aid in fatty acid absorption and digestion and constitutes one of the most frequently reported compound classes suggested as discriminating between HCC patients and a control group. Cholic acid, chenodeoxycholic acid, lithocholic acid and deoxycholic acid had lower levels in HCC patients compared with cirrhosis<sup>[40,42]</sup>. Also, glycochenodeoxycholic acid 3-sulfate (3-sulfo-GCDCA), glycocholic acid (GCA), glycodeoxycholic acid (GDCA), taurocholic acid (TCA), and taurochenodeoxycholate

(TCDCA) are down regulated HCC vs cirrhosis<sup>[37,42]</sup>. Bile acid downregulation in HCC may also reflect a metabolic shift away from  $\beta$ -oxidation and the reduced de novo bile acid production caused by the obliteration of healthy hepatocytes during chronic liver disease<sup>[43]</sup>.

As the liver is the major organ of protein metabolism it is not surprising that a dysregulation of amino acids was found in several studies specifically a decrease in branched chain amino acids (BCAAs: leucine, isoleucine, and valine) and an increase in aromatic amino acids (AAAs: phenylalanine, tryptophan, tyrosine, and histidine) in HCC patients vs healthy controls, indicating enhanced BCAA catabolism and reduced AAA breakdown in the failing liver<sup>[44,45]</sup>. BCAAs have been reported to have a crucial role in cancer by regulating the anabolic process involving protein synthesis and degradation. Alteration of these metabolic pathways was observed after RFA intervention, indicating that application of electrical current during RFA treatment causes burns in the liver and produces coagulative necrosis which results in parenchymal and tumor cell death, enhancement of consumption of BCAA, such as isoleucine which may characterize the inflammatory response in liver<sup>[46]</sup>.

Baniasadi *et al*<sup>[47]</sup> used a targeted approach based on liquid chromatography resolved tandem mass spectrometry (LC-MS/MS) on 73 metabolites out of which 16 were statistically different between the serum of HCC vs cirrhotic HCV patients. Among them, 4 metabolites (methionine, 5-hydroxymethyl-2'-deoxyuridine, N2,N2-dimethylguanosine and uric acid) showed an excellent separation between the two group patients with a sensitivity of 97% and specificity of 95% and an AUROC of 0.98.

Prognostication for HCC after curative treatment is difficult, in part due to the lack of useful biomarkers that would allow for the selection of patients at higher risk of tumor recurrence or enable accurate assessment of treatment response.

Goossens *et al*<sup>[46]</sup> evaluated through 1H-NMR analysis, preoperatively and at various time points post-RFA, the metabolic profile of serum samples from HCC patients in order to identify factors associated with treatment response and recurrence in viral and non-viral HCC patients. The analysis was able to discriminate in the serum of viral HCC between t0 (pre-ablation) and t2 (at 1 to 4 mo post ablation), the t2 being mainly characterized by an increase of glucose, glycerol, methylhistidine, and a decrease of lipids, 3-hydroxybutyrate, and choline but it was not able to predict HCC recurrence.

Zhou *et al*<sup>[48]</sup> evaluated early postoperative recurrence metabolic disturbances in HCC patients and demonstrated that bile acids, steroids and fatty acids showed significant variation in the early recurrent HCC group compared to the late recurrence group. Moreover, with the combination of methionine, GCDCA and cholesterol sulfate, 80% of the early recurrent HCCs can be predicted correctly with the corresponding

AUROC equal to 0.91.

As previously shown there are no specific metabolic changes during the carcinogenetic process and, therefore, by now there is no specific marker to be proposed for diagnostic and prognostic of patients with HCC. Although metabolomics is a powerful strategy for identifying a large panel of metabolites that exhibit promise in accurately diagnosing HCC, integrating two or more "omics" approaches can unveil the complex genomic-proteomic-metabolic network galvanizing cancer development. With this regard, Beyoğlu *et al*<sup>[49]</sup> performed a combined transcriptomics and metabolomics study and was able to evaluate the metabolic profile of G1 to G6 transcriptomics groups of HCC.

## CONCLUSION

The main limitation to the generalization of the results of existing publication is that the methodology used by different groups is not uniform and, thus, the results are sometimes contradictory. Other possible explanation for this variability is the fact that the majority of the studies use non-targeted metabolic analysis and identification of different metabolites is based on molecular mass, which can be similar for different compounds. Despite the important progress that has been made in technology and in understanding the pathological processes, when talking about specific biomarkers for advanced chronic liver diseases we are still in an era of uncertainty and chiromancy.

However, what appears to be a fact, is that during the progression of liver diseases, regardless the etiology, there is a core represented by decrease in serum lysophosphatidylcholine and an increased in bile acids<sup>[20]</sup> (Table 1). These changes augment with the progression of the disease and that's explains the prognostic relevance of these changes. Besides that, several candidate metabolomic biomarkers have been identified in these clinical scenarios. They reflect the changes that occur mainly in lipids, amino-acids and energetic metabolism. Nevertheless, none of them was widely and independently validated, or have been translated into clinical practice.

It is our strong belief that the diversity and quality of emerging data would allow the selection of the best method for metabolomics and further studies would validate new biomarkers for those scenarios where clinical needs are still unmet. Probably, the solution would be to interdisciplinary analyze the data through system's biology, allowing the integration of clinical, biochemical, imaging and "omics" findings, so that we'll be moving towards the era of personalized precision medicine in advanced chronic liver diseases.

## REFERENCES

- 1 de Franchis R. Expanding consensus in portal hypertension Report of the Baveno VI Consensus Workshop: Stratifying risk and

- individualizing care for portal hypertension. *J Hepatol [Internet]* 2015; **63**: 543-545 [DOI: 10.1016/j.jhep.2015.05.022]
- 2 **Ripoll C**, Groszmann R, Garcia-Tsao G, Grace N, Burroughs A, Planas R, Escorsell A, Garcia-Pagan JC, Makuch R, Patch D, Matloff DS, Bosch J; Portal Hypertension Collaborative Group. Hepatic venous pressure gradient predicts clinical decompensation in patients with compensated cirrhosis. *Gastroenterology* 2007; **133**: 481-488 [PMID: 17681169 DOI: 10.1053/j.gastro.2007.05.024]
- 3 **Procopet B**, Tantau M, Bureau C. Are there any alternative methods to hepatic venous pressure gradient in portal hypertension assessment? *J Gastrointest Liver Dis* 2013; **22**: 73-78 [PMID: 23539394]
- 4 **Berzigotti A**, Seijo S, Reverter E, Bosch J. Assessing portal hypertension in liver diseases. *Expert Rev Gastroenterol Hepatol* 2013; **7**: 141-155 [PMID: 23363263 DOI: 10.1586/egh.12.83]
- 5 **Ripoll C**, Bañares R, Rincón D, Catalina MV, Lo Iacono O, Salcedo M, Clemente G, Núñez O, Matilla A, Molinero LM. Influence of hepatic venous pressure gradient on the prediction of survival of patients with cirrhosis in the MELD Era. *Hepatology* 2005; **42**: 793-801 [PMID: 16175621 DOI: 10.1002/hep.20871]
- 6 **Moreau R**, Jalan R, Gines P, Pavesi M, Angeli P, Cordoba J, Durand F, Gustot T, Saliba F, Domenicali M, Gerbes A, Wendon J, Alessandria C, Laleman W, Zeuzem S, Trebicka J, Bernardi M, Arroyo V; CANONIC Study Investigators of the EASL-CLIF Consortium. Acute-on-chronic liver failure is a distinct syndrome that develops in patients with acute decompensation of cirrhosis. *Gastroenterology* 2013; **144**: 1426-1437, 1437.e1-1437.e9 [PMID: 23474284 DOI: 10.1053/j.gastro.2013.02.042] [Available]
- 7 **Arroyo V**, Moreau R, Kamath PS, Jalan R, Ginès P, Nevens F, Fernández J, To U, García-Tsao G, Schnabl B. Acute-on-chronic liver failure in cirrhosis. *Nat Rev Dis Primers* 2016; **2**: 16041 [PMID: 27277335 DOI: 10.1038/nrdp.2016.41]
- 8 **European Association for the Study of Liver**. EASL clinical practical guidelines: management of alcoholic liver disease. *J Hepatol* 2012; **57**: 399-420 [PMID: 22633836 DOI: 10.1016/j.jhep.2012.04.004]
- 9 **Fernández J**, Acevedo J, Castro M, Garcia O, de Lope CR, Roca D, Pavesi M, Sola E, Moreira L, Silva A, Seva-Pereira T, Corradi F, Mensa J, Ginès P, Arroyo V. Prevalence and risk factors of infections by multiresistant bacteria in cirrhosis: a prospective study. *Hepatology* 2012; **55**: 1551-1561 [PMID: 22183941 DOI: 10.1002/hep.25532]
- 10 **Fernández J**, Acevedo J, Wiest R, Gustot T, Amoros A, Deulofeu C, Reverter E, Martínez J, Saliba F, Jalan R, Welzel T, Pavesi M, Hernández-Tejero M, Ginès P, Arroyo V; European Foundation for the Study of Chronic Liver Failure. Bacterial and fungal infections in acute-on-chronic liver failure: prevalence, characteristics and impact on prognosis. *Gut* 2017 [PMID: 28847867 DOI: 10.1136/gutjnl-2017-314240]
- 11 **Alexopoulou A**, Agiasotelli D, Vasilieva LE, Dourakis SP. Bacterial translocation markers in liver cirrhosis. *Ann Gastroenterol* 2017; **30**: 486-497 [PMID: 28845103 DOI: 10.20524/aog.2017.0178]
- 12 **Cabibbo G**, Enea M, Attanasio M, Bruix J, Craxi A, Cammà C. A meta-analysis of survival rates of untreated patients in randomized clinical trials of hepatocellular carcinoma. *Hepatology* 2010; **51**: 1274-1283 [PMID: 20112254 DOI: 10.1002/hep.23485]
- 13 **European Association For The Study Of The Liver**; European Organisation For Research And Treatment Of Cancer. EASL-EORTC clinical practice guidelines: management of hepatocellular carcinoma. *J Hepatol* 2012; **56**: 908-943 [PMID: 22424438 DOI: 10.1016/j.jhep.2011.12.001]
- 14 **Lindon JC**, Holmes E, Nicholson JK. Metabonomics in pharmaceutical R&D. *FEBS J* 2007; **274**: 1140-1151 [PMID: 17298438 DOI: 10.1111/j.1742-4658.2007.05673.x]
- 15 **Wang X**, Zhang A, Sun H. Power of metabolomics in diagnosis and biomarker discovery of hepatocellular carcinoma. *Hepatology* 2013; **57**: 2072-2077 [PMID: 23150189 DOI: 10.1002/hep.26130]
- 16 **Yoshida M**, Hatano N, Nishiumi S, Irino Y, Izumi Y, Takenawa T, Azuma T. Diagnosis of gastroenterological diseases by metabolome analysis using gas chromatography-mass spectrometry. *J Gastroenterol* 2012; **47**: 9-20 [PMID: 22041921 DOI: 10.1007/s00535-011-0493-8]
- 17 **Patel NR**, McPhail MJ, Shariff MI, Keun HC, Taylor-Robinson SD. Biofluid metabolomics using (1)H NMR spectroscopy: the road to biomarker discovery in gastroenterology and hepatology. *Expert Rev Gastroenterol Hepatol* 2012; **6**: 239-251 [PMID: 22375528 DOI: 10.1586/egh.12.1]
- 18 **Schuppan D**, Afdhal NH. Liver cirrhosis. *Lancet* 2008; **371**: 838-851 [PMID: 18328931 DOI: 10.1016/S0140-6736(08)60383-9]
- 19 **Asrani SK**, Kamath PS. Natural history of cirrhosis. *Curr Gastroenterol Rep* 2013; **15**: 308 [PMID: 23314828 DOI: 10.1007/s11894-012-0308-y]
- 20 **Beyoglu D**, Idle JR. The metabolomic window into hepatobiliary disease. *J Hepatol* 2013; **59**: 842-858 [PMID: 23714158 DOI: 10.1016/j.jhep.2013.05.030]
- 21 **Embade N**, Mariño Z, Diercks T, Cano A, Lens S, Cabrera D, Navasa M, Falcón-Pérez JM, Caballeria J, Castro A, Bosch J, Mato JM, Millet O. Metabolic Characterization of Advanced Liver Fibrosis in HCV Patients as Studied by Serum 1H-NMR Spectroscopy. *PLoS One* 2016; **11**: e0155094 [PMID: 27158896 DOI: 10.1371/journal.pone.0155094]
- 22 **Vernocchi P**, Del Chierico F, Putignani L. Gut Microbiota Profiling: Metabolomics Based Approach to Unravel Compounds Affecting Human Health. *Front Microbiol* 2016; **7**: 1144 [PMID: 27507964 DOI: 10.3389/fmicb.2016.01144]
- 23 **Jiménez B**, Montoliu C, MacIntyre DA, Serra MA, Wassel A, Jover M, Romero-Gomez M, Rodrigo JM, Pineda-Lucena A, Felipe V. Serum metabolic signature of minimal hepatic encephalopathy by (1)H-nuclear magnetic resonance. *J Proteome Res* 2010; **9**: 5180-5187 [PMID: 20690770 DOI: 10.1021/pr100486e]
- 24 **Amathieu R**, Nahon P, Triba M, Bouchemal N, Trinchet JC, Beaugrand M, Dhonneur G, Le Moyec L. Metabolomic approach by 1H NMR spectroscopy of serum for the assessment of chronic liver failure in patients with cirrhosis. *J Proteome Res* 2011; **10**: 3239-3245 [PMID: 21568267 DOI: 10.1021/pr200265z]
- 25 **McPhail MJW**, Shawcross DL, Lewis MR, Coltart I, Want EJ, Antoniadis CG, Veselkov K, Triantafyllou E, Patel V, Pop O, Gomez-Romero M, Kyriakides M, Zia R, Abeles RD, Crossey MME, Jassem W, O'Grady J, Heaton N, Auzinger G, Bernal W, Quaglia A, Coen M, Nicholson JK, Wendon JA, Holmes E, Taylor-Robinson SD. Multivariate metabotyping of plasma predicts survival in patients with decompensated cirrhosis. *J Hepatol* 2016; **64**: 1058-1067 [PMID: 26795831 DOI: 10.1016/j.jhep.2016.01.003]
- 26 **Amathieu R**, Triba MN, Nahon P, Bouchemal N, Kamoun W, Haouache H, Trinchet JC, Savarin P, Le Moyec L, Dhonneur G. Serum 1H-NMR metabolomic fingerprints of acute-on-chronic liver failure in intensive care unit patients with alcoholic cirrhosis. *PLoS One* 2014; **9**: e89230 [PMID: 24586615 DOI: 10.1371/journal.pone.0089230]
- 27 **Garcia-Simon M**, Morales JM, Modesto-Alapont V, Gonzalez-Marrachelli V, Vento-Rehues R, Jorda-Miñana A, Blanquer-Olivas J, Monleon D. Prognosis Biomarkers of Severe Sepsis and Septic Shock by 1H NMR Urine Metabolomics in the Intensive Care Unit. *PLoS One* 2015; **10**: e0140993 [PMID: 26565633 DOI: 10.1371/journal.pone.0140993]
- 28 **Neugebauer S**, Giamarellos-Bourboulis EJ, Pelekanou A, Marioli A, Baziaka F, Tsangaris I, Bauer M, Kiehntopf M. Metabolite Profiles in Sepsis: Developing Prognostic Tools Based on the Type of Infection. *Crit Care Med* 2016; **44**: 1649-1662 [PMID: 27097292 DOI: 10.1097/CCM.0000000000001740]
- 29 **Kauppi AM**, Edin A, Ziegler I, Mölling P, Sjöstedt A, Gylfe Å, Strålin K, Johansson A. Metabolites in Blood for Prediction of Bacteremic Sepsis in the Emergency Room. *PLoS One* 2016; **11**: e0147670 [PMID: 26800189 DOI: 10.1371/journal.pone.0147670]
- 30 **Manna SK**, Patterson AD, Yang Q, Krausz KW, Idle JR, Fornace AJ, Gonzalez FJ. UPLC-MS-based urine metabolomics reveals indole-3-lactic acid and phenyllactic acid as conserved biomarkers for alcohol-induced liver disease in the Ppara-null mouse model. *J Proteome Res* 2011; **10**: 4120-4133 [PMID: 21749142 DOI:

- 10.1021/pr200310s]
- 31 **Manna SK**, Thompson MD, Gonzalez FJ. Application of mass spectrometry-based metabolomics in identification of early noninvasive biomarkers of alcohol-induced liver disease using mouse model. *Adv Exp Med Biol* 2015; **815**: 217-238 [PMID: 25427910 DOI: 10.1007/978-3-319-09614-8\_13]
- 32 **Stefanescu H**, Suciu A, Romanciuc F, Crisan D, Procopet B, Radu C, Tantau M, Socaciu C, Grigorescu M. Lyso-phosphatidylcholine: A potential metabolomic biomarker for alcoholic liver disease? *Hepatology* 2016; **64**: 678-679 [PMID: 27123871 DOI: 10.1002/hep.28630]
- 33 **Rachakonda V**, Gabbert C, Raina A, Li H, Malik S, DeLany JP, Behari J. Stratification of risk of death in severe acute alcoholic hepatitis using a panel of adipokines and cytokines. *Alcohol Clin Exp Res* 2014; **38**: 2712-2721 [PMID: 25421508 DOI: 10.1111/acer.12558]
- 34 **Rachakonda V**, Gabbert C, Raina A, Bell LN, Cooper S, Malik S, Behari J. Serum metabolomic profiling in acute alcoholic hepatitis identifies multiple dysregulated pathways. *PLoS One* 2014; **9**: e113860 [PMID: 25461442 DOI: 10.1371/journal.pone.0113860]
- 35 **Ascha M**, Wang Z, Ascha MS, Dweik R, Zein NN, Grove D, Brown JM, Marshall S, Lopez R, Hanounieh IA. Metabolomics studies identify novel diagnostic and prognostic indicators in patients with alcoholic hepatitis. *World J Hepatol* 2016; **8**: 499-508 [PMID: 27057307 DOI: 10.4254/wjh.v8.i10.499]
- 36 **Kimhofer T**, Fye H, Taylor-Robinson S, Thursz M, Holmes E. Proteomic and metabolomic biomarkers for hepatocellular carcinoma: a comprehensive review. *Br J Cancer* 2015; **112**: 1141-1156 [PMID: 25826224 DOI: 10.1038/bjc.2015.38]
- 37 **Wang B**, Chen D, Chen Y, Hu Z, Cao M, Xie Q, Chen Y, Xu J, Zheng S, Li L. Metabonomic profiles discriminate hepatocellular carcinoma from liver cirrhosis by ultraperformance liquid chromatography-mass spectrometry. *J Proteome Res* 2012; **11**: 1217-1227 [PMID: 22200553 DOI: 10.1021/pr2009252]
- 38 **Liu Y**, Hong Z, Tan G, Dong X, Yang G, Zhao L, Chen X, Zhu Z, Lou Z, Qian B, Zhang G, Chai Y. NMR and LC/MS-based global metabolomics to identify serum biomarkers differentiating hepatocellular carcinoma from liver cirrhosis. *Int J Cancer* 2014; **135**: 658-668 [PMID: 24382646 DOI: 10.1002/ijc.28706]
- 39 **Lin L**, Huang Z, Gao Y, Yan X, Xing J, Hang W. LC-MS based serum metabonomic analysis for renal cell carcinoma diagnosis, staging, and biomarker discovery. *J Proteome Res* 2011; **10**: 1396-1405 [PMID: 21186845 DOI: 10.1021/pr101161u]
- 40 **Chen T**, Xie G, Wang X, Fan J, Qiu Y, Zheng X, Qi X, Cao Y, Su M, Wang X, Xu LX, Yen Y, Liu P, Jia W. Serum and urine metabolite profiling reveals potential biomarkers of human hepatocellular carcinoma. *Mol Cell Proteomics* 2011; **10**: M110.004945 [PMID: 21518826 DOI: 10.1074/mcp.M110.004945]
- 41 **Gao R**, Cheng J, Fan C, Shi X, Cao Y, Sun B, Ding H, Hu C, Dong F, Yan X. Serum Metabolomics to Identify the Liver Disease-Specific Biomarkers for the Progression of Hepatitis to Hepatocellular Carcinoma. *Sci Rep* 2015; **5**: 18175 [PMID: 26658617 DOI: 10.1038/srep18175]
- 42 **Ressom HW**, Xiao JF, Tuli L, Varghese RS, Zhou B, Tsai TH, Ranjbar MR, Zhao Y, Wang J, Di Poto C, Cheema AK, Tadesse MG, Goldman R, Shetty K. Utilization of metabolomics to identify serum biomarkers for hepatocellular carcinoma in patients with liver cirrhosis. *Anal Chim Acta* 2012; **743**: 90-100 [PMID: 22882828 DOI: 10.1016/j.aca.2012.07.013]
- 43 **Fitian AI**, Cabrera R. Disease monitoring of hepatocellular carcinoma through metabolomics. *World J Hepatol* 2017; **9**: 1-17 [PMID: 28105254 DOI: 10.4254/wjh.v9.i1.1]
- 44 **Chen S**, Kong H, Lu X, Li Y, Yin P, Zeng Z, Xu G. Pseudotargeted metabolomics method and its application in serum biomarker discovery for hepatocellular carcinoma based on ultra high-performance liquid chromatography/triple quadrupole mass spectrometry. *Anal Chem* 2013; **85**: 8326-8333 [PMID: 23889541 DOI: 10.1021/ac4016787]
- 45 **Fages A**, Duarte-Salles T, Stepien M, Ferrari P, Fedirko V, Pontoizeau C, Trichopoulou A, Aleksandrova K, Tjønneland A, Olsen A, Clavel-Chapelon F, Boutron-Ruault MC, Severi G, Kaaks R, Kuhn T, Floegel A, Boeing H, Lagiou P, Bamia C, Trichopoulos D, Palli D, Pala V, Panico S, Tumino R, Vineis P, Bueno-de-Mesquita HB, Peeters PH, Weiderpass E, Agudo A, Molina-Montes E, Huerta JM, Ardanaz E, Dorronsoro M, Sjöberg K, Ohlsson B, Khaw KT, Wareham N, Travis RC, Schmidt JA, Cross A, Gunter M, Riboli E, Scalbert A, Romieu I, Elena-Herrmann B, Jenab M. Metabolomic profiles of hepatocellular carcinoma in a European prospective cohort. *BMC Med* 2015; **13**: 242 [PMID: 26399231 DOI: 10.1186/s12916-015-0462-9]
- 46 **Goossens C**, Nahon P, Le Moyec L, Triba MN, Bouchemal N, Amathieu R, Ganne-Carrié N, Ziol M, Trinchet JC, Sellier N, Diallo A, Seror O, Savarin P. Sequential Serum Metabolomic Profiling after Radiofrequency Ablation of Hepatocellular Carcinoma Reveals Different Response Patterns According to Etiology. *J Proteome Res* 2016; **15**: 1446-1454 [PMID: 27015127 DOI: 10.1021/acs.jproteome.5b01032]
- 47 **Baniasadi H**, Gowda GA, Gu H, Zeng A, Zhuang S, Skill N, Maluccio M, Raftery D. Targeted metabolic profiling of hepatocellular carcinoma and hepatitis C using LC-MS/MS. *Electrophoresis* 2013; **34**: 2910-2917 [PMID: 23856972 DOI: 10.1002/elps.201300029]
- 48 **Zhou L**, Liao Y, Yin P, Zeng Z, Li J, Lu X, Zheng L, Xu G. Metabolic profiling study of early and late recurrence of hepatocellular carcinoma based on liquid chromatography-mass spectrometry. *J Chromatogr B Analyt Technol Biomed Life Sci* 2014; **966**: 163-170 [PMID: 24582150 DOI: 10.1016/j.jchromb.2014.01.057]
- 49 **Beyoğlu D**, Imbeaud S, Maurhofer O, Bioulac-Sage P, Zucman-Rossi J, Dufour JF, Idle JR. Tissue metabolomics of hepatocellular carcinoma: tumor energy metabolism and the role of transcriptomic classification. *Hepatology* 2013; **58**: 229-238 [PMID: 23463346 DOI: 10.1002/hep.26350]

**P- Reviewer:** Puoti C, Zheng YB, Zhu HF **S- Editor:** Song XX  
**L- Editor:** A **E- Editor:** Wang CH



Observational Study

## Management of restless legs syndrome in chronic liver disease: A challenge for the correct diagnosis and therapy

Rita Moretti, Paola Caruso, Marzia Tecchiolli, Silvia Gazzin, Claudio Tiribelli

Rita Moretti, Paola Caruso, Marzia Tecchiolli, Neurology Clinic, Department of Medical, Surgical and Health Sciences, University of Trieste, Trieste 34149, Italy

Silvia Gazzin, Claudio Tiribelli, Italian Liver Foundation, Centro Studi Fegato, Trieste 34149, Italy

ORCID number: Rita Moretti (0000-0002-9731-2697); Paola Caruso (0000-0002-1466-6060); Marzia Tecchiolli (0000-0003-2474-1500); Silvia Gazzin (0000-0001-9403-3564); Claudio Tiribelli (0000-0001-6596-7595).

**Author contributions:** Moretti R, Caruso P and Gazzin S contributed to study conception and design; Moretti R, Caruso P, Tecchiolli M and Gazzin S contributed to data acquisition, data analysis and interpretation, and writing of the article; Moretti R, Caruso P, Tecchiolli M and Tiribelli C contributed to editing, reviewing and final approval of the article.

**Institutional review board statement:** This observational study has been reviewed by the Committee of Research of Cattinara Hospital.

**Informed consent statement:** Participants gave informed consent for data sharing.

**Conflict-of-interest statement:** No conflicting interests (commercial, personal, political, intellectual or religious interests) are related to this work. The authors do not have any conflict of interest to declare.

**Data sharing statement:** Technical appendix, statistical code, and dataset available from the corresponding author at [moretti@units.it](mailto:moretti@units.it).

**Open-Access:** This article is an open-access article which was selected by an in-house editor and fully peer-reviewed by external reviewers. It is distributed in accordance with the Creative Commons Attribution Non Commercial (CC BY-NC 4.0) license, which permits others to distribute, remix, adapt, build upon this work non-commercially, and license their derivative works on different terms, provided the original work is properly cited and the use is non-commercial. See: <http://creativecommons.org/licenses/by-nc/4.0/>

Manuscript source: Invited manuscript

Correspondence to: Rita Moretti, MD, PhD, Senior Scientist, Department of Medical, Surgical and Health Sciences, University of Trieste, Strada di Fiume 447, Trieste 34149, Italy. [moretti@units.it](mailto:moretti@units.it)  
Telephone: +39-40-3994572  
Fax: +39-40-3994284

Received: October 30, 2017

Peer-review started: October 31, 2017

First decision: December 26, 2017

Revised: December 27, 2017

Accepted: January 23, 2018

Article in press: January 23, 2018

Published online: March 27, 2018

### Abstract

#### AIM

To investigate the association between restless legs syndrome (RLS) and well-defined chronic liver disease, and the possible therapeutic options.

#### METHODS

Two hundred and eleven patients with chronic liver disease, complaining of sleep disturbances, painful leg sensation and daily sleepiness, were included. Patients with persistent alcohol intake, recent worsening of clinical conditions, or hepatitis C virus were excluded. Diagnosis of RLS was suggested by the Johns Hopkins questionnaire and verified by fulfilling the diagnostic criteria by Allen. All patients were tested, both at baseline and during follow-up, with the Hamilton rating scale for depression, sleep quality assessment (PSQI), Epworth sleepiness scale (ESS), International Restless Legs Syndrome Study Group evaluation, and international RLS severity (IRLS) scoring system. Iron-free level, ferritin, folate, vitamin B12 and D-OH25 were detected. Neurological examinations and blood test

occurred at the beginning of the therapy, after 2 wk, and at the 28<sup>th</sup>, 75<sup>th</sup>, 105<sup>th</sup>, 135<sup>th</sup>, 165<sup>th</sup> and 205<sup>th</sup> day. Regarding therapy, pramipexole or gabapentin were used.

## RESULTS

Patients were moderately depressed, with evident nocturnal sleep problems and concomitant daily sleepiness. Sleep problems and involuntary leg movements had been underestimated, and RLS syndrome had not been considered before the neurological visit. All (211/211) patients fulfilled the RLS diagnostic criteria. Twenty-two patients considered their symptoms as mild, according to IRSL, but 189 found them moderate to very severe. No correlation was found between ammonium level and ESS or PSQI. Augmentation was rather precocious in our patients (135<sup>th</sup> day), and more frequent (35%) than previous data (8.3%-9.1%). The dosage of dopamine agonists was found to be associated with augmentation and appears in range with the literature. Previous intake of alcohol and lower levels of vitamins have been related to the phenomenon in our study.

## CONCLUSION

RLS is a common disorder, requiring rapid diagnosis and treatment. Further research is therefore fundamental.

**Key words:** Restless legs syndrome; Chronic liver disease; Dopamine agonist treatment; Augmentation

© **The Author(s) 2018.** Published by Baishideng Publishing Group Inc. All rights reserved.

**Core tip:** The diagnosis of restless legs syndrome (RLS) relies on the presence of unpleasant sensation in the legs associated with the urge to move. Symptoms mostly begin during periods of rest or inactivity and worsen in the evening or night. Partial or total relief is related to movement. Chronic hepatic failure was recently described in association with RLS, but there are very limited studies, with no mention to treatment. We describe RLS syndrome associated with well-defined chronic liver disease along with therapeutic options, discussing risks, benefits and potential side effects, with a particular look at the augmentation phenomenon in hepatic failure.

Moretti R, Caruso P, Tecchiolli M, Gazzin S, Tiribelli C. Management of restless legs syndrome in chronic liver disease: A challenge for the correct diagnosis and therapy. *World J Hepatol* 2018; 10(3): 379-387 Available from: URL: <http://www.wjgnet.com/1948-5182/full/v10/i3/379.htm> DOI: <http://dx.doi.org/10.4254/wjh.v10.i3.379>

## INTRODUCTION

Restless legs syndrome (RLS) is defined as a very sickening, bilateral (even if also unilateral) sensation,

almost described as affecting a very limited zone, between the knees and ankles, sometimes involving thighs and feet and resulting in feelings of scrambles, creeps or crawls. The discomfort is experienced only during the rest phase and it is relieved by active movement of the legs. Patients describe the symptoms of RSL as unbearable, when they are strained to maintain the sit-down position, such as during long flights or social events. But, usually, sleep is the worst moment of the day and RLS can disturb their sleep for hours. The American patients' organization Restless Legs Syndrome Foundation reminds us that RLS is "the most common disorder you have never heard of" (<http://www.rls.org>).

RLS remains a clinical diagnosis based on confirming the four essential diagnostic features of RLS: (1) An urge to move the legs, usually but not always accompanied by or felt to be caused by uncomfortable and unpleasant sensations in the legs; (2) the urge to move, as any accompanying unpleasant sensation begins or worsens during periods of rest or inactivity, such as lying down or sitting; (3) the urge to move, as any accompanying unpleasant sensation is partially or totally relieved by movement, such as walking or stretching; and (4) the urge to move, as any accompanying unpleasant sensation during rest or inactivity only occurs or is worse in the evening or night compared to during the day<sup>[1,2]</sup>. Moreover, supportive criteria should be found in family history, response to dopaminergic therapy and the presence of involuntary, rhythmic muscular jerks in the lower limbs, including dorsiflexion or fanning of toes, flexion of ankles, knees and hips, the so-called periodic limb movements during sleep (PLMS)<sup>[1,3]</sup>.

Helpful tools to make an accurate RLS diagnosis include the Johns Hopkins telephone diagnostic interview, medical history (evaluating for four essential diagnostic features of RLS and iron deficiency), and evaluating and ruling out mimics<sup>[4]</sup>. RLS frequently occurs in patients with kidney disease.

The prevalence of RLS, which is high in dialysis patients and which has been associated with increased risk for cardiovascular disease in the general population, could also play a role in the pathogenesis of hypertension during sleep in renal patients. It should be noted that intravenous iron treatment reduces the RLS symptoms in patients with end-stage renal disease<sup>[2]</sup>. RLS is common in rheumatologic disorders, such as rheumatoid arthritis or Sjögren's syndrome<sup>[1,2]</sup>, but not in isolated peripheral neuropathy, as in hereditary neuropathic patients<sup>[2]</sup>. Some data seem to indicate that there is a considerably higher risk for developing RLS in migraneous patients, especially in those who experienced the dopaminergic anticipatory symptoms, such as nausea, somnolence and yawning<sup>[2]</sup>. RLS is also common during pregnancy, especially during the last trimester, and iron deficiency may be a major cause; the symptoms of RLS usually disappear soon after childbirth. An increased

prevalence of RLS has been described in patients with liver cirrhosis in the United States<sup>[5]</sup> and Japan<sup>[6]</sup>. Very recently, Goel *et al.*<sup>[7]</sup> described in India RLS in a series of chronic hepatic failure patients.

## MATERIALS AND METHODS

This study included 267 adult patients with chronic liver disease, referred to our Neurological Unit by the Liver Unit of the University of Trieste between June 1, 2008 and December 1, 2015. The patients had been referred to the neurologist for the three complaints of sleep disturbances, painful leg sensation, daily sleepiness not correlated to hepatic encephalopathy. Patients with chronic liver disease included primary liver tumor and liver cirrhosis. We excluded 13 patients with chronic and persistent significant alcohol intake (> 30 g/d in men and > 20 g/d in women; to avoid acute alcohol polyneuropathy, which might mimic some symptoms of RLS and low compliance), 25 patients with recent worsening of clinical condition (jaundice, ascites or encephalopathy, gastrointestinal bleeding, or hospitalization), and 12 patients with hepatitis C virus (HCV; to exclude HCV-related peripheral complications).

All the other 211 patients were followed up by a neurologist at least for 24 mo (Table 1). According to neurological exams, the diagnosis of RLS was suggested by the Johns Hopkins questionnaire<sup>[4]</sup> and verified by fulfilling the diagnostic criteria by Allen *et al.*<sup>[1]</sup>. Only 3 patients mentioned a possible familiar history of RLS. Iron-free level, ferritin, folate, vitamin B12 and vitamin D-OH25 was measured in all patients (Table 2).

At baseline, patients were tested with the Hamilton rating scale for depression<sup>[9]</sup>, sleep quality assessment (PSQI)<sup>[10]</sup>, Epworth sleepiness scale (ESS)<sup>[11]</sup>, International Restless Legs Syndrome Study Group (IRLSSG) evaluation<sup>[12]</sup>, and international RLS severity (IRLS) scoring system<sup>[13]</sup>.

The Pittsburgh sleep quality index (PSQI) is an effective instrument, employed to measure the quality and pattern of sleep in adults. It differentiates "poor" from "good" sleep quality by measuring the following seven areas (components): Subjective sleep quality; sleep latency; sleep duration; habitual sleep efficiency; sleep disturbances; use of sleeping medications; and, daytime dysfunction over the last month. A total score of 5 or greater is indicative of poor sleep quality<sup>[10]</sup>.

The ESS questionnaire asks the subject to rate the probability of falling asleep on a scale of increasing probability from 0 to 3 for eight different situations that most people engage in during their daily lives, though not necessarily every day. The scores for the eight questions are added together to obtain a single number. A number in the 0-9 range is considered to be normal, while a number in the 10-24 range indicates that expert medical advice should be sought. For instance, scores of 11-15 are shown to indicate the

**Table 1** Baseline general conditions of patients recruited

Characteristic	Hepatic failure, <i>n</i> = 211
Male/female	107/104
Age in year, mean and standard deviation (median range)	59 ± 4.7 (36-74)
BMI, kg/m <sup>2</sup>	25.43 ± 4.1
Cause of liver disease, <i>n</i>	211
Previous alcohol abuse	139
Hepatic venous outflow tract obstruction	14
Cryptogenic	12
Liver primary tumor	46
Child-Pugh class; number	211
A	132
B	54
C	25

BMI: Body mass index.

possibility of mild to moderate sleep apnea, where a score of 16 and above indicates the possibility of severe sleep apnea or narcolepsy<sup>[10]</sup>.

The IRLSSG<sup>[1]</sup> evaluation is based on the assessment of the following five questions, with the necessary fulfillment of three or more: (1) An urge to move the legs, usually accompanied by uncomfortable and unpleasant sensations in the legs; (2) which begins or worsens during periods of rest or inactivity; (3) which occurs only or is worse in the evening or night than during the day; (4) which is partially or totally relieved by repeated leg movements; and (5) for which the occurrence of the above features is not solely accounted for by another medical or behavioral condition.

The IRLS score<sup>[11,12]</sup> consists of a set of 10 self-administered questions, each of which is scored on a scale extending from 0 to 4. The scores of individual questions are aggregated to yield a total score ranging from 0 to 40. Based on the IRLS score, RLS is graded as mild (0-10), moderate (11-20), severe (21-30), or very severe (31-40).

The drugs used to treat RLS belong to many different pharmacological classes, including the dopaminergic agents, opioids, benzodiazepines and antiepileptic drugs. We decided to avoid the employment of opioids and benzodiazepine due to the hepatic conditions. Therefore, the first-choice drug was pramipexole, a dopamine agonist<sup>[14]</sup>.

Neurological examinations and laboratory tests were performed at the beginning, after 2 wk, at the 28<sup>th</sup>, 75<sup>th</sup>, 105<sup>th</sup>, 135<sup>th</sup> and 165<sup>th</sup> day, and at the final day of the follow-up, the 205<sup>th</sup> day. If major side effects induced by the neurological therapy occurred, such as nausea, vomiting, somnolence, hypotension or optical illusions, the pramipexole was stopped.

The second-choice drug was gabapentin, due to its beneficial properties and to the limited hepatic side effects<sup>[15-18]</sup>.

Another aim of this study was to define the augmentation phenomenon in the liver patients.

**Table 2** Baseline metabolic parameters of 211 patients recruited

Labs parameter (normal values)	Average of 211 patients (range)
Hemoglobin (14-16 g/dL)	11.1 (7.5-12.3)
Platelets counts (150-400 × 1000/μL)	97 (65-423)
Serum protein (g/dL)	7.6 (3.4-10.1)
Serum bilirubin (0.1-1.3 mg/dL)	1.7 (0.9-12)
Alanine aminotransferase (8-55 IU/L)	77 (24-452)
Aspartate aminotransferase (8-48 IU/L)	71 (34-715)
International normalized ratio (INR)	1.8 (1.0-4.9)
Serum creatinine (0.6-1.2 mg/dL)	1.0 (0.6-2.1)
Serum albumin (3.7-5.0 g/dL)	3.5 (1.5-5.1)
Ammonium (40-80 μg/dL)	97 (45-134)
Folate (3.89-26.0 ng/mL)	2.3 (1.9-12.3)
Iron free level (40-150 μg/dL)	26.5 (12-89)
Ferritine (20-200 ng/mL)	235 (126-456)
Vitamin B12 (205-870 pg/mL)	189 (121-245)
Vitamin D-OH25 (30-100 ng/mL)	41 (12-130)

Augmentation is a characteristic phenomenon, well known in RLS patients, even if its mechanisms are not fully understood and most importantly, the possible inducing factors have not been identified<sup>[11,13,18]</sup>. It seems to be a pejorative condition of the earliest symptoms of RLS, or an expansion to other body parts, such as the trunk or upper limbs, compared with the initial benefits of the therapy<sup>[19]</sup>. It has been related to long-term duration of dopaminergic therapy, to higher dosage, and to the dopamine stimulation (up to 14.2%-73% with L-DOPA, and from 8.3 up to 70% with dopamine agonists)<sup>[19-22]</sup>. Opioid analgesics, such as tramadol, methadone and oxycodone, may be considered for RLS treatment; although, trials reviewing long-term efficacy are lacking. The potential for abuse and adverse effects including dizziness, nausea and constipation limit the usefulness of these medications. In addition, tramadol has been rarely associated with RLS symptom augmentation<sup>[23]</sup>.

As far as we know, no study has ever been conducted in hepatic patients to consider this phenomenon.

Titration, side effects, augmentation phenomenon and whichever alterations in laboratory test findings were checked and are reported here.

All procedures complied with ethical standards for human investigations and the principles of the Declaration of Helsinki. All the patients gave written informed consent for participation at the first visit.

## RESULTS

Baseline characteristics of patients are reported in Tables 1 and 2. A synopsis of the various test scores are reported in Table 3.

Patients were moderately depressed, with evident nocturnal sleep problems and a concomitant daily sleepiness. The most relevant aspect is that the sleep problem had been underestimated, and RLS syndrome had not been considered before the neurological visit, since 211/211 patients fulfilled the IRLSSG criteria for RLS.

**Table 3** Synopsis of the tests at baseline

Test (range)	Results
Hamilton rating scale (0-66)	18.5 ± 4.5
PSQI (0-5)	3.4 ± 0.5
ESS (0-24)	11 ± 2.1
IRLSSG	Fulfillment of criteria: 211/211
IRSL (0-40)	0-10 (mild) = 22 11-20 (moderate) = 76 21-30 (severe) = 109 31-40 (very severe) = 4

ESS: Excessive diurnal sleepiness; IRSL: International RLS severity scoring system; IRLSSG: International Restless Legs Syndrome Study Group evaluation; PSQI: Depression, sleep quality assessment.

All the patients pointed out that their involuntary leg movements had not been considered previously, or had been interpreted as neuropathic pain and therefore treated with nonsteroidal antiinflammatory drug. Of the 211 RLS patients, 22 considered their symptoms as mild, according to IRSL, but 189 found them moderate to very severe (Table 3).

Patients were moderately depressed according to an objective test, such as the Hamilton scale. Symptoms included depressed mood, insomnia, work and activities production, retardation as slowness of thought and speech, anxiety and somatic symptoms, insight and diurnal variation, and not in the more psychiatric-related scores, such as feelings of guilt, suicide thoughts, agitation, genital symptoms, hypochondriasis, loss of weight, depersonalization and derealization, paranoid symptoms, obsession and compulsive symptoms.

A Spearman's rank correlation analysis showed the following: (1) A positive correlation between IRLSSG fulfillment criteria and poor nocturnal sleep quality (PSQI:  $r = 0.89$ ,  $P < 0.01$ ); (2) a positive correlation between IRLSSG fulfillment criteria and excessive diurnal sleepiness (ESS:  $r = 0.92$ ,  $P < 0.01$ ); (3) a positive correlation between IRLSSG fulfillment criteria and Hamilton's score ( $r = 0.76$ ,  $P < 0.05$ ); and, (4) a positive correlation between the four levels of IRSL and PSQI (IRSL 0-10 vs PSQI:  $r = 0.71$ ,  $P < 0.05$ ; IRSL 11-20 vs PSQI:  $r = 0.78$ ,  $P < 0.05$ ; IRSL 21-30 vs PSQI:  $r = 0.83$ ,  $P < 0.01$ ; IRSL 31-40 vs PSQI:  $r = 0.89$ ,  $P < 0.01$ ). There was no correlation found between ammonium level and ESS or PSQI.

At the beginning, all patients were prescribed pramipexole at an average dosage of 0.18 mg, to be taken in the evening for the first 2 week. We then duplicated the dosage for 2 more weeks, up to 0.36 mg, once a day; this dosage was maintained till the 75<sup>th</sup> day. At the 75<sup>th</sup> day, we prescribed 0.7 mg daily, which was then increased to 0.88 mg daily at the 105<sup>th</sup> day. Forty-one patients reported side effects at the 135<sup>th</sup> day, such as persistent nausea, optical illusions and visual hallucinations, and decided to stop the pramipexole therapy (see below). The remaining

**Table 4 Synopsis of pramipexole titration**

Patients	Baseline	75 <sup>th</sup> day	105 <sup>th</sup> d	135 <sup>th</sup> day	165 <sup>th</sup> day	205 <sup>th</sup> day
211	0.18 mg					
211		0.7 mg				
211			0.88 mg			
170				1.4 mg		
134					1.4 mg	
36					0.88 mg	
110						1.4 mg
60						0.7 mg

**Table 5 Synopsis of gabapentin titration**

Patients	45 <sup>th</sup> day	75 <sup>th</sup> day	105 <sup>th</sup> day	135 <sup>th</sup> day	165 <sup>th</sup> day	205 <sup>th</sup> day
41	100 mg					
41		300 mg				
35			300 mg			
6			400 mg			
30				300 mg		
11				500 mg		
27					300 mg	
14					600 mg	
16						300 mg
25						600 mg

**Table 6 Results for pramipexole therapy during follow-up of 170 patients**

Test (range)	135 <sup>th</sup> day	165 <sup>th</sup> day	205 <sup>th</sup> day
Hamilton rating	9.2 ± 0.1	8.7 ± 1.3	9.0 ± 1.1
scale (0-66)	(-9.3 ± 3.0; < 0.01)	(-9.8 ± 1.7; < 0.01)	(-9.5 ± 0.2; < 0.01)
PSQI (0-5)	2.2 ± 0.7	1.9 ± 0.7	2.3 ± 0.7
	(-1.2 ± 0.2; < 0.05)	(-1.32 ± 0.2; < 0.05)	(-1.1 ± 0.2; < 0.05)
ESS (0-24)	8.3 ± 0.7	8.5 ± 0.4	8.7 ± 1.1
	(-7.1 ± 0.4; < 0.01)	(-7.3 ± 0.7; < 0.01)	(-7.7 ± 0.2; < 0.01)
IRSL (0-40)	0-10 (mild) = 51	134	110
	11-20 (moderate) = 100	12	45
	21-30 (severe) = 19	14	15
	31-40 (very severe) = 0	0	0

Within-group analysis was done by comparing results at each day's visit *vs* baseline. ESS: Excessive diurnal sleepiness; IRLS: International RLS severity scoring system; PSQI: Depression, sleep quality assessment.

170 patients were prescribed 1.4 mg daily, which seemed quite appropriate in respect of their average body mass index. At the following scheduled visit, on the 165<sup>th</sup> d, we reported that 134 patients (65%) felt well with the 1.4 mg/daily dose (the maximum allowed dosage being 2.1 mg daily). On the contrary, 36 patients (25%) reported the reappearance of unpleasant sensations in their legs and feet, with the urgency to rise up and move, during night and early morning (augmentation phenomenon). These patients were treated with 0.88 mg daily. At the 205<sup>th</sup> day, 110 patients (52%) continued to feel good with the 1.4 mg daily dosage; on the other hand, 60 patients (48%) reported the augmentation symptoms

**Table 7 Results for gabapentin therapy during follow-up of 41 patients**

Test (range)	135 <sup>th</sup> day	165 <sup>th</sup> day	205 <sup>th</sup> day
Hamilton rating	9.7 ± 0.4	9.7 ± 0.5	10.0 ± 0.7
scale(0-66)	(-9.8 ± 0.2; < 0.01)	(-9.8 ± 0.3; < 0.01)	(-9.9 ± 1.2; < 0.01)
PSQI (0-5)	2.7 ± 0.7	2.9 ± 0.3	3.0 ± 0.5
	(+ 0.7 ± 0.2; NS)	(+0.5 ± 0.2; NS)	(+0.6 ± 0.3; NS)
ESS (0-24)	9.9 ± 0.7	9.5 ± 0.4	12.7 ± 1.1
	(-0.7 ± 1.0; NS)	(-0.5 ± 0.1; NS)	(-3.3 ± 0.1; < 0.05)
IRSL (0-40)	0-10 (mild) = 21	18	17
	11-20	19	22
	(moderate) = 14		
	21-30	4	2
	(severe) = 6		
	31-40	0	0
	(very severe) = 0		

Within-group analysis was done by comparing results at each day's visit *vs* the 45<sup>th</sup> day results. ESS: Excessive diurnal sleepiness; IRLS: International RLS severity scoring system; NS: Nonsignificant; PSQI: Depression, sleep quality assessment.

and were titrated to 0.7 mg daily (Table 4).

The 41 patients who abandoned pramipexole, after 2 wash-out weeks, were administered gabapentin at 100 mg daily for 10 d, then 200 mg daily for 20 d, and then 300 mg for 40 d. At the 105<sup>th</sup> day, 6 patients (14%) required 400 mg daily. At the 135<sup>th</sup> day, 11 patients (27%) needed 500 mg gabapentin daily. At the 165<sup>th</sup> day, 14 patients (34%) needed gabapentin up to 600 mg daily, and at the 205<sup>th</sup> day, 25 patients (61%) needed 600 mg gabapentin (Table 5).

Considering the 170 patients who completed the 205 d of follow-up with pramipexole, the results were rather satisfactory (Table 6), with an evident and constant amelioration of depression, of sleep quality and of daily sleepiness, as far as Wilcoxon signed rank test within-group comparison (*vs* baseline) showed. At the final visit, their subjective feeling of the intensity of RLS disturbances was perceived as mild to moderate in 155 patients and severe in 15 of them. Nobody declared a very severe score (Table 6).

The 41 patients who abandoned pramipexole, due to side effects, were treated with gabapentin (Table 5). According to a Wilcoxon signed rank test, there was a slight worsening of nocturnal sleep quality, significantly evident at the 205<sup>th</sup> day (Table 7) according to reporting of an increase in daily sleepiness. The quality of RLS disturbances was perceived at final visit as mild to moderate in 29 patients and severe in 2 of them. All the 41 patients who took gabapentin reported abdominal weight gain (5.2 ± 1.1 kg, range: 2.4-7.6) at the final visit.

We have determined the onset of augmentation symptoms in 170 patients who carried on with pramipexole. Logistic regression analysis to identify factors associated with the augmentation was performed with independent variables, including age, body mass index, IRLS alcohol abuse, iron-free levels, folate, vitamin B<sub>12</sub> and D-OH25, alanine and

**Table 8** Analysis of factors for association with the presence of augmentation

Factor	n	Univariate		Multivariate	
		OR (95%CI)	P value	OR (95%CI)	P value
Age	170	1.07 (0.7-1.2)	0.24	1.1 (0.9-1.3)	0.20
BMI	170	1.3 (0.9-1.5)	0.45	1.6 (1.0-1.9)	0.40
IRLS	170	1.5 (1.1-2.2)	0.36	1.7 (1.2-2.2)	0.57
Alcohol abuse	139	2.3 (0.9-4.1)	< 0.001	3.75 (2.7-6.2)	< 0.001
Daily pramipexole treatment duration, > 75 d / < 75 d	170	3.6 (2.1-6.8)	< 0.001	7.2 (4.1-15.2)	< 0.001
ALT	170	2.3 (1.3-4.2)	0.036	6.6 (3.1-11.2)	0.01
AST	170	1.3 (0.9-1.6)	0.21	3.1 (1.7-3.9)	0.54
Iron-free level	170	1.6 (0.8-1.7)	0.50	2.7 (0.7-4.2)	0.76
Vit. B12	170	2.9 (0.9-4.1)	0.01	5.05 (1.1-12.2)	0.06
Folate	170	4.25 (1.3-9.7)	0.01	6.9 (4.7-7.6)	0.01
Vit. D-OH25	170	4.1 (3.1-13.6)	0.01	5.7 (4.2-8.2)	0.01
	170	4.8 (3.4-12.9)	0.01	5.67 (2.4-8.9)	0.01

ALT: Alanine aminotransferase; AST: Aspartate aminotransferase; BMI: Body mass index; CI: Confidence interval; IRLS: International restless leg syndrome severity; OR: Odds ratio; Vit.: Vitamin.

aspartate aminotransferases, treatment duration of pramipexole, and daily pramipexole doses. Univariate and multivariate logistic regression analyses were performed, and the Wald test was used to assess the significance of each variable, as reported in Table 8. Daily pramipexole dose, duration of treatment, previous alcohol abuse, iron-free levels as well as lower levels of B<sub>12</sub>, D-OH25 and folate were significantly associated with augmentation in univariate analysis (Table 8). On the other hand, abuse of alcohol, dose of pramipexole and its duration, level of vitamin B<sub>12</sub> and D-OH25 and of folate, in the multivariate regression analysis, seemed to be significantly associated with augmentation (Table 8).

## DISCUSSION

In this study, we found that patients with chronic liver disease, such as liver cirrhosis or primitive tumors, who were referred for sleep disorders might have RLS as well. The presence of RLS was not associated with sex, and cause or severity of the liver disease was in line to what has been demonstrated by Goel *et al*<sup>[7]</sup>. As previously reported<sup>[3]</sup>, many causative factors can induce RLS in hepatic chronic disease patients, such as low iron levels, high ferritin levels and associated low folate and vitamin B<sub>12</sub> levels. It has also been described that the increased prevalence of RLS in chronic medical conditions (such as renal failure and, limited to few studies, hepatic failure) might be related to altered electrolyte levels, such as diuretic-induced hypokalemia, dilutional and diuretic-induced hyponatremia, hypocalcemia, or hypomagnesemia. Furthermore, it is possible that vitamin D deficiency, reduced physical activity, reduced muscular tone and increased serum levels of endotoxins and inflammatory

cytokines (due to porta-systemic shunting resulting in low-grade inflammation) account for this phenomenon.

In particular, iron deficiency (present in all our patients) has been associated with dopamine pathology in RLS<sup>[24]</sup>. More specifically, it has been hypothesized that brain iron deficiency produces a dopaminergic pathology, resulting in the RLS symptoms<sup>[2]</sup>. Cerebral spinal fluid (CSF), autopsy and brain imaging studies clearly showed the expected brain iron deficiency, particularly affecting the dopamine-producing cells in the substantia nigra and their terminal fields in the striatum. A low content of iron in the brain is a well-established finding of RLS<sup>[24,25]</sup>. The dopamine pathology was, however, elusive and only recently has it been more clearly identified.

Animal and cellular iron deficiency studies have shown an increased activity of tyrosine hydroxylase in the substantia nigra<sup>[26]</sup> and decreased D<sub>2</sub> receptors in the striatum<sup>[26]</sup>. These variations were associated with a decreased function of the cell membrane dopamine transporter<sup>[28]</sup> with increased concentration of the extracellular dopamine, with a 4-times increase in the amplitude of the circadian variation of extracellular dopamine (night-day difference)<sup>[29]</sup>. These same findings have been confirmed in RLS patients<sup>[2]</sup>. The CSF of these patients has significantly more 3-O-methyldopa, that correlates with the CSF homovanillic acid and RLS severity, indicating that increased dopamine production is proportional to the severity of RLS symptoms<sup>[30]</sup>. Moreover, the CSF tetrahydrobiopterin is significantly increased in the morning compared to night<sup>[30]</sup>, and this finding is consistent with the larger circadian extracellular dopamine pattern observed in the iron-deprived rat.

As pointed out by Salas *et al*<sup>[2]</sup>, RLS, unlike Parkinson's disease, is a hyper-dopaminergic condition with an apparent postsynaptic desensitization that overcompensates during the circadian low point of dopaminergic activity in the evening and night. This overcompensation leads to the RLS symptoms that can be easily corrected by adding dopamine stimulation at that time. The primary finding from multiple studies indicates that the iron deficiency affects dopaminergic function, by increasing tyrosine hydroxylase, which then increases extracellular dopamine<sup>[2,32-34]</sup>. Our study confirms an effective and rapid benefit by the use of dopamine agonist (as well-recognized and reported in the literature<sup>[3,32,33]</sup>).

On the other hand, RLS is a hyperdopaminergic condition, with an apparent postsynaptic desensitization that overcompensates during the circadian low point of dopaminergic activity in the evening and night. This overcompensation leads to the RLS symptoms that in turn often lead to increasing postsynaptic desensitization and augmentation of the RLS<sup>[2,32,34-36]</sup>. In fact, patients with RLS with mood and stress states may be at greater risk of developing compulsive behaviors while receiving standard dosage treatment of dopamine agonists (but

also of other drugs, such as tramadol<sup>[22]</sup>).

It appears evident that RLS remains a still confounding, not immediately recognized condition requiring rapid diagnosis and treatment. Augmentation seems rather precocious in our patients (135<sup>th</sup> day) and more frequent (35%) than previously described by Ferini-Strambi (8.3%)<sup>[20]</sup> and by Takahashi *et al.*<sup>[22]</sup> (9.1%). The dosage of dopamine agonists found to be associated with augmentation in this study appears in range with the literature<sup>[14,19-22]</sup>. Previous intake of alcohol and lower levels of vitamins have been related to the phenomenon in our study.

RLS is a major cause of insomnia, and the structure of sleep of sufferers may be severely impaired. Sleep disruption has, in consequence, a great impact on health and daytime functioning of RLS patients. Despite the fact that RLS is a very common disorder, it is frequently undiagnosed in primary care, and therefore inadequate therapy may be prescribed.

Additional neurophysiologic studies and more extended clinical trials are strenuously needed to explain some crucial pathologic mechanisms of the syndrome, in order to better employ common therapeutic agents and to find novel ones.

## ARTICLE HIGHLIGHTS

### Research background

Restless legs syndrome (RLS) remains a clinical diagnosis based on confirming the four essential diagnostic features of RLS, including: (1) An urge to move the legs, usually but not always accompanied by or felt to be caused by uncomfortable and unpleasant sensations in the legs; (2) the urge to move, as any accompanying unpleasant sensation begins or worsens during periods of rest or inactivity, such as lying down or sitting; (3) the urge to move, as any accompanying unpleasant sensation is partially or totally relieved by movement, such as walking or stretching; and (4) the urge to move, as any accompanying unpleasant sensation during rest or inactivity only occurs or is worse in the evening or night compared to during the day. Chronic medical situations (dialysis, end-stage renal disease and rheumatologic disorders) have a higher prevalence of RLS.

### Research motivation

An increased prevalence of RLS has been described in patients with liver cirrhosis in the United States and Japan. Very recently, RLS has been described in India in a series of chronic hepatic failure patients. Data in hepatic patients are limited.

### Research objectives

According to neurological exams, the diagnosis of RLS was suggested by the Johns Hopkins questionnaire and verified by fulfillment of the diagnostic criteria by Allen. Iron-free level, ferritin, folate and vitamin B12 and vitamin D-OH25 were measured in all patients. Drugs used to treat RLS belong to many different pharmacological classes, such as the dopaminergic agents, opioids, benzodiazepines and antiepileptic drugs. We decided to avoid the employment of opioids and benzodiazepine due to the hepatic conditions. Therefore, the first-choice drug was pramipexole, a dopamine agonist. The second-choice drug was gabapentin, due to its beneficial properties and to the limited hepatic side effects. Neurological examinations and laboratory tests were performed at the beginning, after 2 wk, at the 28<sup>th</sup>, 75<sup>th</sup>, 105<sup>th</sup>, 135<sup>th</sup> and 165<sup>th</sup> day, and at the final day of the follow-up, the 205<sup>th</sup> day. Another aim of this study was to define the augmentation phenomenon in the liver patients.

### Research methods

The study included 267 adult patients with chronic liver disease, referred to

our Neurological Unit by the Liver Unit of the University of Trieste, for three complaints, including sleep disturbances, painful leg sensation, and daily sleepiness not correlated to hepatic encephalopathy. Patients with chronic liver disease included primary liver tumor and liver cirrhosis cases. We excluded 13 patients with chronic and persistent significant alcohol intake, 25 patients with recent worsening of clinical condition, and 12 patients with hepatitis C virus infection. All the other 211 patients were followed up by a neurologist for at least 24 mo. At baseline, patients were tested with the Hamilton rating scale for depression, sleep quality assessment (PSQI), Epworth sleepiness scale (ESS), International Restless Legs Syndrome Study Group (IRLSSG) evaluation, and international RLS severity (IRLS) scoring system. Alterations in titration, side effects, augmentation phenomenon and laboratory test findings were checked and reported. The first-choice drug was pramipexole, a dopamine agonist. If major side effects induced by the neurological therapy occurred, such as nausea, vomiting, somnolence, hypotension or optical illusions, the pramipexole was stopped. The second-choice drug was gabapentin, due to its beneficial properties and to the limited hepatic side effects. Another aim of this study was to define the augmentation phenomenon in the liver patients.

### Research results

Patients included in the study fulfilled the IRLSSG criteria for RLS; they were moderately depressed, with evident nocturnal sleep problems and a concomitant daily sleepiness. Of the 211 RLS patients, 22 considered their symptoms as mild, according to IRLS, but 189 found them moderate to very severe. A Spearman's rank correlation analysis showed the following: (1) a positive correlation between IRLSSG fulfillment criteria and poor nocturnal sleep quality (PSQI); (2) a positive correlation between IRLSSG fulfillment criteria and excessive diurnal sleepiness (ESS); (3) a positive correlation between IRLSSG fulfillment criteria and Hamilton's score; (4) a positive correlation between the four levels of IRLS and PSQI; and (5) no correlation between ammonium level and ESS or PSQI. At the beginning, all patients were prescribed pramipexole at an average dosage of 0.18 mg, to be taken in the evening for the first 2 week. Titration was standard; we duplicated the dosage for 2 more weeks, up to 0.36 mg, till the 75<sup>th</sup> day. At the 75<sup>th</sup> day, we prescribed 0.7 mg daily, which was then increased to 0.88 mg daily at the 105<sup>th</sup> day. Forty-one patients reported heavy side effects at the 135<sup>th</sup> day and decided to stop the pramipexole therapy. The remaining 170 patients were prescribed 1.4 mg daily, which seemed quite appropriate in respect of their average body mass index. At the 205<sup>th</sup> day, 110 patients (52%) continued to feel good with the 1.4 mg daily dosage; on the other hand, 60 patients (48%) reported the augmentation symptoms and were titrated at 0.7 mg daily. The 41 patients who abandoned pramipexole, after 2 wash-out weeks, were administered gabapentin, at increasing dosages. Considering the 170 patients who completed the 205 d of follow-up with pramipexole, the results were rather satisfactory, with an evident and constant amelioration of depression, of sleep quality and of daily sleepiness, as far as Wilcoxon signed rank test within-group comparison (vs baseline) showed. At the final visit, their subjective feeling of the intensity of RLS disturbances was perceived as mild to moderate in 155 patients and severe in 15 of them. Nobody declared a very severe score. The 41 patients who abandoned pramipexole, due to side effects, were treated with gabapentin, reporting a slight worsening of nocturnal sleep quality and an increase of daily sleepiness. All the 41 patients who took gabapentin reported abdominal weight gain at the final visit. As far as the augmentation phenomenon was concerned, a logistic regression analysis to identify factors associated with the augmentation were performed with independent variables, including age, body mass index, IRLS alcohol abuse, iron-free levels, folate, vitamin B12 and D-OH25 levels, alanine and aspartate aminotransferase, treatment duration of pramipexole, and daily pramipexole doses. Univariate and multivariate logistic regression analyses were performed and the Wald test was used to assess the significance of each variable. Daily pramipexole dose, the duration of the treatment, previous alcohol abuse, iron-free levels as well as lower levels of B12, D-OH25 and folate were significantly associated with augmentation in univariate analysis. On the other hand, abuse of alcohol, dose of pramipexole and its duration, level of vitamin B12 and D-OH25 and of folate, in the multivariate regression analysis, seemed to be significantly associated with augmentation.

### Research conclusions

In this study, we found that patients with chronic liver disease, such as liver cirrhosis or primitive tumors, who were referred for sleep disorders might have

RLS as well. The presence of RLS was not associated with sex, and cause or severity of the liver disease was in line with what has been demonstrated by the few other studies. As previously reported, in our study, many causative factors induce RLS in hepatic chronic disease patients, such as low iron levels, high ferritin levels, and associated low folate and vitamin B12 levels. Our study confirms an effective and rapid benefit for the use of dopamine agonist (as is well-recognized and reported in the literature). On the other hand, RLS is a hyperdopaminergic condition with an apparent postsynaptic desensitization that overcompensates during the circadian low point of dopaminergic activity in the evening and night. This overcompensation leads to the RLS symptoms that in turn often lead to increasing postsynaptic desensitization and augmentation of the RLS. In fact, patients with RLS with mood and stress states may be at greater risk of developing compulsive behaviors while receiving standard dosage treatment of dopamine agonists (but also of other drugs, such as tramadol). Augmentation seems rather precocious in our patients (135<sup>th</sup> day), and more frequent (35%) than previously described by the most important study on the topic (8.3%-9.1%). The dosage of dopamine agonists reported in our study to be associated with augmentation appears to be in range with the literature. Previous intake of alcohol and lower levels of vitamins were related to the phenomenon in our study.

### Research perspectives

It appears evident that RLS remains a still confounding, not immediately recognized condition requiring rapid diagnosis and treatment. Despite the fact that RLS is a very common disorder, it is frequently undiagnosed in primary care, and therefore inadequate therapy may be prescribed. Additional neurophysiologic studies and more extended clinical trials are strenuously needed to explain some crucial pathologic mechanisms of the syndrome, in order to better employ common therapeutic agents and to find novel ones.

## ACKNOWLEDGMENTS

The authors thank all the patients participating in the study and all the staff members of the Neurology Clinic of the Centro Studi Fegato that contributed to its realization.

## REFERENCES

- Allen RP, Picchietti D, Hening WA, Trenkwalder C, Walters AS, Montplaisir J; Restless Legs Syndrome Diagnosis and Epidemiology workshop at the National Institutes of Health; International Restless Legs Syndrome Study Group. Restless legs syndrome: diagnostic criteria, special considerations, and epidemiology. A report from the restless legs syndrome diagnosis and epidemiology workshop at the National Institutes of Health. *Sleep Med* 2003; **4**: 101-119 [PMID: 14592341 DOI: 10.1016/S1389-9457(03)00010-8]
- Salas RE, Gamaldo CE, Allen RP. Update in restless legs syndrome. *Curr Opin Neurol* 2010; **23**: 401-406 [PMID: 20581683 DOI: 10.1097/WCO.0b013e32833bcd8]
- Ekbom K, Ulfberg J. Restless legs syndrome. *J Intern Med* 2009; **266**: 419-431 [PMID: 19817966 DOI: 10.1111/j.1365-2796.2009.02159.x]
- Hening WA, Allen RP, Washburn M, Lesage S, Earley CJ. Validation of the Hopkins telephone diagnostic interview for restless legs syndrome. *Sleep Med* 2008; **9**: 283-289 [PMID: 17644424 DOI: 10.1016/j.sleep.2007.04.021]
- Franco RA, Ashwathnarayan R, Deshpandee A, Knox J, Daniel J, Eastwood D, Franco J, Saecian K. The high prevalence of restless legs syndrome symptoms in liver disease in an academic-based hepatology practice. *J Clin Sleep Med* 2008; **4**: 45-49 [PMID: 18350962]
- Matsuzaki T, Ichikawa T, Kondo H, Taura N, Miyaaki H, Isomoto H, Takeshima F, Nakao K. Prevalence of restless legs syndrome in Japanese patients with chronic liver disease. *Hepatol Res* 2012; **42**: 1221-1226 [PMID: 22672613 DOI: 10.1111/j.1872-034X.2012.01043.x]
- Goel A, Jat SL, Sasi A, Paliwal VK, Aggarwal R. Prevalence, severity, and impact on quality of life of restless leg syndrome in patients with liver cirrhosis in India. *Indian J Gastroenterol* 2016; **35**: 216-221 [PMID: 27225798 DOI: 10.1007/s12664-016-0668-6]
- García-Álvarez M, Pineda-Tenor D, Jiménez-Sousa MA, Fernández-Rodríguez A, Guzmán-Fulgencio M, Resino S. Relationship of vitamin D status with advanced liver fibrosis and response to hepatitis C virus therapy: a meta-analysis. *Hepatology* 2014; **60**: 1541-1550 [PMID: 24975775 DOI: 10.1002/hep.27281]
- Hamilton M. A rating scale for depression. *J Neurol Neurosurg Psychiatry* 1960; **23**: 56-62 [PMID: 14399272 DOI: 10.1136/jnnp.23.1.56]
- Buyse DJ, Reynolds CF 3rd, Monk TH, Berman SR, Kupfer DJ. The Pittsburgh Sleep Quality Index: a new instrument for psychiatric practice and research. *Psychiatry Res* 1989; **28**: 193-213 [PMID: 2748771]
- Johns MW. A new method for measuring daytime sleepiness: the Epworth sleepiness scale. *Sleep* 1991; **14**: 540-545 [PMID: 1798888 DOI: 10.1016/j.sleep.2007.08.004]
- Allen RP, Picchietti DL, García-Borreguero D, Ondo WG, Walters AS, Winkelman JW, Zucconi M, Ferri R, Trenkwalder C, Lee HB; International Restless Legs Syndrome Study Group. Restless legs syndrome/Willis-Ekbom disease diagnostic criteria: updated International Restless Legs Syndrome Study Group (IRLSSG) consensus criteria--history, rationale, description, and significance. *Sleep Med* 2014; **15**: 860-873 [PMID: 25023924 DOI: 10.1016/j.sleep.2014.03.025]
- Walters AS, LeBrocq C, Dhar A, Hening W, Rosen R, Allen RP, Trenkwalder C; International Restless Legs Syndrome Study Group. Validation of the International Restless Legs Syndrome Study Group rating scale for restless legs syndrome. *Sleep Med* 2003; **4**: 121-132 [PMID: 14592342 DOI: 10.1016/S1389-9457(02)00258-7]
- García-Borreguero D, Kohnen R, Silber MH, Winkelman JW, Earley CJ, Högl B, Manconi M, Montplaisir J, Inoue Y, Allen RP. The long-term treatment of restless legs syndrome/Willis-Ekbom disease: evidence-based guidelines and clinical consensus best practice guidance: a report from the International Restless Legs Syndrome Study Group. *Sleep Med* 2013; **14**: 675-684 [PMID: 23859128 DOI: 10.1016/j.sleep.2013.05.016]
- Micozkadioglu H, Ozdemir FN, Kut A, Sezer S, Saatci U, Haberal M. Gabapentin versus levodopa for the treatment of Restless Legs Syndrome in hemodialysis patients: an open-label study. *Ren Fail* 2004; **26**: 393-397 [PMID: 15462107 DOI: 10.1081/JDI-120039823]
- García-Borreguero D, Larrosa O, de la Llave Y, Verger K, Masramon X, Hernandez G. Treatment of restless legs syndrome with gabapentin: a double-blind, cross-over study. *Neurology* 2002; **59**: 1573-1579 [PMID: 12451200 DOI: 10.1212/WNL.59.10.1573]
- Stewart BH, Kugler AR, Thompson PR, Bockbrader HN. A saturable transport mechanism in the intestinal absorption of gabapentin is the underlying cause of the lack of proportionality between increasing dose and drug levels in plasma. *Pharm Res* 1993; **10**: 276-281 [PMID: 8456077 DOI: 10.1023/A:1018951214146]
- Cundy KC, Branch R, Chernov-Rogan T, Dias T, Estrada T, Hold K, Koller K, Liu X, Mann A, Panuwat M, Raillard SP, Upadhyay S, Wu QQ, Xiang JN, Yan H, Zerangue N, Zhou CX, Barrett RW, Gallop MA. XP13512 [(+/-)-1-((alpha-isobutanoyloxyethoxy)carbonyl)aminomethyl]-1-cyclohexane acetic acid], a novel gabapentin prodrug. I. Design, synthesis, enzymatic conversion to gabapentin, and transport by intestinal solute transporters. *J Pharmacol Exp Ther* 2004; **311**: 315-323 [PMID: 15146028 DOI: 10.1124/jpet.104.067934]
- García-Borreguero D, Allen RP, Kohnen R, Högl B, Trenkwalder C, Oertel W, Hening WA, Paulus W, Rye D, Walters A, Winkelman J, Earley CJ; International Restless Legs Syndrome Study Group. Diagnostic standards for dopaminergic augmentation of restless legs syndrome: report from a World Association of Sleep Medicine-International Restless Legs Syndrome Study Group consensus conference at the Max Planck Institute. *Sleep Med* 2007; **8**: 520-530 [PMID: 17544323 DOI: 10.1016/j.smrv.2007.05.004]

- 10.1016/j.sleep.2007.03.022]
- 20 **Ferini-Strambi L.** Restless legs syndrome augmentation and pramipexole treatment. *Sleep Med* 2002; **3** Suppl: S23-S25 [PMID: 14592163 DOI: 10.1016/S1389-9457(02)00144-2]
  - 21 **Lipford MC,** Silber MH. Long-term use of pramipexole in the management of restless legs syndrome. *Sleep Med* 2012; **13**: 1280-1285 [PMID: 23036265 DOI: 10.1016/j.sleep.2012.08.004]
  - 22 **Takahashi M,** Nishida S, Nakamura M, Kobayashi M, Matsui K, Ito E, Usui A, Inoue Y. Restless legs syndrome augmentation among Japanese patients receiving pramipexole therapy: Rate and risk factors in a retrospective study. *PLoS One* 2017; **12**: e0173535 [PMID: 28264052 DOI: 10.1371/journal.pone.0173535]
  - 23 **Earley CJ,** Allen RP. Restless legs syndrome augmentation associated with tramadol. *Sleep Med* 2006; **7**: 592-593 [PMID: 16926116 DOI: 10.1016/j.sleep.2006.05.011]
  - 24 **Grote L,** Leissner L, Hedner J, Ulfberg J. A randomized, double-blind, placebo controlled, multi-center study of intravenous iron sucrose and placebo in the treatment of restless legs syndrome. *Mov Disord* 2009; **24**: 1445-1452 [PMID: 19489063 DOI: 10.1002/mds.22562]
  - 25 **Earley CJ,** Heckler D, Allen RP. The treatment of restless legs syndrome with intravenous iron dextran. *Sleep Med* 2004; **5**: 231-235 [PMID: 15165528 DOI: 10.1016/j.sleep.2004.03.002]
  - 26 **Connor JR,** Wang XS, Allen RP, Beard JL, Wiesinger JA, Felt BT, Earley CJ. Altered dopaminergic profile in the putamen and substantia nigra in restless leg syndrome. *Brain* 2009; **132**: 2403-2412 [PMID: 19467991 DOI: 10.1093/brain/awp125]
  - 27 **Erikson KM,** Jones BC, Hess EJ, Zhang Q, Beard JL. Iron deficiency decreases dopamine D1 and D2 receptors in rat brain. *Pharmacol Biochem Behav* 2001; **69**: 409-418 [PMID: 11509198]
  - 28 **Erikson KM,** Jones BC, Beard JL. Iron deficiency alters dopamine transporter functioning in rat striatum. *J Nutr* 2000; **130**: 2831-2837 [PMID: 11053528]
  - 29 **Bianco LE,** Unger EL, Earley CJ, Beard JL. Iron deficiency alters the day-night variation in monoamine levels in mice. *Chronobiol Int* 2009; **26**: 447-463 [PMID: 19360489 DOI: 10.1080/07420520902820905]
  - 30 **Allen RP,** Connor JR, Hyland K, Earley CJ. Abnormally increased CSF 3-Ortho-methyldopa (3-OMD) in untreated restless legs syndrome (RLS) patients indicates more severe disease and possibly abnormally increased dopamine synthesis. *Sleep Med* 2009; **10**: 123-128 [PMID: 18226951 DOI: 10.1016/j.sleep.2007.11.012]
  - 31 **Earley CJ,** Hyland K, Allen RP. CSF dopamine, serotonin, and bipterin metabolites in patients with restless legs syndrome. *Mov Disord* 2001; **16**: 144-149 [PMID: 11215576 DOI: 10.1002/1531-8257(200101)16:13.0.CO;2-F]
  - 32 **Salas RE,** Allen RP, Earley CJ, Gamaldo CE. Drug hoarding: a case of atypical dopamine dysregulation syndrome in a RLS patient. *Mov Disord* 2009; **24**: 627-628 [PMID: 19133660 DOI: 10.1002/mds.22443]
  - 33 **Aurora RN,** Kristo DA, Bista SR, Rowley JA, Zak RS, Casey KR, Lamm CI, Tracy SL, Rosenberg RS; American Academy of Sleep Medicine. The treatment of restless legs syndrome and periodic limb movement disorder in adults--an update for 2012: practice parameters with an evidence-based systematic review and meta-analyses: an American Academy of Sleep Medicine Clinical Practice Guideline. *Sleep* 2012; **35**: 1039-1062 [PMID: 22851801 DOI: 10.5665/sleep.1988]
  - 34 **Allen RP,** Earley CJ. Augmentation of the restless legs syndrome with carbidopa/levodopa. *Sleep* 1996; **19**: 205-213 [PMID: 8723377 DOI: 10.1093/sleep/19.3.205]
  - 35 **Ondo WG,** Lai D. Predictors of impulsivity and reward seeking behavior with dopamine agonists. *Parkinsonism Relat Disord* 2008; **14**: 28-32 [PMID: 17702628 DOI: 10.1016/j.parkreldis.2007.05.006]
  - 36 **Pourcher E,** Rémillard S, Cohen H. Compulsive habits in restless legs syndrome patients under dopaminergic treatment. *J Neurol Sci* 2010; **290**: 52-56 [PMID: 19969309 DOI: 10.1016/j.jns.2009.11.010]

**P- Reviewer:** Chawla S, Dourakis SP, Farshadpour F

**S- Editor:** Cui LJ **L- Editor:** Filipodia **E- Editor:** Wang CH



## *Clostridium paraputrificum* septicemia and liver abscess

Yong K Kwon, Faiqa A Cheema, Bejon T Maneckshana, Caroline Rochon, Patricia A Sheiner

Yong K Kwon, Faiqa A Cheema, Bejon T Maneckshana, Caroline Rochon, Patricia A Sheiner, Department of Transplant, Hartford Hospital, Hartford, CT 06106, United States

Published online: March 27, 2018

ORCID number: Yong K Kwon (0000-0002-6026-5532); Faiqa A Cheema (0000-0002-8837-0916); Bejon T Maneckshana (0000-0002-5583-557X); Caroline Rochon (0000-0002-8338-3216); Patricia A Sheiner (0000-0002-5562-6698).

**Author contributions:** Kwon YK and Cheema FA wrote the initial manuscript; Maneckshana BT, Rochon C and Sheiner PA performed a literature search and analyzed the data; all authors contributed equally to editing and revising the final manuscript.

**Informed consent statement:** Written informed consent and permission to write this manuscript was obtained from the patient of this case report.

**Conflict-of-interest statement:** The authors certify that we have no conflict of interest to disclose and did not receive any financial support for this study.

**Open-Access:** This article is an open-access article which was selected by an in-house editor and fully peer-reviewed by external reviewers. It is distributed in accordance with the Creative Commons Attribution Non Commercial (CC BY-NC 4.0) license, which permits others to distribute, remix, adapt, build upon this work non-commercially, and license their derivative works on different terms, provided the original work is properly cited and the use is non-commercial. See: <http://creativecommons.org/licenses/by-nc/4.0/>

**Manuscript source:** Unsolicited manuscript

**Correspondence to:** Yong K Kwon, MD, Assistant Professor of Surgery, Department of Transplant, Hartford Hospital, 85 Seymour Street, Suite 320, Hartford, CT 06106, United States. [yong.kwon@hhchealth.org](mailto:yong.kwon@hhchealth.org)  
Telephone: +1-860-6962030  
Fax: +1-860-5491476

Received: December 19, 2017

Peer-review started: December 20, 2017

First decision: January 23, 2018

Revised: January 30, 2018

Accepted: March 1, 2018

Article in press: March 1, 2018

### Abstract

We report the first case of a healthy 23-year-old female who underwent an interventional radiology-guided embolization of a hepatic adenoma, which resulted in a gas forming hepatic liver abscess and septicemia by *Clostridium paraputrificum*. A retrospective review of Clostridial liver abscesses was performed using a PubMed literature search, and we found 57 clostridial hepatic abscess cases. The two most commonly reported clostridial species are *C. perfringens* and *C. septicum* (64.9% and 17.5% respectively). *C. perfringens* cases carried a mortality of 67.6% with median survival of 11 h, and 70.2% of the *C. perfringens* cases experienced hemolysis. All *C. septicum* cases were found to have underlying liver malignancy at the time of the presentation with a mortality of only 30%. The remaining cases were caused by various *Clostridium* species, and this cohort's clinical course was significantly milder when compared to the above *C. perfringens* and *C. septicum* cohorts.

**Key words:** *Clostridium*; Hemolysis; Liver cell adenoma; Morbidity; Mortality; Pyogenic liver abscess

© The Author(s) 2018. Published by Baishideng Publishing Group Inc. All rights reserved.

**Core tip:** To our best knowledge, this is the first case where a liver abscess grew *C. paraputrificum*. Although pyogenic liver abscesses caused by *Clostridium* species are extremely rare, early and accurate diagnosis of clostridial hepatic abscess and timely interventions are paramount, as it carries an extremely high morbidity and mortality. However, depending on the exact causative *Clostridium* species, the clinical course can vary unexpectedly.

Kwon YK, Cheema FA, Maneckshana BT, Rochon C, Sheiner

PA. *Clostridium paraputrificum* septicemia and liver abscess. *World J Hepatol* 2018; 10(3): 388-395 Available from: URL: <http://www.wjgnet.com/1948-5182/full/v10/i3/388.htm> DOI: <http://dx.doi.org/10.4254/wjgh.v10.i3.388>

## INTRODUCTION

Pyogenic liver abscesses caused by *Clostridium* species are extremely rare<sup>[1]</sup>, and only 57 cases have been reported in the English medical literature (Table 1). *C. perfringens* was responsible for more than a half of these reported cases. This species carries an extremely high mortality rate, especially when associated with hemolysis<sup>[2-4]</sup>. The previously reported 20 *C. perfringens* cases showed a median age of 65 years at the time of presentation<sup>[5]</sup>. Advanced age, underlying malignancy, liver cirrhosis, and immunocompromised conditions including dialysis, transplant and diabetes mellitus were identified as risk factors<sup>[2,5-8]</sup>. Here we present a very unusual case of a healthy 23-year-old female who underwent interventional radiology (IR) embolization for a hepatic adenoma and presented within 24 h with a gas forming hepatic liver abscess and septicemia. Due to the extremely rapid clinical presentation where the embolized tumor was completely replaced by a gas forming abscess within a day, *C. perfringens* was suspected as the causative organism. Unlike many other fatal *C. perfringens* hepatic abscess cases, our patient did not have any signs of hemolysis nor experienced any end-organ failure. Future speciation work-up revealed *C. paraputrificum*. There have been five case reports of septicemia caused by *C. paraputrificum*<sup>[9-13]</sup>. However, this is the first case of a gas forming hepatic abscess.

## CASE REPORT

A 23-year-old healthy female with obesity (body mass index of 37 kg/m<sup>2</sup>) and Polycystic Ovarian Syndrome on oral contraceptive pills was evaluated for intermittent, right upper quadrant abdominal pain. She was found to have a hepatic adenoma measuring 5.2 cm × 3.3 cm × 6.6 cm abutting the liver capsule in segment 7 (Figure 1) on imaging. The patient's oral contraceptive pill was discontinued for the more than three months, since the adenoma was diagnosed. A repeat computerized tomography (CT) scan did not show regression of the mass (Figure 2). Due to ongoing intractable abdominal right upper quadrant pain and risk of potential rupture, a surgical resection was presented as an option vs IR-guided embolization as an alternative option given her body habitus and fatty liver on magnetic resonance imaging study. The patient elected to proceed with IR embolization.

Angiogram showed conventional hepatic artery anatomy, and the adenoma was exclusively fed by a

single branch coming off of the posterior right hepatic artery (Figure 3). The tumor was completely embolized with 100-300 µm trisacryl gelatin microspheres (Embosphere®, Merit Medical Systems, Inc., South Jordan, United States). The patient was discharged home the same day.

The next day, the patient began to experience a rapid onset of right upper abdominal pain, nausea, vomiting and fever of 101.5 °F. In the emergency room, the patient was tachycardic with a heart rate in the 120 s. She experienced right upper abdominal tenderness on physical exam. Blood tests showed a white blood cell (WBC) count of 16.4 Thou/µL, a lactic acid of 2.4 nmol/L, a serum aspartate transaminase (AST) of 671 U/L, a serum alanine transaminase (ALT) of 310 U/L, and a total bilirubin (T. bili) of 1.4 mg/dL. A CT scan showed the embolized tumor in segment 7 completely replaced with multiple gas pockets (Figure 4). A set of blood cultures was sent, and the patient was started on vancomycin, levofloxacin and metronidazole (patient has a penicillin allergy). The next day, the set of blood cultures grew gram positive rods. The patient's serum WBC was elevated to 25 Thou/µL. Later that day, the preliminary blood culture revealed *clostridium* species. With ongoing fever and the newly diagnosed *clostridium* species infection, a repeat CT scan was performed to rule out potential life threatening gas gangrene. The repeat CT scan showed no changes.

The patient remained persistently febrile, despite antibiotic therapy and subsequent blood cultures showing no growth. The culture speciation showed *Clostridium paraputrificum* and no other organisms were isolated. Despite improving leukocytosis, an IR-guided drain was placed on hospital day 10 due to the persistent fevers. One hundred and twenty cc of dark turbid sterile fluid was aspirated, and the gram stain showed many neutrophils. No bacteria were isolated. Aspirin was started because the patient's platelet count rose above 500 Thou/µL. Over the next a few days since the drain placement, the fluid character became less turbid. However, the color became frankly bilious. The daily drain output persistently remained less than 200 cc, indicating a low output bile leak. Thus an ERCP was not performed. On Hospital day 16, the patient was afebrile for the first time. The patient was discharged home on hospital day 17 since the patient was afebrile for 48 hours. At the time of discharge, the drain output was less than 100 cc per day and the patient was discharged on oral metronidazole only.

The patient presented two weeks after discharge with a follow-up CT, which revealed a significantly reduced gas filled abscess cavity (Figure 5). The IR drain was taken out as the daily output remained minimum, less than 5 cc per day. Oral metronidazole was continued for two more weeks post drain removal. Upon completion of the antibiotic course, blood tests showed a WBC of 9.5 Thou/µL, a platelet count of 379 Thou/µL, an AST of 27 U/L, an ALT of 30 U/L, and a T. bili of 0.6 mg/dL.

**Table 1** Fifty-seven reported clostridial hepatic abscess cases in the English medical literature

Case	Author	Year	Age	Sex	Species	Underlying disease	HML	SSE	TTD	PLM	PMI
1	Fiese <sup>[35]</sup>	1950	67	M	<i>C. perfringens</i>	Cholecystitis	No	Yes	-	No	Yes
2	Kivel et al <sup>[36]</sup>	1958	68	F	<i>C. perfringens</i>	DM	Yes	No	5 d	No	No
3	Kahn et al <sup>[37]</sup>	1972	44	F	<i>C. septicum</i>	Colon cancer	No	Yes	-	Yes	Yes
4	D'Orsi et al <sup>[38]</sup>	1979	52	F	<i>C. septicum</i>	Colon cancer	No	Yes	-	Yes	No
5	D'Orsi et al <sup>[38]</sup>	1979	51	F	<i>C. ramosum</i>	Melanoma	Yes	No	2 d	Yes	No
6	D'Orsi et al <sup>[38]</sup>	1979	29	M	<i>C. ramosum</i> , <i>C. sporogenes</i>	Peri-ampullaryCa	No	Yes	-	Yes	Yes
7	Mera et al <sup>[39]</sup>	1984	6	F	<i>C. perfringens</i>	Fanconi's anemia	Yes	No	14 h	No	No
8	Nachman et al <sup>[40]</sup>	1989	6	M	<i>C. bifermentans</i>	Blunt trauma	No	Yes	-	No	No
9	Yood et al <sup>[41]</sup>	1989	64	F	<i>C. perfringens</i>	Systemic vasculitis	No	Yes	-	No	No
10	Batge et al <sup>[42]</sup>	1992	61	M	<i>C. perfringens</i>	Pancreatic cancer, DM	Yes	Yes	-	No	No
11	Rogstad et al <sup>[43]</sup>	1993	61	M	<i>C. perfringens</i>	None	Yes	No	3 h	No	No
12	Thel et al <sup>[32]</sup>	1994	39	F	<i>C. septicum</i>	Breast Ca, Bone M. txp	No	Yes	-	Yes	No
13	Gutierrez et al <sup>[44]</sup>	1995	74	M	<i>C. perfringens</i>	None	Yes	No	6 h	No	No
14	Jones et al <sup>[45]</sup>	1996	66	F	<i>C. perfringens</i>	OLT, DM	Yes	No	10 h	No	No
15	Lee et al <sup>[34]</sup>	1999	33	F	<i>C. septicum</i>	Uterine cancer	No	Yes	-	Yes	No
16	Eckel et al <sup>[46]</sup>	2000	65	F	<i>C. perfringens</i>	Cholangiocarcinoma	Yes	Yes	-	Yes	Yes
17	Urban et al <sup>[47]</sup>	2000	68	M	<i>C. septicum</i>	Colon cancer	No	Yes	-	Yes	No
18	Sakurai et al <sup>[48]</sup>	2001	75	F	<i>C. difficile</i>	Hepatic cyst	No	Yes	-	Yes	No
19	Kreidl et al <sup>[8]</sup>	2002	80	M	<i>C. perfringens</i>	DM, dialysis	Yes	No	11 h	No	No
20	Sarmiento et al <sup>[49]</sup>	2002	57	M	<i>C. septicum</i>	Colon cancer	No	Yes	-	Yes	No
21	Hsieh et al <sup>[50]</sup>	2003	23	M	Unusual <i>C. spp.</i>	Blunt trauma	No	Yes	-	No	No
22	Quigley et al <sup>[51]</sup>	2003	73	M	<i>C. perfringens</i>	Hepatic cyst	-	No	0 h	Yes	Yes
23	Elsayed et al <sup>[52]</sup>	2004	27	M	<i>C. hathewayi</i>	Cholecystitis	No	Yes	-	No	No
24	Fondran et al <sup>[53]</sup>	2005	63	M	<i>C. perfringens</i>	Pancreatic cancer	No	Yes	-	Yes	Yes
25	Au et al <sup>[7]</sup>	2005	65	M	<i>C. perfringens</i>	DM, dialysis	Yes	No	3 h	No	No
26	Kurtz et al <sup>[54]</sup>	2005	50	F	<i>C. septicum</i>	Colon cancer	No	Yes	-	Yes	No
27	Ohtani et al <sup>[55]</sup>	2006	78	M	<i>C. perfringens</i>	DM	Yes	No	3 h	No	No
28	Daly et al <sup>[56]</sup>	2006	80	M	<i>C. perfringens</i>	DM	Yes	No	3 h	No	No
29	Loran et al <sup>[57]</sup>	2006	69	F	<i>C. perfringens</i>	None	Yes	No	6 h	No	No
30	Chiang et al <sup>[58]</sup>	2007	46	F	<i>C. perfringens</i>	Cholecystitis	No	No	7 d	No	No
31	Abdel-Haq et al <sup>[59]</sup>	2007	11	M	<i>C. novyi type B</i>	Blunt trauma	No	Yes	-	No	No
32	Umgelter et al <sup>[60]</sup>	2007	87	F	<i>C. perfringens</i>	Colon cancer	No	Yes	-	Yes	No
33	Tabarelli et al <sup>[61]</sup>	2009	65	F	<i>C. perfringens</i>	Pancr. Ca s/p whipple	No	No	27 d	No	Yes
34	Merino et al <sup>[62]</sup>	2009	83	F	<i>C. perfringens</i>	None	Yes	No	3 d	No	No
35	Saleh et al <sup>[63]</sup>	2009	53	M	<i>C. septicum</i>	Colon cancer	No	Yes	-	Yes	No
36	Meyns et al <sup>[64]</sup>	2009	64	M	<i>C. perfringens</i>	DM	Yes	No	2 d	No	No
37	Ng et al <sup>[4]</sup>	2010	61	F	<i>C. perfringens</i>	DM	Yes	Yes	-	No	Yes
38	Rajendran et al <sup>[65]</sup>	2010	58	M	<i>C. perfringens</i>	None	Yes	Yes	-	No	No
39	Bradly et al <sup>[66]</sup>	2010	52	M	<i>C. perfringens</i>	OLT	Yes	No	6 h	No	No
40	Ogah et al <sup>[67]</sup>	2012	6	F	<i>C. clostridioforme</i>	None	No	Yes	-	No	No
41	Qandeel et al <sup>[68]</sup>	2012	59	M	<i>C. perfringens</i>	DM, s/p elective chole	Yes	Yes	-	No	No
42	Kim et al <sup>[69]</sup>	2012	80	F	<i>C. perfringens</i>	Hilar cholangiocarcinoma	No	No	3 d	No	Yes
43	Huang et al <sup>[70]</sup>	2012	54	M	<i>C. baratii</i>	Cholecystitis	No	Yes	-	No	No
44	Sucandy et al <sup>[71]</sup>	2012	65	M	<i>C. septicum</i>	Colon cancer	No	No	2 d	Yes	No
45	Law et al <sup>[5]</sup>	2012	50	F	<i>C. perfringens</i>	Rectal cancer	Yes	No	7 d	Yes	No
46	Raghavendra et al <sup>[72]</sup>	2013	63	M	<i>C. septicum</i>	Colon cancer	No	Yes	-	Yes	No
47	Kitterer et al <sup>[73]</sup>	2014	71	M	<i>C. perfringens</i>	OLT, Gastroenteritis	Yes	No	13 h	No	No
48	Imai et al <sup>[74]</sup>	2014	76	M	<i>C. perfringens</i>	None	Yes	No	6.5 h	No	No
49	Kurasawa et al <sup>[2]</sup>	2014	65	M	<i>C. perfringens</i>	DM	Yes	No	6 h	No	No
50	Eltawansy et al <sup>[75]</sup>	2015	81	F	<i>C. perfringens</i>	DM, Gastroenteritis	No	No	N/A <sup>1</sup>	No	Yes
51	Li et al <sup>[76]</sup>	2015	71	M	<i>C. perfringens</i>	HCC, Hepatitis B	Yes	Yes	-	Yes	No
52	Rives et al <sup>[77]</sup>	2015	63	M	<i>C. perfringens</i>	Colon cancer	No	Yes	-	Yes	No
53	Lim et al <sup>[6]</sup>	2016	58	M	<i>C. perfringens</i>	None	Yes	No	7.5 h	No	No
54	Hashiba et al <sup>[78]</sup>	2016	82	M	<i>C. perfringens</i>	DM	Yes	No	2 h	No	No
55	Kyang et al <sup>[79]</sup>	2016	84	M	<i>C. perfringens</i>	Gastric adenoCA	No	Yes	-	Yes	Yes
56	Ulger et al <sup>[80]</sup>	2016	80	F	<i>C. difficile</i>	DM	No	No	18 d	No	No
57	García et al <sup>[81]</sup>	2016	65	M	<i>C. perfringens</i>	DM	Yes	Yes	-	No	Yes

<sup>1</sup>Exact time of TTD was not discussed, but terminal vent weaning was initiated and subsequently expired. HML: Hemolysis; SSE: Survival of septic episode; TTD: Time to death; PLM: Presence of liver mass; PMI: Polymicrobial infection.

## DISCUSSION

Pyogenic liver abscess (PLA) is an uncommon disease. Various incidences have been reported throughout the

world: 1.1 in Denmark<sup>[14]</sup>, 2.3 in Canada<sup>[15]</sup> and 17.6 per 100000 population in Taiwan<sup>[16]</sup>. In the United States, the incidence is 3.6 per 100000 population with a reported in-hospital mortality rate of 5.6%<sup>[17]</sup>.

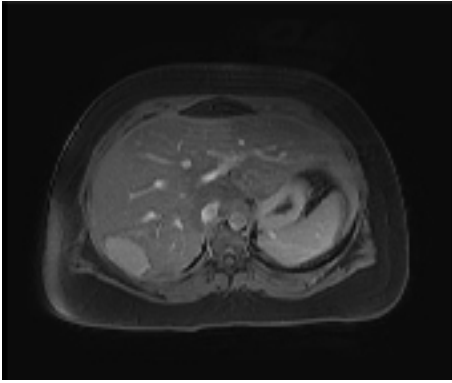


Figure 1 Magnetic resonance imaging of the segment 7 hepatic adenoma measuring 5.2 cm × 3.3 cm × 6.6 cm.

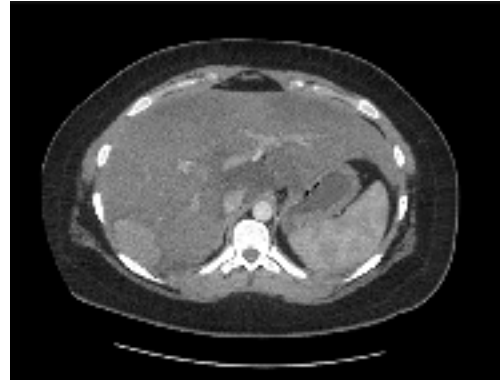


Figure 2 Computed tomography after stopping oral contraceptive pills for 3 mo. No change in size.

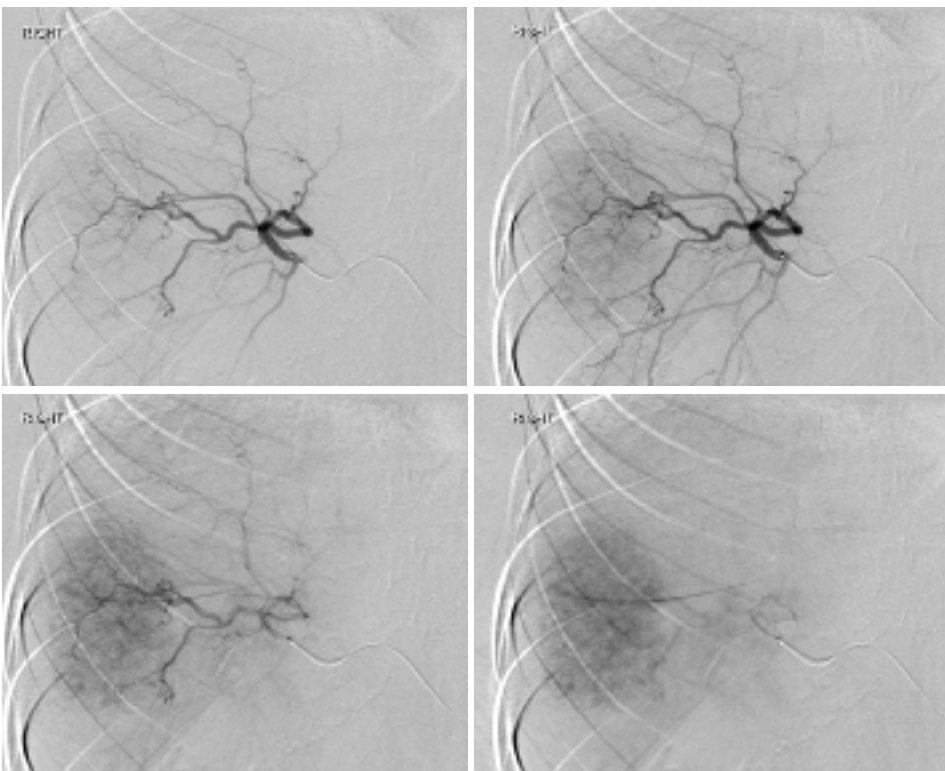


Figure 3 Interventional radiology angiogram of the hepatic adenoma.

The incidences of gas forming pyogenic liver abscess (GFPLA), also known as emphysematous liver abscess, are even rarer, contributing 6.6% to 32% of PLA<sup>[16,18-21]</sup>. It carries a significantly higher mortality rate, 27.7% to 37.1%<sup>[22-25]</sup>. For those who presented with GFPLA, their incidence of septic shock was higher (32.5% vs 11.7%) and they presented with a shorter duration of symptoms (5.2 d vs 7.6 d) when compared to those who presented with non-gas forming pyogenic liver abscess (NGFPLA)<sup>[22]</sup>.

The single strongest risk factor for GFPLA appears to be the presence of diabetes and poorly controlled blood glucose<sup>[15,18,22]</sup>. According to a case report series done in Taiwan which compared 83 patients with GFPLA against 341 NGFPLA patients, 85.5% of

those with GFPLA had diabetes mellitus with an initial glucose level of  $383.0 \pm 167.7$  (mg/dL) vs 33.1% with an initial glucose level of  $262.6 \pm 158.0$  (mg/dL)<sup>[22]</sup>. Similar findings were reported from another single center series from South Korea, where 76% (19 out of 25) were found to have diabetes when comparing 25 patients with GFPLA against 354 NGFPLA patients<sup>[18]</sup>. The most common causative organism for GFPLA was *Klebsiella pneumoniae* contributing 77% to 88%<sup>[18,22,25]</sup>. *Escherichia*, *Streptococcus*, *Enterococcus*, *Pseudomonas*, *Morganella*, *Enterobacter*, *Serratia*, *Bacteroides* and *Clostridium* species were responsible for the remaining<sup>[22]</sup>.

An extremely small portion of GFPLA is caused by clostridial species. The two most commonly reported

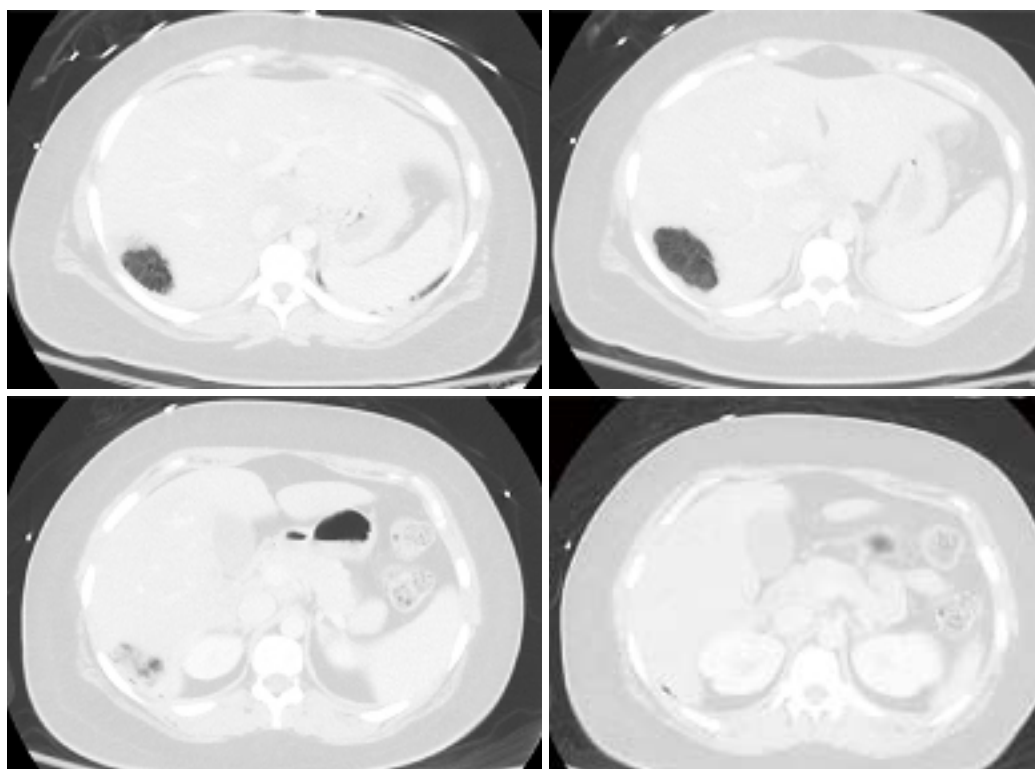


Figure 4 The tumor completely replaced by gas pockets.

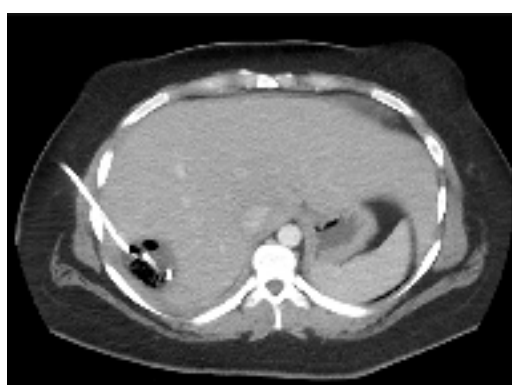

Figure 5 Follow-up computed tomography. The gas pocket reduced.

*clostridium* species are *C. perfringens* and *C. septicum*. We performed a PubMed literature search and identified 57 *clostridium* hepatic abscess cases reported in the English medical literature (Table 1). Our search showed that *C. perfringens* was responsible for 37 cases (64.9%) and *C. septicum* was responsible for 10 cases (17.5%). Nine cases were caused by *C. difficile*, *C. ramosum*, *C. sporogenes*, *C. baratii*, *C. bifermentans*, *C. clostridioforme*, *C. hathewayi*, and *C. novyi* type B. In one case, the exact speciation was not provided due to the institution's microbiology limitation for identifying rare clostridial species.

*C. perfringens* septicemia has been reported to carry a mortality rate ranging from 70%-100%<sup>[4]</sup>. Massive intravascular hemolysis is a well-known complication, occurring in 7%-15% of *C. perfringens* bacteremia

cases<sup>[26-28]</sup>. *C. perfringens*'s alpha-toxin has been shown to be the key virulent factor for this clinical course, by inducing gas gangrene and causing massive hemolysis by destroying red cell membrane integrity<sup>[3]</sup>. In our 37 cases of *C. perfringens* hepatic abscess, the mortality rate was 67.6% (25/37). 70.2% (26/37) experienced hemolysis (Table 1). Among the 25 patients who died, one patient died prior to arriving to the hospital. The mean time of survival for these 24 patients was 11 h. Among the 25 patients who died, only 4 patients (16%) were found to have poly-microbial infection, whereas among those who survived, 6 patients (50%) were found to have poly-microbial infection. The most common underlying disease was diabetes (11/37) followed by underlying malignancy (10/37). Interestingly, 7 patients were found to have no clear underlying medical disease.

Among the 10 cases of *C. septicum* species (Table 1), the patient survival was greater, 70% (7/10). Furthermore, no hemolysis was reported in contrast to the *C. perfringens* cases. Of note, *C. septicum* also produces alpha toxin, but it was shown to be unrelated to the alpha toxin of *C. perfringens*<sup>[29]</sup>. *C. septicum* infection has been well known to be associated with underlying occult malignancy<sup>[30-33]</sup>. It has been hypothesized that a rapidly growing tumor with anaerobic glycolysis provides a relatively hypoxic and acidic environment for germination of the clostridial spores<sup>[34]</sup>. In fact, all of the ten patients had infected liver tumors at the time of the presentation, and only one patient (10%) was found to have a poly-microbial infection.

The remaining 10 cases where the infection was

caused by various clostridial species, including the one with no provided speciation, appeared to have a milder clinical course when compared to the above *C. perfringens* and *C. septicum* cohorts (Table 1). The mortality rate was lower, only 20%, and median age at the time of presentation was significantly younger, 27 years. Interestingly, trauma was the underlying disease for the three cases.

Here, we report a young, healthy 23-year-old female who was diagnosed with a hepatic abscess caused by *Clostridium paraputrificum*. Due to the extremely rapid clinical presentation and from the initial imaging study where the mass was completely replaced with multiple gas pockets, a *C. perfringens* infection was highly suspected. Unlike many typical *C. perfringens* hepatic abscess cases, our patient did not experience hemolysis nor had any end organ failure requiring ICU care. In addition, our patient did not have the typical risk factors for *C. perfringens* nor *C. septicum* infections, except for having a tumor in the liver. At the end, the causative organism was identified as *Clostridium paraputrificum*, which has not been reported before in the literature. A *Clostridium* hepatic abscess is an extremely rare case and *C. perfringens* is the most common causative organism. Early accurate diagnosis and timely interventions are paramount, as it carries an extremely high mortality. However, depending on the exact causative clostridial species, the clinical course can vary significantly.

## ARTICLE HIGHLIGHTS

### Case characteristics

A healthy 23-year-old female developed a *Clostridium paraputrificum* gas forming liver abscess within 24 h after interventional radiology hepatic adenoma embolization.

### Clinical diagnosis

The patient's source of sepsis was unequivocally identified once an imaging study showed a gas forming liver abscess.

### Differential diagnosis

*Klebsiella pneumonia* was suspected to be the causative organism initially as it is known to contributing 77% to 88% of all gas forming pyogenic liver abscesses.

### Laboratory diagnosis

In addition to severe leukocytosis and lactic acidosis, elevated lactate dehydrogenase, decreased haptoglobin and elevated bilirubin, signs of massive hemolysis, can be also seen in certain patients.

### Imaging diagnosis

A gas forming liver abscess can be diagnosed with an abdominal X-ray or ultrasound, but typically a computed tomography scan is commonly used for the diagnosis.

### Pathological diagnosis

A needle aspiration of the hepatic abscess and/or blood culture often will yield the causative organism.

### Treatment

An early recognition and treatment with antibiotics is paramount as *Clostridium*

hepatic abscess infections are often extremely aggressive and lethal.

### Related reports

There have been five case reports of septicemia caused by *C. paraputrificum*, however, none of them caused hepatic abscess.

### Term explanation

Pyogenic liver abscess (PLA) is an uncommon disease. The incidences of gas forming pyogenic liver abscess (GFPLA) also known as emphysematous liver abscess, are even rarer, contributing 6.6% to 32% of PLA.

### Experiences and lessons

A *Clostridium* hepatic abscess requires early accurate diagnosis and timely interventions, as it carries an extremely high mortality. However, depending on the exact causative clostridial species, the clinical course can vary significantly.

## REFERENCES

- 1 Khan MS, Ishaq MK, Jones KR. Gas-Forming Pyogenic Liver Abscess with Septic Shock. *Case Rep Crit Care* 2015; **2015**: 632873 [PMID: 26090240 DOI: 10.1155/2015/632873]
- 2 Kurasawa M, Nishikido T, Koike J, Tominaga S, Tamemoto H. Gas-forming liver abscess associated with rapid hemolysis in a diabetic patient. *World J Diabetes* 2014; **5**: 224-229 [PMID: 24748935 DOI: 10.4239/wjd.v5.i2.224]
- 3 van Bunderen CC, Bomers MK, Wesdorp E, Peerbooms P, Veenstra J. *Clostridium perfringens* septicaemia with massive intravascular haemolysis: a case report and review of the literature. *Neth J Med* 2010; **68**: 343-346 [PMID: 20876913]
- 4 Ng H, Lam SM, Shum HP, Yan WW. *Clostridium perfringens* liver abscess with massive haemolysis. *Hong Kong Med J* 2010; **16**: 310-312 [PMID: 20683077]
- 5 Law ST, Lee MK. A middle-aged lady with a pyogenic liver abscess caused by *Clostridium perfringens*. *World J Hepatol* 2012; **4**: 252-255 [PMID: 22993668 DOI: 10.4254/wjh.v4.i8.252]
- 6 Lim AG, Rudd KE, Halliday M, Hess JR. Hepatic abscess-associated *Clostridium* bacteraemia presenting with intravascular haemolysis and severe hypertension. *BMJ Case Rep* 2016; **2016**: pii: bcr2015213253 [PMID: 26823354 DOI: 10.1136/bcr-2015-213253]
- 7 Au WY, Lau LS. Massive haemolysis because of *Clostridium perfringens* [corrected] liver abscess in a patient on peritoneal dialysis. *Br J Haematol* 2005; **131**: 2 [PMID: 16173955 DOI: 10.1111/j.1365-2141.2005.05634.x]
- 8 Kreidl KO, Green GR, Wren SM. Intravascular hemolysis from a *Clostridium perfringens* liver abscess. *J Am Coll Surg* 2002; **194**: 387 [PMID: 11893140 DOI: S1072-7515(01)01169-3]
- 9 Nerad JL, Pulvirenti JJ. *Clostridium paraputrificum* bacteremia in a patient with AIDS and Duodenal Kaposi's sarcoma. *Clin Infect Dis* 1996; **23**: 1183-1184 [PMID: 8922829]
- 10 Brook I. Clostridial Infections in Children: Spectrum and Management. *Curr Infect Dis Rep* 2015; **17**: 47 [PMID: 26431956 DOI: 10.1099/00222615-42-2-78]
- 11 Shandera WX, Humphrey RL, Stratton LB. Necrotizing enterocolitis associated with *Clostridium paraputrificum* septicemia. *South Med J* 1988; **81**: 283-284 [PMID: 3340884]
- 12 Nachamkin I, DeBlois GE, Dalton HP. *Clostridium paraputrificum* bacteremia associated with aspiration pneumonia. *South Med J* 1982; **75**: 1023-1024 [PMID: 7112187]
- 13 Babenco GO, Joffe N, Tischler AS, Kasdon E. Gas-forming clostridial mycotic aneurysm of the abdominal aorta. A case report. *Angiology* 1976; **27**: 602-609 [PMID: 1053471 DOI: 10.1177/000331977602701007]
- 14 Hansen PS, Schönheyder HC. Pyogenic hepatic abscess. A 10-year population-based retrospective study. *APMIS* 1998; **106**: 396-402 [PMID: 9548429]
- 15 Kaplan GG, Gregson DB, Laupland KB. Population-based study of the epidemiology of and the risk factors for pyogenic liver abscess. *Clin Gastroenterol Hepatol* 2004; **2**: 1032-1038 [PMID:

- 15551257 DOI: S1542356504004598]
- 16 Tsai FC, Huang YT, Chang LY, Wang JT. Pyogenic liver abscess as endemic disease, Taiwan. *Emerg Infect Dis* 2008; **14**: 1592-1600 [PMID: 18826824 DOI: 10.3201/eid1410.071254]
  - 17 Meddings L, Myers RP, Hubbard J, Shaheen AA, Laupland KB, Dixon E, Coffin C, Kaplan GG. A population-based study of pyogenic liver abscesses in the United States: incidence, mortality, and temporal trends. *Am J Gastroenterol* 2010; **105**: 117-124 [PMID: 19888200 DOI: 10.1038/ajg.2009.614]
  - 18 Lee CJ, Han SY, Lee SW, Baek YH, Choi SR, Roh MH, Lee JH, Jang JS, Han J, Cho SH, Choi SW. Clinical features of gas-forming liver abscesses: comparison between diabetic and nondiabetic patients. *Korean J Hepatol* 2010; **16**: 131-138 [PMID: 20606497 DOI: 10.3350/kjhep.2010.16.2.131]
  - 19 Pitt HA. Surgical management of hepatic abscesses. *World J Surg* 1990; **14**: 498-504 [PMID: 2200212]
  - 20 Halvorsen RA Jr, Foster WL Jr, Wilkinson RH Jr, Silverman PM, Thompson WM. Hepatic abscess: sensitivity of imaging tests and clinical findings. *Gastrointest Radiol* 1988; **13**: 135-141 [PMID: 3282964]
  - 21 Rubinson HA, Isikoff MB, Hill MC. Diagnostic imaging of hepatic abscesses: a retrospective analysis. *AJR Am J Roentgenol* 1980; **135**: 735-745 [PMID: 6778107 DOI: 10.2214/ajr.135.4.735]
  - 22 Chou FF, Sheen-Chen SM, Chen YS, Lee TY. The comparison of clinical course and results of treatment between gas-forming and non-gas-forming pyogenic liver abscess. *Arch Surg* 1995; **130**: 401-405; discussion 406 [PMID: 7710340]
  - 23 Lee TY, Wan YL, Tsai CC. Gas-containing liver abscess: radiological findings and clinical significance. *Abdom Imaging* 1994; **19**: 47-52 [PMID: 8161903]
  - 24 Yang CC, Chen CY, Lin XZ, Chang TT, Shin JS, Lin CY. Pyogenic liver abscess in Taiwan: emphasis on gas-forming liver abscess in diabetics. *Am J Gastroenterol* 1993; **88**: 1911-1915 [PMID: 8237941]
  - 25 Lee HL, Lee HC, Guo HR, Ko WC, Chen KW. Clinical significance and mechanism of gas formation of pyogenic liver abscess due to *Klebsiella pneumoniae*. *J Clin Microbiol* 2004; **42**: 2783-2785 [PMID: 15184470 DOI: 10.1128/JCM.42.6.2783-2785.2004]
  - 26 Caya JG, Truant AL. Clostridial bacteremia in the non-infant pediatric population: a report of two cases and review of the literature. *Pediatr Infect Dis J* 1999; **18**: 291-298 [PMID: 10093957]
  - 27 Rechner PM, Agger WA, Mruz K, Cogbill TH. Clinical features of clostridial bacteremia: a review from a rural area. *Clin Infect Dis* 2001; **33**: 349-353 [PMID: 11438901 DOI: 10.1086/321883]
  - 28 Bodey GP, Rodriguez S, Fainstein V, Elting LS. Clostridial bacteremia in cancer patients. A 12-year experience. *Cancer* 1991; **67**: 1928-1942 [PMID: 2004306]
  - 29 Ballard J, Bryant A, Stevens D, Tweten RK. Purification and characterization of the lethal toxin (alpha-toxin) of *Clostridium septicum*. *Infect Immun* 1992; **60**: 784-790 [PMID: 1541552]
  - 30 Kornbluth AA, Danzig JB, Bernstein LH. Clostridium septicum infection and associated malignancy. Report of 2 cases and review of the literature. *Medicine (Baltimore)* 1989; **68**: 30-37 [PMID: 2642585]
  - 31 Kolbeinson ME, Holder WD Jr, Aziz S. Recognition, management, and prevention of Clostridium septicum abscess in immunosuppressed patients. *Arch Surg* 1991; **126**: 642-645 [PMID: 2021349]
  - 32 Thel MC, Ciaccia D, Vredenburg JJ, Peters W, Corey GR. Clostridium septicum abscess in hepatic metastases: successful medical management. *Bone Marrow Transplant* 1994; **13**: 495-496 [PMID: 7517261]
  - 33 Kirchner JT. Clostridium septicum infection. Beware of associated cancer. *Postgrad Med* 1991; **90**: 157-160 [PMID: 1924004]
  - 34 Lee CH, Hsieh SY. Case report: Clostridium septicum infection presenting as liver abscess in a case of choriocarcinoma with liver metastasis. *J Gastroenterol Hepatol* 1999; **14**: 1227-1229 [PMID: 10634163]
  - 35 Fiese MJ. Tympany over the liver in hepatic abscess caused by *Clostridium welchii*. Report of a case. *Calif Med* 1950; **73**: 505-506 [PMID: 14792343]
  - 36 Kivel RM, Kessler A, Cameron DJ. Liver abscess due to *Clostridium perfringens*. *Ann Intern Med* 1958; **49**: 672-679 [PMID: 13571851]
  - 37 Kahn SP, Lindenauer SM, Wojtalik RS, Hildreth D. Clostridia hepatic abscess. An unusual manifestation of metastatic colon carcinoma. *Arch Surg* 1972; **104**: 209-212 [PMID: 5008917]
  - 38 D'Orsi CJ, Ensminger W, Smith EH, Lew M. Gas-forming intrahepatic abscess: a possible complication of arterial infusion chemotherapy. *Gastrointest Radiol* 1979; **4**: 157-161 [PMID: 456830]
  - 39 Mera CL, Freedman MH. Clostridium liver abscess and massive hemolysis. Unique demise in Fanconi's aplastic anemia. *Clin Pediatr (Phila)* 1984; **23**: 126-127 [PMID: 6319064 DOI: 10.1177/000992288402300215]
  - 40 Nachman S, Kaul A, Li KI, Slim MS, San Filippo JA, Van Horn K. Liver abscess caused by *Clostridium bifermentans* following blunt abdominal trauma. *J Clin Microbiol* 1989; **27**: 1137-1138 [PMID: 2745689]
  - 41 Case records of the Massachusetts General Hospital. Weekly clinicopathological exercises. Case 42-1989. A 64-year-old woman with a liver abscess, Clostridium perfringens sepsis, progressive sensorimotor neuropathy, and abnormal serum proteins. *N Engl J Med* 1989; **321**: 1103-1118 [PMID: 2571930 DOI: 10.1056/NEJM198910193211608]
  - 42 Bätge B, Filejski W, Kurowski V, Klüter H, Djonlagic H. Clostridial sepsis with massive intravascular hemolysis: rapid diagnosis and successful treatment. *Intensive Care Med* 1992; **18**: 488-490 [PMID: 1289375]
  - 43 Rogstad B, Ritland S, Lunde S, Hagen AG. Clostridium perfringens septicemia with massive hemolysis. *Infection* 1993; **21**: 54-56 [PMID: 8449584]
  - 44 Gutiérrez A, Florencio R, Ezpeleta C, Cisterna R, Martínez M. Fatal intravascular hemolysis in a patient with Clostridium perfringens septicemia. *Clin Infect Dis* 1995; **20**: 1064-1065 [PMID: 7795054]
  - 45 Jones TK, O'Sullivan DA, Smilack JD. 66-year-old woman with fever and hemolysis. *Mayo Clin Proc* 1996; **71**: 1007-1010 [PMID: 8820778]
  - 46 Eckel F, Lersch C, Huber W, Weiss W, Berger H, Schulte-Frohlinde E. Multimicrobial sepsis including Clostridium perfringens after chemoembolization of a single liver metastasis from common bile duct cancer. *Digestion* 2000; **62**: 208-212 [PMID: 11025370 DOI: 10.1159/000007815]
  - 47 Urban BA, McCormick R, Fishman EK, Lillemoe KD, Petty BG. Fulminant Clostridium septicum infection of hepatic metastases presenting as pneumoperitoneum. *AJR Am J Roentgenol* 2000; **174**: 962-964 [PMID: 10749230 DOI: 10.2214/ajr.174.4.1740962]
  - 48 Sakurai T, Hajiro K, Takakuwa H, Nishi A, Aihara M, Chiba T. Liver abscess caused by Clostridium difficile. *Scand J Infect Dis* 2001; **33**: 69-70 [PMID: 11234983]
  - 49 Sarmiento JM, Sarr MG. Necrotic infected liver metastasis from colon cancer. *Surgery* 2002; **132**: 110-111 [PMID: 12110807]
  - 50 Hsieh CH, Hsu YP. Early-onset liver abscess after blunt liver trauma: report of a case. *Surg Today* 2003; **33**: 392-394 [PMID: 12734739 DOI: 10.1007/s005950300089]
  - 51 Quigley M, Joglekar VM, Keating J, Jagath S. Fatal Clostridium perfringens infection of a liver cyst. *J Infect* 2003; **47**: 248-250 [PMID: 12963388]
  - 52 Elsayed S, Zhang K. Human infection caused by Clostridium hithewayi. *Emerg Infect Dis* 2004; **10**: 1950-1952 [PMID: 15550205 DOI: 10.3201/eid1011.040006]
  - 53 Fondran J, Williams GB. Liver metastasis presenting as pneumoperitoneum. *South Med J* 2005; **98**: 248-249 [PMID: 15759962 DOI: 10.1097/01.SMJ.0000153196.84534.9A]
  - 54 Kurtz JE, Claudel L, Collard O, Limacher JM, Bergerat JP, Dufour P. Liver abscess due to clostridium septicum. A case report and review of the literature. *Hepatogastroenterology* 2005; **52**:

- 1557-1558 [PMID: 16201118]
- 55 **Ohtani S**, Watanabe N, Kawata M, Harada K, Himei M, Murakami K. Massive intravascular hemolysis in a patient infected by a *Clostridium perfringens*. *Acta Med Okayama* 2006; **60**: 357-360 [PMID: 17189980 DOI: 10.18926/AMO/30725]
  - 56 **Daly JJ**, Haeusler MN, Hogan CJ, Wood EM. Massive intravascular haemolysis with T-activation and disseminated intravascular coagulation due to clostridial sepsis. *Br J Haematol* 2006; **134**: 553 [PMID: 16822287 DOI: 10.1111/j.1365-2141.2006.06177.x]
  - 57 **Loran MJ**, McErlean M, Wilner G. Massive hemolysis associated with *Clostridium perfringens* sepsis. *Am J Emerg Med* 2006; **24**: 881-883 [PMID: 17098117 DOI: 10.1016/j.ajem.2006.03.002]
  - 58 **Chiang KH**, Chou AS, Chang PY, Huang HW. Gas-containing liver abscess after transhepatic percutaneous cholecystostomy. *J Vasc Interv Radiol* 2007; **18**: 940-941 [PMID: 17609462 DOI: 10.1016/j.jvir.2007.04.021]
  - 59 **Abdel-Haq NM**, Chearskul P, Salimnia H, Asmar BI. Clostridial liver abscess following blunt abdominal trauma: case report and review of the literature. *Scand J Infect Dis* 2007; **39**: 734-737 [PMID: 17654354 DOI: 10.1080/00365540701199865]
  - 60 **Umgelter A**, Wagner K, Gaa J, Stock K, Huber W, Reindl W. Pneumobilia caused by a clostridial liver abscess: rapid diagnosis by bedside sonography in the intensive care unit. *J Ultrasound Med* 2007; **26**: 1267-1269 [PMID: 17715325]
  - 61 **Tabarelli W**, Bonatti H, Cejna M, Hartmann G, Stelzmueller I, Wenzl E. Clostridium perfringens liver abscess after pancreatic resection. *Surg Infect (Larchmt)* 2009; **10**: 159-162 [PMID: 19388837 DOI: 10.1089/sur.2008.014]
  - 62 **Merino A**, Pereira A, Castro P. Massive intravascular haemolysis during *Clostridium perfringens* sepsis of hepatic origin. *Eur J Haematol* 2010; **84**: 278-279 [PMID: 19682059 DOI: 10.1111/j.1600-0609.2009.01337.x]
  - 63 **Saleh N**, Sohail MR, Hashmey RH, Al Kaabi M. Clostridium septicum infection of hepatic metastases following alcohol injection: a case report. *Cases J* 2009; **2**: 9408 [PMID: 20072687 DOI: 10.1186/1757-1626-2-9408]
  - 64 **Meyns E**, Vermeersch N, Ilsen B, Hoste W, Delooz H, Hubloue I. Spontaneous intrahepatic gas gangrene and fatal septic shock. *Acta Chir Belg* 2009; **109**: 400-404 [PMID: 19943601]
  - 65 **Rajendran G**, Bothma P, Brodbeck A. Intravascular haemolysis and septicemia due to *Clostridium perfringens* liver abscess. *Anaesth Intensive Care* 2010; **38**: 942-945 [PMID: 20865884]
  - 66 **Bradly DP**, Collier M, Frankel J, Jakate S. Acute Necrotizing Cholangiohepatitis With *Clostridium perfringens*: A Rare Cause of Post-Transplantation Mortality. *Gastroenterol Hepatol (N Y)* 2010; **6**: 241-243 [PMID: 20567577]
  - 67 **Ogah K**, Sethi K, Karthik V. Clostridium clostridioforme liver abscess complicated by portal vein thrombosis in childhood. *J Med Microbiol* 2012; **61**: 297-299 [PMID: 21940652 DOI: 10.1099/jmm.0.031765-0]
  - 68 **Qandeel H**, Abudeeb H, Hammad A, Ray C, Sajid M, Mahmud S. Clostridium perfringens sepsis and liver abscess following laparoscopic cholecystectomy. *J Surg Case Rep* 2012; **2012**: 5 [PMID: 24960720 DOI: 10.1093/jscr/2012.1.5]
  - 69 **Kim JH**, Jung ES, Jeong SH, Kim JS, Ku YS, Hahm KB, Kim JH, Kim YS. A case of emphysematous hepatitis with spontaneous pneumoperitoneum in a patient with hilar cholangiocarcinoma. *Korean J Hepatol* 2012; **18**: 94-97 [PMID: 22511909 DOI: 10.3350/kjhep.2012.18.1.94]
  - 70 **Huang WC**, Lee WS, Chang T, Ou TY, Lam C. Emphysematous cholecystitis complicating liver abscess due to *Clostridium baratii* infection. *J Microbiol Immunol Infect* 2012; **45**: 390-392 [PMID: 22561510 DOI: 10.1016/j.jmii.2011.12.007]
  - 71 **Sucandy I**, Gallagher S, Josloff RK, Nussbaum ML. Severe clostridium infection of liver metastases presenting as pneumoperitoneum. *Am Surg* 2012; **78**: E338-E339 [PMID: 22748522]
  - 72 **Raghavendra GK**, Carr M, Dharmadhikari R. Colorectal cancer liver metastasis presenting as pneumoperitoneum: case report and literature review. *Indian J Surg* 2013; **75**: 266-268 [PMID: 24426586 DOI: 10.1007/s12262-012-0666-6]
  - 73 **Kitterer D**, Braun N, Jehs MC, Schulte B, Alscher MD, Latus J. Gas gangrene caused by clostridium perfringens involving the liver, spleen, and heart in a man 20 years after an orthotopic liver transplant: a case report. *Exp Clin Transplant* 2014; **12**: 165-168 [PMID: 23962047 DOI: 10.6002/ect.2013.0034]
  - 74 **Imai J**, Ichikawa H, Tobita K, Watanabe N. Liver abscess caused by *Clostridium perfringens*. *Intern Med* 2014; **53**: 917-918 [PMID: 24739619]
  - 75 **Eltawansy SA**, Merchant C, Atluri P, Dwivedi S. Multi-organ failure secondary to a *Clostridium perfringens* gaseous liver abscess following a self-limited episode of acute gastroenteritis. *Am J Case Rep* 2015; **16**: 182-186 [PMID: 25807198 DOI: 10.12659/AJCR.893046]
  - 76 **Li JH**, Yao RR, Shen HJ, Zhang L, Xie XY, Chen RX, Wang YH, Ren ZG. Clostridium perfringens infection after transarterial chemoembolization for large hepatocellular carcinoma. *World J Gastroenterol* 2015; **21**: 4397-4401 [PMID: 25892893 DOI: 10.3748/wjg.v21.i14.4397]
  - 77 **Rives C**, Chaudhari D, Swenson J, Reddy C, Young M. Clostridium perfringens liver abscess complicated by bacteremia. *Endoscopy* 2015; **47** Suppl 1 UCTN: E457 [PMID: 26465182 DOI: 10.1055/s-0034-1392867]
  - 78 **Hashiba M**, Tomino A, Takenaka N, Hattori T, Kano H, Tsuda M, Takeyama N. Clostridium Perfringens Infection in a Febrile Patient with Severe Hemolytic Anemia. *Am J Case Rep* 2016; **17**: 219-223 [PMID: 27049736]
  - 79 **Kyang LS**, Bin Traiki TA, Alzahrani NA, Morris DL. Microwave ablation of liver metastasis complicated by Clostridium perfringens gas-forming pyogenic liver abscess (GPLA) in a patient with past gastrectomy. *Int J Surg Case Rep* 2016; **27**: 32-35 [PMID: 27529833 DOI: 10.1016/j.ijscr.2016.08.009]
  - 80 **Ulger Toprak N**, Balkose G, Durak D, Dulundu E, Demirbaş T, Yegen C, Soyletir G. Clostridium difficile: A rare cause of pyogenic liver abscess. *Anaerobe* 2016; **42**: 108-110 [PMID: 27693543 DOI: 10.1016/j.anaerobe.2016.09.007]
  - 81 **García Carretero R**, Romero Brugera M, Vazquez-Gomez O, Rebollo-Aparicio N. Massive haemolysis, gas-forming liver abscess and sepsis due to *Clostridium perfringens* bacteraemia. *BMJ Case Rep* 2016; **2016**: pii: bcr2016218014 [PMID: 27888224 DOI: 10.1136/bcr-2016-218014]

P- Reviewer: Cerwenka H, Stanciu C S- Editor: Cui LJ

L- Editor: A E- Editor: Li D



## Liver failure caused by prolonged state of malnutrition following bariatric surgery

Willem J Lammers, Antonie JP van Tilburg, Jan A Apers, Janneke Wiebolt

Willem J Lammers, Department of Gastroenterology and Hepatology, Erasmus Medical Center, Rotterdam 3015 CE, the Netherlands

Antonie JP van Tilburg, Department of Gastroenterology and Hepatology, Franciscus Gasthuis and Vlietland, Rotterdam 3045 PM, the Netherlands

Jan A Apers, Department of Surgery, Franciscus Gasthuis and Vlietland, Rotterdam 3045 PM, the Netherlands

Janneke Wiebolt, Department of Internal Medicine, Franciscus Gasthuis and Vlietland, Rotterdam 3045 PM, the Netherlands

ORCID number: Willem J Lammers (0000-0002-5455-5242); Antonie JP van Tilburg (0000-0002-3701-2879); Jan A Apers (0000-0002-6348-9697); Janneke Wiebolt (0000-0001-7825-7461).

**Author contributions:** Lammers WJ contributed to drafting of the manuscript; all authors contributed to acquisition of data, interpretation of data and critical revision of the manuscript for important intellectual content.

**Informed consent statement:** Patients were not required to give informed consent to this study, because the case report was written after the patients received agreed to and necessary treatments. All patient data were handled as anonymous.

**Conflict-of-interest statement:** All authors certify that they have no affiliations with or involvements in any organization or entity with any financial interest or non-financial interest in the subject matter or materials discussed in this manuscript.

**Open-Access:** This article is an open-access article which was selected by an in-house editor and fully peer-reviewed by external reviewers. It is distributed in accordance with the Creative Commons Attribution Non Commercial (CC BY-NC 4.0) license, which permits others to distribute, remix, adapt, build upon this work non-commercially, and license their derivative works on different terms, provided the original work is properly cited and the use is non-commercial. See: <http://creativecommons.org/licenses/by-nc/4.0/>

Manuscript source: Unsolicited manuscript

Correspondence to: Willem J Lammers, MD, PhD, Academic Fellow, Department of Gastroenterology and Hepatology, Erasmus Medical Center, Rotterdam's-Gravendijkwal 230, Rotterdam 3015 CE, the Netherlands. [w.lammers@erasmusmc.nl](mailto:w.lammers@erasmusmc.nl)  
Telephone: +31-63-3343636  
Fax: +31-10-7035172

Received: December 12, 2017  
Peer-review started: December 13, 2017  
First decision: January 15, 2018  
Revised: January 22, 2018  
Accepted: February 7, 2018  
Article in press: February 7, 2018  
Published online: March 27, 2018

### Abstract

Bariatric surgery is an effective tool in the treatment of patients with morbid obesity. In these case reports we describe 2 patients who developed liver failure after currently-practiced types of bariatric surgery, caused by a prolonged state of malnutrition provoked by psychiatric problems. Despite intensive guidance of a psychologist and dieticians after surgery, our patients deteriorated psychologically, resulting in a prolonged state of severe malnutrition and anorexia. Finally, a state of starvation was reached, passing a critical level of the liver capacity. Patients who present with signs of severe protein malnutrition after bariatric surgery should be closely monitored and checked for nutritional status. Specific attention should be given to patients who develop psychiatric problems post-bariatric surgery. If refeeding does not result in clinical improvement, reversal surgery should be considered in a timely manner.

**Key words:** Protein deficiency; Hyperbilirubinemia; Hyperammonemia; Liver failure; Urea cycle

© The Author(s) 2018. Published by Baishideng Publishing

Group Inc. All rights reserved.

**Core tip:** Monitoring of patients after bariatric surgery is important. When psychiatric problems appear, you should be alert and treat your patients proactively. Unfortunately, these case reports show that psychiatric deterioration can lead to severe malnutrition and anorexia, although rarely resulting in liver insufficiency and failure.

Lammers WJ, van Tilburg AJP, Apers JA, Wiebolt J. Liver failure caused by prolonged state of malnutrition following bariatric surgery. *World J Hepatol* 2018; 10(3): 396-399 Available from: URL: <http://www.wjgnet.com/1948-5182/full/v10/i3/396.htm> DOI: <http://dx.doi.org/10.4254/wjh.v10.i3.396>

## INTRODUCTION

Morbid obesity is an increasing healthcare problem in the Western world, with development of important complications, such as diabetes, cardiovascular disease and fatty liver disease. Among morbidly obese individuals, nonalcoholic fatty liver disease is highly prevalent and a substantial number of patients may develop advanced liver fibrosis or cirrhosis over time<sup>[1,2]</sup>. Ultimately, these conditions will lead to liver failure and death.

Bariatric surgery provides an effective tool in the treatment of patients with morbid obesity and its comorbidity<sup>[3]</sup>. Short-term effects, such as significant weight loss and remission of diabetes, have been extensively documented<sup>[4]</sup>. Several clinical studies have shown that bariatric surgery has an important positive impact on the liver, with improvements of liver enzymes and liver histology<sup>[5,6]</sup>.

The development of liver failure after bariatric surgery has previously been described after jejunoileal bypass and biliopancreatic diversion (Scopinaro) surgery<sup>[7]</sup>, but is rare in modern bariatric surgery. A common idea is that nonuse of the bypassed intestine can lead to changes in the mucosa and bacterial flora. As a result of bacterial overgrowth hepatotoxic macromolecules are produced, passing the damaged mucosa and reaching the liver through the portal venous system and resulting in damage of hepatocytes.

In these case reports we describe 2 patients who developed liver failure after currently-practiced types of bariatric surgery, caused by a prolonged state of malnutrition provoked by psychiatric problems.

## CASE REPORT

### Case 1

A 43-year-old female underwent endoscopic gastric bypass surgery because of morbid obesity [body mass index (BMI) 59 kg/m<sup>2</sup>]. After 1 year, she underwent banded gastric bypass surgery because of insufficient

weight loss [BMI: 47 kg/m<sup>2</sup>, %excess weight loss (EWL): 34.9%, total body weight loss: 20%]. After surgery, she suffered from episodes of abdominal pain and dysphagia. Therefore, 1 year later the gastric band was removed with revision of the gastric bypass to a distal bypass (alimentary limb 735 cm, biliopancreatic limb 60 cm, common channel 100 cm). In the following period, additional weight loss was recorded (BMI: 32 kg/m<sup>2</sup>, %EWL: 79.4%, total body weight loss: 46%) with a relative good quality of life. Another year later, she became pregnant. Unfortunately, after 22 wk she gave birth prematurely, resulting in fetal death. In the following 6 mo, she was hospitalized four times with malnutrition, hypoalbuminemia (serum albumin 12 g/L), generalized edema and depression. During this period, she refused any involvement of psychiatrists.

At her final admission to the hospital, she had abstained from food for more than a week, with suspicion of anorexia. Common causes of hypoalbuminemia, such as protein-losing enteropathy and nephrotic syndrome were excluded. Enteral tube feeding was started with protein plus multi-fiber (protein: 95 g/L). However, on day 8 of admission, she developed a somnolent state caused by a hyperammonemic encephalopathy (serum ammonia: 224 µmol/L) and hypoglycemia, for which she was admitted to the intensive care unit (ICU). No urea cycle disorders were found. Liver test results are presented in Table 1. She was treated for hepatic encephalopathy with lactulose and rifaximin, and enteral feeding was changed to a low-protein diet. Additional imaging studies of the liver did not show parenchyma abnormalities or portal flow disturbance. Common causes of liver disease were excluded. No liver biopsy was performed due to coagulopathy. Unfortunately, she developed progressive liver failure in the following days, followed by aspiration pneumonia. Liver transplantation was deemed not feasible. On day 15, she died of multiorgan failure.

### Case 2

A 34-year-old female underwent gastric sleeve resection because of morbid obesity (BMI: 42 kg/m<sup>2</sup>), which was complicated by anastomotic leakage, abdominal sepsis and recurrent esophageal stenosis with stenting. Subsequently, after 5 mo, a gastric bypass (alimentary limb 150 cm, biliopancreatic limb 60 cm) was performed (BMI: 31 kg/m<sup>2</sup>, %EWL: 62.5%, total body weight loss: 25%). Unfortunately, she suffered from episodes of nausea and vomiting due to persistent gastrojejunal ulcerations distal of the esophageal stent. With regard to these complications, an esophageal-jejunostomy was performed 3 mo later. In the following 28 mo, she was admitted to the hospital 4 times for recurrent problems of malnutrition due to psychosocial problems and depression as a result of the aforementioned complications. During her hospitalization she refused psychiatric treatment.

Finally, she was hospitalized in the ICU in a malnourished (BMI 16 kg/m<sup>2</sup>, %EWL: 153%, total body weight

**Table 1** Results of liver test at presentation of hyperammonemic encephalopathy

	Case 1	Case 2	Normal values
Albumin	12	10	> 35 g/L
Total bilirubin	53	9	< 17 $\mu$ mol/L
Alkaline phosphatase	103	149	< 120 U/L
AST	25	43	< 31 U/L
ALT	21	54	< 31 U/L
$\gamma$ -GT	76	55	< 35 U/L
Antithrombin III	10	20	> 80%
Thrombocytes	105	196	150-400 $\times 10^9$ /L
PT-INR	> 7 <sup>1</sup>	> 7 <sup>1</sup>	
Vitamin B12	1068	273	130-700 pmol/L
Vitamin B1	74	106	75-225 nmol/L
Vitamin B6	37	142	50-180 nmol/L
Vitamin D	17.4	< 10	> 50 nmol/L

<sup>1</sup>Under anticoagulant therapy. ALT: Alanine aminotransferase; AST: Aspartate aminotransferase;  $\gamma$ -GT: Gamma-glutamyl transpeptidase; PT-INR: Prothrombin time-international normalized ratio.

loss: 62%) and somnolent state. She did not eat the days before hospitalization, likely due to psychiatric deterioration and suicidal ideation. She was diagnosed with a hyperammonemic encephalopathy (serum ammonia 86  $\mu$ mol/L) due to liver failure. Liver test results are presented in Table 1. The hepatic encephalopathy was treated with lactulose and rifaximin, and enteral feeding was started with Nutrison Protein plus Multifibre (Nutricia Medical, Dublin, Ireland). Despite these treatments, the patient's condition declined and 2 d after admission she died due to progressive liver failure.

## DISCUSSION

In this case series, we present 2 patients who developed severe protein malnutrition after bariatric surgery, followed by hyperammonemic encephalopathy and liver failure provoked by psychiatric deterioration.

Both patients were hospitalized in a period of 1-3 years after bariatric surgery in a malnourished state with dehydration, severe protein deficiency and anasarca. Importantly, common causes of protein loss, such as nephrotic syndrome or protein-losing enteropathy, were excluded, and no clues of decreased synthesis capacity of the liver were observed as cause of hypoalbuminemia. Most likely, hypoalbuminemia was caused by post-bariatric malabsorption and/or self-induced food restriction.

In malabsorptive procedures, such as distal gastric bypass, malnutrition has been described and bariatric surgeons should be aware of this complication<sup>[8,9]</sup>. Macronutrient deficiencies after restrictive procedures, such as modern gastric bypass surgery, are very rare<sup>[10]</sup>. In the cases presented herein, hypoalbuminemia was enhanced by very poor intake due to psychosocial problems postoperatively, probably resulting in anorexia, despite successful psychiatric screening as part of the work-up prior to bariatric surgery. During repeated hospital admissions, intensive guidance of

psychologists and dieticians was provided. Despite these efforts, both patients remained critically malnourished, finally resulting in liver failure and death. From a clinical perspective it is of utmost importance to recognize patients at risk of psychiatric deterioration after bariatric surgery. Our cases underlined that even close monitoring by a psychiatrist does not guarantee a stable clinical course.

Liver insufficiency in our patients became manifest during hospitalization. Both patients developed somnolence caused by hyperammonemic encephalopathy. In our patients, urea cycle disorders as cause of hyperammonemia were unlikely and excluded. Liver insufficiency was present, as reflected by the laboratory results (Table 1). Common causes of liver disease, such as alcohol abuse, viral infection and autoimmunity, were excluded. Therefore, we consider it likely that our patients developed liver insufficiency due to a prolonged state of severe malnutrition and anorexia, which was not well recognized.

Liver insufficiency has been described after malabsorptive bariatric procedures, such as the Scopinaro procedures. Bacterial overgrowth with the production of hepatotoxic macromolecules was considered the main cause. Malnutrition as cause of liver insufficiency is rare and has been described in non-bariatric patients with anorexia nervosa. The following hypotheses have been proposed in the literature: Liver insufficiency may be caused by acute liver cell necrosis, the result of autophagy<sup>[11]</sup> or dehydration and hypovolemia with poor blood circulation through the liver<sup>[12]</sup>. We hypothesize that our patients developed anorexia following bariatric surgery, reaching a state of starvation and a critical level of the liver reserve capacity, finally resulting in a state of liver insufficiency and death.

In conclusion, liver failure due to severe malnutrition is a very rare but critical complication after bariatric surgery. Patients who present with signs of severe protein malnutrition after bariatric surgery should be closely monitored and checked for nutritional status. Specific attention should be given to patients who develop psychiatric problems post-bariatric surgery. If refeeding does not result in clinical improvement, reversal surgery should be considered in a timely manner.

## ARTICLE HIGHLIGHTS

### Case characteristics

Patients who underwent bariatric surgery in the past developed unconsciousness and liver failure after self-induced food restriction.

### Clinical diagnosis

Development of hepatic encephalopathy and hepatic failure.

### Differential diagnosis

Hypoglycemia or neurological disorders were excluded as the cause of unconsciousness. No viral, autoimmune or toxic agents were found to have caused the liver failure.

**Laboratory diagnosis**

Signs of severe hypoalbuminemia, liver failure and hyperammonemia.

**Treatment**

Lactulose and rifaximin to treat hepatic encephalopathy.

**Term explanation**

Hyperammonemia refers to high blood level of ammonia.

**Experiences and lessons**

Specific attention should be given to patients who develop psychiatric problems post-bariatric surgery. If refeeding does not result in clinical improvement, reversal surgery should be considered in a timely manner.

**REFERENCES**

- 1 **Ong JP**, Elariny H, Collantes R, Younoszai A, Chandhoke V, Reines HD, Goodman Z, Younoszi ZM. Predictors of nonalcoholic steatohepatitis and advanced fibrosis in morbidly obese patients. *Obes Surg* 2005; **15**: 310-315 [PMID: 15826462 DOI: 10.1381/0960892053576820]
- 2 **Vernon G**, Baranova A, Younoszi ZM. Systematic review: the epidemiology and natural history of non-alcoholic fatty liver disease and non-alcoholic steatohepatitis in adults. *Aliment Pharmacol Ther* 2011; **34**: 274-285 [PMID: 21623852 DOI: 10.1111/j.1365-2036.2011.04724.x]
- 3 **Chang SH**, Stoll CR, Song J, Varela JE, Eagon CJ, Colditz GA. The effectiveness and risks of bariatric surgery: an updated systematic review and meta-analysis, 2003-2012. *JAMA Surg* 2014; **149**: 275-287 [PMID: 24352617 DOI: 10.1001/jamasurg.2013.3654]
- 4 **Courcoulas AP**, Yanovski SZ, Bonds D, Eggerman TL, Horlick M, Staten MA, Arterburn DE. Long-term outcomes of bariatric surgery: a National Institutes of Health symposium. *JAMA Surg* 2014; **149**: 1323-1329 [PMID: 25271405 DOI: 10.1001/jamasurg.2014.2440]
- 5 **Bower G**, Athanasiou T, Isla AM, Harling L, Li JV, Holmes E, Efthimiou E, Darzi A, Ashrafian H. Bariatric surgery and nonalcoholic fatty liver disease. *Eur J Gastroenterol Hepatol* 2015; **27**: 755-768 [PMID: 25919774 DOI: 10.1097/MEG.0000000000000375]
- 6 **Lassailly G**, Caiazzo R, Buob D, Pigeyre M, Verkindt H, Labreuche J, Raverdy V, Leteurtre E, Dharancy S, Louvet A, Romon M, Duhamel A, Pattou F, Mathurin P. Bariatric Surgery Reduces Features of Nonalcoholic Steatohepatitis in Morbidly Obese Patients. *Gastroenterology* 2015; **149**: 379-388; quiz e15-16 [PMID: 25917783 DOI: 10.1053/j.gastro.2015.04.014]
- 7 **D'Albuquerque LA**, Gonzalez AM, Wahle RC, de Oliveira Souza E, Mancero JM, de Oliveira e Silva A. Liver transplantation for subacute hepatocellular failure due to massive steatohepatitis after bariatric surgery. *Liver Transpl* 2008; **14**: 881-885 [PMID: 18508357 DOI: 10.1002/lt.21472]
- 8 **Dang H**, Arias E, Szomstein S, Rosenthal R. Laparoscopic conversion of distal mini-gastric bypass to proximal Roux-en-Y gastric bypass for malnutrition: case report and review of the literature. *Surg Obes Relat Dis* 2009; **5**: 383-386 [PMID: 19356992 DOI: 10.1016/j.soard.2009.01.003]
- 9 **Kellum JM**, Chikunguwo SM, Maher JW, Wolfe LG, Sugerman HJ. Long-term results of malabsorptive distal Roux-en-Y gastric bypass in superobese patients. *Surg Obes Relat Dis* 2011; **7**: 189-193 [PMID: 21145293 DOI: 10.1016/j.soard.2010.08.018]
- 10 **Martins Tde C**, Duarte TC, Mosca ER, Pinheiro Cde F, Marçola MA, De-Souza DA. Severe protein malnutrition in a morbidly obese patient after bariatric surgery. *Nutrition* 2015; **31**: 535-538 [PMID: 25701346 DOI: 10.1016/j.nut.2014.10.011]
- 11 **Rautou PE**, Cazals-Hatem D, Moreau R, Francoz C, Feldmann G, Lebrec D, Ogier-Denis E, Bedossa P, Valla D, Durand F. Acute liver cell damage in patients with anorexia nervosa: a possible role of starvation-induced hepatocyte autophagy. *Gastroenterology* 2008; **135**: 840-848, 848.e1-848.e3 [PMID: 18644371 DOI: 10.1053/j.gastro.2008.05.055]
- 12 **Tomita K**, Haga H, Ishii G, Katsumi T, Sato C, Aso R, Okumoto K, Nishise Y, Watanabe H, Saito T, Otani K, Ueno Y. Clinical manifestations of liver injury in patients with anorexia nervosa. *Hepatol Res* 2014; **44**: E26-E31 [PMID: 23841576 DOI: 10.1111/hepr.12202]

**P- Reviewer:** Govindarajan GK, Marchesini GM **S- Editor:** Cui LJ  
**L- Editor:** Filipodia **E- Editor:** Li D



## Do Ayurveda drugs induce liver injury?

Galib Ruknuddin

Galib Ruknuddin, Department of Rasa Shastra and Bhaishajya Kalpana, All India Institute of Ayurveda, New Delhi 110076, India

ORCID number: Galib Ruknuddin (0000-0002-9517-5801).

Author contributions: Ruknuddin G contributed to the manuscript.

Conflict-of-interest statement: No potential conflicts of interest relevant to this article were reported.

Open-Access: This article is an open-access article which was selected by an in-house editor and fully peer-reviewed by external reviewers. It is distributed in accordance with the Creative Commons Attribution Non Commercial (CC BY-NC 4.0) license, which permits others to distribute, remix, adapt, build upon this work non-commercially, and license their derivative works on different terms, provided the original work is properly cited and the use is non-commercial. See: <http://creativecommons.org/licenses/by-nc/4.0/>

Manuscript source: Unsolicited Manuscript

Correspondence to: Galib Ruknuddin, MD, PhD, Associate Professor, Department of Rasa Shastra and Bhaishajya Kalpana, All India Institute of Ayurveda, Mathura Road, Sarita Vihar, New Delhi 110076, India. [galib14@yahoo.co.in](mailto:galib14@yahoo.co.in)  
Telephone: +91-83-68960813

Received: November 28, 2017

Peer-review started: November 29, 2017

First decision: January 6, 2018

Revised: January 8, 2018

Accepted: March 6, 2018

Article in press: March 6, 2018

Published online: March 27, 2018

### Abstract

Drugs fulfilling the criterion of a standard drug will always become panacea provided, if they are used properly. On the other hand, a poorly manufactured drug however used skillfully, will prove to be a poison. Texts of Ayurveda, do mention hazards of drugs, which

are not properly manufactured or administered. Art of drug administration is unique in this ancient medical science that cautions towards concentrating on dose, indications, contra-indications, suitable vehicle, specific diet, certain restrictions *etc.*, while administering medicines in suitable individuals. Though a huge amount of information is available and evidences are being generated on the usefulness of traditional practices in global healthcare; there is a need of generating awareness on Promoting rational use of traditional medicines in particular to Ayurvedic drugs. Conventional researchers wish to work on traditional formulations have to understand traditional principles and involve traditional physicians in their researches in the benefit of mankind.

**Key words:** Ayurveda; Traditional medicines; Safety; Posology; Punarnava Mandura; Guggulu

© **The Author(s) 2018.** Published by Baishideng Publishing Group Inc. All rights reserved.

**Core tip:** Ayurveda principles of treatment and concepts of drug administration are entirely different than the conventional approach. Besides other basic requirements; understanding digestive ability, metabolic capability, tolerability of the patient to a specific dose of the drug, psycho-somatic constitution, *etc.*, of the patient is essential before starting treatment. In absence of which, adverse manifestations are likely. It is also unwise using traditional formulations by procuring over-the-counter for a longer period without any supervision of qualified physician. Considering holistic approaches of traditional remedies, joining hands together respecting fundamental principles of each other will be beneficial in global healthcare.

Ruknuddin G. Do Ayurveda drugs induce liver injury? *World J Hepatol* 2018; 10(3): 400-401 Available from: URL: <http://www.wjgnet.com/1948-5182/full/v10/i3/400.htm> DOI: <http://dx.doi.org/10.4254/wjh.v10.i3.400>

## TO THE EDITOR

We read with great interest the case report entitled "Ayurvedic drug induced liver injury" that was published in *World J Hepatol* 2017 November 8; 9(31): 1205-1209<sup>[1]</sup>. Though the Case Report highlights a newer aspect of some Ayurveda formulations; there are few aspects that need to be addressed.

Both the formulations (Punarnava Mandura and Kanchanara guggulu) are well known in Indian parlance and are being used in therapeutics since centuries. No hepatic injury was noticed or reported till date with such usage and no such scientific data that can convincingly prove harmful nature of these formulations is available till date.

The Case Report mentions that the patient used three different herbal and homoeopathic formulations. Though identity of two herbal formulations is revealed; the nature of the third one is unclear. It also not known these drugs was procured and how they have been used for how much duration from where. A drug can be panacea or poison. Drugs fulfilling the criterion of a standard drug will always become panacea provided, if they are used properly. On the other hand, a poorly prepared or manufactured drug however used skilfully, will always prove to be a poison. Classics of Ayurveda do mention the hazards of drugs, which are not properly manufactured and not used judiciously. There is no sufficient evidence in the article to confirm the posological considerations of the formulations used. Ayurvedic formulations are not used in similar way as that of conventional medicines. Besides other basic requirements; understanding of digestive ability, metabolic capability, tolerability of a patient to a specific dose of the drug, psycho-somatic constitution, etc., of the patient is essential before starting treatment. After meticulous examination; suitable preparations are to be administered orally in specified quantities with great caution along with requisite vehicles like ghee, milk, honey, etc. In absence of a vehicle, adverse reactions are likely<sup>[2]</sup>.

The Case Report also didn't focus on how the drugs have been procured. These medicines are not OTC products and should be used under the supervision of any authorized Ayurveda/Homoeopathy physician, who are the registered authorities, have been trained in that specific field as per the syllabus provided by Ministry of AYUSH, Govt. of India. We are not sure about the identity of the healer referred in the current study. In addition; the nature of the third drug is also not known, in such case why to blame only Ayurvedic formulations for the manifested pathology. There is a possibility of drug-drug interaction too that was not considered in the current work.

As referred in the Case Report; Punarnava Mandura

is not an extract of *Boerhavia diffusa*. Authors need to verify the validity of information being cited from the article. Besides this, editors also should be vigilant and prefer to restrict the authors from citing such articles from predatory journals. Similarly, Kanchanara Guggulu is not an extract of *Bauhinia variegata*. These two drugs are poly herbal combinations prepared by following standard guidelines explained in the classical text books of Ayurveda.

Punarnava Mandura is made-up of twenty ingredients which is familiar hematinic drug. Its efficacy has been well established in geriatric and gestational anaemias<sup>[3,4]</sup>. Kanchanara Guggulu is also a poly herbal formulation, whose efficacy has been well established<sup>[5]</sup>. Traditional medicines, which usually have multi components are helpful in counteracting multi factors of any pathology<sup>[6]</sup>. Different components of a traditional formulation act synergistically exerting various activities like metabolic enhancers, immuno-modulators, antioxidants, rejuvenators, increases bio-availability and help in countering toxic nature of other ingredients. All these activities indicate towards multi-variant nature of compound formulations that are actually need of the time.

Based upon a single and incomplete observation; inferring Ayurvedic drugs with liver injury is unwise. Authors have to understand that Ayurveda always advocate using drug as a whole and never prefer using extracts in a formulation except aqueous or hydro-alcoholic extracts.

This article indirectly clears the need of paying attention towards generating awareness on use of traditional medicines. The impact of such reports in a leading scientific journal like WJH is a serious matter as it may unnecessarily cause disrepute to herbal remedies and ultimately to the system of Ayurveda.

## REFERENCES

- 1 **Dalal KK**, Holdbrook T, Peikin SR. Ayurvedic drug induced liver injury. *World J Hepatol* 2017; **9**: 1205-1209 [PMID: 29152040 DOI: 10.4254/wjh.v9.i31.1205]
- 2 **Kapoor RC**. Some observations on the metal-based preparations in the Indian Systems of Medicine. *Indian J Trad Know* 2010; **9**: 562-575
- 3 **Pandya MG**, Dave AR. A clinical study of Punarnava Mandura in the management of Pandu Roga in old age (geriatric anemia). *Ayu* 2014; **35**: 252-260 [PMID: 26664234 DOI: 10.4103/0974-8520.153735]
- 4 **Khandelwal DA**, Donga SB, Dei L. Clinical efficacy of Punarnava Mandura and Dhatri Lauha in the management of Garbhini Pandu (anemia in pregnancy). *Ayu* 2015; **36**: 397-403 [PMID: 27833367 DOI: 10.4103/0974-8520.190700]
- 5 **Dhiman K**. Ayurvedic intervention in the management of uterine fibroids: A Case series. *Ayu* 2014; **35**: 303-308 [PMID: 26664240 DOI: 10.4103/0974-8520.153750]
- 6 **Keith CT**, Borisy AA, Stockwell BR. Multicomponent therapeutics for networked systems. *Nat Rev Drug Discov* 2005; **4**: 71-78 [PMID: 15688074 DOI: 10.1038/nrd1609]

**P- Reviewer:** Balaban YH, Mizuguchi T, Morales-González JA, Skrypnik IN, Tarantino G, la Tijera FH, Zhu X

**S- Editor:** Cui LJ **L- Editor:** A **E- Editor:** Wang CH





Published by **Baishideng Publishing Group Inc**  
7901 Stoneridge Drive, Suite 501, Pleasanton, CA 94588, USA  
Telephone: +1-925-223-8242  
Fax: +1-925-223-8243  
E-mail: [bpgoffice@wjgnet.com](mailto:bpgoffice@wjgnet.com)  
Help Desk: <http://www.f6publishing.com/helpdesk>  
<http://www.wjgnet.com>

