

World Journal of *Hepatology*

World J Hepatol 2014 August 27; 6(8): 538-625





Editorial Board

2014-2017

The *World Journal of Hepatology* Editorial Board consists of 469 members, representing a team of worldwide experts in hepatology. They are from 53 countries, including Algeria (1), Argentina (6), Armenia (1), Australia (1), Austria (4), Bangladesh (2), Belgium (3), Botswana (2), Brazil (13), Bulgaria (2), Canada (3), Chile (1), China (98), Czech Republic (1), Denmark (2), Egypt (12), France (6), Germany (19), Greece (11), Hungary (5), India (15), Indonesia (2), Iran (4), Israel (1), Italy (52), Japan (35), Jordan (1), Malaysia (2), Mexico (3), Moldova (1), Netherlands (3), Nigeria (1), Pakistan (1), Philippines (2), Poland (1), Portugal (2), Qatar (1), Romania (6), Russia (2), Saudi Arabia (4), Singapore (1), South Korea (11), Spain (20), Sri Lanka (1), Sudan (1), Sweden (1), Switzerland (1), Thailand (4), Turkey (21), Ukraine (3), United Kingdom (17), and United States (56).

EDITORS-IN-CHIEF

Clara Balsano, *Rome*
Wan-Long Chuang, *Kaohsiung*

GUEST EDITORIAL BOARD MEMBERS

King-Wah Chiu, *Kaohsiung*
Tai-An Chiang, *Tainan*
Chi-Tan Hu, *Hualien*
Sen-Yung Hsieh, *Taoyuan*
Wenya Huang, *Tainan*
Liang-Yi Hung, *Tainan*
Jih RU Hwu, *Hsinchu*
Jing-Yi Lee, *Taipei*
Mei-Hsuan Lee, *Taipei*
Chih-Wen Lin, *Kaohsiung*
Chun-Che Lin, *Taichung*
Wan-Yu Lin, *Taichung*
Tai-Long Pan, *Tao-Yuan*
Suh-Ching Yang, *Taipei*
Chun-Yan Yeung, *Taipei*

MEMBERS OF THE EDITORIAL BOARD



Algeria

Samir Rouabhia, *Batna*



Argentina

Fernando O Bessone, *Rosario*
Maria C Carrillo, *Rosario*
Melisa M Dirchwolf, *Buenos Aires*
Bernardo Frider, *Buenos Aires*

Jorge Quarleri, *Buenos Aires*
Adriana M Torres, *Rosario*



Armenia

Narina Sargsyants, *Yerevan*



Australia

Mark D Gorrell, *Sydney*



Austria

Harald Hofer, *Vienna*
Gustav Paumgartner, *Vienna*
Matthias Pinter, *Vienna*
Thomas Reiberger, *Vienna*



Bangladesh

Shahinul Alam, *Dhaka*
Mamun Al Mahtab, *Dhaka*



Belgium

Nicolas Lanthier, *Brussels*
Philip Meuleman, *Ghent*
Luisa Vonghia, *Antwerp*



Botswana

Francesca Cainelli, *Gaborone*

Sandro Vento, *Gaborone*



Brazil

Edson Abdala, *Sao Paulo*
Ilka FSF Boin, *Campinas*
Niels OS Camara, *Sao Paulo*
Ana Carolina FN Cardoso, *Rio de Janeiro*
Roberto J Carvalho-Filho, *Sao Paulo*
Julio CU Coelho, *Curitiba*
Flavio Henrique Ferreira Galvao, *Sao Paulo*
Janaina L Narciso-Schiavon, *Florianopolis*
Sílvia HC Sales-Peres, *Bauru*
Leonardo L Schiavon, *Florianópolis*
Luciana D Silva, *Belo Horizonte*
Vanessa Souza-Mello, *Rio de Janeiro*
Jaques Waisberg, *Santo André*



Bulgaria

Mariana P Penkova-Radicheva, *Stara Zagora*
Marieta Simonova, *Sofia*



Canada

Runjan Chetty, *Toronto*
Michele Molinari, *Halifax*
Giada Sebastiani, *Montreal*



Chile

Luis A Videla, *Santiago*



China

Guang-Wen Cao, Shanghai
 En-Qiang Chen, Chengdu
 Gong-Ying Chen, Hangzhou
 Jin-lian Chen, Shanghai
 Jun Chen, Changsha
 Alfred Cheng, Hong Kong
 Chun-Ping Cui, Beijing
 Shuang-Suo Dang, Xi'an
 Ming-Xing Ding, Jinhua
 Zhi-Jun Duang, Dalian
 He-Bin Fan, Wuhan
 Xiao-Ming Fan, Shanghai
 James Yan Yue Fung, Hong Kong
 Yi Gao, Guangzhou
 Zuo-Jiong Gong, Wuhan
 Zhi-Yong Guo, Guangzhou
 Shao-Liang Han, Wenzhou
 Tao Han, Tianjin
 Jin-Yang He, Guangzhou
 Ming-Liang He, Hong Kong
 Can-Hua Huang, Chengdu
 Bo Jin, Beijing
 Shan Jin, Hohhot
 Hui-Qing Jiang, Shijiazhuang
 Wan-Yee Joseph Lau, Hong Kong
 Guo-Lin Li, Changsha
 Jin-Jun Li, Shanghai
 Qiang Li, Jinan
 Sheng Li, Jinan
 Zong-Fang Li, Xi'an
 Xu Li, Guangzhou
 Xue-Song Liang, Shanghai
 En-Qi Liu, Xi'an
 Pei Liu, Shenyang
 Zhong-Hui Liu, Changchun
 Guang-Hua Luo, Changzhou
 Yi Lv, Xi'an
 Guang-Dong Pan, Liuzhou
 Wen-Sheng Pan, Hangzhou
 Jian-Min Qin, Shanghai
 Wai-Kay Seto, Hong Kong
 Hong Shen, Changsha
 Xiao Su, Shanghai
 Li-Ping Sun, Beijing
 Wei-Hao Sun, Nanjing
 Xue-Ying Sun, Harbin
 Hua Tang, Tianjin
 Ling Tian, Shanghai
 Eric Tse, Hong Kong
 Guo-Ying Wang, Changzhou
 Yue Wang, Beijing
 Shu-Qiang Wang, Chengdu
 Mary MY Wayne, Hong Kong
 Hong-Shan Wei, Beijing
 Danny Ka-Ho Wong, Hong Kong
 Grace Lai-Hung Wong, Hong Kong
 Bang-Fu Wu, Dongguan
 Feng Wu, Chongqing
 Xiong-Zhi Wu, Tianjin
 Chun-Fang Xu, Suzhou
 Rui-An Xu, Quanzhou
 Rui-Yun Xu, Guangzhou
 Wei-Li Xu, Shijiazhuang
 Shi-Ying Xuan, Qingdao
 Ming-Xian Yan, Jinan
 Lv-Nan Yan, Chengdu
 Jin Yang, Hangzhou
 Ji-Hong Yao, Dalian
 Winnie Yeo, Hong Kong

Zheng Zeng, Beijing
 Qi Zhang, Hangzhou
 Shi-Jun Zhang, Guangzhou
 Xiao-Lan Zhang, Shijiazhuang
 Xiao-Yong Zhang, Guangzhou
 Xin-Chen Zhang, Harbin
 Yong Zhang, Xi'an
 Hong-Chuan Zhao, Hefei
 Ming-Hua Zheng, Wenzhou
 Yu-Bao Zheng, Guangzhou
 Ren-Qian Zhong, Shanghai
 Fan Zhu, Wuhan
 Xiao Zhu, Dongguan



Czech Republic

Kamil Vysloulzil, Olomouc



Denmark

Henning Gronbaek, Aarhus
 Christian Mortensen, Hvidovre



Egypt

Ihab T Abdel-Raheem, Damanhour
 NGB G Bader EL Din, Cairo
 Hatem Elalfy, Mansoura
 Mahmoud M El-Bendary, Mansoura
 Mona El SH El-Raziky, Cairo
 Mohammad El-Sayed, Cairo
 Yasser M Fouad, Minia
 Mohamed AA Metwally, Benha
 Hany Shehab, Cairo
 Mostafa M Sira, Shebin El-koom
 Ashraf Taye, Minia
 MA Ali Wahab, Mansoura



France

Laurent Alric, Toulouse
 Sophie Conchon, Nantes
 Daniel J Felmlee, Strasbourg
 Herve Lerat, Creteil
 Dominique Salmon, Paris
 Jean-Pierre Vartanian, Paris



Germany

Laura E Buitrago-Molina, Hannover
 Enrico N De Toni, Munich
 Oliver Ebert, Muenchen
 Rolf Gebhardt, Leipzig
 Janine V Hartl, Regensburg
 Sebastian Hinz, Kiel
 Benjamin Juntermanns, Essen
 Roland Kaufmann, Jena
 Viola Knop, Frankfurt
 Veronika Lukacs-Kornek, Homburg
 Benjamin Maasoumy, Hannover
 Jochen Mattner, Erlangen
 Nadja M Meindl-Beinker, Mannheim
 Ulf P Neumann, Aachen
 Margarete Odenthal, Cologne
 Yoshiaki Sunami, Munich

Christoph Roderburg, Aachen
 Frank Tacke, Aachen
 Yuchen Xia, Munich



Greece

Alex P Betrosian, Athens
 George N Dalekos, Larissa
 Ioanna K Delladetsima, Athens
 Nikolaos K Gatselis, Larissa
 Stavros Gourgiotis, Athens
 Christos G Savopoulos, Thessaloniki
 Tania Siahaniidou, Athens
 Emmanouil Sinakos, Thessaloniki
 Nikolaos G Symeonidi, Thessaloniki
 Konstantinos C Thomopoulos, Larissa
 Konstantinos Tziomalos, Thessaloniki



Hungary

Gabor Banhegyi, Budapest
 Peter L Lakatos, Budapest
 Maria Papp, Debrecen
 Ferenc Sipos, Budapest
 Zsolt J Tulassay, Budapest



India

Deepak N Amarapurkar, Mumbai
 Girish M Bhopale, Pune
 Sibnarayan Datta, Tezpur
 Nutan D Desai, Mumbai
 Sorabh Kapoor, Mumbai
 Jaswinder S Maras, New Delhi
 Nabeen C Nayak, New Delhi
 C Ganesh Pai, Manipal
 Amit Pal, Chandigarh
 K Rajeshwari, New Delhi
 Anup Ramachandran, Vellore
 D Nageshwar Reddy, Hyderabad
 Shivaram P Singh, Cuttack
 Ajith TA, Thrissur
 Balasubramaniyan Vairappan, Pondicherry



Indonesia

Cosmas RA Lesmana, Jakarta
 Neneng Ratnasari, Yogyakarta



Iran

Seyed M Jazayeri, Tehran
 Sedigheh Kafi-Abad, Tehran
 Iradj Maleki, Sari
 Fakhraddin Naghibalhossaini, Shiraz



Israel

Stephen DH Malnick, Rehovot



Italy

Francesco Angelico, Rome

Alfonso W Avolio, *Rome*
 Francesco Bellanti, *Foggia*
 Marcello Bianchini, *Modena*
 Guglielmo Borgia, *Naples*
 Mauro Borzio, *Milano*
 Enrico Brunetti, *Pavia*
 Valeria Cento, *Roma*
 Beatrice Conti, *Rome*
 Francesco D'Amico, *Padova*
 Samuele De Minicis, *Fermo*
 Fabrizio De Ponti, *Bologna*
 Giovan Giuseppe Di Costanzo, *Napoli*
 Luca Fabris, *Padova*
 Giovanna Ferraioli, *Pavia*
 Andrea Galli, *Florence*
 Matteo Garcovich, *Rome*
 Edoardo G Giannini, *Genova*
 Rossano Girometti, *Udine*
 Alessandro Granito, *Bologna*
 Alberto Grassi, *Rimini*
 Alessandro Grasso, *Savona*
 Salvatore Gruttadauria, *Palermo*
 Francesca Guerrieri, *Rome*
 Quirino Lai, *Aquila*
 Andrea Lisotti, *Bologna*
 Marcello F Maida, *Palermo*
 Lucia Malaguarnera, *Catania*
 Andrea Mancuso, *Palermo*
 Luca Maroni, *Ancona*
 Francesco Marotta, *Milano*
 Pierluigi Marzuillo, *Naples*
 Sara Montagnese, *Padova*
 Giuseppe Nigri, *Rome*
 Claudia Piccoli, *Foggia*
 Camillo Porta, *Pavia*
 Chiara Raggi, *Rozzano (MI)*
 Maria Rendina, *Bari*
 Maria Ripoli, *San Giovanni Rotondo*
 Kryssia I Rodriguez-Castro, *Padua*
 Raffaella Romeo, *Milan*
 Amedeo Sciarra, *Milano*
 Antonio Solinas, *Sassari*
 Aurelio Sonzogni, *Bergamo*
 Giovanni Squadrito, *Messina*
 Salvatore Sutti, *Novara*
 Valentina Svicher, *Rome*
 Luca Toti, *Rome*
 Elvira Verduci, *Milan*
 Umberto Vespasiani-Gentilucci, *Rome*
 Maria A Zocco, *Rome*



Japan

Yasuhiro Asahina, *Tokyo*
 Nabil AS Eid, *Takatsuki*
 Kenichi Ikejima, *Tokyo*
 Shoji Ikuo, *Kobe*
 Yoshihiro Ikura, *Takatsuki*
 Shinichi Ikuta, *Nishinomiya*
 Kazuaki Inoue, *Yokohama*
 Toshiya Kamiyama, *Sapporo*
 Takanobu Kato, *Tokyo*
 Saiho Ko, *Nara*
 Haruki Komatsu, *Sakura*
 Masanori Matsuda, *Chuo-city*
 Yasunobu Matsuda, *Niigata*
 Yoshifumi Nakayama, *Kitakyushu*
 Taichiro Nishikawa, *Kyoto*

Satoshi Oeda, *Saga*
 Kenji Okumura, *Urayasu*
 Michitaka Ozaki, *Sapporo*
 Takahiro Sato, *Sapporo*
 Junichi Shindoh, *Tokyo*
 Ryo Sudo, *Yokohama*
 Atsushi Suetsugu, *Gifu*
 Haruhiko Sugimura, *Hamamatsu*
 Reiji Sugita, *Sendai*
 Koichi Takaguchi, *Takamatsu*
 Shinji Takai, *Takatsuki*
 Akinobu Takaki, *Okayama*
 Yasuhito Tanaka, *Nagoya*
 Takuji Tanaka, *Gifu City*
 Atsunori Tsuchiya, *Niigata*
 Koichi Watashi, *Tokyo*
 Hiroshi Yagi, *Tokyo*
 Taro Yamashita, *Kanazawa*
 Shuhei Yoshida, *Chiba*
 Hitoshi Yoshiji, *Kashiwara*



Jordan

Kamal E Bani-Hani, *Zarqa*



Malaysia

Peng Soon Koh, *Kuala Lumpur*
 Yeong Yeh Lee, *Kota Bahru*



Mexico

Francisco J Bosques-Padilla, *Monterrey*
 María de F Higuera-de la Tijera, *Mexico City*
 José A Morales-Gonzalez, *México City*



Moldova

Angela Peltec, *Chishinev*



Netherlands

Wybrich R Cnossen, *Nijmegen*
 Frank G Schaap, *Maastricht*
 Fareeba Sheedfar, *Groningen*



Nigeria

CA Asabamaka Onyekwere, *Lagos*



Pakistan

Bikha Ram Devrajani, *Jamshoro*



Philippines

Janus P Ong, *Pasig*
 JD Decena Sollano, *Manila*



Poland

Jacek Zielinski, *Gdansk*



Portugal

Rui T Marinho, *Lisboa*
 Joao B Soares, *Braga*



Qatar

Reem Al Olaby, *Doha*



Romania

Bogdan Dorobantu, *Bucharest*
 Liana Gheorghe, *Bucharest*
 George S Gherlan, *Bucharest*
 Romeo G Mihaila, *Sibiu*
 Bogdan Procopet, *Cluj-Napoca*
 Streba T Streba, *Craiova*



Russia

Anisa Gumerova, *Kazan*
 Pavel G Tarazov, *St.Petersburg*



Saudi Arabia

Abdulrahman A Aljumah, *Riyadh*
 Ihab MH Mahmoud, *Riyadh*
 Ibrahim Masoodi, *Riyadh*
 Mhoammad K Parvez, *Riyadh*



Singapore

Ser Yee Lee, *Singapore*



South Korea

Young-Hwa Chung, *Seoul*
 Dae-Won Jun, *Seoul*
 Bum-Joon Kim, *Seoul*
 Do Young Kim, *Seoul*
 Ji Won Kim, *Seoul*
 Moon Young Kim, *Wonju*
 Mi-Kyung Lee, *Suncheon*
 Kwan-Kyu Park, *Daegu*
 Young Nyun Park, *Seoul*
 Jae-Hong Ryoo, *Seoul*
 Jong Won Yun, *Kyungsan*



Spain

Ivan G Marina, *Madrid*
 Juan G Acevedo, *Barcelona*
 Javier Ampuero, *Sevilla*
 Jaime Arias, *Madrid*
 Andres Cardenas, *Barcelona*
 Agustin Castiella, *Mendaro*
 Israel Fernandez-Pineda, *Sevilla*
 Rocio Gallego-Duran, *Sevilla*
 Rita Garcia-Martinez, *Barcelona*

José M González-Navajas, *Alicante*
 Juan C Laguna, *Barcelona*
 Elba Llop, *Madrid*
 Laura Ochoa-Callejero, *La Rioja*
 Albert Pares, *Barcelona*
 Sonia Ramos, *Madrid*
 Francisco Rodríguez-Frias, *Córdoba*
 Manuel L Rodríguez-Peralvarez, *Córdoba*
 Marta R Romero, *Salamanca*
 Carlos J Romero, *Madrid*
 Maria Traperó-Marugán, *Madrid*



Sri Lanka

Niranga M Devanarayana, *Ragama*



Sudan

Hatim MY Mudawi, *Khartoum*



Sweden

Evangelos Kalaitzakis, *Lund*



Switzerland

Christoph A Maurer, *Liestal*



Thailand

Taned Chitapanarux, *Chiang mai*
 Temduang Limpaboon, *Khon Kaen*
 Sith Phongkitkarun, *Bangkok*
 Yong Poovorawan, *Bangkok*



Turkey

Osman Abbasoglu, *Ankara*
 Mesut Akarsu, *Izmir*
 Umit Akyuz, *Istanbul*
 Hakan Alagozlu, *Sivas*
 Yasemin H Balaban, *Istanbul*
 Bulent Baran, *Van*
 Mehmet Celikbilek, *Yozgat*

Levent Doganay, *Istanbul*
 Fatih Eren, *Istanbul*
 Abdurrahman Kadayifci, *Gaziantep*
 Ahmet Karaman, *Kayseri*
 Muhsin Kaya, *Diyarbakir*
 Ozgur Kemik, *Van*
 Serdar Moralioglu, *Uskudar*
 A Melih Ozel, *Gebze - Kocaeli*
 Seren Ozenirler, *Ankara*
 Ali Sazci, *Kocaeli*
 Goktug Sirin, *Kocaeli*
 Mustafa Sunbul, *Samsun*
 Nazan Tuna, *Sakarya*
 Ozlem Yonem, *Sivas*



Ukraine

Rostyslav V Bubnov, *Kyiv*
 Nazarii K Kobylak, *Kyiv*
 Igor N Skrypnyk, *Poltava*



United Kingdom

Safa Al-Shamma, *Bournemouth*
 Jayantha Arnold, *Southall*
 Marco Carbone, *Cambridge*
 Rajeev Desai, *Birmingham*
 Ashwin Dhanda, *Bristol*
 Matthew Hoare, *Cambridge*
 Stefan G Hubscher, *Birmingham*
 Nikolaos Karidis, *London*
 Lemonica J Koumbi, *London*
 Patricia Lalor, *Birmingham*
 Ji-Liang Li, *Oxford*
 Evaggelia Liaskou, *Birmingham*
 Rodrigo Liberal, *London*
 Wei-Yu Lu, *Edinburgh*
 Richie G Madden, *Truro*
 Christian P Selinger, *Leeds*
 Esther Una Cidon, *Bournemouth*



United States

Naim Alkhouri, *Cleveland*
 Robert A Anders, *Baltimore*
 Mohammed Sawkat Anwer, *North Grafton*
 Kalyan Ram Bhamidimarri, *Miami*

Brian B Borg, *Jackson*
 Ronald W Busuttil, *Los Angeles*
 Andres F Carrion, *Miami*
 Saurabh Chatterjee, *Columbia*
 Disaya Chavalitdhamrong, *Gainesville*
 Mark J Czaja, *Bronx*
 Jonathan M Fenkel, *Philadelphia*
 Catherine Frenette, *La Jolla*
 Lorenzo Gallon, *Chicago*
 Kalpana Ghoshal, *Columbus*
 Grigoriy E Gurvits, *New York*
 Hie-Won L Hann, *Philadelphia*
 Shuang-Teng He, *Kansas City*
 Wendong Huang, *Duarte*
 Rachel Hudacko, *Suffern*
 Lu-Yu Hwang, *Houston*
 Ijaz S Jamall, *Sacramento*
 Neil L Julie, *Bethesda*
 Hetal Karsan, *Atlanta*
 Ahmed O Kaseb, *Houston*
 Zeid Kayali, *Pasadena*
 Kusum K Kharbanda, *Omaha*
 Timothy R Koch, *Washington*
 Gursimran S Kochhar, *Cleveland*
 Steven J Kovacs, *East Hanover*
 Mary C Kuhns, *Abbott Park*
 Jiang Liu, *Silver Spring*
 Li Ma, *Stanford*
 Francisco Igor Macedo, *Southfield*
 Sandeep Mukherjee, *Omaha*
 Natalia A Osna, *Omaha*
 Jen-Jung Pan, *Houston*
 Christine Pocha, *Minneapolis*
 Yury Popov, *Boston*
 Davide Povero, *La Jolla*
 Phillip Ruiz, *Miami*
 Takao Sakai, *Cleveland*
 Nicola Santoro, *New Haven*
 Eva Schmelzer, *Pittsburgh*
 Zhongjie Shi, *Philadelphia*
 Nathan J Shores, *New Orleans*
 Siddharth Singh, *Rochester*
 Veysel Tahan, *Iowa City*
 Mehlika Toy, *Boston*
 Hani M Wadei, *Jacksonville*
 Gulam Waris, *North Chicago*
 Ruliang Xu, *New York*
 Jun Xu, *Los Angeles*
 Matthew M Yeh, *Seattle*
 Xuchen Zhang, *West Haven*
 Lixin Zhu, *Buffalo*
 Sasa Zivkovic, *Pittsburgh*

**REVIEW**

- 538 Vertical hepatitis C virus transmission: Main questions and answers
Tosone G, Maraolo AE, Mascolo S, Palmiero G, Tambaro O, Orlando R
- 549 From portal to splanchnic venous thrombosis: What surgeons should bear in mind
Lai Q, Spoletini G, Pinheiro RS, Melandro F, Guglielmo N, Lerut J
- 559 Palliation: Hilar cholangiocarcinoma
Goenka MK, Goenka U
- 570 Role of adipokines and peroxisome proliferator-activated receptors in nonalcoholic fatty liver disease
Giby VG, Ajith TA

MINIREVIEWS

- 580 Pictures of focal nodular hyperplasia and hepatocellular adenomas
Sempoux C, Balabaud C, Bioulac-Sage P
- 596 Pancreatic neuroendocrine tumor accompanied with multiple liver metastases
Hori T, Takaori K, Uemoto S

ORIGINAL ARTICLE

- 601 Assessing liver injury associated with antimycotics: Concise literature review and clues from data mining of the FAERS database
Raschi E, Poluzzi E, Koci A, Caraceni P, De Ponti F
- 613 Circulating microRNAs in patients with non-alcoholic fatty liver disease
Celikbilek M, Baskol M, Taheri S, Deniz K, Dogan S, Zararsiz G, Gursay S, Guven K, Ozbakir O, Dunder M, Yucel M

**OBSERVATIONAL
STUDY**

- 621 Early termination of immune tolerance state of hepatitis B virus infection explains liver damage
Mahtab MA, Akbar SMF, Uddin H, Khan SI, Rahman S

Contents

World Journal of Hepatology
Volume 6 Number 8 August 27, 2014

APPENDIX I-V Instructions to authors

ABOUT COVER

Editorial Board Member of *World Journal of Hepatology*, Ruliang Xu, MD, PhD, Associate Professor, Chief Doctor, Department of Pathology, New York University Langone Medical Center, New York, NY 10016, United States

AIM AND SCOPE

World Journal of Hepatology (*World J Hepatol*, *WJH*, online ISSN 1948-5182, DOI: 10.4254), is a peer-reviewed open access academic journal that aims to guide clinical practice and improve diagnostic and therapeutic skills of clinicians.

WJH covers topics concerning liver biology/pathology, cirrhosis and its complications, liver fibrosis, liver failure, portal hypertension, hepatitis B and C and inflammatory disorders, steatohepatitis and metabolic liver disease, hepatocellular carcinoma, biliary tract disease, autoimmune disease, cholestatic and biliary disease, transplantation, genetics, epidemiology, microbiology, molecular and cell biology, nutrition, geriatric and pediatric hepatology, diagnosis and screening, endoscopy, imaging, and advanced technology. Priority publication will be given to articles concerning diagnosis and treatment of hepatology diseases. The following aspects are covered: Clinical diagnosis, laboratory diagnosis, differential diagnosis, imaging tests, pathological diagnosis, molecular biological diagnosis, immunological diagnosis, genetic diagnosis, functional diagnostics, and physical diagnosis; and comprehensive therapy, drug therapy, surgical therapy, interventional treatment, minimally invasive therapy, and robot-assisted therapy.

We encourage authors to submit their manuscripts to *WJH*. We will give priority to manuscripts that are supported by major national and international foundations and those that are of great basic and clinical significance.

INDEXING/ABSTRACTING

World Journal of Hepatology is now indexed in PubMed Central, PubMed, Digital Object Identifier, Directory of Open Access Journals, and Scopus.

FLYLEAF I-IV Editorial Board

EDITORS FOR THIS ISSUE

Responsible Assistant Editor: *Xiang Li*
Responsible Electronic Editor: *Huan-Liang Wu*
Proofing Editor-in-Chief: *Lian-Sheng Ma*

Responsible Science Editor: *Xue-Mei Gong*
Proofing Editorial Office Director: *Xin-Xia Song*

NAME OF JOURNAL
World Journal of Hepatology

ISSN
ISSN 1948-5182 (online)

LAUNCH DATE
October 31, 2009

FREQUENCY
Monthly

EDITORS-IN-CHIEF
Clara Balsano, PhD, Professor, Departement of Biomedicine, Institute of Molecular Biology and Pathology, Rome 00161, Italy

Wan-Long Chuang, MD, PhD, Doctor, Professor, Hepatobiliary Division, Department of Internal Medicine, Kaohsiung Medical University Hospital, Kaohsiung Medical University, Kaohsiung 807, Taiwan

EDITORIAL OFFICE
Jin-Lei Wang, Director

Xiu-Xia Song, Vice Director
World Journal of Hepatology
Room 903, Building D, Ocean International Center, No. 62 Dongsihuan Zhonglu, Chaoyang District, Beijing 100025, China
Telephone: +86-10-59080039
Fax: +86-10-85381893
E-mail: editorialoffice@wjgnet.com
Help Desk: <http://www.wjgnet.com/esps/helpdesk.aspx>
<http://www.wjgnet.com>

PUBLISHER
Baishideng Publishing Group Inc
8226 Regency Drive,
Pleasanton, CA 94588, USA
Telephone: +1-925-223-8242
Fax: +1-925-223-8243
E-mail: bpgoffice@wjgnet.com
Help Desk: <http://www.wjgnet.com/esps/helpdesk.aspx>
<http://www.wjgnet.com>

PUBLICATION DATE
August 27, 2014

COPYRIGHT

© 2014 Baishideng Publishing Group Inc. Articles published by this Open Access journal are distributed under the terms of the Creative Commons Attribution Non-commercial License, which permits use, distribution, and reproduction in any medium, provided the original work is properly cited, the use is non commercial and is otherwise in compliance with the license.

SPECIAL STATEMENT

All articles published in journals owned by the Baishideng Publishing Group (BPG) represent the views and opinions of their authors, and not the views, opinions or policies of the BPG, except where otherwise explicitly indicated.

INSTRUCTIONS TO AUTHORS

Full instructions are available online at http://www.wjgnet.com/1948-5182/g_info_20100316080002.htm

ONLINE SUBMISSION

<http://www.wjgnet.com/esps/>

Vertical hepatitis C virus transmission: Main questions and answers

Grazia Tosone, Alberto Enrico Maraolo, Silvia Mascolo, Giulia Palmiero, Orsola Tambaro, Raffaele Orlando

Grazia Tosone, Alberto Enrico Maraolo, Silvia Mascolo, Giulia Palmiero, Orsola Tambaro, Raffaele Orlando, Department of Clinical Medicine and Surgery, Section of Infectious Diseases, University of Naples Federico II, 80131 Napoli, Italy

Author contributions: Tosone G and Orlando R designed the review and made the overview of the manuscript; Maraolo AE and Palmiero G collected and analyzed the data on hepatitis C virus infection in pregnancy and vertical transmission; Mascolo S and Tambaro O collected and analyzed the data on antiviral drugs, including animal model data.

Correspondence to: Grazia Tosone, MD, Department of Clinical Medicine and Surgery, Section of Infectious Diseases, University of Naples Federico II, Via Sergio Pansini 5, 80131 Napoli, Italy. grazia.tosone@unina.it

Telephone: +39-08-17463082 Fax: +39-08-17493094

Received: February 14, 2014 Revised: May 7, 2014

Accepted: June 10, 2014

Published online: August 27, 2014

Abstract

Hepatitis C virus (HCV) affects about 3% of the world's population and peaks in subjects aged over 40 years. Its prevalence in pregnant women is low (1%-2%) in most western countries but drastically increases in women in developing countries or with high risk behaviors for blood-transmitted infections. Here we review clinical, prognostic and therapeutic aspects of HCV infection in pregnant women and their offspring infected through vertical transmission. Pregnancy-related immune weakness does not seem to affect the course of acute hepatitis C but can affect the progression of chronic hepatitis C. In fact, postpartum immune restoration can exacerbate hepatic inflammation, thereby worsening the liver disease, particularly in patients with liver cirrhosis. HCV infection increases the risk of gestational diabetes in patients with excessive weight gain, premature rupture of membrane and caesarean delivery. Only 3%-5% of infants born to HCV-positive mothers have been infected by intrauterine or perinatal transmission. Maternal viral load, human immunodeficiency virus coinfection, prolonged rupture of mem-

branes, fetal exposure to maternal infected blood consequent to vaginal or perineal lacerations and invasive monitoring of fetus increase the risk of viral transmission. Cesarean delivery and breastfeeding increases the transmission risk in HCV/human immunodeficiency virus coinfecting women. The consensus is not to offer antiviral therapy to HCV-infected pregnant women because it is based on ribavirin (pregnancy category X) because of its embryocidal and teratogenic effects in animal species. In vertically infected children, chronic C hepatitis is often associated with minimal or mild liver disease and progression to liver cirrhosis and hepatocarcinoma is lower than in adults. Infected children may be treated after the second year of life, given the adverse effects of current antiviral agents.

© 2014 Baishideng Publishing Group Inc. All rights reserved.

Key words: Hepatitis C infection; Pregnancy; Vertical transmission; Antiviral therapy; Prevention

Core tip: Hepatitis C virus (HCV) infection during pregnancy is an emerging problem. While not negatively affecting acute hepatitis, it may exacerbate chronic hepatitis and worsen liver function in woman with liver cirrhosis. HCV does not affect delivery outcome apart from an increased risk of premature membrane rupture and cesarean delivery. The mother-to-child HCV transmission rate is low (3%-5%) and is related to high maternal viremia, human immunodeficiency virus (HIV) coinfection, prolonged rupture of membranes, vaginal lacerations and invasive fetal monitoring. Cesarean delivery and no breastfeeding are indicated for HIV/HCV coinfecting women. Antiviral therapy is not routinely offered to pregnant women and infants because of its side effects.

Tosone G, Maraolo AE, Mascolo S, Palmiero G, Tambaro O, Orlando R. Vertical hepatitis C virus transmission: Main questions and answers. *World J Hepatol* 2014; 6(8): 538-548 Available from: URL: <http://www.wjgnet.com/1948-5182/full/v6/i8/538>.

INTRODUCTION

Since its discovery in 1989, hepatitis C virus (HCV) has been recognized as a global public health problem that affects about 3% of the world's population (150-200 million people)^[1,2]. In the United States, almost 4 million people have been infected by the virus and more than half of these are estimated to have chronic hepatitis C^[3,4]. In most European countries, the prevalence of HCV in the general population ranges between 0.5% and 2% (*i.e.*, 5 to 10 million people)^[5]; the prevalence rate peaks in subjects between 40 and 59 years old^[1,3].

HCV infection can cause chronic hepatitis, liver cirrhosis and hepatocellular carcinoma (HCC). Acute HCV infection, which is asymptomatic in 50% to 90% of cases, can progress to chronic hepatitis in more than half of patients and can be associated with variable rates of fibrosis progression^[1,3]. About 10% to 20% of patients with chronic C hepatitis develop cirrhosis 20-30 years after contracting the infection. Patients with liver cirrhosis have a risk of about 1% to 5% of developing HCC^[1,3]. In addition, HCV can be associated with extra-hepatic complications such as lymphoma^[4,6]. Notably, HCV-related liver cirrhosis is the major cause of liver transplantation in developed countries^[1,3]. Unfortunately, the burden of liver cirrhosis, HCC and death related to HCV is expected to increase in the next few years^[6], although the incidence of acute infection is declining^[1,5].

HCV infection occurs after exposure to infected blood, through the parenteral and inapparent parenteral route^[7]. Injection drug use, unsafe medical practices, high-risk sexual practices and birth to an infected mother are the most frequent routes of infection^[3]. In most countries, only people with high risk behaviors are currently tested for HCV infection. However, the United States Center for Disease Control recommends HCV screening for all individuals born between 1945 and 1965 (irrespective of risk factors) because of the high prevalence of HCV infection in that birth cohort^[8].

Despite research conducted in the last 20 years, an effective vaccine against HCV has not yet been developed. On the contrary, antiviral therapies are now available that guarantee viral clearance (also called "sustained virological response") in a remarkable percentage of patients affected by chronic hepatitis C.

An emerging problem is HCV infection during pregnancy. In fact, the incidence of pregnancies and deliveries has increased (four-fold and between 5% and 10%, respectively) in women over the age of 40 years in most western countries, including the United States^[9,10]. Since these women are at a higher risk of HCV infection than younger women, physicians might have to treat an increasing number of HCV-infected pregnant women in the near future. The true size of the problem has not yet been defined; in fact, data related to the prevalence of

HCV infection in pregnant women are largely discordant. Between 1% to 2% of pregnant women in the United States and Europe have been estimated to be anti-HCV positive^[11-17] and more than 70% of them have HCV viremia^[12,13]. The prevalence is reported to be higher in pregnant women with high risk behaviors for blood-transmitted infections (*i.e.*, intravenous drug use, multiple sexual partners, co-infection with human immunodeficiency virus (HIV), or who live in developing countries)^[16-20]. Because HCV screening is recommended only for high risk subjects, a large number of infected women in the general population without classical risk behaviors or history of blood exposure eludes the screening strategy. Unfortunately, even in Italy, where a free-of-charge test for HCV, hepatitis B virus (HBV) and HIV is offered to all women from the 33th to the 37th week of pregnancy^[21], many women remain untested until delivery.

Here we review the clinical, prognostic and therapeutic aspects of HCV infection in pregnant women, as well as aspects of HCV vertical infection. Specifically, we address the following topics: (1) Can pregnancy worsen HCV-related disease? (2) Can HCV increase obstetrical complications? (3) What is the risk of transmitting HCV infection to the newborn and how is it prevented? (4) What is the course of HCV infection in the newborn? and (5) What are the benefits and risks of antiviral therapy for the mother and her child?

HCV INFECTION AND PREGNANCY: RECIPROCAL EFFECTS

During pregnancy, the maternal immune system undergoes various modifications that enable tolerance of the paternal alloantigens, therefore preventing anti-fetal immune aggression^[17,22,23]. In fact, consequent to these modifications, pregnant women experience a condition of immunological weakness that results in increased immunoglobulin production, a decreased T-cell mediated response (due to a shift in the Th1/Th2 balance toward the Th2 response) and expansion of regulatory T-cells^[22]. Also, sex hormones and immunosuppressive cytokines produced by pregnant women may concur to modulate the immune response to HCV^[22,23]. Pregnancy-associated immune modulation can also influence the immune response to HCV, thereby affecting both the maternal viral disease and mother-to-child transmission of the virus.

The innate immune system, through natural killer (NK) cells, also plays a role in modulating immune response to the virus. This process involves the interaction between the inhibitory NK cell receptor KIR2DL3, which belongs to the family of cell immunoglobulin-like receptors (KIR), and its human leukocyte antigen C group 1 (HLA-C1), which is an inhibitory receptor for self-MHC class I ligand. The effector functions of NK cells occur only when activating signals overcome inhibitory signals. Therefore, individuals with two copies of HLA-C1 alleles (HLA-C1C1) and homozygous for KIR2DL3 (which binds HLA-C1 with less affinity than

other inhibitory receptors) tend to resolve HCV infection. In these subjects, the weaker inhibitory receptor-ligand interaction is easily overridden by activating signals and results in a stronger activity of NK cells. This effect was demonstrated in Caucasians and African Americans with expected low infectious doses of HCV but not in those with high-dose exposure, in whom the innate immune response is likely to be overwhelmed^[24].

Question 1: Impact of pregnancy on maternal HCV-related disease

Acute hepatitis C has been rarely reported during pregnancy^[17,23,25]. Consequently, the data available are not sufficient to draw any conclusion about its course. The few reports available indicate that pregnant women with acute hepatitis C may have the same course and outcome as non-pregnant women, except for an increased risk of developing jaundice^[17,23,25].

Various studies have been carried out on women affected by chronic hepatitis C who become pregnant. The results showed that serum aminotransferase levels (ALT) decrease and reach normal range during the second and third trimester of pregnancy^[17,22,26,27]. The HCV viral load increases concomitant with the decrease in serum ALT and reaches a peak during the third trimester. These fluctuations, which are similar to those described in HBV-infected women during pregnancy^[28], were not found in another study^[23]. Only one study reported sustained clearance of HCV RNA during the second trimester of pregnancy^[29]. After delivery, restoration of the maternal immune system results in a better control of HCV replication. In fact, exacerbation of chronic hepatitis C, including rebound of ALT levels and worsening liver histopathology (Knodel score, portal necrosis, lobular degeneration and inflammation) were reported in the postpartum period, together with a reduction in the plasma HCV load. It is feasible that the decrease in ALT levels and the increased HCV viral load observed in the third trimester of pregnancy in women chronically infected with HCV could be due to a pregnancy-associated decline in immune-mediated hepatocellular destruction. Indeed, expansion of CD4⁺ CD25⁺ Treg cells begins early in gestation and reaches a peak in the second trimester. CD4⁺ CD25⁺ T regulatory cells may affect the clinical presentations of chronic HCV infection by suppressing CD4⁺ T cell responses. Le Campion *et al*^[22] and Bolacchi *et al*^[30] reported that the HCV-specific TGF- β response induced by CD4⁺ CD25⁺ (high) T cells was significantly greater in patients with a normal ALT level than in patients with abnormal ALT levels. This phenomenon is the hallmark of exacerbation of hepatic inflammation^[17,22] which, in some patients, can worsen the course of chronic hepatitis C^[31-35] but in a few cases it can be associated with viral clearance^[36], suggesting that postpartum may be an optimal time to start antiviral therapy in the attempt to achieve a sustained response.

HCV-infected pregnant women seem to develop cholestasis earlier and more frequently than anti-HCV-negative women. This phenomenon has been attributed

to altered transport of sulfated hormones in the liver, a failure in the transport of toxic substances, and a defect of the bile salt export pump^[16,23,37-41], but its pathogenesis is still being debated.

Lastly, HCV-infected women with advanced liver disease seem to be at a high risk of developing liver decompensation, which results in worsening of the portal hypertension and coagulopathy^[42-44]. Hence, pregnancy should be strongly discouraged in these women.

Question 2: Effect of HCV infection on pregnancy and delivery

Very few studies have investigated the impact of maternal hepatitis C infection on pregnancy outcome. Although it can be difficult to separate the role of HCV from other risk factors (*i.e.*, alcohol intake, tobacco smoking and drug abuse), the data available indicate an increased risk of gestational diabetes (reported in patients with excessive weight gain), premature membrane rupture and an increased rate of caesarean delivery in HCV-infected pregnant women than in anti-HCV-negative pregnant women^[16,17,22,45-47]. In addition, various obstetrical complications have been reported in HCV-infected women, namely, higher rates of preterm delivery, placental abruption, low birth weight, prematurity, low Apgar scores at 1 min, increased neonatal jaundice, congenital malformations and newborn perinatal mortality^[22,45,48]. However, these findings were not confirmed in other studies^[23, 49,50].

Question 3: Risk of mother-to-child HCV transmission and preventive measures

Numerous studies have evaluated the risk of mother-to-child HCV transmission (vertical transmission) with conflicting results. In fact, the rates of transmission varied from 0% to 30%^[11-20,22]. These large fluctuations are probably due to differences in study size (*e.g.*, the number of HCV-infected mothers enrolled), the study methodology (prospective or retrospective study; detection of maternal infection based on anti-HCV antibody positivity or on HCV RNA positivity) and the diagnostic criteria of neonatal HCV infection (*e.g.*, number of polymerase chain reactions performed and duration and timing of follow-up in the neonates)^[14,15]. The rate of HCV transmission is estimated to be lower^[14,15,17,23,51-57] than the rate of HBV and HIV transmission. However, unlike HIV-infected or HBV-infected pregnant women, no drugs or vaccines are available for HCV-infected pregnant women to reduce and/or prevent vertical transmission, which is the main cause of HCV infection in the pediatric setting^[15,22,51]. Thus, when a HCV-infected pregnant woman asks "How can I avoid infecting my child?", the answer is unfortunately, "we do not know".

The pathogenesis of vertical transmission, specifically the timing and route of transmission of the virus, and the host's defense mechanisms are unknown. The timing of vertical transmission is based on the appearance of HCV RNA positivity in the newborn: if a neonate tests HCV-RNA-positive at delivery or within the first 3 d of life, he/she was probably infected *in utero* (intrauterine

Table 1 Clinical factors and risk of vertical transmission

| |
|--|
| Associated with vertical transmission |
| Pregnant woman: |
| High HCV viral load |
| Elevated ALT levels before pregnancy |
| HIV-HCV co-infection <i>in vivo</i> drug abuse ¹ |
| Obstetric procedures: |
| Prolonged rupture of membranes vaginal and/or perineal lacerations |
| invasive monitoring of fetus intrauterine pressure catheter |
| amniocentesis (debated) |
| Father HCV infection ¹ |
| Fetus gender ¹ |
| Not associated with vertical transmission |
| Maternal HCV genotype |
| Mode of delivery ² |
| Breastfeeding ² |

¹To be confirmed; ²Except in the presence of HIV-HCV coinfection. HCV: Hepatitis C virus; HIV: Human immunodeficiency virus.

transmission); if a neonate who tests HCV-RNA-negative in the first 3 d of life becomes positive, he/she was probably infected in the *peripartum* or *postpartum* period (perinatal transmission)^[22,23]. The data available support both intrauterine^[23,58,59] and perinatal transmission^[22,23,53,60,61], the former accounting for 30% of cases and the latter for 40-50% of cases. Many sites of human placenta could act as HCV-receptors and/or entry cofactors (*e.g.*, claudin-1, occludin, SR-B1, LDLr or DC-SIGN)^[22,23]. Consequently, they could be directly implicated in HCV infection of placental cells. However, the rate of vertical transmission (3%-5%) seems to be lower than the potential biological exposure of fetus/neonate to maternal HCV. In fact, in the case of intrauterine transmission, although maternal HCV RNA has not been detected in amniotic fluid^[11], a very large amount of virus (1×10^{13} to 1×10^{14} virions) has been estimated to reach the placental bed during gestation^[11]. Therefore, the fetus could be exposed to free virions or to the cell-associated virus that crosses the placenta^[22] in a percentage higher than the reported transmission rate (30%)^[22,62]. Also, in the case of perinatal transmission, leakage of maternal HCV-infected blood into the fetal bloodstream and/or labor trauma (which exposes the offspring to maternal HCV-infected blood)^[15] occurs more frequently than vertical transmission of the virus (40%-50%)^[15,22].

The reason for the low rate of vertical transmission is not known. Various biological and immunological factors could protect the fetus against HCV infection, *i.e.*, placental immune cells, fetal cellular adaptive immunity, fetal plasma inflammatory markers, maternal HLA class II alleles and IL-28B genotype^[22,60,63-65], but their role is poorly understood. Also, the suggested association with gender (girls seem to be infected twice as often as boys) could reflect biological differences in susceptibility or in the response to infection^[66], although this has yet to be confirmed.

Many factors related to the status of pregnant women and delivery/obstetrical practices have been associated with an increased risk of transmission (Table 1)^[11,16,17,22,23].

The first factor is the mother's viral load, especially at the time of delivery. In fact, there is evidence that HCV-RNA-negative mothers have a low risk of infecting their infant, whereas this risk increases in HCV-RNA-positive mothers parallel to increases in levels of viral load above 10^5 IU/mL^[60,67] and reaches a maximum in women who have viremia levels above 10^7 IU/mL^[68]. Moreover, a high maternal serum ALT level in the 12 mo before conception and/or at the time of delivery has recently been associated with a higher rate of vertical transmission. In fact, a high ALT level is a hallmark of high viral replication in both the maternal bloodstream and in mononucleated blood cells^[22,54,55]. However, the effects of maternal HCV disease activity on vertical transmission are not completely understood. Lastly, HCV genotype is not considered a significant risk factor in terms of vertical HCV transmission^[22].

The second factor is HIV co-infection, which can cause a three-four fold increase of the risk of mother-to-child-transmission^[16,22,69]. How HIV-1 infection enhances the rate of HCV transmission is unclear. It is conceivable that HIV-1 infection facilitates HCV entry and replication in peripheral mononucleated blood cells^[16,22,69].

Moreover, HIV induces immune suppression, which can result in a less effective HCV-specific innate or cell-mediated maternal immune response at the maternal/fetal interface^[16,22]. On the other hand, HIV can infect trophoblasts, thereby compromising the integrity of the placenta and enhancing the passage of HCV through this barrier. HIV-associated chorioamnionitis could also induce placental microtransfusions through which HCV infection can be transmitted to the fetus^[22,69]. Lastly, anti-retroviral treatment of HIV/HCV co-infected pregnant women can dramatically lower the risk of HCV transmission from 19% to 8%^[16]. Additional risk factors, namely, intravenous drug abuse by the mother and concomitant HCV infection of the father, have been proposed but have yet to be confirmed^[16].

The main obstetrical factors associated with the risk of vertical transmission are prolonged rupture of membranes (more than 6 h before delivery), exposure of the fetus to maternal infected blood during vaginal delivery (consequent to vaginal and/or perineal lacerations) and invasive monitoring of the fetus with scalp electrodes or intrauterine pressure catheter placement^[11,16,22,60]. Amniocentesis may contribute to the risk of maternal-to-fetus transmission^[17,22], although its impact is still being debated^[17]. On the contrary, neither the delivery mode nor breastfeeding (two main concerns for the pregnant woman) appear to influence the risk of transmission^[11,16,17,22,66,70,71] in HCV-infected women. In fact, a cohort study of 1787 mother-child pairs showed that the rate of vertical HCV transmission was 6.2% and was not influenced by caesarean section^[66]. The failed protective effects of cesarean delivery was confirmed in a meta-analysis study^[72]. The issue of breastfeeding is more complex and needs to be discussed with the mother. In fact, although the amount of HCV in maternal milk and colostrum is very low and probably inactivated in the infant⁷

s digestive tract, the presence of cracked or bleeding nipples can be a contraindication to breastfeeding because it can expose the infant to contaminated milk. On the other hand, cesarean delivery must be recommended for HIV/HCV co-infected patients, associated with antiretroviral therapy to prevent or to reduce the risk of transmission of both viral agents^[54]. Vaginal delivery and breastfeeding are contraindicated in HIV/HCV co-infected mothers^[16,54,71,73].

Question 4: Outcome of HCV infection in the newborn

HCV infection is the most common cause of chronic hepatitis in childhood. The prevalence of pediatric infection seems to be very low in the United States and Europe (0.05%-0.36%), while it increases (1.8%-5.8%) in some developing countries and reaches its highest prevalence in Egypt, Sub-Saharan Africa, the Amazon Basin and Mongolia; the highest prevalence worldwide has been reported in Egypt (9% and up to 50% in certain rural areas)^[22,74]. Vertical or perinatal transmission is the most common route of pediatric HCV infection^[11] and can lead to an estimated 10000-60000 cases per year^[11].

At the time of delivery and during the first year of life, the anti-HCV positivity detected in the newborn can be due to the passive transfer of maternal antibodies. Therefore, the diagnosis of HCV infection based on antibody assays in children of HCV-infected mothers before the age of 12 mo is not reliable^[75]. The diagnosis can be made by testing neonates for HCV RNA, preferably 1 or 2 mo after birth^[76]. Indeed, the sensitivity of PCR for HCV RNA is about 22% at birth and increases to 70%-85% 1 mo after birth. Similarly, the predictive positive value of PCR testing is 33% at birth and reaches 78% when the child is 9 mo old^[77]. These findings could reflect the very low viral loads in the first month of age and/or the incubation period of HCV that ranges from 2 wk to 6 mo^[11]. Notably, a negative PCR test at birth/first month of age cannot exclude HCV infection and must be confirmed by further testing.

Spontaneous clearance of HCV has been reported in up to 25%-30% of HCV-infected children^[78,79] irrespective of the route of infection (vertical or parenteral transmission). However, the rate of chronicity seems to be higher in infants with perinatally acquired HCV infection than in infants infected by parenteral transmission^[80-83]. Various factors are associated with HCV clearance, namely, a younger age of the child, normal ALT levels^[84], the IL-28B genotype^[74] and IFN- γ responses against structural and non-structural recombinant HCV antigens^[85]. The clinical course of chronic HCV infection in childhood seems to differ from that in adulthood. Pediatric HCV infection is associated with minimal or mild liver disease. In fact, advanced liver damage is uncommon^[86-88], although another study suggested that fibrosis can be severe in children despite the relatively short duration of infection^[89]. Progression of liver damage in children depends on viral load, serum ALT levels, gender, ethnicity, obesity, toxins, environmental factors and co-morbid risk factors (hemolytic anemias, chemotherapy for malignancy, immu-

nosuppression and concomitant HIV or HBV infection) and genetic factors such as the IL-28B genotype^[90].

Differently from adults, data about the rate of progression from cirrhosis to HCC in childhood and early adolescence are scarce but it seems that HCC is rare in children with HCV infection^[91] and the number of HCV-infected children requiring liver transplantation is low in developed countries^[91]. Long-term studies are required to quantify the incidence of cirrhosis and HCC in adults who acquired hepatitis C infection by vertical transmission.

In childhood, membranoproliferative glomerulonephritis is one of the most frequent extra-hepatic manifestations of chronic HCV infection but, unlike adults, neither cryoglobulinemia nor lymphoma have been reported in children^[91]. The involvement of the central nervous system in HCV-infected children could explain the developmental delay, learning disorders and cognitive deficits that have been reported in some cases^[92,93].

Question 5: Antiviral therapy of hepatitis C in pregnant women and infants

The last, but not least, question regards the treatment of HCV infection in both the pregnant woman and the newborn. While some anti-HBV and anti-HIV drugs can be safely used to prevent or reduce the risk of vertical transmission, the two cornerstones of the standard-of-care treatment for HCV infection, namely, pegylated interferon (PEG IFN) and ribavirin (RBV), have several side effects or contraindications that limit their use during pregnancy and childhood^[11,16].

The problem of therapy in HCV-infected pregnant women is not negligible. In fact, in a United States study of 45690 HCV-infected patients, pregnancy was the third most common contraindication (1.9%) to treatment, after bipolar disorders (6.5%) and anemia (5.9%). In addition, about 1.3% of women became pregnant during a median follow up of 33 mo^[94]. Consequently, the concern is not only about the indication of antiviral therapy for pregnant women but also how to manage a woman who becomes pregnant during antiviral therapy. The answers to these issues are mainly based on limited clinical data. Recombinant interferon alpha is classified by the United States Food and Drug Administration in pregnancy category C. In fact, given its abortifacient effect in animals^[1], it could have the same effect in humans^[95,96] as PEG IFN^[97,98]. In fact, abortifacient effects have been observed in *Macaca mulatta* (rhesus monkeys) treated with interferon alpha-2b or alpha 2a during the early to middle fetal period of organogenesis (gestation day 22 to 70). Abortifacient activity was also observed in pregnant rhesus monkeys treated (500 times the human dosage) during late fetal development (days 79 to 100 of gestation). These drugs may impair fertility. In fact, in nonhuman primates, menstrual cycle irregularities, *i.e.*, prolonged or shortened menstrual periods and erratic bleeding (anovulatory cycle) have been observed and the females returned to a normal menstrual rhythm after discontinuation of therapy. Decreased serum estradiol and progesterone concentrations have been reported in

women treated with human leukocyte interferon. No mutagenic effects or toxicity has been reported. However, due to the species specificity of interferon, the effects in animals are unlikely to be predictive of those in man. Lastly, the injectable solution contains benzyl alcohol that can be transmitted *via* the placenta and could be toxic in premature infants. No effect on male fertility has been reported^[95,96]. No studies on the teratogenic effect of PEG-IFN are available. Since non-pegylated interferon alpha resulted in a statistically significant increase in abortions of Macaca, PEG-IFN should also be assumed to have abortifacient potential. There are no well-controlled studies in pregnant women^[97,98].

Nevertheless, in clinical practice, IFN- α is used to treat essential thrombocythemia in pregnant women to prevent or lower the risk of thrombocythemia-related fetal loss^[99]. A systematic review of data about pregnancies exposed to IFN- α (60% of women had received IFN throughout pregnancy) showed that IFN did not significantly increase the risk of major malformation, miscarriage, stillbirth or preterm delivery above the rates observed in the general population^[99]. Therefore, the treatment of HCV-infected pregnant women with IFN does not seem to entail a risk for the offspring. Data on PEG-IFN treatment during pregnancy are lacking. It is not known whether IFN is excreted in human milk. Given the potential for serious adverse reactions in nursing infants, a decision should be made whether to discontinue nursing or to discontinue the drug based on the importance of the drug for the mother. The main concern of IFN therapy is not only the risk for the fetus, but also the risk of serious psychiatric side effects, namely exacerbation of postpartum depression^[111]. Therefore, all pregnant women who are candidates for PEG-IFN must be carefully selected, also considering their psychological and psychiatric conditions.

The other drug available for HCV infection is RBV, which is classified by the USA Food and Drug Administration in pregnancy category X^[100,101]. Ribavirin is absolutely contraindicated, not only for HCV-infected pregnant and childbearing women, but also for HCV-infected men whose partners may become pregnant. These subjects are recommended to take contraceptive measures during RBV therapy because of its significant embryocidal and teratogenic effects^[11] in animals^[100-102]. Malformations of the skull, palate, eye, jaw, limbs, skeleton and gastrointestinal tract have been described in the offspring of female animals that have been directly exposed to the drug^[102]. In addition, RBV caused cell toxicity, mutagenicity and a decrease in the epididymal sperm count in all the animal species studied; these sperm cell mutations are believed to cause cell death or to be associated with infertility^[102].

In HCV-infected treated men, the RBV concentration was two-fold higher in seminal fluid than in serum^[103]. In addition, the round cell/spermatozoa ratio (suggestive of spermatogenic abnormality) and the sperm DNA fragmentation index were significantly higher in a HCV-infected man during RBV therapy and returned to base-

line levels only four and eight months, respectively, after treatment withdrawal^[104]. All these data indicate the need to avoid pregnancy for longer than the recommended 6 mo after discontinuing RBV treatment in men^[102].

Only a few cases of direct or indirect exposure to RBV have been reported in pregnant women and these resulted in healthy infants and no miscarriages or elective terminations^[102,105-110]. However, it is difficult to quantify the true risk of direct or indirect exposure to RBV. Consequently, a Ribavirin Pregnancy Registry was established in 2003 to monitor pregnancy exposure to RBV. Between 2003 and 2009, 118 live births from mothers exposed to RBV (49 direct and 69 indirect exposures) were recorded. Birth defects were reported only in 6 cases (3 direct and 3 indirect exposures): torticollis (2 cases), hypospadias (1 case), polydactyly and a neonatal tooth (1 case), glucose-6-phosphate dehydrogenase deficiency (1 case), ventricular septal defect, and cyst of the 4th ventricle of the brain (1 case). Although these preliminary results did not indicate that RBV exerts a teratogenic effect, it is not possible to draw conclusions about the risk of direct or indirect prenatal exposure to the drug in humans^[102].

More recently, new therapeutic approaches targeting essential components of the HCV life cycle have been developed, including the protease inhibitors (boceprevir, telaprevir) and polymerase inhibitor (sofosbuvir), indicated mainly for the treatment of chronic hepatitis C patients infected by genotype 1 virus.

Boceprevir and telaprevir are classified by the United States Food and Drug Administration in the Pregnancy Category B^[111,112]. In fact, although no adequate and well-controlled studies are available in humans, the absence of negative effects on fetal development in animals (mice, rats and rabbits) seems to indicate “no evidence of risk in humans”^[42], although the chance of fetal harm still remains possible. Boceprevir did not cause genotoxicity in *in vitro* or *in vivo* assays, including bacterial mutagenicity, chromosomal aberration in human peripheral blood lymphocytes and mouse micronucleus assays^[111]. Nevertheless, reversible effects on fertility and early embryonic development in female rats have been reported, as well as decreased fertility in male rats, most likely due to testicular degeneration. No effects on fetal development have been observed in rats or rabbits exposed to boceprevir at doses higher than the recommended dosage in humans^[111]. A clinical study showed the absence of testicular toxicity in humans^[107] at the recommended clinical dose, while a decrease in percent motile sperm and an increase in non-motile sperm count occurred in rats at exposures 0.3-fold the human recommended clinical dose^[111]. Telaprevir did not result in fetal harm in mice or rats. The effects on fertility parameters in rats (*e.g.*, decreased percent motile sperm and increased non-motile sperm count) may be associated with testicular toxicity in male animals. Telaprevir did not affect the birth body weight of rat offspring^[112].

Since these drugs cannot be used as monotherapy but have to be associated with PEG-IFN and RBV (triple therapy), their use is contraindicated during pregnancy

and childbearing females have to take adequate contraceptive measures. Similarly, the excretion of protease inhibitors into human breast milk is not known yet; in lactating rats, the levels of both boceprevir (or its metabolites) and telaprevir in the milk were slightly higher than levels observed in maternal blood^[111,112]. Because of the potential adverse reactions in infants, nursing must be discontinued prior to starting the treatment^[111,112].

The last licensed polymerase inhibitor (sofosbuvir^[11]) is classified by the United States Food and Drug Administration in the pregnancy category B. In this case also, adequate and well-controlled studies with the drug in pregnant women are missing but no effects on fetal development have been observed in rats and rabbits at the highest doses tested^[113]. Similarly, no data are available on the excretion of sofosbuvir and/or its metabolites in human breast milk; no data are available for the pediatric setting^[113]. When used in triple therapy (associated with PEG IFN and RBV), sofosbuvir is contraindicated as well as the protease inhibitors; when used in regimen IFN and RBV-free, it could be a promising option in the treatment for the pregnant women.

The therapy of HCV-infected infants is still being debated in the absence of a consensus on when or how to optimally treat. Because of the low rates of vertical transmission (overall between 3% and 5%) and the favorable course of hepatitis C (relatively high rate of spontaneous resolution of HCV infection, the lack of symptoms, *etc.*) in the first class of age, the rationale is to only treat the child with chronic hepatitis C at high risk of progression^[11]. A previous meta-analysis showed that children had a higher SVR and tolerated IFN alpha monotherapy better than adults^[114]. In contrast, there are few pediatric trials on the standard of care therapy; a systematic review of 4 randomized controlled trials and 31 non-randomized studies showed that children had an SVR similar to adults^[115]. The standard of care therapy seemed to be well tolerated in the large majority of children; the main adverse effects (*i.e.*, flu-like symptoms and neutropenia) were mild or moderate. The rate of treatment discontinuation was low but half of the children required a reduction of PEG-IFN dosage^[115].

The decision of when to start antiviral therapy in the early ages must be based on several factors: the estimated/known duration of infection, HCV genotype, presence/degree of fibrosis, co-morbidities, predicted parents' compliance with the therapy, expected adverse events and possible interference with home life or school activities and the IL-28 genotype^[111]. Injectable solutions of IFN contain benzyl alcohol and are not indicated for use in neonates or infants because of reports of death in neonates and infants exposed to excessive doses of benzyl alcohol^[91-94].

It has been suggested that treatment with weight-adjusted doses of PEG-IFN and RBV should be offered to HCV-infected children over 2 years old and with significant hepatic fibrosis (detected by liver biopsy or transient elastography), irrespective of HCV genotype^[116]. Moreover, such treatment should be avoided in children under

2 years of age because of the risk of PEG-IFN-related neurotoxicity^[115] and growth suppression described in older children^[11,116]. In fact, PEG IFN- α -2a has an inhibitory effect^[1] on children's growth. A study of 31 Japanese children showed that the Z-scores of height and body weight decreased during treatment and, although they improved after withdrawal, they were significantly lower than pre-treatment scores. This growth inhibitory effect was smaller in children aged 10 years and older^[116].

Antiviral therapy for hepatitis C can be routinely offered to all HCV-infected newborns only when new drugs with a well demonstrated long-term safety profile become available^[11], but at the moment both the safety and effectiveness of protease or polymerase inhibitors in pediatric patients have not been established.

CONCLUSION

The problem of HCV infection in pregnancy is still a matter of concern. The first concern is the possible impact of HCV infection on the mother's health during pregnancy and in the postpartum period due to the intense physiological changes and the virus/host interaction that characterize this period. Pregnancy-associated immune modulation affects the immune response against HCV because it leads to immune tolerance during pregnancy and immune restoration immediately after delivery. This phenomenon does not seem to impact negatively on liver disease in most pregnant women but may worsen liver function in some cases. Differently, childbearing women with HCV-related liver cirrhosis are at high risk of liver decompensation during pregnancy.

The second concern is the impact of HCV on delivery outcome. HCV-infected women may have an increased risk for premature membrane rupture and for cesarean delivery but there is no evident risk for complications for offspring.

The main concern is that HCV-infected women may transmit the infection to their offspring during pregnancy, upon delivery or during breastfeeding. The overall rate of vertical transmission is low (3%-5%) but the risk is higher for women with high viremia or HIV co-infection and in the case of exposure of the neonate to infected blood (*i.e.*, during prolonged rupture of membranes or vaginal lacerations and consequent to invasive monitoring of the fetus during pregnancy). Cesarean delivery, which limits the exposure to vaginal/perineal lacerations, was formerly suggested to avoid this risk of transmission.

However, it is currently recommended only for HIV/HCV coinfecting women. The problem of breastfeeding is complex and must be discussed with the woman. In fact, the risk is not due to milk or colostrum (which contain a very low amount of virus and can be inactivated in the infant's digestive tract) but to contamination by infected blood through damaged or cracked nipples. HIV/HCV co-infected pregnant women are recommended to avoid vaginal delivery and breastfeeding because of the high risk of infecting their offspring.

The last concern is antiviral therapy. Currently, the

consensus is not to routinely offer antiviral therapy to all HCV-infected pregnant women and HCV-infected offspring. Given the side effects of the drugs available in these settings, candidates for therapy must be carefully selected based on the benefits of therapy and the severity of the disease. The ideal solution would be to encourage young women infected with HCV to start and complete therapy before pregnancy in order to lower or clear the virus and so reduce the risk of vertical transmission. Another strategy would be to start treatment postpartum and to avoid breastfeeding.

In the childhood setting, the standard of care therapy should be started only after the second year of life, except in cases that require immediate treatment to avoid rapid progression of liver disease.

The recently approved new generation drugs (protease and polymerase inhibitors) for the treatment of HCV infection have opened a new perspective in HCV therapy for pregnant women and infected infants since one of these agents, *i.e.*, sofosbuvir, has been reported to also be effective in IFN-free and RBV-free regimens.

REFERENCES

- Available from: URL: <http://www.who.int/mediacentre/factsheets/fs312/en/index.html>
- Shepard CW, Finelli L, Alter MJ. Global epidemiology of hepatitis C virus infection. *Lancet Infect Dis* 2005; **5**: 558-567 [PMID: 16122679 DOI: 10.1016/S1473-3099(05)70216-4]
- NIH Consensus Statement on Management of Hepatitis C: 2002. *NIH Consens State Sci Statements* 2002; **19**: 1-46 [PMID: 14768714]
- Armstrong GL, Wasley A, Simard EP, McQuillan GM, Kuhner WL, Alter MJ. The prevalence of hepatitis C virus infection in the United States, 1999 through 2002. *Ann Intern Med* 2006; **144**: 705-714 [PMID: 16702586 DOI: 10.7326/0003-4819-144-10-200605160-00004]
- WHO. Global Alert and Response (GAR). Letter: Hepatitis C virus. Available from: URL: <http://www.who.int/csr/disease/hepatitis/whodcscrlyo2003/en/index4.html>
- Kim WR. The burden of hepatitis C in the United States. *Hepatology* 2002; **36**: S30-S34 [PMID: 12407574 DOI: 10.1053/jhep.2002.36791]
- Piazza M, Cacciato L, Molinari V, Picciotto L. Letter: Hepatitis B not transmissible via faecal-oral route. *Lancet* 1975; **2**: 706 [PMID: 52076]
- Smith BD, Morgan RL, Beckett GA, Falck-Ytter Y, Holtzman D, Ward JW. Hepatitis C virus testing of persons born during 1945-1965: recommendations from the Centers for Disease Control and Prevention. *Ann Intern Med* 2012; **157**: 817-822 [PMID: 22910836 DOI: 10.7326/0003-4819-157-9-201211060-00529]
- Orsini LF, Sansavini S, Fratto R, Bolletta M. Gravidanza oltre i 40 anni: rischi materni. *Riv It Ost Gin* 2008; **19**: 862-864
- Walker KF, Bugg G, Macpherson M, McCormick C, Wildsmith C, Smith G, Thornton J. Induction of labour versus expectant management for nulliparous women over 35 years of age: a multi-centre prospective, randomised controlled trial. *BMC Pregnancy Childbirth* 2012; **12**: 145 [PMID: 23231750 DOI: 10.1186/1471-2393-12-145]
- Arshad M, El-Kamary SS, Jhaveri R. Hepatitis C virus infection during pregnancy and the newborn period--are there opportunities for treatment? *J Viral Hepat* 2011; **18**: 229-236 [PMID: 21392169 DOI: 10.1111/j.1365-2893.2010.01413.x]
- Ward C, Tudor-Williams G, Cotzias T, Hargreaves S, Regan L, Foster GR. Prevalence of hepatitis C among pregnant women attending an inner London obstetric department: uptake and acceptability of named antenatal testing. *Gut* 2000; **47**: 277-280 [PMID: 10896922 DOI: 10.1136/gut.47.2.277]
- Conte D, Fraquelli M, Prati D, Colucci A, Minola E. Prevalence and clinical course of chronic hepatitis C virus (HCV) infection and rate of HCV vertical transmission in a cohort of 15,250 pregnant women. *Hepatology* 2000; **31**: 751-755 [PMID: 10706568 DOI: 10.1002/hep.510310328]
- Yeung LT, King SM, Roberts EA. Mother-to-infant transmission of hepatitis C virus. *Hepatology* 2001; **34**: 223-229 [PMID: 11481604 DOI: 10.1053/jhep.2001.25885]
- Thomas SL, Newell ML, Peckham CS, Ades AE, Hall AJ. A review of hepatitis C virus (HCV) vertical transmission: risks of transmission to infants born to mothers with and without HCV viraemia or human immunodeficiency virus infection. *Int J Epidemiol* 1998; **27**: 108-117 [PMID: 9563703 DOI: 10.1093/ije/27.1.108]
- Valladares G, Chacaltana A, Sjogren MH. The management of HCV-infected pregnant women. *Ann Hepatol* 2010; **9** Suppl: 92-97 [PMID: 20714003]
- Prasad MR, Honegger JR. Hepatitis C virus in pregnancy. *Am J Perinatol* 2013; **30**: 149-159 [PMID: 23389935 DOI: 10.1055/s-0033-1334459]
- Zahran KM, Badary MS, Agban MN, Abdel Aziz NH. Pattern of hepatitis virus infection among pregnant women and their newborns at the Women's Health Center of Assiut University, Upper Egypt. *Int J Gynaecol Obstet* 2010; **111**: 171-174 [PMID: 20708181 DOI: 10.1016/j.ijgo.2010.06.013]
- Stoszek SK, Abdel-Hamid M, Narooz S, El Daly M, Saleh DA, Mikhail N, Kassem E, Hawash Y, El Kafrawy S, Said A, El Batany M, Shebl FM, Sayed M, Sharaf S, Fix AD, Strickland GT. Prevalence of and risk factors for hepatitis C in rural pregnant Egyptian women. *Trans R Soc Trop Med Hyg* 2006; **100**: 102-107 [PMID: 16289168 DOI: 10.1016/j.trstmh.2005.05.021]
- Aziz S, Hossain N, Karim SA, Rajper J, Soomro N, Noorulain W, Qamar R, Khanani R. Vertical transmission of hepatitis C virus in low to middle socio-economic pregnant population of Karachi. *Hepatol Int* 2011; **5**: 677-680 [PMID: 21484109 DOI: 10.1007/s12072-010-9229-8]
- Gazzetta Ufficiale Repubblica Italiana. Serie generale n.245 del 20.10.1998
- Le Campion A, Larouche A, Fauteux-Daniel S, Soudeyns H. Pathogenesis of hepatitis C during pregnancy and childhood. *Viruses* 2012; **4**: 3531-3550 [PMID: 23223189 DOI: 10.3390/v4123531]
- Floreani A. Hepatitis C and pregnancy. *World J Gastroenterol* 2013; **19**: 6714-6720 [PMID: 24187446 DOI: 10.3748/wjg.v19.i40.6714]
- Khakoo SI, Thio CL, Martin MP, Brooks CR, Gao X, Astemborski J, Cheng J, Goedert JJ, Vlahov D, Hilgartner M, Cox S, Little AM, Alexander GJ, Cramp ME, O'Brien SJ, Rosenberg WM, Thomas DL, Carrington M. HLA and NK cell inhibitory receptor genes in resolving hepatitis C virus infection. *Science* 2004; **305**: 872-874 [PMID: 15297676]
- Gonzalez F, Medam-Djomo MA, Lucidarme D, Khalil A, Decoster A, Houze de l'Aulnoit D, Filoche B. Acute hepatitis C during the third trimester of pregnancy. *Gastroenterol Clin Biol* 2006; **30**: 786-789 [PMID: 16801905]
- Gervais A, Bacq Y, Bernuau J, Martinot M, Auperin A, Boyer N, Kilani A, Erlinger S, Valla D, Marcellin P. Decrease in serum ALT and increase in serum HCV RNA during pregnancy in women with chronic hepatitis C. *J Hepatol* 2000; **32**: 293-299 [PMID: 10707870 DOI: 10.1016/S0168-8278(00)80075-6]
- Paternoster DM, Santarossa C, Grella P, Palù G, Baldo V, Boccagni P, Floreani A. Viral load in HCV RNA-positive pregnant women. *Am J Gastroenterol* 2001; **96**: 2751-2754 [PMID: 11569706 DOI: 10.1111/j.1572-0241.2001.04135.x]
- ter Borg MJ, Leemans WF, de Man RA, Janssen HL. Exacerbation of chronic hepatitis B infection after delivery. *J*

- Viral Hepat* 2008; **15**: 37-41 [PMID: 18088243 DOI: 10.1111/j.1365-2893.2007.00894.x]
- 29 **Zein CO**, Abu-Lebdeh H, Zein NN. Spontaneous clearance of chronic hepatitis C during pregnancy. *Am J Gastroenterol* 2001; **96**: 3044-3045 [PMID: 11693357 DOI: 10.1111/j.1572-0241.2001.04697.x]
- 30 **Bolacchi F**, Sinistro A, Ciapriani C, Demin F, Capozzi M, Carducci FC, Drapeau CM, Rocchi G, Bergamini A. Increased hepatitis C virus (HCV)-specific CD4+CD25+ regulatory T lymphocytes and reduced HCV-specific CD4+ T cell response in HCV-infected patients with normal versus abnormal alanine aminotransferase levels. *Clin Exp Immunol* 2006; **144**: 188-196 [PMID: 16634790]
- 31 **Jabeen T**, Cannon B, Hogan J, Crowley M, Devereux C, Fanning L, Kenny-Walsh E, Shanahan F, Whelton MJ. Pregnancy and pregnancy outcome in hepatitis C type 1b. *QJM* 2000; **93**: 597-601 [PMID: 10984554 DOI: 10.1093/qjmed/93.9.597]
- 32 **Fontaine H**, Nalpas B, Carnot F, Bréchet C, Pol S. Effect of pregnancy on chronic hepatitis C: a case-control study. *Lancet* 2000; **356**: 1328-1329 [PMID: 11073028 DOI: 10.1016/S0140-6736(00)02823-3]
- 33 **Vento S**, Longhi MS, Cainelli F, Concia E. Effect of pregnancy on chronic hepatitis C. *Lancet* 2001; **357**: 389-390 [PMID: 11211018 DOI: 10.1016/S0140-6736(05)71517-8]
- 34 **Oketani M**, Shibata T, Yamashita K, Arima T, Arima T. Postpartum acute exacerbation of chronic hepatitis C with complete response to interferon-alpha. *J Gastroenterol* 2002; **37**: 658-662 [PMID: 12203084 DOI: 10.1007/s005350200105]
- 35 **Latt NC**, Spencer JD, Beeby PJ, McCaughan GW, Saunders JB, Collins E, Cossart YE. Hepatitis C in injecting drug-using women during and after pregnancy. *J Gastroenterol Hepatol* 2000; **15**: 175-181 [PMID: 10735542 DOI: 10.1046/j.1440-1746.2000.02060.x]
- 36 **Hattori Y**, Orito E, Ohno T, Sugauchi F, Suzuki S, Sugiura M, Suzumori K, Hattori K, Ueda R, Mizokami M. Loss of hepatitis C virus RNA after parturition in female patients with chronic HCV infection. *J Med Virol* 2003; **71**: 205-211 [PMID: 12938194 DOI: 10.1002/jmv.10471]
- 37 **Ropponen A**, Sund R, Riikonen S, Ylikorkala O, Aittomäki K. Intrahepatic cholestasis of pregnancy as an indicator of liver and biliary diseases: a population-based study. *Hepatology* 2006; **43**: 723-728 [PMID: 16557542 DOI: 10.1002/hep.21111]
- 38 **Locatelli A**, Roncaglia N, Arreghini A, Bellini P, Vergani P, Ghidini A. Hepatitis C virus infection is associated with a higher incidence of cholestasis of pregnancy. *Br J Obstet Gynaecol* 1999; **106**: 498-500 [PMID: 10430202 DOI: 10.1111/j.1471-0528.1999.tb08305.x]
- 39 **Paternoster DM**, Fabris F, Palù G, Santarossa C, Braccianti R, Snijders D, Floreani A. Intra-hepatic cholestasis of pregnancy in hepatitis C virus infection. *Acta Obstet Gynecol Scand* 2002; **81**: 99-103 [PMID: 11942897 DOI: 10.1034/j.1600-0412.2002.810202.x]
- 40 **Hinoshita E**, Taguchi K, Inokuchi A, Uchiumi T, Kinukawa N, Shimada M, Tsuneyoshi M, Sugimachi K, Kuwano M. Decreased expression of an ATP-binding cassette transporter, MRP2, in human livers with hepatitis C virus infection. *J Hepatol* 2001; **35**: 765-773 [PMID: 11738104]
- 41 **Iwata R**, Baur K, Stieger B, Mertens JC, Daly AK, Frei P, Braun J, Vergopoulos A, Stickel F, Sabrane K, Martin IV, Schmitt J, Goetze O, Day CP, Müllhaupt B, Geier A. A common polymorphism in the ABCB11 gene is associated with advanced fibrosis in hepatitis C but not in non-alcoholic fatty liver disease. *Clin Sci (Lond)* 2011; **120**: 287-296 [PMID: 20883210 DOI: 10.1042/CS20100246]
- 42 **García Ferrera WO**, López Menéndez J. [Hepatitis c and pregnancy]. *Rev Gastroenterol Peru* 2007; **27**: 275-282 [PMID: 17934534]
- 43 **Britton RC**. Pregnancy and esophageal varices. *Am J Surg* 1982; **143**: 421-425 [PMID: 6978619]
- 44 **Cheng YS**. Pregnancy in liver cirrhosis and/or portal hypertension. *Am J Obstet Gynecol* 1977; **128**: 812-822 [PMID: 327818]
- 45 **Pergam SA**, Wang CC, Gardella CM, Sandison TG, Phipps WT, Hawes SE. Pregnancy complications associated with hepatitis C: data from a 2003-2005 Washington state birth cohort. *Am J Obstet Gynecol* 2008; **199**: 38.e1-38.e9 [PMID: 18486089 DOI: 10.1016/j.ajog.2008.03.052]
- 46 **Buresi MC**, Lee J, Gill S, Kong JM, Money DM, Yoshida EM. The prevalence of gestational diabetes mellitus and glucose abnormalities in pregnant women with hepatitis C virus infection in British Columbia. *J Obstet Gynaecol Can* 2010; **32**: 935-941 [PMID: 21176301]
- 47 **Reddick KL**, Jhaveri R, Gandhi M, James AH, Swamy GK. Pregnancy outcomes associated with viral hepatitis. *J Viral Hepat* 2011; **18**: e394-e398 [PMID: 21692952 DOI: 10.1111/j.1365-2893.2011.01436.x]
- 48 **Connell LE**, Salihu HM, Salemi JL, August EM, Weldelesasse H, Mbah AK. Maternal hepatitis B and hepatitis C carrier status and perinatal outcomes. *Liver Int* 2011; **31**: 1163-1170 [PMID: 21745298 DOI: 10.1111/j.1478-3231.2011.02556.x]
- 49 **Granovsky MO**, Minkoff HL, Tess BH, Waters D, Hatzakis A, Devoid DE, Landesman SH, Rubinstein A, Di Bisceglie AM, Goedert JJ. Hepatitis C virus infection in the mothers and infants cohort study. *Pediatrics* 1998; **102**: 355-359 [PMID: 9685438]
- 50 **Delotte J**, Barjoan EM, Berrébi A, Laffont C, Benos P, Pradier C, Bongain A. Obstetric management does not influence vertical transmission of HCV infection: results of the ALHICE group study. *J Matern Fetal Neonatal Med* 2014; **27**: 664-670 [PMID: 23971940 DOI: 10.3109/14767058.2013.829813]
- 51 **Zanetti AR**, Tanzi E, Newell ML. Mother-to-infant transmission of hepatitis C virus. *J Hepatol* 1999; **31** Suppl 1: 96-100 [PMID: 10622569]
- 52 **Tovo PA**, Palomba E, Ferraris G, Principi N, Ruga E, Dallacasa P, Maccabruni A. Increased risk of maternal-infant hepatitis C virus transmission for women coinfecting with human immunodeficiency virus type 1. Italian Study Group for HCV Infection in Children. *Clin Infect Dis* 1997; **25**: 1121-1124 [PMID: 9402369 DOI: 10.1086/516102]
- 53 **Gibb DM**, Goodall RL, Dunn DT, Healy M, Neave P, Cafferkey M, Butler K. Mother-to-child transmission of hepatitis C virus: evidence for preventable peripartum transmission. *Lancet* 2000; **356**: 904-907 [PMID: 11036896 DOI: 10.1016/S0140-6736(00)02681-7]
- 54 **European Paediatric Hepatitis C Virus Network**. Effects of mode of delivery and infant feeding on the risk of mother-to-child transmission of hepatitis C virus. European Paediatric Hepatitis C Virus Network. *BJOG* 2001; **108**: 371-377 [PMID: 11305543 DOI: 10.1111/j.1471-0528.2001.00088.x]
- 55 **Hayashida A**, Inaba N, Oshima K, Nishikawa M, Shoda A, Hayashida S, Negishi M, Inaba F, Inaba M, Fukasawa I, Watanabe H, Takamizawa H. Re-evaluation of the true rate of hepatitis C virus mother-to-child transmission and its novel risk factors based on our two prospective studies. *J Obstet Gynaecol Res* 2007; **33**: 417-422 [PMID: 17688606 DOI: 10.1111/j.1447-0756.2007.00582.x]
- 56 **Sood A**, Midha V, Bansal M, Sood N, Puri S, Thara A. Perinatal transmission of hepatitis C virus in northern India. *Indian J Gastroenterol* 2012; **31**: 27-29 [PMID: 22362316 DOI: 10.1007/s12664-012-0163-7]
- 57 **Parthiban R**, Shanmugam S, Velu V, Nandakumar S, Dhevahi E, Thangaraj K, Nayak HK, Gupte MD, Thyagarajan SP. Transmission of hepatitis C virus infection from asymptomatic mother to child in southern India. *Int J Infect Dis* 2009; **13**: e394-e400 [PMID: 19376736 DOI: 10.1016/j.ijid.2009.01.013]
- 58 **Resti M**, Azzari C, Mannelli F, Moriondo M, Novembre E, de Martino M, Vierucci A. Mother to child transmission of hepatitis C virus: prospective study of risk factors and timing of infection in children born to women seronegative for HIV-1. Tuscany Study Group on Hepatitis C Virus Infec-

- tion. *BMJ* 1998; **317**: 437-441 [PMID: 9703524 DOI: 10.1136/bmj.317.7156.437]
- 59 **Mok J**, Pembrey L, Tovo PA, Newell ML. When does mother to child transmission of hepatitis C virus occur? *Arch Dis Child Fetal Neonatal Ed* 2005; **90**: F156-F160 [PMID: 15724041 DOI: 10.1136/adc.2004.059436]
 - 60 **Babik JM**, Cohan D, Monto A, Hartigan-O'Connor DJ, McCune JM. The human fetal immune response to hepatitis C virus exposure in utero. *J Infect Dis* 2011; **203**: 196-206 [PMID: 21288819 DOI: 10.1093/infdis/jiq044]
 - 61 **Steininger C**, Kundi M, Jatzko G, Kiss H, Lischka A, Holzmann H. Increased risk of mother-to-infant transmission of hepatitis C virus by intrapartum infantile exposure to maternal blood. *J Infect Dis* 2003; **187**: 345-351 [PMID: 12552417 DOI: 10.1086/367704]
 - 62 **Spencer JD**, Latt N, Beeby PJ, Collins E, Saunders JB, McCaughan GW, Cossart YE. Transmission of hepatitis C virus to infants of human immunodeficiency virus-negative intravenous drug-using mothers: rate of infection and assessment of risk factors for transmission. *J Viral Hepat* 1997; **4**: 395-409 [PMID: 9430360 DOI: 10.1046/j.1365-2893.1997.00073.x]
 - 63 **Ruiz-Extremera A**, Muñoz-Gómez JA, Salmerón-Ruiz MA, de Rueda PM, Quiles-Pérez R, Gila-Medina A, Casado J, Belén Martín A, Sanjuan-Núñez L, Carazo A, Pavón EJ, Ocete-Hita E, León J, Salmerón J. Genetic variation in interleukin 28B with respect to vertical transmission of hepatitis C virus and spontaneous clearance in HCV-infected children. *Hepatology* 2011; **53**: 1830-1838 [PMID: 21413051 DOI: 10.1002/hep.24298]
 - 64 **Bevilacqua E**, Fabris A, Floreano P, Pembrey L, Newell ML, Tovo PA, Amoroso A. Genetic factors in mother-to-child transmission of HCV infection. *Virology* 2009; **390**: 64-70 [PMID: 19481774 DOI: 10.1016/j.virol.2009.05.007]
 - 65 **Azzari C**, Indolfi G, Betti L, Moriondo M, Massai C, Becciolini L, Bertelli L, Poggi GM, De Martino M, Resti M. Vertical hepatitis C virus transmission is not related to mother-child class-1 HLA concordance. *Int J Immunopathol Pharmacol* 2007; **20**: 827-831 [PMID: 18179755]
 - 66 **European Paediatric Hepatitis C Virus Network**. A significant sex--but not elective cesarean section--effect on mother-to-child transmission of hepatitis C virus infection. *J Infect Dis* 2005; **192**: 1872-1879 [PMID: 16267757 DOI: 10.1086/497695]
 - 67 **Mast EE**, Hwang LY, Seto DS, Nolte FS, Nainan OV, Wurtzel H, Alter MJ. Risk factors for perinatal transmission of hepatitis C virus (HCV) and the natural history of HCV infection acquired in infancy. *J Infect Dis* 2005; **192**: 1880-1889 [PMID: 16267758 DOI: 10.1086/497701]
 - 68 **Dal Molin G**, D'Agaro P, Ansaldi F, Ciana G, Fertz C, Alberico S, Campello C. Mother-to-infant transmission of hepatitis C virus: rate of infection and assessment of viral load and IgM anti-HCV as risk factors. *J Med Virol* 2002; **67**: 137-142 [PMID: 11992574 DOI: 10.1002/jmv.2202]
 - 69 **Polis CB**, Shah SN, Johnson KE, Gupta A. Impact of maternal HIV coinfection on the vertical transmission of hepatitis C virus: a meta-analysis. *Clin Infect Dis* 2007; **44**: 1123-1131 [PMID: 17366462 DOI: 10.1086/512815]
 - 70 **McIntyre PG**, Tosh K, McGuire W. Caesarean section versus vaginal delivery for preventing mother to infant hepatitis C virus transmission. *Cochrane Database Syst Rev* 2006; **(4)**: CD005546 [PMID: 17054264 DOI: 10.1002/14651858.CD005546.pub2]
 - 71 **Mast EE**. Mother-to-infant hepatitis C virus transmission and breastfeeding. *Adv Exp Med Biol* 2004; **554**: 211-216 [PMID: 15384578 DOI: 10.1007/978-1-4757-4242-8_18]
 - 72 **Ghamar Chehreh ME**, Tabatabaei SV, Khazanehdari S, Alavian SM. Effect of cesarean section on the risk of perinatal transmission of hepatitis C virus from HCV-RNA+/HIV-mothers: a meta-analysis. *Arch Gynecol Obstet* 2011; **283**: 255-260 [PMID: 20652289 DOI: 10.1007/s00404-010-1588-9]
 - 73 **Pembrey L**, Newell ML, Tovo PA. The management of HCV infected pregnant women and their children European paediatric HCV network. *J Hepatol* 2005; **43**: 515-525 [PMID: 16144064 DOI: 10.1016/j.jhep.2005.06.002]
 - 74 **El-Shabrawi MH**, Kamal NM. Burden of pediatric hepatitis C. *World J Gastroenterol* 2013; **19**: 7880-7888 [PMID: 24307782 DOI: 10.3748/wjg.v19.i44.7880]
 - 75 **Recommendations for prevention and control of hepatitis C virus (HCV) infection and HCV-related chronic disease**. Centers for Disease Control and Prevention. *MMWR Recomm Rep* 1998; **47**: 1-39 [PMID: 9790221]
 - 76 **Centers for Disease Control and Prevention**. Recommendations for the identification of chronic hepatitis C virus infection among persons born during 1945-1965. *MMWR* 2012; **61** (RR-4): 2-36. Available from: URL: <http://www.cdc.gov/mmwr/preview/mmwrhtml/rr6104a1.htm>
 - 77 **Polywka S**, Pembrey L, Tovo PA, Newell ML. Accuracy of HCV-RNA PCR tests for diagnosis or exclusion of vertically acquired HCV infection. *J Med Virol* 2006; **78**: 305-310 [PMID: 16372293 DOI: 10.1002/jmv.20540]
 - 78 **Yeung LT**, To T, King SM, Roberts EA. Spontaneous clearance of childhood hepatitis C virus infection. *J Viral Hepat* 2007; **14**: 797-805 [PMID: 17927616 DOI: 10.1111/j.1365-2893.2007.00873.x]
 - 79 **Farmand S**, Wirth S, Löffler H, Woltering T, Kenzel S, Lainka E, Henneke P. Spontaneous clearance of hepatitis C virus in vertically infected children. *Eur J Pediatr* 2012; **171**: 253-258 [PMID: 21735055 DOI: 10.1007/s00431-011-1517-3]
 - 80 **Resti M**, Jara P, Hierro L, Azzari C, Giachino R, Zuin G, Zancan L, Pedditi S, Bortolotti F. Clinical features and progression of perinatally acquired hepatitis C virus infection. *J Med Virol* 2003; **70**: 373-377 [PMID: 12766999 DOI: 10.1002/jmv.10405]
 - 81 **Tovo PA**, Pembrey LJ, Newell ML. Persistence rate and progression of vertically acquired hepatitis C infection. European Paediatric Hepatitis C Virus Infection. *J Infect Dis* 2000; **181**: 419-424 [PMID: 10669321 DOI: 10.1086/315264]
 - 82 **Alter HJ**, Seeff LB. Recovery, persistence, and sequelae in hepatitis C virus infection: a perspective on long-term outcome. *Semin Liver Dis* 2000; **20**: 17-35 [PMID: 10895429 DOI: 10.1055/s-2000-9505]
 - 83 **Vogt M**, Lang T, Frösner G, Klingler C, Sendl AF, Zeller A, Wiebecke B, Langer B, Meisner H, Hess J. Prevalence and clinical outcome of hepatitis C infection in children who underwent cardiac surgery before the implementation of blood-donor screening. *N Engl J Med* 1999; **341**: 866-870 [PMID: 10498458 DOI: 10.1056/NEJM199909163411202]
 - 84 **Simanis R**, Lejniece S, Sochnevs A, Eglite J, Chernevska G, Kovalova Z, Gardovska D, Jeruma A, Kuse V, Viksna L. Natural clearance of hepatitis C virus in hemophilia patients. *Medicina (Kaunas)* 2008; **44**: 15-21 [PMID: 18277084]
 - 85 **El-Kamary SS**, Hashem M, Saleh DA, Abdelwahab SF, Sobhy M, Shebl FM, Shardell MD, Strickland GT, Shata MT. Hepatitis C virus-specific cell-mediated immune responses in children born to mothers infected with hepatitis C virus. *J Pediatr* 2013; **162**: 148-154 [PMID: 22883419 DOI: 10.1016/j.jpeds.2012.06.057]
 - 86 **European Paediatric Hepatitis C Virus Network**. Three broad modalities in the natural history of vertically acquired hepatitis C virus infection. *Clin Infect Dis* 2005; **41**: 45-51 [PMID: 15937762 DOI: 10.1086/430601]
 - 87 **Jonas MM**. Children with hepatitis C. *Hepatology* 2002; **36**: S173-S178 [PMID: 12407591 DOI: 10.1053/jhep.2002.36799]
 - 88 **Palomba E**, Manzini P, Fiammengio P, Maderni P, Saracco G, Tovo PA. Natural history of perinatal hepatitis C virus infection. *Clin Infect Dis* 1996; **23**: 47-50 [PMID: 8816128 DOI: 10.1093/clinids/23.1.47]
 - 89 **Badizadegan K**, Jonas MM, Ott MJ, Nelson SP, Perez-Atayde AR. Histopathology of the liver in children with chronic hepatitis C viral infection. *Hepatology* 1998; **28**: 1416-1423 [PMID: 9794930 DOI: 10.1002/hep.510280534]
 - 90 **Maasoumy B**, Wedemeyer H. Natural history of acute and

- chronic hepatitis C. *Best Pract Res Clin Gastroenterol* 2012; **26**: 401-412 [PMID: 23199500 DOI: 10.1016/j.bpg.2012.09.009]
- 91 **Mack CL**, Gonzalez-Peralta RP, Gupta N, Leung D, Narkewicz MR, Roberts EA, Rosenthal P, Schwarz KB. NASP-GHAN practice guidelines: Diagnosis and management of hepatitis C infection in infants, children, and adolescents. *J Pediatr Gastroenterol Nutr* 2012; **54**: 838-855 [PMID: 22487950 DOI: 10.1097/MPG.0b013e318258328d]
 - 92 **Rodrigue JR**, Balistreri W, Haber B, Jonas MM, Mohan P, Molleston JP, Murray KF, Narkewicz MR, Rosenthal P, Smith LJ, Schwarz KB, Robuck P, Barton B, González-Peralta RP. Impact of hepatitis C virus infection on children and their caregivers: quality of life, cognitive, and emotional outcomes. *J Pediatr Gastroenterol Nutr* 2009; **48**: 341-347 [PMID: 19242286 DOI: 10.1097/MPG.0b013e318185998f]
 - 93 **Nydegger A**, Srivastava A, Wake M, Smith AL, Hardikar W. Health-related quality of life in children with hepatitis C acquired in the first year of life. *J Gastroenterol Hepatol* 2008; **23**: 226-230 [PMID: 18289357 DOI: 10.1111/j.1440-1746.2007.04859.x]
 - 94 **Talal AH**, LaFleur J, Hoop R, Pandya P, Martin P, Jacobson I, Han J, Korner EJ. Absolute and relative contraindications to pegylated-interferon or ribavirin in the US general patient population with chronic hepatitis C: results from a US database of over 45 000 HCV-infected, evaluated patients. *Aliment Pharmacol Ther* 2013; **37**: 473-481 [PMID: 23289640 DOI: 10.1111/apt.12200]
 - 95 Available from: URL: <http://dailymed.nlm.nih.gov/dailymed/lookup.cfm?setid=4c918b02-f158-4f7c-8ecc-fd49574ec228>
 - 96 Available from: URL: <http://dailymed.nlm.nih.gov/dailymed/lookup.cfm?setid=fd653d74-48ab-49e4-a42d-ec1cb59badb>
 - 97 Available from: URL: <http://dailymed.nlm.nih.gov/dailymed/lookup.cfm?setid=de61685e-2b8c-4e22-84bb-869e13600440>
 - 98 Available from: URL: <http://dailymed.nlm.nih.gov/dailymed/lookup.cfm?setid=0a8f3137-0e3a-4a60-a872-cb7d761b30e1>
 - 99 **Yazdani Brojeni P**, Matok I, Garcia Bournissen F, Koren G. A systematic review of the fetal safety of interferon alpha. *Reprod Toxicol* 2012; **33**: 265-268 [PMID: 22200624 DOI: 10.1016/j.reprotox.2011.11.003]
 - 100 Available from: URL: <http://dailymed.nlm.nih.gov/dailymed/lookup.cfm?setid=d370635f-5530-4d42-a019-76b61639787>
 - 101 Available from: URL: <http://dailymed.nlm.nih.gov/dailymed/lookup.cfm?setid=04d2b6f4-bd9b-4871-9527-92c81aa2d4d0>
 - 102 **Roberts SS**, Miller RK, Jones JK, Lindsay KL, Greene MF, Maddrey WC, Williams IT, Liu J, Spiegel RJ. The Ribavirin Pregnancy Registry: Findings after 5 years of enrollment, 2003-2009. *Birth Defects Res A Clin Mol Teratol* 2010; **88**: 551-559 [PMID: 20564430 DOI: 10.1002/bdra.20682]
 - 103 **Hofer H**, Donnerer J, Sator K, Staufer K, Scherzer TM, Dejaco C, Sator M, Kessler H, Ferenci P. Seminal fluid ribavirin level and functional semen parameters in patients with chronic hepatitis C on antiviral combination therapy. *J Hepatol* 2010; **52**: 812-816 [PMID: 20399525 DOI: 10.1016/j.jhep.2009.12.039]
 - 104 **Pecou S**, Moinard N, Walschaerts M, Pasquier C, Daudin M, Bujan L. Ribavirin and pegylated interferon treatment for hepatitis C was associated not only with semen alterations but also with sperm deoxyribonucleic acid fragmentation in humans. *Fertil Steril* 2009; **91**: 933. e17-22 [DOI: 10.1016/j.fertnstert.2008.07.1755]
 - 105 **Maddrey WC**. Safety of combination interferon alfa-2b/ribavirin therapy in chronic hepatitis C-relapsed and treatment-naïve patients. *Semin Liver Dis* 1999; **19** Suppl 1: 67-75 [PMID: 10349694 DOI: 10.1016/j.reprotox.2011.11.003]
 - 106 **Mishkin D**, Deschênes M. Conception soon after discontinuing interferon/ribavirin therapy: a successful outcome. *Am J Gastroenterol* 2001; **96**: 2285-2286 [PMID: 11467686 DOI: 10.1111/j.1572-0241.2001.03996.x]
 - 107 **Rezvani M**, Koren G. Pregnancy outcome after exposure to injectable ribavirin during embryogenesis. *Reprod Toxicol* 2006; **21**: 113-115 [PMID: 16122903 DOI: 10.1016/j.reprotox.2005.06.005]
 - 108 **Hegenbarth K**, Maurer U, Kroisel PM, Fickert P, Trauner M, Stauber RE. No evidence for mutagenic effects of ribavirin: report of two normal pregnancies. *Am J Gastroenterol* 2001; **96**: 2286-2287 [PMID: 11467687 DOI: 10.1111/j.1572-0241.2001.03997.x]
 - 109 **Bianca S**, Ettore G. Male periconceptional ribavirin-interferon alpha-2b exposure with no adverse fetal effects. *Birth Defects Res A Clin Mol Teratol* 2003; **67**: 77-78 [PMID: 12749388 DOI: 10.1002/bdra.10105]
 - 110 **De Santis M**, Carducci B, Cavaliere AF, De Santis L, Lucchese A, Straface G, Caruso A. Paternal exposure to ribavirin: pregnancy and neonatal outcome. *Antivir Ther* 2003; **8**: 73-75 [PMID: 12713067]
 - 111 Available from: URL: <http://dailymed.nlm.nih.gov/dailymed/lookup.cfm?setid=ae879ebe-b620-4829-b6f8-74b58da1c771>
 - 112 Available from: URL: <http://dailymed.nlm.nih.gov/dailymed/lookup.cfm?setid=ed0e4f33-cf21-4fe3-918d-1d5b3a23eee4>
 - 113 Available from: URL: <http://dailymed.nlm.nih.gov/dailymed/lookup.cfm?setid=80beab2c-396e-4a37-a4dc-40fdb62859cf>
 - 114 **Jacobson KR**, Murray K, Zellos A, Schwarz KB. An analysis of published trials of interferon monotherapy in children with chronic hepatitis C. *J Pediatr Gastroenterol Nutr* 2002; **34**: 52-58 [PMID: 11753165]
 - 115 **Hu J**, Doucette K, Hartling L, Tjosvold L, Robinson J. Treatment of hepatitis C in children: a systematic review. *PLoS One* 2010; **5**: e11542 [PMID: 20644626 DOI: 10.1371/journal.pone.0011542]
 - 116 **Tsunoda T**, Inui A, Kawamoto M, Sogo T, Komatsu H, Fujisawa T. Effects of pegylated interferon- α -2a monotherapy on growth in Japanese children with chronic hepatitis C. *Hepatol Res* 2014; **44**: 251-258 [PMID: 23607340 DOI: 10.1111/hepr.12118]

P- Reviewer: Chiu KW, Komatsu H, Koumbi L, Kanda T, Lee TY
S- Editor: Ji FF **L- Editor:** Roemmele A **E- Editor:** Wu HL



From portal to splanchnic venous thrombosis: What surgeons should bear in mind

Quirino Lai, Gabriele Spoleitini, Rafael S Pinheiro, Fabio Melandro, Nicola Guglielmo, Jan Lerut

Quirino Lai, Jan Lerut, Starzl Unit of Abdominal Transplantation, University Hospitals Saint-Luc, Université Catholique Louvain, B-1200 Brussels, Belgium

Gabriele Spoleitini, Oxford Transplant Centre, Churchill Hospital, Oxford University Hospitals NHS Trust, Oxford OX3 7LE, United Kingdom

Rafael S Pinheiro, Department of Gastroenterology, University of São Paulo Medical School, 05508-070 São Paulo, Brazil

Fabio Melandro, Nicola Guglielmo, Department of General Surgery and Organ Transplantation, University Sapienza, Umberto I Hospital, 00186 Rome, Italy

Author contributions: Lai Q gave substantial contributions to conception and design of the research; all the authors wrote the article and revised it critically and gave the final approval of the version to be published.

Correspondence to: Quirino Lai, MD, Starzl Unit of Abdominal Transplantation, University Hospital Saint-Luc, Université Catholique Louvain, Avenue Hippocrate 10, B-1200 Brussels, Belgium. lai.quirino@libero.it

Telephone: +32-2-7641401 Fax: +32-2-7649039

Received: October 20, 2013 Revised: February 9, 2014

Accepted: June 18, 2014

Published online: August 27, 2014

thrombosis may preferentially be referred to specialized centres, in which complex vascular approaches and even multivisceral transplantation are performed.

© 2014 Baishideng Publishing Group Inc. All rights reserved.

Key words: Liver transplantation; Portal vein thrombosis; Splanchnic vein thrombosis; Thrombectomy; Vascular graft; Spleno-renal shunt; Cavo-portal hemi-transposition; Portal vein arterialization; Intestinal transplantation; Multi-visceral transplant

Core tip: The present study aims to review the evolution of surgical management of portal and splanchnic venous thrombosis in the context of liver transplantation.

Lai Q, Spoleitini G, Pinheiro RS, Melandro F, Guglielmo N, Lerut J. From portal to splanchnic venous thrombosis: What surgeons should bear in mind. *World J Hepatol* 2014; 6(8): 549-558 Available from: URL: <http://www.wjgnet.com/1948-5182/full/v6/i8/549.htm> DOI: <http://dx.doi.org/10.4254/wjh.v6.i8.549>

Abstract

The present study aims to review the evolution of surgical management of portal (PVT) and splanchnic venous thrombosis (SVT) in the context of liver transplantation over the last 5 decades. PVT is more commonly managed by endovenous thrombectomy, while SVT requires more complex technical expedients. Several surgical techniques have been proposed, such as extensive eversion thrombectomy, anastomosis to collateral veins, reno-portal anastomosis, cavo-portal hemi-transposition, portal arterialization and combined liver-intestinal transplantation. In order to achieve satisfactory outcomes, careful planning of the surgical strategy is mandatory. The excellent results that are obtained nowadays confirm that, even extended, splanchnic thrombosis is no longer an absolute contraindication for liver transplantation. Patients with advanced portal

INTRODUCTION

Portal vein thrombosis (PVT) has been described as a multi-factorial condition resulting from the combination of both inherited and acquired factors^[1]. Cirrhosis represents the most common etiologic factor, accounting for up to 24%-32% of cases^[2]. Other common causes include cancer, infection, inflammation and thrombophilic disorders.

The incidence of PVT also correlates with the severity of cirrhosis^[3], thus being a common problem during liver transplantation (LT). PVT usually arises within the liver and extends downwards into the extra-hepatic portion of the portal vein (PV). In some cases the thrombosis further extends to the mesenteric branches resulting in

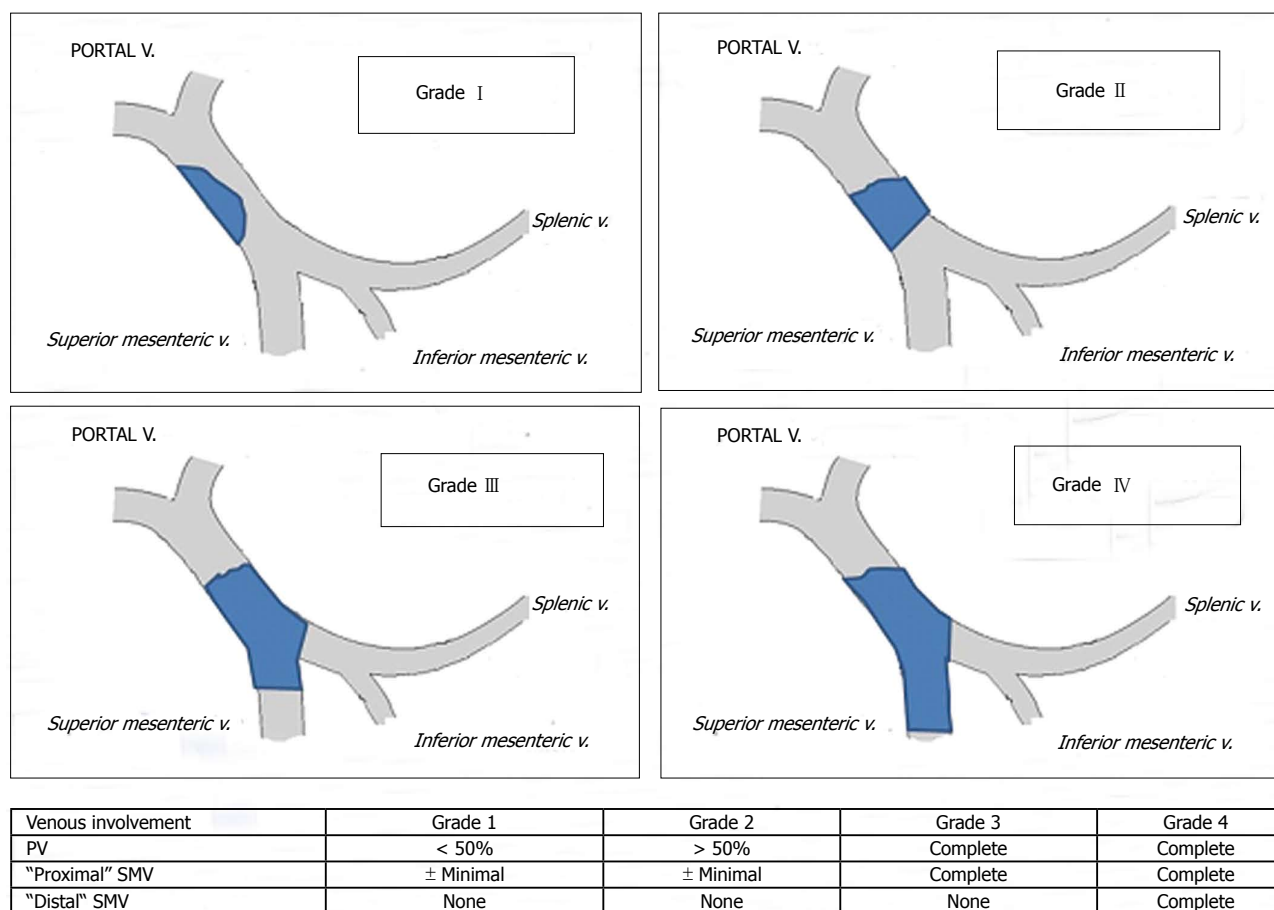


Figure 1 Portal vein thrombosis classification according to Yerdel *et al.*^[3]. PV: Portal vein; SMV: Superior mesenteric vein.

a splanchnic venous thrombosis (SVT).

Until the late 1980's, PVT and SVT were considered contra-indications for LT due to concerns about compromised portal allograft inflow.

The first successful LT in a patient with PVT was reported by the Pittsburgh group in 1985 using a free iliac vein allograft^[4]. Two years later, the same group presented the first large series of LT in patients with PVT ($n = 22$), representing a landmark paper in this field^[5]. Since that seminal experience, several new techniques have been proposed to overcome this problem. The present study reviews the surgical evolution in this field of LT over the last five decades.

DIAGNOSIS AND CLASSIFICATION

Despite progress in preoperative and cross-sectional imaging, a substantial number of cases of PVT or SVT are still discovered at the time of LT^[6,7]. Doppler-ultrasound examination remains the most common initial diagnostic tool. However, it has limitations in detecting thrombosis due to (spontaneous or medical) recanalization and because of thrombus extension to the mesenteric veins, which cannot always be visualised clearly. Therefore, computed tomography and magnetic resonance angiography have an important role in diagnosing this condition^[8]. The presence of arterial enhancement in contrast-

enhanced ultrasound may help differentiate between malignant and benign thromboses^[9].

The sensitivity in detecting complete venous thrombosis ranges from 92% to 100%, decreasing to 14%-50% in partial thrombosis^[10]. The preoperative identification of PVT enables surgical planning and the exclusion of patients with malignant thrombosis from listing for LT. Several classifications have been proposed so far; the Yerdel classification gained the greatest acceptance and widespread clinical application^[3] (Figure 1). Grade I and II PVT can almost always be managed by portal vein resection with or without thrombectomy; grade III and IV PVT require a more complex technique (Figure 2).

Management of grade I - II PVT

The initial strategy for grades I - II PVT is the removal of the thrombus. This is best done by removing it together with the innermost layer of the vessel (thrombo-endovenectomy)^[3]. If the thrombosis involves a short segment of the PV, this can be resected; the residual part of the thrombus can also be fixed to the vessel wall^[3]. The thrombus is separated from the PV wall using an endarterectomy spatula and the thrombus is freed under direct vision whilst evertting the vessel wall^[11-13]. Thrombi extending up to the mesenteric vein can be extracted successfully with this technique. Blind extraction using

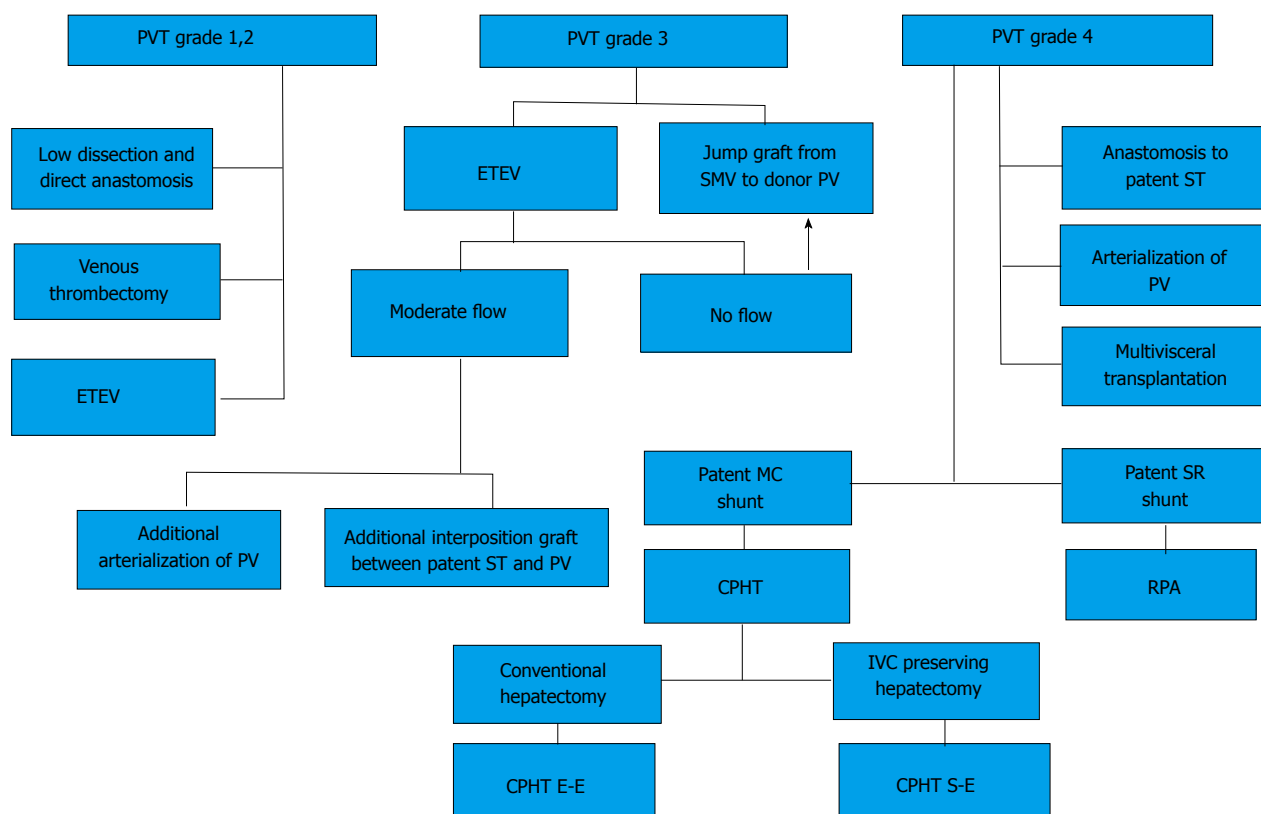


Figure 2 Algorithm for the management of portal and splanchnic vein thrombosis during liver transplantation. CPHT: Cavo-portal hemitransposition; CPHT E-E: End-to-end cavo-portal hemitransposition; CPHT S-E: Side-to-end cavo-portal hemitransposition; ETEV: Eversion thromboendovenectomy; IVC: Inferior vena cava; MC: Mesocaval shunt (spontaneous or surgical); PV: Portal vein; PVT: Portal vein thrombosis; RPA: Reno-portal anastomosis; SMV: Superior mesenteric vein; SR: Spleno-renal shunt (spontaneous or surgical); ST: Splanchnic tributary (coronary, gastroepiploic vein). From Paskonis *et al*^[63], with modifications.

vascular clamps should be avoided as it can rip the vessel, which may result in uncontrollable bleeding, especially at the level of the pancreatic head. The completeness of the thrombectomy can be verified by restoration of an adequate portal blood flow (Figure 3).

Eversion thromboendovenectomy (ETEV) is another surgical technique applicable to type I–III thromboses. Type IV thrombosis can only be occasionally treated with this technique, but typically requires more complex procedures. With ETEV, the clot is progressively and circumferentially freed with the aid of a tonsil clamp by everting the venous wall, and clamping the free edge of the clot with a tonsil. Some authors consider ETEV a risky technique, as a piece of diseased venous wall with thrombogenic potential is left in place^[14].

Pan *et al*^[15] described a modification of ETEV, called improved eversion thrombectomy, in which 1 cm of the anterior wall of the PV is cut, with the final removal of the smooth wall of PV after clot removal. This technique was reported in 23 type I–III cases, with no PVT recurrences or post-operative deaths.

Several single-centre series have been reported in relation to the treatment of grade I–II PVT^[14–19]. A large review of 1957 LT recipients with PVT^[10] showed that thrombectomy and/or thromboendovenectomy with end-to-end portal anastomosis was the most frequently used technique (75% of cases) with a very low risk of

PVT recurrence and complications.

Management of grade III PVT

In the case of type III PVT, ETEV alone can be insufficient, due to involvement of the distal portion of the SMV^[15]. If portal flow is insufficient, different options can be considered in order to establish an adequate portal flow (> 600 mL/min). Porto-systemic shunt collaterals can be suture-ligated; in the case of spontaneous or surgical spleno-renal shunt, the left renal vein can be divided^[20]. Sometimes a reno-portal anastomosis using a free iliac vein graft between the left renal vein and the PV (end-to-side or end-to-end anastomosis) can provide adequate portal inflow^[21]. Another technique in grade III PVT may consist of anastomosing (eventually with a venous graft) the PV to recipient collaterals (coronary or choledochal veins). All these techniques can be considered when the PV is found to be a small fibrotic vessel.

A jump graft can be used in cases in which a low dissection of the retro-pancreatic PV or distal SMV part is required. This method avoids hazardous dissection with potential fatal bleeding and risk of pancreatitis^[5,22].

Rodríguez-Castro *et al*^[10], adopted venous interposition grafting between donor and recipient PV in 158 cases (8.4%), which represents the second most commonly used surgical technique after thrombectomy/thromboendovenectomy.

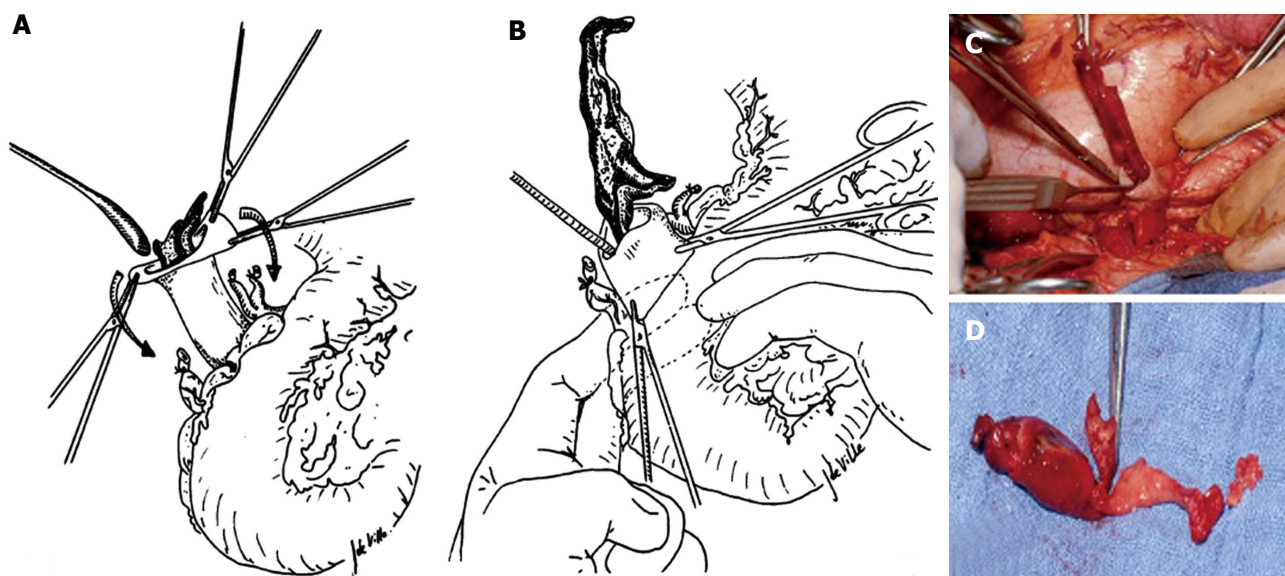


Figure 3 Eversion venous thrombectomy technique. A and B: Schematic representation of the manoeuvre; C: Intraoperative image of thrombectomy procedure; D: The thrombus removed from the portal vein. Modified from Lerut *et al.*^[13]. Figures from the experience of Prof. Jan Lerut.

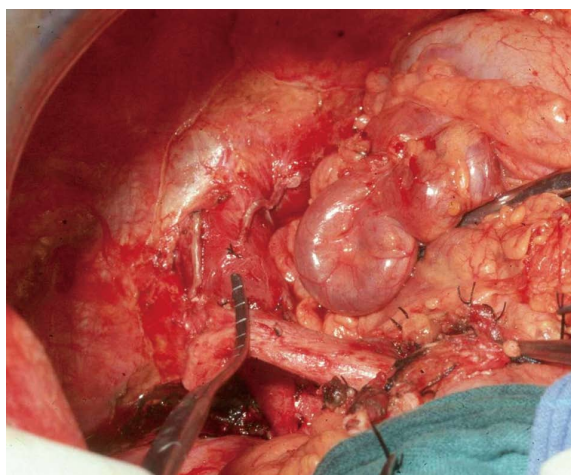


Figure 4 Intraoperative image of a large coronary vein and a thrombosed portal vein. Figure from the experience of Prof. Jan Lerut.

Kim reported 50 cases of living donor LT with PVT: in one case (2.4%) of partial PVT, the PV was reconstructed using a cryopreserved interposition graft after resection of a thrombosed segment; in 3/7 cases of total PVT, the distal SMV or coronary vein were used for the inflow using a jump graft; two patients with SVT, both needed jump grafts^[17].

Management of grade IV PVT

Up to 15 years ago, patients with diffuse SVT were not considered for LT. More recently, 5 different surgical techniques to restore portal inflow have been suggested: (1) anastomosis to a patent splanchnic tributary (APST); (2) PV arterialization (PVA); (3) reno-portal anastomosis (RPA); (4) cavo-portal hemitransposition (CPHT); (5) hepato-intestinal or (6) multi-visceral transplantation (MVT).

APST represents, when feasible, the preferred approach in the case of SVT as it is the “easiest” to perform. This technique was initially described by Lerut *et al.*^[5] and Hiatt *et al.*^[25]. In the review by Rodríguez-Castro *et al.*^[10], 49 (2.4%) cases of APST were described; the reported series rarely contain more than 5 cases^[3,24]. Virtually any large collateral (2 cm of diameter or more) can suffice to supply the graft; these are mostly a bile duct varix or a middle colic or coronary (left gastric) veins (Figure 4). The venous flow must be tested before implanting the graft to ensure adequate inflow. An interposition graft is sometimes necessary^[25]. Particular care must be taken when suturing these variceal structures to the donor portal vein.

PVA is a simple method to restore the portal blood flow into the graft, anastomosing the PV of the graft to the hepatic or gastro-duodenal artery or aorta using an iliac interposition graft. This revascularisation procedure is well documented in surgery for portal hypertension^[26] and post-LT arterial thrombosis^[27] or, more commonly in the setting of PVT during LT^[28-35]. It is occasionally used to deal with early PVT complicating LT. Here, PVA is usually associated with PV thrombectomy. PVA has been reported once in a case of auxiliary heterotopic LT^[36].

The PV can be directly anastomosed to the recipient hepatic artery^[28,29,32,33], or anastomosed to the supra- or infra-renal aorta with an interposition graft from a segment of donor iliac artery^[28-31]. In one case, PV was anastomosed to the accessory right hepatic artery originating from the superior mesenteric artery^[34]. However, this is associated with significant mortality due to haemorrhage, right heart failure, acute^[28,32] and secondary PVT^[28,30-34]. Some patients developed graft fibrosis due to modified hepatic microcirculation^[28,32], right-sided heart decompensation^[29] as well as persistent portal hypertension due to “over-arterialization”^[28,32]. Experimental syngenic rat

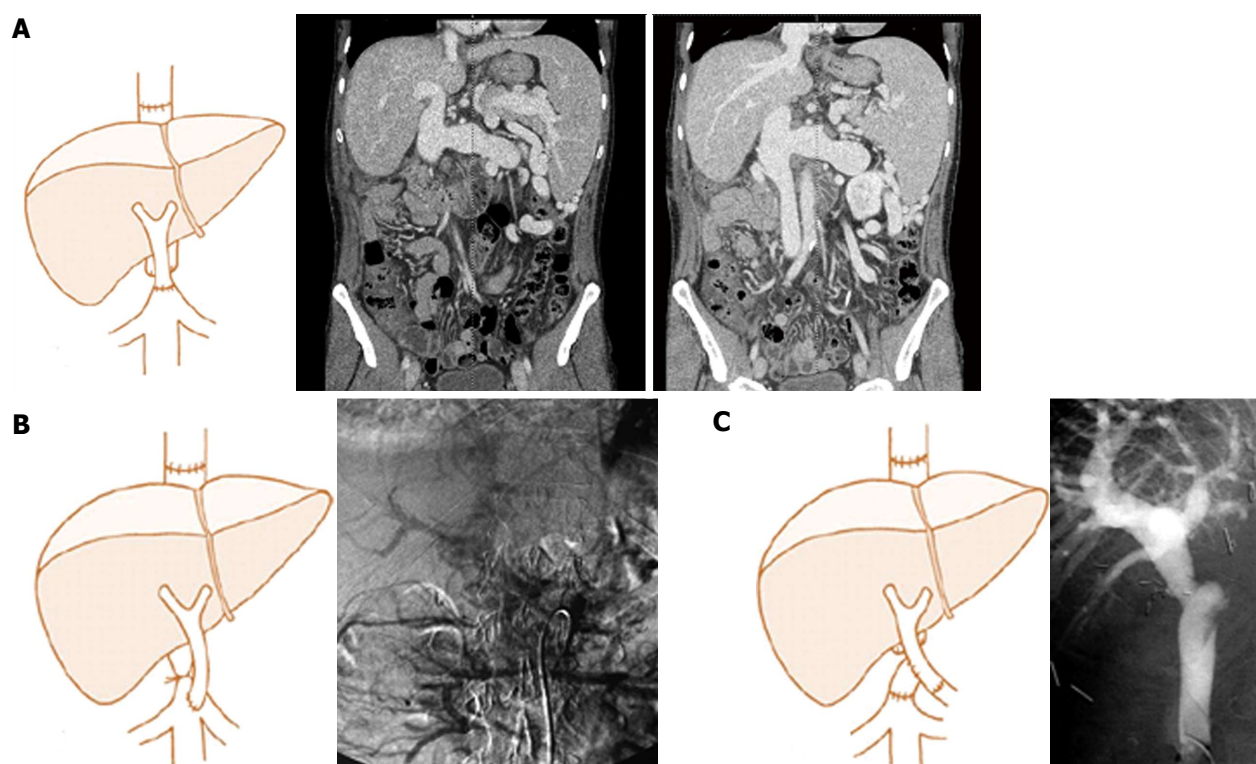


Figure 5 Examples of different techniques of portal flow reconstruction during cavo-portal hemitransposition. A: End-to-end cavoportal anastomosis; B: Side-to-end cavoportal anastomosis with retro-hepatic caval vein constriction; C: End-to-side cavoportal anastomosis using vein interposition graft distal to the conventional portal vein anastomosis. Modified from Paskonis *et al.*^[43]. Figures from the experience of Prof. Jan Lerut.

models confirmed that PV “over-arterialization” during LT can lead to liver fibrogenesis^[37]. A possible solution for this problem is the surgical modulation of the arterialized portal inflow. There is, however, no agreement regarding the “ideal” flow to aim at in this setting; some authors propose 0.6–0.8 L/min^[33], others 1 L/min^[30] or even 1.5–1.8 L/min^[32]. The calibration of arterio-portal anastomosis can also be done either surgically or radiologically using coil embolization of the artery anastomosed to the PV^[29,36]. In the 3 cases in which calibration of PVA was performed either surgically or radiologically favourable outcome were observed, with a follow-up up to 36 mo^[29,36]. However, the progressive aneurysmal dilatation of intrahepatic portal branches and the possible risk of liver fibrosis suggest that PVA should be used only exceptionally.

RPA was originally reported by Sheil *et al.*^[38], and subsequently modified with a venous interposition graft by Bhangu *et al.*^[39] and Kato *et al.*^[40]. This approach represents a good option in grade IV PVT when engorged collateral vessels are unavailable or when their blood flow is inadequate. However, the liver pathophysiological consequences of this reconstruction are not yet clearly elucidated^[41,42]. This method, when possible to adopt, is safe^[43]. Until now, RPA has been reported in about 50 cases worldwide; however, only a handful of series contain more than five cases^[39,40].

After identification and control of the renal vein, a free iliac vein can be anastomosed either end-to-end or side-to-end to the renal vein. Next, the renal vein itself or

the interposition graft will be anastomosed to the donor PV. Kocherisation of the duodenum can be useful when the renal vein has a lower location.

This technique also has some complications such as ascites, renal dysfunction, GI-bleeding, deep venous thrombosis and oedema of lower limbs. These events are all due to a persistent portal hypertension that is resolved only partially by this technique^[44].

CPHT represents an exceptional technique to over-pass an extensive splanchnic venous thrombosis. The inflow from IVC is used to perfuse the PV of the allograft. CPHT was developed in animal models for the treatment of some metabolic diseases^[45–47]. The first human series were performed by Starzl *et al.*^[48] and Riddell *et al.*^[49] for glycogen storage disease. In 1998, Tzakis *et al.*^[50] reported a series of nine cases of CPHT performed during LT due to diffuse PVT. To date, 107 cases have been reported worldwide (Table 1) with the largest series described by Tzakis ($n = 23$)^[14,15,24,50–80].

CPHT can be performed either as an end-to-end or an end-to-side anastomosis between IVC and PV; with the latter carried out in the case of IVC sparing hepatectomy (Figure 5). Both connections may require the use of an interposition graft. In the end-to-side anastomosis, the IVC is best ligated in order to redirect the systemic venous blood flow to the allograft. This procedure carries a high mortality [36 (33.6%) patients] mainly due to sepsis and multiple organ failure. The longest reported survival is 139 mo.

Postoperative complications are mainly related to

Table 1 Cavoportal hemitransposition: Experiences worldwide

| Ref. | Year | Country | Pts | Post-LT | | | Mortality | Survival (mo) ¹ |
|---|------|----------------|-----------------------|-------------------|------------------------|----------------------|-----------|----------------------------|
| | | | | Variceal bleeding | Cavo-portal thrombosis | Severe renal failure | | |
| Weeks <i>et al</i> ^[52] | 2000 | United States | 1 | 0 | 1 | 0 | 0 | 20 |
| Varma <i>et al</i> ^[53] | 2000 | United States | 1 | 0 | 0 | 0 | 0 | 12 |
| Olausson <i>et al</i> ^[55] | 2001 | Sweden | 6 (1 ²) | 1 | 2 | 2 | 1 | 13 |
| Santaniello <i>et al</i> ^[56] | 2001 | Italy | 1 | 1 | 0 | 1 | 0 | 9 |
| Bakthavatsalam <i>et al</i> ^[58] | 2001 | United States | 1 ² | 0 | 0 | 0 | 0 | 12 |
| Urbani <i>et al</i> ^[59] | 2002 | Italy | 6 (2 ²) | 1 | 1 | 1 | 1 | 23 |
| Gerunda <i>et al</i> ^[60] | 2002 | Italy | 2 | 2 | 0 | 2 | 1 | 12 |
| Azoulay <i>et al</i> ^[61] | 2002 | France | 8 | 2 | 0 | 1 | 3 | 37 |
| Shrotri <i>et al</i> ^[62] | 2003 | United Kingdom | 1 | 0 | 1 | 0 | 0 | 12 |
| Kumar <i>et al</i> ^[63] | 2003 | United Kingdom | 1 | 0 | 0 | 0 | 0 | 24 |
| Verran <i>et al</i> ^[64] | 2004 | Australia | 1 ² | 0 | 0 | 0 | 0 | 6 |
| Bertelli <i>et al</i> ^[66] | 2005 | Italy | 1 | 1 | 0 | 0 | 0 | 84 |
| Wang <i>et al</i> ^[67] | 2005 | China | 1 | 0 | 0 | 0 | 0 | 6 |
| Ozden <i>et al</i> ^[68] | 2006 | Turkey | 1 ² | 0 | 0 | 0 | 0 | 13 |
| Lipshutz <i>et al</i> ^[69] | 2006 | United States | 7 (1 ²) | 0 | 0 | 0 | 2 | 96 |
| Egawa <i>et al</i> ^[70] | 2006 | Japan | 1 | 0 | 0 | 1 | 1 | 0 |
| Lladó <i>et al</i> ^[24] | 2007 | Spain | 1 | 0 | 0 | 0 | 1 | 1 |
| Selvaggi <i>et al</i> ^[71] | 2007 | United States | 23 | 7 | 6 | 3 | 13 | 112 |
| Li <i>et al</i> ^[72] | 2008 | China | 1 | 0 | 1 | 0 | 0 | 18 |
| Yan <i>et al</i> ^[73] | 2008 | China | 3 | 1 | 0 | 0 | 1 | 48 |
| Pan <i>et al</i> ^[15] | 2009 | China | 1 | 0 | 0 | 0 | 1 | - |
| Tao <i>et al</i> ^[16] | 2009 | China | 2 | 0 | 1 | 0 | 0 | - |
| Gao <i>et al</i> ^[74] | 2009 | China | 2 | 1 | 0 | 0 | 2 | 6 |
| Campsen <i>et al</i> ^[75] | 2010 | United States | 10 | 0 | 0 | 0 | 0 | - |
| Suarez <i>et al</i> ^[76] | 2010 | Spain | 4 | - | - | - | 2 | - |
| Ravaioli <i>et al</i> ^[77] | 2011 | Italy | 6 | 0 | 0 | 0 | 1 | - |
| Shi <i>et al</i> ^[78] | 2011 | China | 1 | 0 | 0 | 0 | 0 | - |
| Lai <i>et al</i> ^[79] | 2012 | Belgium | 8 | 3 | 4 | 2 | 5 | 139 |
| Chmurowicz <i>et al</i> ^[80] | 2013 | Poland | 1 ² | 0 | 0 | 0 | 0 | - |
| Total | | | 103 (7 ²) | 20 | 17 | 13 | 35 | |

¹Maximum survival in the series; ²Retransplantation. LT: Liver transplantation.

anastomotic thrombosis or stenosis, congestion of the inferior vena cava (IVC) and incompletely resolved portal hypertension. Complications related to IVC congestion are mild to severe oedema of the lower torso and limbs and renal dysfunction. Mild renal dysfunction, observed in almost all patients, usually resolves spontaneously without the need for haemodialysis; haemodialysis was required in 13 (12.1%) patients. Within the second group of complications, the most commonly observed were ascites and (early or delayed) variceal bleeding. In 21 (19.6%) patients, bleeding occurred post-operatively due to persistent portal hypertension. Varma reported a case in which a venous graft was interposed between a retroperitoneal varix and the PV in order to improve the drainage of the portal venous system^[53]. The majority of variceal bleedings were controlled with sclerotherapy, splenic artery embolization or splenectomy with or without gastric devascularization^[79].

Thrombosis at the level of the anastomosis was seen in 17 (15.9%) patients. Such complication can sometimes be treated by endovascular stenting.

Hepato-intestinal or MVT represents the very last surgical option in grade IV PVT, allowing replacement of the entire splanchnic venous system of the recipient^[81]. Such a radical expedient still represents a major technical and immunological challenge, and carries a high risk of

rejection, infection and surgical complications. In recent years, surgical technique and peri-operative management have evolved substantially, achieving one- and three-year survival rates up to 80% and 70%^[65,82,83]. Particular attention should be given to the graft procurement and to ensure a low cold ischemia time (≤ 6 h) in order to avoid irreversible intestinal mucosal injury^[84,85]. The MVT surgical technique consists of complete replacement of the abdominal viscera after exenteration^[86]. Arterial inflow is established with a unique anastomosis between the donor aortic patch encompassing the coeliac trunk and superior mesenteric artery and recipient aorta. Venous anastomosis is routinely performed with a piggy-back technique. A terminal ileostomy is created in order to allow endoscopic monitoring of the bowel graft. The decision to opt for a MVT may be undertaken during the transplant procedure. If adequate portal flow can be restored, the Indiana group led by Vianna proposed that only the liver should be implanted and the multivisceral graft split on the back table; the remaining organs are next directed towards a backup recipient needing an isolated intestinal transplantation. If portal flow cannot be established, then a MVT is required^[87].

SVT used to represent a common indication for MVT in adults. The Pittsburgh experience consisting of five hundred transplants included MVT for SVT in 10% of

cases^[88]. The Indiana group obtained excellent one- and three-year survival rates of 80% and 72%. However, the procedure carried a complication rate of 56% with half the patients requiring a surgical re-exploration^[83]. Nowadays, MVT is less frequently offered in cases of SVT due to the introduction of more sophisticated surgical techniques when dealing with extended SVT.

CONCLUSION

PVT and SVT are no longer a contraindication for LT. However, in order to achieve satisfactory outcomes, the surgical strategy needs to be carefully planned before the transplant procedure. Patients with extended splanchnic thrombosis may need complex vascular interventions; others may even require a multivisceral transplantation.

ACKNOWLEDGMENTS

We thank Reena Ravikumar, Specialty Registrar in General Surgery, London, United Kingdom, for her support with English language revision.

REFERENCES

- Garcia-Pagan JC, Valla DC. Portal vein thrombosis: a predictable milestone in cirrhosis? *J Hepatol* 2009; **51**: 632-634 [PMID: 19660824 DOI: 10.1016/j.jhep.2009.06.009]
- Cohen J, Edelman RR, Chopra S. Portal vein thrombosis: a review. *Am J Med* 1992; **92**: 173-182 [PMID: 1543202]
- Yerdel MA, Gunson B, Mirza D, Karayalçin K, Olliff S, Buckels J, Mayer D, McMaster P, Pirenne J. Portal vein thrombosis in adults undergoing liver transplantation: risk factors, screening, management, and outcome. *Transplantation* 2000; **69**: 1873-1881 [PMID: 10830225]
- Shaw BW, Iwatsuki S, Bron K, Starzl TE. Portal vein grafts in hepatic transplantation. *Surg Gynecol Obstet* 1985; **161**: 66-68 [PMID: 3892734]
- Lerut J, Tzakis AG, Bron K, Gordon RD, Iwatsuki S, Esquivel CO, Makowka L, Todo S, Starzl TE. Complications of venous reconstruction in human orthotopic liver transplantation. *Ann Surg* 1987; **205**: 404-414 [PMID: 3551857]
- Francoz C, Belghiti J, Vilgrain V, Sommacale D, Paradis V, Condat B, Denninger MH, Sauvanet A, Valla D, Durand F. Splanchnic vein thrombosis in candidates for liver transplantation: usefulness of screening and anticoagulation. *Gut* 2005; **54**: 691-697 [PMID: 15831918]
- Dumortier J, Czyglik O, Poncet G, Blanchet MC, Boucaud C, Henry L, Boillot O. Eversion thrombectomy for portal vein thrombosis during liver transplantation. *Am J Transplant* 2002; **2**: 934-938 [PMID: 12482145]
- DeLeve LD, Valla DC, Garcia-Tsao G. Vascular disorders of the liver. *Hepatology* 2009; **49**: 1729-1764 [PMID: 19399912 DOI: 10.1002/hep.22772]
- Raza SA, Jang HJ, Kim TK. Differentiating malignant from benign thrombosis in hepatocellular carcinoma: contrast-enhanced ultrasound. *Abdom Imaging* 2014; **39**: 153-161 [PMID: 24002440]
- Rodríguez-Castro KI, Porte RJ, Nadal E, Germani G, Burra P, Senzolo M. Management of nonneoplastic portal vein thrombosis in the setting of liver transplantation: a systematic review. *Transplantation* 2012; **94**: 1145-1153 [PMID: 23128996 DOI: 10.1097/TP.0b013e31826e8e53]
- Stieber AC, Zetti G, Todo S, Tzakis AG, Fung JJ, Marino I, Casavilla A, Selby RR, Starzl TE. The spectrum of portal vein thrombosis in liver transplantation. *Ann Surg* 1991; **213**: 199-206 [PMID: 1998400]
- Molmenti EP, Roodhouse TW, Molmenti H, Jaiswal K, Jung G, Marubashi S, Sanchez EQ, Gogel B, Levy MF, Goldstein RM, Fasola CG, Elliott EE, Bursac N, Mulligan D, Gonwa TA, Klintmalm GB. Thrombendovenectomy for organized portal vein thrombosis at the time of liver transplantation. *Ann Surg* 2002; **235**: 292-296 [PMID: 11807371]
- Lerut JP, Mazza D, van Leeuw V, Laterre PF, Donatiggio M, de Ville de Goyet J, Van Beers B, Bourlier P, Goffette P, Puttemans T, Otte JB. Adult liver transplantation and abnormalities of splanchnic veins: experience in 53 patients. *Transpl Int* 1997; **10**: 125-132 [PMID: 9089998]
- Seu P, Shackleton CR, Shaked A, Imagawa DK, Olthoff KM, Rudich SR, Kinkhabwala M, Busuttil RW. Improved results of liver transplantation in patients with portal vein thrombosis. *Arch Surg* 1996; **131**: 840-844; discussion 844-845 [PMID: 8712907]
- Pan C, Shi Y, Zhang JJ, Deng YL, Zheng H, Zhu ZJ, Shen ZY. Single-center experience of 253 portal vein thrombosis patients undergoing liver transplantation in China. *Transplant Proc* 2009; **41**: 3761-3765 [PMID: 19917382 DOI: 10.1016/j.transproceed.2009.06.215]
- Tao YF, Teng F, Wang ZX, Guo WY, Shi XM, Wang GH, Ding GS, Fu ZR. Liver transplant recipients with portal vein thrombosis: a single center retrospective study. *Hepatobiliary Pancreat Dis Int* 2009; **8**: 34-39 [PMID: 19208512]
- Kim SJ, Kim DG, Park JH, Moon IS, Lee MD, Kim JI, Yoon YC, Yoo YK. Clinical analysis of living donor liver transplantation in patients with portal vein thrombosis. *Clin Transplant* 2011; **25**: 111-118 [PMID: 20184630 DOI: 10.1111/j.1399-0012.2010.01217.x]
- Robles R, Fernández JA, Hernández Q, Marin C, Ramirez P, Sánchez Bueno F, Luján JA, Rodríguez JM, Acosta F, Parrilla P. Eversion thromboendovenectomy for organized portal vein thrombosis encountered during liver transplantation. *Transplant Proc* 2003; **35**: 1915-1917 [PMID: 12962847]
- Song S, Kwon CH, Shin M, Kim TS, Lee S, Moon HH, Park JB, Kim SJ, Joh JW, Lee SK. A new technique for complete portal vein and superior mesenteric vein thrombosis in a liver transplant recipient. *Exp Clin Transplant* 2014; **12**: 67-70 [PMID: 23901822]
- Slater RR, Jabbour N, Abbass AA, Patil V, Hundley J, Kazimi M, Kim D, Yoshida A, Abouljoud M. Left renal vein ligation: a technique to mitigate low portal flow from splenic vein siphon during liver transplantation. *Am J Transplant* 2011; **11**: 1743-1747 [PMID: 21668639 DOI: 10.1111/j.1600-6143.2011.03578.x]
- Akbulut S, Kayaalp C, Yilmaz M, Yilmaz S. Auxiliary reno-portal anastomosis in living donor liver transplantation: a technique for recipients with low portal inflow. *Transpl Int* 2012; **25**: e73-e75 [PMID: 22487422 DOI: 10.1111/j.1432-2277.2012.01471.x]
- Aydin C, Ersan V, Baskiran A, Unal B, Kayaalp C, Yilmaz S. Controlling massive hemorrhage from the retropancreatic portal vein as a complication of thromboendovenectomy during liver transplantation with balloon catheter tamponade: how to do it. *Surg Today* 2014; **44**: 792-794 [PMID: 23812900]
- Hiatt JR, Quinones-Baldrich WJ, Ramming KP, Lois JF, Busuttil RW. Bile duct varices. An alternative to portoportal anastomosis in liver transplantation. *Transplantation* 1986; **42**: 85 [PMID: 3523887]
- Lladó L, Fabregat J, Castellote J, Ramos E, Torras J, Jorba R, Garcia-Borobia F, Busquets J, Figueras J, Rafecas A. Management of portal vein thrombosis in liver transplantation: influence on morbidity and mortality. *Clin Transplant* 2007; **21**: 716-721 [PMID: 17988264]
- Wu TH, Chou HS, Pan KT, Lee CS, Wu TJ, Chu SY, Chen MF, Lee WC. Application of cryopreserved vein grafts as a

- conduit between the coronary vein and liver graft to reconstruct portal flow in adult living liver transplantation. *Clin Transplant* 2009; **23**: 751-755 [PMID: 19659513 DOI: 10.1111/j.1399-0012.2009.01045.x]
- 26 **Otte JB**, Reynaert M, De Hemptinne B, Geubel A, Carlier M, Jamart J, Lambotte L, Kestens PJ. Arterialization of the portal vein in conjunction with a therapeutic portacaval shunt. Hemodynamic investigations and results in 75 patients. *Ann Surg* 1982; **196**: 656-663 [PMID: 7149816]
 - 27 **Melandro F**, Lai Q, Levi Sandri GB, Guglielmo N, Di Laudo M, Morabito V, Pretagostini R, Berloco PB, Rossi M. A case of portal vein arterialization after a liver transplant. *Exp Clin Transplant* 2013; **11**: 287-289 [PMID: 23767946]
 - 28 **Ott R**, Böhner C, Müller S, Aigner T, Bussenius-Kammerer M, Yedibela S, Kissler H, Hohenberger W, Reck T, Müller V. Outcome of patients with pre-existing portal vein thrombosis undergoing arterialization of the portal vein during liver transplantation. *Transpl Int* 2003; **16**: 15-20 [PMID: 12545336]
 - 29 **Stange B**, Glanemann M, Nüssler NC, Bechstein WO, Neuhaus P, Settmacher U. Indication, technique, and outcome of portal vein arterialization in orthotopic liver transplantation. *Transplant Proc* 2001; **33**: 1414-1415 [PMID: 11267352]
 - 30 **Erhard J**, Lange R, Giebler R, Rauen U, de Groot H, Eigler FW. Arterialization of the portal vein in orthotopic and auxiliary liver transplantation. A report of three cases. *Transplantation* 1995; **60**: 877-879 [PMID: 7482751]
 - 31 **Aspinall RJ**, Seery JP, Taylor-Robinson SD, Habib N. Comments on "arterialization of the portal vein in orthotopic and auxiliary liver transplantation". *Transplantation* 1996; **62**: 1375-1376 [PMID: 8932292]
 - 32 **Charco R**, Margarit C, López-Talavera JC, Hidalgo E, Castells L, Allende L, Segarra A, Moreiras M, Bilbao I. Outcome and hepatic hemodynamics in liver transplant patients with portal vein arterialization. *Am J Transplant* 2001; **1**: 146-151 [PMID: 12099362]
 - 33 **Nivatvongs S**, Sirijindakul B, Nontasoot B. Portal vein arterialization for liver transplantation with extensive portomesenteric vein thrombosis: a case report. *Transplant Proc* 2004; **36**: 2267-2268 [PMID: 15561214]
 - 34 **Paloyo S**, Nishida S, Fan J, Tekin A, Selvaggi G, Levi D, Tzakis A. Portal vein arterialization using an accessory right hepatic artery in liver transplantation. *Liver Transpl* 2013; **19**: 773-775 [PMID: 23554089 DOI: 10.1002/lt.23653]
 - 35 **Settmacher U**, Stange B, Schaser KD, Puhl G, Glanemann M, Steinmüller T, Heise M, Neuhaus P. Primary permanent arterialization of the portal vein in liver transplantation. *Transpl Int* 2003; **16**: 430-433 [PMID: 12819875]
 - 36 **Margarit C**, Bilbao I, Charco R, Lázaro JL, Hidalgo E, Allende E, Murio E. Auxiliary heterotopic liver transplantation with portal vein arterialization for fulminant hepatic failure. *Liver Transpl* 2000; **6**: 805-809 [PMID: 11084073]
 - 37 **Müller V**, Ott R, Tannapfel A, Hohenberger W, Reck T. Arterialization of the portal vein in liver transplantation: a new microsurgical model in the rat. *Transplantation* 2001; **71**: 977-981 [PMID: 11349734]
 - 38 **Sheil AG**, Stephen MS, Chui AK, Ling J, Bookallil MJ. A liver transplantation technique in a patient with a thrombosed portal vein and a functioning renal-lien shunt. *Clin Transplant* 1997; **11**: 71-73 [PMID: 9067699]
 - 39 **Bhangui P**, Lim C, Salloum C, Andreani P, Sebbagh M, Hoti E, Ichai P, Saliba F, Adam R, Castaing D, Azoulay D. Caval inflow to the graft for liver transplantation in patients with diffuse portal vein thrombosis: a 12-year experience. *Ann Surg* 2011; **254**: 1008-1016 [PMID: 21869678 DOI: 10.1097/SLA.0b013e31822d7894]
 - 40 **Kato T**, Levi DM, DeFaria W, Nishida S, Tzakis AG. Liver transplantation with renoportal anastomosis after distal splenorenal shunt. *Arch Surg* 2000; **135**: 1401-1404 [PMID: 11115340]
 - 41 **Moon DB**, Lee SG, Ahn CS, Kim KH, Hwang S, Ha TY, Song GW, Jung DH, Ryu JH, Kim KW, Choi NK, Ko G, Sung K, Lee S. Technical modification of reno-portal anastomosis in living donor liver transplantation for patients with obliterated portal vein and large spontaneous splenorenal shunts. *Hepatology* 2008; **55**: 2193-2199 [PMID: 19260504]
 - 42 **Miyamoto A**, Kato T, Dono K, Umeshita K, Kawabata R, Hayashi S, Kubota M, Kobayashi S, Nagano H, Nakamori S, Sakon M, Monden M. Living-related liver transplantation with renoportal anastomosis for a patient with large spontaneous splenorenal collateral. *Transplantation* 2003; **75**: 1596-1598 [PMID: 12792522]
 - 43 **Paskonis M**, Jurgaitis J, Mehrabi A, Kashfi A, Fonouni H, Strupas K, Büchler MW, Kraus TW. Surgical strategies for liver transplantation in the case of portal vein thrombosis-current role of cavoportal hemitransposition and renoportal anastomosis. *Clin Transplant* 2006; **20**: 551-562 [PMID: 16968480]
 - 44 **Pécora RA**, Canedo BF, Andraus W, Martino RB, Santos VR, Arantes RM, Pugliese V, D Albuquerque LA. Portal vein thrombosis in liver transplantation. *Arq Bras Cir Dig* 2012; **25**: 273-278 [PMID: 23411928]
 - 45 **Child CG**, Barr D, Holswade GR, Harrison CS. Liver regeneration following portacaval transposition in dogs. *Ann Surg* 1953; **138**: 600-608 [PMID: 13092790]
 - 46 **Silen W**, Mawdsley DL, Weirich WL, Harper HA. Studies of hepatic function in dogs with Eck fistula or portacaval transposition. *AMA Arch Surg* 1957; **74**: 964-970 [PMID: 13423997]
 - 47 **Tarzl TE**, Scanlan WA, Thornton FH, Wendel RM, Stearn B, Larzarus RE, Mcallister W, Shoemaker WC. Effect of insulin on glucose metabolism in the dog after portacaval transposition. *Am J Physiol* 1965; **209**: 221-226 [PMID: 14343762]
 - 48 **Starzl TE**, Putnam CW, Porter KA, Halgrimson CG, Corman J, Brown BI, Gotlin RW, Rodgerson DO, Greene HL. Portal diversion for the treatment of glycogen storage disease in humans. *Ann Surg* 1973; **178**: 525-539 [PMID: 4517839]
 - 49 **Riddell AG**, Davies RP, Clark AD. Portacaval transposition in the treatment of glycogen-storage disease. *Lancet* 1966; **2**: 1146-1148 [PMID: 4162539]
 - 50 **Tzakis AG**, Kirkegaard P, Pinna AD, Jovine E, Misiakos EP, Mazioti A, Dodson F, Khan F, Nery J, Rasmussen A, Fung JJ, Demetris A, Ruiz PJ. Liver transplantation with cavoportal hemitransposition in the presence of diffuse portal vein thrombosis. *Transplantation* 1998; **65**: 619-624 [PMID: 9521194]
 - 51 **Azoulay D**, Hargreaves GM, Castaing D, Bismuth H. Caval inflow to the graft: a successful way to overcome diffuse portal system thrombosis in liver transplantation. *J Am Coll Surg* 2000; **190**: 493-496 [PMID: 10757390]
 - 52 **Weeks SM**, Alexander JR, Sandhu J, Mauro MA, Fair JH, Jaques PF. Mechanic and pharmacologic treatment of a saddle embolus to the portal vein after liver transplantation and portacaval hemitransposition. *AJR Am J Roentgenol* 2000; **175**: 537-539 [PMID: 10915710]
 - 53 **Varma CR**, Mistry BM, Glockner JF, Solomon H, Garvin PJ. Cavoportal hemitransposition in liver transplantation. *Transplantation* 2001; **72**: 960-963 [PMID: 11571468]
 - 54 **Norrby J**, Mjörnstedt L, Liden H, Friman S, Olausson M. Liver transplantation using cavoportal hemitransposition: a possibility in the presence of extensive portal vein thrombosis. *Transplant Proc* 2001; **33**: 2495-2496 [PMID: 11406225]
 - 55 **Olausson M**, Norrby J, Mjörnstedt L, Liden H, Friman S. Liver transplantation using cavoportal hemitransposition-a life-saving procedure in the presence of extensive portal vein thrombosis. *Transplant Proc* 2001; **33**: 1327-1328 [PMID: 11267310]
 - 56 **Santaniello W**, Ceriello A, Defez M, Maida P, Monti GN, Sicoli F, Calise F. Liver transplant with cavoportal hemitransposition for portal and mesenteric thrombosis: case report. *Transplant Proc* 2001; **33**: 1488-1489 [PMID: 11267386]

- 57 **Pinna AD**, Nery J, Kato T, Levi D, Nishida S, Tzakis AG. Liver transplant with portocaval hemitransposition: experience at the University of Miami. *Transplant Proc* 2001; **33**: 1329-1330 [PMID: 11267311]
- 58 **Bakthavatsalam R**, Marsh CL, Perkins JD, Levy AE, Healey PJ, Kuhr CS. Rescue of acute portal vein thrombosis after liver transplantation using a cavoportal shunt at re-transplantation. *Am J Transplant* 2001; **1**: 284-287 [PMID: 12102263]
- 59 **Urbani L**, Cioni R, Catalano G, Iaria G, Bindi L, Biancofiore G, Vignali C, Mosca F, Filipponi F. Cavoportal hemitransposition: patient selection criteria and outcome. *Transplant Proc* 2002; **34**: 3331-3333 [PMID: 12493464]
- 60 **Gerunda GE**, Merenda R, Neri D, Angeli P, Barbazza F, Valmasoni M, Feltracco P, Zangrandi F, Gangemi A, Miotto D, Gagliesi A, Faccioli AM. Cavoportal hemitransposition: a successful way to overcome the problem of total portosplenomesenteric thrombosis in liver transplantation. *Liver Transpl* 2002; **8**: 72-75 [PMID: 11799489]
- 61 **Azoulay D**, Adam R, Castaing D, Muresan S, Essomba A, Vibert E, Savier E, Smail A, Veilhan LA, Bismuth H. Liver transplantation with cavoportal or renoportal anastomosis: a solution in cases of diffuse portal thrombosis. *Gastroenterol Clin Biol* 2002; **26**: 325-330 [PMID: 12070406]
- 62 **Shrotri M**, Sudhindran S, Gibbs P, Watson CJ, Alexander GJ, Gimson AE, Jamieson NV, Delriviere L. Case report of cavoportal hemitransposition for diffuse portal vein thrombosis in liver transplantation. *Transplant Proc* 2003; **35**: 397-398 [PMID: 12591457]
- 63 **Kumar N**, Atkison P, Fortier MV, Grant DR, Wall WJ. Cavoportal transposition for portal vein thrombosis in a pediatric living-related liver transplantation. *Liver Transpl* 2003; **9**: 874-876 [PMID: 12884203]
- 64 **Verran D**, Crawford M, Stormon M, Shun A. Liver retransplantation in an infant requiring cavoportal hemi transposition. *Pediatr Transplant* 2004; **8**: 416-419 [PMID: 15265170]
- 65 **Ceulemans B**, Aerts R, Monbaliu D, Coosemans W, Verslype C, Van Steenberghe W, Yap P, Fevery J, Nevens F, Pirenne J. Liver transplantation using cavoportal transposition: an effective treatment in patients with complete splanchnic venous thrombosis. *Transplant Proc* 2005; **37**: 1112-1114 [PMID: 15848638]
- 66 **Bertelli R**, Nardo B, Montalti R, Beltempo P, Puviani L, Cavallari A. Liver transplantation in recipients with portal vein thrombosis: experience of a single transplant center. *Transplant Proc* 2005; **37**: 1119-1121 [PMID: 15848641]
- 67 **Wang C**, Zhang T, Song S, Xiu D, Jiang B. Liver transplant with portocaval hemitransposition: blood supply with only hepatic artery is possible? *Transplant Proc* 2005; **37**: 2163-2165 [PMID: 15964367]
- 68 **Ozden I**, Suoglu OD, Aydogan A, Bilge O, Yavru A, Sokucu S, Acarli K. Successful living-donor liver transplantation and retransplantation with cavoportal hemitransposition: a case report. *Exp Clin Transplant* 2006; **4**: 562-566 [PMID: 17238859]
- 69 **Lipshutz GS**, Patel S, Hiatt JR, Yersiz H, Farmer DG, McDiarmid SV, Ghobrial RM, Busuttil RW. Portocaval hemitransposition in pediatric liver transplant recipients: a single-center experience. *Liver Transpl* 2006; **12**: 1097-1103 [PMID: 16799947]
- 70 **Egawa H**, Tanaka K, Kasahara M, Takada Y, Oike F, Ogawa K, Sakamoto S, Kozaki K, Taira K, Ito T. Single center experience of 39 patients with preoperative portal vein thrombosis among 404 adult living donor liver transplantations. *Liver Transpl* 2006; **12**: 1512-1518 [PMID: 17004256]
- 71 **Selvaggi G**, Weppler D, Nishida S, Moon J, Levi D, Kato T, Tzakis AG. Ten-year experience in porto-caval hemitransposition for liver transplantation in the presence of portal vein thrombosis. *Am J Transplant* 2007; **7**: 454-460 [PMID: 17229075]
- 72 **Li FG**, Yan LN, Wang WT. Extensive thrombosis of the portal vein and vena cava after orthotopic liver transplantation with cavoportal hemitransposition: a case report. *Transplant Proc* 2008; **40**: 1777-1779 [PMID: 18589194 DOI: 10.1016/j.transproceed.2007.09.048]
- 73 **Yan ML**, Zeng Y, Li B, Xu MQ, Wen TF, Wang WT, Yang JY, Yan LN. Postoperative complications after liver transplantation with cavoportal hemitransposition. *Hepatobiliary Pancreat Dis Int* 2008; **7**: 322-324 [PMID: 18522891]
- 74 **Gao PJ**, Zhu JY, Li GM, Leng XS. Liver transplantation for the patients with end stage liver disease and portal vein thrombosis. *Beijing Da Xue Xue Bao* 2009; **41**: 558-560 [PMID: 19829674]
- 75 **Campsen J**, Kam I. Combined piggyback technique and cavoportal hemitransposition for liver transplant. *Case Rep Med* 2010; **2010**: 595289 [PMID: 20671910 DOI: 10.1155/2010/595289]
- 76 **Suarez Artacho G**, Barrera Pulido L, Alamo Martinez JM, Serrano Diez-Canedo J, Bernal Bellido C, Marín Gomez LM, Padillo Ruiz J, Gómez Bravo MA. Outcomes of liver transplantation in candidates with portal vein thrombosis. *Transplant Proc* 2010; **42**: 3156-3158 [PMID: 20970634 DOI: 10.1016/j.transproceed.2010.05.057]
- 77 **Ravaioli M**, Zanello M, Grazi GL, Ercolani G, Cescon M, Del Gaudio M, Cucchetti A, Pinna AD. Portal vein thrombosis and liver transplantation: evolution during 10 years of experience at the University of Bologna. *Ann Surg* 2011; **253**: 378-384 [PMID: 21183851 DOI: 10.1097/SLA.0b013e318206818b]
- 78 **Shi Z**, Yan L, Wen T, Chen Z. Cavoportal hemitransposition in an adult-to-adult, living-donor liver transplantation. *Dig Liver Dis* 2011; **43**: e2 [PMID: 19945363 DOI: 10.1016/j.dld.2009.10.003]
- 79 **Lai Q**, Darius T, Monbaliu D, Pinheiro R, Ciccirelli O, Pirenne J, Lerut J. Cavoportal hemitransposition in liver transplant recipients with complete and diffuse splanchnic venous thrombosis. *Transplantation* 2012; **94** Suppl 10: 168
- 80 **Chmurowicz T**, Zasada-Cedro K, Wojcicki M. Cavoportal hemitransposition for unrecognized spontaneous mesocaval shunt after liver transplantation: a case report. *Transpl Int* 2013; **26**: E46-E49 [PMID: 23506649 DOI: 10.1111/tri.12086]
- 81 **Francoz C**, Valla D, Durand F. Portal vein thrombosis, cirrhosis, and liver transplantation. *J Hepatol* 2012; **57**: 203-212 [PMID: 22446690 DOI: 10.1016/j.jhep.2011.12.034]
- 82 **Fujishiro J**, Pech TC, Finger TF, Praktinjo M, Stoffels B, Standop J, Abu-Elmagd K, Tuerler A, Hirner A, Kalff JC, Schaefer N. Influence of immunosuppression on alloresponse, inflammation and contractile function of graft after intestinal transplantation. *Am J Transplant* 2010; **10**: 1545-1555 [PMID: 20642681 DOI: 10.1111/j.1600-6143.2010.03117.x]
- 83 **Vianna RM**, Mangus RS, Kubal C, Fridell JA, Beduschi T, Tector AJ. Multivisceral transplantation for diffuse portomesenteric thrombosis. *Ann Surg* 2012; **255**: 1144-1150 [PMID: 22549750 DOI: 10.1097/SLA.0b013e31825429c0]
- 84 **Nickkholgh A**, Contin P, Abu-Elmagd K, Golriz M, Gotthardt D, Morath C, Schemmer P, Mehrabi A. Intestinal transplantation: review of operative techniques. *Clin Transplant* 2013; **27** Suppl 25: 56-65 [PMID: 23909503 DOI: 10.1111/ctr.12190]
- 85 **Wunderlich H**, Brockmann JG, Voigt R, Rauchfuss F, Pascher A, Brose S, Binner C, Bittner H, Klar E. DTG procurement guidelines in heart beating donors. *Transpl Int* 2011; **24**: 733-757 [PMID: 21668528 DOI: 10.1111/j.1432-2277.2011.01266.x]
- 86 **Vianna RM**, Mangus RS, Tector AJ. Current status of small bowel and multivisceral transplantation. *Adv Surg* 2008; **42**: 129-150 [PMID: 18953814]
- 87 **Mangus RS**, Tector AJ, Kubal CA, Fridell JA, Vianna RM. Multivisceral transplantation: expanding indications and improving outcomes. *J Gastrointest Surg* 2013; **17**: 179-86; discussion p.186-7 [PMID: 23070622]
- 88 **Abu-Elmagd KM**, Costa G, Bond GJ, Soltys K, Sindhi R,

Wu T, Koritsky DA, Schuster B, Martin L, Cruz RJ, Murase N, Zeevi A, Irish W, Ayyash MO, Matarese L, Humar A, Mazariegos G. Five hundred intestinal and multivisceral

transplantations at a single center: major advances with new challenges. *Ann Surg* 2009; **250**: 567-581 [PMID: 19730240 DOI: 10.1097/SLA.0b013e3181b67725]

P- Reviewer: Di Costanzo GG, Xia VW **S- Editor:** Gou SX
L- Editor: Webster JR **E- Editor:** Wu HL



Palliation: Hilar cholangiocarcinoma

Mahesh Kr Goenka, Usha Goenka

Mahesh Kr Goenka, Institute of Gastro Sciences, Apollo Gleneagles Hospitals, Kolkata 700054, India

Usha Goenka, Department of Imaging and Interventional Radiology, Apollo Gleneagles Hospitals, Kolkata 700054, India

Author contributions: Goenka MK conceptualized, reviewed the literature and prepared the final draft; Goenka U reviewed the literature, revised the draft and prepared the final version for publication.

Correspondence to: Mahesh Kr Goenka, MD, DM, FACG, FASGE, Director, Institute of Gastro Sciences, Apollo Gleneagles Hospitals, 58 Canal Circular Road, Kolkata 700054, India. mkgkolkata@gmail.com

Telephone: +91-33-23203040 Fax: +91-33-23205218

Received: October 29, 2013 Revised: May 28, 2014

Accepted: June 14, 2014

Published online: August 27, 2014

Abstract

Hilar cholangiocarcinomas are common tumors of the bile duct that are often unresectable at presentation. Palliation, therefore, remains the goal in the majority of these patients. Palliative treatment is particularly indicated in the presence of cholangitis and pruritus but is often also offered for high-grade jaundice and abdominal pain. Endoscopic drainage by placing stents at endoscopic retrograde cholangio-pancreatography (ERCP) is usually the preferred modality of palliation. However, for advanced disease, percutaneous stenting has been shown to be superior to endoscopic stenting. Endosonography-guided biliary drainage is emerging as an alternative technique, particularly when ERCP is not possible or fails. Metal stents are usually preferred over plastic stents, both for ERCP and for percutaneous biliary drainage. There is no consensus as to whether it is necessary to place multiple stents within advanced hilar blocks or whether unilateral stenting would suffice. However, recent data have suggested that, contrary to previous belief, it is useful to drain more than 50% of the liver volume for favorable long-term results. In the presence of cholangitis, it is beneficial to drain all of the obstructed biliary segments. Surgical bypass plays a limited role in palliation and is offered primarily as a

segment III bypass if, during a laparotomy for resection, the tumor is found to be unresectable. Photodynamic therapy and, more recently, radiofrequency ablation have been used as adjuvant therapies to improve the results of biliary stenting. The exact technique to be used for palliation is guided by the extent of the biliary involvement (Bismuth class) and the availability of local expertise.

© 2014 Baishideng Publishing Group Inc. All rights reserved.

Key words: Cholangiocarcinoma; Hilar cholangiocarcinoma; Klatskin's tumor; Palliation; Biliary stenting

Core tip: The majority of patients with hilar cholangiocarcinoma present in advanced stages and are candidates for palliation only. The techniques of palliation, primarily at endoscopy or by percutaneous techniques, are evolving as better stents become available. Alternate techniques, such as endosonography-guided procedures, are also becoming popular. Photodynamic therapy and radio-frequency ablation are also used to improve the results of biliary stents. This review article provides a consolidated picture of the present knowledge in this field based on recent data.

Goenka MK, Goenka U. Palliation: Hilar cholangiocarcinoma. *World J Hepatol* 2014; 6(8): 559-569 Available from: URL: <http://www.wjgnet.com/1948-5182/full/v6/i8/559.htm> DOI: <http://dx.doi.org/10.4254/wjh.v6.i8.559>

INTRODUCTION

Bile duct cancers at or around the confluence of the right and left hepatic ducts are termed as hilar cholangiocarcinomas (HC) or Klatskin's tumors. HC is the most common type of bile duct cancer throughout the world and constitutes 46%-97% of all bile duct cancers^[1,2]. It has a particularly high prevalence in certain Asian countries, such as Thailand and China^[3]. This could be related to

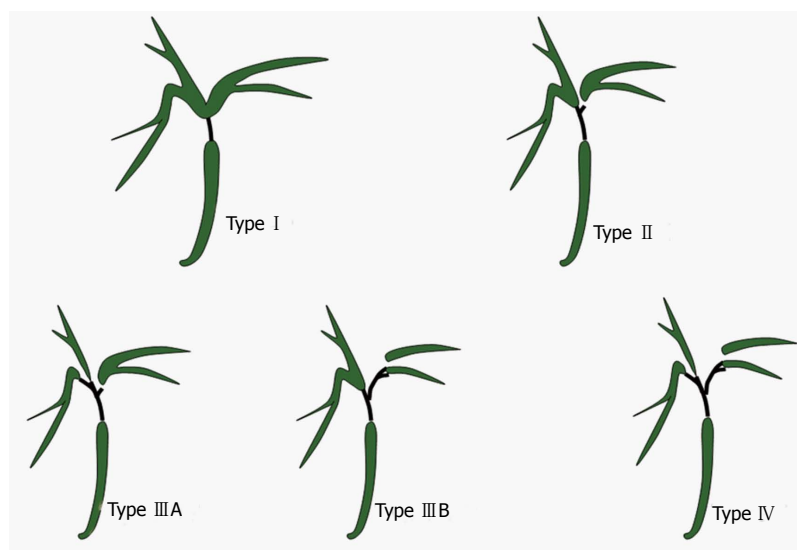


Figure 1 Hilar Cholangiocarcinoma-Bismuth classification.

Type I : Confluence of right and left hepatic duct is intact; Type II : Right and left hepatic ducts are separated; Type III : Tumor extends into second degree branches of right (IIIA) or left (IIIB) hepatic duct; Type IV : Involvement of both side secondary branches.

Table 1 Criteria for non-resectability of hilar cholangiocarcinoma

| |
|--|
| Bilateral hepatic duct involvement up to the secondary biliary radicles (Bismuth type IV) |
| Encasement or occlusion of the main portal vein (relative) |
| Unilateral tumor extension to secondary biliary radicles (Bismuth type III) with contralateral portal vein or hepatic artery involvement or encasement |
| Hepatic lobar atrophy with contralateral portal vein or hepatic artery involvement or encasement |
| Hepatic lobar atrophy with contralateral tumor extension to the secondary biliary radicles |

Available from Aljiffry *et al*^[6].

the liver fluke infestation in these areas. Due to the critical nature and site of the disease, patients with HC suffer greatly from progressive jaundice, anorexia, pruritus, cholangitis and liver failure. Unfortunately, a majority of HC cases manifest late and are diagnosed at a stage when curative resection is not possible^[4,5]. Palliation, therefore, is the goal for this subset of patients. This review addresses the indications, techniques and results of various palliative methods. There are a number of “grey zones” in the palliative treatment of HC; these have also been addressed.

INDICATIONS FOR PALLIATION

Only approximately 20%-30% of patients with HC are diagnosed at a stage when surgical resection is possible. Table 1 gives the criteria for surgical non-resectability^[6]. Moreover, the associated co-morbidity often precludes any form of surgery. While the median survival for resected patients (R0) can be up to 4 years, for those without the feasible option of resection, survival is almost always less than 1 year^[4,7]. Multi-detector CT scan (MDCT) and magnetic resonance imaging (MRI) with MR Cholangiography continue to be the most two accurate modalities in the evaluation of the stages and resectability of HC^[8,9]. The accuracy of predicting hepatic artery invasion, portal vein involvement, lymph nodal metastasis and the extent of biliary ductal spread is approximately

85%-95% in both of these approaches^[8,9]. Endoscopic ultrasonography (EUS), positron emission tomography (PET) and diagnostic laparoscopy are additional means of evaluating the resectability of HC, but their role is not yet fully established^[10-12].

Not every patient with unresectable HC needs palliative intervention. Patients with complications of cholangitis and intractable pruritus are definite candidates for palliation. Palliation is also often performed in patients with abdominal pain and high bilirubin with the hope of ameliorating their pain and sense of well-being, respectively. There are three established methods for the palliation of HC: endoscopic insertion of a stent, percutaneous placement of biliary drainage and surgical bypass. Endosonography-guided procedures have been evolving as alternatives to these standard techniques.

ENDOSCOPIC PALLIATION BY STENTING

Before planning any palliative drainage, either by endoscopy or percutaneously, it is mandatory to obtain a cholangiogram to define the extent of biliary ductal involvement. Magnetic resonance cholangio-pancreatography (MRCP) continues to be the most preferred investigation for this purpose, and HC has been classified as Bismuth type I to type IV at cholangiogram (Figure 1).

Metal vs plastic stents

Both plastic stents (PS) and self-expanding metal stents (SEMS) have been used for biliary drainage (Figure 2). PS have smaller diameters (10-12 Fr), resulting in faster occlusions and a median patency time of only 1.4 to 3 mo^[13]. SEMS have a wider diameter (8-10 mm), resulting in longer patency of 6-10 mo^[13]. SEMS, which are used for HC, are uncovered with an open mesh, allowing the drainage of side branches. Perdue *et al*^[14], in a multicenter study involving 62 patients, compared metal stents with plastic stents in HC for 30 d outcomes. Adverse effects, including cholangitis, stent occlusion, migration, perforation and the need for reinterventions, occurred in a

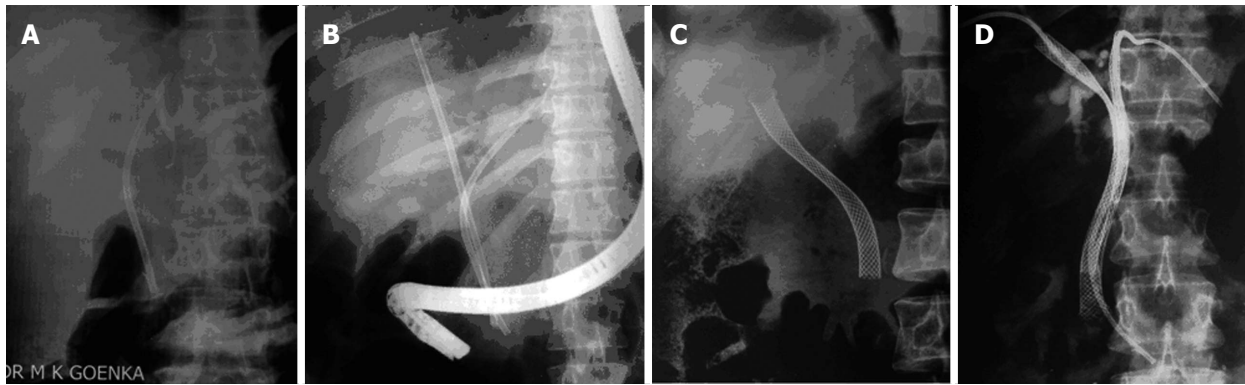


Figure 2 Stenting for hilar cholangiocarcinoma. A: Unilateral plastic stent; B: Bilateral plastic stents; C: Unilateral metal stent; D: Bilateral metal stents (previously placed percutaneous drains are still in place).

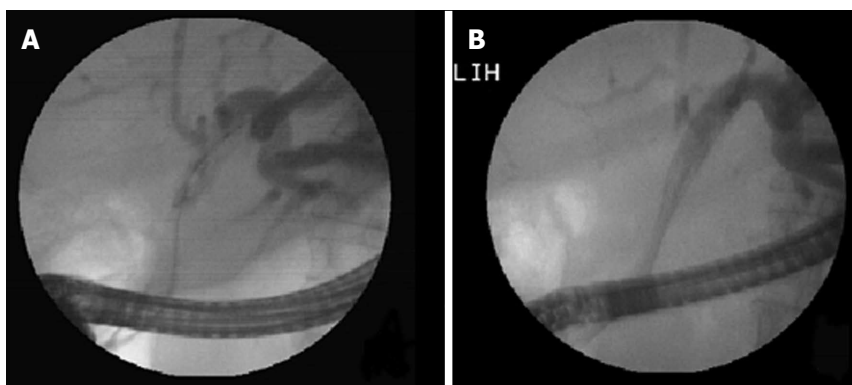


Figure 3 Hilar stricture: Unilateral metal stent placed in dilated left lobe duct. A: Left duct selectively cannulated and showing dilated system; B: Metal stent being deployed in the left ductal system.

Table 2 Unilateral *vs* bilateral drainage for hilar cholangiocarcinoma

| | Unilateral | Bilateral | P |
|-------------------------|------------|-----------|-------|
| No. of pts | 79 | 78 | - |
| Stent insertion (%) | 88.6 | 76.9 | 0.041 |
| Successful drainage (%) | 81.0 | 73.0 | 0.049 |
| Early complication (%) | 18.9 | 26.9 | 0.026 |
| Survival (d) | 140 | 142 | 0.482 |

Available from De Palma *et al*^[16].

significantly higher proportion of patients in the plastic stent group (39.3%), compared to metal stents (11.8%). These results were revalidated in a recent study from Thailand^[15]. In this randomized study involving 108 patients, Sangchan *et al*^[15] demonstrated that metal stents were better in terms of success rate (70% *vs* 46%) and patient survival (126 d *vs* 49 d). In spite of its high initial cost, SEMs are considered more cost-effective than PS. This result could be due to the greater success rate, shorter hospital stays, fewer blockages, fewer re-interventions and lower antibiotic needs associated with SEMs. The superior cost-effectiveness of SEMs compared to PS is particularly apparent if patient survival is expected to be more than 4–6 mo. However, in situations where a decision of palliation has not been made, plastic stents may be preferred because uncovered SEMs used for hilar blocks are not easily removable.

Volume of drainage and number of stents (unilateral *vs* bilateral)

For Bismuth type I HC, it is obvious that one stent is sufficient to drain both lobes of the liver because the confluence is patent. However, the placement of single stent for Bismuth type II to type IV HC would drain only a proportion of liver; instead, multiple stents are often placed in these advanced HC patients. However, no consensus has been reached in terms of the need for multiple stents.

De Palma *et al*^[16] reported better results with unilateral stenting (*vs* bilateral stenting) in terms of successful stent placement, effective drainage and complication rates (Table 2). However, approximately one-third of the patients in this series had Bismuth type I HC, leading to a bias in the study result. Contrary to this study, Naitoh *et al*^[17] demonstrated a trend towards longer survival and lower cholangitis with bilateral, compared to unilateral, drainage. An important conclusion was drawn in a study by Chang *et al*^[18], which showed that patients with HC fared very poorly, with high cholangitis rates (32%), high 30 d mortality (30%) and poor survival (45 d) if only one stent was placed after opacifying both sides of the liver. This was in contrast to the other two groups, in which the opacified lobes were drained by one or two stents (Table 3). It therefore seems that any contrast placed in an obstructed system must be drained. An experienced endoscopist dealing with hilar blocks is always reluctant to inject any contrast until a guide wire has been negotiat-

Table 3 Malignant hilar obstruction-1 stent or 2

| | Group A | Group B | Group C |
|-------------------|---------|---------|---------|
| <i>n</i> | 32 | 29 | 37 |
| Early cholangitis | 6% | 0% | 32% |
| 30-d mortality | 0% | 3% | 30% |
| Survival (d) | 145 | 225 | 45 |

Group A: One lobe opacified and the same lobe drained; Group B: Both lobes opacified and both lobes drained; Group C: Both lobes opacified with just one lobe drained. Available from Chang *et al*^[18].

ed well beyond the site of the biliary obstruction. A study in India^[19] demonstrated the importance of contrast-free unilateral endoscopic palliation in Bismuth type II HC. In 18 patients submitting to this technique, successful drainage was achieved in all, with no cholangitis or 30 d mortality.

Conventional teaching suggests that, in the absence of cholangitis, it is only necessary to drain 25% of the liver volume for the adequate palliation of jaundice^[20]. However, a recent study by Vienne *et al*^[21] showed better results with the drainage of more than half of the liver volume. More than a 50% drainage of the liver volume was associated with a greater decrease in bilirubin levels, a lower incidence of early cholangitis and longer patient survival compared to patients with less than a 50% drainage of the liver volume. It is known that the right lobe, left lobe and caudate lobes of liver constitute 55%-60%, 30%-35% and approximately 10% of the liver volume, respectively^[22]. Incorporating this information in the results of the study by Vienne *et al*^[21], a significant proportion of patients should undergo the draining of at least two segments and the placement of more than one stent to achieve good long-term palliation. However, more data are needed in this respect. It is important to note that, in the presence of cholangitis, all infected ductal systems need to be drained.

It is important to select the appropriate segments of the liver that need to be drained when unilateral or incomplete drainage is planned in patients with advanced HC (Bismuth type II to type IV). It is advisable to select segments with dilated ductal systems and to avoid atrophic segments (Figure 3). MDCT or MRI can provide this useful information prior to palliative stenting^[23,24]. A number of studies with both PS and SEMS have shown the usefulness of CT/MRCP-guided, selective biliary drainage (Table 4)^[16,25,26]. This CT/MRCP approach can reduce the need for further intervention and has been found to be cost-effective compared to routine bilateral stenting^[27]. A recent study^[28] with a small number of patients used air cholangiography rather than MRCP to act as a lower cost road map and found air cholangiography to be safe and effective with no cholangitis and no 30 d mortality or morbidity.

Endoscopic stenting technique

Stents in HC are mostly introduced at endoscopy^[23]. In terms of the complexity of endoscopic procedures,

Table 4 Computed tomography/magnetic resonance cholangio-pancreatography -Guided Selective Unilateral Stenting

| Ref. | Hintze <i>et al</i> ^[25] | Freeman <i>et al</i> ^[26] | De Palma <i>et al</i> ^[16] |
|-----------------------|-------------------------------------|--------------------------------------|---------------------------------------|
| No. of pts | 35 | 35 | 61 |
| Stent | Plastic | Metal | Metal |
| Tech. success (%) | 100 | 100 | 97 |
| Effective drain (%) | 86 | 77 | 97 |
| Early cholangitis (%) | 6 | 0 | 5 |
| Median patency (d) | - | 165 | 169 |
| Median survival (d) | 300 | 150 | 140 |

stenting a hilar block is considered one of the most difficult. In a recent consensus, the American Society of Gastrointestinal Endoscopy graded endoscopic hilar stenting as a level 3 ERCP procedure in terms of complexity, with level 1 being the simplest and level 4 being most complex^[29]. In general, a higher level of complexity is associated with a lower success rate and a higher complication rate^[30]. Therefore, hilar stenting should be practiced only by experienced therapeutic endoscopists.

A variety of plastic and SEMS are available and have been used for the stenting in HC. In general, 10 Fr plastic stent and uncovered SEMS are preferred. The distal end of stents may be left in the duodenum or in distal bile duct, but the later situation may make reintervention more difficult. When more than one stent (plastic or SEMS) is to be placed, the stents are usually placed side by side (Figure 4). However, in the last few years, a new dual stent design called "stent-in-stent" has been developed for metal stenting^[31,32] (Figure 5). In this device, the first stent has an open-cell design, allowing the second stent to pass easily through the first stent. In a recent study by Lee *et al*^[33] from South Korea, stent-in-stent technology for bilateral stenting was evaluated in 84 patients with inoperable, high-grade HC. Technical and clinical success was achieved in 95.2% and 92.9% of patients, respectively. The median survival and patency were noted to be 256 d and 239 d, respectively. Still, this new stent design can be problematic if the first stent becomes occluded. In the study by Lee *et al*^[33], 30.8% patients had an obstruction of the primary biliary stents. For revision stenting, bilateral metal stents could be placed in 55%, while plastic stents were placed in the remaining patients^[33].

It is important to institute antibiotic prophylaxis in patients with anticipated incomplete biliary drainage by any technique^[34]. Antibiotics should be continued in cases of incomplete biliary drainage. The choice of antibiotics should be based on local hospital data.

The occlusion of metal stents, while more common and earlier with plastic stents, can still occur^[35]. Blocked plastic stents should always be removed, and the bile ducts should be cleaned of all sludge by a balloon. Then, a new plastic stent can be positioned. Metal stents, however, may be the better choice, particularly in the presence of thick bile or purulent material. It may also be a good idea to temporarily place a nasobiliary drain for repeated flushing prior to restenting^[35]. Uncovered SEMS

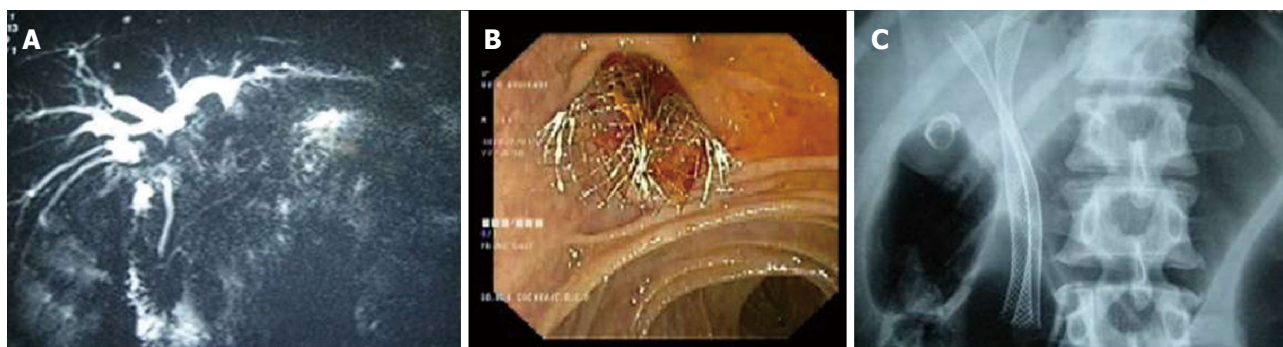


Figure 4 Two metal stents placed side by side in a Type II Bismuth hilar cholangiocarcinoma. A: Magnetic resonance cholangiopancreatography showing the stricture; B: Endoscopic view showing two metal stents placed side by side; C: X-ray showing two parallel stents with proximal ends in the right or left ductal systems.

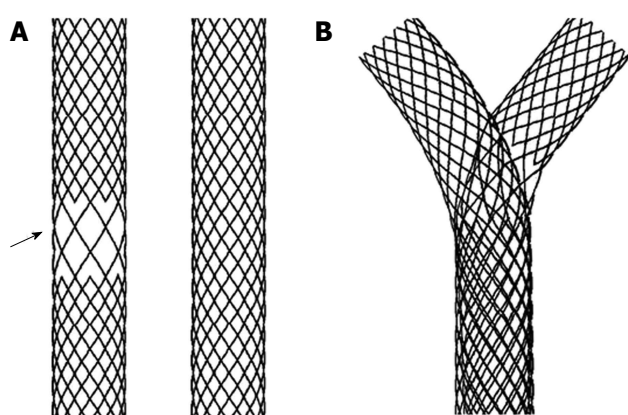


Figure 5 Y stent (stent-in-stent) from Tae Woong Medical (South Korea) for Hilar Cholangiocarcinoma. A: Two stents one with open mesh in the middle (arrow) and other with normal mesh; B: Y stent system in which the normal mesh stent passes through the open mesh of the second stent.

cannot be removed and therefore should be cleaned if they become clogged. However, it is advisable to place another stent through the blocked metal stent. The new stent could be either plastic or SEMS, depending upon the patient's life expectancy.

PERCUTANEOUS BILIARY DRAINAGE

With technical expertise, it is also possible to perform palliative intervention in HC by percutaneous techniques (Figure 6). Percutaneous procedures have the theoretical advantage of precise lobar selection, which can result in less cholangitis. Moreover, the percutaneous approach can be performed with minimal sedation, which may be beneficial in an unstable patient. Alternatively, the percutaneous approach may be a two-step procedure with external drainage (percutaneous transhepatic biliary drainage) during first session, followed by internalization and subsequent stenting. Pain at the puncture site and the risk of biliary peritonitis are additional concerns with the use of percutaneous approach.

Just as with the endoscopic data, the advantages of metal stents over plastic stents have been demonstrated in percutaneous approaches as well. Prolonged survival

and lower morbidity have been shown with metal stents compared to plastic stents^[36]. While using multiple SEMS percutaneously, stents may be placed side by side. However, a T or Y configuration (Figure 7), in which one stent crosses the block and the second stent only reaches the first stent or crosses from the left to the right ducts, have also been used successfully^[37]. T or Y configuration stents have been shown to have a median patency of 279 and 218 d and a median survival of 334 and 375 d, respectively^[38,39].

Few studies have compared percutaneous procedures with endoscopic techniques in HC, and no randomized controlled trials are available addressing this issue. A multicenter retrospective study^[40] from South Korea has compared the results of endoscopy *vs* percutaneous techniques for advanced HC (Bismuth type III and IV). In their 85 patients (endoscopy 44, percutaneous 41), they noted better results for percutaneous procedure, (compared to endoscopy) with a significantly higher success rate (93% *vs* 77%, $P = 0.049$) and a trend towards a lesser cholangitis risk (22% *vs* 29.5%). Similar conclusions were drawn from two other studies from Asia^[41,42]. Non-infective complications, such as bleeding and pancreatitis, were more frequent in the percutaneous group. This result suggests that, if infective complication can be avoided by performing contrast-free cannulation, ERCP may have an advantage, even in advanced HC.

In contrast to these results, endoscopy in general is the preferred approach for less advanced Bismuth type (Type I and II) HCs, mainly because endoscopy is a less invasive and faster procedure. However, no comparative data are available, and local expertise usually guides the treatment approach in these patients. Occasionally, palliation after endoscopic stenting may be suboptimal due to the presence of pus flakes, mucus or blood clots in the biliary ductal system. A temporary placement of a percutaneous catheter can allow repeated saline irrigations and may enable effective biliary drainage. It must be recognized that HC requires a multidisciplinary approach, with close co-ordination between the endoscopist and radiologist. For example, a failed endoscopic drainage after ductal opacification may result in suppurative cholangitis,

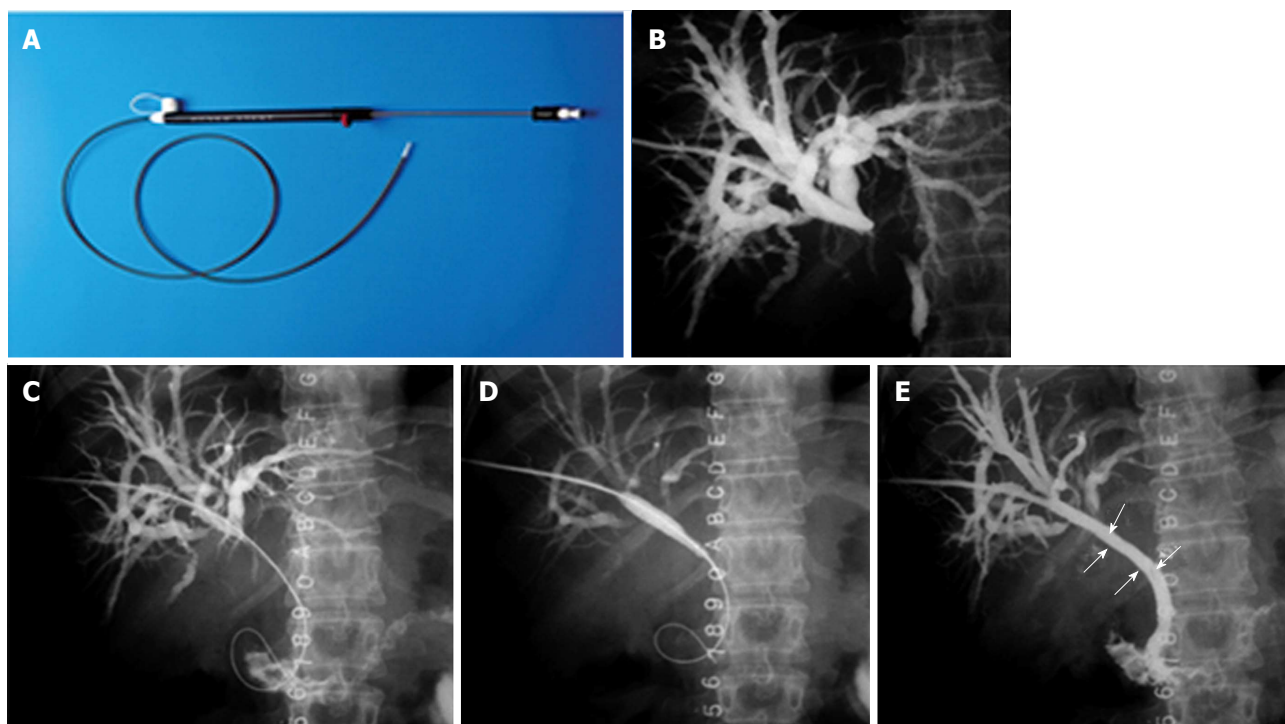


Figure 6 Percutaneous stenting in Bismuth Type I hilar cholangiocarcinoma. A: Stent assembly; B: Cholangiogram showing the block; C: Guide wire being negotiated across the stricture; D: Balloon dilatation being performed; E: Stent (arrow) after deployment.

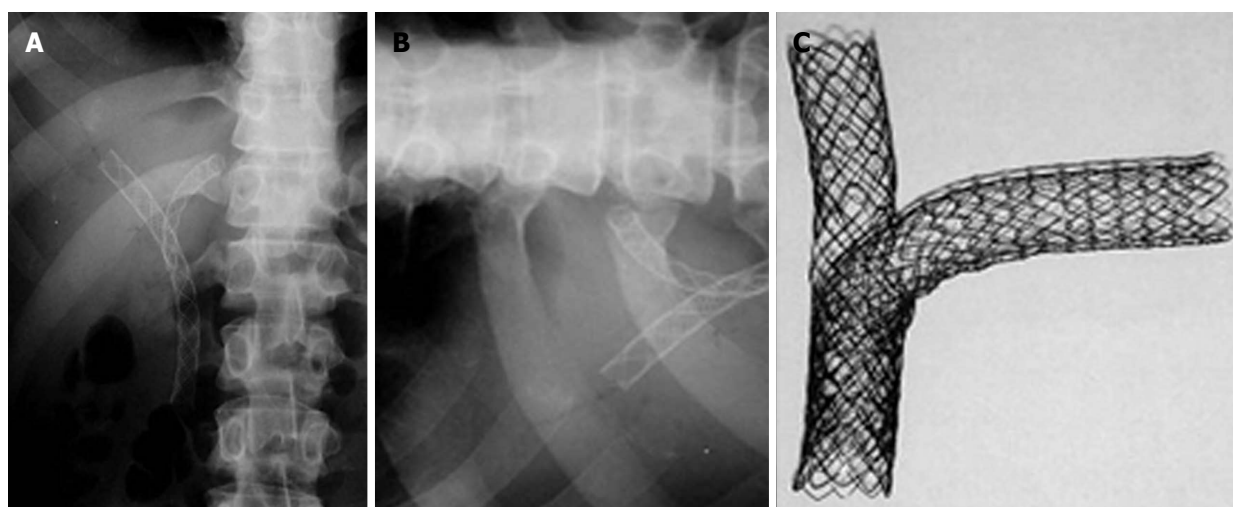


Figure 7 Percutaneous double stenting. A: X-ray showing the Y configuration of the stent (Boston Scientific MA, United States); B: Transverse limb of a T stent (Taewoong Medial, South Korea) showing the open mesh in the center; C: Assembly of a T stent showing the vertical stent passing through the open mesh of the transverse stent.

and an emergency percutaneous drainage may become mandatory.

ENDOSONOGRAPHY GUIDED BILIARY DRAINAGE

Endosonography (EUS)-guided biliary drainage is emerging as an alternative to ERCP and percutaneous biliary stenting^[43-46]. In the present scenario, an EUS-guided procedure is performed only if the ERCP fails in the presence of a tight hilar block or distorted duodenal anatomy. It remains unclear if EUS-guided drainage should be the

second preferred modality or if it should be performed only when the percutaneous procedure fails or is contraindicated. Prospective randomized trials are needed to solve this issue.

The EUS technique involves the puncture of the left hepatic ducts, usually through the gastric wall, *i.e.*, hepatocogastrostomy. A guide wire is then passed through this tract. Stenting can then be achieved in one of the three ways: (1) negotiating the wire across the hilar stricture and then passing it through the ampulla into the duodenum; the rendezvous procedure is then performed by catching the wire at the papilla, positioning the stent as in the ERCP

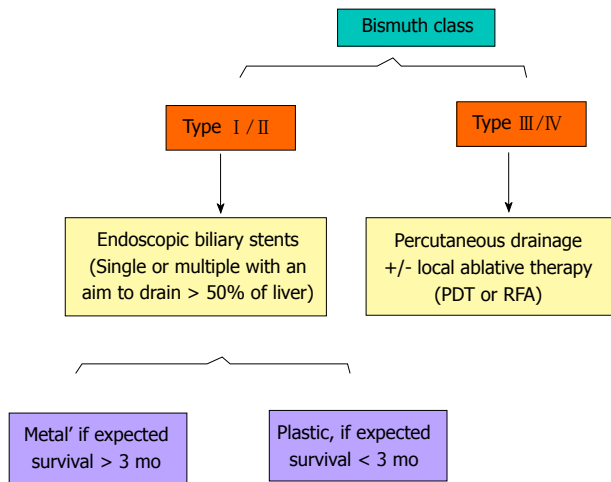


Figure 8 A simplified algorithm suggested for the palliation of Hilar Cholangiocarcinoma, based on Bismuth type. Additional percutaneous procedures may be required if the endoscopic stenting results are suboptimal. PDT: Photodynamic therapy; RFA: Radiofrequency ablation.

procedure^[43,44]; (2) negotiating the wire across the hilar stricture and then placing the stent across the stricture^[45]; or (3) placing the stent across the hepatico-jejunostomy itself without negotiating the wire across the stricture^[46].

In experienced hands, EUS-guided biliary drainage has a technical success rate of 70%-98%. However, up to 20% of patients can have complications, such as bile leak, biliary peritonitis, pneumoperitoneum, bleeding, pain or stent migration^[43-50]. This complication rate is higher than that reported historically with ERCP. All types of stents, including plastic, uncovered SEMS and covered (partial or total) SEMS, have been used. However, covered SEMS are usually preferred. Between the three techniques described above, the rendezvous technique is more natural and is preferred; however, there are no comparative data with other techniques, and the procedure is more demanding^[43,44].

EUS-guided procedures are exciting but still evolving. Because most of the data are in the form of a case series, prospective randomized studies are required to position the modality correctly in the management algorithm of hilar blocks.

SURGICAL BYPASS

Due to its invasiveness, surgical bypass has a very limited role to play in palliating hilar tumors. It is only accepted when all of the other techniques described above have failed or are not available, as well as occasionally when laparotomy has been performed for curative intent but an unresectable tumor is revealed^[51,52]. The various surgical drainage procedures that can be carried out include segment III hepaticojejunostomy, stent placement across the tumor and sectoral duct (*i.e.*, right anterior, right posterior or left hepatic duct) bypass. However, segment III bypass is the preferred choice because it resolves jaundice in approximately two-thirds of HC patients and has a median survival of approximately 6.3 mo^[53,54].

Table 5 Photodynamic therapy as an adjunct to biliary stenting: Improved survival

| | Year | No. of pts | Median survival (mo) | | P value |
|-------------------------------------|------|------------|----------------------|-------------------|----------|
| | | | Stenting alone | Stenting with PDT | |
| Ortner <i>et al</i> ^[56] | 2003 | 39 | 3 | 16 | < 0.0001 |
| Cheon <i>et al</i> ^[57] | 2004 | 47 | 10 | 18 | 0.0143 |
| Zoepef <i>et al</i> ^[58] | 2005 | 32 | 7 | 21 | 0.0109 |

PDT: Photodynamic therapy.

LOCAL ABLATIVE THERAPY

A few exciting techniques have been used to improve the results of biliary stenting with the aim of delaying stent blockage and prolonging patient survival. These techniques include photodynamic therapy, radiofrequency ablation and chemo/radiotherapy.

Photodynamic therapy

Photodynamic therapy (PDT) is a relatively new technique that has evolved over the last 10 years^[55]. PDT uses a photosensitive agent that concentrates preferentially in malignant tumors. Subsequent photoactivation with red laser lights of a specific wavelength^[56] creates reactive oxygen, leading to selective tumor cell death. Table 5 summarizes some of the studies^[56-58] that have shown improved patient survival by the addition of PDT to biliary stenting. Studies have also shown improved quality of life after PDT^[56,58]. In HC patients who have been treated with plastic stents, the stents should be removed temporarily for light delivery during PDT. In cases of SEMS, PDT can be performed through the stent by adjusted the required light dose to compensate for the decreased transmission of light^[59]. A further moot point that should be addressed is whether these results can be reproduced in certain Asian countries, in which the sun does not affect skin photosensitivity to the same extent as in the Western white population^[57,60].

In general, PDT is preferred through the percutaneous route [compared to the endoscopic] because of the lower chance of laser tip fracture, the easy repeatability of the procedure and the feasibility of obtaining cholangiogram. Shim *et al*^[61] showed that PDT using percutaneous cholangioscopy is safe and effective, improving quality of life with a good median survival time (*i.e.*, 558 ± 178.8 d). Cholangitis, hemobilia and photosensitivity are known complications of PDT.

A recent study by Wagner *et al*^[62] used temoporfin rather than conventional porfimer for PDT in 10 patients with HC. Temoporfin PDT was highly tumoricidal and had double the depth of local tumor ablative effect, compared to porfimer PDT. Infectious complications and skin photosensitivity were similar with both agents^[62].

Radiofrequency ablation

Radiofrequency ablation (RFA) is an ablative procedure that is well established for treating small liver cancers. With the introduction of an endoscopic probe for RFA

and the use of a lower power setting with the existing generators, it is now possible to treat pancreatobiliary cancers with this modality^[63]. Within the bile duct, it has the potential of improving stent patency by decreasing tumor ingrowth and benign epithelial hyperplasias. Steel *et al*^[64] were the first to demonstrate its safety and efficacy in 22 patients with biliary malignancy (pancreatic/cholangiocarcinoma). A recent study involving 20 patients with pancreatobiliary malignancy (11 with cholangiocarcinoma) showed a significant increase in bile duct diameter after RFA^[65]. Further studies are required to revalidate these results, but the preliminary data are interesting.

Chemo/radiotherapy

Radiotherapy has a very limited role in HC. Intraluminal brachytherapy has been delivered to cholangiocarcinoma using Ir-192 seeds, with a total dose of 30-50 Gy through the percutaneous route. Good short-term effects were demonstrated, showing prolonged stent patency and improved survival^[66]. A number of studies from Japan have shown better SEMS patency (10-18 mo *vs* 4-12 mo) after external beam radiotherapy^[67,68].

Chemotherapy has been used in HC as a palliative therapy for both locally advanced cancers and metastatic disease^[69]. However, most of these studies involved case series with a heterogeneous mixture of patients with HC or distal bile duct cancers, as well as pancreatic or gall bladder cancers. A retrospective study comparing a gemcitabine-based regimen with a cisplatin-based therapy and a fluoropyrimidine-based therapy clearly showed the gemcitabine-based regimen to be superior in terms of the lowest fatality^[70]. Gemcitabine has been used in combination with cisplatin, oxaliplatin or capecitabine to improve its efficacy^[69]. Valle *et al*^[71,72] compared gemcitabine with a combination of gemcitabine with cisplatin in their two ABC trials, which were published sequentially. ABC-02 trial by Valle *et al*^[72], which involved 410 patients with advanced biliary cancers in a multicenter randomized phase III study, clearly showed the superiority of the combination over gemcitabine alone. The combination improved progression-free survival and overall survival by 30% over gemcitabine alone. Another multicenter trial from Japan^[73] also demonstrated the superiority of gemcitabine combined with cisplatin over gemcitabine alone in terms of one year survival, median survival time, median progression-free survival time and overall response rate. These data have resulted in this combination being used as standard of care chemotherapy for advanced cholangiocarcinoma, including HC. Gemcitabine-free combinations, such as capecitabine with oxaliplatin, capecitabine with cisplatin and 5 fluorouracil with cisplatin, have also been used for bile duct cancers with modest results^[69]. However, newer drugs are being investigated for bile duct cancers; these include erlotinib, cetuximab and bevacizumab^[69].

CONCLUSION

HC is the most common type of malignancy of the bile

duct and is highly prevalent in the Eastern Hemisphere. Unfortunately, the majority of patients with HC manifest too late for resection. Therefore, palliation is the goal in the majority of patients. Palliation is usually performed with ERCP or through a percutaneous route. Figure 8 shows our approach and suggested guidelines based on Bismuth types. For advanced HC (Bismuth type III and IV), we prefer the percutaneous route because this has been shown to be superior to the endoscopic approach. For Bismuth type I and II, ERCP is usually preferred in view of its being less invasive and faster. Generally, we prefer metal stents over plastic stents because of the former's documented better median patency and patient survival. Plastic stents are only offered when the expected survival is very short. Controversy continues as to whether single or multiple stents should be preferred for advanced HC. Recent data suggesting that better outcomes will be obtained if > 50% of the liver is drained have made us change our policy such that we offer two stents in the majority of patients. EUS-guided biliary drainage is also gradually emerging as an alternative modality. Percutaneous or EUS-guided biliary drainage is at present offered for all patients who fail ERCP or for patients who cannot undergo ERCP due to their altered anatomy or duodenal obstructions from tumors. A few reports showed that photodynamic therapy and radiofrequency ablation could improve the patency of biliary stenting and patient survival, suggesting that this procedure should be considered in advanced tumors (Bismuth type III and IV). Local expertise is often the deciding factor for choosing one modality over the other.

REFERENCES

- 1 **Shaib Y**, El-Serag HB. The epidemiology of cholangiocarcinoma. *Semin Liver Dis* 2004; **24**: 115-125 [PMID: 15192785 DOI: 10.1055/s-2004-828889]
- 2 **Yusoff AR**, Siti ZM, Muzammil AR, Yoong BK, Vijeyasingam R. Cholangiocarcinoma: a 10-year experience of a single tertiary centre in the multi ethnicity-Malaysia. *Med J Malaysia* 2012; **67**: 45-51 [PMID: 22582548]
- 3 **Shin HR**, Oh JK, Masuyer E, Curado MP, Bouvard V, Fang YY, Wiangnon S, Sripan B, Hong ST. Epidemiology of cholangiocarcinoma: an update focusing on risk factors. *Cancer Sci* 2010; **101**: 579-585 [PMID: 20085587 DOI: 10.1111/j.1349-7006.2009.01458.x]
- 4 **Otani K**, Chijiwa K, Kai M, Ohuchida J, Nagano M, Tsuchiya K, Kondo K. Outcome of surgical treatment of hilar cholangiocarcinoma. *J Gastrointest Surg* 2008; **12**: 1033-1040 [PMID: 18085342 DOI: 10.1007/s11605-007-0453-z]
- 5 **Li H**, Qin Y, Cui Y, Chen H, Hao X, Li Q. Analysis of the surgical outcome and prognostic factors for hilar cholangiocarcinoma: a Chinese experience. *Dig Surg* 2011; **28**: 226-231 [PMID: 21540611 DOI: 10.1159/000327361]
- 6 **Aljiffry M**, Walsh MJ, Molinari M. Advances in diagnosis, treatment and palliation of cholangiocarcinoma: 1990-2009. *World J Gastroenterol* 2009; **15**: 4240-4262 [PMID: 19750567 DOI: 10.3748/wjg.15.4240]
- 7 **Hemming AW**, Reed AI, Fujita S, Foley DP, Howard RJ. Surgical management of hilar cholangiocarcinoma. *Ann Surg* 2005; **241**: 693-699; discussion 699-702 [PMID: 15849505 DOI: 10.1097/01.sla.0000160701.38945.82]
- 8 **Masselli G**, Manfredi R, Vecchioli A, Gualdi G. MR imaging and MR cholangiopancreatography in the preoperative

- evaluation of hilar cholangiocarcinoma: correlation with surgical and pathologic findings. *Eur Radiol* 2008; **18**: 2213-2221 [PMID: 18463877 DOI: 10.1007/s00330-008-1004-z]
- 9 **Lee MG**, Park KB, Shin YM, Yoon HK, Sung KB, Kim MH, Lee SG, Kang EM. Preoperative evaluation of hilar cholangiocarcinoma with contrast-enhanced three-dimensional fast imaging with steady-state precession magnetic resonance angiography: comparison with intraarterial digital subtraction angiography. *World J Surg* 2003; **27**: 278-283 [PMID: 12607051 DOI: 10.1007/s00268-002-6701-1]
 - 10 **Petrowsky H**, Wildbrett P, Husarik DB, Hany TF, Tam S, Jochum W, Clavien PA. Impact of integrated positron emission tomography and computed tomography on staging and management of gallbladder cancer and cholangiocarcinoma. *J Hepatol* 2006; **45**: 43-50 [PMID: 16690156 DOI: 10.1016/j.jhep.2006.03.009]
 - 11 **Tamada K**, Ido K, Ueno N, Ichiyama M, Tomiyama T, Nishizono T, Wada S, Noda T, Tano S, Aizawa T. Assessment of portal vein invasion by bile duct cancer using intraductal ultrasonography. *Endoscopy* 1995; **27**: 573-578 [PMID: 8608749 DOI: 10.1055/s-2007-1005760]
 - 12 **Ruys AT**, Busch OR, Gouma DJ, van Gulik TM. Staging laparoscopy for hilar cholangiocarcinoma: is it still worthwhile? *Ann Surg Oncol* 2011; **18**: 2647-2653 [PMID: 21347792 DOI: 10.1245/s10434-011-1576-8]
 - 13 **Raju RP**, Jagannathan SR, Ross WA, Davila ML, Javle M, Raju GS, Lee JH. Optimum palliation of inoperable hilar cholangiocarcinoma: comparative assessment of the efficacy of plastic and self-expanding metal stents. *Dig Dis Sci* 2011; **56**: 1557-1564 [PMID: 21222156 DOI: 10.1007/s10620-010-1550-5]
 - 14 **Perdue DG**, Freeman ML, DiSario JA, Nelson DB, Fennerly MB, Lee JG, Overby CS, Ryan ME, Bochna GS, Snady HW, Moore JP. Plastic versus self-expanding metallic stents for malignant hilar biliary obstruction: a prospective multicenter observational cohort study. *J Clin Gastroenterol* 2008; **42**: 1040-1046 [PMID: 18719507 DOI: 10.1097/MCG.0b013e31815853e0]
 - 15 **Sangchan A**, Kongkasame W, Pugkhem A, Jenwitheesuk K, Mairiang P. Efficacy of metal and plastic stents in unresectable complex hilar cholangiocarcinoma: a randomized controlled trial. *Gastrointest Endosc* 2012; **76**: 93-99 [PMID: 22595446 DOI: 10.1016/j.gie.2012.02.048]
 - 16 **De Palma GD**, Galloro G, Siciliano S, Iovino P, Catanzano C. Unilateral versus bilateral endoscopic hepatic duct drainage in patients with malignant hilar biliary obstruction: results of a prospective, randomized, and controlled study. *Gastrointest Endosc* 2001; **53**: 547-553 [PMID: 11323577 DOI: 10.1067/mge.2001.113381]
 - 17 **Naitoh I**, Ohara H, Nakazawa T, Ando T, Hayashi K, Okumura F, Okayama Y, Sano H, Kitajima Y, Hirai M, Ban T, Miyabe K, Ueno K, Yamashita H, Joh T. Unilateral versus bilateral endoscopic metal stenting for malignant hilar biliary obstruction. *J Gastroenterol Hepatol* 2009; **24**: 552-557 [PMID: 19220678 DOI: 10.1111/j.1440-1746.2008.05750.x]
 - 18 **Chang WH**, Kortan P, Haber GB. Outcome in patients with bifurcation tumors who undergo unilateral versus bilateral hepatic duct drainage. *Gastrointest Endosc* 1998; **47**: 354-362 [PMID: 9609426 DOI: 10.1016/S0016-5107[98]70218-4]
 - 19 **Singh V**, Singh G, Verma GR, Singh K, Gulati M. Contrast-free unilateral endoscopic palliation in malignant hilar biliary obstruction: new method. *J Gastroenterol Hepatol* 2004; **19**: 589-592 [PMID: 15086605 DOI: 10.1111/j.1440-1746.2003.03313.x]
 - 20 **Dowsett JF**, Vaira D, Hatfield AR, Cairns SR, Polydorou A, Frost R, Croker J, Cotton PB, Russell RC, Mason RR. Endoscopic biliary therapy using the combined percutaneous and endoscopic technique. *Gastroenterology* 1989; **96**: 1180-1186 [PMID: 2925062]
 - 21 **Vienne A**, Hobeika E, Gouya H, Lapidus N, Fritsch J, Choury AD, Chrysostalis A, Gaudric M, Pelletier G, Buffet C, Chaussade S, Prat F. Prediction of drainage effectiveness during endoscopic stenting of malignant hilar strictures: the role of liver volume assessment. *Gastrointest Endosc* 2010; **72**: 728-735 [PMID: 20883850 DOI: 10.1016/j.gie.2010.06.040]
 - 22 **Bismuth H**. Surgical anatomy and anatomical surgery of the liver. *World J Surg* 1982; **6**: 3-9 [PMID: 7090393 DOI: 10.1007/BF01656368]
 - 23 **Khan SA**, Davidson BR, Goldin R, Pereira SP, Rosenberg WM, Taylor-Robinson SD, Thillainayagam AV, Thomas HC, Thursz MR, Wasan H. Guidelines for the diagnosis and treatment of cholangiocarcinoma: consensus document. *Gut* 2002; **51** Suppl 6: VI1-VI9 [PMID: 12376491 DOI: 10.1136/gut.51.suppl_6.vi1]
 - 24 **Khan SA**, Davidson BR, Goldin RD, Heaton N, Karani J, Pereira SP, Rosenberg WM, Tait P, Taylor-Robinson SD, Thillainayagam AV, Thomas HC, Wasan H. Guidelines for the diagnosis and treatment of cholangiocarcinoma: an update. *Gut* 2012; **61**: 1657-1669 [PMID: 22895392 DOI: 10.1136/gutjnl-2011-301748]
 - 25 **Hintze RE**, Abou-Rebyeh H, Adler A, Veltzke-Schlieker W, Felix R, Wiedenmann B. Magnetic resonance cholangiopancreatography-guided unilateral endoscopic stent placement for Klatskin tumors. *Gastrointest Endosc* 2001; **53**: 40-46 [PMID: 11154487 DOI: 10.1067/mge.2001.111388]
 - 26 **Freeman ML**, Overby C. Selective MRCP and CT-targeted drainage of malignant hilar biliary obstruction with self-expanding metallic stents. *Gastrointest Endosc* 2003; **58**: 41-49 [PMID: 12838219 DOI: 10.1067/mge.2003.292]
 - 27 **Harewood GC**, Baron TH. Cost analysis of magnetic resonance cholangiography in the management of inoperable hilar biliary obstruction. *Am J Gastroenterol* 2002; **97**: 1152-1158 [PMID: 12014720]
 - 28 **Singh V**, Singh G, Gupta V, Gupta R, Kapoor R. Contrast-free air cholangiography-assisted unilateral plastic stenting in malignant hilar biliary obstruction. *Hepatobiliary Pancreat Dis Int* 2010; **9**: 88-92 [PMID: 20133236]
 - 29 **Cotton PB**, Eisen G, Romagnuolo J, Vargo J, Baron T, Tarnasky P, Schutz S, Jacobson B, Bott C, Petersen B. Grading the complexity of endoscopic procedures: results of an ASGE working party. *Gastrointest Endosc* 2011; **73**: 868-874 [PMID: 21377673 DOI: 10.1016/j.gie.2010.12.036]
 - 30 **Ragunath K**, Thomas LA, Cheung WY, Duane PD, Richards DG. Objective evaluation of ERCP procedures: a simple grading scale for evaluating technical difficulty. *Postgrad Med J* 2003; **79**: 467-470 [PMID: 12954961 DOI: 10.1136/pmj.79.934.467]
 - 31 **Park do H**, Lee SS, Moon JH, Choi HJ, Cha SW, Kim JH, Seo DW, Lee SK, Park SH, Lee MS, Kim SJ, Kim MH. Newly designed stent for endoscopic bilateral stent-in-stent placement of metallic stents in patients with malignant hilar biliary strictures: multicenter prospective feasibility study (with videos). *Gastrointest Endosc* 2009; **69**: 1357-1360 [PMID: 19481654 DOI: 10.1016/j.gie.2008.12.250]
 - 32 **Chahal P**, Baron TH. Expandable metal stents for endoscopic bilateral stent-within-stent placement for malignant hilar biliary obstruction. *Gastrointest Endosc* 2010; **71**: 195-199 [PMID: 19945101 DOI: 10.1016/j.gie.2009.08.006]
 - 33 **Lee TH**, Moon JH, Kim JH, Park DH, Lee SS, Choi HJ, Cho YD, Park SH, Kim SJ. Primary and revision efficacy of cross-wired metallic stents for endoscopic bilateral stent-in-stent placement in malignant hilar biliary strictures. *Endoscopy* 2013; **45**: 106-113 [PMID: 23212727 DOI: 10.1055/s-0032-1325928]
 - 34 **Banerjee S**, Shen B, Baron TH, Nelson DB, Anderson MA, Cash BD, Dominitz JA, Gan SI, Harrison ME, Ikenberry SO, Jagannath SB, Lichtenstein D, Fanelli RD, Lee K, van Guilder T, Stewart LE. Antibiotic prophylaxis for GI endoscopy. *Gastrointest Endosc* 2008; **67**: 791-798 [PMID: 18374919 DOI: 10.1016/j.gie.2008.02.068]

- 35 **Dumonceau JM**, Tringali A, Blero D, Devière J, Laugier R, Heresbach D, Costamagna G. Biliary stenting: indications, choice of stents and results: European Society of Gastrointestinal Endoscopy (ESGE) clinical guideline. *Endoscopy* 2012; **44**: 277-298 [PMID: 22297801 DOI: 10.1055/s-0031-1291633]
- 36 **Hii MW**, Gibson RN, Speer AG, Collier NA, Sherson N, Jardine C. Role of radiology in the treatment of malignant hilar biliary strictures 2: 10 years of single-institution experience with percutaneous treatment. *Australas Radiol* 2003; **47**: 393-403 [PMID: 14641192 DOI: 10.1046/j.1440-1673.2003.01209.x]
- 37 **Ahn SJ**, Bae JI, Han TS, Won JH, Kim JD, Kwack KS, Lee JH, Kim YC. Percutaneous biliary drainage using open cell stents for malignant biliary hilar obstruction. *Korean J Radiol* 2012; **13**: 795-802 [PMID: 23118579 DOI: 10.3348/kjr.2012.13.6.795]
- 38 **Gwon DI**, Ko GY, Yoon HK, Kim JH, Lee JM, Ohm JY, Sung KB. Prospective evaluation of a newly designed T-configured stent graft system for palliative treatment of advanced hilar malignant biliary obstructions. *J Vasc Interv Radiol* 2010; **21**: 1410-1418 [PMID: 20800780 DOI: 10.1016/j.jvir.2010.05.019]
- 39 **Gwon DI**, Ko GY, Yoon HK, Kim YJ, Kim TH, Lee WH, Sung KB. Safety and efficacy of percutaneous Y-configured covered stent placement for malignant hilar biliary obstruction: a prospective, pilot study. *J Vasc Interv Radiol* 2012; **23**: 528-534 [PMID: 22341884 DOI: 10.1016/j.jvir.2011.12.022]
- 40 **Paik WH**, Park YS, Hwang JH, Lee SH, Yoon CJ, Kang SG, Lee JK, Ryu JK, Kim YT, Yoon YB. Palliative treatment with self-expandable metallic stents in patients with advanced type III or IV hilar cholangiocarcinoma: a percutaneous versus endoscopic approach. *Gastrointest Endosc* 2009; **69**: 55-62 [PMID: 18657806 DOI: 10.1016/j.gie.2008.04.005]
- 41 **Rerknimitr R**, Kladcharoen N, Mahachai V, Kullavanijaya P. Result of endoscopic biliary drainage in hilar cholangiocarcinoma. *J Clin Gastroenterol* 2004; **38**: 518-523 [PMID: 15220688 DOI: 10.1097/01.mcg.0000123204.36471.be]
- 42 **Lee SH**, Park JK, Yoon WJ, Lee JK, Ryu JK, Yoon YB, Kim YT. Optimal biliary drainage for inoperable Klatskin's tumor based on Bismuth type. *World J Gastroenterol* 2007; **13**: 3948-3955 [PMID: 17663508]
- 43 **Dhir V**, Bhandari S, Bapat M, Maydeo A. Comparison of EUS-guided rendezvous and precut papillotomy techniques for biliary access (with videos). *Gastrointest Endosc* 2012; **75**: 354-359 [PMID: 22248603 DOI: 10.1016/j.gie.2011.07.075]
- 44 **Kim YS**, Gupta K, Mallory S, Li R, Kinney T, Freeman ML. Endoscopic ultrasound rendezvous for bile duct access using a transduodenal approach: cumulative experience at a single center. A case series. *Endoscopy* 2010; **42**: 496-502 [PMID: 20419625 DOI: 10.1055/s-0029-1244082]
- 45 **Nguyen-Tang T**, Binmoeller KF, Sanchez-Yague A, Shah JN. Endoscopic ultrasound (EUS)-guided transhepatic antegrade self-expandable metal stent (SEMS) placement across malignant biliary obstruction. *Endoscopy* 2010; **42**: 232-236 [PMID: 20119894 DOI: 10.1055/s-0029-1243858]
- 46 **Park do H**, Song TJ, Eum J, Moon SH, Lee SS, Seo DW, Lee SK, Kim MH. EUS-guided hepaticogastrostomy with a fully covered metal stent as the biliary diversion technique for an occluded biliary metal stent after a failed ERCP (with videos). *Gastrointest Endosc* 2010; **71**: 413-419 [PMID: 20152319 DOI: 10.1016/j.gie.2009.10.015]
- 47 **Shami VM**, Kahaleh M. Endoscopic ultrasound-guided cholangiopancreatography and rendezvous techniques. *Dig Liver Dis* 2010; **42**: 419-424 [PMID: 19897427 DOI: 10.1016/j.dld.2009.09.009]
- 48 **Eum J**, Park do H, Ryu CH, Kim HJ, Lee SS, Seo DW, Lee SK, Kim MH. EUS-guided biliary drainage with a fully covered metal stent as a novel route for natural orifice transluminal endoscopic biliary interventions: a pilot study (with videos). *Gastrointest Endosc* 2010; **72**: 1279-1284 [PMID: 20870224 DOI: 10.1016/j.gie.2010.07.026]
- 49 **Park do H**, Koo JE, Oh J, Lee YH, Moon SH, Lee SS, Seo DW, Lee SK, Kim MH. EUS-guided biliary drainage with one-step placement of a fully covered metal stent for malignant biliary obstruction: a prospective feasibility study. *Am J Gastroenterol* 2009; **104**: 2168-2174 [PMID: 19513026 DOI: 10.1038/ajg.2009.254]
- 50 **Yamao K**, Hara K, Mizuno N, Sawaki A, Hijioka S, Niwa Y, Tajika M, Kawai H, Kondo S, Shimizu Y, Bhatia V. EUS-Guided Biliary Drainage. *Gut Liver* 2010; **4** Suppl 1: S67-S75 [PMID: 21103298 DOI: 10.5009/gnl.2010.4.S1.S67]
- 51 **Witzigmann H**, Lang H, Lauer H. Guidelines for palliative surgery of cholangiocarcinoma. *HPB (Oxford)* 2008; **10**: 154-160 [PMID: 18773044 DOI: 10.1080/13651820801992567]
- 52 **Zhang BH**, Cheng QB, Luo XJ, Zhang YJ, Jiang XQ, Zhang BH, Yi B, Yu WL, Wu MC. Surgical therapy for hilar cholangiocarcinoma: analysis of 198 cases. *Hepatobiliary Pancreat Dis Int* 2006; **5**: 278-282 [PMID: 16698591]
- 53 **Guthrie CM**, Banting SW, Garden OJ, Carter DC. Segment III cholangiojejunostomy for palliation of malignant hilar obstruction. *Br J Surg* 1994; **81**: 1639-1641 [PMID: 7530149 DOI: 10.1002/bjs.1800811125]
- 54 **Li HM**, Dou KF, Sun K, Gao ZQ, Li KZ, Fu YC. Palliative surgery for hilar cholangiocarcinoma. *Hepatobiliary Pancreat Dis Int* 2003; **2**: 110-113 [PMID: 14607660]
- 55 **Lee TY**, Cheon YK, Shim CS. Current status of photodynamic therapy for bile duct cancer. *Clin Endosc* 2013; **46**: 38-44 [PMID: 23423177 DOI: 10.5946/ce.2013.46.1.38]
- 56 **Ortner ME**, Caca K, Berr F, Liebetruhl J, Mansmann U, Huster D, Voderholzer W, Schachschal G, Mössner J, Lochs H. Successful photodynamic therapy for nonresectable cholangiocarcinoma: a randomized prospective study. *Gastroenterology* 2003; **125**: 1355-1363 [PMID: 14598251 DOI: 10.1016/j.gastro.2003.07.015]
- 57 **Cheon YK**, Cho YD, Baek SH, Cha SW, Moon JH, Kim YS, Lee JS, Lee MS, Shim CS, Kim BS. Comparison of survival of advanced hilar cholangiocarcinoma after biliary drainage alone versus photodynamic therapy with external drainage. *Korean J Gastroenterol* 2004; **44**: 280-287 [PMID: 15564808]
- 58 **Zoeft T**, Jakobs R, Arnold JC, Apel D, Riemann JF. Palliation of nonresectable bile duct cancer: improved survival after photodynamic therapy. *Am J Gastroenterol* 2005; **100**: 2426-2430 [PMID: 16279895 DOI: 10.1111/j.1572-0241.2005.00318.x]
- 59 **Wang LW**, Li LB, Li ZS, Chen YK, Hetzel FW, Huang Z. Self-expandable metal stents and trans-stent light delivery: are metal stents and photodynamic therapy compatible? *Lasers Surg Med* 2008; **40**: 651-659 [PMID: 18951422 DOI: 10.1002/lsm.20680]
- 60 **Tomizawa Y**, Tian J. Photodynamic therapy for unresectable cholangiocarcinoma. *Dig Dis Sci* 2012; **57**: 274-283 [PMID: 22057285 DOI: 10.1007/s10620-011-1957-7]
- 61 **Shim CS**, Cheon YK, Cha SW, Bhandari S, Moon JH, Cho YD, Kim YS, Lee LS, Lee MS, Kim BS. Prospective study of the effectiveness of percutaneous transhepatic photodynamic therapy for advanced bile duct cancer and the role of intraductal ultrasonography in response assessment. *Endoscopy* 2005; **37**: 425-433 [PMID: 15844020]
- 62 **Wagner A**, Kiesslich T, Neureiter D, Friesenbichler P, Puspoeck A, Denzer UW, Wolkersdorfer GW, Emmanuel K, Lohse AW, Berr F. Photodynamic therapy for hilar bile duct cancer: clinical evidence for improved tumoricidal tissue penetration by temoporfin. *Photochem Photobiol Sci* 2013; **12**: 1065-1073 [PMID: 23558738 DOI: 10.1039/c3pp25425a]
- 63 **Monga A**, Gupta R, Ramchandani M, Rao GV, Santosh D, Reddy DN. Endoscopic radiofrequency ablation of cholangiocarcinoma: new palliative treatment modality (with videos). *Gastrointest Endosc* 2011; **74**: 935-937 [PMID: 21168839 DOI: 10.1016/j.gie.2010.10.018]
- 64 **Steel AW**, Postgate AJ, Khorsandi S, Nicholls J, Jiao L, Vlavianos P, Habib N, Westaby D. Endoscopically applied radiofrequency ablation appears to be safe in the treatment of malignant biliary obstruction. *Gastrointest Endosc* 2011; **73**:

- 149-153 [PMID: 21184881 DOI: 10.1016/j.jgie.2010.09.031]
- 65 **Figuerola-Barojas P**, Bakhru MR, Habib NA, Ellen K, Millman J, Jamal-Kabani A, Gaidhane M, Kahaleh M. Safety and efficacy of radiofrequency ablation in the management of unresectable bile duct and pancreatic cancer: a novel palliation technique. *J Oncol* 2013; **2013**: 910897 [PMID: 23690775 DOI: 10.1155/2013/910897]
 - 66 **Larghi A**, Tringali A, Lecca PG, Giordano M, Costamagna G. Management of hilar biliary strictures. *Am J Gastroenterol* 2008; **103**: 458-473 [PMID: 18028506 DOI: 10.1111/j.1572-0241.2007.01645.x]
 - 67 **Isayama H**, Tsujino T, Nakai Y, Sasaki T, Nakagawa K, Yamashita H, Aoki T, Koike K. Clinical benefit of radiation therapy and metallic stenting for unresectable hilar cholangiocarcinoma. *World J Gastroenterol* 2012; **18**: 2364-2370 [PMID: 22654427 DOI: 10.3748/wjg.v18.i19.2364]
 - 68 **Shinchi H**, Takao S, Nishida H, Aikou T. Length and quality of survival following external beam radiotherapy combined with expandable metallic stent for unresectable hilar cholangiocarcinoma. *J Surg Oncol* 2000; **75**: 89-94 [DOI: 10.1002/1096-9098[200010]75:2<89::AID-JSO3>3.0.CO;2-V]
 - 69 **Ramírez-Merino N**, Aix SP, Cortés-Funes H. Chemotherapy for cholangiocarcinoma: An update. *World J Gastrointest Oncol* 2013; **5**: 171-176 [PMID: 23919111 DOI: 10.4251/wjgo.v5.i7.171]
 - 70 **Yonemoto N**, Furuse J, Okusaka T, Yamao K, Funakoshi A, Ohkawa S, Boku N, Tanaka K, Nagase M, Saisho H, Sato T. A multi-center retrospective analysis of survival benefits of chemotherapy for unresectable biliary tract cancer. *Jpn J Clin Oncol* 2007; **37**: 843-851 [PMID: 17942578 DOI: 10.1093/jjco/hym116]
 - 71 **Valle JW**, Wasan H, Johnson P, Jones E, Dixon L, Swindell R, Baka S, Maraveyas A, Corrie P, Falk S, Gollins S, Locks F, Evans L, Meyer T, Anthoney A, Iveson T, Highley M, Osborne R, Bridgewater J. Gemcitabine alone or in combination with cisplatin in patients with advanced or metastatic cholangiocarcinomas or other biliary tract tumours: a multicentre randomised phase II study - The UK ABC-01 Study. *Br J Cancer* 2009; **101**: 621-627 [PMID: 19672264 DOI: 10.1038/sj.bjc.6605211]
 - 72 **Valle J**, Wasan H, Palmer DH, Cunningham D, Anthoney A, Maraveyas A, Madhusudan S, Iveson T, Hughes S, Pereira SP, Roughton M, Bridgewater J. Cisplatin plus gemcitabine versus gemcitabine for biliary tract cancer. *N Engl J Med* 2010; **362**: 1273-1281 [PMID: 20375404 DOI: 10.1056/NEJMoa0908721]
 - 73 **Okusaka T**, Nakachi K, Fukutomi A, Mizuno N, Ohkawa S, Funakoshi A, Nagino M, Kondo S, Nagaoka S, Funai J, Koshiji M, Nambu Y, Furuse J, Miyazaki M, Nimura Y. Gemcitabine alone or in combination with cisplatin in patients with biliary tract cancer: a comparative multicentre study in Japan. *Br J Cancer* 2010; **103**: 469-474 [PMID: 20628385 DOI: 10.1038/sj.bjc.6605779]

P- Reviewer: Cheon YK, Fusai G, Shim CS

S- Editor: Song XX **L- Editor:** A **E- Editor:** Wu HL



Role of adipokines and peroxisome proliferator-activated receptors in nonalcoholic fatty liver disease

Vettickattuparambil George Giby, Thekkuttuparambil Ananthanarayanan Ajith

Vettickattuparambil George Giby, Thekkuttuparambil Ananthanarayanan Ajith, Department of Biochemistry, Amala Institute of Medical Sciences, Thrissur-680 555, Kerala, India

Author contributions: Giby VG wrote the paragraphs: role of leptin, adiponectin, resistin, retinol binding protein-4 and pro-inflammatory cytokines in NAFLD; Ajith TA wrote the remaining paragraphs, introduction, conclusion, involved in designing, and revision of the manuscript; both authors were involved in editing the manuscript.

Correspondence to: Thekkuttuparambil Ananthanarayanan Ajith, PhD, Professor Biochemistry, Department of Biochemistry, Amala Institute of Medical Sciences, Amala Nagar, Thrissur-680 555, Kerala, India. taajith@rediffmail.com

Telephone: +91-487-2304116 Fax: +91-487-2307969

Received: March 3, 2014 Revised: April 29, 2014

Accepted: May 28, 2014

Published online: August 27, 2014

Abstract

Intrahepatic fat deposition has been demonstrated in patients with nonalcoholic fatty liver disease (NAFLD). Genetic and environmental factors are important for the development of NAFLD. Diseases such as obesity, diabetes, and hypertension have been found to be closely associated with the incidence of NAFLD. Evidence suggests that obesity and insulin resistance are the major factors that contribute to the development of NAFLD. In comparing the factors that contribute to the buildup of excess calories in obesity, an imbalance of energy homeostasis can be considered as the basis. Among the peripheral signals that are generated to regulate the uptake of food, signals from adipose tissue are of major relevance and involve the maintenance of energy homeostasis through processes such as lipogenesis, lipolysis, and oxidation of fatty acids. Advances in research on adipose tissue suggest an integral role played by adipokines in NAFLD. Cytokines secreted by adipocytes, such as tumor necrosis factor- α , transforming growth factor- β , and interleukin-6, are implicated in NAFLD. Other adipokines, such as leptin and adiponec-

tin and, to a lesser extent, resistin and retinol binding protein-4 are also involved. Leptin and adiponectin can augment the oxidation of fatty acid in liver by activating the nuclear receptor super-family of transcription factors, namely peroxisome proliferator-activated receptor (PPAR)- α . Recent studies have proposed downregulation of PPAR- α in cases of hepatic steatosis. This review discusses the role of adipokines and PPARs with regard to hepatic energy metabolism and progression of NAFLD.

© 2014 Baishideng Publishing Group Inc. All rights reserved.

Key words: Nonalcoholic fatty liver disease; Adipose tissue; Energy homeostasis; Peroxisome proliferator-activated receptors; Adipokines

Core tip: Nonalcoholic fatty liver disease (NAFLD) is one of the principal causes for chronic liver disease. Recent reports suggested a positive association between cytokines secreted by the adipocytes, such as tumor necrosis factor- α , transforming growth factor- β , and interleukin (IL)-6 in NAFLD. Furthermore, hepatic natural killer T-cells produce IL-13 and IL-4; IL-13 may then activate hepatic stellate cells to produce pro-inflammatory cytokines and initiate oxidative stress, iron overload and fibrosis. Downregulation of peroxisome proliferator-activated receptors (PPAR), particularly PPAR- α in cases of hepatic steatosis, may facilitate the activity of hepatic proinflammatory cytokines. Hence, PPAR- γ and PPAR- α ligands have been considered for administration to prevent the initial inflammatory reactions and render protection to the liver cells.

Giby VG, Ajith TA. Role of adipokines and peroxisome proliferator-activated receptors in nonalcoholic fatty liver disease. *World J Hepatol* 2014; 6(8): 570-579 Available from: URL: <http://www.wjgnet.com/1948-5182/full/v6/i8/570.htm> DOI: <http://dx.doi.org/10.4254/wjh.v6.i8.570>

INTRODUCTION

Nonalcoholic fatty liver disease (NAFLD) is a disease spectrum encompassing simple steatosis, steatohepatitis, fibrosis and, ultimately, liver cirrhosis^[1]. It is reported to be one of the principal causes of chronic liver disease, and is predominant in developed countries. Results of several studies proposed NAFLD as the hepatic component of metabolic syndrome (MS), which is characterized by hyperinsulinemia, insulin resistance (IR), obesity, type II diabetes mellitus (TDM), dyslipidemia, and hypertension^[2]. NAFLD has a wide histological spectrum ranging from simple steatosis to nonalcoholic steatohepatitis (NASH), which may progress to cirrhosis. In simple NAFLD, the presence of macrovesicular fat droplets in hepatocytes, foci of lobular inflammation, mild portal inflammation, and lipogranulomas may be seen, while increased portal inflammation has been reported in untreated NAFLD patients^[3]. In approximately 25% of cases, histological signs of fibrosis and necroinflammatory injury that define NASH are present^[4]. Patients with NASH are at higher risk of developing fibrosis, cirrhosis and hepatocellular carcinoma^[4]. The exact cause of NAFLD is still unknown. However, incidences of NAFLD have been associated with cases of IR in both diabetes and obesity, and with hypertension. It has been proposed that an imbalance in energy homeostasis may be the basis for obesity and thus NAFLD.

Complex physiologic processes, constant communication within and among tissues such as adipose tissue, liver, skeletal muscle, pancreas, and the central nervous system are required for energy homeostasis. The brain is referred to as the central regulator of energy homeostasis and thus the primary controller of body weight. Peripherally, the major organs participating in the regulation of food intake are the stomach, intestines, pancreas, and adipose tissue^[5]. The imbalance in energy homeostasis stems etiologically from either excess food intake or insufficient energy expenditure. This may also be secondarily related to endocrinopathies such as hypothyroidism, Cushing's syndrome, etc., that evolve into MS, which, in turn, is related to NAFLD^[6,7].

Among various peripheral organs, the role played by adipose tissue in energy homeostasis remains central. Adipose tissue, far from being an inert depot of storage fat, is an active endocrine organ, as evidenced by the variety of hormones or adipokines it synthesizes, including leptin and adiponectin, among others^[8]. Signals controlling energy intake originate from adipose tissue, mediated by leptin. The afferent and efferent signals fluctuate in a coordinated manner to maintain energy homeostasis. It is necessary to determine the role played by various adipokines and nuclear receptors such as peroxisome proliferators-activated receptors (PPARs), in the initiation and progression of NAFLD. Research in this field is evolving to explain the exact role of the adipokines in NAFLD. This review discusses the role of adipokines and PPARs in NAFLD.

ADIPOSE TISSUE IN ENERGY

HOMEOSTASIS

Energy homeostasis is maintained by the integration of major metabolic functions such as lipogenesis, lipolysis, and fatty acid oxidation, and is mediated through adipose tissue^[9]. Of the two types of adipose tissues, white (WAT) and brown (BAT), WAT is concerned with energy balance in adults and has been found to be increased in obesity^[10,11]. Cells constituting WAT include preadipocytes, fibroblasts, endothelial cells, macrophages, and monocytes^[12]. The functional adipocyte secretes several factors known as adipokines to communicate actively with the liver, muscle, and hypothalamus^[13,14]. Such factors include pro-inflammatory cytokines produced by resident macrophages such as tumor necrosis factor (TNF)- α , interleukin (IL)-6, and monocyte chemoattractant protein (MCP)-1. The majority of adipokines, however, maintain equilibrium in the utilization of energy substrates between adipose and non adipose tissues in the intestine, liver, brain, and skeletal muscle^[14]. Among such adipokines, leptin and adiponectin and, to a lesser extent, resistin and retinol binding protein-4 have a role in energy homeostasis.

ROLE OF LEPTIN, ADIPONECTIN, RESISTIN, AND RETINOL BINDING PROTEIN-4 IN LIPID METABOLISM

Leptin (16 kDa) is a peptide hormone synthesized by adipocytes and in inconsequential amounts by the liver and skeletal muscle^[15]. Its gene expression (*Lep/Ob* gene) is regulated by food intake, energy status, hormones, and the overall inflammatory state^[16]. Leptin signals are mediated through a membrane receptor and signaling pathways involve Janus activating kinase/signal transducer and activator of transcription, mitogen-activated protein kinase, phosphatidylinositol 3' kinase, and AMP-dependent protein kinase (AMPK)^[17,18]. Through such pathways, leptin acts on the hypothalamus to reduce appetite and thus function as an adipostat^[16]. The stimulating pathways, in general, favor fatty acid oxidation and decrease lipogenesis. Leptin also tends to decrease the ectopic deposition of fat in liver and muscle. Furthermore, leptin can also act on the pancreas, inhibiting both insulin and glucagon secretion *via* short-term/non-genomic and long-term/genomic mechanisms, thereby promoting glucose homeostasis^[19]. In excess calorie states, such as obesity, hyperleptinemia associated with leptin receptor inactivation/downregulation has been observed in the hypothalamus and liver of obese rats^[20].

Adiponectin (30 kDa) is a protein hormone, which exists in several globular, trimeric, and high molecular weight forms in circulation. Adiponectin stimulates insulin sensitivity, decreases hepatic glucose production, increases glucose utilization in muscle and oxidation of fatty acid in muscle, liver, and peripheral tissues, thus

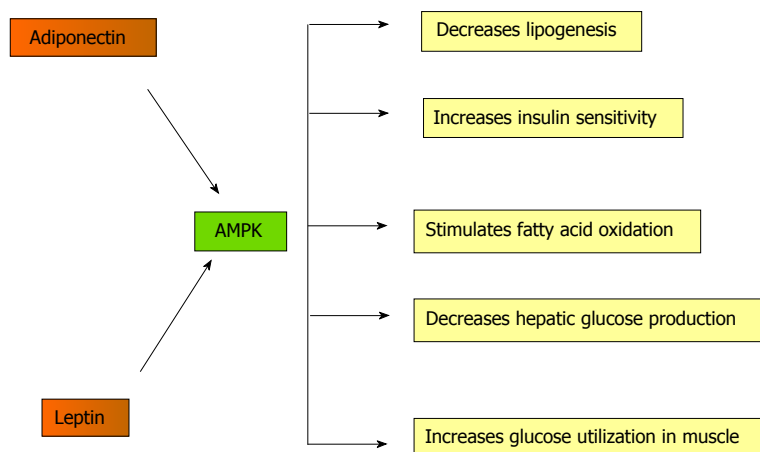


Figure 1 Mechanism of action of adenosine monophosphate-dependent protein kinase. AMP: Adenosine monophosphate; AMPK: AMP-dependent protein kinase.

down-regulating the secretion of pro-inflammatory cytokines IL-6, IL-8 and MCP-1^[21,22]. Adiponectin receptors activate AMPK, p38 mitogen-activated protein kinase, and PPAR- α , which in turn regulate fatty acid metabolism^[23]. Low levels of adiponectin are associated with low-grade inflammation, oxidative stress, and endothelial dysfunction^[24]. Its receptors are largely decreased in obese animals and humans.

Both leptin and adiponectin stimulate AMPK in skeletal muscle, liver, and adipose tissue^[25]. In skeletal muscle, AMPK activation promotes glucose transport, glycolysis, and fatty acid oxidation, and inhibits fatty acid synthesis (Figure 1). AMPK directly inhibits acetyl CoA carboxylase, preventing lipogenesis; consequentially, carnitine palmitoyl transferase-1 is stimulated leading to fatty acid oxidation^[22]. AMPK is activated during exercise and is involved in glucose transport and fatty acid oxidation in skeletal muscle. Hepatic lipid turnover is regulated by transcription factors carbohydrate-responsive element-binding protein, sterol regulatory element binding protein 1c (SREBP-1c), CCAAT-enhancer-binding protein α , and PPARs. In liver, AMPK is a cellular metabolic sensor, inhibiting lipogenesis and cholesterol synthesis; its activation suppresses the SREBP1c^[9]. Disequilibrium in lipid homeostasis causes triglycerides to accumulate in the liver.

Resistin (12.5 kDa) is a 108 amino acid protein; its circulatory form consists of a dimer united by a single disulfide bridge. Although its function in humans is still unclear, in mice it has been shown to increase blood glucose and insulin concentrations by means of promoting hepatic IR and gluconeogenesis^[26]. Its exact role in IR and obesity has not yet been determined; however, studies have demonstrated that obese individuals display higher serum resistin values than lean subjects and a positive correlation may exist between BMI and resistin, although the latter remains under debate^[15].

Correspondingly, retinol binding protein-4 (RBP4) (21 kDa), the transport protein for retinol in blood, has also been linked to cases of IR^[27]. Although primarily hepatic in origin, high levels of RBP4 were detected in the adipose tissue of glucose transport protein 4 knockout mice^[28]. The blood concentration of RBP4 was also

found to be increased in obese and diabetic human individuals. Alternatively, RBP4 knockout mice displayed increased insulin sensitivity^[27]. A more positive association, however, was distinguished between adipocyte inflammatory cytokine production in cases of IR and RBP4 levels^[28].

ROLE OF LEPTIN, ADIPONECTIN, RESISTIN, AND RETINOL BINDING PROTEIN-4 IN NAFLD

NAFLD usually occurs concomitantly with obesity, TDM, and/or hyperlipidemia. The current explanation for the pathogenesis of NAFLD is two-fold; according to the “two-hit” theory, IR develops first. Excess free fatty acid flux occurs from adipose stores, and discrepancies in liver function lead to excessive fatty acid synthesis, insufficient fatty acid oxidation, and/or inadequate incorporation of fatty acids into very low density lipoproteins, eventually result in steatosis^[12,26,29]. Secondly, oxidative stress paves the way for portal inflammation, lipid peroxidation, and ultimately fibrosis^[12]. Assuming defective lipid metabolism as one of the underlying causes for intrahepatic fat deposition in NAFLD, serum adipokine levels are of certain interest. As such, leptin and adiponectin are of foremost importance in the formation of NAFLD.

Although the exact role of adipokines in the development and progression of NAFLD is unknown, Huang *et al*^[29] proposed a positive association between blood leptin levels and incidences of NAFLD, while soluble leptin receptors were found to be significantly reduced in such cases. Other studies expounded on this claim and found that the elevated leptin levels cannot be tied definitively to IR in adults, but rather may be linked to the fibrogenesis noted in NAFLD^[30]. It was found that hepatic stellate cells (HSCs) are responsible for the fibrotic changes that characterize NAFLD; HSCs produce leptin, suggesting that they may be implicated in fibrogenesis. According to Canbakan *et al*^[30], leptin may increase the level of reactive oxygen species (ROS) in the liver, provoking Kupffer cells to produce TNF- α and other cytokines, thus enhancing collagen production and the progression

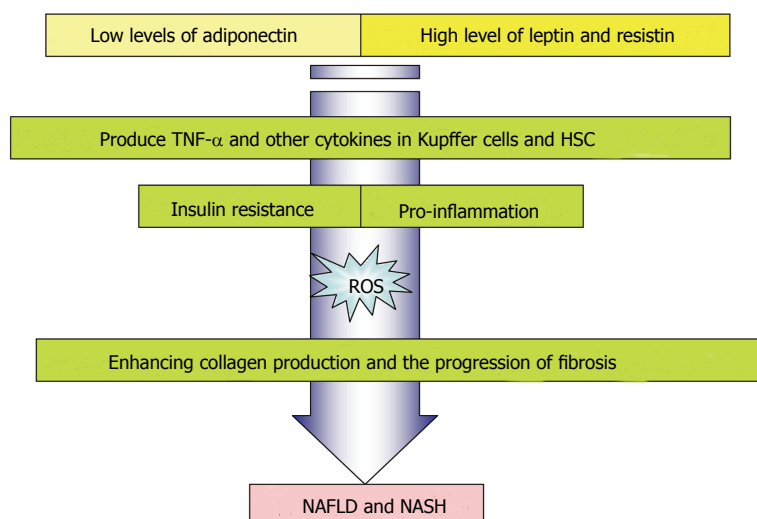


Figure 2 Role of adipokines in inflammation and fibrosis. NAFLD: Nonalcoholic fatty liver disease; NASH: Nonalcoholic steatohepatitis. TNF- α : Tumor necrosis factor alpha; HSCs: Hepatic stellate cells.

of fibrosis (Figure 2). In children, hyperleptinemia was observed and was found to be correlated to the degree of liver impairment^[31]. However, such studies performed in adults yielded inconclusive results, implying that hyperleptinemia may emerge in cases of early NAFLD, leading ultimately to IR and obesity. It is thought that the hyperleptin state only aggravates the inflammatory changes and fibrogenesis initiated by HSCs^[31].

Adiponectin enhances glucose utilization and hepatic fatty acid oxidation *via* its receptors, AdipoR1 and AdipoR2. NAFLD patients displayed low adiponectin levels along with IR^[12]. It was observed in mice that the hyperinsulinemic state in most liver disorders led to the downregulation of adiponectin receptors, leading to adiponectin resistance; studies have demonstrated, however, that the characteristically low adiponectin level observed in NAFLD is linked more to intrahepatic fat deposition rather than to the degree of liver damage^[32]. High adiponectin levels in mice have succeeded in preventing intrahepatic fat deposition *via* inhibition of fatty acid synthesis. Bugianesi *et al*^[32] identified increased serum activity of alanine transaminase (ALT) and γ -glutamyl transpeptidase (GGT) associated with hypo adiponectinemia in healthy individuals, highlighting the importance of adiponectin in preventing liver damage. Adiponectin plays a role in the inflammation observed in NAFLD; unlike leptin, however, high levels of adiponectin have been shown to inhibit the secretion of TNF- α by HSCs. One may surmise that there exists interplay between leptin-adiponectin levels and the inflammatory and fibrotic changes seen in NAFLD^[12]. Adiponectin was reported to have antifibrogenic and antisteatogenic effects in the liver as opposed to leptin, which is involved in fibrogenesis. A retrospective study of serum adipokine levels in patients with NAFLD, who underwent liver biopsy due to elevated transaminase activities, found that a lower serum adiponectin/leptin ratio was useful as a non-invasive approach to discriminate NASH from simple steatosis^[33]. The hepatic expression of AdipoR2 was found to be significantly higher in patients with NASH compared with controls and was related with necroinflammatory

injury^[33].

Adult NAFLD patients displayed increased serum resistin values. Although there is debate surrounding the exact relation between resistin and obesity and IR, recent studies seem to support the notion that increased resistin levels may be correlated with IR, BMI, and the severity of NAFLD^[33]. Women were found to display a higher level of serum resistin than men, attributable to the disparity in body fat content. Murad *et al*^[34] discovered that patients with moderate to severe steatosis displayed higher serum resistin values than those with mild steatosis. Such a finding may be related to the link between resistin and IR and later inflammation. Resistin may exacerbate the inflammation brought on by TNF- α and IL-6 secreted from HSCs^[34]. Specifically, it is proposed that resistin can induce the secretion of TNF- α and IL-12 from macrophages *via* a nuclear factor-kappa B-dependent cascade to control the release of IL-6 and IL-1 β ^[35-37]. There exists the likelihood that HSCs themselves may produce resistin, as they do leptin, contributing to the hyper-resistin state observed in NAFLD^[34].

Serum RBP4 was found to be increased in cases with IR, including obesity, TDM, and impaired glucose tolerance, suggesting that RBP4 may play a similar role in NAFLD^[38]. Earlier research indicated that RBP4 is raised in non-diabetic NAFLD patients, and selected studies claimed that there exists a positive association between RBP4 and liver enzymes, specifically ALT and GGT^[38]. However, Alkhoury *et al*^[39] reported an inverse relationship between the degree of fibrosis and RBP4 levels, such that patients with late fibrosis and cirrhosis displayed lower RBP4 values.

Additionally, there have been several studies investigating the association between polymorphisms in the genes for adipokines and the susceptibility to NAFLD within populations sharing common environmental and metabolic predisposing factors^[40]. Of the many leptin polymorphisms reported, the *LEPR* G3057A variant was shown to be expressed by many NAFLD patients, implying that this polymorphism may be an independent risk factor for developing NAFLD in patients with TDM^[41].

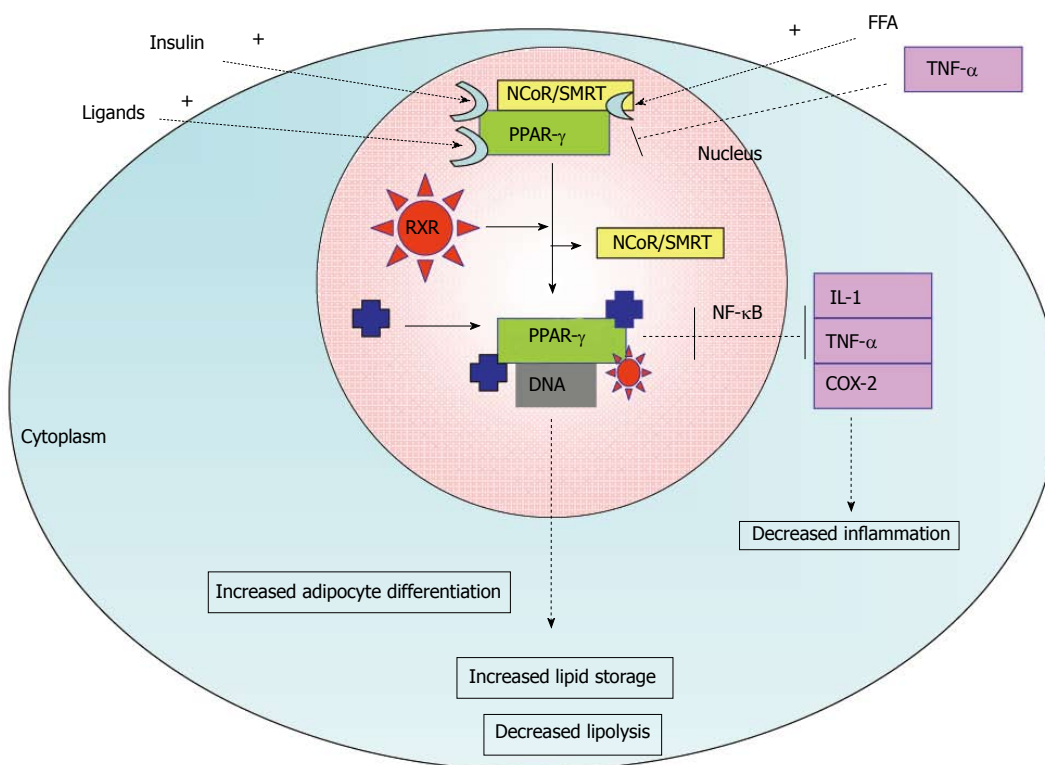


Figure 3 Activation of peroxisome proliferator-activated receptors α and associated biological response in adipose tissue. TNF- α : Tumor necrosis factor α ; COX-2: Cyclooxygenase-2; IL-1: Interleukin-1; FFA: Free fatty acids; RXR: Retinoid receptor; SMRT: Silencing mediator of retinoid and thyroid hormone receptors; NCoR1: Nuclear receptor co-repressor 1; PPAR: Peroxisome proliferator-activated receptors.

Adiponectin gene short nucleotide polymorphisms (SNPs) 45TG and 276GT were demonstrated in non-obese and non-diabetic NAFLD patients. Furthermore, these reported SNPs indicated the extent of liver injury in NAFLD^[42]. A recent finding showed that a SNP in the Patatin-like phospholipase domain-containing 3 (*PNPLA3*), *i.e.*, I148M *PNPLA3* variant predicts the extent of steatosis in NAFLD^[43]. The I148M *PNPLA3* genotype may represent a genetic determinant of serum adiponectin levels. Therefore, in carriers of the I148M *PNPLA3* variant, modulation of serum adiponectin might be involved in mediating the susceptibility to steatosis^[44].

FUNCTION OF PEROXISOME PROLIFERATOR-ACTIVATED RECEPTORS IN LIPID METABOLISM

The key element in the process of lipogenesis and lipolysis in adipose and non adipose tissues is mediated by PPARs. They are members of the steroid/retinoid nuclear receptor superfamily, and they act namely in two ways: transactivation and transrepression^[45]. Three types of PPARs have been identified: alpha, gamma, and delta (beta)^[46]. PPAR- α is expressed in the liver, kidney, heart, muscle, adipose tissue, and other organs. PPAR- β is expressed in many tissues, but markedly in the brain, adipose tissue, and skin^[47]. Finally, PPAR- γ (γ 2 and γ 3) is expressed namely in adipose tissue.

PPAR- γ is activated by fatty acids and their derivatives. It plays a role in insulin sensitivity, adipogenesis, placental function, and transcription activation in concert with coactivators like steroid receptor coactivator-1. Coordination is required between PPAR- α and PPAR- γ activity for the maintenance of equilibrium between oxidation and synthesis of fatty acids. PPAR- α regulates the expression of genes involved in peroxisomal and mitochondrial beta-oxidation in liver and skeletal muscle; such genes encode for proteins such as fatty acid transport protein, fatty acid translocase, liver cytosolic fatty acid-binding protein, and uncoupling proteins-2 and 3. PPAR- γ 2, on the other hand, is the central regulator of adipogenesis, favoring the deposition of excess calories in adipocytes. PPAR- γ 2 is involved in growth arrest, clonal expansion, early and terminal differentiation, and anti-inflammatory effects in adipose tissue macrophages^[48]. It modulates differentiation and cytokine production. Endogenous ligands of PPARs include FFA and eicosanoids^[49].

Activation of PPAR- γ can promote secretion of anti-hyperglycemic adipokines like adiponectin, and shift the deposition of non-esterified fatty acids (NEFAs) to adipose tissue and away from liver and skeletal muscle, as it serves as an activator of lipoprotein lipase^[50]. Moreover, adiponectin can increase PPAR- γ in adipose tissue. This process enhances its anti-inflammatory effects and thus insulin sensitivity in adipose tissue. The mechanism of activation of PPAR- γ is shown in Figure 3. It functions as a heterodimer with retinoic acid receptor (RXR), which binds direct repeat sequences AGGTCA in the promoter

region of its target genes, enhancing their expression^[51]. Histone deacetylase and RNA pol II activation are observed in response to PPAR- γ action in BAT and WAT^[52]. Other ligands have been found to activate PPAR- γ and may be suitable as insulin-sensitizing agents to treat DM2.

ROLE OF PPARS IN NAFLD

Recent studies have proposed a downregulation of PPAR- α in cases of hepatic steatosis and obesity-related IR^[53], thereby favoring lipogenesis over oxidation. This effect may be further aggravated by PPAR- γ upregulation, promoting overall lipogenesis. Adiponectin is responsible for the expression of PPAR- α in liver cells^[54]. It has also been suggested that PPAR- α downregulation may facilitate the activity of hepatic pro-inflammatory cytokines, expediting the transition from steatosis to steatohepatitis; however, further research must be conducted to confirm such proposals^[55]. Accordingly, PPAR- γ has been implicated in preventing pro-inflammatory cytokine gene expression *via* transrepression. As such, PPAR- γ ligands have been considered for administration in cases of inflammation, including NAFLD. In mice, PPAR- γ ligands successfully reversed the effects of cytokines produced by HSCs and managed to restore HSC quiescence. The thiazolidinedione class of antidiabetic drugs, which includes rosiglitazone and pioglitazone, acts as a PPAR- γ agonist in adipose tissue, reducing the release of NEFAs and enhancing hepatic insulin sensitivity. Although reversal of fibrosis was not observed in the 6-mo treatment with pioglitazone, improvement was noted in the 12-mo treatment of non-diabetic NASH subjects^[45]. Treatment of NAFLD patients with n-3 polyunsaturated fatty acid, a known PPAR- α ligand, slightly alleviated steatosis and decreased transaminase activity^[45].

Of the PPAR polymorphisms reported, a Leu162Val SNP for PPAR- α has been observed and severity of fibrosis in NAFLD^[56]. Similarly, a Pro12Ala SNP has been documented for PPAR- γ . Though earlier studies have documented many NAFLD patients with the alanine variant of PPAR- γ , recent meta-analyses have failed to establish such an association between Pro12Ala SNP and NAFLD risk^[50]. Further investigations are required to corroborate such findings.

ROLE OF PROINFLAMMATORY CYTOKINES IN NAFLD

Cytokines are soluble chemical mediators credited with a number of functions. They are renowned for their role in inflammatory diseases, including NAFLD. They are not normally secreted by the liver. Gradual hepatic lipid accumulation provokes HSCs and Kupffer cells to synthesize various cytokines, leading to portal inflammation, slow necrosis or apoptosis, and eventual fibrosis^[57]. Of the cytokines implicated in NAFLD, TNF- α , TGF- β , and IL-6 will be discussed.

TNF- α is secreted by a number of body cells, but

in particular by HSCs, Kupffer cells, and adipocytes. Selected studies have demonstrated a link between TNF- α expression and IR in steatohepatitis associated with NAFLD, indicating that adipocyte TNF- α has a key role in inflammation and IR by binding to the tyrosine kinase insulin receptor^[57-59]. It has also been demonstrated that TNF- α induces swelling of hepatic mitochondria, resulting in eventual rupture and disruption of respiratory chain complexes, principally complexes I and III^[60]. Reduced activity of mitochondrial complexes were reported in experimental animals followed by hepatotoxicity^[61,62]. Although the results from rodent studies supported an association between enhanced TNF- α expression in inflammatory diseases, such as NAFLD and NASH, and IR, in human subjects, such an association is under debate. In both species, however, TNF- α upregulation was observed in obese subjects, and a positive association was observed between the severity of hepatic fibrosis and serum TNF- α levels. Additionally, in both mice and humans, treatment with either anti-TNF- α antibodies or a TNF- α inhibitor (pentoxifylline), respectively, served to alleviate inflammatory and fibrotic changes. In humans, the drug also succeeded in reducing serum aminotransferase activity. Excess TNF- α is also thought to enhance the expression of SREBP-1c, and promote lipogenesis^[58].

Of the many isoforms of TGF- β , TGF- β 1 is most predominant within the inflamed liver and has been suggested to induce the transformation of HSCs to myofibroblasts through the production of proteins like collagen 1^[57]. The production of TGF- β 1 leads to a cascade of irreversible events, including further synthesis of TGF- β 1, connective tissue growth factors, and type I collagen; a reduction in cell turnover as a result of impeded DNA synthesis; inhibition of metalloprotease expression; and initiation of apoptosis *via* the phosphatidylinositol 3-kinase (PI3K)-AKT pathway and of fibrosis *via* increased production of fibronectin^[63]. It was also suggested that elevated serum TGF- β 1 may be considered an independent predictor of fibrosis^[63].

IL-6 possesses a contradictory role; a study in a mouse model claimed that in addition to activating hepatocytes, stem cells, and osteoclasts, IL-6 acts as a protective shield for the liver, hindering mitochondrial dysfunction in cases of hepatic steatosis^[57]. Recent reports suggested a positive association between IL-6 and IR through its inhibition of hepatic cytokine signaling^[59]. Administration of anti-IL-6 antibodies in obese mice was observed to enhance insulin sensitivity, and NAFLD mice and human subjects have demonstrated elevated serum IL-6 and IL-6 receptor levels. Mahmoud *et al.*^[63] established IL-6 to be the most important biomarker for NAFLD in their study. In contrast, IL-10 has been suggested to inhibit inflammation, and prevent steatosis, while some research has also shown IL-10 serum levels to be inversely related to incidence of MS^[57]. There is preliminary evidence that hepatic natural killer T-cells accumulate in liver diseases and produce IL-13 and IL-4; IL-13 may then activate HSCs to produce further pro-inflammatory cytokines, recruiting TGF- β and initiating fibrosis^[58].

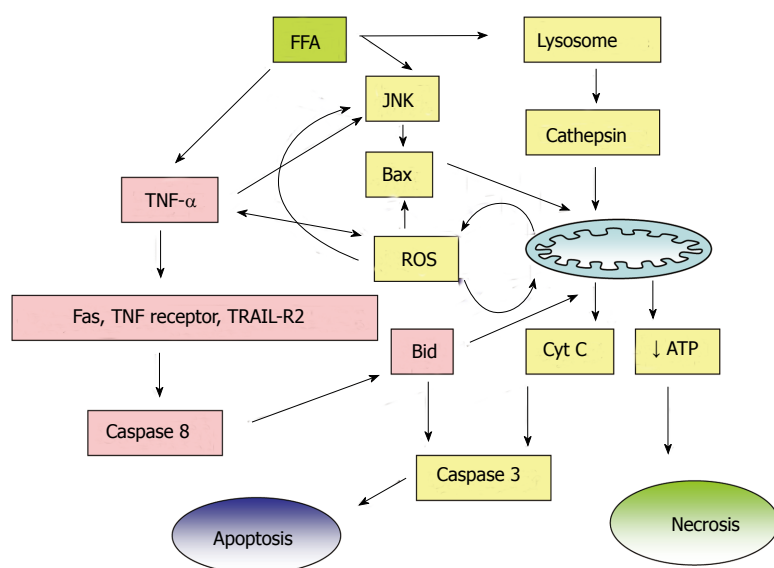


Figure 4 Cytotoxic effects of free fatty acids in nonalcoholic fatty liver disease. FFA: Free fatty acid; JNK: c-Jun NH(2)-terminal kinase; ROS: Reactive oxygen species; TRAIL-R2: Tumor necrosis factor-related apoptosis inducing ligand; ATP: Adenosine triphosphate.

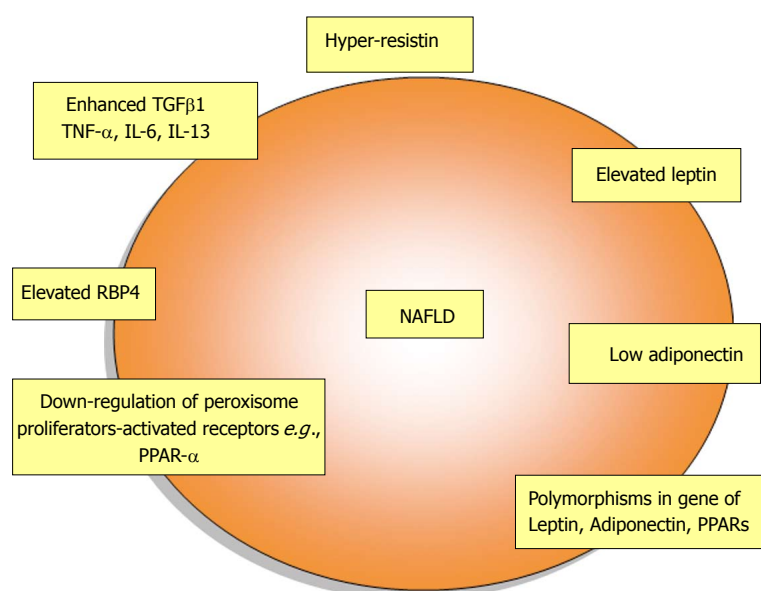


Figure 5 Changes of adipokines and peroxisome proliferator-activated receptors in nonalcoholic fatty liver disease. TGFβ1: Transforming growth factor beta 1; TNF-α: Tumor necrosis factor alpha; RBP4: Retinol binding protein 4. NAFLD: Nonalcoholic fatty liver disease; PPAR: Peroxisome proliferator-activated receptors.

Mild overload of iron is frequently observed in NAFLD. Significantly increased local as well as systemic TNF-α may favor the accumulation of iron in the liver. The progressive retention of iron can be ascribed to the impaired iron export from liver cells *via* cytokine-mediated downregulation of the iron exporter, ferroportin-1 (FP-1) in sinusoidal Kupffer cells. Iron accumulation may also result from an ineffective sensing of hepatic iron due to low hemojuvelin (HJV) expression. The increased hepatic and serum concentrations of TNF-α in NAFLD patients were inversely correlated with liver FP-1 and HJV mRNA levels whereas, it was positively associated with body mass index and hepatic hepcidin mRNA. Hepatic iron accumulation as well as increased level of TNF-α stimulates hepcidin formation, which decreases the duodenal and hepatic FP-1 expression and results in the blockage of duodenal iron uptake to compensate for liver iron overload. Nevertheless, decreased intestinal absorption of iron, and hepatic iron overload is found in NAFLD patients. Iron reduction therapy was found to

be beneficial with regard to NAFLD disease activity and insulin sensitivity^[64].

Mechanisms of NAFLD are closely linked to chronic inflammatory and oxidative stress responses. Increased intrahepatic levels of fatty acids as well as iron load provide a source of oxidative stress. Fatty liver is injured by ROS generated from microsomal, mitochondrial, and/or other hepatocellular pro-oxidant pathways when the antioxidant defenses are critically lowered. In the diminished antioxidant response, cells are susceptible to mitochondrial damage and cellular apoptotic injury. Ajith *et al*^[65-67] reported reduced activity of antioxidant enzymes such as superoxide dismutase, catalase, and glutathione peroxidase during acute and chronic liver injury in experimental animals. In NASH, FFAs induce lipooapoptosis in hepatocytes^[68]. Cytotoxic products of lipid peroxidation (*e.g.*, malondialdehyde, and 4-hydroxynonenal) may impair cellular functions including nucleotide and protein synthesis and may play a role in hepatic fibrogenesis. Increased ROS can release more TNF-α from hepatocytes, Kupffer

cells, and adipose tissue^[69], and can further upregulate pro-inflammatory pathways. Increased levels of nitric oxide and superoxide radical interact to form peroxynitrite, which is an important mediator of free radical toxicity. The role played by the toxic FFAs is depicted in Figure 4. TNF- α can induce mitochondrial ROS and thus exacerbate NAFLD by attenuating the anti-inflammatory effects of adiponectin and PPAR- γ ^[70], and results in secondary inflammation and fibrosis in NAFLD. Animal models of NAFLD suggest that an increased translocation of bacterial endotoxins lead to an activation of toll-like receptor-dependent signaling cascades and increased formation of ROS^[71].

CONCLUSION

NAFLD is one of the principal causes of chronic liver disease. Cytokines secreted by the adipocytes, such as TNF- α , TGF- β , and IL-6, are implicated in NAFLD. TNF- α , IL-6 and leptin have been shown to exert pro-inflammatory effects and adiponectin has been shown to exert anti-inflammatory effects at the liver level. Furthermore, preliminary evidence suggests that hepatic natural killer T-cells accumulate in liver diseases and produce IL-13 and IL-4; IL-13 may then activate HSCs to produce further pro-inflammatory cytokines, increase TGF- β and initiate fibrosis. Downregulation of PPAR- α in cases of hepatic steatosis favors lipogenesis over oxidation (Figure 5). PPAR- α downregulation may facilitate the activity of hepatic proinflammatory cytokines, expediting the transition from steatosis to steatohepatitis; however, further research must be conducted to confirm such proposals. PPAR- γ ligands have been considered for administration in cases of inflammation, including NAFLD; PPAR- γ ligands successfully reversed the effects of cytokines produced by HSCs and managed to restore HSC quiescence. Treatment of NAFLD patients with n-3 polyunsaturated fatty acid, a known PPAR- α ligand, slightly alleviated steatosis and decreased transaminase activity. Hence, ligands that activate these receptors may prevent the initial inflammatory reactions and render protection to the liver cells. Mechanisms of NAFLD are closely linked to chronic inflammatory and the oxidative stress response. However, there are insufficient data to support the use of antioxidant supplements for patients with NAFLD. Iron reduction therapy and lipid lowering drugs were found to be beneficial in NAFLD. Future research in these fields is required to design specific compounds to prevent fat deposition in liver cells.

REFERENCES

- Méndez-Sánchez N, Arrese M, Zamora-Valdés D, Uribe M. Current concepts in the pathogenesis of nonalcoholic fatty liver disease. *Liver Int* 2007; **27**: 423-433 [PMID: 17403181 DOI: 10.1111/j.1478-3231.2007.01483.x]
- Fabbrini E, Sullivan S, Klein S. Obesity and nonalcoholic fatty liver disease: biochemical, metabolic, and clinical implications. *Hepatology* 2010; **51**: 679-689 [PMID: 20041406 DOI: 10.1002/hep.23280]
- Brunt EM, Tiniakos DG. Histopathology of nonalcoholic fatty liver disease. *World J Gastroenterol* 2010; **16**: 5286-5296 [PMID: 21072891 DOI: 10.3748/wjg.v16.i42.5286]
- Matteoni CA, Younossi ZM, Gramlich T, Boparai N, Liu YC, McCullough AJ. Nonalcoholic fatty liver disease: a spectrum of clinical and pathological severity. *Gastroenterology* 1999; **116**: 1413-1419 [PMID: 10348825 DOI: 10.1016/S0016-5085(99)70506-8]
- Friedman JM. Obesity in the new millennium. *Nature* 2000; **404**: 632-634 [PMID: 10766249 DOI: 10.1038/35007504]
- Spiegelman BM, Flier JS. Obesity and the regulation of energy balance. *Cell* 2001; **104**: 531-543 [PMID: 11239410 DOI: 10.1016/S0092-8674(01)00240-9]
- Flier JS. Obesity wars: molecular progress confronts an expanding epidemic. *Cell* 2004; **116**: 337-350 [PMID: 14744442 DOI: 10.1016/S0092-8674(03)01081-X]
- Kershaw EE, Flier JS. Adipose tissue as an endocrine organ. *J Clin Endocrinol Metab* 2004; **89**: 2548-2556 [PMID: 15181022 DOI: 10.1210/jc.2004-0395]
- Vázquez-Vela ME, Torres N, Tovar AR. White adipose tissue as endocrine organ and its role in obesity. *Arch Med Res* 2008; **39**: 715-728 [PMID: 18996284 DOI: 10.1016/j.arcmed.2008.09.005]
- Gesta S, Tseng YH, Kahn CR. Developmental origin of fat: tracking obesity to its source. *Cell* 2007; **131**: 242-256 [PMID: 17956727 DOI: 10.1016/j.cell.2007.03.058]
- Cannon B, Nedergaard J. Developmental biology: Neither fat nor flesh. *Nature* 2008; **454**: 947-948 [PMID: 18719573 DOI: 10.1038/454947a]
- Mirza MS. Obesity, Visceral Fat, and NAFLD: Querying the Role of Adipokines in the Progression of Nonalcoholic Fatty Liver Disease. *ISRN Gastroenterol* 2011; **2011**: 592404 [PMID: 21991518 DOI: 10.5402/2011/592404]
- Ahima RS, Qi Y, Singhal NS. Adipokines that link obesity and diabetes to the hypothalamus. *Prog Brain Res* 2006; **153**: 155-174 [PMID: 16876574 DOI: 10.1016/S0079-6123(06)53009-2]
- Badman MK, Flier JS. The adipocyte as an active participant in energy balance and metabolism. *Gastroenterology* 2007; **132**: 2103-2115 [PMID: 17498506 DOI: 10.1053/j.gastro.2007.03.058]
- Meier U, Gressner AM. Endocrine regulation of energy metabolism: review of pathobiochemical and clinical chemical aspects of leptin, ghrelin, adiponectin, and resistin. *Clin Chem* 2004; **50**: 1511-1525 [PMID: 15265818 DOI: 10.1373/clinchem.2004.032482]
- Denver RJ, Bonett RM, Boorse GC. Evolution of leptin structure and function. *Neuroendocrinology* 2011; **94**: 21-38 [PMID: 21677426 DOI: 10.1159/000328435]
- Yang R, Barouch LA. Leptin signaling and obesity: cardiovascular consequences. *Circ Res* 2007; **101**: 545-559 [PMID: 17872473]
- Wautman J, Tavernier J. Leptin receptor signaling: pathways to leptin resistance. *Front Biosci (Landmark Ed)* 2011; **16**: 2771-2793 [PMID: 21622208 DOI: 10.2741/3885]
- Marroquí L, Vieira E, Gonzalez A, Nadal A, Quesada I. Leptin downregulates expression of the gene encoding glucagon in alphaTC1-9 cells and mouse islets. *Diabetologia* 2011; **54**: 843-851 [PMID: 21234744 DOI: 10.1007/s00125-010-2024-1]
- Fuentes T, Ara I, Guadalupe-Grau A, Larsen S, Stallknecht B, Olmedillas H, Santana A, Helge JW, Calbet JA, Guerra B. Leptin receptor 170 kDa (OB-R170) protein expression is reduced in obese human skeletal muscle: a potential mechanism of leptin resistance. *Exp Physiol* 2010; **95**: 160-171 [PMID: 19717488 DOI: 10.1113/expphysiol.2009.049270]
- Yamauchi T, Kamon J, Minokoshi Y, Ito Y, Waki H, Uchida S, Yamashita S, Noda M, Kita S, Ueki K, Eto K, Akanuma Y, Froguel P, Foufelle F, Ferre P, Carling D, Kimura S, Nagai R, Kahn BB, Kadowaki T. Adiponectin stimulates glucose utilization and fatty-acid oxidation by activating AMP-activated

- protein kinase. *Nat Med* 2002; **8**: 1288-1295 [PMID: 12368907 DOI: 10.1038/nm788]
- 22 **Yoon MJ**, Lee GY, Chung JJ, Ahn YH, Hong SH, Kim JB. Adiponectin increases fatty acid oxidation in skeletal muscle cells by sequential activation of AMP-activated protein kinase, p38 mitogen-activated protein kinase, and peroxisome proliferator-activated receptor alpha. *Diabetes* 2006; **55**: 2562-2570 [PMID: 16936205 DOI: 10.2337/db05-1322]
 - 23 **Frqhbeck G**, Salvador J. Role of adipocytokines in metabolism and disease. *Nutrition Res* 2004; **24**: 803-826 [DOI: 10.1016/j.nutres.2004.07.002]
 - 24 **Balistreri CR**, Caruso C, Candore G. The role of adipose tissue and adipokines in obesity-related inflammatory diseases. *Mediators Inflamm* 2010; **2010**: 802078 [PMID: 20671929 DOI: 10.1155/2010/802078]
 - 25 **Daval M**, Fougelle F, Ferré P. Functions of AMP-activated protein kinase in adipose tissue. *J Physiol* 2006; **574**: 55-62 [PMID: 16709632 DOI: 10.1113/jphysiol.2006.111484]
 - 26 **Pagano C**, Soardo G, Pilon C, Milocco C, Basan L, Milan G, Donnini D, Faggian D, Mussap M, Plebani M, Avellini C, Federspil G, Sechi LA, Vettor R. Increased serum resistin in nonalcoholic fatty liver disease is related to liver disease severity and not to insulin resistance. *J Clin Endocrinol Metab* 2006; **91**: 1081-1086 [PMID: 16394091 DOI: 10.1210/jc.2005-1056]
 - 27 **Klötting N**, Graham TE, Berndt J, Kralisch S, Kovacs P, Watson CJ, Fasshauer M, Schön MR, Stumvoll M, Blüher M, Kahn BB. Serum retinol-binding protein is more highly expressed in visceral than in subcutaneous adipose tissue and is a marker of intra-abdominal fat mass. *Cell Metab* 2007; **6**: 79-87 [PMID: 17618858 DOI: 10.1016/j.cmet.2007.06.002]
 - 28 **Yao-Borengasser A**, Varma V, Bodles AM, Rasouli N, Phanavanh B, Lee MJ, Starks T, Kern LM, Spencer HJ, Rashidi AA, McGehee RE, Fried SK, Kern PA. Retinol binding protein 4 expression in humans: relationship to insulin resistance, inflammation, and response to pioglitazone. *J Clin Endocrinol Metab* 2007; **92**: 2590-2597 [PMID: 17595259 DOI: 10.1210/jc.2006-0816]
 - 29 **Huang XD**, Fan Y, Zhang H, Wang P, Yuan JP, Li MJ, Zhan XY. Serum leptin and soluble leptin receptor in non-alcoholic fatty liver disease. *World J Gastroenterol* 2008; **14**: 2888-2893 [PMID: 18473416 DOI: 10.3748/wjg.14.2888]
 - 30 **Canbakan B**, Tahan Y, Balci H, Hatemi I, Erer B, Ozbay G, Sut N, Hacibekiroglu M, Imeryuz N, Senturk H. Leptin in nonalcoholic fatty liver disease. *Ann Hepatol* 2008; **7**: 249-254 [PMID: 18753993]
 - 31 **Nobili V**, Manco M, Ciampalini P, Diciommo V, Devito R, Piemonte F, Comparcola D, Guidi R, Marcellini M. Leptin, free leptin index, insulin resistance and liver fibrosis in children with non-alcoholic fatty liver disease. *Eur J Endocrinol* 2006; **155**: 735-743 [PMID: 17062890 DOI: 10.1530/eje.1.02288]
 - 32 **Bugianesi E**, Pagotto U, Manini R, Vanni E, Gastaldelli A, de Iasio R, Gentilcore E, Natale S, Cassader M, Rizzetto M, Pasquali R, Marchesini G. Plasma adiponectin in non-alcoholic fatty liver is related to hepatic insulin resistance and hepatic fat content, not to liver disease severity. *J Clin Endocrinol Metab* 2005; **90**: 3498-3504 [PMID: 15797948 DOI: 10.1210/jc.2004-2240]
 - 33 **Lemoine M**, Ratzu V, Kim M, Maachi M, Wendum D, Paye F, Bastard JP, Poupon R, Housset C, Capeau J, Serfaty L. Serum adipokine levels predictive of liver injury in non-alcoholic fatty liver disease. *Liver Int* 2009; **29**: 1431-1438 [PMID: 19422483 DOI: 10.1111/j.1478-3231.2009.02022.x]
 - 34 **Murad A**, Hassan H, Husein H, Ayad A. Serum resistin levels in nonalcoholic fatty liver disease and their relationship to severity of liver disease. *JEMDSA* 2010; **15**: 53-56
 - 35 **Bokarewa M**, Nagaev I, Dahlberg L, Smith U, Tarkowski A. Resistin, an adipokine with potent proinflammatory properties. *J Immunol* 2005; **174**: 5789-5795 [PMID: 15843582 DOI: 10.4049/jimmunol.174.9.5789]
 - 36 **Silswal N**, Singh AK, Aruna B, Mukhopadhyay S, Ghosh S, Ehtesham NZ. Human resistin stimulates the pro-inflammatory cytokines TNF-alpha and IL-12 in macrophages by NF-kappaB-dependent pathway. *Biochem Biophys Res Commun* 2005; **334**: 1092-1101 [PMID: 16039994 DOI: 10.1016/j.bbrc.2005.06.202]
 - 37 **Zhang LY**, Jin YJ, Jin QS, Lin LY, Zhang DD, Kong LL. Association between resistin +299A/A genotype and non-alcoholic fatty liver disease in Chinese patients with type 2 diabetes mellitus. *Gene* 2013; **529**: 340-344 [PMID: 23954219 DOI: 10.1016/j.gene.2013.08.001]
 - 38 **Seo JA**, Kim NH, Park SY, Kim HY, Ryu OH, Lee KW, Lee J, Kim DL, Choi KM, Baik SH, Choi DS, Kim SG. Serum retinol-binding protein 4 levels are elevated in non-alcoholic fatty liver disease. *Clin Endocrinol (Oxf)* 2008; **68**: 555-560 [PMID: 17941908 DOI: 10.1111/j.1365-2265.2007.03072.x]
 - 39 **Alkhouiri N**, Lopez R, Berk M, Feldstein AE. Serum retinol-binding protein 4 levels in patients with nonalcoholic fatty liver disease. *J Clin Gastroenterol* 2009; **43**: 985-989 [PMID: 19525859 DOI: 10.1097/MCG.0b013e3181a0998d]
 - 40 **Duvnjak M**, Barsić N, Tomasić V, Lerotić I. Genetic polymorphisms in non-alcoholic fatty liver disease: clues to pathogenesis and disease progression. *World J Gastroenterol* 2009; **15**: 6023-6027 [PMID: 20027673 DOI: 10.3748/wjg.15.6023]
 - 41 **Lu H**, Sun J, Sun L, Shu X, Xu Y, Xie D. Polymorphism of human leptin receptor gene is associated with type 2 diabetic patients complicated with non-alcoholic fatty liver disease in China. *J Gastroenterol Hepatol* 2009; **24**: 228-232 [PMID: 18713300 DOI: 10.1111/j.1440-1746.2008.05544.x]
 - 42 **Musso G**, Gambino R, De Micheli F, Durazzo M, Pagano G, Cassader M. Adiponectin gene polymorphisms modulate acute adiponectin response to dietary fat: Possible pathogenic role in NASH. *Hepatology* 2008; **47**: 1167-1177 [PMID: 18311774 DOI: 10.1002/hep.22142]
 - 43 **Romeo S**, Kozlitina J, Xing C, Pertsemlidis A, Cox D, Pennacchio LA, Boerwinkle E, Cohen JC, Hobbs HH. Genetic variation in PNPLA3 confers susceptibility to nonalcoholic fatty liver disease. *Nat Genet* 2008; **40**: 1461-1465 [PMID: 18820647]
 - 44 **Valenti L**, Rametta R, Ruscica M, Dongiovanni P, Steffani L, Motta BM, Canavesi E, Fracanzani AL, Mozzi E, Roviario G, Magni P, Fargion S. The I148M PNPLA3 polymorphism influences serum adiponectin in patients with fatty liver and healthy controls. *BMC Gastroenterol* 2012; **12**: 111 [PMID: 22898488 DOI: 10.1186/1471-230X-12-111]
 - 45 **Vanni E**, Bugianesi E, Kotronen A, De Minicis S, Yki-Järvinen H, Svegliati-Baroni G. From the metabolic syndrome to NAFLD or vice versa? *Dig Liver Dis* 2010; **42**: 320-330 [PMID: 20207596 DOI: 10.1016/j.dld.2010.01.016]
 - 46 **Berger J**, Moller DE. The mechanisms of action of PPARs. *Annu Rev Med* 2002; **53**: 409-435 [PMID: 11818483 DOI: 10.1146/annurev.med.53.082901.104018]
 - 47 **Schmidt A**, Endo N, Rutledge SJ, Vogel R, Shinar D, Rodan GA. Identification of a new member of the steroid hormone receptor superfamily that is activated by a peroxisome proliferator and fatty acids. *Mol Endocrinol* 1992; **6**: 1634-1641 [PMID: 1333051 DOI: 10.1210/mend.6.10.1333051]
 - 48 **Michalik L**, Auwerx J, Berger JP, Chatterjee VK, Glass CK, Gonzalez FJ, Grimaldi PA, Kadowaki T, Lazar MA, O'Rahilly S, Palmer CN, Plutzky J, Reddy JK, Spiegelman BM, Staels B, Wahli W. International Union of Pharmacology. LXI. Peroxisome proliferator-activated receptors. *Pharmacol Rev* 2006; **58**: 726-741 [PMID: 17132851 DOI: 10.1124/pr.58.4.5]
 - 49 **Tan NS**, Shaw NS, Vinckenbosch N, Liu P, Yasmin R, Desvergne B, Wahli W, Noy N. Selective cooperation between fatty acid binding proteins and peroxisome proliferator-activated receptors in regulating transcription. *Mol Cell Biol* 2002; **22**: 5114-5127 [PMID: 12077340 DOI: 10.1128/MCB.22.14.5114-5127.2002]

- 50 **Wang J**, Guo X, Wu P, Song J, Ye C, Yu S, Zhang J, Dong W. Association between the Pro12Ala polymorphism of PPAR- γ gene and the non-alcoholic fatty liver disease: a meta-analysis. *Gene* 2013; **528**: 328-334 [PMID: 23891820 DOI: 10.1016/j.gene.2013.07.014]
- 51 **Yu S**, Reddy JK. Transcription coactivators for peroxisome proliferator-activated receptors. *Biochim Biophys Acta* 2007; **1771**: 936-951 [PMID: 17306620 DOI: 10.1016/j.bbali.2007.01.008]
- 52 **Powell E**, Kuhn P, Xu W. Nuclear Receptor Cofactors in PPAR γ -Mediated Adipogenesis and Adipocyte Energy Metabolism. *PPAR Res* 2007; **2007**: 53843 [PMID: 17389765 DOI: 10.1155/2007/53843]
- 53 **Tyagi S**, Gupta P, Saini AS, Kaushal C, Sharma S. The peroxisome proliferator-activated receptor: A family of nuclear receptors role in various diseases. *J Adv Pharm Technol Res* 2011; **2**: 236-240 [PMID: 22247890 DOI: 10.4103/2231-4040.90879]
- 54 **Kadowaki T**, Yamauchi T. Adiponectin and adiponectin receptors. *Endocr Rev* 2005; **26**: 439-451 [PMID: 15897298 DOI: 10.1210/er.2005-0005]
- 55 **Videla LA**, Pettinelli P. Misregulation of PPAR Functioning and Its Pathogenic Consequences Associated with Nonalcoholic Fatty Liver Disease in Human Obesity. *PPAR Res* 2012; **2012**: 107434 [PMID: 23304111 DOI: 10.1155/2012/107434]
- 56 **Domenici FA**, Brochado MJ, Martinelli Ade L, Zucoloto S, da Cunha SF, Vannucchi H. Peroxisome proliferator-activated receptors alpha and gamma2 polymorphisms in nonalcoholic fatty liver disease: a study in Brazilian patients. *Gene* 2013; **529**: 326-331 [PMID: 23891824 DOI: 10.1016/j.gene.2013.06.091]
- 57 **Braunersreuther V**, Viviani GL, Mach F, Montecucco F. Role of cytokines and chemokines in non-alcoholic fatty liver disease. *World J Gastroenterol* 2012; **18**: 727-735 [PMID: 22371632 DOI: 10.3748/wjg.v18.i8.727]
- 58 **Syn WK**, Choi SS, Diehl AM. Apoptosis and cytokines in non-alcoholic steatohepatitis. *Clin Liver Dis* 2009; **13**: 565-580 [PMID: 19818305 DOI: 10.1016/j.cld.2009.07.003]
- 59 **Pearce SG**, Thosani NC, Pan JJ. Noninvasive biomarkers for the diagnosis of steatohepatitis and advanced fibrosis in NAFLD. *Biomark Res* 2013; **1**: 7 [PMID: 24252302 DOI: 10.1186/2050-7771-1-7]
- 60 **Wei Y**, Rector RS, Thyfault JP, Ibdah JA. Nonalcoholic fatty liver disease and mitochondrial dysfunction. *World J Gastroenterol* 2008; **14**: 193-199 [PMID: 18186554 DOI: 10.3748/wjg.14.193]
- 61 **Sudheesh NP**, Ajith TA, Mathew J, Nima N, Janardhanan KK. Ganoderma lucidum protects liver mitochondrial oxidative stress and improves the activity of electron transport chain in carbon tetrachloride intoxicated rats. *Hepatol Res* 2012; **42**: 181-191 [PMID: 22050471 DOI: 10.1111/j.1872-034X.2011.00906.x]
- 62 **Sudheesh NP**, Ajith TA, Janardhanan KK. Hepatoprotective effects of DL- α -lipoic acid and α -Tocopherol through amelioration of the mitochondrial oxidative stress in acetaminophen challenged rats. *Toxicol Mech Methods* 2013; **23**: 368-376 [PMID: 23343353 DOI: 10.3109/15376516.2013.769289]
- 63 **Mahmoud AA**, Bakir AS, Shabana SS. Serum TGF- β , Serum MMP-1, and HOMA-IR as non-invasive predictors of fibrosis in Egyptian patients with NAFLD. *Saudi J Gastroenterol* 2012; **18**: 327-333 [PMID: 23006461 DOI: 10.4103/1319-3767.101132]
- 64 **Valenti L**, Fracanzani AL, Dongiovanni P, Bugianesi E, Marchesini G, Manzini P, Vanni E, Fargion S. Iron depletion by phlebotomy improves insulin resistance in patients with nonalcoholic fatty liver disease and hyperferritinemia: evidence from a case-control study. *Am J Gastroenterol* 2007; **102**: 1251-1258 [PMID: 17391316 DOI: 10.1111/j.1572-0241.2007.01192.x]
- 65 **Ajith TA**, Hema U, Aswathy MS. Zingiber officinale Roscoe prevents acetaminophen-induced acute hepatotoxicity by enhancing hepatic antioxidant status. *Food Chem Toxicol* 2007; **45**: 2267-2272 [PMID: 17637489 DOI: 10.1016/j.fct.2007.06.001]
- 66 **Ajith TA**, Janardhanan KK. Chemopreventive activity of a macrofungus Phellinus rimosus against N-nitrosodiethylamine induced hepatocellular carcinoma in rat. *J Exp Ther Oncol* 2006; **5**: 309-321 [PMID: 17024971]
- 67 **Ajith TA**, Sheena N, Janardhanan KK. Phellinus rimosus protects carbon tetrachloride induced chronic hepatotoxicity in rat: Antioxidant defense mechanism. *Pharm Biol* 2006; **44**: 1-8 [DOI: 10.1080/13880200600798569]
- 68 **Wree A**, Kahraman A, Gerken G, Canbay A. Obesity affects the liver - the link between adipocytes and hepatocytes. *Digestion* 2011; **83**: 124-133 [PMID: 21042023 DOI: 10.1159/000318741]
- 69 **Kern PA**, Saghizadeh M, Ong JM, Bosch RJ, Deem R, Simsolo RB. The expression of tumor necrosis factor in human adipose tissue. Regulation by obesity, weight loss, and relationship to lipoprotein lipase. *J Clin Invest* 1995; **95**: 2111-2119 [PMID: 7738178 DOI: 10.1172/JCI117899]
- 70 **Moschen AR**, Wieser V, Tilg H. Adiponectin: key player in the adipose tissue-liver crosstalk. *Curr Med Chem* 2012; **19**: 5467-5473 [PMID: 22876924 DOI: 10.2174/092986712803833254]
- 71 **Kanuri G**, Ladurner R, Skibovskaya J, Spruss A, Königsrainer A, Bischoff SC, Bergheim I. Expression of toll-like receptors 1-5 but not TLR 6-10 is elevated in livers of patients with non-alcoholic fatty liver disease. *Liver Int* 2013 Dec 18; Epub ahead of print [PMID: 24351080 DOI: 10.1111/liv.12442]

P- Reviewer: Mascitelli L, Milic S, Navarro-Jarabo JM, Yoshiji H
S- Editor: Wen LL **L- Editor:** Cant MR **E- Editor:** Wu HL



Pictures of focal nodular hyperplasia and hepatocellular adenomas

Christine Sempoux, Charles Balabaud, Paulette Bioulac-Sage

Christine Sempoux, Service d'Anatomie Pathologique, Cliniques universitaires Saint Luc, Université catholique de Louvain, 1200 Brussels, Belgium

Charles Balabaud, Paulette Bioulac-Sage, Inserm U 1053, Université Bordeaux Segalen, 33076 Bordeaux cedex, France

Author contributions: Sempoux C, Balabaud C, Bioulac-Sage P selected the photographs and wrote the paper.

Supported by Association pour la Recherche sur le Cancer, No. 3194

Correspondence to: Dr. Paulette Bioulac-Sage, Inserm U1053, Université Bordeaux Segalen, 146 Rue Léo Saignat, 33076 Bordeaux Cedex, France. paulette.bioulac-sage@chu-bordeaux.fr

Telephone: + 32-276-46764 Fax: + 32-276-46934

Received: February 12, 2013 Revised: June 10, 2013

Accepted: August 19, 2013

Published online: August 27, 2014

Abstract

This practical atlas aims to help liver and non liver pathologists to recognize benign hepatocellular nodules on resected specimen. Macroscopic and microscopic views together with immunohistochemical stains illustrate typical and atypical aspects of focal nodular hyperplasia and of hepatocellular adenoma, including hepatocellular adenomas subtypes with references to clinical and imaging data. Each step is important to make a correct diagnosis. The specimen including the nodule and the non-tumoral liver should be sliced, photographed and all different looking areas adequately sampled for paraffin inclusion. Routine histology includes HE, trichrome and cytokeratin 7. Immunohistochemistry includes glutamine synthase and according to the above results additional markers such as liver fatty acid binding protein, C reactive protein and beta catenin may be realized to differentiate focal nodular hyperplasia from hepatocellular adenoma subtypes. Clues for differential diagnosis and pitfalls are explained and illustrated.

© 2014 Baishideng Publishing Group Inc. All rights reserved.

Key words: Focal nodular hyperplasia; Hepatocellular

adenoma; Inflammatory hepatocellular adenoma; Beta catenin; Hepatocyte nuclear factor 1 alpha

Core tip: In this paper are illustrated macroscopic and microscopic aspects of focal nodular hyperplasia and hepatocellular adenoma. These illustrations represent typical as well as less usual aspects of these two benign hepatocellular tumors. Microscopic pictures are performed using classical routine stains such as HE, trichrome or cytokeratin 7 or less usual markers proven of great interest to identify focal nodular hyperplasia (FNH) such as glutamine synthase or liver fatty acid binding protein, C reactive protein or b catenin to identify hepatocyte nuclear factor 1 alpha mutated hepatocellular adenoma (HCA), inflammatory HCA, β -catenin mutated HCA respectively. These illustrations combined with brief clinical information should be helpful for pathologists for their practice. Indeed if FNH are rather frequent tumor easy to recognize, there are difficulties when key features are lacking or when features such as steatosis or sinusoidal dilatation, features of HCA, are present. The great message of this paper is the possibility to identify HCA subtypes, a key feature for the coming years to better manage patients.

Sempoux C, Balabaud C, Bioulac-Sage P. Pictures of focal nodular hyperplasia and hepatocellular adenomas. *World J Hepatol* 2014; 6(8): 580-595 Available from: URL: <http://www.wjgnet.com/1948-5182/full/v6/i8/580.htm> DOI: <http://dx.doi.org/10.4254/wjh.v6.i8.580>

INTRODUCTION

In the most recent liver pathology textbooks^[1-4], the description of focal nodular hyperplasia (FNH) and hepatocellular adenoma (HCA) taking into account the new classification of HCA allows to better differentiate FNH from HCA and to identify HCA subtypes, but not surprisingly there are few pictures of these 2 entities by lack

of space.

The aim of this atlas is to illustrate more extensively than in textbooks^[1-4] and journals^[5-7] the most frequent pathological aspects of FNH and HCA both macroscopically and microscopically, using traditional routine stainings and more recently described immunohistochemical approach.

It is important to mention that if these new immunohistochemical techniques have allowed the classification of HCA into subtypes by the pathologists, the definite criteria to classify HCA relies on molecular analysis^[8]. The strict correlation between the interpretation of the HCA classification based on the phenotype (macroscopy, routine techniques and immunohistochemistry) versus the genotype defined by the molecular analysis has to be strictly performed. In addition, the molecular classification is still in progress; therefore some data presented here should be interpreted cautiously in particular regarding the subgroups of β -catenin mutated HCA (β -HCA) and unclassified HCA (UHCA).

FOCAL NODULAR HYPERPLASIA

FNH are frequent hepatocellular nodules. Until recently the diagnosis was not always easy^[9]. If the diagnosis is certain, resection is not recommended^[10]; however, resection is occasionally performed upon pain, organ compression, doubt in differential diagnosis with HCA or with hepatocellular carcinoma. Using routine histopathological techniques [HE, trichrome, cytokeratin 7 (CK7)] the diagnosis is certain in more than 80% of cases. Glutamine synthase (GS) staining has the great advantage to confirm rapidly and with high confidence the diagnosis^[11]. When combining all the markers, the accuracy of the diagnosis is close to 100%.

HEPATOCELLULAR ADENOMA

HCA are rare hepatocellular nodules frequently resected when their size exceed 5 cm. HCA are divided into subtypes using molecular markers and immunohistochemistry^[12]. The most common HCA: HNF1A mutated HCA (H-HCA, 35%) and inflammatory HCA (IHCA, 50%) can be recognized with some degree of confidence by imaging techniques and by HE^[13-15]. GS is a surrogate marker to identify β -catenin mutated HCA (β -HCA, 10% and β -catenin activated inflammatory HCA, β -IHCA, 10% of IHCA)^[15,16]. Identification of β -catenin mutated HCA is of major clinical relevance because of the highest risk of malignant transformation^[17,18]. The mutation can be confirmed using β -catenin staining. The absence of aberrant nuclear staining is not however an argument to refute the diagnosis, because it is often focal^[15,16]. When GS is difficult to interpret, molecular biology is necessary to demonstrate β -catenin mutation in order to confirm the diagnosis^[8]. When the diagnosis of H-HCA or IHCA is not self-evident on routine stainings, immunostainings included liver-fatty acid binding protein (L-FABP), C-re-

active protein (CRP), markers which are useful to identify H-HCA (absence of LFABP) and IHCA (diffuse positivity of CRP). The absence of the above markers identifies unclassified HCA (less than 10%). The differential diagnosis between FNH and HCA is important as well as the identification of HCA subtypes thought to be of great importance for the present and future management^[19-22]. Indeed, in the past there has been a great confusion between FNH and HCA^[23,24].

Below are figures of FNH and HCA. For each macroscopic or microscopic pictures, we have given in the legend a minimum of clinical information. In this practical atlas we have not illustrated HCA with malignant transformation.

DIAGNOSIS

To increase the chance to make a correct diagnosis, some rules must be respected: the specimen must be carefully sliced; photographs should be taken to illustrate necrosis, hemorrhage and fibrotic bands; all areas of interest must be sampled as well as the non tumoral liver and the junction between the nodule and the non tumoral liver; routine histology includes HE, trichrome, and CK7; these markers may be sufficient to make a diagnosis of FNH, HCA and eventually HCA subtypes. When needed to differentiate an FNH from an HCA or to identify HCA subtypes, additional immunomarkers may be useful. In some occasions all of them may be useful when there is no indication for a specific diagnosis or HCA subtypes: it includes LFABP, C reactive protein (CRP), GS and β -catenin. Even when all the rules are followed, difficulties in interpretation may occur. First of all to have to check the quality of the technique; it is not necessary to overinterpret doubtful immunohistochemical data. When there is no way to interpret satisfactorily the data, one is forced to rely on the molecular data. This is why it is highly recommended for referral center to freeze material (tumor and non tumoral tissue) when their counterparts are analysed by routine histology.

RESULTS

FNH

The macroscopic aspects are presented in Figure 1. Microscopic typical features on Masson's Trichrome, GS and CK7 immunostainings are presented in Figure 2. Microscopic atypical features on Masson's trichrome and GS immunostaining are presented in Figure 3. The other microscopic aspects dealing with steatotic, pre-FNH and regressing FNH are presented in Figure 4.

HCA

The macroscopic aspects of different subtypes are presented in Figure 5.

H-HCA

The microscopic typical and atypical features are present-

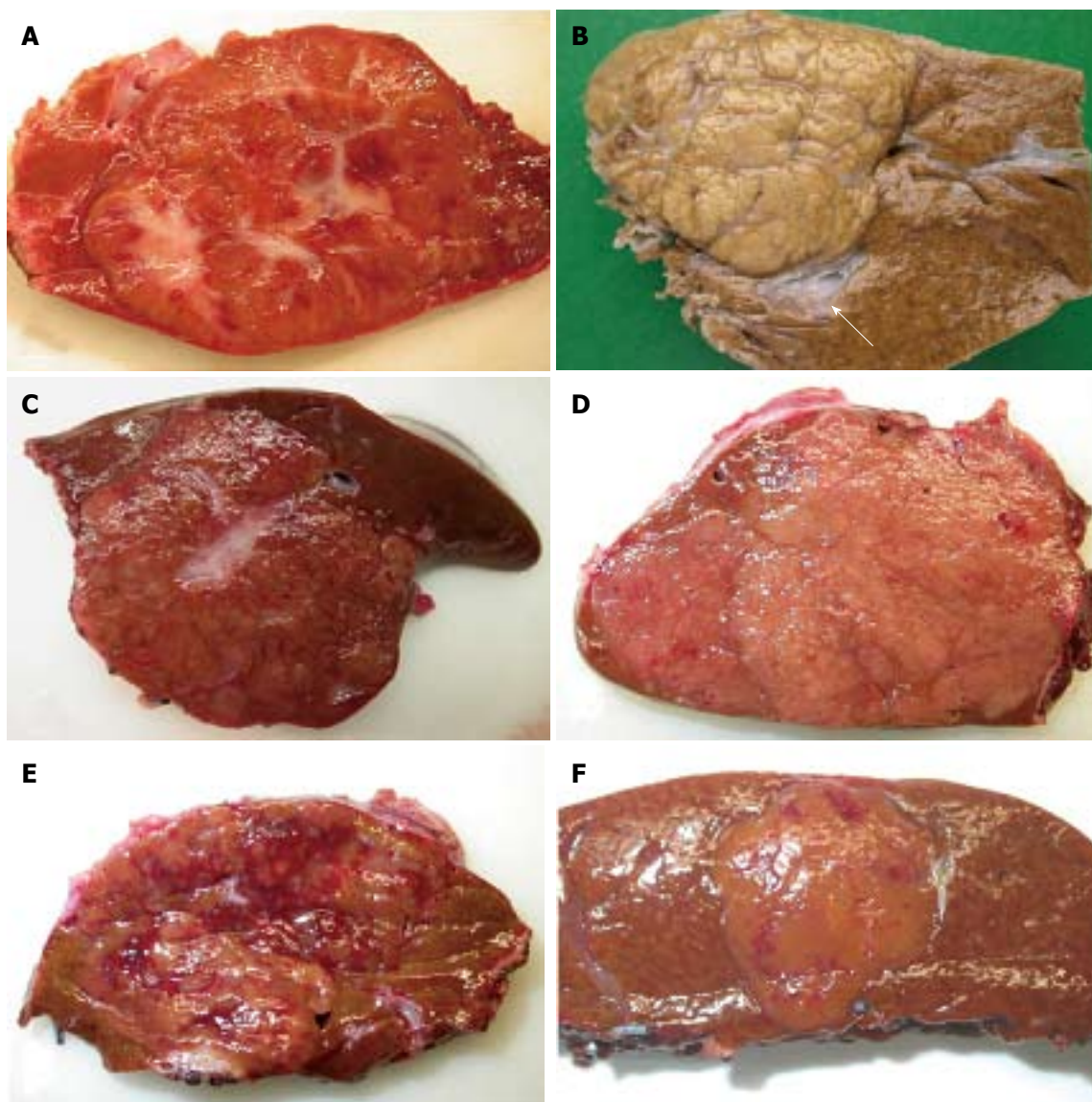


Figure 1 Focal nodular hyperplasia the macroscopic aspects. A: Man born in 1988; 100 kg/1.95 m; abdominal pain; abnormal liver function tests; magnetic resonance imaging (MRI): liver mass 9.5 cm: Focal nodular hyperplasia (FNH)/hepatocellular adenoma (HCA) (bisegmentectomy in 2009). Fresh specimen: typical aspect of FNH: Tan, vaguely plurinodular tumor, non encapsulated, with central stellate scar. This macroscopic aspect is typical and the diagnosis of FNH is evident. The diagnosis was confirmed on HE and CK7. B: Woman born in 1951; acute abdominal pain followed by discomfort and pain on abdominal palpation; ultrasound (US): 2 nodules, largest one 3.5 cm. Magnetic resonance imaging (MRI): FNH (left hepatectomy in 2008). Fixed specimen: plurinodular tumor with thin fibrous bands, non encapsulated but well demarcated from surrounding liver parenchyma, with large portal tract at the interface (arrow). The diagnosis of FNH is evident. The diagnosis was confirmed on HE and CK7. C: Woman born in 1986; abdominal pain; MRI 2007: FNH 6.4 cm close to the biliary convergence; US in 2000: hemangioma 15 mm; 2004: 4.5 cm (tumorectomy in 2007). Fresh specimen: pedunculated irregular nodule with eccentric fibrous scar, well demarcated from the surrounding liver. The diagnosis of FNH is likely. D: Woman born in 1965; oral contraceptives for 18 years; abdominal pain; imaging (6 cm): FNH [surgery in 2005 (tumorectomy)]. Fresh specimen: clear-tan, vaguely plurinodular tumor, without clear-cut fibrous scar. The diagnosis of FNH is not self-evident. The diagnosis was confirmed on HE, CK7 and glutamine synthase (GS). E: Woman born in 1961; abnormal liver function tests; liver US: nodule 5.5 cm, MRI and US favors HCA over FNH (segmentectomy VII in 2009). Fresh specimen: irregular cut surface with tan nodules separated by congestive/reddish, atrophic areas. The diagnosis of FNH is unlikely. F: Woman born in 1956; check-up for arterial hypertension; liver imaging (2 cm nodule): probable HCA (tumorectomy in 2003) (other nodules were found). Fresh specimen: well-limited, non encapsulated, smooth nodule, with small reddish areas, without any fibrous bands or scar visible. The diagnosis of FNH is unlikely. The diagnosis was confirmed by HE, CK7 and GS.

ed in Figures 6 and 7 respectively. The different aspects of LFABP and GS stainings are presented in Figures 8 and 9 respectively.

Inflammatory HCA

The typical microscopic aspects are presented in Figures 10 and 11. The immunohistochemistry is presented in

Figure 12.

β -IHCA

Microphotographs are presented in Figures 13-15.

β -catenin

Micrographs are presented in Figures 16 and 17 showing

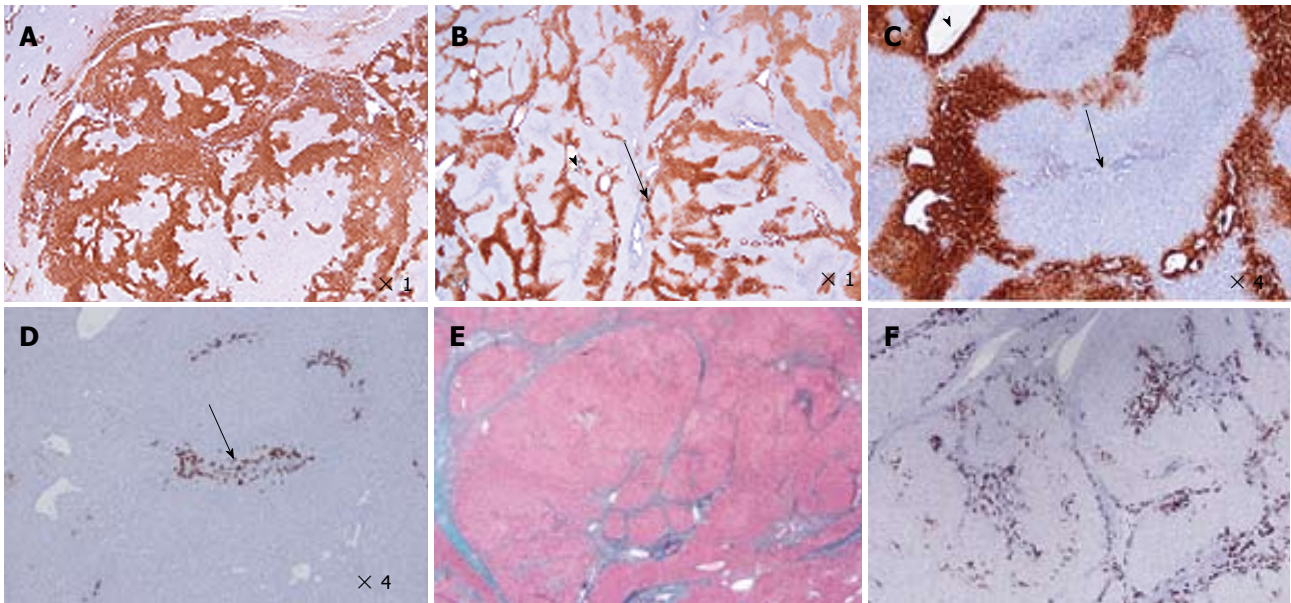


Figure 2 Focal nodular hyperplasia microscopic typical features on Masson's trichrome, glutamine synthase and CK7 immunostainings. A: Same patient as Figure 1C. Glutamine synthase (GS) immunostaining: typical aspect of focal nodular hyperplasia (FNH) with large anastomosed positive areas in a "map-like" pattern^[11]. B-D: Woman born in 1969; abnormal liver function tests (GGT); ultrasound (US): nodule interpreted as a hemangioma, computed tomography scan and magnetic resonance imaging: FNH 8 cm, segment VIII with minor dilatation of the right biliary tree (compression by the tumor). Left lobectomy + segmentectomy VIII in 2002 (other nodule segment II : 0.5 cm). B, C: GS immunostaining: typical aspect of FNH with anastomosed positive areas often centered by veins (arrowhead) and at distance of fibrous bands (arrows). C and D are from 2 serial sections. D: CK7 immunostaining: ductular reaction at the periphery of fibrous bands. E, F: Same patient as Figure 1C. E: Masson's trichrome - fibrous bands surrounding benign hepatocytic nodules of different sizes. F: CK7 immunostaining - prominent ductular reaction at the junction between parenchymal nodules and fibrous bands. Typical aspect of FNH.

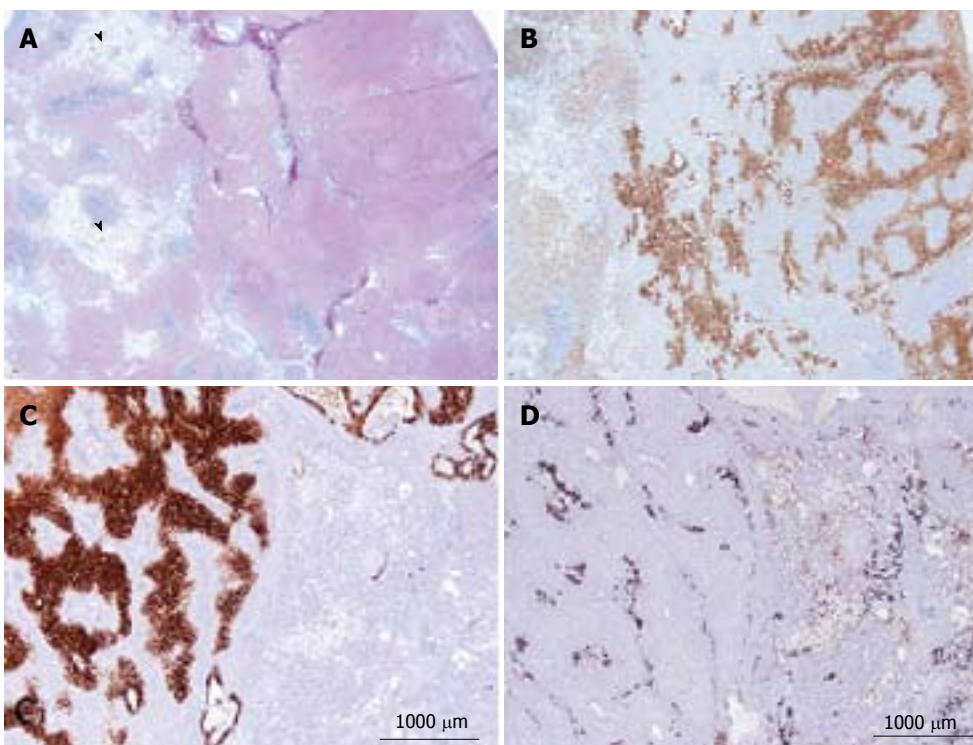


Figure 3 Focal nodular hyperplasia microscopic atypical features on Masson's trichrome and glutamine synthase immunostaining. A, B: Same patient as Figure 1E. A: Masson's trichrome - large areas of sinusoidal dilatation (arrowhead), nearby solid hepatocytic areas (right) with thin, short fibrotic bands. B: Glutamine synthase (GS) immunostaining - typical aspect of focal nodular hyperplasia (FNH) with anastomosed positive areas in a "map-like" pattern in the nodular area (right); no staining in the sinusoidal dilatation area (left). This aspect is very unusual. This nodule should not be interpreted as a mixed tumor (part FNH and part hepatocellular adenoma) and should not be called "telangiectatic FNH"^[23,24]. A better term could be FNH with major sinusoidal dilatation. C, D: Woman born in 1969, 2003; 2 FNH: first hepatic resection (tumorectomy in 2003 for a 7-cm FNH). In 2004, persistence of abdominal discomfort (no change in size of the 7 cm FNH). Right hepatectomy. C: Typical GS staining (left); no GS staining in the area of sinusoidal dilatation (right). D: Obvious ductular reaction on the CK7 immunostaining. Although the 2 above cases are very rare, FNH with areas of sinusoidal dilatation are seen occasionally.

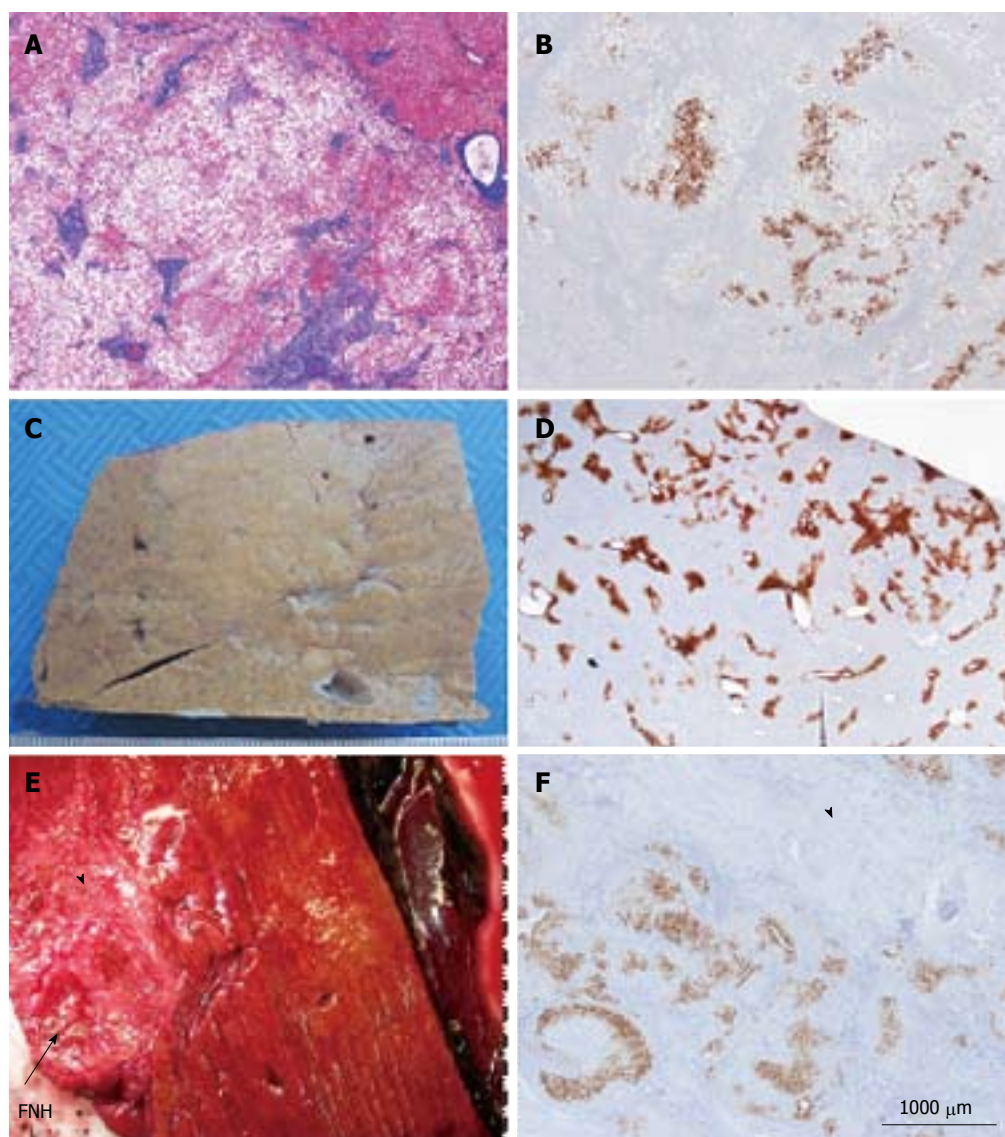


Figure 4 Other aspects (steatotic, pre-focal nodular hyperplasia, regressing focal nodular hyperplasia). A, B: Woman born in 1959; heavy alcohol consumption, tobacco; hepatomegaly, no evidence for cirrhosis on liver function tests, virus negative. Computed tomography scan: nodule 3.5 cm and others (1.5, 0.3 and 0.8 cm). No firm radiological diagnosis: ?focal nodular hyperplasia (FNH)/hepatocellular adenoma (HCA)/HCC, left hepatectomy in 2001. A: Masson's trichrome - the nodule is composed of benign steatotic hepatocytes separated by fibrous bands. Steatosis is not a rare event in FNH. B: Glutamine synthase (GS) immunostaining - anastomosed GS positive areas, favoring the diagnosis of steatotic FNH. The diagnosis of FNH remains doubtful, however. In this case, the diagnoses of HNF1A mutated HCA, inflammatory HCA, β -HCA and β -IHCA were ruled out (specific IHC markers were negative). The diagnosis of unclassified HCA cannot, however, be ruled out. Molecular analysis is necessary to confirm the diagnosis. C, D: Woman born in 1950; abdominal pain: gallbladder lithiasis; Magnetic resonance imaging (MRI): 2.5 cm nodule, probably an HCA. Left hepatectomy plus cholecystectomy in 2000. C: Fixed specimen - subcapsular, not well defined nodule barely visible, clearer than the surrounding liver. D: GS immunostaining - the positive perivenular areas are slightly but significantly larger than in the surrounding normal liver; this aspect is interpreted as a "pre-FNH" without fibrosis and nodulation. Pre FNH is probably not a rare entity but to-day there is no consensus concerning its denomination^[6]. This type of lesion has been named in congenital vascular abnormalities such as Rendu-Osler disease. E, F: Woman born in 1948; intrahepatic hemorrhagic rupture of a large nodule of segment VII in 2009. MRI favors HCC, additional 4 nodules known since 2005 and interpreted as FNH. Size of the FNH nodule resected with the HCC has decreased significantly. Right hepatectomy (HCC + 1 additional not identified nodule, previously known as FNH). E: Fresh specimen: close to the hemorrhagic HCC, a 4 cm hard white/brown nodule, under the capsule (arrow), with irregular surface. F: GS immunostaining: limited positive areas (map-like pattern) surrounded by large areas of dense fibrous tissue (arrowhead). All these features are interpreted as a regressing FNH. This interpretation needs to be confirmed by additional cases.



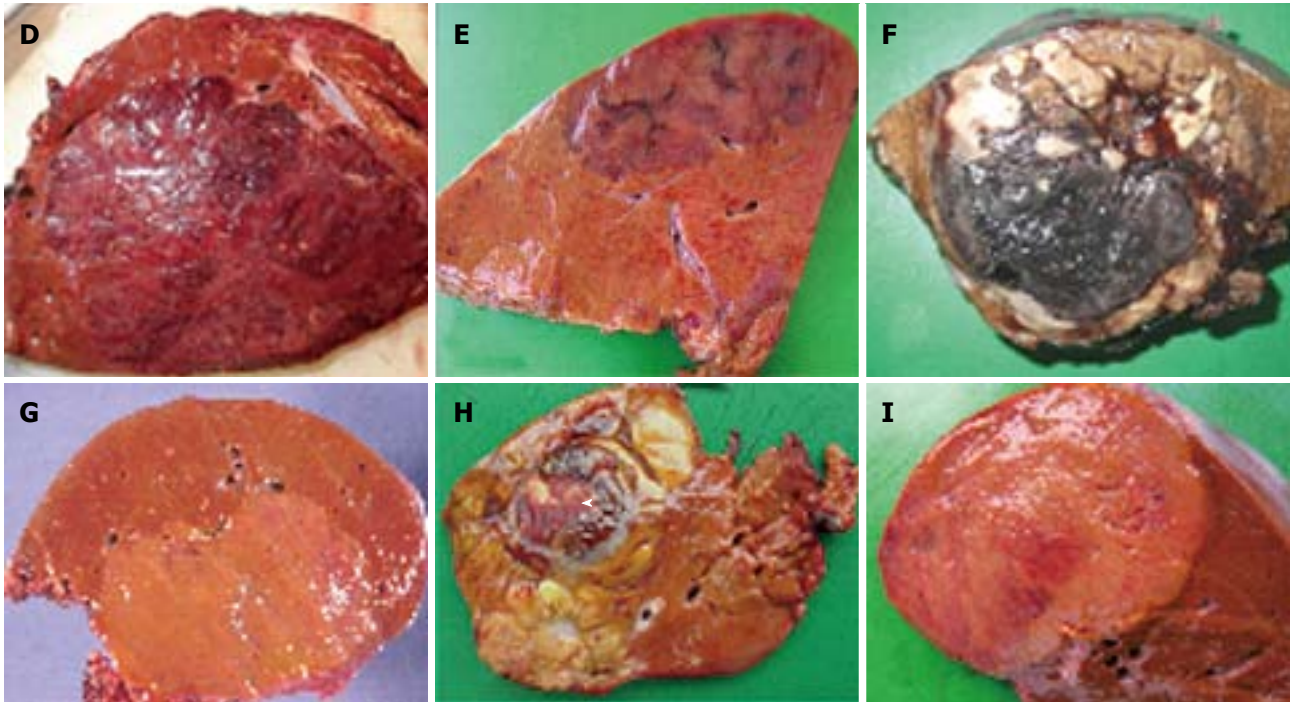


Figure 5 Hepatocellular adenoma macroscopic aspects of different subtypes: A-C: Examples of HNF1A mutated hepatocellular adenoma (H-HCA). A: Woman born in 1972; oral contraceptives for 8 years. Discovery of a liver nodule (3.5 cm). No regression after stopping contraceptives. Fear of complications by the patient. Left hepatectomy in 2008; fresh specimen: yellowish tumor, clearer than the surrounding liver. The diagnosis of H-HCA is likely but not self-evident. The diagnosis was confirmed by immunohistochemistry. B: Woman born in 1974; oral contraceptives for 12 years. Liver nodules discovered by chance on imaging and diagnosis of adenomatosis. Largest nodule 5 cm. Segmentectomy IVb 2006. Other small nodules. One nodule was an focal nodular hyperplasia (FNH). Fixed specimen of one nodule: yellowish, clear tumor, non encapsulated, contrasting with the surrounding liver. The diagnosis of H-HCA is likely. The diagnosis was confirmed by immunohistochemistry. C: Woman born in 1978. Massive right hepatomegaly discovered in the obstetric department (miscarriage at 6 wk). No oral contraception. Right hepatectomy in 2004. Fresh specimen: large irregular, mammillated tumor occupying the whole right liver. This is an exceptional case. The diagnosis was confirmed by immunohistochemistry. D-F: Examples of IHCA (D, E) and β -IHCA (F). D: Woman born in 1968; overweight, BMI > 40 kg/m². Oral contraceptives for 18 years. Several nodules detected on imaging. Doubtful diagnosis. Surgical biopsies: HCA. Right hepatectomy in 2008 (largest nodule 10 cm). In 2009, another known HCA removed in the left liver (11 cm). Fresh specimen: reddish tumor with congestive areas. The diagnosis of inflammatory HCA (IHCA) is likely. The diagnosis was confirmed by immunohistochemistry. E: Woman born in 1956; oral contraceptives for 31 years. Biological abnormalities (inflammatory syndrome). CT scan and MRI multiple liver nodules (largest nodule 7 cm) in favor of IHCA. Surgery in 2007: bisegmentectomy VI-VII plus 2 tumorectomies. Fresh specimen: ill defined tumor with congestive strands. The diagnosis of IHCA is very likely. The diagnosis was confirmed by immunohistochemistry. F: Woman born in 1971; liver hemorrhage. Imaging: 5 nodules, largest 8 cm. No oral contraceptives; BMI 20.4 kg/m². Segmentectomy III, VI, VIII 2007. Fixed specimen: large hematoma and a narrow viable tissue at the periphery. No obvious diagnosis. The diagnosis of HCC cannot be ruled out. The diagnosis was confirmed by immunohistochemistry. G: Example of β -catenin HCA. Woman born in 1981; one nodule 8 cm discovered by chance. Imaging HCA. Oral contraceptives for 8 years; BMI 21.1 kg/m². Right hepatectomy 2005. Fresh specimen: well limited clear nodule. The diagnosis of HCA is likely. H-HCA and IHCA are unlikely. H: Example of HCC developed on β -IHCA. Woman born in 1934; intramuscular injection of hormones as contraceptive. Liver nodule interpreted as hemangioma, known for several years. Growth of the nodule. Segmentectomy in 2000. Fresh specimen: irregular, multinodular tumor, with a large necrotic and hemorrhagic area (arrowhead) surrounded by a fibrous rim. The diagnosis of HCC is likely. I: Example of unclassified HCA. Woman born in 1983; abdominal pain. Imaging: one nodule 8 cm; no final diagnosis. Oral contraceptives for 8 years. BMI 20.2 kg/m². Right hepatectomy 2007. Fresh specimen: well limited clear nodule with a pale reddish area. The diagnosis of HCA is likely. H-HCA and IHCA are unlikely.

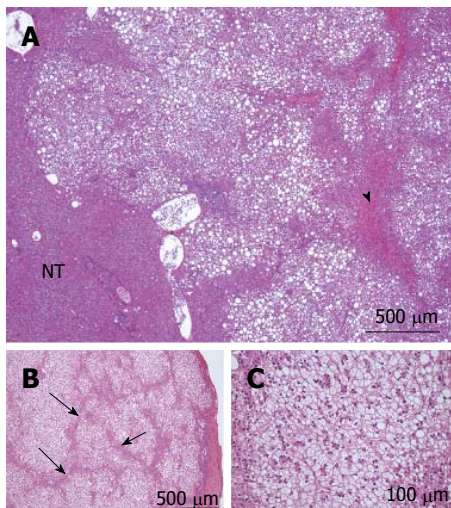


Figure 6 HNF1A mutated hepatocellular adenoma microscopic typical features. A: Woman born in 1955; surgery in 2010 for an HCC (6 cm) developed on a non fibrotic liver. Discovery of another small nodule on the surgical specimen. No oral contraceptives; BMI 24.1 kg/m². HE: typical aspect of HNF1A mutated hepatocellular adenoma (H-HCA): nodule with lobulated contours, made of benign hepatocytes with diffuse steatosis; some congestive areas (arrowhead); sharp contrast with non steatotic surrounding liver. The diagnosis was confirmed by immunohistochemistry. B, C: Woman born in 1952; abdominal pain; imaging: nodule 1.8 cm, no firm diagnosis by magnetic resonance imaging. Oral contraceptives, 27 years; BMI 22.0 kg/m². Tumorectomy in 2008. B: Nodule composed of benign, clear hepatocytes, sometimes steatotic, separated by thin strands of atrophic hepatocytes (arrow). C: Same nodule seen at higher magnification. Although clear hepatocytes are not the hallmark of H-HCA, the lobular pattern is very characteristic. It consists of steatotic or clear hepatocytes arranged in a lobular pattern separated by tumoral, atrophic, not steatotic hepatocytes. Commonly, arterioles/small arteries are seen in this space (not shown on this micrograph). The diagnosis was confirmed by immunohistochemistry.

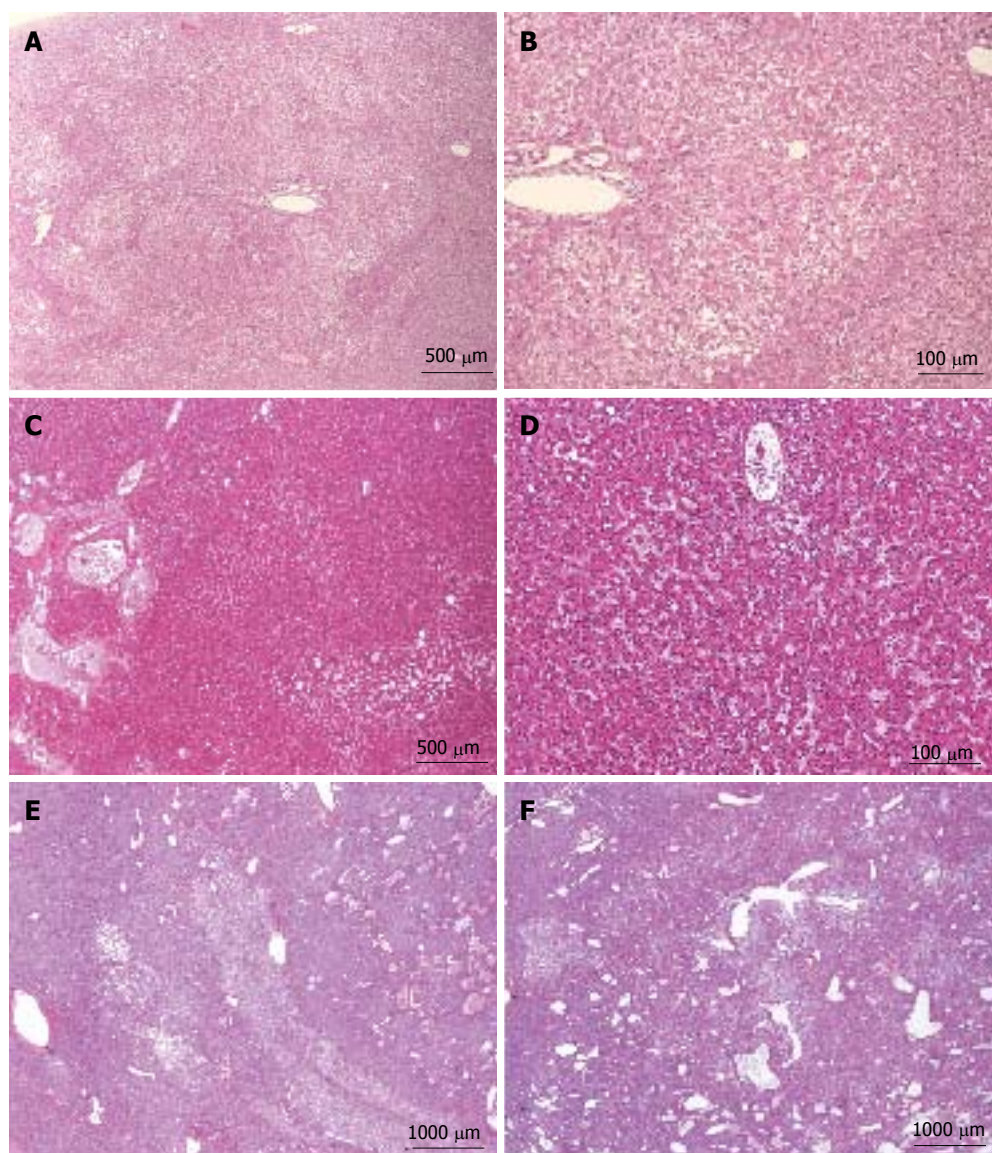
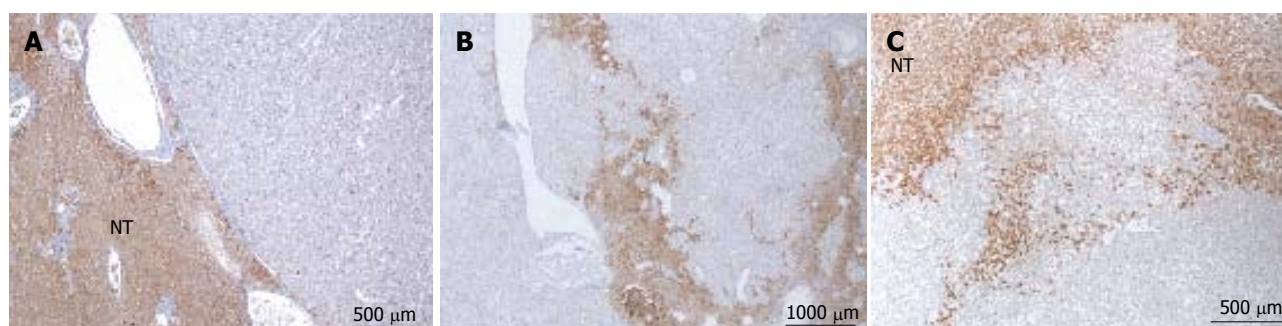


Figure 7 HNF1a inactivated hepatocellular adenoma microscopic atypical feature. A, B: Woman born in 1952; abnormal liver function tests; oral contraceptives 13 years; BMI 25.4; magnetic resonance imaging (MRI): adenomatosis, largest nodule 6 cm. Segmentectomy IV/VI in 2001. A: ill defined nodule composed of clear hepatocytes, with mild steatosis. B: Same nodule seen at a higher magnification. The normal portal tract from the periphery of non tumoral parenchyma is entrapped in the nodule. The diagnosis of HNF1A mutated hepatocellular adenoma (H-HCA) is less evident than in Figure 6B, C. The diagnosis was confirmed by immunohistochemistry. C, D: Woman born in 1950; abnormal liver function tests; imaging: probable FNH 12 cm. Right hepatectomy 2002. HE: proliferation of benign hepatocytes, no steatosis, mild sinusoidal dilatation. This is a rare case. The diagnosis of H-HCA cannot be suspected without performing immunohistochemistry. E, F: Woman born in 1965; past history of cancer. Abdominal pain. Oral contraceptives 10 years, BMI 21 kg/m². MRI: Adenomatosis, largest nodule 3.9 cm. Segmentectomy and tumorectomy in 2011. HE: Proliferation of benign hepatocytes, no steatosis, mild sinusoidal dilatation, numerous ectatic vessels. As above, in this rare case the diagnosis of H-HCA cannot be suspected without immunohistochemistry, and malignant transformation has to be ruled out.



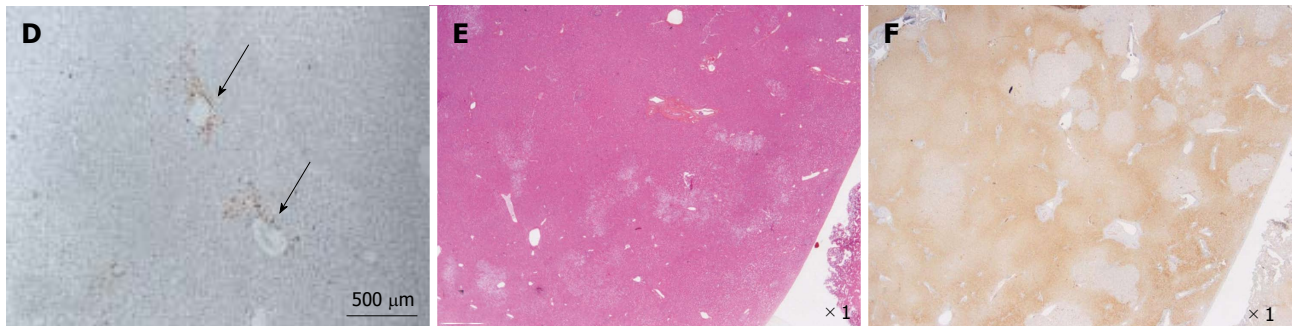


Figure 8 HNF1a inactivated hepatocellular adenoma different aspects of liver-fatty acid binding protein staining. A: Same patient as Figure 7C, D. Typical aspect: absence of liver-fatty acid binding protein (LFABP) staining in tumor contrasting with normal expression in non tumoral liver (NT). B: Same patient as Figure 7E, F. Bands of non tumoral (NT) parenchyma normally expressing LFABP are penetrating within the unstained tumor. Indeed, the growth of HNF1A mutated hepatocellular adenoma (H-HCA) is due to the coalescence of several adenomatous liver nodules and it is not rare to find non adenomatous liver lobules squeezed in between. C: Woman born in 1962; abdominal pain. Oral contraceptives 25 years; BMI 25 kg/m². Two liver nodules, largest 3.7 cm. Segmentectomy V/VI (2005). Bands of hepatocytes expressing LFABP within the unstained typical H-HCA. Same comment as above. D: Same patient as Figure 7E, F. LFABP expression in a few perivenular hepatocytes, particularly at the periphery of H-HCA, is a frequent observation, as well as a rim of positive hepatocytes at the border. E, F: Woman born in 1967; adenomatosis suspected during coelioscopy for extrauterine pregnancy. Segmentectomy for a 6 cm liver nodule. On HE (E), at distance from the main lesion, the presence of several steatotic small nodules well identified on LFABP staining (F). This is a very specific and characteristic aspect of H-HCA adenomatosis.

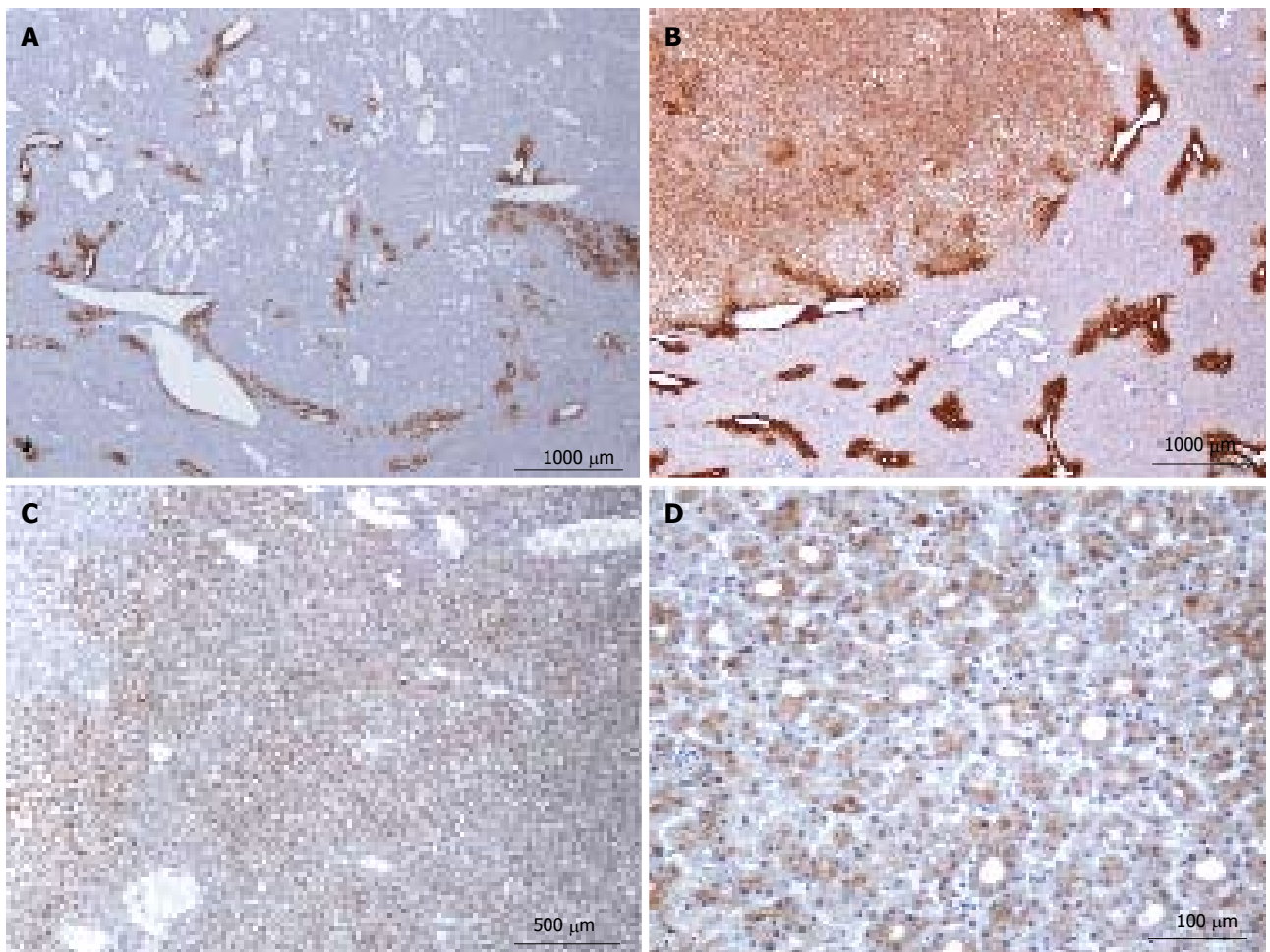


Figure 9 HNF1a inactivated hepatocellular adenoma different aspects of glutamine synthase immunostaining. A: Same patient as Figure 7E, F. There is no staining within the lesion, except around some veins, mainly at the borders where liver-fatty acid binding protein staining (not shown) demonstrates intermingled HNF1A mutated hepatocellular adenoma (H-HCA) and normal parenchyma areas. It was impossible on HE staining to clearly identify the border of the tumor. B: Woman born in 1964; one nodule discovered by chance, 5.5 cm; oral contraceptives 21 years; BMI 18.4 kg/m². Biopsy: β -HCA. Segmentectomy VIII 2007. Diffuse, moderate glutamine synthase (GS) staining, contrasting with normal staining in non tumoral liver in which the GS staining is limited to 1-3 rows of centrilobular hepatocytes. Today, in the absence of β -catenin nuclear staining, the significance of this abnormal GS staining in HCA remains unknown and molecular analysis is mandatory to search for β -catenin mutations. C, D: Same patient as Figure 7C, D. Heterogeneous, mild staining in tumoral hepatocytes, sometimes arranged in rosettes. The presence of rosettes is often considered as a criterion suggesting a possible malignant transformation; it may also reflect cholestatic features. Same comment as above: in the absence of molecular analysis, it is not possible to conclude and a search for β -catenin mutations is mandatory.

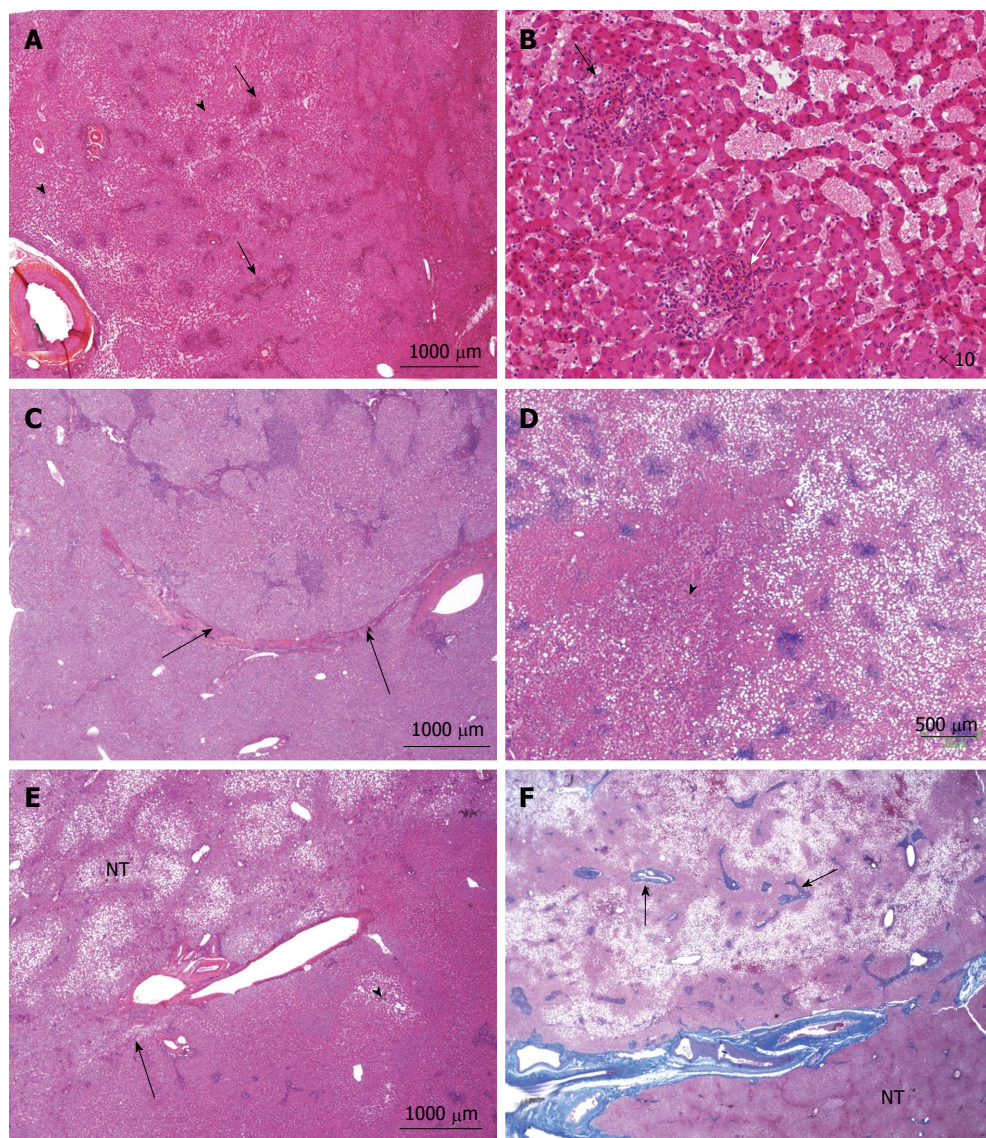
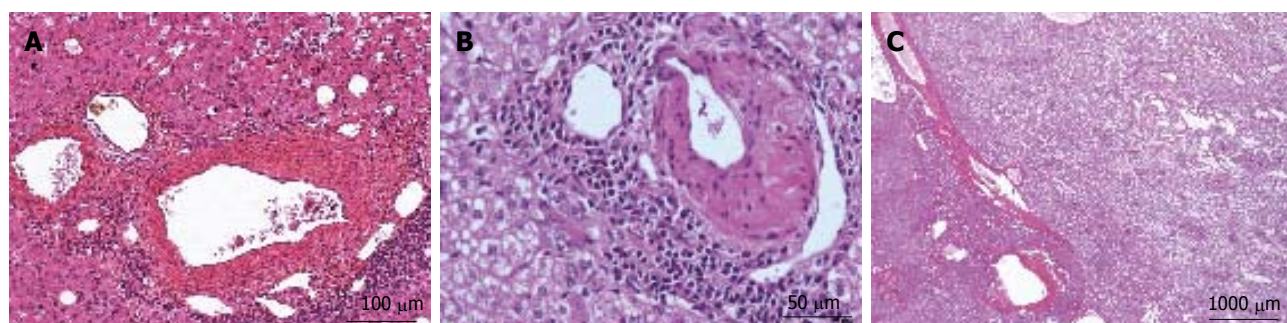


Figure 10 Inflammatory hepatocellular adenoma typical microscopic aspects. A: Woman born in 1959; adenomatosis discovered by chance. Size of the largest nodule: 11 cm. Oral contraceptives for 23 years; BMI 27.0 kg/m². Left hepatectomy 2008. HE: typical aspect of an inflammatory hepatocellular adenoma (IHCA) with many small inflammatory foci (arrows) dispersed within the tumor, associated with areas of moderate sinusoidal dilation (arrowhead). In this area, sinusoids are dilated, another hallmark of this subgroup. B: Woman born in 1969; abnormal liver function tests. One liver nodule, 12 cm. Oral contraceptives for 16 years; BMI 26.0 kg/m². Right hepatectomy 2004. HE: areas of sinusoidal dilatation and pseudo portal tracts with thick walled arteries and inflammatory cells (arrows), hallmarks of this subgroup. The diagnosis was confirmed by immunohistochemistry. C: Man born in 1968; abnormal liver function tests. One nodule 12 cm. BMI 30.0 kg/m². Right hepatectomy 2011. HE: prominent inflammatory foci dispersed in the tumor; thick vessels at the border of the HCA (arrow). The diagnosis was confirmed by immunohistochemistry. D: Woman born in 1966; liver nodule, 3.5 cm discovered by chance. No oral contraceptives, BMI 24.5 kg/m². Right hepatectomy 2004. HE: inflammatory foci, areas of sinusoidal dilatation; in this area, tumoral hepatocytes are steatotic. E: Woman born in 1973; overweight. Adenomatosis discovered by chance. Largest nodule 7 cm. Biopsy HCA. Tumorectomy IV, VI, VII 2003. HE: ill defined benign hepatocellular tumor (arrow); limited areas of sinusoidal dilatation (arrowhead) predominating at the periphery of the tumor. The non tumoral liver is steatotic, a frequent finding in this group of patients. F: Woman born in 1966; abnormal liver function tests. Several liver nodules. Biopsy HCA; oral contraceptives for 10 years, BMI 29.6 kg/m². Left hepatectomy and tumorectomy IV and VI, 2007. Masson's trichrome: pseudo portal tracts (arrows) with arteries in fibrous tissue; large areas of steatosis, within the tumor. The tumor is limited by thick arteries and veins from the non tumoral liver (NT).



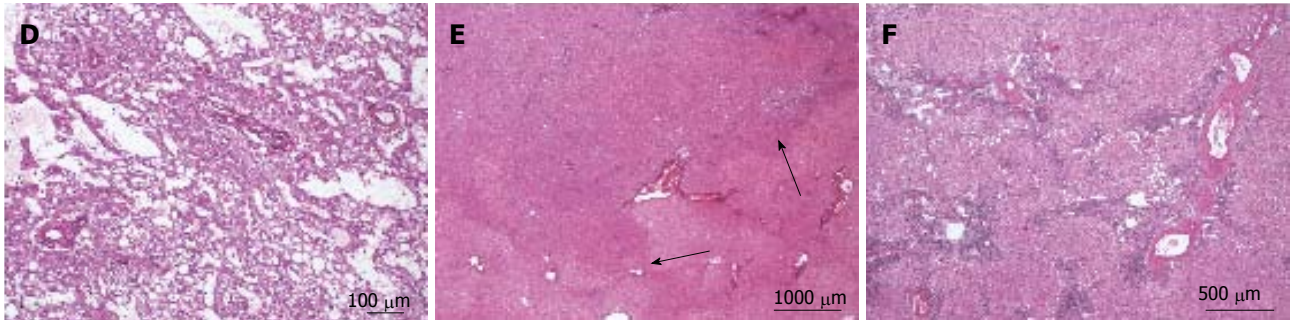


Figure 11 Inflammatory hepatocellular adenoma typical microscopic aspects. A: Same patient as Figure 10 D. B: Same patient as Figure 10F. HE: thick-walled arteries surrounded by inflammatory cells. These pseudo portal tracts are very characteristic of inflammatory hepatocellular adenoma (IHCA). C, D: Woman born in 1972; oral contraceptives for 19 years. BMI 19.6 kg/m². One nodule 10 cm discovered by chance. Magnetic resonance imaging: IHCA. Right hepatectomy 2009. HE: prominent sinusoidal dilatation. E, F: Same patient as Figure 10F, different tumors. E: HE - tumor ill-defined from the surrounding liver without any inflammation or sinusoidal dilatation. F: HE - the histological aspect is different with a more typical aspect of IHCA. Here, thick arteries are surrounded by inflammatory cells and fibrous tissue within the hepatocellular proliferation.

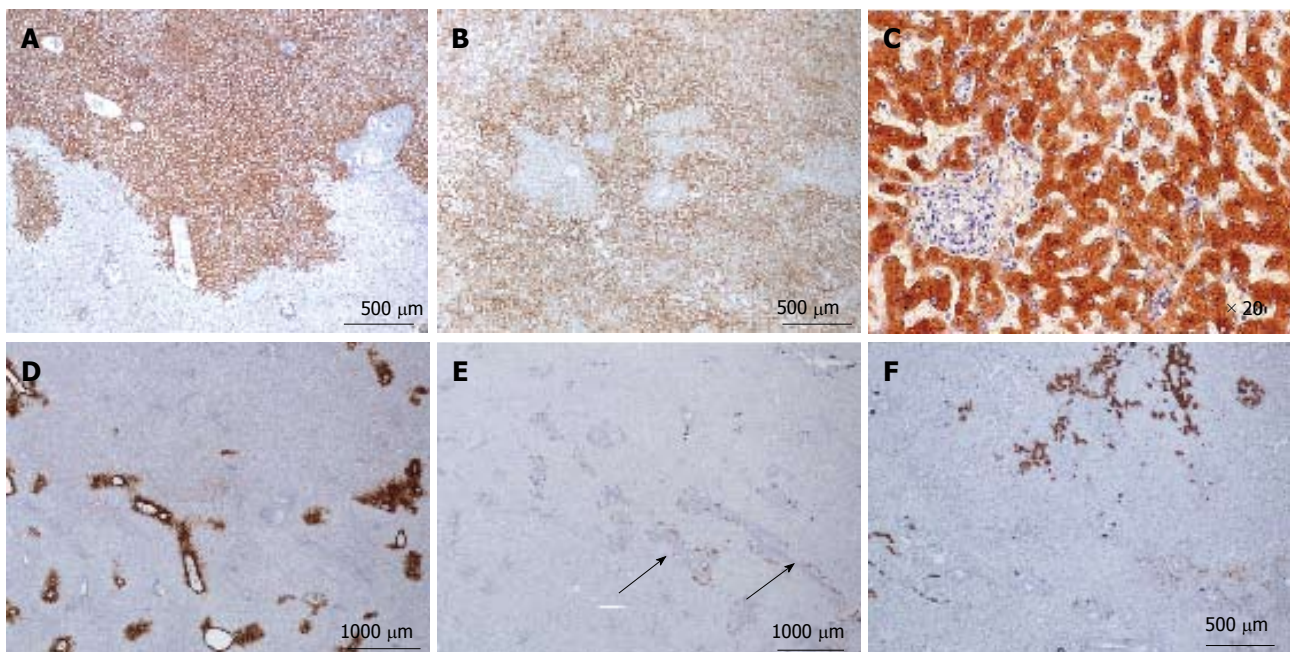
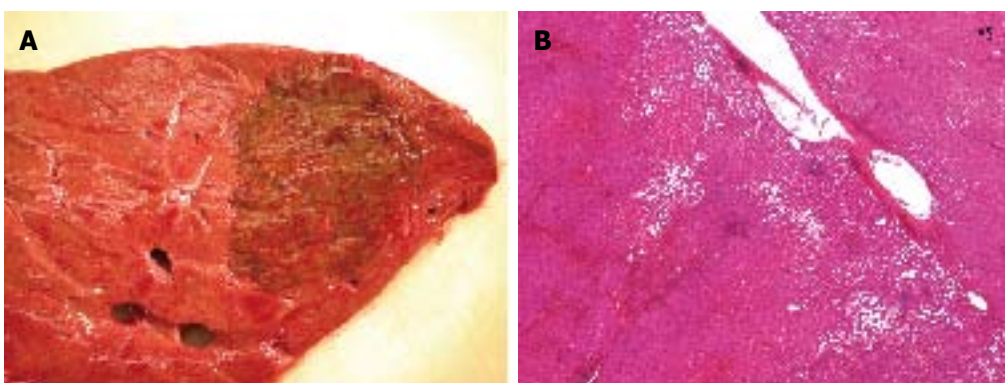


Figure 12 Inflammatory hepatocellular adenoma immunohistochemistry. A, B: Same patient as Figure 10 F, different tumors. C-reactive protein (CRP): typical aspect of inflammatory hepatocellular adenoma (IHCA) with strong and diffuse expression in tumoral hepatocytes, with sharp demarcation from the surrounding non tumoral liver (A); more irregular CRP staining with limited areas remaining negative (B); C: Same patient as Figure 10D. CRP is expressed only in hepatocytes. D, E: Same patient as Figure 10F. D: Glutamine synthase: no abnormal staining; positivity only in some perivenous hepatocytes at the periphery of the nodule. E: CK7: faint staining around pseudo portal tracts, underlining ductular reaction, a common finding in IHCA. F: Same patient as Figure 10A. CK7 highlights the major ductular reaction at the periphery of pseudo portal tracts.



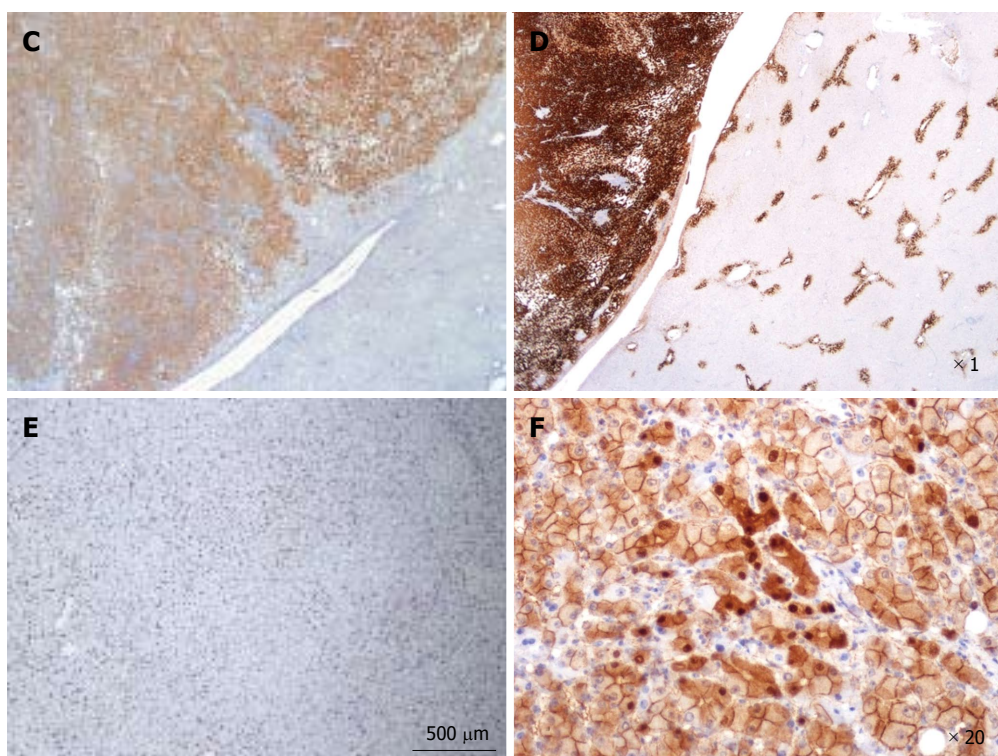


Figure 13 β -catenin activated, inflammatory hepatocellular adenoma. A-F: Man born in 1971. BMI 21.6 kg/m². By chance, discovery of one nodule 6 cm. Imaging: focal nodular hyperplasia. Right hepatectomy 2006. A: Fresh specimen: pigmented, irregular tumor. Non tumoral liver is normal. B: HE: Hepatocellular adenoma with sinusoidal dilatation and inflammatory infiltrate (on the left); large vessels at the junction with non tumoral liver. C: Diffuse expression of C-reactive protein by tumoral hepatocytes, with sharp demarcation from the non tumoral liver. D: Strong and diffuse glutamine synthase (GS) expression contrasting with normal staining of GS in adjacent non tumoral liver (in a few pericentrolobular hepatocytes). E: Large areas are positive for CD34, but not diffuse diffusely; F: Aberrant nuclear and cytoplasmic expression of β -catenin in quite numerous hepatocytes.

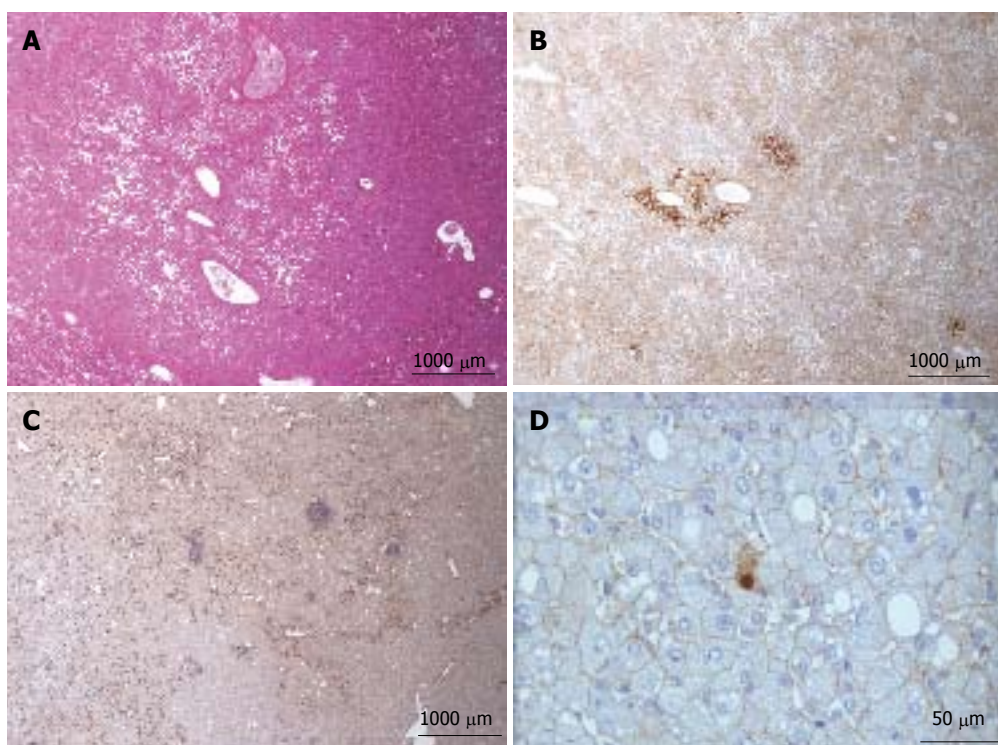


Figure 14 β -catenin activated, inflammatory hepatocellular adenoma. A, B: Woman born in 1967. Oral contraceptives 20 years, BMI 20.0 kg/m². By chance, discovery of one nodule 18 cm. Imaging hepatocellular adenoma (HCA). Segmentectomy IV and V 2005. A: HE: features of inflammatory HCA (IHCA): sinusoidal dilatation, thick vessels, mild inflammation. B: Glutamine synthase immunostaining is abnormal, but faint and heterogeneous with reinforcement around veins. C, D: Woman born in 1974; oral contraceptives 13 years. BMI 21.0 kg/m². By chance, discovery of one nodule 6.5 cm. Imaging IHCA. Segmentectomy VI and VII 2009. C: Marked but not diffuse CD34 immunostaining. D: Very few tumoral hepatocytes expressed aberrant nuclear β -catenin.

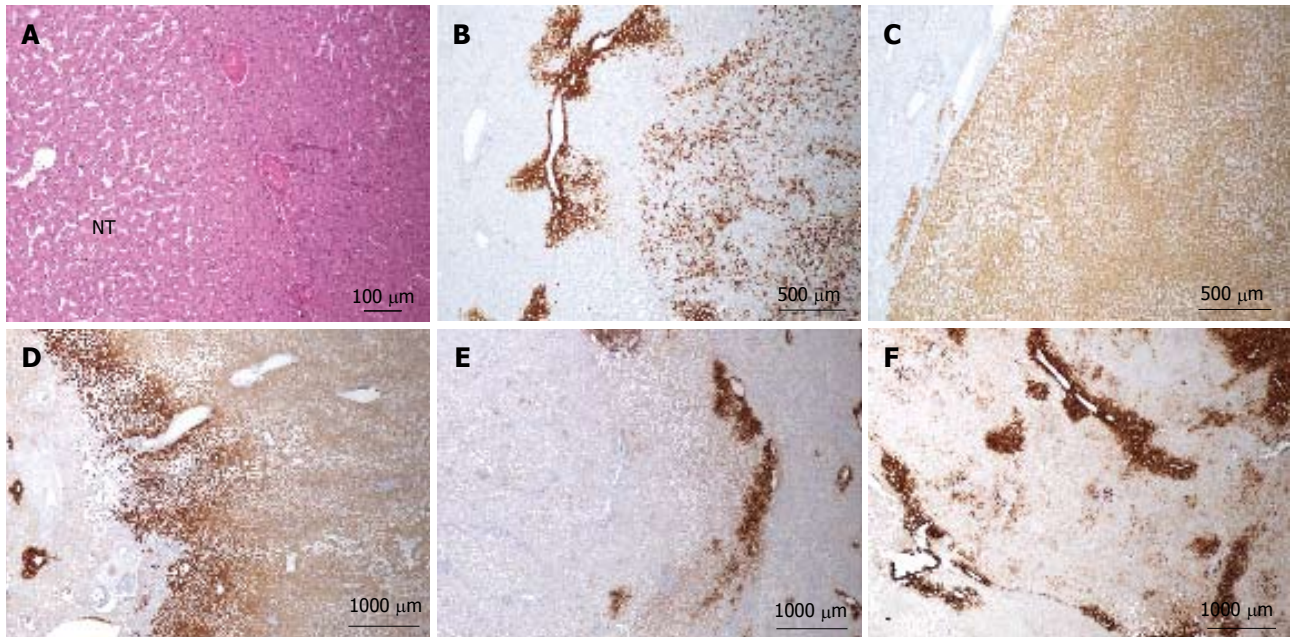


Figure 15 β -catenin activated, inflammatory hepatocellular adenoma. A-C: Woman born in 1971; liver hemorrhage. No oral contraceptives. BMI 20.4 kg/m². Imaging 5 nodules, largest 8 cm. Segmentectomy III, VI, VIII 2007. A: HE - large arteries at the periphery of the nodule. Mild sinusoidal dilatation in the non tumoral liver (NT). B: Abnormal patchy GS staining in one nodule. C: Abnormal homogeneous glutamine synthase (GS) staining in another nodule. D-F: Woman born in 1959; oral contraceptives for 21 years. BMI 21.8 kg/m². Abnormal liver function tests. Imaging: 3 nodules, largest 10 cm. Right hepatectomy 2005. In the three nodules, GS staining is different but definitely abnormal. D: Homogeneous. E: Extremely faint. F: Patchy GS staining. The difficulty in interpreting GS often comes from the positivity that can be found around veins. This perivenular staining is normal when it is strictly limited to 1 or 2 rows of perivenular hepatocytes; the interpretation of a GS staining larger than 2 or 3 rows of hepatocytes, even if faint or patchy, remains poorly understood in the absence of molecular analysis.

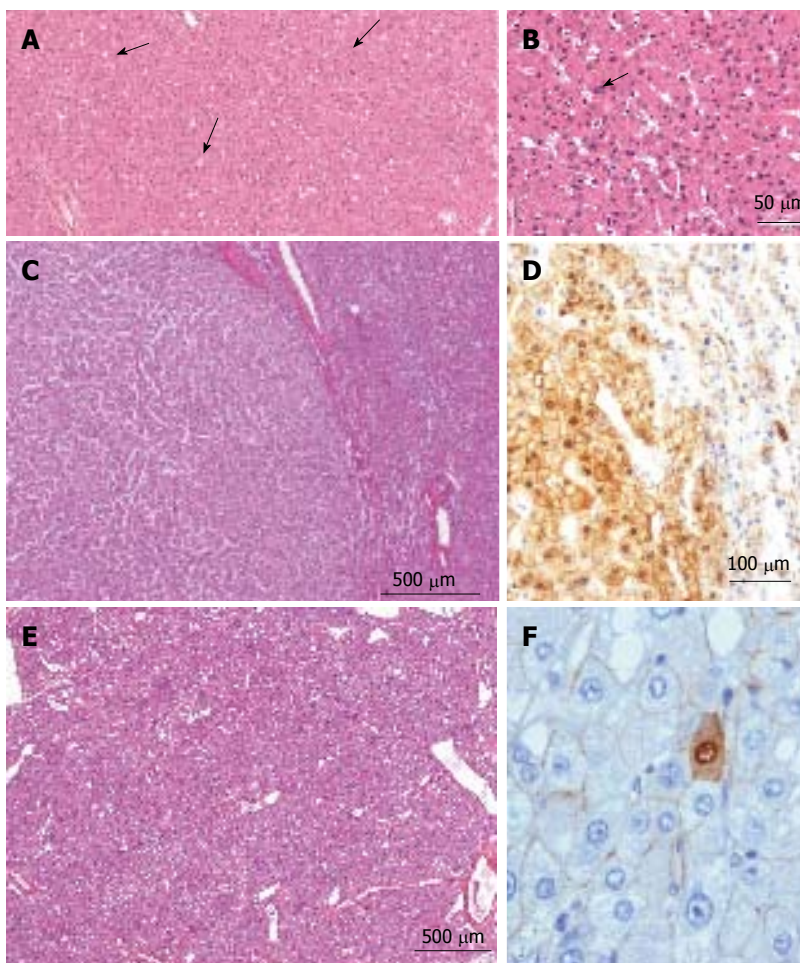


Figure 16 β -hepatocellular adenoma. A, B: Man, 16 years old under androgen treatment for a hematological disorder. Imaging: several nodules; tumorectomy of one nodule 3 cm. HE: Hepatocellular adenoma (HCA) with some glandular arrangements (arrowhead) and a few larger, irregular nuclei (arrow). According to the clinical context, the diagnosis of β -catenin is very likely. C, D: Woman born in 1953; oral contraceptives for 4 years. Danazol one year (endometriosis). BMI 19.5 kg/m². Asthenia. Imaging: one nodule 3 cm. Right hepatectomy in 1989. C: HE: Well limited HCA with no features of H-HCA, or of IHCA. By default, the diagnosis of β -catenin is therefore a possibility. D: Aberrant cytoplasmic and nuclear expression of β -catenin in numerous hepatocytes confirms the diagnosis of β -HCA; E, F: Woman born in 1980; oral contraceptives for 12 years. BMI 20.4 kg/m². Abdominal pain. Imaging: one nodule 15 cm: HCA. Right hepatectomy 2009. E: HE - numerous vessels within the HCA. This aspect seems to be quite characteristic of β -HCA and of some unclassified HCA; F: Aberrant expression of β -catenin in very few hepatocytes confirms the diagnosis of β -HCA.

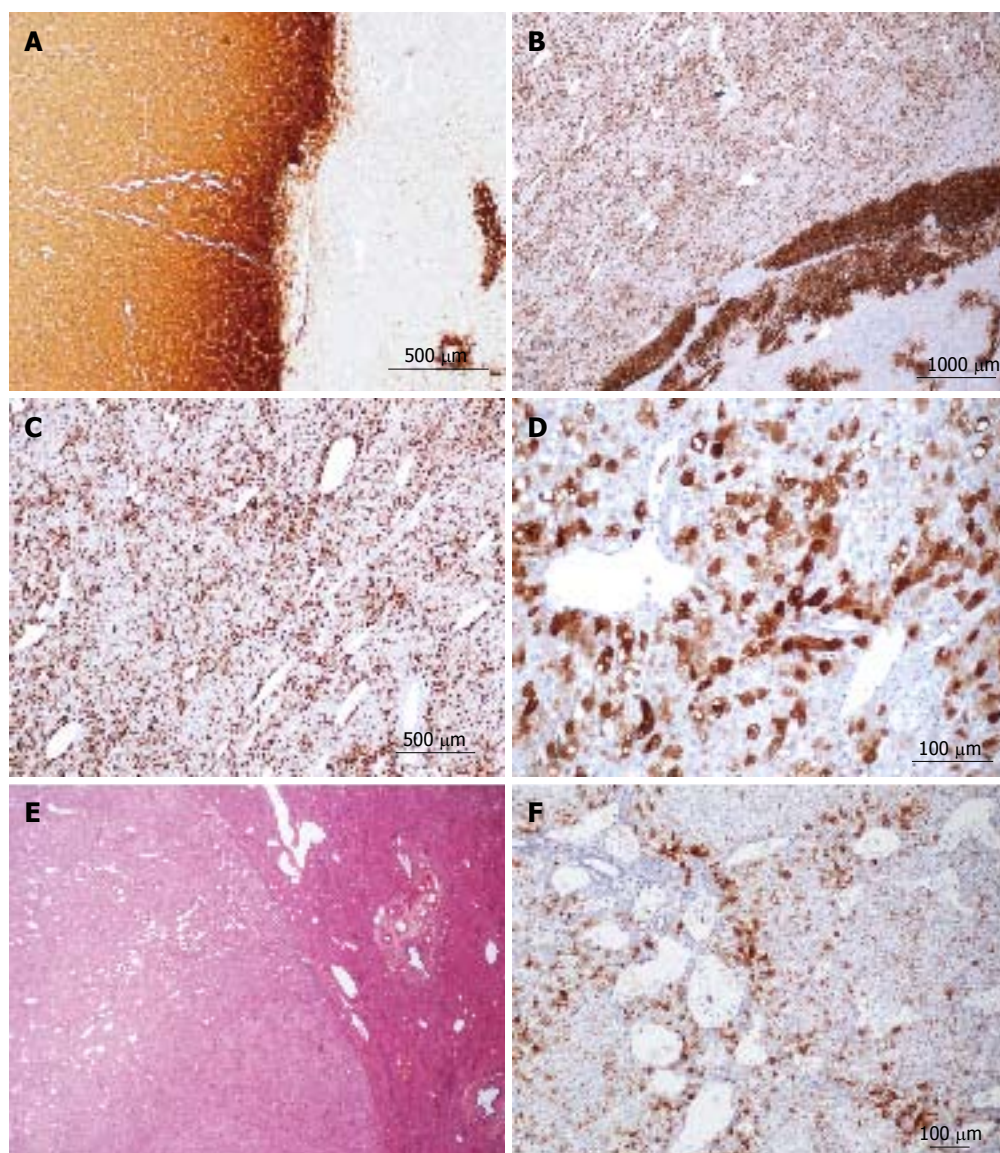
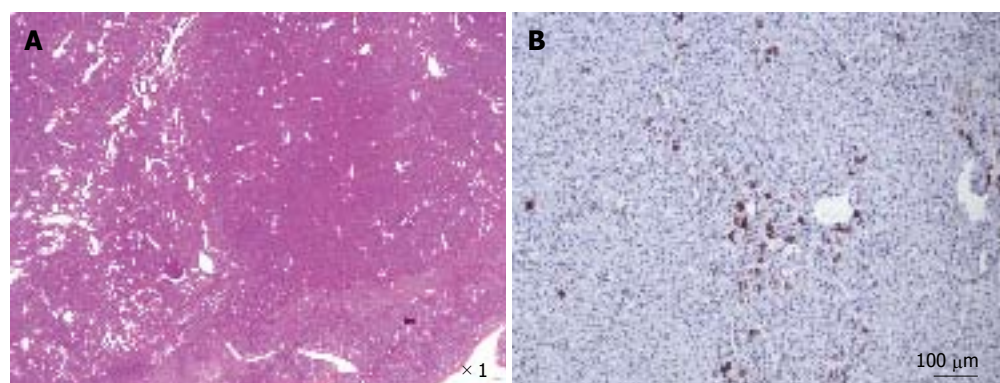


Figure 17 β -hepatocellular adenoma different types of glutamine synthase immunostaining. A: Same patient as Figure 16C, D. Strong and diffuse expression of glutamine synthase (GS) in hepatocellular adenoma (HCA) (left), contrasting with non tumoral liver (positivity in only few pericentrolobular hepatocytes). B-D: Same patient as Figure 16 E, F. Strong, heterogeneous (patchy) positivity of GS seen at different magnification, with a reinforcement rim at the periphery of the HCA (the rim positivity has no pathological significance). E, F: Woman born in 1986; abnormal liver function tests. Imaging: one nodule 9 cm, HCA. Left hepatectomy 2007. E: HE - no specific abnormalities. The presence of numerous vessels is, however, intriguing in this young patient. F: Patchy positivity of GS from mild to strong.



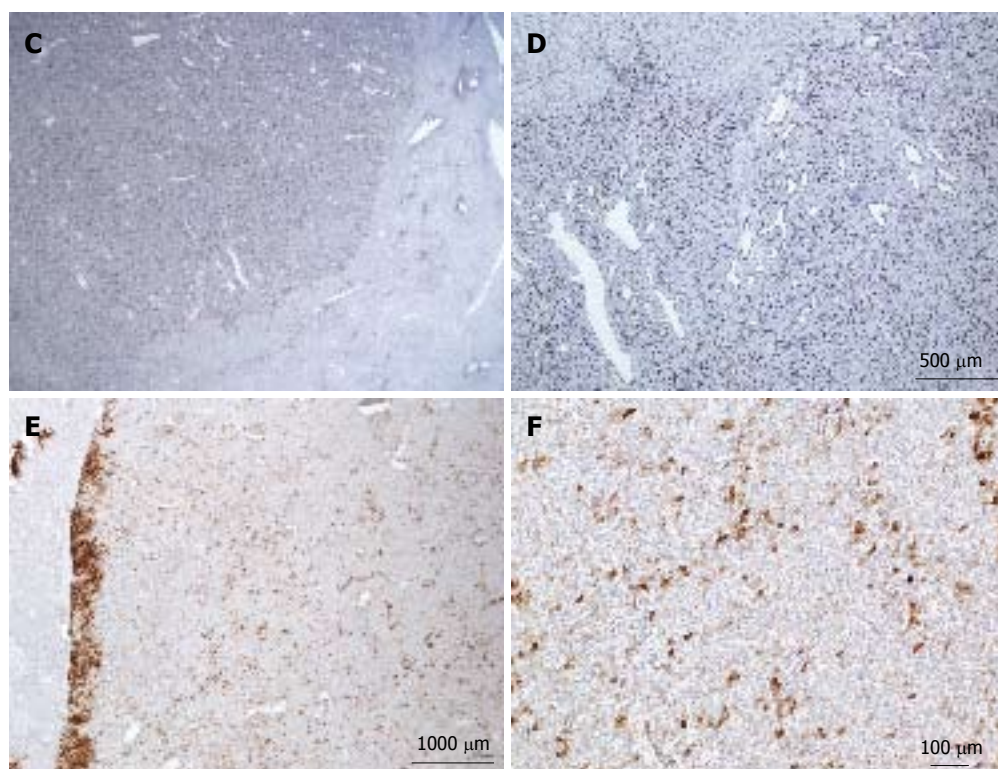
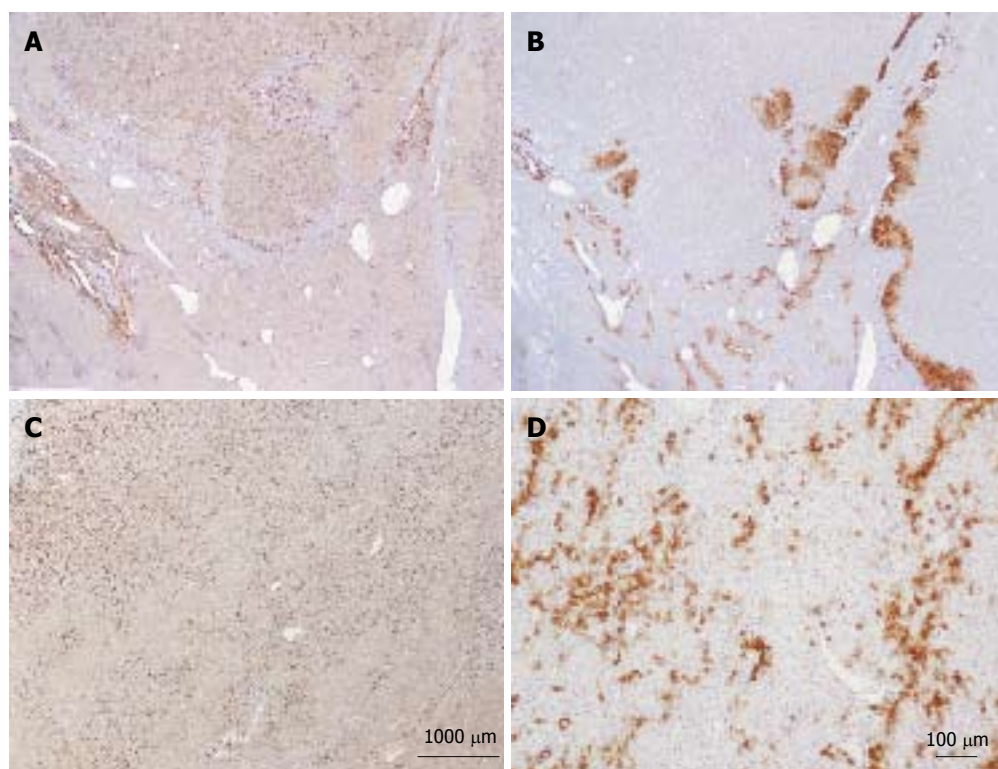


Figure 18 β -catenin hepatocellular adenoma. A, F: Same patient as Figure 5G. A: HE: Numerous vessels dispersed within the hepatocellular proliferation. B: Quite numerous CK7+ cells dispersed within the tumor; some are small, looking like progenitor cells; others are larger as intermediate cells. C, D: Diffuse positivity of CD 34 within the tumor. E, F: Patchy positivity of glutamine synthase.



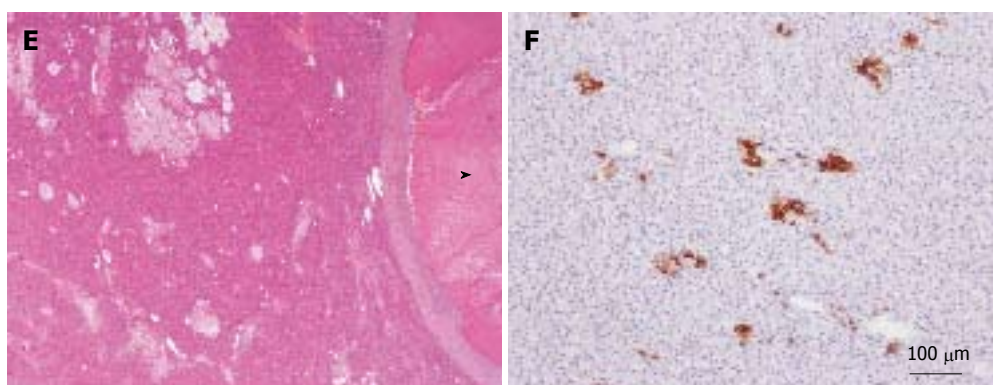


Figure 19 Unclassified hepatocellular adenoma. A, B: Woman born in 1988; oral contraceptives for 4 years. BMI 16.8. Abdominal pain. Imaging: one nodule 11 cm. No final diagnosis. Left hepatectomy 2009. A: Diffuse expression of CD34 in hepatocellular adenoma (HCA) (top) contrasting with adjacent non tumoral liver (below). B: No expression of glutamine synthase (GS) except at the periphery of the HCA. Here the nodule is divided in 2 parts at its periphery by a thin band of normal tissue containing vessels. C, D: Woman born in 1975; oral contraceptives for 12 years. BMI 24.2 kg/m². Hemorrhage. Imaging: one nodule 5 cm, HCA. Right hepatectomy 2003. C: Widespread but not diffuse expression of CD34 within the HCA. D: Numerous cells overexpressing CK7: small cells looking like progenitor cells and intermediate cells. GS was normal. E, F: Same patient as Figure 51. E: HE: thick fibrous rim around a necrotic area (arrowhead); peliotic areas within the viable HCA. F: Some small CK7 positive cells dispersed within the HCA. GS (not shown) was normal. CD34 staining was more or less diffuse (not shown).

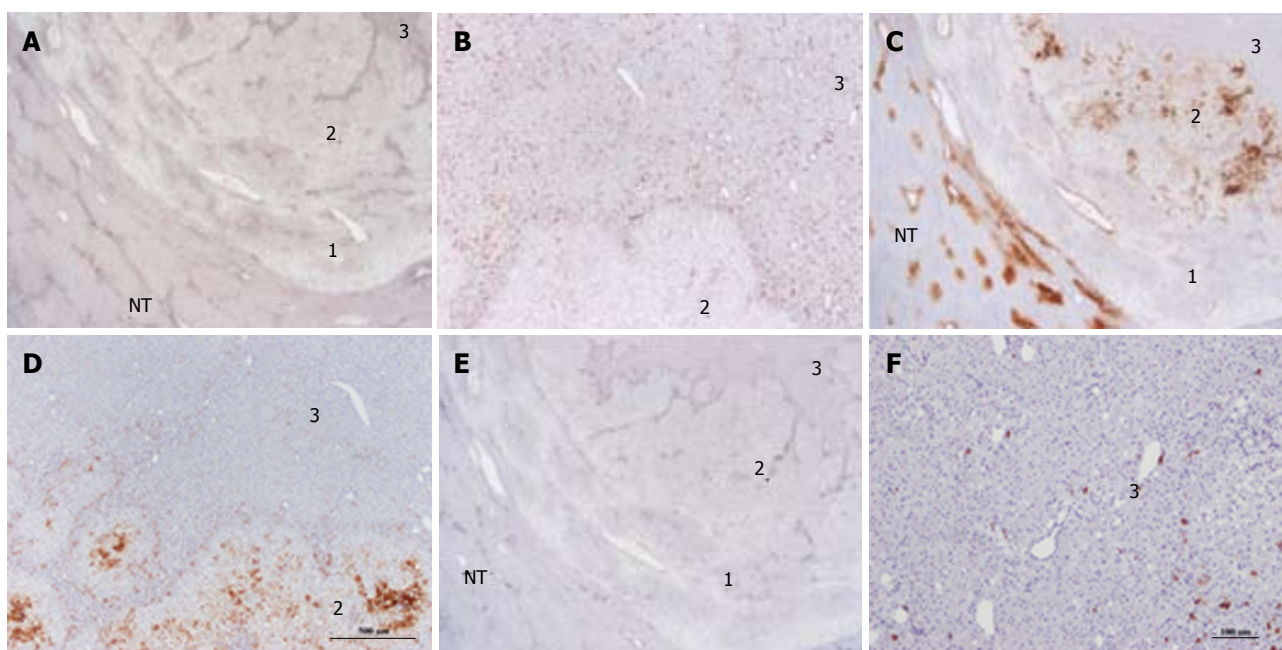


Figure 20 Unclassified hepatocellular adenoma. Woman born in 1980; oral contraceptives for 6 years. BMI 22.2 kg/m². Abdominal pain. Imaging: one nodule 3 cm, hepatocellular adenoma (HCA). Segmentectomy VI 2004. A, B: On CD34, three zones (1-3) are seen in this nodule. Zone 1 is the external limit of the nodule; zone 2 is intermediate and zone 3 represents the quasi totality of the nodule. Only zone 3 is diffusely positive. In zone 2, CD34 positivity is seen along vascular axis. C, D: Glutamine synthase (GS) staining: zone 3 is negative. Zone 1 is negative except around veins. In zone 2, GS staining is patchy. E, F: CK 7 - in zone 3, few cells, possibly progenitor cells are positive. In zone 2, positive cells are seen along vascular axis. This nodule has been classified as UHCA because all specific markers were negative. It is not rare to observe a thin peripheral rim which is CD34 negative /GS positive in unclassified HCA or β -HCA. In this case, the presence of 2 zones different from the bulk of the tumor remains unexplained but should not change the diagnosis.

different types of GS staining and Figure 18.

UHCA

UHCA are still poorly understood entities. However, their histological characteristics are worrisome and in many aspects in at least 50% of cases are reminiscent of β catenin HCA. Micrographs are presented in Figures 19 and 20.

REFERENCES

- 1 Goodman ZD, Terracciano LM, Wee A. Tumours and tumour-like lesions of the liver. In: Burt A, Portmann B, Ferrell L, editions. Philadelphia: McSween's Pathology of the liver, Churchill Livingstone Elsevier, 2012: 761-851
- 2 Lefkowitz JH. Neoplasms and nodules. In: Lefkowitz JH, edition. Scheuer's Liver biopsy interpretation. Philadelphia: Elsevier Saunders, 2010: 181-232
- 3 Bioulac-Sage P, Laumonier H, Balabaud C. Benign hepa-

- tocellular tumors. In: Saxena R, edition. Practical Hepatic Pathology: A Diagnostic Approach. Philadelphia: Elsevier Saunders, 2010: 473-488
- 4 **Bioulac-Sage P**, Balabaud C, Wanless I. Focal nodular hyperplasia and hepatocellular adenoma. In: Bosman F, Carneiro F, Hruban R, Theise ND, eds. Tumors of the Digestive Tract. Lyon, France: World Health Organization, IARC; 2010: 198-204
 - 5 **Bioulac-Sage P**, Cubel G, Balabaud C, Zucman-Rossi J. Revisiting the pathology of resected benign hepatocellular nodules using new immunohistochemical markers. *Semin Liver Dis* 2011; **31**: 91-103 [PMID: 21344354 DOI: 10.1055/s-0031-1272837]
 - 6 **Bioulac-Sage P**, Cubel G, Balabaud C. Pathological diagnosis of hepatocellular adenoma in clinical practice. *Diagnostic histopathology* 2011; **17**: 521-529
 - 7 **Bioulac-Sage P**, Balabaud C, Zucman-Rossi J. Subtype classification of hepatocellular adenoma. *Dig Surg* 2010; **27**: 39-45 [PMID: 20357450 DOI: 10.1159/000268406]
 - 8 **Nault JC**, Bioulac-Sage P, Zucman-Rossi J. Hepatocellular benign tumors-from molecular classification to personalized clinical care. *Gastroenterology* 2013; **144**: 888-902 [PMID: 23485860]
 - 9 **Bioulac-Sage P**, Balabaud C, Wanless IR. Diagnosis of focal nodular hyperplasia: not so easy. *Am J Surg Pathol* 2001; **25**: 1322-1325 [PMID: 11688469]
 - 10 **Bioulac-Sage P**, Balabaud C, Bedossa P, Scoazec JY, Chiche L, Dhillon AP, Ferrell L, Paradis V, Roskams T, Vilgrain V, Wanless IR, Zucman-Rossi J. Pathological diagnosis of liver cell adenoma and focal nodular hyperplasia: Bordeaux update. *J Hepatol* 2007; **46**: 521-527 [PMID: 17239484]
 - 11 **Bioulac-Sage P**, Laumonier H, Rullier A, Cubel G, Laurent C, Zucman-Rossi J, Balabaud C. Over-expression of glutamine synthetase in focal nodular hyperplasia: a novel easy diagnostic tool in surgical pathology. *Liver Int* 2009; **29**: 459-465 [PMID: 18803590 DOI: 10.1111/j.1478-3231.2008.01849.x]
 - 12 **Bioulac-Sage P**, Rebouissou S, Thomas C, Blanc JF, Saric J, Sa Cunha A, Rullier A, Cubel G, Couchy G, Imbeaud S, Balabaud C, Zucman-Rossi J. Hepatocellular adenoma subtype classification using molecular markers and immunohistochemistry. *Hepatology* 2007; **46**: 740-748 [PMID: 17663417]
 - 13 **Laumonier H**, Cailliez H, Balabaud C, Possenti L, Zucman-Rossi J, Bioulac-Sage P, Trillaud H. Role of contrast-enhanced sonography in differentiation of subtypes of hepatocellular adenoma: correlation with MRI findings. *AJR Am J Roentgenol* 2012; **199**: 341-348 [PMID: 22826395 DOI: 10.2214/AJR.11.7046]
 - 14 **Laumonier H**, Bioulac-Sage P, Laurent C, Zucman-Rossi J, Balabaud C, Trillaud H. Hepatocellular adenomas: magnetic resonance imaging features as a function of molecular pathological classification. *Hepatology* 2008; **48**: 808-818 [PMID: 18688875 DOI: 10.1002/hep.22417]
 - 15 **Bioulac-Sage P**, Taouji S, Le Bail B, Possenti L, Balabaud C. Value and limits of routine histology alone or combined with glutamine synthetase immunostaining in the diagnosis of hepatocellular adenoma subtypes on surgical specimens. *Int J Hepatol* 2013; **2013**: 417323 [PMID: 23509631 DOI: 10.1155/2013/417323]
 - 16 **Bioulac-Sage P**, Cubel G, Taouji S, Scoazec JY, Letteurtre E, Paradis V, Sturm N, Nhieu JT, Wendum D, Bancel B, Ramos J, Paraf F, Saint Paul MC, Michalak S, Fabre M, Guettier C, Le Bail B, Zucman-Rossi J, Balabaud C. Immunohistochemical markers on needle biopsies are helpful for the diagnosis of focal nodular hyperplasia and hepatocellular adenoma subtypes. *Am J Surg Pathol* 2012; **36**: 1691-1699 [PMID: 23060349 DOI: 10.1097/PAS.0b013e3182653ece.]
 - 17 **Zucman-Rossi J**, Jeannot E, Nhieu JT, Scoazec JY, Guettier C, Rebouissou S, Bacq Y, Letteurtre E, Paradis V, Michalak S, Wendum D, Chiche L, Fabre M, Mellottee L, Laurent C, Partensky C, Castaing D, Zafrani ES, Laurent-Puig P, Balabaud C, Bioulac-Sage P. Genotype-phenotype correlation in hepatocellular adenoma: new classification and relationship with HCC. *Hepatology* 2006; **43**: 515-524 [PMID: 16496320]
 - 18 **Farges O**, Dokmak S. Malignant transformation of liver adenoma: an analysis of the literature. *Dig Surg* 2010; **27**: 32-38 [PMID: 20357449 DOI: 10.1159/000268405]
 - 19 **Sa Cunha A**, Blanc JF, Lazaro E, Mellottee L, Le Bail B, Zucman-Rossi J, Balabaud C, Bioulac-Sage P. Inflammatory syndrome with liver adenomatosis: the beneficial effects of surgical management. *Gut* 2007; **56**: 307-309 [PMID: 17303609]
 - 20 **Bioulac-Sage P**, Laumonier H, Couchy G, Le Bail B, Sa Cunha A, Rullier A, Laurent C, Blanc JF, Cubel G, Trillaud H, Zucman-Rossi J, Balabaud C, Saric J. Hepatocellular adenoma management and phenotypic classification: the Bordeaux experience. *Hepatology* 2009; **50**: 481-489 [PMID: 19585623 DOI: 10.1002/hep.22995]
 - 21 **Bioulac-Sage P**, Taouji S, Possenti L, Balabaud C. Hepatocellular adenoma subtypes: the impact of overweight and obesity. *Liver Int* 2012; **32**: 1217-1221 [PMID: 22429502 DOI: 10.1111/j.1478-3231.2012.02786.x]
 - 22 **Bioulac-Sage P**, Balabaud C, Zucman-Rossi J. Will the pathomolecular classification of hepatocellular adenomas improve their clinical management? *J Hepatol* 2011; **55**: 8-10 [PMID: 21300118 DOI: 10.1016/j.jhep.2011.01.016]
 - 23 **Paradis V**, Benzekri A, Dargère D, Bièche I, Laurendeau I, Vilgrain V, Belghiti J, Vidaud M, Degott C, Bedossa P. Telangiectatic focal nodular hyperplasia: a variant of hepatocellular adenoma. *Gastroenterology* 2004; **126**: 1323-1329 [PMID: 15131793]
 - 24 **Bioulac-Sage P**, Rebouissou S, Sa Cunha A, Jeannot E, Lepreux S, Blanc JF, Blanché H, Le Bail B, Saric J, Laurent-Puig P, Balabaud C, Zucman-Rossi J. Clinical, morphologic, and molecular features defining so-called telangiectatic focal nodular hyperplasias of the liver. *Gastroenterology* 2005; **128**: 1211-1218 [PMID: 15887105]

P- Reviewer: Roncalli M, Xu R **S- Editor:** Gou SX **L- Editor:** A
E- Editor: Wu HL



Pancreatic neuroendocrine tumor accompanied with multiple liver metastases

Tomohide Hori, Kyoichi Takaori, Shinji Uemoto

Tomohide Hori, Kyoichi Takaori, Shinji Uemoto, Department of Hepato-Pancreato-Biliary and Transplant Surgery, Kyoto University Hospital, Kyoto 606-8507, Japan

Author contributions: Hori T wrote the paper; Takaori K and Uemoto S supervised this paper.

Correspondence to: Tomohide Hori, MD, PhD, Department of Hepato-Pancreato-Biliary and Transplant Surgery, Kyoto University Hospital, 54 Shogoin Kawara-cho, Sakyo-ku, Kyoto 606-8507, Japan. horit@kuhp.kyoto-u.ac.jp

Telephone: +81-75-7513651 Fax: +81-75-7513106

Received: April 18, 2014 Revised: June 25, 2014

Accepted: July 15, 2014

Published online: August 27, 2014

Abstract

Pancreatic neuroendocrine tumor (P-NET) is rare and slow-growing. Current classifications predict its prognosis and postoperative recurrence. Curative resection is ideal, although often difficult, because over 80% of patients have unresectable multiple liver metastases and extrahepatic metastasis. Aggressive surgery for liver metastases is important to improve survival. Aggressive or cytoreductive surgery for liver metastases is indicated to reduce hormone levels and improve symptoms and prognosis. Liver transplantation was originally conceived as an ideal therapy for unresectable liver metastases. Unfortunately, there is no clear consensus on the role and timing of surgery for primary tumor and liver metastases. Surgeons still face questions in deciding the best surgical scenario in patients with P-NET with unresectable liver metastases.

© 2014 Baishideng Publishing Group Inc. All rights reserved.

Key words: Gastroenteropancreatic neuroendocrine tumor; Pancreas; Liver metastasis; Liver surgery; Liver transplantation

Core tip: Pancreatic neuroendocrine tumor is rare. Current classifications predict its prognosis and postopera-

tive recurrence. Curative resection is often difficult, because over 80% of patients have unresectable multiple liver metastases and extrahepatic metastasis. Aggressive or cytoreductive surgery for liver metastases is indicated to reduce hormone levels and improve symptoms and prognosis. Liver transplantation was originally conceived as an ideal therapy for unresectable liver metastases. However, there is no clear consensus on the role and timing of surgery for primary tumor and liver metastases.

Hori T, Takaori K, Uemoto S. Pancreatic neuroendocrine tumor accompanied with multiple liver metastases. *World J Hepatol* 2014; 6(8): 596-600 Available from: URL: <http://www.wjgnet.com/1948-5182/full/v6/i8/596.htm> DOI: <http://dx.doi.org/10.4254/wjh.v6.i8.596>

INTRODUCTION

Pancreatic neuroendocrine tumor (P-NET) is a rare and slow-growing tumor^[1]. The American Joint Committee on Cancer stated a new TNM classification in 2009, based on tumor size, including direct invasion and lymphoid and distant metastases^[2]. In 2010, the World Health Organization categorized gastroenteropancreatic neuroendocrine tumor (GEP-NET) into three categories (G1, G2 and G3) based on histopathological differentiation, proliferation index (Ki-67), neuroendocrine biomarkers (such as chromogranin A and synaptophysin), hormonal behavior, tumor size, direct invasion, and distant metastasis^[3]. These classifications are useful for predicting the prognosis and postoperative recurrence^[1]. Curative resection is ideal for this slow-growing tumor^[1,4-6], and postoperative surveillance of at least 10 years is required, because long-term recurrence can occur after surgery^[1].

Curative surgery is often difficult, because over 80% of P-NET patients already have unresectable multiple liver metastases and extrahepatic metastasis^[1]. Some cur-

rent opinions suggest an expanded surgical indication for P-NET patients with liver metastases, because survival is improved^[1,6-9]. Aggressive surgery for liver metastases or cytoreductive surgery for over 90% of the visible tumors are important to improve survival^[6,9]. Cytoreductive surgery for liver metastases is indicated to reduce hormone levels and improve clinical symptoms and prognosis^[1,6,9]. Liver transplantation (LT) was originally conceived as an ideal therapy for unresectable liver metastases^[1,10].

Unfortunately, there is no clear consensus on the role and timing of surgery for primary tumor and liver metastases, although current reports refer to liver surgery including LT for unresectable liver metastases. Surgeons still face questions in deciding the best surgical scenario in patients with P-NET with unresectable liver metastases. Here, we reviewed previous studies about therapeutic strategies for P-NET, with our regretful case.

RESECTION OF PRIMARY TUMOR

Approximately half of P-NETs are nonfunctioning^[11], and tumors < 10-30 mm are not indications for surgery^[1,6]. Functional P-NET should be removed even if the tumor is < 10 mm^[1,6], because functional P-NET has malignant potential despite a small tumor size^[1]. Some factors, such as young age, hormonal function, and surgical resection, are important for overall survival^[6,12]. Seventy to ninety percent of enlarging P-NETs have malignant potential^[1], and the aim of surgery for primary nonfunctioning tumor is to avoid malignant change and subsequent distant metastasis^[6]. Although endoscopic ultrasonography with fine-needle aspiration biopsy is useful for determining the malignant potential and predicting prognosis^[13-15], there are no definitive criteria regarding whether P-NET should be removed or observed based on tumor size^[1,6]. Curative resection is considered as standard therapy in well-differentiated GEP-NET G1/G2 with a Ki-67 index of < 10%^[1,4]. Cytoreductive surgery for primary tumor is indicated to reduce hormone levels and improve clinical symptoms^[1,6,16], although the effects on prognosis are still controversial^[1,5]. Overall, surgery for primary tumor should be curative resection^[1,4-6], although palliative therapy may be indicated if there is a possibility of improvement of clinical symptoms, such as endocrine symptoms, oppression on surrounding organs by primary tumor, jaundice and oral passage disturbance^[6,17].

RESECTION OF LIVER METASTASES

Curative surgery is often difficult, because over 80% of P-NET patients already have unresectable multiple liver metastases and extrahepatic metastasis^[1]. Current opinions suggest extended surgical indications for P-NET patients with liver metastases, because survival is improved and P-NET is a slow-growing tumor^[1,6-9]. For liver metastasis without extrahepatic metastasis, standard/aggressive surgery is the first choice for well-differentiated P-NET categorized as GEP-NET G1/G2^[1,7,8]. Aggressive surgery for liver metastases and cytoreductive surgery for

> 90% of the visible tumors are important to improve survival^[6,9]. Cytoreductive surgery for liver metastases is indicated to reduce hormone levels and improve clinical symptoms and prognosis^[1,6,9].

LT FOR UNRESECTABLE LIVER METASTASES

LT was originally conceived as an ideal therapy for advanced hepatic malignancy, because it eliminates the liver tumors and the potential for recurrence in the liver remnant^[1,10]. LT for unresectable metastases has essentially been abandoned^[10]. Several attempts to implement this strategy between 1960 and the 1980s showed poor results, although LT for early hepatocellular carcinoma has been established^[18]. It is well known that highly selected P-NET patients with liver metastases may be candidates for LT^[10,19-21]. The only prospective study recommended strict selection criteria for LT with curative intent (*i.e.*, low grade, removal of primary tumor, liver involvement < 50%, age < 55 years, and stable disease for ≥ 6 mo before LT)^[21], and a study reported 96% overall survival and 80% disease-free survival^[22]. However, it was also reported that P-NET patients with liver metastases who received LT had a follow-up term of no longer than 5.8 years, and the longest tumor-free survival was 5.1 years^[23], and a high rate of tumor recurrence was reported at almost 60%^[20].

Use of LT for extended indications always presents an ethical dilemma^[10]. The United Network for Organ Sharing has generally held that LT for malignancy should be considered only when results are essentially equivalent to results with standard indications, generally requiring a 5-year survival rate of 60%-70%^[10]. LT in selected GEP-NET patients has shown a 5-year recurrence-rate as low as 30%^[21]. Previous results that indicate LT for P-NET^[20-22] must be interpreted cautiously^[10], especially given the global scarcity of liver grafts available^[10]. These results should not justify LT at this time^[10]. The Milan Criteria is maybe a better definition of selection criteria for LT^[21]. In the last decade, selection criteria based on clinical presentation have been integrated with a proper histopathologic classification and diagnostic techniques^[21]. In particular, Ki67 expression has been considered as a prognostic factor of risk of recurrence^[21,24-28]. A Ki67 proliferation index of < 10% is a characteristic of well-differentiated tumor, which we have adopted as a cut-off value to consider GEP-NET patients for LT candidates^[21,24]. Current studies suggest a growing consensus concerning LT for liver metastases of P-NET as follows^[20,24-28]: (1) liver metastases of symptomatic or asymptomatic P-NET are unresectable; (2) disease is confined to the liver, and extrahepatic metastases are ruled out; (3) LT is indicated for well-differentiated P-NET categorized as GEP-NET G1/G2. Poorly differentiated P-NET categorized as GEP-NET G3 is considered as a contraindication for LT. Ki67 index < 10% is recommended; and (4) LT should not be associated with major extrahepatic

resection. Primary tumor should be removed before LT.

As described above, primary tumor should be removed before LT. However, optimal timing for LT in patients with stable versus progressive disease remains unclear^[20]. In previous report, 83% of patients had undergone surgical treatment for primary tumor, and a 5-year overall survival has increased to 59% in relation with fewer patients presenting poor prognostic factors^[20]. Favorable outcomes in cases of unknown primary tumor might suggest that a failure to detect the primary tumor before LT should not be considered as an absolute contraindication^[20].

MANAGEMENT OF UNRESECTABLE LIVER METASTASES

For metastatic poorly-differentiated P-NET categorized as GEP-NET G3, cisplatin-based combination therapy is considered as the first-line therapy. Radiofrequency ablation, transarterial chemoembolization (TACE), transcatheter arterial infusion (TAI) and selective inhibitor of mammalian target of rapamycin are available as optional treatments^[1]. Systemic biotherapy, such as somatostatin analog and interferon- α , is indicated for functional P-NET and postoperative recurrence^[1].

Peptide receptor radionuclide therapy (PRRT) with radiolabeled somatostatin analogs is a novel treatment in patients with somatostatin receptor-expressing, well-differentiated and metastatic neuroendocrine tumors^[29-31], and the PRRT with yttrium and/or lutetium is a potent therapeutic approach. On the other hand, transarterial radioembolization [*i.e.*, selective internal radiotherapy (SIRT)] is an innovative therapy in liver-limited unresectable, neuroendocrine liver metastases^[32-34]. SIRT is an effective treatment option for patients with metastatic liver disease in a salvage setting with acceptable toxicity.

OUR REGRETFUL CASE

A 39-year-old man was diagnosed with nonfunctioning P-NET in the pancreatic head, with multiple liver metastases. The tumor was 2.5 cm in diameter, and was histopathologically well-differentiated with a Ki-67 expression of < 10%. He was asymptomatic. Small but multiple metastases were detected in the liver, and no extrahepatic metastases were observed. We initially intended to control the liver metastases before resection of the primary tumor. To begin with, TACE/TAI were repeated. Thereafter, TACE/TAI, systemic chemotherapies and biotherapies were repeated. Although liver metastases seemed to be stable for a while, the primary tumor was enlarged even after therapy. At 3.5 years after initial diagnosis, the primary tumor became symptomatic. Liver metastases enlarged and massive swelling of the para-aortic lymph nodes was observed. Thereafter, palliative therapy was the main course of action. He died at 4.3 years after initial diagnosis. We understand that P-NET patients often have unresectable liver metastases at initial diagnosis^[1],

and that surgical indications for P-NET with liver metastases should be determined individually in each case^[6]. Resection of the primary tumor in metastatic nonfunctioning P-NET patients with unresectable liver metastases does not significantly improve survival^[4]. Presence of liver metastases is a major prognostic factor for P-NET patients^[1,20], and surgical management of liver metastases remains controversial^[9]. In our case, we initially intended to control the liver metastases before resection of the primary tumor, because we considered liver metastases as the most important prognostic factor. Our decision at that time may have been consistent with previous opinions^[1,4,6,9,20]. However, in our case, aggressive surgery for liver metastases seemed to be difficult even during a period of stable liver metastases, and resection of primary tumor is required before LT. We retrospectively regret that aggressive surgery for primary tumor and subsequent LT for unresectable liver metastases may have provided a better course in our case.

DISCUSSION

Currently, classification of GEP-NET is useful for evaluating malignancy, predicting prognosis, and determining therapeutic strategies^[1,2]. Though this report focused surgical options for P-NET with liver metastases, novel managements (*i.e.*, PRRT and SIRT) are currently available for unresectable liver metastases, with acceptable side effects^[29-34]. Effective and beneficial treatment options for P-NET patients with liver metastases should be carefully considered. From the viewpoint of surgical option, surgical indications for primary tumor^[1,4-6,16] and hepatic surgery, including LT for liver metastases^[11,10,20,24-28] have already been stated. However, it seems to be not easy to decide optimal timing of surgery for primary tumor and liver metastases. Currently, surgical procedures and devices are well developed, and the question is whether pancreatoduodenectomy or distal pancreatectomy is risky. We believe that pancreatic surgery is safe and beneficial for patients, if indicated.

In LT for P-NET patients, previous excellent reports focused on a prognostic factors for overall survival, a post-transplant risk of recurrence, a better selection criteria, a difference between P-NET and others, and an importance of the post-transplant surveillance^[21,24,28]. There is a difference in behaviors between P-NET and the other tumors, the indication for LT for unresectable liver metastases is unique for P-NET^[21,24]. Also, an importance of careful surveillance after LT due to the risk of recurrence was documented^[21,24]. Tumor re-staging should be scheduled at least 4 times per year for the first two years and continued thereafter with progressively longer follow-up intervals^[21].

Though we understand that any decisions cannot be made based on a single patient experience, we retrospectively speculate that a negative approach to aggressive surgery for primary tumor may have resulted in poor quality of life and deprived patient of the opportunity of LT for unresectable liver metastases. P-NET patient with

liver metastases could have been a candidate for initial surgery for primary tumor and might have had a chance of subsequent LT for unresectable metastases. Surgeons still face questions in deciding the best surgical scenario in patients with P-NET with liver metastases.

REFERENCES

- Kimura W, Tezuka K, Hirai I. Surgical management of pancreatic neuroendocrine tumors. *Surg Today* 2011; **41**: 1332-1343 [PMID: 21922354 DOI: 10.1007/s00595-011-4547-6]
- International Union Against Cancer (UICC). TNM classification of malignant tumors. 7th ed. Sobin LH, Gospodarowicz MK, Wittekind C, editors. Oxford: Wiley-Blackwell (New York), 2009
- Heitz P, Komminoth P, Perren A, Klimstra D, Dayal Y. Tumors of the endocrine pancreas. In: De Lellis R, Lloyd R, Heitz P, Eng C, editors. World Health Organization classification of tumors: pathology and genetics of tumors of endocrine organs. 1st ed. Lyon: IARC Press, 2004: 177-182
- Bettini R, Mantovani W, Boninsegna L, Crippa S, Capelli P, Bassi C, Scarpa A, Pederzoli P, Falconi M. Primary tumour resection in metastatic nonfunctioning pancreatic endocrine carcinomas. *Dig Liver Dis* 2009; **41**: 49-55 [PMID: 18463008 DOI: 10.1016/j.dld.2008.03.015]
- Bloomston M, Muscarella P, Shah MH, Frankel WL, Al-Saif O, Martin EW, Ellison EC. Cytoreduction results in high perioperative mortality and decreased survival in patients undergoing pancreatectomy for neuroendocrine tumors of the pancreas. *J Gastrointest Surg* 2006; **10**: 1361-1370 [PMID: 17175455]
- Hanazaki K, Sakurai A, Munekage M, Ichikawa K, Nami-kawa T, Okabayashi T, Imamura M. Surgery for a gastroenteropancreatic neuroendocrine tumor (GEPNET) in multiple endocrine neoplasia type 1. *Surg Today* 2013; **43**: 229-236 [PMID: 23076685 DOI: 10.1007/s00595-012-0376-5]
- Touzios JG, Kiely JM, Pitt SC, Rilling WS, Quebbeman EJ, Wilson SD, Pitt HA. Neuroendocrine hepatic metastases: does aggressive management improve survival? *Ann Surg* 2005; **241**: 776-783; discussion 783-785 [PMID: 15849513 DOI: 10.1097/01.sla.0000161981.58631.ab]
- Norton JA, Warren RS, Kelly MG, Zuraek MB, Jensen RT. Aggressive surgery for metastatic liver neuroendocrine tumors. *Surgery* 2003; **134**: 1057-1063; discussion 1063-1065 [PMID: 14668741 DOI: 10.1016/j.surg.2003.07.025]
- Mayo SC, de Jong MC, Pulitano C, Clary BM, Reddy SK, Gamblin TC, Celinski SA, Kooby DA, Staley CA, Stokes JB, Chu CK, Ferrero A, Schulick RD, Choti MA, Mentha G, Strub J, Bauer TW, Adams RB, Aldrighetti L, Capussotti L, Pawlik TM. Surgical management of hepatic neuroendocrine tumor metastasis: results from an international multi-institutional analysis. *Ann Surg Oncol* 2010; **17**: 3129-3136 [PMID: 20585879 DOI: 10.1245/s10434-010-1154-5]
- Chapman WC. Liver transplantation for unresectable metastases to the liver: a new era in transplantation or a time for caution? *Ann Surg* 2013; **257**: 816-817 [PMID: 23532106 DOI: 10.1097/SLA.0b013e3182908c8d]
- Shibata C, Egawa S, Motoi F, Morikawa T, Naitoh T, Unno M, Sasaki I. Surgery for pancreatic neuroendocrine tumors. *Nihon Geka Gakkai Zasshi* 2012; **113**: 502-506 [PMID: 23330458]
- Kouvaraki MA, Shapiro SE, Cote GJ, Lee JE, Yao JC, Waguespack SG, Gagel RF, Evans DB, Perrier ND. Management of pancreatic endocrine tumors in multiple endocrine neoplasia type 1. *World J Surg* 2006; **30**: 643-653 [PMID: 16680581 DOI: 10.1007/s00268-006-0360-y]
- Patel KK, Kim MK. Neuroendocrine tumors of the pancreas: endoscopic diagnosis. *Curr Opin Gastroenterol* 2008; **24**: 638-642 [PMID: 19122508 DOI: 10.1097/MOG.0b013e32830bf7fb]
- Figueiredo FA, Giovannini M, Monges G, Bories E, Pesenti C, Caillol F, Delperio JR. EUS-FNA predicts 5-year survival in pancreatic endocrine tumors. *Gastrointest Endosc* 2009; **70**: 907-914 [PMID: 19640525 DOI: 10.1016/j.gie.2009.05.020]
- Chatzipantelis P, Konstantinou P, Kakkamanos M, Apostolou G, Salla C. The role of cytomorphology and proliferative activity in predicting biologic behavior of pancreatic neuroendocrine tumors: a study by endoscopic ultrasound-guided fine-needle aspiration cytology. *Cancer* 2009; **117**: 211-216 [PMID: 19350669 DOI: 10.1002/cncy.20025]
- McEntee GP, Nagorney DM, Kvols LK, Moertel CG, Grant CS. Cytoreductive hepatic surgery for neuroendocrine tumors. *Surgery* 1990; **108**: 1091-1096 [PMID: 1701060]
- Thompson NW. Current concepts in the surgical management of multiple endocrine neoplasia type 1 pancreaticoduodenal disease. Results in the treatment of 40 patients with Zollinger-Ellison syndrome, hypoglycaemia or both. *J Intern Med* 1998; **243**: 495-500 [PMID: 9681848 DOI: 10.1046/j.1365-2796.1998.00307.x]
- Mazzaferro V, Regalia E, Doci R, Andreola S, Pulvirenti A, Bozzetti F, Montalto F, Ammatuna M, Morabito A, Gennari L. Liver transplantation for the treatment of small hepatocellular carcinomas in patients with cirrhosis. *N Engl J Med* 1996; **334**: 693-699 [PMID: 8594428 DOI: 10.1056/NEJM199603143341104]
- Gottwald T, Köveker G, Büsing M, Lauchart W, Becker HD. Diagnosis and management of metastatic gastrinoma by multimodality treatment including liver transplantation: report of a case. *Surg Today* 1998; **28**: 551-558 [PMID: 9607910]
- Le Treut YP, Grégoire E, Klempnauer J, Belghiti J, Jouve E, Lerut J, Castaing D, Soubrane O, Boillot O, Manton G, Homayounfar K, Bustamante M, Azoulay D, Wolf P, Krawczyk M, Pascher A, Suc B, Chiche L, de Urbina JO, Mejlitz V, Pascual M, Lodge JP, Gruttaduria S, Paye F, Pruvot FR, Thorban S, Foss A, Adam R. Liver transplantation for neuroendocrine tumors in Europe-results and trends in patient selection: a 213-case European liver transplant registry study. *Ann Surg* 2013; **257**: 807-815 [PMID: 23532105 DOI: 10.1097/SLA.0b013e3182908c8d]
- Mazzaferro V, Pulvirenti A, Coppa J. Neuroendocrine tumors metastatic to the liver: how to select patients for liver transplantation? *J Hepatol* 2007; **47**: 460-466 [PMID: 17697723 DOI: 10.1016/j.jhep.2007.07.004]
- de Herder WW, Mazzaferro V, Tavecchio L, Wiedenmann B. Multidisciplinary approach for the treatment of neuroendocrine tumors. *Tumori* 2010; **96**: 833-846 [PMID: 21302641]
- Alessiani M, Tzakis A, Todo S, Demetris AJ, Fung JJ, Starzl TE. Assessment of five-year experience with abdominal organ cluster transplantation. *J Am Coll Surg* 1995; **180**: 1-9 [PMID: 8000645]
- Pavel M, Baudin E, Couvelard A, Krenning E, Öberg K, Steinmüller T, Anlauf M, Wiedenmann B, Salazar R. ENETS Consensus Guidelines for the management of patients with liver and other distant metastases from neuroendocrine neoplasms of foregut, midgut, hindgut, and unknown primary. *Neuroendocrinology* 2012; **95**: 157-176 [PMID: 22262022 DOI: 10.1159/000335597]
- Pascher A, Klupp J, Neuhaus P. Endocrine tumours of the gastrointestinal tract. Transplantation in the management of metastatic endocrine tumours. *Best Pract Res Clin Gastroenterol* 2005; **19**: 637-648 [PMID: 16183532 DOI: 10.1016/j.bpg.2005.03.008]
- Grégoire E, Le Treut YP. Liver transplantation for primary or secondary endocrine tumors. *Transpl Int* 2010; **23**: 704-711 [PMID: 20492617 DOI: 10.1111/j.1432-2277.2010.01110.x]
- Bonaccorsi-Riani E, Apestegui C, Jouret-Mourin A, Sempoux C, Goffette P, Ciccirelli O, Borbath I, Hubert C, Gigot JF, Hassoun Z, Lerut J. Liver transplantation and neuroendocrine tumors: lessons from a single centre experience and from the literature review. *Transpl Int* 2010; **23**: 668-678

- [PMID: 20478000 DOI: 10.1111/j.1432-2277.2010.01086.x]
- 28 **Rosenau J**, Bahr MJ, von Wasielewski R, Mengel M, Schmidt HH, Nashan B, Lang H, Klempnauer J, Manns MP, Boeker KH. Ki67, E-cadherin, and p53 as prognostic indicators of long-term outcome after liver transplantation for metastatic neuroendocrine tumors. *Transplantation* 2002; **73**: 386-394 [PMID: 11884935]
 - 29 **Delpassand ES**, Samarghandi A, Zamanian S, Wolin EM, Hamiditabar M, Espenan GD, Erion JL, O'Dorisio TM, Kvols LK, Simon J, Wolfangel R, Camp A, Krenning EP, Mojtahedi A. Peptide receptor radionuclide therapy with ¹⁷⁷Lu-DOT-ATATE for patients with somatostatin receptor-expressing neuroendocrine tumors: the first US phase 2 experience. *Pancreas* 2014; **43**: 518-525 [PMID: 24632546]
 - 30 **Sabet A**, Nagarajah J, Dogan AS, Biersack HJ, Sabet A, Gohlke S, Ezziddin S. Does PRRT with standard activities of ¹⁷⁷Lu-octreotate really achieve relevant somatostatin receptor saturation in target tumor lesions?: insights from intra-therapeutic receptor imaging in patients with metastatic gastroenteropancreatic neuroendocrine tumors. *EJNMMI Res* 2013; **3**: 82 [PMID: 24369053]
 - 31 **Frilling A**, Weber F, Saner F, Bockisch A, Hofmann M, Mueller-Brand J, Broelsch CE. Treatment with (90)Y- and (177)Lu-DOTATOC in patients with metastatic neuroendocrine tumors. *Surgery* 2006; **140**: 968-976; discussion 976-977 [PMID: 17188146]
 - 32 **Turkmen C**, Ucar A, Poyanli A, Vatankulu B, Ozkan G, Basaran M, Serin K, Sanli Y, Adalet I. Initial outcome after selective intraarterial radionuclide therapy with yttrium-90 microspheres as salvage therapy for unresectable metastatic liver disease. *Cancer Biother Radiopharm* 2013; **28**: 534-540 [PMID: 23647219]
 - 33 **Kucuk ON**, Soydal C, Lacin S, Ozkan E, Bilgic S. Selective intraarterial radionuclide therapy with Yttrium-90 (Y-90) microspheres for unresectable primary and metastatic liver tumors. *World J Surg Oncol* 2011; **9**: 86 [PMID: 21819613]
 - 34 **Kalinowski M**, Dressler M, König A, El-Sheik M, Rinke A, Höffken H, Gress TM, Arnold R, Klose KJ, Wagner HJ. Selective internal radiotherapy with Yttrium-90 microspheres for hepatic metastatic neuroendocrine tumors: a prospective single center study. *Digestion* 2009; **79**: 137-142 [PMID: 19307736]

P- Reviewer: Massironi S, Scherubl H **S- Editor:** Ji FF
L- Editor: A **E- Editor:** Wu HL



Assessing liver injury associated with antimycotics: Concise literature review and clues from data mining of the FAERS database

Emanuel Raschi, Elisabetta Poluzzi, Ariola Koci, Paolo Caraceni, Fabrizio De Ponti

Emanuel Raschi, Elisabetta Poluzzi, Ariola Koci, Paolo Caraceni, Fabrizio De Ponti, Pharmacology Unit, Department of Medical and Surgical Sciences, Alma Mater Studiorum, University of Bologna, I-40126 Bologna BO, Italy

Author contributions: Raschi E and De Ponti F conceived the study; Koci A extracted data and performed statistical analysis; Raschi E drafted the first version of the manuscript; Poluzzi E, Caraceni P and De Ponti F provided substantial contribution to the discussion; all authors provided comments to the first draft and approved the final version of the manuscript.

Correspondence to: Fabrizio De Ponti, MD, PhD, Pharmacology Unit, Department of Medical and Surgical Sciences, Alma Mater Studiorum, University of Bologna, Via Imerio, 48, I-40126 Bologna BO, Italy. fabrizio.deponti@unibo.it

Telephone: +39-051-2091805 Fax: +39-051-2091780

Received: February 10, 2014 Revised: March 26, 2014

Accepted: July 17, 2014

Published online: August 27, 2014

112 of acute liver failure). Eleven systemic antimycotics (including ketoconazole and the newer triazole derivatives voriconazole and posaconazole) and terbinafine (used systemically to treat onychomycosis) generated a significant disproportionality, indicating a post-marketing signal of risk.

CONCLUSION: Virtually all antimycotics with systemic action or absorption are commonly reported in clinically significant cases of DILI. Clinicians must be aware of this aspect and monitor patients in case switch is considered, especially in critical poly-treated patients under chronic treatment.

© 2014 Baishideng Publishing Group Inc. All rights reserved.

Key words: Drug-induced hepatotoxicity; Antimycotics; Drug safety; Pharmacovigilance; Spontaneous reporting systems

Abstract

AIM: To inform clinicians on the level of hepatotoxic risk among antimycotics in the post-marketing setting, following the marketing suspension of oral ketoconazole for drug-induced liver injury (DILI).

METHODS: The publicly available international FAERS database (2004-2011) was used to extract DILI cases (including acute liver failure events), where antimycotics with systemic use or potential systemic absorption were reported as suspect or interacting agents. The reporting pattern was analyzed by calculating the reporting odds ratio and corresponding 95%CI, a measure of disproportionality, with time-trend analysis where appropriate.

RESULTS: From 1687284 reports submitted over the 8-year period, 68115 regarded liver injury. Of these, 2.9% are related to antimycotics (1964 cases, of which

Core tip: The recent regulatory interventions (United States restriction and Europe suspension) concerning ketoconazole for drug-induced liver injury (DILI) poses a prescribing challenge to clinicians, who should now carefully consider safer therapeutic alternatives. Data mining of FAERS database (2004-2011) highlighted that: (1) antimycotics are involved in approximately 3% of DILI cases (including acute liver failure events); (2) virtually all systemic antimycotics (*e.g.*, azole derivatives), are associated with disproportionality signals; careful monitoring is therefore recommended, especially in critical poly-treated patients with multiple comorbidities; and (3) topical antimycotics, as expected, do not generate a post-marketing signal of DILI, thus indicating the accuracy of our approach.

Raschi E, Poluzzi E, Koci A, Caraceni P, De Ponti F. Assessing liver injury associated with antimycotics: Concise literature re-

view and clues from data mining of the FAERS database. *World J Hepatol* 2014; 6(8): 601-612 Available from: URL: <http://www.wjgnet.com/1948-5182/full/v6/i8/601.htm> DOI: <http://dx.doi.org/10.4254/wjh.v6.i8.601>

INTRODUCTION

Following the recent interest and regulatory measures on ketoconazole-related liver injury, the present manuscript provides: (1) a concise overview of the literature on drug-induced liver injury (DILI), namely a practical guide for clinicians to realize the need for active post-marketing vigilance; and (2) a case study on antimycotics, based on key results obtained from our original analysis of the international publicly available Food and Drug Administration (FDA) database, to advance the reporting pattern of DILI in the real-world practice. This approach can provide physicians with practical clues to assign the level of DILI risk among antimycotics.

Overview of DILI

Definition of DILI: Hepatotoxicity and DILI are interchangeable terms adopted by clinicians, researchers as well as drug developers to describe a broad spectrum of liver manifestations. Indeed, DILI can be defined as a liver injury induced by a drug or herbal medicinal products leading to liver test abnormalities or liver dysfunction with reasonable exclusion of other competing etiologies. More than 1100 medicines, natural products, vitamins, dietary supplements, recreational and illicit compounds have been reported to cause DILI, and the list is constantly growing. Antibiotics, anticonvulsants, and antidepressant therapy remain the commonest causes of DILI in the Western Hemisphere^[1]. Among others, tumor necrosis factor- α antagonists, fluoroquinolones, tyrosine kinase inhibitors, statins and food supplements are gaining appreciation^[2].

Issues in clinical practice: A number of classifications have been proposed to facilitate diagnoses and research in the field. From a pharmacological standpoint, DILI can be divided into “intrinsic” (*i.e.*, dose-related) and “idiosyncratic” (*i.e.*, dose-independent)^[3]; however, the validity of this classification remains controversial and debated^[4]. The term idiosyncratic was first used to identify a reaction occurring in susceptible individuals, usually associated with variable or prolonged latency (several weeks to 1 year) and generally unexpected on the basis of the pharmacological action of the drug. Idiosyncratic DILI is linked to the vast majority of compounds, although a common misconception of idiosyncratic DILI regards its non relation with the dose. As a matter of fact, recent data suggested that a daily dose > 50 mg (and especially when the dose exceeds 100 mg daily) for drugs with high lipophilicity undergoing extensive hepatic metabolism is associated with a higher risk of idiosyncratic DILI^[5-7]. The latest evidence revealed that (1) drugs which are sub-

strates of CYP enzymes would have the higher likelihood of causing DILI (which is dose-independent); (2) drugs which are cytochrome P450 (CYP) inhibitors would have the higher likelihood of generating DILI only when they are administered at a high daily dose; and (3) drugs which are CYP inducers are not observed to be associated with DILI^[8].

From a clinical standpoint, DILI can be classified into acute and chronic persistent (*i.e.*, evidence of continue liver injury after discontinuation of causative agent beyond 12 mo of follow-up). Paracetamol (acetaminophen in the United States) represents the leading cause of acute dose-dependent DILI. More precisely, an international DILI working group of clinicians and scientists developed uniform consensus criteria to standardize the phenotypes of DILI^[9]. Although liver enzymes such as transaminases lack specificity, liver injury in the context of DILI has been defined decades ago as an elevation in the serum concentration of alanine aminotransferase (ALT), conjugated bilirubin or alkaline phosphatase exceeding $2 \times$ the upper limit of normal (ULN)^[10]. The expert working group proposed a cut-off level of $5 \times$ ULN for ALT as better threshold to exclude clinically unimportant and self-limited drug-related hepatic events as well as nonalcoholic steatohepatitis not related to DILI.

The most common clinical presentations of DILI are hepatocellular, cholestatic and mixed, which should be defined on the basis of biochemical criteria. The R value is used for this purpose [$R = (ALT/ULN)/(ALP/ULN)$]; when $R \geq 5$ the pattern is considered hepatocellular, whereas if $R < 2$ is cholestatic. Usually, the damage induced by amoxicillin-clavulanate is considered to be cholestatic, as compared to the hepatocellular pattern caused by methotrexate.

Diagnosis is a major challenge for clinicians and is based on a combination of factors, which are influenced by the expertise: (1) exclusion of other causes that may elevate hepatic biochemical tests (*in primis* hepatitis viruses); (2) causality assessment methods, which may be based on expert opinion or on standardized liver-specific scoring instruments such as the Roussel Uclaf causality assessment method (RUCAM), endorsed by the Council of International Organization of Medical Sciences^[11]; and (3) the presence of a signature pattern indicative of a specific causative agent (*e.g.*, typical features of DILI by telithromycin include short latency and abrupt onset of fever, abdominal pain, and jaundice, sometimes with the presence of ascites even in cases that resolved)^[12]. In this context, a clinical research workshop took place to review and attempt to standardize the current nomenclature and terminology used in DILI research. Because DILI is a diagnosis of exclusion, selected elements of the medical history, laboratory tests, and previous reports were proposed to improve causality assessment^[13]. The role of liver biopsy is still controversial, especially histological features and their relationship with biochemical parameters, although a systematic approach has been recently proposed as a foundation to correlate DILI pathology with its causality and outcome^[14]. Efforts have been also

directed to identify a list of essential elements (minimum requirements) when submitting case reports for publication^[15]. Recently, a dedicated website was finally created as an aid for clinicians and researchers to quickly extract updated information on DILI (<http://livertox.nih.gov/>).

Issues in drug development: The regulatory impact of DILI is appreciably expanding, as demonstrated by the fact that specific Consortia have been established, especially in the United States, where the DILI Network was created in 2003 to prospectively identify a large number of patients with *bona fide* DILI that will allow for collection of epidemiological data and biological samples for future mechanistic studies^[16].

DILI has been a major cause of drug withdrawals, non approval and variegate regulatory actions in the past 50 years. In one study of 38 drugs withdrawn from the market between 1990 and 2006, 14 (37%) were related to hepatotoxicity^[17]. A more recent review highlighted that of the 25 safety-based withdrawals in Europe and United States, ten (40%) were for cardiovascular events and seven (28%) for gastrointestinal, primarily hepatic, adverse events. It is clear that the majority of these regulatory measures concerned rare events with delayed onset and were not predicted based on known pharmacological action^[18]. It is also remarkable that spontaneous reporting systems have been a primary source of information that mainly contributed to regulatory actions, especially for newly marketed drugs and events that are likely to be drug-induced.

From a historical perspective, in several circumstances, hepatotoxic agents were identified after being approved by regulators and marketed for some time; this was the case, for instance, of bromfenac (withdrawn 11 mo after its approval) and more recently troglitazone, which was marketed in 1997 and withdrawn worldwide in March 2000. In other cases, DILI led to non approval or interruption of late phases of drug development (*e.g.*, in 2006, the manufacturer of the oral anticoagulant ximelagatran withdrew a pending application to the FDA).

In this context, potential safety issues on DILI should be recognized as early as possible during drug development in order to accurately predict the actual risk in the post-marketing phase^[19]. There are currently a number of challenges and controversies in exploiting predictive pre-clinical studies, especially for animal models, where ethical issues pose important limitations^[20].

In line with the clinical situation, there are no specific biomarkers that may be used for optimal prediction of the risk. In fact, the frequency of asymptomatic rise in serum ALT in the pre-approval phase does not correlate *per se* with the frequency of symptomatic liver injury in the post-marketing period. The quest for highly predictive biomarkers has been underway for years and remains an ongoing challenge^[21]. Although some genetic associations (*e.g.*, flucloxacillin and HLA-B*5701) have been identified, the clinical utility of genetic polymorphisms associated with drug-specific DILI appears still limited^[1]. In addition, there are at least 3 groups of individuals

showing different pattern of hepatic response: tolerates (the vast majority of patients without significant changes in liver biochemical tests), susceptibles (showing progressive increase in ALT level that continues to increase and evolves into clinically significant liver damage with signs and symptoms) and adaptors (showing transient increase in enzyme levels, which eventually return to baseline despite continuation of the drug)^[19].

So far, regulatory authorities and drug developers have mainly relied on the so-called Hy's law or rule^[22], coined following Zimmerman's observations, to predict post-marketing risk of serious hepatic events and for making recommendations on whether treatment should be continued, stopped or its dose reduced, following biochemical abnormalities with the suspect drug. To define a clinical trial subject as a Hy's law case, the following components must be present: (1) ALT increase to a level ≥ 3 times ULN; (2) total bilirubin increase ≥ 2 times ULN; (3) no significant increase in ALP (initial Alp values does not reach 2 times ULN); and (4) no other cause is found to explain liver injury.

When the above criteria are met, Hy's rule predicts a mortality rate that can exceed 10%. In the last decade, two population-based studies further support the validity of this rule by demonstrating a mortality rate of 9%-12%^[23,24]. Based on the 2009 FDA guidance, finding two cases is considered highly predictive that the drug has the potential to cause severe DILI when given to a larger population^[25]. Thus, Hy's law calls for enhanced vigilance on the patient so that the drug is discontinued before the patient crosses the threshold of hepatotoxic irreversibility. The correct timing of discontinuation and the exact level of ALT elevation is still a matter of debate; an eight-fold increase from baseline is generally considered a standard cut-off, although even levels greater than 3 times the ULN may be sufficient if accompanied by additional symptoms. Given the importance of monitoring thousands of laboratory parameters during clinical phases, the eDISH method was developed to visualize, assess and summarize hepatic safety data during clinical trials^[26]. As regards causality assessment, pharmaceutical companies prefer to rely on a 3-category scale instead of using the 5-category scale adopted by the DILIN consortium or the RUCAM score^[19].

Antimycotics and DILI: clinical and regulatory aspects: The true incidence of DILI associated with antimycotics in the post-marketing phase challenges precise estimation, especially as compared to other antimicrobials^[27]. Previous studies, mostly based on data derived from clinical trials, reported a 2%-23% range, depending on the drug of interest and especially the severity of the disease^[28]. Clinical evidence on ketoconazole emerged in early 80', when 54 reports of alleged ketoconazole-induced liver injury submitted to the FDA from the time of initial marketing in 1980, of which 33 were labeled as likely. The incidence of symptomatic, potentially serious hepatic injury appeared to be very low, perhaps 1 in 15000 exposed individuals, whereas the incidence

of mild, asymptomatic, reversible elevations in serum transaminases has been estimated to be 5%-10%^[29]. Also García Rodríguez *et al.*^[30] found that ketoconazole was associated with significant risk. Very recently, a systematic review and meta-analysis documented an overall incidence of 3.6%-4.2%, which may be considered as common^[31]. Data on other antifungals such as terbinafine are more scant and mostly based on individual case reports^[32-34]. The latest population-based study in Taiwanese concluded that oral antifungal agents are associated with a low incidence of DILI, which may be fatal (especially in the elderly) and increased for longer treatment^[35].

On July 26th, 2013, the European Medicines Agency (EMA) and the FDA issued important safety announcements: the EMA's Committee on Medicinal Products for Human Use (CHMP) has recommended that the marketing authorisations of oral ketoconazole-containing medicines should be suspended throughout the European Union (the CHMP concluded that the risk of liver injury is greater than the benefits in treating fungal infections) (http://www.ema.europa.eu/ema/index.jsp?curl=pages/news_and_events/news/2013/07/news_detail_001855.jsp&mid=WC0b01ac058004d5c1), whereas the FDA limits usage of Nizoral® (ketoconazole) oral tablets due to potentially fatal liver injury and risk of drug interactions and adrenal gland problems (<http://www.fda.gov/drugs/drugsafety/ucm362415.htm>). The FDA has revised the Boxed Warning, added a strong recommendation against its use (contraindication) in patients with liver disease, and included new recommendations for assessing and monitoring patients for liver toxicity. The FDA has also approved a new patient Medication Guide containing information on the potential risks associated with Nizoral® tablets, which must be dispensed with every prescription for the drug. In the revised US drug label, indications for dermatophyte and *Candida* infections have been removed and the indications for treatment of blastomycosis, coccidioidomycosis, histoplasmosis, chromomycosis, and paracoccidioidomycosis have been retained only for patients in whom other antifungal treatments have failed or are not tolerated.

These regulatory measures were driven by the following reasons: (1) suspension of the drug in France (June 2011), which asked the EMA to carry out a full assessment of the benefit-risk balance of oral ketoconazole-containing medicines; (2) the incidence and severity of liver injury with oral ketoconazole were higher than with other antifungals; (3) reports of liver injury occurred early after starting treatment with recommended doses, and it was not possible to identify measures to adequately reduce this risk; and (4) the widespread off-label use of oral ketoconazole for treating patients with Cushing's syndrome; and (5) currently available alternative treatments are deemed to be safer.

Possible contribution of pharmacovigilance in DILI research: Pharmacovigilance, namely post-marketing phase of drug development, represents the mainstay to evaluate the safety of recently marketed drugs or to monitor high-priority adverse events^[36]. On one hand,

spontaneous reports and data mining of large spontaneous reporting systems still represent the traditional source for safety surveillance; on the other hand, exploiting electronic healthcare records. Both approaches are important and can be viewed to complement each other. However, it is a common opinion (corroborated by original research) that spontaneous reporting systems are more suited for newly approved drugs (as they aim at early signal detection) and rare events with suggestive drug-related component^[18]. It is noteworthy that the diagnostic potential of commonly applied signal-detection algorithms is reasonably efficient and accurate to discriminate true drug-event associations from those that are likely to be spurious^[37].

In this context, the aim of this study is to show that spontaneous reporting systems can contribute in characterizing the hepatotoxic potential of systemic antifungals. As a matter of fact, a recent systematic review highlighted that regulatory measures on drug risk (*e.g.*, dear doctor letters, safety warnings) may differently but substantially impact prescribers' attitudes, thus causing a switch towards therapeutic alternatives, perceived as safe^[38]. This could be the case for some systemic antifungals, especially following marketing suspension of oral ketoconazole, both in US and Europe, for risk of DILI.

MATERIALS AND METHODS

Data source

The publicly available international FDA Adverse Event Reporting System, now termed FAERS database (2004-2011), was used for data mining of DILI associated with antimycotics. FAERS serves as repository of potential adverse events and medication errors associated with chemical and biological agents spontaneously submitted by healthcare professionals, patients and manufacturers. Since 2003, more than 7 million reports have been accumulated into FAERS, with more than 700000 records entered in 2011. In the light of its large catchment area (including also European reports potentially related to serious events) and public availability (since 2004), FAERS plays a leading role in signal detection and characterization, especially for rare events with high drug-attributable risk such as torsade de pointes (TdP)^[39-41]. DILI shares different clinical, pharmacological and regulatory issues with TdP and, remarkably, the accuracy of FAERS to investigate DILI cases has been very recently demonstrated, especially as an important aid to systematically track emerging signals of DILI for newly marketed drug^[42].

Data selection and analysis

Data processing and management (*e.g.*, duplicate detection and removal, handling of missing data) were performed according to previous methodology, extensively described in a dedicated book chapter^[43]. In this study, main selection criteria regards the role code assigned to the drug (*i.e.*, only "Primary Suspect", "Secondary Suspect" or "Interacting", whereas cases where antimycotics were reported as "Concomitant" were not included) and information on age and gender (records with missing

Table 1 MedDRA preferred terms used to retrieve liver events in FAERS

| PT | Liver injury | Acute hepatic failure |
|---|--------------|-----------------------|
| Acute hepatic failure | | X |
| Alanine aminotransferase abnormal | X | |
| Alanine aminotransferase increased | X | |
| Ammonia increased | X | |
| Aspartate aminotransferase abnormal | X | |
| Aspartate aminotransferase increased | X | |
| Bilirubin conjugated increased | X | |
| Bilirubin urine | X | |
| Blood bilirubin abnormal | X | |
| Blood bilirubin increased | X | |
| Blood bilirubin unconjugated increased | X | |
| Cholestasis | X | |
| Coma hepatic | | X |
| Cytolytic hepatitis | X | |
| Hepatic encephalopathy | | X |
| Hepatic enzyme abnormal | X | |
| Hepatic enzyme increased | X | |
| Hepatic failure | | X |
| Hepatic function abnormal | X | |
| Hepatic necrosis | X | |
| Hepatitis | X | |
| Hepatitis acute | X | |
| Hepatitis cholestatic | X | |
| Hepatitis fulminant | | X |
| Hepatitis toxic | X | |
| Hepatocellular damage | X | |
| Hepatotoxicity | X | |
| Hyperammonaemia | X | |
| Hyperbilirubinaemia | X | |
| Jaundice | X | |
| Jaundice cholestatic | X | |
| Jaundice hepatocellular | X | |
| Liver function test abnormal | X | |
| Liver injury | X | |
| Liver transplant | | X |
| Mixed hepatocellular-cholestatic injury | X | |
| Subacute hepatic failure | X | |
| Transaminases abnormal | X | |
| Transaminases increased | X | |
| Urine bilirubin increased | X | |

PT: Preferred term of the MedDRA terminology. "X" indicates that the PT was used to define the liver event; MedDRA: Medical Dictionary for Regulatory Activities.

data in these fields were not considered). Drugs of interest were represented by antimycotics with systemic use, including those agents used for topical indications that may have systemic absorption (*e.g.*, terbinafine and griseofulvine). These compounds were mapped through an *ad hoc* created archive of drug names and converted into relevant active substances. Events of interest were selected according to a pre-specified search strategy (see below) and based on the standard MedDRA (Medical Dictionary for Regulatory Activities) terminology for codification.

Search strategy

In line with a previous multidisciplinary collaborative work^[44], a two-fold approach was carried out to identify any type of liver damage, namely acute and chronic injuries as well as acute liver failure events. To this aim, dif-

ferent MedDRA Preferred Terms (PTs) were identified to define two patterns of liver event with different severity and clinical implication: "liver injury" (LI, including both chronic and acute liver events) and "acute liver failure" (ALF, a severe liver injury potentially reversible in nature and with onset of encephalopathy^[45]) (Table 1). In order to assign a certain report to a precise group, at least one pre-specified PT should be present. A mutually exclusive approach was performed; a single case report of interest was classified only in one group based on the following priority: ALF>LI. Therefore, LI does not include cases with ALF; this allowed us the identification of a so-called "overall liver injury" (OLI).

Statistical analysis

Description of the overall number of cases was first provided, both in terms of ALF, LI and OLI; demographic information (age and gender) were also analysed. Then, a case/non case disproportionality approach was carried out by calculating the Reporting Odds Ratio (ROR) with relevant Confidential Interval (CI). Statistically significant disproportionality was formally defined when the lower limit of the 95%CI was > 1, with at least 3 cases^[46]. Cases were represented by reports of DILI according the aforementioned pre-specified MedDRA PTs, whereas non cases were defined as all other reports (*i.e.*, those without such PTs). The ROR was first calculated by comparing a given antimycotic against all remaining drugs recorded in the entire FAERS database (*i.e.*, comprising all spontaneous reports from all drugs), by considering ALF and LI both separately and cumulatively (*i.e.*, by providing the ROR for OLI). Finally, where appropriate, the ROR was calculated within antimycotics by using a subset of data (*i.e.*, reports associated only with antimycotics). Restricting the analysis among agents belonging to the same pharmaco-therapeutic class may be useful as a sensitivity approach to test whether any potential intraclass differences exist in terms of risk. Cumulative time-trend disproportionality analysis was also performed, when appropriate^[47].

RESULTS

Over the 8-year period, 2612807 reports with at least one mapped active substance were processed; in 3.4% of these, at least one pre-selected PT of interest was recorded. The precise allocation of reports is provided in Figure 1, according to case definition and drugs of interest. Based on our selection criteria, 68,115 DILI cases (OLI) were identified, corresponding to 4% of overall FAERS reports; the majority (91.7%) regarded LI. Antimycotics were reported in 3% of LI and 2% of ALF cases.

In the entire FAERS database, 52% of cases of DILI occurred in females, whereas only in 44% of cases associated with antimycotics female gender was recorded. The analysis on age distribution showed a peak occurring in patients with 50-60 years of age (all FAERS database, no matter the drug under scrutiny), both for ALF and LI; only 26% and 27% of DILI cases occurred in patients

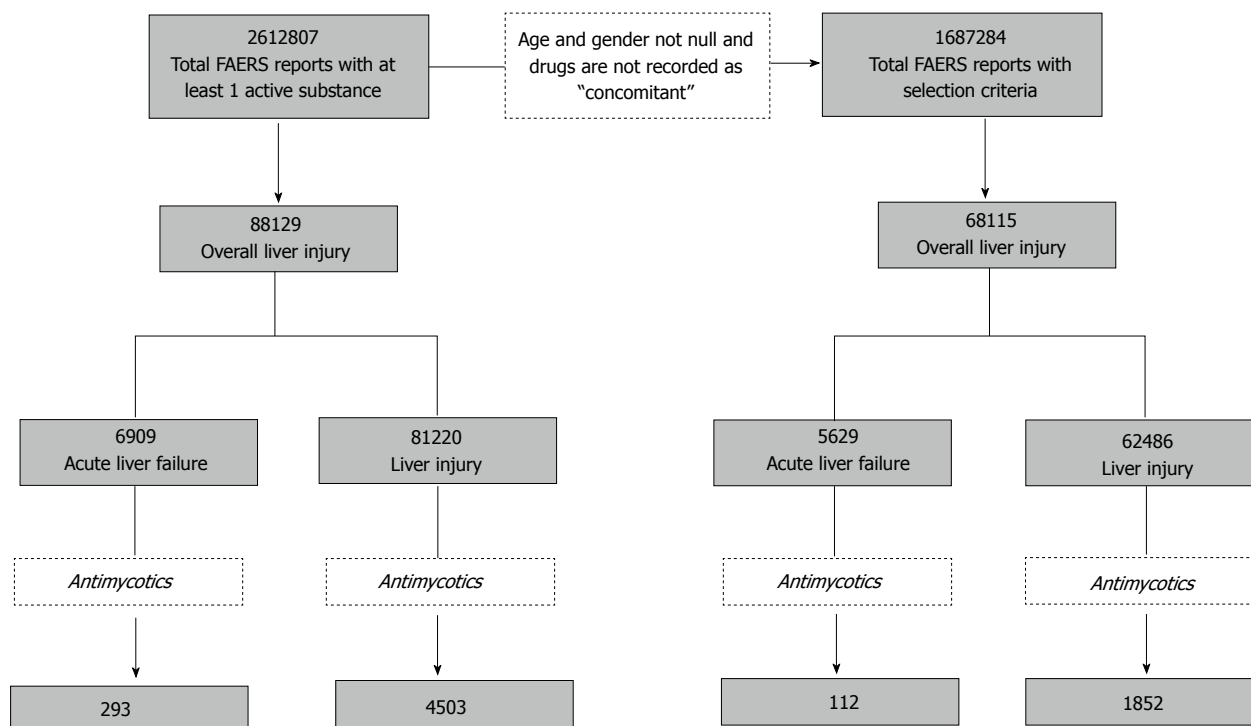


Figure 1 Flowchart describing data-mining approach to allocate cases of interest according to selection criteria and case definition.

Table 2 Top-10 drugs ranked in FAERS according to their reporting frequency for overall liver injury

| ATC code | Active substance | Cases LI | Cases ALF | Cases OLI | ROR (95%CI) LI | ROR (95%CI) ALF | ROR (95%CI) OLI |
|----------|-----------------------------|----------|-----------|-----------|--------------------------------|----------------------------------|-------------------------------|
| N02BE01 | Paracetamol | 2780 | 645 | 3425 | 3.69 (3.54-3.84) ¹ | 9.58 (8.82-10.41) ¹ | 4.31 (4.16-4.48) ¹ |
| C10AA05 | Atorvastatin | 1763 | 131 | 1894 | 3.46 (3.29-3.64) ¹ | 2.62 (2.20-3.12) ¹ | 3.43 (3.27-3.60) ¹ |
| C10AA01 | Simvastatin | 1516 | 80 | 1596 | 2.62 (2.49-2.77) ¹ | 1.44 (1.15-1.80) ¹ | 2.54 (2.41-2.67) ¹ |
| N06AX21 | Duloxetine | 1456 | 59 | 1515 | 3.34 (3.15-3.53) ¹ | 1.42 (1.10-1.83) ¹ | 3.32 (3.14-3.50) ¹ |
| L03AB07 | Interferon beta-1 | 1377 | 46 | 1423 | 0.73 (0.70-0.78) | 0.27 (0.20-0.36) | 0.69 (0.66-0.73) |
| J05AF05 | Lamivudine | 1162 | 130 | 1292 | 4.68 (4.40-4.98) ¹ | 5.22 (4.38-6.22) ¹ | 4.86 (4.57-5.16) ¹ |
| L01BA01 | Methotrexate | 1200 | 86 | 1286 | 2.89 (2.72-3.07) ¹ | 2.15 (1.74-2.66) ¹ | 2.85 (2.69-3.02) ¹ |
| J01CR02 | Amoxicillin/clavulanic acid | 1164 | 94 | 1258 | 5.86 (5.49-11.36) ¹ | 4.50 (3.67-5.53) ¹ | 5.89 (5.54-6.27) ¹ |
| C02KX01 | Bosentan | 1177 | 49 | 1226 | 9.53 (8.91-10.19) ¹ | 3.35 (3.53-4.45) ¹ | 9.20 (8.61-9.83) ¹ |
| L01XE05 | Sorafenib | 920 | 271 | 1191 | 4.98 (4.64-5.35) ¹ | 15.39 (13.58-17.44) ¹ | 6.22 (5.83-6.63) ¹ |

¹Statistically significant disproportionality (Lower limit 95%CI > 1). ATC: Anatomical therapeutic chemical classification; ALF: Acute liver failure; LI: Liver injury; OLI: Overall liver injury; ROR: Reporting odds ratio.

aged > 65 years (ALF and LI, respectively). Concerning antimycotics, a peak was found for patients aged 60 (number of OLI cases = 48), with only 30% of OLI cases occurring in subjects aged > 65 years. The analysis on the outcome of the events revealed that: (1) in the entire FAERS database, death was recorded in 37% and 17% of cases, whereas hospitalization or life-threatening conditions were reported in 52% and 49% of cases (ALF and LI, respectively); and (2) as regards antimycotics, death occurred in 51% and 24% of events, hospitalization or life-threatening conditions in 39% and 47% of events (ALF and LI, respectively).

As a first screening to test the sensitivity of the approach in detecting drug-event associations, we generated a list of top-10 drugs based on their reporting frequency for DILI (Table 2). Paracetamol ranked first both for ALF and LI and also generated statistically significant

disproportionality; it was followed by a number of drugs with known hepatotoxic potential such as statins, duloxetine, amoxicillin clavulanate, bosentan. Except for interferon, all these agents showed statistically significant ROR. Sorafenib ranked second in terms of ALF.

The analysis on antimycotics revealed a total of 1964 DILI cases; 35% were submitted by European Countries, 21% by Japan and 18% by United States. Terbinafine ranked first in terms of number of cases (422), followed by fluconazole and voriconazole (Table 3). Except griseofulvin, and miconazole, all remaining compounds generated a significant disproportion for ALF or LI or OLI. The intraclass analysis on OLI among azole-derivate agents showed the following ranking: ketoconazole (ROR = 1.70; 95%CI: 1.34-2.15) > voriconazole (1.47; 1.29-1.68) > posaconazole (1.36; 1.04-1.77) > fluconazole > itraconazole > miconazole (no statistical significance obtained).

Table 3 Key results of drug-induced liver injury associated with antimycotics: Number of cases with relevant disproportionality analyses

| Pharmacological class | Active substance | Cases LI | Cases ALF | Cases OLI | ROR (95%CI) LI | ROR (95%CI) ALF | ROR (95%CI) OLI |
|--|---------------------------|----------|-----------|-----------|--------------------------------|-------------------------------|-------------------------------|
| Antibiotics | Amphotericin B | 251 | 14 | 265 | 5.33 (4.65-6.10) ¹ | 2.86 (1.69-4.84) ¹ | 5.20 (4.55-5.94) ¹ |
| Imidazole derivatives | Miconazole ² | 16 | - | 16 | 0.33 (0.20-0.54) | - | 0.30 (0.18-0.50) |
| | Ketoconazole ² | 88 | 6 | 94 | 6.68 (5.28-8.44) ¹ | 4.22 (1.88-9.45) ¹ | 6.64 (5.28-8.34) ¹ |
| Triazole derivatives | Fluconazole | 381 | 31 | 412 | 4.25 (3.81-4.74) ¹ | 3.46 (2.42-4.93) ¹ | 4.26 (3.83-4.73) ¹ |
| | Itraconazole | 178 | 4 | 182 | 3.73 (3.19-4.37) ¹ | 0.84 (0.32-2.25) | 3.50 (2.99-4.09) ¹ |
| | Voriconazole | 342 | 19 | 361 | 5.61 (4.99-6.31) ¹ | 2.97 (1.89-4.67) ¹ | 5.48 (4.89-6.14) ¹ |
| | Posaconazole | 65 | 5 | 70 | 5.39 (4.12-7.04) ¹ | 4.00 (1.65-9.66) ¹ | 5.39 (4.16-6.99) ¹ |
| Other antimycotics for systemic use | Flucytosine | 6 | - | 6 | 3.06 (1.31-7.13) ¹ | - | 2.80 (1.20-6.52) ¹ |
| | Caspofungin | 161 | 7 | 168 | 7.03 (5.90-7.37) ¹ | 2.79 (1.32-5.87) ¹ | 6.78 (5.71-8.05) ¹ |
| | Micafungin | 48 | 2 | 50 | 6.90 (5.02-9.49) ¹ | - | 6.64 (4.86-9.09) ¹ |
| | Anidulafungin | 13 | 1 | 14 | 4.97 (2.75-9.00) ¹ | - | 4.97 (2.79-8.84) ¹ |
| Antimycotics used for topical indications (dermatological use) with systemic absorption | Griseofulvin ³ | 3 | - | 3 | 2.00 (0.62-6.47) | - | 1.83 (0.57-5.92) |
| | Terbinafine ³ | 395 | 27 | 422 | 5.11 (4.58-5.69) ¹ | 3.39 (2.32-4.96) ¹ | 5.06 (4.55-5.62) ¹ |
| | | | | | | | |
| Antimycotics for topical use with potential systemic absorption (e.g., gynecological and intestinal use) | Nystatin | 12 | - | 12 | 2.01 (1.12-3.62) ¹ | - | 1.84 (1.02-3.31) ¹ |
| | Econazole | 6 | - | 6 | 3.25 (1.39-7.60) ¹ | - | 2.97 (1.27-6.94) ¹ |
| | Ciclopirox | 3 | - | 3 | 3.39 (1.02-11.30) ¹ | - | 3.10 (0.93-10.33) |

Only agents with at least three cases for the event of interest are shown (*i.e.*, those for which disproportionality can be calculated). ¹Statistically significant disproportionality (Lower limit 95%CI > 1); ²Frequent topical use; ³Also topical use. ALF: Acute liver failure; LI: Liver injury; OLI: Overall liver injury; ROR: Reporting odds ratio.

The time-trend cumulative analysis of the ROR (performed on the two most recently marketed compounds and ketoconazole, the only antimycotic receiving recent regulatory intervention on DILI) showed that: (1) ketoconazole reached significant ROR in the first quarter of 2005 (*i.e.*, well before the recent safety measure); (2) posaconazole (marketed in October 2005 by EMA and in September 2006 by the FDA) showed significant disproportion in the second quarter of 2005 (*i.e.*, before its actual marketing approval), which persisted throughout the period of analysis, although fluctuations were recorded during the first 2-year period; and (3) voriconazole (marketed in March 2002 by EMA and May 2002 by FDA) showed significant disproportion in the second quarter of 2002, a striking correspondence with its regulatory approval (Figure 2).

DISCUSSION

This study shows that virtually all antimycotics for systemic use are associated with clinically significant risk of DILI in the post-marketing setting, where comorbidities and poly-pharmacotherapy exist. Although the summary of product characteristics of all highlighted compounds and the livertox database already addressed this safety issue (*e.g.*, by mentioning liver monitoring in the warning section), clinicians should be aware of this aspect, especially following the marketing suspension of oral ketoconazole. This means that switching prescription towards therapeutic alternatives of ketoconazole does not sufficiently protect patients from risk and active vigilance is still needed.

Although actual incidence cannot be inferred from

spontaneous reporting systems, the fact that antimycotics are reported in approx 3% of the total cases in FAERS suggests that the risk could be common. Our study also confirmed that miconazole and griseofulvin are not associated with clinically significant risk of DILI, a finding in line with recent data from EU-ADR and OMOP Consortia (Europe and United States projects, respectively), which labeled these drugs as “negative controls” in drug safety studies investigating DILI, based on the existing scientific literature and expert opinion^[48,49]. As a matter of fact, miconazole is mainly used as topical preparation, whereas griseofulvin has specific tropism for keratin tissues with only low plasma concentrations. This kinetic features could explain the lack of a signal of liver injury. On the other hand, one recent population-based study in Taiwanese detected 8 cases of DILI associated with griseofulvin, although the cumulative exposure dose and the concomitant co-prescription of antibiotics and anti-inflammatory drugs (which have hepatotoxic potential) may have contributed to the occurrence of liver events^[35].

Clinicians should interpret our data in the light of limitations affecting pharmacovigilance data. In particular, apart from well-described bias inherent to all spontaneous reporting systems (*e.g.*, underreporting, causality assessment, influence of media attention/safety alerts^[50]), it should be kept in mind that these analyses, although formally quantitative, do not allow firm quantification of risk, especially because the role of concomitant drugs as culprit agents in the occurrence of the event cannot be ruled out with certainty. However, they allow early identification of alert signals, which require further confirmation through pharmacoepidemiological approaches. In our case, the evaluation of “old” drugs may be useful to

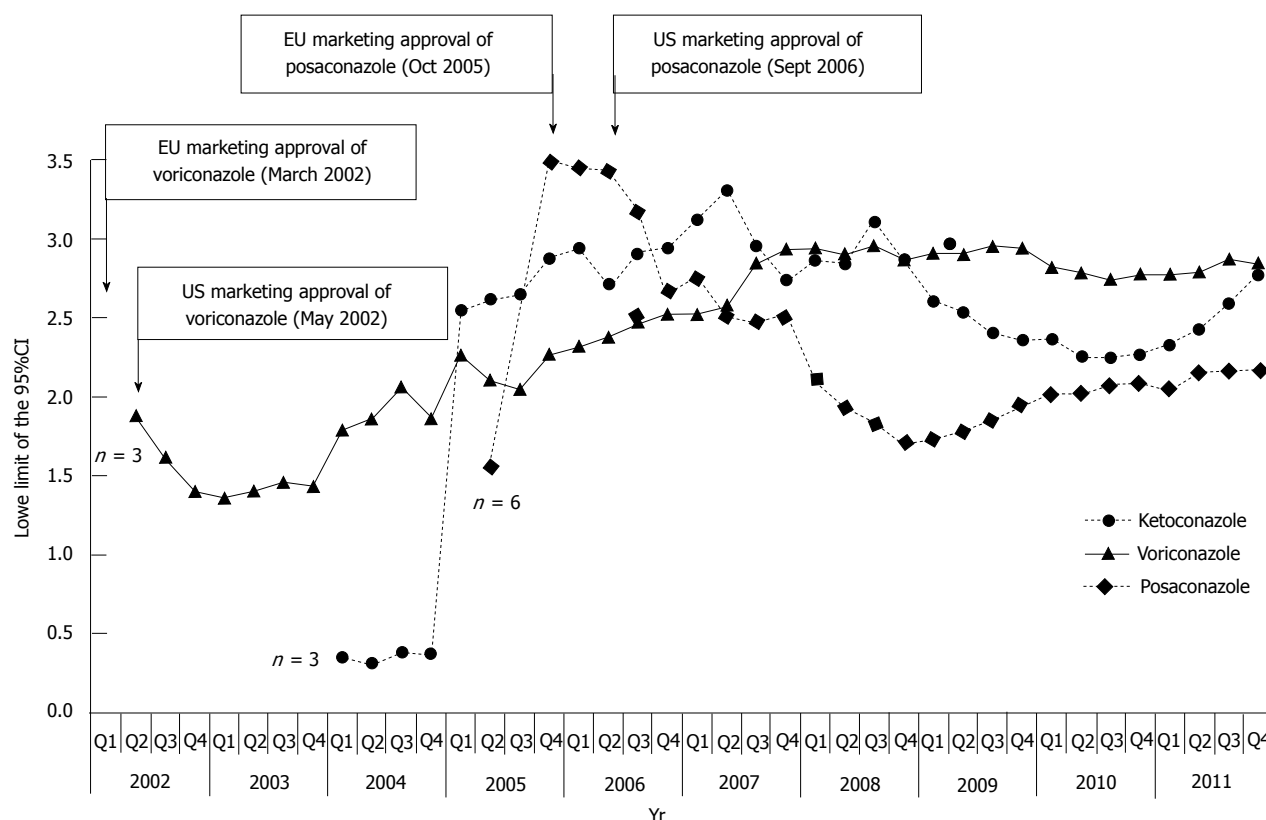


Figure 2 Cumulative time trend analysis of disproportionality (*i.e.*, lower limit of 95%CI) on overall liver injury for ketoconazole (recently restricted/suspended), voriconazole and posaconazole (the most recent antimycotics receiving marketing authorization in United States and Europe). Relevant regulatory milestones (*i.e.*, marketing approvals) are indicated by arrows. The total number of cases is also indicated when disproportionality was calculated for the first time (the first point of the lower limit of the 95%CI is provided when at least 3 cases of interest were recorded); EU: Europe; US: United states.

understand the reporting pattern over time and contribute to the general picture of perceived risk in a consolidated clinical setting. In any case, it should be recognized that DILI cases cannot be fully validated and precisely classified because laboratory values and liver biopsy are not available.

Nonetheless, our analysis has some strengths which can be summarized as follows. First, the validity of FAERS in early detection of DILI risk has been recently shown in a study allowing discrimination of a broad range of hepatotoxic drugs with clinically significant serious DILI, including those with only clinically apparent risk (*e.g.*, amlodipine)^[42]. In this context, our top-10 ranking drugs have already known hepatotoxic risk (*e.g.*, paracetamol), a finding in line with similar pharmacovigilance study recently performed on Vigibase^[44], and can be considered our positive controls. Second, it should be noticed that: (1) sorafenib (a novel tyrosine kinase inhibitor for which liver toxicity is under scrutiny and requires diligent surveillance^[51]) is ranked second in terms of ALF (after paracetamol); and (2) in our analysis, voriconazole and posaconazole are associated with significant disproportion already in their first year of marketing life (Figure 2). Although the indication for unresectable hepatocellular carcinoma complicates the causality assessment for sorafenib, EMA and FDA amended the prescribing information to add the hepatotoxic potential in the label (2010 and 2012, respectively)^[52,53].

An incidental observation of this study is that female gender does not seem to be associated with a reporting pattern of DILI for antimycotics, which differs from current data showing that females predominated in liver cases associated with a number of drug class^[54].

The large number of cases associated with triazole antifungals and terbinafine can be partially explained by the underlying clinical conditions of patients (critically ill patients, usually with systemic infections, cancer and other diseases that may increase the likelihood of adverse drug reactions). Moreover, when discussing and interpreting pharmacovigilance results, drug consumption data should be also taken into account can provide an additional perspective to regulators and clinicians in assessing the possible consequences of side effects of drugs (*e.g.*, by mapping the level of risk in a population standpoint)^[55,56]. Notably, the first ESAC survey on 2007 consumption data found that terbinafine, ketoconazole, itraconazole and fluconazole represented > 94% of the total outpatient antimycotic and antifungal use in 20 European Countries. Terbinafine use represented > 50% of the total systemic antimycotic and antifungal use in 16 out of 20 Countries^[57]. The updated analysis on 2009 data showed an increased outpatient use and confirms terbinafine and fluconazole as the most used compounds^[58]. Two point-prevalence ESAC surveys in European hospitals revealed that the most used antifungal was fluconazole (60.5%) followed by caspofungin (10.5%).

Table 4 Clinical, pharmacological and regulatory aspects of antimycotics for systemic use currently on the market (ketoconazole not shown)

| Drug | Approval (EMA-FDA) | Indication(s) | Main hepatic issues | Drug interactions |
|----------------|--------------------------|--|---|---|
| Amphotericin B | 1995 (FDA) ¹ | Empirical therapy for presumed fungal infection in febrile, neutropenic patients Cryptococcal Meningitis in HIV infected patients Visceral leishmaniasis | No detailed information provided (general statement in the section on side effects) | Unclear from the label (metabolic pathway unknown) |
| Miconazole | No centralized approval | Onychomycosis (topical) | Not reported | CYP3A4 and CYP2C9 inhibitor (when administered systemically) |
| Fluconazole | 1990 (FDA) | Local candida infections (topical and systemic) Acute vaginal candidiasis when local therapy is not appropriate Candidal balanitis when local therapy is not appropriate Mucosal and invasive candidiasis, genital candidiasis (thrush), cryptococcal meningitis, dermatomycosis, coccidioidomycosis and onychomycosis (EMA revision in 2011) | Hepatic injury (warning FDA and EMA) | Potent CYP2C9 inhibitor; moderate CYP3A4 inhibitor; CYP2C19 inhibitor |
| Itraconazole | 1992 (FDA) | Onychomycosis of the toenail caused by Trichophyton rubrum or T. mentagrophytes (FDA) | Hepatic injury (FDA) | Potent CYP3A4 inhibitor (drug interactions in warnings) |
| Voriconazole | 2002 (EMA and FDA) | Invasive aspergillosis Candidemia in non-neutropenic patients Esophageal candidiasis (FDA) Fluconazole-resistant serious invasive Candida infections (including <i>C. krusei</i>) (EMA) Serious fungal infections caused by <i>Scedosporium spp.</i> and <i>Fusarium spp.</i> | Hepatic toxicity and monitoring of hepatic function (EMA and FDA) | CYP2C9, 2C19 and 3A4 inhibitor (several contraindicated drugs) |
| Posaconazole | 2006 (FDA) 2005 (EMA) | Refractory IFI/Patients with IFI intolerant to first line therapy Oropharyngeal candidiasis Prophylaxis of IFI | Hepatic toxicity and monitoring of hepatic function (EMA and FDA) | Potent CYP3A4 inhibitor (drug interactions in contraindications) |
| Caspofungin | 2001(EMA and FDA) | Empirical therapy for presumed fungal infections in febrile, neutropenic patients Invasive candidiasis Invasive aspergillosis (patients refractory or intolerant) | Hepatic effects | No CYP3A4 inhibition; No P-gp induction and poor substrate |
| Micafungin | 2005 (only FDA) | Treatment of invasive candidiasis Treatment of esophageal candidiasis Prophylaxis of Candida infection | Hepatic effects | No P-gp induction or substrate |
| Anidulafungin | 2006 (FDA) 2007 (EMA) | Invasive candidiasis in adult non-neutropenic patients (EMA) Esophageal candidiasis (FDA) | Hepatic effects (warning FDA and EMA) | No CYP substrate, inhibitor or inducer |
| Terbinafine | 1995 ² | Fingernail onychomycosis Toenail onychomycosis | Hepatotoxicity | CYP2D6 inhibitor |
| Griseofulvin | 1975 (FDA) | Various forms of tinea (corporis, pedis, cruris, barbae, capitis, unguium) | Hepatotoxicity | Unclear from the label |

Information are derived from relevant summary of product characteristic (EMA) or product information (FDA), as of March 26th, 2013. When no information could be obtained from EMA and FDA documents, the Italian label was used. ¹On 28 August 2006, orphan designation (EU/3/06/391) was granted by the European Commission to Nektar Therapeutics United Kingdom Ltd, United Kingdom, for amphotericin B (for inhalation use) for the prevention of pulmonary fungal infections in patients deemed at risk; ²Pediatric investigation plan agreed with EMA. EMA: European Medicines Agency; FDA: Food and Drug Administration; IFI: Invasive fungal infections.

Notably, antifungal-antibacterial combinations were frequently used (77.5%)^[59]. As clearly emerged from these drug utilization studies, widely used antimycotics are also frequently reported in DILI cases extracted from FAERS. Therefore, not only active monitoring is warranted, but also appropriateness of prescriptions should be carefully considered by clinicians.

Another important aspect regards the issue of potential drug interactions. As a matter of fact, several antimycotics are metabolized or even inhibit crucial liver cytochromes for drug metabolism (*e.g.*, CYP3A4) (Table 4). Although the clinical relevance of drug interactions is still

a matter of debate, concomitant administration of drugs and/or herb (which are recognized to have hepatotoxic potential) should be assessed for potential interactions or interference with hepatic metabolism. Remarkably, the clinical implications of our data are also influenced by the different therapeutic indications of antimycotics (Table 4). In this context, griseofulvin, terbinafine, fluconazole and itraconazole share onychomycosis as main indication, whereas micafungin, voriconazole, posaconazole, caspofungin and amphotericin are used for systemic invasive infections, implying different baseline patients' conditions that may contribute to increase their hepatotoxic poten-

tial. In particular, voriconazole and posaconazole are the most recently marketed compound and are indicated as second-line treatment for invasive fungal infections (*e.g.*, following treatment failure with fluconazole); therefore, a potential channeling bias should be considered (*i.e.*, the possibility that drugs may be differently prescribed in relation to the severity of disease).

In a conclusion, we have used the recent regulatory case of ketoconazole to provide clues to clinicians needing practical guidance to assign the level of DILI risk among antimycotics.

From our analysis, it clearly emerges that it is not possible to identify a safe systemic antimycotic because all agents show a disproportionality signal for DILI. Although this safety issue was already formally mentioned in the label, it is still possible that clinicians do not fully appreciate this aspect.

The recent marketing restrictions of ketoconazole by regulatory Agencies should not lead physicians to overlook hepatotoxicity due to other systemic antifungals. Careful monitoring is therefore recommended, especially in critical poly-treated patients, keeping in mind that treatment usually requires drug exposure for a significant period of time.

It is clear that drug developers and clinicians face a challenging task in early recognition of DILI, a rare but potentially serious event for which drug discontinuation remains the key aspect of management, provided that diagnosis is correct. Therefore, the creation of novel multidisciplinary projects and the implementation of existing consortia (*e.g.*, the DILI network) is desirable to achieve the best risk prediction in the preclinical phase and make pharmacovigilance a reliable indicator of the post-marketing risk. This is also in line with new European pharmacovigilance legislation (in force since July 2012), which advocates the need for global risk-benefit assessment.

COMMENTS

Background

The recent regulatory interventions (United States restriction and Europe suspension) concerning ketoconazole for drug-induced liver injury (DILI) poses a prescribing challenge to clinicians, who should now carefully consider safer therapeutic alternatives.

Research frontiers

Eleven systemic antimycotics (including ketoconazole and the newer triazole derivatives voriconazole and posaconazole) and terbinafine (used systemically to treat onychomycosis) generated a significant disproportionality, indicating a post-marketing signal of risk.

Innovations and breakthroughs

Authors have used the recent regulatory case of ketoconazole to provide clues to clinicians needing practical guidance to assign the level of DILI risk among antimycotics.

Peer review

This is a well-written manuscript that provides valuable information about drug hepatotoxicity, particularly those induced by antimycotics.

REFERENCES

- 1 Hussaini SH, Farrington EA. Idiosyncratic drug-induced liver injury: an update on the 2007 overview. *Expert Opin*

- 2 *Drug Saf* 2014; **13**: 67-81 [PMID: 24073714 DOI: 10.1517/14740338.2013.828032]
- 2 Leise MD, Poterucha JJ, Talwalkar JA. Drug-induced liver injury. *Mayo Clin Proc* 2014; **89**: 95-106 [PMID: 24388027 DOI: 10.1016/j.mayocp.2013.09.016]
- 3 Kaplowitz N. Idiosyncratic drug hepatotoxicity. *Nat Rev Drug Discov* 2005; **4**: 489-499 [PMID: 15931258 DOI: 10.1038/nrd1750]
- 4 Roth RA, Ganey PE. Intrinsic versus idiosyncratic drug-induced hepatotoxicity--two villains or one? *J Pharmacol Exp Ther* 2010; **332**: 692-697 [PMID: 20019161 DOI: 10.1124/jpet.109.162651]
- 5 Lammert C, Björnsson E, Niklasson A, Chalasani N. Oral medications with significant hepatic metabolism at higher risk for hepatic adverse events. *Hepatology* 2010; **51**: 615-620 [PMID: 19839004 DOI: 10.1002/hep.23317]
- 6 Lammert C, Einarsson S, Saha C, Niklasson A, Björnsson E, Chalasani N. Relationship between daily dose of oral medications and idiosyncratic drug-induced liver injury: search for signals. *Hepatology* 2008; **47**: 2003-2009 [PMID: 18454504 DOI: 10.1002/hep.22272]
- 7 Chen M, Borlak J, Tong W. High lipophilicity and high daily dose of oral medications are associated with significant risk for drug-induced liver injury. *Hepatology* 2013; **58**: 388-396 [PMID: 23258593 DOI: 10.1002/hep.26208]
- 8 Yu K, Geng X, Chen M, Zhang J, Wang B, Ilic K, Tong W. High daily dose and being a substrate of cytochrome P450 enzymes are two important predictors of drug-induced liver injury. *Drug Metab Dispos* 2014; **42**: 744-750 [PMID: 24464804 DOI: 10.1124/dmd.113.056267]
- 9 Aithal GP, Watkins PB, Andrade RJ, Larrey D, Molokhia M, Takikawa H, Hunt CM, Wilke RA, Avigan M, Kaplowitz N, Björnsson E, Daly AK. Case definition and phenotype standardization in drug-induced liver injury. *Clin Pharmacol Ther* 2011; **89**: 806-815 [PMID: 21544079 DOI: 10.1038/clpt.2011.58]
- 10 Bénichou C. Criteria of drug-induced liver disorders. Report of an international consensus meeting. *J Hepatol* 1990; **11**: 272-276 [PMID: 2254635 DOI: 10.1016/0168-8278(90)90124-A]
- 11 Teschke R, Wolff A, Frenzel C, Schwarzenboeck A, Schulze J, Eickhoff A. Drug and herb induced liver injury: Council for International Organizations of Medical Sciences scale for causality assessment. *World J Hepatol* 2014; **6**: 17-32 [PMID: 24653791]
- 12 Brinker AD, Wassell RT, Lyndly J, Serrano J, Avigan M, Lee WM, Seeff LB. Telithromycin-associated hepatotoxicity: Clinical spectrum and causality assessment of 42 cases. *Hepatology* 2009; **49**: 250-257 [PMID: 19085949 DOI: 10.1002/hep.22620]
- 13 Fontana RJ, Seeff LB, Andrade RJ, Björnsson E, Day CP, Serrano J, Hoofnagle JH. Standardization of nomenclature and causality assessment in drug-induced liver injury: summary of a clinical research workshop. *Hepatology* 2010; **52**: 730-742 [PMID: 20564754 DOI: 10.1002/hep.23696]
- 14 Kleiner DE, Chalasani NP, Lee WM, Fontana RJ, Bonkovsky HL, Watkins PB, Hayashi PH, Davern TJ, Navarro V, Reddy R, Talwalkar JA, Stolz A, Gu J, Barnhart H, Hoofnagle JH. Hepatic histological findings in suspected drug-induced liver injury: systematic evaluation and clinical associations. *Hepatology* 2014; **59**: 661-670 [PMID: 24037963]
- 15 Agarwal VK, McHutchison JG, Hoofnagle JH. Important elements for the diagnosis of drug-induced liver injury. *Clin Gastroenterol Hepatol* 2010; **8**: 463-470 [PMID: 20170750 DOI: 10.1016/j.cgh.2010.02.008]
- 16 Fontana RJ, Watkins PB, Bonkovsky HL, Chalasani N, Davern T, Serrano J, Rochon J. Drug-Induced Liver Injury Network (DILIN) prospective study: rationale, design and conduct. *Drug Saf* 2009; **32**: 55-68 [PMID: 19132805 DOI: 10.2165/00002018-200932010-00005]
- 17 Shah RR. Can pharmacogenetics help rescue drugs withdrawn from the market? *Pharmacogenomics* 2006; **7**: 889-908 [PMID: 16981848 DOI: 10.2217/14622416.7.6.889]
- 18 Coloma PM, Trifirò G, Patadia V, Sturkenboom M. Postmar-

- ketting safety surveillance : where does signal detection using electronic healthcare records fit into the big picture? *Drug Saf* 2013; **36**: 183-197 [PMID: 23377696 DOI: 10.1007/s40264-013-0018-x]
- 19 **Regev A**. How to avoid being surprised by hepatotoxicity at the final stages of drug development and approval. *Clin Liver Dis* 2013; **17**: 749-67, xi [PMID: 24099029 DOI: 10.1016/j.cld.2013.07.014]
- 20 **Corsini A**, Ganey P, Ju C, Kaplowitz N, Pessayre D, Roth R, Watkins PB, Albassam M, Liu B, Stancic S, Suter L, Bortolini M. Current challenges and controversies in drug-induced liver injury. *Drug Saf* 2012; **35**: 1099-1117 [PMID: 23137150]
- 21 **Hawkins MT**, Lewis JH. Latest advances in predicting DILI in human subjects: focus on biomarkers. *Expert Opin Drug Metab Toxicol* 2012; **8**: 1521-1530 [PMID: 22998122 DOI: 10.1517/17425255.2012.724060]
- 22 **Temple R**. Hy's law: predicting serious hepatotoxicity. *Pharmacoevidemiol Drug Saf* 2006; **15**: 241-243 [PMID: 16552790 DOI: 10.1002/pds.1211]
- 23 **Andrade RJ**, Lucena MI, Fernández MC, Pelaez G, Pachkoria K, García-Ruiz E, García-Muñoz B, González-Grande R, Pizarro A, Durán JA, Jiménez M, Rodrigo L, Romero-Gomez M, Navarro JM, Planas R, Costa J, Borrás A, Soler A, Salmerón J, Martín-Vivaldi R. Drug-induced liver injury: an analysis of 461 incidences submitted to the Spanish registry over a 10-year period. *Gastroenterology* 2005; **129**: 512-521 [PMID: 16083708 DOI: 10.1016/j.gastro.2005.05.006]
- 24 **Björnsson E**, Olsson R. Outcome and prognostic markers in severe drug-induced liver disease. *Hepatology* 2005; **42**: 481-489 [PMID: 16025496 DOI: 10.1002/hep.20800]
- 25 **FDA**. Guidance for Industry. Drug-Induced Liver Injury: Premarketing Clinical Evaluation (2009). Available from: URL: <http://www.fda.gov/downloads/Drugs/.../Guidances/UCM174090.pdf>
- 26 **Watkins PB**, Desai M, Berkowitz SD, Peters G, Horsmans Y, Larrey D, Maddrey W. Evaluation of drug-induced serious hepatotoxicity (eDISH): application of this data organization approach to phase III clinical trials of rivaroxaban after total hip or knee replacement surgery. *Drug Saf* 2011; **34**: 243-252 [PMID: 21332248 DOI: 10.2165/11586600-000000000-00000]
- 27 **Andrade RJ**, Tulkens PM. Hepatic safety of antibiotics used in primary care. *J Antimicrob Chemother* 2011; **66**: 1431-1446 [PMID: 21586591 DOI: 10.1093/jac/dkr159]
- 28 **Cronin S**, Chandrasekar PH. Safety of triazole antifungal drugs in patients with cancer. *J Antimicrob Chemother* 2010; **65**: 410-416 [PMID: 20035021 DOI: 10.1093/jac/dkp464]
- 29 **Lewis JH**, Zimmerman HJ, Benson GD, Ishak KG. Hepatic injury associated with ketoconazole therapy. Analysis of 33 cases. *Gastroenterology* 1984; **86**: 503-513 [PMID: 6319220]
- 30 **García Rodríguez LA**, Duque A, Castellsague J, Pérez-Gutthann S, Stricker BH. A cohort study on the risk of acute liver injury among users of ketoconazole and other antifungal drugs. *Br J Clin Pharmacol* 1999; **48**: 847-852 [PMID: 10594489 DOI: 10.1046/j.1365-2125.1999.00095.x]
- 31 **Yan JY**, Nie XL, Tao QM, Zhan SY, Zhang YD. Ketoconazole associated hepatotoxicity: a systematic review and meta-analysis. *Biomed Environ Sci* 2013; **26**: 605-610 [PMID: 23895707]
- 32 **Fernandes NF**, Geller SA, Fong TL. Terbinafine hepatotoxicity: case report and review of the literature. *Am J Gastroenterol* 1998; **93**: 459-460 [PMID: 9517658 DOI: 10.1111/j.1572-0241.1998.00459.x]
- 33 **Ajit C**, Suvannasankha A, Zaeri N, Munoz SJ. Terbinafine-associated hepatotoxicity. *Am J Med Sci* 2003; **325**: 292-295 [PMID: 12792250 DOI: 10.1097/00000441-200305000-00008]
- 34 **Anania FA**, Rabin L. Terbinafine hepatotoxicity resulting in chronic biliary ductopenia and portal fibrosis. *Am J Med* 2002; **112**: 741-742 [PMID: 12079721 DOI: 10.1016/S0002-9343(02)01109-9]
- 35 **Kao WY**, Su CW, Huang YS, Chou YC, Chen YC, Chung WH, Hou MC, Lin HC, Lee FY, Wu JC. Risk of oral antifungal agent-induced liver injury in Taiwanese. *Br J Clin Pharmacol* 2014; **77**: 180-189 [PMID: 23750489 DOI: 10.1111/bcp.12178]
- 36 **Trifirò G**, Pariente A, Coloma PM, Kors JA, Polimeni G, Miremont-Salamé G, Catania MA, Salvo F, David A, Moore N, Caputi AP, Sturkenboom M, Molokhia M, Hippisley-Cox J, Acedo CD, van der Lei J, Fourrier-Reglat A. Data mining on electronic health record databases for signal detection in pharmacovigilance: which events to monitor? *Pharmacoevidemiol Drug Saf* 2009; **18**: 1176-1184 [PMID: 19757412 DOI: 10.1002/pds.1836]
- 37 **Harpaz R**, DuMouchel W, LePendu P, Bauer-Mehren A, Ryan P, Shah NH. Performance of pharmacovigilance signal-detection algorithms for the FDA adverse event reporting system. *Clin Pharmacol Ther* 2013; **93**: 539-546 [PMID: 23571771 DOI: 10.1038/clpt.2013.24]
- 38 **Dusetzina SB**, Higashi AS, Dorsey ER, Conti R, Huskamp HA, Zhu S, Garfield CF, Alexander GC. Impact of FDA drug risk communications on health care utilization and health behaviors: a systematic review. *Med Care* 2012; **50**: 466-478 [PMID: 22266704 DOI: 10.1097/MLR.0b013e318245a160]
- 39 **Poluzzi E**, Raschi E, Moretti U, De Ponti F. Drug-induced torsades de pointes: data mining of the public version of the FDA Adverse Event Reporting System (AERS). *Pharmacoevidemiol Drug Saf* 2009; **18**: 512-518 [PMID: 19358226 DOI: 10.1002/pds.1746]
- 40 **Poluzzi E**, Raschi E, Motola D, Moretti U, De Ponti F. Antimicrobials and the risk of torsades de pointes: the contribution from data mining of the US FDA Adverse Event Reporting System. *Drug Saf* 2010; **33**: 303-314 [PMID: 20297862 DOI: 10.2165/11531850-000000000-00000]
- 41 **Poluzzi E**, Raschi E, Koci A, Moretti U, Spina E, Behr ER, Sturkenboom M, De Ponti F. Antipsychotics and torsadogenic risk: signals emerging from the US FDA Adverse Event Reporting System database. *Drug Saf* 2013; **36**: 467-479 [PMID: 23553446 DOI: 10.1007/s40264-013-0032-z]
- 42 **Brinker AD**, Lyndly J, Tonning J, Moeny D, Levine JG, Avigan MI. Profiling cumulative proportional reporting ratios of drug-induced liver injury in the FDA Adverse Event Reporting System (FAERS) database. *Drug Saf* 2013; **36**: 1169-1178 [PMID: 24178291 DOI: 10.1007/s40264-013-0116-9]
- 43 **Poluzzi E**, Raschi E, Piccinni C, De Ponti F. Data Mining Techniques in Pharmacovigilance: Analysis of the Publicly Accessible FDA Adverse Event Reporting System (AERS). In: Karahoca A. Data Mining Applications in Engineering and Medicine. InTech: Rijeka, Croatia, 2012: 267-301
- 44 **Suzuki A**, Andrade RJ, Björnsson E, Lucena MI, Lee WM, Yuen NA, Hunt CM, Freston JW. Drugs associated with hepatotoxicity and their reporting frequency of liver adverse events in Vigibase: unified list based on international collaborative work. *Drug Saf* 2010; **33**: 503-522 [PMID: 20486732 DOI: 10.2165/11535340-000000000-00000]
- 45 **Bernal W**, Wendon J. Acute liver failure. *N Engl J Med* 2013; **369**: 2525-2534 [PMID: 24369077 DOI: 10.1056/NEJMra1208937]
- 46 **van Puijnenbroek EP**, Bate A, Leufkens HG, Lindquist M, Orre R, Egberts AC. A comparison of measures of disproportionality for signal detection in spontaneous reporting systems for adverse drug reactions. *Pharmacoevidemiol Drug Saf* 2002; **11**: 3-10 [PMID: 11998548 DOI: 10.1002/pds.668]
- 47 **Raschi E**, Piccinni C, Poluzzi E, Marchesini G, De Ponti F. The association of pancreatitis with antidiabetic drug use: gaining insight through the FDA pharmacovigilance database. *Acta Diabetol* 2013; **50**: 569-577 [PMID: 22008948 DOI: 10.1007/s00592-011-0340-7]
- 48 **Ryan PB**, Schuemie MJ, Welebob E, Duke J, Valentine S, Hartzema AG. Defining a reference set to support methodological research in drug safety. *Drug Saf* 2013; **36** Suppl 1: S33-S47 [PMID: 24166222 DOI: 10.1007/s40264-013-0097-8]
- 49 **Coloma PM**, Avillach P, Salvo F, Schuemie MJ, Ferrajolo C, Pariente A, Fourrier-Réglat A, Molokhia M, Patadia V, van

- der Lei J, Sturkenboom M, Trifirò G. A reference standard for evaluation of methods for drug safety signal detection using electronic healthcare record databases. *Drug Saf* 2013; **36**: 13-23 [PMID: 23315292 DOI: 10.1007/s40264-012-0002-x]
- 50 Bate A, Evans SJ. Quantitative signal detection using spontaneous ADR reporting. *Pharmacoepidemiol Drug Saf* 2009; **18**: 427-436 [PMID: 19358225 DOI: 10.1002/pds.1742]
- 51 Shah RR, Morganroth J, Shah DR. Hepatotoxicity of tyrosine kinase inhibitors: clinical and regulatory perspectives. *Drug Saf* 2013; **36**: 491-503 [PMID: 23620168 DOI: 10.1007/s40264-013-0048-4]
- 52 NEVAXAR. EMA: procedural steps taken and scientific information after the authorisation (2010). Available from: URL: http://www.ema.europa.eu/docs/en_GB/document_library/EPAR_Procedural_steps_taken_and_scientific_information_after_authorisation/human/000690/WC500027709.pdf
- 53 NEVAXAR. FDA: Labeling Revision (2010). Available from: URL: http://www.accessdata.fda.gov/drugsatfda_docs/applletter/2012/021923Orig1s13ltr.pdf
- 54 Petronijevic M, Ilic K. Associations of gender and age with the reporting of drug-induced hepatic failure: data from the Vigibase™. *J Clin Pharmacol* 2013; **53**: 435-443 [PMID: 23440959 DOI: 10.1002/jcph.3]
- 55 Raschi E, Poluzzi E, Zuliani C, Muller A, Goossens H, De Ponti F. Exposure to antibacterial agents with QT liability in 14 European countries: trends over an 8-year period. *Br J Clin Pharmacol* 2009; **67**: 88-98 [PMID: 19076158 DOI: 10.1111/j.1365-2125.2008.03319.x]
- 56 Raschi E, Poluzzi E, Godman B, Koci A, Moretti U, Kalaba M, Bennie M, Barbui C, Wettermark B, Sturkenboom M, De Ponti F. Torsadogenic risk of antipsychotics: combining adverse event reports with drug utilization data across Europe. *PLoS One* 2013; **8**: e81208 [PMID: 24278396 DOI: 10.1371/journal.pone.0081208]
- 57 Adriaenssens N, Coenen S, Muller A, Vankerckhoven V, Goossens H. European Surveillance of Antimicrobial Consumption (ESAC): outpatient systemic antimycotic and antifungal use in Europe. *J Antimicrob Chemother* 2010; **65**: 769-774 [PMID: 20142264 DOI: 10.1093/jac/dkq023]
- 58 Adriaenssens N, Coenen S, Versporten A, Goossens H. Outpatient systemic antimycotic and antifungal use in Europe: new outcome measure provides new insight. *Int J Antimicrob Agents* 2013; **42**: 466-470 [PMID: 23993932 DOI: 10.1016/j.ijantimicag.2013.07.004]
- 59 Zarb P, Amadeo B, Muller A, Drapier N, Vankerckhoven V, Davey P, Goossens H. Antifungal therapy in European hospitals: data from the ESAC point-prevalence surveys 2008 and 2009. *Clin Microbiol Infect* 2012; **18**: E389-E395 [PMID: 22827696 DOI: 10.1111/j.1469-0691.2012.03973.x]

P- Reviewer: Julie NL, Neil L S- Editor: Wen LL
L- Editor: A E- Editor: Wu HL



Circulating microRNAs in patients with non-alcoholic fatty liver disease

Mehmet Celikbilek, Mevlut Baskol, Serpil Taheri, Kemal Deniz, Serkan Dogan, Gokmen Zararsiz, Sebnem Gursay, Kadri Guven, Omer Ozbakir, Munis Dundar, Mehmet Yucesoy

Mehmet Celikbilek, Mevlut Baskol, Serkan Dogan, Sebnem Gursay, Kadri Guven, Omer Ozbakir, Mehmet Yucesoy, Department of Gastroenterology, Erciyes University, Medical School, 38039 Kayseri, Turkey
Serpil Taheri, Munis Dundar, Department of Medical Genetics, Erciyes University, Medical School, 38039 Kayseri, Turkey
Kemal Deniz, Department of Pathology, Erciyes University, Medical School, 38039 Kayseri, Turkey
Gokmen Zararsiz, Department of Biostatistics and Medical Informatics, Erciyes University, Medical School, 38039 Kayseri, Turkey

Author contributions: Celikbilek M, Taheri S and Dogan S contributed to the design of the study, data collection, drafted the manuscript, and revised it in accordance with suggestions from the other authors; Baskol M contributed to the design of the study, drafted the manuscript and participated in the critical revision of the manuscript for important intellectual content; Deniz K contributed to the study conception and design, analysis and interpretation of data, drafted the manuscript, and participated in the critical revision of the manuscript for important intellectual content; Zararsiz G performed the statistical and bioinformatics analysis; Gursay S, Guven K, Ozbakir O, Dundar M, Yucesoy M contributed to the design of the study, interpretation of data, and participated in the critical revision of the manuscript for important intellectual content.

Correspondence to: Mehmet Celikbilek, MD, Department of Gastroenterology, Erciyes University, Medical School, 38039 Kayseri, Turkey. drcekbilek@yahoo.com

Telephone: +90-505-6615375 Fax: +90-354-2140612

Received: January 28, 2014 Revised: March 13, 2014

Accepted: July 12, 2014

Published online: August 27, 2014

Abstract

AIM: To identify novel non-invasive biomarkers for non-alcoholic fatty liver disease (NAFLD).

METHODS: Twenty patients with histologically proven NAFLD and 20 controls were included. All NAFLD cases were scored using the NAFLD activity score. The relative expressions of miR-197, miR-146b, miR-10b, miR-

181d, miR-34a, miR-122, miR-99a and miR-29a were analyzed using real-time polymerase chain reaction.

RESULTS: Serum levels of miR-181d, miR-99a, miR-197 and miR-146b were significantly lower in biopsy-proven NAFLD patients than in the healthy controls. Serum levels of miR-197 and miR-10b were inversely correlated with degree of inflammation and miR-181d and miR-99a were inversely correlated with serum gamma glutamyl transferase levels in non-alcoholic steatohepatitis patients.

CONCLUSION: NAFLD is associated with altered serum miRNA expression pattern. This study provides clues for defining the non-invasive diagnosis of NAFLD.

© 2014 Baishideng Publishing Group Inc. All rights reserved.

Key words: Nonalcoholic fatty liver disease; Nonalcoholic steatohepatitis; MicroRNA; Noninvasive; Serum markers

Core tip: Due to the limitations of liver biopsy, the use of non-invasive markers has emerged in recent years. MicroRNAs (miRNAs) are a class of naturally occurring small noncoding RNAs that regulate gene expression. Altered miRNA expression has been reported in animal and human liver samples in non-alcoholic fatty liver disease (NAFLD). There is, however, only limited information on their detection in blood and their correlation with histological disease severity in patients with NAFLD. For this reason, we measured the serum levels of some miRNAs in non-alcoholic steatohepatitis (NASH) patients. Of these microRNAs, miR-181d, miR-99a, miR-197 and miR-146b were expressed at lower levels in NASH patients than in controls. Serum levels of miR-197 and miR-10b were inversely correlated with degree of inflammation and miR-181d and miR-99a were inversely correlated with serum gamma glutamyl transferase levels in NASH patients.

Celikbilek M, Baskol M, Taheri S, Deniz K, Dogan S, Zararsiz G, Gursoy S, Guven K, Ozbakir O, Dundar M, Yucesoy M. Circulating microRNAs in patients with non-alcoholic fatty liver disease. *World J Hepatol* 2014; 6(8): 613-620 Available from: URL: <http://www.wjgnet.com/1948-5182/full/v6/i8/613.htm> DOI: <http://dx.doi.org/10.4254/wjh.v6.i8.613>

INTRODUCTION

Non-alcoholic fatty liver disease (NAFLD) is the most common cause of chronic liver disease in Western populations. It comprises a disease spectrum which includes variable degrees of simple steatosis (fatty liver), non-alcoholic steatohepatitis (NASH) and cirrhosis which are likely to be characterized by different pathogenesis and clinical history^[1]. Liver biopsy is used in daily practice for the diagnosis of NASH and histologic severity. The identification of novel non-invasive biomarkers for NAFLD is needed due to the invasive nature of liver biopsy.

MicroRNAs (miRNAs) are a class of naturally occurring small noncoding RNAs of approximately 22 nucleotides in length that regulate gene expression either by promoting mRNA degradation or by attenuating protein translation^[2,3]. miRNAs can influence NAFLD through pathways involving inflammation, fibrosis, insulin resistance, lipid metabolism and the metabolic syndrome. Recently, altered miRNA expression has been reported in animal and human liver samples in NAFLD^[4-6]. Serum levels of miR-29a were significantly down-regulated in fibrotic/cirrhotic livers compared with nonfibrotic livers^[7]. miRNA-10b was proven to regulate the level of steatosis in human hepatocyte cell culture^[8]. miR-122 was significantly underexpressed in liver samples of NASH subjects compared to controls and miR-34a was significantly overexpressed^[5]. miR-181d may play a role in regulating the lipid content of hepatocytes^[9]. miR-197 and miR-99, in the visceral adipose tissue, were significantly associated with pericellular fibrosis in NAFLD^[10]. Serum free fatty acid (FFA) levels negatively correlated with adipose tissue level of miR-99a^[11]. miR-146b was up-regulated in adipose tissue after long-term high-fat diet-induced obesity in mice^[12].

There is insufficient data in the literature regarding serum miRNA expression patterns in NAFLD. In the present study, we analyzed the serum expression profile of these eight miRNAs (miR-29a, miR-10b, miR-122, miR-34a, miR-181d, miR-197, miR-99a, miR-146b) which are related to NAFLD progression and pathogenesis, and are related to serum FFAs, insulin resistance, and adipose tissue.

MATERIALS AND METHODS

Study population

A total of 40 patients were enrolled in this study between September 2010 and January 2012 at Erciyes University Department of Gastroenterology. Twenty patients with

histologically proven NAFLD were included. The inclusion criteria were as follows: (1) 18 years or older; (2) persistently elevated (for at least 6 mo) aminotransferases; (3) ultrasonographic presence of hyperechogenic liver and (4) liver histology with a diagnosis of non-alcoholic steatohepatitis (NASH) without cirrhosis obtained no more than 6 mo before the study. The exclusion criteria were as follows: (1) a history of any level of alcohol consumption; (2) hypertension (≥ 135 systolic, ≥ 85 diastolic or antihypertensive use); (3) any other form of chronic liver disease; (4) use of any medications thought to cause or affect NAFLD; (5) abnormal thyroid function tests; (6) plasma fasting glucose ≥ 126 mg/dL or antidiabetic drug use; (7) chronic obstructive pulmonary disease; (8) peripheral and cerebral vascular disease; (9) hematologic disorders; (10) acute or chronic infection; (11) history of cancer; (12) chronic kidney diseases and (13) documented coronary artery disease.

The control group consisted of 20 healthy age-matched subjects from our institution staff with normal liver enzymes and abdominal ultrasonography findings. All subjects underwent a clinical examination and were questioned regarding their medical history. BMI was calculated as body weight/height².

The study was performed in accordance with the principles of the Helsinki Declaration of 1975, as revised in 2008. This study was approved by the ethics committee of the Medical School of Erciyes University and informed consent was obtained from all participants.

This work was supported by a grant, number TSD-10-3368, from the Erciyes University as well as by a grant from the Turkish Association for the Study of the Liver. The funders had no role in the study design, data collection and analysis, decision to publish, or preparation of the manuscript.

Biochemical measurements

Blood samples were drawn after an overnight fast from an antecubital vein; fasting plasma glucose, serum basal insulin level, high density lipoprotein cholesterol, triglycerides, low density lipoprotein cholesterol, creatinine, alanine aminotransferase, aspartate aminotransferase, serum total bilirubin, serum indirect bilirubin, alkaline phosphatase, and gamma glutamyl transferase (GGT) were determined by standard methods.

The estimate of IR by the homeostasis model assessment insulin resistance index (HOMA-IR) was calculated using the formula: fasting serum insulin (mIU/L) \times fasting plasma glucose (mmol/L)/22.5.

Histopathologic analysis

The liver tissue was stained with hematoxylin-eosin and Masson's trichrome stains. The review of the specimens was carried out by a single experienced liver pathologist. NASH was diagnosed according to the consensus arrived at a meeting of the American Association for the Study of Liver Diseases^[13]. All cases were scored using NAS to compare miRNA expression and laboratory param-

ters^[14]. A 4-point scale for steatosis [(0) < 5%, (1) 5%-33%, (2) > 33%-66%, and (3) > 66%], lobular inflammation [(0) no foci, (1) < 2 foci, (2) 2-4 foci, and (3) > 4 foci] and a 3-point scale for ballooning [(0) none, (1) mild, and (2) moderate-marked] resulted in a maximal sum score of 8. A NAS score of 5 and over correlated with salient NASH, patients with scores < 3 were diagnosed as not having NASH, and patients with scores of 3 and 4 were diagnosed as having borderline NASH. Fibrosis was scored by Masson's trichrome stain using the NASH scoring system [(0): none, (1) perisinusoidal or periportal fibrosis, (2) perisinusoidal and periportal fibrosis, (3) bridging fibrosis, and (4) cirrhosis]. Steatosis was coded as 0 = mild (steatosis grade 1) or 1 = moderate to severe (steatosis grade 2-3). Ballooning was coded as 0 = mild (ballooning grade 1), or 1 = moderate-severe (ballooning grade 2). Lobular inflammation was coded as 0 = absent-mild (lobular inflammation 0-1) or 1 = moderate-severe (lobular inflammation 2-3). Fibrosis was coded as 0 = no significant fibrosis (F0-F1) or 1 = significant fibrosis (F2-F4).

miRNA quantitation

miRNA was isolated from serum using a miRNeasy Mini Kit (Qiagen, Cat; 217004) according to the manufacturer's protocol. The yield and purity of RNA were measured using a NanoDrop ND-1000 spectrophotometer (NanoDrop Technologies). cDNA was isolated from obtained miRNA samples using a miScript Reverse Transcription Kit (Qiagen, Cat; 218060). We performed quantitative Real-Time PCR (qPCR) according to the manufacturer's instructions (miScript SYBR Green PCR Kit Qiagen Cat. No: 218073) to profile the distribution of eight miRNAs in serum samples and RUN1A1 was used as an internal control. The qPCR assays were performed in duplicate. The relative expressions of miR-197, miR-146b, miR-10b, miR-181d, miR-34a, miR-122, miR-99a and miR-29a were analyzed using the standard 2- $\Delta\Delta$ CT method^[15]. These miRNAs were selected due to their pathophysiological relation with NAFLD.

Statistical analysis

For statistical analysis of clinical data, the Shapiro-Wilk's test was used, and histograms and q-q plots were constructed to check data normality. Either a two-sided independent samples *t*-test or Mann-Whitney *U* test was used for the comparison of continuous variables. χ^2 analysis was used for the comparison of categorical variables. Values are expressed as frequencies and percentages, mean \pm SD deviation or median and 25th-75th percentiles.

miRNA expression data analysis was performed according to the 2- $\Delta\Delta$ CT method. For additional pre-processing we applied a logarithmic transformation to the data, then centered genes as follows: [(value)-mean(gene)/standard deviation(gene)]. A *t* test was used to find the differentially expressed (DE) miRNAs between the NAFLD and control groups. Significant analysis of microarrays was also performed using 100 permutations to assess if the significance of the differential expression was by chance. The agglomerative hierarchical clustering

method with average linkage and the Pearson correlation distance metric were used for DE miRNAs and a cluster heat-map was constructed to visualize the data values of the samples and DE miRNAs simultaneously in a hierarchical cluster structure. Receiver operating characteristic (ROC) curves were plotted for DE miRNAs, and the area under the ROC curve values were calculated with 95% intervals and compared with each other. A series of cut-off values were applied, sensitivity and specificity statistical measures were computed for each cut-off value. Next, a ROC curve was generated and the area under this curve was calculated for each miRNA using the trapezoidal rule. Also, Pearson and point-biserial correlation coefficients were calculated to identify the relationship between laboratory parameters, NAS-scale parameters and miRNAs.

All *P* values obtained from clinical data and miRNA expression data were adjusted with the false discovery rate to control the multiple testing problem. Analyses were performed using several packages of R 2.14.0 software.

RESULTS

The clinical and laboratory data of age- and sex-matched patients and controls are summarized in Table 1. To determine whether serum levels of miR-181d, miR-10b, miR-122, miR-34a, miR-146b, miR-197, miR-99a and miR-29a change in patients with NAFLD, we measured these eight miRNAs in sera collected from 20 patients diagnosed with definite steatohepatitis according to Sanyal *et al.*^[13] and compared them with those of 20 controls.

miR-181d expression was significantly lower in the serum of NASH patients compared to healthy controls (*P* < 0.0001). miR-99a, miR-197 and miR-146b serum levels were also lower in NASH patients (*P* < 0.05). Serum levels of miR-10b, miR-122, miR-34a and miR-29a did not differ between the control and patient groups (Figure 1). miR-181d levels were decreased by 2.49-fold in NASH patients compared to healthy controls (*q* < 5%). miR-99a levels were decreased by 1.92-fold, miR-197 levels were decreased by 1.61-fold and miR-146b levels were decreased by 1.52-fold in NASH patients compared to healthy controls (*q* < 5%) (Table 2). A cluster heat-map which displays the data values of samples and differentially expressed miRNAs simultaneously in a hierarchical cluster structure was produced and is shown in Figure 2.

In our study, serum levels of miR-197 and miR-10b were negatively correlated with degree of inflammation (*P* < 0.05) (Table 3). Serum levels of these two miRNAs were decreased, while the degree of inflammation increased from absent-mild to moderate-severe. miRNA levels were similar in both groups according to NAS, steatosis, ballooning and fibrosis. Because both miR-197 and miR-10b levels correlated with degree of inflammation, we investigated the relationship between their serum levels and laboratory parameters in NASH patients (Table 4). Based on the correlation results between laboratory parameters and miRNAs (Table 4), a negative moderate and significant correlation was detected between GGT and miR-181d (*r* = -0.464, *P* < 0.05), and between GGT

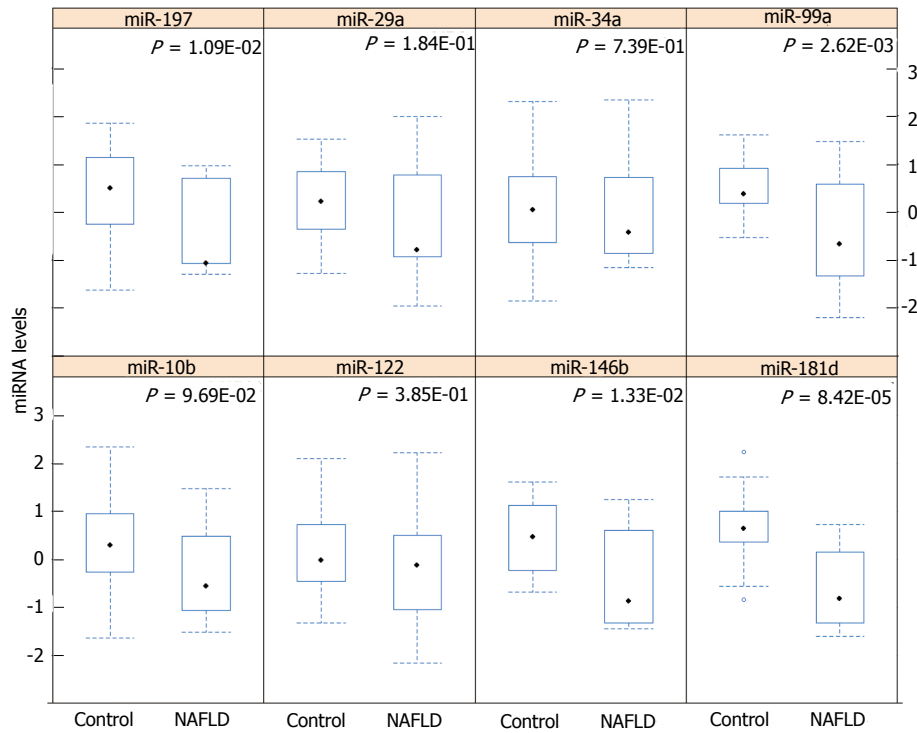


Figure 1 Box plots showing the expression value of 8 genes between control and non-alcoholic fatty liver disease groups. The middle line indicates the median statistic, the bottom and top of the box show the 25th and 75th percentiles, the lower and upper whiskers show the minimum and maximum values of the data after detecting outliers (circles). *P* values were obtained from a two-sided *t* test and adjusted with false discovery rate. NAFLD: Non-alcoholic fatty liver disease.

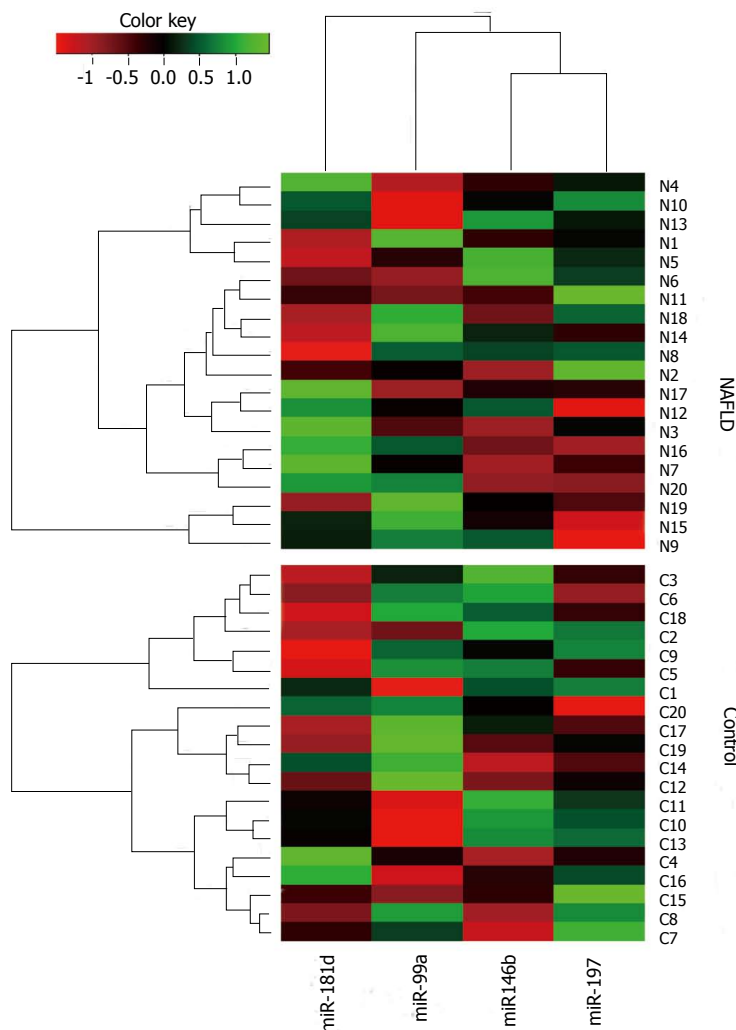


Figure 2 A cluster heatmap displaying the data values of samples and differentially expressed miRNAs simultaneously in a hierarchical cluster structure. Bright red: Under-expression; black: No change; bright green: Over-expression.

Table 1 Clinical and demographic characteristics of non-alcoholic fatty liver disease patients and controls

| Variable | NAFLD (n = 20) | Control (n = 20) | P |
|----------------------------------|------------------------|-----------------------|---------|
| Age (yr) | 42.75 ± 8.17 | 44.50 ± 9.31 | 0.761 |
| Sex (male/female) | 9 (45.0)/11 (55.0) | 9 (45.0)/11 (55.0) | 0.761 |
| BMI (kg/m ²) | 31.86 ± 4.76 | 27.26 ± 3.07 | 0.006 |
| Waist circumference (cm) | 103.25 ± 13.65 | 90.75 ± 11.02 | 0.014 |
| Systolic blood pressure (mmHg) | 120.25 ± 8.66 | 120.25 ± 7.69 | 0.999 |
| Diastolic blood pressure (mmHg) | 76.50 ± 6.09 | 77.50 ± 8.96 | 0.761 |
| Fasting glucose (mg/dL) | 97.85 ± 13.88 | 86.80 ± 11.92 | 0.034 |
| Triglycerides (mg/dL) | 151.10 ± 65.06 | 167.70 ± 51.46 | 0.645 |
| HDL-C (mg/dL) | 43.00 (36.50-48.50) | 45.00 (38.45-49.95) | 0.761 |
| LDL-C (mg/dL) | 125.50 (100.00-139.00) | 108.00 (89.25-121.25) | 0.511 |
| Insulin (mIU/mL) | 14.81 (11.88-22.75) | 11.76 (8.61-15.70) | 0.229 |
| HOMA-IR | 4.05 (2.71-5.51) | 2.21 (1.77-3.12) | 0.034 |
| Total bilirubin (mg/dL) | 0.65 (0.50-0.80) | 0.60 (0.55-0.80) | 0.761 |
| Direct bilirubin (mg/dL) | 0.20 (0.12-0.25) | 0.20 (0.10-0.20) | 0.761 |
| AST (IU/L) | 45.00 (34.50-59.00) | 21.00 (18.00-27.00) | < 0.001 |
| ALT (IU/L) | 68.50 (52.50-85.50) | 18.50 (14.00-29.00) | < 0.001 |
| AP (IU/L) | 76.00 (55.50-96.00) | 69.00 (57.00-78.50) | 0.761 |
| GGT (IU/L) | 48.00 (33.00-73.00) | 20.00 (14.50-33.00) | < 0.001 |
| Creatinine (mg/dL) | 0.87 ± 0.15 | 0.80 ± 0.18 | 0.401 |
| WBC (μL) | 6709.50 ± 1709.47 | 6618.00 ± 1425.37 | 0.892 |
| Trombocyte (10 ³ /μL) | 252.10 ± 64.85 | 275.90 ± 69.82 | 0.511 |
| Hct | 43.37 ± 3.53 | 44.25 ± 4.19 | 0.761 |

Values are expressed as n (%), mean ± SD or median (25th-75th percentiles). P values were adjusted with FDR to control multiple testing problem. NAFLD: Non-alcoholic fatty liver disease; BMI: Body mass index; HDL-C: High density lipoprotein cholesterol; LDL-C: Low density lipoprotein cholesterol; HOMA-IR: Homeostasis model assessment insulin resistance index; AST: Aspartate aminotransferase; ALT: Alanine aminotransferase; AP: Alkaline phosphatase; GGT: Gamma glutamyl transferase; WBC: White blood cell.

Table 2 Log₂ (Fold change) ratios of differentially expressed miRNAs which were statistically significant by *t* test (*P* < 0.05) and further confirmed by SAM test (*q* < 5%)

| miRNAs | log ₂ (Fold change) | | <i>q</i> value (%) |
|-----------------|--------------------------------|------|--------------------|
| | Mean | SEM | |
| Over-expressed | - | - | - |
| Under-expressed | | | |
| miR-197 | -1.61 | 0.54 | 0 |
| miR-146b | -1.52 | 0.55 | 0 |
| miR-181d | -2.49 | 0.50 | 0 |
| miR-99a | -1.92 | 0.53 | 0 |

A *q* value less than 5% by SAM corresponds to a *P* value less than 0.05 by *t* test. SEM: Standard error of mean.

and miR-99a (*r* = -0.479, *P* < 0.05). Other correlation coefficients between laboratory parameters and miRNAs were not statistically significant (*P* > 0.05).

To determine the presence of NASH, we performed ROC curve analyses of miR-197, miR-146b, miR-181d and miR-99a (Figure 3). AUROC values were 0.77 (0.60-0.88), 0.75 (0.59-0.87), 0.86 (0.72-0.95), and 0.76 (0.60-0.88), respectively. miR-181d seemed to be the best marker for NASH, and there was no statistically significant difference between any two miRNA AUROC values (*P* > 0.05). Using the Youden index, best cut-off values and the related diagnostic measures are given in Table 5.

DISCUSSION

The microRNA expression pattern changes in NAFLD

have been demonstrated in animal and human studies^[4,5]. There is, however, only limited information regarding their detection in blood and their correlation with histological disease severity in patients with NAFLD. For this reason, we measured the serum levels of miR-181d, miR-10b, miR-122, miR-34a, miR-146b, miR-197, miR-99a and miR-29a in NAFLD patients. Of these microRNAs, miR-181d, miR-99a, miR-197 and miR-146b were expressed at lower levels in NASH patients than in controls.

miR-29a was significantly down-regulated in fibrotic/cirrhotic livers compared with nonfibrotic livers^[7]. Roderburg *et al*^[7] also showed that significantly lower serum levels of miR-29a were observed in fibrosis patients compared with healthy controls. In our study, miR-29a serum levels were not different from controls. miRNA-10b significantly increased the triglyceride level and lipid content in human hepatocyte cell line L02 cells. miRNA-10b was proven to regulate the steatosis level in human hepatocyte cell culture *via* the peroxisome proliferator-activated receptor-α pathway^[8]. miR-122 was significantly under-expressed in liver samples of NASH subjects compared to controls^[5]. Overexpression of miR-122 in cell culture resulted in a significant decrease in lipogenic genes^[5]. Although miR-10b and miR-122 were found to regulate lipid content in hepatocyte cell cultures, serum expression patterns did not differ in patients with NASH in our study. The miR-34a expression pattern was not changed in our study, which was significantly overexpressed in NASH in human liver tissue^[5].

There is insufficient data on miR-181d in NAFLD. miR-181d may play a role in regulating the lipid content

Table 3 Point-biserial correlation coefficients between NAS-scale parameters and miRNAs in non-alcoholic fatty liver disease patients

| | miR-197 | miR-146b | miR-10b | miR-181d | miR-34a | miR-122 | miR-99a | miR-29a |
|--------------|---------------------|----------|---------------------|----------|---------|---------|---------|---------|
| Steatosis | 0.229 | 0.191 | 0.179 | 0.179 | 0.245 | 0.067 | 0.311 | 0.256 |
| Inflammation | -0.457 ¹ | -0.396 | -0.492 ¹ | -0.402 | -0.302 | -0.23 | -0.431 | -0.315 |
| Ballooning | 0.154 | 0.114 | 0.175 | 0.254 | 0.165 | -0.037 | -0.029 | 0.096 |
| Fibrosis | -0.112 | -0.171 | -0.213 | -0.098 | 0.033 | -0.137 | -0.197 | -0.103 |
| NAS | 0.051 | 0.015 | 0.035 | 0.069 | 0.124 | -0.027 | 0.074 | 0.041 |

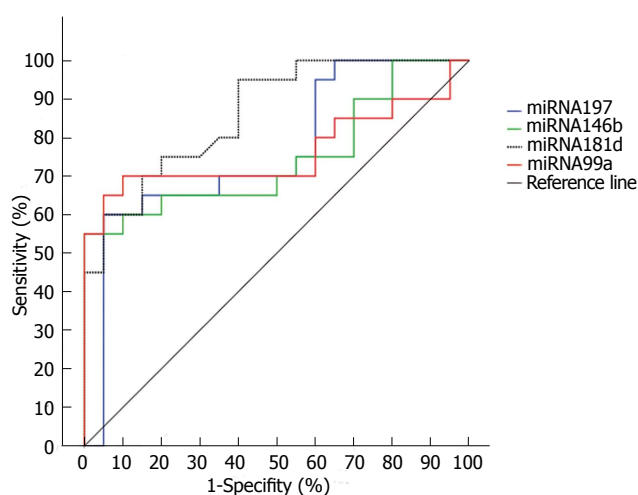
¹Correlation is significant at the 0.05 level (2-tailed).**Table 4** Correlation analysis between laboratory parameters and miRNAs in non-alcoholic fatty liver disease patients

| | miR-197 | miR-146b | miR-10b | miR-181d | miR-34a | miR-122 | miR-99a | miR-29a |
|--------------|---------|----------|---------|---------------------|---------|---------|---------------------|---------|
| AST | -0.257 | -0.331 | -0.225 | -0.252 | -0.084 | -0.225 | -0.138 | -0.322 |
| ALT | -0.131 | -0.147 | -0.080 | -0.215 | 0.122 | 0.103 | 0.077 | -0.143 |
| GGT | -0.327 | -0.225 | -0.303 | -0.464 ¹ | -0.29 | -0.231 | -0.479 ¹ | -0.221 |
| Triglyceride | 0.008 | -0.039 | 0.009 | -0.035 | -0.075 | 0.087 | -0.239 | -0.058 |
| HDL-C | 0.027 | 0.051 | -0.031 | 0.042 | 0.052 | 0.111 | 0.16 | 0.034 |
| LDL-C | 0.078 | 0.042 | 0.067 | 0.015 | 0.139 | 0.102 | 0.213 | 0.155 |
| HOMA-IR | -0.055 | 0.117 | 0.011 | -0.015 | 0.195 | 0.205 | 0.221 | 0.177 |

¹Correlation is significant at the 0.05 level (2-tailed). ALT: Alanine aminotransferase; AST: Aspartate aminotransferase; HOMA-IR: Homeostasis model assessment insulin resistance index; GGT: Gamma glutamyl transferase; HDL-C: High density lipoprotein cholesterol; LDL-C: Low density lipoprotein cholesterol.**Table 5** Statistical diagnostic measures for miR-197, miR-146b, miR-181d and miR-99a in identifying non-alcoholic fatty liver disease

| miRNA | Cut-off value | SEN (95%CI) | SPE (95%CI) | PPV (95%CI) | NPV (95%CI) |
|----------|---------------|------------------|--------------------|--------------------|------------------|
| miR-197 | ≤ -1.0144 | 60.0 (36.1-80.9) | 95.0 (75.1-99.9) | 92.3 (64.0-99.8) | 70.4 (49.8-86.2) |
| miR-146b | ≤ -0.7689 | 55.0 (31.6-76.9) | 100.0 (83.0-100.0) | 100.0 (71.3-100.0) | 69.0 (49.2-84.7) |
| miR-181d | ≤ -0.2861 | 70.0 (45.7-88.0) | 85.0 (62.1-96.6) | 82.4 (56.6-96.0) | 73.9 (51.6-89.7) |
| miR-99a | ≤ -0.1562 | 65.0 (40.8-84.5) | 95.0 (75.1-99.2) | 92.9 (66.1-98.8) | 73.1 (52.2-88.4) |

SEN: Sensitivity; SPE: Specificity; PPV: Positive predictive value; NPV: Negative predictive value.

**Figure 3** Comparison of area under receiver operating characteristic curve values of miR-197, miR-146b, miR-181d and miR-99a miRNA's in the detection of non-alcoholic fatty liver disease. Area under receiver operating characteristic values were 0.77 (0.60-0.88), 0.75 (0.59-0.87), 0.86 (0.72-0.95), and 0.76 (0.60-0.88), respectively, and there was no statistically significant difference between any two miRNAs ($P > 0.05$).

of hepatocytes. miR-181d has been shown to decrease lipid droplets, and to reduce cellular triglycerides and

cholesterol ester in cell culture^[9]. In our study, serum levels of miR-181d were decreased in NAFLD by 2.49-fold compared to controls. Estep *et al*^[10] studied miRNA expression in the visceral adipose tissue of patients with NAFLD. They found that significant changes in miRNA expression were characterized by overall down-regulation in the visceral adipose tissue. They also found that down-regulation of miR-197 and miR-99 in the visceral adipose tissue was significantly associated with pericellular fibrosis in NAFLD patients. We also found that miR-99 and miR-197 were down-regulated in the serum of NASH patients, but we did not find any relationship between fibrosis stages. A study conducted by Klöting *et al*^[11] showed that the human adipose tissue level of miR-99a negatively correlated with FFA levels. NAFLD is significantly associated with obesity, type II diabetes mellitus, and the metabolic syndrome. Serum FFA levels are elevated in all of these disorders^[16]. It was reported that the main source for TG in hepatocytes was derived from circulating FFAs in NAFLD^[17]. Although we did not analyze serum fatty acid levels in our study, down-regulation of miR-99a in NASH was concordant with this evidence. Chartoumpakis *et al*^[12] examined miRNA profiling after long-term high-fat diet-induced obesity in mice and found that miR-146a and miR-146b were up-regulated in adipose tissue.

In one study, the miR-146a expression levels were significantly decreased in peripheral blood mononuclear cells from patients with Type 2 diabetes compared to control subjects. They also reported that reduced miR-146a levels are associated with insulin resistance and poor glycemic control^[18]. Although miR-146a and miR-146b are encoded on different chromosomes, their mRNA targets are predicted to overlap significantly^[19]. The data in this study showed decreased miR-146b levels which seems reasonable in light of these findings.

During our research, the study by Cermelli *et al.*^[20] showed that serum levels of miR-122, miR-34a and miR-16 were significantly higher in NAFLD patients. They also found that miR-122 and miR-34a levels were correlated with liver enzyme levels, fibrosis stage and inflammation activity in NAFLD. These findings regarding miR-122 and miR-34a were not confirmed by our study results. This may be attributed to patient selection. We did not include hypertensive patients due to their impaired miRNA profile^[21,22].

The current study provides evidence that biopsy proven NAFLD is associated with altered serum miRNA expression. The potential targets of differentially expressed miRNAs are known to play a role in metabolism, immune function, cell proliferation, apoptosis, tissue development and differentiation; all these are key processes involved in the development and progression of NASH^[5]. While our findings do not provide direct proof of the involvement of these differentially expressed miRNAs in the development, progression and systemic effect of NASH, they serve as a resource for future studies on the role of miRNAs in the non-invasive assessment of NASH. This was a principal aim of this study.

The pattern of miRNA expression can be affected by hypertension^[21,22]. This possibility was minimized by excluding patients with hypertension. The miRNA expression pattern is also possibly affected by the development of cirrhosis. We excluded patients with cirrhosis from this study. We want to point out that the aim of this study was to determine whether biopsy proven NAFLD was associated with altered serum miRNA expression without hypertension. Therefore, only subjects without hypertension were studied. At the same time, this study does not provide any information on the serum miRNA expression pattern in those with isolated hepatic steatosis due to insufficient funding. Differential expression of microRNA with two distinct clinical entities, in simple steatosis and NASH, may exist. It will be very interesting to investigate the serum expression pattern of miRNA in simple steatosis and NASH. In addition, this study had a cross-sectional design. Due to the financial constraints we selected these eight miRNAs from earlier studies which were related to NAFLD progression and pathogenesis and were also related to serum FFA, insulin resistance and adipose tissue.

This study showed the following: (1) miR-181d, miR-99a, miR-197 and miR-146b expression was significantly lower in the serum of biopsy proven NAFLD patients than in healthy controls; (2) The serum levels of miR-197

and miR-10b were inversely correlated with degree of inflammation; and (3) miR-181d and miR-99a were inversely correlated with serum GGT levels in NASH patients. In conclusion, biopsy proven NAFLD is associated with an altered serum miRNA expression pattern. This study provides clues for defining the non-invasive diagnosis of NAFLD.

COMMENTS

Background

Due to the limitations of liver biopsy, the use of non-invasive markers has emerged in recent years. MicroRNAs (miRNAs) are a class of naturally occurring small noncoding RNAs that regulate gene expression. Altered miRNA expression has been reported in animal and human liver samples in non-alcoholic fatty liver disease (NAFLD). There is, however, only limited information regarding their detection in blood and their correlation with histological disease severity in patients with NAFLD.

Research frontiers

miRNAs are a class of naturally occurring small noncoding RNAs of approximately 22 nucleotides in length that regulate gene expression either by promoting mRNA degradation or by attenuating protein translation. miRNAs can influence NAFLD through pathways involving inflammation, fibrosis, insulin resistance, lipid metabolism and the metabolic syndrome. A research hotspot is the evaluation of miRNAs to determine hepatic damage and fibrosis in patients with NAFLD.

Innovations and breakthroughs

miR-181d, miR-99a, miR-197 and miR-146b were expressed at lower levels in non-alcoholic steatohepatitis (NASH) patients than in controls. Serum levels of miR-197 and miR-10b were inversely correlated with degree of inflammation and miR-181d and miR-99a were inversely correlated with serum gamma glutamyl transferase levels in NASH patients.

Applications

Biopsy proven NAFLD is associated with an altered serum miRNA expression pattern. This study provides clues for defining the non-invasive diagnosis of NAFLD.

Terminology

NAFLD is the most common cause of chronic liver disease in Western populations. It comprises a disease spectrum which includes variable degrees of simple steatosis (fatty liver), NASH and cirrhosis which are likely to be characterized by different pathogenesis and clinical history. The identification of novel non-invasive biomarkers for NAFLD is needed. miRNAs are a class of naturally occurring small noncoding RNAs of approximately 22 nucleotides in length that regulate gene expression either by promoting mRNA degradation or by attenuating protein translation. miRNAs can influence NAFLD through pathways involving inflammation, fibrosis, insulin resistance, lipid metabolism and the metabolic syndrome.

Peer review

This is a good descriptive study in which authors evaluate the serum miRNA levels to determine hepatic damage and fibrosis in patients with NAFLD. The results are interesting and suggest that miRNAs may be useful to determine hepatic inflammation with a non-invasive tool in NAFLD patients. The data analysis and presentation were appropriate, and the manuscript was well prepared.

REFERENCES

- 1 Yilmaz Y. Is nonalcoholic fatty liver disease the hepatic expression of the metabolic syndrome? *World J Hepatol* 2012; 4: 332-334 [PMID: 23355910 DOI: 10.4254/wjh.v4.i12.332]
- 2 Esteller M. Non-coding RNAs in human disease. *Nat Rev Genet* 2011; 12: 861-874 [PMID: 22094949 DOI: 10.1038/nrg3074]
- 3 Shrivastava S, Mukherjee A, Ray RB. Hepatitis C virus infection, microRNA and liver disease progression. *World J Hepatol* 2013; 5: 479-486 [PMID: 24073299 DOI: 10.4254/wjh.v5.i9.479]
- 4 Li S, Chen X, Zhang H, Liang X, Xiang Y, Yu C, Zen K, Li Y,

- Zhang CY. Differential expression of microRNAs in mouse liver under aberrant energy metabolic status. *J Lipid Res* 2009; **50**: 1756-1765 [PMID: 19372595 DOI: 10.1194/jlr.M800509-JLR200]
- 5 **Cheung O**, Puri P, Eicken C, Contos MJ, Mirshahi F, Maher JW, Kellum JM, Min H, Luketic VA, Sanyal AJ. Nonalcoholic steatohepatitis is associated with altered hepatic MicroRNA expression. *Hepatology* 2008; **48**: 1810-1820 [PMID: 19030170 DOI: 10.1002/hep.22569]
 - 6 **Li YY**. Genetic and epigenetic variants influencing the development of nonalcoholic fatty liver disease. *World J Gastroenterol* 2012; **18**: 6546-6551 [PMID: 23236228 DOI: 10.3748/wjg.v18.i45.6546]
 - 7 **Roderburg C**, Urban GW, Bettermann K, Vucur M, Zimmermann H, Schmidt S, Janssen J, Koppe C, Knolle P, Castoldi M, Tacke F, Trautwein C, Luedde T. Micro-RNA profiling reveals a role for miR-29 in human and murine liver fibrosis. *Hepatology* 2011; **53**: 209-218 [PMID: 20890893 DOI: 10.1002/hep.23922]
 - 8 **Zheng L**, Lv GC, Sheng J, Yang YD. Effect of miRNA-10b in regulating cellular steatosis level by targeting PPAR-alpha expression, a novel mechanism for the pathogenesis of NAFLD. *J Gastroenterol Hepatol* 2010; **25**: 156-163 [PMID: 19780876 DOI: 10.1111/j.1440-1746.2009.05949.x]
 - 9 **Whittaker R**, Loy PA, Sisman E, Suyama E, Aza-Blanc P, Ingermanson RS, Price JH, McDonough PM. Identification of MicroRNAs that control lipid droplet formation and growth in hepatocytes via high-content screening. *J Biomol Screen* 2010; **15**: 798-805 [PMID: 20639500 DOI: 10.1177/1087057110374991]
 - 10 **Estep M**, Armistead D, Hossain N, Elarainy H, Goodman Z, Baranova A, Chandhoke V, Younossi ZM. Differential expression of miRNAs in the visceral adipose tissue of patients with non-alcoholic fatty liver disease. *Aliment Pharmacol Ther* 2010; **32**: 487-497 [PMID: 20497147 DOI: 10.1111/j.1365-2036.2010.04366.x]
 - 11 **Klötting N**, Berthold S, Kovacs P, Schön MR, Fasshauer M, Ruschke K, Stumvoll M, Blüher M. MicroRNA expression in human omental and subcutaneous adipose tissue. *PLoS One* 2009; **4**: e4699 [PMID: 19259271 DOI: 10.1371/journal.pone.0004699]
 - 12 **Chartoumpekis DV**, Zaravinos A, Ziros PG, Iskrenova RP, Psyrogiannis AI, Kyriazopoulou VE, Habeos IG. Differential expression of microRNAs in adipose tissue after long-term high-fat diet-induced obesity in mice. *PLoS One* 2012; **7**: e34872 [PMID: 22496873 DOI: 10.1371/journal.pone.0034872]
 - 13 **Sanyal AJ**, Brunt EM, Kleiner DE, Kowdley KV, Chalasani N, Lavine JE, Ratzliff V, McCullough A. Endpoints and clinical trial design for nonalcoholic steatohepatitis. *Hepatology* 2011; **54**: 344-353 [PMID: 21520200 DOI: 10.1002/hep.24376]
 - 14 **Kleiner DE**, Brunt EM, Van Natta M, Behling C, Contos MJ, Cummings OW, Ferrell LD, Liu YC, Torbenson MS, Unalp-Arida A, Yeh M, McCullough AJ, Sanyal AJ. Design and validation of a histological scoring system for nonalcoholic fatty liver disease. *Hepatology* 2005; **41**: 1313-1321 [PMID: 15915461 DOI: 10.1002/hep.20701]
 - 15 **Livak KJ**, Schmittgen TD. Analysis of relative gene expression data using real-time quantitative PCR and the 2(-Delta Delta C(T)) Method. *Methods* 2001; **25**: 402-408 [PMID: 11846609 DOI: 10.1006/meth.2001.1262]
 - 16 **Bradbury MW**. Lipid metabolism and liver inflammation. I. Hepatic fatty acid uptake: possible role in steatosis. *Am J Physiol Gastrointest Liver Physiol* 2006; **290**: G194-G198 [PMID: 16407588 DOI: 10.1152/ajpgi.00413.2005]
 - 17 **Donnelly KL**, Smith CI, Schwarzenberg SJ, Jessurun J, Boldt MD, Parks EJ. Sources of fatty acids stored in liver and secreted via lipoproteins in patients with nonalcoholic fatty liver disease. *J Clin Invest* 2005; **115**: 1343-1351 [PMID: 15864352 DOI: 10.1172/JCI23621]
 - 18 **Balasubramanyam M**, Aravind S, Gokulakrishnan K, Prabu P, Sathishkumar C, Ranjani H, Mohan V. Impaired miR-146a expression links subclinical inflammation and insulin resistance in Type 2 diabetes. *Mol Cell Biochem* 2011; **351**: 197-205 [PMID: 21249428 DOI: 10.1007/s11010-011-0727-3]
 - 19 **Hurst DR**, Edmonds MD, Welch DR. Metastamir: the field of metastasis-regulatory microRNA is spreading. *Cancer Res* 2009; **69**: 7495-7498 [PMID: 19773429 DOI: 10.1158/0008-5472.CAN-09-2111]
 - 20 **Cermelli S**, Ruggieri A, Marrero JA, Ioannou GN, Beretta L. Circulating microRNAs in patients with chronic hepatitis C and non-alcoholic fatty liver disease. *PLoS One* 2011; **6**: e23937 [PMID: 21886843 DOI: 10.1371/journal.pone.0023937]
 - 21 **Yamakuchi M**. MicroRNAs in Vascular Biology. *Int J Vasc Med* 2012; **2012**: 794898 [PMID: 23056947 DOI: 10.1155/2012/794898]
 - 22 **Schroen B**, Heymans S. MicroRNAs and beyond: the heart reveals its treasures. *Hypertension* 2009; **54**: 1189-1194 [PMID: 19841290 DOI: 10.1161/HYPERTENSIONAHA.109.133942]

P- Reviewer: Ampuero J, Dirchwolf M, Ikura Y, Kobylak NK, Lin CW
S- Editor: Wen LL **L- Editor:** Webster JR
E- Editor: Wu HL



Early termination of immune tolerance state of hepatitis B virus infection explains liver damage

Mamun-Al-Mahtab, Sheikh Mohammad Fazle Akbar, Helal Uddin, Sakirul Islam Khan, Salimur Rahman

Mamun-Al-Mahtab, Salimur Rahman, Department of Hepatology, Bangabandhu Sheikh Mujib Medical University, Dhaka 1000, Bangladesh

Sheikh Mohammad Fazle Akbar, Department of Medical Sciences, Toshiba General Hospital, Tokyo 140-0013, Japan

Helal Uddin, Clinical Research Organization, Dhaka 1213, Bangladesh

Sakirul Islam Khan, Department of Anatomy and Embryology, Ehime University Graduate School of Medicine, Ehime 791-0295, Japan

Author contributions: All authors contributed to this paper.

Correspondence to: Dr. Mamun-Al-Mahtab, Associate Professor of Hepatology, Bangabandhu Sheikh Mujib Medical University, Shahbagh Rd, Dhaka 1000, Bangladesh. shwapnil@agni.com

Telephone: +880-171-1567275

Received: February 22, 2014 Revised: April 24, 2014

Accepted: June 10, 2014

Published online: August 27, 2014

Abstract

AIM: To assess an early termination of immune tolerance state of chronic hepatitis B virus infection in Bangladesh and its clinical significance.

METHODS: From a series of 167 treatment-naïve chronic hepatitis B patients aged between 12 to 20 years (mean \pm SD; 17.5 ± 2.8 years), percutaneous liver biopsies of 89 patients who were all hepatitis B e antigen negative at presentation were done. Of them, 81 were included in the study. They had persistently normal or raised serum alanine aminotransferase (ALT) values. A precore mutation (PCM) study was accomplished in 8 patients who were randomly selected.

RESULTS: Forty-four (53.7%) patients had significant necroinflammation (HAI-NI > 7), while significant fibrosis (HAI-F ≥ 3) was seen in 15 (18.5%) patients. Serum ALT (cut off 42 U/L) was raised in 29 (35.8%) patients, while low HBV DNA load ($< 10^5$ copies/mL)

was observed in 57 (70.4%) patients. PCM was negative in all 8 patients.

CONCLUSION: This study indicates that the current concept of age-related immune tolerance state of HBV infection deserves further analyses in different population groups.

© 2014 Baishideng Publishing Group Inc. All rights reserved.

Key words: Chronic hepatitis B; Immune tolerance; Early termination

Core tip: Immune tolerance phase usually prevails for up to 20-25 years in subjects with chronic hepatitis B virus (HBV) infection. However, the present study showed that considerable numbers of chronic HBV-infected patients of Bangladesh lost hepatitis B e antigen and developed anti-HBe. Early termination of immune tolerance phase of these young patients was also associated with elevated alanine aminotransferase, hepatic necroinflammation and considerable hepatic fibrosis in some patients. Treatment guidelines are warranted for these patients as there is a paucity of information about their entity.

Mahtab MA, Akbar SMF, Uddin H, Khan SI, Rahman S. Early termination of immune tolerance state of hepatitis B virus infection explains liver damage. *World J Hepatol* 2014; 6(8): 621-625 Available from: URL: <http://www.wjgnet.com/1948-5182/full/v6/i8/621.htm> DOI: <http://dx.doi.org/10.4254/wjh.v6.i8.621>

INTRODUCTION

Maybe nearly 2 billion people have been infected with hepatitis B virus (HBV) worldwide. The clinical manifestations vary widely with asymptomatic acute viral B hepatitis at one end and hepatocellular carcinoma (HCC) at

the other. There are about 400 million chronic HBV carriers worldwide. Of them, 75%-80% resides in Asia and the Western Pacific region. HBV is responsible for over one million deaths per year globally. It is a major cause of cirrhosis of liver and HCC worldwide^[1].

Although there is a paucity of information about a nation-wide survey regarding HBV prevalence in Bangladesh, published data show that about 5%-6% of apparently healthy individuals are HBV carriers in Bangladesh^[2-4]. There may be about 6-8 million chronic HBV carriers in Bangladesh and most of them are unaware of their disease. In intermediate prevalence countries like Bangladesh, lifetime risk of acquiring HBV infection is above 40%^[1].

The precore/core region of the HBV genome encodes the nucleocapsid protein (HBcAg) and hepatitis B e antigen (HBeAg)^[5,6]. The biological role of HBeAg in HBV replication cycle is uncertain. Expression of HBeAg is nonessential for virus replication in animal models^[7] and in humans^[8]. In utero exposure to HBeAg can induce immune tolerance in newborn mice^[9]. Mutations in the precore region of the HBV genome have been described^[10-12] resulting in HBeAg negative HBV infection. The core promoter region (nucleotides 1742 to 1849) has an important role in HBV replication as well as HBeAg production^[13] and mutations in this region commonly lead to HBeAg negative HBV infection^[14].

Chronic HBV infection can be divided into different phases, which may not be sequential. Patients may present: (1) in a state of immune tolerance; (2) with hepatitis B e antigen (HBeAg)-positive chronic HBV; (3) with HBeAg-negative chronic HBV; or (4) as an inactive hepatitis B surface antigen (HBsAg) carrier. A state of immune tolerance with minimum liver damage is usually seen in chronic HBV carriers until 25 years of age.

The present study was accomplished to evaluate the biochemical, virological and immunological statuses of young chronic HBV carriers in Bangladesh. It seems that there may be an early termination of immune tolerance state of HBV in Bangladesh. However, there is no therapeutic recommendation for these young HBV-infected patients. Here, we provide evidence suggesting that considerable numbers of these patients should be treated as otherwise they may develop complications of chronic HBV infection.

MATERIALS AND METHODS

Patients

One hundred and sixty-seven treatment naive young chronic HBV-infected patients, aged between 12 and 20 years (17.5 ± 2.8 years, $n = 167$), were enrolled in this study. At presentation they were asymptomatic with no features of chronic liver disease. They were all HBsAg positive either at vaccination, school health screening or family screening. All of them had at least two HBsAg positive results at a minimum of 6 mo apart.

Of these patients, 89 were HBeAg negative, while the others tested positive for HBeAg. They were all negative

for serological markers of hepatitis C virus, IgM antibodies to hepatitis A virus and hepatitis E viruses. Also, they had no history of alcohol consumption and no evidence of pregnancy. None of the patients had received an antiviral drug for treatment of HBV infection. The Ethical Committee of Farabi General Hospital, Dhaka, Bangladesh gave ethical approval for the study. The nature and purpose of the study were explained to all patients or their guardians in the case of minors. Informed written consent for undergoing percutaneous liver biopsy was obtained. Patients were excluded from further analyses if an adequate amount of liver tissue (*i.e.*, 1.0 cm) was not available at liver biopsy^[15]. Eight patients were excluded from final analyses as adequate amounts of liver tissue were not available from them. Thus, a total of 81 HBeAg negative chronic hepatitis B (CHB) patients were included for final analyses.

Biochemical and serological tests

The level of ALT in serum was measured by auto-analyzer (Microlab 300, Vitalab Micro Series, Vital Scientific NV, The Netherlands). The cut off for the upper limit of normal (ULN) was ALT 42 U/L. HBsAg was assessed using an ELISA kit (Diasorin, Fallugia, Italy). HBeAg was checked in the sera using an ELISA kit (Abbott Labs, Chicago, IL, USA).

Quantification of serum HBV DNA level

First, HBV DNA was extracted from the patient's serum. It was then amplified by polymerase chain reaction (PCR) and detected using fluorescent reporter dye probes specific for HBV (Amplicon HBV Monitor Assay, Roche Molecular Systems, CA, United States). The lower limit of detection was 250 copies of HBV DNA/mL.

Amplification of the pre-core region by the PCR

Oligonucleotide primers were synthesized in a 380B DNA synthesizer (Applied Biosystems Japan, Tokyo, Japan). PCR was performed by a modification of the procedure originally described by Saiki *et al.*^[16]. Briefly, 10 μ L of the DNA sample was heated at 95 °C for 7 min to denature proteases, spun in a microcentrifuge for 5 seconds and allowed to cool at room temperature. Target sequences were amplified in a 100- μ L reaction volume with the use of the Gene Amp DNA amplification reagent kit (Perkin-Elmer Cetus, Norwalk, Conn., United States), as recommended by the manufacturer. The amplification was carried on for 30 cycles in a programmable DNA thermal cycler (Perkin-Elmer Cetus). The reaction was allowed to proceed at 94 °C for 1 min, at 55 °C for 1.5 min, and at 72 °C for 3 min in each cycle. In the last cycle, the reaction at 72 °C was continued for 10 min to ensure complete DNA extension.

Liver biopsy

Percutaneous liver biopsy was performed under local anesthesia using a 16G Tru-cut biopsy needle (Cardinal Health, McGaw Park, IL, United States). A biopsy specimen of more than 1.0 cm in length with five to six portal

Table 1 Baseline characteristics of study population

| Parameters | |
|--|---------------------------------|
| Total number of patients | 81 |
| Male | 60 ^a (74%) |
| Female | 21 (26%) |
| Age (yr) | 17.5 ± 2.8 (12-20) |
| ALT ≤ 42 (U/L) | 52 ^a (65.2%) (13-42) |
| ALT > 42 (U/L) | 29 (34.8%) (44-281) |
| DNA ≤ 100000 (copies/mL) | 57 ^a (70.4%) |
| DNA > 100000 (copies/mL) | 24 (29.6%) |
| Non-significant hepatic necroinflammation (HAI-NI ≤ 7) | 44 (53.8%) |
| Significant hepatic necroinflammation (HAI-NI > 7) | 37 (45.7%) |
| Non-significant hepatic fibrosis (HAI-F < 3) | 66 ^a (81%) |
| Significant hepatic fibrosis (HAI-F ≥ 3) | 15 (18.5%) |
| Cirrhosis | 2/15 |

Figure in the round bracket indicates the percentage and the square bracket indicates range. ^a $P < 0.05$ vs same parameter. HAI-NI: Histologic activity index-necroinflammation; ALT: Alaninaminotransferase; HAI-F: Histologic activity index-fibrosis.

tracts was evaluated. Histology was graded according to histological activity index (HAI) using the criteria of Knodell *et al*^[17]. The total HAI score comprises necroinflammation (HAI-NI) and fibrosis (HAI-F) scores. The HAI-NI scale includes three components (0-10, piecemeal necrosis; 0-4, lobular necrosis and inflammation; 0-4, portal inflammation). HAI-F was graded according to severity: 0, absence of fibrosis; 1, fibrous portal expansion; 3, bridging fibrosis; 4, cirrhosis.

Statistical analysis

Data are shown as mean ± SD. Means were compared using the Student's *t* test. For differences determined by the *F* test, the *t* test was adjusted for unequal variances (Mann-Whitney's *U* test). $P < 0.05$ was considered statistically significant.

RESULTS

A total of 81 patients with HBeAg-negative chronic HBV infection were enrolled in this study as a sufficient amount of liver biopsy specimens could be collected from these patients. The baseline data of these patients is given in Table 1. Sixty of them (74%) were male and the remaining 21 were female (26%). The numbers of male patients were significantly higher than females (60 vs 21, $P < 0.05$). The age of the patients was 17.5 ± 2.8 years ($n = 81$). The levels of ALT were below ULN in 52 patients (65.2%) (28.7 ± 8.6 IU/L, range, 13-42 IU/L) and ALT levels were above ULN in the remaining 29 patients (34.8%) (79.7 ± 47.4 IU/L; range, 44-281 IU/L, $P < 0.05$). The levels of HBV DNA varied considerably among patients, ranging from 779 copies/mL to 1.4×10^{12} copies/mL. In 57 patients (70.4%), the levels of HBV DNA were less than 100000 copies/mL whereas these were more than 100000 copies/mL in 24 patients (29.6%). Considering 100000 copies HBV DNA as a cut-off point

of "high level" of HBV DNA, significantly higher levels of patients had low levels of HBV DNA (HBV DNA < 100000 copies/mL) compared to patients with high levels of HBV DNA (HBV DNA > 100000 copies/mL) ($P < 0.05$).

Significant levels of hepatic necroinflammation (HAI-NI > 7) were detected in 37 of 81 patients (46%) (Table 1) and this was not statistically different with patients with low hepatic necroinflammation (44 patients, $P > 0.05$). Significant levels of hepatic fibrosis (HAI-F ≥ 3) were detected in the liver biopsy specimens of 15 patients (19%). Among these, cirrhosis of liver was detected in two patients (Table 1).

DISCUSSION

Our study reveals that young HBeAg negative CHB patients can have significant necroinflammation and/or fibrosis in the liver. This is in contrast to our existing understanding of clinical course of chronic HBV infection that patients in the immunotolerance age group tend to have no significant hepatic pathology.

Although the study shows that a significant proportion of our patients were at risk of developing more severe liver diseases, they were not aware of this scenario. More importantly, no major guideline recommends treatment of this group of patients^[18]. Similar studies have been conducted in different parts of the world to assess the extent of a similar scenario. Kumar *et al*^[19] from India showed that more than 50% of their 1387 incidentally-detected chronic HBV carriers had evidence of progressive liver diseases for which treatment was indicated. A similar outcome has also been reported from Pakistan, Egypt and other countries^[20-25].

There are studies from Bangladesh, India, South Korea and Turkey suggesting that HBeAg negative CHB patients as a whole tend to develop more significant liver fibrosis than those who are HBeAg positive^[26-30].

An exact explanation for such a high incidence of HBeAg negative infection in our young chronic HBV infected population of the immunotolerant age group is difficult to reach. All 8 patients in our series, who were randomly picked up, tested negative for precore mutation. However, in Bangladesh most HBV infections are acquired early in life, either soon after birth or at a pre-school age^[1]. This possibly leads to early termination of an immune tolerance state in our population.

Non-alcoholic fatty liver disease (NAFLD) is now regarded as a leading cause of chronic liver disease in Bangladesh, perhaps second only to HBV infection. The incidence of non-alcoholic steatohepatitis (NASH) in our NAFLD patients is 88.5%^[31]. Co-existence of NASH and CHB may also be responsible for significant hepatic injury in many of the apparently healthy chronic HBV infected population; however, this is an area that needs much more exploration. Finally, viral genotype may also be responsible^[32].

Although many patients included in this present study were suitable candidates for anti-viral treatment, they are

usually not considered for treatment owing to complex socio-economic problems, social taboos and lack of scientific information. However, we recommend that all HBV-infected patients, irrespective of their age, should be properly evaluated for anti-HBV therapy.

Our study has a few limitations. One is that HBV DNA, ALT and liver histology were assessed only once. Serial assessment of virological, biochemical and histological parameters would provide more insight into the natural disease course in these patients. Our main aim was to gain an insight into the pathogenesis of these patients to initiate a strategy for their management. We found that a considerable number of young Bangladeshi HBV infected individuals have significant liver damage. This is important evidence to convince physicians and policy makers in developing countries to develop a management strategy for such patients.

In conclusion, chronic HBV infection is a complex disease entity and here we describe a group of such patients whose clinical course is not well studied and is difficult to explain. Although considered to be apparently healthy, a proportion of them are eligible for treatment. They not only pose a threat to themselves. In fact, in the fragile health economics of the developing world, they simply give rise to more questions than answers. As clinical hepatologists of the developing world, it remains our responsibility to look into these issues in further detail and develop a strategy for their appropriate management.

COMMENTS

Background

The immune tolerance phase usually persists for 20-25 years in chronic hepatitis B virus (HBV) infected subjects. However, early termination of the immune tolerance phase is seen in clinics.

Research frontiers

The clinical, biochemical, virological and histological aspects of young chronic HBV-infected patients of Bangladeshi origin were analyzed.

Innovations and breakthroughs

Early termination of the immune tolerance phase was detected in considerable numbers of chronic HBV-infected patients in this cohort. Many of them also developed progressive liver damage and increased fibrosis.

Applications

The management of these patients remains a major challenge as they express anti-HBe, a marker usually considered to have a better prognosis in the context of chronic HBV infection.

Terminology

Immune tolerance phase: HBV infected patients expressing hepatitis B e antigen, high HBV DNA but no liver damage.

Peer review

The article is properly written, endeavored and well constructed. Although there are an inadequate number of patients, it is an interesting article in terms of having insight on regional data.

REFERENCES

- 1 **Yahyapour Y**, Karimi M, Molaei HR, Khoddami E, Mahmoudi M. Active-passive Immunization Effectiveness Against Hepatitis B Virus in Children Born to HBsAg Positive Mothers in Amol, North of Iran. *Oman Med J* 2011; **26**: 399-403 [PMID: 22253947 DOI: 10.5001/omj.2011.103]
- 2 **Rudra S**, Chakrabarty P, Poddar B. Prevalence of hepatitis B and hepatitis C virus infection in human of Mymensingh, Bangladesh. *Mymensingh Med J* 2011; **20**: 183-186 [PMID: 21522084]
- 3 **Ashraf H**, Alam NH, Rothermundt C, Brooks A, Bardhan P, Hossain L, Salam MA, Hassan MS, Beglinger C, Gyr N. Prevalence and risk factors of hepatitis B and C virus infections in an impoverished urban community in Dhaka, Bangladesh. *BMC Infect Dis* 2010; **10**: 208 [PMID: 20630111]
- 4 **Mahtab MA**, Rahman S, Karim MF, Khan M, Foster G, Solaiman S, Afroz S. Epidemiology of hepatitis B virus in Bangladeshi general population. *Hepatobiliary Pancreat Dis Int* 2008; **7**: 595-600 [PMID: 19073404]
- 5 **Uy A**, Bruss V, Gerlich WH, Köchel HG, Thomssen R. Pre-core sequence of hepatitis B virus inducing e antigen and membrane association of the viral core protein. *Virology* 1986; **155**: 89-96 [PMID: 3535236 DOI: 10.1016/0042-6822(86)90170-4]
- 6 **Ou JH**, Laub O, Rutter WJ. Hepatitis B virus gene function: the precore region targets the core antigen to cellular membranes and causes the secretion of the e antigen. *Proc Natl Acad Sci USA* 1986; **83**: 1578-1582 [PMID: 3006057 DOI: 10.1073/pnas.83.6.1578]
- 7 **Ganem D**, Varmus HE. The molecular biology of the hepatitis B viruses. *Annu Rev Biochem* 1987; **56**: 651-693 [PMID: 3039907 DOI: 10.1146/annurev.bi.56.070187.003251]
- 8 **Tong SP**, Li JS, Vitvitski L, Trépo C. Replication capacities of natural and artificial precore stop codon mutants of hepatitis B virus: relevance of pregenome encapsidation signal. *Virology* 1992; **191**: 237-245 [PMID: 1413504 DOI: 10.1016/0042-6822(92)90185-R]
- 9 **Milich DR**, Jones JE, Hughes JL, Price J, Raney AK, McLachlan A. Is a function of the secreted hepatitis B e antigen to induce immunologic tolerance in utero? *Proc Natl Acad Sci USA* 1990; **87**: 6599-6603 [PMID: 2395863 DOI: 10.1073/pnas.87.17.6599]
- 10 **Carman WF**, Jacyna MR, Hadziyannis S, Karayiannis P, McGarvey MJ, Makris A, Thomas HC. Mutation preventing formation of hepatitis B e antigen in patients with chronic hepatitis B infection. *Lancet* 1989; **2**: 588-591 [PMID: 2570285 DOI: 10.1016/S0140-6736(89)90713-7]
- 11 **Akahane Y**, Yamanaka T, Suzuki H, Sugai Y, Tsuda F, Yotsumoto S, Omi S, Okamoto H, Miyakawa Y, Mayumi M. Chronic active hepatitis with hepatitis B virus DNA and antibody against e antigen in the serum. Disturbed synthesis and secretion of e antigen from hepatocytes due to a point mutation in the precore region. *Gastroenterology* 1990; **99**: 1113-1119 [PMID: 2394332]
- 12 **Brunetto MR**, Giarin MM, Oliveri F, Chiaberge E, Baldi M, Alfarano A, Serra A, Saracco G, Verme G, Will H. Wild-type and e antigen-minus hepatitis B viruses and course of chronic hepatitis. *Proc Natl Acad Sci USA* 1991; **88**: 4186-4190 [PMID: 2034663 DOI: 10.1073/pnas.88.10.4186]
- 13 **Yuh CH**, Chang YL, Ting LP. Transcriptional regulation of precore and pregenomic RNAs of hepatitis B virus. *J Virol* 1992; **66**: 4073-4084 [PMID: 1602534]
- 14 **Okamoto H**, Tsuda F, Akahane Y, Sugai Y, Yoshida M, Moriyama K, Tanaka T, Miyakawa Y, Mayumi M. Hepatitis B virus with mutations in the core promoter for an e antigen-negative phenotype in carriers with antibody to e antigen. *J Virol* 1994; **68**: 8102-8110 [PMID: 7966600]
- 15 **Shiha G**, Sarin SK, Ibrahim AE, Omata M, Kumar A, Lesmana LA, Leung N, Tozun N, Hamid S, Jafri W, Maruyama H, Bedossa P, Pinzani M, Chawla Y, Esmat G, Doss W, Elzanaty T, Sakhuja P, Nasr AM, Omar A, Wai CT, Abdallah A, Salama M, Hamed A, Yousry A, Waked I, Elshahar M, Fateen A, Mogawer S, Hamdy H, Elwakil R. Liver fibrosis: consensus recommendations of the Asian Pacific Association for the Study of the Liver (APASL). *Hepatol Int* 2009; **3**: 323-333 [PMID: 19669358]
- 16 **Saiki RK**, Gelfand DH, Stoffel S, Scharf SJ, Higuchi R, Horn

- GT, Mullis KB, Erlich HA. Primer-directed enzymatic amplification of DNA with a thermostable DNA polymerase. *Science* 1988; **239**: 487-491 [PMID: 2448875 DOI: 10.1126/science.2448875]
- 17 **Knodel RG**, Ishak KG, Black WC, Chen TS, Craig R, Kaplowitz N, Kiernan TW, Wollman J. Formulation and application of a numerical scoring system for assessing histological activity in asymptomatic chronic active hepatitis. *Hepatology* 1981; **1**: 431-435 [PMID: 7308988 DOI: 10.1002/hep.1840010511]
- 18 **Liaw YF**, Leung N, Kao JH, Piratvisuth T, Gane E, Han KH, Guan R, Lau GK, Locarnini S. Asian-Pacific consensus statement on the management of chronic hepatitis B: a 2008 update. *Hepatol Int* 2008; **2**: 263-283 [PMID: 19669255]
- 19 **Kumar M**, Sarin SK, Hissar S, Pande C, Sakhuja P, Sharma BC, Chauhan R, Bose S. Virologic and histologic features of chronic hepatitis B virus-infected asymptomatic patients with persistently normal ALT. *Gastroenterology* 2008; **134**: 1376-1384 [PMID: 18471514 DOI: 10.1053/j.gastro.2008.02.075]
- 20 **Khokar N**, Gill ML. Serological profile of incidentally detected asymptomatic HBsAg positive subjects (ADAHS). *J Coll Physicians Surg Pak* 2004; **14**: 208-210 [PMID: 15228822]
- 21 **El-Zayadi AR**, Badran HM, Saied A, Shawky S, Attia Mel-D, Zalata K. Evaluation of liver biopsy in Egyptian HBeAg-negative chronic hepatitis B patients at initial presentation: implications for therapy. *Am J Gastroenterol* 2009; **104**: 906-911 [PMID: 19293791 DOI: 10.1038/ajg.2009.30]
- 22 **Papatheodoridis GV**, Manesis EK, Manolakopoulos S, Elefsiniotis IS, Goulis J, Giannousis J, Bilalis A, Kafiri G, Tzourmakliotis D, Archimandritis AJ. Is there a meaningful serum hepatitis B virus DNA cutoff level for therapeutic decisions in hepatitis B e antigen-negative chronic hepatitis B virus infection? *Hepatology* 2008; **48**: 1451-1459 [PMID: 18924246 DOI: 10.1002/hep.22518]
- 23 **Tai DI**, Lin SM, Sheen IS, Chu CM, Lin DY, Liaw YF. Long-term outcome of hepatitis B e antigen-negative hepatitis B surface antigen carriers in relation to changes of alanine aminotransferase levels over time. *Hepatology* 2009; **49**: 1859-1867 [PMID: 19378345 DOI: 10.1002/hep.22878]
- 24 **Hui CK**, Leung N, Yuen ST, Zhang HY, Leung KW, Lu L, Cheung SK, Wong WM, Lau GK. Natural history and disease progression in Chinese chronic hepatitis B patients in immune-tolerant phase. *Hepatology* 2007; **46**: 395-401 [PMID: 17628874 DOI: 10.1002/hep.21724]
- 25 **Andreani T**, Serfaty L, Mohand D, Dernaika S, Wendum D, Chazouillères O, Poupon R. Chronic hepatitis B virus carriers in the immunotolerant phase of infection: histologic findings and outcome. *Clin Gastroenterol Hepatol* 2007; **5**: 636-641 [PMID: 17428739 DOI: 10.1016/j.cgh.2007.01.005]
- 26 **Mahtab MA**, Rahman S. Correlation between HAI score and HBeAg in chronic hepatitis B. *Digestive Dis Sci* 2005; **50** (Abstract): 1993-1994
- 27 **Mahtab MA**, Rahman S, Khan M, Mamun AA, Kamal M. Pre-core/core Promoter mutant hepatitis B virus produces more severe histologic liver disease than wild type hepatitis B virus. *Hungarian Med J* 2007; **1**: 41-46 [DOI: 10.1556/HMJ.1.2007.1.6]
- 28 **Sakhuja P**, Malhotra V, Gondal R, Sarin SK, Guptan R, Thakur V. Histological spectrum of chronic hepatitis in pre-core mutants and wild-type hepatitis B virus infection. *Trop Doct* 2004; **34**: 147-149 [PMID: 15267041]
- 29 **Kim TH**, Kim YS, Yeom JJ, Cho EY, Kim HS, Kim HC, Park DS, Cho JH, Yoon GJ, Moon HB. [Relevancy between liver injury, serum HBV-DNA, and intrahepatic HBeAg in young male chronic HBV carriers]. *Korean J Gastroenterol* 2004; **44**: 84-92 [PMID: 15329519]
- 30 **Yalçin K**, Degertekin H, Alp MN, Tekeş S, Satici O, Budak T. Determination of serum hepatitis B virus DNA in chronic HBsAg carriers: clinical significance and correlation with serological markers. *Turk J Gastroenterol* 2003; **14**: 157-163 [PMID: 14655057]
- 31 **Mahtab MA**, Rahman S, Karim MF, Hussain MF, Khan M, Kamal M. Prevalence of non-alcoholic steatohepatitis in patients with non-alcoholic fatty liver disease: Experience from a tertiary centre in Bangladesh. *J Gastroenterol Hepatol* 2008; **23** (Abstract): 47
- 32 **Kumar SI**, Rahman S, Kamal M, Khan M, Aggarwal R. Hepatitis B genotypes virus among chronically infected patients in a tertiary-care hospital in Bangladesh. *Indian J Gastroenterol* 2006; **25**: 219-221 [PMID: 16974050]

P- Reviewer: Rodriguez-Frias F, Sener A, Taylor JM
S- Editor: Song XX **L- Editor:** Roemmele A **E- Editor:** Wu HL





INSTRUCTIONS TO AUTHORS

GENERAL INFORMATION

World Journal of Hepatology (*World J Hepatol*, *WJH*, online ISSN 1948-5182, DOI: 10.4254) is a peer-reviewed open access (OA) academic journal that aims to guide clinical practice and improve diagnostic and therapeutic skills of clinicians.

Aim and scope

WJH covers topics concerning arrhythmia, heart failure, vascular disease, stroke, hypertension, prevention and epidemiology, dyslipidemia and metabolic disorders, cardiac imaging, pediatrics, nursing, and health promotion. Priority publication will be given to articles concerning diagnosis and treatment of hepatology diseases. The following aspects are covered: Clinical diagnosis, laboratory diagnosis, differential diagnosis, imaging tests, pathological diagnosis, molecular biological diagnosis, immunological diagnosis, genetic diagnosis, functional diagnostics, and physical diagnosis; and comprehensive therapy, drug therapy, surgical therapy, interventional treatment, minimally invasive therapy, and robot-assisted therapy.

We encourage authors to submit their manuscripts to *WJH*. We will give priority to manuscripts that are supported by major national and international foundations and those that are of great basic and clinical significance.

WJH is edited and published by Baishideng Publishing Group (BPG). BPG has a strong professional editorial team composed of science editors, language editors and electronic editors. BPG currently publishes 43 OA clinical medical journals, including 42 in English, has a total of 15471 editorial board members or peer reviewers, and is a world first-class publisher.

Columns

The columns in the issues of *WJH* will include: (1) Editorial: The editorial board members are invited to make comments on an important topic in their field in terms of its current research status and future directions to lead the development of this discipline; (2) Frontier: The editorial board members are invited to select a highly cited cutting-edge original paper of his/her own to summarize major findings, the problems that have been resolved and remain to be resolved, and future research directions to help readers understand his/her important academic point of view and future research directions in the field; (3) Diagnostic Advances: The editorial board members are invited to write high-quality diagnostic advances in their field to improve the diagnostic skills of readers. The topic covers general clinical diagnosis, differential diagnosis, pathological diagnosis, laboratory diagnosis, imaging diagnosis, endoscopic diagnosis, biotechnological diagnosis, functional diagnosis, and physical diagnosis; (4) Therapeutics Advances: The editorial board members are invited to write high-quality therapeutic advances in their field to help improve the therapeutic skills of readers. The topic covers medication therapy, psychotherapy, physical therapy, replacement therapy, interventional therapy, minimally invasive therapy, endoscopic therapy, transplantation therapy, and surgical therapy; (5) Field of Vision: The editorial board members are invited to write commentaries on classic articles, hot topic articles, or latest articles to keep readers at the forefront of research and increase their levels of clinical research. Classic articles refer to papers that are included in Web of Knowledge and have received a large number of citations (ranking in the top 1%) after being published for more than years, reflecting the quality and impact of papers. Hot topic articles refer to papers that are included in Web of Knowledge and have received a large number of citations after being

published for no more than 2 years, reflecting cutting-edge trends in scientific research. Latest articles refer to the latest published high-quality papers that are included in PubMed, reflecting the latest research trends. These commentary articles should focus on the status quo of research, the most important research topics, the problems that have now been resolved and remain to be resolved, and future research directions. Basic information about the article to be commented (including authors, article title, journal name, year, volume, and inclusive page numbers); (6) Minireviews: The editorial board members are invited to write short reviews on recent advances and trends in research of molecular biology, genomics, and related cutting-edge technologies to provide readers with the latest knowledge and help improve their diagnostic and therapeutic skills; (7) Review: To make a systematic review to focus on the status quo of research, the most important research topics, the problems that have now been resolved and remain to be resolved, and future research directions; (8) Topic Highlight: The editorial board members are invited to write a series of articles (7-10 articles) to comment and discuss a hot topic to help improve the diagnostic and therapeutic skills of readers; (9) Medical Ethics: The editorial board members are invited to write articles about medical ethics to increase readers' knowledge of medical ethics. The topic covers international ethics guidelines, animal studies, clinical trials, organ transplantation, etc.; (10) Clinical Case Conference or Clinicopathological Conference: The editorial board members are invited to contribute high-quality clinical case conference; (11) Original Articles: To report innovative and original findings in hepatology; (12) Research Report: To briefly report the novel and innovative findings in hepatology; (13) Meta-Analysis: Covers the systematic review, mixed treatment comparison, meta-regression, and overview of reviews, in order to summarize a given quantitative effect, e.g., the clinical effectiveness and safety of clinical treatments by combining data from two or more randomized controlled trials, thereby providing more precise and externally valid estimates than those which would stem from each individual dataset if analyzed separately from the others; (14) Case Report: To report a rare or typical case; (15) Letters to the Editor: To discuss and make reply to the contributions published in *WJH*, or to introduce and comment on a controversial issue of general interest; (16) Book Reviews: To introduce and comment on quality monographs of hepatology; and (17) Autobiography: The editorial board members are invited to write their autobiography to provide readers with stories of success or failure in their scientific research career. The topic covers their basic personal information and information about when they started doing research work, where and how they did research work, what they have achieved, and their lessons from success or failure.

Name of journal

World Journal of Hepatology

ISSN

ISSN 1948-5182 (online)

Launch date

October 31, 2009

Frequency

Monthly

Editors-in-Chief

Clara Balsano, PhD, Professor, Departement of Biomedicine,

Instructions to authors

Institute of Molecular Biology and Pathology, Rome 00161, Italy

Wan-Long Chuang, MD, PhD, Doctor, Professor, Hepatobiliary Division, Department of Internal Medicine, Kaohsiung Medical University Hospital, Kaohsiung Medical University, Kaohsiung 807, Taiwan

Editorial office

Jin-Lei Wang, Director
Xiu-Xia Song, Vice Director
World Journal of Hepatology
Room 903, Building D, Ocean International Center,
No. 62 Dongsihuan Zhonglu, Chaoyang District,
Beijing 100025, China
Telephone: +86-10-59080039
Fax: +86-10-85381893
E-mail: editorialoffice@wjgnet.com
Help Desk: <http://www.wjgnet.com/esps/helpdesk.aspx>
<http://www.wjgnet.com>

Publisher

Baishideng Publishing Group Inc
8226 Regency Drive,
Pleasanton, CA 94588, USA
Telephone: +1-925-223-8242
Fax: +1-925-223-8243
E-mail: bpgoffice@wjgnet.com
Help Desk: <http://www.wjgnet.com/esps/helpdesk.aspx>
<http://www.wjgnet.com>

Instructions to authors

Full instructions are available online at http://www.wjgnet.com/1948-5182/g_info_20100316080002.htm.

Indexed and Abstracted in

PubMed Central, PubMed, Digital Object Identifier, Directory of Open Access Journals, and Scopus.

SPECIAL STATEMENT

All articles published in journals owned by the BPG represent the views and opinions of their authors, and not the views, opinions or policies of the BPG, except where otherwise explicitly indicated.

Biostatistical editing

Statistical review is performed after peer review. We invite an expert in Biomedical Statistics to evaluate the statistical method used in the paper, including *t*-test (group or paired comparisons), chi-squared test, Redit, probit, logit, regression (linear, curvilinear, or stepwise), correlation, analysis of variance, analysis of covariance, *etc.* The reviewing points include: (1) Statistical methods should be described when they are used to verify the results; (2) Whether the statistical techniques are suitable or correct; (3) Only homogeneous data can be averaged. Standard deviations are preferred to standard errors. Give the number of observations and subjects (*n*). Losses in observations, such as drop-outs from the study should be reported; (4) Values such as ED50, LD50, IC50 should have their 95% confidence limits calculated and compared by weighted probit analysis (Bliss and Finney); and (5) The word 'significantly' should be replaced by its synonyms (if it indicates extent) or the *P* value (if it indicates statistical significance).

Conflict-of-interest statement

In the interests of transparency and to help reviewers assess any potential bias, *WJH* requires authors of all papers to declare any competing commercial, personal, political, intellectual, or religious interests in relation to the submitted work. Referees are also asked to indicate any potential conflict they might have reviewing a particular paper. Before submitting, authors are suggested to read "Uniform Requirements for Manuscripts Submitted to Biomedical Journals: Ethical Considerations in the Conduct and Reporting of Research: Conflicts of Interest" from International Committee of Medical

Journal Editors (ICMJE), which is available at: http://www.icmje.org/ethical_4conflicts.html.

Sample wording: [Name of individual] has received fees for serving as a speaker, a consultant and an advisory board member for [names of organizations], and has received research funding from [names of organization]. [Name of individual] is an employee of [name of organization]. [Name of individual] owns stocks and shares in [name of organization]. [Name of individual] owns patent [patent identification and brief description].

Statement of informed consent

Manuscripts should contain a statement to the effect that all human studies have been reviewed by the appropriate ethics committee or it should be stated clearly in the text that all persons gave their informed consent prior to their inclusion in the study. Details that might disclose the identity of the subjects under study should be omitted. Authors should also draw attention to the Code of Ethics of the World Medical Association (Declaration of Helsinki, 1964, as revised in 2004).

Statement of human and animal rights

When reporting the results from experiments, authors should follow the highest standards and the trial should conform to Good Clinical Practice (for example, US Food and Drug Administration Good Clinical Practice in FDA-Regulated Clinical Trials; UK Medicines Research Council Guidelines for Good Clinical Practice in Clinical Trials) and/or the World Medical Association Declaration of Helsinki. Generally, we suggest authors follow the lead investigator's national standard. If doubt exists whether the research was conducted in accordance with the above standards, the authors must explain the rationale for their approach and demonstrate that the institutional review body explicitly approved the doubtful aspects of the study.

Before submitting, authors should make their study approved by the relevant research ethics committee or institutional review board. If human participants were involved, manuscripts must be accompanied by a statement that the experiments were undertaken with the understanding and appropriate informed consent of each. Any personal item or information will not be published without explicit consents from the involved patients. If experimental animals were used, the materials and methods (experimental procedures) section must clearly indicate that appropriate measures were taken to minimize pain or discomfort, and details of animal care should be provided.

SUBMISSION OF MANUSCRIPTS

Manuscripts should be typed in 1.5 line spacing and 12 pt. Book Antiqua with ample margins. Number all pages consecutively, and start each of the following sections on a new page: Title Page, Abstract, Introduction, Materials and Methods, Results, Discussion, Acknowledgements, References, Tables, Figures, and Figure Legends. Neither the editors nor the publisher are responsible for the opinions expressed by contributors. Manuscripts formally accepted for publication become the permanent property of Baishideng Publishing Group Co., Limited, and may not be reproduced by any means, in whole or in part, without the written permission of both the authors and the publisher. We reserve the right to copy-edit and put onto our website accepted manuscripts. Authors should follow the relevant guidelines for the care and use of laboratory animals of their institution or national animal welfare committee. For the sake of transparency in regard to the performance and reporting of clinical trials, we endorse the policy of the ICMJE to refuse to publish papers on clinical trial results if the trial was not recorded in a publicly-accessible registry at its outset. The only register now available, to our knowledge, is <http://www.clinicaltrials.gov> sponsored by the United States National Library of Medicine and we encourage all potential contributors to register with it. However, in the case that other registers become available you will be duly notified. A letter of recommendation from each author's organization should be provided with the contributed article to ensure the privacy and secrecy of research is protected.

Authors should retain one copy of the text, tables, photographs and illustrations because rejected manuscripts will not be returned to the author(s) and the editors will not be responsible

for loss or damage to photographs and illustrations sustained during mailing.

Online submissions

Manuscripts should be submitted through the Online Submission System at: <http://www.wjnet.com/esps/>. Authors are highly recommended to consult the ONLINE INSTRUCTIONS TO AUTHORS (http://www.wjnet.com/1948-5182/g_info_20100316080002.htm) before attempting to submit online. For assistance, authors encountering problems with the Online Submission System may send an email describing the problem to bpgoffice@wjnet.com, or by telephone: +86-10-85381892. If you submit your manuscript online, do not make a postal contribution. Repeated online submission for the same manuscript is strictly prohibited.

MANUSCRIPT PREPARATION

All contributions should be written in English. All articles must be submitted using word-processing software. All submissions must be typed in 1.5 line spacing and 12 pt. Book Antiqua with ample margins. Style should conform to our house format. Required information for each of the manuscript sections is as follows:

Title page

Title: Title should be less than 12 words.

Running title: A short running title of less than 6 words should be provided.

Authorship: Authorship credit should be in accordance with the standard proposed by ICMJE, based on (1) substantial contributions to conception and design, acquisition of data, or analysis and interpretation of data; (2) drafting the article or revising it critically for important intellectual content; and (3) final approval of the version to be published. Authors should meet conditions 1, 2, and 3.

Institution: Author names should be given first, then the complete name of institution, city, province and postcode. For example, Xu-Chen Zhang, Li-Xin Mei, Department of Pathology, Chengde Medical College, Chengde 067000, Hebei Province, China. One author may be represented from two institutions, for example, George Sgourakis, Department of General, Visceral, and Transplantation Surgery, Essen 45122, Germany; George Sgourakis, 2nd Surgical Department, Korgialenio-Benakio Red Cross Hospital, Athens 15451, Greece

Author contributions: The format of this section should be: Author contributions: Wang CL and Liang L contributed equally to this work; Wang CL, Liang L, Fu JF, Zou CC, Hong F and Wu XM designed the research; Wang CL, Zou CC, Hong F and Wu XM performed the research; Xue JZ and Lu JR contributed new reagents/analytic tools; Wang CL, Liang L and Fu JF analyzed the data; and Wang CL, Liang L and Fu JF wrote the paper.

Supportive foundations: The complete name and number of supportive foundations should be provided, e.g. Supported by National Natural Science Foundation of China, No. 30224801

Correspondence to: Only one corresponding address should be provided. Author names should be given first, then author title, affiliation, the complete name of institution, city, postcode, province, country, and email. All the letters in the email should be in lower case. A space interval should be inserted between country name and email address. For example, Montgomery Bissell, MD, Professor of Medicine, Chief, Liver Center, Gastroenterology Division, University of California, Box 0538, San Francisco, CA 94143, United States. montgomery.bissell@ucsf.edu

Telephone and fax: Telephone and fax should consist of +, country number, district number and telephone or fax number, e.g. Telephone: +86-10-85381892 Fax: +86-10-85381893

Peer reviewers: All articles received are subject to peer review. Normally, three experts are invited for each article. Decision on acceptance is made only when at least two experts recommend publication of an article. All peer-reviewers are acknowledged on Express Submission and Peer-review System website.

Abstract

There are unstructured abstracts (no less than 200 words) and structured abstracts. The specific requirements for structured abstracts are as follows:

An informative, structured abstract should accompany each manuscript. Abstracts of original contributions should be structured into the following sections: AIM (no more than 20 words; Only the purpose of the study should be included. Please write the Aim in the form of "To investigate/study/..."), METHODS (no less than 140 words for Original Articles; and no less than 80 words for Brief Articles), RESULTS (no less than 150 words for Original Articles and no less than 120 words for Brief Articles; You should present *P* values where appropriate and must provide relevant data to illustrate how they were obtained, e.g., 6.92 ± 3.86 vs 3.61 ± 1.67 , $P < 0.001$), and CONCLUSION (no more than 26 words).

Key words

Please list 5-10 key words, selected mainly from *Index Medicus*, which reflect the content of the study.

Core tip

Please write a summary of less than 100 words to outline the most innovative and important arguments and core contents in your paper to attract readers.

Text

For articles of these sections, original articles and brief articles, the main text should be structured into the following sections: INTRODUCTION, MATERIALS AND METHODS, RESULTS and DISCUSSION, and should include appropriate Figures and Tables. Data should be presented in the main text or in Figures and Tables, but not in both.

Illustrations

Figures should be numbered as 1, 2, 3, *etc.*, and mentioned clearly in the main text. Provide a brief title for each figure on a separate page. Detailed legends should not be provided under the figures. This part should be added into the text where the figures are applicable. Keeping all elements compiled is necessary in line-art image. Scale bars should be used rather than magnification factors, with the length of the bar defined in the legend rather than on the bar itself. File names should identify the figure and panel. Avoid layering type directly over shaded or textured areas. Please use uniform legends for the same subjects. For example: Figure 1 Pathological changes in atrophic gastritis after treatment. A: ...; B: ...; C: ...; D: ...; E: ...; F: ...; G: ...*etc.* It is our principle to publish high resolution-figures for the E-versions.

Tables

Three-line tables should be numbered 1, 2, 3, *etc.*, and mentioned clearly in the main text. Provide a brief title for each table. Detailed legends should not be included under tables, but rather added into the text where applicable. The information should complement, but not duplicate the text. Use one horizontal line under the title, a second under column heads, and a third below the Table, above any footnotes. Vertical and italic lines should be omitted.

Notes in tables and illustrations

Data that are not statistically significant should not be noted. ^a $P < 0.05$, ^b $P < 0.01$ should be noted ($P > 0.05$ should not be noted). If there are other series of *P* values, ^c $P < 0.05$ and ^d $P < 0.01$ are used. A third series of *P* values can be expressed as ^e $P < 0.05$ and ^f $P < 0.01$. Other notes in tables or under illustrations should be expressed as ¹F, ²F, ³F; or sometimes as other symbols with a superscript (Arabic numerals) in the upper left corner. In a multi-curve illustration, each curve

Instructions to authors

should be labeled with ●, ○, ■, ▲, △, etc., in a certain sequence.

Acknowledgments

Brief acknowledgments of persons who have made genuine contributions to the manuscript and who endorse the data and conclusions should be included. Authors are responsible for obtaining written permission to use any copyrighted text and/or illustrations.

REFERENCES

Coding system

The author should number the references in Arabic numerals according to the citation order in the text. Put reference numbers in square brackets in superscript at the end of citation content or after the cited author's name. For citation content which is part of the narration, the coding number and square brackets should be typeset normally. For example, "Crohn's disease (CD) is associated with increased intestinal permeability^[1,2]". If references are cited directly in the text, they should be put together within the text, for example, "From references^[19,22-24], we know that..."

When the authors write the references, please ensure that the order in text is the same as in the references section, and also ensure the spelling accuracy of the first author's name. Do not list the same citation twice.

PMID and DOI

Please provide PubMed citation numbers to the reference list, e.g. PMID and DOI, which can be found at <http://www.ncbi.nlm.nih.gov/sites/entrez?db=pubmed> and <http://www.crossref.org/SimpleTextQuery/>, respectively. The numbers will be used in E-version of this journal.

Style for journal references

Authors: the name of the first author should be typed in bold-faced letters. The family name of all authors should be typed with the initial letter capitalized, followed by their abbreviated first and middle initials. (For example, Lian-Sheng Ma is abbreviated as Ma LS, Bo-Rong Pan as Pan BR). The title of the cited article and italicized journal title (journal title should be in its abbreviated form as shown in PubMed), publication date, volume number (in black), start page, and end page [PMID: 11819634 DOI: 10.3748/wjg.13.5396].

Style for book references

Authors: the name of the first author should be typed in bold-faced letters. The surname of all authors should be typed with the initial letter capitalized, followed by their abbreviated middle and first initials. (For example, Lian-Sheng Ma is abbreviated as Ma LS, Bo-Rong Pan as Pan BR) Book title. Publication number. Publication place: Publication press, Year: start page and end page.

Format

Journals

English journal article (list all authors and include the PMID where applicable)

- 1 **Jung EM**, Clevert DA, Schreyer AG, Schmitt S, Rennert J, Kubale R, Feuerbach S, Jung F. Evaluation of quantitative contrast harmonic imaging to assess malignancy of liver tumors: A prospective controlled two-center study. *World J Gastroenterol* 2007; **13**: 6356-6364 [PMID: 18081224 DOI: 10.3748/wjg.13.6356]

Chinese journal article (list all authors and include the PMID where applicable)

- 2 **Lin GZ**, Wang XZ, Wang P, Lin J, Yang FD. Immunologic effect of Jianpi Yishen decoction in treatment of Pixu-diarhoea. *Shijie Huaren Xiaohua Zazhi* 1999; **7**: 285-287

In press

- 3 **Tian D**, Araki H, Stahl E, Bergelson J, Kreitman M. Signature of balancing selection in Arabidopsis. *Proc Natl Acad Sci USA* 2006; In press

Organization as author

- 4 **Diabetes Prevention Program Research Group**. Hypertension, insulin, and proinsulin in participants with impaired glu-

cose tolerance. *Hypertension* 2002; **40**: 679-686 [PMID: 12411462 PMID:2516377 DOI:10.1161/01.HYP.0000035706.28494.09]

Both personal authors and an organization as author

- 5 **Vallancien G**, Emberton M, Harving N, van Moorselaar RJ; Alf-One Study Group. Sexual dysfunction in 1, 274 European men suffering from lower urinary tract symptoms. *J Urol* 2003; **169**: 2257-2261 [PMID: 12771764 DOI:10.1097/01.ju.0000067940.76090.73]

No author given

- 6 21st century heart solution may have a sting in the tail. *BMJ* 2002; **325**: 184 [PMID: 12142303 DOI:10.1136/bmj.325.7357.184]

Volume with supplement

- 7 **Geraud G**, Spierings EL, Keywood C. Tolerability and safety of frovatriptan with short- and long-term use for treatment of migraine and in comparison with sumatriptan. *Headache Relat Res* 2002; **42** Suppl 2: S93-99 [PMID: 12028325 DOI:10.1046/j.1526-4610.42.s2.7.x]

Issue with no volume

- 8 **Banit DM**, Kaufer H, Hartford JM. Intraoperative frozen section analysis in revision total joint arthroplasty. *Clin Orthop Relat Res* 2002; **(401)**: 230-238 [PMID: 12151900 DOI:10.1097/00003086-200208000-00026]

No volume or issue

- 9 Outreach: Bringing HIV-positive individuals into care. *HRS-A Careaction* 2002; 1-6 [PMID: 12154804]

Books

Personal author(s)

- 10 **Sherlock S**, Dooley J. Diseases of the liver and biliary system. 9th ed. Oxford: Blackwell Sci Pub, 1993: 258-296

Chapter in a book (list all authors)

- 11 **Lam SK**. Academic investigator's perspectives of medical treatment for peptic ulcer. In: Swabb EA, Azabo S. Ulcer disease: investigation and basis for therapy. New York: Marcel Dekker, 1991: 431-450

Author(s) and editor(s)

- 12 **Breedlove GK**, Schorfheide AM. Adolescent pregnancy. 2nd ed. Wiczorek RR, editor. White Plains (NY): March of Dimes Education Services, 2001: 20-34

Conference proceedings

- 13 **Harnden P**, Joffe JK, Jones WG, editors. Germ cell tumours V. Proceedings of the 5th Germ cell tumours Conference; 2001 Sep 13-15; Leeds, UK. New York: Springer, 2002: 30-56

Conference paper

- 14 **Christensen S**, Oppacher F. An analysis of Koza's computational effort statistic for genetic programming. In: Foster JA, Lutton E, Miller J, Ryan C, Tettamanzi AG, editors. Genetic programming. EuroGP 2002: Proceedings of the 5th European Conference on Genetic Programming; 2002 Apr 3-5; Kinsdale, Ireland. Berlin: Springer, 2002: 182-191

Electronic journal (list all authors)

- 15 Morse SS. Factors in the emergence of infectious diseases. *Emerg Infect Dis* serial online, 1995-01-03, cited 1996-06-05; 1(1): 24 screens. Available from: URL: <http://www.cdc.gov/ncidod/eid/index.htm>

Patent (list all authors)

- 16 **Pagedas AC**, inventor; Ancel Surgical R&D Inc., assignee. Flexible endoscopic grasping and cutting device and positioning tool assembly. United States patent US 20020103498. 2002 Aug 1

Statistical data

Write as mean \pm SD or mean \pm SE.

Statistical expression

Express *t* test as *t* (in italics), *F* test as *F* (in italics), chi square test as χ^2 (in Greek), related coefficient as *r* (in italics), degree of freedom as *v* (in Greek), sample number as *n* (in italics), and probability as *P* (in italics).

Units

Use SI units. For example: body mass, m (B) = 78 kg; blood pressure, p (B) = 16.2/12.3 kPa; incubation time, t (incubation) = 96 h; blood glucose concentration, c (glucose) 6.4 ± 2.1 mmol/L; blood CEA mass concentration, p (CEA) = 8.6 24.5 $\mu\text{g/L}$; CO_2 volume fraction, 50 mL/L CO_2 , not 5% CO_2 ; likewise for 40 g/L formaldehyde, not 10% formalin; and mass fraction, 8 ng/g, *etc.* Arabic numerals such as 23, 243, 641 should be read 23243641.

The format for how to accurately write common units and quantum numbers can be found at: http://www.wjgnet.com/1948-5182/g_info_20100107115140.htm.

Abbreviations

Standard abbreviations should be defined in the abstract and on first mention in the text. In general, terms should not be abbreviated unless they are used repeatedly and the abbreviation is helpful to the reader. Permissible abbreviations are listed in Units, Symbols and Abbreviations: A Guide for Biological and Medical Editors and Authors (Ed. Baron DN, 1988) published by The Royal Society of Medicine, London. Certain commonly used abbreviations, such as DNA, RNA, HIV, LD50, PCR, HBV, ECG, WBC, RBC, CT, ESR, CSF, IgG, ELISA, PBS, ATP, EDTA, mAb, can be used directly without further explanation.

Italics

Quantities: t time or temperature, c concentration, A area, l length, m mass, V volume.

Genotypes: *gyrA*, *arg 1*, *c myc*, *c fos*, *etc.*

Restriction enzymes: *EcoRI*, *HindIII*, *BamHI*, *Kho I*, *Kpn I*, *etc.*

Biology: *H. pylori*, *E. coli*, *etc.*

Examples for paper writing

All types of articles' writing style and requirement will be found in the link: <http://www.wjgnet.com/esps/NavigationInfo.aspx?id=15>

RESUBMISSION OF THE REVISED MANUSCRIPTS

Authors must revise their manuscript carefully according to the revision policies of Baishideng Publishing Group Co., Limited. The revised version, along with the signed copyright transfer agreement, responses to the reviewers, and English language Grade A certificate (for non-native speakers of English), should be submitted to

the online system *via* the link contained in the e-mail sent by the editor. If you have any questions about the revision, please send e-mail to esps@wjgnet.com.

Language evaluation

The language of a manuscript will be graded before it is sent for revision. (1) Grade A: priority publishing; (2) Grade B: minor language polishing; (3) Grade C: a great deal of language polishing needed; and (4) Grade D: rejected. Revised articles should reach Grade A.

Copyright assignment form

Please download a Copyright assignment form from http://www.wjgnet.com/1948-5182/g_info_20100107114726.htm.

Responses to reviewers

Please revise your article according to the comments/suggestions provided by the reviewers. The format for responses to the reviewers' comments can be found at: http://www.wjgnet.com/1948-5182/g_info_20100107114601.htm.

Proof of financial support

For papers supported by a foundation, authors should provide a copy of the approval document and serial number of the foundation.

STATEMENT ABOUT ANONYMOUS PUBLICATION OF THE PEER REVIEWERS' COMMENTS

In order to increase the quality of peer review, push authors to carefully revise their manuscripts based on the peer reviewers' comments, and promote academic interactions among peer reviewers, authors and readers, we decide to anonymously publish the reviewers' comments and author's responses at the same time the manuscript is published online.

PUBLICATION FEE

WJH is an international, peer-reviewed, OA online journal. Articles published by this journal are distributed under the terms of the Creative Commons Attribution Non-commercial License, which permits use, distribution, and reproduction in any medium and format, provided the original work is properly cited. The use is non-commercial and is otherwise in compliance with the license. Authors of accepted articles must pay a publication fee. Publication fee: 698 USD per article. All invited articles are published free of charge.



Published by **Baishideng Publishing Group Inc**

8226 Regency Drive, Pleasanton, CA 94588, USA

Telephone: +1-925-223-8242

Fax: +1-925-223-8243

E-mail: bpgoffice@wjgnet.com

Help Desk: <http://www.wjgnet.com/esps/helpdesk.aspx>

<http://www.wjgnet.com>

