ISSN 1007-9327
CN 14-1219/R

WJG

World Journal of Gastroenterology®

Indexed and Abstracted in:
Current Contents®/Clinical Medicine, Science Citation Index Expanded (also known as SciSearch®), Journal Citation Reports®, Index Medicus, MEDLINE, PubMed, PubMed Central, Digital Object Identifier, and EMBASE/Excerpta Medica. ISI, Thomson Reuters, 2009 Impact Factor: 2.092 (33/65 Gastroenterology and Hepatology).

Volume 16 Number 26
July 14, 2010
World J Gastroenterol
2010 July 14; 16(26): 3219-3346
Online Submissions
www.wjgnet.com/1007-9327office
www.wjgnet.com
Printed on Acid-free Paper
世界胃腸病学杂志

A Weekly Journal of Gastroenterology and Hepatology

WJG World Journal of Gastroenterology

A peer-reviewed, online, open-access journal of gastroenterology and hepatology

Editorial Board

2010-2013

The *World Journal of Gastroenterology* Editorial Board consists of 1144 members, representing a team of worldwide experts in gastroenterology and hepatology. They are from 60 countries, including Albania (1), Argentina (8), Australia (29), Austria (14), Belgium (12), Brazil (10), Brunei Darussalam (1), Bulgaria (2), Canada (20), Chile (3), China (69), Colombia (1), Croatia (2), Cuba (1), Czech (4), Denmark (8), Ecuador (1), Egypt (2), Estonia (2), Finland (8), France (24), Germany (75), Greece (14), Hungary (10), India (26), Iran (6), Ireland (7), Israel (12), Italy (101), Japan (112), Jordan (1), Kuwait (1), Lebanon (3), Lithuania (2), Malaysia (1), Mexico (10), Moldova (1), Netherlands (29), New Zealand (2), Norway (11), Pakistan (2), Poland (11), Portugal (4), Romania (3), Russia (1), Saudi Arabia (3), Serbia (3), Singapore (10), South Africa (2), South Korea (32), Spain (38), Sweden (18), Switzerland (11), Thailand (1), Trinidad and Tobago (1), Turkey (24), United Arab Emirates (2), United Kingdom (82), United States (249), and Uruguay (1).

HONORARY EDITORS-IN-CHIEF
James L Boyer, *New Haven*
Ke-Ji Chen, *Beijing*
Martin H Floch, *New Haven*
Emmet B Keeffe, *Palo Alto*
Geng-Tao Liu, *Beijing*
Lein-Ray Mo, *Tainan*
Eamonn M Quigley, *Cork*
Rafiq A Sheikh, *Sacramento*
Nicholas J Talley, *Rochester*
Ming-Lung Yu, *Kaohsiung*

PRESIDENT AND EDITOR-IN-CHIEF
Lian-Sheng Ma, *Beijing*

ACADEMIC EDITOR-IN-CHIEF
Tauseef Ali, *Oklahoma City*
Mauro Bortolotti, *Bologna*
Tarkan Karakan, *Ankara*
Weekitt Kittisupamongkol, *Bangkok*
Anastasios Koulaouzidis, *Edinburgh*
Bo-Rong Pan, *Xi'an*
Sylvia LF Pender, *Southampton*
Max S Petrov, *Auckland*
George Y Wu, *Farmington*

STRATEGY ASSOCIATE EDITORS-IN-CHIEF
Peter Draganov, *Florida*
Hugh J Freeman, *Vancouver*
Maria C Gutiérrez-Ruiz, *Mexico*
Kazuhiro Hanazaki, *Kochi*
Akio Inui, *Kagoshima*
Kalpesh Jani, *Baroda*
Javier S Martin, *Punta del Este*
Natalia A Osna, *Omaha*
Wei Tang, *Tokyo*
Alan BR Thomson, *Edmonton*
Harry HX Xia, *Hanover*
Jesus K Yamamoto-Furusho, *Mexico*
Yoshio Yamaoka, *Houston*

ASSOCIATE EDITORS-IN-CHIEF
You-Yong Lu, *Beijing*
John M Luk, *Singapore*
Hiroshi Shimada, *Yokohama*

GUEST EDITORIAL BOARD MEMBERS
Chien-Jen Chen, *Taipei*
Yang-Yuan Chen, *Changhua*
Jen-Hwey Chiu, *Taipei*
Seng-Kee Chuah, *Kaohsiung*
Wan-Long Chuang, *Kaohsiun*
Ming-Chih Hou, *Taipei*
Kevin Cheng-Wen Hsiao, *Taipei*
Po-Shiuan Hsieh, *Taipei*
Tsung-Hui Hu, *Kaohsiung*
Wen-Hsin Huang, *Taichung*
Chao-Hung Hung, *Kaohsiung*
I-Rue Lai, *Taipei*
Teng-Yu Lee, *Taichung*
Ching Chung Lin, *Taipei*
Hui-Kang Liu, *Taipei*
Hon-Yi Shi, *Kaohsiung*
Chih-Chi Wang, *Kaohsiung*
Jin-Town Wang, *Taipei*
Cheng-Shyong Wu, *Chia-Yi*
Jaw-Ching Wu, *Taipei*
Jiunn-Jong Wu, *Tainan*
Ming-Shiang Wu, *Taipei*
Ta-Sen Yeh, *Taoyuan*
Hsu-Heng Yen, *Changhua*
Ming-Whei Yu, *Taipei*

MEMBERS OF THE EDITORIAL BOARD

Albania

Bashkim Resuli, *Tirana*

Argentina

Julio H Carri, *Córdoba*
Eduardo de Santibañes, *Buenos Aires*
Bernardo Frider, *Buenos Aires*
Carlos J Pirola, *Buenos Aires*
Bernabe Matias Quesada, *Buenos Aires*
Silvia Sookoian, *Buenos Aires*
Adriana M Torres, *Rosario*
Maria Ines Vaccaro, *Buenos Aires*

Australia

Leon Anton Adams, *Nedlands*
Richard Anderson, *Victoria*
Minoti V Apte, *New South Wales*
Andrew V Biankin, *Sydney*
Filip Braet, *Sydney*
Christopher Christophi, *Melbourne*
Philip G Dinning, *Koagarah*
Guy D Eslick, *Sydney*
Michael A Fink, *Melbourne*

Robert JL Fraser, *Daw Park*
Jacob George, *Westmead*
Mark D Gorrell, *Sydney*
Alexander G Heriot, *Melbourne*
Michael Horowitz, *Adelaide*
John E Kellow, *Sydney*
William Kemp, *Melbourne*
Finlay A Macrae, *Victoria*
Daniel Markovich, *Brisbane*
Vance Matthews, *Melbourne*
Phillip S Oates, *Perth*
Shan Rajendra, *Tasmania*
Rajvinder Singh, *Elizabeth Vale*
Ross C Smith, *Sydney*
Kevin J Spring, *Brisbane*
Nathan Subramaniam, *Brisbane*
Phil Sutton, *Melbourne*
Cuong D Tran, *North Adelaide*
Debbie Trinder, *Fremantle*
David Ian Watson, *Bedford Park*

Austria

Herwig R Cerwenka, *Graz*
Ashraf Dahaba, *Graz*
Peter Ferenci, *Vienna*
Valentin Fuhrmann, *Vienna*
Alfred Gangl, *Vienna*
Alexander M Hirschl, *Wien*
Kurt Lenz, *Linz*
Dietmar Öfner, *Salzburg*
Markus Peck-Radosavljevic, *Vienna*
Markus Raderer, *Vienna*
Stefan Riss, *Vienna*
Georg Roth, *Vienna*
Michael Trauner, *Graz*
Thomas Wild, *Kapellerfeld*

Belgium

Rudi Beyaert, *Gent*
Benedicte Y De Winter, *Antwerp*
Inge I Depoortere, *Leuven*
Olivier Detry, *Liège*
Philip Meuleman, *Ghent*
Marc Peeters, *De Pintelaan*
Freddy Penninckx, *Leuven*
Jean-Yves L Reginster, *Liège*
Mark De Ridder, *Brussels*
Etienne M Sokal, *Brussels*
Kristin Verbeke, *Leuven*
Eddie Wisse, *Keerbergen*

Brazil

José LF Caboclo, *São José do Rio Preto*
Roberto J Carvalho-Filho, *São Paulo*
Jaime Natan Eisig, *São Paulo*
Andre Castro Lyra, *Salvador*
Marcelo Lima Ribeiro, *Braganca Paulista*
Joao Batista Teixeira Rocha, *Santa Maria*
Heitor Rosa, *Goiania*
Damiao C Moraes Santos, *Rio de Janeiro*
Ana Cristina Simões e Silva, *Belo Horizonte*
Eduardo Garcia Vilela, *Belo Horizonte*

Brunei Darussalam

Vui Heng Chong, *Bandar Seri Begawan*

Bulgaria

Zahariy Krastev, *Sofia*
Mihaela Petrova, *Sofia*

Canada

Alain Bitton, *Montreal*
Michael F Byrne, *Vancouver*
Kris Chadee, *Calgary*
Wangxue Chen, *Ottawa*
Ram Prakash Galwa, *Ottawa*
Philip H Gordon, *Montreal*
Waliul Khan, *Ontario*
Qiang Liu, *Saskatoon*
John K Marshall, *Ontario*
Andrew L Mason, *Alberta*
Kostas Pantopoulos, *Quebec*
Nathalie Perreault, *Sherbrooke*
Baljinder Singh Salh, *Vancouver*
Eldon Shaffer, *Calgary*
Martin Storr, *Calgary*
Pingchang Yang, *Hamilton*
Eric M Yoshida, *Vancouver*
Claudia Zwingmann, *Montreal*

Chile

Marcelo A Beltran, *La Serena*
Xabier De Aretxabala, *Santiago*
Silvana Zanlungo, *Santiago*

China

Hui-Jie Bian, *Xi'an*
San-Jun Cai, *Shanghai*
Guang-Wen Cao, *Shanghai*
Xiao-Ping Chen, *Wuhan*
Chi-Hin Cho, *Hong Kong*
Zong-Jie Cui, *Beijing*
Jing-Yuan Fang, *Shanghai*
De-Liang Fu, *Shanghai*
Ze-Guang Han, *Shanghai*
Chun-Yi Hao, *Beijing*
Ming-Liang He, *Hong Kong*
Ching-Lung Lai, *Hong Kong*
Simon Law, *Hong Kong*
Yuk-Tong Lee, *Hong Kong*
En-Min Li, *Shantou*
Fei Li, *Beijing*
Yu-Yuan Li, *Guangzhou*
Zhao-Shen Li, *Shanghai*
Xing-Hua Lu, *Beijing*
Yi-Min Mao, *Shanghai*
Qin Su, *Beijing*
Paul Kwong-Hang Tam, *Hong Kong*
Yuk Him Tam, *Hong Kong*
Ren-Xiang Tan, *Nanjing*
Wei-Dong Tong, *Chongqing*
Eric WC Tse, *Hong Kong*
Fu-Sheng Wang, *Beijing*
Xiang-Dong Wang, *Shanghai*
Nathalie Wong, *Hong Kong*
Justin CY Wu, *Hong Kong*
Wen-Rong Xu, *Zhenjiang*
An-Gang Yang, *Xi'an*
Wei-Cheng You, *Beijing*
Chun-Qing Zhang, *Jinan*
Jian-Zhong Zhang, *Beijing*
Xiao-Peng Zhang, *Beijing*
Xuan Zhang, *Beijing*

Colombia

Germán Campuzano-Maya, *Medellín*

Croatia

Tamara Cacev, *Zagreb*
Marko Duvnjak, *Zagreb*

Cuba

Damian C Rodriguez, *Havana*

Czech

Jan Bures, *Hradec Kralove*
Milan Jirsa, *Praha*
Marcela Kopacova, *Hradec Kralove*
Pavel Trunečka, *Prague*

Denmark

Leif Percival Andersen, *Copenhagen*
Asbjørn M Drewes, *Aalborg*
Morten Frisch, *Copenhagen*
Jan Mollenhauer, *Odense*
Morten Hylander Møller, *Holte*
Søren Rafaelsen, *Vejle*
Jorgen Rask-Madsen, *Skodsborg*
Peer Wille-Jørgensen, *Copenhagen*

Ecuador

Fernando E Sempértegui, *Quito*

Egypt

Zeinab Nabil Ahmed, *Cairo*
Hussein M Atta, *El-Minia*

Estonia

Riina Salupere, *Tartu*
Tamara Vorobjova, *Tartu*

Finland

Saila Kauhanen, *Turku*

Thomas Kietzmann, *Oulu*
Kaija-Leena Kolho, *Helsinki*
Jukka-Pekka Mecklin, *Jyvaskyla*
Minna Nyström, *Helsinki*
Pauli Antero Puolakkainen, *Turku*
Juhani Sand, *Tampere*
Lea Veijola, *Helsinki*

France

Claire Bonithon-Kopp, *Dijon*
Lionel Bueno, *Toulouse*
Sabine Colnot, *Paris*
Catherine Daniel, *Lille Cedex*
Alexis Desmoulière, *Limoges*
Thabut Dominique, *Paris*
Francoise L Fabiani, *Angers*
Jean-Luc Faucheron, *Grenoble*
Jean Paul Galmiche, *Nantes cedex*
Boris Guiu, *Dijon*
Paul Hofman, *Nice*
Laurent Huwart, *Paris*
Juan Iovanna, *Marseille*
Abdel-Majid Khatib, *Paris*
Philippe Lehours, *Bordeaux*
Flavio Maina, *Marseille*
Patrick Marcellin, *Paris*
Rene Gerolami Santandera, *Marseille*
Annie Schmid-Alliana, *Nice cedex*
Alain L Servin, *Châtenay-Malabry*
Stephane Supiot, *Nantes*
Baumert F Thomas, *Strasbourg*
Jean-Jacques Tuech, *Rouen*
Frank Zerbib, *Bordeaux Cedex*

Germany

Erwin Biecker, *Siegburg*
Hubert Blum, *Freiburg*
Thomas Bock, *Tuebingen*
Dean Bogoevski, *Hamburg*
Elfriede Bollschweiler, *Köln*
Jürgen Borlak, *Hannover*
Christa Buechler, *Regensburg*
Jürgen Büning, *Lübeck*
Elke Cario, *Essen*
Bruno Christ, *Halle/Saale*
Christoph F Dietrich, *Bad Mergentheim*
Ulrich R Fölsch, *Kiel*
Nikolaus Gassler, *Aachen*
Markus Gerhard, *Munich*
Dieter Glebe, *Giessen*
Ralph Graeser, *Freiburg*
Axel M Gressner, *Aachen*
Nils Habbe, *Marburg*
Thilo Hackert, *Heidelberg*
Wolfgang Hagmann, *Heidelberg*
Dirk Haller, *Freising*
Philip D Hard, *Giessen*
Claus Hellerbrand, *Regensburg*
Klaus R Herrlinger, *Stuttgart*
Eberhard Hildt, *Berlin*
Andrea Hille, *Goettingen*
Joerg C Hoffmann, *Berlin*
Philipe N Khalil, *Munich*
Andrej Khandoga, *Munich*
Jorg Kleeff, *Munich*
Ingmar Königsrainer, *Tübingen*
Peter Konturek, *Erlangen*
Stefan Kubicka, *Hannover*
Joachim Labenz, *Siegen*
Michael Linnebacher, *Rostock*
Jutta Elisabeth Lüttges, *Riegelsberg*
Peter Malfertheiner, *Magdeburg*
Oliver Mann, *Hamburg*
Peter N Meier, *Hannover*
Sabine Mihm, *Göttingen*
Klaus Mönkemüller, *Bottrop*
Jonas Mudter, *Erlangen*
Sebastian Mueller, *Heidelberg*
Robert Obermaier, *Freiburg*
Matthias Ocker, *Erlangen*
Stephan Johannes Ott, *Kiel*
Gustav Paumgartner, *Munich*
Christoph Reichel, *Bad Brückenau*
Markus Reiser, *Bochum*
Steffen Rickes, *Magdeburg*
Elke Roeb, *Giessen*
Christian Rust, *Munich*
Hans Scherubl, *Berlin*
Martin K Schilling, *Homburg*
Joerg F Schlaak, *Essen*
Rene Schmidt, *Freiburg*
Andreas G Schreyer, *Regensburg*
Karsten Schulmann, *Bochum*
Henning Schulze-Bergkamen, *Mainz*
Manfred V Singer, *Mannheim*
Jens Standop, *Bonn*
Jurgen M Stein, *Frankfurt*
Ulrike S Stein, *Berlin*
Wolfgang R Stremmel, *Heidelberg*
Harald F Teutsch, *Ulm*
Hans L Tillmann, *Leipzig*
Christian Trautwein, *Aachen*
Joerg Trojan, *Frankfurt*
Arndt Vogel, *Hannover*
Siegfried Wagner, *Deggendorf*
Frank Ulrich Weiss, *Greifswald*
Fritz von Weizsäcker, *Berlin*
Thomas Wex, *Magdeburg*
Stefan Wirth, *Wuppertal*
Marty Zdichavsky, *Tübingen*

Greece

Helen Christopoulou-Aletra, *Thessaloniki*
T Choli-Papadopoulou, *Thessaloniki*
Tsianos Epameinondas, *Ioannina*
Ioannis Kanellos, *Thessaloniki*
Elias A Kouroumalis, *Heraklion*
Ioannis E Koutroubakis, *Heraklion*
Michael Koutsilieris, *Athens*
Andreas Larentzakis, *Athens*
Emanuel K Manesis, *Athens*
Spilios Manolakopoulos, *Athens*
Konstantinos Mimidis, *Alexandroupolis*
George Papatheodoridis, *Athens*
Spiros Sgouros, *Athens*
Evangelos Tsiambas, *Ag Paraskevi Attiki*

Hungary

György M Buzás, *Budapest*
László Czakó, *Szeged*
Gyula Farkas, *Szeged*
Peter Hegyi, *Szeged*
Peter L Lakatos, *Budapest*
Yvette Mándi, *Szeged*
Zoltan Rakonczay, *Szeged*
Ferenc Sipos, *Budapest*
Zsuzsa Szondy, *Debrecen*
Gabor Veres, *Budapest*

India

Philip Abraham, *Mumbai*
Vineet Ahuja, *New Delhi*
Giriraj Ratan Chandak, *Hyderabad*
Devinder Kumar Dhawan, *Chandigarh*
Radha K Dhiman, *Chandigarh*
Pankaj Garg, *Panchkula*
Pramod Kumar Garg, *New Delhi*
Debidas Ghosh, *Midnpore*
Uday C Ghoshal, *Lucknow*
Bhupendra Kumar Jain, *Delhi*
Ashok Kumar, *Lucknow*
Bikash Medhi, *Chandigarh*
Sri P Misra, *Allahabad*
Gopal Nath, *Varanasi*
Samiran Nundy, *New Delhi*
Jagannath Palepu, *Mumbai*
Vandana Panda, *Mumbai*
Benjamin Perakath, *Tamil Nadu*
Ramesh Roop Rai, *Jaipur*
Nageshwar D Reddy, *Hyderabad*
Barjesh Chander Sharma, *New Delhi*
Virendra Singh, *Chandigarh*
Rupjyoti Talukdar, *Guwahati*
Rakesh Kumar Tandon, *New Delhi*
Jai Dev Wig, *Chandigarh*

Iran

Mohammad Abdollahi, *Tehran*
Peyman Adibi, *Isfahan*
Seyed-Moayed Alavian, *Tehran*
Seyed Mohsen Dehghani, *Shiraz*
Reza Malekzadeh, *Tehran*
Alireza Mani, *Tehran*

Ireland

Billy Bourke, *Dublin*
Ted Dinan, *Cork*
Catherine Greene, *Dublin*
Ross McManus, *Dublin*
Anthony P Moran, *Galway*
Marion Rowland, *Dublin*

Israel

Simon Bar-Meir, *Hashomer*
Alexander Becker, *Afula*
Abraham R Eliakim, *Haifa*
Sigal Fishman, *Tel Aviv*
Boris Kirshtein, *Beer Sheva*
Eli Magen, *Ashdod*
Menachem Moshkowitz, *Tel-Aviv*
Assy Nimer, *Safed*
Shmuel Odes, *Beer Sheva*
Mark Pines, *Bet Dagan*
Ron Shaoul, *Haifa*
Ami D Sperber, *Beer-Sheva*

Italy

Donato F Altomare, *Bari*
Piero Amodio, *Padova*
Angelo Andriulli, *San Giovanni Rotondo*
Paolo Angeli, *Padova*
Bruno Annibale, *Rome*
Paolo Aurello, *Rome*
Salvatore Auricchio, *Naples*
Antonio Basoli, *Rome*
Claudio Bassi, *Verona*
Gabrio Bassotti, *Perugia*
Mauro Bernardi, *Bologna*
Alberto Biondi, *Rome*
Luigi Bonavina, *Milano*
Guglielmo Borgia, *Naples*
Roberto Berni Canani, *Naples*
Maria Gabriella Caruso, *Bari*
Fausto Catena, *Bologna*
Giuseppe Chiarioni, *Valeggio*
Michele Cicala, *Rome*
Dario Conte, *Milano*
Francesco Costa, *Pisa*
Antonio Craxì, *Palermo*
Salvatore Cucchiara, *Rome*
Giuseppe Currò, *Messina*
Mario M D'Elios, *Florence*
Mirko D'Onofrio, *Verona*
Silvio Danese, *Milano*
Roberto de Franchis, *Milano*
Paola De Nardi, *Milan*
Giovanni D De Palma, *Naples*
Giuliana Decorti, *Trieste*
Gianlorenzo Dionigi, *Varese*
Massimo Falconi, *Verona*
Silvia Fargion, *Milan*
Giammarco Fava, *Ancona*
Francesco Feo, *Sassari*
Alessandra Ferlini, *Ferrara*
Alessandro Ferrero, *Torino*
Mirella Fraquelli, *Milan*
Luca Frulloni, *Verona*
Giovanni B Gaeta, *Napoli*
Antonio Gasbarrini, *Rome*
Edoardo G Giannini, *Genoa*
Alessandro Granito, *Bologna*
Fabio Grizzi, *Milan*
Salvatore Gruttadauria, *Palermo*
Pietro Invernizzi, *Milan*
Achille Iolascon, *Naples*
Angelo A Izzo, *Naples*
Ezio Laconi, *Cagliari*
Giovanni Latella, *L'Aquila*
Massimo Levrero, *Rome*
Francesco Luzza, *Catanzaro*
Lucia Malaguarnera, *Catania*
Francesco Manguso, *Napoli*
Pier Mannuccio Mannucci, *Milan*
Giancarlo Mansueto, *Verona*
Giulio Marchesini, *Bologna*
Mara Massimi, *Coppito*
Giovanni Milito, *Rome*
Giuseppe Montalto, *Palermo*
Giovanni Monteleone, *Rome*
Luca Morelli, *Trento*
Giovanni Musso, *Torino*
Mario Nano, *Torino*
Gerardo Nardone, *Napoli*
Riccardo Nascimbeni, *Brescia*
Valerio Nobili, *Rome*
Fabio Pace, *Milan*
Nadia Peparini, *Rome*
Marcello Persico, *Naples*
Mario Pescatori, *Rome*
Raffaele Pezzilli, *Bologna*
Alberto Piperno, *Monza*
Anna C Piscaglia, *Rome*
Piero Portincasa, *Bari*
Michele Reni, *Milan*
Vittorio Ricci, *Pavia*
Oliviero Riggio, *Rome*
Mario Rizzetto, *Torino*
Ballarin Roberto, *Modena*
Gerardo Rosati, *Potenza*
Franco Roviello, *Siena*
Cesare Ruffolo, *Treviso*
Massimo Rugge, *Padova*
Marco Scarpa, *Padova*
C armelo Scarpignato, *Parma*
Giuseppe Sica, *Rome*
Marco Silano, *Rome*
Pierpaolo Sileri, *Rome*
Vincenzo Stanghellini, *Bologna*
Fiorucci Stefano, *Perugia*
Giovanni Tarantino, *Naples*
Alberto Tommasini, *Trieste*
Guido Torzilli, *Rozzano Milan*
Cesare Tosetti, *Porretta Terme*
Antonello Trecca, *Rome*
Vincenzo Villanacci, *Brescia*
Lucia Ricci Vitiani, *Rome*
Marco Vivarelli, *Bologna*

Japan

Kyoichi Adachi, *Izumo*
Yasushi Adachi, *Sapporo*
Takafumi Ando, *Nagoya*
Akira Andoh, *Otsu*
Masahiro Arai, *Tokyo*
Hitoshi Asakura, *Tokyo*
Kazuo Chijiiwa, *Miyazaki*
Yuichiro Eguchi, *Saga*
Itaru Endo, *Yokohama*
Munechika Enjoji, *Fukuoka*
Yasuhiro Fujino, *Akashi*
Mitsuhiro Fujishiro, *Tokyo*
Kouhei Fukushima, *Sendai*
Masanori Hatakeyama, *Tokyo*
Keiji Hirata, *Kitakyushu*
Toru Hiyama, *Higashihiroshima*
Masahiro Iizuka, *Akita*
Susumu Ikehara, *Osaka*
Kenichi Ikejima, *Bunkyo-ku*
Yutaka Inagaki, *Kanagawa*
Hiromi Ishibashi, *Nagasaki*
Shunji Ishihara, *Izumo*
Toru Ishikawa, *Niigata*
Toshiyuki Ishiwata, *Tokyo*
Hajime Isomoto, *Nagasaki*
Yoshiaki Iwasaki, *Okayama*
Satoru Kakizaki, *Gunma*
Terumi Kamisawa, *Tokyo*
Mototsugu Kato, *Sapporo*
Naoya Kato, *Tokyo*
Takumi Kawaguchi, *Kurume*
Yohei Kida, *Kainan*
Shogo Kikuchi, *Aichi*
Tsuneo Kitamura, *Chiba*
Takashi Kobayashi, *Tokyo*
Yasuhiro Koga, *Isehara*
Takashi Kojima, *Sapporo*
Norihiro Kokudo, *Tokyo*
Masatoshi Kudo, *Osaka*
Shin Maeda, *Tokyo*
Satoshi Mamori, *Hyogo*
Atsushi Masamune, *Sendai*
Yasushi Matsuzaki, *Tsukuba*
Kenji Miki, *Tokyo*
Toshihiro Mitaka, *Sapporo*
Hiroto Miwa, *Hyogo*
Kotaro Miyake, *Tokushima*
Manabu Morimoto, *Yokohama*
Yoshiharu Motoo, *Kanazawa*
Yoshiaki Murakami, *Hiroshima*
Yoshiki Murakami, *Kyoto*
Kunihiko Murase, *Tusima*
Akihito Nagahara, *Tokyo*
Yuji Naito, *Kyoto*
Atsushi Nakajima, *Yokohama*
Hisato Nakajima, *Tokyo*
Hiroki Nakamura, *Yamaguchi*
Shotaro Nakamura, *Fukuoka*
Akimasa Nakao, *Nagogya*
Shuhei Nishiguchi, *Hyogo*
Mikio Nishioka, *Niihama*
Keiji Ogura, *Tokyo*
Susumu Ohmada, *Maebashi*
Hirohide Ohnishi, *Akita*
Kenji Okajima, *Nagoya*
Kazuichi Okazaki, *Osaka*
Morikazu Onji, *Ehime*
Satoshi Osawa, *Hamamatsu*
Hidetsugu Saito, *Tokyo*
Yutaka Saito, *Tokyo*
Naoaki Sakata, *Sendai*
Yasushi Sano, *Chiba*
Tokihiko Sawada, *Tochigi*
Tomohiko Shimatan, *Hiroshima*
Yukihiro Shimizu, *Kyoto*
Shinji Shimoda, *Fukuoka*
Yoshio Shirai, *Niigata*
Masayuki Sho, *Nara*
Shoichiro Sumi, *Kyoto*
Hidekazu Suzuki, *Tokyo*
Masahiro Tajika, *Nagoya*
Yoshihisa Takahashi, *Tokyo*
Toshinari Takamura, *Kanazawa*
Hiroaki Takeuchi, *Kochi*
Yoshitaka Takuma, *Okayama*
Akihiro Tamori, *Osaka*
Atsushi Tanaka, *Tokyo*
Shinji Tanaka, *Hiroshima*
Satoshi Tanno, *Hokkaido*
Shinji Togo, *Yokohama*
Hitoshi Tsuda, *Tokyo*
Hiroyuki Uehara, *Osaka*
Masahito Uemura, *Kashihara*
Yoshiyuki Ueno, *Sendai*
Mitsuyoshi Urashima, *Tokyo*
Takuya Watanabe, *Niigata*
Satoshi Yamagiwa, *Niigata*
Taketo Yamaguchi, *Chiba*
Mitsunori Yamakawa, *Yamagata*
Takayuki Yamamoto, *Yokkaichi*
Yutaka Yata, *Maebashi*
Hiroshi Yoshida, *Tokyo*
Norimasa Yoshida, *Kyoto*
Yuichi Yoshida, *Osaka*
Kentaro Yoshika, *Toyoake*
Hitoshi Yoshiji, *Nara*
Katsutoshi Yoshizato, *Higashihiroshima*
Tomoharu Yoshizumi, *Fukuoka*

Jordan

Ismail Matalka, *Irbid*

Kuwait

Islam Khan, *Safat*

Lebanon

Bassam N Abboud, *Beirut*
Ala I Sharara, *Beirut*
Rita Slim, *Beirut*

Lithuania

Giedrius Barauskas, *Kaunas*
Limas Kupcinskas, *Kaunas*

Malaysia

Andrew Seng Boon Chua, *Ipoh*

Mexico

Richard A Awad, *Mexico*
Aldo Torre Delgadillo, *Mexico*
Diego Garcia-Compean, *Monterrey*
Paulino M Hernández Magro, *Celaya*
Miguel Angel Mercado, *Distrito Federal*
Arturo Panduro, *Jalisco*
Omar Vergara-Fernandez, *Tlalpan*
Saúl Villa-Trevio, *Mexico*

Moldova

Igor Mishin, *Kishinev*

Netherlands

Ulrich Beuers, *Amsterdam*
Lee Bouwman, *Leiden*
Albert J Bredenoord, *Nieuwegein*
Lodewijk AA Brosens, *Utrecht*
J Bart A Crusius, *Amsterdam*
Wouter de Herder, *Rotterdam*
Pieter JF de Jonge, *Rotterdam*
Robert J de Knegt, *Rotterdam*
Wendy W Johanna de Leng, *Utrecht*
Annemarie de Vries, *Rotterdam*
James CH Hardwick, *Leiden*
Frank Hoentjen, *Haarlem*
Misha Luyer, *Sittard*
Jeroen Maljaars, *Maastricht*
Gerrit A Meijer, *Amsterdam*
Servaas Morré, *Amsterdam*
Chris JJ Mulder, *Amsterdam*
John Plukker, *Groningen*
Albert Frederik Pull ter Gunne, *Tilburg*
Paul E Sijens, *Groningen*
BW Marcel Spanier, *Arnhem*
Shiri Sverdlov, *Maastricht*
Maarten Tushuizen, *Amsterdam*
Jantine van Baal, *Heidelberglaan*
Astrid van der Velde, *The Hague*
Karel van Erpecum, *Utrecht*
Loes van Keimpema, *Nijmegen*
Robert Christiaan Verdonk, *Groningen*
Erwin G Zoetendal, *Wageningen*

New Zealand

Andrew S Day, *Christchurch*

Norway

Olav Dalgard, *Oslo*
Trond Peder Flaten, *Trondheim*
Reidar Fossmark, *Trondheim*
Rasmus Goll, *Tromso*
Ole Høie, *Arendal*
Asle W Medhus, *Oslo*
Espen Melum, *Oslo*
Trine Olsen, *Tromso*
Eyvind J Paulssen, *Tromso*
Jon Arne Søreide, *Stavanger*
Kjetil Soreide, *Stavanger*

Pakistan

Shahab Abid, *Karachi*
Syed MW Jafri, *Karachi*

Poland

Marek Bebenek, *Wroclaw*
Tomasz Brzozowski, *Cracow*
Halina Cichoż-Lach, *Lublin*
Andrzej Dabrowski, *Bialystok*
Hanna Gregorek, *Warsaw*
Marek Hartleb, *Katowice*
Beata Jolanta Jablońska, *Katowice*
Stanislaw J Konturek, *Krakow*
Jan Kulig, *Krakow*
Dariusz M Lebensztejn, *Bialystok*
Julian Swierczynski, *Gdansk*

Portugal

Raquel Almeida, *Porto*
Ana Isabel Lopes, *Lisboa Codex*
Ricardo Marcos, *Porto*
Guida Portela-Gomes, *Estoril*

Romania

Dan L Dumitrascu, *Cluj*
Adrian Saftoiu, *Craiova*
Andrada Seicean, *Cluj-Napoca*

Russia

Vasiliy I Reshetnyak, *Moscow*

Saudi Arabia

Ibrahim A Al Mofleh, *Riyadh*
Abdul-Wahed Meshikhes, *Qatif*
Faisal Sanai, *Riyadh*

Serbia

Tamara M Alempijevic, *Belgrade*
Dusan M Jovanovic, *Sremska Kamenica*
Zoran Krivokapic, *Belgrade*

Singapore

Madhav Bhatia, *Singapore*
Kong Weng Eu, *Singapore*
Brian Kim Poh Goh, *Singapore*
Khek-Yu Ho, *Singapore*
Kok Sun Ho, *Singapore*
Fock Kwong Ming, *Singapore*
London Lucien Ooi, *Singapore*
Nagarajan Perumal, *Singapore*
Francis Seow-Choen, *Singapore*

South Africa

Rosemary Joyce Burnett, *Pretoria*
Michael Kew, *Cape Town*

South Korea

Sang Hoon Ahn, *Seoul*
Sung-Gil Chi, *Seoul*
Myung-Gyu Choi, *Seoul*
Hoon Jai Chun, *Seoul*
Yeun-Jun Chung, *Seoul*
Young-Hwa Chung, *Seoul*
Kim Donghee, *Seoul*
Ki-Baik Hahm, *Incheon*
Sun Pyo Hong, *Geonggi-do*
Seong Gyu Hwang, *Seongnam*
Hong Joo Kim, *Seoul*
Jae J Kim, *Seoul*
Jin-Hong Kim, *Suwon*
Nayoung Kim, *Seongnam-si*
Sang Geon Kim, *Seoul*
Seon Hahn Kim, *Seoul*
Sung Kim, *Seoul*
Won Ho Kim, *Seoul*
Jeong Min Lee, *Seoul*
Kyu Taek Lee, *Seoul*
Sang Kil Lee, *Seoul*
Sang Yeoup Lee, *Gyeongsangnam-do*
Yong Chan Lee, *Seoul*
Eun-Yi Moon, *Seoul*
Hyoung-Chul Oh, *Seoul*
Seung Woon Paik, *Seoul*
Joong-Won Park, *Goyang*
Ji Kon Ryu, *Seoul*
Si Young Song, *Seoul*
Marie Yeo, *Suwon*
Byung Chul Yoo, *Seoul*
Dae-Yeul Yu, *Daejeon*

Spain

Maria-Angeles Aller, *Madrid*
Raul J Andrade, *Málaga*
Luis Aparisi, *Valencia*
Gloria González Aseguinolaza, *Navarra*
Matias A Avila, *Pamplona*

Fernando Azpiroz, *Barcelona*
Ramon Bataller, *Barcelona*
Belén Beltrán, *Valencia*
Adolfo Benages, *Valencia*
Josep M Bordas, *Barcelona*
Lisardo Boscá, *Madrid*
Luis Bujanda, *San Sebastián*
Juli Busquets, *Barcelona*
Matilde Bustos, *Pamplona*
José Julián calvo Andrés, *Salamanca*
Andres Cardenas, *Barcelona*
Antoni Castells, *Barcelona*
Fernando J Corrales, *Pamplona*
J E Domínguez-Muñoz, *Santiago de Compostela*
Juan Carlos Laguna Egea, *Barcelona*
Isabel Fabregat, *Barcelona*
Antoni Farré, *Barcelona*
Vicente Felipo, *Valencia*
Laureano Fernández-Cruz, *Barcelona*
Luis Grande, *Barcelona*
Angel Lanas, *Zaragoza*
Juan-Ramón Larrubia, *Guadalajara*
María IT López, *Jaén*
Juan Macías, *Seville*
Javier Martin, *Granada*
José Manuel Martin-Villa, *Madrid*
Julio Mayol, *Madrid*
Mireia Miquel, *Sabadell*
Albert Parés, *Barcelona*
Jesús M Prieto, *Pamplona*
Pedro L Majano Rodriguez, *Madrid*
Joan Roselló-Catafau, *Barcelona*
Eva Vaquero, *Barcelona*

Sweden

Lars Erik Agréus, *Stockholm*
Mats Andersson, *Stockholm*
Roland Andersson, *Lund*
Mauro D'Amato, *Huddinge*
Evangelos Kalaitzakis, *Gothenburg*
Greger Lindberg, *Stockholm*
Annika Lindblom, *Stockholm*
Sara Lindén, *Göteborg*
Hanns-Ulrich Marschall, *Stockholm*
Pär Erik Myrelid, *Linköping*
Åke Nilsson, *Lund*
Helena Nordenstedt, *Stockholm*
Kjell Öberg, *Uppsala*
Lars A Pahlman, *Uppsala*
Stefan G Pierzynowski, *Lund*
Sara Regnér, *Malmö*
Bobby Tingstedt, *Lund*
Zongli Zheng, *Stockholm*

Switzerland

Pascal Bucher, *Geneva*
Michelangelo Foti, *Geneva*
Jean L Frossard, *Geneva*
Andreas Geier, *Zürich*
Pascal Gervaz, *Geneva*
Gerd A Kullak-Ublick, *Zürich*
Fabrizio Montecucco, *Geneva*
Paul M Schneider, *Zürich*
Felix Stickel, *Berne*
Bruno Stieger, *Zürich*
Inti Zlobec, *Basel*

Trinidad and Tobago

Shivananda Nayak, *Mount Hope*

Turkey

Sinan Akay, *Tekirdag*
Metin Basaranoglu, *Istanbul*
Yusuf Bayraktar, *Ankara*
A Mithat Bozdayi, *Ankara*
Hayrullah Derici, *Balıkesir*
Eren Ersoy, *Ankara*
Mukaddes Esrefoglu, *Malatya*
Can Goen, *Kutahya*
Selin Kapan, *Istanbul*
Aydin Karabacakoglu, *Konya*
Cuneyt Kayaalp, *Malatya*
Kemal Kismet, *Ankara*
Seyfettin Köklü, *Ankara*
Mehmet Refik Mas, *Etlik-Ankara*
Osman C Ozdogan, *Istanbul*
Bülent Salman, *Ankara*
Orhan Sezgin, *Mersin*
Ilker Tasci, *Ankara*
Müge Tecder-Ünal, *Ankara*
Ahmet Tekin, *Mersin*
Mesut Tez, *Ankara*
Ekmel Tezel, *Ankara*
Özlem Yilmaz, *Izmir*

United Arab Emirates

Fikri M Abu-Zidan, *Al-Ain*
Sherif M Karam, *Al-Ain*

United Kingdom

Simon Afford, *Birmingham*
Navneet K Ahluwalia, *Stockport*
Mohamed H Ahmed, *Southampton*
Basil Ammori, *Salford*
Lesley A Anderson, *Belfast*
Chin Wee Ang, *Liverpool*
Yeng S Ang, *Wigan*
Anthony TR Axon, *Leeds*
Kathleen B Bamford, *London*
Jim D Bell, *London*
John Beynon, *Swansea*
Chris Briggs, *Sheffield*
Geoffrey Burnstock, *London*
Alastair D Burt, *Newcastle*
Jeff Butterworth, *Shrewsbury*
Jeremy FL Cobbold, *London*
Jean E Crabtree, *Leeds*
Tatjana Crnogorac-Jurcevic, *London*
William Dickey, *Londonderry*
Sunil Dolwani, *Cardiff*
Emad M El-Omar, *Aberdeen*
A M El-Tawil, *Birmingham*
Charles B Ferguson, *Belfast*
Andrew Fowell, *Southampton*
Piers Gatenby, *London*
Daniel R Gaya, *Edinburgh*
Anil George, *London*
Rob Glynne-Jones, *Northwood*
Jason CB Goh, *Birmingham*
Gianpiero Gravante, *Leicester*
Brian Green, *Belfast*
William Greenhalf, *Liverpool*
Indra N Guha, *Nottingham*
Stefan G Hübscher, *Birmingham*
Robin Hughes, *London*
Pali Hungin, *Stockton*
Nawfal Hussein, *Nottingham*
Clement W Imrie, *Glasgow*
Janusz AZ Jankowski, *Oxford*
Sharad Karandikar, *Birmingham*
Peter Karayiannis, *London*
Shahid A Khan, *London*
Patricia F Lalor, *Birmingham*
John S Leeds, *Sheffield*
Ian Lindsey, *Oxford*
Hong-Xiang Liu, *Cambridge*
Dileep N Lobo, *Nottingham*
Graham MacKay, *Glasgow*
Mark Edward McAlindon, *Sheffield*
Anne McCune, *Bristol*
Donald Campbell McMillan, *Glasgow*
Giorgina Mieli-Vergani, *London*
Jamie Murphy, *London*
Guy Fairbairn Nash, *Poole*
James Neuberger, *Birmingham*
Patrick O'Dwyer, *Glasgow*
Christos Paraskeva, *Bristol*
Richard Parker, *North Staffordshire*
Thamara Perera, *Birmingham*
Kondragunta Rajendra Prasad, *Leeds*
D Mark Pritchard, *Liverpool*
Alberto Quaglia, *London*
Akhilesh B Reddy, *Cambridge*
Kevin Robertson, *Glasgow*
Sanchoy Sarkar, *Liverpool*
John B Schofield, *Kent*
Marco Senzolo, *Padova*
Venkatesh Shanmugam, *Derby*
Paul Sharp, *London*
Chew Thean Soon, *Manchester*
Aravind Suppiah, *East Yorkshire*
Noriko Suzuki, *Middlesex*
Simon D Taylor-Robinson, *London*
Frank I Tovey, *London*
A McCulloch Veitch, *Wolverhampton*
Vamsi R Velchuru, *Lowestoft*
Sumita Verma, *Brighton*
Catherine Walter, *Cheltenham*
Julian RF Walters, *London*
Roger Williams, *London*

United States

Kareem M Abu-Elmagd, *Pittsburgh*
Sami R Achem, *Florida*
Golo Ahlenstiel, *Bethesda*
Bhupinder S Anand, *Houston*
M Ananthanarayanan, *New York*
Balamurugan N Appakalal, *Minneapolis*
Dimitrios V Avgerinos, *New York*
Shashi Bala, *Worcester*
Anthony J Bauer, *Pittsburgh*
Kevin E Behrns, *Gainesville*
Roberto Bergamaschi, *New York*
Henry J Binder, *New Haven*
Edmund J Bini, *New York*
Wojciech Blonski, *Philadelphia*
Mark Bloomston, *Columbus*
Edward L Bradley III, *Sarasota*
Carla W Brady, *Durham*

David A Brenner, *San Diego*
Adeel A Butt, *Pittsburgh*
Shi-Ying Cai, *New Haven*
Justin MM Cates, *Nashville*
Eugene P Ceppa, *Durham*
Jianyuan Chai, *Long Beach*
Ronald S Chamberlain, *Livingston*
Fei Chen, *Morgantown*
Xian-Ming Chen, *Omaha*
Ramsey Chi-man Cheung, *Palo Alto*
Denesh Chitkara, *East Brunswick*
Clifford S Cho, *Madison*
Parimal Chowdhury, *Arkansas*
John David Christein, *Birmingham*
Thomas Clancy, *Boston*
Ana J Coito, *Los Angeles*
Ricardo Alberto Cruciani, *New York*
Joseph J Cullen, *Iowa City*
Mark J Czaja, *New York*
Mariana D Dabeva, *Bronx*
Jessica A Davila, *Houston*
Conor P Delaney, *Cleveland*
Laurie DeLeve, *Los Angeles*
Anthony J Demetris, *Pittsburgh*
Sharon DeMorrow, *Temple*
Bijan Eghtesad, *Cleveland*
Yoram Elitsur, *Huntington*
Mohamad A Eloubeidi, *Alabama*
Wael El-Rifai, *Nashville*
Sukru H Emre, *New Haven*
Giamila Fantuzzi, *Chicago*
Ashkan Farhadi, *Irvine*
Ronnie Fass, *Tucson*
Martín E Fernández-Zapico, *Rochester*
Alessandro Fichera, *Chicago*
Josef E Fischer, *Boston*
Piero Marco Fisichella, *Maywood*
Fritz Francois, *New York*
Glenn T Furuta, *Aurora*
T Clark Gamblin, *Pittsburgh*
Henning Gerke, *Iowa City*
Jean-Francois Geschwind, *Baltimore*
R Mark Ghobrial, *Texas*
John F Gibbs, *Buffalo*
Shannon S Glaser, *Temple*
Ajay Goel, *Dallas*
Jon C Gould, *Madison*
Eileen F Grady, *San Francisco*
James H Grendell, *New York*
John R Grider, *Richmond*
Anna S Gukovskaya, *Los Angeles*
Chakshu Gupta, *St. Joseph*
Grigoriy E Gurvits, *New York*
Hai-Yong Han, *Phoenix*
Yuan-Ping Han, *Los Angeles*
Imran Hassan, *Springfield*
Charles P Heise, *Madison*
Lisa J Herrinton, *Oakland*
Oscar Joe Hines, *Los Angeles*
Samuel B Ho, *San Diego*
Steven Hochwald, *Gainesville*
Richard Hu, *Los Angeles*
Eric S Hungness, *Chicago*
Jamal A Ibdah, *Columbia*
Atif Iqbal, *Omaha*
Hartmut Jaeschke, *Tucson*
Donald M Jensen, *Chicago*
Robert Jensen, *Bethesda*
Leonard R Johnson, *Memphis*
Andreas M Kaiser, *Los Angeles*
JingXuan Kang, *Charlestown*
John Y Kao, *Michigan*
Randeep Singh Kashyap, *New York*
Rashmi Kaul, *Tulsa*
Jonathan D Kaunitz, *Los Angeles*
Stephen M Kavic, *Baltimore*
Ali Keshavarzian, *Chicago*
Amir Maqbul Khan, *Marshall*
Kusum K Kharbanda, *Omaha*
Chang Kim, *West Lafayette*
Dean Y Kim, *Detroit*
Miran Kim, *Providence*
Burton I Korelitz, *New York*
Josh Korzenik, *Boston*
Richard A Kozarek, *Seattle*
Alyssa M Krasinskas, *Pittsburgh*
Shiu-Ming Kuo, *Buffalo*
Michelle Lai, *Boston*
Michael Leitman, *New York*
Dong-Hui Li, *Houston*
Ming Li, *New Orleans*
Zhiping Li, *Baltimore*
Gary R Lichtenstein, *Philadelphia*
Chen Liu, *Gainesville*
Zhang-Xu Liu, *Los Angeles*
Craig D Logsdon, *Houston*
Kaye M Reid Lombardo, *Rochester*
Michael R Lucey, *Madison*
Kirk Ludwig, *Wisconsin*
James D Luketich, *Pittsburgh*
Patrick M Lynch, *Houston*
John S Macdonald, *New York*
Willis C Maddrey, *Dallas*
Mercedes Susan Mandell, *Aurora*
Christopher Mantyh, *Durham*
Wendy M Mars, *Pittsburgh*
John Marshall, *Columbia*
Robert CG Martin, *Louisville*
Laura E Matarese, *Pittsburgh*
Craig J McClain, *Louisville*
Lynne V McFarland, *Washington*
David J McGee, *Shreveport*
Valentina Medici, *Sacramento*
Stephan Menne, *New York*
Didier Merlin, *Atlanta*
George Michalopoulos, *Pittsburgh*
James M Millis, *Chicago*
Pramod K Mistry, *New Haven*
Emiko Mizoguchi, *Boston*
Huanbiao Mo, *Denton*
Robert C Moesinger, *Ogden*
Smruti R Mohanty, *Chicago*
John Morton, *Stanford*
Peter L Moses, *Burlington*
Sandeep Mukherjee, *Omaha*
Million Mulugeta, *Los Angeles*
Michel M Murr, *Tampa*
Pete Muscarella, *Columbus*
Ece A Mutlu, *Chicago*
Masaki Nagaya, *Boston*
Laura E Nagy, *Cleveland*
Aejaz Nasir, *Tampa*
Udayakumar Navaneethan, *Cincinnati*
Stephen JD O'Keefe, *Pittsburgh*
Robert D Odze, *Boston*
Giuseppe Orlando, *Winston Salem*
Pal Pacher, *Rockville*
Georgios Papachristou, *Pittsburgh*
Jong Park, *Tampa*
William R Parker, *Durham*
Mansour A Parsi, *Cleveland*
Marco Giuseppe Patti, *Chicago*
Zhiheng Pei, *New York*
CS Pitchumoni, *New Brunswiuc*
Parviz M Pour, *Omaha*
Xiaofa Qin, *Newark*
Florencia Georgina Que, *Rochester*
Massimo Raimondo, *Jacksonville*
Raymund R Razonable, *Minnesota*
Kevin Michael Reavis, *Orange*
Robert V Rege, *Dallas*
Douglas K Rex, *Indianapolis*
Victor E Reyes, *Galveston*
Basil Rigas, *New York*
Richard A Rippe, *Chapel Hill*
Alexander S Rosemurgy, *Tampa*
Philip Rosenthal, *San Francisco*
Raul J Rosenthal, *Weston*
Joel H Rubenstein, *Ann Arbor*
Shawn D Safford, *Norfolk*
Rabih M Salloum, *Rochester*
Bruce E Sands, *Boston*
Tor C Savidge, *Galveston*
Michael L Schilsky, *New Haven*
Beat Schnüriger, *California*
Robert E Schoen, *Pittsburgh*
Matthew James Schuchert, *Pittsburgh*
Ekihiro Seki, *La Jolla*
Le Shen, *Chicago*
Perry Shen, *Winston-Salem*
Stuart Sherman, *Indianapolis*
Mitchell L Shiffman, *Richmond*
Shivendra Shukla, *Columbia*
Bronislaw L Slomiany, *Newark*
Scott Steele, *Fort Lewis*
Branko Stefanovic, *Tallahassee*
Lygia Stewart, *San Francisco*
Luca Stocchi, *Cleveland*
Daniel S Straus, *Riverside*
Robert Todd Striker, *Madison*
Jonathan Strosberg, *Tampa*
Christina Surawicz, *Seattle*
Patricia Sylla, *Boston*
Wing-Kin Syn, *Durham*
Yvette Taché, *Los Angeles*
Kazuaki Takabe, *Richmond*
Kam-Meng Tchou-Wong, *New York*
Klaus Thaler, *Columbia*
Charles Thomas, *Oregon*
Natalie J Torok, *Sacramento*
George Triadafilopoulos, *Stanford*
Chung-Jyi Tsai, *Lexington*
Thérèse Tuohy, *Salt Lake City*
Andrew Ukleja, *Florida*
Santhi Swaroop Vege, *Rochester*
Aaron Vinik, *Norfolk*
Dinesh Vyas, *Washington*
Arnold Wald, *Wisconsin*
Scott A Waldman, *Philadelphia*
Jack R Wands, *Providence*
Jiping Wang, *Boston*
Irving Waxman, *Chicago*
Wilfred M Weinstein, *Los Angeles*
Steven D Wexner, *Weston*
John W Wiley, *Ann Arbor*
Jackie Wood, *Ohio*
Jian Wu, *Sacramento*
Wen Xie, *Pittsburgh*
Guang-Yin Xu, *Galveston*
Fang Yan, *Nashville*
Radha Krishna Yellapu, *New York*
Anthony T Yeung, *Philadelphia*
Zobair M Younossi, *Virginia*
Liqing Yu, *Winston-Salem*
Run Yu, *Los Angeles*
Ruben Zamora, *Pittsburgh*
Michael E Zenilman, *New York*
Mark A Zern, *Sacramento*
Lin Zhang, *Pittsburgh*
Martin D Zielinski, *Rochester*
Michael A Zimmerman, *Colorado*

WJG World Journal of Gastroenterology

Contents

Weekly Volume 16 Number 26 July 14, 2010

EDITORIAL

3219 Black esophagus: Acute esophageal necrosis syndrome
Gurvits GE

3226 *Helicobacter pylori* and gastric cancer in the Middle East: A new enigma?
Hussein NR

GUIDELINES FOR BASIC SCIENCE

3235 Two-layer cold storage method for pancreas and islet cell transplantation
Fujino Y

REVIEW

3239 Interstitial cells of Cajal, the Maestro in health and disease
Mostafa RM, Moustafa YM, Hamdy H

ORIGINAL ARTICLE

3249 *Nardostachys jatamansi* extract protects against cytokine-induced β-cell damage and streptozotocin-induced diabetes
Song MY, Bae UJ, Lee BH, Kwon KB, Seo EA, Park SJ, Kim MS, Song HJ, Kwon KS, Park JW, Ryu DG, Park BH

3258 CD74 is a survival receptor on colon epithelial cells
Maharshak N, Cohen S, Lantner F, Hart G, Leng L, Bucala R, Shachar I

3267 Identification of cytokines involved in hepatic differentiation of mBM-MSCs under liver-injury conditions
Dong XJ, Zhang H, Pan RL, Xiang LX, Shao JZ

3279 Randomized controlled trial of minimally invasive surgery using acellular dermal matrix for complex anorectal fistula
A ba-bai-ke-re MMTJ, Wen H, Huang HG, Chu H, Lu M, Chang ZS, Ai EHT, Fan K

BRIEF ARTICLE

3287 Safety of same-day endoscopic ultrasound and endoscopic retrograde cholangiopancreatography under conscious sedation
Che K, Muckova N, Olafsson S, Srikureja W

3292 Functional magnetic resonance imaging in an animal model of pancreatic cancer
Lewandowski RJ, Eifler AC, Bentrem DJ, Chung JC, Wang D, Woloschak GE, Yang GY, Ryu R, Salem R, Larson AC, Omary RA

3299 Wireless capsule endoscopy and proximal small bowel lesions in Crohn's disease
Petruzziello C, Onali S, Calabrese E, Zorzi F, Ascolani M, Condino G, Lolli E, Naccarato P, Pallone F, Biancone L

3305 Experience with the surgical treatment of hepatic hydatidosis: Case series with follow-up
Losada Morales H, Burgos San Juan L, Silva Abarca J, Muñoz Castro C

3310 Comparison of different nutritional assessments in detecting malnutrition among gastric cancer patients
Ryu SW, Kim IH

3318 Oncological outcome of unresectable lung metastases without extrapulmonary metastases in colorectal cancer
Li WH, Peng JJ, Xiang JQ, Chen W, Cai SJ, Zhang W

3325 Relationship between let-7a and gastric mucosa cancerization and its significance
Zhu YM, Zhong ZX, Liu ZM

3330 Paclitaxel ameliorates fibrosis in hepatic stellate cells *via* inhibition of TGF-β/Smad activity
Zhou J, Zhong DW, Wang QW, Miao XY, Xu XD

CASE REPORT

3335 Vanishing bile duct syndrome in human immunodeficiency virus: Nevirapine hepatotoxicity revisited
Kochar R, Nevah MI, Lukens FJ, Fallon MB, Machicao VI

3339 Isolated ileal perforation due to cytomegalovirus reactivation during management of terbinafine hypersensitivity
Sano S, Ueno H, Yamagami K, Yakushiji Y, Isaka Y, Kawasaki I, Takemura M, Inoue T, Hosoi M

3343 Abdominal separation in an adult male patient with acute abdominal pain
Liu BL, Chen Y, Liu SQ, Zhang XB, Cui DX, Dai XW

Contents

World Journal of Gastroenterology
Volume 16 Number 26 July 14, 2010

ACKNOWLEDGMENTS I Acknowledgments to reviewers of *World Journal of Gastroenterology*

APPENDIX I Meetings

I-IV Instructions to authors

AIM AND SCOPE

World Journal of Gastroenterology (*World J Gastroenterol*, *WJG*, print ISSN 1007-9327, DOI: 10.3748) is a weekly, open-access, peer-reviewed journal supported by an editorial board of 1144 experts in gastroenterology and hepatology from 60 countries.

The major task of *WJG* is to report rapidly the most recent results in basic and clinical research on esophageal, gastrointestinal, liver, pancreas and biliary tract diseases, *Helicobacter pylori*, endoscopy and gastrointestinal surgery, including: gastroesophageal reflux disease, gastrointestinal bleeding, infection and tumors; gastric and duodenal disorders; intestinal inflammation, microflora and immunity; celiac disease, dyspepsia and nutrition; viral hepatitis, portal hypertension, liver fibrosis, liver cirrhosis, liver transplantation, and metabolic liver disease; molecular and cell biology; geriatric and pediatric gastroenterology; diagnosis and screening, imaging and advanced technology.

FLYLEAF I-VII Editorial Board

EDITORS FOR THIS ISSUE

Responsible Assistant Editor: *Xiao-Fang Liu*
Responsible Electronic Editor: *Xiao-Mei Zheng*
Proofing Editor-in-Chief: *Lian-Sheng Ma*
Responsible Science Editor: *Lin Tian*
Proofing Editorial Office Director: *Jian-Xia Cheng*

NAME OF JOURNAL
World Journal of Gastroenterology

LAUNCH DATE
October 1, 1995

RESPONSIBLE INSTITUTION
Department of Science and Technology of Shanxi Province

SPONSOR
Taiyuan Research and Treatment Center for Digestive Diseases, 77 Shuangta Xijie, Taiyuan 030001, Shanxi Province, China

EDITING
Editorial Board of *World Journal of Gastroenterology*, Room 903, Building D, Ocean International Center, No. 62 Dongsihuan Zhonglu, Chaoyang District, Beijing 100025, China
Telephone: +86-10-5908-0039
Fax: +86-10-8538-1893
E-mail: wjg@wjgnet.com
http://www.wjgnet.com

PUBLISHING
Beijing Baishideng BioMed Scientific Co., Ltd., Room 903, Building D, Ocean International Center, No. 62 Dongsihuan Zhonglu, Chaoyang District, Beijing 100025, China
Telephone: +86-10-8538-1892
Fax: +86-10-8538-1893
E-mail: baishideng@wjgnet.com
http://www.wjgnet.com

SUBSCRIPTION
Beijing Baishideng BioMed Scientific Co., Ltd., Room 903, Building D, Ocean International Center, No. 62 Dongsihuan Zhonglu, Chaoyang District, Beijing 100025, China
Telephone: +86-10-8538-1892
Fax: +86-10-8538-1893
E-mail: baishideng@wjgnet.com
http://www.wjgnet.com

PRINT SUBSCRIPTION
RMB 245 Yuan for each issue, RMB 11760 Yuan for one year.

ONLINE SUBSCRIPTION
One-Year Price 864.00 USD

PUBLICATION DATE
July 14, 2010

CSSN
ISSN 1007-9327 (print)
CN 14-1219/R

HONORARY EDITORS-IN-CHIEF
James L Boyer, *New Haven*
Ke-Ji Chen, *Beijing*
Martin H Floch, *New Haven*
Geng-Tao Liu, *Beijing*
Emmet B Keeffe, *Palo Alto*
Lein-Ray Mo, *Tainan*
Eamonn M Quigley, *Cork*
Rafiq A Sheikh, *Sacramento*
Nicholas J Talley, *Rochester*
Ming-Lung Yu, *Kaohsiung*

PRESIDENT AND EDITOR-IN-CHIEF
Lian-Sheng Ma, *Beijing*

ACADEMIC EDITOR-IN-CHIEF
Tauseef Ali, *Oklahoma*
Mauro Bortolotti, *Bologna*
Tarkan Karakan, *Ankara*
Weekitt Kittisupamongkol, *Bangkok*
Anastasios Koulaouzidis, *Edinburgh*
Gerd A Kullak-Ublick, *Zürich*
Bo-Rong Pan, *Xi'an*
Sylvia LF Pender, *Southampton*
Max S Petrov, *Auckland*
George Y Wu, *Farmington*

STRATEGY ASSOCIATE EDITORS-IN-CHIEF
Peter Draganov, *Florida*
Hugh J Freeman, *Vancouver*
Maria Concepción Gutiérrez-Ruiz, *México*
Kazuhiro Hanazaki, *Kochi*
Akio Inui, *Kagoshima*
Kalpesh Jani, *Baroda*
Javier S Martin, *Punta del Este*
Natalia A Osna, *Omaha*
Wei Tang, *Tokyo*
Alan BR Thomson, *Edmonton*
Harry HX Xia, *Hanover*

ASSOCIATE EDITORS-IN-CHIEF
You-Yong Lu, *Beijing*
John M Luk, *Pokfulam*
Hiroshi Shimada, *Yokohama*

EDITORIAL OFFICE
Jian-Xia Cheng, Director
World Journal of Gastroenterology
Room 903, Building D, Ocean International Center, No. 62 Dongsihuan Zhonglu, Chaoyang District, Beijing 100025, China
Telephone: +86-10-5908-0039
Fax: +86-10-8538-1893
E-mail: wjg@wjgnet.com
http://www.wjgnet.com

COPYRIGHT
© 2010 Baishideng. All rights reserved; no part of this publication may be reproduced, stored in a retrieval system, or transmitted in any form or by any means, electronic, mechanical, photocopying, recording, or otherwise without the prior permission of Baishideng. Authors are required to grant *World Journal of Gastroenterology* an exclusive license to publish.

SPECIAL STATEMENT
All articles published in this journal represent the viewpoints of the authors except where indicated otherwise.

INSTRUCTIONS TO AUTHORS
Full instructions are available online at http://www.wjgnet.com/1007-9327/g_info_20100315215714.htm. If you do not have web access please contact the editorial office.

ONLINE SUBMISSION
http://www.wjgnet.com/1007-9327office

World Journal of Gastroenterology

Online Submissions: http://www.wjgnet.com/1007-9327office
wjg@wjgnet.com
doi:10.3748/wjg.v16.i26.3219

World J Gastroenterol 2010 July 14; 16(26): 3219-3225
ISSN 1007-9327 (print)
© 2010 Baishideng. All rights reserved.

EDITORIAL

Black esophagus: Acute esophageal necrosis syndrome

Grigoriy E Gurvits

Grigoriy E Gurvits, Department of Gastroenterology, St. Vincent's Medical Center/New York Medical College, 170 West 12th Street, New York, NY 10011, United States
Author contributions: Gurvits GE is the sole contributor to this work.
Correspondence to: Grigoriy E Gurvits, MD, Department of Gastroenterology, St. Vincent's Medical Center/New York Medical College, 170 West 12th Street, New York, NY 10011, United States. dr.gurvits@hotmail.com
Telephone: +1-212-6048325 Fax: +1-212-6048446
Received: March 15, 2010 Revised: April 2, 2010
Accepted: April 9, 2010
Published online: July 14, 2010

Abstract

Acute esophageal necrosis (AEN), commonly referred to as "black esophagus", is a rare clinical entity arising from a combination of ischemic insult seen in hemodynamic compromise and low-flow states, corrosive injury from gastric contents in the setting of esophago-gastroparesis and gastric outlet obstruction, and decreased function of mucosal barrier systems and reparative mechanisms present in malnourished and debilitated physical states. AEN may arise in the setting of multiorgan dysfunction, hypoperfusion, vasculopathy, sepsis, diabetic ketoacidosis, alcohol intoxication, gastric volvulus, traumatic transection of the thoracic aorta, thromboembolic phenomena, and malignancy. Clinical presentation is remarkable for upper gastrointestinal bleeding. Notable symptoms may include epigastric/abdominal pain, vomiting, dysphagia, fever, nausea, and syncope. Associated laboratory findings may reflect anemia and leukocytosis. The hallmark of this syndrome is the development of diffuse circumferential black mucosal discoloration in the distal esophagus that may extend proximally to involve variable length of the organ. Classic "black esophagus" abruptly stops at the gastroesophageal junction. Biopsy is recommended but not required for the diagnosis. Histologically, necrotic debris, absence of viable squamous epithelium, and necrosis of esophageal mucosa, with possible involvement of submucosa and muscularis propria, are present. Classification of the disease spectrum is best described by a staging system. Treatment is directed at correcting coexisting clinical conditions, restoring hemodynamic stability, nil-per-os restriction, supportive red blood cell transfusion, and intravenous acid suppression with proton pump inhibitors. Complications include perforation with mediastinal infection/abscess, esophageal stricture and stenosis, superinfection, and death. A high mortality of 32% seen in the setting of AEN syndrome is usually related to the underlying medical co-morbidities and diseases.

© 2010 Baishideng. All rights reserved.

Key words: Acute esophageal necrosis; Black esophagus; Acute necrotizing esophagitis; Ischemia; Endoscopy; Gastrointestinal hemorrhage

Peer reviewers: Volker F Eckardt, MD, Professor, Chief, Department of Gastroenterology, Deutsche Klinik für Diagnostik, Aukammallee 33, 65191 Wiesbaden, Germany; Akihito Nagahara, Associate Professor, Department of Gastroenterology, Juntendo University School of Medicine, 2-1-1 Hongo Bunkyo-ku, Tokyo 113-8421, Japan

Gurvits GE. Black esophagus: Acute esophageal necrosis syndrome. *World J Gastroenterol* 2010; 16(26): 3219-3225 Available from: URL: http://www.wjgnet.com/1007-9327/full/v16/i26/3219.htm DOI: http://dx.doi.org/10.3748/wjg.v16.i26.3219

INTRODUCTION

Acute esophageal necrosis (AEN), commonly referred to as "black esophagus" or "acute necrotizing esophagitis", is a rare clinical disorder classically characterized by a striking endoscopic image of diffuse, circumferential, black-appearing, distal esophageal mucosa on esophagogastroduodenoscopy (EGD) (Figure 1) that stops abruptly at the gastroesophageal junction (GEJ)[1,2]. Proximal esophageal extension is common. Biopsy is recommended although not required to make the diagnosis. First described in 1990 by Goldenberg *et al*[3], this medical phenomenon was again brought into the spotlight by our large review series

in 2007, in which we analyzed all cases reported in the English literature to date and formulated the concept of a distinct clinical syndrome[2]. Its etiology is likely multifactorial. AEN is thought to arise from a combination of an ischemic insult to the esophagus, impaired mucosal barrier systems, and a backflow injury from chemical contents of gastric secretions[2,4-6]. Male sex, older age, chronic medical conditions, including diabetes mellitus, hematologic and solid organ malignancy, malnutrition, renal insufficiency, cardiovascular compromise, trauma, and thromboembolic phenomena place a patient at a higher risk for developing AEN[4,7-13]. Clinical presentation is almost universally related to upper gastrointestinal bleeding. Complications may include stenosis or stricture formation in the distal esophagus, perforation, mediastinitis, and death. Overall mortality is largely related to the underlying medical condition and approaches 32%[2].

In this latest review, we discuss the epidemiology of AEN syndrome, its pathophysiological and clinical features, etiology, presentation, distinction from other mimickers of "black esophagus", natural course of the disease, staging, complications, suggested treatment options, and prognosis.

EPIDEMIOLOGY

Literature analysis shows that the estimated prevalence of AEN is low. Two large autopsy series from the United States and France have reported zero cases in a series of 1000 adult autopsies[14] and 0.2% in 3000 autopsies, respectively[15]. Two large retrospective series that have reviewed the findings in > 100 000 endoscopies have estimated the incidence at approximately 0.01% (12 patients)[5,12], and another retrospective analysis of 10 295 endoscopies has shown an incidence of 0.28% (29 patients)[13]. A 1-year prospective study of EGD findings in 3900 patients has identified eight cases of AEN (0.2%)[6]. However, these numbers are likely underestimated and the true prevalence of AEN remains unknown, largely due to the potential of subclinical presentation of the disease and the early healing of the mucosa that can be seen with transient ischemic or chemical injury. An intriguing paper by Japanese authors has reported AEN as the fourth leading cause of coffee ground emesis, hematemesis, or melena in a series of 239 hospital admissions for upper gastrointestinal bleeding, which accounted for approximately 6% of the cases[16].

AEN clearly shows sex and age predilection. Men are four times more commonly affected than women, and although the disease has been documented in every age group, the peak incidence occurs in the sixth decade of life with an average age of 67 years[2]. General debilitation and poor clinical condition with multiple medical co-morbidities are associated with increased likelihood of development of AEN. Personal history of diabetes mellitus (24%), malignancy (20%), hypertension (20%), alcohol abuse (10%), and coronary artery disease (9%) places a patient at risk of developing AEN[2].

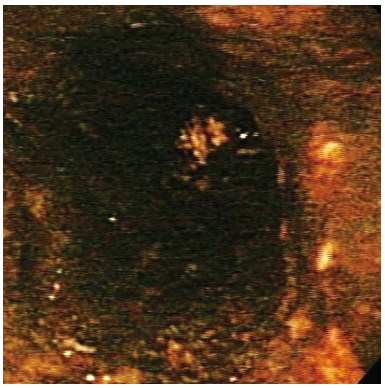

Figure 1 Black esophagus: acute esophageal necrosis.

ANATOMY AND PATHOPHYSIOLOGY

The esophagus is an expandable muscular organ lined by a stratified squamous epithelium. Characteristically, esophageal wall is composed of four distinct layers: mucosa, submucosa, muscularis propria, and adventitia. Unlike the rest of gastrointestinal tract, the esophagus lacks serosa and is separated from the adjacent organs by few millimeters of connective tissue, an important factor in potential development of extrinsic necrotic injury to the organ and spread of the infectious processes.

The esophagus receives an intricate segmental vascular supply that separates this organ into three parts: upper, middle, and distal esophagus. The arterial network of the upper esophagus is derived from the descending branches of the inferior thyroid arteries. Additional variable supply may come from branches of the subclavian, thyroidea ima, common carotid, or superior thyroid arteries. Mid-esophageal blood supply is derived from the bronchial arteries, right third or fourth intercostal arteries, and numerous small esophageal arteries off the descending aorta. Distal esophagus receives its blood flow from branches off the left gastric artery or left inferior phrenic artery, but variations are common and small branches off the celiac, splenic, short gastric, or left hepatic arteries may provide additional or alternative blood supplies[17,18]. Relative to the densely vascularized proximal and middle parts of the organ, the distal esophagus is slightly more "watershed" and therefore the first signs of the ischemic injury to the esophagus typically appear there. Overall, the complex anastomotic vascular network that is present in the esophageal submucosa generally makes esophageal infarction a rare clinical disease[18].

An important physiological property of the esophagus is the ability to use intricate protective barrier systems to shield itself from the injurious chemical reflux of the stomach contents. A delicate microarray of the epithelial tight junctions, zonula adherens, intercellular glycoconjugated material, intrinsic cellular buffering systems and anion exchangers, and extensive desmosomal network, coupled with bicarbonate, lubricant, mucus, and epidermal growth factor production by submucosal glands account for comprehensive defense mechanisms and restorative

function of the organ[18]. Compromise or inadequacy of these barriers may lead to cell damage, and ultimately, death. Local blood supply to the lamina propria and submucosa, which is essential in maintaining effective buffering systems, is influenced by a variety of factors, including autoregulation in response to the intraluminal acidic pH of gastric contents[19,20]. Initial augmentation in blood delivery needed for maintenance of protective and reparative processes may be significantly downregulated by an overwhelming back diffusion of hydrogen ions[19,21]; an important factor in pathogenesis of AEN, particularly in the setting of an already compromised blood flow. At the cellular and molecular level, the mechanism of the esophageal injury is similar to the development of ischemic changes in the small and large bowel. Reactive oxygen metabolites formed as a result of reperfusion injury and leukocytic migration may directly and indirectly damage important mechanisms of cellular viability and function, which results in cellular lysis and death[18,22].

Finally, anti-reflux barriers and luminal clearance are important factors in preventing significant esophageal injury. Integrity of the lower esophageal sphincter mechanism, gravity and esophageal peristalsis are vital. Compromise or ineffectiveness of any one of these may deeply potentiate necrotic injury[23].

ETIOLOGY

Tissue insult seen in AEN is likely multifactorial and usually results from a combination of tissue hypoperfusion, impaired local defense barriers, and massive influx of gastric contents that acutely overwhelm the already vulnerable esophageal mucosa[2]. Perfusion injury in the development of AEN is best demonstrated by an avascular distal esophagus reported by Goldenberg *et al*[24]. Significant vasculopathy that is typically associated with diabetes mellitus, atherosclerosis, cardiovascular and renal diseases is an important risk factor that may predispose some patients to rapid tissue injury, as well as general susceptibility to hemodynamic instability and compromise. Low-flow state related to sepsis, cardiac arrhythmias, congestive heart failure, severe third spacing, systemic inflammatory response syndrome due to severe pancreatitis, lactic- and ketoacidosis, acute blood loss, hypothermia, trauma and shock may lead to ischemic compromise of the esophagus[2,12,16,25-31]. Thromboembolic phenomena and underlying coagulopathy seen in patients with solid tumor or hematological malignancies, anticardiolipin antibody syndrome, and atherosclerosis have also been implicated in the development of AEN[8,9,11,16,29]. Striking predilection to the distal esophagus is likely explained by its lesser degree of vascularization relative to the proximal and middle portions of the organ[12].

Vascular compromise to the distal esophageal tissue can also explain some of the duodenal pathology commonly seen in association with AEN, namely, duodenal bulb ulcers, erosions, inflammation, and edema[3,6,24]. The common blood supply from the branches off the celiac axis makes distal esophageal and duodenal pathologies less of a coincidence, but rather possibly related entities. Characteristic relative sparing of the gastric mucosa can be explained by the acidic impact on the ischemic esophageal and duodenal surface[7], as well as typically rapid repair of the injured gastric mucosa (within hours) compared to the esophagus (may take days)[18]. The duodenal bulb ulcers and edema may result in gastric outlet obstruction that, in turn, potentiates the development of mucosal necrosis of the distal esophagus[5,32]. A transient form of non-obstructive gastropathy can be seen in acute alcohol intoxication and diabetic ketoacidosis, two medical conditions that are linked to the development of AEN[25,26,33,34]. Back flow injury from the acid, pepsin, and other gastric contents is augmented by the increased transient lower esophageal sphincter relaxation, decreased resting lower esophageal pressure, prolonged recumbence, decreased esophageal peristalsis, and increased gastroesophageal reflux that may be related to the multiple medical conditions seen in the patient with AEN (debilitated condition, significant hiatal hernia, alcohol use, diabetes mellitus, postoperative state, *etc*.).

Alteration in physiological processes is an important co-factor in the development of AEN. Critical illness, poor nutritional status, and general deconditioning may contribute to the diminished mucosal buffering, compromised local protective barriers, and impaired defensive mechanisms that may potentiate ischemic and chemical injury to the esophagus[6]. Such risk factors include malignancy, cirrhosis, chronic pulmonary disease, neutropenia, renal insufficiency or failure, diabetes mellitus, hypoalbuminemia, immunosupression after solid organ transplantation, acquired immune deficiency syndrome (AIDS), postoperative status, and sepsis[2,10,12,13,27,35-39].

Diffuse AEN may be associated with local infection and tissue biopsy is essential for proper management, which includes antiviral or antimicrobial agents. Exact distribution is variable and probably depends on mode of transmission of the infectious agent, from external spread reported from a superior mediastinitis that affects cervical and thoracic esophagus[40], to primary esophageal intraluminal infection seen in viral and fungal disease in immunocompromised patients[35,36,41]. Reported pathogens include *Klebsiella pneumoniae*[40] and cytomegalovirus[36,41], herpes simplex virus[37], *Penicillium chrysogenum*[35], *Candida*[7], and other fungal species.

Other diseases and medical conditions associated with the development of AEN include erythema multiforme or Stevens-Johnson syndrome, gastric volvulus, hematoma from traumatic transection of thoracic aorta, hypersensitivity to antibiotics, acute fatty liver of pregnancy, drug-induced hepatitis, photodynamic therapy, polyarteritis nodosa, pulmonary lobectomy with paraesophageal lymph node dissection, severe infectious mediastinitis, emphysematous gastritis, hypoxia, and pancreatitis[2,7,12,39,40,42-49]. A single case of isolated proximal black esophagus has been reported in a patient who underwent cardiac catheterization, an event that was possibly related to the procedure[50,51].

PRESENTATION

A typical patient with AEN is an elderly male with mul-

tiple medical comorbidities, who manifests with signs of upper gastrointestinal bleeding. Clinical presentation of AEN ranges from hematemesis, coffee ground emesis, and melena (overall, accounting for nearly 90% of the cases) to asymptomatic black esophagus that was noted during a percutaneous gastrostomy tube placement[2,52]. Review of systems may be remarkable for epigastric/abdominal pain, vomiting, dysphagia, nausea, low-grade fever, lightheadedness, and syncope. Other associated clinical conditions or endoscopic findings may include multiorgan failure[53], cardiac, pulmonary, and renal disease, diabetes mellitus and ketoacidosis, vasculopathy, coagulopathy, peptic ulcer disease, general debilitation and malnourishment, cirrhosis, acute alcoholic hepatitis, acute fatty liver of pregnancy, acute pancreatitis, sepsis, ischemic processes (stroke, ischemic bowel, ischemic gangrene), and trauma. Physical findings in a patient with AEN are usually confounded by the underlying medical conditions but may be notable for cachectia, fever, hypoxia, hemodynamic instability or compromise, including arrhythmia and hypotension, pallor, abdominal tenderness, and guaiac-positive stools. Laboratory analysis may show leukocytosis and anemia and computed tomography (CT) may reveal thickened distal esophagus, hiatal hernia, distended fluid-filled stomach with possible gastric outlet obstruction, and rarely, external compression of the esophagus by a large mediastinal process.

DIFFERENTIAL DIAGNOSIS

Classic AEN presents as a circumferential, black-appearing, diffusely necrotic esophageal mucosa, preferentially affecting the distal esophagus, of variable length, that stops abruptly at the GEJ. Proximal extension of the mucosal injury is common and the entire esophagus can appear black. Differential diagnosis includes malignant melanoma, acanthosis nigricans, coal dust deposition, pseudomelanosis, and melanocytosis of the esophagus[54-63]. Detailed history and physical examination provide essential clues to the diagnosis. Classic endoscopic appearance may be supported by brush cytology or biopsy specimen that will confirm the diagnosis. This is especially important in rare cases of isolated involvement of proximal and middle esophagus. Additionally, a history of corrosive ingestion[64] should be sought for and diligently excluded.

CLINICAL DIAGNOSIS

The characteristic endoscopic appearance described above makes the diagnosis of AEN. Almost universal predilection to the distal esophagus (97%) is a remarkable feature of this disorder[2]. Additional endoscopic findings may include duodenal peptic ulcer disease, erosions, edema, and sings of gastric outlet obstruction[23]. Early evaluation may also be notable for signs of bleeding, including active oozing from the distal esophagus and blood clots and "coffee grounds" material in the stomach. Esophageal biopsy or brushings of the affected esophageal tissue are supportive but not required to make the proper diagnosis. Histological findings include absence of viable epithelium, abundant necrotic debris, and necrotic changes in the mucosa, possibly extending into the submucosa and even muscularis propria. Full-thickness necrosis has been described in the surgical specimens. Associated findings may include heavy leukocytic infiltrate, visible vascular thrombi, deranged muscle fibers, and severe inflammatory changes[2]. Biopsy specimens should be sent for bacterial, fungal, and viral cultures to exclude infectious etiologies associated with AEN or a superimposed infection[7,26]. Special care should be taken to evaluate for the presence of multinucleated giant cells or viral inclusion bodies, particularly in immunocompromised patients. At this time, the role of angiography for diagnosis of AEN is not clearly defined, likely related to its potential risks, lack of effective therapeutic intervention in the absence of a recognizable lesion, and tendency for a spontaneous recovery with correction of the underlying medical illness.

Upper gastrointestinal bleeding in a patient with multiple medical conditions, vasculopathy, hemodynamic compromise, general debilitation, malignancy, ischemic disease, and hypercoagulable state should raise the possibility of AEN among other diagnoses. A strong association between diabetic ketoacidosis and AEN has been suggested by some authors, with four cases of black esophagus seen in 29 hospital admissions (14%)[16].

DISEASE COURSE AND STAGING

Generally, uncomplicated AEN follows an indolent clinical course and has a predictable endoscopic and histopathological trajectory. The recently proposed staging system attempts to classify disease progression and detail the distinct phases of AEN[2]. Stage 0 designates a prenecrotic viable esophagus. Stage 1 refers to an acutely diseased organ with an endoscopic picture dominated by a striking diffuse, circumferential, black-appearing esophageal mucosa with occasional yellow exudates and signs of friability, loss of light reflex, rigidity and under-distension of the lumen. These endoscopic findings nearly universally start at the GEJ, involve the distal esophagus, and variably extend proximally, potentially covering the entire organ. Histological appearance is notable for lack of viable squamous epithelium, presence of necrotic debris, and pronounced necrosis of the mucosa with possible extension into the submucosa and muscularis propria. Associated findings may include heavy leukocytic infiltrate with severe inflammatory changes, visible vascular thrombi, deranged muscle fibers, and mucosal infection with viral, fungal, and bacterial pathogens. Stage 2 describes the healing phase of the AEN dominated by residual black areas in the esophagus and thick white exudates composed of necrotic debris that cover friable pink mucosa. This "chess-board" appearance can sometimes be the presenting endoscopic picture of AEN on delayed endoscopy. The exact timing of this change is unknown and it likely parallels the underlying general condition of the patient. However, it has been observed as late as 1 mo after the diagnosis. Stage 2 is also notable for some improvement

in histological appearance of the esophageal tissue, with scattered areas of necrosis among underlying cellular regeneration, granulation tissue, and inflammatory changes. As early as 1-2 wk after diagnosis, the esophageal mucosa acquires its normal endoscopic appearance in stage 3 of the AEN with only microscopically present granulation tissue, a sequelae of recent injury.

COMPLICATIONS

The most serious complication of AEN is perforation, which can occur in severe cases that result in full-thickness necrosis of the esophageal tissue. Its reported incidence is just below 7%[2], and should be suspected in rapidly decompensating patients. Traumatic or spontaneous rupture of the thoracic aorta resulting in extrinsic esophageal compression by hematoma, photodynamic therapy for esophageal cancer, herniated gastric volvulus, and severe thromboembolic disease place a patient at a higher risk for this complication. Perforation can be seen in stage 1 of the disease, and it may lead to rapid clinical deterioration, mediastinitis, mediastinal abscess formation, empyema, and generalized sepsis. Prompt recognition, intravenous antibiotics, and surgical intervention are life-saving. Mortality may be especially high given a generally poor underlying medical condition and a limited reserve in many patients with AEN.

Another possible sequela of AEN is the formation of stenotic areas or strictures, which can be seen in > 10% of patients. These findings typically occur in stages 2 and 3 of the disease and likely result from protective scar formation during the acute, reparative, and healing phase of AEN. Acid suppression followed by possible endoscopic dilatation, if needed, typically produces resolution of reported symptoms.

Microbial superinfection of necrotic media is an important consideration in treating patients with AEN[26]. Patients should be diligently monitored for early signs of clinical decompensation and sepsis with prompt institution of intravenous antimicrobial therapy.

MANAGEMENT

Development of AEN carries a generally poor prognosis and the goal of therapy should be directed at treating the coexisting medical diseases. Timely systemic resuscitation and patient stabilization play pivotal roles in the management of this disease. Intravenous hydration, correcting anemia with packed red blood cell transfusion, and keeping the patient nil-per-os should be instituted. Parenteral support may be needed in malnourished patients to improve their nutritional status and expedite healing. Passage of the nasogastric tube should not be undertaken, to avoid perforation.

Medical management of AEN includes aggressive intravenous proton pump inhibitor or histamine receptor blocker therapy until improvement in clinical status, at which time, a change to an oral formulation is appropriate. Probably, oral therapy should be continued for a few months after the resolution of symptoms to aid prevention of stricture formation, in the absence of underlying reflux disease. Recent reports of esophageal manometry and pH monitoring in patients with AEN have shown a lack of significant acid reflux and normal motility at 5-7 mo after recovery[23,65]. Oral suspension of sucralfate may be used as a single therapy or as a supplement to the intravenous acid-reducing agents, excluding the cases with concomitant renal failure.

Antimicrobial therapy is important in the setting of positive esophageal cultures, stains for fungal agents, or visualization of multinucleated giant cells or inclusion bodies on histological evaluation of the biopsy specimen. Empirical antibiotics should be initiated in cases of suspected esophageal perforation, rapid clinical decompensation, unexplained fevers, and immune compromise in AIDS, cirrhosis, transplant recipient, and dialysis patients. Prophylactic use of antibiotics in sterile necrosis is probably not necessary and few reports have potentially linked the antibiotic use itself to the development of AEN[49].

Surgical intervention in patients with AEN is reserved for perforated esophagus with resultant mediastinitis and abscess formation. Esophagectomy, decortication, lavage, and delayed reconstruction may be performed in addition to standard surgical approaches in the setting of gastric volvulus or transected thoracic aorta. Primary closure of the perforated esophageal tissue should not be attempted. Subtotal esophagectomy and esophagogastrostomy have been reported in AEN-induced esophageal stricture that was refractory to repeated dilatations[3,26].

PROGNOSIS AND ROLE OF REPEAT ENDOSCOPY

Prognosis of AEN largely depends on coexisting medical conditions and ordinarily parallels the general state of health of a patient. As a rule, overall prognosis is poor with nearly one third of patients succumbing to the underlying critical illness. However, mortality specific to the AEN is much lower, at around 6%[2]. Important risk factors include esophageal perforation, diabetic ketoacidosis, and compromised immune system. Overall, reversible phenomena of the disease and its tendency for spontaneous healing are favorable factors in predicting complete recovery in otherwise healthy individuals. Relapsing AEN has been reported only once[66] but may be an important diagnosis to consider in the appropriate clinical setting. It may also explain some of the observed color changes of black esophagus reported in the literature[4]. Repeat endoscopic evaluation should be done to assess mucosal healing and document resolution of AEN, as well as to determine the duration of antacid therapy. Endoscopic sessions with balloon dilatation may be necessary in patients suffering from dysphasia in the setting of esophageal stenosis or stricture formation, which are well-known complications of AEN.

CONCLUSION

AEN is a rare syndrome that arises in the characteristic

clinical setting of combined ischemia from hemodynamic compromise, gastric outlet obstruction with backflow chemical injury, and inadequate protective barriers and physiological reserve due to critical illness and general deconditioning. It presents with signs of upper gastrointestinal bleeding and has a characteristic appearance on upper endoscopy of circumferential, diffuse, black-appearing, friable esophageal mucosa, almost universally affecting the distal part of the organ and abruptly ending at the GEJ. Histological tissue necrosis confirms the diagnosis. Treatment relies on aggressive resuscitation, correction of underlying medical conditions, institution of therapy with proton pump inhibitors and sucralfate, and monitoring for signs of infection or perforation. Mortality is high and is largely related to the principal medical conditions and the gravity of the overall state of health.

REFERENCES

1 **Sako A**, Kitayama J, Inoue T, Kaizaki S, Nagawa H, Suzuki H. Black oesophagus--cause? *Gut* 2005; **54**: 192, 227

2 **Gurvits GE**, Shapsis A, Lau N, Gualtieri N, Robilotti JG. Acute esophageal necrosis: a rare syndrome. *J Gastroenterol* 2007; **42**: 29-38

3 **Goldenberg SP**, Wain SL, Marignani P. Acute necrotizing esophagitis. *Gastroenterology* 1990; **98**: 493-496

4 **Le K**, Ahmed A. Acute necrotizing esophagitis: case report and review of the literature. *J La State Med Soc* 2007; **159**: 330, 333-330, 338

5 **Lacy BE**, Toor A, Bensen SP, Rothstein RI, Maheshwari Y. Acute esophageal necrosis: report of two cases and a review of the literature. *Gastrointest Endosc* 1999; **49**: 527-532

6 **Ben Soussan E**, Savoye G, Hochain P, Hervé S, Antonietti M, Lemoine F, Ducrotté P. Acute esophageal necrosis: a 1-year prospective study. *Gastrointest Endosc* 2002; **56**: 213-217

7 **Grudell AB**, Mueller PS, Viggiano TR. Black esophagus: report of six cases and review of the literature, 1963-2003. *Dis Esophagus* 2006; **19**: 105-110

8 **Cappell MS**. Esophageal necrosis and perforation associated with the anticardiolipin antibody syndrome. *Am J Gastroenterol* 1994; **89**: 1241-1245

9 **Odelowo OO**, Hassan M, Nidiry JJ, Marshalleck JJ. Acute necrotizing esophagitis: a case report. *J Natl Med Assoc* 2002; **94**: 735-737

10 **Marie-Christine BI**, Pascal B, Jean-Pierre P. Acute necrotizing esophagitis: another case. *Gastroenterology* 1991; **101**: 281-282

11 **Hawari R**, Pasricha PJ. Esophageal infarction. *Curr Treat Options Gastroenterol* 2007; **10**: 57-60

12 **Moretó M**, Ojembarrena E, Zaballa M, Tánago JG, Ibánez S. Idiopathic acute esophageal necrosis: not necessarily a terminal event. *Endoscopy* 1993; **25**: 534-538

13 **Augusto F**, Fernandes V, Cremers MI, Oliveira AP, Lobato C, Alves AL, Pinho C, de Freitas J. Acute necrotizing esophagitis: a large retrospective case series. *Endoscopy* 2004; **36**: 411-415

14 **Postlethwait RW**, Musser AW. Changes in the esophagus in 1,000 autopsy specimens. *J Thorac Cardiovasc Surg* 1974; **68**: 953-956

15 **Etienne JP**, Roge J, Delavierre P, Veyssier P. [Esophageal necrosis of vascular origin] *Sem Hop* 1969; **45**: 1599-1606

16 **Yasuda H**, Yamada M, Endo Y, Inoue K, Yoshiba M. Acute necrotizing esophagitis: role of nonsteroidal anti-inflammatory drugs. *J Gastroenterol* 2006; **41**: 193-197

17 **Park JH**, Kim HC, Chung JW, Jae HJ, Park JH. Transcatheter arterial embolization of arterial esophageal bleeding with the use of N-butyl cyanoacrylate. *Korean J Radiol* 2009; **10**: 361-365

18 **Long JD**, Orlando RC. Anatomy, histology, embryology, and developmental anomalies of the esophagus. In: Feldman M, Friedman LS, Brandt LJ, editors. Gastrointestinal and liver disease. 8th ed. Philadelphia: Saunders Elsevier, 2006: 841-853

19 **Sandler AD**, Schmidt C, Richardson K, Murray J, Maher JW. Regulation of distal esophageal mucosal blood flow: the roles of nitric oxide and substance P. *Surgery* 1993; **114**: 285-293; discussion 293-294

20 **Luketich JD**, Friedman DM, Weigel TL, Meehan MA, Keenan RJ, Townsend DW, Meltzer CC. Evaluation of distant metastases in esophageal cancer: 100 consecutive positron emission tomography scans. *Ann Thorac Surg* 1999; **68**: 1133-1136; discussion 1136-1137

21 **Bass BL**, Schweitzer EJ, Harmon JW, Kraimer J. H+ back diffusion interferes with intrinsic reactive regulation of esophageal mucosal blood flow. *Surgery* 1984; **96**: 404-413

22 **Baffy G**, Strate LL, Krnsky ML. Image of the month. Adherent, yellow exudate speckled with black spots in the distal two thirds of the esophagus. Diagnosis: This distinctive endoscopic image shows an acute necrotizing esophagitis, also known as the black esophagus. *Gastroenterology* 2000; **118**: 252, 453

23 **Reichart M**, Busch OR, Bruno MJ, Van Lanschot JJ. Black esophagus: a view in the dark. *Dis Esophagus* 2000; **13**: 311-313

24 **Goldenberg SP**, Wain SL, Marignani P. Acute necrotizing esophagitis: another case; reply. *Gastroenterology* 1991; **101**: 281-282

25 **Endo T**, Sakamoto J, Sato K, Takimoto M, Shimaya K, Mikami T, Munakata A, Shimoyama T, Fukuda S. Acute esophageal necrosis caused by alcohol abuse. *World J Gastroenterol* 2005; **11**: 5568-5570

26 **Kim YH**, Choi SY. Black esophagus with concomitant candidiasis developed after diabetic ketoacidosis. *World J Gastroenterol* 2007; **13**: 5662-5663

27 **Casella G**, Perego D, Corti G, Cambareri AR, Buda CA, Zoldan C, Baldini V. Black esophagus: should it be considered an unfavorable prognostic factor? *Dis Esophagus* 2001; **14**: 166-168

28 **Brennan JL**. Case of extensive necrosis of the oesophageal mucosa following hypothermia. *J Clin Pathol* 1967; **20**: 581-584

29 **Burtally A**, Gregoire P. Acute esophageal necrosis and low-flow state. *Can J Gastroenterol* 2007; **21**: 245-247

30 **Haviv YS**, Reinus C, Zimmerman J. "Black esophagus": a rare complication of shock. *Am J Gastroenterol* 1996; **91**: 2432-2434

31 **de la Serna-Higuera C**, Martínez J, Martín-Arribas MI, Rodríquez-Gómez S, Pérez-Villoria A, Betancourt A. Acute necrotizing esophagitis. *Gastrointest Endosc* 2001; **54**: 225

32 **Cummings DR**. Acute necrotizing esophagitis. *Gastroenterology* 1991; **101**: 281-282

33 **Katsinelos P**, Pilpilidis I, Dimiropoulos S, Paroutoglou G, Kamperis E, Tsolkas P, Kapelidis P, Limenopoulos B, Papagiannis A, Pitarokilis M, Trakateli C. Black esophagus induced by severe vomiting in a healthy young man. *Surg Endosc* 2003; **17**: 521

34 **Săftoiu A**, Cazacu S, Kruse A, Georgescu C, Comănescu V, Ciurea T. Acute esophageal necrosis associated with alcoholic hepatitis: is it black or is it white? *Endoscopy* 2005; **37**: 268-271

35 **Hoffman M**, Bash E, Berger SA, Burke M, Yust I. Fatal necrotizing esophagitis due to Penicillium chrysogenum in a patient with acquired immunodeficiency syndrome. *Eur J Clin Microbiol Infect Dis* 1992; **11**: 1158-1160

36 **Trappe R**, Pohl H, Forberger A, Schindler R, Reinke P. Acute esophageal necrosis (black esophagus) in the renal transplant recipient: manifestation of primary cytomegalovirus infection. *Transpl Infect Dis* 2007; **9**: 42-45

37 **Cattan P**, Cuillerier E, Cellier C, Carnot F, Landi B, Dusoleil A, Barbier JP. Black esophagus associated with herpes esophagitis. *Gastrointest Endosc* 1999; **49**: 105-107

38 **Khan AM**, Hundal R, Ramaswamy V, Korsten M, Dhuper S. Acute esophageal necrosis and liver pathology, a rare combination. *World J Gastroenterol* 2004; **10**: 2457-2458

39 **Katsuhara K**, Takano S, Yamamoto Y, Ueda S, Nobuhara K,

Kiyasu Y. Acute esophageal necrosis after lung cancer surgery. *Gen Thorac Cardiovasc Surg* 2009; **57**: 437-439
40 **Liu YH**, Lin YS, Chen HJ, Tu CY, Chen W. Klebsiella pneumoniae deep neck infection with acute necrotizing esophagitis. *South Med J* 2009; **102**: 219
41 **Barjas E**, Pires S, Lopes J, Valente A, Oliveira E, Palma R, Raimundo M, Alexandrino P, Moura MC. Cytomegalovirus acute necrotizing esophagitis. *Endoscopy* 2001; **33**: 735
42 **Mahé A**, Kéita S, Blanc L, Bobin P. Esophageal necrosis in the Stevens-Johnson syndrome. *J Am Acad Dermatol* 1993; **29**: 103-104
43 **Kram M**, Gorenstein L, Eisen D, Cohen D. Acute esophageal necrosis associated with gastric volvulus. *Gastrointest Endosc* 2000; **51**: 610-612
44 **Macedo G**, Correia A, Maia J, Ribeiro T. Re: black esophagus. *Am J Gastroenterol* 1998; **93**: 855-856
45 **Mall JW**, Zuckermann-Becker H, Pollmann C, Opitz I, Rogalla P, Walter M. Esophageal necrosis and perforation of the left main bronchus following photodynamic therapy of esophageal carcinoma. *Thorac Cardiovasc Surg* 2002; **50**: 111-113
46 **Park NH**, Kim JH, Choi DY, Choi SY, Park CK, Lee KS, Han SW, Yoo YS. Ischemic esophageal necrosis secondary to traumatic aortic transection. *Ann Thorac Surg* 2004; **78**: 2175-2178
47 **Watermeyer GA**, Shaw JM, Krige JE. Education and imaging. Gastrointestinal: acute necrotizing esophagitis. *J Gastroenterol Hepatol* 2007; **22**: 1162
48 **Agarwal N**, Kumar S, Sharma MS, Agrawal R, Joshi M. Emphysematous gastritis causing gastric and esophageal necrosis in a young boy. *Acta Gastroenterol Belg* 2009; **72**: 354-356
49 **Mangan TF**, Colley AT, Wytock DH. Antibiotic-associated acute necrotizing esophagitis. *Gastroenterology* 1990; **99**: 900
50 **Neumann DA 2nd**, Francis DL, Baron TH. Proximal black esophagus: a case report and review of the literature. *Gastrointest Endosc* 2009; **70**: 180-181
51 **Gurvits GE**, Robilotti JG. Isolated proximal black esophagus: etiology and the role of tissue biopsy. *Gastrointest Endosc* 2010; **71**: 658
52 **Rejchrt S**, Douda T, Kopácová M, Siroký M, Repák R, Nozicka J, Spacek J, Bures J. Acute esophageal necrosis (black esophagus): endoscopic and histopathologic appearance. *Endoscopy* 2004; **36**: 1133
53 **Erdozain JC**, Herrera A, Molina E, Muñoz F, Presa M, Martin-de-Argila C. Idiopathic acute esophageal necrosis: report of a new case. *Endoscopy* 1994; **26**: 713
54 **Obermeyer R**, Kasirajan K, Erzurum V, Chung D. Necrotizing esophagitis presenting as a black esophagus. *Surg Endosc* 1998; **12**: 1430-1433
55 **Khan HA**. Coal dust deposition--rare cause of "black esophagus". *Am J Gastroenterol* 1996; **91**: 2256
56 **Geller A**, Aguilar H, Burgart L, Gostout CJ. The black esophagus. *Am J Gastroenterol* 1995; **90**: 2210-2212
57 **Raven RW**, Dawson I. Malignant melanoma of the oesophagus. *Br J Surg* 1964; **51**: 551-555
58 **Kimball MW**. Pseudomelanosis of the esophagus. *Gastrointest Endosc* 1978; **24**: 121-122
59 **Sharma SS**, Venkateswaran S, Chacko A, Mathan M. Melanosis of the esophagus. An endoscopic, histochemical, and ultrastructural study. *Gastroenterology* 1991; **100**: 13-16
60 **Dumas O**, Barthélémy C, Billard F, Dumollard JM, Boucheron S, Calmard P, Rousset H, Audigier JC. Isolated melanosis of the esophagus: systematic endoscopic diagnosis. *Endoscopy* 1990; **22**: 94-95
61 **Ertekin C**, Alimoglu O, Akyildiz H, Guloglu R, Taviloglu K. The results of caustic ingestions. *Hepatogastroenterology* 2004; **51**: 1397-1400
62 **Chang F**, Deere H. Esophageal melanocytosis morphologic features and review of the literature. *Arch Pathol Lab Med* 2006; **130**: 552-557
63 **Kozlowski LM**, Nigra TP. Esophageal acanthosis nigricans in association with adenocarcinoma from an unknown primary site. *J Am Acad Dermatol* 1992; **26**: 348-351
64 **Boybeyi O**, Karnak I, Tanyel FC, Senocak ME. Management of unusually extensive esophagogastric corrosive injuries: emergency measures and gastric reconstruction. *J Pediatr Surg* 2009; **44**: 1022-1026
65 **Yamauchi J**, Mitsufuji S, Taniguchi J, Sakai M, Tatsumi N, Yasuda Y, Konishi H, Wakabayashi N, Kataoka K, Okanoue T. Acute esophageal necrosis followed by upper endoscopy and esophageal manometry/pH test. *Dig Dis Sci* 2005; **50**: 1718-1721
66 **Tanaka K**, Toyoda H, Hamada Y, Aoki M, Kosaka R, Noda T, Katsurahara M, Nakamura M, Ninomiya K, Inoue H, Imoto I, Takei Y. A relapse case of acute necrotizing esophagitis. *Endoscopy* 2007; **39** Suppl 1: E305

S- Editor Wang YR **L- Editor** Kerr C **E- Editor** Ma WH

World Journal of Gastroenterology

Online Submissions: http://www.wjgnet.com/1007-9327office
wjg@wjgnet.com
doi:10.3748/wjg.v16.i26.3226

World J Gastroenterol 2010 July 14; 16(26): 3226-3234
ISSN 1007-9327 (print)
© 2010 Baishideng. All rights reserved.

EDITORIAL

Helicobacter pylori and gastric cancer in the Middle East: A new enigma?

Nawfal R Hussein

Nawfal R Hussein, Institute of Infection, Immunity and Inflammation and the Centre for Biomolecular Sciences, University of Nottingham, Nottingham, NG7 2RD, United Kingdom
Author contributions: Hussein NR solely contributed to this paper.
Supported by The University of Nottingham
Correspondence to: Dr. Nawfal R Hussein, MD, PhD, Institute of Infection, Immunity and Inflammation and the Centre for Biomolecular Sciences, University of Nottingham, Nottingham, NG7 2RD, United Kingdom. nawfal.hussein@nottingham.ac.uk
Telephone: +44-115-8468925 Fax: +44-115-8468002
Received: February 8, 2010 Revised: April 19, 2010
Accepted: April 26, 2010
Published online: July 14, 2010

Abstract

The Middle East is the home of ethnic groups from three main backgrounds: Semitic (Arabs and Jews), Indo-European (Persians and Kurdish) and Turkic (Turkish and Turkmens). Its geographic location, which has been under continuous influences from Asia, Europe and Africa, has made it an ideal site for epidemiological studies on *Helicobacter pylori* (*H. pylori*) infection and genotyping. The gastric cancer rate differs in this region from very high in Iran ($26.1/10^5$) to low in Israel ($12.5/10^5$) and very low in Egypt ($3.4/10^5$). Epidemiological studies showed that the prevalence of *H. pylori* is almost similar in those countries with a high level of infection in childhood. Importantly, the frequency of *vacA* s1 and m1 regions and *cagA*+ genotypes were higher in non Semitic populations who inhabit the North than Semitic populations, the inhabitants of Southern parts of the Middle East. *H. pylori* infection prevalence, distribution pattern of virulence factors, diet and smoking could not have explained the difference in cancer rate. This reflects the multifactorial aetiology of gastric cancer and suggests that *H. pylori* infection does not always directly correlate with the risk for gastrointestinal disease, such as gastric cancer. Further detailed investigations and international comparative studies of each risk factor need to be performed to investigate whether this represents a true enigma.

© 2010 Baishideng. All rights reserved.

Key words: *Helicobacter pylori*; Middle East; Gastric cancer; *dupA*; *cagA*; *vacA*; *iceA*

Peer reviewer: Ulrich KS Peitz, MD, Department of Gastroenterology, Hepatology and Infectious Disease, Otto-von-Guericke University Magdeburg, Leipziger Str. 44, D 39120 Magdeburg, Germany

Hussein NR. *Helicobacter pylori* and gastric cancer in the Middle East: A new enigma? *World J Gastroenterol* 2010; 16(26): 3226-3234 Available from: URL: http://www.wjgnet.com/1007-9327/full/v16/i26/3226.htm DOI: http://dx.doi.org/10.3748/wjg.v16.i26.3226

INTRODUCTION

Helicobacter pylori (*H. pylori*) causes gastritis and peptic ulceration and it is an important risk factor for gastric adenocarcinoma, the second highest cause of cancer deaths worldwide. The disease process is thought to have a multifactorial aetiology, and bacterial strain type, pattern of gastritis, and environmental conditions, are all thought to contribute[1]. *H. pylori* strains differ, and possession of specific virulence factors greatly increases the risk of disease. The best recognised of these are the cag pathogenicity island and active forms of the vacuolating cytotoxin (VacA). Duodenal ulcer promoting gene A (*dupA*) is a recently described gene shown to be associated with duodenal ulceration and protective against gastric cancer[2]. It was observed that the early acquisition of *H. pylori* infection in childhood resulted in pangastritis in adulthood. This pattern of gastritis is usually associated with mucosal atrophy which is a precancerous condition[3]. Therefore, acquiring the infection at an early age is a recognised risk factor for the development of

gastric cancer[4]. Additionally, antral predominant gastritis is usually associated with duodenal ulcer. Furthermore, different environmental factors such as high salt intake and inadequate consumption of fruit and vegetables containing vitamin C has been regarded as risk a factor for development of gastric cancer[5].

The Middle East is home to ethnic groups from three main backgrounds: Semitic (Arabs and Jews), Indo-European (Persians and Kurdish) and Turkic (Turkish and Turkmens)[6-8]. Its geographic location, which has been under continuous influences from Asia, Europe and Africa, has made it an ideal site for epidemiological studies on *H. pylori* infection and genotyping. The prevalence of *H. pylori* infection has been reported from many Middle Eastern countries, including Iraq, Iran, Turkey, Libya, Egypt, Israel, Bahrain, Oman, Saudi Arabia, and the United Arab Emirates. It has been shown that the prevalence rates of infection in these countries are almost similar to each other and to the reported prevalence from Europe and United States. However, gastric cancer and other *H. pylori* related diseases rates vary from very high in Iran to rare in Iraq and Egypt (Table 1)[9]. It is not known whether the difference is due to host, environment, or bacterial factors or a combination of these factors. In this review I tried to find a reason for the difference in *H. pylori* related diseases amongst Middle Eastern countries by discussing the prevalence of *H. pylori* and its virulence determinants, the pattern of gastritis, and environmental factors that might influence the disease process in the Middle East.

PREVALENCE OF *H. PYLORI*

The prevalence of *H. pylori* infection varies between countries; generally, the prevalence is about 30% in developed and up to 80% in developing countries[5]. Diagnosis of *H. pylori* can be achieved by taking biopsies by endoscopy. However, this procedure is invasive and might not give accurate results if colonisation is patchy[10]. Furthermore, it does not suit population based studies. For population screening, serodiagnosis remains one of the methods of choice for detecting the prevalence of infection[11]. Systemic humoral immunoglobulin G (IgG) immune responses to the organism are developed by humans infected with *H. pylori*[12-14]. Serological tests are useful tools for the diagnosis of *H. pylon* infection because all *H. pylori*-infected patients produce an antibody response which can be detected in the serum[14]. The technique of choice is currently enzyme-linked immunosorbent assay because it is a simple, quick, and low-cost technique that permits immunoglobulin class-specific determinations[14].

In a study conducted in Iraq, the prevalence varied in various ages (age: percentage, 6 mo: 0%; 6-24 mo: 27%; 2-18 years: 58%). In the same study, it was shown that 78% of adults were infected with *H. pylori* which was significantly higher than children. The prevalence of *H. pylori* increased markedly with age with the maximum colonization (81.5%) occurring in adults (40-60 years)[15]. The same scenario was found in Saudi Arabia, Iran, Libya and Israel. In Saudi, the prevalence of *H. pylori* infection markedly increased with age. The prevalence of *H. pylori* infection rose from 32.4% in those aged 0-10 years to more than 66.4% in those aged 20-30 years and 75% in those over 50 years[16]. In Iran, the prevalence of *H. pylori* infection increased with age [age (years): percentage, 6-10: 46%; 10-20: 50%; 20-30: 67%; 30-40: 80%; 40-50: 85%; 50-60: 84%; 60-70: 81%; over 70: 83%][17]. In Libya, overall prevalence was 67% with a steady increase with age [age (years): percentage, 0-10: 50%; 10-20: 84%; 20-30: 66%; 30-40: 80%; 40-50: 88%; 50-60: 83%; 60-70: 83%; over 70: 94%][18]. In a study conducted in Israeli rural communal settlements with an age range from 6 to 90 years[19], the prevalence *H. pylori* infection was shown to be 72%. It was also found that the prevalence of *H. pylori* increased with age [age (years): percentage, 6-10: 10%; 10-20: 39%; 30-40: 60%; 40-60: 70%; over 60: 85%]. In the same study, a significant association was shown between *H. pylori* infection and the country of origin of Israeli migrants. The highest prevalence (85%) was found in migrants from the Mediterranean and Asia. While 80% of East European migrants were *H. pylori* positive, the prevalence in West Europeans was 57%. The prevalence in people born in Israel was 66%. The association between *H. pylori* infection and country of origin was not changed after age adjustment[19].

In Turkey[20], the overall prevalence of *H. pylori* infection was 81%. There is no marked difference in *H. pylori* prevalence in different ages [age (years): percentage, 0-10: 70%; 10-20: 83%; 20-30: 77%; 30-40: 87%; 40-50: 88%; 50-60: 90%].

In some countries in the Middle East, the prevalence of *H. pylori* infection has been studied using polymerase chain reaction and histopathology. The prevalence of *H. pylori* infection in Jordan and Bahrain was 77.5% and 79%, respectively[21,22]. In Kuwait and Egypt, *H. pylori*, as detected by H and E and *H. pylori* special stains, was present in 84% and 86% of the biopsy samples, respectively[23,24]. There was no significant difference in the prevalence of infection between male and female subjects in this region. In a study conducted in Western Saudi, the prevalence of VacA and CagA were significantly elevated in males *vs* females[25]. In another study in Jordan, there was a clear trend that females were infected with less virulent *H. pylori* strains, though the correlation was not significant[22].

INCIDENCE OF GASTRIC CANCER IN THE MIDDLE EAST

Despite declining incidence rates in Western countries, gastric cancer remains the second most common cancer type and second cause of cancer-related death worldwide. *H. pylori* infection is strongly associated with gastric cancer risk. Gastric cancer rate varies from country to country and from region to region. For example, it is very high in Japan ($62.7/10^5$) and estimated to be 12 times higher than India[9]. Gastric cancer occurs nearly 7 times more frequently in Iran than in Iraq (Table 1). These data might not be very accurate because of incompetent di-

Table 1 Prevalence of atrophy, gastric cancer and the distribution of *vacA* allelic types and *cagA* status among *H. pylori* strains isolated in the Middle East

Country	s1 (%)	s2 (%)	m1 (%)	m2 (%)	i1 (%)	i2 (%)	*cagA* (%)	Atrophy (%)	Male gastric cancer
Saudi Arabia	58.3[61]	41.7[61]	12.6[61]	87.4[61]	No data	No data	52.0[43]	3-19[77]	$5.7/10^5$
Kuwait	46.4[23]	53.6[23]	No data	No data	No data	No data	41.0[23]	28[75]	$4.8/10^5$
Jordan	45.3[22]	54.7[22]	48.9[22]	51.1[22]	No data	No data	26.4[22]	65[76]	$6.6/10^5$
Iran	69.2[39]	30.8[39]	30.8[39]	69.2[39]	36.5[39]	63.5[39]	76.0[39]	22-39[74]	$26.1/10^5$
Iraq	88.6[39]	11.4[39]	25.7[39]	74.3[39]	28.5[39]	71.5[39]	71.0[39]	3[69]	$4.5/10^5$
Turkey	94.8[40]	5.2[40]	22.2[40]	77.8[40]	No data	No data	78.0[40]	43-75[72,73]	$12.2/10^5$
Egypt	42.9[41]	57.1[41]	14.3[41]	85.7[41]	No data	No data	35.7[41]	54[24]	$3.4/10^5$

agnostic methods, limitation of medical services, and the lack of unique reporting systems. However, I searched through all published literature and could not find any major discordance. Despite the geographical proximity, the gastric cancer rate varies from very low in Iraq and Egypt to intermediate in Israel and Turkey to high in Iran (Table 1)[9,26-28]. Interestingly, *H. pylori* infection prevalence in these countries is relatively high and almost the same. This discordance between gastric cancer incidence and *H. pylori* seroprevalence might imply that *H. pylori* infection is not the only factor related to gastric cancer risk[29,30]. A 6-fold variation was found in the association between gastric cancer risk and *H. pylori* infection[31]. *H. pylori* virulence factors, immune response, diet, environment, and other factors should be considered.

BACTERIAL VIRULENCE FACTORS

Cytotoxin associated gene A

The cytotoxin associated gene A (CagA) protein, which is encoded by the *cagA* gene, is a highly immunogenic protein. *H. pylori* strains possessing *cagA* are associated with a significantly increased risk for the development of atrophic gastritis, peptic ulcer diseases and gastric cancer[32-36]. The *cagA* gene is situated at one end of a 40 kb DNA insertion called the *cag* PAI and may have been acquired from a non-*Helicobacter* origin[33,37]. The *cag* PAI contains approximately 30 genes which are multicistronic. The difference in the ability of *H. pylori* strains to trigger chemokines from gastric mucosa depends upon the expression of genes within the *cag* PAI[33,37,38].

Strains from Iraq, Turkey and Iran possessing *cagA* were found in 71%, 78% and 76% of the samples analysed, respectively. *cagA* presence was significantly associated with peptic ulcer disease incidence in Iraq and Turkey but not in Iran[39,40]. In Iraq, the majority of the population are Arabs. However in a study by Hussein *et al*[39], samples were collected from Kurdish majority (Kurdistan) region.

In Jordan, the *cagA* genotype was detected in 26.4%[22]. While Kuwaitis and other Arabian Gulf Arabs had essentially the same prevalence rate of about 41%, Egyptians had a modest positivity of 35.7%[23,41]. In a study conducted in Israel, *cagA* and *cagE* genes were present in only 25.5% and 24.5%, respectively[42]. The prevalence of *cagA* positivity in Saudi was 52%[43]. *cagA* was associated with gastric cancer and/or peptic ulceration in Iran, Iraq, Saudi, Turkey and Israel[39,42-45]. However, Hussein *et al*[39] could not find significant relationships between *cagA* status and disease risk in the Iranian population.

Argent *et al*[46], suggested that the presence or absence of *cagA* is not enough to understand the relationship between *cagA* and clinical outcomes. It was found that there was a size variation of the CagA protein and this variation was shown to be related to the presence of the repeat tyrosine phosphorylation motifs (TPM) sequences containing the EPIYA within the 3' variable ends[47]. It was found that *H. pylori* strains in Western and East Asian countries carry the EPIYA-A, EPIYA-B. While Western *H. pylori* strains carry Western *cagA*-specific EPIYA-C segments which vary in number ranging from 1-3[48], East Asian strains carry the CagA-specific EPIYA-D motif. We previously studied the TPM of the *cagA* in Iraq and Iran. The presence of *cagA* alleles with more than 3 phosphorylation motifs was significantly higher amongst Iranian strains than those from Iraq (there was no Iraqi *cagA*-positive strain with more than 3 TPM, 12% in Iran). We thought that the presence of *cagA* with more phosphorylation motifs in Iran may help explain the higher cancer incidence rate in Iran[39]. However, a recent study from Turkey, where the gastric cancer rate is much lower than Iran, found that 34% of *cagA*-positive Turkish strains carried more than three motifs. For the first time, in this study, they reported a *cagA* positive strain with 5 C motifs[49]. The absence of *cagA* with more than 3 motifs in Iraq can be due to a type 2 error.

There is clear discrimination in *cagA* distribution between Semitic (Arab and Jew) and non Semitic (Kurd, Turk and Persian) populations[39,40,50]. Semitic populations tend to carry less virulent *H. pylori*[22,23,41]. The *cagA* positivity in Saudi Arabia is higher than other Semitic countries. This might be due the fact that Saudi society has been influenced by Hajj.

VacA

The VacA is another *H. pylori* virulence factor[35]. Unlike *cagA*, almost all *H. pylori* strains posses the vacuolating cytotoxin gene (*vacA*). Vacuolating cytotoxin activity is related to the mosaic structure of *vacA*. In general, type s1/m1 and s1/m2 strains produce high and moderate levels of toxin activity, respectively, whereas s2/m2 strains produce no vacuolating activity[51]. A 12-amino-acid hydrophilic amino-terminal segment, present in type s2 but absent from type s1 *VacA* proteins, slows the capacity of *VacA* to form membrane channels and abolishes vacuolation.

Some type s1/m2 *VacA* toxins show cytotoxic activity toward selected cell types, including RK-13, but relatively little activity for HeLa or AGS cells[51-53]. Heterogeneity among *vacA* alleles may be an important factor in understanding variations in clinical manifestations among *H. pylori*-infected subjects. Several studies have demonstrated that gastric infection with *H. pylori* strains containing type s1 *vacA* alleles is associated with a higher risk for development of peptic ulcer disease than infection with strains containing type s2 *vacA* alleles[51]. This relation is not seen in East Asia as the vast majority of East Asian strains are *vacA* type s1[51,54-56]. Thus in these countries, s1 cannot be used as a marker for the presence of peptic ulcer disease because the prevalence of the s1 genotype is uniformly high.

Rhead *et al*[45] have described a novel determinant of VacA toxicity, called the intermediate or i-region. They showed that two allelic variants of this region existed, i1, and i2. Furthermore, only s1/m2 strains varied in i-type; s1/m1 and s2/m2 strains were exclusively i1 and i2, respectively. This novel region determines vacuolating activity among these s1/m2 strains. More importantly, a significant correlation has been established between the i1 region and gastric cancer[45]. In contrast to Rhead *et al*[45], no disease association between *vacA* i genotypes and outcome was found in East Asian and Southeast Asian countries. More studies, from other countries, are needed to determine whether this region is a true virulence determinant[57].

The studies from Turkey, Iran and Iraq (non-Semitic countries) had a high prevalence of *vacA* s1 genotype of more than 70%, whereas strains from Semitic countries such as Egypt, Jordan, Saudi Arabia, Kuwait and Israel, had a low prevalence of less than 60%. The prevalence of *vacA* s1 genotype in the non Semitic countries was significantly higher than that in the Semitic countries[41,58].

Reports from Turkey, Iraq and Iran showed that *vacA* m2 was found in around 70% of typed strains. In Egypt, Saudi and Israel, the percentage of *vacA* m2 was between 85% and 92%. 51.1% of Jordanian strains typed *vacA* m2. *vacA* i region was studied in Iran and Iraq only. *vacA* i1 was associated with gastric cancer and gastric ulcer in Iran and Iraq, respectively.

Studies from Iraq, Kuwait, Jordan, Israel and Iran did not show any association between *vacA* s and m genotypes and gastroduodenal diseases[22,23,39,42,59]. In Iraq, an association with gastroduodenal diseases and *vacA* i-region genotype was shown. Studies from Iran and Turkey[44,60] reported a significant relationship between *vacA* s1 genotype and peptic ulcers. The *vacA* m1 genotype was linked to an increased risk for peptic ulcers in Turkey and Saudi Arabia[61,62].

Studies from Iran, Iraq, Jordan, Turkey and Israel have shown a significant association between *cagA* status and *vacA* s1, m1 and/or i1 genotypes[22,39,42,44,45]. In *cagA*-negative strains, most of the *vacA* genotypes were i2 genotypes[58].

Other virulence factors

***dupA*:** Recently, a novel virulence factor *dupA* (duodenal ulcer promoting gene A) (jhp0917-jhp0918) was shown to be associated with duodenal ulceration and increased epithelial cell interleukin-8 secretion[2]. The *dupA* gene is located in the region of the bacterial genome that encodes surface proteins. A significant relationship between *dupA* and duodenal ulcer was found, and the presence of *dupA* was associated with neutrophil infiltration. These findings, however, were not confirmed in a study of Brazilian children and adults[63], thus indicating possible geographic differences. More recently, it has been found that *dupA* was not significantly associated with duodenal ulceration in populations from Belgium, South Africa, China, and the USA, but was significantly associated with gastric cancer development[64]. In the Middle East, *dupA* was studied in Iraq and Iran. *dupA* was found to be associated with duodenal ulcers in Iraq but not Iran[39]. In addition, *dupA*-negative *H. pylori* strains were found to associate with pre-malignant lesions in Iran[65]. No other studies have been conducted in the Middle East. More studies are needed to address the prevalence of *dupA*-negative strains and the association between this gene and clinical outcome.

***iceA*:** *iceA* (induced by contact with epithelium) exists in allelic variants including *iceA*1 and *iceA*2. *iceA*1 only can be induced in the gastric epithelium. The *iceA*1-positive *H. pylori* strains were shown to be associated with peptic ulceration and increased mucosal IL-8 secretion, while a higher prevalence of *iceA*2 strains was found among patients with non-ulcer dyspepsia[66,67]. In Turkey, *iceA*1 was found to be positive in 32.2% of the strains[68]. In Jordan, analyses of virulence genes revealed that *iceA*2 (73.6%) was the predominant genotype[22]. In a study conducted in Saudi, it was shown that all ulcer cases were infected with *iceA*1, while 94.6% of gastritis and 90.9% of normal subjects were infected with *iceA*2[43]. In Israel, *iceA1* was found in 37% and *iceA*2 in 52% of cases. Both *iceA* alleles were found in 11%[42]. More research is needed to study *iceA* and its association with diseases in this region.

HISTOPATHOLOGICAL CHANGES

All strains of *H. pylori* induce a marked inflammation in the gastric mucosa which is characterised by neutrophil, lymphocyte and other inflammatory cell infiltration. While antral-predominant gastritis leads to increased acid production from the uninflamed corpus and predisposes to duodenal ulceration, corpus-predominant gastritis leads to hypochlorhydria and predisposes to gastric ulceration and adenocarcinoma[3]. In studies conducted in Iraq, Turkey and UAE, it was found there is antral-predominant mononuclear cell infiltration[59,69,70]. In a study conducted in Iran, where the gastric cancer rate is very high, it was found that mononuclear cell infiltration was similar throughout the stomach; on average, patients had pangastritis[71].

Gradual loss of gastric glandular tissue as a consequence of long term mucosal destruction is called atrophic gastritis[3]. The tissue damage may involve progressive loss of all specific mucosal cells including the acid pro-

ducing parietal cells, pepsinogen producing chief cells and mucus producing gland cells. When these cell types have shrunk, the protective mucus layer will gradually disappear and acid secretion will cease[5]. Such pathological changes increase the risk of gastric ulceration and development of gastric adenocarcinoma[72]. However, this protects against duodenal ulcers because of low acid secretion[5]. In a study conducted in Turkey, histological evidence of mucosal atrophy was found in 43% of *H. pylori*-infected subjects[72] while in another study in Turkey atrophy was found in 75% of the subjects[73]. In UAE, gastric atrophy in *Helicobacter* associated gastritis was seen in 54% of cases[70]. In a study conducted in Iran, where the gastric cancer rate is much higher than Turkey, histological evidence of mucosal atrophy was found in 39% and 22% of antral and corpus biopsies, respectively[74]. In Iraq, glandular atrophy was found in only one (3%) specimen taken from the antrum. In Kuwait, *H. pylori* were found in 81.7% patients, of which 28.3% had atrophic gastritis and 15.1% intestinal metaplasia[75]. Atrophy was found in 65% and 54% of examined subjects in Jordan and Egypt, respectively[24,76] (Table 1).

In a study conducted in Saudi where a comparison of Sydney scores from younger and older patients was made, no significant differences were seen in the scores of *H. pylori* density, neutrophilic activity, or chronic inflammatory cell infiltration between the two groups. While intestinal metaplasia was not found in any young patient, 22% of older patients had focal metaplastic changes. The atrophic changes were seen in 19% of older patients and one (3%) younger patient[77].

In Turkey, while a significant relationship was found between *cagA* positivity and neutrophil activity and glandular atrophy in antral specimens, corpus neutrophil infiltration was found to be more severe in the *vacA* m1 group than in the v*acA* m2 group[59]. No association between virulence factors and histopathology was found in Iraq[69]. In Iran, *dupA*-negative strains were associated with premalignant histological changes[65].

In most of the studies conducted in the Middle East, histological changes seen in the antral sections (such as neutrophil infiltration of the lamina propria and the glands and the increase in the number of lymphocytes and plasma cells) were on average of mild scores.

DIET IN THE MIDDLE EAST

Diet pattern correlates with gastric diseases. Most populations in the Mediterranean region (including Middle Eastern populations) adhere to the Mediterranean dietary pattern. Mediterranean food has several common features including low consumption of meat and animal products, a high consumption of fish, vegetables, fruit, and cereal, and olive oil as the main source of fat. A Mediterranean diet, particularly olive oil, vegetable and fruit consumption, has been shown to be related to a low risk of cardiovascular disease and several cancers including upper gastrointestinal tract cancer[78,79]. Whole grain is also related to low risk of gastric cancer[78]. In contrast, intake of refined grains by some Mediterranean populations was associated with increased risk of stomach cancer[78]. Overall, the Mediterranean dietary pattern is associated with better health and protects against various chronic diseases. After revision of most recently published papers about diet and food in the Middle East, I did not find any significant differences in the diet pattern amongst the countries of this region[80,81].

Table 2 Smoking prevalence in different countries (%)

	Males	Females
Saudi: Male Adult (30-70 yr and older), 1996-2001	19.1	8.3
Kuwait: Adult, 1996	29.6	1.5
Italy: Adult (15 yr and older), 2002	31.1	22.3
Iraq: Adult (16 yr and older), 1990	40	5
Jordan: Adult, 1999	48	10
Japan: Adult (15 yr and older), 2002	51	10
Iran: Adult (15 yr and older), 1999-2000	22.2	2.1
Egypt: Adult (15 yr and older), 2000	40	18
Spain: Adult (16 yr and older), 2001	39.1	24.6
Turkey: Adult (20 yr and older), 1997-1998	50.9	10.9
Israel: Adult (25-64 yr and older), 1999-2001	38.6	22.1
Costa Rica: Adult (20-49 yr and older), 2001	29	9.7

SMOKING IN THE MIDDLE EAST

The association between smoking and increased risk of gastric cancer has been observed. In an epidemiological study conducted in Portugal it was shown that smoking is associated with gastric intestinal metaplasia[82]. In other studies, it was shown that tobacco can increase the risk of gastric cancer[83], and epidemiological evidence linking smoking and gastric cancer has been found[84]. The prevalence of smoking in Iraq where the gastric cancer rate is very low is twice as the prevalence in Iran where the gastric cancer is very high. On the other hand, the highest prevalence was found in Turkey[85]. The prevalence of smoking in other Middle Eastern countries can be seen in Table 2.

GENERAL CONSIDERATIONS

H. pylori is a causative agent of peptic ulcer disease and an important risk factor of gastric cancer. Despite the high *H. pylori* infection rate in Middle Eastern countries, gastric cancer incidence is low in all countries but Iran. Previous reports have shown that the age of patients at the onset of infection may help predict the disease development process as the early acquisition of infection carries more risk of disease development. As shown above, *H. pylori* infection is acquired early in life in this region. In spite of this, the cancer rate is low.

In the Middle East, the populations can ethnically be divided into two main groups: Semitic populations (Arab and Jew who are southern region inhabitants) and non Semitic populations (Kurd, Turk, and Persian who are northern region inhabitants).

The prevalence of virulence factors in countries inhabited by non Semitic populations (Turkey, Iran and Iraq) is similar to what was found in South Asian and

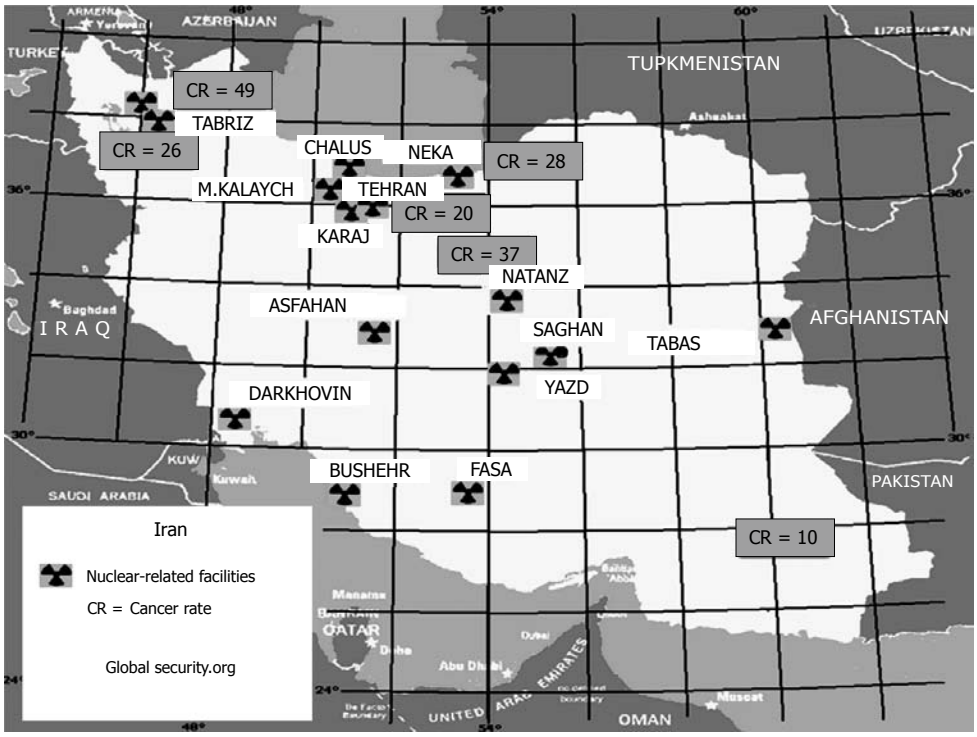

Figure 1 Map showing Iran's nuclear sites and annual incidence of gastric cancer in Iran reported from different cancer registries presented as male age standardized rate per 100 000.

Europe[41] and significantly more than what was found in countries with a Semitic background. This might be because populations which lived in the northern part of the Middle East near Europe and south Asia might correlate with European and south Asian populations. Additionally, this provides more evidence of the ethnical tropism of *H. pylori* infection. It is noticed that virulence factor rates in Saudi *H. pylori* are higher than other Arabic countries. This might be due the fact that Saudi society has been an open society due to continued population movement into this region to perform pilgrimage (Hajj).

Graham *et al*[86] suggested a better strategy for the explanation of the relationship between *H. pylori* and diseases by focusing on underlying patterns of gastritis. This, to a certain extent, is true in this region because all histopathology reports have shown that antral predominant gastritis is the main pattern of gastritis in this region apart from Iran where corpus or pan gastritis is the main pattern. However, if atrophic gastritis, which is precancerous and shown to be associated with cancer, is considered, the high cancer rate in Iran cannot be explained because atrophic gastritis is very high in Turkey, Jordan, UAE, and Egypt with much lower cancer rates. Yet another question to be answered: why this difference in gastritis pattern? Previous reports have blamed environmental factors and diet. For the sake of argument, one would accept the blame but which environmental factor can play such a role in a region which has almost the same environment and traditions. Moreover, as seen above, most Mediterranean countries (including Middle Eastern and South European countries) adhere to a Mediterranean diet pattern and neither diet pattern nor smoking rates seem to explain the difference in cancer rate. The only difference, however, that can be found between Iran and other countries (apart from Israel) is the presence of nuclear facilities in Iran. Examining the map of Iran's nuclear sites, Iranian uranium mines, nuclear reactors, and uranium processing facilities that include three known uranium enrichment plants can be found in Iran's most populous urban areas especially in the northwest and central region where there is a very high gastric cancer rate (Figure 1)[87]. On the other hand, there is no nuclear facility in the southeast where the gastric cancer rate is similar to that found in neighboring countries[87]. In Israel, these facilities are in the desert and relatively isolated areas. But if the theory of the relationship between those facilities and cancer is true, one would expect high rates of other cancers in Iran and this is not true[28].

Host genetics play an essential role in the inflammatory process and in the interactions between the host and *H. pylori* (see review by Kusters *et al*[88]). It has been shown that proinflammatory genetic polymorphisms tend to increase the risk of development of gastric cancer. Hence, would the genetic make-up explain the dilemma of cancer rate in this region? Proinflammatory host genetic facilitates gastric cancer through the development of hypochlorhydric and atrophic gastritis which has been studied and could not have explained the difference in cancer rate. Graham *et al*[86], suggested that host genetics affect individuals and generally cannot explain widespread changes. In addition, the genetic markers we have at present are not sensitive or specific enough to form the basis of a screening strategy[89]. According to Canedo *et al*[89], any genetic association studies should fulfil specific criteria among which there should be no evidence of population admixture. This criterion is almost impossible to fulfil in this region. When looking back through history, you will find that Indo-European races (Kurd and Iranian) are not indigenous. In addition, after the rise of Islam and the Arab conquest of the surrounding countries, there was much

intermixture between Indo-European and Semitic populations. Further evidence for this intermixture is that in a study of human genetics, a close relatedness of Semitic and Indo-Europeans with each other and with neighbouring geographic groups was shown. In the same study it was shown that Semitic North African groups are more distant genetically from Semitic-speaking groups from the Near East and Iran[90]. Hence, avoiding a mixed population is insuperable in this region. However, this does not negate the importance of the host genetic analyses of cytokine polymorphisms affecting mucosal inflammation and gastric acid secretion. Carefully planned projects would provide additional information to identify predictive markers for an individual's risk for gastric atrophy and malignancy.

CONCLUSION

To conclude, there is unexplained variation in the distribution of virulence factors and gastritis patterns in the Middle East. These variations fail to explain the discordance between *H. pylori* infection rates and the variations in gastric cancer prevalence. Although detailed studies are needed to investigate dietary pattern, generally diet is unlikely to contribute because all the countries are following the same Mediterranean pattern. Smoking rates could not explain the variation in cancer rates as we have seen countries with a very high smoking rate but low cancer rate. This might indicate the presence of an enigma similar to or part of that reported (controversially) in Africa and Asia[91,92]. Further detailed investigations and international comparative studies of each risk factor need to be performed to investigate whether this phenomenon represents a true enigma.

REFERENCES

1 **Peek RM Jr**, Blaser MJ. Helicobacter pylori and gastrointestinal tract adenocarcinomas. *Nat Rev Cancer* 2002; **2**: 28-37

2 **Lu H**, Hsu PI, Graham DY, Yamaoka Y. Duodenal ulcer promoting gene of Helicobacter pylori. *Gastroenterology* 2005; **128**: 833-848

3 **Asaka M**, Kato M, Kudo M, Katagiri M, Nishikawa K, Koshiyama H, Takeda H, Yoshida J, Graham DY. Atrophic changes of gastric mucosa are caused by Helicobacter pylori infection rather than aging: studies in asymptomatic Japanese adults. *Helicobacter* 1996; **1**: 52-56

4 **Blaser MJ**, Nomura A, Lee J, Stemmerman GN, Perez-Perez GI. Early-life family structure and microbially induced cancer risk. *PLoS Med* 2007; **4**: e7

5 **Atherton JC**. The pathogenesis of Helicobacter pylori-induced gastro-duodenal diseases. *Annu Rev Pathol* 2006; **1**: 63-96

6 **In Encyclopædia Britannica**. Available from: URL: http://www.britannica.com/EBchecked/topic/286417/Indo-Iranian-languages Indo-Iranian languages. Accessed on November 12, 2009

7 **In Encyclopædia Britannica**. Available from: URL: http://www.britannica.com/EBchecked/topic/31677/Arabic-language Arabic language. Accessed on November 12, 2009

8 In Encyclopædia Britannica.Available from: URL: http://www.britannica.com/EBchecked/topic/609790/Turkey Turkey. Accessed on November 12, 2009

9 **GLOBOCAN IARC**. Cancer Map: Male Stomach Cancer, Age-Standardized Incidence Rate per 100,000 in 2002. Available from: URL: http://www-dep.iarc.fr/. Accessed on May 30, 2007

10 **Ormand JE**, Talley NJ. Helicobacter pylori: controversies and an approach to management. *Mayo Clin Proc* 1990; **65**: 414-426

11 **Dooley CP**, Cohen H, Fitzgibbons PL, Bauer M, Appleman MD, Perez-Perez GI, Blaser MJ. Prevalence of Helicobacter pylori infection and histologic gastritis in asymptomatic persons. *N Engl J Med* 1989; **321**: 1562-1566

12 **Talley NJ**, Newell DG, Ormand JE, Carpenter HA, Wilson WR, Zinsmeister AR, Perez-Perez GI, Blaser MJ. Serodiagnosis of Helicobacter pylori: comparison of enzyme-linked immunosorbent assays. *J Clin Microbiol* 1991; **29**: 1635-1639

13 **Veenendaal RA**, Peña AS, Meijer JL, Endtz HP, van der Est MM, van Duijn W, Eulderink F, Kreuning J, Lamers CB. Long term serological surveillance after treatment of Helicobacter pylori infection. *Gut* 1991; **32**: 1291-1294

14 **Perez-Perez GI**, Dworkin BM, Chodos JE, Blaser MJ. Campylobacter pylori antibodies in humans. *Ann Intern Med* 1988; **109**: 11-17

15 **Hussein NR**, Robinson K, Atherton JC. A study of age-specific Helicobacter pylori seropositivity rates in Iraq. *Helicobacter* 2008; **13**: 306-307

16 **Marie MA**. Seroprevalence of Helicobacter pylori Infection in Large Series of Patients in an Urban Area of Saudi Arabia. *Korean J Gastroenterol* 2008; **52**: 226-229

17 **Alizadeh AH**, Ansari S, Ranjbar M, Shalmani HM, Habibi I, Firouzi M, Zali MR. Seroprevalence of Helicobacter pylori in Nahavand: a population-based study. *East Mediterr Health J* 2009; **15**: 129-135

18 **Bakka AS**, Salih BA. Prevalence of Helicobacter pylori infection in asymptomatic subjects in Libya. *Diagn Microbiol Infect Dis* 2002; **43**: 265-268

19 **Gilboa S**, Gabay G, Zamir D, Zeev A, Novis B. Helicobacter pylori infection in rural settlements (Kibbutzim) in Israel. *Int J Epidemiol* 1995; **24**: 232-237

20 **Novis BH**, Gabay G, Naftali T. Helicobacter pylori: the Middle East scenario. *Yale J Biol Med* 1998; **71**: 135-141

21 **Fakhro AR**, Fateha Bel D, Amin Farid IM, Jamsheer HM. The association between Helicobacter pylori infection and lymphoid reaction in patients suffering from dyspepsia in Bahrain. *Saudi J Gastroenterol* 1999; **5**: 129-133

22 **Nimri LF**, Matalka I, Bani Hani K, Ibrahim M. Helicobacter pylori genotypes identified in gastric biopsy specimens from Jordanian patients. *BMC Gastroenterol* 2006; **6**: 27

23 **Al Qabandi A**, Mustafa AS, Siddique I, Khajah AK, Madda JP, Junaid TA. Distribution of vacA and cagA genotypes of Helicobacter pylori in Kuwait. *Acta Trop* 2005; **93**: 283-288

24 **Mahmoud RAK**, Morcos HH, Hegazi AA, Abo Seif MA, El-Hadidy KS. The serological gastric biopsy: a non-endoscopical/histopathologic diagnostic approach in management of the dyspeptic patients. *Am J Immunol* 2006; **2**: 88-96

25 **Jaber SM**. The pattern of CagA and VacA proteins in Helicobacter pylori seropositive asymptomatic children in western Saudi Arabia. *Saudi Med J* 2005; **26**: 1372-1377

26 **Nouarie M**, Pourshams A, Kamangar F, Sotoudeh M, Derakhshan MH, Akbari MR, Fakheri H, Zahedi MJ, Caldwell K, Abnet CC, Taylor PR, Malekzadeh R, Dawsey SM. Ecologic study of serum selenium and upper gastrointestinal cancers in Iran. *World J Gastroenterol* 2004; **10**: 2544-2546

27 **Sadjadi A**, Malekzadeh R, Derakhshan MH, Sepehr A, Nouraie M, Sotoudeh M, Yazdanbod A, Shokoohi B, Mashayekhi A, Arshi S, Majidpour A, Babaei M, Mosavi A, Mohagheghi MA, Alimohammadian M. Cancer occurrence in Ardabil: results of a population-based cancer registry from Iran. *Int J Cancer* 2003; **107**: 113-118

28 **Sadjadi A**, Nouraie M, Mohagheghi MA, Mousavi-Jarrahi A, Malekezadeh R, Parkin DM. Cancer occurrence in Iran in 2002, an international perspective. *Asian Pac J Cancer Prev*

2005; **6**: 359-363
29 **Kikuchi S**, Wada O, Nakajima T, Nishi T, Kobayashi O, Konishi T, Inaba Y. Serum anti-Helicobacter pylori antibody and gastric carcinoma among young adults. Research Group on Prevention of Gastric Carcinoma among Young Adults. *Cancer* 1995; **75**: 2789-2793
30 **Nomura A**, Stemmermann GN, Chyou PH, Kato I, Perez-Perez GI, Blaser MJ. Helicobacter pylori infection and gastric carcinoma among Japanese Americans in Hawaii. *N Engl J Med* 1991; **325**: 1132-1136
31 **Forman D**. Helicobacter pylori and gastric cancer. *Scand J Gastroenterol Suppl* 1996; **220**: 23-26
32 **Rokkas T**, Ladas S, Liatsos C, Petridou E, Papatheodorou G, Theocharis S, Karameris A, Raptis S. Relationship of Helicobacter pylori CagA status to gastric cell proliferation and apoptosis. *Dig Dis Sci* 1999; **44**: 487-493
33 **Atherton JC**. CagA: a role at last. *Gut* 2000; **47**: 330-331
34 **Atherton JC**. CagA, the cag pathogenicity island and Helicobacter pylori virulence. *Gut* 1999; **44**: 307-308
35 **Atherton JC**. H. pylori virulence factors. *Br Med Bull* 1998; **54**: 105-120
36 **Peek RM Jr**, Moss SF, Tham KT, Pérez-Pérez GI, Wang S, Miller GG, Atherton JC, Holt PR, Blaser MJ. Helicobacter pylori cagA+ strains and dissociation of gastric epithelial cell proliferation from apoptosis. *J Natl Cancer Inst* 1997; **89**: 863-868
37 **Censini S**, Lange C, Xiang Z, Crabtree JE, Ghiara P, Borodovsky M, Rappuoli R, Covacci A. cag, a pathogenicity island of Helicobacter pylori, encodes type I-specific and disease-associated virulence factors. *Proc Natl Acad Sci USA* 1996; **93**: 14648-14653
38 **Tomb JF**, White O, Kerlavage AR, Clayton RA, Sutton GG, Fleischmann RD, Ketchum KA, Klenk HP, Gill S, Dougherty BA, Nelson K, Quackenbush J, Zhou L, Kirkness EF, Peterson S, Loftus B, Richardson D, Dodson R, Khalak HG, Glodek A, McKenney K, Fitzegerald LM, Lee N, Adams MD, Hickey EK, Berg DE, Gocayne JD, Utterback TR, Peterson JD, Kelley JM, Cotton MD, Weidman JM, Fujii C, Bowman C, Watthey L, Wallin E, Hayes WS, Borodovsky M, Karp PD, Smith HO, Fraser CM, Venter JC. The complete genome sequence of the gastric pathogen Helicobacter pylori. *Nature* 1997; **388**: 539-547
39 **Hussein NR**, Mohammadi M, Talebkhan Y, Doraghi M, Letley DP, Muhammad MK, Argent RH, Atherton JC. Differences in virulence markers between Helicobacter pylori strains from Iraq and those from Iran: potential importance of regional differences in H. pylori-associated disease. *J Clin Microbiol* 2008; **46**: 1774-1779
40 **Saribasak H**, Salih BA, Yamaoka Y, Sander E. Analysis of Helicobacter pylori genotypes and correlation with clinical outcome in Turkey. *J Clin Microbiol* 2004; **42**: 1648-1651
41 **Van Doorn LJ**, Figueiredo C, Mégraud F, Pena S, Midolo P, Queiroz DM, Carneiro F, Vanderborght B, Pegado MD, Sanna R, De Boer W, Schneeberger PM, Correa P, Ng EK, Atherton J, Blaser MJ, Quint WG. Geographic distribution of vacA allelic types of Helicobacter pylori. *Gastroenterology* 1999; **116**: 823-830
42 **Benenson S**, Halle D, Rudensky B, Faber J, Schlesinger Y, Branski D, Rabinowitz N, Wilschanski M. Helicobacter pylori genotypes in Israeli children: the significance of geography. *J Pediatr Gastroenterol Nutr* 2002; **35**: 680-684
43 **Momenah AM**, Tayeb MT. Helicobacter pylori cagA and iceA genotypes status and risk of peptic ulcer in Saudi patients. *Saudi Med J* 2007; **28**: 382-385
44 **Erzin Y**, Koksal V, Altun S, Dobrucali A, Aslan M, Erdamar S, Dirican A, Kocazeybek B. Prevalence of Helicobacter pylori vacA, cagA, cagE, iceA, babA2 genotypes and correlation with clinical outcome in Turkish patients with dyspepsia. *Helicobacter* 2006; **11**: 574-580
45 **Rhead JL**, Letley DP, Mohammadi M, Hussein N, Mohagheghi MA, Eshagh Hosseini M, Atherton JC. A new Helicobacter pylori vacuolating cytotoxin determinant, the intermediate region, is associated with gastric cancer. *Gastroenterology* 2007; **133**: 926-936
46 **Argent RH**, Hale JL, El-Omar EM, Atherton JC. Differences in Helicobacter pylori CagA tyrosine phosphorylation motif patterns between western and East Asian strains, and influences on interleukin-8 secretion. *J Med Microbiol* 2008; **57**: 1062-1067
47 **Argent RH**, Zhang Y, Atherton JC. Simple method for determination of the number of Helicobacter pylori CagA variable-region EPIYA tyrosine phosphorylation motifs by PCR. *J Clin Microbiol* 2005; **43**: 791-795
48 **Ren S**, Higashi H, Lu H, Azuma T, Hatakeyama M. Structural basis and functional consequence of Helicobacter pylori CagA multimerization in cells. *J Biol Chem* 2006; **281**: 32344-32352
49 **Salih BA**, Bolek BK, Arikan S. DNA sequence analysis of cagA 3′ motifs of Helicobacter pylori strains from patients with peptic ulcer diseases. *J Med Microbiol* 2010; **59**: 144-148
50 **Salih BA**, Abasiyanik MF, Ahmed N. A preliminary study on the genetic profile of cag pathogenicity-island and other virulent gene loci of Helicobacter pylori strains from Turkey. *Infect Genet Evol* 2007; **7**: 509-512
51 **Atherton JC**, Cao P, Peek RM Jr, Tummuru MK, Blaser MJ, Cover TL. Mosaicism in vacuolating cytotoxin alleles of Helicobacter pylori. Association of specific vacA types with cytotoxin production and peptic ulceration. *J Biol Chem* 1995; **270**: 17771-17777
52 **Letley DP**, Lastovica A, Louw JA, Hawkey CJ, Atherton JC. Allelic diversity of the Helicobacter pylori vacuolating cytotoxin gene in South Africa: rarity of the vacA s1a genotype and natural occurrence of an s2/m1 allele. *J Clin Microbiol* 1999; **37**: 1203-1205
53 **van Doorn LJ**, Figueiredo C, Sanna R, Pena S, Midolo P, Ng EK, Atherton JC, Blaser MJ, Quint WG. Expanding allelic diversity of Helicobacter pylori vacA. *J Clin Microbiol* 1998; **36**: 2597-2603
54 **Pan ZJ**, Berg DE, van der Hulst RW, Su WW, Raudonikiene A, Xiao SD, Dankert J, Tytgat GN, van der Ende A. Prevalence of vacuolating cytotoxin production and distribution of distinct vacA alleles in Helicobacter pylori from China. *J Infect Dis* 1998; **178**: 220-226
55 **Ito Y**, Azuma T, Ito S, Miyaji H, Hirai M, Yamazaki Y, Sato F, Kato T, Kohli Y, Kuriyama M. Analysis and typing of the vacA gene from cagA-positive strains of Helicobacter pylori isolated in Japan. *J Clin Microbiol* 1997; **35**: 1710-1714
56 **Han SR**, Schreiber HJ, Bhakdi S, Loos M, Maeurer MJ. vacA genotypes and genetic diversity in clinical isolates of Helicobacter pylori. *Clin Diagn Lab Immunol* 1998; **5**: 139-145
57 **Ogiwara H**, Graham DY, Yamaoka Y. vacA i-region subtyping. *Gastroenterology* 2008; **134**: 1267; author reply 1268
58 **Sugimoto M**, Zali MR, Yamaoka Y. The association of vacA genotypes and Helicobacter pylori-related gastroduodenal diseases in the Middle East. *Eur J Clin Microbiol Infect Dis* 2009; **28**: 1227-1236
59 **Umit H**, Tezel A, Bukavaz S, Unsal G, Otkun M, Soylu AR, Tucer D, Otkun M, Bilgi S. The relationship between virulence factors of Helicobacter pylori and severity of gastritis in infected patients. *Dig Dis Sci* 2009; **54**: 103-110
60 **Mohammadi M**, Oghalaie A, Mohajerani N, Massarrat S, Nasiri M, Bennedsen M, Colding H, Andersen LP. Prevalence of Helicobacter pylori vacuolating cytotoxin and its allelic mosaicism as a predictive marker for Iranian dyspeptic patients. *Bull Soc Pathol Exot* 2003; **96**: 3-5
61 **Momenah AM**, Tayeb MT. Relationship between Helicobacter pylori vacA genotypes status and risk of peptic ulcer in Saudi patients. *Saudi Med J* 2006; **27**: 804-807
62 **Salih BA**, Abasiyanik MF, Saribasak H, Huten O, Sander E. A follow-up study on the effect of Helicobacter pylori eradication on the severity of gastric histology. *Dig Dis Sci* 2005; **50**:

1517-1522
63 **Gomes LI**, Rocha GA, Rocha AM, Soares TF, Oliveira CA, Bittencourt PF, Queiroz DM. Lack of association between Helicobacter pylori infection with dupA-positive strains and gastroduodenal diseases in Brazilian patients. *Int J Med Microbiol* 2008; **298**: 223-230
64 **Argent RH**, Burette A, Miendje Deyi VY, Atherton JC. The presence of dupA in Helicobacter pylori is not significantly associated with duodenal ulceration in Belgium, South Africa, China, or North America. *Clin Infect Dis* 2007; **45**: 1204-1206
65 **Douraghi M**, Mohammadi M, Oghalaie A, Abdirad A, Mohagheghi MA, Hosseini ME, Zeraati H, Ghasemi A, Esmaieli M, Mohajerani N. dupA as a risk determinant in Helicobacter pylori infection. *J Med Microbiol* 2008; **57**: 554-562
66 **Figueiredo C**, Quint WG, Sanna R, Sablon E, Donahue JP, Xu Q, Miller GG, Peek RM Jr, Blaser MJ, van Doorn LJ. Genetic organization and heterogeneity of the iceA locus of Helicobacter pylori. *Gene* 2000; **246**: 59-68
67 **van Doorn LJ**, Figueiredo C, Sanna R, Plaisier A, Schneeberger P, de Boer W, Quint W. Clinical relevance of the cagA, vacA, and iceA status of Helicobacter pylori. *Gastroenterology* 1998; **115**: 58-66
68 **Baglan PH**, Srinay E, Ahmed K, Ozkan M, Bozday G, Bozday AM, Ozden A. Turkish isolates of Helicobacter pylori belong to the Middle Eastern genotypes. *Clin Microbiol Infect* 2006; **12**: 97-98
69 **Hussein NR**, Napaki SM, Atherton JC. A study of Helicobacter pylori-associated gastritis patterns in Iraq and their association with strain virulence. *Saudi J Gastroenterol* 2009; **15**: 125-127
70 **Zaitoun AM**. Histological study of chronic gastritis from the United Arab Emirates using the Sydney system of classification. *J Clin Pathol* 1994; **47**: 810-815
71 **Sotoudeh M**, Derakhshan MH, Abedi-Ardakani B, Nouraie M, Yazdanbod A, Tavangar SM, Mikaeli J, Merat S, Malekzadeh R. Critical role of Helicobacter pylori in the pattern of gastritis and carditis in residents of an area with high prevalence of gastric cardia cancer. *Dig Dis Sci* 2008; **53**: 27-33
72 **Fikret D**, Kaya Ö, Suna E, Vahap O, Mustafa A, Şebnem A. Relationship between atrophic gastritis, intestinal metaplasia, dysplasia and Helicobacter pylori infection. *Turkish J Gastro* 2001; **12**: 169-170
73 **Kaklikkaya N**, Cubukcu K, Aydin F, Bakir T, Erkul S, Tosun I, Topbas M, Yazici Y, Buruk CK, Erturk M. Significance of cagA status and vacA subtypes of Helicobacter pylori in determining gastric histopathology: virulence markers of H. pylori and histopathology. *J Gastroenterol Hepatol* 2006; **21**: 1042-1047
74 **Malekzadeh R**, Sotoudeh M, Derakhshan MH, Mikaeli J, Yazdanbod A, Merat S, Yoonessi A, Tavangar M, Abedi BA, Sotoudehmanesh R, Pourshams A, Asgari AA, Doulatshahi S, Alizadeh BZ, Arshi S, Madjidpoor A, Mir Moomen S, Fleischer DE. Prevalence of gastric precancerous lesions in Ardabil, a high incidence province for gastric adenocarcinoma in the northwest of Iran. *J Clin Pathol* 2004; **57**: 37-42
75 **Sarkar C**, Anim JT, Ibrahim BH. Atrophic Gastritis and Intestinal Metaplasia in Helicobacter pylori-Associated Antral Gastritis. *Medical Principles Practice* 1994; **4**: 197-203
76 **Matalka II**, Al-Omari FA, Al-Jarrah MA, Obeidat FN, Kanaan FM. Image-based discriminating morphological features for gastric atrophy assessment: a step to go further. *Pathol Res Pract* 2008; **204**: 235-240
77 **Khan AR**. Comparison of H. pylori-gastritis among young and old patients by using "the modified Sydney system of classification and grading". *Saudi J Gastroenterol* 1999; **5**: 81-84
78 **La Vecchia C**. Mediterranean diet and cancer. *Public Health Nutr* 2004; **7**: 965-968
79 **Visioli F**, Grande S, Bogani P, Galli C. The role of antioxidants in the mediterranean diets: focus on cancer. *Eur J Cancer Prev* 2004; **13**: 337-343
80 **Musaiger AO**. Diet and prevention of coronary heart disease in the Arab Middle East countries. *Med Princ Pract* 2002; **11** Suppl 2: 9-16
81 **da Silva R**, Bach-Faig A, Raidó Quintana B, Buckland G, Vaz de Almeida MD, Serra-Majem L. Worldwide variation of adherence to the Mediterranean diet, in 1961-1965 and 2000-2003. *Public Health Nutr* 2009; **12**: 1676-1684
82 **Peleteiro B**, Lunet N, Figueiredo C, Carneiro F, David L, Barros H. Smoking, Helicobacter pylori virulence, and type of intestinal metaplasia in Portuguese males. *Cancer Epidemiol Biomarkers Prev* 2007; **16**: 322-326
83 **De Stefani E**, Boffetta P, Carzoglio J, Mendilaharsu S, Deneo-Pellegrini H. Tobacco smoking and alcohol drinking as risk factors for stomach cancer: a case-control study in Uruguay. *Cancer Causes Control* 1998; **9**: 321-329
84 **González CA**, Pera G, Agudo A, Palli D, Krogh V, Vineis P, Tumino R, Panico S, Berglund G, Simán H, Nyrén O, Agren A, Martinez C, Dorronsoro M, Barricarte A, Tormo MJ, Quiros JR, Allen N, Bingham S, Day N, Miller A, Nagel G, Boeing H, Overvad K, Tjonneland A, Bueno-De-Mesquita HB, Boshuizen HC, Peeters P, Numans M, Clavel-Chapelon F, Helen I, Agapitos E, Lund E, Fahey M, Saracci R, Kaaks R, Riboli E. Smoking and the risk of gastric cancer in the European Prospective Investigation Into Cancer and Nutrition (EPIC). *Int J Cancer* 2003; **107**: 629-634
85 **WHO.** Smoking prevalence tobacco economy. Available from: URL: http://www.who. int/tobacco/media/en. Accessed on December 7, 2009
86 **Graham DY**, Lu H, Yamaoka Y. African, Asian or Indian enigma, the East Asian Helicobacter pylori: facts or medical myths. *J Dig Dis* 2009; **10**: 77-84
87 **Malekzadeh R**, Derakhshan MH, Malekzadeh Z. Gastric cancer in Iran: epidemiology and risk factors. *Arch Iran Med* 2009; **12**: 576-583
88 **Kusters JG**, van Vliet AH, Kuipers EJ. Pathogenesis of Helicobacter pylori infection. *Clin Microbiol Rev* 2006; **19**: 449-490
89 **Canedo P**, Figueiredo C, Machado JC. After Helicobacter pylori, genetic susceptibility to gastric carcinoma revisited. *Helicobacter* 2007; **12** Suppl 2: 45-49
90 **Nasidze I**, Quinque D, Rahmani M, Alemohamad SA, Stoneking M. Close genetic relationship between Semitic-speaking and Indo-European-speaking groups in Iran. *Ann Hum Genet* 2008; **72**: 241-252
91 **Holcombe C**. Helicobacter pylori: the African enigma. *Gut* 1992; **33**: 429-431
92 **Miwa H**, Go MF, Sato N. H. pylori and gastric cancer: the Asian enigma. *Am J Gastroenterol* 2002; **97**: 1106-1112

S- Editor Wang YR **L- Editor** O'Neill M **E- Editor** Ma WH

World Journal of Gastroenterology

Online Submissions: http://www.wjgnet.com/1007-9327office
wjg@wjgnet.com
doi:10.3748/wjg.v16.i26.3235

World J Gastroenterol 2010 July 14; 16(26): 3235-3238
ISSN 1007-9327 (print)
© 2010 Baishideng. All rights reserved.

GUIDELINES FOR BASIC SCIENCE

Two-layer cold storage method for pancreas and islet cell transplantation

Yasuhiro Fujino

Yasuhiro Fujino, Department of Surgery, Hyogo Cancer Center, Akashi 673-8558, Japan
Author contributions: Fujino Y solely contributed to this paper.
Correspondence to: Yasuhiro Fujino, MD, PhD, Department of Surgery, Hyogo Cancer Center, 13-70, Kitaoji-cho, Akashi 673-8558, Japan. yasu120@hp.pref.hyogo.jp
Telephone: +81-78-9291151 Fax: +81-78-9292380
Received: March 19, 2010 Revised: April 19, 2010
Accepted: April 26, 2010
Published online: July 14, 2010

Abstract

The two-layer cold storage method (TLM) was first reported in 1988, consisting of a perfluorochemical (PFC) and initially Euro-Collins' solution, which was later replaced by University of Wisconsin solution (UW). PFC is a biologically inert liquid and acts as an oxygen-supplying agent. A pancreas preserved using the TLM is oxygenated through the PFC and substrates are supplied by the UW solution. This allows the pancreas preserved using the TLM to generate adenosine triphosphate during storage, prolonging the preservation time. In a canine model, the TLM was shown to repair and resuscitate warm ischemically damaged pancreata during preservation, improve pancreas graft survival after transplantation, and also improve the islet yield after isolation. Clinical trials using the TLM in pancreas preservation before whole-pancreas transplantation and islet isolation have shown promising outcomes. We describe the role of the TLM in pancreas and islet transplantation.

© 2010 Baishideng. All rights reserved.

Key words: Two-layer method; Pancreas preservation; Pancreas transplantation; Islet transplantation; Perfluorochemical

Peer reviewer: Norbert Senninger, Professor, Department of General Surgery, University Clinics, Westphalian-Wilhelm's-University, Waldeyerstrasse 1, D-48149 Muenster, Germany

Fujino Y. Two-layer cold storage method for pancreas and islet cell transplantation. *World J Gastroenterol* 2010; 16(26): 3235-3238 Available from: URL: http://www.wjgnet.com/1007-9327/full/v16/i26/3235.htm DOI: http://dx.doi.org/10.3748/wjg.v16.i26.3235

INTRODUCTION

Successful transplantation depends on multiple factors including the prevention of preservation injuries incurred by cold storage and reperfusion[1,2]. A shortage of donor organs has an impact on the development of preservation methods. We developed the two-layer cold storage method (TLM) using perfluorochemicals (PFC) to reduce ischemic injury and maintain cellular integrity during preservation.

In 1966, it was reported that mice could breathe and survive in oxygen-saturated PFC[3]. PFC is a hydrocarbon, comprising a colorless and odorless solution with specific gravity approximately twice that of water. The most interesting property of PFC is a very high capacity for dissolving respiratory and other nonpolar gases[4]. A negligible O_2-binding constant of PFC allows them to release O_2 more effectively than hemoglobin into the surrounding tissue. As a result of this unique property, PFC-based solutions have been examined as oxygen carriers for blood substitutes, myocardial protection, respiratory support[4], and organ preservation before transplantation[5].

In this editorial, the role of the TLM in pancreas and islet transplantation is discussed.

DEVELOPMENT OF TWO-LAYER COLD STORAGE METHOD

The TLM was first reported in 1988 at Kobe University as a pancreas cold storage method[5]. The TLM first consisted of a PFC and initially Euro-Collins' solution (EC), which was later replaced by University of Wiscon-

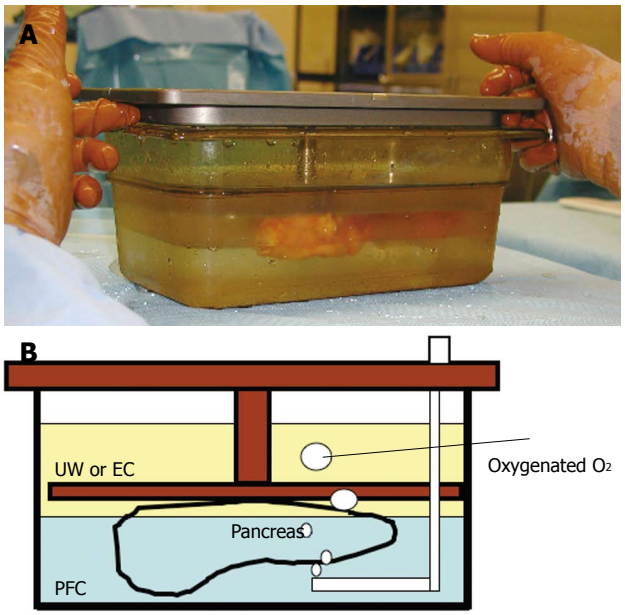

Figure 1 The two-layer method. The pancreas graft is surrounded by UW or EC and floated on the oxygenated PFC. A: The photograph; B: The schema. UW: University of Wisconsin solution; EC: Euro-Collin's solution; PFC: Perfluorochemical.

sin solution (UW)[6]. Because the PFC is lipophilic and has a high density, the PFC and EC or UW separate into layers. This allows for the pancreas graft to float on the oxygenated PFC surrounded by EC or UW (Figure 1).

Before UW was developed, EC was the standard solution for pancreas preservation before whole-pancreas transplantation. EC could preserve human pancreata for up to 10 h[7] and canine pancreata for up to 24 h[5]. The original TLM (EC/ PFC) could preserve canine pancreata for up to 72 h[5]. UW solution could preserve canine pancreata for up to 72 h[6], and the modified TLM (UW/ PFC) could preserve canine pancreata for up to 96 h[6]. Although PFC alone may provide an excellent preservation solution, this solution only preserved canine pancreata for 48 h[8]. Despite evidence for the superiority of the TLM, simple cold storage using UW has become the standard organ preservation method in clinical pancreas transplantation. This is likely to be because UW effectively preserves human pancreata for more than 24 h and the TLM is relatively more complicated compared with UW cold storage.

MECHANISM OF THE TWO-LAYER METHOD

The TLM reduced cold ischemic[6], warm ischemic[9], rewarming ischemic[10], and reperfusion[11] injuries in pancreas and islet transplantation. The mechanisms of the TLM have been vigorously examined using experimental transplantation models. During preservation by the TLM, the pancreas is directly oxygenated through PFC and maintains an oxygen tension at about 60% of the normal physiologic level[12].

During ischemia, tissue adenosine triphosphate (ATP) degrades to hypoxanthine following an increase of xanthine oxidase. Next, reactive oxygen radicals are generated and involved in a complex interaction of immediate cellular damage in ischemia-reperfusion injury[13,14]. On the other hand, tissue ATP is maintained in grafts preserved by the two-layer method and is rapidly recovered after reperfusion, which may be a better prophylaxis and treatment for the first step of ischemia-reperfusion injuries. During preservation by the TLM, pancreas grafts continuously generate ATP for up to 96 h[6]. ATP levels are also enhanced in human pancreas stored using the TLM. This proves the ability of the TLM to oxygenate human pancreas[15,16]. The ATP generated is used to drive a sodium-potassium pump to maintain cell integrity; thus, the TLM prevents pancreas swelling more effectively than UW solution[17]. Furthermore, the TLM improves the viability of the vascular endothelium and microcirculation[18]. Although the mechanisms involved in reducing ischemic reperfusion injury are unclear, one possibility is the induction of heat shock proteins during preservation[11]. ATP is essential for protein synthesis, and we demonstrated that protein synthesis was likely to be involved in the process of postischemic cellular recovery during preservation by the two-layer method[11,19]. These heat shock proteins may work to provide an anti-reperfusion or cell repair property.

The TLM also has an excellent ability to resuscitate pancreas grafts that have suffered from warm ischemic injury and to prolong the preservation time of ischemically damaged pancreata[20]. After 90 min of warm ischemic injury, the canine pancreas grafts lost ATP and were no longer viable. However, when the damaged pancreata were preserved and resuscitated by the TLM for 24 to 48 h at 4℃, the grafts regained tissue ATP and became viable[19]. The resuscitation effect is associated with active protein synthesis, suggesting active cell repair, and may involve heat shock proteins[19]. This suggested the possibility of pancreas transplantation from ischemically damaged or non-heart-beating donors.

Resuscitation by the TLM before pancreas transplantation correlates with the pancreatic tissue ATP levels after the TLM[21]. This is important because it predicts the outcomes of marginal donor grafts before transplantation. Recently, the TLM has shown promise in small intestine[22] and heart preservation[23].

PANCREAS PRESERVATION BEFORE ISLET ISOLATION

The most common exclusion criteria of pancreata for islet isolation are an unstable blood pressure, significant downtime, and high-level vasopressor usage for donor management. All of these criteria are related to warm ischemic injury and can be alleviated using the TLM; thus, the TLM could potentially make the majority of the donor pancreata usable for islet isolation.

Tanioka *et al*[24] first reported islet isolation after preservation by the TLM in a canine pancreas model. After

24 h storage of the canine pancreas in UW solution, islet yields were significantly decreased and the posttransplant outcome was further deteriorated. However, after 24 h of preservation by the TLM, the islet yield and posttransplant outcome were essentially equal to the immediate isolation.

After 60 min of warm ischemia, the islet yield after islet isolation was significantly decreased compared with the islet yield from the pancreas without warm ischemia[25]. When pancreata ischemically damaged for 60 min were preserved using the TLM for 24 h, the level of islet yield became similar to that from pancreata without warm ischemia[26]. Tanaka *et al*[27] also demonstrated that pancreata damaged on 30 min warm ischemia were restored by 3 h TLM preservation. The TLM may facilitate the selective use of non-heart-beating donors as an alternative source for islet transplantation.

In the rat model, the TLM for pancreas preservation prior to islet isolation resulted in an excellent islet function in addition to improved islet yield, which was almost comparable to freshly isolated islets[28].

At the University of Alberta (Edmonton, Canada), it was observed that seven of seven patients with type 1 diabetes receiving allogeneic islet transplants became insulin independent[29]. Two major drawbacks of the Edmonton protocol are that it requires pancreata to have short preservation periods before islet isolation, and almost always requires two or more donor pancreata to cure one diabetic patient.

On the basis of these data, Matsumoto *et al*[30] examined the effect of the TLM on the pancreas before islet isolation using preclinical, nonhuman primate pancreata and human pancreata. In the primate model, storing pancreata in UW solution for 5 h yielded a similar islet number, viability, and *in vitro* function compared with immediate isolation. However, 5 h of TLM preservation significantly increased the islet yield, viability, and *in vitro* function. They also suggested that the TLM maintains or repairs exocrine cell integrity and prevents trypsin activation, which enables effective collagenase delivery and protects islets from enzymatic digestion.

Zhang *et al*[31] also demonstrated that the islet yield from pancreata preserved using the TLM was more than that from pancreata stored in UW solution. Islet viability was significantly higher with the TLM *vs* UW solution. This experiment confirmed the superiority of the TLM-based preservation of pancreata for human islet isolation compared with UW solution. Although the beneficial effect of the TLM is controversial, the overall performance of the TLM could improve the outcome of islet isolation and transplantation[32].

CLINICAL APPLICATION OF THE TWO-LAYER METHOD

The TLM was clinically employed for pancreas transplantation at the University of Minnesota for the first time in 1999[33]. In this first clinical trial involving 10 cases, the TLM had no adverse effect on the recipients after transplantation. Furthermore, the morphologic quality of the human pancreas grafts after reperfusion was excellent compared with the pancreata stored in UW solution. There was no episode of acute rejection of pancreata preserved using the TLM. This is interesting because the immunosuppressive property of PFCs was one of the reasons not to use them as a blood substitute[34]. This immunosuppressive property could be beneficial for allogeneic organ preservation, and the role is under investigation.

Pancreas preservation using the TLM before islet isolation for clinical islet transplantation began at the University of Minnesota[35]. Hering *et al*[35] reported the cure of four patients with islets from a single donor. In this report, cadaver pancreata were subjected to the TLM immediately after retrieval at the procurement site without UW solution storage before islet isolation. Their islet yield was sufficient to cure one patient from one donor. Their experiment suggests that pancreata should be preserved by the TLM immediately at the time of procurement.

CONCLUSION

Irrespective of these promising data, the role of the TLM requires further investigation in pancreas and islet transplantation.

ACKNOWLEDGMENTS

The author would like to thank Dr. Yoshikazu Kuroda for his advice.

REFERENCES

1 **Grewal HP**, Garland L, Novak K, Gaber L, Tolley EA, Gaber AO. Risk factors for postimplantation pancreatitis and pancreatic thrombosis in pancreas transplant recipients. *Transplantation* 1993; **56**: 609-612

2 **Büsing M**, Hopt UT, Quacken M, Becker HD, Morgenroth K. Morphological studies of graft pancreatitis following pancreas transplantation. *Br J Surg* 1993; **80**: 1170-1173

3 **Clark LC Jr**, Gollan F. Survival of mammals breathing organic liquids equilibrated with oxygen at atmospheric pressure. *Science* 1966; **152**: 1755-1756

4 **Lowe KC**, Davey MR, Power JB. Perfluorochemicals: their applications and benefits to cell culture. *Trends Biotechnol* 1998; **16**: 272-277

5 **Kuroda Y**, Kawamura T, Suzuki Y, Fujiwara H, Yamamoto K, Saitoh Y. A new, simple method for cold storage of the pancreas using perfluorochemical. *Transplantation* 1988; **46**: 457-460

6 **Fujino Y**, Kuroda Y, Suzuki Y, Fujiwara H, Kawamura T, Morita A, Ku Y, Saitoh Y. Preservation of canine pancreas for 96 hours by a modified two-layer (UW solution/perfluorochemical) cold storage method. *Transplantation* 1991; **51**: 1133-1135

7 **Toledo-Pereyra LH**, Rodríguez FJ. Scientific basis and current status of organ preservation. *Transplant Proc* 1994; **26**: 309-311

8 **Kuroda Y**, Fujino Y, Kawamura T, Suzuki Y, Fujiwara H, Saitoh Y. Excellence of perfluorochemical with simple oxygen bubbling as a preservation medium for simple cold storage of canine pancreas. *Transplantation* 1990; **49**: 648-650

9 **Kuroda Y**, Morita A, Fujino Y, Tanioka Y, Ku Y, Saitoh Y. Restoration of pancreas graft function preserved by a two-layer (University of Wisconsin solution/perfluorochemical) cold storage method after significant warm ischemia. *Transplantation* 1993; **55**: 227-228

10 **Kuroda Y**, Tanioka Y, Morita A, Hiraoka K, Matsumoto S, Fujino Y, Yamamoto K, Ku Y, Saitoh Y. Protective effect of preservation of canine pancreas by the two-layer (University of Wisconsin solution/perfluorochemical) method against rewarming ischemic injury during implantation. *Transplantation* 1994; **57**: 658-661

11 **Fujino Y**, Suzuki Y, Tsujimura T, Takahashi T, Tanioka Y, Tominaga M, Ku Y, Kuroda Y. Possible role of heat shock protein 60 in reducing ischemic-reperfusion injury in canine pancreas grafts after preservation by the two-layer method. *Pancreas* 2001; **23**: 393-398

12 **Matsumoto S**, Kuroda Y, Hamano M, Kim Y, Suzuki Y, Ku Y, Saitoh Y. Direct evidence of pancreatic tissue oxygenation during preservation by the two-layer method. *Transplantation* 1996; **62**: 1667-1670

13 **Bilbao G**, Contreras JL, Eckhoff DE, Mikheeva G, Krasnykh V, Douglas JT, Thomas FT, Thomas JM, Curiel DT. Reduction of ischemia-reperfusion injury of the liver by in vivo adenovirus-mediated gene transfer of the antiapoptotic Bcl-2 gene. *Ann Surg* 1999; **230**: 185-193

14 **Clavien PA**, Harvey PR, Strasberg SM. Preservation and reperfusion injuries in liver allografts. An overview and synthesis of current studies. *Transplantation* 1992; **53**: 957-978

15 **Kuroda Y**, Fujino Y, Morita A, Tanioka Y, Ku Y, Saitoh Y. Oxygenation of the human pancreas during preservation by a two-layer (University of Wisconsin solution/perfluorochemical) cold-storage method. *Transplantation* 1992; **54**: 561-562

16 **Kuroda Y**, Tanioka Y, Morita A, Hiraoka K, Matsumoto S, Fujino Y, Ku Y, Saitoh Y, Sugihara J, Okumura S. The possibility of restoration of human pancreas function during preservation by the two-layer (University of Wisconsin solution/perfluorochemical) method following normothermic ischemia. *Transplantation* 1994; **57**: 282-285

17 **Tanioka Y**, Kuroda Y, Kim Y, Matsumoto S, Suzuki Y, Ku Y, Fujita H, Saitoh Y. The effect of ouabain (inhibitor of an ATP-dependent Na+/K+ pump) on the pancreas graft during preservation by the two-layer method. *Transplantation* 1996; **62**: 1730-1734

18 **Kuroda Y**, Fujita H, Matsumoto S, Suzuki Y, Kim Y, Tanioka Y, Ku Y. Protection of canine pancreatic microvascular endothelium against cold ischemic injury during preservation by the two-layer method. *Transplantation* 1997; **64**: 948-953

19 **Matsumoto S**, Fujino Y, Suzuki Y, Tanioka Y, Muramatsu S, Sugimoto T, Ku Y, Yasunami Y, Kuroda Y. Evidence of protein synthesis during resuscitation of ischemically damaged canine pancreas by the two-layer method. *Pancreas* 2000; **20**: 411-414

20 **Kuroda Y**, Morita A, Fujino Y, Tanioka Y, Ku Y, Saitoh Y. Successful extended preservation of ischemically damaged pancreas by the two-layer (University of Wisconsin solution/perfluorochemical) cold storage method. *Transplantation* 1993; **56**: 1087-1090

21 **Morita A**, Kuroda Y, Fujino Y, Tanioka Y, Ku Y, Saitoh Y. Assessment of pancreas graft viability preserved by a two-layer (University of Wisconsin solution/perfluorochemical) method after significant warm ischemia. *Transplantation* 1993; **55**: 667-669

22 **Fujino Y**, Kakinoki K, Suzuki Y, Li S, Tanaka T, Tanioka Y, Sakai T, Ku Y, Kuroda Y. Successful 24-hour preservation of ischemically damaged canine small intestine by the cavitary two-layer method. *Transplantation* 2003; **76**: 777-780

23 **Kamoda Y**, Fujino Y, Tanioka Y, Sakai T, Kuroda Y. Ischemically damaged heart after preservation by the cavitary two-layer method as a possible donor in rat heart transplantation. *J Heart Lung Transplant* 2007; **26**: 1320-1325

24 **Tanioka Y**, Sutherland DE, Kuroda Y, Gilmore TR, Asaheim TC, Kronson JW, Leone JP. Excellence of the two-layer method (University of Wisconsin solution/perfluorochemical) in pancreas preservation before islet isolation. *Surgery* 1997; **122**: 435-441; discussion 441-442

25 **Tanioka Y**, Hering BJ, Sutherland DE, Kronson JW, Kuroda Y, Gilmore TR, Aasheim TC, Rusten MC, Leone JP. Effect of pancreatic warm ischemia on islet yield and viability in dogs. *Transplantation* 1997; **64**: 1637-1641

26 **Deai T**, Tanioka Y, Suzuki Y, Kuroda Y. The effect of the two-layer cold storage method on islet isolation from ischemically damaged pancreas. *Kobe J Med Sci* 1999; **45**: 191-199

27 **Tanaka T**, Suzuki Y, Tanioka Y, Sakai T, Kakinoki K, Goto T, Li S, Yoshikawa T, Matsumoto I, Fujino Y, Kuroda Y. Possibility of islet transplantation from a nonheartbeating donor pancreas resuscitated by the two-layer method. *Transplantation* 2005; **80**: 738-742

28 **Kakinoki K**, Fujino Y, Suzuki Y, Li S, Tanioka Y, Sakai T, Kuroda Y. Superiority of the two-layer method before islet isolation confirmed by in vivo viability assessment. *Transplantation* 2005; **79**: 1516-1521

29 **Shapiro AM**, Lakey JR, Ryan EA, Korbutt GS, Toth E, Warnock GL, Kneteman NM, Rajotte RV. Islet transplantation in seven patients with type 1 diabetes mellitus using a glucocorticoid-free immunosuppressive regimen. *N Engl J Med* 2000; **343**: 230-238

30 **Matsumoto S**, Rigley TH, Qualley SA, Kuroda Y, Reems JA, Stevens RB. Efficacy of the oxygen-charged static two-layer method for short-term pancreas preservation and islet isolation from nonhuman primate and human pancreata. *Cell Transplant* 2002; **11**: 769-777

31 **Zhang G**, Matsumoto S, Newman H, Strong DM, Robertson RP, Reems JA. Improve islet yields and quality when clinical grade pancreata are preserved by the two-layer method. *Cell Tissue Bank* 2006; **7**: 195-201

32 **Noguchi H**, Levy MF, Kobayashi N, Matsumoto S. Pancreas preservation by the two-layer method: does it have a beneficial effect compared with simple preservation in University of Wisconsin solution? *Cell Transplant* 2009; **18**: 497-503

33 **Matsumoto S**, Kandaswamy R, Sutherland DE, Hassoun AA, Hiraoka K, Sageshima J, Shibata S, Tanioka Y, Kuroda Y. Clinical application of the two-layer (University of Wisconsin solution/perfluorochemical plus O2) method of pancreas preservation before transplantation. *Transplantation* 2000; **70**: 771-774

34 **Lane TA**, Lamkin GE. Paralysis of phagocyte migration due to an artificial blood substitute. *Blood* 1984; **64**: 400-405

35 **Hering BJ**, Kandaswamy R, Harmon JV, Ansite JD, Clemmings SM, Sakai T, Paraskevas S, Eckman PM, Sageshima J, Nakano M, Sawada T, Matsumoto I, Zhang HJ, Sutherland DE, Bluestone JA. Transplantation of cultured islets from two-layer preserved pancreases in type 1 diabetes with anti-CD3 antibody. *Am J Transplant* 2004; **4**: 390-401

S- Editor Wang YR **L- Editor** O'Neill M **E- Editor** Ma WH

World Journal of Gastroenterology

Online Submissions: http://www.wjgnet.com/1007-9327office
wjg@wjgnet.com
doi:10.3748/wjg.v16.i26.3239

World J Gastroenterol 2010 July 14; 16(26): 3239-3248
ISSN 1007-9327 (print)
© 2010 Baishideng. All rights reserved.

REVIEW

Interstitial cells of Cajal, the Maestro in health and disease

Randa M Mostafa, Yasser M Moustafa, Hosam Hamdy

Randa M Mostafa, Department of Basic Medical Sciences, College of Medicine, Sharjah University, Sharjah 27272, United Arab Emirates
Yasser M Moustafa, Department of Pharmacology and Toxicology, College of Pharmacy, Suez Canal University, Ismaelia 24421, Egypt
Hosam Hamdy, Department of Surgery, Vice Chancellor of Medical and Health sciences Colleges, Sharjah University, Sharjah 27272, United Arab Emirates
Author contributions: All authors contributed extensively in preparing this manuscript; Mostafa RM provided a significant editorial and literature contribution; Moustafa YM performed the literature review; Hamdy H provided significant literature related comments and extensive review.
Correspondence to: Randa M Mostafa, Professor, Department of Basic Medical Sciences, College of Medicine, Sharjah University, Sharjah 27272,
United Arab Emirates. mostafaranda@sharjah.ac.ae
Telephone: +971-6-5057204 Fax: +971-6-5585879
Received: April 12, 2010 Revised: May 15, 2010
Accepted: May 22, 2010
Published online: July 14, 2010

Abstract

Interstitial cells of Cajal (ICC) are important players in the symphony of gut motility. They have a very significant physiological role orchestrating the normal peristaltic activity of the digestive system. They are the pacemaker cells in gastrointestinal (GI) muscles. Absence, reduction in number or altered integrity of the ICC network may have a dramatic effect on GI system motility. More understanding of ICC physiology will foster advances in physiology of gut motility which will help in a future breakthrough in the pharmacological interventions to restore normal motor function of GI tract. This mini review describes what is known about the physiologic function and role of ICCs in GI system motility and in a variety of GI system motility disorders.

© 2010 Baishideng. All rights reserved.

Key words: Interstitial cells of Cajal; Gastrointestinal motility; Peristalsis

Peer reviewers: Akio Inui, MD, PhD, Professor, Department of Behavioral Medicine, Kagoshima University Graduate School of Medical and Dental Sciences, 8-35-1 Sakuragaoka, Kagoshima 890-8520, Japan; Tomohiko Shimatani, Assistant Professor, Department of General Medicine, Hiroshima University Hospital, 1-2-3 Kasumi, Minami-ku, Hiroshima 7348551, Japan

Mostafa RM, Moustafa YM, Hamdy H. Interstitial cells of Cajal, the Maestro in health and disease. *World J Gastroenterol* 2010; 16(26): 3239-3248 Available from: URL: http://www.wjgnet.com/1007-9327/full/v16/i26/3239.htm DOI: http://dx.doi.org/10.3748/wjg.v16.i26.3239

INTRODUCTION

Physiology of gut motility has been always a fascinating chapter in gastroenterology. It poses interesting challenges to physiologists. Our understanding of basic gut motility processes is advancing; a major emphasis is placed on elucidating gut regulatory mechanisms. A better appreciation of the importance of the presence of normal function of interstitial cells of Cajal (ICC) transformed this field of research. In 1893, Spanish Nobel Laureate physician and neuropathologist Santiago Ramon y Cajal, was the first to describe cells that are located between the nerve endings and smooth muscle cells in the gastrointestinal (GI) tract. Their location prompted him to call them "interstitial". They are now known as the ICC.

ICC may be considered to be a specialized population of smooth muscle cells. Both arise from common mesenchymal cells[1-3]. However, whereas smooth muscle cells develop an extensive array of contractile elements, ICC have few contractile elements but contain large numbers of mitochondria, an abundance of endoplasmic reticulum and distinct sets of channels in their membrane. The ICC consist of a fusiform cell body with a thin cytoplasm, a large oval nucleus and dendritic-like processes[4]. Two to five primary dendritic processes divide further into secondary and tertiary processes[5]. Many ICC express Kit, a tyrosine kinase receptor (Kit-ir); this allows them to be recognized by their ability to bind antibodies to Kit[4]. Similarly ICC readily react with

antibodies to vimentin whereas nearby smooth muscle cells do not[6]. The presence of ICC is not restricted to the GI tract. They can be found in the bladder[7,8], the ureteropelvic junction[9], the vas deferens[10], the prostate[11], the penis[12,13], the mammary gland, the uterus[14], the pancreas[15], blood vessels[16] such as the portal vein[17] and the vagina[18]. More recently, they have been found in the vermiform appendix in childhood[19]. Some of these cells are thought to have a pacemaker function (such as those in the portal vein, in the lymphatics or prostate) but not those in the arteries, uterus (where the influence is, if any, an inhibitory one) or bladder[20].

The motor activity of the GI tract is critical for life[21]. It is a complex process involving multiple cell types such as enteric neurons that can sense the contents of the GI tract, integrate information and devise a suitable motor pattern, ICC that transduce inputs from enteric motor neurons and generate intrinsic electrical rhythmicity, and smooth muscle cells that can interpret and integrate large arrays of inputs and develop appropriate responses[22]. ICC are a minor component of the tunica muscularis of the GI tract (only about 5% of cells present[23]); however, these cells have very significant physiological roles in GI motility[22].

Many tissues, isolated from different regions of the GI tract, contract rhythmically in the absence of neuronal or hormonal stimulation. When contractions and membrane potential are recorded simultaneously each contraction is seen to be triggered by a long lasting wave of depolarization: because of their low frequency of occurrence and long duration, the waves of depolarization have been termed slow waves[24]. The origin and basis of the generation of slow waves have been debated for many years. It was initially thought that the generation of slow waves reflected some properties of GI smooth muscle cells[25,26], but studies on isolated smooth muscle cells have consistently failed to demonstrate a capability to generate slow wave activity[27]. It has also long been recognized that the generation of slow waves does not rely on the sequential activation of voltage-dependent ion channels as do cardiac pacemaker cells. Rather, many early studies raised the possibility that rhythmical activity relied on the cycling of one or more metabolic processes within cells of the gut wall. Thus Conner and his colleagues proposed that the generation of slow waves involved changes in the activity of the sodium pump[25].

Subsequently Nakayama *et al*[28] suggested an involvement of glycolytic pathways, again assuming that pace making activity originated in smooth muscle cells. Although ICC were first described in the intestine a century ago by Cajal, they were long viewed as an oddity. Their role in the generation of pacemaker activity in the GI tract was suggested on the basis of histological studies[29]. More recently, studies on mutants that lack subpopulations of ICC revealed their role in the generation of rhythmicity[30].

Critically, whereas isolated smooth muscle cells rarely generate spontaneous electrical activity[27], isolated ICC invariably do[31,32].

STRUCTURAL ORGANIZATION AND IDENTIFICATION OF SPECIFIC POPULATIONS OF ICC

The discovery that ICC express *c-Kit*, the proto-oncogene that encodes the receptor tyrosine kinase Kit has offered a simple and reliable immunohistochemical method for determining the structure and distribution of ICC networks[30]. ICC are found throughout the GI tract from the esophagus to the internal anal sphincter[33,34]. Hanani *et al*[35] mentioned that while it is becoming clear that more than one type of ICC exists, based on both morphological and functional data, we still subdivide ICC based on location. Furthermore, Farrugia[36] emphasized the importance of revisiting a classification based solely on location and move towards a classification that is based on function, suggesting a reasonable start, to subdivide ICC into those that have the machinery to, and generate, unitary potential and slow waves and those that do not. Morphological studies now supported by some functional evidence suggest that at least three separate functional groups of ICC exist. In most regions of the GI tract, a network of ICC are located within the intermuscular space at the level of the myenteric plexus (ICC-MY) between the circular and longitudinal muscle layers. ICC-MY are the pacemaker cells in the stomach and small intestine that trigger the generation of slow waves in the tunica muscularis[37].

A second population of ICC (referred to as intramuscular ICC or ICC-IM) are found within the muscle layers of the GI tract and are innervated preferentially by enteric motor nerves[37]. ICC-IM are closely associated with not only enteric motor nerves but also vagal afferent nerves. Vagal afferent nerve fibers, labeled by the injection of neural tracers into the nodose ganglia, can terminate as intramuscular arrays within the musculature and as intraganglionic laminar ending within the myenteric ganglion of the stomach and duodenum. These afferent fibers transmit mechanoreceptive information from the muscle wall[38,39]. Horiguchi *et al*[40] gave histological evidence that a third population of ICC, ICC-SEP, lies within the septa between the circular muscle bundles, and suggested that it may play a role in conducting electrical information from ICC-MY deep into the distant circular muscle bundles, Figure 1 showing functional organization of ICC in the canine gastric antrum[41].

Electrophysiological data are presented which indicate that when the normal pathway from ICC-MY is sectioned, electrical stimulation of the cut ends of the muscle bundles can initiate slow waves over considerable distances. In the absence of stimulation, the muscle bundles isolated from ICC-MY can generate rhythmical activity but do so at low frequencies. Thus a distinct population of ICC, ICC-SEP, exists which can transfer pacemaker depolarization from ICC-MY deep into the distant bundles of circular muscle. Although ICC-SEP have the potential to generate pacemaker activity they are not normally the dominant pacemaker centre. As an analogy with the

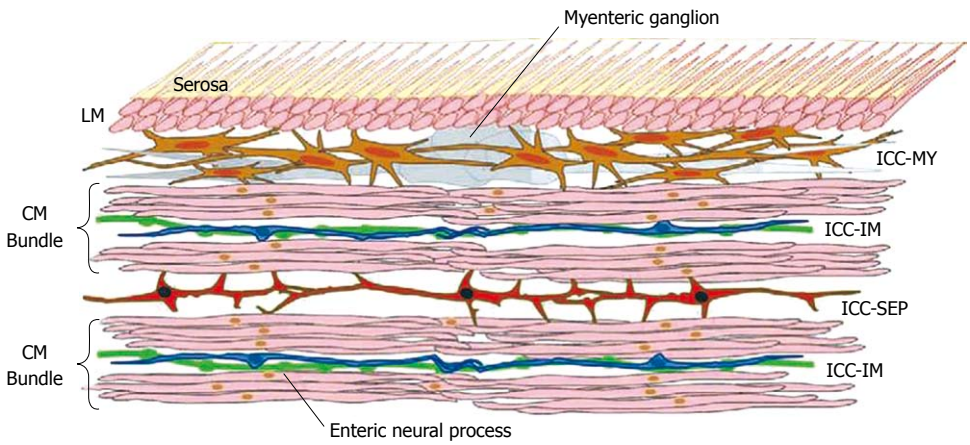

Figure 1 Diagram showing functional organization of ICC in the canine gastric antrum[41]. ICC: Interstitial cells of Cajal.

generation of pacemaker activity in the heart, the plexus of ICC-MY, like the sino-atrial node, is the dominant pacemaker centre. ICC-SEP, like Purkinje fibers, have the potential to generate pacemaker activity, but normally function to convey electrical activity from the dominant pacemaker region to more distant tissues[41].

PHYSIOLOGICAL FUNCTIONS OF ICC

Peristaltic motor activity is a motor pattern orchestrated by complex sequencing of neural excitation and inhibition in cooperation with intrinsic muscular control mechanisms, including those residing in ICC[42]. Peristalsis is defined as waves of contraction propagating along the GI tract for various distances as a means of mixing and propelling its content distally. Both the type of neural activity and the type of intrinsic myogenic control mechanism differ widely throughout the GI tract[42]. Physiological activation of peristalsis will in most cases involve the stretching of a segment of stomach, intestine, or colon and it will occur by neural pathways that contain additional mechanisms to those required for the ascending excitatory reflex[43]. When peristaltic motor activity occurs, in particular in stomach and proximal small intestine, the waves of contraction always have rhythmicity to it. This rhythmicity is determined by electrical slow wave activity in the musculature, referred to as pace maker activity[44].

New reagents, coupled with immunohistochemical techniques and new electrophysiological experimental approaches opened the door to recent progress in identification of the important roles of ICC as pacemakers, in propagation of slow waves and as mediators of inputs from enteric motor neurons[45]. Other functions, such as mechanosensors have also been proposed, but little physiological evidence supporting this function has been published[45].

Laboratory approaches used for ICC study

Isolated ICC have been examined using conventional patch clamp recording techniques. This approach, which has been applied to ICC-MY, allows a description of the specific populations of ion channels present in their membrane[31,32,46] and an analysis of the cellular mechanisms which regulate the channels[47,48]. Simple intracellular recording from smooth muscle cells in isolated segments of GI tissues and isolated segments of urethra, after blocking smooth muscle L-type Ca^{2+} channels, record primarily the activity of the ICC in the tissues. The properties of ICC-MY can be determined *in situ* using sharp electrodes, allowing one to monitor the behavior of populations of interconnected ICC-MY and to determine how pacemaker potentials generate signals in adjacent smooth muscle layers[47,49,50]. A third method used to study the properties of ICC IM involves recording from small isolated segments of circular muscles; if dissected appropriately the preparations are isopotential and contain up to 2000 smooth muscle cells linked to up to 200 ICC-IM. The membrane potential of both smooth muscle cells and ICC-IM, can be varied over a limited range and the effects of nerve stimulation can be analyzed[51-53]. Finally, the use of mutant mice in which specific sets of ICC are either absent of dramatically reduced in numbers has allowed an evaluation of the physiological properties of tissues, with and without different sets of ICC[24].

PATHOPHYSIOLOGY OF ICCs

Many GI motor disorders can be related to changes in number and/or structure and/or density of ICCs[54-57]. These changes can be primary, due to toxin substances, neurotoxins or viral diseases, or secondary as a consequence of neural damage, degraded tissue or treatment effect[54,58].

An absence or reduction in the number of ICCs causes abnormal electrical slow waves causing a decreased contractility of smooth muscle cells resulting in a diminished intestinal transit[56]. Although the density decreases, the slow wave is still present in most affected patients but the frequency and duration are prolonged[54].

COMMON GI MOTILITY PROBLEMS

ICC in the human esophagus and cardia

ICC in human esophagus has a myoid ultrastructure with abundant smooth endoplasmic reticulum, numerous mitochondria, intermediate filaments, scattered caveolae, and discontinuous basal lamina. They are most frequent in the esophageal part of the lower esophageal sphincter (LES)

but rare in the gastric part. They are in close contact with nerve terminals and make specific junctions with smooth muscle cells[59,60].

Achalasia: Achalasia is a disorder of esophageal motility that has been well documented for over 300 years[61]. Achalasia is characterized by relaxation failure of the LES and lack of peristaltic contraction of the esophageal body[62]. The mechanism of LES relaxation is complex, requiring the coordinated interaction of nerves, smooth muscle, ICC and hormones. The LES is a functional and anatomic barrier between the stomach and esophagus. It consists of a thickening of the circular smooth muscle layer of the esophagus at the gastroesophageal junction. It is anatomically asymmetric, and this is reflected in the physiology of the sphincter as demonstrated by ultrasound and pharmacologic manometric studies[63]. The LES is tonically contracted. Initiation of a peristaltic wave in the esophagus is accompanied by a decrease in LES pressure as a result of smooth muscle relaxation. This allows the swallowed bolus to enter the stomach[61].

ICC involvement in achalasia is debated. Electron microscope studies of the muscle coat of the LES in seven patients with achalasia showed that muscle wall components (nerve endings, smooth muscle cells, ICC and connective tissue) were modified. ICC ultrastructure was altered, namely clear cytoplasm, fewer mitochondria, and scarce smooth endoplasmic reticulum[64].

A reduced number of contacts between nerves and ICC were reported. Specific changes in smooth muscle cells were also documented, whereas the nerve endings had abnormal ultrastructure. Alterations in older patients were more pronounced[65]. Since the LES components specifically altered in achalasia are the nerve endings and ICC, they are regarded as principally responsible for abnormal motility[65].

Achalasia is uncommon among the pediatric population. It is usually sporadic and affects mainly teenagers[66]. A rare familial form combining early onset achalasia of cardia, alacrymia (absence of tears), and ACTH insensitivity, are known as Allgrove's syndrome[67,68] or "Triple A" syndrome[69]. These forms are inherited on the autosomal recessive mode[70]. Massive loss of neural elements and neuronal nitric oxide synthase as well as a marked fibrotic process of the muscle layers of the cardia have been observed in "Triple A" syndrome[71]. ICC in the cardia are also markedly diminished or are completely absent while ICC (and neural structures) are preserved in the pylorus[59].

Gastroesophageal reflux: Gastroesophageal reflux (GERD) is a common condition and its prevalence varies in different parts of the World[72]. Typical symptoms of heartburn and acid regurgitation are encountered in 15%-20% of the general population[62]. The major mechanism for GERD is transient relaxation of the LES[73]. The role of the ICC in inhibitory transmission in the LES is still being discussed[62].

In W/Wv mutant mice (lack of ICC) LES pressure was lower than wild-type mice but a normal swallow still induced LES relaxation, arguing against the role of ICC in inhibitory transmission[74]. Another study demonstrated that in W/Wv animals, cholinergic and nitrergic neurotransmission is greatly reduced pleading for the role of ICC in mediating neural inputs[37]. However, enteric neurons, varicose processes, and the ability to release neurotransmitters are not reduced, and smooth muscle cells demonstrate responsiveness to exogenous transmitters[37].

Loss of ICC during development or in pathologic conditions would significantly compromise the ability of GI muscles to generate typical motor reflexes[75].

Esophagitis itself may be at the origin of an alteration of normal function of the Cajal cells: in advanced stages of GERD, inflammatory changes in the esophageal wall will also involve the ICC. That way, the more severe the esophagitis, the more severe is the ICC impairment. This destruction leads to loss of effective contraction of esophagus, maintaining reflux and thus aggravating the symptoms[76].

ICC in the human stomach and pylorus

Gastroparesis: The pathogenesis of gastroparesis is complicated and poorly understood. This lack of understanding remains a major impediment to the development of effective therapies for this condition. Most of the scientific information available on the pathogenesis of gastroparesis has been derived from experimental studies of diabetes in animals. These studies suggest that the disease process can affect nerves (particularly those producing nitric oxide, but also the vagus nerve), ICC and smooth muscle[77]. It is broadly defined as disordered gastric emptying, and is a commonly encountered clinical problem[78]. Delayed gastric emptying can be secondary to muscular, neural, humoral causes or use of anticholinergic and opiate medicines. In the absence of an identified cause, gastroparesis is termed as idiopathic[79]. Gastroparesis has a broad range of clinical presentations ranging from dyspeptic symptoms to nausea, vomiting, abdominal pain, malnutrition, frequent hospitalizations and incapacitation[80], chronic abdominal pain and vomiting leading to dehydration, electrolyte imbalance, nutritional impairment and weight loss[81].

The ICC are fundamental in the generation of gastric slow waves[79]. A decrease in ICC density ranging from 60%-100% depending on the area investigated was demonstrated in histologic studies of the stomach of type 1 diabetic patients[55]. The number of immunopositive cells for c-kit was significantly decreased in the corpus and antrum of the gastroparesis patients compared with control tissues[62]. The loss of intramuscular ICC and associated nerves in the gastric fundus could explain the low basal gastric tone and increased compliance of the stomach. The hypomotility of the antrum can also be explained by the absence of slow wave generation by the ICC[23].

Infantile hypertrophic pyloric stenosis: Infantile hy-

pertrophic pyloric stenosis (IHPS) is common in infants, characterized by marked delayed gastric emptying and hypertrophy of the inner (circular) muscle layer of the pylorus[59]. IHPS has been known for more than a century[82] but it remains a puzzling disorder[83]. The genetic susceptibility to development of IHPS seems to be multifactorial[84]. Hypertrophy of the pyloric musculature develops after birth[85] and produces the characteristic palpable pyloric "olive." The pyloric lumen is however not fully occluded[86] and can be intubated relatively easily[87], suggesting that the obstruction of the gastric outlet in IHPS is not merely due to a mechanical obstruction by the hypertrophied musculature. The extent of muscle hypertrophy appeared to be unrelated to the age or duration of symptoms[88].

Various neurotransmitters[89-91] and the neuronal isoform of NO synthase[92] are reduced or lacking in the hypertrophic musculature. The increased thickness of the pyloric muscular coats appears to be due to hypertrophy, rather than to hyperplasia, of the smooth muscle cells[93]. ICC, identified either by electron microscopy[94] or by Kit-ir[95,96] were consistently lacking in the hypertrophic circular muscle layer. However, Kit-ir cells, similar to Kit-ir ICC observed in controls, were observed in the innermost part of the hypertrophic pylorus and in the antrum, indicating that the lack of Kit-ir is restricted to the hypertophic pyloric musculature[95].

The lack of ICC in IHPS may interfere with the propagation of slow waves and may be, at least partly, involved in antro-pyloric incoordination[59]. Homozygous transgenic mice carrying inactivated genes ("knock-out") coding for the neuronal NO synthase developed hypertrophy of the pylorus[97]. The link between the lack of ICC, the lack of inhibitory nitrergic neurotransmission, and the hypertrophy of the smooth musculature in IHPS remains to be elucidated[59].

Small intestine and colon

Hirschsprung's disease: Hirschsprung's disease (HD) is characterized by the lack of intrinsic enteric nervous system (ENS) in the distal part of the GI tract ("aganglionosis"). The affected segment extends cranially from the anus and encompasses a variable portion of the gut. Functionally, the lack of propulsive movements may lead either to an early obstructive syndrome in infancy or to a severe constipation[98]. Lack of slow wave activity in the aganglionic segment has been identified[99]. Kit immunohistochemistry identified ICC in HD. However, the cellular density of Kit+ ICC appeared markedly reduced in the aganglionic segment[100]. ICC-MP were rather abundant in the (aganglionic) space between the muscle layers. Kit+ ICC were specially scarce in the inner part of the circular musculature and in the submuscular plexus. However, the presence of some ICC-SMP was confirmed by electron microscopy.

In contrast, another study reported a distribution of Kit+ ICC in HD comparable to controls and claimed that Kit1 ICC-MP form "normal" networks in aganglionic segments when studied by confocal microscopy on whole mount preparations[101].

Differences in interpretation may be less significant than it appears as there is an agreement in the literature to acknowledge the presence of a number of interconnecting ICC-MP in aganglionic segments but there is no objective criterion to assess the "normality" of networks. Considering the very close relationships of ICC with intrinsic nerves and glial cells in the normal gut, a normal arrangement of ICC appears quite unlikely in the absence of both intrinsic nerves and glial cells as encountered in aganglionic segments. In the embryonic chicken[1] or mouse[102] gut experimentally deprived of neural crest derivatives, ICC develop in the absence of ENS, confirming the mesenchymal nature of ICC. But it has not been established if ICC fully develop morphologically and functionally in such conditions.

HD is a heterogenous, multigenic disease and reviewing its genetic aspects is beyond the scope of this paper. Several systems regulating neural crest migration have recently been identified[103]. Some genes are expressed by the neural crest, others by the mesenchyme of the gut. Kit has previously been considered as a possible candidate in the search for genes involved in hereditary forms of HD[104] but the absence of linkage between HD and the region of the *Kit* gene has been more recently reported[105]. The genetic defects leading to aganglionosis in the HD patients enrolled in all studies on ICC published so far have not been assessed. Subtle differences may explain the discrepancies observed between studies, and a link between some specific genetic defect leading to aganglionosis and the differentiation of ICC in HD patients cannot be ruled out.

Intestinal neural dysplasia: A clinical condition that resembles HD was first described by Meier-Ruge[106] in 1971 as a malformation of the enteric plexus. In 1983, Fadda *et al*[107] subclassified intestinal neural dysplasia (IND) into two clinically and histologically distinct subtypes. Type A occurs in less than 5% of cases, is characterized by congenital aplasia or hypoplasia of the sympathetic innervations, and presents acutely in the neonatal period with episodes of intestinal obstruction, diarrhea and bloody stools. The clinical picture of Type B resembles HD and is characterized by malformation of the parasympathetic submucous and myenteric plexuses and accounts for over 95% of cases of isolated IND. IND occurring in association with HD is of Type B[108]. IND have been reported to be associated with loss or deficiency of ICC networks[109].

Chronic intestinal pseudo-obstruction: Chronic intestinal pseudoobstruction (CIPO) is characterized by defective GI propulsion together with symptoms and signs of bowel obstruction in the absence of any lesions or mechanical obstacle[110]. It is generally a serious, even life-threatening, condition with frequent need for long-term parenteral nutrition. CIPO can either be restricted to the intestine, can involve other parts of the GI tract, or can be part of

a multisystemic disorder[59]. CIPO can be secondary to a number of identified disorders or can be "idiopathic"[111]. Very little is known about the etiology of idiopathic CIPO. Pathological features of CIPO are pleiomorphic. A number of alterations of the ENS ("neuropathic" forms)[112] and "myopathic" forms, limited to the musculature of the GI tract or involving also the musculature of the urinary system[113,114], have been described.

Slow transit constipation: Functional constipation encompasses a group of functional disorders that exhibit persistent difficult, infrequent, or seemingly incomplete defecation and infrequent, lumpy, or hard stools[115,116]. This symptom is very common and may occur in up to 20% of populations, depending on demographic factors, sampling, and the definitions employed[115,117]. The term constipation is probably better viewed as a sort of semantic umbrella, covering pathophysiologic subtypes, among which 2 major groups may now be identified: slow transit constipation (STC) and pelvic floor dysfunction[118].

STC is thought to have, as a primary defect, slower than normal movement of contents from the cecum to the rectum[119]. This is a very prevalent motility problem, but its mechanisms are unclear[62]. Although STC may not be a congenital disease, the frequent onset in adolescence and strong female predominance suggest that STC could be a result of a sex modified multifactorial disorder of the GI tract with a genetic basis[120].

ICC volume was significantly lower in the STC patien+ cross all colonic regions[121]. Expression of *c-kit* mRNA and c-kit protein was significantly decreased in the colon of STC, suggesting that the c-kit signal pathway may play an important role in ICC reduction in STC[122]. Shafik *et al*[123] concluded that a disorder of the ICC, which generate electric activity, may have a role in inducing diminished or absent colonic motor activity, a point that should be further investigated.

TUMORS OF GI TRACT

GI stromal tumors (GISTs) have been recognized as a biologically distinctive tumor type, different from smooth muscle and neural tumors of the GI tract. They constitute the majority of GI mesenchymal tumors[124].

GISTs exhibit considerable phenotypic heterogeneity[125]. Their origin remains unclear, although origin in smooth muscle cells has been proposed[126,127]. CD34-ir is often present in GIST[125,128-130], a property shared with various other solid tumors[131,132].

Kit-ir may be a suitable marker for GIST[133], possibly superior to CD34-ir[134]. Mutations (usually activating) of the proto-oncogene Kit have been identified in GIST[133,135-137]. GIST with Kit mutation appear to have a poorer prognosis[133,135-138]. Therefore Kit mutations may merely be part of the oncogenic process rather than an indication of the origin of these tumors.

Recent studies suggesting that ICC in the human gut were both Kit-ir and CD34-ir raised the idea that Kit+ CD34+ GIST may derive from ICC[128,133,137].

The majority of GISTs occurs in the stomach (60%-70%), small intestine (20%-30%) and only 10% or less in the esophagus, colon and rectum, and they affect mainly middle aged patients. Similar tumors, sometimes known as extra-GIST, may arise in the omentum, mesentery, or retroperitoneum and at least one case of pancreatic tumor was described[139,140]. The presence of ICC in normal pancreas was demonstrated recently[15].

The symptoms may vary from none or slight abdominal discomfort to brisk GI hemorrhage, perforation or obstruction.

Imatinib mesylate, a synthetic tyrosine kinase inhibitor developed for the use in the management of interferon resistant chronic myeloid leukemia, was shown to be effective against a number of other tyrosine kinases including c-kit and platelet derived growth factor and now it is considered to be the drug of choice for metastatic and inoperable GISTs[124,141].

CONCLUSION

Knowledge on the role of ICC in GI disorders is increasing and there is currently overwhelming evidence to support the idea that ICC play important roles in GI motility in laboratory animals. Studies of several animal models have shown that the lack of specific ICC subpopulations produces major disturbances of GI motility. ICC are unique cell types with a central role in the control of gut function. Further studies of ICC may, therefore, lead to a major breakthrough in more understanding of GI physiology which may be considered as a promising target, at least in the long run, for specific pharmacological interventions to restore the normal physiology and motor functions of the GI tract.

ACKNOWLEDGMENTS

This article is dedicated to the memory of Professor Ahmed Shafik, my teacher, guide and guardian. His productive and creative mind, his unabated interest in new fields of research, and his unflagging energy were all qualities which formed part of a great personality. He is perhaps the last encyclopedic mind to be found on the crossroads of research and gastrointestinal tract surgery. May his soul rest in peace and tranquility.

REFERENCES

1 **Lecoin L**, Gabella G, Le Douarin N. Origin of the c-kit-positive interstitial cells in the avian bowel. *Development* 1996; **122**: 725-733

2 **Young HM**, Ciampoli D, Johnson PJ, Stebbing MJ. Inhibitory transmission to the longitudinal muscle of the mouse caecum is mediated largely by nitric oxide acting via soluble guanylyl cyclase. *J Auton Nerv Syst* 1996; **61**: 103-108

3 **Young HM**. Embryological origin of interstitial cells of Cajal. *Microsc Res Tech* 1999; **47**: 303-308

4 **Sanders KM**. A case for interstitial cells of Cajal as pacemakers and mediators of neurotransmission in the gastrointestinal tract. *Gastroenterology* 1996; **111**: 492-515

5 **Faussone-Pellegrini MS**, Thuneberg L. Guide to the identi-

fication of interstitial cells of Cajal. *Microsc Res Tech* 1999; **47**: 248-266
6 **Rumessen JJ**, Thuneberg L. Pacemaker cells in the gastrointestinal tract: interstitial cells of Cajal. *Scand J Gastroenterol Suppl* 1996; **216**: 82-94
7 **Piaseczna Piotrowska A**, Rolle U, Solari V, Puri P. Interstitial cells of Cajal in the human normal urinary bladder and in the bladder of patients with megacystis-microcolon intestinal hypoperistalsis syndrome. *BJU Int* 2004; **94**: 143-146
8 **Shafik A**, El-Sibai O, Shafik AA, Shafik I. Identification of interstitial cells of Cajal in human urinary bladder: concept of vesical pacemaker. *Urology* 2004; **64**: 809-813
9 **Solari V**, Piotrowska AP, Puri P. Altered expression of interstitial cells of Cajal in congenital ureteropelvic junction obstruction. *J Urol* 2003; **170**: 2420-2422
10 **Fischer C**, Johnson J, Stillwell B, Conner J, Cerovac Z, Wilson-Rawls J, Rawls A. Activating transcription factor 4 is required for the differentiation of the lamina propria layer of the vas deferens. *Biol Reprod* 2004; **70**: 371-378
11 **Shafik A**, Shafik I, el-Sibai O. Identification of c-kit-positive cells in the human prostate: the interstitial cells of Cajal. *Arch Androl* 2005; **51**: 345-351
12 **Hashitani H**, Suzuki H. Identification of interstitial cells of Cajal in corporal tissues of the guinea-pig penis. *Br J Pharmacol* 2004; **141**: 199-204
13 **Shafik A**. Study of interstitial cells in the penis: human study. *J Sex Med* 2007; **4**: 66-71
14 **Shafik A**, El-Sibai O, Shafik I. Identification of c-kit-positive cells in the uterus. *Int J Gynaecol Obstet* 2004; **87**: 254-255
15 **Popescu LM**, Hinescu ME, Ionescu N, Ciontea SM, Cretoiu D, Ardelean C. Interstitial cells of Cajal in pancreas. *J Cell Mol Med* 2005; **9**: 169-190
16 **Harhun MI**, Pucovský V, Povstyan OV, Gordienko DV, Bolton TB. Interstitial cells in the vasculature. *J Cell Mol Med* 2005; **9**: 232-243
17 **Povstyan OV**, Gordienko DV, Harhun MI, Bolton TB. Identification of interstitial cells of Cajal in the rabbit portal vein. *Cell Calcium* 2003; **33**: 223-239
18 **Shafik A**, El-Sibai O, Shafik I, Shafik AA. Immunohistochemical identification of the pacemaker cajal cells in the normal human vagina. *Arch Gynecol Obstet* 2005; **272**: 13-16
19 **Richter A**, Wit C, Vanderwinden JM, Wit J, Barthlen W. Interstitial cells of Cajal in the vermiform appendix in childhood. *Eur J Pediatr Surg* 2009; **19**: 30-33
20 **McHale N**, Hollywood M, Sergeant G, Thornbury K. Origin of spontaneous rhythmicity in smooth muscle. *J Physiol* 2006; **570**: 23-28
21 **Huizinga JD**, Lammers WJ. Gut peristalsis is governed by a multitude of cooperating mechanisms. *Am J Physiol Gastrointest Liver Physiol* 2009; **296**: G1-G8
22 **Sanders KM**, Ward SM. Kit mutants and gastrointestinal physiology. *J Physiol* 2007; **578**: 33-42
23 **Ordög T**, Redelman D, Horváth VJ, Miller LJ, Horowitz B, Sanders KM. Quantitative analysis by flow cytometry of interstitial cells of Cajal, pacemakers, and mediators of neurotransmission in the gastrointestinal tract. *Cytometry A* 2004; **62**: 139-149
24 **Hirst GD**, Ward SM. Interstitial cells: involvement in rhythmicity and neural control of gut smooth muscle. *J Physiol* 2003; **550**: 337-346
25 **Connor JA**, Prosser CL, Weems WA. A study of pace-maker activity in intestinal smooth muscle. *J Physiol* 1974; **240**: 671-701
26 **El-Sharkaway TY**, Daniel EE. Ionic mechanisms of intestinal electrical control activity. *Am J Physiol* 1975; **229**: 1287-1298
27 **Farrugia G**. Ionic conductances in gastrointestinal smooth muscles and interstitial cells of Cajal. *Annu Rev Physiol* 1999; **61**: 45-84
28 **Nakayama S**, Chihara S, Clark JF, Huang SM, Horiuchi T, Tomita T. Consequences of metabolic inhibition in smooth muscle isolated from guinea-pig stomach. *J Physiol* 1997; **505** (Pt 1): 229-240
29 **Thuneberg L**. Interstitial cells of Cajal: intestinal pacemaker cells? *Adv Anat Embryol Cell Biol* 1982; **71**: 1-130
30 **Huizinga JD**, Thuneberg L, Klüppel M, Malysz J, Mikkelsen HB, Bernstein A. W/kit gene required for interstitial cells of Cajal and for intestinal pacemaker activity. *Nature* 1995; **373**: 347-349
31 **Langton P**, Ward SM, Carl A, Norell MA, Sanders KM. Spontaneous electrical activity of interstitial cells of Cajal isolated from canine proximal colon. *Proc Natl Acad Sci USA* 1989; **86**: 7280-7284
32 **Tokutomi N**, Maeda H, Tokutomi Y, Sato D, Sugita M, Nishikawa S, Nishikawa S, Nakao J, Imamura T, Nishi K. Rhythmic Cl- current and physiological roles of the intestinal c-kit-positive cells. *Pflugers Arch* 1995; **431**: 169-177
33 **Daniel EE**, Posey-Daniel V. Neuromuscular structures in opossum esophagus: role of interstitial cells of Cajal. *Am J Physiol* 1984; **246**: G305-G315
34 **Hagger R**, Gharaie S, Finlayson C, Kumar D. Distribution of the interstitial cells of Cajal in the human anorectum. *J Auton Nerv Syst* 1998; **73**: 75-79
35 **Hanani M**, Farrugia G, Komuro T. Intercellular coupling of interstitial cells of cajal in the digestive tract. *Int Rev Cytol* 2005; **242**: 249-282
36 **Farrugia G**. Interstitial cells of Cajal in health and disease. *Neurogastroenterol Motil* 2008; **20** Suppl 1: 54-63
37 **Ward SM**, Beckett EA, Wang X, Baker F, Khoyi M, Sanders KM. Interstitial cells of Cajal mediate cholinergic neurotransmission from enteric motor neurons. *J Neurosci* 2000; **20**: 1393-1403
38 **Iino S**, Horiguchi K. Interstitial cells of cajal are involved in neurotransmission in the gastrointestinal tract. *Acta Histochem Cytochem* 2006; **39**: 145-153
39 **Fox EA**, Phillips RJ, Martinson FA, Baronowsky EA, Powley TL. Vagal afferent innervation of smooth muscle in the stomach and duodenum of the mouse: morphology and topography. *J Comp Neurol* 2000; **428**: 558-576
40 **Horiguchi K**, Semple GS, Sanders KM, Ward SM. Distribution of pacemaker function through the tunica muscularis of the canine gastric antrum. *J Physiol* 2001; **537**: 237-250
41 **Hirst GD**. An additional role for ICC in the control of gastrointestinal motility? *J Physiol* 2001; **537**: 1
42 **Huizinga JD**. Gastrointestinal peristalsis: joint action of enteric nerves, smooth muscle, and interstitial cells of Cajal. *Microsc Res Tech* 1999; **47**: 239-247
43 **Tonini M**, Costa M, Brookes SJ, Humphreys CM. Dissociation of the ascending excitatory reflex from peristalsis in the guinea-pig small intestine. *Neuroscience* 1996; **73**: 287-297
44 **Huizinga JD**, Thuneberg L, Vanderwinden JM, Rumessen JJ. Interstitial cells of Cajal as targets for pharmacological intervention in gastrointestinal motor disorders. *Trends Pharmacol Sci* 1997; **18**: 393-403
45 **Sanders KM**, Ordög T, Ward SM. Physiology and pathophysiology of the interstitial cells of Cajal: from bench to bedside. IV. Genetic and animal models of GI motility disorders caused by loss of interstitial cells of Cajal. *Am J Physiol Gastrointest Liver Physiol* 2002; **282**: G747-G756
46 **Lee HK**, Sanders KM. Comparison of ionic currents from interstitial cells and smooth muscle cells of canine colon. *J Physiol* 1993; **460**: 135-152
47 **Ward SM**, Ordog T, Koh SD, Baker SA, Jun JY, Amberg G, Monaghan K, Sanders KM. Pacemaking in interstitial cells of Cajal depends upon calcium handling by endoplasmic reticulum and mitochondria. *J Physiol* 2000; **525** Pt 2: 355-361
48 **Koh SD**, Jun JY, Kim TW, Sanders KM. A Ca(2+)-inhibited non-selective cation conductance contributes to pacemaker currents in mouse interstitial cell of Cajal. *J Physiol* 2002; **540**: 803-814

49 **Hirst GD**, Edwards FR. Generation of slow waves in the antral region of guinea-pig stomach--a stochastic process. *J Physiol* 2001; **535**: 165-180
50 **Dickens EJ**, Hirst GD, Tomita T. Identification of rhythmically active cells in guinea-pig stomach. *J Physiol* 1999; **514** (Pt 2): 515-531
51 **Suzuki H**, Hirst GD. Regenerative potentials evoked in circular smooth muscle of the antral region of guinea-pig stomach. *J Physiol* 1999; **517** (Pt 2): 563-573
52 **Suzuki H**, Ward SM, Bayguinov YR, Edwards FR, Hirst GD. Involvement of intramuscular interstitial cells in nitrergic inhibition in the mouse gastric antrum. *J Physiol* 2003; **546**: 751-763
53 **Edwards FR**, Hirst GD, Suzuki H. Unitary nature of regenerative potentials recorded from circular smooth muscle of guinea-pig antrum. *J Physiol* 1999; **519** Pt 1: 235-250
54 **Hudson N**, Mayhew I, Pearson G. A reduction in interstitial cells of Cajal in horses with equine dysautonomia (grass sickness). *Auton Neurosci* 2001; **92**: 37-44
55 **Long QL**, Fang DC, Shi HT, Luo YH. Gastro-electric dysrhythm and lack of gastric interstitial cells of cajal. *World J Gastroenterol* 2004; **10**: 1227-1230
56 **Rolle U**, Piotrowska AP, Nemeth L, Puri P. Altered distribution of interstitial cells of Cajal in Hirschsprung disease. *Arch Pathol Lab Med* 2002; **126**: 928-933
57 **Zárate N**, Mearin F, Wang XY, Hewlett B, Huizinga JD, Malagelada JR. Severe idiopathic gastroparesis due to neuronal and interstitial cells of Cajal degeneration: pathological findings and management. *Gut* 2003; **52**: 966-970
58 **Fintl C**, Hudson NP, Mayhew IG, Edwards GB, Proudman CJ, Pearson GT. Interstitial cells of Cajal (ICC) in equine colic: an immunohistochemical study of horses with obstructive disorders of the small and large intestines. *Equine Vet J* 2004; **36**: 474-479
59 **Vanderwinden JM**, Rumessen JJ. Interstitial cells of Cajal in human gut and gastrointestinal disease. *Microsc Res Tech* 1999; **47**: 344-360
60 **Torihashi S**, Horisawa M, Watanabe Y. c-Kit immunoreactive interstitial cells in the human gastrointestinal tract. *J Auton Nerv Syst* 1999; **75**: 38-50
61 **Kraichely RE**, Farrugia G. Achalasia: physiology and etiopathogenesis. *Dis Esophagus* 2006; **19**: 213-223
62 **Negreanu LM**, Assor P, Mateescu B, Cirstoiu C. Interstitial cells of Cajal in the gut--a gastroenterologist's point of view. *World J Gastroenterol* 2008; **14**: 6285-6288
63 **Richardson BJ**, Welch RW. Differential effect of atropine on rightward and leftward lower esophageal sphincter pressure. *Gastroenterology* 1981; **81**: 85-89
64 **Ward SM**, Morris G, Reese L, Wang XY, Sanders KM. Interstitial cells of Cajal mediate enteric inhibitory neurotransmission in the lower esophageal and pyloric sphincters. *Gastroenterology* 1998; **115**: 314-329
65 **Faussone-Pellegrini MS**, Cortesini C. The muscle coat of the lower esophageal sphincter in patients with achalasia and hypertensive sphincter. An electron microscopic study. *J Submicrosc Cytol* 1985; **17**: 673-685
66 **Myers NA**, Jolley SG, Taylor R. Achalasia of the cardia in children: a worldwide survey. *J Pediatr Surg* 1994; **29**: 1375-1379
67 **Allgrove J**, Clayden GS, Grant DB, Macaulay JC. Familial glucocorticoid deficiency with achalasia of the cardia and deficient tear production. *Lancet* 1978; **1**: 1284-1286
68 **Moore PS**, Couch RM, Perry YS, Shuckett EP, Winter JS. Allgrove syndrome: an autosomal recessive syndrome of ACTH insensitivity, achalasia and alacrima. *Clin Endocrinol* (Oxf) 1991; **34**: 107-114
69 **Dugardeyn C**, Anooshiravani M, Christophe C, Goyens P, Perlmutter N. Achalasia-alacrima-ACTH insensitivity syndrome (Triple-A-syndrome). *J Belge Radiol* 1993; **76**: 167-168
70 **Weber A**, Wienker TF, Jung M, Easton D, Dean HJ, Heinrichs C, Reis A, Clark AJ. Linkage of the gene for the triple A syndrome to chromosome 12q13 near the type II keratin gene cluster. *Hum Mol Genet* 1996; **5**: 2061-2066
71 **Lui H**, Vanderwinden JM, Ji P, De Laet MH. Nitric oxide synthase distribution in the enteric nervous system of children with cardiac achalasia. *Chin Med J* (Engl) 1997; **110**: 358-361
72 **Yamagishi H**, Koike T, Ohara S, Kobayashi S, Ariizumi K, Abe Y, Iijima K, Imatani A, Inomata Y, Kato K, Shibuya D, Aida S, Shimosegawa T. Prevalence of gastroesophageal reflux symptoms in a large unselected general population in Japan. *World J Gastroenterol* 2008; **14**: 1358-1364
73 **Kaltenbach T**, Crockett S, Gerson LB. Are lifestyle measures effective in patients with gastroesophageal reflux disease? An evidence-based approach. *Arch Intern Med* 2006; **166**: 965-971
74 **Dickens EJ**, Edwards FR, Hirst GD. Selective knockout of intramuscular interstitial cells reveals their role in the generation of slow waves in mouse stomach. *J Physiol* 2001; **531**: 827-833
75 **Ward SM**, Sanders KM. Physiology and pathophysiology of the interstitial cell of Cajal: from bench to bedside. I. Functional development and plasticity of interstitial cells of Cajal networks. *Am J Physiol Gastrointest Liver Physiol* 2001; **281**: G602-G611
76 **Shafik A**, El-Sibai O, Shafik I, Shafik A. Electroesophagogram in gastroesophageal reflux disease with a new theory on the pathogenesis of its electric changes. *BMC Surg* 2004; **4**: 13
77 **Vittal H**, Farrugia G, Gomez G, Pasricha PJ. Mechanisms of disease: the pathological basis of gastroparesis--a review of experimental and clinical studies. *Nat Clin Pract Gastroenterol Hepatol* 2007; **4**: 336-346
78 **Abell TL**, Malinowski S, Minocha A. Nutrition aspects of gastroparesis and therapies for drug-refractory patients. *Nutr Clin Pract* 2006; **21**: 23-33
79 **Forster J**, Damjanov I, Lin Z, Sarosiek I, Wetzel P, McCallum RW. Absence of the interstitial cells of Cajal in patients with gastroparesis and correlation with clinical findings. *J Gastrointest Surg* 2005; **9**: 102-108
80 **Reddymasu SC**, McCallum RW. Pharmacotherapy of gastroparesis. *Expert Opin Pharmacother* 2009; **10**: 469-484
81 **Hirst GD**, Edwards FR. Role of interstitial cells of Cajal in the control of gastric motility. *J Pharmacol Sci* 2004; **96**: 1-10
82 **Hayes MA**, Goldenberg IS. The problems of infantile pyloric stenosis. *Surg Gynecol Obstet* 1957; **104**: 105-138
83 **Rogers IM**. The enigma of pyloric stenosis. Some thoughts on the aetiology. *Acta Paediatr* 1997; **86**: 6-9
84 **Mitchell LE**, Risch N. The genetics of infantile hypertrophic pyloric stenosis. A reanalysis. *Am J Dis Child* 1993; **147**: 1203-1211
85 **Rollins MD**, Shields MD, Quinn RJ, Wooldridge MA. Pyloric stenosis: congenital or acquired? *Arch Dis Child* 1989; **64**: 138-139
86 **Lynn HB**. The mechanism of pyloric stenosis and its relationship to preoperative preparation. *Arch Surg* 1960; **81**: 453-459
87 **Yamashiro Y**, Mayama H, Yamamoto K, Sato M, Nawate G. Conservative management of infantile pyloric stenosis by nasoduodenal feeding. *Eur J Pediatr* 1981; **136**: 187-192
88 **Ukabiala O**, Lister J. The extent of muscle hypertrophy in infantile hypertrophic pyloric stenosis does not depend on age and duration of symptoms. *J Pediatr Surg* 1987; **22**: 200-202
89 **Kobayashi H**, O'Briain DS, Puri P. Immunochemical characterization of neural cell adhesion molecule (NCAM), nitric oxide synthase, and neurofilament protein expression in pyloric muscle of patients with pyloric stenosis. *J Pediatr Gastroenterol Nutr* 1995; **20**: 319-325
90 **Schröder JM**, Dieler R, Skopnik H, Steinau G. Immunohistochemical reactivity of neuropeptides in plastic-embedded semithin sections of the myenteric plexus in infantile hypertrophic pylorus stenosis. *Acta Histochem Suppl* 1992; **42**: 341-344

91 **Wattchow DA**, Cass DT, Furness JB, Costa M, O'Brien PE, Little KE, Pitkin J. Abnormalities of peptide-containing nerve fibers in infantile hypertrophic pyloric stenosis. *Gastroenterology* 1987; **92**: 443-448

92 **Vanderwinden JM**, Mailleux P, Schiffmann SN, Vanderhaeghen JJ, De Laet MH. Nitric oxide synthase activity in infantile hypertrophic pyloric stenosis. *N Engl J Med* 1992; **327**: 511-515

93 **Tam PK**. Observations and perspectives of the pathology and possible aetiology of infantile hypertrophic pyloric stenosis--a histological, biochemical, histochemical and immunocytochemical study. *Ann Acad Med Singapore* 1985; **14**: 523-529

94 **Langer JC**, Berezin I, Daniel EE. Hypertrophic pyloric stenosis: ultrastructural abnormalities of enteric nerves and the interstitial cells of Cajal. *J Pediatr Surg* 1995; **30**: 1535-1543

95 **Vanderwinden JM**, Liu H, De Laet MH, Vanderhaeghen JJ. Study of the interstitial cells of Cajal in infantile hypertrophic pyloric stenosis. *Gastroenterology* 1996; **111**: 279-288

96 **Yamataka A**, Fujiwara T, Kato Y, Okazaki T, Sunagawa M, Miyano T. Lack of intestinal pacemaker (C-KIT-positive) cells in infantile hypertrophic pyloric stenosis. *J Pediatr Surg* 1996; **31**: 96-98; discussion 98-99

97 **Huang PL**, Dawson TM, Bredt DS, Snyder SH, Fishman MC. Targeted disruption of the neuronal nitric oxide synthase gene. *Cell* 1993; **75**: 1273-1286

98 **Meier-Ruge W**, Gambazzi F, Käufeler RE, Schmid P, Schmidt CP. The neuropathological diagnosis of neuronal intestinal dysplasia (NID B). *Eur J Pediatr Surg* 1994; **4**: 267-273

99 **Kubota M**, Ito Y, Ikeda K. Membrane properties and innervation of smooth muscle cells in Hirschsprung's disease. *Am J Physiol* 1983; **244**: G406-G415

100 **Yamataka A**, Kato Y, Tibboel D, Murata Y, Sueyoshi N, Fujimoto T, Nishiye H, Miyano T. A lack of intestinal pacemaker (c-kit) in aganglionic bowel of patients with Hirschsprung's disease. *J Pediatr Surg* 1995; **30**: 441-444

101 **Horisawa M**, Watanabe Y, Torihashi S. Distribution of c-Kit immunopositive cells in normal human colon and in Hirschsprung's disease. *J Pediatr Surg* 1998; **33**: 1209-1214

102 **Young HM**, Ciampoli D, Southwell BR, Newgreen DF. Origin of interstitial cells of Cajal in the mouse intestine. *Dev Biol* 1996; **180**: 97-107

103 **Bidaud C**, Salomon R, Van Camp G, Pelet A, Attié T, Eng C, Bonduelle M, Amiel J, Nihoul-Fékété C, Willems PJ, Munnich A, Lyonnet S. Endothelin-3 gene mutations in isolated and syndromic Hirschsprung disease. *Eur J Hum Genet* 1997; **5**: 247-251

104 **Kapur RP**. Contemporary approaches toward understanding the pathogenesis of Hirschsprung disease. *Pediatr Pathol* 1993; **13**: 83-100

105 **Dow E**, Cross S, Wolgemuth DJ, Lyonnet S, Mulligan LM, Mascari M, Ladda R, Williamson R. Second locus for Hirschsprung disease/Waardenburg syndrome in a large Mennonite kindred. *Am J Med Genet* 1994; **53**: 75-80

106 **Meier-Ruge W**. [Casuistic of colon disorder with symptoms of Hirschsprung's disease (author's transl)] *Verh Dtsch Ges Pathol* 1971; **55**: 506-510

107 **Fadda B**, Maier WA, Meier-Ruge W, Schärli A, Daum R. [Neuronal intestinal dysplasia. Critical 10-years' analysis of clinical and biopsy diagnosis] *Z Kinderchir* 1983; **38**: 305-311

108 **Puri P**. Intestinal neuronal dysplasia. *Semin Pediatr Surg* 2003; **12**: 259-264

109 **Rolle U**, Piaseczna-Piotrowska A, Puri P. Interstitial cells of Cajal in the normal gut and in intestinal motility disorders of childhood. *Pediatr Surg Int* 2007; **23**: 1139-1152

110 **De Giorgio R**, Sarnelli G, Corinaldesi R, Stanghellini V. Advances in our understanding of the pathology of chronic intestinal pseudo-obstruction. *Gut* 2004; **53**: 1549-1552

111 **Rudolph CD**, Hyman PE, Altschuler SM, Christensen J, Colletti RB, Cucchiara S, Di Lorenzo C, Flores AF, Hillemeier AC, McCallum RW, Vanderhoof JA. Diagnosis and treatment of chronic intestinal pseudo-obstruction in children: report of consensus workshop. *J Pediatr Gastroenterol Nutr* 1997; **24**: 102-112

112 **Krishnamurthy S**, Heng Y, Schuffler MD. Chronic intestinal pseudo-obstruction in infants and children caused by diverse abnormalities of the myenteric plexus. *Gastroenterology* 1993; **104**: 1398-1408

113 **Anuras S**, Mitros FA, Soper RT, Pringle KC, Maves BV, Younoszai MK, Franken EA Jr, Whitington P. Chronic intestinal pseudoobstruction in young children. *Gastroenterology* 1986; **91**: 62-70

114 **Smith VV**, Milla PJ. Histological phenotypes of enteric smooth muscle disease causing functional intestinal obstruction in childhood. *Histopathology* 1997; **31**: 112-122

115 **Bassotti G**, Chistolini F, Nzepa FS, Morelli A. Colonic propulsive impairment in intractable slow-transit constipation. *Arch Surg* 2003; **138**: 1302-1304

116 **Camilleri M**, Thompson WG, Fleshman JW, Pemberton JH. Clinical management of intractable constipation. *Ann Intern Med* 1994; **121**: 520-528

117 **Locke GR 3rd**. The epidemiology of functional gastrointestinal disorders in North America. *Gastroenterol Clin North Am* 1996; **25**: 1-19

118 **Locke GR 3rd**, Pemberton JH, Phillips SF. AGA technical review on constipation. American Gastroenterological Association. *Gastroenterology* 2000; **119**: 1766-1778

119 **Nyam DC**, Pemberton JH. Long-term results of lateral internal sphincterotomy for chronic anal fissure with particular reference to incidence of fecal incontinence. *Dis Colon Rectum* 1999; **42**: 1306-1310

120 **Tong WD**, Liu BH, Zhang LY, Zhang SB. Analysis of the c-kit gene in patients with slow transit constipation. *Gut* 2006; **55**: 1207-1208

121 **Lyford GL**, He CL, Soffer E, Hull TL, Strong SA, Senagore AJ, Burgart LJ, Young-Fadok T, Szurszewski JH, Farrugia G. Pan-colonic decrease in interstitial cells of Cajal in patients with slow transit constipation. *Gut* 2002; **51**: 496-501

122 **Schiller LR**. New and emerging treatment options for chronic constipation. *Rev Gastroenterol Disord* 2004; **4** Suppl 2: S43-S51

123 **Shafik A**, Shafik AA, El-Sibai O, Mostafa RM. Electric activity of the colon in subjects with constipation due to total colonic inertia: an electrophysiologic study. *Arch Surg* 2003; **138**: 1007-1011; discussion 1011

124 **D'Amato G**, Steinert DM, McAuliffe JC, Trent JC. Update on the biology and therapy of gastrointestinal stromal tumors. *Cancer Control* 2005; **12**: 44-56

125 **Erlandson RA**, Klimstra DS, Woodruff JM. Subclassification of gastrointestinal stromal tumors based on evaluation by electron microscopy and immunohistochemistry. *Ultrastruct Pathol* 1996; **20**: 373-393

126 **Saul SH**, Rast ML, Brooks JJ. The immunohistochemistry of gastrointestinal stromal tumors. Evidence supporting an origin from smooth muscle. *Am J Surg Pathol* 1987; **11**: 464-473

127 **Mikami T**, Terada T, Nakamura K, Okayasu I. The gastric hypercellular microleiomyoma as a precursor lesion for clinical gastrointestinal stromal tumors. *Hum Pathol* 1997; **28**: 1355-1360

128 **Sakurai S**, Fukasawa T, Chong JM, Tanaka A, Fukayama M. Embryonic form of smooth muscle myosin heavy chain (SMemb/MHC-B) in gastrointestinal stromal tumor and interstitial cells of Cajal. *Am J Pathol* 1999; **154**: 23-28

129 **Monihan JM**, Carr NJ, Sobin LH. CD34 immunoexpression in stromal tumours of the gastrointestinal tract and in mesenteric fibromatoses. *Histopathology* 1994; **25**: 469-473

130 **Miettinen M**, Sarlomo-Rikala M, Lasota J. Gastrointestinal stromal tumours. *Ann Chir Gynaecol* 1998; **87**: 278-281

131 **Silverman JS**, Tamsen A. Mammary fibroadenoma and some phyllodes tumour stroma are composed of CD34+ fibroblasts

and factor XIIIa+ dendrophages. *Histopathology* 1996; **29**: 411-419
132 **Chaubal A**, Paetau A, Zoltick P, Miettinen M. CD34 immunoreactivity in nervous system tumors. *Acta Neuropathol* 1994; **88**: 454-458
133 **Kindblom LG**, Remotti HE, Aldenborg F, Meis-Kindblom JM. Gastrointestinal pacemaker cell tumor (GIPACT): gastrointestinal stromal tumors show phenotypic characteristics of the interstitial cells of Cajal. *Am J Pathol* 1998; **152**: 1259-1269
134 **Sarlomo-Rikala M**, Kovatich AJ, Barusevicius A, Miettinen M. CD117: a sensitive marker for gastrointestinal stromal tumors that is more specific than CD34. *Mod Pathol* 1998; **11**: 728-734
135 **Nakahara M**, Isozaki K, Hirota S, Miyagawa J, Hase-Sawada N, Taniguchi M, Nishida T, Kanayama S, Kitamura Y, Shinomura Y, Matsuzawa Y. A novel gain-of-function mutation of c-kit gene in gastrointestinal stromal tumors. *Gastroenterology* 1998; **115**: 1090-1095
136 **Lasota J**, Jasinski M, Sarlomo-Rikala M, Miettinen M. Mutations in exon 11 of c-Kit occur preferentially in malignant versus benign gastrointestinal stromal tumors and do not occur in leiomyomas or leiomyosarcomas. *Am J Pathol* 1999; **154**: 53-60
137 **Hirota S**, Isozaki K, Moriyama Y, Hashimoto K, Nishida T, Ishiguro S, Kawano K, Hanada M, Kurata A, Takeda M, Muhammad Tunio G, Matsuzawa Y, Kanakura Y, Shinomura Y, Kitamura Y. Gain-of-function mutations of c-kit in human gastrointestinal stromal tumors. *Science* 1998; **279**: 577-580
138 **Ernst SI**, Hubbs AE, Przygodzki RM, Emory TS, Sobin LH, O'Leary TJ. KIT mutation portends poor prognosis in gastrointestinal stromal/smooth muscle tumors. *Lab Invest* 1998; **78**: 1633-1636
139 **Yamaura K**, Kato K, Miyazawa M, Haba Y, Muramatsu A, Miyata K, Koide N. Stromal tumor of the pancreas with expression of c-kit protein: report of a case. *J Gastroenterol Hepatol* 2004; **19**: 467-470
140 **Nakagawa M**, Akasaka Y, Kanai T, Yamashita T, Kuroda M, Takayama H, Miyazawa N. Extragastrointestinal stromal tumor of the greater omentum: case report and review of the literature. *Hepatogastroenterology* 2003; **50**: 691-695
141 **de Silva CM**, Reid R. Gastrointestinal stromal tumors (GIST): C-kit mutations, CD117 expression, differential diagnosis and targeted cancer therapy with Imatinib. *Pathol Oncol Res* 2003; **9**: 13-19

S- Editor Tian L **L- Editor** O'Neill M **E- Editor** Zheng XM

World Journal of Gastroenterology

Online Submissions: http://www.wjgnet.com/1007-9327office
wjg@wjgnet.com
doi:10.3748/wjg.v16.i26.3249

World J Gastroenterol 2010 July 14; 16(26): 3249-3257
ISSN 1007-9327 (print)
© 2010 Baishideng. All rights reserved.

ORIGINAL ARTICLE

Nardostachys jatamansi extract protects against cytokine-induced β-cell damage and streptozotocin-induced diabetes

Mi-Young Song, Ui-Jin Bae, Bong-Hee Lee, Kang-Beom Kwon, Eun-A Seo, Sung-Joo Park, Min-Sun Kim, Ho-Joon Song, Keun-Sang Kwon, Jin-Woo Park, Do-Gon Ryu, Byung-Hyun Park

Mi-Young Song, Jin-Woo Park, Byung-Hyun Park, Department of Biochemistry, Medical School and Diabetes Research Center, Chonbuk National University, Jeonju, Jeonbuk 561-756, South Korea
Ui-Jin Bae, Bong-Hee Lee, Kang-Beom Kwon, Do-Gon Ryu, Department of Physiology, School of Oriental Medicine, Wonkwang University, Iksan, Jeonbuk 570-749, South Korea
Eun-A Seo, Department of Food and Nutrition, School of Human Environmental Science, Wonkwang University, Iksan, Jeonbuk 570-749, South Korea
Sung-Joo Park, Min-Sun Kim, Ho-Joon Song, Department of Herbology, School of Oriental Medicine, Wonkwang University, Iksan, Jeonbuk 570-749, South Korea
Keun-Sang Kwon, Department of Preventive Medicine, Medical School, Chonbuk National University, Jeonju, Jeonbuk 561-756, South Korea
Author contributions: Song MY and Bae UJ contributed equally to this work; Song MY and Bae UJ performed the research; Kwon KB, Seo EA and Park JW designed the research; Park SJ, Kim MS and Song HJ prepared *Nardostachys jatamansi* extract; Lee BH performed the research; Kwon KS analyzed the data; Ryu DG and Park BH wrote the paper.
Supported by Grant from the Ministry of Science and Technology/Korea Science and Engineering Foundation through the Diabetes Research Center at Chonbuk National University, R13-2008-005-0000-0, and by a Research Fund of Chonbuk National University in 2009 (to Park BH)
Correspondence to: Byung-Hyun Park, MD, PhD, Department of Biochemistry, Medical School and Diabetes Research Center, Chonbuk National University, Jeonju, Jeonbuk 561-756, South Korea. bhpark@jbnu.ac.kr
Telephone: +82-63-2703139 Fax: +82-63-2749833
Received: February 3, 2010 Revised: March 17, 2010
Accepted: March 24, 2010
Published online: July 14, 2010

Abstract

AIM: To investigate the anti-diabetogenic mechanism of *Nardostachys jatamansi* extract (NJE).

METHODS: Mice were injected with streptozotocin *via* a tail vein to induce diabetes. Rat insulinoma RINm5F cells and isolated rat islets were treated with interleukin-1β and interferon-γ to induce cytotoxicity.

RESULTS: Treatment of mice with streptozotocin resulted in hyperglycemia and hypoinsulinemia, which was confirmed by immunohistochemical staining of the islets. The diabetogenic effects of streptozotocin were completely abolished when mice were pretreated with NJE. Inhibition of streptozotocin-induced hyperglycemia by NJE was mediated by suppression of nuclear factor (NF)-κB activation. In addition, NJE protected against cytokine-mediated cytotoxicity. Incubation of RINm5F cells and islets with NJE resulted in a significant reduction in cytokine-induced NF-κB activation and downstream events, inducible nitric oxide synthase expression and nitric oxide production. The protective effect of NJE was further demonstrated by the normal insulin secretion of cytokine-treated islets in response to glucose.

CONCLUSION: NJE provided resistance to pancreatic β-cell damage from cytokine or streptozotocin treatment. The β-cell protective effect of NJE is mediated by suppressing NF-κB activation.

© 2010 Baishideng. All rights reserved.

Key words: *Nardostachys jatamansi*; Cytokines; Streptozotocin; Pancreatic β cells; Nuclear factor κB; Nitric oxide; Diabetes mellitus

Peer reviewer: Dr. Shivananda Nayak, PhD, Department of Preclinical Sciences, Biochemistry Unit, Faculty of Medical Sciences, The University of The West Indies, Building 36, EWMSC, Mount Hope, Trinidad and Tobago

Song MY, Bae UJ, Lee BH, Kwon KB, Seo EA, Park SJ, Kim MS, Song HJ, Kwon KS, Park JW, Ryu DG, Park BH. *Nardostachys jatamansi* extract protects against cytokine-induced β-cell damage and streptozotocin-induced diabetes. *World J Gastroenterol* 2010; 16(26): 3249-3257 Available from: URL: http://www.

wjgnet.com/1007-9327/full/v16/i26/3249.htm DOI: http://dx.doi.org/10.3748/wjg.v16.i26.3249

INTRODUCTION

Type 1 diabetes mellitus is an autoimmune disease that causes selective destruction of insulin producing β-cells in the islets of Langerhans. In early-stage disease, infiltration of inflammatory cells into the pancreatic islets can be observed histologically[1]. The inflammatory cells produce and release cytokines, including interleukin-1β (IL-1β), tumor necrosis factor-α (TNF-α), and interferon-γ (IFN-γ). IL-1β, alone or in combination with TNF-α or IFN-γ, upregulates inducible nitric oxide synthase (iNOS), and produces high levels of nitric oxide (NO) in pancreatic islets[2,3]. NO is produced by the oxidation of L-arginine to L-citruline by NOS, and generation of excess NO can inhibit mitochondrial metabolism, protein modification, and DNA cleavage; any one of which could lead to impaired insulin secretion and β-cell death[4,5]. Streptozotocin (STZ) is a diabetogenic agent that is toxic to pancreatic β-cells and is commonly used in diabetes research[6]. Streptozotocin contains a nitroso moiety and releases NO during its metabolism[7]. In rodents, STZ activates poly-ADP ribose polymerase, depletes cellular NAD and ATP, breaks DNA strands, and initiates β-cell necrosis[8].

NO production is regulated by transcription factors that bind to specific sites in the iNOS promoter. Nuclear factor (NF)-κB, which can be activated by cytokines and STZ, has been implicated as a key signaling mediator in iNOS induction[9,10]. When inactive, NF-κB is located in the cytosol complexed with NF-κB inhibitory factor (IκB). Various inducers cause complex dissociation, presumably *via* IκB phosphorylation. Released NF-κB translocates to the nucleus, where it interacts with recognition sites to mediate gene transcription[11]. We and others have shown that NF-κB-dependent NO production is involved in the dysfunction and destruction of β-cells, which suggests NO involvement in autoimmune diabetes pathogenesis[9,12-15].

Nardostachys jatamansi (*N. jatamansi*) is used in Ayurvedic medicine to treat mental disorders, hyperlipidemia, hypertension, and convulsions[16-18]. Various sesquiterpenes such as lignans and neolignans are present in root extracts of this plant[19]. *N. jatamansi* is suggested to protect cells and tissues through its antioxidative properties[20,21]. We found that *N. jatamansi* extract (NJE) protects against development of acute cerulean-induced pancreatitis[22]. However, as far as we are aware, no studies have reported on the antidiabetic effects of NJE. Therefore, in this study we examined the effect of NJE on cytokine- or STZ-stimulated pancreatic β-cell damage and the resultant development of type 1 diabetes.

MATERIALS AND METHODS

Cell culture and reagents

Rat pancreatic β-cell line RINm5F was from the American Type Culture Collection and were grown at 37℃ in a humidified 5% CO_2 atmosphere in RPMI 1640 medium (Gibco BRL, Grand Island, NY, USA), supplemented with 10% fetal bovine serum and 2 mmol/L glutamine, 100 U/mL penicillin, 100 μg/mL streptomycin, and 2.5 μg/mL amphotericin B. IL-1β and IFN-γ were obtained from R&D Systems (Minneapolis, MN, USA). All reagents were from Sigma (St. Louis, MO, USA), unless otherwise noted.

Preparation of NJE

N. jatamansi was from a standard commercial source (Omni Herb, Seoul, Korea), and its identity was confirmed at the Korean Drug Test Laboratory (Seoul, Korea). Voucher specimens (NO; Oh/wh/nj-43) were deposited at the School of Oriental Medicine Herbarium, Wonkwang University. NJE was prepared by decocting 200 g of dried herbs with 1800 mL boiling distilled water for approximately 2 h. The extract was filtered, freeze-dried and stored at 4℃.

Type 1 diabetes induction

Specific pathogen-free male ICR mice, weighing 25-30 g, were purchased from Orientbio Inc. (Seoungnam, Korea) and housed at our animal facility for 1 wk. All mice were kept under specific pathogen-free conditions with free access to a standard commercial diet and were used at 5-6 wk of age. To induce diabetes, mice were injected *via* the tail vein with 80 mg/kg STZ dissolved in 0.1 mol/L sodium citrate buffer (pH 4.0), prepared within 5 min of administration. Mice were divided into the following groups: (1) non-treated controls; (2) STZ; (3) NJE; and (4) NJE + STZ (n = 5 for each group). Control animals received citrate buffer alone. Group 4 received intraperitoneal injections of 125 mg/kg NJE daily for 3 d before administration of STZ. The day on which STZ was first administered was defined as day 1. At day 5, mice were sacrificed by decapitation without anesthesia and trunk blood was collected in pre-chilled tubes that contained 1 mg/mL EDTA. Plasma glucose was assayed using the glucose oxidase-peroxidase method, and plasma insulin was measured using a radioimmunoassay kit (Linco Research, St. Charles, MO, USA). All experimental procedures were approved by the Institutional Animal Care and Use Committee at Chonbuk National University, Jeonbuk, Korea.

3-(4,5-dimethylthiazol-2-yl)-2,5-diphenyltetrazolium bromide assay for cell viability

The viability of cultured cells was determined by the reduction of 3-(4,5-dimethylthiazol-2-yl)-2,5-diphenyltetrazolium bromide (MTT) to formazan. RINm5F cells were seeded overnight in clear, flat-bottomed 96-well tissue culture plates at 10^5 cells/well in 100 μL medium. Cells were pretreated with NJE as indicated for 3 h, then IL-1β (1 U/mL) and IFN-γ (100 U/mL) were added for an additional 48 h. Cells were washed twice with PBS, and MTT was added (100 μg/100 μL PBS). After incubation at 37℃ for 1 h, 100 μL DMSO was added to dissolve the formazan crystals, and absorbance was measured at

570 nm using a Spectra MAX PLUS spectrophotometer (Molecular Devices, Sunnyvale, CA, USA).

NO measurement

Biologically produced NO is rapidly oxidized to nitrite and nitrate in aqueous solutions. NO production was measured as nitrite concentration in cell-free culture supernatants using a colorimetric assay. Briefly, 5×10^5 RINm5F cells or 30 islet samples were pretreated with the indicated concentrations of NJE for 3 h prior to the addition of IL-1β (1 U/mL) and IFN-γ (100 U/mL). After 24 h, 100 μL aliquots of culture supernatant were incubated with 100 μL of a modified Griess reagent of a 1:1 mixture of 1% sulfanilamide in 30% acetic acid and 0.1% N-(1-naphthyl) ethylenediamine dihydrochloride in 60% acetic acid, at room temperature for 5 min, and the absorbance was measured at 540 nm using a spectrophotometer (Ultrospec 2100 pro; Amersham Biosciences). NO concentration was determined from a linear standard curve of serial dilutions of sodium nitrite in a working medium.

Whole cell and nuclear protein extracts

Cells, islets, or pancreatic tissues were washed with PBS and lysed in CytoBuster protein extraction buffer (Novagen, Madison, WI, USA). Lysate was centrifuged at 10 000 × *g* for 5 min at 4℃, and the supernatant was used as whole cell protein extract. Cytosolic and nuclear extracts were prepared from cells using NE-PER Nuclear and Cytoplasmic Extraction Reagent (Pierce Biotechnology, Rockford, IL, USA).

Western blotting analysis

RINm5F cells (5×10^6) or 30 islet samples were homogenized in 100 μL ice-cold lysis buffer (20 mmol/L HEPES, pH 7.2, 1% Triton X-100, 10% glycerol, 1 mmol/L PMSF, 10 μg/mL leupeptin, 10 μg/mL aprotinin) and 20 μg protein separated by SDS-PAGE and transferred to nitrocellulose membranes. Blots were probed with 1 μg/mL primary antibody against p50, p65, iNOS, actin, or PCNA (Santa Cruz Biotechnology, Santa Cruz, CA, USA) and detected with horseradish peroxidase-conjugated IgG (Zymed, South San Francisco, CA, USA).

Electrophoretic mobility shift assay

NF-κB activation was assayed using a gel mobility shift assay with nuclear extracts from control and treated cells. An oligonucleotide that contained the κ-chain binding site (κB, 5'-CCGGTTAACAGAGGGGGCTTTCCGAG-3') was used as a probe. The two complementary strands were annealed and labeled with [α-^{32}P]dCTP. Binding reactions that contained labeled oligonucleotide (10 000 cpm), 10 μg nuclear extract protein, and binding buffer (10 mmol/L Tris-HCl, pH 7.6, 500 mmol/L KCl, 10 mmol/L EDTA, 50% glycerol, 100 ng poly (dI·dC), 1 mmol/L dithiothreitol) in a final volume of 20 μL were incubated for 30 min at room temperature. Reactions were separated on 4% polyacrylamide gels in 0.5 × Tris-borate buffer, and the gels were dried and visualized by autoradiography. Specificity of the DNA/NF-κB interaction was demonstrated by competitive assays with 50-fold excess unlabeled oligonucleotide.

RNA isolation and real-time RT-PCR

RNA was isolated from RINm5F cells or islets using Trizol reagent (Invitrogen, Carlsbad, CA, USA). RNA was precipitated with isopropanol and dissolved in DEPC-treated distilled water. Total RNA (2 μg) was treated with RNase-free DNase (Invitrogen), and first-strand cDNA was generated using random hexamer primer in a first-strand cDNA synthesis kit (Applied Biosystems, Foster City, CA, USA). Specific primers for iNOS were designed using primer express software (Applied Biosystems): iNOS (accession No. NM_012611), 5'-TGTGCTAATGCGGAAGGTCAT-3' (forward), and 5'-CGACTTTCCTGTCTCAGTAGCAAA-3' (reverse). Control 18S rRNA was purchased from Applied Biosystems and was used as the invariant control. Real-time RT-PCR mixtures consisted of 10 ng reverse transcribed total RNA, 167 nmol/L forward and reverse primers, and 2 × PCR Master Mix in a final volume of 10 μL. Reactions were carried out in 384-well plates using the ABI Prism 7900HT Sequence Detection System (Applied Biosystems). All experiments were performed in triplicate.

Glucose-stimulated insulin secretion assay

Pancreatic islets were isolated from 250-300 g male Sprague-Dawley rats, using the collagenase digestion method[23]. Islets were cultured for 24 h with IL-1β and IFN-γ in the presence or absence of NJE, then washed three times in Krebs-Ringer bicarbonate buffer (25 mmol/L HEPES, 115 mmol/L NaCl, 24 mmol/L $NaHCO_3$, 5 mmol/L KCl, 1 mmol/L $MgCl_2$, 2.5 mmol/L $CaCl_2$, 0.1% bovine serum albumin, pH 7.4), which contained 3 mmol/L D-glucose. Insulin secretion assays were performed with either 5.5 or 20 mmol/L D-glucose. All experiments were performed in triplicate.

Immunohistochemistry

Immunohistochemical staining was performed with the DAKO Envision system (DAKO, Carpinteria, CA, USA), which used dextran polymers conjugated with horseradish peroxidase to avoid contamination with endogenous biotin. Pancreases were removed and immediately placed in fixative (10% formalin solution in 0.1 mol/L PBS). Histological sections of 4 μm were cut from formalin-fixed, paraffin-embedded tissue blocks. After deparaffinization, tissue sections were treated using a microwave antigen retrieval procedure in 0.01 mol/L sodium citrate buffer. After blocking endogenous peroxidase, the sections were incubated with Protein Block Serum-Free (DAKO) to block nonspecific staining, then with anti-insulin antibody (Santa Cruz Biotechnology). Peroxidase activity was detected with 3-amino-9-ethylcarbazole.

Statistical analysis

Statistical analyses were performed using ANOVA and

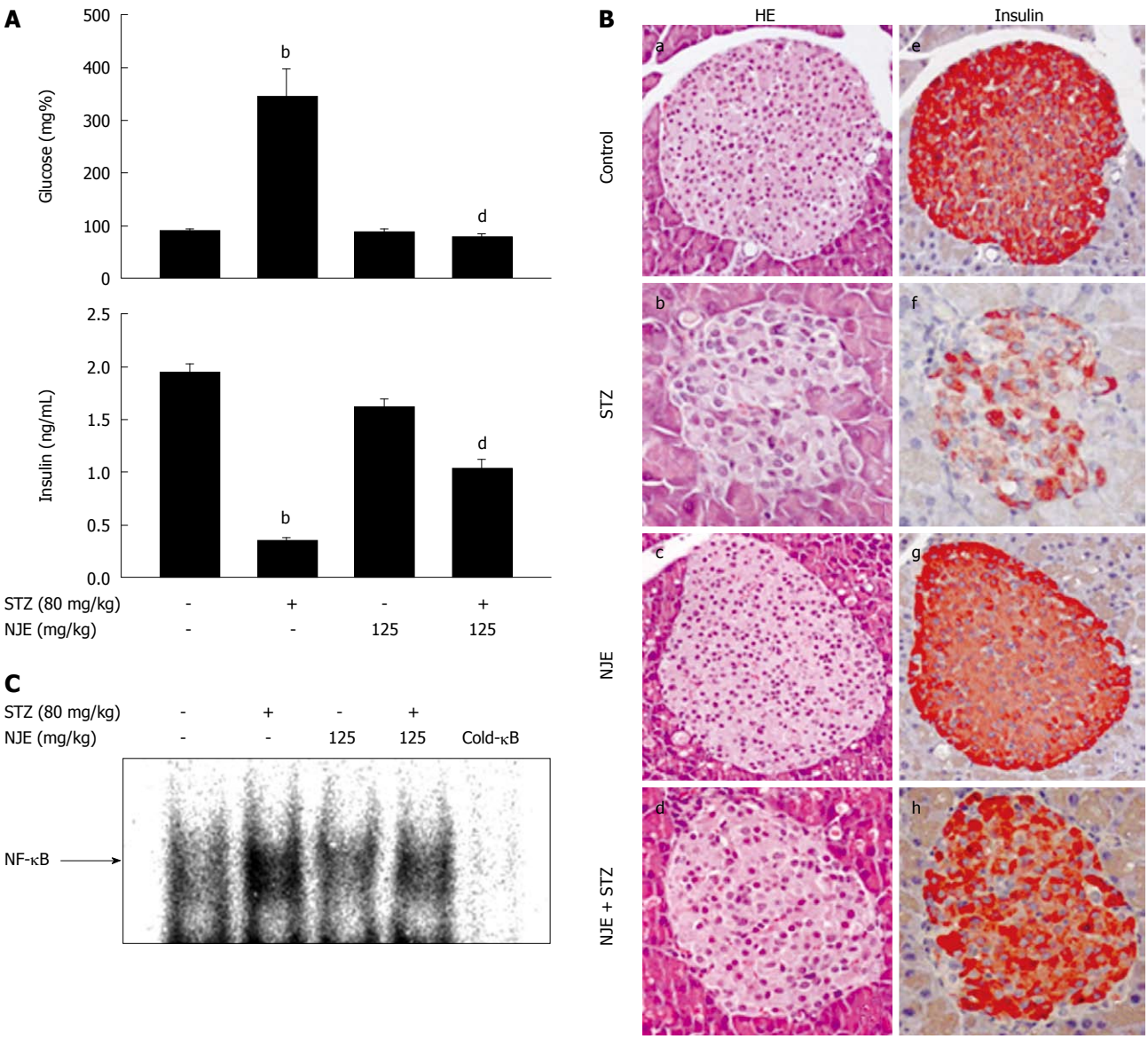

Figure 1 NJE protects islets from STZ-induced destruction. A: ICR mice were intraperitoneally injected daily with NJE at 125 mg/kg for 3 d and then injected with STZ (80 mg/kg) intravenously. Levels of fasting glucose and insulin were determined; B: Pancreases were obtained from normal controls (a, e), and STZ-injected (b, f), NJE-injected (c, g), and NJE and STZ-injected mice (d, h). Islets and adjoining exocrine regions were counterstained with HE (a-d). Islets were labeled with insulin antibody and peroxidase-labeled anti-rabbit IgG (e-h); C: Nuclear extracts from pancreatic tissues were prepared 30 min after STZ injection, and NF-κB DNA binding was analyzed using electrophoretic mobility shift assay. $^{b}P < 0.01$ *vs* untreated control; $^{d}P < 0.01$ *vs* STZ-injected group. NJE: *Nardostachys jatamansi* extract; STZ: Streptozotocin; NF-κB: Nuclear factor κB.

Duncan's tests. Differences with $P < 0.05$ were considered statistically significant.

RESULTS

Anti-diabetic effect of NJE in mice

Mice injected with STZ gradually became hyperglycemic, with an increased incidence of diabetes observed starting at day 3. At day 5, the average blood glucose level of mice injected with STZ was 344 ± 52.8 mg/dL. Mice that were pretreated with NJE were fully resistant to diabetes development (Figure 1A), and treatment with NJE alone did not affect blood glucose concentration. In addition, the mean plasma insulin level at day 5 in the STZ group decreased by 84.2% compared with the control (from 1.9 ± 0.1 to 0.3 ± 0.1 ng/mL), while the severity of hypoinsulinemia was attenuated in mice pretreated with NJE (Figure 1A). These results indicate that NJE is protective against STZ-induced diabetes.

The preventative effect of NJE on STZ-induced diabetes was histologically examined. Pancreatic tissues at 5 d after STZ administration, with or without NJE pretreatment, were subjected to hematoxylin and eosin (HE) staining and immunohistochemistry. STZ-treated mice showed degenerative and necrotic changes and islet shrinkage (Figure 1B, b), as well as weak insulin-reactivity in a few β-cells (Figure 1B, f). However, tissues from STZ-treated mice pretreated with NJE showed round, nearly normal, and clearly defined islets that were strongly positive for insulin (Figure 1B, d and h).

To elucidate the antidiabetogenic mechanism of NJE, we examined its effect on STZ-induced NF-κB activation. Figure 1C is a representative electrophoretic mobility shift assay (EMSA) that shows the ^{32}P-DNA/NF-κB complex formed with nuclear extracts from the pancreas 30 min after STZ administration. The findings were similar to those of our previous study, with STZ treatment resulting in increased NF-κB binding to DNA[10]. This complex was not detected in pancreatic nuclear extracts from NJE-pretreated mice. Taken together, these results show that NJE inhibits NF-κB activation and prevents type 1 diabetes development in mice.

NJE prevented cytokine-mediated cell death in RINm5F cells

We investigated the antidiabetogenic effect of NJE at the cellular level. Untreated RINm5F cells or cells pretreated with NJE for 3 h were exposed to cytokine for 48 h, and viability was assessed using an MTT assay. Treatment with cytokine significantly reduced cell viability to 39.8% ± 0.6% of the controls (Figure 2A). Conversely, NJE increased the viability of cytokine-treated RINm5F cells in a concentration-dependent manner. Treatment with NJE alone did not affect cell viability at the concentrations used in this study (data not shown).

NO production was also evaluated. In 24 h, control RINm5F cells generated 9.8 ± 0.5 μmol/L nitrite, while cytokine-treated cells generated 34.2 ± 2.7 μmol/L (Figure 2B). A concentration-dependent reduction in cytokine-mediated nitrite production was observed in RINm5F cells treated with cytokine plus NJE. Near complete inhibition of nitrite production was observed in cells that were pretreated with 100 μg/mL NJE.

To investigate the regulatory effects of NJE on NO production, we examined the effects of NJE on cytokine-induced iNOS mRNA and protein expression, using real-time RT-PCR and Western blotting. Cytokine increased iNOS mRNA and protein levels (Figure 2C). However, when cells were treated with NJE prior to cytokine treatment, mRNA and protein levels decreased in a concentration-dependent manner. Treatment with 100 μg/mL NJE completely blocked iNOS expression.

NF-κB was implicated in STZ toxicity (Figure 1C). Therefore, the effect of NJE on the cytokine-stimulated translocation of NF-κB from the cytosol to the nucleus in RINm5F cells was examined. Nuclear extracts from cytokine-stimulated RINm5F cells showed increased NF-κB binding activity (Figure 3A, lane 2), as well as increased nuclear levels of p65 and p50 subunits (Figure 3B), compared to those of unstimulated cells. In contrast, cytokine-induced NF-κB activation was markedly suppressed by NJE pretreatment, which suggested that NJE inhibited iNOS expression by suppressing NF-κB activation. We previously have reported that IκBα, but not IκBβ, is the major participant in cytokine-induced NF-κB activation[23]. Therefore, we investigated IκBα levels in the cytosol following cytokine treatment (Figure 3B). Cytokine-treated RINm5F cells showed a decreased level of IκBα protein in the cytosol compared to a similar fraction from unstimulated cells; however, increased IκBα degradation as a result of cytokine treatment was markedly suppressed by pretreatment with NJE.

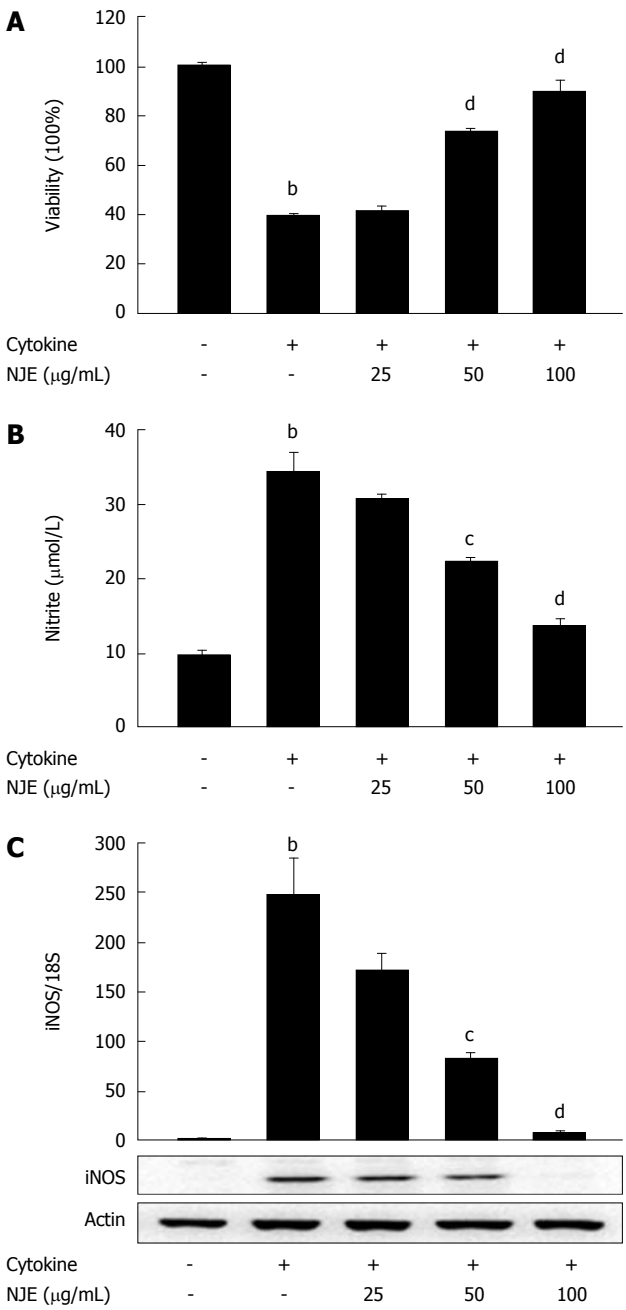

Figure 2 NJE prevents cytokine-induced cell death in RINm5F cells. A: RINm5F cells were pretreated with NJE for 3 h, and IL-1β (1 U/mL) and IFN-γ (100 U/mL) were added for 48 h. Cell viability was determined using an 3-(4,5-dimethylthiazol-2-yl)-2,5-diphenyltetrazolium bromide assay; B and C: RINm5F cells were pretreated with NJE for 3 h, and IL-1β and IFN-γ were added. Following 24 h of incubation, the level of nitrite production and iNOS mRNA and protein expression were determined. Each value is the mean ± SE of three independent experiments. $^{b}P < 0.01$ *vs* untreated controls; $^{c}P < 0.05$, $^{d}P < 0.01$ *vs* cytokine. IL-1β: Interleukin 1β; IFN-γ: Interferon γ.

NJE suppressed the cytokine-induced NF-κB pathway and preserved glucose-stimulated insulin secretion in rat islets

We further assayed the preventive effects of NJE using rat

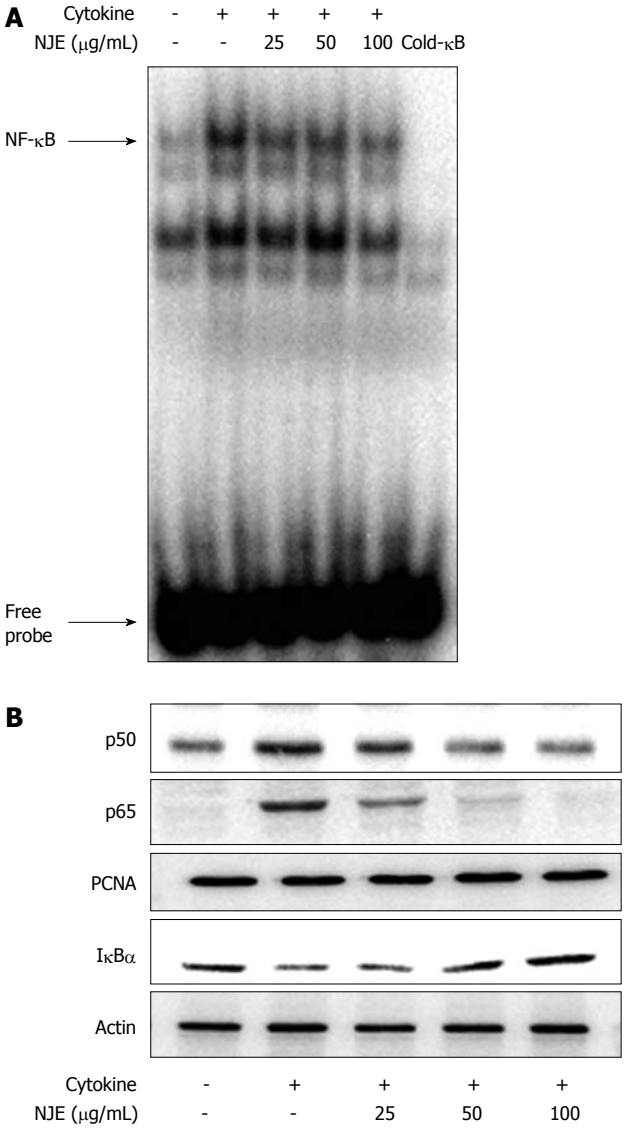

Figure 3 NJE inhibits cytokine-induced NF-κB activation in RINm5F cells. RINm5F cells were pretreated with NJE for 3 h, and IL-1β (1 U/mL) and IFN-γ (100 U/mL) were added. After 30 min, NF-κB DNA binding was analyzed by EMSA (A), and translocation of p65 and p50 to the nucleus and IκBα degradation in the cytosol (B) were determined by Western blotting. β-actin and PCNA were used as loading controls for cytosolic and nuclear proteins, respectively.

pancreatic islets isolated from male Sprague-Dawley rats. Incubation of rat islets with cytokine for 24 h resulted in a 2.8-fold increase in NO production (Figure 4A). Real time RT-PCR and Western blotting revealed that iNOS mRNA and protein levels were markedly increased by cytokines (Figure 4A). Consistent with results from RINm5F cells, pretreatment of islets with NJE abolished the cytokine effects and reduced NO production and iNOS expression to the level of those of control islets. Additionally, treatment with cytokine increased NF-κB DNA binding activity in islets (Figure 4B), and pretreatment of islets with NJE completely abolished these effects. To add functional data, NJE protection against cytokine-induced impairment of glucose-stimulated insulin secretion (GSIS) was evaluated. After 24 h of cytokine exposure, insulin secretion was assayed in response to 20 mmol/L glucose. Control islets secreted 3.4 ± 0.4 ng/mL insulin, while cytokine-treated islets secreted significantly less, at 1.2 ± 0.2 ng/mL ($P < 0.01$) (Figure 4C). However, pretreatment with NJE blocked the cytokine effect and maintained islet cell insulin secretion to levels similar to those of the controls. In addition, treatment with NJE alone did not affect insulin secretion in response to glucose (data not shown).

DISCUSSION

In this study, we present a mode of action for NJE protection against development of type 1 diabetes. Intraperitoneal administration of NJE prevented diabetes development after STZ and preserved β-cell mass. In addition, NJE protected β-cells from cytokine toxic challenge in RINm5F cells and islets.

We demonstrated that NJE prevented STZ-induced diabetes in mice. STZ destroys islet cells through several mechanisms, including the production of reactive oxygen species (ROS)[24], activation of pancreatic NF-κB[25], and induction of pronounced immune and inflammatory responses[26]. STZ-treated mice showed marked islet destruction and relatively small numbers of insulin-positive β-cells, while NJE pre-treated mice showed well-defined islets and strong insulin staining. An EMSA revealed increased NF-κB binding activity in pancreatic nuclear extracts derived from STZ-treated hyperglycemic diabetic mice. However, pretreatment with NJE prevented NF-κB activation, which resulted in the maintenance of plasma glucose and insulin levels in the normal range. NF-κB participates in the transcriptional regulation of pro-inflammatory genes, and their activation results in the production of pro-inflammatory mediators[27,28]. Therefore, NF-κB might be a key regulator in local cytokine response pathways in STZ-mediated β-cell destruction. Alternatively, the NJE anti-diabetic effect could be related to its anti-oxidative properties. Several studies have confirmed that NJE is an ROS scavenger[20,21], and that ROS induces NF-κB activation[29,30], which suggests that ROS scavenging by NJE suppresses STZ-induced NF-κB activation. Taken together, these results suggest that manipulation of NF-κB activity by NJE in pancreatic β-cells allows these cells to withstand and survive STZ-mediated immune attack.

NJE not only protected against STZ-induced diabetes, but also protected RINm5F cells and rat islets against cytokine toxicity. IL-1β has been implicated in early events in β-cell destruction. Suppression of IL-1β production or inhibition of its interaction with corresponding cellular receptors significantly inhibits IL-1β-mediated deleterious effects on β-cells[31,32]. IL-1β exerts its main effects through the NF-κB pathway[33-35]. IFN-γ alone does not stimulate iNOS expression in rodent or human islets, but it reduces the concentration of IL-1β required to induce iNOS expression in rat islets, and a combination of IL-1β and IFN-γ is required to induce iNOS expression and β-cell dysfunction in mouse and human islets[36]. In addition to cytokines, different intracellular pathways that lead to β-cell death (e.g. oxidative stress, chemical generation

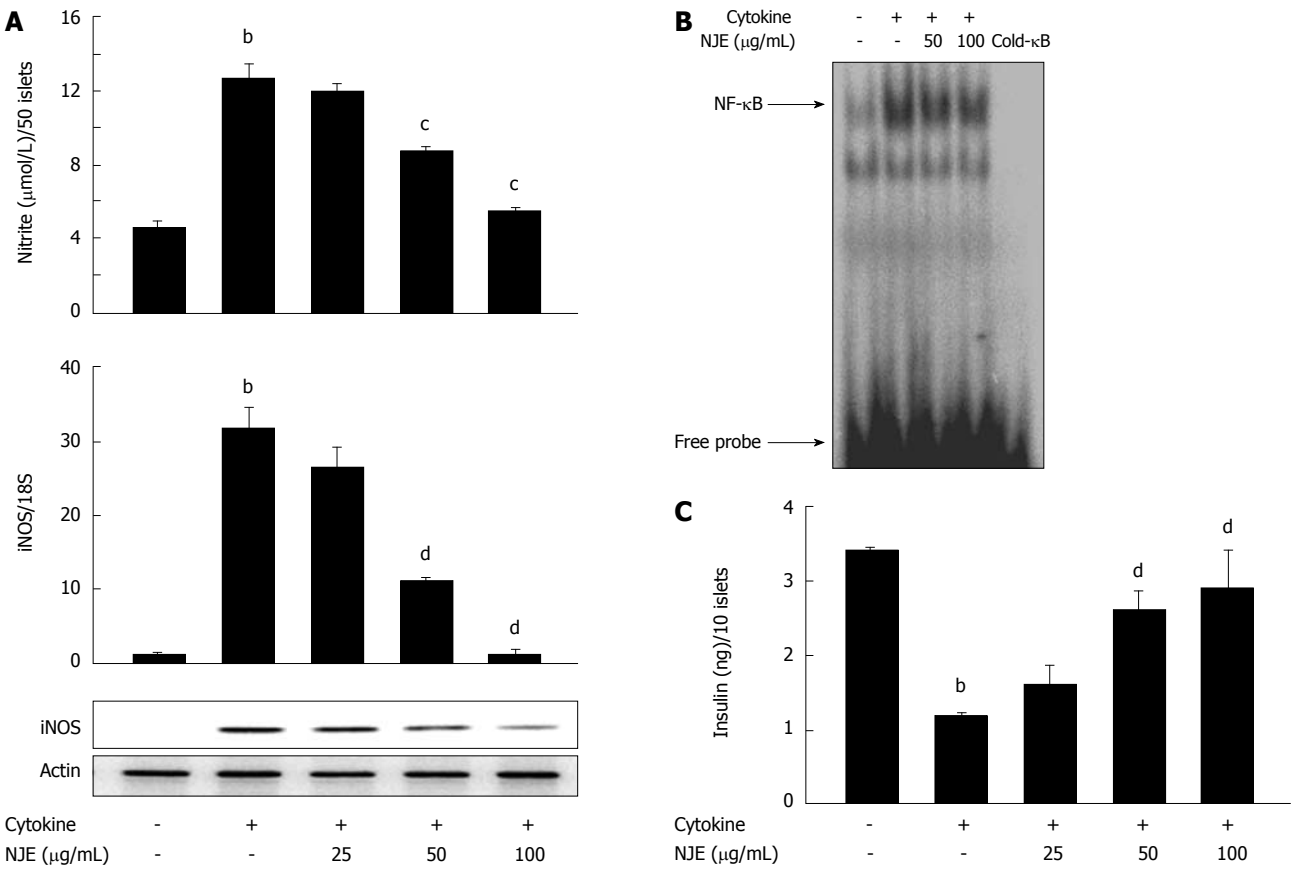

Figure 4 NJE inhibits cytokine-induced activation of NF-κB and maintains glucose-stimulated insulin secretion in rat islets. Rat islets were treated with IL-1β (1 U/mL) and IFN-γ (100 U/mL) with or without 3 h pretreatment with NJE. Nitrite production and iNOS mRNA and protein expression (A) were determined after 24 h, and NF-κB DNA binding (B) was determined 1 h later; C: Rat islets (10 islets/500 μL) were treated with IL-1β (1 U/mL) and IFN-γ (100 U/mL) with or without 3 h pretreatment with NJE. Following 24 h incubation, glucose-stimulated insulin secretion was quantified. The results of triplicate samples are expressed as the mean ± SE. $^{b}P < 0.01$ *vs* untreated controls; $^{c}P < 0.05$, $^{d}P < 0.01$ *vs* cytokine.

of NO, mitogen-activated protein kinase activation, JAK-STAT activation, and endoplasmic reticulum stress) partially converge at NF-κB[12,14,37,38]. Hypothetically, this gives us, employing only one approach, the ability to block NF-κB signaling, to save β-cell mass and thereby prevent diabetes development. In this model, NJE completely inhibits NO production in IL-1β- and IFN-γ-stimulated RINm5F cells and islets, through suppression of NF-κB-dependent iNOS expression, thereby protecting RINm5F cells and islets from IL-1β and IFN-γ cytotoxicity. In addition to increased cell viability, we observed the preservation of insulin secretion in NJE pretreated rat islets. The molecular mechanism by which NJE inhibits NF-κB activation by IL-1β and IFN-γ appears to involve both inhibition of IκBα degradation and translocation of p65 and p50 into the nucleus.

Flavonoids comprise the most common group of plant polyphenols and provide much of the flavor and color to fruits and vegetables. Several flavonoids have been shown to inhibit the expression of NF-κB-dependent cytokines, iNOS, and *cyclooxygenase-2* genes[39]. Therefore, it would be interesting to analyze flavonoid composition in NJE extracts.

In summary, this study is believed to be the first to demonstrate that NJE has a β-cell protective effect. Specifically, NJE protected β-cells from cytokine-induced injury *in vitro* and counteracted the development of type 1 diabetes in response to STZ *in vivo*. This β-cell protective effect might be mediated, at least in part, by suppressing NF-κB activation. NJE did not cause serious side effects in mice, therefore, it could be a therapeutic alternative for rescuing β-cells in cases of ongoing β-cell destruction.

COMMENTS

Background

Type 1 diabetes mellitus is an autoimmune disease that causes selective destruction of insulin-producing β-cells in the islets of Langerhans. Once those cells are destroyed, they do not ever produce insulin again. Type 1 diabetes affects younger individuals and requires lifelong insulin treatment. Without treatment, the blood glucose rises to levels which can cause hyperglycemia. Type 1 diabetes cannot be prevented. There is no practical way to predict who will develop the disease because most people who develop it are otherwise healthy. Therefore, the best way to control type 1 diabetes is understanding the disease better and finding a therapeutic regimen to preserve functional β-cell damage.

Research frontiers

Cytokines such as interleukin (IL)-1β and interferon (IFN)-γ, which are released during islet inflammation, are believed to participate in β-cell damage during the development of autoimmune type 1 diabetes. Evidence has suggested that activation of nuclear factor (NF)-κB in response to cytokines is an important component of the signal that triggers β-cell death. For this reason, NF-κB has been targeted for preventing type 1 diabetes development.

Innovations and breakthroughs

Nardostachys jatamansi is used in Ayurvedic medicine to treat mental disorders, hyperlipidemia, hypertension, and convulsions. *N. jatamansi* has been suggested to protect cells and tissues through its antioxidative properties. However, no studies to date have reported the antidiabetic effects of *N. jatamansi*. In this study, the authors observed that *N. jatamansi* extract (NJE) had antidiabetic effects in *in vitro* and *in vivo* models of diabetes.

Applications

NJE did not cause serious side effects *in vivo*, therefore, it might be a therapeutic alternative for rescuing β-cells in cases of ongoing β-cell destruction. NJE-treated islets can also be used to increase islet survival in an allograft transplantation model.

Terminology

IL-1β and IFN-γ are cytokines that are secreted from infiltrated inflammatory cells into the pancreatic islets. Streptozotocin is a diabetogenic drug and particularly toxic to pancreatic β-cells.

Peer review

The article is written well, however, there are many major queries which have to be answered by the authors. Authors have to report on the phytochemical constituents of the extract (at least qualitative analysis).

REFERENCES

1 **Papaccio G**. Insulitis and islet microvasculature in type 1 diabetes. *Histol Histopathol* 1993; **8**: 751-759

2 **Cnop M**, Welsh N, Jonas JC, Jörns A, Lenzen S, Eizirik DL. Mechanisms of pancreatic beta-cell death in type 1 and type 2 diabetes: many differences, few similarities. *Diabetes* 2005; **54** Suppl 2: S97-S107

3 **Eizirik DL**, Colli ML, Ortis F. The role of inflammation in insulitis and beta-cell loss in type 1 diabetes. *Nat Rev Endocrinol* 2009; **5**: 219-226

4 **Corbett JA**, McDaniel ML. Does nitric oxide mediate autoimmune destruction of beta-cells? Possible therapeutic interventions in IDDM. *Diabetes* 1992; **41**: 897-903

5 **Stadler J**, Billiar TR, Curran RD, Stuehr DJ, Ochoa JB, Simmons RL. Effect of exogenous and endogenous nitric oxide on mitochondrial respiration of rat hepatocytes. *Am J Physiol* 1991; **260**: C910-C916

6 **Szkudelski T**. The mechanism of alloxan and streptozotocin action in B cells of the rat pancreas. *Physiol Res* 2001; **50**: 537-546

7 **Kwon NS**, Lee SH, Choi CS, Kho T, Lee HS. Nitric oxide generation from streptozotocin. *FASEB J* 1994; **8**: 529-533

8 **Yamamoto H**, Uchigata Y, Okamoto H. Streptozotocin and alloxan induce DNA strand breaks and poly(ADP-ribose) synthetase in pancreatic islets. *Nature* 1981; **294**: 284-286

9 **Heimberg H**, Heremans Y, Jobin C, Leemans R, Cardozo AK, Darville M, Eizirik DL. Inhibition of cytokine-induced NF-kappaB activation by adenovirus-mediated expression of a NF-kappaB super-repressor prevents beta-cell apoptosis. *Diabetes* 2001; **50**: 2219-2224

10 **Kwon KB**, Kim EK, Jeong ES, Lee YH, Lee YR, Park JW, Ryu DG, Park BH. Cortex cinnamomi extract prevents streptozotocin- and cytokine-induced beta-cell damage by inhibiting NF-kappaB. *World J Gastroenterol* 2006; **12**: 4331-4337

11 **Melloul D**. Role of NF-kappaB in beta-cell death. *Biochem Soc Trans* 2008; **36**: 334-339

12 **Kim EK**, Kwon KB, Song MY, Seo SW, Park SJ, Ka SO, Na L, Kim KA, Ryu DG, So HS, Park R, Park JW, Park BH. Genistein protects pancreatic beta cells against cytokine-mediated toxicity. *Mol Cell Endocrinol* 2007; **278**: 18-28

13 **Lv N**, Song MY, Kim EK, Park JW, Kwon KB, Park BH. Guggulsterone, a plant sterol, inhibits NF-kappaB activation and protects pancreatic beta cells from cytokine toxicity. *Mol Cell Endocrinol* 2008; **289**: 49-59

14 **Song MY**, Kim EK, Moon WS, Park JW, Kim HJ, So HS, Park R, Kwon KB, Park BH. Sulforaphane protects against cytokine- and streptozotocin-induced beta-cell damage by suppressing the NF-kappaB pathway. *Toxicol Appl Pharmacol* 2009; **235**: 57-67

15 **Mabley JG**, Haskó G, Liaudet L, Soriano F, Southan GJ, Salzman AL, Szabó C. NFkappaB1 (p50)-deficient mice are not susceptible to multiple low-dose streptozotocin-induced diabetes. *J Endocrinol* 2002; **173**: 457-464

16 **Dixit VP**, Jain P, Joshi SC. Hypolipidaemic effects of Curcuma longa L and Nardostachys jatamansi, DC in triton-induced hyperlipidaemic rats. *Indian J Physiol Pharmacol* 1988; **32**: 299-304

17 **Joshi H**, Parle M. Nardostachys jatamansi improves learning and memory in mice. *J Med Food* 2006; **9**: 113-118

18 **Rao VS**, Rao A, Karanth KS. Anticonvulsant and neurotoxicity profile of Nardostachys jatamansi in rats. *J Ethnopharmacol* 2005; **102**: 351-356

19 **Bagchi A**, Oshima Y, Hikino H. Neolignans and Lignans of Nardostachys jatamansi Roots1. *Planta Med* 1991; **57**: 96-97

20 **Lyle N**, Bhattacharyya D, Sur TK, Munshi S, Paul S, Chatterjee S, Gomes A. Stress modulating antioxidant effect of Nardostachys jatamansi. *Indian J Biochem Biophys* 2009; **46**: 93-98

21 **Lyle N**, Gomes A, Sur T, Munshi S, Paul S, Chatterjee S, Bhattacharyya D. The role of antioxidant properties of Nardostachys jatamansi in alleviation of the symptoms of the chronic fatigue syndrome. *Behav Brain Res* 2009; **202**: 285-290

22 **Bae GS**, Park HJ, Kim DY, Song JM, Kim TH, Oh HJ, Yun KJ, Park RK, Lee JH, Shin BC, Sim HJ, Hong SP, Song HJ, Park SJ. Nardostachys jatamansi protects against cerulein-induced acute pancreatitis. *Pancreas* 2010; **39**: 520-529

23 **Kim EK**, Kwon KB, Koo BS, Han MJ, Song MY, Song EK, Han MK, Park JW, Ryu DG, Park BH. Activation of peroxisome proliferator-activated receptor-gamma protects pancreatic beta-cells from cytokine-induced cytotoxicity via NF kappaB pathway. *Int J Biochem Cell Biol* 2007; **39**: 1260-1275

24 **Takasu N**, Komiya I, Asawa T, Nagasawa Y, Yamada T. Streptozocin- and alloxan-induced H2O2 generation and DNA fragmentation in pancreatic islets. H2O2 as mediator for DNA fragmentation. *Diabetes* 1991; **40**: 1141-1145

25 **Eldor R**, Yeffet A, Baum K, Doviner V, Amar D, Ben-Neriah Y, Christofori G, Peled A, Carel JC, Boitard C, Klein T, Serup P, Eizirik DL, Melloul D. Conditional and specific NF-kappaB blockade protects pancreatic beta cells from diabetogenic agents. *Proc Natl Acad Sci USA* 2006; **103**: 5072-5077

26 **Iwakiri R**, Nagafuchi S, Kounoue E, Nakamura M, Kikuchi M, Nakano S, Niho Y. Immunohistochemical study of insulitis induced by multiple low doses of streptozocin in CD-1 mice. *Diabetes Res Clin Pract* 1990; **9**: 75-82

27 **Blackwell TS**, Christman JW. The role of nuclear factor-kappa B in cytokine gene regulation. *Am J Respir Cell Mol Biol* 1997; **17**: 3-9

28 **Richmond A**. Nf-kappa B, chemokine gene transcription and tumour growth. *Nat Rev Immunol* 2002; **2**: 664-674

29 **Adcock IM**, Brown CR, Kwon O, Barnes PJ. Oxidative stress induces NF kappa B DNA binding and inducible NOS mRNA in human epithelial cells. *Biochem Biophys Res Commun* 1994; **199**: 1518-1524

30 **Schmidt KN**, Amstad P, Cerutti P, Baeuerle PA. The roles of hydrogen peroxide and superoxide as messengers in the activation of transcription factor NF-kappa B. *Chem Biol* 1995; **2**: 13-22

31 **Giannoukakis N**, Rudert WA, Ghivizzani SC, Gambotto A, Ricordi C, Trucco M, Robbins PD. Adenoviral gene transfer of the interleukin-1 receptor antagonist protein to human islets prevents IL-1beta-induced beta-cell impairment and activation of islet cell apoptosis in vitro. *Diabetes* 1999; **48**: 1730-1736

32 **Téllez N**, Montolio M, Biarnés M, Castaño E, Soler J, Montanya E. Adenoviral overexpression of interleukin-1 receptor antagonist protein increases beta-cell replication in rat pan-

creatic islets. *Gene Ther* 2005; **12**: 120-128
33 **Arnush M**, Heitmeier MR, Scarim AL, Marino MH, Manning PT, Corbett JA. IL-1 produced and released endogenously within human islets inhibits beta cell function. *J Clin Invest* 1998; **102**: 516-526
34 **Corbett JA**, McDaniel ML. Intraislet release of interleukin 1 inhibits beta cell function by inducing beta cell expression of inducible nitric oxide synthase. *J Exp Med* 1995; **181**: 559-568
35 **Lee JH**, Song MY, Song EK, Kim EK, Moon WS, Han MK, Park JW, Kwon KB, Park BH. Overexpression of SIRT1 protects pancreatic beta-cells against cytokine toxicity by suppressing the nuclear factor-kappaB signaling pathway. *Diabetes* 2009; **58**: 344-351
36 **Heitmeier MR**, Scarim AL, Corbett JA. Interferon-gamma increases the sensitivity of islets of Langerhans for inducible nitric-oxide synthase expression induced by interleukin 1. *J Biol Chem* 1997; **272**: 13697-13704
37 **Kharroubi I**, Ladrière L, Cardozo AK, Dogusan Z, Cnop M, Eizirik DL. Free fatty acids and cytokines induce pancreatic beta-cell apoptosis by different mechanisms: role of nuclear factor-kappaB and endoplasmic reticulum stress. *Endocrinology* 2004; **145**: 5087-5096
38 **Lv N**, Kim EK, Song MY, Choi HN, Moon WS, Park SJ, Park JW, Kwon KB, Park BH. JANEX-1, a JAK3 inhibitor, protects pancreatic islets from cytokine toxicity through downregulation of NF-kappaB activation and the JAK/STAT pathway. *Exp Cell Res* 2009; **315**: 2064-2071
39 **Bremner P**, Heinrich M. Natural products as targeted modulators of the nuclear factor-kappaB pathway. *J Pharm Pharmacol* 2002; **54**: 453-472

S- Editor Wang YR **L- Editor** Kerr C **E- Editor** Ma WH

World Journal of Gastroenterology

Online Submissions: http://www.wjgnet.com/1007-9327office
wjg@wjgnet.com
doi:10.3748/wjg.v16.i26.3258

World J Gastroenterol 2010 July 14; 16(26): 3258-3266
ISSN 1007-9327 (print)
© 2010 Baishideng. All rights reserved.

ORIGINAL ARTICLE

CD74 is a survival receptor on colon epithelial cells

Nitsan Maharshak, Sivan Cohen, Frida Lantner, Gili Hart, Lin Leng, Richard Bucala, Idit Shachar

Nitsan Maharshak, Sivan Cohen, Frida Lantner, Gili Hart, Idit Shachar, Department of Immunology, Weizmann Institute of Science, Rehovot 76100, Israel
Nitsan Maharshak, Department of Gastroenterology and Liver Diseases, Tel Aviv Sourasky Medical Center, Affiliated to the Sackler Faculty of Medicine, Tel Aviv University, Tel Aviv 69978, Israel
Lin Leng, Richard Bucala, Department of Medicine, Yale University School of Medicine, New Haven, CT 06520, United States
Author contributions: Maharshak N and Cohen S contributed equally to this article; Maharshak N, Cohen S, Lantner F, Hart G and Shachar I designed the research; Maharshak N, Cohen S, Lantner F and Hart G performed the research; Maharshak N, Cohen S and Shachar I analyzed the data; Leng L and Bucala R contributed essential reagents; Maharshak N, Cohen S, Bucala R and Shachar I wrote the paper.
Supported by The Israel Science Foundation (Morasha), the Minerva foundation, the Israel Cancer Association, and the Moross institute
Correspondence to: Idit Shachar, PhD, Department of Immunology, Weizmann Institute of Science, Rehovot 76100, Israel. idit.shachar@weizmann.ac.il
Telephone: +972-8-9344257 Fax: +972-8-9344141
Received: November 10, 2009 Revised: January 24, 2010
Accepted: January 31, 2010
Published online: July 14, 2010

Abstract

AIM: To investigate the expression and function of CD74 in normal murine colon epithelial cells (CEC) and colon carcinoma cells.

METHODS: Expression of CD74 mRNA and protein were measured by reverse transcriptase-polymerase chain reaction (RT-PCR), Western blotting and fluorescence-activated cell sorter (FACS). The effect of migration inhibitory factor (MIF) on the survival of normal CEC from C57BL/6, NOD/SCID, and CD74 deficient mice both *in vitro* and *in vivo*, and on the CT26 carcinoma cell line was analyzed by (quantitative) qRT-PCR, RT-PCR, Western blotting and FACS.

RESULTS: CD74 was found to be expressed on normal CEC. Stimulation of CD74 by MIF induced a signaling cascade leading to up-regulation of Bcl-2 expression, resulting in a significant increased survival of CEC. CD74 was also expressed on the CT26 colon carcinoma cell line and its stimulation by MIF resulted in enhanced cell survival, up-regulation of Akt phosphorylation and Bcl-2 expression.

CONCLUSION: CD74 is expressed on CEC and colon carcinoma cells and serves as a survival receptor in these cells. These results may have implications on colorectal cancer research.

© 2010 Baishideng. All rights reserved.

Key words: CD74; Migration inhibitory factor; Colon epithelial cells

Peer reviewer: Shanthi V Sitaraman, MD, Division of Digestive Diseases, Room 201-F, 615, Michael Street, Whitehead Research Building, Emory University, Atlanta, Georgia, GA 30322, United States

Maharshak N, Cohen S, Lantner F, Hart G, Leng L, Bucala R, Shachar I. CD74 is a survival receptor on colon epithelial cells. *World J Gastroenterol* 2010; 16(26): 3258-3266 Available from: URL: http://www.wjgnet.com/1007-9327/full/v16/i26/3258.htm
DOI: http://dx.doi.org/10.3748/wjg.v16.i26.3258

INTRODUCTION

CD74 (Invariant chain; Ii) is a type Ⅱ integral membrane protein, which acts as a chaperone for major histocompatibility complex (MHC) class Ⅱ protein expression[1]. It is a non-polymorphic type Ⅱ integral membrane protein; the mouse protein is comprised of a 30 amino acid (aa) N-terminal cytoplasmic tail, followed by a single 24 aa transmembrane region and an approximately 150 aa long lumenal domain. The CD74 chain was initially thought to function mainly as an MHC class Ⅱ chaperone, which promotes endoplasmic reticulum (ER) exit of MHC class Ⅱ molecules, directs them to endocytic compartments,

prevents peptide binding in the ER, and contributes to peptide editing in the MHC class Ⅱ compartment[1]. A small proportion of CD74 is modified by the addition of chondroitin sulfate (CD74-CS), and this form of CD74 is expressed on the surface of antigen presenting cells (APCs), including monocytes and B cells. In addition to APCs, other cells of the gastrointestinal tract, such as epithelial cells, express class Ⅱ MHC proteins and CD74 and act as APCs[2]. The role of CD74 in the epithelium is not fully defined. It was formerly accepted that the functions of CD74 in these cells have been correlated with its role in antigen processing and presentation in conventional APCs. However, CD74 may play additional roles in epithelial cells. CD74 expression on normal human colon epithelial cells (CEC) is still controversial, as the presence of this molecule was demonstrated using immunohistochemistry by some groups[3], but not by others[4,5]. On human colonic epithelial cell lines it was found to be expressed only after interferon-γ treatment[6]. In mice, CD74 expression on CEC is also not clear, although CD74 was not demonstrated on normal murine CEC[7]. In one study, CLIP (class Ⅱ invariant chain peptide) was shown to be expressed in a complex with MHC class Ⅱ, suggesting that CD74 is expressed on these cells as well[8]. Recently, it was demonstrated that CD74 is expressed on CEC of $APC^{Min/+}$ mice. However, these mice bear a point mutation in the murine homolog of the *APC* gene and develop multiple intestinal adenomas[9]. In humans, on the contrary, there was no CD74 expression on normal CEC, but it was expressed on CEC of sporadic colorectal adenomas[10].

It was shown previously that macrophage migration inhibitory factor (MIF) binds to the CD74 extracellular domain, a process that results in the initiation of a signaling pathway in a CD44 dependent manner[11-13].

In our previous studies, we showed that CD74 expressed on B cells is directly involved in shaping the B cell repertoire[14-16] through a pathway leading to the activation of transcription mediated by the nuclear factor-κB (NF-κB) p65/RelA homodimer and its co-activator, TAFII105[17]. We demonstrated that CD74 stimulation with anti-CD74 antibody or MIF leads to NF-κB activation, enabling entry of the stimulated B cells into the S phase, an increase in DNA synthesis, cell division, and augmented expression of anti-apoptotic proteins. These findings indicated that surface CD74 functions as a survival receptor[13,18,19].

In addition, CD74 is expressed at high levels from an early stage of the B cell leukemia, B-CLL. The activation of CD74 on human B-CLL cells by MIF, initiates a signaling cascade that contributes to tumor progression. This pathway induces NF-κB activation, resulting in the secretion of interleukin 8, which in turn promotes cell survival. Blocking of this pathway leads to decreased cell survival. Thus, CD74 expressed on the surface of B-CLL cells plays a critical role in regulating the survival of these malignant cells[20].

MHC class Ⅱ expression was initially thought to be limited to a restricted set of cells collectively known as APCs. However, in addition to conventional APCs, other cell types, including mucosal epithelial cells, were subsequently reported to express class Ⅱ MHC molecules and to present antigens[21].

Surface expression of newly synthesized CD74 is followed by rapid internalization to the endosomal pathway. Experiments that investigate cell surface CD74 are complicated by the fact that CD74 remains on the cell surface for a very short time. The surface half-life of CD74 was calculated to be less than 10 min[22,23].

In this article, we followed CD74 expression in colonic intestinal epithelial cells in the mouse. We show that CD74 is expressed on CEC derived from C57BL/6 and on the CT26 colon carcinoma cell line and serves as a survival receptor on these cells. This finding may suggest a role for CD74 in colon cancer development.

MATERIALS AND METHODS

Mice

C57BL/6, C57BL/6 CD74 deficient[24], C57BL/6 MIF deficient[25], CD44 deficient NOD/SCID mice (Jackson Lab), were used. All animals were used at 6-10 wk of age.

All animal procedures were approved by the Animal Research Committee at the Weizmann Institute of Science.

Intraperitoneal MIF administration

Recombinant murine MIF was purified from an expression system as previously described and contaminating endotoxin removed by C8 chromatography[26]. Mice were injected daily ip with MIF (400 ng) or with PBS, as indicated. Mice were sacrificed after 3.5 or 24 h and CEC were isolated.

Isolation of CECs

CEC were isolated using a modification of the method described previously[27]. Briefly, mice were sacrificed, colons were immediately removed and washed with phosphate buffered saline (PBS) until all content was removed. Colons were inverted and washed gently with Roswell Park Memorial Institute solution. Mucus was removed by incubation for 10 min in 1 mmol/L DTT. Specimens were treated with Dispase Ⅱ (Roche Diagnostics; 3 mg/mL) in DMEM for 30 min (vortexing every 5 min) at 37℃. CEC were isolated from the remaining tissue by passage through a metal filter. In order to purify CEC, cells were centrifuged on a discontinuous Percoll gradient for 30 min, 2000 r/min. Cells found on the top 0%-30% gradient are CEC[28]. Isolated cells were washed in PBS. CEC isolated in this fashion contained over 90% viable cells as determined by Trypan blue exclusion. A total of 92%-95% of the cells stained with the anti-epithelial cell marker anti-pan cytokeratin-26 (FITC conjugated) (Sigma-Aldrich). The remaining contaminating cells represented $CD3^+$ and $B220^+$ cells.

CT26 cell line

CT26 murine colon carcinoma cells were grown as monolayer cultures in DMEM-10%, fetal bovine serum (FBS) (Invitrogen) supplemented with 100 IU/mL penicillin and

100 μg/mL streptomycin. Cells were maintained in a 37℃ incubator with 5% CO_2-humidified air.

Stimulation of cells by MIF

CECs (3-6 × 10^6 cells/well) isolated from CD57BL/6 mice, were cultured in 12-well plates at 37℃ in DMEM medium supplemented with 10% FCS, 2 mmol/L glutamate, 300 U/mL penicillin, 300 μg/mL streptomycin, with or without 400 ng/mL of MIF for 17 h.

1.5 × 10^6 cells (CT26 cell line) were plated in complete medium into dishes of 6-well cell culture plates, and were allowed to adhere for 24 h. After washing the cells twice with PBS, they were incubated with MIF (400 ng/mL) for 3 or 6 h (as indicated in the text) in serum-free medium.

RNA isolation and reverse transcription

Total RNA was isolated from cells using the Tri Reagent Kit (MRC), according to the manufacturer's instructions. Reverse transcription was carried out using Superscript Ⅱ RT (Gibco-BRL).

Primers that were used in polymerase chain reaction (PCR) reactions: Bcl-2: 5'-CACCGAACACTTGATTCTG, 3'-AGATCTCTGGTTGGGATTC; Cyclin E: 5'-GAAAATCAGACCACCCAGAGCC, 3'-GAAATGATACAAAGCAGAAGCAGCG; CD74: 5'-GGAGTACCCGCAGCTGAAGGGG, 3'-GAAGATAGGTCTTCCATGTCCAGTG; HPRT: 5'-GAGGGTAGGCTGGCCTATGCCT, 3'-GTTGGATACAGGCCAGACTTTGTTG.

Real time PCR

Levels of mRNA of Actin, Bcl-2 and Cyclin E, were analyzed by quantitative real-time reverse transcriptase (RT)-PCR using a Light-Cycler instrument (Roche Diagnostics, Mannheim, Germany). Total RNA was isolated from cells using the Tri Reagent Kit (MRC). Reverse transcription was carried out using Superscript Ⅱ RT (Gibco-BRL). The reaction volume (10 mL) contained 3 mmol/L $MgCl_2$, LightCycler HotStart DNA SYBR Green I mix (Roche Diagnostics), specific primer pairs, and 2.5 mL of cDNA. Conditions for PCR were as follows: 10 min at 95℃ followed by 60 cycles of 15 s at 95℃, 15 s at 60℃, and 15 s at 72℃. PCR was performed in triplicates. Primer sequences were as follows: Bcl-2: 5'-GCTACCGTCGTGACTT-3', 5'-GCCGGTTCAGGTACTC-3'; Cyclin E: 5'-GTAACATAAGCAAACTG-3', 5'-TTCTTCTGGATTGGCTAA-3'; Actin: 5'-CAGTAACAGTCCGCCT-3', 5'-GTGACGTTGACATCCG-3'; β-actin levels were used to normalize samples for calculation of the relative expression levels of the genes.

Western blotting analysis

To detect whether CD74 protein is expressed by CEC and to examine levels of Bcl-2 protein, cells were lysed in RIPA lysis buffer (10 mmol/L Tris, pH 7.2, 150 mmol/L NaCl, 1% deoxycholate, 1% Triton X-100, 0.1% SDS, 5 mmol/L EDTA) containing complete protease inhibitor cocktail [10 μg/mL leupeptin, 10 μg/mL aprotinin, 10 μg/mL pepstatin, 10 μg/mL chymostatin (Roche), 1 mmol/L PMSF (Sigma), and 20 mmol/L N-etheyl-melamide (Sigma)], for 30 min on ice and then centrifuged at 14000 *g* at 4℃ to remove cell debris. Lysates were separated by 12% (w/v) SDS-PAGE. The proteins were then transferred onto a nitrocellulose membrane and probed with anti-CD74 (FL-293; Santa Cruz) or anti-Bcl-2 (C-2; Santa Cruz), followed by horseradish peroxidase-conjugated anti-mouse (Jackson Laboratories).

To detect changes in Akt phosphorylation, stimulated cells were lysed in buffer containing: 25 mmol/L Tris, pH 7.4; 2 mmol/L vanadate; 75 mmol/L glycophosphate, pH 7.2; 2 mmol/L EDTA; 2 mmol/L EGTA; 10 mmol/L NaPPi; and 0.5% NP-40 in the presence of protease inhibitors. Lysates were separated by 10% (w/v) SDS-PAGE. The proteins were transferred onto a nitrocellulose membrane and probed with anti-p-Akt antibody (Cell Signaling Technology) followed by peroxidase-conjugated anti-mouse (Jackson Labs). The membrane was then stripped and reprobed with anti-tubulin antibody (Sigma), followed by peroxidase-conjugated anti-mouse (Jackson Laboratories).

Immunofluorescence and flow cytometry

Staining of IECs was performed using anti-CD74 (Santa Cruz), anti pan-cytokeratin (Sigma-Aldrich).

Cell survival assays

Annexin and PI staining: Cells were centrifuged, washed, and stained with annexin (BD Biosciences) and propidium iodide (PI) for 15 min at room temperature. The extent of annexin and PI staining was analyzed by FACS. Unstained cells were classified as living cells; annexin stained cells are apoptotic, and PI stained cells were considered necrotic.

FLICA staining: Analysis of apoptosis. To detect earlier stages of apoptosis, intracellular caspase 3 and 7 activity was analyzed using the FLICA (Fluorochrome Inhibitors of Caspases) Apoptosis Detection kit from Immunochemistry Technologies (Bloomington, MN). The kit contains carboxyfluorescein-labeled valylalanylaspartic acid fluoromethyl ketone, which tightly binds activated caspases. Cells were harvested and incubated with a FLICA solution in the complete medium at 37℃ for 1 h. After washing twice cells were analyzed by FACS.

Statistical analysis

Results are represented as averages of several experiments (as indicated) ± SE. Comparison between groups was done by Student's *t*-test.

RESULTS

CD74 is expressed on mouse colonic epithelial cells

To determine whether CD74 is expressed in normal CEC, we first analyzed its mRNA and protein levels in control and CD74 deficient (CD74-/-) CEC. As shown in Figure 1, CD74 mRNA (Figure 1A) and protein (Figure 1B) were detected in CEC, while they were not observed in the CD74 deficient cells. Isolation of CEC from C57BL/6

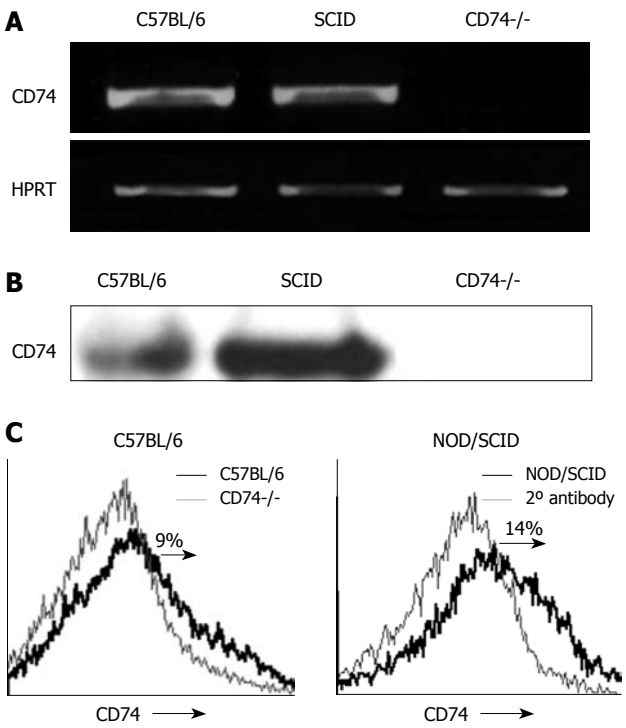

Figure 1 CD74 is expressed on naive CEC isolated from C57BL/6 mice. CEC were isolated from C57BL/6, NOD/SCID and CD74-/- mice. A: RNA was purified and CD74 or HPRT mRNA were analyzed by RT-PCR. The results presented are representative of four separate experiments; B: Cells were lysed and proteins were analyzed by Western blotting; C: Cells were stained with anti cytokeratin and anti CD74 antibodies, and analyzed by FACS. Histograms show CD74 expression on cytokeratin positive cells. CEC: Colon epithelial cells; RT-PCR: Reverse transcriptase-polymerase chain reaction; FACS: Fluorescence-activated cell sorter.

resulted in a population that was more than 90% pure, containing less than 5% B cells (data not shown), which expressed relatively high levels CD74. To eliminate contamination by B cell CD74, we analyzed CD74 mRNA and protein levels in CEC isolated from NOD/SCID mice, which lack B and T cells. As demonstrated in Figure 1, CD74 mRNA (Figure 1A) and protein (Figure 1B) were detected in CEC derived from NOD/SCID mice as well, showing that normal CEC express CD74. We next analyzed, by FACS analysis, CD74 cell surface expression on normal CEC. As shown in Figure 1C, CD74 is specifically expressed on normal CEC derived from C57BL/6 or NOD/SCID mice. Thus, CD74 is expressed on normal CEC.

CD74 serves as a survival receptor on CEC

We have previously shown that CD74 stimulation results in augmented expression of anti-apoptotic proteins, resulting in induction of cell survival[13,18]. In order to examine whether CD74 serves as a survival receptor on CEC, we followed the downstream cascade initiated by MIF in CEC. CEC from C57BL/6 mice were incubated *in vitro* for 17 h with MIF or with PBS, and the percentage of live and apoptotic cells in each group was analyzed using annexin-PI staining. As shown in Figure 2, MIF stimulation resulted in elevation of the proportion of live CEC (42%, $n = 4$, $P = 0.003$) and reduction in the apoptotic population.

To further show the *in vivo* role of MIF and CD74 in CEC survival, MIF was injected ip to control C57BL/6 and NOD/SCID mice and Bcl-2 mRNA and protein levels were determined. As can be seen in Figure 3A and B, a significant elevation in Bcl-2 mRNA and protein levels were detected following MIF stimulation compared to PBS-treated cells. The MIF-induced cascade was CD74 dependent, since in its absence, MIF was not able to increase Bcl-2 levels.

Since CEC survive poorly *in vitro*, and following 17 h incubation a large proportion of the cells are dead, we followed CEC survival immediately after their isolation. Thus, 24 h after MIF injection to C57BL/6, NOD/SCID and CD74-/- mice, cells were isolated and their cell death was analyzed using FLICA, which detects early stages of apoptosis by analyzing intracellular caspase 3 and 7 activity. The percentage of apoptotic cells was significantly higher in the PBS treated cells compared with the MIF treated cells derived from C57BL/6 and NOD/SCID mice (Figure 3C), while the CD74-/- cells were insensitive to MIF treatment. Results of four experiments are summarized in Figure 3D.

It has been recently shown that CD44 forms a complex with CD74 which regulates MIF-induced B cell survival[11,13]. CD44 expressed on CEC was previously characterized as a negative regulator of apoptosis as well[29]. Accordingly, CD44 deficient cells (CD44-/-) demonstrated an elevated basal apoptotic rate compared to control mice. In addition, there was no increase in CEC survival upon MIF stimulation (Figure 3C and D), suggesting that CD44 is a crucial component in the CD74-induced survival cascade.

Cell cycle progression is regulated by cyclin dependent kinases (Cdks). Cdks are constitutively expressed during the cell cycle and are activated upon specific cyclin binding. Different cyclins are differentially expressed during various stages of the cell cycle. This transient expression activates Cdks and regulates cell cycle progression. To further determine whether CD74 regulates cell entry to the S-phase, we followed cyclin E, which is expressed upon S-phase initiation. MIF (400 ng) was injected to C57BL/6 and NOD/SCID mice. 3.5 h later, CEC were isolated and their cyclin E mRNA levels were analyzed. As demonstrated in Figure 4A and B, cyclin E mRNA levels were upregulated in both C57BL/6 and NOD/SCID derived cells. These results demonstrate that following CD74 stimulation, CEC cells synthesize DNA, enter S phase, and probably divide.

Taken together, our results demonstrate that CD74 serves as a survival receptor on CEC. MIF binding to CD74 induces a signaling cascade resulting in Bcl-2 and cyclin E expression and survival in normal CEC.

In order to evaluate whether our finding may have implications on malignant cells, we further assessed the expression and function of CD74 in the colon carcinoma cell line CT26. We found that CD74 is expressed on the CT26 cell line (Figure 5A) and MIF stimulation reduces their apoptosis (Figure 5B and C), by upregulating Bcl-2 mRNA (Figure 5D and E), protein (Figure 5F) and cyclin E (Figure 5G) mRNA levels.

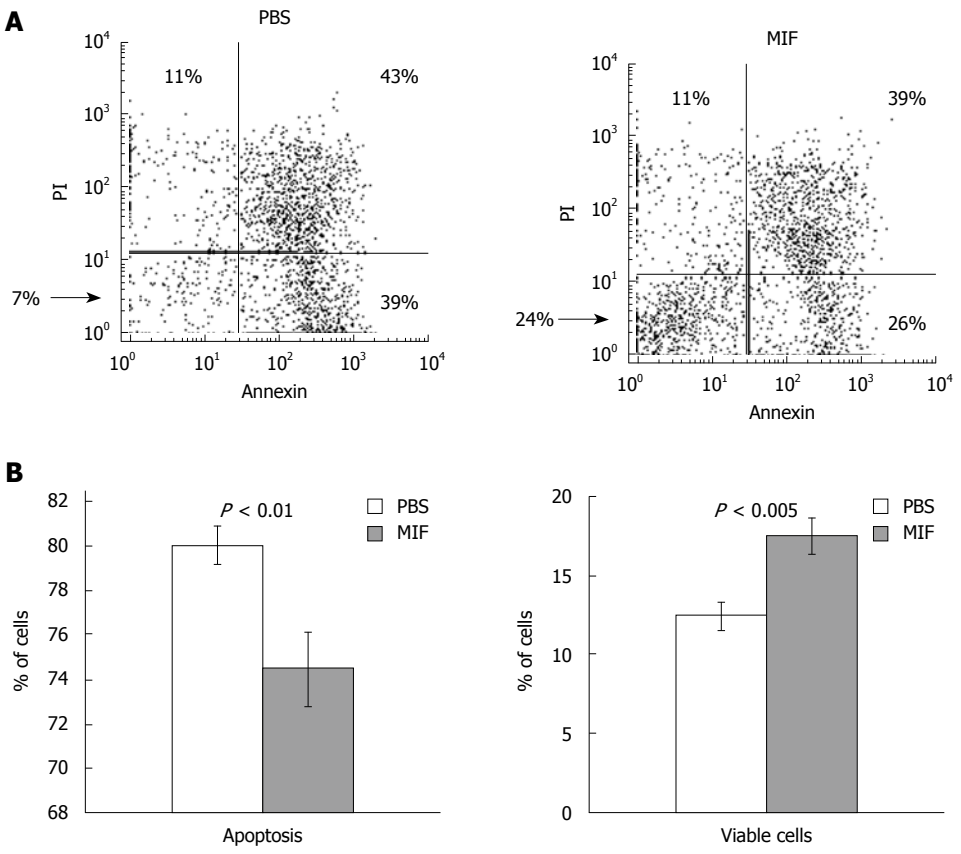

Figure 2 ***In vitro*** **stimulation with MIF induces CEC survival.** CEC from C57BL/6 mice were incubated in the presence or absence of MIF (400 ng/mL). A: After 17 h, cells were collected and analyzed for survival by annexin and propidium iodide staining; B: Graphs summarizing the results of four independent experiments. MIF: Migration inhibitory factor; PBS: Phosphate buffered saline.

We have previously shown that in B cells the CD74 induced survival cascade involves Akt phosphorylation[18]. In intestinal epithelial cells, it has been shown that phosphorylation of Akt enhances cell survival as well[30] and is closely associated with CRC[31,32]. We therefore analyzed Akt phosphorylation in CT26 cells. As shown in Figure 5H, MIF elevated Akt phosphorylation 1 min following stimulation.

Together, our results suggest that MIF and CD74 regulate colon tumor cell proliferation and survival.

DISCUSSION

The importance of CD74 as a survival receptor on B cells, and its role in the pathogenesis of certain malignancies is a subject of intense study. In the colon, CD74 is expressed on malignant cells, and its expression correlates with tumor grade[5]. Recent evidence suggests that up-regulation of CD74 and MIF on human colon adenomas is in correlation with dysplasia of the epithelial cells[10]. However, contradictory results regarding the presence of CD74 on normal human CEC were published through the years. In one report, the authors were able to detect the presence of CD74 by using immunohistochemistry, whereas, in a more recent study, using similar methodology, CD74 was not detected. In this article, we show CD74 expression in mouse normal CEC at the levels of mRNA, protein, and cell surface expression. Furthermore, we found that stimulation of CD74 by its natural ligand, MIF, results in increased survival of CEC. This can be at least partially attributed to enhanced expression of the survival gene, Bcl-2, which was found to be up-regulated in MIF-stimulated CEC. These findings suggest a role for CD74 on normal CEC.

Demonstration of CD74 on CEC is complicated by two main phenomena. First, CD74 has a very short half-life on these cells, and secondly, CEC are difficult to handle. These cells typically undergo apoptosis and/or necrosis, shortly after isolation[33]. Therefore, experiments involving incubation of these cells for more than a few hours usually result in death of most of the cells. In addition, isolates of CEC are never free of contaminating cells, specifically B cells from the lamina propria that also express CD74. In order to overcome these limitations, we performed our experiments shortly after CEC isolation. In experiments where we tested stimulation by MIF, we used mainly *in vivo* stimulation by ip injections of MIF for various amounts of time. To avoid contamination with B cells, we also repeated most of the experiments in NOD/SCID mice, which lack B cells. Our results show that CD74 is expressed on normal CEC cells.

Due to the difficulties discussed above, we used multiple models in order to demonstrate the positive effect CD74 has on CEC survival. In these experiments, we analyzed by FACS the percentage of living and apoptotic CEC. We demonstrated that stimulation by MIF either

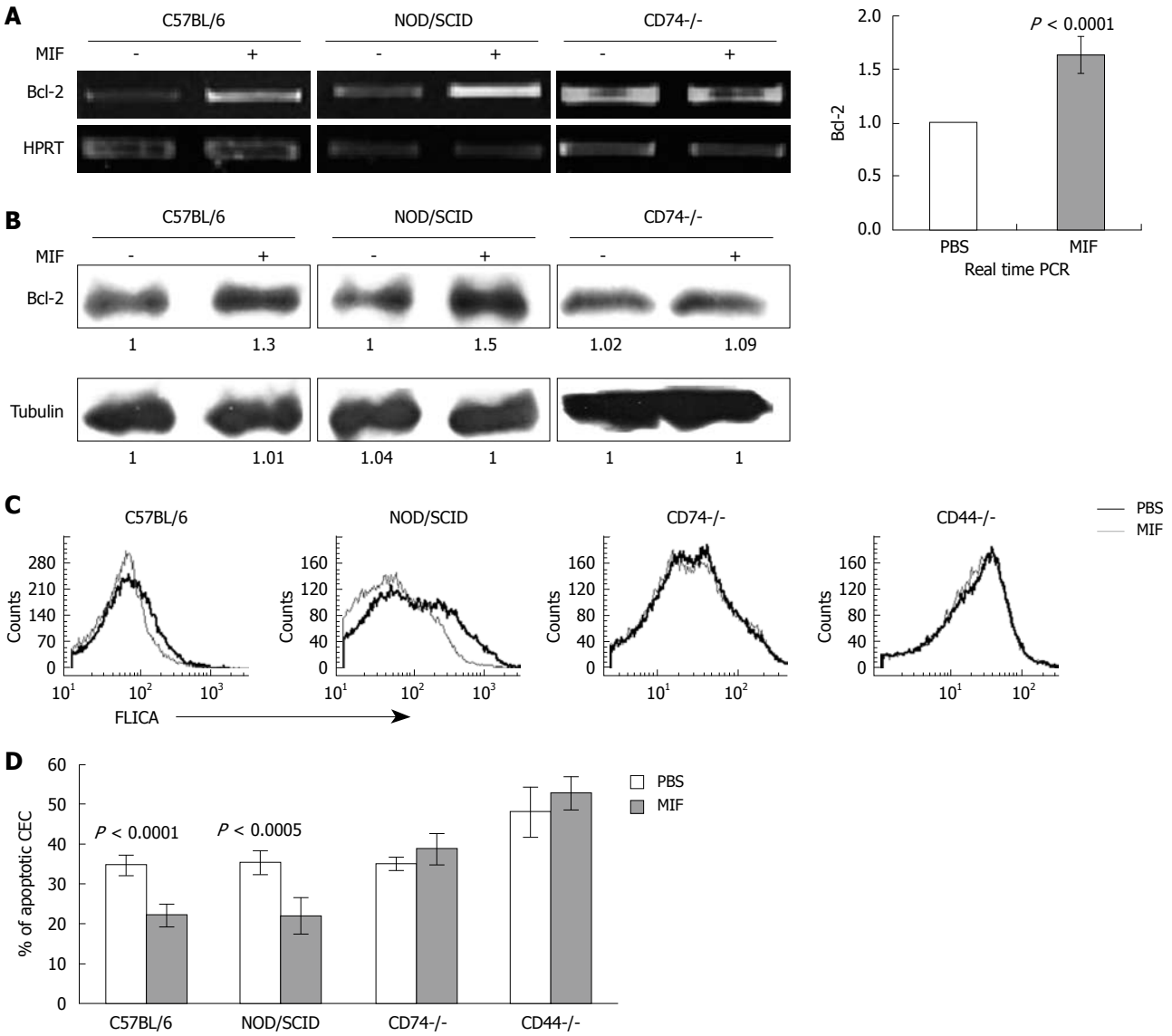

Figure 3 MIF stimulation elevates Bcl-2 and survival in CEC and their *in vivo*. CEC were isolated from CD74-/-, C57BL/6 and from NOD/SCID mice that were i.p injected with MIF (400 ng) or PBS 3.5 h before sacrifice. A: CEC were isolated, and RNA was purified; Bcl-2 or HPRT mRNA were analyzed by RT-PCR. The results presented are representative of four different experiments. The graph is a summary of four separate experiments of quantitative real time PCR using primers for Bcl-2 in CEC isolated from C57BL/6; B: Cells were lysed and Bcl-2 protein expression was analyzed by Western blotting analysis; C, D: C57BL/6, NOD/SCID, CD44-/- and CD74-/- mice were injected with MIF (400 ng) or PBS. After 24 h, mice were sacrificed and their CEC were isolated and stained with FLICA. C: Histograms show FLICA staining in MIF injected (grey line) compared to PBS injected (black line) CEC; D: Graph representing the average of five different experiments, demonstrating decreased apoptosis CEC in MIF treated C57BL/6 and NOD/SCID mice, compared to PBS treated animals.

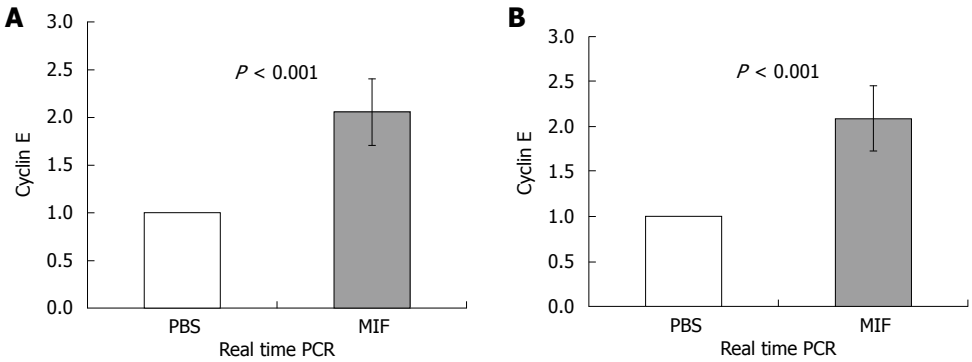

Figure 4 MIF induces cyclin E expression. CEC were isolated from C57BL/6 (A) and NOD/SCID (B) mice that were i.p injected with MIF (400 ng) or PBS 3.5 h prior to isolation of CEC. A, B: Quantitative real time PCR was performed using primers for cyclin E and β-actin. β-actin levels were used to normalize samples for calculation of the relative expression levels of cyclin E. Results are expressed as a fold of change in cyclin E expression at stimulated cells compared to non stimulated cells, which was defined as 1. Results shown are summary of four separate experiments.

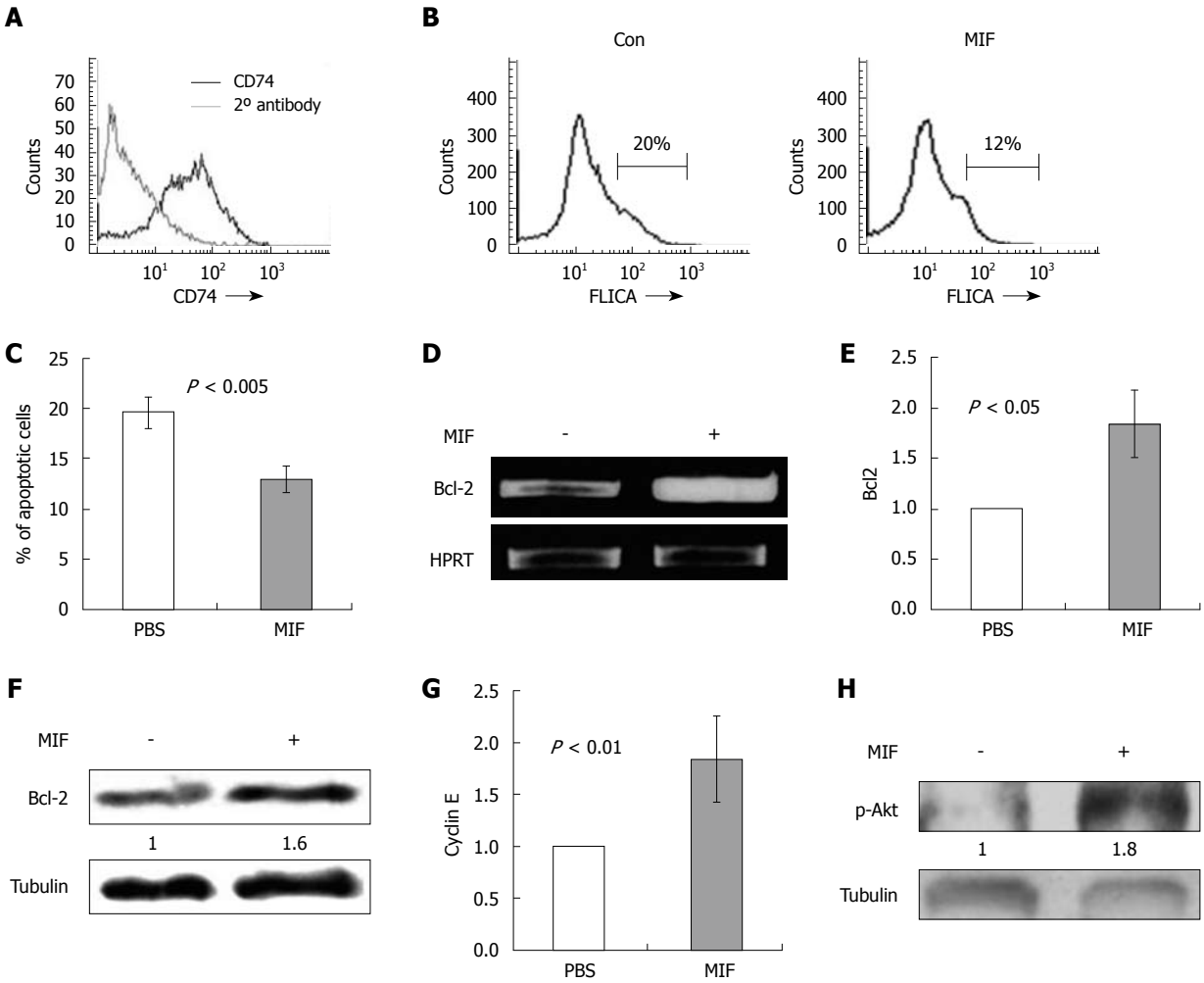

Figure 5 CD74 is expressed on CT26 cells and regulates their survival. A: CT26 cells were stained with anti CD74 antibodies, and analyzed by FACS. Histogram shows CD74 expression on these cells; B: Serum-starved CT26 cells were incubated in the presence or absence of MIF (400 ng/mL) for 6 h. Histograms show FLICA staining for apoptotic cells in both groups; C: Graph representing the average of five different experiments, demonstrating decreased apoptosis in MIF treated compared to untreated CT26 cell line; D: Serum-starved CT26 cells were either kept untreated or treated with MIF (400 ng/mL) for 3 h and levels of Bcl-2 mRNA were analyzed by RT-PCR. The results presented are representative of five different experiments; E: Quantitative real time PCR was performed using primers for Bcl-2. β-actin levels were used to normalize samples for calculation of the relative expression of Bcl2 level. Results are expressed as a fold of change in Bcl-2 expression at stimulated cells compared to non stimulated cells, which was defined as 1. Results shown are a summary of four separate experiments; F: Following 6 h of starvation the CT26 cells were lysed and Bcl-2 protein expression was analyzed by Western blotting analysis; G: Quantitative real time PCR was performed using primers for cyclin E and β-actin. β-actin levels were used to normalize samples for calculation of the relative expression levels of cyclin E. Results are expressed as a fold of change in cyclin E expression at stimulated cells compared to non stimulated cells, which was defined as 1. Results shown are a summary of four separate experiments; H: CT26 cells were incubated in the presence or absence of MIF (400 ng/mL) for 1 min. Cells were fast-frozen and lysed as described in Methods. Lysates were separated on 10% (wt/vol) SDS/PAGE and blotted with anti-p-Akt antibody (results presented are representative of three separate experiments) followed by HRP-conjugated anti-mouse antibodies. The membranes were then stripped and blotted with anti-tubulin.

by ip injection *in vivo* or by incubation of isolated CEC with MIF *in vitro*, resulted in elevated CEC survival and decreased apoptosis. These results strengthen our hypothesis that CD74 is a survival receptor on CEC and suggests that MIF is the natural ligand of CD74 on CEC, as described for B lymphocytes[13,18,19].

MIF is expressed throughout the human gastrointestinal tract, and has previously been implicated in control of apoptosis of non-epithelial and epithelial cells[34,35]. MIF induces Bcl-2 expression and cell survival. It was previously shown that CD74 forms a complex with CD44 in normal[11,12] and tumor cells[36]. We show here that CD44 is crucial for the MIF/CD74 induced survival cascade, since stimulation of CD44 deficient cells by MIF did not affect cell death.

Evidence for a role of CD74 in colorectal cancer was suggested by its expression on carcinoma cell lines of the colon[37], and by the observation that in human colorectal carcinomas, the grade of the tumor correlated with the level of CD74 expression on the transformed CEC[5]. Interestingly, both MIF and CD74 have been associated with tumor progression and metastasis. It was reported that MIF mRNA is over-expressed in various tumors[38,39] and MIF has also been associated with the growth of malignant cells[40]. Numerous studies have demonstrated the overexpression of CD74 in various cancers[20,41-46]. CD74 expression may also serve as a prognostic factor in many of these cancers, with higher relative expression of CD74 behaving as a marker of tumor progression[47]. Our findings further support a possible role for CD74 in

CRC. Additionally, CD44, which we showed essential in the MIF-CD74 survival cascade, is overexpressed in CRC, and has an anti-apoptotic effect on these cells, and probably involved in disease progression and metastases[29,48]. Moreover, we show that CD74 is expressed on the CT26 cell line and its stimulation by MIF enhances Akt phosphorylation, cyclin E and Bcl-2 expression resulting in their survival.

Our work clearly shows that CD74 is expressed on mouse intestinal epithelial cells, and serves as a survival receptor on these cells. Our results further show that CD74 may regulate survival of colorectal carcinoma tumor cells. Since we found that CD74 is a survival receptor on CEC, any change in gene expression that causes enhanced expression of CD74 or MIF may result in increased risk of colorectal cancer. Thus, CD74 may be found in the future to serve not only as a marker of colorectal cancer, but also as a therapeutic target.

COMMENTS

Background

CD74 is a protein that is expressed in and on some of the cells of the immune system, such as B lymphocytes and antigen presenting cells. This protein is known for its function in helping the immune cells to process and present foreign bodies. During recent years it was found that CD74 serves additionally as a survival receptor on cells of the immune system, and that its stimulation by its natural ligand - migration inhibitory factor (MIF) - prevents apoptosis (self destruction) of the cells.

Research frontiers

CD74 was found to be markedly expressed on numerous tumors - hematologic as well as epithelial; in some of these tumors it can serve as a tumor marker and its level of expression may be related to the prognosis. Moreover, activation of CD74 on B lymphocytes in B cell leukaemia, results in tumor progression, and blocking this pathway leads to decreased cell survival, and thus may be applicable as a therapeutic intervention. Whether CD74 is expressed on colon intestinal epithelial cells is controversial, although it was shown to be expressed on epithelial cells of colorectal adenomas.

Innovations and breakthroughs

The authors' work clearly shows that CD74 is expressed on mouse intestinal epithelial cells and serves as a novel survival receptor on these cells. They show that CD74 may regulate survival of colorectal carcinoma as well. Since they found that CD74 is a survival receptor on colonic epithelial cells, any change in gene expression that causes enhanced expression of CD74 or MIF may result in increased risk of colorectal cancer.

Applications

As CD74 is a survival receptor on colon epithelial cells and on malignant cell lines from mice, CD74 may be found in the future to serve not only as a marker of colorectal cancer, but also as a therapeutic target. Future research should focus on the role of CD74 in colorectal cancer models in animals and on human tissues.

Peer review

This paper is well written and documents expression on CD74 receptor mRNA and protein in colon epithelial cells. The study is very well done and straightforward. The experiments are of good quality.

REFERENCES

1 **Stumptner-Cuvelette P**, Benaroch P. Multiple roles of the invariant chain in MHC class II function. *Biochim Biophys Acta* 2002; **1542**: 1-13

2 **Beswick EJ**, Reyes VE. CD74 in antigen presentation, inflammation, and cancers of the gastrointestinal tract. *World J Gastroenterol* 2009; **15**: 2855-2861

3 **Momburg F**, Koretz K, Von Herbay A, Möller P. Nonimmune human cells can express MHC class II antigens in the absence of invariant chain--an immunohistological study on normal and chronically inflamed small intestine. *Clin Exp Immunol* 1988; **72**: 367-372

4 **Möller P**, Momburg F, Koretz K, Moldenhauer G, Herfarth C, Otto HF, Hämmerling GJ, Schlag P. Influence of major histocompatibility complex class I and II antigens on survival in colorectal carcinoma. *Cancer Res* 1991; **51**: 729-736

5 **Jiang Z**, Xu M, Savas L, LeClair P, Banner BF. Invariant chain expression in colon neoplasms. *Virchows Arch* 1999; **435**: 32-36

6 **Hershberg RM**, Framson PE, Cho DH, Lee LY, Kovats S, Beitz J, Blum JS, Nepom GT. Intestinal epithelial cells use two distinct pathways for HLA class II antigen processing. *J Clin Invest* 1997; **100**: 204-215

7 **Vidal K**, Samarut C, Magaud JP, Revillard JP, Kaiserlian D. Unexpected lack of reactivity of allogeneic anti-Ia monoclonal antibodies with MHC class II molecules expressed by mouse intestinal epithelial cells. *J Immunol* 1993; **151**: 4642-4650

8 **Beers C**, Burich A, Kleijmeer MJ, Griffith JM, Wong P, Rudensky AY. Cathepsin S controls MHC class II-mediated antigen presentation by epithelial cells in vivo. *J Immunol* 2005; **174**: 1205-1212

9 **Moser AR**, Mattes EM, Dove WF, Lindstrom MJ, Haag JD, Gould MN. ApcMin, a mutation in the murine Apc gene, predisposes to mammary carcinomas and focal alveolar hyperplasias. *Proc Natl Acad Sci USA* 1993; **90**: 8977-8981

10 **Cuthbert RJ**, Wilson JM, Scott N, Coletta PL, Hull MA. Differential CD74 (major histocompatibility complex Class II invariant chain) expression in mouse and human intestinal adenomas. *Eur J Cancer* 2009; **45**: 1654-1663

11 **Shi X**, Leng L, Wang T, Wang W, Du X, Li J, McDonald C, Chen Z, Murphy JW, Lolis E, Noble P, Knudson W, Bucala R. CD44 is the signaling component of the macrophage migration inhibitory factor-CD74 receptor complex. *Immunity* 2006; **25**: 595-606

12 **Leng L**, Metz CN, Fang Y, Xu J, Donnelly S, Baugh J, Delohery T, Chen Y, Mitchell RA, Bucala R. MIF signal transduction initiated by binding to CD74. *J Exp Med* 2003; **197**: 1467-1476

13 **Gore Y**, Starlets D, Maharshak N, Becker-Herman S, Kaneyuki U, Leng L, Bucala R, Shachar I. Macrophage migration inhibitory factor induces B cell survival by activation of a CD74-CD44 receptor complex. *J Biol Chem* 2008; **283**: 2784-2792

14 **Shachar I**, Flavell RA. Requirement for invariant chain in B cell maturation and function. *Science* 1996; **274**: 106-108

15 **Matza D**, Lantner F, Bogoch Y, Flaishon L, Hershkoviz R, Shachar I. Invariant chain induces B cell maturation in a process that is independent of its chaperonic activity. *Proc Natl Acad Sci USA* 2002; **99**: 3018-3023

16 **Matza D**, Kerem A, Shachar I. Invariant chain, a chain of command. *Trends Immunol* 2003; **24**: 264-268

17 **Matza D**, Wolstein O, Dikstein R, Shachar I. Invariant chain induces B cell maturation by activating a TAF(II)105-NF-kappaB-dependent transcription program. *J Biol Chem* 2001; **276**: 27203-27206

18 **Starlets D**, Gore Y, Binsky I, Haran M, Harpaz N, Shvidel L, Becker-Herman S, Berrebi A, Shachar I. Cell-surface CD74 initiates a signaling cascade leading to cell proliferation and survival. *Blood* 2006; **107**: 4807-4816

19 **Lantner F**, Starlets D, Gore Y, Flaishon L, Yamit-Hezi A, Dikstein R, Leng L, Bucala R, Machluf Y, Oren M, Shachar I. CD74 induces TAp63 expression leading to B-cell survival. *Blood* 2007; **110**: 4303-4311

20 **Binsky I**, Haran M, Starlets D, Gore Y, Lantner F, Harpaz N, Leng L, Goldenberg DM, Shvidel L, Berrebi A, Bucala R, Shachar I. IL-8 secreted in a macrophage migration-inhibitory factor- and CD74-dependent manner regulates B cell chronic lymphocytic leukemia survival. *Proc Natl Acad Sci USA* 2007; **104**: 13408-13413

21 **Barrera CA**, Almanza RJ, Ogra PL, Reyes VE. The role of the invariant chain in mucosal immunity. *Int Arch Allergy Immunol* 1998; **117**: 85-93

22 **Ghosh P**, Amaya M, Mellins E, Wiley DC. The structure of an intermediate in class II MHC maturation: CLIP bound to HLA-DR3. *Nature* 1995; **378**: 457-462

23 **Freisewinkel IM**, Schenck K, Koch N. The segment of invariant chain that is critical for association with major histocompatibility complex class II molecules contains the sequence of a peptide eluted from class II polypeptides. *Proc Natl Acad Sci USA* 1993; **90**: 9703-9706

24 **Elliott EA**, Drake JR, Amigorena S, Elsemore J, Webster P, Mellman I, Flavell RA. The invariant chain is required for intracellular transport and function of major histocompatibility complex class II molecules. *J Exp Med* 1994; **179**: 681-694

25 **Fingerle-Rowson G**, Petrenko O, Metz CN, Forsthuber TG, Mitchell R, Huss R, Moll U, Müller W, Bucala R. The p53-dependent effects of macrophage migration inhibitory factor revealed by gene targeting. *Proc Natl Acad Sci USA* 2003; **100**: 9354-9359

26 **Bernhagen J**, Mitchell RA, Calandra T, Voelter W, Cerami A, Bucala R. Purification, bioactivity, and secondary structure analysis of mouse and human macrophage migration inhibitory factor (MIF). *Biochemistry* 1994; **33**: 14144-14155

27 **van de Wal Y**, Corazza N, Allez M, Mayer LF, Iijima H, Ryan M, Cornwall S, Kaiserlian D, Hershberg R, Koezuka Y, Colgan SP, Blumberg RS. Delineation of a CD1d-restricted antigen presentation pathway associated with human and mouse intestinal epithelial cells. *Gastroenterology* 2003; **124**: 1420-1431

28 **Panja A**, Barone A, Mayer L. Stimulation of lamina propria lymphocytes by intestinal epithelial cells: evidence for recognition of nonclassical restriction elements. *J Exp Med* 1994; **179**: 943-950

29 **Lakshman M**, Subramaniam V, Jothy S. CD44 negatively regulates apoptosis in murine colonic epithelium via the mitochondrial pathway. *Exp Mol Pathol* 2004; **76**: 196-204

30 **Zhang HM**, Rao JN, Guo X, Liu L, Zou T, Turner DJ, Wang JY. Akt kinase activation blocks apoptosis in intestinal epithelial cells by inhibiting caspase-3 after polyamine depletion. *J Biol Chem* 2004; **279**: 22539-22547

31 **Chen J**. Is Src the key to understanding metastasis and developing new treatments for colon cancer? *Nat Clin Pract Gastroenterol Hepatol* 2008; **5**: 306-307

32 **Garcia-Echeverria C**, Sellers WR. Drug discovery approaches targeting the PI3K/Akt pathway in cancer. *Oncogene* 2008; **27**: 5511-5526

33 **Hofmann C**, Obermeier F, Artinger M, Hausmann M, Falk W, Schoelmerich J, Rogler G, Grossmann J. Cell-cell contacts prevent anoikis in primary human colonic epithelial cells. *Gastroenterology* 2007; **132**: 587-600

34 **Wilson JM**, Coletta PL, Cuthbert RJ, Scott N, MacLennan K, Hawcroft G, Leng L, Lubetsky JB, Jin KK, Lolis E, Medina F, Brieva JA, Poulsom R, Markham AF, Bucala R, Hull MA. Macrophage migration inhibitory factor promotes intestinal tumorigenesis. *Gastroenterology* 2005; **129**: 1485-1503

35 **Cordon-Cardo C**, Prives C. At the crossroads of inflammation and tumorigenesis. *J Exp Med* 1999; **190**: 1367-1370

36 **Meyer-Siegler KL**, Iczkowski KA, Leng L, Bucala R, Vera PL. Inhibition of macrophage migration inhibitory factor or its receptor (CD74) attenuates growth and invasion of DU-145 prostate cancer cells. *J Immunol* 2006; **177**: 8730-8739

37 **Ong GL**, Goldenberg DM, Hansen HJ, Mattes MJ. Cell surface expression and metabolism of major histocompatibility complex class II invariant chain (CD74) by diverse cell lines. *Immunology* 1999; **98**: 296-302

38 **Meyer-Siegler K**, Hudson PB. Enhanced expression of macrophage migration inhibitory factor in prostatic adenocarcinoma metastases. *Urology* 1996; **48**: 448-452

39 **Bando H**, Matsumoto G, Bando M, Muta M, Ogawa T, Funata N, Nishihira J, Koike M, Toi M. Expression of macrophage migration inhibitory factor in human breast cancer: association with nodal spread. *Jpn J Cancer Res* 2002; **93**: 389-396

40 **Nishihira J**, Ishibashi T, Fukushima T, Sun B, Sato Y, Todo S. Macrophage migration inhibitory factor (MIF): Its potential role in tumor growth and tumor-associated angiogenesis. *Ann N Y Acad Sci* 2003; **995**: 171-182

41 **Young AN**, Amin MB, Moreno CS, Lim SD, Cohen C, Petros JA, Marshall FF, Neish AS. Expression profiling of renal epithelial neoplasms: a method for tumor classification and discovery of diagnostic molecular markers. *Am J Pathol* 2001; **158**: 1639-1651

42 **Meyer-Siegler KL**, Leifheit EC, Vera PL. Inhibition of macrophage migration inhibitory factor decreases proliferation and cytokine expression in bladder cancer cells. *BMC Cancer* 2004; **4**: 34

43 **Lazova R**, Moynes R, May D, Scott G. LN-2 (CD74). A marker to distinguish atypical fibroxanthoma from malignant fibrous histiocytoma. *Cancer* 1997; **79**: 2115-2124

44 **Ishigami S**, Natsugoe S, Tokuda K, Nakajo A, Iwashige H, Aridome K, Hokita S, Aikou T. Invariant chain expression in gastric cancer. *Cancer Lett* 2001; **168**: 87-91

45 **Ioachim HL**, Pambuccian SE, Hekimgil M, Giancotti FR, Dorsett BH. Lymphoid monoclonal antibodies reactive with lung tumors. Diagnostic applications. *Am J Surg Pathol* 1996; **20**: 64-71

46 **Datta MW**, Shahsafaei A, Nadler LM, Freeman GJ, Dorfman DM. Expression of MHC class II-associated invariant chain (Ii;CD74) in thymic epithelial neoplasms. *Appl Immunohistochem Mol Morphol* 2000; **8**: 210-215

47 **Mizue Y**, Nishihira J, Miyazaki T, Fujiwara S, Chida M, Nakamura K, Kikuchi K, Mukai M. Quantitation of macrophage migration inhibitory factor (MIF) using the one-step sandwich enzyme immunosorbent assay: elevated serum MIF concentrations in patients with autoimmune diseases and identification of MIF in erythrocytes. *Int J Mol Med* 2000; **5**: 397-403

48 **Subramaniam V**, Vincent IR, Gardner H, Chan E, Dhamko H, Jothy S. CD44 regulates cell migration in human colon cancer cells via Lyn kinase and AKT phosphorylation. *Exp Mol Pathol* 2007; **83**: 207-215

S- Editor Wang YR **L- Editor** O'Neill M **E- Editor** Lin YP

World Journal of Gastroenterology

Online Submissions: http://www.wjgnet.com/1007-9327office
wjg@wjgnet.com
doi:10.3748/wjg.v16.i26.3267

World J Gastroenterol 2010 July 14; 16(26): 3267-3278
ISSN 1007-9327 (print)
© 2010 Baishideng. All rights reserved.

ORIGINAL ARTICLE

Identification of cytokines involved in hepatic differentiation of mBM-MSCs under liver-injury conditions

Xue-Jun Dong, Hui Zhang, Ruo-Lang Pan, Li-Xin Xiang, Jian-Zhong Shao

Xue-Jun Dong, Hui Zhang, Molecular Medicine Center of Shaoxing People's Hospital, Shaoxing 312000, Zhejiang Province, China; School of Laboratory Medicine and Life Science, Wenzhou Medical College, Wenzhou 325035, Zhejiang Province, China

Ruo-Lang Pan, Li-Xin Xiang, Jian-Zhong Shao, College of Life Sciences, Zhejiang University, Hangzhou 310058, Zhejiang Province, China; Key Laboratory for Cell and Gene Engineering of Zhejiang Province, Hangzhou 310058, Zhejiang Province, China

Author contributions: Dong XJ, Xiang LX and Shao JZ designed the research, analyzed the data and edited the manuscript; Zhang H and Pan RL performed the research and edited the manuscript.

Supported by The Grant of Medicine and Health Key Projects of Zhejiang Province, Science and Technology Fund of Ministry of Health of the People's Republic of China, No. WKJ2007-2-037; Shaoxing Key Project for Science and Technology, No. 2007A23008; the Natural Science Foundation of Zhejiang Province, China, No. Y2090337

Correspondence to: Jian-Zhong Shao, Professor, College of Life Sciences, Zhejiang University, Hangzhou 310058, Zhejiang Province, China. shaojz@zju.edu.cn

Telephone: +86-571-88206582 Fax: +86-571-88206582

Received: March 23, 2010 Revised: April 26, 2010
Accepted: May 3, 2010
Published online: July 14, 2010

Abstract

AIM: To identify the key cytokines involved in hepatic differentiation of mouse bone marrow mesenchymal stem cells (mBM-MSCs) under liver-injury conditions.

METHODS: Abdominal injection of CCl_4 was adopted to duplicate a mouse acute liver injury model. Global gene expression analysis was performed to evaluate the potential genes involved in hepatic commitment under liver-injury conditions. The cytokines involved in hepatic differentiation of mBM-MSCs was functionally examined by depletion experiment using specific antibodies, followed by rescue experiment and direct inducing assay. The hepatic differentiation was characterized by the expression of hepatic lineage genes and proteins, as well as functional features.

RESULTS: Cytokines potentially participating in hepatic fate commitment under liver-injury conditions were initially measured by microarray. Among the up-regulated genes determined, 18 cytokines known to closely relate to liver growth, repair and development, were selected for further identification. The fibroblast growth factor-4 (FGF-4), hepatocyte growth factor (HGF) and oncostatin M (OSM) were finally found to be involved in hepatic differentiation of mBM-MSCs under liver-injury conditions. Hepatic differentiation could be dramatically decreased after removing FGF-4, HGF and OSM from the liver-injury conditioned medium, and could be rescued by supplementing these cytokines. The FGF-4, HGF and OSM play different roles in the hepatic differentiation of mBM-MSCs, in which FGF-4 and HGF are essential for the initiation of hepatic differentiation, while OSM is critical for the maturation of hepatocytes.

CONCLUSION: FGF-4, HGF and OSM are the key cytokines involved in the liver-injury conditioned medium for the hepatic differentiation of mBM-MSCs.

© 2010 Baishideng. All rights reserved.

Key words: Hepatic differentiation; Mouse bone marrow mesenchymal stem cells; Inducing cytokines; Fibroblast growth factor-4; Hepatocyte growth factor; Oncostatin M

Peer reviewers: Belén Beltrán, MD, PhD, Gastroenterology Department (Medicina Digestiva), Hospital Universitari La Fe, Avda Campanar 21, 46009 Valencia, Spain; Catherine Greene, PhD, Senior Lecturer, Department of Medicine, Royal College of Surgeons in Ireland, Education and Research Centre, Beaumont Hospital, Dublin 9, Ireland

Dong XJ, Zhang H, Pan RL, Xiang LX, Shao JZ. Identification of cytokines involved in hepatic differentiation of mBM-MSCs under liver-injury conditions. *World J Gastroenterol* 2010; 16(26): 3267-3278 Available from: URL: http://www.wjgnet.com/1007-9327/full/v16/i26/3267.htm DOI: http://dx.doi.org/10.3748/wjg.v16.i26.3267

INTRODUCTION

It is generally believed that the bone marrow mesenchymal stem cells (BM-MSCs) provide an appropriate hematopoietic microenvironment that exerts regulatory effects on the self-renewal and differentiation of hematopoietic stem/progenitor cells. They are capable of differentiating into mesoderm cell lineages, including osteoblasts, chondrocytes and adipocytes[1-3]. However, emerging new findings suggest that BM-MSCs are able to give rise to a more broad range of cells, including hepatocytes, neurons, epithelial cells and keratinocytes[4-8]. This plasticity of BM-MSCs has attracted much attention to their *in vivo* new functions under either metabolic or pathologic conditions, and their clinical therapy for tissue repair. In fact, several studies in animal models have suggested that endogenous MSCs may "naturally" be involved in wound healing and tissue regeneration, and the engrafted exogenous MSCs have beneficial effects in tissue repair, including that of bone, myocardial tissue, skin, kidney and liver[9-19]. These may encourage further studies on the new insight into MSCs biology and the mechanisms underlying MSCs differentiation, which are still poorly understood at present.

Recently, by an *in vivo* tracing technology, we have demonstrated that BM-MSCs could be recruited from the bone marrow into peripheral blood, and toward into the wounded sites in response to the injured-liver signals, which indicated a close relationship between BM-MSCs and liver repair[20]. Moreover, we have also found that the engrafted exogenous BM-MSCs could be recruited to the injured liver, and were able to differentiate into multiple hepatic-lineage cells, which greatly improved the wound healing, providing further insight into the relationship between BM-MSCs and injured liver[20]. Our previous reports also support the idea that the liver-injury conditioned culture medium can induce the differentiation of BM-MSCs into functional hepatic cells in an *in vitro* experiment[4]. These observations indicated that the hepatic differentiation of BM-MSCs may be induced by the cytokines secreted from the injured liver cells, since no cellular interactions existed in such cell-free cultural medium. However, which cytokines direct hepatic fate specification of BM-MSCs still remains unclear. In the present study, we identified the key cytokines that play a crucial role in the differentiation of mBM-MSCs in the liver-injury conditioned medium. We hope our finding will benefit the better understanding of the novel mechanisms underlying BM-MSCs involved liver repair and regeneration, and help improve the cytokine-based hepatic inducing strategy and provide a rich cellular resource from BM-MSCs for cytotherapy of acute liver diseases.

MATERIALS AND METHODS

Experimental animals

Eight to ten-week-old male ICR mice obtained from the Laboratory Animal Unit of Zhejiang Academy of Medical Sciences (Hangzhou, China) were used in the experiments. Animals were housed under specified pathogen-free conditions. All animal experiments were done in accordance with a legal regulation, which includes approval by a local ethical committee.

Isolation and culture of bone marrow MSCs

The mouse bone marrow MSCs (mBM-MSCs) were prepared as described previously[4]. Briefly, the bone marrow was extruded by clipping of the epiphysial ends of the bones and flushing with IMDM (Sigma, St. Louis, MO), supplemented with 10% fetal bovine serum (Hyclone, Rockville, MD), 1% penicillin/streptomycin (Medium A). After 3 d, non-adherent cells and debris were removed, and the adherent cells were cultured continuously. At near confluence, the cells were replated at 5×10^4 cells/cm^2. Osteogenic, chondrogenic and adipogenic differentiations were examined for functional identification[5].

Preparation of acute liver-injury mouse model

The acute liver-injury mouse model was prepared according to the method described previously[21]. Briefly, the mice were treated with CCl_4 (1.0 mL/kg body weight of a 10% solution in mineral oil injected intraperitoneally) twice a day and then sacrificed by cervical vertebrae luxation on the 24th h after the last injection.

Hepatocyte isolation and preparation of conditioned medium

The hepatocytes were isolated by the two-step collagenase perfusion from healthy mice (as control) or liver-injury mouse model prepared by the method described above. Briefly, donor animals received 25 U heparin (Sigma) prior to cell isolation. After cannulation of the portal vein, the liver was perfused with a calcium-free buffer solution, 3 mL/min at 37℃ for 10 min. Then, the liver was perfused with 0.025% collagenase Ⅳ (Invitrogen, Carlsbad, CA), 2 mL/min at 37℃ for 15 min. The perfused liver was resected, and the cells were released by gentle shaking and collected in 20 mL IMDM. The supernatant cell suspension was filtered using a 200 mm nylon mesh and the filtrate was washed twice with PBS by centrifugation at 50 × *g* for 45 s to remove cell debris, damaged cells, and non-parenchymal cells. After washing, the hepatocytes were cultured in medium A at 5×10^4 cells/cm^2. Forty-eight hours later, the supernatant was collected and passed through a 0.25 mm filter. The filtrate was finally defined as hepatocyte-injury conditioned medium and stored in aliquots at -20℃ for future use.

Induction of hepatogenic differentiation of mBM-MSCs in conditioned medium

The mBM-MSCs of passage 3 were inoculated in differentiation medium at 5×10^4 cells/cm^2 on culture flasks. The differentiation medium consisted of 50% fresh IMDM medium (Medium A) and 50% conditioned medium. As a negative control, mBM-MSCs were cultured in medium A only. Cells were cultured in a humidified atmosphere of 5% CO_2 and 95% air at 37℃. Cultures were maintained by medium exchange every 3 d. The cell morphology was observed under a confocal laser-scanning microscope (LSM 510; Carl Zeiss Inc., Jena, Germany).

Gene expression analysis by real-time polymerase chain reaction

The expressions of hepatic linage genes [α-fetoprotein (AFP), albumin (ALB), hepatocyte nuclear factor 3β (HNF3β), tyrosine aminotransferase (TAT)] and cytokine genes [fibroblast growth factor-4 (FGF-4), hepatocyte growth factor (HGF) and oncostatin M (OSM)] involved in hepatic differentiation and commitment were analyzed by real-time polymerase chain reaction (PCR). For this, total RNA was extracted from undifferentiated control or differentiated cells, normal or injured liver cells, respectively, using NucleoSpin® RNAIIKits, and then 5 μg of which was reversely transcribed into cDNA with SuperScript Ⅲ first-strand synthesis system (Invitrogen, Carlsbad, CA, USA) according to the manufacturer's instructions. The transcripts normalized to β-actin were measured by real-time PCR using Mastercyclerep realplex system and Real-Time Detection software (Eppendorf, Germany), in which the standard double-stranded DNA dye (SYBR Grean Ⅰ) was used. Gene-specific primers were designed using the Primer Premier software (Table 1).

Protein expression analysis by ELISA

The expressions of hepatic linage proteins (AFP and ALB) in differentiated hepatocytes and cytokine proteins (FGF-4, HGF and OSM) in injured liver cells were further analyzed by ELISA. The total proteins from differentiated cells or undifferentiated control cells, normal or injured liver cells were extracted using T-PER (a protein extraction reagent) (Qiagen, Germany) according to the manufacturer's manual, and were coated on a 96-well polystyrene plate at 4℃ overnight. The wells were washed with PBST (500 μL Tween 20/L PBS) and then blocked with 0.5% BSA for 1 h at 37℃. The hepatic linage proteins (AFP and ALB) or cytokines (FGF-4, HGF and OSM) were detected using the polyclonal antibodies, including rabbit anti-mouse HGF and FGF4, goat anti-mouse OSM (abcam, UK) rabbit anti-AFP and goat anti-ALB (Biodesign, Saco, Maine, USA) after washing with PBST for 3 times. The secondary antibodies, including goat anti-rabbit and rabbit anti-goat (Santa Cruz Biotechnology, Santa Cruz, CA, USA), labeled with horseradish peroxidase (HRP) were added at a proper dilution. Finally, the TMB was added, and the observation density was detected by a microplate reader at 450 nm after 2 mol/L sulphuric acid was added to stop the reaction.

Table 1 Primers and annealing temperatures used for PCR

Gene	Sequence (5′-3′)	Annealing (℃)	Product (bp)
AFP-F	CACTGCTGCAACTCTTCGTA	52	300
AFP-R	CTTTGGACCCTCTTCTGTGA		
HNF3b-F	GACCTCTTCCCTTTCTACCG	51	551
HNF3b-R	TTGAAGGCGTAATGGTGC		
ALB-F	TCTTCGTCTCCGGCTCTG	55	475
ALB-R	CTGGCAACTTCATGCAAAT		
TAT-F	CTTCAGTCCTGGATGTTCGC	55	619
TAT-R	CAGGGATTGGACGGGTTGTT		
FGF4-F	CTGGTGGCTCACAGGACAATAA GAT	62	483
FGF4-R	GCTGGCTGAAGAAACAGGTAAT AGGT		
HGF-F	GTGCCAACAGGTGTATCAG	62	399
HGF-R	TGTCACAGACTTCGTAGCG		
OSM-F	CTCACGGTCCACTACAACAC	62	123
OSM-R	GAGCCATCGTCCCATTCC		
β-actin-F	TTCCTTCTTGGGTATGGAAT	55	200
β-actin-R	GAGCAATGATCTTGATCTTC		

PCR: Polymerase chain reaction; AFP: α-fetoprotein; HNF: Hepatocyte nuclear factor; ALB: Albumin; TAT: Tyrosine aminotransferase; FGF-4: Fibroblast growth factor-4; HGF: Hepatocyte growth factor; OSM: Oncostatin M.

Periodic acid-Schiff stain for glycogen

The hepatic differentiation was functionally determined by glycogen storage. For this, the culture dishes containing differentiated cells were fixed in 95% alcohol for 10 min. Samples were then oxidized in 1% periodic acid for 5 min, rinsed three times in deionized (d) H_2O, treated with Schiff's reagent for 15 min, and rinsed in dH_2O for 5 min. Finally, the preparations were assessed under light microscope, and the positive rate of differentiated cells was counted as previously described[4].

Evaluation of urea synthesis

The hepatic differentiation was functionally determined by urea synthesis. The mBM-MSCs were plated at 5×10^4 cells/cm^2 on collagen coated six-well plates in differentiation medium or control medium. After washing extensively with PBS, cells differentiated at days 0, 4, 8, 16, 20 and 21 were incubated in 2 mL of serum-free Hanks' buffered salt solution containing 5 mmol/L NH_4Cl for 2 h at 37℃. After incubation, the urea concentrations in the supernatant were measured according to the method described previously[22].

Global evaluation of cytokines potentially involved in injured liver commitment

A global gene expression analysis was performed by microarray to identify the potential cytokines responsible for hepatic commitment. Total RNA and complementary DNA were prepared from CCl_4-treated and untreated mouse livers. An Illumina Mouse WG-6 v2.0 BeadChip

(Illumina, San Diego, CA, USA) was used to generate expression profiles of more than 48 000 transcripts with 500 ng of labelled cDNA for each sample, following manufacturer's recommended protocols. A randomized design was used to minimize chip effects. Four individuals were replicated in the two batches. Expression intensity was measured with an average of 30 beads for each transcript. The BeadChips were imaged with an Illumina BeadArray Reader. The raw intensities were extracted with the Gene Expression Module in Illumina's BeadStudio software. Expression intensities were log2 transformed and median-centered by subtracting the mean value of each array from each intensity value.

Cytokine identification in depletion experiment

The cytokines involved in hepatic specification in liver-injury conditioned medium were initially identified in a depletion experiment. The liver-injury conditioned medium was incubated with a number of different cytokine antibodies (anti-HGF, -FGF-4, -OSM, -FGF-3, -FGF-10, -FGF-12, -FGF-13, -FGF-14, -FGF-15, -FGF-17, -FGF-18, -FGF-20, -FGF-21, -bNGF, -IGF-1, -TGF-β1, -TGF-β2, and -TGF-β3, abcam and Biodesign) at different concentrations (1:100, 1:200 and 1:500) overnight at 4℃ under agitation. Then, the cytokines were removed by affinity co-immunoprecipitation. The protein A-coupled sepharose beads were prepared according to the manufacturer's instructions (Abcam), and were added into the antibody pretreated liver-injury conditioned medium. After being incubated at 4℃ for 4 h, the samples were centrifuged at 10 000 × *g* for 5 min. Supernatants were collected for hepatic differentiation induction assay. The hepatic differentiation was examined based on the hepatic lineage gene and protein expressions and functional characterizations as described above. In parallel, a non-specific rabbit antibody (IgG isotype) was used in control groups.

Cytokine identification in rescue experiment

To confirm the observation from depletion experiment that HGF, FGF-4 and OSM may be involved in hepatic differentiation in liver-injury conditioned medium, a rescue experiment was performed by adding back these three cytokines into the co-immunoprecipitated liver-injury conditioned medium. The liver-injury conditioned medium was pretreated with anti-HGF, anti-FGF-4 and anti-OSM, followed by protein A-coupled Sepharose beads as described above, and mouse FGF-4 (0, 1.25, 2.5, and 5 μg/mL), HGF (0, 2.5, 5 and 10 μg/mL) and OSM (0, 1.25, 2.5 and 5 μg/mL) (R&D Systems, Abingdon, UK) were added back to this medium to rescue its liver-inducing activity. The hepatic differentiation was examined based on the hepatic lineage gene and protein expressions and functional characterizations as described above.

Induction of hepatic differentiation by FGF-4, HGF and OSM

To further investigate the role of FGF-4, HGF and OSM in hepatic differentiation, an *in vitro* hepatic induction assay was conducted using different combinations of FGF-4, HGF and OSM. The mBM-MSCs were inoculated in medium A with different combinations of 10 ng/mL FGF-4, 20 ng/mL HGF and 10 ng/mL OSM[21] at 5×10^4 cells/cm^2 on culture flasks. As a negative control, the mBM-MSCs were cultured in medium A without FGF-4, HGF and OSM. Cells were cultured in a humidified atmosphere of 5% CO_2 and 95% air at 37℃. After 72 h, non-adherent cells and debris were removed and the adherent cells were cultured continuously. Cultures were maintained by medium exchange every 3 d. The hepatic differentiation was examined based on the hepatic lineage gene and protein expressions and functional characterizations as described above.

Statistical analysis

Statistical analysis was performed using the SPSS version 16.0, and data were expressed as mean ± SD. Differences between the values were determined by paired-samples *t* test. A value of $P < 0.05$ was considered statistically significant.

RESULTS

Evaluation of cytokines in response to liver injury

To evaluate the possible cytokines that participate in the hepatic differentiation of BM-MSCs under liver-injury conditions, the gene expression levels of cytokines/proteins in injured liver were initially examined at different injury time-points (12, 24 and 48 h) by microarray analysis. The results showed that more than 1200 genes were significantly up- or down-regulated during these time periods, and most of them were closely related to hepatocyte detoxification and metabolisms (data not shown). Totally, 40 cytokines/chemokines or their corresponding receptors closely associated with cellular growth, differentiation and migration were found to be significantly up-regulated (2-62 folds), among which 18 cytokines, including FGF-3, FGF-4, FGF-10, FGF-12, FGF-13, FGF-14, FGF-15, FGF-17, FGF-18, FGF-20, FGF-21, HGF, OSM, b-NGF, IGF-2, TGFβ-1, TGFβ-2 and TGFβ-3, were largely contributed to the hepatic growth and development. Therefore, these cytokines were considered to be potentially involved in the hepatic differentiation of mBM-MSCs under liver-injury conditions, and to be the candidates for further identification.

Cytokine identification in depletion experiment

Based on the microarray analysis as described above, the cytokine candidates were removed from the conditioned medium by a co-immunoprecipitation strategy using different combinations of specific antibodies which fall into several groups, designated as E1 (anti-FGF-3 and -FGF-4), E2 (anti-FGF-10, -FGF-12 and -FGF-13), E3 (anti-FGF-14, -FGF-15 and -FGF-17), E4 (anti-FGF-18, -FGF-20 and -FGF-21), E5 (anti-HGF, -OSM and -bNGF) and E6 (anti-IGF-1, -TGF-β1, -TGF-β2 and -TGF-β3). The conditioned medium from each group

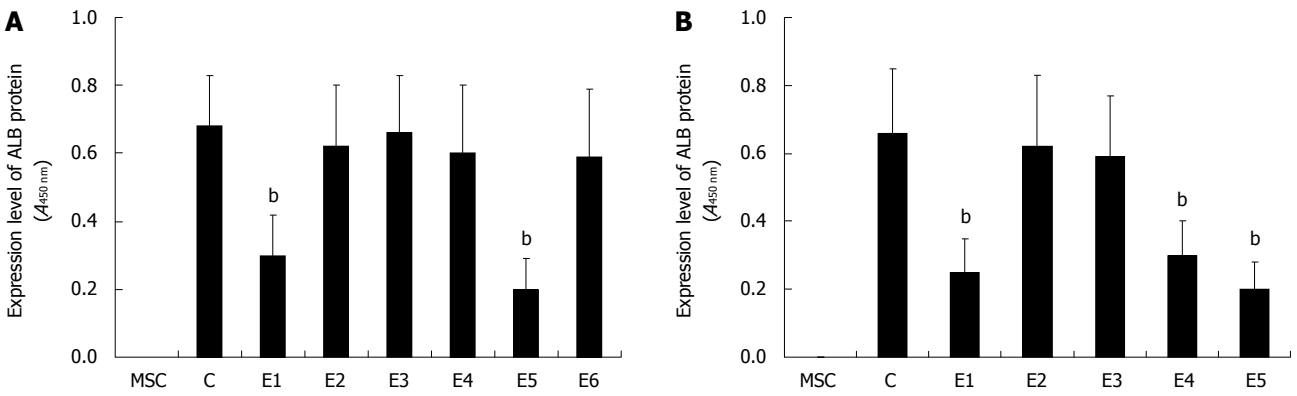

Figure 1 Analysis of albumin synthesis in cells for 20 d by ELISA ($A_{450\ nm}$). MSC group: Control MSCs cultured in medium A with PBS; C group: MSCs induced with liver-injury conditioned medium with nonspecific IgG; (A) E1-E6 groups: MSCs induced with liver-injury conditioned medium and different combinations of specific antibodies (E1: Anti-FGF-3 + anti-FGF-4; E2: Anti-FGF-10 + anti-FGF-12 + anti-FGF13; E3: Anti-FGF-14 + anti-FGF-15 + anti-FGF-17; E4: Anti-FGF-18 + anti-FGF-20 + anti-FGF-21; E5: Anti-HGF + anti-OSM + anti-bNGF; E6: Anti-IGF-1 + anti-TGF-β1 + anti-TGF-β2 + anti-TGF-β3); (B) E1-E5 groups: MSCs induced with liver-injury conditioned medium and different specific antibody lonely (E1: Anti-FGF-4; E2: Anti-FGF-3; E3: Anti-bNGF; E4: Anti-HGF; E5: Anti-OSM). $^{b}P < 0.01$ *vs* C group. ELISA: Enzyme-linked immunosorbent assay; MSC: Mesenchymal stem cells; PBS: Phosphate buffered saline; FGF: Fibroblast growth factor; HGF: Hepatocyte growth factor; OSM: Oncostatin M.

was used for further hepatic differentiation. The results showed that, after being induced for 20 d, the ALB in differentiated cells in E1 and E5 groups was more significantly down-regulated ($P < 0.01$) than that in the control group. However, no significant down-regulations of ALB could be observed in other experimental groups (E2, E3, E4 and E6), suggesting that FGF-3, FGF-4, HGF, OSM and bNGF in the conditioned medium examined in E1 and E5 groups may play essential roles in the hepatic differentiation of mBM-MSCs (Figure 1A). In an attempt to verify this observation, the FGF-3, FGF-4, HGF, OSM and bNGF were removed selectively: E1, anti-FGF-4; E2, anti-FGF-3; E3, anti-bNGF; E4, anti-HGF; and E5, anti-OSM. The hepatic differentiation of mBM-MSCs in each group was detected and the results showed that the ALB in differentiated cells in E1, E4 and E5 groups was significantly down-regulated ($P < 0.01$) compared with that in the control group. However, no significant down-regulations of ALB could be observed in E2 and E3 groups (Figure 1B). These results indicated that FGF-4, HGF and OSM are key factors involved in the hepatic differentiation of mBM-MSCs. This observation seems in accordance with some previous reports showing that FGF-4, HGF and OSM played important roles in liver healing, regeneration and initiation of development[23-26].

Expression analysis of FGF-4, HGF and OSM during liver injury

To obtain a deep insight into the role of FGF-4, HGF and OSM in liver injury, a kinetic expression analysis of these cytokines during liver injury was performed. The results showed that the expression of HGF mRNA was significantly up-regulated at 6 h after injury ($P < 0.05$), peaked at 12 h ($P < 0.01$) and kept in high level up to 72 h (Figure 2A). Similarly, the expressions of FGF-4 and OSM mRNAs were importantly up-regulated at 12 h ($P < 0.01$) after injury, peaked in 24-48 h ($P < 0.01$) and also kept in high levels up to 72 h (Figure 2B and C). Accordingly, the expression changes of HGF, FGF-4 and OSM proteins were generally identical with their mRNA expressions (Figure 2D-F).

Detection of FGF-4, HGF and OSM in culture medium

To further investigate the existence and occurrence of FGF-4, HGF and OSM in liver-injury conditioned medium, the kinetic secretion of FGF-4, HGF and OSM into the cultured medium was determined. The results showed that the concentrations of HGF and OSM proteins were dramatically up-regulated at 12 h after culture, peaked at 24 or 48 h and kept in high levels up to 72 h (Figure 3A and C); while the FGF-4 was significantly up-regulated at 24 h and peaked at 48 h (Figure 3B). Notably, it showed that FGF-4, HGF and OSM protein expressions could also be detected in the cell culture without undergoing liver injury (Figure 3), possibly due to the fact that isolation of cells from liver itself is a tissue "anatomy" which may result in the "injured signal" to stimulate the cells to secrete cytokines.

Effects of FGF-4, HGF and OSM in hepatic differentiation

To investigate the effects of each cytokine in the hepatic differentiation, a number of depletion experiments were conducted using different combinations of antibodies. The results showed that after treatment with anti-FGF-4 and anti-HGF independently, the hepatic differentiation induced by the conditioned medium was significantly ($P < 0.01$) down-regulated with the increased use of antibody (E1: 1:500, E2: 1:200, E3: 1:100) as determined by the expression of both the early liver-specific marker (HNF3β and AFP) and the late liver-specific marker (ALB and TAT) at mRNA or protein levels, and by the functional [Periodic acid-Schiff (PAS) and urea production] analyses (Figure 4A-H). However, after treatment with anti-OSM alone, the expressions of HNF3β and AFP in cells were not significantly decreased (Figure 4A and B), while the expressions of ALB and TAT were dramatically ($P < 0.01$)

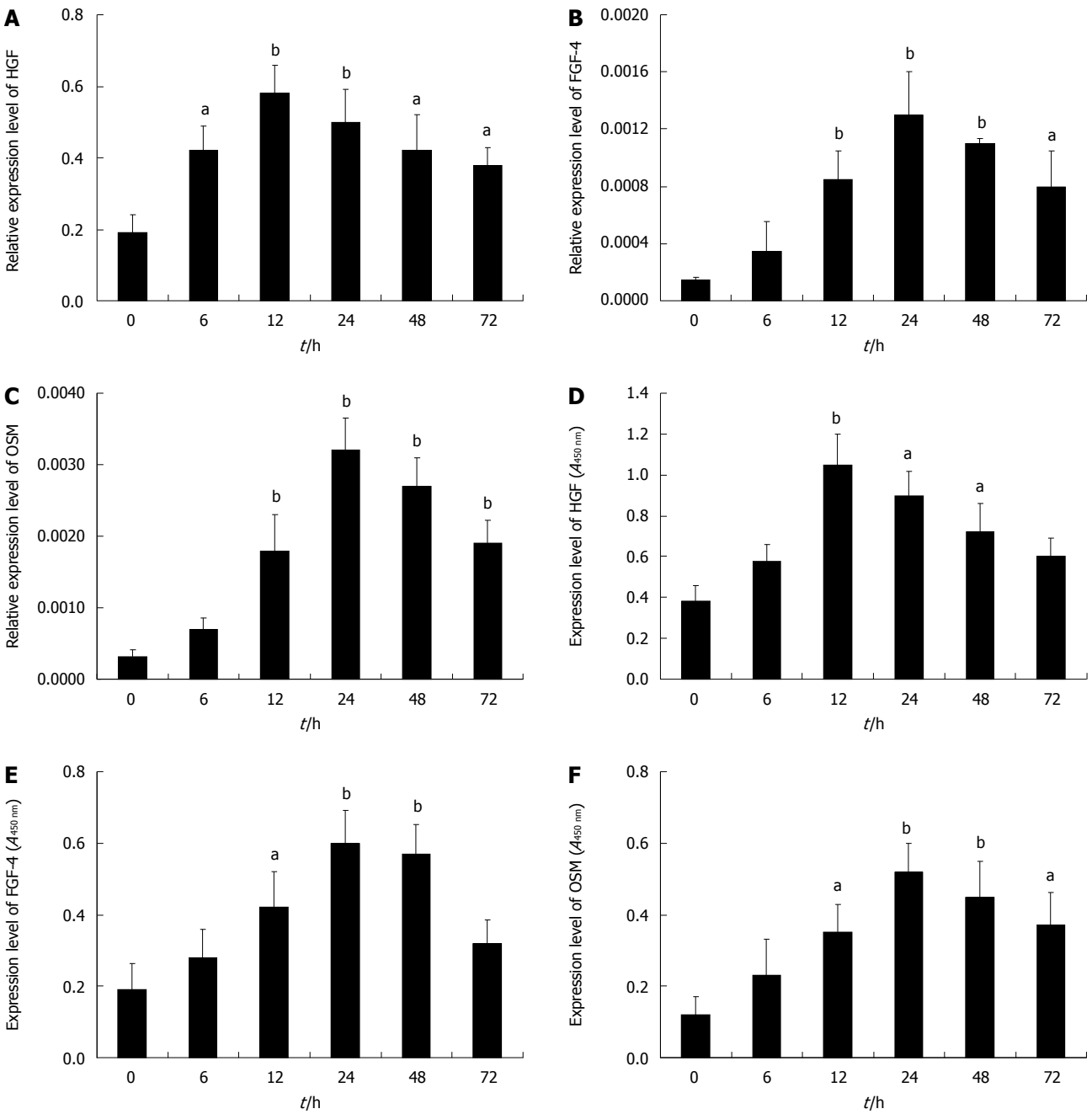

Figure 2 Expression analyses of FGF-4, HGF and OSM during liver injury. A-C: The kinetic expression of FGF-4, HGF and OSM mRNAs detected by real-time PCR during liver injury; D-F: The kinetic expression of FGF-4, HGF and OSM proteins detected by ELISA during liver injury. $^{a}P < 0.05$, $^{b}P < 0.01$ *vs* 0 h.

restrained at both mRNA and protein levels (Figure 4C, D and F). Accordingly, the PAS and urea production were also dramatically ($P < 0.01$) decreased in anti-OSM treatment groups (Figure 4G and H). These results suggested that FGF-4, HGF and OSM may play different roles in the hepatic differentiation of mBM-MSCs. Among these factors, FGF-4 and HGF may be essential for the initiation of early hepatic differentiation, while OSM may be critical for the maturation of hepatocytes.

Functional evaluation of FGF-4, HGF and OSM in rescue experiment

In order to find further evidence on the role of FGF-4, HGF and OSM in the conditioned medium in hepatic differentiation, we performed a rescue experiment in which three recombinant cytokines were added back to the cytokine-removed medium treated with anti-FGF-4 (1:100), anti-HGF (1:100) and anti-OSM (1:100). The results showed that administration of FGF-4, HGF and OSM into this cytokine-removed medium could significantly rescue the hepatic differentiation with the increased concentrations of the cytokines as determined by the expression of ALB protein and urea synthesis (E1: 0 ng/mL FGF-4 + 0 ng/mL HGF + 0 ng/mL OSM; E2: 1.25 ng/mL FGF-4 + 2.5 ng/mL HGF + 1.25 ng/mL OSM; E3: 2.5 ng/mL FGF-4 + 5 ng/mL HGF + 2.5 ng/mL OSM;

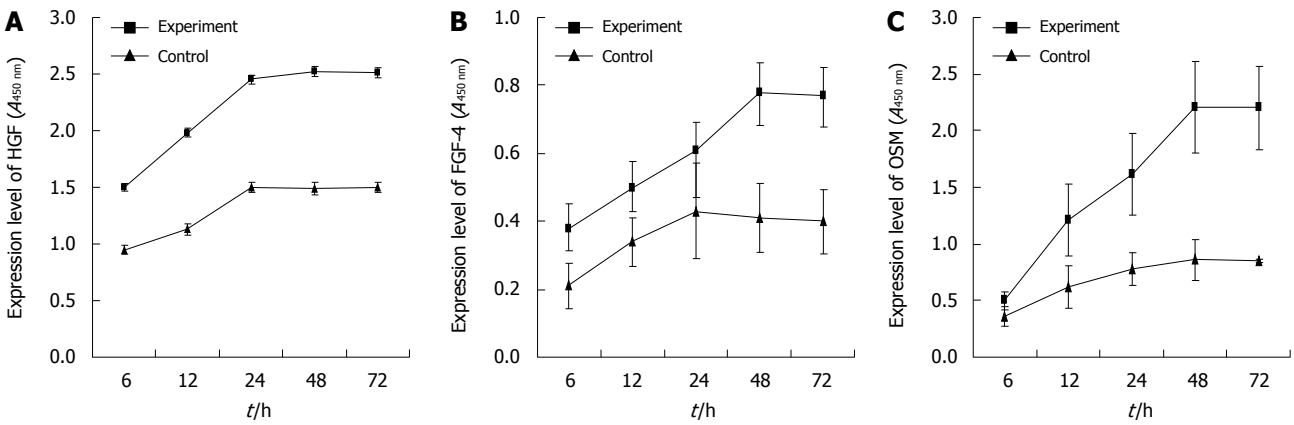

Figure 3 Detection of kinetic secretions of HGF (A), FGF-4 (B) and OSM (C) proteins in liver-injury conditioned medium. Experiment: Hepatocyte-injury conditioned medium; Control: Normal-hepatocyte conditioned medium.

E4: 5 ng/mL FGF-4 + 10 ng/mL HGF + 5 ng/mL OSM) (Figure 5A and B). These results provided solid support that FGF-4, HGF and OSM are the key cytokines that contribute to the induction of hepatic differentiation in the liver-injury conditioned medium.

Hepatic differentiation induced directly by FGF-4, HGF and OSM

Based on the observations from the above experiments that FGF-4, HGF and OSM are crucial for hepatic differentiation in the conditioned medium, we performed a further hepatic differentiation experiment induced directly by FGF-4, HGF and OSM in different combinations. The results showed that FGF-4, HGF and OSM may have synergistic effects on the hepatic differentiation of mBM-MSCs, indicating that the three cytokines may play different roles in the induction of hepatic differentiation. As shown in Figure 6, after induced with a factor alone or combination of the two, the hepatic differentiation of mBM-MSCs was lowly detectable as determined by the synthesis of both AFP (early hepatic differentiation marker) and ALB (late hepatic differentiation marker) in differentiated cells. In the group induced with FGF-4 (10 ng/mL) and HGF (20 ng/mL, E4), the concentration of AFP was highly detectable, while ALB was lowly detectable, suggesting that FGF-4 and HGF have a synergistic effect on the initiation of early hepatic differentiation. In contrast, both of the AFP and ALB proteins could be highly detected in group E5 in which the mBM-MSCs were induced by the combination of these three factors. This indicated that FGF-4, HGF and OSM had a synergistic effect in the differentiation of functional hapatocytes from mBM-MSCs. Furthermore, FGF-4 and HGF exhibited a cooperative effect on the early hepatic differentiation of mBM-MSCs, while OSM is essential to the maturation of hepatocytes in the late hepatic differentiation.

DISCUSSION

Mesenchymal stem cells (MSCs) have emerged as a promising resource of functional hepatocytes for treatment of liver diseases because of its plasticity of multiple cell lineages. To date, many inducing systems for hepatic differentiation from MSCs have been developed[22,27,28]. However, the rate of hepatocyte-like cells differentiated from MSCs is still very low and the mechanisms are also not well known. It is undoubted that exposition of MSCs to the inducing systems, resembling the conditions in liver development, injury and regeneration, could acquire a more efficient differentiation[29]. Our previous studies have shown that mBM-MSCs could be induced to differentiate into hepatic cells by conditioned culture medium of hepatocytes[4]. Thus identification of the exact cytokines involved in liver-injury conditions for the mBM-MSCs differentiation needed further studies. This study provides such investigation. Eighteen cytokines closely related to liver growth, repair and development were chosen as candidates from numerous up-regulated cytokine genes by microarray. It was found that three cytokines (FGF-4, HGF and OSM) may play a crucial role in the conditioned medium-induced hepatic differentiation, since hepatic differentiation was dramatically decreased after removing FGF-4, HGF and OSM from the conditioned medium. Therefore, the present study provided a direct basis on the selection of cytokines for hepatic differentiation. However, besides these three key cytokines, some other factors involved in the liver injury need to be identified for improving the cytokine-based inducing system.

FGF-4, HGF and OSM play important roles in liver regeneration, healing, initiation and development. FGF-4 was considered to be one of the most important fibroblast growth factor family members that can irritate the proliferation of mesodermal and endodermal cells and improve development of fetal liver[30]. HGF was found to be essential for the development of several epithelial organs and was one of the most well characterized cytokine for the stimulation of DNA synthesis in primary hepatocyte cultures, and for liver development[31]. The OSM, however, is a member of the interleukin-6 family produced by hematopoietic cells and induces differentiation of fetal hepatic cells, conferring various metabolic activities of

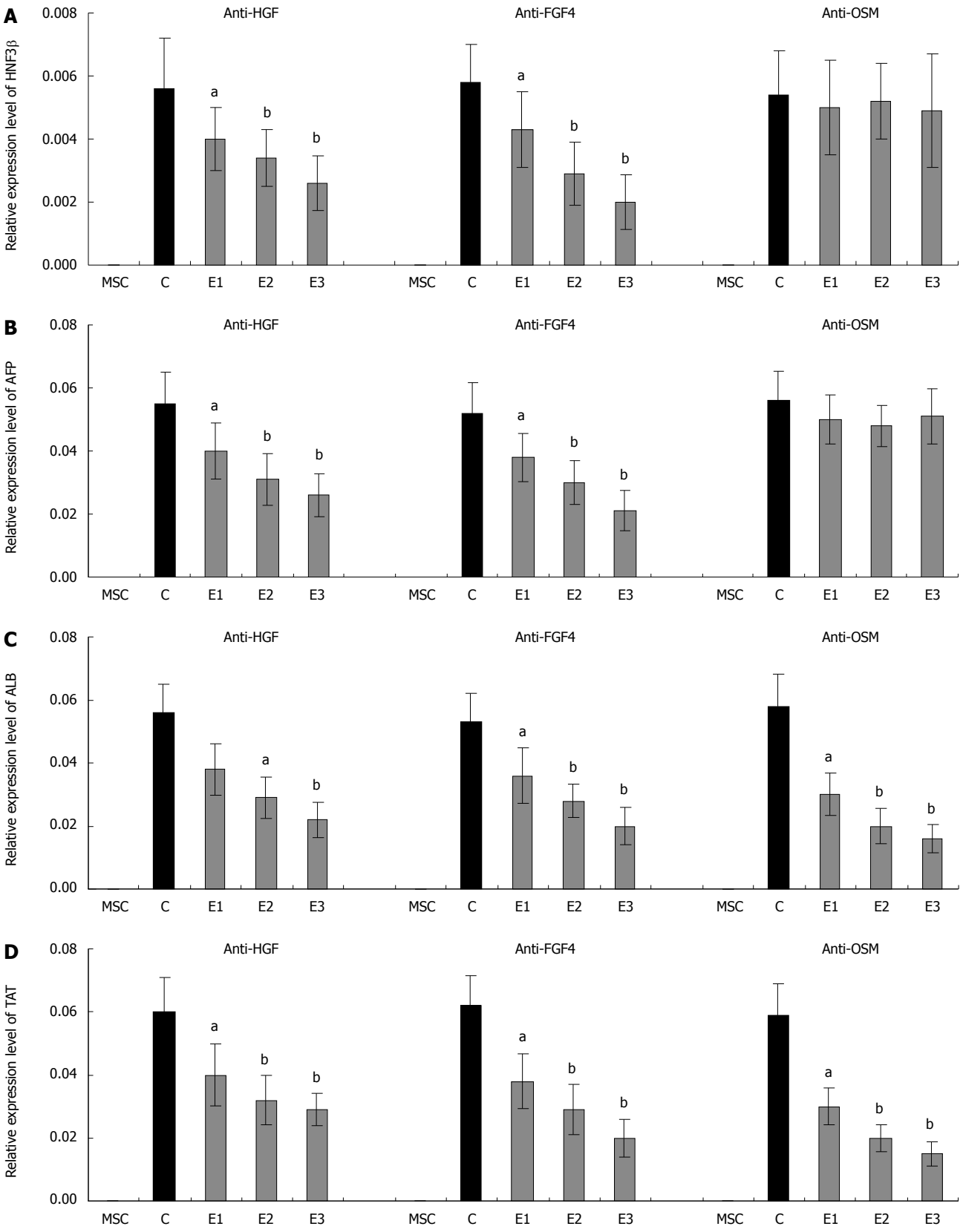
A
Relative expression level of HNF3β
0.008
0.006
0.004
0.002
0.000
Anti-HGF
Anti-FGF4
Anti-OSM
a
b
b
a
b
b
MSC
C
E1
E2
E3
B
Relative expression level of AFP
0.08
0.06
0.04
0.02
0.00
C
Relative expression level of ALB
D
Relative expression level of TAT

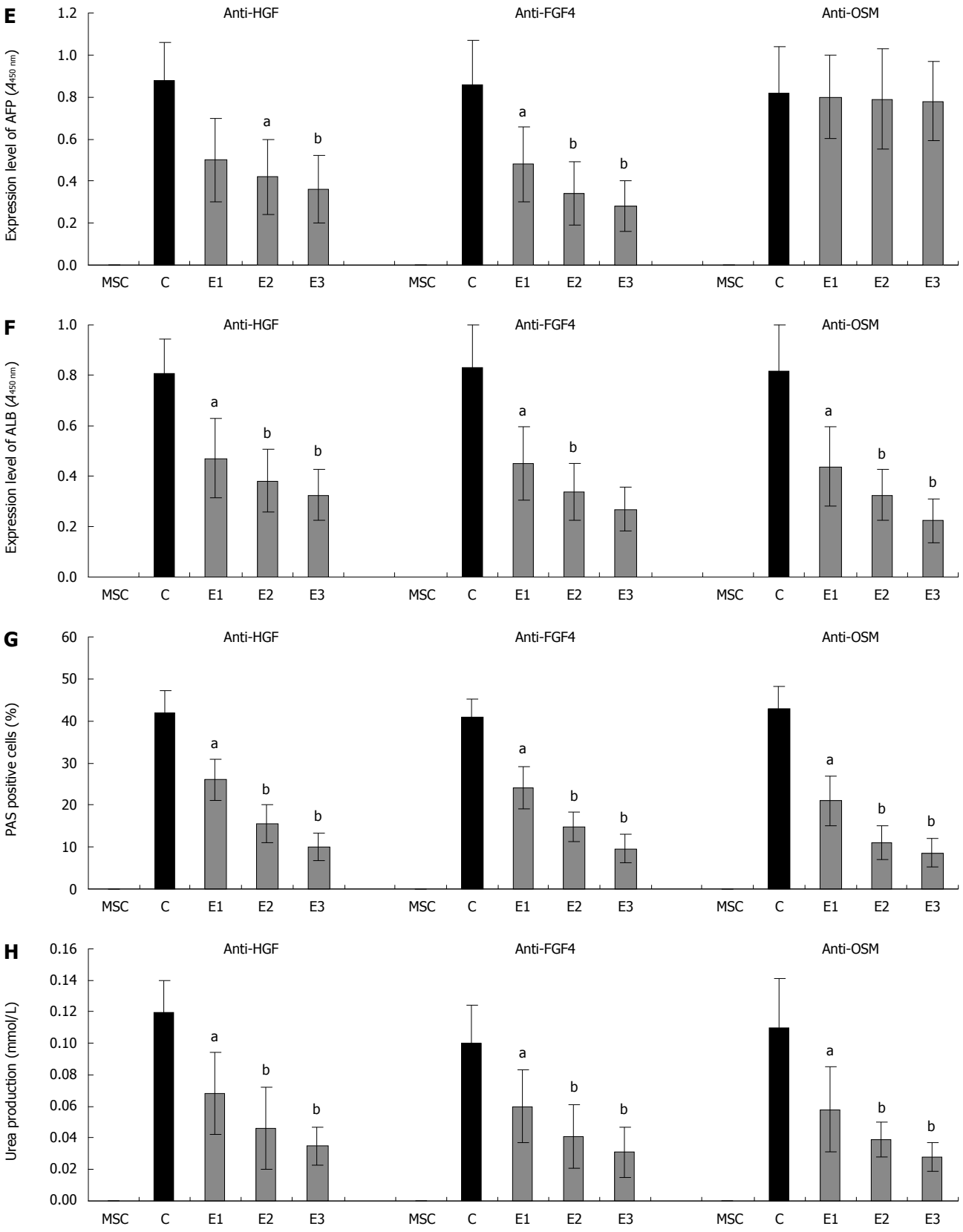

Figure 4 Effects of FGF-4, HGF and OSM in hepatic differentiation. A number of depletion experiments using different combination of antibodies were conducted, and the expression of both liver-specific markers and function was analyzed. A-D: The expression of both the early liver-specific markers (HNF3β and AFP) 10 d after induction and the late liver-specific markers 20 d after induction (ALB and TAT) at mRNA levels detected by real-time PCR; E, F: The expression of AFP 10 d after induction and ALB 20 d after induction at protein levels detected by ELISA; G: Analysis of intracellular glycogen accumulation by PAS staining on day 20 after induction; H: Urea production by differentiated cells on day 20 after induction. MSC group: Control MSCs cultured in medium A with PBS; C group: MSCs induced with liver-injury conditioned medium with non-specific IgG; E1-E3 groups: MSCs induced with liver-injury conditioned medium and different concentrations of specific antibodies (E1: 1:500; E2: 1:200; E3:1:100). $^{a}P < 0.05$, $^{b}P < 0.01$ *vs* C group.

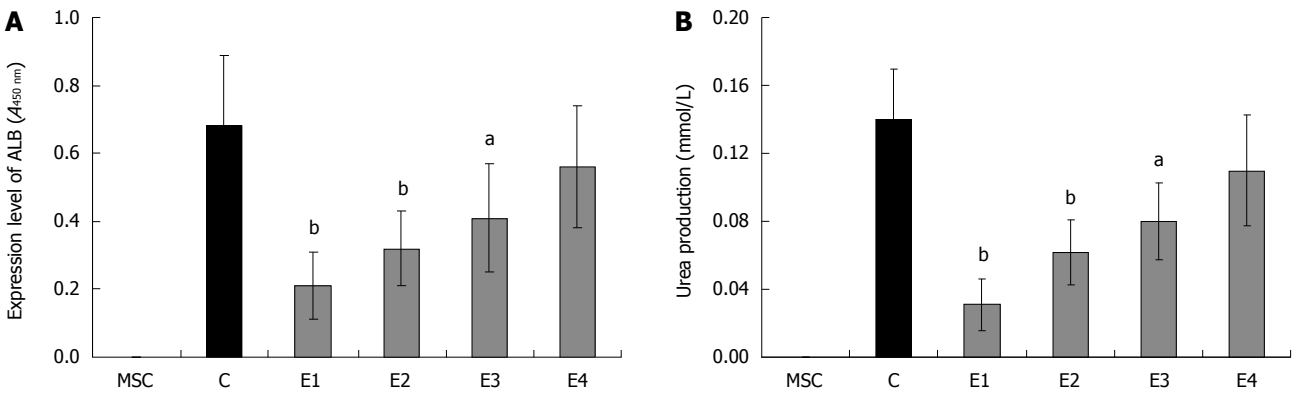

Figure 5 ALB and urea production detection on day 20 after induction in a rescue experiment in which FGF-4, HGF and OSM were added back to the cytokine-removed medium treated with anti-FGF-4 (1:100), anti-HGF (1:100) and anti-OSM (1:100). A: Analysis of albumin secretion by ELISA; B: Urea production was measured using a colorimetric assay kit. MSC group: Control MSCs cultured in medium A with PBS; C group: MSCs induced with liver-injury conditioned medium only; E1-E4: MSCs induced with liver-injury conditioned medium including anti-FGF-4 (1:100), anti-HGF (1:100) and anti-OSM (1:100), as well as different concentrations of the cytokines (E1: 0 ng/mL FGF-4 + 0 ng/mL HGF + 0 ng/mL OSM; E2: 1.25 ng/mL FGF-4 + 2.5 ng/mL HGF + 1.25 ng/mL OSM; E3: 2.5 ng/mL FGF-4 + 5 ng/mL HGF + 2.5 ng/mL OSM; E4: 5 ng/mL FGF-4 + 10 ng/mL HGF + 5 ng/mL OSM). $^{a}P < 0.05$, $^{b}P < 0.01$ *vs* C group.

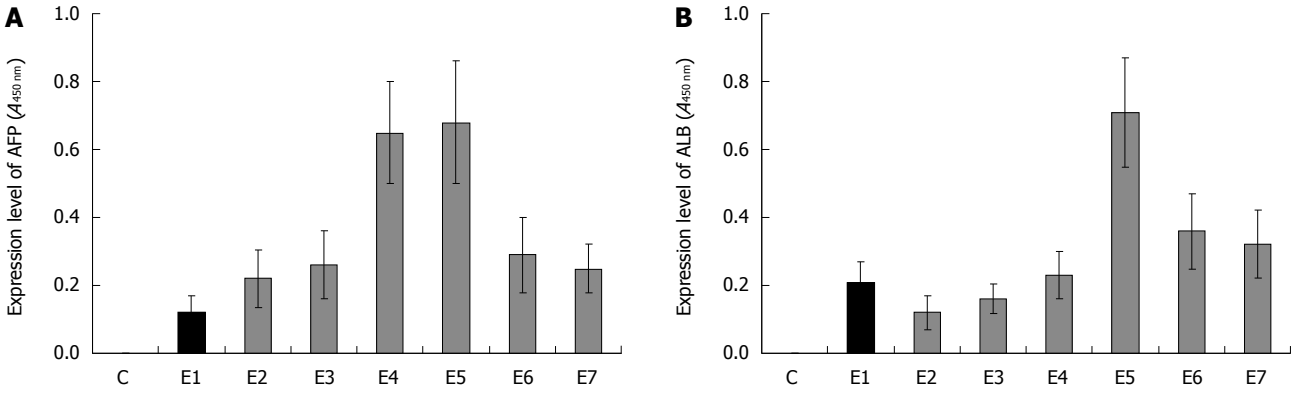

Figure 6 Hepatic differentiation induced directly by different combinations of FGF-4, HGF and OSM. A: Analysis of AFP synthesis by ELISA on day 10; B: Analysis of albumin synthesis by ELISA on day 20. C group: MSCs induced with medium A and PBS; E1-E7: MSCs induced with different combinations of FGF-4, HGF and OSM (E1: OSM 10 ng/mL; E2: HGF 20 ng/mL; E3: FGF-4 10 ng/mL; E4: HGF 20 ng/mL + FGF-4 10 ng/mL; E5: HGF 20 ng/mL + FGF-4 10 ng/mL + OSM 10 ng/mL; E6: FGF-4 10 ng/mL + OSM 10 ng/mL; E7: HGF 20 ng/mL + OSM 10 ng/mL).

adult liver[32]. These three factors participate in different liver developmental stages. Thus, we further examined the exact roles of FGF-4, HGF and OSM in the hepatic differentiation from mBM-MSCs. It clearly showed that after removing FGF-4 and HGF from the conditioned medium by their antibodies, either the early or the late hepatic differentiation induced by the conditioned medium could be significantly down-regulated, while after removing OSM from the conditioned medium, only the late hepatic differentiation was down-regulated. It suggested that FGF-4, HGF and OSM also play different roles in the hepatic differentiation of mBM-MSCs, and FGF-4 and HGF are essential for the initiation of hepatic differentiation, while OSM is critical for the maturation of hepatocytes.

In conclusion, the present study analyzed the potential factors in injured liver for hepatic differentiation from mBM-MSCs. It was found that FGF-4, HGF and OSM might be the key cytokines. They played different roles during hepatic differentiation, which is similar to their functions in liver development. Hopefully, our study would not only provide evidence of cytokine selection for hepatic differentiation, but also benefit the exploration of the molecular mechanisms underlying the differentiation of BM-MSCs into hepatocytes.

COMMENTS

Background

Acute liver failure is a severe liver disease with a mortality of 60%-90%. The only therapeutic option, orthotopic liver transplantation, is limited because of the shortage of suitable donor organs. Mesenchymal stem cells (MSCs), known for their capacity to proliferate indefinitely and differentiate into almost all types of cells, including hepatocytes, have provided the hope of cellular replacement therapy for liver failure.

Research frontiers

Mouse liver-injury conditioned culture medium dramatically facilitated the differentiation of mouse bone marrow MSCs (mBM-MSCs) into functional hepatic cells. However, which cytokines direct hepatic fate specification of mBM-MSCs still remains unclear. In this study, the authors demonstrate that fibroblast growth factor-4 (FGF-4), hepatocyte growth factor (HGF) and oncostatin M (OSM) may play crucial roles in the differentiation of mBM-MSCs in the liver-injury conditioned medium.

Innovations and breakthroughs

In the present study, the authors reported the identification of cytokines involved in hepatic fate specification of mBM-MSCs in the liver-injury conditioned medium. By removing cytokines from conditioned medium and adding back cytokines into the "cytokine-removed" conditioned medium, it was demonstrated that FGF-4, HGF and OSM may play crucial roles in the conditioned medium-induced hepatic differentiation. Furthermore, different combinations of FGF-4, HGF and OSM were used to induce hepatic differentiation, and the result showed that FGF-4 and HGF had a cooperative effect on the early hepatic differentiation of mBM-MSCs, while OSM was essential to the maturation of hepatocytes in the late hepatic differentiation. This is the first study to report that FGF-4, HGF and OSM FGF-4, HGF and OSM not only play crucial roles in the hepatic differentiation of mBM-MSCs, but also have profound synergistic effect on the hepatic differentiation of mBM-MSCs pro and con. This *in vitro* study would contribute to the improvement of hepatic cell resource for cell-based therapies for acute and chronic end-stage liver diseases and provide a model for more detailed characterization on the molecular mechanisms underlying the differentiation of BM-MSCs into hepatocytes.

Applications

This study may benefit not only the better understanding of novel mechanisms underlying BM-MSCs involved in liver repair and regeneration, but also the improvement of cytokine-based hepatic inducing strategy, in which a rich cellular resource for cytotherapy of acute liver diseases with BM-MSCs would be provided.

Terminology

FGF-4 is one of the most important fibroblast growth factor family members that can irritate the proliferation of mesodermal and endodermal cells and improve development of fetal liver; HGF is one of the most well characterized cytokines for the stimulation of DNA synthesis in primary hepatocyte cultures and liver development; OSM is a member of the interleukin-6 family which is produced by hematopoietic cells and induces differentiation of fetal hepatic cells, conferring various metabolic activities of adult liver.

Peer review

The authors corroborate that 3 cytokines (HGF, FGF4 and OSM) are fundamental for directing the differentiation of BM-MSCs towards hepatocytes. The work is interesting and could be helpful for developing effective inducing systems of hepatic differentiation from BM-MSCs.

REFERENCES

1 **Bianco P**, Robey PG, Simmons PJ. Mesenchymal stem cells: revisiting history, concepts, and assays. *Cell Stem Cell* 2008; **2**: 313-319

2 **Jiang Y**, Jahagirdar BN, Reinhardt RL, Schwartz RE, Keene CD, Ortiz-Gonzalez XR, Reyes M, Lenvik T, Lund T, Blackstad M, Du J, Aldrich S, Lisberg A, Low WC, Largaespada DA, Verfaillie CM. Pluripotency of mesenchymal stem cells derived from adult marrow. *Nature* 2002; **418**: 41-49

3 **Bianco P**, Riminucci M, Gronthos S, Robey PG. Bone marrow stromal stem cells: nature, biology, and potential applications. *Stem Cells* 2001; **19**: 180-192

4 **Chen Y**, Dong XJ, Zhang GR, Shao JZ, Xiang LX. In vitro differentiation of mouse bone marrow stromal stem cells into hepatocytes induced by conditioned culture medium of hepatocytes. *J Cell Biochem* 2007; **102**: 52-63

5 **Chen Y**, Shao JZ, Xiang LX, Dong XJ, Zhang GR. Mesenchymal stem cells: a promising candidate in regenerative medicine. *Int J Biochem Cell Biol* 2008; **40**: 815-820

6 **Phinney DG**, Prockop DJ. Concise review: mesenchymal stem/multipotent stromal cells: the state of transdifferentiation and modes of tissue repair--current views. *Stem Cells* 2007; **25**: 2896-2902

7 **Black IB**, Woodbury D. Adult rat and human bone marrow stromal stem cells differentiate into neurons. *Blood Cells Mol Dis* 2001; **27**: 632-636

8 **Hermann A**, Gastl R, Liebau S, Popa MO, Fiedler J, Boehm BO, Maisel M, Lerche H, Schwarz J, Brenner R, Storch A. Efficient generation of neural stem cell-like cells from adult human bone marrow stromal cells. *J Cell Sci* 2004; **117**: 4411-4422

9 **Cheng Z**, Ou L, Zhou X, Li F, Jia X, Zhang Y, Liu X, Li Y, Ward CA, Melo LG, Kong D. Targeted migration of mesenchymal stem cells modified with CXCR4 gene to infarcted myocardium improves cardiac performance. *Mol Ther* 2008; **16**: 571-579

10 **Wang Y**, Deng Y, Zhou GQ. SDF-1alpha/CXCR4-mediated migration of systemically transplanted bone marrow stromal cells towards ischemic brain lesion in a rat model. *Brain Res* 2008; **1195**: 104-112

11 **Zhao J**, Zhang N, Prestwich GD, Wen X. Recruitment of endogenous stem cells for tissue repair. *Macromol Biosci* 2008; **8**: 836-842

12 **Zhang D**, Fan GC, Zhou X, Zhao T, Pasha Z, Xu M, Zhu Y, Ashraf M, Wang Y. Over-expression of CXCR4 on mesenchymal stem cells augments myoangiogenesis in the infarcted myocardium. *J Mol Cell Cardiol* 2008; **44**: 281-292

13 **Sasaki M**, Abe R, Fujita Y, Ando S, Inokuma D, Shimizu H. Mesenchymal stem cells are recruited into wounded skin and contribute to wound repair by transdifferentiation into multiple skin cell type. *J Immunol* 2008; **180**: 2581-2587

14 **Morigi M**, Introna M, Imberti B, Corna D, Abbate M, Rota C, Rottoli D, Benigni A, Perico N, Zoja C, Rambaldi A, Remuzzi A, Remuzzi G. Human bone marrow mesenchymal stem cells accelerate recovery of acute renal injury and prolong survival in mice. *Stem Cells* 2008; **26**: 2075-2082

15 **Wu Y**, Chen L, Scott PG, Tredget EE. Mesenchymal stem cells enhance wound healing through differentiation and angiogenesis. *Stem Cells* 2007; **25**: 2648-2659

16 **Sackstein R**, Merzaban JS, Cain DW, Dagia NM, Spencer JA, Lin CP, Wohlgemuth R. Ex vivo glycan engineering of CD44 programs human multipotent mesenchymal stromal cell trafficking to bone. *Nat Med* 2008; **14**: 181-187

17 **Oyagi S**, Hirose M, Kojima M, Okuyama M, Kawase M, Nakamura T, Ohgushi H, Yagi K. Therapeutic effect of transplanting HGF-treated bone marrow mesenchymal cells into CCl4-injured rats. *J Hepatol* 2006; **44**: 742-748

18 **Wang Y**, Johnsen HE, Mortensen S, Bindslev L, Ripa RS, Haack-Sørensen M, Jørgensen E, Fang W, Kastrup J. Changes in circulating mesenchymal stem cells, stem cell homing factor, and vascular growth factors in patients with acute ST elevation myocardial infarction treated with primary percutaneous coronary intervention. *Heart* 2006; **92**: 768-774

19 **Jin HK**, Carter JE, Huntley GW, Schuchman EH. Intracerebral transplantation of mesenchymal stem cells into acid sphingomyelinase-deficient mice delays the onset of neurological abnormalities and extends their life span. *J Clin Invest* 2002; **109**: 1183-1191

20 **Chen Y**, Xiang LX, Shao JZ, Pan RL, Wang YX, Dong XJ, Zhang GR. Recruitment of endogenous bone marrow mesenchymal stem cells towards injured liver. *J Cell Mol Med* 2009; Epub ahead of print

21 **Chen Y**, Pan RL, Zhang XL, Shao JZ, Xiang LX, Dong XJ, Zhang GR. Induction of hepatic differentiation of mouse bone marrow stromal stem cells by the histone deacetylase inhibitor VPA. *J Cell Mol Med* 2009; **13**: 2582-2592

22 **Pan RL**, Chen Y, Xiang LX, Shao JZ, Dong XJ, Zhang GR. Fetal liver-conditioned medium induces hepatic specification from mouse bone marrow mesenchymal stromal cells: a novel strategy for hepatic transdifferentiation. *Cytotherapy* 2008; **10**: 668-675

23 **Lee KD**, Kuo TK, Whang-Peng J, Chung YF, Lin CT, Chou SH, Chen JR, Chen YP, Lee OK. In vitro hepatic differentiation of human mesenchymal stem cells. *Hepatology* 2004; **40**: 1275-1284

24 **Kang XQ**, Zang WJ, Song TS, Xu XL, Yu XJ, Li DL, Meng KW, Wu SL, Zhao ZY. Rat bone marrow mesenchymal stem cells differentiate into hepatocytes in vitro. *World J Gastroenterol* 2005; **11**: 3479-3484

25 **Ong SY**, Dai H, Leong KW. Hepatic differentiation potential of commercially available human mesenchymal stem cells. *Tissue Eng* 2006; **12**: 3477-3485

26 **Ong SY**, Dai H, Leong KW. Inducing hepatic differentiation

of human mesenchymal stem cells in pellet culture. *Biomaterials* 2006; **27**: 4087-4097

27 **Snykers S**, Vanhaecke T, De Becker A, Papeleu P, Vinken M, Van Riet I, Rogiers V. Chromatin remodeling agent trichostatin A: a key-factor in the hepatic differentiation of human mesenchymal stem cells derived of adult bone marrow. *BMC Dev Biol* 2007; **7**: 24

28 **Aurich H**, Sgodda M, Kaltwasser P, Vetter M, Weise A, Liehr T, Brulport M, Hengstler JG, Dollinger MM, Fleig WE, Christ B. Hepatocyte differentiation of mesenchymal stem cells from human adipose tissue in vitro promotes hepatic integration in vivo. *Gut* 2009; **58**: 570-581

29 **Snykers S**, Vanhaecke T, Papeleu P, Luttun A, Jiang Y, Vander Heyden Y, Verfaillie C, Rogiers V. Sequential exposure to cytokines reflecting embryogenesis: the key for in vitro differentiation of adult bone marrow stem cells into functional hepatocyte-like cells. *Toxicol Sci* 2006; **94**: 330-341; discussion 235-239

30 **Rappolee DA**, Basilico C, Patel Y, Werb Z. Expression and function of FGF-4 in peri-implantation development in mouse embryos. *Development* 1994; **120**: 2259-2269

31 **Schmidt C**, Bladt F, Goedecke S, Brinkmann V, Zschiesche W, Sharpe M, Gherardi E, Birchmeier C. Scatter factor/hepatocyte growth factor is essential for liver development. *Nature* 1995; **373**: 699-702

32 **Miyajima A**, Kinoshita T, Tanaka M, Kamiya A, Mukouyama Y, Hara T. Role of Oncostatin M in hematopoiesis and liver development. *Cytokine Growth Factor Rev* 2000; **11**: 177-183

S- Editor Wang YR **L- Editor** Ma JY **E- Editor** Ma WH

World Journal of Gastroenterology

Online Submissions: http://www.wjgnet.com/1007-9327office
wjg@wjgnet.com
doi:10.3748/wjg.v16.i26.3279

World J Gastroenterol 2010 July 14; 16(26): 3279-3286
ISSN 1007-9327 (print)
© 2010 Baishideng. All rights reserved.

ORIGINAL ARTICLE

Randomized controlled trial of minimally invasive surgery using acellular dermal matrix for complex anorectal fistula

Ma-Mu-Ti-Jiang A ba-bai-ke-re, Hao Wen, Hong-Guo Huang, Hui Chu, Ming Lu, Zhong-Sheng Chang, Er-Ha-Ti Ai, Kai Fan

Ma-Mu-Ti-Jiang A ba-bai-ke-re, Hong-Guo Huang, Hui Chu, Ming Lu, Zhong-Sheng Chang, Er-Ha-Ti Ai, Kai Fan, Anorectal Surgical Department, First Affiliated Hospital of Xinjiang Medical University, Urumqi 830011, Xinjiang Uygur Autonomous Region, China

Hao Wen, Digestive and Vascular Surgical Center, First Affiliated Hospital, Xinjiang Medical University, Urumqi 830011, Xinjiang Uygur Autonomous Region, China

Author contributions: Wen H contributed to the conception and design of the study, and revised the article (critically important intellectual content); A ba-bai-ke-re MMTJ contributed to the research, study design, intervention control, recording, data collection and final approval of the article; Huang HG, Fan K, Lu M, Chang ZS and Ai EHT analyzed and interpreted the data; Chu H drafted the article.

Correspondence to: Hao Wen, MD, PhD, Digestive and Vascular Surgical Center, First Affiliated Hospital of Xinjiang Medical University, Urumqi 830011, Xinjiang Uygur Autonomous Region, China. mamutjan206@sina.com

Telephone: +86-991-4366142 Fax: +86-991-4366062

Received: May 13, 2010 Revised: May 31, 2010
Accepted: June 7, 2010
Published online: July 14, 2010

Abstract

AIM: To compare the efficacy and safety of acellular dermal matrix (ADM) bioprosthetic material and endorectal advancement flap (ERAF) in treatment of complex anorectal fistula.

METHODS: Ninety consecutive patients with complex anorectal fistulae admitted to Anorectal Surgical Department of First Affiliated Hospital, Xinjiang Medical University from March 2008 to July 2009, were enrolled in this study. Complex anorectal fistula was diagnosed following its clinical, radiographic, or endoscopic diagnostic criteria. Under spinal anesthesia, patients underwent identification and irrigation of the fistula tracts using hydrogen peroxide. ADM was securely sutured at the secondary opening to the primary opening using absorbable suture. Outcomes of ADM and ERAF closure were compared in terms of success rate, fecal incontinence rate, anorectal deformity rate, postoperative pain time, closure time and life quality score. Success was defined as closure of all external openings, absence of drainage without further intervention, and absence of abscess formation. Follow-up examination was performed 2 d, 2, 4, 6, 12 wk, and 5 mo after surgery, respectively.

RESULTS: No patient was lost to follow-up. The overall success rate was 82.22% (37/45) 5.7 mo after surgery. ADM dislodgement occured in 5 patients (11.11%), abscess formation was found in 1 patient, and fistula recurred in 2 patients. Of the 13 patients with recurrent fistula using ERAF, 5 (11.11%) received surgical drainage because of abscess formation. The success rate, postoperative pain time and closure time of ADM were significantly higher than those of ERAF ($P < 0.05$). However, no difference was observed in fecal incontinence rate and anorectal deformity rate after treatment with ADM and ERAF.

CONCLUSION: Closure of fistula tract opening with ADM is an effective procedure for complex anorectal fistula. ADM should be considered a first line treatment for patients with complex anorectal fistula.

© 2010 Baishideng. All rights reserved.

Key words: Acellular dermal matrix; Surgery; Transsphincteric complex fistula

Peer reviewer: Marc Basson, MD, PhD, MBA, Department of Surgery, Michigan State University, 1200 East Michigan Avenue, Suite #655, Lansing, MI 48912, United States

A ba-bai-ke-re MMTJ, Wen H, Huang HG, Chu H, Lu M, Chang ZS, Ai EHT, Fan K. Randomized controlled trial of minimally invasive surgery using acellular dermal matrix for complex anorectal fistula. *World J Gastroenterol* 2010; 16(26): 3279-3286 Available from: URL: http://www.wjgnet.com/1007-9327/full/v16/i26/3279.htm DOI: http://dx.doi.org/10.3748/wjg.v16.i26.3279

INTRODUCTION

Anal fistula, an abnormal communication between the anal or rectal lumen and perianal skin, is a common condition in general population, and occurs in 5.6 per 100 000 women and in 12.3 per 100 000 men[1], predominantly in the third and fourth decades of life[2]. It is believed that infection of the intersphincteric glands is the initiating event in anorectal fistula, in a process known as the cryptoglandular hyposis[3]. It is also commonly believed that surgery is the only way to cure it. Up to now, its treatment is diverse due to lack of standard treatment. Incorrect diagnosis and treatment are the important reason of anorectal surgery failure[4]. Traditional surgical procedures include fistulotomy, endorectal advancement flap (ERAF), loose-seton placement, and fibrin glue installation. Anal fistula is described according to the level at which it transgresses the anal sphincter. If the internal opening begins above the anal sphincter, the fistula is described as "high" or transphincteric. Traditional surgery for transsphincteric anal fistula often requires staged operations with fistulotomy and seton insertion. The surgery usually results in large and deep wounds which can take months to heal. Moreover, risk of fecal incontinence is inevitable because part of the anal sphincter is divided during surgery. The success rate of these techniques is disappointed. Fistulotomy invariably requires at least some division of the sphincter muscle with risk of incontinence[4], thus leading to a high recurrence and fecal incontinence. It has been reported that the recurrence rate of ERAF for transsphincteric anal fistula is 0%-63%[5]. Although fibrin glue is an alternative to fistulotomy, its long-term closure rate is low[6-11]. The liquid consistency of fibrin glue is not ideal for closing anorectal fistula, because it is easily extruded from the fistula tract due to the increased pressure[12]. Meta analysis indicates that the healing rate of fibrin glue is not significantly different from that of other sphincter saving procedures for fistula[13]. Complete closure of primary opening and sphincter preserving are the key to successful anorectal fistula surgery. An alternative strategy is to obliterate the fistula tract.

Using a biological substance to close complex anorectal fistula has attracted attention in recent years. A biological anal fistula plug can securely close the primary opening, thus enabling the surgeon to eradicate the fistula tract with a minimal damage to the sphincter. We report our experience with the management of complex anorectal fistulae using acellular dermal matrix (ADM) which is similar to acellular extracellular matrix (AEM). It is a newly developed biomaterial from pigs that have a collagen structure almost identical to that of humans. During manufacturing of the ADM, living cells are removed by special processes to ensure that no transmittable diseases are present in the tissue.

MATERIALS AND METHODS

Study design

Protocol synopsis for this trial and supporting CONSORT checklist were used as supporting information (Figure 1). ADM trial was a single-center, randomized, prospective, single blinded, controlled trial.

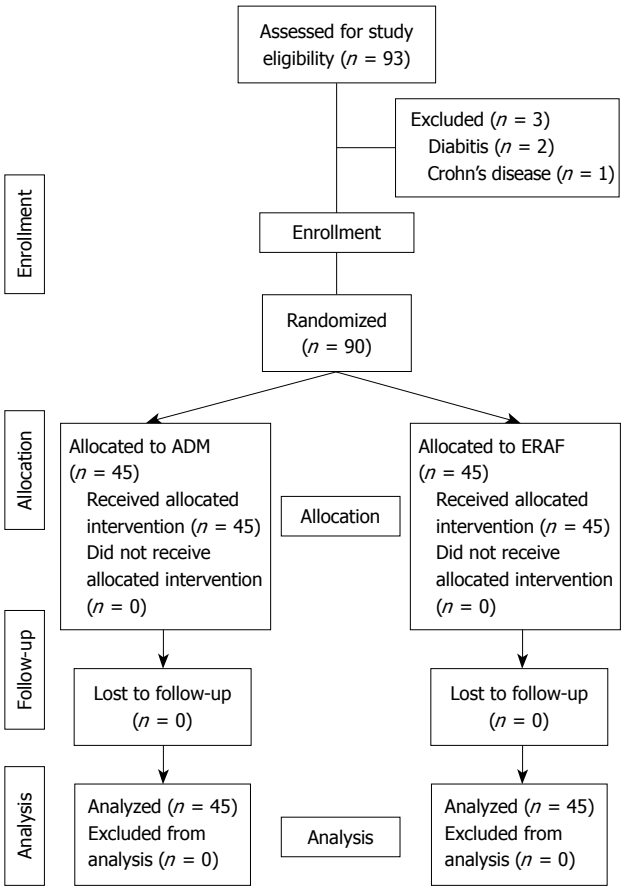

Figure 1 CONSORT diagram. ADM: Acellular dermal matrix; ERAF: Endorectal advancement flap.

Inclusion/exclusion criteria

Patients at the age of 12-60 years with 2-6 cm long intrasphincteric and transsphincteric anorectal complex fistulae identified with a fistula probe during surgery, who gave their informed consent, were included in this trial. Patients with no internal opening found during surgery, and those with positive human immunodeficiency virus, Crohn's disease, malignant cause, tuberculosis, hydradenitis suppurativa, severe cardiovascular state, diabetes, pregnancy, and sepsis were excluded.

Patients

Ninety consecutive patients with complex anorectal fistula, admitted to First Affiliated Hospital of Xinjiang Medical University from March 2008 and July 2009, were randomized into ADM group or ERAF group. Patients were blinded for ADM or ERAF. Demographic data (age and gender of the patients), smoking history, course of disease, fistula types and follow-up time of each patient were recorded (Table 1).

Randomization

Randomization was performed during surgery after the internal opening of fistula was identified. Computer-

Table 1 Demographic data about the patients included in this study

Characteristic	ADM (n = 45)	ERAF (n = 45)	P value
Gender (male/female)	24/21	25/20	NS
Age (SD, range)	18-59 (44.8)	17-61 (45.1)	NS
Smoking history, n (%)	14 (31)	11 (24)	NS
Course of disease (SD, range, mo)	3.0-7.1 (4.6)	2.8-6.9 (5.1)	NS
Type of fistula (intrasphincteric/transsphincteric)	19/26	17/28	NS
Median follow-up time	5.7 (5.1-6.4)	6.1 (5.9-6.5)	NS

ADM: Acellular dermal matrix; ERAF: Endorectal advancement flap; NS: Not significant.

generated random codes were used to produce envelopes containing the information about "ADM" or "ERAF". These envelopes were prepared by a statistician who was not involved in treatment of patients or in other work specific to the study. Computer randomization was completed at Medical Statistical Center, First Affiliated Hospital of Xinjiang Medical University.

Ethics

The trial, conducted in accordance with the Declaration of Helsinki and "good clinical practice" guidelines, local regulations, and China government laws, was approved by the Medical Ethics Committee of First Affiliated Hospital of Xinjiang Medical University. Prior to the randomization, all patients who gave their informed consent were required to comment on the informed consent before the trial.

Sample size and power

Before the trial, sample size was calculated using SPSS software 13.0 version. Armstrong reported that the success rate of anal fistula plug is 87% for the closure of fistula opening[14] and van der Hagen *et al*[5] showed that the success rate of ERAF is 37% for the closure of fistula opening, indicating that to increase the success rate from 40% to 80%, at least 44 patients in each group had to be randomized to achieve a power of 90%.

Surgical technique

All patients underwent a proctology at surgery for configuration of the fistula passage. All patients who were given prophylactic broad-spectrum antibiotics underwent preoperative regular test, endoscopy, anorectal ultrasound and mechanical bowel preparation before surgery. Anesthesia was induced with broad-spectrum parenteral antibiotics and 500 mg of intravenous metronidazole. Patients were placed in the prone jackknife position under spinal or general anesthesia. Primary opening was located using a fistula probe or by injecting hydrogen peroxide into the fistula tract. All fistula tracts were irrigated with a hydrogen peroxide solution. A fistula probe was passed through the fistula tract from the secondary opening and pulled out through the primary opening. After the fistula tract was identified and cleaned with curettage and hydrogen peroxide, ADM materials were prepared according to the length and lumen of the fistula tract, inserted into the clean fistula tracts, and pulled into a position using a silk suture passed through the fistula tract and secured to the tip of ADM, then *via* the secondary opening until it fitted snugly into the primary opening. Excess ADM material was trimmed with the secondary and primary openings flushed and secured to the mucosa and internal sphincter with a 3-0 vicryl suture. All data were recorded and analyzed by the same statistic member who did not attend the intervention.

Rectal advancement flap was done for the control group according to the following techniques. In brief, the primary opening was excised followed by mobilization of the mucosa, submucosa, and a small amount of muscular fibers from the internal sphincter complex. A rectal flap with a 2-3 cm broad base was mobilized. The rectal flap was mobilized sufficiently to cover the internal opening with overlap. Hemostasis was performed to prevent a hematoma under the flap. The fistula tract was curetted. The internal opening was not closed before the flap was advanced over the primary opening. Finally, the flap was sutured to the distal anal canal. All patients were not given analgesics after surgery. Patients were followed up at the discretion of the operating surgeon. Per-operative management (including daily activities, diet) of the two groups was identical.

ADM used in this study was an absorbable J-I type (J. Y. Life Tissue Engineering Co., Ltd., China). It is a complex collagen structure manufactured from the submucosa of porcine small intestine. According to the information about the J-I ADM product, its manufacturing is completely similar to Surgisis AFP™ (Cook Surgical Inc., Bloomington, Indiana, USA). These biologically absorbable xenografts including ADM, AEM, Surgisis or other kinds of anal fistula plug consist of an acellular scaffold similar to the human extracellular matrix[14]. In general, integration into the implant begins within a few days after such materials are placed into the fistula tract through penetrating capillaries.

Postoperative care and follow-up

All patients were hospitalized with a clear liquid diet and bed rest for 48 h. Activity was restricted to minimal. Patients were required to have a warm Sitz bath, 3 times a day. All patients were given intravenous broad-spectrum antibiotics and metronidazole for 3 d after surgery. Stool softeners were used for 10 d. No activity restriction was requested after discharge. Follow-up examination was performed in the outpatient department 2 d, 2, 4, 6, 12 wk, and 5 mo after surgery, respectively. The primary endpoints of this trial were fistula closure rate. Success was defined as closure of all external openings, absence of drainage without further intervention, and no abscess formation. The presence of one persistent fistula tract was considered surgical failure. Outcomes of ADM and ERAF closure were compared in terms of success rate, fecal incontinence rate, anorectal deformity rate, postoperative pain time, closure time and life quality score.

Continence was evaluated before and after opera-

Table 2 Vaizey score system

	Never	Rare	Some-times	Each week	Everyday
Frequency of incontinence	0	1	2	3	4
Solid	0	1	2	3	4
Liquid	0	1	2	3	4
Gas	0	1	2	3	4
Alteration in lifestyle				No	Yes
Need to wear a pad or plug				0	2
Use of constipating medication				0	2
Lack of ability to defer defecation for 15 min				0	4

Table 3 Life quality scale system[16]

Physical
P1 It is difficult for me to get out and do things like going to a movie or to church
P2 I avoid travelling
P3 Whenever I am away from home, I try and stay near a toilet as much as possible
P4 I can't hold on to my bowel motion long enough to get to the bathroom
P5 I try to prevent bowel accidents by staying very near a bathroom
P6 I cut down on how much I eat before I go out
P7 Whenever I go somewhere new, I make sure I know where the toilets are
Social
S1 I avoid visiting my friends
S2 I avoid staying the night away from home
S3 It is important to plan my daily activities around my bowel habit
S4 I leak stool without even noticing it
S5 I can't do many things I want to do
S6 I have sex less often than I would like
S7 I feel different from other people
S8 I avoid travelling by plane or public transport
S9 I avoid going out to eat
S10 I am afraid to have sex
Emotional
E1 I am afraid to go out
E2 I worry about not being able to get to the toilet in time
E3 I feel unhealthy
E4 I feel ashamed
E5 I worry about bowel accidents
E6 I feel depressed
E7 I worry about the smell
E8 I enjoy life less
E9 The possibility of bowel accidents is always on my mind
E10 During the past month have you felt so sad, discouraged, hopeless, or had so many
Problems that you wondered whether anything was worthwhile?
Overall sense of well-being
In general, would you say your health is excellent/very good/good/fair/poor?

tion using the Wexner score and Vaizey scale. The Vaizey scale consists of 3 items about the type (gas, fluid, solid) and frequency of incontinence (Table 2)[15]. The secondary endpoints were healing time, postoperative pain time, postoperative deformity rate, incontinence rate and quality of life. Patients after operation were asked to grade their pain on a visual analogue scale (VAS: 0 = no pain; 10 = worst imaginable pain) at different time points during the follow-up. Fecal incontinence was evaluated according to the Williams grade. Quality of life was evaluated using the life quality scale system (Table 3)[16].

Statistical analysis

Statistical analysis was performed using SPSS software 13.0 version. Recurrence rate, fecal incontinence rate and anal deformity rate associated with each intervention option were assessed by χ^2 test or Fisher's exact test. Healing time and postoperative pain time were calculated by Wilcoxon's test or log rank test. $P < 0.05$ was considered statistically significant.

RESULTS

Three patients were excluded from this trial because of diabetes and Crohn's disease. All patients completed the follow-up during which their data were collected. No patient was lost to follow-up. No significant difference was found in the characteristics of patients including age, sex, classification of fistula and median follow-up time between the two groups. The median follow-up time of ADM and ERAF groups was 5.7 mo (range 5.1-6.4 mo) and 6.1 mo (range 5.9-6.5 mo), respectively ($P = 0.12$). No severe adverse effect occurred in the patients.

The fistula recurred in 2 (4.45%) and 13 (28.89%) of the 45 patients in the ADM and ERAF groups, respectively ($P = 0.0047$), and was healed in 37 (82.22%) and 29 (64.44%) of the 45 patients in ADM and ERAF groups, respectively. Early extrusion of ADM occured in 4 patients, and late extrusion in 1 patient. The overall fistula healing rate was 82.22% (37/45) in ADM group. Five and 1 patients received drainage surgery in ERAF and ADM groups, respectively. The life quality score was higher, the fistula healing time and postoperative pain time were shorter in the ADM group than in the ERAF group ($P < 0.05$, Tables 4-7). The recurrence rate of fistula was significantly lower in the ADM group than in the ERAF group. However, no significant difference was observed in incontinence and anal deformity rate between the two groups. In order to clarify the effect of classification on the results, the efficacy and complication rate of intrasphincteric and transsphincteric fistulae were compared (Tables 5 and 6). The recurrence rate of transsphincteric fistula was significantly lower in the ADM group than in the ERAF group. However, no significant difference was observed in the incontinence and anal deformity rate between the two groups.

DISCUSSION

Surgery is considered the predominant and only procedure for anorectal fistula. Although fistulotomy is a simple procedure for fistula, it is not indicated for transsphincteric fistulae because of prohibitive risk of incontinence. Seton cutting, which can slowly divide the sphincter and prevent recurrent abscess formation, is considered a more efficient procedure for trassphincteric fistula, but can cause incontinence of solid stool in up to 25% of patients[17]. ERAF has become a treatment of choice for most fistulae. However, recent reports sug-

Table 4 Recurrence, fecal incontinence, anal deformity, postoperative pain time, and healing time of patients with ADM or ERAF *n* (%)

	ADM	ERAF	*P* value
n	45	45	
Recurrence	2 (4.45)	13 (28.89)	0.0047
Fecal incontinence	1 (2.22)	4 (8.89)	0.3574
Anal deformity	0 (0)	3 (6.67)	0.2402
Postoperative pain time (d)	1.5 ± 0.5	7.5 ± 1.8	0.0000
Healing time (d)	7.5 ± 3.5	24.5 ± 5.5	0.0000

Table 5 Recurrence, fecal incontinence, anal deformity, postoperative pain time, and healing time of patients with intrasphincteric fistula, ADM or ERAF *n* (%)

	Intra ADM	Intra ERAF	*P* value
n	19	17	
Recurrence	0 (0.00)	3 (17.65)	0.1907
Fecal incontinence	0 (0.00)	0 (0.00)	
Anal deformity	0 (0.00)	0 (0.00)	
Postoperative pain time (d)	1.2 ± 0.4	5.5 ± 1.9	0.0000
Healing time (d)	7.1 ± 3.4	24.6 ± 5.4	0.0000

Table 6 Recurrence, fecal incontinence, anal deformity, postoperative pain time, and healing time of patients with transsphincteric fistula, ADM or ERAF *n* (%)

	Trans ADM	Trans ERAF	*P* value
n	26	28	
Recurrence	2 (7.69)	10 (35.71)	0.0318
Fecal incontinence	1 (3.85)	4 (14.29)	0.9390
Anal deformity	0 (0.00)	3 (10.71)	0.2615
Postoperative pain time (d)	1.5 ± 0.6	8.6 ± 1.4	0.0000
Healing time (d)	7.6 ± 3.6	25.9 ± 5.7	0.0000

Table 7 Life quality score in different groups

Group	*n*	Life quality score	*P* value
ADM	45	85.9 ± 5.3	
Intra ADM	19	87.6 ± 6.5	
Trans ADM	26	83.5 ± 5.7	
ERAF	45	65.3 ± 8.9	0.0000
Intra ERAF	17	64.3 ± 5.1	0.0000[1]
Trans ERAF	28	65.9 ± 7.8	0.0000[2]

[1]Represents comparison between intrasphincteric fistulae using ADM and ERAF; [2]Represents comparison between transsphincteric fistulae using ADM and ERAF.

gest that the recurrence rate of fistula is 36%-45% after ERAF[5,18,19]. ERAF is also technically difficult, and carries a risk of rectal bleeding and incontinence. In our study, hemorrhage occurred in 2 (4.44%) and incontinence occurred in 4 (14.29%) patients in the ERAF group, which are lower than the reported findings[20]. Over the last few years, fibrin glue has been widely described as a better treatment of choice with no side effects, such as pain and incontinence[6,7,9,12,21,22]. However, it was reported that the healing rate of fistula is 78% and 40%-54%, respectively, after the use of fibrin glue[7,23,24], which is not improved even after antibiotics are added or mucosal advancement flap is supplemented[25].

Continence and healing are the two treatment goals to be achieved, but they often conflict with each other. Another sphincter-preserving surgical method is to use bioabsorbable material for anal fistula, which was first reported by Johnson *et al*[14] in 2006 with a success rate of 87%, and O'Connor *et al*[26] reported that the short-term success rate of bioabsorbable material is 80% for anal fistula, indicating that bioabsorbable material can be used in treatment of fistula due to its inherent resistance to infection. Placement of ADM, a minimally invasive procedure for fistula, is an attractive treatment of choice for fistula. Pocrine ADM is a regenerative tissue matrix isolated from decellularized intestines. Similar to Surgisis or other prosthetic meshes, ADM has also been shown to resist infection[27,28]. In our study, the short-term success rate of ADM was 82.22% (37/45) for complex anorectal fistula, which is consistent with the reported findings[26]. In order to compare and evaluate its efficacy, we searched most of the original effects of bioabsorbable material on anorectal fistula across the world (Table 8). Christoforidis *et al*[36] and Ky *et al*[40] showed that the success rate of biologically absorbable substance for complex anorectal fistulas is lower than that reported by Song *et al*[39].

The possible reason why our success rate was much lower than the reported findings[39] is that all the procedures were performed by 4 surgeons. Another possible explanation for this difference may be the selection bias of patients. Contrary to our results, however, Zubaidi *et al*[32] found that trassphincteric fistula is more likely to heal after plug placement. Ky *et al*[40] and Ellis[42] have reported a high success rate of plug placement for trassphincteric fistula. We focused on fistula channel debridement and complete drainage during surgery in order to prevent abscess formation as previously described[31]. Because more granulation tissues in the fistula tract can function as a barrier to cellular infiltration into ADM, it is difficult to imagine that simple irrigation with hydrogen peroxide without thorough curettage of the tract can clean the tract and allow incorporation of ADM material into its surroundings. We believe that the low success rate in the study by Safar *et al*[37] is due to inadequate debridement and curettage of granulation tissue. Complete debridement, curettage of the tract, and hydrogen peroxide irrigation may be important for the surgery to achieve a greater success rate. This point differs from that of Schwandner *et al*[31]. In our study, 5 patients (11.11%) experienced ADM dislodgement, which may be due to the poor ADM fixation to the sphincter in the primary opening. Technical failure associated with plug-falling out is an important reason for surgery failure[31].

In our study, the success rate of ADM for complex fistula was 82.22% (37/45), indicating that placement of ADM is a safe, beneficial, minimally invasive procedure for fistula, and can protect the anal function.

Lawes *et al*[41] proposed to combine anal fistula plug and advancement flap for fistula. However, we hold that selection of patients, complete debridement, tract prepa-

Table 8 Publications on anal fistula plug in the World

Author	Publication form	Total patients (*n*)	Crohn's patients (*n*)	Follow-up median (mo)	Success rate (%)
Adamina *et al*[29], 2010	Article	12	0	12.6 (10-14)	50.0
Schwandner *et al*[30], 2009	Article	60	0	12	62.0
Schwandner *et al*[31], 2009	Article	36	0	9	75.0
Zubaidi *et al*[32], 2009	Article	23	0	12	83.0
Ortiz *et al*[33], 2009	Article	15	0	12	20.0
Chung W *et al*[34], 2009	Article	65	0	12	59.3
Wang *et al*[35], 2009	Article	29	0	18 (9.1-26.8)	34.0
Christoforidis *et al*[36], 2009	Article	37	4	14 (6-22)	32.0
Safar *et al*[37], 2009	Article	35	4	4	14.0
Christoforidis *et al*[38], 2008	Article	49	4	6.5	43.0
Song *et al*[39], 2008	Article	30	0	6.3	100.0
Ky *et al*[40], 2008	Article	45	14	6.5 (3-13)	84.0
Lawes *et al*[41], 2008	Article	20	0	7.4	24.0
Ellis[42], 2007	Article	17	5	6	88.0
van Koperen *et al*[43], 2007	Article	17	1	7	41.0
Ky *et al*[44], 2007	Abstract	37	8	3	84.0
Abbas *et al*[45], 2007	Abstract	17	0	7.4	24.0
Bohe *et al*[46], 2007	Abstract	32	7	6	65.0
Lenisa *et al*[47], 2007	Abstract	27	0	11	63.0
Thekkinkattil *et al*[48], 2007	Abstract	40	0	6	40.0
Poirier *et al*[49], 2006	Abstract	27	0	5	59.0
Champagne *et al*[50], 2006	Article	46	0	12	83.0

ration and plug fixation are closely associated with the final success rate.

It is essential to use antibiotics before surgery. It was reported that anorectal abscess is not formed in patients after treatment with AEM[39] or Surgisis[50]. However, early infection occurred in our study. Although use of Surgisis is not associated with perianal sepsis[14], it has been shown that the incidence of severe perianal sepsis is 23%[41]. Although the sepsis rate of ADM (1/45) was significantly lower than that of ERAF (5/45) in our study, more evidence is needed for the evaluation of ADM. Safar *et al*[37] suggested that the success rate of plug for fistula is not associated with the preoperative bowel preparation, but we performed mechanical bowel preparation before surgery to avoid possible constipation or infection after surgery.

In our study, ADM could obviously shorten the postoperative pain time and the fistula healing time, but not the deformity and incontinence rate of transsphincteric fistula. Transsphincteric fistula recurred in 2 patients, suggesting that it is necessary to perform multicenter randomized controlled trial to evaluate the efficiency of ADM on transsphincteric complex fistula.

A significant number of patients in ERAF group in this study had long-term continence disturbances in forms of gas and liquid stool incontinence, which may be associated with ERAF or fistulotomy, abscess drainage, and other anorectal treatment modalities.

An adequate follow-up time is essential in a comparative study of ADM and ERAF for complex fistula. Only one study is available with a long follow-up time[33]. The follow-up time in our study is similar to that in previous studies[42,43,46]. The success rate of ADM for fistula (82.22%) was associated with the ADM itself and the adequate follow-up time in our study. Zubaidi *et al*[32] showed that a longer follow-up time and over an 80% success rate of biologically absorbable substance for fistula provide better evidence for the use of ADM. Song *et al*[39] reported convincing results based on 6.3 mo follow-up time. However, Wang *et al*[35] showed that the success rate of biologically absorbable substance for fistula is only 34% after a follow-up time of 18 mo.

In conclusion, closure of the fistula tract primary opening using ADM is an effective and acceptable procedure for complex anorectal fistula. ADM is a a safe, beneficial, minimally invasive procedure for fistula, and can protect anal function. ADM dislodgement is associated with the closure techniques. Further longer-term multicenter randomized controlled clinical trials are needed to evaluate its efficacy on complex anorectal fistula.

ACKNOWLEDGMENTS

The authors thank Professor Wei-Li Yan, Department of Epidemiology and Biostatistics, School of Public Health, Xinjiang Medical University, for her help and excellent technical and methodological support to this randomized trial.

COMMENTS

Background

Anal fistula is an abnormal chronic communication between the anal or rectal lumen and perianal skin. Surgery usually results in large and deep wounds which can take months to heal. Moreover, risk of fecal incontinence is inevitable because part of the anal sphincter is divided during surgery. The success rate of different techniques is disappointed. Using a biological substance to close complex anorectal fistula is attractive.

Research frontiers

Acellular dermal matrix (ADM) is a bioabsorbable xenograft for tissue defect. Application of different kinds of ADM in treatment of anorectal fistula is a hotspot in the World.

Innovations and breakthroughs

Closure of the fistula tract primary opening using ADM is an effective and acceptable alternative to complex anorectal fistula. ADM is a safe, beneficial,

minimally invasive procedure for fistula, and can protect anal function. It should be considered a first line treatment for patients with complex anorectal fistula.

Applications

This method can reduce postoperative pain, shorten fistula healing time, and improve the postoperative life quality of patients.

Peer review

This is an interesting and generally well written paper with the effects of endorectal mucosal advancement flap and acellular dermis plug on complex fistula compared. The results are striking.

REFERENCES

1 **Sainio P**. Fistula-in-ano in a defined population. Incidence and epidemiological aspects. *Ann Chir Gynaecol* 1984; **73**: 219-224

2 **Marks CG**, Ritchie JK. Anal fistulas at St Mark's Hospital. *Br J Surg* 1977; **64**: 84-91

3 **Parks AG**. Pathogenesis and treatment of fistuila-in-ano. *Br Med J* 1961; **1**: 463-469

4 **Hamadani A**, Haigh PI, Liu IL, Abbas MA. Who is at risk for developing chronic anal fistula or recurrent anal sepsis after initial perianal abscess? *Dis Colon Rectum* 2009; **52**: 217-221

5 **van der Hagen SJ**, Baeten CG, Soeters PB, van Gemert WG. Long-term outcome following mucosal advancement flap for high perianal fistulas and fistulotomy for low perianal fistulas: recurrent perianal fistulas: failure of treatment or recurrent patient disease? *Int J Colorectal Dis* 2006; **21**: 784-790

6 **Buchanan GN**, Bartram CI, Phillips RK, Gould SW, Halligan S, Rockall TA, Sibbons P, Cohen RG. Efficacy of fibrin sealant in the management of complex anal fistula: a prospective trial. *Dis Colon Rectum* 2003; **46**: 1167-1174

7 **Ellis CN**, Clark S. Fibrin glue as an adjunct to flap repair of anal fistulas: a randomized, controlled study. *Dis Colon Rectum* 2006; **49**: 1736-1740

8 **Sentovich SM**. Fibrin glue for all anal fistulas. *J Gastrointest Surg* 2001; **5**: 158-161

9 **Sentovich SM**. Fibrin glue for anal fistulas: long-term results. *Dis Colon Rectum* 2003; **46**: 498-502

10 **Williams JG**, Farrands PA, Williams AB, Taylor BA, Lunniss PJ, Sagar PM, Varma JS, George BD. The treatment of anal fistula: ACPGBI position statement. *Colorectal Dis* 2007; **9** Suppl 4: 18-50

11 **Gisbertz SS**, Sosef MN, Festen S, Gerhards MF. Treatment of fistulas in ano with fibrin glue. *Dig Surg* 2005; **22**: 91-94

12 **Hammond TM**, Grahn MF, Lunniss PJ. Fibrin glue in the management of anal fistulae. *Colorectal Dis* 2004; **6**: 308-319

13 **Cirocchi R**, Farinella E, La Mura F, Cattorini L, Rossetti B, Milani D, Ricci P, Covarelli P, Coccetta M, Noya G, Scianameo F. Fibrin glue in the treatment of anal fistula: a systematic review. *Ann Surg Innov Res* 2009; **3**: 12

14 **Johnson EK**, Gaw JU, Armstrong DN. Efficacy of anal fistula plug vs. fibrin glue in closure of anorectal fistulas. *Dis Colon Rectum* 2006; **49**: 371-376

15 **Vaizey CJ**, Carapeti E, Cahill JA, Kamm MA. Prospective comparison of faecal incontinence grading systems. *Gut* 1999; **44**: 77-80

16 **Rockwood TH**, Church JM, Fleshman JW, Kane RL, Mavrantonis C, Thorson AG, Wexner SD, Bliss D, Lowry AC. Fecal Incontinence Quality of Life Scale: quality of life instrument for patients with fecal incontinence. *Dis Colon Rectum* 2000; **43**: 9-16; discussion 16-17

17 **García-Aguilar J**, Belmonte C, Wong DW, Goldberg SM, Madoff RD. Cutting seton versus two-stage seton fistulotomy in the surgical management of high anal fistula. *Br J Surg* 1998; **85**: 243-245

18 **Dubsky PC**, Stift A, Friedl J, Teleky B, Herbst F. Endorectal advancement flaps in the treatment of high anal fistula of cryptoglandular origin: full-thickness vs. mucosal-rectum flaps. *Dis Colon Rectum* 2008; **51**: 852-857

19 **van Koperen PJ**, Wind J, Bemelman WA, Bakx R, Reitsma JB, Slors JF. Long-term functional outcome and risk factors for recurrence after surgical treatment for low and high perianal fistulas of cryptoglandular origin. *Dis Colon Rectum* 2008; **51**: 1475-1481

20 **Schouten WR**, Zimmerman DD, Briel JW. Transanal advancement flap repair of transsphincteric fistulas. *Dis Colon Rectum* 1999; **42**: 1419-1422; discussion 1422-1423

21 **Zmora O**, Mizrahi N, Rotholtz N, Pikarsky AJ, Weiss EG, Nogueras JJ, Wexner SD. Fibrin glue sealing in the treatment of perineal fistulas. *Dis Colon Rectum* 2003; **46**: 584-589

22 **Cintron JR**, Park JJ, Orsay CP, Pearl RK, Nelson RL, Abcarian H. Repair of fistulas-in-ano using autologous fibrin tissue adhesive. *Dis Colon Rectum* 1999; **42**: 607-613

23 **Maralcan G**, Başkonuş I, Aybasti N, Gökalp A. The use of fibrin glue in the treatment of fistula-in-ano: a prospective study. *Surg Today* 2006; **36**: 166-170

24 **van Koperen PJ**, Wind J, Bemelman WA, Slors JF. Fibrin glue and transanal rectal advancement flap for high transsphincteric perianal fistulas; is there any advantage? *Int J Colorectal Dis* 2008; **23**: 697-701

25 **Singer M**, Cintron J, Nelson R, Orsay C, Bastawrous A, Pearl R, Sone J, Abcarian H. Treatment of fistulas-in-ano with fibrin sealant in combination with intra-adhesive antibiotics and/or surgical closure of the internal fistula opening. *Dis Colon Rectum* 2005; **48**: 799-808

26 **O'Connor L**, Champagne BJ, Ferguson MA, Orangio GR, Schertzer ME, Armstrong DN. Efficacy of anal fistula plug in closure of Crohn's anorectal fistulas. *Dis Colon Rectum* 2006; **49**: 1569-1573

27 **Buinewicz B**, Rosen B. Acellular cadaveric dermis (AlloDerm): a new alternative for abdominal hernia repair. *Ann Plast Surg* 2004; **52**: 188-194

28 **Holton LH 3rd**, Chung T, Silverman RP, Haerian H, Goldberg NH, Burrows WM, Gobin A, Butler CE. Comparison of acellular dermal matrix and synthetic mesh for lateral chest wall reconstruction in a rabbit model. *Plast Reconstr Surg* 2007; **119**: 1238-1246

29 **Adamina M**, Hoch JS, Burnstein MJ. To plug or not to plug: a cost-effectiveness analysis for complex anal fistula. *Surgery* 2010; **147**: 72-78

30 **Schwandner T**, Roblick MH, Kierer W, Brom A, Padberg W, Hirschburger M. Surgical treatment of complex anal fistulas with the anal fistula plug: a prospective, multicenter study. *Dis Colon Rectum* 2009; **52**: 1578-1583

31 **Schwandner O**, Fuerst A. Preliminary results on efficacy in closure of transsphincteric and rectovaginal fistulas associated with Crohn's disease using new biomaterials. *Surg Innov* 2009; **16**: 162-168

32 **Zubaidi A**, Al-Obeed O. Anal fistula plug in high fistula-in-ano: an early Saudi experience. *Dis Colon Rectum* 2009; **52**: 1584-1588

33 **Ortiz H**, Marzo J, Ciga MA, Oteiza F, Armendáriz P, de Miguel M. Randomized clinical trial of anal fistula plug versus endorectal advancement flap for the treatment of high cryptoglandular fistula in ano. *Br J Surg* 2009; **96**: 608-612

34 **Chung W**, Kazemi P, Ko D, Sun C, Brown CJ, Raval M, Phang T. Anal fistula plug and fibrin glue versus conventional treatment in repair of complex anal fistulas. *Am J Surg* 2009; **197**: 604-608

35 **Wang JY**, Garcia-Aguilar J, Sternberg JA, Abel ME, Varma MG. Treatment of transsphincteric anal fistulas: are fistula plugs an acceptable alternative? *Dis Colon Rectum* 2009; **52**: 692-697

36 **Christoforidis D**, Pieh MC, Madoff RD, Mellgren AF. Treatment of transsphincteric anal fistulas by endorectal advancement flap or collagen fistula plug: a comparative study. *Dis Colon Rectum* 2009; **52**: 18-22

37 **Safar B**, Jobanputra S, Sands D, Weiss EG, Nogueras JJ, Wexner SD. Anal fistula plug: initial experience and outcomes. *Dis Colon Rectum* 2009; **52**: 248-252

38 **Christoforidis D**, Etzioni DA, Goldberg SM, Madoff RD,

Mellgren A. Treatment of complex anal fistulas with the collagen fistula plug. *Dis Colon Rectum* 2008; **51**: 1482-1487
39 **Song WL**, Wang ZJ, Zheng Y, Yang XQ, Peng YP. An anorectal fistula treatment with acellular extracellular matrix: a new technique. *World J Gastroenterol* 2008; **14**: 4791-4794
40 **Ky AJ**, Sylla P, Steinhagen R, Steinhagen E, Khaitov S, Ly EK. Collagen fistula plug for the treatment of anal fistulas. *Dis Colon Rectum* 2008; **51**: 838-843
41 **Lawes DA**, Efron JE, Abbas M, Heppell J, Young-Fadok TM. Early experience with the bioabsorbable anal fistula plug. *World J Surg* 2008; **32**: 1157-1159
42 **Ellis CN**. Bioprosthetic plugs for complex anal fistulas: an early experience. *J Surg Educ* 2007; **64**: 36-40
43 **van Koperen PJ**, D'Hoore A, Wolthuis AM, Bemelman WA, Slors JF. Anal fistula plug for closure of difficult anorectal fistula: a prospective study. *Dis Colon Rectum* 2007; **50**: 2168-2172
44 **Ky A**, Sylla P, Kim S, Steinhagen R. Short-term results in the treatment of anal fistulas with Surgisis® AFP. *Dis Colon Rectum* 2007; **50**: 725
45 **Abbas M**, Lawes D, Tejirian T, Hamadani A, Heppell J. Young-Fadok T. Anal fistula plug (AFP™) for the treatment of fistula in ano. *Dis Colon Rectum* 2007; **50**: 749
46 **Bohe M**, Stark M, Zawadzki A. The results of the anal fistula plug for high transsphincteric fistula. *Colorectal Dis* 2007; **9**: 7
47 **Lenisa L**, Rusconi A, Mascheroni L, Andreoli M, Grignani R, Mégevand J. Obliterative treatment for cryptoglandular fistula with anal plug. Does it work in Europe? *Colorectal Dis* 2007; **9**: 54
48 **Thekkinkattil D**, Gonsalves S, Burke D. Efficacy of anal fistula plug in closure of recurrent anorectal fistulae. *Colorectal Dis* 2007; **9**: 59
49 **Poirier M**, Citron J, Nelson R, Prasad L, Abcarian H. Surgisis AFP: a changing paradigm in the treatment of fistula-in-ano. *Dis Colon Rectum* 2006; **49**: 770
50 **Champagne BJ**, O'Connor LM, Ferguson M, Orangio GR, Schertzer ME, Armstrong DN. Efficacy of anal fistula plug in closure of cryptoglandular fistulas: long-term follow-up. *Dis Colon Rectum* 2006; **49**: 1817-1821

S- Editor Tian L **L- Editor** Wang XL **E- Editor** Lin YP

World Journal of Gastroenterology

Online Submissions: http://www.wjgnet.com/1007-9327office
wjg@wjgnet.com
doi:10.3748/wjg.v16.i26.3287

World J Gastroenterol 2010 July 14; 16(26): 3287-3291
ISSN 1007-9327 (print)
© 2010 Baishideng. All rights reserved.

BRIEF ARTICLE

Safety of same-day endoscopic ultrasound and endoscopic retrograde cholangiopancreatography under conscious sedation

Kendrick Che, Natasha Muckova, Snorri Olafsson, Wichit Srikureja

Kendrick Che, Natasha Muckova, Snorri Olafsson, Wichit Srikureja, Department of Internal Medicine, Division of Gastroenterology, Loma Linda University Medical Center, Loma Linda, CA 92354, United States
Author contributions: Srikureja W designed the research; Che K and Muckova N performed the research; Olafsson S provided the analytic tools and analyzed the data; Che KM wrote the paper.
Correspondence to: Kendrick Che, DO, Department of Internal Medicine, Division of Gastroenterology, Loma Linda University Medical Center, 11234 Anderson Street, Room 1556, Loma Linda, CA 92354, United States. kche@llu.edu
Telephone: +1-909-5584905 Fax: +1-909-5580274
Received: February 18, 2010 Revised: March 25, 2010
Accepted: April 1, 2010
Published online: July 14, 2010

Abstract

AIM: To assess the tolerability and safety of same-day tandem procedures, endoscopic ultrasound (EUS) followed by endoscopic retrograde cholangiopancreatography (ERCP) under conscious sedation.

METHODS: A retrospective review was conducted at Loma Linda University Medical Center, a tertiary-care center. All 54 patients who underwent EUS followed by ERCP (group A) from 2004 to 2006 were included in the study. A second group of 56 patients who underwent EUS only (group B), and a third group of 53 patients who underwent ERCP only (group C) during the same time period were selected consecutively as control groups for comparison.

RESULTS: Conscious sedation was used in 96% of patients in group A. Mean dosages of meperidine and midazolam used in group A were significantly higher than in group B or C. Mean recovery time in group A was not statistically longer than in group B or C. There was no significant difference in the incidence of sedation-related and procedural-related complications.

CONCLUSION: Tandem EUS/ERCP procedure can be safely performed under conscious sedation with minimal adverse events. Combined procedures, however, are associated with higher dosages of sedatives, and slightly longer recovery time.

© 2010 Baishideng. All rights reserved.

Key words: Conscious sedation; Safety; Same-day; Endoscopic ultrasound; Endoscopic retrograde cholangiopancreatography

Peer reviewer: Dr. Ram Prakash Galwa, MBBS, MD, Department of Diagnostic Imaging, The Ottawa Hospital, 751 Parkdale Avenue, Apartment 803, Ottawa, k1y1j7, Canada

Che K, Muckova N, Olafsson S, Srikureja W. Safety of same-day endoscopic ultrasound and endoscopic retrograde cholangiopancreatography under conscious sedation. *World J Gastroenterol* 2010; 16(26): 3287-3291 Available from: URL: http://www.wjgnet.com/1007-9327/full/v16/i26/3287.htm DOI: http://dx.doi.org/10.3748/wjg.v16.i26.3287

INTRODUCTION

Endoscopic ultrasound (EUS) and/or EUS-guided fine needle aspiration (EUS-guided FNA) is increasingly utilized for the diagnosis of pancreatico-biliary diseases including malignancies and choledocholithiasis. The diagnostic accuracy in reported studies of EUS or EUS-guided FNA in the diagnosis of obstructive jaundice is from 80% to 98%[1,2]. In addition, EUS is associated with lower morbidity compared to endoscopic retrograde cholangiopancreatography (ERCP), with an overall EUS-FNA complication rate of 1%-2%[2-4]. EUS is now being performed

first for evaluation in patients with suspected pancreatico-biliary diseases, especially those with obstructive jaundice[5]. Based on EUS findings, therapeutic ERCP interventions, such as stent placement for biliary drainage or stone extraction can then be performed in a tandem fashion.

The literature is scarce on the safety of same-day tandem EUS and ERCP procedures done under conscious sedation. The tandem procedure approach is believed to reduce procedure time and be cost-effective[6]. Potential risks associated with such a strategy are unknown. There are only 2 reported cases in the medical literature of bile leakage into the peritoneum as a result of performing ERCP immediately after EUS-guided FNA[7]. In 2007, Tarantino *et al*[8] evaluated the safety of performing ERCP immediately after EUS in 25 patients done under general anesthesia using propofol. In 1999, Duchmann *et al*[9] also examined the feasibility of performing EUS and ERCP in 57 patients during the same general anesthesia session. Although widely practiced, the safety of performing tandem procedures under conscious sedation is unclear. At our institution, a tandem approach with EUS and/or EUS-guided FNA is sometimes performed for patients with suspected obstructive jaundice, followed by therapeutic ERCP if indicated.

MATERIALS AND METHODS

From October 2004 to November 2005, 54 patients underwent same-day tandem EUS followed by ERCP procedures for the indication of obstructive, or post-hepatic jaundice. This cohort was designated as group A.

From the above time period, 60 consecutive patients who underwent EUS-only and 60 consecutive patients who underwent ERCP-only for the indication of jaundice were chosen as the EUS and ERCP control groups. Of the 60 EUS-only procedures reviewed, only 56 procedures had complete data for analysis (group B). Of the 60 ERCP-only procedures reviewed, only 53 procedures had complete data for analysis (group C).

This retrospective review included: demographics, indications, completion rate of procedures, sedation medication dosages, procedure and recovery times, and adverse events. Vital signs recorded during each procedure and during post-procedure recovery were reviewed. Adverse events included hypotension (defined as systolic blood pressure < 90 mmHg requiring intravenous fluids), bradycardia (heart rate < 60 bpm, or in patients with a baseline heart rate under 60 bpm, heart rate < 45 bpm), and oxygen desaturation (pulse oximetry reading < 90%). The use of reversal agents such as flumazenil and/or naloxone due to oversedation was examined. Post-ERCP pancreatitis was defined as amylase and lipase over five times normal values with abdominal pain and/or leukocytosis persisting 24 h after ERCP. Some of the patients in this study were inpatients, whereas the majority were outpatients. For those who underwent outpatient procedures, it was not standard practice to bring them back for scheduled follow-up laboratory tests.

Statistical analysis

Statistical analysis was performed using StatView version 5.0 for Windows. Numeric variables were expressed as mean ± SD. Differences between groups were analyzed using student's *t*-test for continuous variables. Fisher's exact test was performed for categorical variables but was not done if there was zero in a cell. All differences were considered statistically significant at the *P*-value of < 0.05.

Informed consent was waived for this retrospective study and the research committee at Loma Linda University Medical Center approved the study.

RESULTS

A total of 163 patients were included in this study: tandem EUS/ERCP (group A: n = 54), EUS-only (group B: n = 56), and ERCP-only (group C: n = 53). Mean age, gender, indication, and procedure completion rate are shown in Table 1. There were significantly less males in group A compared to group B, but not significantly different compared to group C. All procedures were performed for the indication of obstructive jaundice. When cholangitis was presumed to be the cause of jaundice, ERCP only, as it should be, was performed. Patients with jaundice and abnormal pancreatico-biliary imaging underwent EUS as part of the work-up.

All patients who underwent EUS in group A and in group B completed the procedures. There was no significant difference in the number of patients who had EUS-FNA in groups A *vs* B (57% *vs* 68%, P = 0.32). In group A, ERCP was not completed in five patients compared to seven patients in control group C. Two patients (one each from group A and C) had difficult anatomy and the ampulla was not reached. Eight patients (four from both group A and C) had failed deep cannulation of the desired duct. Two patients from group C had cardiac dysrhythmias (atrial fibrillation and ventricular tachycardia) necessitating early abortion of the procedures.

The amount and type of sedation used is displayed in Table 2. Conscious sedation was used in 96% of group A patients, 100% of group B and 98% of group C patients. General anesthesia and/or propofol were used in three patients, two patients in group A and one patient in group C. The mean total dose of meperidine used in group A was significantly higher than in group B (151.1 ± 64.0 mg *vs* 104.0 ± 43.6 mg, P < 0.0001) or in group C (151.1 ± 64.0 mg *vs* 104.5 ± 32.5 mg, P < 0.0001). The mean total dose of midazolam used in group A was significantly higher than in group B (8.5 ± 3.2 mg *vs* 6.3 ± 2.4 mg, P = 0.0001), or in group C (8.5 ± 3.2 mg *vs* 6.9 ± 3.4 mg, P = 0.01).

Procedure and recovery time data are shown in Table 3. The total procedure time for group A was 93.5 ± 36.1 min (range: 30-185 min), 59.0 ± 35.0 min (range: 10-129 min) for group B, and 40.1 ± 20.4 min (range: 20-170 min) for group C. The mean procedure time for EUS in group A, when compared as a separate procedure to the EUS procedure time in group B was not statistically significant (48.0 ± 28.0 min *vs* 59.0 ± 35.0 min, P = 0.07). Similarly, the mean procedure time for ERCP in group A, when compared as a

Table 1 Patient demographics, indications, and procedure completion rates *n* (%)

	Tandem (group A) (*n* = 54)	EUS only (group B) (*n* = 56)	*P*-value[1]	ERCP only (group C) (*n* = 53)	*P*-value[2]
Demographics					
Age (yr) (mean ± SD) (Range)	65.2 ± 15.6 (18-93)	63.4 ± 15.7 (19-85)	0.54	54.7 ± 21.3 (14-96)	0.004
Sex, male (%)	43%	66%	0.02	59%	0.12
Indications					
Pancreatic mass	10 (19)	16 (29)	0.26	3 (6)	0.07
Cholangiocarcinoma	3 (6)	1 (2)	0.36	0 (0)	0.24
CBD stones	3 (6)	2 (4)	0.68	6 (11)	0.32
CBD stricture	1 (2)	10 (18)	0.01	1 (2)	1.00
Cholangitis	0	0	NA	8 (15)	NA
Abnormal imaging	10 (19)	10 (18)	1.00	2 (4)	0.03
Pancreatitis	4 (7)	4 (7)	1.00	1 (2)	0.36
Completion					
Completion of procedures	EUS 54 (100) ERCP 49 (91)	56 (100)	1.00	46 (87)	0.56

[1]*P*-value of group A *vs* group B; [2]*P*-value of group A *vs* group C. EUS: Endoscopic ultrasound; ERCP: Endoscopic retrograde cholangiopancreatography; CBD: Common bile duct; NA: Not available.

Table 2 Sedation medication used and dosages *n* (%)

	Tandem (group A) (*n* = 54)	EUS only (group B) (*n* = 56)	*P*-value[1]	ERCP only (group C) (*n* = 53)	*P*-value[2]
Sedation type					
Conscious sedation	52 (96)	56 (100)	0.24	52 (98)	0.22
GA/propofol	2 (4)	0	0.24	1 (2)	0.22
Medications used for sedation					
Meperidine	49 (91)	56 (100)	0.03	44 (83)	0.27
Midazolam	54 (96)	56 (100)	0.24	53 (98)	1.00
Diphenhydramine	16 (30)	4 (7)	0.003	28 (53)	0.02
Promethazine	5 (9)	4 (7)	0.74	0	0.06
Fentanyl	7 (13)	0	0.01	8 (15)	0.12
Total dosage of sedatives used (mean ± SD) (range)					
Meperidine (mg)	151.1 ± 64 (25-325)	104 ± 43.6 (25-250)	< 0.0001	104.5 ± 32.5 (25-175)	< 0.0001
Midazolam (mg)	8.5 ± 3.2 (0-16)	6.3 ± 2.4 (2-13)	0.0001	6.9 ± 3.4 (0-16)	0.01
Diphenhydramine (mg)	50 ± 15.8 (25-100)	50 ± 0 (50)	1.00	51.8 ± 9.45 (50-100)	0.64
Promethazine (mg)	25 ± 0 (25)	25 ± 0 (25)	1.00	0	NA
Fentanyl (mcg)	100.0 ± 55.9 (25-175)	0	NA	146.9 ± 54.2 (75-200)	0.12

[1]*P*-value of group A *vs* group B; [2]*P*-value of group A *vs* group C. GA: General anesthesia.

separate procedure to the ERCP procedure time in group C was not significantly different (45.1 ± 20.7 min *vs* 40.1 ± 20.4 min, $P = 0.20$). The mean recovery time in group A was slightly longer than in group B (105.1 ± 74.8 min *vs* 84.0 ± 51.7 min, $P = 0.06$) or in group C (105.1 ± 74.8 min *vs* 84.5 ± 42.6 min, $P = 0.07$).

The complications among the three study groups are reported in Table 4. There was no significant difference in the number of patients who had hypotension, bradycardia, or desaturation among the groups. Reversal agents (flumazenil and/or naloxone) were used in 2% of patients in group A *vs* 0% in group B ($P = 1.00$) *vs* 6% in group C ($P = 0.36$). The number of patients with post-ERCP pancreatitis when comparing group A and group C was similar. One patient in group A was hospitalized due to rectal bleeding that was unrelated to the procedures; a colonoscopy during hospital stay revealed colon cancer. Two patients were hospitalized in group C, one due to oversedation and another due to ventricular tachycardia. The patient admitted for oversedation returned home the following day with no complications. Hypokalemia was the cause of ventricular tachycardia in one patient with metastatic colon cancer who died a month later due to septic pneumonia unrelated to the ERCP procedure.

DISCUSSION

More patients with suspected pancreatico-biliary diseases are now first undergoing EUS with possible EUS-guided FNA. Some of these patients will also undergo ERCP and interventions based on EUS findings. Performing tandem procedures starting with EUS followed by ERCP is logical and is being done at many centers. However, there is little data on its safety when done under conscious sedation. There have been 2 reported cases of bile leak with ERCP following immediately after EUS-guided FNA[7]. Mergener *et al*[10] described a case of massive pneumoperitoneum in a patient who underwent ERCP immediately after EUS-

Table 3 Procedure and recovery times (mean ± SD) (range)

	Tandem (group A) (n = 54)	EUS only (group B) (n = 56)	P-value[1]	ERCP only (group C) (n = 53)	P-value[2]
EUS time (min)	48 ± 28 (8-110)	59 ± 35 (10-129)	0.07	NA	NA
ERCP time (min)	45.1 ± 20.7 (10-105)	NA	NA	40.1 ± 20.4 (7-90)	0.20
EUS and ERCP time (min)	93.5 ± 36.1 (30-185)	NA	NA	NA	NA
Recovery time (min)	105.1 ± 74.8 (15-350)	84.0 ± 51.7 (9-252)	0.06	84.5 ± 42.6 (20-170)	0.07

[1]P-value of group A *vs* group B; [2]P-value of group A *vs* group C.

Table 4 Procedure complications n (%)

	Tandem (group A) (n = 54)	EUS only (group B) (n = 56)	P-value[1]	ERCP only (group C) (n = 53)	P-value[2]
Hypotension	4 (7)	7 (13)	0.53	3 (6)	1.00
Bradycardia	12 (22)	14 (25)	0.82	14 (26)	0.66
Desaturation	1 (2)	0	NA	3 (6)	0.36
Use of reversal agent	2 (4)	0	NA	2 (4)	1.00
Post procedure pancreatitis	2 (4)	0	NA	4 (8)	0.68
Hospitalization	1 (2)	0	0.49	2 (4)	0.62

[1]P-value of group A *vs* group B; [2]P-value of group A *vs* group C.

FNA. Despite this, two other studies have reported the safety of tandem procedures when done under general anesthesia[8,9]. The objective of our study was to assess safety in a retrospective review of tandem cases done under conscious sedation at our center.

Our study reviewed 54 patients with tandem procedures EUS/ERCP along with 56 control patients with EUS only and 53 control patients with ERCP only. Appropriately, patients with presumed cholangitis underwent ERCP only and more patients with obstructive jaundice and abnormal pancreatico-biliary imaging underwent EUS, EUS-FNA as part of the evaluation.

Almost all (96%) of the procedures in the tandem group were done under conscious sedation with meperidine and midazolam. The procedure time for the tandem group was longer than either the EUS or ERCP alone control groups. This is intuitive because two procedures were done at the same setting in the tandem group. Given longer procedures, the amount of meperidine and midazolam was higher in the tandem group as compared to the controls. However, a similar amount of time was needed for EUS and ERCP when the procedures were compared separately to each control group.

In our setting, EUS is performed in the GI Lab at the medical center and ERCP is done at a different location in the radiology suite under fluoroscopy. The total time reported for the tandem group would be even shorter if EUS and ERCP were performed in one place, eliminating patient transfer and transport times.

Given the higher amount of sedation used, the recovery time was slightly longer (although not statistically significant) in the tandem group compared to the two control groups. Despite the longer procedure and recovery time, no significant difference in sedation-related and procedure-related complications were noted in the tandem group compared with the controls. There was no difference in hemodynamic adverse events, use of reversal agents, or rate of hospitalization post procedures. None of the patients with bradycardia required atropine, and none of the patients were intubated due to oxygen desaturation. The post-ERCP pancreatitis rate was 4% in the tandem group, which was statistically similar to the ERCP control group and is within the accepted level. In a large prospective study by Freeman *et al*[11], post-ERCP pancreatitis occurred after 6.7% procedures. No bile leaks were noted with the tandem group.

Nonetheless, there are limitations to our study. Given that the study was a retrospective review, we were unable to assess patient tolerability through direct patient questionnaire. It was not known whether patients were comfortable during the procedures, if they had any recollection of the procedures, or if they would undergo the tandem procedure again. Another limitation was the lack of uniform follow-up of patients to evaluate long-term adverse events due to the tandem procedure. In this study, the few patients who were admitted for observation and those who were already inpatients were all discharged home without complications. It appears that tandem procedures may be safely done under conscious sedation. With the size of groups studied here, no significant complications were noted in the tandem group compared to either study alone. However, it would seem reasonable that a prospective study should be carried out, where a larger number of patients were included and patient tolerance was assessed. Overall, our study is the first of its kind to try to assess issues concerning the safety and feasibility of performing tandem EUS/ERCP procedures under conscious sedation.

In conclusion, a tandem EUS/ERCP procedure can be safely performed under conscious sedation with minimal adverse events. The combined procedure, however, is associated with higher dosages of sedatives and with slightly longer recovery time.

COMMENTS

Background

Same-day endoscopic ultrasound (EUS) followed by endoscopic retrograde cholangiopancreatography (ERCP) is performed at many medical centers for pancreatico-biliary diseases. Little data exists regarding the safety of performing tandem procedures under conscious sedation.

Research frontiers

Efficiency and cost savings are important issues in our current healthcare system, however, this should not be done at the expense of patient safety.

Innovations and breakthroughs

Several studies have examined the safety of combined procedures under propofol or general anesthesia but none, to date, have evaluated the safety of combined procedures under conscious sedation.

Applications

In medical centers where propofol or general anesthesia is not readily available, same-day combined EUS and ERCP under conscious sedation can be performed safely.

Peer review

It is a good manuscript comparing the retrospective data of the procedures (EUS, ERCP and EUS + ERCP) including a good number of patients. This manuscript will be of use for the medical fraternity.

REFERENCES

1 **Erickson RA**, Garza AA. EUS with EUS-guided fine-needle aspiration as the first endoscopic test for the evaluation of obstructive jaundice. *Gastrointest Endosc* 2001; **53**: 475-484

2 **Eloubeidi MA**, Chen VK, Eltoum IA, Jhala D, Chhieng DC, Jhala N, Vickers SM, Wilcox CM. Endoscopic ultrasound-guided fine needle aspiration biopsy of patients with suspected pancreatic cancer: diagnostic accuracy and acute and 30-day complications. *Am J Gastroenterol* 2003; **98**: 2663-2668

3 **Eloubeidi MA**, Gress FG, Savides TJ, Wiersema MJ, Kochman ML, Ahmad NA, Ginsberg GG, Erickson RA, Dewitt J, Van Dam J, Nickl NJ, Levy MJ, Clain JE, Chak A, Sivak MV Jr, Wong R, Isenberg G, Scheiman JM, Bounds B, Kimmey MB, Saunders MD, Chang KJ, Sharma A, Nguyen P, Lee JG, Edmundowicz SA, Early D, Azar R, Etemad B, Chen YK, Waxman I, Shami V, Catalano MF, Wilcox CM. Acute pancreatitis after EUS-guided FNA of solid pancreatic masses: a pooled analysis from EUS centers in the United States. *Gastrointest Endosc* 2004; **60**: 385-389

4 **O'Toole D**, Palazzo L, Arotçarena R, Dancour A, Aubert A, Hammel P, Amaris J, Ruszniewski P. Assessment of complications of EUS-guided fine-needle aspiration. *Gastrointest Endosc* 2001; **53**: 470-474

5 **Liu CL**, Fan ST, Lo CM, Tso WK, Wong Y, Poon RT, Lam CM, Wong BC, Wong J. Comparison of early endoscopic ultrasonography and endoscopic retrograde cholangiopancreatography in the management of acute biliary pancreatitis: a prospective randomized study. *Clin Gastroenterol Hepatol* 2005; **3**: 1238-1244

6 **Rollhauser C**, Kim CY, Bandres D, Benjamin SB, Eisen GM, Tio TL, Al-Kawas FH. Feasibility of same-day endoscopic ultrasound (EUS) and ERCP [abstract]. *Gastrointest Endosc* 1997; **45**: AB178

7 **Di Matteo F**, Shimpi L, Gabbrielli A, Martino M, Caricato M, Esposito A, De Cicco ML, Coppola R, Costamagna G. Same-day endoscopic retrograde cholangiopancreatography after transduodenal endoscopic ultrasound-guided needle aspiration: do we need to be cautious? *Endoscopy* 2006; **38**: 1149-1151

8 **Tarantino I**, Barresi L, Di Pisa M, Traina M. Simultaneous endoscopic ultrasound fine needle aspiration and endoscopic retrograde cholangio-pancreatography: Evaluation of safety. *World J Gastroenterol* 2007; **13**: 3861-3863

9 **Duchmann JC**, Benkirane A, Herve E, Barbare JC, Latrive JP, Messerschmitt C. [Endoscopic ultrasonography and endoscopic retrograde cholangiopancreatography performed during the same anesthesia session] *Gastroenterol Clin Biol* 1999; **23**: 1028-1032

10 **Mergener K**, Jowell PS, Branch MS, Baillie J. Pneumoperitoneum complicating ERCP performed immediately after EUS-guided fine needle aspiration. *Gastrointest Endosc* 1998; **47**: 541-542

11 **Freeman ML**, DiSario JA, Nelson DB, Fennerty MB, Lee JG, Bjorkman DJ, Overby CS, Aas J, Ryan ME, Bochna GS, Shaw MJ, Snady HW, Erickson RV, Moore JP, Roel JP. Risk factors for post-ERCP pancreatitis: a prospective, multicenter study. *Gastrointest Endosc* 2001; **54**: 425-434

S- Editor Tian L **L- Editor** Webster JR **E- Editor** Lin YP

World Journal of Gastroenterology

Online Submissions: http://www.wjgnet.com/1007-9327office
wjg@wjgnet.com
doi:10.3748/wjg.v16.i26.3292

World J Gastroenterol 2010 July 14; 16(26): 3292-3298
ISSN 1007-9327 (print)
© 2010 Baishideng. All rights reserved.

BRIEF ARTICLE

Functional magnetic resonance imaging in an animal model of pancreatic cancer

Robert J Lewandowski, Aaron C Eifler, David J Bentrem, Johnathan C Chung, Dingxin Wang, Gayle E Woloschak, Guang-Yu Yang, Robert Ryu, Riad Salem, Andrew C Larson, Reed A Omary

Robert J Lewandowski, Aaron C Eifler, Johnathan C Chung, Dingxin Wang, Robert Ryu, Riad Salem, Andrew C Larson, Reed A Omary, Department of Radiology, Northwestern University Feinberg School of Medicine, Chicago, IL 60611, United States
David J Bentrem, Department of Surgical Oncology, Northwestern University Feinberg School of Medicine, Chicago, IL 60611, United States
Gayle E Woloschak, Department of Radiation Oncology, Northwestern University Feinberg School of Medicine, Chicago, IL 60611, United States
Guang-Yu Yang, Department of Pathology, Northwestern University Feinberg School of Medicine, Chicago, IL 60611, United States
Author contributions: Larson AC, Omary RA and Lewandowski RJ designed the research; Bentrem DJ, Woloschak GE and Yang GY contributed the animal model; Chung JC, Wang D and Larson AC performed the imaging; Ryu R, Salem R and Omary RA performed catheterization of rabbits; Eifler AC analyzed the data; Lewandowski RJ and Eifler AC wrote the manuscript.
Supported by A Society of Interventional Radiology Foundation Pilot Research Grant (to Lewandowski RJ) and a Howard Hughes Medical Institute Medical Research Training Fellow (to Eifler AC)
Correspondence to: Robert J Lewandowski, MD, Assistant Professor, Department of Radiology, Northwestern University Feinberg School of Medicine, 676 N St Clair St, Suite 800, Chicago, IL 60611, United States. r-lewandowski@northwestern.edu
Telephone: +1-312-6959121 Fax: +1-312-9265991
Received: November 25, 2009 Revised: December 24, 2009
Accepted: December 31, 2009
Published online: July 14, 2010

Abstract

AIM: To test the hypotheses that diffusion weighed (DW)- and transcatheter intraarterial perfusion (TRIP)-magnetic resonance imaging (MRI) can each be used to assess regional differences in tumor function in an animal pancreatic cancer model.

METHODS: VX2 tumors were implanted in pancreata of 6 rabbits. MRI and digital subtraction angiography (DSA) were performed 3 wk following implantation. With a 2-French catheter secured in the rabbit's gastroduodenal artery, each rabbit was transferred to an adjacent 1.5T MRI scanner. DW- and TRIP-MRI were performed to determine if necrotic tumor core could be differentiated from viable tumor periphery. For each, we compared mean differences between tumor core/periphery using a 2-tailed paired *t*-test (α = 0.05). Imaging was correlated with histopathology.

RESULTS: Tumors were successfully grown in all rabbits, confirmed by necropsy. On DW-MRI, mean apparent diffusion coefficient (ADC) value was higher in necrotic tumor core (2.1 ± 0.3 mm^2/s) than in viable tumor periphery (1.4 ± 0.5 mm^2/s) ($P < 0.05$). On TRIP-MRI, mean perfusion values was higher in tumor periphery (110 ± 47 relative units) than in tumor core (66 ± 31 relative units) ($P < 0.001$).

CONCLUSION: Functional MRI can be used to differentiate necrotic from viable tumor cells in an animal pancreatic cancer model using ADC (DW-MRI) and perfusion (TRIP-MRI) values.

© 2010 Baishideng. All rights reserved.

Key words: Animal model; Functional magnetic resonance imaging; Pancreatic cancer

Peer reviewers: Dr. Mark De Ridder, MD, PhD, Professor, Department of Radiotherapy, UZ Brussels, Vrije Universiteit Brussels, Laarbeeklaan 101, B-1090 Brussels, Belgium; Xiao-Peng Zhang, Professor, Department of Radiology, Peking University School of Oncology, Beijing Cancer Hospital and Institute, No. 52 Haidian District, Beijing 100142, China

Lewandowski RJ, Eifler AC, Bentrem DJ, Chung JC, Wang D, Woloschak GE, Yang GY, Ryu R, Salem R, Larson AC, Omary

RA. Functional magnetic resonance imaging in an animal model of pancreatic cancer. *World J Gastroenterol* 2010; 16(26): 3292-3298 Available from: URL: http://www.wjgnet.com/1007-9327/full/v16/i26/3292.htm DOI: http://dx.doi.org/10.3748/wjg.v16.i26.3292

INTRODUCTION

Pancreatic cancer, the fourth leading cause of cancer-related mortality in the United States[1], portends a median survival of 6 mo and a 5-year survival of less than 5%[1-4]. Operative resection is indicated in less than 20% of patients and only increases median 5-year survival to 12%[5,6]. Given these grim statistics and paucity of therapeutic options, this disease represents an arena in which the development of novel therapies is greatly needed.

Since the 1980s, innovative, minimally invasive transcatheter intraarterial techniques to treat malignancies, particularly in the liver, have been developed. These techniques, including bland-, chemo-, and radio-embolization, have been shown to improve survival and/or induce imaging responses while being well tolerated by patients[7,8]. Despite some reports demonstrating preliminary success in the treatment of advanced pancreatic cancer with the transcatheter intraarterial infusion of chemotherapy directly to the pancreas[9-12], few studies have assessed local pancreas-directed therapies.

Before catheter-directed clinical therapies can be developed, it would be useful to develop functional imaging targets in a pre-clinical animal model of pancreatic cancer. Functional imaging is important because conventional anatomic magnetic resonance imaging (MRI) has a low sensitivity to detect pancreatic cancer and separate tumor from adjacent uninvolved pancreatic tissue[13,14]. In addition, even in instances where the tumor can be readily visualized with conventional MRI, therapies might have an effect on tumor function but no effect on overall tumor size. Functional targets could include the assessment of changes in water mobility (diffusion) and tumor perfusion using MRI.

The mouse is the most commonly used animal model of pancreatic cancer[15]. However, catheter-based therapies require an animal model large enough to permit catheterization of mesenteric vessels and tumor sizes large enough that can be visible using clinical MRI scanners. The VX2 model of cancer in rabbits is established in translational studies of uterine[16], liver[17,18], lung[19,20], brain[21,22], and renal neoplasms[23,24]. We have recently established this cancer model in the pancreas[25]. The purpose of this study is to test the hypotheses that (1) diffusion weighted (DW); and (2) perfusion MRI can be used to assess regional differences in tumor function in this rabbit model of pancreatic cancer. If feasible, these functional MRI parameters could potentially be used as surrogate functional endpoints when testing future novel transcatheter pancreatic therapies.

MATERIALS AND METHODS

VX2 animal model

Our Animal Care and Use Committee approved this study. Three VX2 tumors were implanted by an attending surgical oncologist and grown in the pancreata of 6 New Zealand White rabbits using the chunk implantation method[26]. At 2 wk following pancreatic VX2 implantation, MRI scans were obtained using a 1.5-T scanner (Espree; Siemens Medical Solutions, Erlangen, Germany). Rabbits were imaged in the supine position with a single-channel head coil. We obtained T2-weighted turbo spin echo images with the following parameters: 4210/86 (repetition time ms/echo time ms), 3 mm thick sections, 180 mm × 121 mm field of view, 256 × 172 matrix, 150° flip angle, 205 Hz per pixel bandwidth, and two signals acquired. Tumor growth was considered positive when tumor was identified in axial and coronal imaging planes by two independent attending interventional radiologists.

Digital subtraction angiography and catheter placement

We performed X-ray digital subtraction angiography (DSA) using a C-arm unit (Powermobil; Siemens Medical Solutions, Erlangen, Germany) 3 wk after VX2 tumor implantation. The femoral artery was accessed through a surgical cut-down and catheterized with a 22-gauge angiocatheter (Terumo Medical, Somerset, NJ, USA). A 2-F catheter (Cook, Bloomington, IN, USA) was advanced over a 0.014-inch diameter guide wire (Terumo Medical, Tokyo, Japan). We then selectively catheterized the gastroduodenal artery. We performed X-ray DSA of the celiac artery and gastroduodenal artery by using hand injections of iohexol (Omnipaque 350; Amersham Health, Princeton, NJ, USA). Once catheter placement was complete, a 2-0 silk suture in the rabbit's groin was used to hold the catheter in place while the rabbit was transferred to the adjacent MRI suite.

MRI following catheterization

MRI after catheter placement was performed using a Siemens 1.5-T Espree clinical MR scanner. To depict tumor anatomy, we first acquired two-dimensional turbo spin-echo T2-weighted images with the above described scan parameters. DW-MRI was performed with single-shot spin-echo echo planar imaging with the following scan parameters: repetition time/echo time, 4000/93 ms; slice thickness 3 mm; bandwidth, 1185 Hz/pixel; partial Fourier factor, 6/8; nonselective fat saturation; twice refocused spin-echo diffusion weighting to reduce eddy current-induced distortion with b values of 0, 50 and 500 s/mm^2. DW-MRI measures changes in the mobility of water as a means of differentiating viable and highly cellular regions from acellular or necrotic regions of tumors. The mobility of water is measured using the apparent diffusion coefficient (ADC). ADC maps, which showed water mobility measurements corresponding to separate spatial locations, were reconstructed from each series of DW images. In these ADC maps, signal intensity directly correlates with water mobility. Using T1-weighted contrast agent-enhanced images as a reference, we drew regions of interest to calculate mean tumor ADC values. Regions of interest were also drawn to compare the ADC values for the necrotic core and the viable outer ring typically present in VX2 tumors.

For tumor perfusion imaging, we used transcatheter intraarterial perfusion (TRIP)-MRI[27], an innovative first-pass perfusion technique employing direct catheter-based intraarterial injections of contrast medium. This technique can be used to detect intra-procedural changes in perfusion to targeted tumor cells and surrounding parenchyma[28]. For TRIP-MRI, we used a three-dimensional spoiled gradient echo sequence with the following parameters: repetition time/echo time, 5/1.6 ms; 15° flip angle; contiguous axial slices of 3 mm thickness; eight partitions; 200 mm × 100 mm field of view; 128 × 64 matrix; and 660 Hz/pixel bandwidth. This TRIP-MRI sequence is a real-time three-dimensional MR fluoroscopy technique[29] that rapidly and continuously images the entire tumor during transcatheter contrast medium injection. TRIP-MRI scans were obtained during hand injections of 2 mL 20% gadopentetate dimeglumine solution (Magnevist; Berlex, Wayne, NJ, USA) over 5 s *via* a catheter previously placed during DSA. Each contrast medium injection was immediately followed by a 4-mL saline solution flush injected over 5 s. For each TRIP-MRI scan, the entire pancreas area including tumor(s) was continuously sampled at 1.6-s intervals for 100 s.

Before and after TRIP-MRI, we obtained anatomic images with two-dimensional T1-weighted gradient-echo MRI. The T1-weighted scan parameters were as follows: repetition time/echo time, 193/6 ms; average of 2; flip angle of 80°; bandwidth of 475 Hz/pixel; slice thickness of 3; 256 × 160 matrix; and field of view of 180 mm × 113 mm.

With the baseline R_{10} map, a longitudinal relaxation rate R_1 map time series was derived from the signal intensity ratio between the baseline image and each TRIP-MRI series with nonlinear curve fitting. Increases in R_1 after injection are proportional to increases in contrast agent concentration. For each R_1 map time series, we calculated the first-pass area under the curve for each voxel, thereby producing spatially resolved perfusion maps for each TRIP-MRI scan. Regions of interest were drawn to measure mean tumor area under the curve. Each TRIP-MRI area under the curve (AUC) measurement served as a semi-quantitative index of tumor perfusion. Tumor regions of interest were placed in peripheral hypervascular regions to avoid the necrotic core.

Necropsy and histopathology

Once the MRI was completed, each rabbit was sacrificed with intravenous administration of 150-200 mg/kg sodium pentobarbital (Euthasol; Delmarva Laboratories, Midlothian, VA, USA). Each rabbit tumor was harvested for pathologic confirmation of VX2 tumor growth and location in pancreatic tissue. Pancreatic tumors were inspected grossly for anatomic consistency with MR images. Tumor samples, including surrounding tissue, were then removed, embedded in paraffin, and mounted on glass slides. These 4-μm-thick slices were stained with hematoxylin and eosin. An attending surgical pathologist performed histopathologic analysis using a Zeiss Axioskop Confocal (Germany) microscope and Zeiss Plan (NEOFLUAR 2.5 ×) objective lens. Imaging was performed with a Cambridge Research and Instrumentation model N-MSI-420-FL camera and Cri Nuance Multispectral Imaging System version 1.6 software.

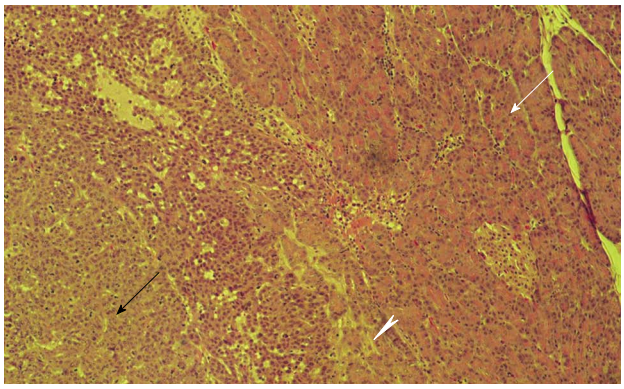

Figure 1 Histopathologic image obtained at necropsy. Border between viable VX2 tumor cells (black arrow) and healthy pancreatic tissue (white arrow) with irritated pancreatitis-like tissue at the tumor-pancreas interface (arrowhead). Note islet of Langerhans within healthy pancreatic tissue. Hematoxylin-eosin stain; original magnification × 25.

Statistical analysis

MR and X-ray DSA images were viewed in conjunction with one another. All MR images were analyzed on a computer workstation (Argus; Siemens Medical Solutions). We compared mean differences between necrotic tumor core and viable tumor periphery for DW-MRI (ADC value) and TRIP-MRI (AUC) using a 2-tailed paired *t*-test, with $\alpha = 0.05$. Mean values were reported ± 1SD. All statistical tests were performed using InStat version 3.06 for Windows (GraphPad Software, San Diego, CA, USA).

RESULTS

Eleven tumors were successfully grown in 6 rabbits, as confirmed by necropsy (Figure 1). Tumors in all 6 rabbits were successfully depicted using anatomic and DW-MRI. Anatomic T2-weighted images showed increased signal intensity within the tumors compared to surrounding tissues (Figure 2).

With DW-MRI, tumors showed regions of low water mobility within the viable periphery, as signified by increased signal intensity (SI) at higher *b* values (Figure 3). This finding suggests increased cellularity compared to the tumor core and surrounding tissues. The mean ADC value was higher in the necrotic tumor core (2.1 ± 0.3 mm^2/s) than in the viable tumor periphery (1.4 ± 0.5 mm^2/s) ($P < 0.05$).

TRIP-MRI was successful in 5 of 6 rabbits. One rabbit could not be catheterized for DSA due to severe vasospasm. TRIP-MRI scans showed tumor perfusion to the peripheral viable portions of the tumor, with lack of perfusion to the central necrotic portions of the tumor (Figure 4). Mean AUC was significantly higher in the periphery (110 ± 47 relative units) than in the central core (66 ± 31 relative units) ($P < 0.00002$) (Figure 5).

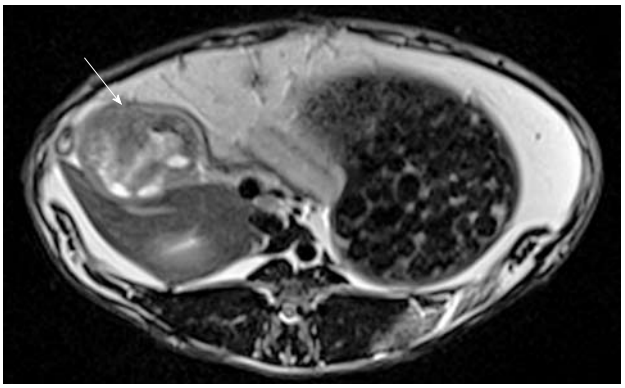

Figure 2 T2-weighted turbo spin echo magnetic resonance imaging showing pancreatic tumor (arrow) in axial view.

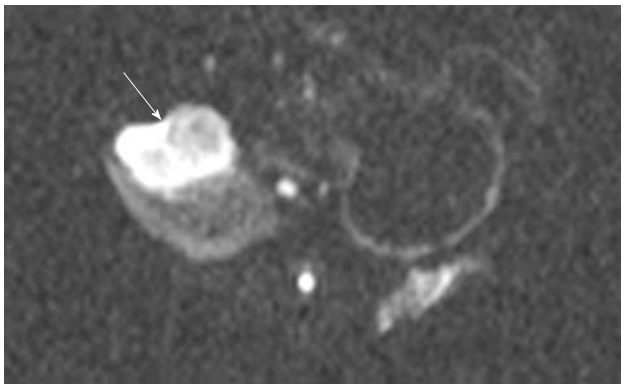

Figure 3 Single shot spin-echo planar diffusion weighted MRI (b = 500 s/mm^2) showing pancreatic tumor (arrow) in axial view.

When comparing DW- and TRIP-MRI, regions of relatively low water mobility correlated with relatively greater tissue perfusion.

DISCUSSION

The results of this study confirm the hypothesis that functional MRI can be used to differentiate necrotic from viable tumor cells in an animal model of pancreatic cancer. Regions of necrosis were delineated from viable tumor cells by larger ADC values on DW-MRI and reduced perfusion values with TRIP-MRI. These results are relevant because the differentiation between malignant and uninvolved or adequately treated pancreatic tissue is difficult with conventional anatomic MRI.

In several preliminary clinical studies enrolling 8-26 patients, DW-MRI has been shown to be able to detect pancreatic carcinoma and differentiate neoplasm from confluent pancreatitis[30-32]. Viable tumor cells are highly cellular and have intact cell membranes. This restricts the motion of water molecules and results in a decrease in the ADC value. Conversely, cellular necrosis causes increased membrane permeability, allowing free diffusion of water molecules and a marked increase in the ADC value. DW-MRI has also been shown to be able to accurately predict the degree of tumor necrosis in hepatocellular carcinoma

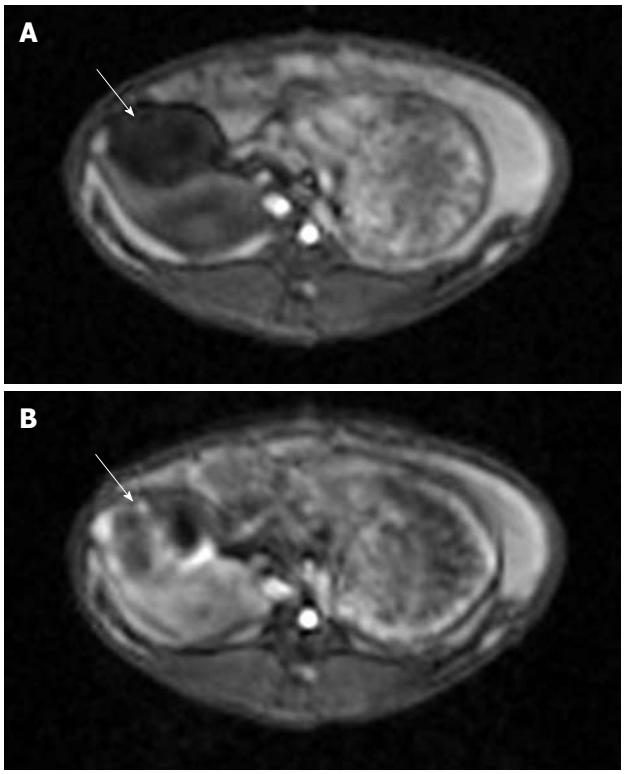

Figure 4 T1-weighted gradient-echo magnetic resonance [taken before (A) and after (B) TRIP imaging occurred]. Each image shows a VX2 tumor (solid arrows) located in the pancreas. Note the areas of increased perfusion to the viable tumor periphery in image B.

following transcatheter liver-directed therapy[33-36]. Our current study demonstrates that DW-MRI can be used to differentiate necrotic from viable cells in this animal model of pancreatic cancer.

TRIP-MRI uses catheter-directed intraarterial injections of gadolinium. This technique is distinct from dynamic contrast-enhanced (DCE)-MRI, which uses intravenous injections of gadolinium. TRIP-MRI has several advantages over DCE-MRI including the capacity for dramatically lower volumes of contrast agents and the ability to perform serial injections without needing to wait > 1 h for injected contrast agent to wash-out. A pre-clinical study in the VX2 rabbit liver tumor model has validated the utility of TRIP-MRI to monitor iterative changes in liver tumor perfusion during embolization[27]. This technique has been translated clinically to measure intra-procedural changes in perfusion to targeted tumors during the treatment of patients with hepatocellular carcinoma with chemoembolization[28]. Because of its ability to enhance tissue distal to the catheter tip, TRIP-MRI can also verify that tumors will be adequately targeted by localized catheter-based techniques prior to their injection. This study demonstrates that TRIP-MRI can be used to detect differences in perfusion to necrotic and viable pancreatic tumor cells.

The development of localized therapies for unresectable pancreatic cancer represents a new avenue for research. As recently demonstrated by Olive *et al*[37], a stromal

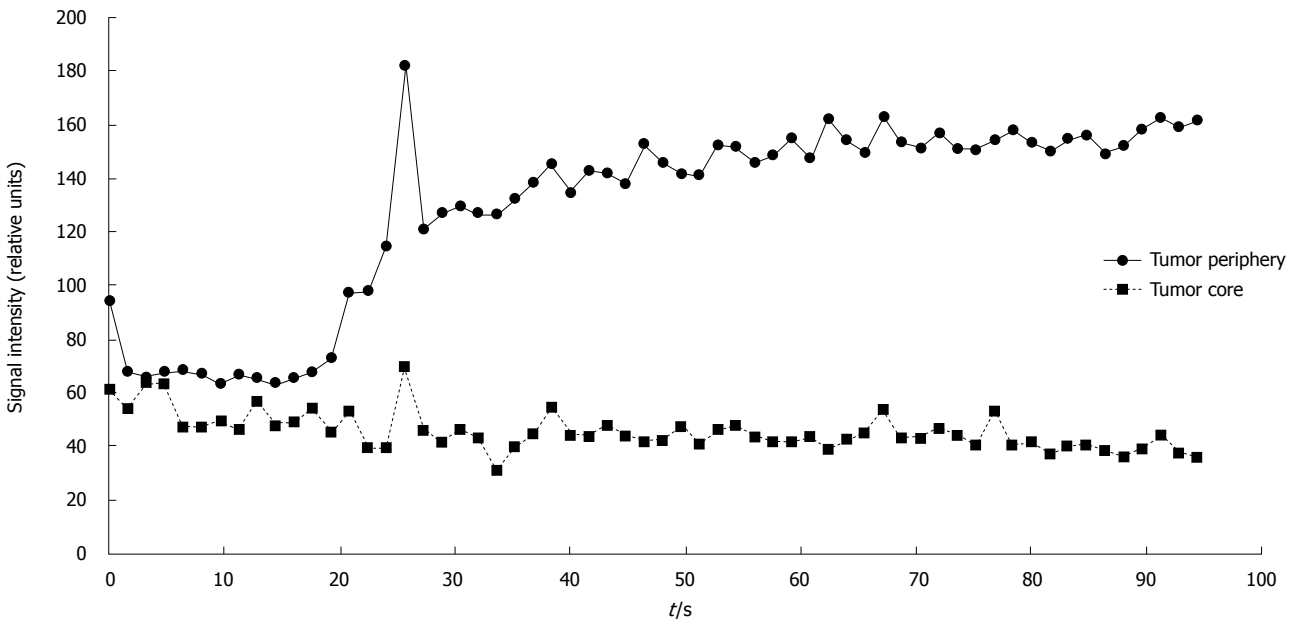

Figure 5 Signal intensity *vs* time curve for one pancreatic tumor, depicting higher signal intensity in the viable tumor periphery than in the necrotic tumor core.

desmoplastic reaction encapsulating pancreatic tumors greatly impedes systemic therapies and thus localized therapies that are able to greatly increase the local concentration of therapeutics may offer benefit in overcoming this fibrotic capsule. Preliminary studies have reported on transcatheter intraarterial infusion of chemotherapy for advanced pancreatic cancer[9-11], which may provide improved response to therapy[12]. The functional MRI parameters described in this animal model of pancreatic cancer could potentially be used as surrogate functional endpoints to test such transcatheter pancreatic therapies. The animal model and functional MRI techniques described in this paper could also be used to assess novel localized therapies intended to target some of the molecular mechanisms underlying pancreatic cancer, including a mutant *p53* tumor suppressor gene[38] or other inhibitors of apoptosis, such as survivin[39,40].

Our study had several important limitations. First, the molecular mechanisms that govern pancreatic ductal adenocarcinoma and VX2-based tumors differ. VX2 is a squamous cell carcinoma that does not have the alterations in the multiple molecular pathways seen with true pancreatic cancer[41]. Our model, however, does mimic well the position and blood supply of a human pancreatic tumor which makes it well suited to the translational development of localized therapies. Second, the smaller diameter of rabbit pancreatic arteries precluded direct catheterization of the pancreaticoduodenal, dorsal pancreatic, great pancreatic, and caudal pancreatic arteries. These arteries are also extremely difficult to selectively catheterize in patients. Additionally, TRIP-MRI verified that perfusion to viable pancreatic tumor cells could be achieved *via* catheterization of the rabbit gastroduodenal artery. Third, although functional imaging in animals is not entirely novel, previous studies have focused on rodents instead of rabbits[42], and have primarily employed high field strength magnets[43]. Using a 1.5-T scanner, we believe, allows our findings to be more readily translated into future clinical studies. Finally, we did not assess the effect of therapy in this animal model. Such assessment will be the subject of future studies.

In conclusion, functional MRI parameters can be used to differentiate necrotic from viable tumor cells in an animal model of pancreatic cancer. Regions of necrosis are delineated by larger ADC values on DW-MRI and reduced perfusion values with TRIP-MRI. In a disease that so desperately needs a more effective treatment, these functional MRI parameters could potentially be used as surrogate functional endpoints when testing future novel local transcatheter pancreatic therapies.

COMMENTS

Background

Pancreatic ductal adenocarcinoma (commonly referred to as pancreatic cancer) carries the worst prognosis of any cancer, thus novel therapies must be developed to treat this disease. Because evaluation of these new therapies may be difficult, imaging modalities to assess therapeutic efficacy based on tumor necrosis are desirable.

Research frontiers

Functional magnetic resonance imaging (MRI) modalities are quickly emerging as new imaging methods with the potential to provide more information about structures in the body than traditional anatomic MRI. In this study, the authors demonstrate that the use of two specific types of functional MRI: diffusion-weighted MRI (DW-MRI) to measure tissue diffusion; and transcatheter intraarterial perfusion MRI (TRIP-MRI) to measure perfusion, could be used to differentiate tumor cells that are dead from those that are still alive.

Innovations and breakthroughs

This study is the first to combine cutting edge imaging modalities (DW-MRI and TRIP-MRI) performed using a clinical 1.5T MRI scanner with a recently created rabbit model of pancreatic cancer which allows for intraarterial catheterization.

Applications

By characterizing this model of pancreatic cancer using functional MRI, this

study may allow for more effective development of much-needed novel therapeutics for the treatment of this disease.

Terminology

DW-MRI and TRIP-MRI are types of MRI called "functional" MRI because they provide information about tissue function in addition to anatomical information provided by traditional MRI. DW-MRI is used to acquire a value called the apparent diffusion coefficient which is a relative measure of water diffusion within a tissue. TRIP-MRI is used to acquire a measure of relative perfusion which represents the amount of blood flow to a tissue.

Peer review

The manuscript is well written and methodology is accurately described. The manuscript applied function MRI in pancreas tumor model and results showed that MR-DWI and TRIP-MRI can distinguish the necrotic tissue form living tissue of pancreas tumor model. This gives us more confidence on the potential of function MRI in the therapy response evaluation. Limitations of the study are considered by the authors themselves and substantiated in the discussion.

REFERENCES

1 **American Cancer Society**. Cancer Facts & Figures 2008. Atlanta: American Cancer Society, 2008

2 **Ries L**, Melbert D, Krapcho M, Stinchcomb D, Howlader N, Horner M, Mariotto A, Miller B, Feuer E, Altekruse S, Lewis D, Clegg L, Eisner M, Reichman M, Edwards B. SEER Cancer Statistics Review, 1975-2005. Bethesda: National Cancer Institute, 2008

3 **Mayer RJ**. Neoplastic disorders. In: Kasper DL, Fauci AS, Longo DL, Braunwald E, Hanser SL, Jameson JL, editors. Harrison's principles of internal medicine. 16th ed. New York: McGaw-Hill, 2005: 537-539

4 **Carpelan-Holmström M**, Nordling S, Pukkala E, Sankila R, Lüttges J, Klöppel G, Haglund C. Does anyone survive pancreatic ductal adenocarcinoma? A nationwide study re-evaluating the data of the Finnish Cancer Registry. *Gut* 2005; **54**: 385-387

5 **Conlon KC**, Klimstra DS, Brennan MF. Long-term survival after curative resection for pancreatic ductal adenocarcinoma. Clinicopathologic analysis of 5-year survivors. *Ann Surg* 1996; **223**: 273-279

6 **Garcea G**, Dennison AR, Pattenden CJ, Neal CP, Sutton CD, Berry DP. Survival following curative resection for pancreatic ductal adenocarcinoma. A systematic review of the literature. *JOP* 2008; **9**: 99-132

7 **Lo CM**, Ngan H, Tso WK, Liu CL, Lam CM, Poon RT, Fan ST, Wong J. Randomized controlled trial of transarterial lipiodol chemoembolization for unresectable hepatocellular carcinoma. *Hepatology* 2002; **35**: 1164-1171

8 **Llovet JM**, Real MI, Montaña X, Planas R, Coll S, Aponte J, Ayuso C, Sala M, Muchart J, Solà R, Rodés J, Bruix J. Arterial embolisation or chemoembolisation versus symptomatic treatment in patients with unresectable hepatocellular carcinoma: a randomised controlled trial. *Lancet* 2002; **359**: 1734-1739

9 **Homma H**, Doi T, Mezawa S, Takada K, Kukitsu T, Oku T, Akiyama T, Kusakabe T, Miyanishi K, Niitsu Y. A novel arterial infusion chemotherapy for the treatment of patients with advanced pancreatic carcinoma after vascular supply distribution via superselective embolization. *Cancer* 2000; **89**: 303-313

10 **Ohigashi H**, Ishikawa O, Yokayama S, Sasaki Y, Yamada T, Imaoka S, Nakaizumi A, Uehara H. Intra-arterial infusion chemotherapy with angiotensin-II for locally advanced and nonresectable pancreatic adenocarcinoma: further evaluation and prognostic implications. *Ann Surg Oncol* 2003; **10**: 927-934

11 **Tanaka T**, Sakaguchi H, Anai H, Yamamoto K, Morimoto K, Nishiofuku H, Kichikawa K. Catheter position for adequate intra-arterial chemotherapy for advanced pancreatic cancer: evaluation with CT during arterial injection of contrast material. *J Vasc Interv Radiol* 2004; **15**: 1089-1097

12 **Miyanishi K**, Ishiwatari H, Hayashi T, Takahashi M, Kawano Y, Takada K, Ihara H, Okuda T, Takanashi K, Takahashi S, Sato Y, Matsunaga T, Homma H, Kato J, Niitsu Y. A Phase I trial of arterial infusion chemotherapy with gemcitabine and 5-fluorouracil for unresectable advanced pancreatic cancer after vascular supply distribution via superselective embolization. *Jpn J Clin Oncol* 2008; **38**: 268-274

13 **Megibow AJ**, Zhou XH, Rotterdam H, Francis IR, Zerhouni EA, Balfe DM, Weinreb JC, Aisen A, Kuhlman J, Heiken JP. Pancreatic adenocarcinoma: CT versus MR imaging in the evaluation of resectability--report of the Radiology Diagnostic Oncology Group. *Radiology* 1995; **195**: 327-332

14 **Semelka RC**, Ascher SM. MR imaging of the pancreas. *Radiology* 1993; **188**: 593-602

15 **Grippo PJ**, Sandgren EP. Modeling pancreatic cancer in animals to address specific hypotheses. *Methods Mol Med* 2005; **103**: 217-243

16 **Rhee TK**, Ryu RK, Bangash AK, Wang D, Szolc-Kowalska B, Harris KR, Sato KT, Chrisman HB, Vogelzang RL, Paunesku T, Woloschak GE, Larson AC, Omary RA. Rabbit VX2 tumors as an animal model of uterine fibroids and for uterine artery embolization. *J Vasc Interv Radiol* 2007; **18**: 411-418

17 **Geschwind JF**, Artemov D, Abraham S, Omdal D, Huncharek MS, McGee C, Arepally A, Lambert D, Venbrux AC, Lund GB. Chemoembolization of liver tumor in a rabbit model: assessment of tumor cell death with diffusion-weighted MR imaging and histologic analysis. *J Vasc Interv Radiol* 2000; **11**: 1245-1255

18 **Nijsen JF**, Seppenwoolde JH, Havenith T, Bos C, Bakker CJ, van het Schip AD. Liver tumors: MR imaging of radioactive holmium microspheres--phantom and rabbit study. *Radiology* 2004; **231**: 491-499

19 **Goldberg SN**, Gazelle GS, Compton CC, Mueller PR, McLoud TC. Radio-frequency tissue ablation of VX2 tumor nodules in the rabbit lung. *Acad Radiol* 1996; **3**: 929-935

20 **Ogilvie RW**, Blanding JD Jr, Wood ML, Knisely WH. The arterial supply to experimental metastatic vx2 and xy tumors in rabbit lungs. *Cancer Res* 1964; **24**: 1418-1431

21 **Brem SS**, Zagzag D, Tsanaclis AM, Gately S, Elkouby MP, Brien SE. Inhibition of angiogenesis and tumor growth in the brain. Suppression of endothelial cell turnover by penicillamine and the depletion of copper, an angiogenic cofactor. *Am J Pathol* 1990; **137**: 1121-1142

22 **Frank JA**, Girton M, Dwyer AJ, Cohen PJ, Knop RH, Diggs R, Cobb J, Doppman JL. A reproducible model of metastatic brain and ocular tumor by hematogenous inoculation of the VX2 tumor in rabbits. *J Neurosurg* 1987; **67**: 106-109

23 **Horkan C**, Ahmed M, Liu Z, Gazelle GS, Solazzo SA, Kruskal JB, Goldberg SN. Radiofrequency ablation: Effect of pharmacologic modulation of hepatic and renal blood flow on coagulation diameter in a VX2 tumor model. *J Vasc Interv Radiol* 2004; **15**: 269-274

24 **Miao Y**, Ni Y, Bosmans H, Yu J, Vaninbroukx J, Dymarkowski S, Zhang H, Marchal G. Radiofrequency ablation for eradication of renal tumor in a rabbit model by using a cooled-tip electrode technique. *Ann Surg Oncol* 2001; **8**: 651-657

25 **Eifler AC**, Lewandowski RJ, Virmani S, Chung JC, Wang D, Tang R, Szolc-Kowalska B, Woloschak GE, Mulcahy MF, Ryu RK, Salem R, Larson AC, Cheon E, Strouch M, Zarlengo D, Bentrem D, Omary RA. Development of the VX2 Pancreatic Cancer Model in Rabbits: A Platform to Test Future Interventional Radiology Therapies. Society of Intervetional Radiology 34th Annual Scientific Meeting. San Diego, CA, 2009

26 **Virmani S**, Harris KR, Szolc-Kowalska B, Paunesku T, Woloschak GE, Lee FT, Lewandowski RJ, Sato KT, Ryu RK, Salem R, Larson AC, Omary RA. Comparison of two different methods for inoculating VX2 tumors in rabbit livers and hind limbs. *J Vasc Interv Radiol* 2008; **19**: 931-936

27 **Wang D**, Bangash AK, Rhee TK, Woloschak GE, Paunesku T, Salem R, Omary RA, Larson AC. Liver tumors: monitoring embolization in rabbits with VX2 tumors--transcatheter in-

traarterial first-pass perfusion MR imaging. *Radiology* 2007; **245**: 130-139

28 **Larson AC**, Wang D, Atassi B, Sato KT, Ryu RK, Lewandowski RJ, Nemcek AA Jr, Mulcahy MF, Kulik LM, Miller FH, Salem R, Omary RA. Transcatheter intraarterial perfusion: MR monitoring of chemoembolization for hepatocellular carcinoma--feasibility of initial clinical translation. *Radiology* 2008; **246**: 964-971

29 **Wang D**, Virmani S, Tang R, Szolc-Kowalska B, Woloschak G, Omary RA, Larson AC. Four-dimensional transcatheter intra-arterial perfusion (TRIP)-MRI for monitoring liver tumor embolization in VX2 rabbits. *Magn Reson Med* 2008; **60**: 970-975

30 **Matsuki M**, Inada Y, Nakai G, Tatsugami F, Tanikake M, Narabayashi I, Masuda D, Arisaka Y, Takaori K, Tanigawa N. Diffusion-weighed MR imaging of pancreatic carcinoma. *Abdom Imaging* 2007; **32**: 481-483

31 **Takeuchi M**, Matsuzaki K, Kubo H, Nishitani H. High-b-value diffusion-weighted magnetic resonance imaging of pancreatic cancer and mass-forming chronic pancreatitis: preliminary results. *Acta Radiol* 2008; **49**: 383-386

32 **Ichikawa T**, Erturk SM, Motosugi U, Sou H, Iino H, Araki T, Fujii H. High-b value diffusion-weighted MRI for detecting pancreatic adenocarcinoma: preliminary results. *AJR Am J Roentgenol* 2007; **188**: 409-414

33 **Kamel IR**, Bluemke DA, Eng J, Liapi E, Messersmith W, Reyes DK, Geschwind JF. The role of functional MR imaging in the assessment of tumor response after chemoembolization in patients with hepatocellular carcinoma. *J Vasc Interv Radiol* 2006; **17**: 505-512

34 **Kamel IR**, Reyes DK, Liapi E, Bluemke DA, Geschwind JF. Functional MR imaging assessment of tumor response after 90Y microsphere treatment in patients with unresectable hepatocellular carcinoma. *J Vasc Interv Radiol* 2007; **18**: 49-56

35 **Deng J**, Miller FH, Rhee TK, Sato KT, Mulcahy MF, Kulik LM, Salem R, Omary RA, Larson AC. Diffusion-weighted MR imaging for determination of hepatocellular carcinoma response to yttrium-90 radioembolization. *J Vasc Interv Radiol* 2006; **17**: 1195-1200

36 **Kamel IR**, Bluemke DA, Ramsey D, Abusedera M, Torbenson M, Eng J, Szarf G, Geschwind JF. Role of diffusion-weighted imaging in estimating tumor necrosis after chemoembolization of hepatocellular carcinoma. *AJR Am J Roentgenol* 2003; **181**: 708-710

37 **Olive KP**, Jacobetz MA, Davidson CJ, Gopinathan A, McIntyre D, Honess D, Madhu B, Goldgraben MA, Caldwell ME, Allard D, Frese KK, Denicola G, Feig C, Combs C, Winter SP, Ireland-Zecchini H, Reichelt S, Howat WJ, Chang A, Dhara M, Wang L, Rückert F, Grützmann R, Pilarsky C, Izeradjene K, Hingorani SR, Huang P, Davies SE, Plunkett W, Egorin M, Hruban RH, Whitebread N, McGovern K, Adams J, Iacobuzio-Donahue C, Griffiths J, Tuveson DA. Inhibition of Hedgehog signaling enhances delivery of chemotherapy in a mouse model of pancreatic cancer. *Science* 2009; **324**: 1457-1461

38 **Li D**, Xie K, Wolff R, Abbruzzese JL. Pancreatic cancer. *Lancet* 2004; **363**: 1049-1057

39 **Hamacher R**, Schmid RM, Saur D, Schneider G. Apoptotic pathways in pancreatic ductal adenocarcinoma. *Mol Cancer* 2008; **7**: 64

40 **Altieri DC**. Survivin, cancer networks and pathway-directed drug discovery. *Nat Rev Cancer* 2008; **8**: 61-70

41 **Jones S**, Zhang X, Parsons DW, Lin JC, Leary RJ, Angenendt P, Mankoo P, Carter H, Kamiyama H, Jimeno A, Hong SM, Fu B, Lin MT, Calhoun ES, Kamiyama M, Walter K, Nikolskaya T, Nikolsky Y, Hartigan J, Smith DR, Hidalgo M, Leach SD, Klein AP, Jaffee EM, Goggins M, Maitra A, Iacobuzio-Donahue C, Eshleman JR, Kern SE, Hruban RH, Karchin R, Papadopoulos N, Parmigiani G, Vogelstein B, Velculescu VE, Kinzler KW. Core signaling pathways in human pancreatic cancers revealed by global genomic analyses. *Science* 2008; **321**: 1801-1806

42 **Bangard C**, Gossmann A, Papyan A, Tawadros S, Hellmich M, Bruns CJ. Magnetic resonance imaging in an orthotopic rat model: blockade of epidermal growth factor receptor with EMD72000 inhibits human pancreatic carcinoma growth. *Int J Cancer* 2005; **114**: 131-138

43 **Kim H**, Morgan DE, Buchsbaum DJ, Zeng H, Grizzle WE, Warram JM, Stockard CR, McNally LR, Long JW, Sellers JC, Forero A, Zinn KR. Early therapy evaluation of combined anti-death receptor 5 antibody and gemcitabine in orthotopic pancreatic tumor xenografts by diffusion-weighted magnetic resonance imaging. *Cancer Res* 2008; **68**: 8369-8376

S- Editor Wang JL **L- Editor** Webster JR **E- Editor** Ma WH

World Journal of Gastroenterology

Online Submissions: http://www.wjgnet.com/1007-9327office
wjg@wjgnet.com
doi:10.3748/wjg.v16.i26.3299

World J Gastroenterol 2010 July 14; 16(26): 3299-3304
ISSN 1007-9327 (print)
© 2010 Baishideng. All rights reserved.

BRIEF ARTICLE

Wireless capsule endoscopy and proximal small bowel lesions in Crohn's disease

Carmelina Petruzziello, Sara Onali, Emma Calabrese, Francesca Zorzi, Marta Ascolani, Giovanna Condino, Elisabetta Lolli, Paola Naccarato, Francesco Pallone, Livia Biancone

Carmelina Petruzziello, Sara Onali, Emma Calabrese, Francesca Zorzi, Marta Ascolani, Giovanna Condino, Elisabetta Lolli, Paola Naccarato, Francesco Pallone, Livia Biancone, GI Unit, Department of Internal Medicine, University "Tor Vergata", Rome 00133, Italy
Author contributions: Petruzziello C performed the majority of the WCE procedures; Naccarato P reviewed the WCE images; Onali S, Calabrese E, Zorzi F and Ascolani M enrolled and followed up the patients; Lolli E and Condino G provided the requested clinical parameters; Pallone F contributed to writing of the manuscript; Biancone L designed the study and wrote the manuscript.
Supported by (in part) The Foundation "Fondazione Umberto Di Mario, Largo Marchiafava", Rome, Italy
Correspondence to: Livia Biancone, MD, PhD, GI Unit, Department of Internal Medicine, University "Tor Vergata", Via Montpellier, 1, Rome 00133, Italy. biancone@med.uniroma2.it
Telephone: +39-6-20903737 Fax: +39-6-20903738
Received: November 6, 2009 Revised: December 11, 2009
Accepted: December 18, 2009
Published online: July 14, 2010

Abstract

AIM: To investigate the prevalence of proximal small bowel (SB) lesions detected by wireless capsule endoscopy (WCE) in Crohn's disease (CD).

METHODS: WCE was performed in 64 patients: 32 with CD of the distal ileum, and 32 controls with iron-deficiency anemia (IDA) or diarrhea. WCE was performed using the Given SB-WCE, followed by small intestine contrast ultrasonography (SICUS). Findings compatible with CD by using WCE included erosions, aphthoid or deep ulcers, and strictures/stenosis.

RESULTS: WCE detected proximal SB lesions in 16/32 (50%) patients (14 aphthoid ulcers, 2 deep ulcers, one stricture), which appeared not to be related to clinical parameters [epigastric pain, age, smoking, non-steroidal anti-inflammatory drugs (NSAIDs), IDA]. Among patients with proximal SB lesions, 6 (37%) were smokers, 3 (19%) NSAID users, 3 (19%) had epigastric pain and 4 (25%) had IDA. SICUS detected proximal SB lesions in 3/32 patients (19%) also showing lesions with WCE. No correlations were observed between proximal SB lesions assessed by WCE or by SICUS ($\chi^2 = 1.5$, $P = 0.2$).

CONCLUSION: The use of WCE allows the detection of previously unknown upper SB lesions in a high proportion of patients with a previous diagnosis of CD involving the distal ileum.

© 2010 Baishideng. All rights reserved.

Key words: Wireless capsule endoscopy; Crohn's disease; Small bowel

Peer reviewer: Javier San Martín, Chief, Gastroenterology and Endoscopy, Sanatorio Cantegril, Av. Roosevelt y P 13, Punta del Este 20100, Uruguay

Petruzziello C, Onali S, Calabrese E, Zorzi F, Ascolani M, Condino G, Lolli E, Naccarato P, Pallone F, Biancone L. Wireless capsule endoscopy and proximal small bowel lesions in Crohn's disease. *World J Gastroenterol* 2010; 16(26): 3299-3304 Available from: URL: http://www.wjgnet.com/1007-9327/full/v16/i26/3299.htm DOI: http://dx.doi.org/10.3748/wjg.v16.i26.3299

INTRODUCTION

Wireless capsule endoscopy (WCE) is a non-invasive technique for visualizing the mucosal surface of the small bowel (SB)[1-7]. However, a variable impact risk (from 0%-6.7%) has been reported[8]. WCE showed a high sensitivity and specificity for detecting lesions related to SB Crohn's disease (CD)[1-7]. A meta-analysis showed an incremental diagnostic yield of WCE *vs* small bowel follow through (SBFT) ($P < 0.001$), ileocolonoscopy ($P =$

0.02), computed tomography enteroclysis ($P = 0.001$) and push enteroscopy ($P < 0.001$)[9]. WCE has in particular been shown to be able to detect minor lesions (erosions, aphthoid ulcer), not visualized by conventional radiologic techniques, which result in high radiation exposure. WCE has therefore been proposed as an alternative non-invasive technique for assessing CD lesions.

Ultrasonography also is a non-invasive technique proposed for detecting SB lesions in CD[10]. The use of an oral contrast [small intestine contrast ultrasonography (SICUS)] significantly increases, in experienced hands, the sensitivity of ultrasonography for assessing SB lesions in CD (> 95%)[11,12].

Although several studies concordantly showed that WCE is able to visualize superficial lesions in the SB, its role in defining the extent of the lesions in CD is undefined. In particular, the frequency and clinical relevance of superficial lesions in the upper SB as detected by WCE, but not by conventional techniques, in patients with an established diagnosis of CD involving the distal ileum, is currently unknown. Disease-specificity of the small lesions as detected by WCE is also under investigation.

On the basis of these observations we therefore aimed to assess, in a prospective longitudinal study in patients with a known diagnosis of CD of the distal ileum, the prevalence of lesions in the proximal SB (jejunum, proximal ileum) compatible with CD, as assessed by WCE. The secondary end point was to evaluate the possible concordance between WCE and SICUS, in detecting SB lesions compatible with CD. Additional end points included investigation of possible correlations between proximal SB lesions in WCE and specific signs and symptoms, including anemia and/or epigastric pain in patients with CD. A comparison between characteristics of SB lesions detected by WCE in patients with CD *vs* patients undergoing WCE for other indications was also performed. The safety of WCE in CD patients with no radiological or clinical evidence of sub/obstructive symptoms was further addressed.

MATERIALS AND METHODS

Study population

In a prospective longitudinal study, WCE was performed in all consecutive CD patients referred to our Unit from May 2004 to May 2008, fulfilling the following inclusion criteria: (1) age 18-75 years; (2) regular follow-up; and (3) established diagnosis of CD involving the distal ileum, according to standard procedures.

As a control group (C), WCE was performed in all consecutive patients referred to our Unit from May 2004 to May 2008, with the following inclusion criteria: (1) age 18-75 years; and (2) clinical indication for WCE such as iron-deficiency anemia (IDA) or chronic diarrhea of unknown origin with no diagnosis by conventional procedures. No patients showed evidence of stenoses/strictures. Written informed content was provided by all patients.

Study design

CD group: Before WCE, recorded parameters included: findings at physical examination, activity (CD activity index, CDAI)[13], epigastric pain (yes/no), IDA, laboratory tests (complete blood count, hemoglobin, serum iron, ferritin, creatine phosphate, erythrocyte sedimentation rate), non-steroidal antiinflammatory drug (NSAID) use, and smoking habit. Before WCE, all 32 patients were studied by both SICUS and ileocolonoscopy (median time interval 1 mo, range 0-7 mo, and 1 mo, range 0-14 mo, respectively). After WCE, patients were clinically followed up at least 12 mo (median 24 mo, range 12-36 mo).

C group: Before WCE, recorded parameters included: findings at physical examination, gastrointestinal symptoms, laboratory tests (as above), NSAID use, and smoking habit.

SICUS

SICUS was performed after 375 mL polyethylene glycol (PEG) ingestion[11] using 3.5 and 5 MHz convex and linear-array transducers, by the same expert gastroenterologist (> 2000 examinations). Findings compatible with CD included: increased bowel wall thickness (BWT) (≥ 3 mm), SB dilation (diameter > 2.5 cm), bowel stricture (diameter < 1 cm, at the level of the maximally distended loop)[11,12]. Fistulas or abscesses were considered.

Ileocolonoscopy

All endoscopies were performed by the same gastroenterologist, according to standard procedures.

WCE

WCE was performed with the Given Pillcam SB capsule system (Given Imaging Limited, Yoqneam, Israel)[1] after 3 d of a fiber-free diet and bowel preparation [2 L PEG, (Promefarm, Milano, Italy)]. Images were reviewed by a single gastroenterologist unaware of the SICUS findings.

CD group: The following WCE findings were considered compatible with CD: aphthoid ulcers (> 3), deep ulcers, strictures or stenoses. Erosions, villous dropouts and mucosal breaks were reported, although considered not related to CD. As no standard criteria for defining upper SB lesions using WCE were available, distal SB lesions were considered lesions proximal to the ileo-cecal valve or to the ileo-colonic anastomosis. Upper SB lesions were considered the SB lesions proximal to these areas (jejunum, proximal ileum).

In a subgroup of 10 CD patients with ileo-colonic resection, WCE findings were blindly scored by 2 independent gastroenterologists. For this purpose, lesions in the peri-anastomotic area and in the upper SB were graded as follows[5]: absent (G0), erythema/loss of villi (G1), erosions/aphthoid ulcers (G2), deep ulcers (G3).

C group: Any lesion detected by WCE was reported. A comparison with the CD group considered only those lesions in the upper or distal SB compatible with CD, including: aphthoid or deep ulcers, strictures, stenoses. Planar X-ray of the abdomen was performed in all patients

Table 1 Clinical characteristics of the 32 CD patients studied with WCE

Parameter	*n* (%)
Gender	
Male	16 (50)
Female	16 (50)
Clinical activity	
Active (CDAI > 150)	5 (16)
Inactive (CDAI < 150)	27 (84)
Lesions extent before WCE	
Distal ileum only	27 (84)
Distal ileum and colon	2 (6)
Distal ileum and esophagus/stomach	3 (10)
Previous intestinal resections	
Yes	25 (78)
Smoking habits	
Smokers	14 (44)
Ex-smokers	4 (12)
Non-smokers	14 (44)
NSAID use	
Yes	3 (9)

CD: Crohn's disease; WCE: Wireless capsule endoscopy; CDAI: CD activity index; NSAID: Non-steroidal anti-inflammatory drug.

with no WCE excretion after 48-72 h. Retention was defined as WCE persistence after 14 d. Incomplete studies were defined when WCE did not reach the cecum.

Comparison between WCE and SICUS findings

Comparison between WCE and SICUS in terms of findings compatible with SB lesions related to CD was made using the following parameters: presence (yes/no), site (upper *vs* distal SB) and severity of the lesions (deep *vs* aphthoid ulcers) by using WCE and presence (yes/no) and site (upper *vs* distal SB) of increased BWT (≥ 3 mm) using SICUS. Correlations between WCE findings compatible with upper SB lesions and clinical parameters (age, smoking habits, epigastric pain, IDA) were determined.

Statistical analysis

Results were expressed as median and range both in the text and in the tables. Differences between groups were assessed by the Student's *t*-test. The interobserver variation in terms of presence and severity of upper SB lesions detected by WCE was assessed.

RESULTS

Study population

CD group: Thirty two consecutive patients (16 male, median age 32 years, range 19-65 years) with an established diagnosis of CD of the distal ileum fulfilled the inclusion criteria. Clinical characteristics of the enrolled patients are summarized in Table 1.

Treatment included budesonide (9 mg/d) in 6 (19%) and mesalazine 2.4 g/d in 26 (81%) patients. Among the 32 patients, 4 (12%) had IDA and 7 (22%) epigastric pain.

C group: Thirty two consecutive C patients (16 male, median age 42 years, range 18-72 years) undergoing WCE fulfilled the inclusion criteria. Clinical indications for WCE included IDA in 17 (53%) and chronic diarrhea in 15 (47%) patients.

Figure 1 Plain film of the abdomen from one Crohn's disease patient showing capsule retention for 12 wk, with no associated symptoms. The patient had 2 anastomoses (ileo-ileal and ileo-colonic). Surgical removal was required, showing wireless capsule endoscopy within the "*cul de sac*" of the side-to-side ileo-ileal anastomosis not reachable by the endoscope.

Adverse events

CD group: Retention was observed in one patient (3%) with 2 anastomoses (ileo-ileal and ileo-colonic), showing no symptoms despite capsule retention for > 12 wk (Figure 1). Surgical removal of WCE was required after 2 unsuccessful therapeutic endoscopies. During surgery, WCE was detected within the "*cul de sac*" of the side-to-side ileo-ileal anastomosis not reachable by the endoscope.

C group: No adverse events were reported.

Proximal SB lesions detected by WCE

CD group: WCE detected previously unknown proximal SB lesions compatible with CD in 16/32 (50%) patients. Among these 16 patients, lesions included > 3 aphthoid ulcers in 14 (87.5%), deep ulcers in 2 (12.5%) and one ulcerated stricture identified by WCE in one patient (Figure 2A-C). All lesions compatible with CD appeared discontinuous and surrounded by macroscopically uninvolved mucosa. In all 16 patients showing lesions in the upper SB, WCE also detected lesions in the distal ileum compatible with CD.

The median age was comparable in patients showing or not (n = 16 for both) proximal SB lesions at WCE (44 years, range 20-65 years *vs* 32 years, range 19-48 years, P = NS).

Table 2 summarizes the clinical characteristics of the 32 patients grouped according to the presence or not of upper SB lesions in WCE. No statistically significant concordance was observed between upper SB lesions in WCE for both clinical parameters and risk factors considered (CD site $\chi^2 = 3.3$, $P = 0.18$, epigastric pain $\chi^2 = 0.0$, $P = 1.0$, smoking habits $\chi^2 = 1.3$, $P = 0.5$, NSAIDs use $\chi^2 = 1.5$, $P = 0.2$, IDA $\chi^2 = 0.0$, $P = 1.0$).

The interobserver agreement for SB lesions visualized by WCE (score 0-4)[5] was very high when considering proximal SB lesions ($\kappa = 0.86$) and high when considering distal SB lesions ($\kappa = 0.61$). At 12 mo, none of the 32 patients showing lesions in the upper SB developed related symptoms (anemia, epigastric pain) or symptomatic SB stenosis.

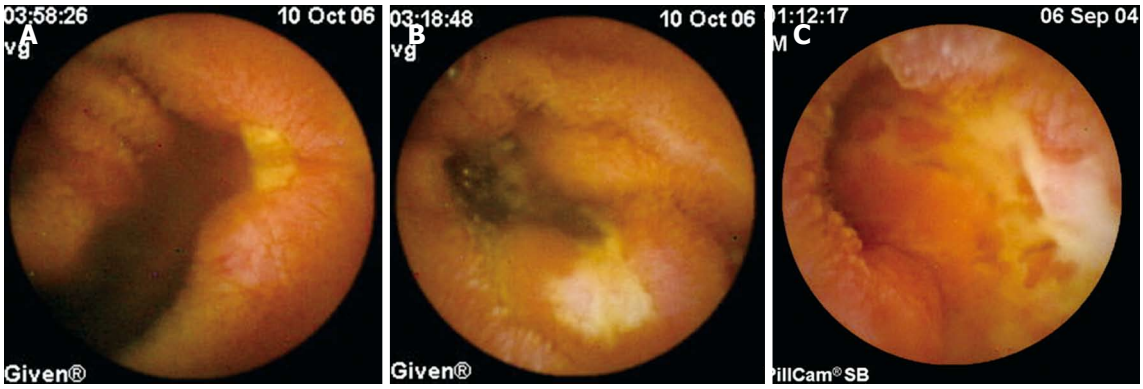

Figure 2 Upper small bowel lesions detected at wireless capsule endoscopy in 3 patients with an established diagnosis of Crohn's disease involving the distal ileum. Aphthoid ulcer (A), deep ulcer (B) and one ulcerated stricture easily identified by wireless capsule endoscopy (C). All lesions compatible with Crohn's disease detected by wireless capsule endoscopy appeared discontinuous and surrounded by macroscopically uninvolved mucosa.

Table 2 Clinical characteristics of the 32 CD patients grouped according to the presence of upper small bowel lesions at WCE

	Small bowel lesions at WCE (%)	
	Yes (n = 16)	No (n = 16)
Known CD extent before WCE		
Distal ileum	12 (75)	15 (94)
Distal ileum and colon	1 (6)	1 (6)
Distal ileum and esophagus stomach	3 (19)	0
Epigastric pain		
Yes	3 (19)	4 (25)
No	13 (81)	12 (75)
Smoking habits		
Smokers	6 (37)	8 (50)
Ex-smokers	3 (19)	1 (6)
Non-smokers	7 (44)	7 (44)
NSAID use		
Yes	3 (19)	0
No	13 (81)	16 (100)
IDA		
Yes	4 (25)	5 (31)
No	12 (75)	11 (69)

IDA: Iron-deficiency anemia.

C group: WCE detected proximal SB lesions not compatible with CD in 5/32 (16%) patients, represented by erosions in 3 (9%) and angiodysplasia in 2 (6%). In contrast to CD patients, none of the 32 C patients showed aphthoid or deep ulcers in the SB with WCE.

Proximal SB lesions detected by SICUS

SICUS detected proximal SB lesions in 3/32 (9%) CD patients, represented by increased jejunal BWT with bowel dilation, associated with stenosis in one patient.

Comparison between WCE and SICUS in detecting upper SB lesions

When considering the 16 CD patients showing upper SB lesions with WCE, only 3 (19%) also showed SICUS findings compatible with CD lesions in the same area (BWT > 3 mm). Therefore, all 3 (9%) patients showing SICUS results compatible with CD lesions in the proximal SB had the findings confirmed by WCE. Upper SB lesions in WCE in these patients included deep ulcers in 2 and aphthoid ulcers in one patient. The only stricture identified by WCE was also visualized by SICUS. However, these 2 techniques showed no significant concordance in detecting proximal SB lesions ($\chi^2 = 1.5$, $P = 0.2$).

Distal SB lesions detected by WCE

CD group: Findings compatible with CD lesions in the distal SB were detected by WCE in 30/32 (93%) patients. In the remaining 2 patients, WCE did not visualize the colon, thus not allowing the evaluation of the distal SB. Of the 30 patients with available distal SB images with WCE, lesions included erosions in 2 (7%), aphthoid ulcers in 13 (43%), deep ulcers in 11 (37%), both aphthoid and deep ulcers in 3 (10%) and one single ulcerated substenosis in one (3%) patient. In all patients showing lesions in the upper SB, WCE also showed lesions in the distal SB.

One patient (PL) showed WCE impaction at the level of the anastomosis as detected by a plain film of the abdomen showing capsule retention for 12 wk, with no associated symptoms (Figure 1). The patient had 2 anastomoses (ileo-ileal and ileo-colonic) for CD-related surgery. Surgical removal of the WCE was required, showing the capsule retained within the "*cul de sac*" of the side-to-side ileo-ileal anastomosis not reachable by the endoscope. In a second patient (CE) with IDA, WCE images stopped at the level of a bleeding ulcerated substenosis in the proximal SB, with no retention (Figure 2C). In this patient indication for surgery was also determined after WCE examination, followed by resection of the ulcerated substenosis not detected by conventional techniques, with histological findings compatible with CD.

C group: WCE detected distal SB lesions not compatible with CD in 2/32 (6%) patients, including erosions in one patient and one single angiodysplasia in the other patient. No patients showed aphthoid or deep ulcers compatible with CD.

Distal SB lesions detected by SICUS

CD group: SICUS detected distal SB lesions in 30/32

(93%) patients, including all 3 patients showing upper SB lesions by SICUS. In both patients with normal SICUS, conventional techniques detected lesions in the distal ileum.

Comparison between WCE and SICUS in detecting distal SB lesions

Findings compatible with CD in the distal SB were detected by both WCE and SICUS in 30/32 (93%) patients, as SICUS detected no lesions in 2 patients. These 2 techniques showed no significant concordance in detecting proximal SB lesions ($\chi^2 = 0.5$, $P = 0.4$).

Additional findings at WCE

CD group: WCE detected gastric and/or duodenal lesions in 7/32 (22%) patients. Gastric lesions were detected in 5/32 (15%) patients, including aphthoid ulcers in one and erosions in 4 patients. Duodenal lesions (erosions) were detected by WCE in 5/32 (15%) patients, and were also visualized in the stomach in 4 patients. Of the 7 patients showing gastric/duodenal lesions at WCE, 5 (71%) also showed upper SB lesions with WCE.

C group: Additional findings were detected in 6/32 (19%) C patients, including gastric/duodenal erosions in 5 and colonic angiodysplasia in 2 (with gastric erosions in one).

DISCUSSION

Proximal SB lesions are detected in a low proportion of CD patients (about 5%)[14-16]. However, these rates have been reported using radiologic techniques which show a low sensitivity for visualizing superficial lesions. Recently, WCE has been shown to visualize the inner SB surface, providing a high sensitivity in detecting minor lesions (i.e. erosions, aphthoid ulcers)[2-4]. Two independent studies reported that WCE visualizes lesions related to early CD recurrence in the SB[17,18]. As the frequency, natural history and clinical relevance of proximal SB lesions in CD is undefined, we investigated this issue in a prospective longitudinal study. A high frequency of WCE findings compatible with proximal SB lesions related to CD was observed. As WCE does not allow an histological characterization of the lesions, WCE findings in CD patients were compared with those observed in control patients requiring WCE for IDA or chronic diarrhea. No control patients showed aphthoid or deep ulcers, thus supporting the specificity of the upper SB lesions detected by WCE in our CD population. No correlations were observed between risk factors and proximal SB lesions, supporting the disease-specificity of our findings.

The frequency of WCE impaction was within the expected range (3%)[8]. The finding of WCE impaction within the "*cul the sac*" of a side-to-side ileo-ileal anastomosis may indicate a higher impaction risk in these patients, even in the absence of overt stenosis. In addition, a WCE examination allowed the detection of a previously unknown ulcerated substenosis in one additional patient with IDA associated with CD of the distal ileum. This observation further supports the role of WCE in identifying upper SB lesions not detected by conventional radiology.

No concordance was observed between proximal SB lesions at WCE and related signs/symptoms, even when patients were followed up for at least 12 mo. This observation provides additional evidence for a diffuse involvement of the SB in patients with CD of the distal ileum, even if not associated with overt symptoms. Present findings also suggest that no treatment changes may be required in CD patients showing upper SB lesions at WCE. The observed frequency of upper SB lesions is in agreement with previous findings in the early postoperative period (56%)[17].

When WCE and SICUS findings were compared, a small proportion of patients (3 of 16) showing upper SB lesions with WCE, also showed the same finding with SICUS. This discrepancy is in agreement with our previous studies[18,19] and may be related to the observation that WCE and SICUS provide a different view of the SB (i.e. intraluminal *vs* extraluminal). In addition, WCE allows the visualization of superficial lesions not detected by SICUS[18]. In the 3 patients showing upper SB lesions by both WCE and SICUS, lesions were represented by deep ulcers at WCE in 2, suggesting that discrepancies are mainly observed for superficial lesions. In contrast to the upper SB lesions, WCE and SICUS findings appeared comparable in the distal SB. This observation indicates that the characteristics of the SB lesions, including not only the severity (deep *vs* aphthoid ulcers) and number, but also the site (upper *vs* distal SB) may influence the sensitivity of ultrasonography. A good interobserver agreement was observed, supporting previous findings[17]. Although some patients were studied by SBFT, this technique was not included for ethical and economic reasons, in relation to both the high radiation exposure and to the known low sensitivity of SBFT in detecting superficial SB lesions. In addition, there was no clinical indication for SBFT in our population, including only 5 active patients with an established diagnosis of CD.

To our knowledge, no studies have investigated the role of WCE in comparison with SICUS in detecting the presence and clinical relevance of upper SB lesions in patients with CD involving the distal ileum, diagnosed by conventional radiological techniques. The present findings supports that WCE is a non-invasive technique which allows the visualization of superficial proximal SB lesions in a high proportion of patients with an established diagnosis of CD of the distal ileum. Despite no significant clinical relevance appearing to be associated with these findings even in the long term, the use of WCE in CD involving the distal SB may add clues in defining the extent of the lesions and its relation with clinical manifestations of the disease.

COMMENTS

Background

Wireless capsule endoscopy (WCE) is a non-invasive technique visualizing the

mucosal surface of the small bowel (SB). WCE showed a high sensitivity and specificity for detecting lesions related to SB Crohn's disease (CD). WCE has in particular been shown to be able to detect minor lesions, not visualized by conventional radiologic techniques, providing high radiation exposure. WCE has therefore been proposed as an alternative non-invasive technique for assessing CD lesions. Ultrasonography also is a non-invasive technique proposed for detecting SB lesions in CD. The use of an oral contrast (SICUS) significantly increases, in experienced hands, the sensitivity of ultrasonography for assessing SB lesions in CD (> 95%). Although several studies concordantly showed that WCE is able to visualize superficial lesions in the SB, its role in defining the extent of the lesions in CD is undefined.

Research frontiers

Proximal small bowel lesions are detected in a low proportion of CD patients (about 5%). However, these frequencies have been reported using radiologic techniques which have a low sensitivity for visualizing superficial lesions. WCE has been shown to visualize the inner SB surface, providing a high sensitivity in detecting minor lesions (i.e. erosions, aphthoid ulcers). Two independent studies reported that WCE visualizes lesions related to early CD recurrence in the SB. However, the frequency, natural history and clinical relevance of proximal SB lesions in CD is currently undefined.

Innovations and breakthroughs

The present study showed that WCE is a non-invasive technique allowing the visualization of superficial proximal small bowel lesions in a high proportion of patients with an established diagnosis of CD of the distal ileum.

Applications

Despite no significant clinical manifestations appearing to be associated with these findings even in the long term, the use of WCE in CD involving the distal SB may add clues in defining the extent of the lesions and the relationship with clinical symptoms of the disease.

Terminology

WCE is a non-invasive technique able to visualize the inner surface of the small intestine. SICUS is also a non invasive technique showing, in experienced hands, a high sensitivity and specificity in terms of assessment of small bowel lesions, including increased bowel wall thickness in ileal CD.

Peer review

This is a small (32 patients) prospective study, with a control population, that evaluates the diagnostic accuracy of WCE in CD, and compares it with different diagnostic tools. It is well presented and performed in an ethical manner.

REFERENCES

1 **Iddan G**, Meron G, Glukhovsky A, Swain P. Wireless capsule endoscopy. *Nature* 2000; **405**: 417

2 **Sidhu R**, Sanders DS, Morris AJ, McAlindon ME. Guidelines on small bowel enteroscopy and capsule endoscopy in adults. *Gut* 2008; **57**: 125-136

3 **Fireman Z**, Mahajna E, Broide E, Shapiro M, Fich L, Sternberg A, Kopelman Y, Scapa E. Diagnosing small bowel Crohn's disease with wireless capsule endoscopy. *Gut* 2003; **52**: 390-392

4 **Eliakim R**, Suissa A, Yassin K, Katz D, Fischer D. Wireless capsule video endoscopy compared to barium follow-through and computerised tomography in patients with suspected Crohn's disease--final report. *Dig Liver Dis* 2004; **36**: 519-522

5 **Buchman AL**, Miller FH, Wallin A, Chowdhry AA, Ahn C. Videocapsule endoscopy versus barium contrast studies for the diagnosis of Crohn's disease recurrence involving the small intestine. *Am J Gastroenterol* 2004; **99**: 2171-2177

6 **Fireman Z**, Mahajna E, Broide E, Shapiro M, Fich L, Sternberg A, Kopelman Y, Scapa E. Diagnosing small bowel Crohn's disease with wireless capsule endoscopy. *Gut* 2003; **52**: 390-392

7 **Costamagna G**, Shah SK, Riccioni ME, Foschia F, Mutignani M, Perri V, Vecchioli A, Brizi MG, Picciocchi A, Marano P. A prospective trial comparing small bowel radiographs and video capsule endoscopy for suspected small bowel disease. *Gastroenterology* 2002; **123**: 999-1005

8 **Cheifetz AS**, Kornbluth AA, Legnani P, Schmelkin I, Brown A, Lichtiger S, Lewis BS. The risk of retention of the capsule endoscope in patients with known or suspected Crohn's disease. *Am J Gastroenterol* 2006; **101**: 2218-2222

9 **Triester SL**, Leighton JA, Leontiadis GI, Gurudu SR, Fleischer DE, Hara AK, Heigh RI, Shiff AD, Sharma VK. A meta-analysis of the yield of capsule endoscopy compared to other diagnostic modalities in patients with non-stricturing small bowel Crohn's disease. *Am J Gastroenterol* 2006; **101**: 954-964

10 **Sonnenberg A**, Erckenbrecht J, Peter P, Niederau C. Detection of Crohn's disease by ultrasound. *Gastroenterology* 1982; **83**: 430-434

11 **Calabrese E**, La Seta F, Buccellato A, Virdone R, Pallotta N, Corazziari E, Cottone M. Crohn's disease: a comparative prospective study of transabdominal ultrasonography, small intestine contrast ultrasonography, and small bowel enema. *Inflamm Bowel Dis* 2005; **11**: 139-145

12 **Parente F**, Greco S, Molteni M, Anderloni A, Sampietro GM, Danelli PG, Bianco R, Gallus S, Bianchi Porro G. Oral contrast enhanced bowel ultrasonography in the assessment of small intestine Crohn's disease. A prospective comparison with conventional ultrasound, x ray studies, and ileocolonoscopy. *Gut* 2004; **53**: 1652-1657

13 **Best WR**, Becktel JM, Singleton JW, Kern F Jr. Development of a Crohn's disease activity index. National Cooperative Crohn's Disease Study. *Gastroenterology* 1976; **70**: 439-444

14 **Wagtmans MJ**, Verspaget HW, Lamers CB, van Hogezand RA. Clinical aspects of Crohn's disease of the upper gastrointestinal tract: a comparison with distal Crohn's disease. *Am J Gastroenterol* 1997; **92**: 1467-1471

15 **D'Haens G**, Rutgeerts P, Geboes K, Vantrappen G. The natural history of esophageal Crohn's disease: three patterns of evolution. *Gastrointest Endosc* 1994; **40**: 296-300

16 **Carter MJ**, Lobo AJ, Travis SP. Guidelines for the management of inflammatory bowel disease in adults. *Gut* 2004; **53** Suppl 5: V1-V16

17 **Bourreille A**, Jarry M, D'Halluin PN, Ben-Soussan E, Maunoury V, Bulois P, Sacher-Huvelin S, Vahedy K, Lerebours E, Heresbach D, Bretagne JF, Colombel JF, Galmiche JP. Wireless capsule endoscopy versus ileocolonoscopy for the diagnosis of postoperative recurrence of Crohn's disease: a prospective study. *Gut* 2006; **55**: 978-983

18 **Biancone L**, Calabrese E, Petruzziello C, Onali S, Caruso A, Palmieri G, Sica GS, Pallone F. Wireless capsule endoscopy and small intestine contrast ultrasonography in recurrence of Crohn's disease. *Inflamm Bowel Dis* 2007; **13**: 1256-1265

19 **Calabrese E**, Petruzziello C, Onali S, Condino G, Zorzi F, Pallone F, Biancone L. Severity of postoperative recurrence in Crohn's disease: correlation between endoscopic and sonographic findings. *Inflamm Bowel Dis* 2009; **15**: 1635-1642

S- Editor Wang JL **L- Editor** Cant MR **E- Editor** Ma WH

World Journal of Gastroenterology

Online Submissions: http://www.wjgnet.com/1007-9327office
wjg@wjgnet.com
doi:10.3748/wjg.v16.i26.3305

World J Gastroenterol 2010 July 14; 16(26): 3305-3309
ISSN 1007-9327 (print)
© 2010 Baishideng. All rights reserved.

BRIEF ARTICLE

Experience with the surgical treatment of hepatic hydatidosis: Case series with follow-up

Hector Losada Morales, Luis Burgos San Juan, Jorge Silva Abarca, Cesar Muñoz Castro

Hector Losada Morales, Luis Burgos San Juan, Jorge Silva Abarca, Cesar Muñoz Castro, Department of Surgery, Universidad de La Frontera, 4780000 Temuco, Chile; Hepato Pancreatic and Biliary Surgery, Hospital Hernán Henríquez Aravena, 4780000 Temuco, Chile
Hector Losada Morales, Luis Burgos San Juan, Jorge Silva Abarca, Department of Surgery, Clínica Alemana de Temuco, 4780000 Temuco, Chile
Hector Losada Morales, MinCir, Clinical Epidemiology in Surgery, Department of Surgery, Universidad de La Frontera, 4780000 Temuco, Chile
Author contributions: Losada Morales H, Burgos San Juan L, Silva Abarca J and Muñoz Castro C performed clinical research; Losada Morales H designed the research, collected the data and analyzed the data; Losada Morales H and Muñoz Castro C wrote the paper.
Correspondence to: Dr. Hector Losada Morales, Department of Surgery, Universidad de La Frontera, 4780000 Temuco, Chile. hflosada@ufro.cl
Telephone: +56-45-325760 Fax: +56-45-325761
Received: December 7, 2009 Revised: May 9, 2010
Accepted: May 16, 2010
Published online: July 14, 2010

Abstract

AIM: To describe patient characteristics and the results of surgical treatment for hepatic hydatidosis (HH) in the Hospital Hernán Henríquez Aravena from December 2001 to March 2005.

METHODS: Subjects older than 16 years with suspected HH were included based on the clinical picture and radiological studies. Variables examined included clinical and laboratory aspects, outcome, features of the parasite and surgical aspects. Descriptive statistics were used, calculating central tendency, dispersion and extreme tendency.

RESULTS: The series was comprised of 122 patients, with an average age of 44 ± 16.9 years. The most frequently used surgical technique was subtotal cystectomy in 90% of the patients, followed by hepatic resection (hepatectomy, segmentectomy and subsegmentectomy) in 5%. In 2%, a combination of subtotal cystectomy and segmentectomy was performed. In addition, 28% of the series presented complications in the postoperative period and mortality was 2%.

CONCLUSION: The most frequently used surgical technique for HH was subtotal cystectomy and the morbidity and mortality rates in this Chilean series are comparable to other national and international series.

© 2010 Baishideng. All rights reserved.

Key words: Echinococcosis of liver; Surgery; Cases series; Mortality; Morbidity

Peer reviewer: Beat Schnüriger, MD, University of Southern California, Keck School of Medicine, Department of Surgery, Division of Acute Care Surgery (Trauma, Emergency Surgery and Surgical Critical Care), 1200 North State Street, Inpatient Tower (C), 5th Floor, Room C5L100, Los Angeles, CA 90033-4525, United States

Losada Morales H, Burgos San Juan L, Silva Abarca J, Muñoz Castro C. Experience with the surgical treatment of hepatic hydatidosis: Case series with follow-up. *World J Gastroenterol* 2010; 16(26): 3305-3309 Available from: URL: http://www.wjgnet.com/1007-9327/full/v16/i26/3305.htm DOI: http://dx.doi.org/10.3748/wjg.v16.i26.3305

INTRODUCTION

Hepatic hydatidosis (HH) is a zoonosis produced by *Equinococcus granulosus* that presents a high prevalence and incidence in southern Chile, at a rate of 38 per 100 000[1-2]. There are many options for HH treatment. Based on World Health Organization guidelines and our experience, surgery is one of the most effective treatments for HH[3-5].

There is a wide range of surgical techniques for treating HH, from radical surgery with complete removal of

the cyst leaving no residual cavity (pericystectomy or regulated hepatic resection), to more conservative techniques with partial removal of the cyst and treatment of that part of the cyst remaining in the hepatic parenchyma: subtotal cystectomy plus epiploplasty, subtotal cystectomy plus capitonnage, cystostomy plus epiploplasty, among others[3-12]. Some reports show that epiploplasty decreases the incidence of deep abdominal abscess after surgical treatment[10-12].

The surgical technique preferred by our team is subtotal cystectomy, leaving the smallest amount of cyst in the hepatic parenchyma, accompanied by epiploplasty[11,12]. Performing complete dissection of the liver's ligamentous attachments we can thus provide even better exposure for resection of the cyst, only leaving the part close to vascular structures.

Our hypothesis is that morbidity and mortality rates associated with the surgical treatment of HH in the Hospital Hernán Henríquez Aravena, Temuco, Chile, are comparable to national and international figures. Our aim is to describe patient characteristics, the results of the surgical treatment and the morbidity and mortality associated with the surgical treatment of HH in the Hospital Hernán Henríquez Aravena from December 2001 to March 2005.

MATERIALS AND METHODS

Study design and population

Patients were subjects older than 16 years with suspected HH based on the clinical findings and radiological studies which were performed in Hospital Hernán Henríquez Aravena (Temuco, Chile) from December 2001 to March 2005. Our protocol did not include preoperative albendazole.

Definitions

Subtotal cystectomy: Surgical technique in which part of the adventitious membrane of the hydatid cyst is resected. In this technique, we only leave the part of the adventitia adjacent to the vascular structures. When possible, this part is covered by a vascularized omental flap (epiploplasty).

Pericystectomy: Total resection of the cyst's adventitious membrane, in which the plane between the adventitious membrane and hepatic parenchyma is dissected. This technique is used for peripheral cysts and is performed with afferent vascular control (Figure 1A).

Maneuver

The biliopancreatic surgery team prefers to treat HH *via* the abdomen no matter where the cysts are located. A subcostal laparotomy is used, either right or bilateral, depending on the location of the cysts; or a J laparotomy towards the right. The round ligament is sectioned and tied off and the liver is then moved to locate the cyst (Figure 1B). On some occasions, intraoperative echography is used when cysts are difficult to locate. Once a cyst has been located, we protect the surgical area with compresses containing either diluted povidone or 20% hypertonic saline solution as per the surgeon's choice (Figure 1C). The cyst is subsequently punctured and all the hydatid fluid and daughter vesicles are aspirated (Figure 1D and E). The germinative membrane is removed and the protection field withdrawn. Depending on the location, the subtotal cystectomy is planned, beginning the resection of the cyst wall with electrocoagulation, controlling the hemostasia, leaving only that part of the cyst which is adjacent to the vascular structures. This area is then reviewed in search of biliary communications, which are sutured with 3-0 resorbable material. Some team members perform a cholecystectomy and they inject physiological serum into the cystic duct through a nelaton probe to make small biliary communications visible (Figure 1F). Depending on the number of communications, satisfaction with the closing of the communications and the diameter of the bile duct, a choledochostomy is performed. The only absolute indication for a choledochostomy is a clinical picture compatible with cholangiohydatidosis, in which the bile duct is always drained. Nevertheless, in recent months, we have tried to drain the bile duct using endoscopic retrograde cholangiography. An epiploplasty is subsequently performed with a greater omentum pedicle flap. Drains are not positioned as a matter of course and are at the surgeon's discretion.

Study variables

Variables examined included clinical and laboratory features, clinical images and evolutionary complications, surgical and clinical evolution variables.

Variables examined included ultrasound (US) and computed tomography (CT) characteristics of the cyst, the number of cysts (continuous variable), location of the cysts (categorized into right hemi-liver, left hemiliver, bilateral or central liver), diameter of the lesion, evolutionary complications of the cyst (hepatic abscess of hydatid origin (HAH), hepatothoracic transit (HHT), rupture to the abdominal cavity and cholangiohydatidosis.

Surgical variables: The substance used to protect the surgical area is considered (povidone and/or hypertonic solution), as is the surgical technique (categorized into subtotal cystectomy, pericystectomy, segmentectomy and hepatectomy). The use of choledochostomy and/or drain (dichotomized: yes or no) is evaluated.

Clinical evolution variables: The duration of hospitalization is assessed, and the presence of postoperative complications (categorized into: residual cavity, infection of the operating site, atelectasis, pneumonia, hemoperitoneum, bilioperitoneum, evisceration and pneumothorax).

Abscess in the residual cavity is defined as any purulent collection in relation to the liver surgical bed that needs treatment (surgery or CT-guided drainage).

Postoperative follow-up was carried out by clinical assessment. For any abnormal finding US or CT was un-

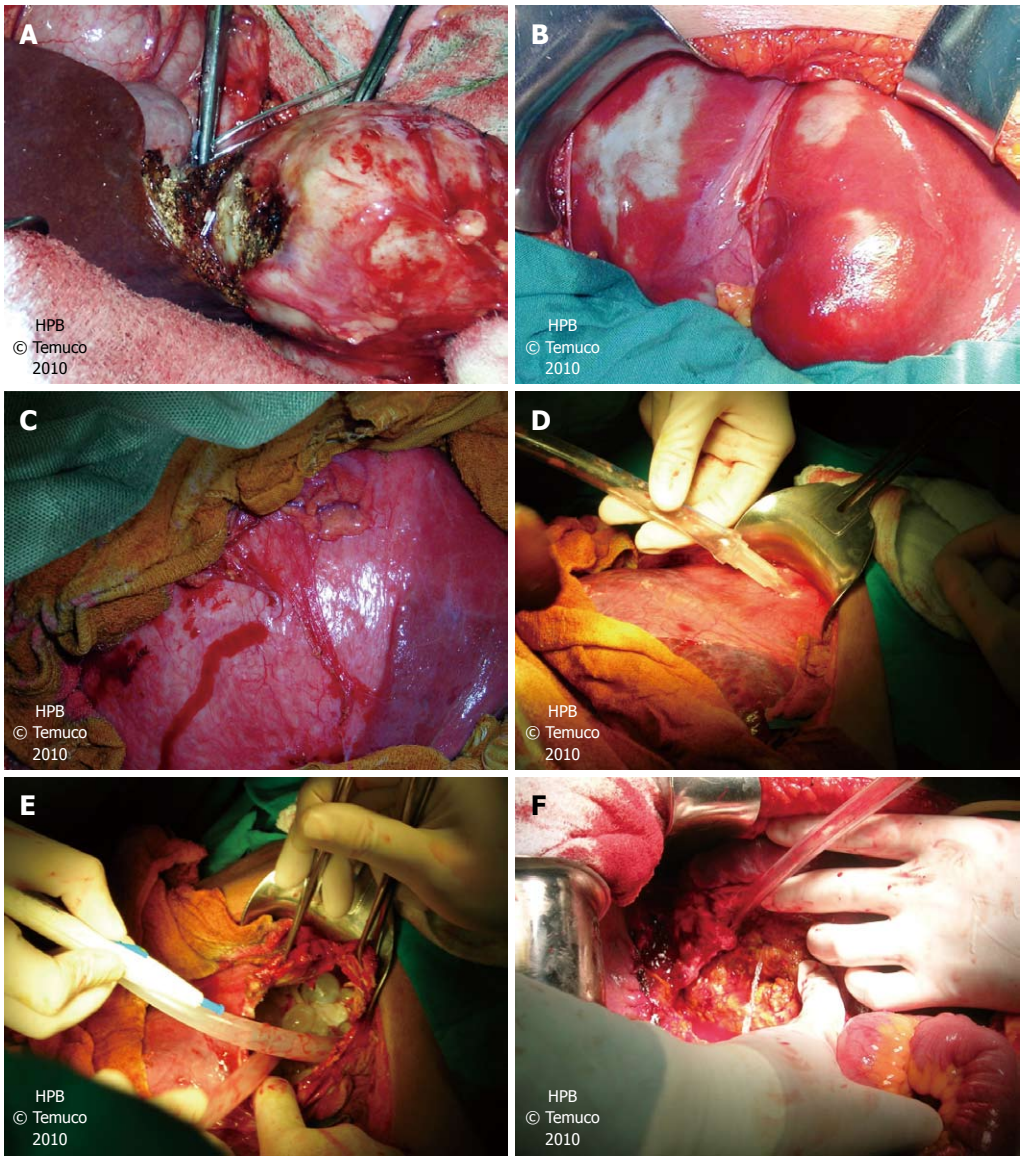

Figure 1 Surgical technique. A: Pericystectomy used for peripheral cyst; B: Subcostal laparotomy is used. Round ligament is sectioned and tied off and the liver is then moved to locate the cyst; C: Protection of the surgical area with compresses containing diluted povidone; D: Puncturing hydatid cyst with trocar; E: Aspirating daughter vesicles; F: Once the cystectomy has been performed, saline solution is injected *via* cyst duct or choledochostomy to locate the biliary communications.

dertaken. Liver recurrence was defined as any cyst image (such as hydatid cyst) with postoperative normal images.

Statistical analysis

Descriptive statistics were used, calculating measures of central tendency (mean, median) dispersion (SD) and extreme values. Database was analyzed using the program Stata® 8.0.

RESULTS

The series included 122 patients with a mean age of 44 ± 16.90 years; with a median of 44 years and range 17-85 years. The distribution by gender showed 73 (60%) male and 49 (40%) female. Forty-nine patients (40%) were admitted by the emergency service and 73 (60%) by the clinic. The mean number of cysts found by US was 1.57 ± 0.91 and the mean number found in surgery was 1.37 ± 0.63. The mean diameter of the main lesion was 10.77 ± 5.62 cm with a median of 10 cm and range 5-30 cm.

When describing the location of the largest cyst, we found that 73 (60%) were located in the right hemi-liver and 49 (40%) in the left hemi-liver. At the time of this study only 49 patients (40%) had undergone CT. Ninety-eight lesions (80%) were hypodense.

The most frequently used surgical technique was subtotal cystectomy in 110 (90%) cases (Table 1). In those patients who underwent a subtotal cystectomy, 90 (82%) also received epiploplasty.

There were evolutionary complications of HH in 20 patients (16%). Intraoperatively, evolutionary complications were found in 49 patients (40%), with the most frequent being cholangiohydatidosis in 38 (31%), followed by HHT in 24 (20%), HAH in 18 (15%) and rupture in 12 (10%).

The surgical area was protected with povidone in 107 patients (88%) and hypertonic solution in 15 (12%).

Table 1 Surgical techniques for HH in this patient series

Technique	*n* (%)
Subtotal cystectomy	110 (90)
Liver resection	6 (5)
Subtotal cystectomy + liver segmentectomy	2 (2)
Others	4 (3)
Total	122 (100)

HH: Hepatic hydatidosis.

The bile duct was explored *via* choledochostomy in 39 patients (32%), with the most common indication being suspected cholangiohydatidosis. Cholangiohydatidosis was treated by bile duct exploration and antibiotic treatment. A drain was left in the cystectomy site at the end of the surgery in 81 patients (66%). Twenty-eight per cent of the series (34 patients) presented postoperative complications. The most frequent was atelectasis and pneumonia in 28 patients (23%), surgical site infection in 6 (5%), hemorrhage in 6 (5%). Three patients presented abscess in the residual cavity. Two were solved surgically and 1 patient was treated by CT-guided drainage.

The clinical, evolutionary and laboratory variables according to the presence of complications are described in Table 2.

The mortality of the series was 3 patients (2%). Six patients (5%) received albendazole as a pharmacological therapy subsequent to the surgery, despite our protocol. Twenty-three patients (19%) were operated on for pulmonary hydatidosis at some point in the postoperative evolution, with the most frequent surgery being cystectomy in 111 patients (91%), followed by pulmonary lobectomy (9%).

With an average follow-up of 22.4 ± 8 mo, 13 patients (11%) presented recurrence. In 10 patients recurrence was in relation to a surgical site.

When the biopsies of the patients operated for suspected HH were reviewed, we found that HH was confirmed in 120 patients (98%). In only 3 patients did the biopsy show different results: in 2 patients the biopsy revealed a simple hepatic cyst with signs of inflammation and in 1 patient a primitive neuroectodermic tumor was discovered.

The mean hospital stay was 16.33 ± 8 d with a median of 13 d and range 3-62 d.

DISCUSSION

All the patients in our series had abdominal pain as the main symptom upon admittance. Our center does not run routine immunological exams for *Equinococcus* because several previous reports from our center question their diagnostic value[13]. Our diagnostic suspicion is based on epidemiological history, the study of images and the clinical presentation of the patient.

The mean age of the series (44 years) and the predominance of males are remarkable aspects in that these vary from what was recently reported by a Greek series where female gender was higher and patients were younger[14].

Table 2 Clinical, evolutionary and laboratory variables according to postoperative complications (mean ± SD)

Variables	Patients with postoperative complications (*n* = 25)	Patients without postoperative complications (*n* = 97)
Age (yr)	48.2 ± 15	43.63 ± 17
Sex (% male)	60	33
Evolutionary complications of the cyst (before surgery) (%) (HAH, HHT, rupture to the abdominal cavity and cholangiohydatidosis)	20	9
Protection of the surgical area (% povidone)	24	21
Number of cysts	1.56 ± 0.9	1.32 ± 0.5
Leukocyte count (cells/mm^3)	10 245 ± 3955	9095 ± 4605
Total bilirubin (mg/dL)	2.03 ± 2.4	1.43 ± 3.7
Alkaline phosphatase (U/L)	616 ± 576	397 ± 440
AST (U/L)	85.8 ± 39	55.8 ± 91
ALT (U/L)	83.47 ± 94	73 ± 96

HAH: Hepatic abscess of hydatid origin; HHT: Hepatothoracic transit; AST: Aspartate transaminase; ALT: Alanine transaminase.

The average diameter of the main lesion (10.77 ± 5.62 cm) is less than that reported in a previous cohort conducted in our center (14.5 ± 6 cm). Predominant location in the right hemi-liver tallies with national and international series[11-15].

Among the evolutionary complications of HH, the most frequent was cholangiohydatidosis (31%), followed by hepatothoracic transit (20%). This contrasts with a previous cohort studied in our center, where the most frequent evolutionary complication was HAH (51.5%) followed by cholangiohydatidosis (10.6%)[11].

We have changed the preference of surgical area protection to diluted povidone, due to some cases of hypernatremia which occurred with use of hypertonic saline solution.

With respect to the surgical technique, our team prefers subtotal cystectomy with epiploplasty. We are emphatic about resecting most of the content of the cyst, leaving only the surface in contact with the vascular structures, which we would call an "almost total cystectomy". To this end, it is necessary to have a complete mobilization of the liver and to be familiar with the vascular structures of the hepatic segments.

Our service does not perform routine choledochostomies in HH surgery. This is demonstrated in the 32% of patients in the series who underwent this procedure, where the majority had suspected cholangiohydatidosis.

Unlike other centers[14], postoperative treatment with albendazole is not routine in our service; this is based on previous studies made in our center that showed a low concentration in the interior of the cyst and the non-existence of an association between the intracystic concentration of albendazole and the viability of the scolices[16].

The recurrence of abdominal hydatidosis (11%) is comparable to a recently published series carried out in Turkey with similar surgical approach[15].

The morbidity (28%) is comparable to that reported

by 2 recent international series and 1 cohort conducted in our center[11,12,14] and the mortality (2%) is comparable to that reported recently in a Greek series[14].

A greater prevalence of evolutionary complications and a greater alteration in hepatic test results can be seen in those patients who presented postoperative complications. This tendency must be corroborated in a cohort study designed for this purpose.

The median duration of the hospital stay (16.33 d) is comparable to that published by a previous Chilean series (17 d)[17].

In conclusion, in our Chilean series, subtotal cystectomy was the most common procedure undertaken for HH. The rates of morbidity and mortality are comparable to those reported by other national and international series.

COMMENTS

Background

Hepatic hydatidosis (HH) is a zoonosis produced by *Equinococcus granulosus* that presents a high prevalence and incidence in southern Chile. Based on World Health Organization guidelines and our experience, surgery is one of the most effective treatments for HH.

Research frontiers

Patient characteristics and the results of surgical treatment for HH in the Hospital Hernán Henríquez Aravena from December 2001 to March 2005 were described.

Applications

The authors are very experienced with the treatment of HH and the number of patients presented would allow for a meaningful analysis, which could help to improve the quality of care for these patients.

Peer review

The authors describe their surgical technique used in HH treating and compare morbidity and mortality with the available literature.

REFERENCES

1 **Craig PS**, Larrieu E. Control of cystic echinococcosis/hydatidosis: 1863-2002. *Adv Parasitol* 2006; **61**: 443-508

2 **Aliaga F**, Oberg C. [Epidemiology of human hydatidosis in the IX Region of la Araucania, Chile 1991-1998] *Bol Chil Parasitol* 2000; **55**: 54-58

3 Guidelines for treatment of cystic and alveolar echinococcosis in humans. WHO Informal Working Group on Echinococcosis. *Bull World Health Organ* 1996; **74**: 231-242

4 **Manterola C**, Fernández O, Muñoz S, Vial M, Losada H, Carrasco R, Bello N, Barroso M. Laparoscopic pericystectomy for liver hydatid cysts. *Surg Endosc* 2002; **16**: 521-524

5 **Belchev B**, Donev S, Belchev N. [The postoperative results of the surgical treatment of hepatic echinococcosis using a closed surgical method] *Khirurgiia* (Sofiia) 1997; **50**: 20-21

6 **Sabău D**, Coman A, Bratu D, Smarandache G, Dumitra A, Sabău A. [Laparoscopic surgery for hepatic hydatid cyst--possibilities and limitations] *Chirurgia* (Bucur) 2007; **102**: 543-548

7 **Daradkeh S**, El-Muhtaseb H, Farah G, Sroujieh AS, Abu-Khalaf M. Predictors of morbidity and mortality in the surgical management of hydatid cyst of the liver. *Langenbecks Arch Surg* 2007; **392**: 35-39

8 **Demirci S**, Eraslan S, Anadol E, Bozatli L. Comparison of the results of different surgical techniques in the management of hydatid cysts of the liver. *World J Surg* 1989; **13**: 88-90; discussion 90-91

9 **Reza Mousavi S**, Khoshnevis J, Kharazm P. Surgical treatment of hydatid cyst of the liver: drainage versus omentoplasty. *Ann Hepatol* 2005; **4**: 272-274

10 **Dziri C**, Paquet JC, Hay JM, Fingerhut A, Msika S, Zeitoun G, Sastre B, Khalfallah T. Omentoplasty in the prevention of deep abdominal complications after surgery for hydatid disease of the liver: a multicenter, prospective, randomized trial. French Associations for Surgical Research. *J Am Coll Surg* 1999; **188**: 281-289

11 **Manterola C**, Vial M, Pineda V, Sanhueza A, Barroso M. Factors associated with morbidity in liver hydatid surgery. *ANZ J Surg* 2005; **75**: 889-892

12 **Safioleas MC**, Misiakos EP, Kouvaraki M, Stamatakos MK, Manti CP, Felekouras ES. Hydatid disease of the liver: a continuing surgical problem. *Arch Surg* 2006; **141**: 1101-1108

13 **Manterola C**, Cuadra A, Muñoz S, Sanhueza A, Bustos L, Vial M, Fonseca F. In a diagnostic test study the validity of three serodiagnostic test was compared in patients with liver echinococcosis. *J Clin Epidemiol* 2005; **58**: 401-406

14 **Avgerinos ED**, Pavlakis E, Stathoulopoulos A, Manoukas E, Skarpas G, Tsatsoulis P. Clinical presentations and surgical management of liver hydatidosis: our 20 year experience. *HPB* (Oxford) 2006; **8**: 189-193

15 **Akbulut S**, Senol A, Sezgin A, Cakabay B, Dursun M, Satici O. Radical vs conservative surgery for hydatid liver cysts: experience from single center. *World J Gastroenterol* 2010; **16**: 953-959

16 **Manterola C**, Mansilla JA, Fonseca F. Preoperative albendazole and scolices viability in patients with hepatic echinococcosis. *World J Surg* 2005; **29**: 750-753

17 **Lorca HM**, Campanella RC, Gavrilovics AB, Lagos LS, Florín CV. Estimation of total and partial costs about diagnosis, surgical treatment and monitoring of hepatic hydatid disease in Hospital San Juan de Dios , Santiago, Chile, 1990-1999. *Rev Chil Cir* 2003; **55**: 60-64

S- Editor Tian L **L- Editor** Logan S **E- Editor** Lin YP

World Journal of Gastroenterology

Online Submissions: http://www.wjgnet.com/1007-9327office
wjg@wjgnet.com
doi:10.3748/wjg.v16.i26.3310

World J Gastroenterol 2010 July 14; 16(26): 3310-3317
ISSN 1007-9327 (print)
© 2010 Baishideng. All rights reserved.

BRIEF ARTICLE

Comparison of different nutritional assessments in detecting malnutrition among gastric cancer patients

Seung Wan Ryu, In Ho Kim

Seung Wan Ryu, In Ho Kim, Department of Surgery and Division of Gastrointestinal Surgery, The Keimyung University School of Medicine, Daegu 700-712, South Korea
Author contributions: Ryu SW performed the majority of experiments and wrote the manuscript; Kim IH designed the study and wrote the manuscript.
Supported by The Bisa Research Grant of Keimyung University in 2006
Correspondence to: Dr. In Ho Kim, Department of Surgery and Division of Gastrointestinal Surgery, The Keimyung University School of Medicine, Daegu 700-712, South Korea. kih309@dsmc.or.kr
Telephone: +82-53-2507386 Fax: +82-53-2507322
Received: December 2, 2009 Revised: January 27, 2010
Accepted: February 3, 2010
Published online: July 14, 2010

Abstract

AIM: To evaluate the prevalence of preoperative and postoperative malnutrition and the relationships between objective and subjective nutritional assessment of gastric cancer patients.

METHODS: From October 2005 to July 2006, we studied 80 patients with no evidence of recurrent disease and no loss to follow-up after curative surgery for gastric cancer. In this group, 9 patients underwent total gastrectomy and 71 patients subtotal gastrectomy. At admission, 6 and 12 mo after surgery, the patients were assessed on the subjective global assessment (SGA), nutritional risk screening (NRS-2002), nutritional risk index (NRI) and by anthropometric measurements and laboratory data. Differences between the independent groups were assessed with the Student's *t* test and one-way analysis of variance. Spearman's rank correlation coefficients were calculated to evaluate the association between the scores and variables.

RESULTS: The prevalence of malnutrition at admission was 31% by SGA and 43% by NRS-2002. At admission, the anthropometric data were lower in the malnourished groups defined by the SGA and NRS-2002 assessments, but did not differ between the groups using the NRI assessment. Body weight (BW), body mass index (BMI), triceps skin fold and midarm circumference were significantly reduced, but the total lymphocyte count, albumin, protein, cholesterol and serum iron levels did not decrease during the postoperative period. Six months after surgery, there was a good correlation between the nutritional assessment tools (SGA and NRS-2002) and the other nutritional measurement tools (BW, BMI, and anthropometric measurements). However, 12 mo after surgery, most patients who were assessed as malnourished by SGA and NRS-2002 had returned to their preoperative status, although their BW, BMI, and anthropometric measurements still indicated a malnourished status.

CONCLUSION: A combination of objective and subjective assessments is needed for the early detection of the nutritional status in case of gastric cancer patients after gastrectomy.

© 2010 Baishideng. All rights reserved.

Key words: Gastrectomy; Malnutrition; Nutritional assessment; Nutritional risk screening; Postoperative follow up; Subjective global assessment

Peer reviewer: Wallace F Berman, MD, Professor, Division of Pediatric GI/Nutrition, Department of Pediatrics, Duke University Medical Center, Duke University School of Medicine, Durham, Box 3009, NC 27710, United States

Ryu SW, Kim IH. Comparison of different nutritional assessments in detecting malnutrition among gastric cancer patients. *World J Gastroenterol* 2010; 16(26): 3310-3317 Available from: URL: http://www.wjgnet.com/1007-9327/full/v16/i26/3310.htm DOI: http://dx.doi.org/10.3748/wjg.v16.i26.3310

INTRODUCTION

We should pay special attention to the alarming report that 30%-50% of patients in general hospitals have some degree of malnutrition[1-5]. Malnutrition is defined as a state of deficiency in energy, protein or other specific nutrients, producing an appreciable change in body function[6]. Patients who have had gastrointestinal problems and who have undergone gastrointestinal surgery constitute an important risk group for malnutrition[7,8]. Malnutrition is an important factor, influencing both their morbidity and recovery after gastrectomy surgery including radical lymphadenectomy[9,10]. The early detection of nutritional risk would allow early intervention, which may prevent later complications.

The assessment of a patient's initial nutritional status and its evaluation during the disease and/or treatment plays an important role in tailoring nutritional support[11]. The goals of a formal nutrition assessment are: to identify patients who are malnourished or are at risk of malnutrition; to collect the information necessary to create a nutrition care plan; and to monitor the adequacy of nutritional therapy[12]. Studies have consistently revealed the inadequacy of any single method or tool in assessing a patient's nutritional status. The absence of a single gold-standard objective measure has led investigators to develop various nutritional indices that can be used to stratify patients at increased risk of poor outcomes[13]. As a result, combinations of diverse measurements have been developed into subjective scoring systems designed to increase the sensitivity and specificity of nutritional status determinations[14]. Traditionally, scoring systems have been based on objective measurements of nutritional status, such as oral energy intake, body weight, weight loss over time, loss of subcutaneous fat, muscle wasting, serum protein levels, and immune competence. These prognostic indices include the nutritional risk index (NRI)[15], which is based on mathematical equations, and the subjective global assessment (SGA)[16] and nutritional risk screening (NRS-2002), which are based on clinical and subjective assessments[17].

This study was performed to evaluate the prevalence of preoperative and postoperative malnutrition in patients with gastric cancer who underwent radical gastrectomy, and the relationships between the objective variables (anthropometric and laboratory measurements) and the subjective scoring systems in the assessment of nutritional status during the postoperative follow-up period.

MATERIALS AND METHODS

Patients

Between October 2005 and July 2006, 80 patients were studied following curative surgery for gastric cancer. Among this group, 9 patients underwent total gastrectomy and 71 patients underwent subtotal gastrectomy. We assessed the nutritional status and laboratory parameters of the patients on admission and at 6 and 12 mo after surgery. Patients with evidence of recurrent disease or who were lost to follow-up were excluded.

This study was approved by the research ethics committee of the institution, and informed consent was obtained from all patients.

Nutritional measurements

The patients were assessed on the following items: SGA, NRS-2002, NRI, anthropometric measurements and laboratory data. The nutritional assessments were performed by a trained nurse specializing in nutrition and a dietitian.

SGA questionnaire

The SGA is a screening tool to determine the nutritional status of patients and was developed by Detsky *et al*[16]. The SGA is a clinical technique with subjective elements and assesses nutritional status based on features of the patient's history and physical examination. During the SGA, two trained investigators used a standardized questionnaire concerning the patients' height and weight (current, before illness, and weight range during the previous 6 mo) and took a nutritional history (appetite, intake, gastrointestinal symptoms). In addition, the dietitian evaluated their physical appearances (subjective assessment of fat loss, muscle wasting, edema and ascites) and noted any existing medical conditions (e.g. encephalopathy, infection, renal insufficiency). Based on this evaluation, the patients were classified as being well nourished (SGA A), moderately malnourished (SGA B), or severely malnourished (SGA C). The SGA examiner was not aware of the laboratory test results at the time of the assessment.

Nutritional risk screening

The NRS-2002 was introduced by the European Society of Parenteral and Enteral Nutrition as the preferred method for screening and assessing hospital patients[17]. Its stated purpose was "Identification of those hospitalized patients, who are malnourished or at risk for malnourishment and who would gain benefit from the improvement of their nutritional situation." The NRS-2002 consists of a nutritional score and a severity of disease score and an age adjustment for patients aged > 70 years (+1). Nutritional score: weight loss > 5% in 3 mo or food intake below 50%-75% in the preceding week = 1; weight loss > 5% in 2 mo or BMI 18.5-20.5 kg/m^2 and impaired general condition or food intake 25%-60% in the preceding week = 2; weight loss > 5% in 1 mo or > 15% in 3 mo or BMI < 18.5 kg/m^2 and impaired general condition or food intake 0%-25% in the preceding week = 3. Severity of disease score: hip fracture, chronic patients with acute complications = 1; major abdominal surgery, stroke, severe pneumonia, hematological malignancies = 2; head injury, bone marrow transplantation, intensive care patients with APACHE > 10 = 3. The NRS-2002 score is the total of the nutritional score, severity of disease score and age adjustment. Patients are classified as no risk = 0, low risk = 0-1, medium risk = 3-4 and high risk = > 5.

Nutritional risk indicator

The NRI was developed by the Veteran's Affairs Total

Parenteral Nutrition group[15] in 1991 for use in the evaluation of the efficacy of perioperative total parenteral nutrition in patients undergoing thoracic or abdominal surgery. The NRI is a simple equation that uses serum albumin and recent weight loss: NRI = [1.519 × serum albumin (g/L)] + 0.417 × (present weight/usual weight × 100). An NRI score higher than 100 indicates that the patient is not malnourished, a score of 97.5 to 100 indicates mild malnourishment, a score of 83.5 to 97.5 indicates moderate malnourishment, and a score lower than 83.5 indicates severe malnourishment.

Anthropometric measurements

Body weight (BW; nearest 0.1 kg) and height (nearest cm) were measured while the patient was standing without shoes and in light clothes. Body mass index (BMI) was derived as weight (kg) divided by height (m) squared (kg/m^2). The triceps skinfold thickness (TSF), to the nearest mm, was measured at the midpoint between the acromion and olecranon processes on the nondominant side with a Holtain caliper (Holtain Ltd., Crymych, UK). The midarm circumference (MAC) was measured to the nearest 0.1 cm with a tape at the same point as the TSF. All anthropometric measurements were made at least three times by the same investigator, and the reported values are the means of the repeated measurements.

Serological measurements

Blood samples were taken from the cubital vein and tests included the measurement of serum protein, albumin, and cholesterol, and total lymphocyte counts (TLC). Laboratory data were collected using standard laboratory methods.

Statistical analysis

The data were analyzed with the statistical software "Statistical Package for Social Science (SPSS)" version 12.0 for Windows (SPSS, Inc., Chicago, IL, USA). Differences between the independent groups were assessed with Student's *t* test and one-way analysis of variance. Spearman's rank correlation coefficients were calculated to evaluate the association between the scores and variables. Data are presented as mean ± SD. Differences were considered to be statistically significant at $P < 0.05$. Agreement between two assessment methods was analyzed with the κ statistic. The value of κ varies from 0 to 1; a value of 0.4 or less indicates that chance alone can account for the observed agreement, and a value of 1 indicates perfect concordance.

RESULTS

Eighty patients who were treated with gastrectomy for gastric carcinoma were enrolled. The patients' characteristics are summarized in Table 1.

Preoperative nutritional status

We assessed the nutritional status and laboratory parameters of patients within 24 h of their hospital admission. The prevalence of malnutrition at admission was 31% when determined with the SGA (moderately and severely malnourished) or 43% when determined with the NRS-2002 (medium and high risk). The frequency of any degree of malnutrition at admission was 31% according to the NRI (mild, moderate, and severe malnutrition). There was no difference in age or TLC between malnourished and well-nourished groups defined according to the three assessments, but the percentage weight loss differed between the groups (Table 2). The anthropometric data were lower in the malnourished groups based on SGA and NRS-2002 assessments, but did not differ between the groups defined with the NRI assessment. Albumin, protein, and total cholesterol levels differed between the malnourished and well-nourished groups based on the NRI assessment, but there was no significant difference between the groups defined with the SGA and NRS-2002 techniques (Table 2).

Table 1 Demographic characteristics of gastric cancer patients (mean ± SD) *n* (%)

	Subtotal gastrectomy (*n* = 71)	Total gastrectomy (*n* = 9)	*P* value
Age (yr)	58.5 ± 11.9	56.5 ± 13.2	0.641
Sex			
Male	37 (52.1)	6 (66.7)	0.409
Female	34 (47.9)	3 (33.3)	
Cancer Stage			0.003
Ⅰ	57 (81.4)	5 (55.6)	
Ⅱ	8 (11.4)	0 (0)	
Ⅲ	2 (2.9)	3 (33.3)	
Ⅳ	3 (4.3)	1 (11.1)	
Complications			0.219
Major	2 (2.8)	1 (11.1)	
Minor	24 (33.8)	1 (11.1)	
Hospital stay (d)	12.8 ± 8.4	16.4 ± 6.8	0.223

P values were determined with the use of the Pearson χ^2 test and independent *t* test.

Malnutrition scores correlated significantly with the percentage weight loss according to the SGA and NRS-2002 groupings. BMI and anthropometric data correlated inversely in the SGA and NRS-2002 groupings, but did not correlate in the NRI grouping, which correlated inversely with the nutrition factors albumin, protein, and total cholesterol (Table 3). Concordance between the SGA and NRS-2002 assessments was observed in 68 of the 80 (85%) patients, but was not observed between the SGA and NRI assessments in 50 of the 80 (63%) patients (Table 4). Sensitivity was 80% with the NRS-2002 and 73% with the NRI. Specificity was 96% and 40% with the NRS-2002 and NRI, respectively. Agreement was higher between the SGA and NRS-2002 (κ = 0.685, $P = 0.000$) than between the SGA and NRI (κ = 0.127, $P = 0.255$) (Table 4).

Postoperative nutritional status

At 6 and 12 mo after surgery, BW, BMI, TSF and MAC were significantly reduced, whereas the TLC, and albumin, protein, cholesterol and serum iron levels did not decrease

Table 2 Patient characteristics and anthropometric and laboratory data according to nutritional status (mean ± SD)

	SGA			NRS-2002			NRI		
	Well-nourished (n = 55)	Malnourished (n = 25)	P value	Well-nourished (n = 45)	Malnourished (n = 35)	P value	Well-nourished (n = 55)	Malnourished (n = 25)	P value
Age (yr)	57.58 ± 11.5	60.00 ± 13.2	0.410	56.53 ± 9.9	60.65 ± 14.1	0.130	58.07 ± 12.3	58.92 ± 11.6	0.769
Weight (kg)	62.04 ± 9.1	59.30 ± 8.3	0.207	63.64 ± 8.4	58.03 ± 8.6	0.005	61.80 ± 9.0	59.83 ± 8.7	0.360
Weight loss (%)	1.03 ± 1.5	7.31 ± 4.5	0.000	0.89 ± 1.4	6.42 ± 4.6	0.000	2.71 ± 3.1	5.32 ± 5.9	0.047
TSF (mm)	17.88 ± 7.5	13.72 ± 6.5	0.020	18.25 ± 7.8	14.44 ± 6.4	0.020	16.99 ± 8.0	15.69 ± 6.2	0.435
MAC (cm)	27.95 ± 2.5	26.70 ± 2.3	0.040	28.37 ± 2.4	26.51 ± 2.2	0.001	27.81 ± 2.6	26.99 ± 2.1	0.155
BMI (kg/m^2)	24.26 ± 2.7	22.47 ± 2.6	0.008	24.69 ± 2.4	22.42 ± 2.7	0.000	23.88 ± 2.9	23.29 ± 2.6	0.366
Albumin (g/dL)	3.86 ± 0.3	3.85 ± 0.3	0.924	3.87 ± 0.3	3.84 ± 0.3	0.618	4.02 ± 0.2	3.50 ± 0.1	0.000
Total protein (g/dL)	6.89 ± 0.6	6.75 ± 0.6	0.391	6.88 ± 0.6	6.80 ± 0.6	0.568	7.13 ± 0.5	6.23 ± 0.4	0.000
Total cholesterol (mg/dL)	169.65 ± 42.3	167.8 ± 42.5	0.863	166.04 ± 42.2	173.02 ± 42.2	0.466	176.4 ± 39.6	152.8 ± 43.6	0.026
TLC (× 10^3/mm^3)	1856.6 ± 503	1905.9 ± 569	0.698	1874.7 ± 536	1868.6 ± 511	0.959	1903.9 ± 511	1801.8 ± 549	0.698

All P values were determined with the use of independent t test. SGA: Subjective global assessment; NRS-2002: Nutritional risk screening; NRI: Nutrition risk index; TSF: Triceps skinfold; MAC: Midarm circumference; BMI: Body mass index; TLC: Total lymphocyte count.

Table 3 Correlation coefficients and *P* values for patient data and nutritional assessment techniques

	SGA[1]		NRS-2002[2]		NRI[3]	
	r	P value	r	P value	r	P value
Age (yr)	0.118	0.297	0.246	0.028	0.035	0.758
Weight (kg)	-0.132	0.243	-0.314	0.005	-0.091	0.425
Weight loss (%)	0.754	0.000	0.690	0.000	0.199	0.166
TSF (mm)	-0.272	0.015	-0.234	0.037	-0.048	0.669
MAC (cm)	-0.228	0.042	-0.378	0.001	-0.170	0.132
BMI (kg/m^2)	-0.279	0.012	-0.393	0.000	-0.109	0.335
Albumin (g/dL)	0.004	0.971	-0.043	0.703	-0.783	0.000
Total protein (g/dL)	-0.086	0.448	-0.062	0.583	-0.636	0.000
Total cholesterol (mg/dL)	-0.006	0.955	0.088	0.436	-0.285	0.010
TLC (× 10^3/mm^3)	0.038	0.738	-0.008	0.943	-0.116	0.305

[1]SGA rating: 0, not malnourished; 1, moderate malnutrition; 2, severe malnutrition; [2]NRS-2002 rating: 0, no risk; 1, medium risk; 2, high risk; [3]NRI rating: 0, not malnourished; 1, mild malnutrition; 2, moderate malnutrition; 3, severe malnutrition; All P values were determined with the use of Pearson's correlation coefficient.

Table 4 Statistical comparison of nutritional assessments and screening tool values at hospital admission: NRS-2002 and NRI *vs* SGA

	NRS-2002			NRI		
	Low	Medium/ high	Total	Low	Medium/ high	Total
SGA well-nourished	44	11	55	40	15	55
SGA malnourished	1	24	25	15	10	25
Total	45	35	80	55	25	80
Sensitivity	80.0% (44/55)			72.7% (40/55)		
Specificity	96.0% (24/25)			40.0% (10/25)		
	κ = 0.685, P = 0.000			κ = 0.127, P = 0.255		

κ statistic: percent of agreement.

Table 5 Patient anthropometric and laboratory data after curative surgery for gastric cancer

	Preoperative day 1	Postoperative 6 mo	Postoperative 12 mo	P value
Weight (kg)	61.4 ± 8.8	55.4 ± 8.2	55.2 ± 8.6	0.000
TSF (mm)	17.0 ± 7.5	12.7 ± 6.5	12.1 ± 6.2	0.000
MAC (cm)	27.7 ± 2.5	25.1 ± 4.9	25.5 ± 2.4	0.000
BMI (kg/m^2)	23.9 ± 2.7	21.4 ± 2.4	21.5 ± 2.4	0.000
Albumin (g/dL)	3.88 ± 0.3	4.28 ± 0.2	4.30 ± 0.2	0.000
Total protein (g/dL)	6.87 ± 0.6	7.18 ± 0.5	7.25 ± 0.5	0.000
Total cholesterol (mg/dL)	170.9 ± 37.4	168.2 ± 38.1	173.3 ± 31.4	0.679
TLC (× 10^3/mm^3)	1863 ± 493	1799 ± 633	1752 ± 578	0.328
Serum iron (μg/dL)	72.9 ± 37.6	110.4 ± 52.8	118.2 ± 57.8	0.000
Serum ferritin (μg/L)	77.7 ± 75.3	74.9 ± 81.3	60.2 ± 64.4	0.358
Vitamin B12 (pg/mL)	686.5 ± 249	666.8 ± 281	709.1 ± 330	0.731

P values were determined with the use of ANOVA or the Kruskal-Wallis nonparametric test.

during the postoperative period (Table 5). The nutritional status of the patients who had undergone subtotal gastrectomy stabilized 6 mo after surgery, but the total gastrectomy patients showed a significantly reduced nutritional status in terms of BW, BMI and anthropometric measurements 12 mo after surgery (Figure 1).

Relationship between the nutritional assessment tools and nutritional status after gastrectomy

At 6 mo after surgery, a good correlation was observed between the results of the nutritional assessment tools (SGA, and NRS-2002) and those of the other nutritional measurement tools (BW, BMI, and anthropometric measurements).

According to the SGA and NRS-2002, the proportion of malnourished patients was 80% and 83%, respectively, 6 mo after surgery. At 12 mo after surgery, most patients who had been assessed as malnourished by SGA and NRS-2002 had returned to their preoperative status (Figure 2), although the other nutritional measurement tools (BW, BMI, and anthropometric measurements) still showed a malnourished status.

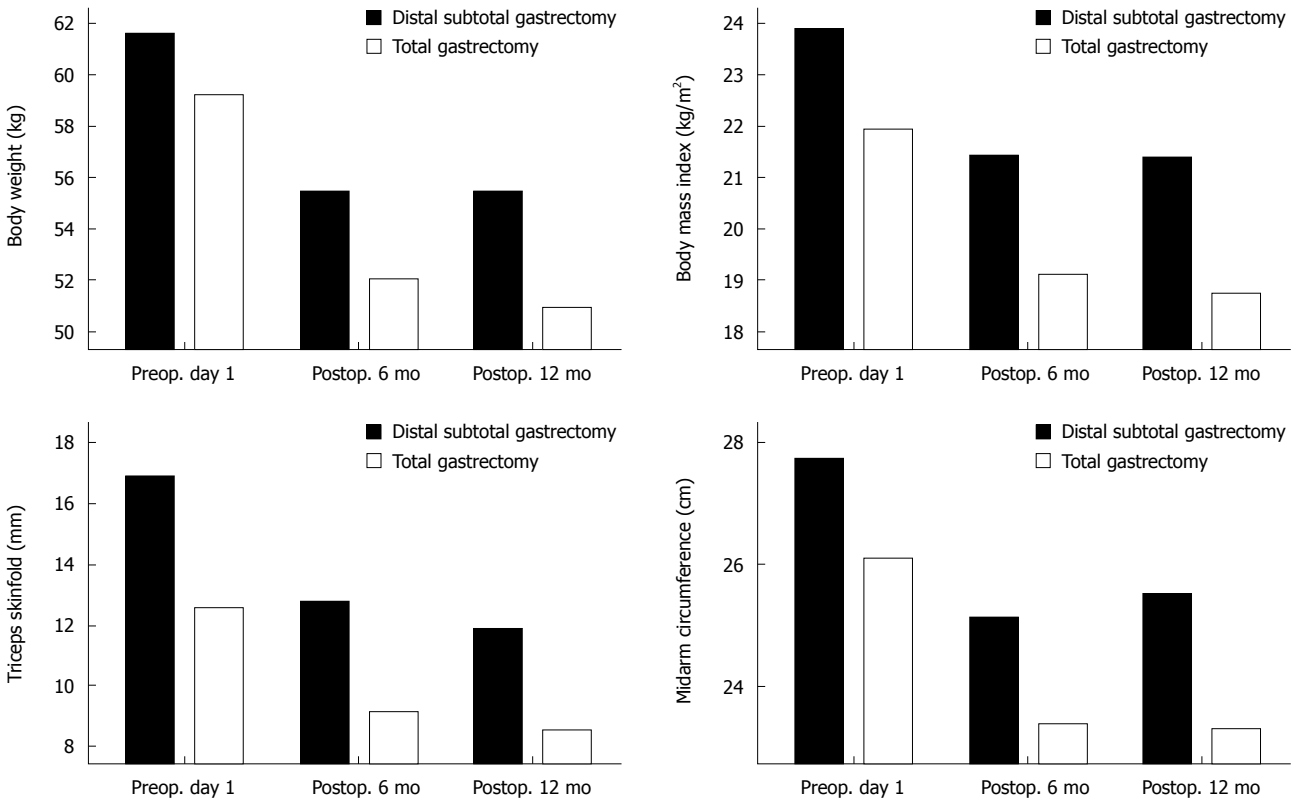

Figure 1 Postoperative nutritional status. Comparison of postoperative changes in objective nutritional parameters of patients undergoing distal subtotal gastrectomy and total gastrectomy from preoperative day 1 until 12 mo after surgery.

DISCUSSION

Nutritional depletion is a common problem in critically ill patients with cancer and is associated with a poor outcome. It is specifically reversible with nutritional support. Several studies have shown that patients with malignant gastrointestinal disease have a higher prevalence of weight loss before surgery, and during the first postoperative months, an additional weight loss of approximately 10% has been reported[7,18-21]. Plausible reasons for the development of malnutrition are a reduced food intake because of poor appetite, postprandial symptoms, and malabsorption[22,23]. Hospitalization, surgery, and chemo/radiotherapy can also cause malnutrition. In this study, the overall prevalence of malnutrition in patients with gastric cancer at admission was 31% according to the SGA and 43% according to the NRS-2002. Based on the objective assessment techniques, BW loss, BMI and anthropometric data were lower in the malnourished groups.

The purpose of nutritional screening is to identify those patients who are at nutritional risk and therefore at higher risk of complications. Malnutrition in hospitalized patients is a critical issue and has been associated with a significant increase in morbidity and mortality[9,10,24]. The detection of malnourished patients is possible if the importance of the issue is understood and the patient's nutritional status is evaluated on admission to hospital. Multiple clinical parameters are available to assess the nutritional status of critically ill patients, but no standard recommendation can be made at this time. Each method has its own advantages and disadvantages[25].

A traditional nutritional assessment often includes dietary and medical evaluations to identify significant weight loss over time, significantly low or high BW or BMI, reduction in MAC, SFT, serum protein levels, or immune competence, and functional measurements of muscle strength may be incorporated into the overall final assessment[26]. Individually, these measurements often have limited value in accurately determining a patient's nutritional risk. Studies have consistently revealed the inadequacy of any single assessment method or tool in evaluating a patient's nutritional status. An effective nutritional screening tool will generally combine both objective and subjective factors.

In this analysis of the preoperative and postoperative anthropometric p arameters of patients with gastric cancer, an interesting observation was that, although the mean BMI was within the normal range, malnutrition scores correlated significantly with the percentage weight loss according to the SGA and NRS-2002. This means that BMI alone is not sufficient to determine the real malnutrition rate. Aydin *et al*[27] reported that a patient can be malnourished even when the BMI is normal and that the SGA can detect malnutrition before the BMI drops below 20 kg/m^2. For this reason, it is very important to use several methods in combination to evaluate a patient's nutritional status.

Albumin is commonly considered a good marker of

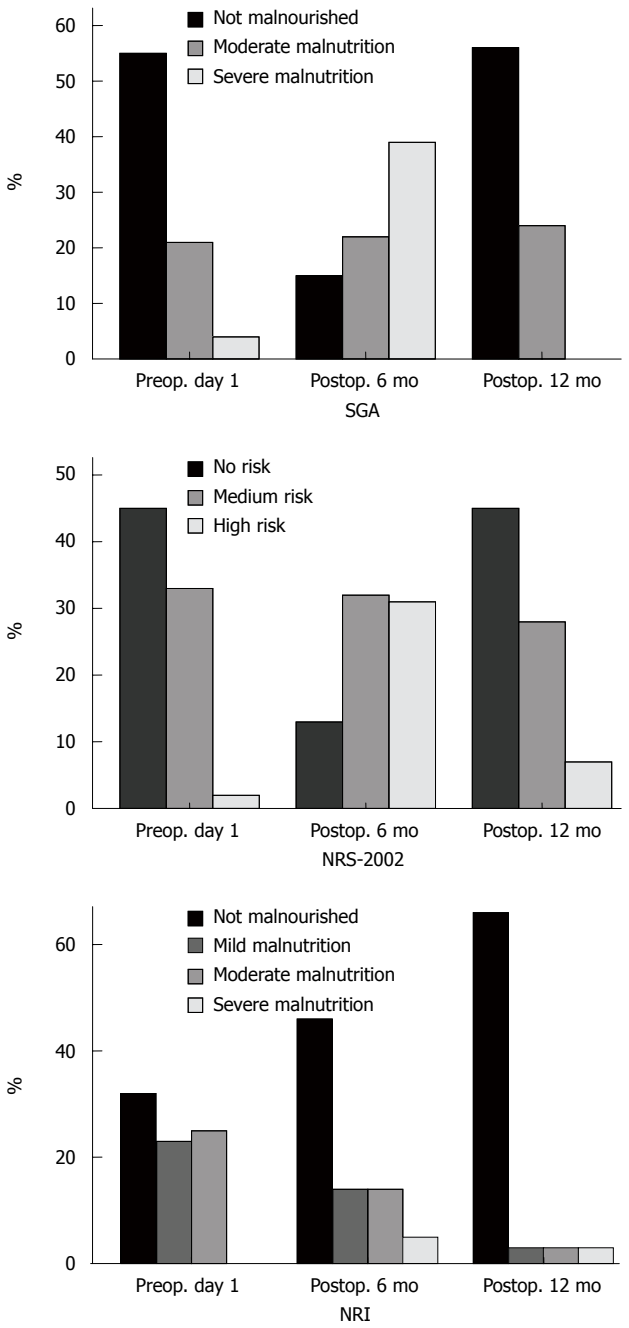

Figure 2 Malnutrition rate. Frequency of malnutrition during the postoperative period assessed with various subjective scoring techniques. SGA: Subjective global assessment; NRS-2002: Nutritional risk screening; NRI: Nutritional risk index.

nutritional status and visceral protein stores. The NRI is derived with an equation from the serum albumin concentration and the ratio of the actual to the usual weight. In this study, serum protein and albumin levels correlated statistically with the malnourished and well-nourished groups based on NRI assessment, but there was no statistical correlation with the groups defined by the SGA or NRS-2002. From this result, it can be inferred that albumin and serum protein parameters are not as sensitive as anthropometric measurements in the evaluation of nutritional status. Some studies have demonstrated that low serum albumin concentrations correlate with longer hospital stays, medical complications, and increased mortality[28,29], whereas other studies have reported that low serum protein levels do not always indicate malnutrition and malnutrition does not always accompany low serum protein levels[27,30,31]. Usually, many serum proteins and albumin are affected by the inflammatory response, liver disease, cancer, or idiopathically[32]. For these reasons, hypoalbuminemia has been reported to be a predictor of risk in a broad sense, rather than a parameter that indicates malnutrition[33]. Therefore, there are arguments for discounting hypoalbuminemia as a marker of malnutrition because patient populations differ. In this study, we evaluated only preoperative patients with gastric cancer who had no other serious medical problems. There was no good correlation between the NRI and objective assessments. The concordance and agreement were higher between the SGA and NRS-2002 than between the SGA and NRI. In this respect, the NRI may not be specific for the diagnosis of malnutrition in preoperative cancer patients.

Weight loss is a common problem after gastrectomy. The main mechanisms implicated include impaired food intake and malabsorption[34]. Patients who undergo gastrectomy consume fewer calories during the first 3-6 mo after surgery, after which their intake improves[20]. In this study, mean BW, BMI, TSF, and MAC were significantly reduced from the time of hospital discharge until 6 mo after surgery. Conversely, serum albumin levels, total protein, cholesterol, and TLC were similar between the groups before and 6 mo after surgery.

According to the subjective assessment of nutritional status 6 mo after surgery, 80% and 83% of the patients were malnourished according to the SGA and NRS-2002, respectively, compared with 31% and 43% of patients who were malnourished on preoperative day 1, respectively. In the group of patients who underwent subtotal gastrectomy, the patients' anthropometric parameters did not change between 6 and 12 mo after surgery. At 12 mo after surgery, their nutritional status was assessed as similar to its preoperative value according to the SGA, NRS-2002 and NRI, but their objective nutritional parameters were still low, especially mean BW, BMI, TSF, and MAC. Subjective assessment is a validated method of nutritional assessment when based on a medical history (weight change, dietary intake change, gastrointestinal symptoms, changes in functional capacity) and physical examination (loss of subcutaneous fat, muscle wasting). Therefore, according to the SGA and NRS-2002, the proportion of malnourished patients was high at 6 mo after surgery, but weight loss was not significant between 6 and 12 mo after surgery. Most of the patients who were assessed as malnourished had returned to their preoperative status, although the other nutritional measurement tools (BW, BMI, and anthropometric measurements) still indicated a malnourished status.

Patients with malignant gastrointestinal disease have a high prevalence of malnutrition. In cancer, reduced food intake and an increased energy gap result in the deterioration of nutritional status. It is very important to detect malnourished patients during the preoperative period and

postoperative follow-up. Not only objective nutritional parameters but also subjective assessments have some limitations in the accurate measurement of nutritional status. Therefore, measuring the nutritional status of patients who have undergone gastrectomy requires a combination of objective variables (anthropometric and laboratory measurements) and a subjective scoring system during the postoperative follow-up period.

COMMENTS

Background

Nutritional depletion is a common problem in critically ill patients with cancer and is associated with a poor outcome. The assessment of nutritional status and its evaluation plays an important role in tailoring nutritional support. Multiple clinical parameters are available to assess the nutritional status of gastric cancer patients, but no standard recommendation can be made at this time. This study would suggest that a specific tailored nutritional assessment is needed for the accurate measurement of nutritional status in patients.

Research frontiers

A traditional nutritional assessment often includes dietary and medical evaluations to identify significant weight loss over time, significantly low or high body weight, skinfold thickness, serum nutritional factor levels and functional measurements of muscle strength. Individually, these measurements often have limited value in accurately determining a patient's nutritional risk. As a result, combinations of diverse measurements have been developed into subjective scoring systems [subjective global assessment (SGA) and nutritional risk screening (NRS-2002)] designed to increase the sensitivity and specificity of nutritional status determinations. Scoring systems have been based on objective measurements of nutritional status, such as oral energy intake, body weight, weight loss over time, loss of subcutaneous fat, muscle wasting, serum protein levels, and immune competence.

Innovations and breakthroughs

When the authors analyzed the nutritional status in gastric cancer patients after gastrectomy surgery, body weight (BW), body mass index (BMI) and fat thickness were significantly reduced, but the total lymphocyte count, albumin, protein, cholesterol and serum iron levels did not decrease during the postoperative period. From this result, it can be inferred that albumin and serum protein parameters are not as sensitive as anthropometric measurements in the evaluation of nutritional status. Six months after surgery, there was a good correlation between the scoring nutritional assessment tools and the other general nutritional measurement tools (BW, BMI, and anthropometric measurements). However, 12 mo after surgery, most patients who were assessed as malnourished by the scoring nutritional assessment tool had returned to their preoperative normal nutritional status, although their BW, BMI, and anthropometric measurements still indicated a malnourished status.

Applications

The authors studied the prevalence of preoperative and postoperative malnutrition in patients with gastric cancer who underwent radical gastrectomy. This is the first study to report on the relationship between nutritional assessment tools and the nutritional status of gastric cancer patients after gastrectomy. From this study, not only objective nutritional parameters but also subjective scoring assessments have some limitations in the accurate measurement of nutritional status. Therefore, measuring the nutritional status of patients who have undergone gastrectomy requires a combination of objective variables (anthropometric and laboratory measurements) and a subjective scoring system during the postoperative follow-up period.

Peer review

This is a nicely written paper and well executed small study. There is enough presented to alert clinicians to both the problem of malnutrition in the sample studies and the problem of nutritional assessment tools used. The combination of assessment tools should allow for improvement in the identification of at risk patients.

REFERENCES

1 **Walesby RK**, Goode AW, Spinks TJ, Herring A, Ranicar AS, Bentall HH. Nutritional status of patients requiring cardiac surgery. *J Thorac Cardiovasc Surg* 1979; **77**: 570-576

2 **Bistrian BR**, Blackburn GL, Vitale J, Cochran D, Naylor J. Prevalence of malnutrition in general medical patients. *JAMA* 1976; **235**: 1567-1570

3 **Agradi E**, Messina V, Campanella G, Venturini M, Caruso M, Moresco A, Giacchero A, Ferrari N, Ravera E. Hospital malnutrition: incidence and prospective evaluation of general medical patients during hospitalization. *Acta Vitaminol Enzymol* 1984; **6**: 235-242

4 **Waitzberg DL**, Cordeiro AC, Faintuch J, Gama-Rodrigues J, Habr-Gama A. [Nutritional status in pre and immediate postoperative periods in patients with digestive diseases] *Rev Paul Med* 1983; **101**: 7-13

5 **Doerr TD**, Marks SC, Shamsa FH, Mathog RH, Prasad AS. Effects of zinc and nutritional status on clinical outcomes in head and neck cancer. *Nutrition* 1998; **14**: 489-495

6 **Allison SP**. Malnutrition, disease, and outcome. *Nutrition* 2000; **16**: 590-593

7 **Copland L**, Liedman B, Rothenberg E, Bosaeus I. Effects of nutritional support long time after total gastrectomy. *Clin Nutr* 2007; **26**: 605-613

8 **Tian J**, Chen JS. Nutritional status and quality of life of the gastric cancer patients in Changle County of China. *World J Gastroenterol* 2005; **11**: 1582-1586

9 **Giner M**, Laviano A, Meguid MM, Gleason JR. In 1995 a correlation between malnutrition and poor outcome in critically ill patients still exists. *Nutrition* 1996; **12**: 23-29

10 **Hill GL**, Blackett RL, Pickford I, Burkinshaw L, Young GA, Warren JV, Schorah CJ, Morgan DB. Malnutrition in surgical patients. An unrecognised problem. *Lancet* 1977; **1**: 689-692

11 **Wong PW**, Enriquez A, Barrera R. Nutritional support in critically ill patients with cancer. *Crit Care Clin* 2001; **17**: 743-767

12 Guidelines for the use of parenteral and enteral nutrition in adult and pediatric patients. *JPEN J Parenter Enteral Nutr* 2002; **26**: 1SA-138SA

13 **Jones HJ**, de Cossart L. Risk scoring in surgical patients. *Br J Surg* 1999; **86**: 149-157

14 **Schneider SM**, Hebuterne X. Use of nutritional scores to predict clinical outcomes in chronic diseases. *Nutr Rev* 2000; **58**: 31-38

15 Perioperative total parenteral nutrition in surgical patients. The Veterans Affairs Total Parenteral Nutrition Cooperative Study Group. *N Engl J Med* 1991; **325**: 525-532

16 **Detsky AS**, McLaughlin JR, Baker JP, Johnston N, Whittaker S, Mendelson RA, Jeejeebhoy KN. What is subjective global assessment of nutritional status? *JPEN J Parenter Enteral Nutr* 1987; **11**: 8-13

17 **Kondrup J**, Allison SP, Elia M, Vellas B, Plauth M. ESPEN guidelines for nutrition screening 2002. *Clin Nutr* 2003; **22**: 415-421

18 **Braga M**, Molinari M, Zuliani W, Foppa L, Gianotti L, Radaelli G, Cristallo M, Di Carlo V. Surgical treatment of gastric adenocarcinoma: impact on survival and quality of life. A prospective ten year study. *Hepatogastroenterology* 1996; **43**: 187-193

19 **Hyltander A**, Bosaeus I, Svedlund J, Liedman B, Hugosson I, Wallengren O, Olsson U, Johnsson E, Kostic S, Henningsson A, Körner U, Lundell L, Lundholm K. Supportive nutrition on recovery of metabolism, nutritional state, health-related quality of life, and exercise capacity after major surgery: a randomized study. *Clin Gastroenterol Hepatol* 2005; **3**: 466-474

20 **Liedman B**, Andersson H, Berglund B, Bosaeus I, Hugosson I, Olbe L, Lundell L. Food intake after gastrectomy for gastric carcinoma: the role of a gastric reservoir. *Br J Surg* 1996; **83**: 1138-1143

21 **Takahashi S**, Maeta M, Mizusawa K, Kaneko T, Naka T, Ashida K, Tsujitani S, Kaibara N. Long-term postoperative analysis of nutritional status after limited gastrectomy for early gastric cancer. *Hepatogastroenterology* 1998; **45**: 889-894

22 **Bae JM**, Park JW, Yang HK, Kim JP. Nutritional status of gastric cancer patients after total gastrectomy. *World J Surg*

1998; **22**: 254-260; discussion 260-261
23 **Iivonen MK**, Ahola TO, Matikainen MJ. Bacterial overgrowth, intestinal transit, and nutrition after total gastrectomy. Comparison of a jejunal pouch with Roux-en-Y reconstruction in a prospective random study. *Scand J Gastroenterol* 1998; **33**: 63-70
24 **Naber TH**, Schermer T, de Bree A, Nusteling K, Eggink L, Kruimel JW, Bakkeren J, van Heereveld H, Katan MB. Prevalence of malnutrition in nonsurgical hospitalized patients and its association with disease complications. *Am J Clin Nutr* 1997; **66**: 1232-1239
25 **Waitzberg DL**, Correia MI. Nutritional assessment in the hospitalized patient. *Curr Opin Clin Nutr Metab Care* 2003; **6**: 531-538
26 **DeLegge MH**, Drake LM. Nutritional assessment. *Gastroenterol Clin North Am* 2007; **36**: 1-22, v
27 **Aydin N**, Karaöz S. Nutritional assessment of patients before gastrointestinal surgery and nurses' approach to this issue. *J Clin Nurs* 2008; **17**: 608-617
28 **Gibbs J**, Cull W, Henderson W, Daley J, Hur K, Khuri SF. Preoperative serum albumin level as a predictor of operative mortality and morbidity: results from the National VA Surgical Risk Study. *Arch Surg* 1999; **134**: 36-42
29 **Delgado-Rodríguez M**, Medina-Cuadros M, Gómez-Ortega A, Martínez-Gallego G, Mariscal-Ortiz M, Martinez-Gonzalez MA, Sillero-Arenas M. Cholesterol and serum albumin levels as predictors of cross infection, death, and length of hospital stay. *Arch Surg* 2002; **137**: 805-812
30 **Shenkin A**. Impact of disease on markers of macronutrient status. *Proc Nutr Soc* 1997; **56**: 433-441
31 **Young VR**, Marchini JS, Cortiella J. Assessment of protein nutritional status. *J Nutr* 1990; **120** Suppl 11: 1496-1502
32 **Hill GL**. Surgical nutrition: time for some clinical common sense. *Br J Surg* 1988; **75**: 729-730
33 **Franch-Arcas G**. The meaning of hypoalbuminaemia in clinical practice. *Clin Nutr* 2001; **20**: 265-269
34 **Armbrecht U**, Lundell L, Lindstedt G, Stockbruegger RW. Causes of malabsorption after total gastrectomy with Roux-en-Y reconstruction. *Acta Chir Scand* 1988; **154**: 37-41

S- Editor Wang YR **L- Editor** Webster JR **E- Editor** Ma WH

World Journal of Gastroenterology

Online Submissions: http://www.wjgnet.com/1007-9327office
wjg@wjgnet.com
doi:10.3748/wjg.v16.i26.3318

World J Gastroenterol 2010 July 14; 16(26): 3318-3324
ISSN 1007-9327 (print)
© 2010 Baishideng. All rights reserved.

BRIEF ARTICLE

Oncological outcome of unresectable lung metastases without extrapulmonary metastases in colorectal cancer

Wen-Hua Li, Jun-Jie Peng, Jia-Qing Xiang, Wei Chen, San-Jun Cai, Wen Zhang

Wen-Hua Li, Wen Zhang, Department of Medical Oncology, Fudan University Shanghai Cancer Center, Shanghai 200032, China; Department of Oncology, Shanghai Medical College, Fudan University, Shanghai 200032, China
Jun-Jie Peng, San-Jun Cai, Department of Colorectal Surgery, Fudan University Shanghai Cancer Center, Shanghai 200032, China
Jia-Qing Xiang, Department of Thoracic Surgery, Fudan University Shanghai Cancer Center, Shanghai 200032, China
Wei Chen, Department of Biostatistics, University of Michigan, Ann Arbor, MI 48710, United States
Author contributions: Li WH and Peng JJ contributed equally to this work; Li WH, Peng JJ, Zhang W, Cai SJ and Xiang JQ designed study; Chen W contributed statistical analysis; Li WH and Peng JJ collected and interpreted the data; Li WH, Peng JJ and Zhang W wrote the paper.
Supported by The Grant from Shanghai Science and Technology Committee, No. 09411967000
Correspondence to: Wen Zhang, Associate Professor, Department of Medical Oncology, Fudan University Shanghai Cancer Center, 270 Dong An Road, Shanghai 200032, China. whliiris@hotmail.com
Telephone: +86-21-64175590 Fax: +86-21-64035387
Received: March 23, 2010 Revised: April 22, 2010
Accepted: April 29, 2010
Published online: July 14, 2010

Abstract

AIM: To explore the oncological outcomes of unresectable lung metastases without extrapulmonary metastases in colorectal cancer.

METHODS: Patients with unresectable isolated lung metastases from colorectal cancer were prospectively collected in a single institution during a 5-year period. All patients received either the fluorouracil/leucovorin plus oxaliplatin, fluorouracil/leucovorin plus irinotecan or capecitabine plus oxaliplatin regimen as first-line treatment. The resectability after preoperative chemotherapy was evaluated. Patients' outcome and predictive factors for overall survival were also investigated by univariate and multivariate analysis.

RESULTS: A total of 70 patients were included in the study. After standardized first-line chemotherapy, only 4 patients (5.7%) were converted to resectable disease. The median overall survival time in all patients was 19 mo (95% CI: 12.6-25.4), with a 2-year overall survival rate of 38.8%. No survival difference was found among different first-line chemotherapeutic regimens. Prognostic analysis demonstrated that only the first response assessment for first-line treatment was the independent factor for predicting overall survival. The median survival time in partial response, stable disease and progressive disease patients were 27 mo, 16 mo and 8 mo (P = 0.00001).

CONCLUSION: Pulmonary metastasectomy can only be performed in a small part of unresectable lung metastases patients after chemotherapy. Patients' first response assessment is an important prognostic factor.

© 2010 Baishideng. All rights reserved.

Key words: Colorectal cancer; Lung; Metastases; Chemotherapy

Peer reviewer: Francis Seow-Choen, MBBS, FRCSEd, FAMS, Professor, Seow-Choen Colorectal Centre, Mt Elizabeth Medical Centre, Singapore, 3 Mt Elizabeth Medical Centre #09-10, Singapore 228510, Singapore

Li WH, Peng JJ, Xiang JQ, Chen W, Cai SJ, Zhang W. Oncological outcome of unresectable lung metastases without extrapulmonary metastases in colorectal cancer. *World J Gastroenterol* 2010; 16(26): 3318-3324 Available from: URL: http://www.wjgnet.com/1007-9327/full/v16/i26/3318.htm DOI: http://dx.doi.org/10.3748/wjg.v16.i26.3318

INTRODUCTION

Colorectal cancer is the second leading cause of cancer death in the USA, and its frequency is increasing in China in recent years. In Shanghai, colorectal cancer has

become the third most prevalent malignancy[1]. Approximately 50%-60% of patients diagnosed with colorectal cancer will develop metastases[2,3]. The liver and lungs are the most common sites of metastases for colorectal cancers. Nearly 50% of patients with colorectal cancer will develop liver metastases, while only approximately 10%-15% of patients will develop lung metastases ultimately[4,5]. Commonly, metastases from colorectal cancer occur first in the liver and then later appear systemically, because of venous drainage *via* the portal system. However, lung metastases without extrapulmonary metastasis, also called isolated lung metastases, have been reported in several studies[4,6,7]. Through the bypass route of venous or lymphatic drainage, isolated lung metastases were only found in 2%-8% of all colorectal cancers[4,6].

Since the majority of metastases from colorectal cancer are considered initially unresectable disease, neoadjuvant chemotherapy has been applied in potentially resectable liver metastases for years. Studies demonstrated that 10%-15% of initially unresectable liver metastases could be converted to resectable disease after preoperative chemotherapy. However, the experience in unresectable isolated lung metastasis was rare. Current opinions consider that the recommendation in liver metastases may be reasonable to apply to the treatment of lung metastasis[8], but the evidence is weak and the result of this application is unknown, especially for initially unresectable isolated lung metastases.

In this current study, we prospectively collected data from all patients with unresectable isolated lung metastases from colorectal cancer at the first recurrence in a single institution during a 5-year period. The resectability after chemotherapy, outcomes of the patients, results with different chemotherapeutic regimens, and predictive factors for overall survival were all studied in the current cohort.

MATERIALS AND METHODS

Between May 2003 and January 2008, a prospective study was performed to collect data from all the colorectal cancer patients who developed unresectable lung metastasis without extrapulmonary lesions as the first recurrence from the outpatient and inpatient services of Fudan University Shanghai Cancer Center. All the unresectable patients had multiple lung metastastic lesions in two or more than two lobes and had no possibility of radical resection. According to the institutional protocol, all patients who were diagnosed with recurrence received intensive oncological assessment, including chest computed tomography (CT) scans, abdominopelvic CT or magnetic resonance imaging scans and serum carcinoembryonic antigen (CEA). Positron emission tomography-CT scans were performed in some patients, and digital rectal examinations were performed in all patients whose primary tumor was located in rectum.

For viable patients, core biopsy or fine needle biopsy was performed to confirm the diagnosis. For patients whose cytological or histological diagnosis was unavailable, the diagnoses of lung metastases were discussed by the colorectal cancer multidisciplinary treatment (MDT) team, which included a specialized radiologist. When there was doubt about the case, close follow-up without chemotherapy and dynamic change in CT scans were observed to confirm the diagnosis. The resectability of lung metastases was discussed by the colorectal MDT team and a specialized thoracic surgeon according to image study.

Patients with extrapulmonary metastasis or local recurrence were excluded from the current study. Patients, who refused to receive chemotherapy (3 cases) or sign the informed consent form (2 cases), were also excluded from the study. Besides concurrent chemotherapy, 4 patients received weekly administration of cetuximab 8, 8, 11 and 16 times, respectively, in the first line setting; they were excluded from the following outcome analysis because of the small number of cases. After screening, a total of 70 colorectal cancer patients who developed synchronous or metachronous unresectable isolated lung metastasis were included in the study.

Chemotherapeutic regimens and response assessment

According to the medical oncologists' preference, either the fluorouracil/leucovorin plus oxaliplatin (FOLFOX), fluorouracil/leucovorin plus irinotecan (FOLFIRI) or capecitabine plus oxaliplatin (XELOX) regimen was used as first-line treatment for patients who never received chemotherapy or who had received adjuvant chemotherapy over 12 mo ago. For patients who received adjuvant chemotherapy within 12 mo, a different regimen from their original first-line treatment was used. Second-line or third-line treatment regimens were determined by considering the first-line regimen, adjuvant regimen and patients' consent. The "stop-and-go" strategy using a modified FOLFOX6 regimen with maintenance capecitabine during the interval period was applied to 5 patients in our cohort, and they were considered to have received first-line treatment of FOLFOX in the following analysis.

Physical examination, chest CT scans, abdominopelvic ultrasound or CT scans, and serum CEA were used according to the institutional routine assessment for metastatic colorectal cancers. During chemotherapy, response assessment was performed after the first 3 (XELOX regimen) or 4 cycles (FOLFOX or FOLFIRI regimen) and then repeated every 2 to 3 mo. In patients who stopped treatment, similar oncological assessments were asked to be performed every 3 to 6 mo. The response to treatment was defined based on Response Assessment Criteria in Solid Tumors (RECIST)[9].

Statistical analysis

All surviving patients were followed up between January and March 2009 for the purpose of this project. Progression free survival (PFS) was calculated from the start of first-line treatment to the time when disease progression was determined by response assessment. In patients with metachronous metastasis, the time from resection of the primary lesion to occurrence of metastases in the lung was defined as time to metastasis in the current study. The

prognostic value of the first response assessment, which was performed after the first 3 (XELOX regimen) or 4 cycles (FOLFOX or FOLFIRI regimen) of chemotherapy, was analyzed as an independent factor.

The distribution of PFS and overall survival (OS) was calculated by the Kaplan-Meier method, and a log-rank test was used to compare the differences among curves in univariate analyses. Cox regression was used in multivariate analyses, and hazard ratios were calculated including 95% confidence interval (CI). $P < 0.05$ was considered statistically significant.

RESULTS

Basic clinical characteristics

Of the 70 patients who had unresectable lung metastases, 19 patients (27.1%) had synchronous lung metastases with primary colorectal cancers, while the other 51 patients (72.9%) had metachronous metastatic disease. All the patients with synchronous metastases in our series underwent resection of primary colorectal cancer first, and chemotherapy started within 2 mo of the surgery. All 70 patients received first-line treatment with a regimen of FOLFOX, FOLFIRI or XELOX. The detailed clinicopathological features are summarized in Table 1. In 51 patients who had metachronous lung metastasis, the median time to metastasis was 17 mo (range: 3-67 mo). The cumulative proportions of time to metastasis within 1, 2 and 3 years were 29.4%, 70.6% and 84.3%, respectively.

Treatment outcomes

With a median follow-up time of 17 mo (range: 5-44 mo), 81.4% of patients (57 cases) had disease progression, and 26 patients were still alive (37.1%). The median PFS for first-line treatment was 8 mo (95% CI: 6.4-9.6 mo, range: 1-32 mo, Figure 1A). The median PFS for FOLFOX, XELOX and FOLFIRI regimens in the first-line setting were 10, 8 and 8 mo, respectively ($P = 0.693$). The median overall survival time was 19 mo (95% CI: 12.6-25.4 mo, range: 5-44 mo), with a 2 years OS rate of 38.8% (Figure 1B). At the patients' first response assessment, none of the patients had complete response; partial response (PR), stable disease (SD) and progressive disease (PD) were observed in 35.7%, 51.4% and 12.9% of patients, respectively. Four patients (5.7%) in our cohort underwent pulmonary resection of metastases for curative intent after first-line chemotherapy. We analyzed the 4 patients whose pulmonary metastastic lesions converted to resection in more detail: all 4 patients had multiple lesions in bilateral lungs. Two patients received preoperative chemotherapy with a regimen of modified FOLFOX6, while the other two received FOLFIRI. All 4 patients had a PR after first-line chemotherapy. The decision to perform metastatectomy in the 4 patients was made on the basis of the disappearance of lesions in one side of lung and stillness of residual disease in the other side of lung during ongoing chemotherapy. One patient underwent thoracoscopic surgery and the other three underwent open surgery. Wedge resections were performed and postoperative chemotherapy was applied using the same regimen before resection in all 4 patients. However, 1 patient developed disseminated liver and pelvic metastases later and died of cancer 7 mo after surgery; 1 patient had lung metastasis recurrence in the place where lesions disappeared after first-line chemotherapy. The other two patients were still free of recurrence until the last follow-up.

Table 1 The clinicopathological characteristics and survival time of all the unresectable pulmonary metastases patients

Characteristics	Number (%)	Median OS (mo)	95% CI	*P* value
Gender				
Male	21 (30)	22	9.0-35.0	0.487
Female	49 (70)	19	10.8-27.1	
Age (yr)				
≤ 60	42 (60)	24	19.5-28.5	0.093
> 60	28 (40)	13	7.8-13.2	
Location of primary lesion				
Colon	23 (32.9)	22	6.8-37.2	0.957
Rectum	47 (67.1)	19	10.7-27.2	
Stage of primary lesion				
Ⅰ	4 (5.7)	11	5.1-16.9	0.766
Ⅱ	11 (15.7)	27	14.1-39.9	
Ⅲ	36 (51.4)	18	8.6-27.4	
Ⅳ	19 (27.1)	22	11.7-32.3	
Unilateral or bilateral				
Unilateral	3 (4.3)	Not reached	Not reached	0.769
Bilateral	67 (95.7)	19	12.6-25.4	
Synchronous or metachronous				
Synchronous	19 (27.1)	22	11.5-32.5	0.693
Metachronous	51 (72.9)	18	11.0-24.9	
Regimen of first-line treatment				
FOLFOX	32 (45.7)	17	9.4-24.6	0.556
XELOX	12 (17.1)	24	18.5-29.5	
FOLFIRI	26 (37.1)	17	8.0-26.0	
First response assessment				
PR	25 (35.7)	27	23.4-30.6	0.00001
SD	36 (51.4)	16	8.3-23.7	
PD	9 (12.9)	8	5.2-10.8	

FOLFOX: Fluorouracil/leucovorin plus oxaliplatin; XELOX: Capecitabine plus oxaliplatin; FOLFIRI: Fluorouracil/leucovorin plus irinotecan; PR: Partial response; SD: Stable disease; PD: Progressive disease.

Clinical characteristics, including patients' gender, age, location of primary lesion, stage of primary lesion, metachronous or synchronous lung metastasis, unilateral or bilateral lung metastases, first-line chemotherapeutic regimens and first response assessment, were analyzed in univariate analyses to find potential predictive factors for patients' OS. The time to metastasis (continuous variable) in 51 patients with metachronous lung metastases was also studied using univariate Cox regression. Univariate analysis revealed that only the first response assessment was related to overall survival. Using Cox regression, multivariate analyses also demonstrated that first response assessment was the only independent factor for predicting OS. The risks of death within 2 years in SD and PD patients at their first response assessment were 3.5 times (95% CI: 1.4-8.7, $P = 0.007$) and 18.2 times (95% CI: 6.1-54.5, $P = 2 \times 10^{-8}$) higher than that of PR patients at the first response assessment. The median survival time in PR, SD and PD patients was 27 mo, 16 mo and 8 mo ($P = 0.00001$, Figure 1C).

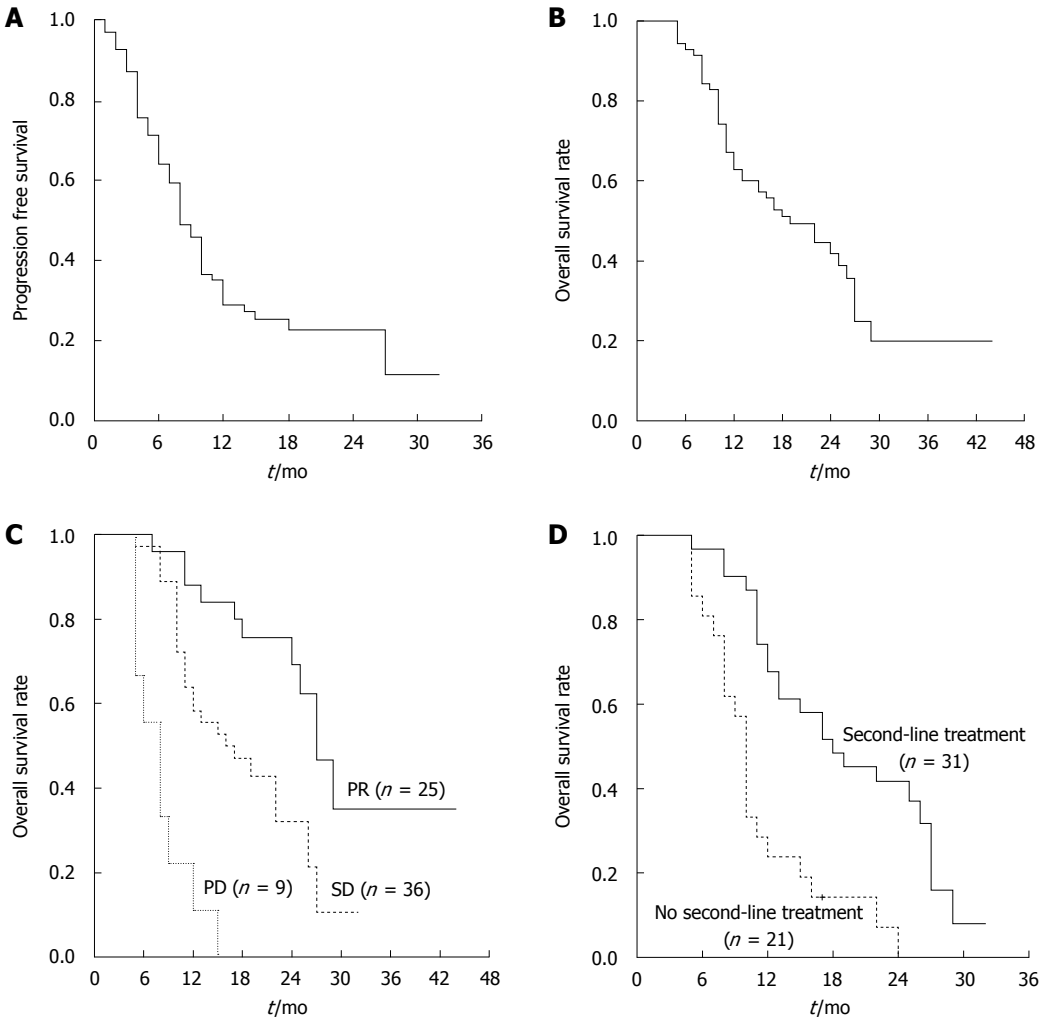

Figure 1 The median progression free survival and overall survival time. A: Progression free survival time of first-line chemotherapy; B: Overall survival rate for colorectal cancer patients with unresectable pulmonary metastases; C: Kaplan and Meier plots for median survival time according to chemotherapy efficacy; D: Kaplan and Meier plots for median survival time according to whether the second-line treatment was received. PR: Partial response; SD: Stable disease; PD: Progressive disease.

Second-line treatment

None of the patients without disease progression received second-line treatment. A total of 52 patients (74.3%) had disease progression during first-line chemotherapy. Thirty-one patients (59.2% of all first-line PD patients) underwent second-line chemotherapy. Unlike the first-line regimens, the chemotherapeutic regimens in the second-line were varied. Three patients only had a single agent regimen with 5-FU/leucovorin or capecitabine; 8 patients received FOLFOX or XELOX regimen; 16 patients received FOLFIRI or XELIRI regimen; 4 patients received a combination of chemotherapy and cetuximab. In 52 first-line PD patients, the median survival time was 18 mo for those receiving any of the above second-line regimens, compared with 10 mo for patients without any further chemotherapy ($P = 0.0004$, Figure 1D) .

DISCUSSION

In the current study, we focused on a typical group of patients with isolated lung metastasis. Lung metastases in all of our patients were the first and the only site of metastasis after diagnosing the primary tumor in the colon or rectum. Isolated lung metastasis is considered uncommon in colorectal cancers, as the major venous drainage is through the portal vein system and metastases in lungs usually occur along with concomitant systemic metastases. Pihl *et al*[4] reported 8.6% of 1578 patients with colorectal cancer who had undergone curative resection developed lung metastases, and that 11.5% of lung metastases were found in patients with rectal cancer, compared with 3.5% in colon cancer. Tan *et al*[6] reported 56 cases (7.4%) of isolated lung metastasis in 754 patients with colorectal cancer, and 13.3% of lung metastases were found in patients with primary rectal cancer *vs* 6.3% with primary colon cancer ($P = 0.011$). In our series, we also observed more isolated lung metastases in patients with primary rectal cancer. This result may partly be attributed to the bypass route of spreading into systemic circulation *via* the hemorrhoidal veins. However, the precise mechanism for this phenomenon of skip metastasis bypassing the first venous or lymphatic draining route is unclear. Differences in tumor biology among various patients, tumor types, or even within a given tumor, may also be related to this result[10,11].

Most of the lung metastases from colorectal cancer were unresectable disease because of synchronous metastases in other organs or multiple unilateral or bilateral lesions. Although resection of synchronous liver and lung metastases was performed in selected patients in several studies, a favorable outcome was only observed in a study with a small number of patients with limited metastases in liver and lung[12-14]. Different from the situation in the liver, lung metastases are more prone to disseminating to the lungs bilaterally, making the resection rate lower than that of liver metastasis[15,16]. The use of CT scans in diagnosing multiple lesions and thoracoscopic resection in the management of metastatic disease were also questioned[17-19]. Most of the patients selected for pulmonary metastasectomy presented with a single lesion in lung, and patients with a single metastasis were proven to have a better outcome compared with patients with multiple metastases[20-22]. The effectiveness of pulmonary resection in patients with multiple lesions is still unclear, and no consensus has been obtained for the indication of resection concerning the number of metastases[8,22-25]. Multiple lesions in bilateral lungs were usually considered unresectable disease. In our study, after discussing the resectability of isolated lung metastases, all cases with unresectable metastases were treated with first line chemotherapy. We reported the possibility of converting to resection in patients with multiple bilateral lesions by preoperative chemotherapy for the first time. Four cases (5.7%) were converted to resectable disease after first line treatment. To our knowledge, this is the first study reporting the resectability of initially unresectable lung metastases after preoperative chemotherapy. The proportion of resection seems lower than that of inoperable liver metastases[26], suggesting a different strategy might be used when considering preoperative chemotherapy for initially unresectable lung metastases. However, there are still other reasons which may be responsible for the low rate of conversion to resection, including the undetermined surgical indication, doubtful nodules in other areas, multiple lobular lesions after chemotherapy, and patients' consent.

In our study, the median PFS for first-line treatment and OS was similar to other studies in stage Ⅳ colorectal cancer, which combined all metastatic disease together[27,28]. Different chemotherapeutic regimens in the first-line setting, including FOLFOX, FOLFIRI and XELOX, resulted in a similar PFS and response rate. The National Comprehensive Cancer Network (NCCN) guidelines recommended that the practice in liver metastases can be applied to lung metastases[29]. However, few data were focused on this group of patients with unresectable isolated lung metastases. Our data confirmed the similar oncological results in the management of isolated lung metastases. Although the second-line chemotherapy regimens varied in progressed patients, we confirmed the benefit of continuing chemotherapy for patients with isolated lung metastases who progressed after first-line treatment. However, which regimen would be better and whether a monoclonal antibody should be used were unknown according to our study.

During first-line chemotherapy, the first response assessment is usually performed after the second month of treatment in most clinical trials of metastatic colorectal cancer. In our cohort, multivariate analysis demonstrated that the first response assessment was the independent factor predicting patients' overall survival. The risk of death within 2 years was found to be 3.5 times higher in SD patients than that in PR patients. This result raised doubts about whether we should continue first-line treatment in SD patients. In our study, the response assessment was performed according to RECIST guidelines. Patients assessed to have SD included patients whose targeted lesions showed less than 20% increase to less than 30% decrease in the sum of the longest diameter. Changing of chemotherapeutic regimens might be reasonable in selected SD patients, such as patients with increased lesions. For patients with metachronous lung metastases, the time to relapse was considered a risk factor predicting survival in several studies[30], but most other studies did not find the time to relapse a significant risk factor[31-33]. In 906 patients who relapsed after curative treatment of colorectal cancer, Kobayashi *et al*[16] found that the time to relapse was only related to the survival of liver metastases and local recurrence, but no survival difference was found in patients with lung metastases.

Novel treatment approaches have been introduced into the local treatment of unresectable lung metastases. Radiofrequency ablation was studied for patients with unresectable lung metastases in several studies. Marginal survival benefit and improvement in quality of life were observed in selected cases[34-36], and it is only used as an adjunct to resection or as an alternative for unresectable lesions. Transpulmonary chemoembolization is another new technique used for the local treatment of inoperable lung metastases. Preliminary results found this technique was a well-tolerated procedure for palliative treatment, but the benefit of survival was still unknown[37-39].

In conclusion, isolated lung metastases were relatively rare in metastatic colorectal cancer. The outcomes of chemotherapy in unresectable lung metastases patients were similar to the results of liver metastases, and first response assessment was an important risk factor to predict survival. Pulmonary metastasectomy can only be performed in a small group of patients with initially unresectable lung metastases after preoperative chemotherapy. Further studies are needed to validate our results and evaluate the rate of resectability after chemotherapy.

COMMENTS

Background

Approximately 50%-60% of colorectal cancer patients will develop metastases. Nearly half of patients with colorectal cancer will develop liver metastases, while only approximately 10%-15% of patients will develop lung metastases ultimately. Studies demonstrated that 10%-15% of initially unresectable liver metastases could be converted to resectable disease after preoperative chemotherapy. However, there was little experience in unresectable isolated lung metastasis.

Research frontiers

Current opinions consider that it may be reasonable to apply the recommendations for treatment of liver metastases to the treatment of lung metastasis, but

the evidence is weak and the result of this application is unknown, especially for initially unresectable isolated lung metastases.

Innovations and breakthroughs

This study prospectively collected data from all patients with unresectable isolated lung metastases from colorectal cancer as the first recurrence in a single institution during a 5-year period. The outcomes of chemotherapy were similar to the results of liver metastases, and first response assessment was an important risk factor to predict survival. Furthermore, only 5.7% of patients were converted to resectable disease after preoperative chemotherapy, which was obviously lower than the conversion rate in liver metastasis. It is the first study reporting the resectability of initially unresectable lung metastases after preoperative chemotherapy.

Applications

The results of this study suggested that a different strategy might be used when considering the preoperative chemotherapy for initially unresectable lung metastases.

Peer review

This is an interesting and novel paper looking at isolated lung metastases in colorectal cancer.

REFERENCES

1 Shanghai Municipal Center for Disease Control and Prevention. Shanghai Cancer Report 2007. Shanghai: SCDC, 2007

2 **Van Cutsem E**, Nordlinger B, Adam R, Köhne CH, Pozzo C, Poston G, Ychou M, Rougier P. Towards a pan-European consensus on the treatment of patients with colorectal liver metastases. *Eur J Cancer* 2006; **42**: 2212-2221

3 **Yoo PS**, Lopez-Soler RI, Longo WE, Cha CH. Liver resection for metastatic colorectal cancer in the age of neoadjuvant chemotherapy and bevacizumab. *Clin Colorectal Cancer* 2006; **6**: 202-207

4 **Pihl E**, Hughes ES, McDermott FT, Johnson WR, Katrivessis H. Lung recurrence after curative surgery for colorectal cancer. *Dis Colon Rectum* 1987; **30**: 417-419

5 **Foster JH**. Treatment of metastatic disease of the liver: a skeptic's view. *Semin Liver Dis* 1984; **4**: 170-179

6 **Tan KK**, Lopes Gde L Jr, Sim R. How uncommon are isolated lung metastases in colorectal cancer? A review from database of 754 patients over 4 years. *J Gastrointest Surg* 2009; **13**: 642-648

7 **Scheele J**, Altendorf-Hofmann A, Stangl R, Gall FP. Pulmonary resection for metastatic colon and upper rectum cancer. Is it useful? *Dis Colon Rectum* 1990; **33**: 745-752

8 **Headrick JR**, Miller DL, Nagorney DM, Allen MS, Deschamps C, Trastek VF, Pairolero PC. Surgical treatment of hepatic and pulmonary metastases from colon cancer. *Ann Thorac Surg* 2001; **71**: 975-979; discussion 979-980

9 **Therasse P**, Arbuck SG, Eisenhauer EA, Wanders J, Kaplan RS, Rubinstein L, Verweij J, Van Glabbeke M, van Oosterom AT, Christian MC, Gwyther SG. New guidelines to evaluate the response to treatment in solid tumors. European Organization for Research and Treatment of Cancer, National Cancer Institute of the United States, National Cancer Institute of Canada. *J Natl Cancer Inst* 2000; **92**: 205-216

10 **Merrie AE**, Phillips LV, Yun K, McCall JL. Skip metastases in colon cancer: assessment by lymph node mapping using molecular detection. *Surgery* 2001; **129**: 684-691

11 **Tang R**, Wang JY, Chen JS, Chang-Chien CR, Tang S, Lin SE, You YT, Hsu KC, Ho YS, Fan HA. Survival impact of lymph node metastasis in TNM stage III carcinoma of the colon and rectum. *J Am Coll Surg* 1995; **180**: 705-712

12 **Miller G**, Biernacki P, Kemeny NE, Gonen M, Downey R, Jarnagin WR, D'Angelica M, Fong Y, Blumgart LH, DeMatteo RP. Outcomes after resection of synchronous or metachronous hepatic and pulmonary colorectal metastases. *J Am Coll Surg* 2007; **205**: 231-238

13 **Nagakura S**, Shirai Y, Yamato Y, Yokoyama N, Suda T, Hatakeyama K. Simultaneous detection of colorectal carcinoma liver and lung metastases does not warrant resection. *J Am Coll Surg* 2001; **193**: 153-160

14 **Mineo TC**, Ambrogi V, Tonini G, Bollero P, Roselli M, Mineo D, Nofroni I. Longterm results after resection of simultaneous and sequential lung and liver metastases from colorectal carcinoma. *J Am Coll Surg* 2003; **197**: 386-391

15 **Kobayashi H**, Mochizuki H, Sugihara K, Morita T, Kotake K, Teramoto T, Kameoka S, Saito Y, Takahashi K, Hase K, Oya M, Maeda K, Hirai T, Kameyama M, Shirouzu K, Muto T. Characteristics of recurrence and surveillance tools after curative resection for colorectal cancer: a multicenter study. *Surgery* 2007; **141**: 67-75

16 **Kobayashi H**, Mochizuki H, Morita T, Kotake K, Teramoto T, Kameoka S, Saito Y, Takahashi K, Hase K, Ohya M, Maeda K, Hirai T, Kameyama M, Shirouzu K, Sugihara K. Timing of relapse and outcome after curative resection for colorectal cancer: a Japanese multicenter study. *Dig Surg* 2009; **26**: 249-255

17 **McCormack PM**, Ginsberg KB, Bains MS, Burt ME, Martini N, Rusch VW, Ginsberg RJ. Accuracy of lung imaging in metastases with implications for the role of thoracoscopy. *Ann Thorac Surg* 1993; **56**: 863-865; discussion 865-866

18 **Nakajima J**, Murakawa T, Fukami T, Sano A, Sugiura M, Takamoto S. Is finger palpation at operation indispensable for pulmonary metastasectomy in colorectal cancer? *Ann Thorac Surg* 2007; **84**: 1680-1684

19 **Parsons AM**, Detterbeck FC, Parker LA. Accuracy of helical CT in the detection of pulmonary metastases: is intraoperative palpation still necessary? *Ann Thorac Surg* 2004; **78**: 1910-1916; discussion 1916-1918

20 **Kanemitsu Y**, Kato T, Hirai T, Yasui K. Preoperative probability model for predicting overall survival after resection of pulmonary metastases from colorectal cancer. *Br J Surg* 2004; **91**: 112-120

21 **Watanabe I**, Arai T, Ono M, Sugito M, Kawashima K, Ito M, Nagai K, Saito N. Prognostic factors in resection of pulmonary metastasis from colorectal cancer. *Br J Surg* 2003; **90**: 1436-1440

22 **Welter S**, Jacobs J, Krbek T, Poettgen C, Stamatis G. Prognostic impact of lymph node involvement in pulmonary metastases from colorectal cancer. *Eur J Cardiothorac Surg* 2007; **31**: 167-172

23 **Yano T**, Fukuyama Y, Yokoyama H, Tanaka Y, Miyagi J, Kuninaka S, Asoh H, Ichinose Y. Failure in resection of multiple pulmonary metastases from colorectal cancer. *J Am Coll Surg* 1997; **185**: 120-122

24 **McCormack PM**, Burt ME, Bains MS, Martini N, Rusch VW, Ginsberg RJ. Lung resection for colorectal metastases. 10-year results. *Arch Surg* 1992; **127**: 1403-1406

25 **Onaitis MW**, Petersen RP, Haney JC, Saltz L, Park B, Flores R, Rizk N, Bains MS, Dycoco J, D'Amico TA, Harpole DH, Kemeny N, Rusch VW, Downey R. Prognostic factors for recurrence after pulmonary resection of colorectal cancer metastases. *Ann Thorac Surg* 2009; **87**: 1684-1688

26 **Adam R**, Avisar E, Ariche A, Giachetti S, Azoulay D, Castaing D, Kunstlinger F, Levi F, Bismuth F. Five-year survival following hepatic resection after neoadjuvant therapy for nonresectable colorectal. *Ann Surg Oncol* 2001; **8**: 347-353

27 **Chibaudel B**, Maindrault-Goebel F, Lledo G, Mineur L, André T, Bennamoun M, Mabro M, Artru P, Carola E, Flesch M, Dupuis O, Colin P, Larsen AK, Afchain P, Tournigand C, Louvet C, de Gramont A. Can chemotherapy be discontinued in unresectable metastatic colorectal cancer? The GERCOR OPTIMOX2 Study. *J Clin Oncol* 2009; **27**: 5727-5733

28 **Golfinopoulos V**, Salanti G, Pavlidis N, Ioannidis JP. Survival and disease-progression benefits with treatment regimens for advanced colorectal cancer: a meta-analysis. *Lancet Oncol* 2007; **8**: 898-911

29 NCCN Clinical Practice Guidlines in Oncology. V2 2009. Accessed Apr 28, 2009. Available from: URL: http://www.

nccn.org/professionals/physician_gls/PDF/colon.pdf
30 **Rena O**, Casadio C, Viano F, Cristofori R, Ruffini E, Filosso PL, Maggi G. Pulmonary resection for metastases from colorectal cancer: factors influencing prognosis. Twenty-year experience. *Eur J Cardiothorac Surg* 2002; **21**: 906-912
31 **Saito Y**, Omiya H, Kohno K, Kobayashi T, Itoi K, Teramachi M, Sasaki M, Suzuki H, Takao H, Nakade M. Pulmonary metastasectomy for 165 patients with colorectal carcinoma: A prognostic assessment. *J Thorac Cardiovasc Surg* 2002; **124**: 1007-1013
32 **Sakamoto T**, Tsubota N, Iwanaga K, Yuki T, Matsuoka H, Yoshimura M. Pulmonary resection for metastases from colorectal cancer. *Chest* 2001; **119**: 1069-1072
33 **Shiono S**, Ishii G, Nagai K, Yoshida J, Nishimura M, Murata Y, Tsuta K, Nishiwaki Y, Kodama T, Ochiai A. Histopathologic prognostic factors in resected colorectal lung metastases. *Ann Thorac Surg* 2005; **79**: 278-282; discussion 283
34 **Suh RD**, Wallace AB, Sheehan RE, Heinze SB, Goldin JG. Unresectable pulmonary malignancies: CT-guided percutaneous radiofrequency ablation--preliminary results. *Radiology* 2003; **229**: 821-829
35 **Shah SA**, Haddad R, Al-Sukhni W, Kim RD, Greig PD, Grant DR, Taylor BR, Langer B, Gallinger S, Wei AC. Surgical resection of hepatic and pulmonary metastases from colorectal carcinoma. *J Am Coll Surg* 2006; **202**: 468-475
36 **Yan TD**, King J, Sjarif A, Glenn D, Steinke K, Morris DL. Percutaneous radiofrequency ablation of pulmonary metastases from colorectal carcinoma: prognostic determinants for survival. *Ann Surg Oncol* 2006; **13**: 1529-1537
37 **Vogl TJ**, Lehnert T, Zangos S, Eichler K, Hammerstingl R, Korkusuz H, Lindemayr S. Transpulmonary chemoembolization (TPCE) as a treatment for unresectable lung metastases. *Eur Radiol* 2008; **18**: 2449-2455
38 **Vogl TJ**, Wetter A, Lindemayr S, Zangos S. Treatment of unresectable lung metastases with transpulmonary chemoembolization: preliminary experience. *Radiology* 2005; **234**: 917-922
39 **Lindemayr S**, Lehnert T, Korkusuz H, Hammerstingl R, Vogl TJ. Transpulmonary chemoembolization: a novel approach for the treatment of unresectable lung tumors. *Tech Vasc Interv Radiol* 2007; **10**: 114-119

S- Editor Wang YR **L- Editor** O'Neill M **E- Editor** Lin YP

World Journal of Gastroenterology

Online Submissions: http://www.wjgnet.com/1007-9327office
wjg@wjgnet.com
doi:10.3748/wjg.v16.i26.3325

World J Gastroenterol 2010 July 14; 16(26): 3325-3329
ISSN 1007-9327 (print)
© 2010 Baishideng. All rights reserved.

BRIEF ARTICLE

Relationship between let-7a and gastric mucosa cancerization and its significance

Yi-Min Zhu, Zheng-Xiang Zhong, Zhi-Ming Liu

Yi-Min Zhu, Department of General Surgery, The Second Hospital of Jiaxing, Jiaxing 314000, Zhejiang Province, China
Zheng-Xiang Zhong, Department of General Surgery, The Second Hospital of Jiaxing, Jiaxing 314000, Zhejiang Province, China
Zhi-Ming Liu, Department of General Surgery, The First Affiliated Hospital of Guangxi Medical University, Nanning 530021, Guangxi Zhuang Autonomous Region, China
Author contributions: Zhu YM and Liu ZM planed the study; Zhu YM performed the research and wrote the paper; Zhong ZX revised the manuscript.
Supported by Research Grants from the Key Science and Technology Projects of Guangxi Zhuang Autonomous Region
Correspondence to: Zhi-Ming Liu, Professor, Department of General Surgery, The First Affiliated Hospital of Guangxi Medical University, Nanning 530021, Guangxi Zhuang Autonomous Region, China. zym330422@163.com
Telephone: +86-771-5356738 Fax: +86-771-5356738
Received: January 12, 2010 Revised: April 30, 2010
Accepted: May 7, 2010
Published online: July 14, 2010

Abstract

AIM: To investigate let-7a expression and analyze the correlation between let-7a and progression of gastric mucosa cancerization.

METHODS: The tissue microarray was constructed previously in 52 cases of human gastric carcinoma, 17 cases of chronic atrophic gastritis (atypical hyperplasia) and 11 cases of normal gastric tissue, and tissue microarrays combined with *in situ* hybridization were used to detect the expression of let-7a.

RESULTS: The positive rates of let-7a in normal gastric tissue, chronic atrophic gastritis and gastric carcinoma were 90.9%, 88.2% and 86.5%, respectively, without significant differences among the groups ($P > 0.05$). However, an intense signal of let-7a was observed in gastric epithelial cells, whereas a less intense signal was found in gastric atypical hyperplasia epithelial cells and a weak signal in gastric carcinoma epithelial cells. The expression of let-7a decreased along with the progression of gastric mucosa cancerization ($P < 0.05$). In the group of gastric carcinoma, the expression of let-7a was even significantly lower in gastric carcinomas with lymph node metastasis than in those without metastasis ($P < 0.05$).

CONCLUSION: Gastric carcinoma has relatively lower expression of let-7a. Reduced let-7a may be a fundamental factor in the formation and lymph node metastasis of gastric carcinoma.

© 2010 Baishideng. All rights reserved.

Key words: Tissue microarray; *In situ* hybridization; MicroRNA; Gastric carcinoma; Precancerous lesions

Peer reviewers: Nikolaus Gassler, Professor, Institute of Pathology, University Hospital RWTH Aachen, Pauwelsstrasse 30, 52074 Aachen, Germany; Wei Tang, MD, EngD, Assistant Professor, H-B-P Surgery Division, Artificial Organ and Transplantation Division, Department of Surgery, Graduate School of Medicine, The University of Tokyo, Tokyo 113-8655, Japan

Zhu YM, Zhong ZX, Liu ZM. Relationship between let-7a and gastric mucosa cancerization and its significance. *World J Gastroenterol* 2010; 16(26): 3325-3329 Available from: URL: http://www.wjgnet.com/1007-9327/full/v16/i26/3325.htm DOI: http://dx.doi.org/10.3748/wjg.v16.i26.3325

INTRODUCTION

MicroRNAs (miRNAs) are a recently discovered class of short noncoding RNA genes that act post-transcriptionally as negative regulators of gene expression[1,2]. A large body of research shows that animal miRNAs play a fundamental role in many biological processes, including cell growth and apoptosis, hematopoietic lineage differentiation, insulin secretion, brain morphogenesis, and muscle

cell proliferation and differentiation[3]. About 1000 miRNA genes are thought to be encoded in the human genome[4,5]. Although it is still difficult to identify accurately individual miRNA/target interactions[6], computational predictions of miRNA target genes indicate that as many as one-third of all human protein-encoding genes may be regulated by miRNAs[7]. This suggests that miRNAs could be involved in a wide variety of human diseases, including cancer. As a result of in-depth researches over the last 5 years, miRNA-mediated regulation of tumorigenesis is emerging as a new paradigm in the field of cancer biology[8,9]. It has also been reported that these miRNA signatures may be a more robust tool than expression patterns of protein-encoding genes for distinguishing normal from tumor tissues[10,11]. One particular miRNA, let-7, was discovered in the early 1990s in humans and mice. It has been reported that let-7 as a novel candidate of tumor suppressor gene is involved in several cancers such as lung carcinoma and colon carcinoma.

Gastric carcinoma is one of the most frequent cancers and one of the most common causes of cancer-related mortality in China, with an incidence of 0.4 million new cases and 0.3 million deaths annually. Gastric carcinoma is also an inadequately understood, and often fatal disease when not detected at early stages. Atypical hyperplasia is generally accepted as a precancerous lesion. Cancerization from normal gastric mucosa, chronic atrophic gastritis to gastric carcinoma has been well acknowledged. In this study, the expression of let-7a in normal gastric tissue, chronic atrophic gastritis (atypical hyperplasia) and gastric carcinoma was detected by *in situ* hybridization (ISH) using a locked nucleic acid (LNA) probe and gastric mucosa cancerizing tissue microarrays; the relation between expression level of let-7a and the progression of gastric mucosa cancerization was discussed.

MATERIALS AND METHODS

Tissue microarray and probe

The tissue bank at Shanxi Chaoying Biotechnology Company maintains a series of formalin-fixed, paraffin-embedded (FFPE) tissue blocks of patients with gastric carcinoma, chronic atrophic gastritis (atypical hyperplasia) and normal gastric tissue. Information on tumor histologic grade, patient's age and sex was collected and anonymized in a secure database. We generated a tissue microarray (TMA) from archived FFPE blocks of 80 cases, including 11 cases of normal gastric tissue, 17 cases of chronic atrophic gastritis with atypical hyperplasia (incomplete intestinal metaplasia) and 52 cases of gastric carcinoma (intestinal type). In the gastric carcinoma group, there were 10 cases with lymph node metastasis and 42 cases without lymph node metastasis. This study complied with the rules and regulations of the Ethics Committee of the hospital. Informed consent was obtained from all subjects. All FFPE blocks were reviewed and tissue cores were selected by a board-certified pathologist. The 5'Digoxin-labeled, LNA-modified oligonucleotide probe (sequence 5'-3': aactatacaacctactacctca) complementary to the entire mature sequence of let-7a, was synthesized by Exiqon DNA technologies.

Detection of miRNAs by ISH in FFPE sections

The experiment was conducted at a laboratory of Shanxi Chaoying Biotechnology Company in November 2009. Sections (5 μm) of archived paraffin-embedded specimens were deparaffinized in xylenes and then rehydrated through an ethanol dilution series (from 100% to 25%). Slides were submerged in diethyl pyrocarbonate-treated water and subjected to proteinase K digestion (5-10 μg/mL) and 0.2% glycine treatment, refixed in 4% paraformaldehyde, and treated with acetylation solution [66 mmol/L HCl, 0.66% (v/v) acetic anhydride, and 1.5% (v/v) triethanolamine]; slides were rinsed thrice with 1 × PBS between the treatment. Slides were prehybridized in hybridization solution (50% formamide, 5 × SSC, 500 Ag/mL yeast tRNA, and 1 × Denhardt's solution) at 50℃ for 30 min. Then 5-10 pmol of Digoxin-labeled, LNA-modified probe, was added to 150 μL hybridization solution and hybridized for 18 h at a temperature of 42℃ below the calculated Tm of the LNA probe. Subsequently, the samples were incubated at 37℃ for 90 min with 50 μL biotin-labeled anti-digoxin antibody, rinsed with 0.5 × SSC four times for 5 min, incubated at 37℃ for 30 min with 50 μL SABC solution, and rinsed with 0.5 × SSC solution three times for 5 min. After added 50 μL biotin-labeled peroxidase and incubated at 37℃ for 30 min, the samples were rinsed five times with 0.5 × SSC for 5 min, then stained with Nitro-Blue-Tetrazolium/5-bromo-4-chloro-3-indolyl-phosphate. Finally, the sections were restained with eosin before covering. For a negative control, the hybridization solution was replaced with pre-hybridization solution. Likewise, β-actin was used as the probe of positive control.

Determination of results

Signals were visually quantified by a pathologist according to the reference of Frantz *et al*[12]. A total of 100 × 10 cells were counted randomly. Then, tissue sections were blindly examined by a second individual for an agreement with the initial quantifications. If there was no positive cell, the sample was scored as 0 point. If the percentage of positive cells was less than or equal to 30%, the sample was scored as 1 point; less than or equal to 70% as 2 points; and more than 70% as 3 points. The staining intensity was recorded as negative, light, moderate, or strong, and scored as 0, 1, 2 or 3 points, respectively. The two values were multiplied, and a sum of 0 point represented negative expression, and 1-9 points represented positive expression. Points 1-2 were marked ±, 3-4 marked +, 6 marked ++, and 9 marked +++.

Statistical analysis

Statistical analysis was performed using SPSS 11.5 Package. The χ^2 and correlation tests were used in this study. A difference was considered significant when *P* value was less than 0.05.

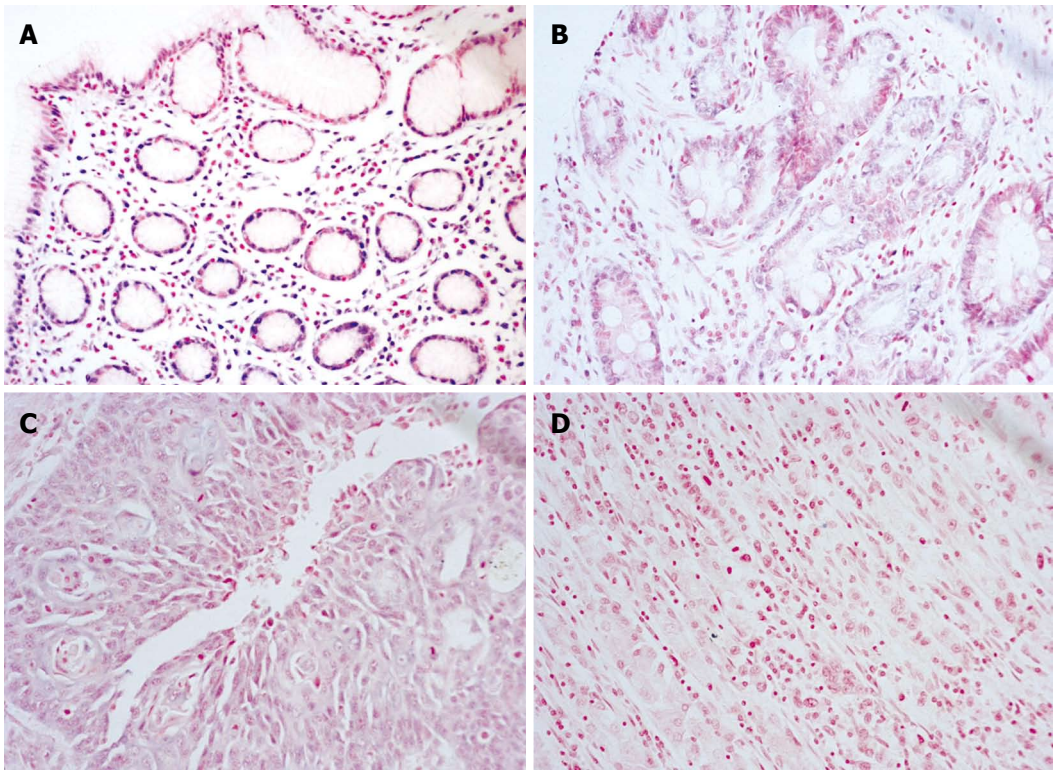

Figure 1 Expression let-7a in stomach cancer progression tissue array (*in situ* hybridization, Nitro-Blue-Tetrazolium/5-bromo-4-chloro-3-indolyl-phosphate staining, original magnification × 200). A: Positive expression (++) of let-7a in gastric tissue; B: Positive expression (+) of let-7a in chronic atrophic gastritis; C: Positive expression (±) of let-7a in gastric carcinoma; D: Negative expression of let-7a in gastric carcinoma.

Table 1 Expression of let-7a in gastric mucosa cancerization tissue array

	Cases (*n*)	Results					Positive rate (%)
		-	±	+	++	+++	
Normal gastric mucosa	11	1	0	2	8	0	90.9
Chronic atrophic gastritis	17	2	2	7	5	1	88.2
Gastric carcinoma	52	7	18	18	7	2	86.5

Table 2 Expression of let-7a in gastric carcinomas

Lymph node metastasis	Cases (*n*)	Results					*P* value
		-	±	+	++	+++	0.043
Negative	42	4	11	18	7	2	
Positive	10	3	6	1	0	0	

RESULTS

Expression of let-7a was determined on 5-μm sections obtained from each of the TMA blocks. Generally, let-7a appeared as blue-purple particles in the cytoplasm or nucleus after staining, and predominantly expressed in normal gastric mucosa epithelia and its expression was down-regulated in atypical hyperplasia epithelia, especially in malignant cells. The let-7a probe revealed an intense cytoplasmic signal in gastric epithelial cells, whereas a less intense signal was observed in gastric atypical hyperplasia epithelial cells and a weak signal in gastric carcinoma epithelial cells (Figure 1). Let-7a was also detected in endothelial cells lining blood vessels and in fibroblasts (data not shown). The classification of let-7a expression grade in each group is shown in Table 1. There was no significant difference in the positive rates of let-7a among gastric carcinoma, chronic atrophic gastritis and normal gastric tissues ($P > 0.05$). However, by analysis of the signal levels of let-7a in each group, the levels of let-7a expression were reversely related to the progression of gastric mucosa cancerization ($P = 0.008$). The expression of let-7a decreased along with the progression of gastric mucosa cancerization. In the gastric carcinoma group, the expression of let-7a in the 10 cases with lymph node metastasis was even lower than in the 42 cases without lymph node metastasis ($P = 0.043$) as shown in Table 2. In this study, β-actin showed an intense cytoplasmic signal in each of the TMA blocks in positive control while no blue-purple staining was found in blocks of negative control.

DISCUSSION

The let-7 family consists of 12 genes encoding for nine distinct miRNAs (let-7a to let-7i). Historically, let-7 was found to bind to the 3' UTR of lin-41 and hbl-1 (lin-57)

to inhibit their translation in nematodes[13], and control the developmental transition from the L4 stage into the adult stage[14-16]. An evolutionarily conserved regulation of the RAS family of growth control proteins by let-7 from nematodes to human cancer cells has also been demonstrated. Recently, let-7 implication in cancerogenesis has been extended to the repression of high mobility group A2, thus preventing oncogenic transformation in many tumors[17]. Johnson *et al*[18] showed that let-7 miRNA expression was lower in lung tumors than in normal lung tissues. The detection of mature miRNAs by ISH is technically challenging because of their small size. LNAs are a class of bicyclic high-affinity RNA analogues, in which the furanose ring in the sugar-phosphate backbone is chemically locked in a conformation mimicking the North-type (C3'-endo) conformation of RNA[19,20]. This results in an unprecedented hybridization affinity of LNA toward complementary single-stranded RNA molecules. A limitation to identifying and validating potential biomarkers makes it difficult to conduct retrospective studies with archived tumor specimens due in part to protein and RNA degradation[21]. Hence, the very small size of miRNAs offers a unique advantage because short RNA molecules are substantially less susceptible than mRNAs to enzymatic and mechanical degradation. In this study, we used a method for detection of miRNAs in gastric carcinoma specimens, LNA-ISH, which offers a spatial resolution of miRNA expression unsurpassed by other available techniques. Zhang *at al*[22] established an accurate and rapid stem-loop reverse transcriptional real-time PCR (RT-PCR) method to quantify human let-7a miRNA in gastric cancer. It was found that the expression level of let-7a miRNA in gastric tumor tissues was significantly lower than in normal tissues of 14 samples from 32 patients. There might be a discordance between ISH and RT-PCR results, which could be explained by the overrepresentation of epithelial cells in tumor lesions, resulting in a high let-7 signal in gross tissue biopsies. However, let-7a expression is diminished within individual cancer cells, which can be determined only by the ISH approach. We noticed that long fixation periods in 10% formalin (more than 12-18 h) can affect negatively the intensity of the miRNA *in situ* signal. There is no significant difference of the positive rates of let-7a expression among gastric carcinoma, chronic atrophic gastritis and normal gastric tissue, which may be partly due to the limitation of normal gastric tissue cases in the TMA. Decrease of let-7a expression is already apparent in hyperplasia (possibly preneoplastic). Its further decrease in gastric carcinoma is reminiscent of reduction of let-7a related to the gastric mucosa cancerization progression. Hence, this suggests that reduction of let-7a is an early event during intestinal-type gastric carcinoma formation. The most essential behavior of the malignant tumor is metastasis. Lymph nodes metastasis is an important index for clinical stages of gastric carcinoma before surgery and it is also an important prognosis factor for gastric carcinoma patients. Our study showed that the expression of let-7a was even lower in gastric carcinoma with lymph nodes metastasis than in those without lymph nodes metastasis. Decreased expression or absence of let-7a may determine initially the occurrence, development, metastasis and prognosis of gastric carcinoma. Using combined LNA-ISH and RT-PCR, quantitative detection of let-7a may have a potential clinical application as a novel biomarker for early diagnosis and prognosis of gastric carcinoma. Infecting breast tumor-initiating cells with let-7-lentivirus reduced proliferation, mammosphere formation, and the proportion of undifferentiated cells *in vitro* and tumor formation and metastasis in NOD/SCID mice[23]. Thus, the reason why let-7a in human gastric carcinoma has generated great interest is that it not only has a potency in diagnosis, but also can shed light on the molecular mechanisms of the tumorigenic process and has a high potential as novel targets for therapeutic intervention using synthetic oligonucleotide technologies. Further studies are being carried out on the relationship between gastric carcinoma and let-7a in our laboratory.

COMMENTS

Background

Gastric carcinoma is one of the malignancies with highest incidence and mortality rates and it is of great significance to investigate the mechanisms behind the occurrence and development of gastric carcinoma. Down-regulated expression let-7a has been shown to play an important role in the tumorigenesis and cancer progression. Therefore, the exploration into the expression of let-7a in gastric carcinoma and precancerous lesions may shed a new light on early detection and therapy of gastric carcinoma.

Research frontiers

Let-7a has been shown to exert tumor suppressor gene effects in various human neoplasms. In this study, the author investigated the expression of let-7a in normal gastric mucosa, chronic atrophic gastritis and gastric carcinoma to explore its correlation with gastric carcinogenesis and metastasis. They found that reduced expression of let-7a may take part in early carcinogenesis and metastasis of gastric carcinoma.

Innovations and breakthroughs

Let-7a is down-regulated in a wide range of human cancers such as gastric, colorectal and breast carcinomas, and may play a key role in cancer pathogenesis. Down-regulated let-7a increases cancer cell proliferation, migration and invasion. This is the first study to report that expression of let-7a has a reverse correlation with gastric cancerization.

Applications

The expression level of let-7a was significantly lower in gastric carcinoma than in chronic atrophic gastritis and normal gastric mucosa. In the malignant tumor group, the expression level of let-7a was even significantly lower in gastric carcinoma with lymph node metastasis than in those without metastasis. Detection of let-7a expression might be helpful in early detection and prognosis judgment of gastric carcinoma patients. In addition, let-7a may serve as a potential therapeutic tool for gastric carcinoma.

Peer review

In this descriptive study, let-7a miRNA expression is analyzed in human gastric mucosa, chronic atrophic gastritis, and gastric cancer with *in situ* hybridization technique on tissue microarray. The study confirms the results by Zhang *et al* demonstrating a decrease of let-7a in gastric carcinogenesis.

REFERENCES

1 **Ambros V**. The functions of animal microRNAs. *Nature* 2004; **431**: 350-355

2 **Bartel DP**, Chen CZ. Micromanagers of gene expression: the potentially widespread influence of metazoan microRNAs. *Nat Rev Genet* 2004; **5**: 396-400

3 **Kloosterman WP**, Plasterk RH. The diverse functions of mi-

croRNAs in animal development and disease. *Dev Cell* 2006; **11**: 441-450
4 **Bentwich I**, Avniel A, Karov Y, Aharonov R, Gilad S, Barad O, Barzilai A, Einat P, Einav U, Meiri E, Sharon E, Spector Y, Bentwich Z. Identification of hundreds of conserved and non-conserved human microRNAs. *Nat Genet* 2005; **37**: 766-770
5 **Berezikov E**, van Tetering G, Verheul M, van de Belt J, van Laake L, Vos J, Verloop R, van de Wetering M, Guryev V, Takada S, van Zonneveld AJ, Mano H, Plasterk R, Cuppen E. Many novel mammalian microRNA candidates identified by extensive cloning and RAKE analysis. *Genome Res* 2006; **16**: 1289-1298
6 **Didiano D**, Hobert O. Perfect seed pairing is not a generally reliable predictor for miRNA-target interactions. *Nat Struct Mol Biol* 2006; **13**: 849-851
7 **Lewis BP**, Burge CB, Bartel DP. Conserved seed pairing, often flanked by adenosines, indicates that thousands of human genes are microRNA targets. *Cell* 2005; **120**: 15-20
8 **Zhang B**, Pan X, Cobb GP, Anderson TA. microRNAs as oncogenes and tumor suppressors. *Dev Biol* 2007; **302**: 1-12
9 **Calin GA**, Croce CM. MicroRNA signatures in human cancers. *Nat Rev Cancer* 2006; **6**: 857-866
10 **Volinia S**, Calin GA, Liu CG, Ambs S, Cimmino A, Petrocca F, Visone R, Iorio M, Roldo C, Ferracin M, Prueitt RL, Yanaihara N, Lanza G, Scarpa A, Vecchione A, Negrini M, Harris CC, Croce CM. A microRNA expression signature of human solid tumors defines cancer gene targets. *Proc Natl Acad Sci USA* 2006; **103**: 2257-2261
11 **Lu J**, Getz G, Miska EA, Alvarez-Saavedra E, Lamb J, Peck D, Sweet-Cordero A, Ebert BL, Mak RH, Ferrando AA, Downing JR, Jacks T, Horvitz HR, Golub TR. MicroRNA expression profiles classify human cancers. *Nature* 2005; **435**: 834-838
12 **Frantz GD**, Pham TQ, Peale FV Jr, Hillan KJ. Detection of novel gene expression in paraffin-embedded tissues by isotopic in situ hybridization in tissue microarrays. *J Pathol* 2001; **195**: 87-96
13 **Jérôme T**, Laurie P, Louis B, Pierre C. Enjoy the Silence: The Story of let-7 MicroRNA and Cancer. *Curr Genomics* 2007; **8**: 229-233
14 **Reinhart BJ**, Slack FJ, Basson M, Pasquinelli AE, Bettinger JC, Rougvie AE, Horvitz HR, Ruvkun G. The 21-nucleotide let-7 RNA regulates developmental timing in Caenorhabditis elegans. *Nature* 2000; **403**: 901-906
15 **Abrahante JE**, Daul AL, Li M, Volk ML, Tennessen JM, Miller EA, Rougvie AE. The Caenorhabditis elegans hunchback-like gene lin-57/hbl-1 controls developmental time and is regulated by microRNAs. *Dev Cell* 2003; **4**: 625-637
16 **Lin SY**, Johnson SM, Abraham M, Vella MC, Pasquinelli A, Gamberi C, Gottlieb E, Slack FJ. The C elegans hunchback homolog, hbl-1, controls temporal patterning and is a probable microRNA target. *Dev Cell* 2003; **4**: 639-650
17 **Mayr C**, Hemann MT, Bartel DP. Disrupting the pairing between let-7 and Hmga2 enhances oncogenic transformation. *Science* 2007; **315**: 1576-1579
18 **Johnson SM**, Grosshans H, Shingara J, Byrom M, Jarvis R, Cheng A, Labourier E, Reinert KL, Brown D, Slack FJ. RAS is regulated by the let-7 microRNA family. *Cell* 2005; **120**: 635-647
19 **Kauppinen S**, Vester B, Wengel J. Locked nucleic acid: high-affinity targeting of complementary RNA for RNomics. *Handb Exp Pharmacol* 2006; 405-422
20 **Koshkin AA**, Wengel J. Synthesis of Novel 2′,3′-Linked Bicyclic Thymine Ribonucleosides. *J Org Chem* 1998; **63**: 2778-2781
21 **Ludwig JA**, Weinstein JN. Biomarkers in cancer staging, prognosis and treatment selection. *Nat Rev Cancer* 2005; **5**: 845-856
22 **Zhang HH**, Wang XJ, Li GX, Yang E, Yang NM. Detection of let-7a microRNA by real-time PCR in gastric carcinoma. *World J Gastroenterol* 2007; **13**: 2883-2888
23 **Yu F**, Yao H, Zhu P, Zhang X, Pan Q, Gong C, Huang Y, Hu X, Su F, Lieberman J, Song E. let-7 regulates self renewal and tumorigenicity of breast cancer cells. *Cell* 2007; **131**: 1109-1123

S- Editor Tian L **L- Editor** Ma JY **E- Editor** Ma WH

World Journal of Gastroenterology

Online Submissions: http://www.wjgnet.com/1007-9327office
wjg@wjgnet.com
doi:10.3748/wjg.v16.i26.3330

World J Gastroenterol 2010 July 14; 16(26): 3330-3334
ISSN 1007-9327 (print)
© 2010 Baishideng. All rights reserved.

BRIEF ARTICLE

Paclitaxel ameliorates fibrosis in hepatic stellate cells *via* inhibition of TGF-β/Smad activity

Jun Zhou, De-Wu Zhong, Qun-Wei Wang, Xiong-Ying Miao, Xun-Di Xu

Jun Zhou, De-Wu Zhong, Qun-Wei Wang, Xiong-Ying Miao, Xun-Di Xu, Department of Hepatobiliary Surgery, Second Xiangya Hospital, Central South University, Changsha 410011, Hunan Province, China
Author contributions: Zhou J did most of the experiments and data acquisition; Wang QW, Miao XY and Xu XD were involved in initial experiments in this paper; Zhou J and Zhong DW participated actively in the design of experiments, interpretation of data, and preparation of the manuscript.
Supported by Grants from the Creative Research Group Fund of the National Foundation Committee of Natural Science of China, No. 30871169/C140405
Correspondence to: De-Wu Zhong, MD, Department of Hepatobiliary Surgery, Second Xiangya Hospital, Central South University, Changsha 410011, Hunan Province, China. wangqiner2004@163.com
Telephone: +86-731-84897389 Fax: +86-731-84454382
Received: January 29, 2010 Revised: March 9, 2010
Accepted: March 16, 2010
Published online: July 14, 2010

Abstract

AIM: To investigated if paclitaxel can attenuate hepatic fibrosis in rat hepatic stellate cells (RHSCs).

METHODS: RHSCs were cultured *in vitro* and randomly assigned to four groups: normal control group (treated only with Dulbecco's Modified Eagle's Medium), Taxol group (200 nmol/L paclitaxel was added to the cell culture), transforming growth factor (TGF)-β group (5 ng/mL recombinant human TGF-β1 was added to the cell culture), and TGF-β + Taxol group. TGF-β signaling cascade and status of various extracellular matrix proteins were evaluated by real time reverse transcriptase polymerase chain reaction and Western blotting.

RESULTS: The paclitaxel treatment markedly suppressed Smad2/3 phosphorylation. This was associated with attenuated expression of collagen Ⅰ and Ⅲ and fibronectin in RHSCs.

CONCLUSION: These data indicate that 200 nmol/L paclitaxel ameliorates hepatic fibrosis *via* modulating TGF-β signaling, and that paclitaxel may have some therapeutic value in humans with hepatic fibrosis.

© 2010 Baishideng. All rights reserved.

Key words: Transforming growth factor-β; Hepatic fibrosis; Paclitaxel; Smad; Microtubules

Peer reviewer: Dariusz M Lebensztejn, Associate Professor, IIIrd Department of Pediatrics, Medical University of Bialystok, 17 Waszyngtona Str., Bialystok, 15-247, Poland

Zhou J, Zhong DW, Wang QW, Miao XY, Xu XD. Paclitaxel ameliorates fibrosis in hepatic stellate cells *via* inhibition of TGF-β/Smad activity. *World J Gastroenterol* 2010; 16(26): 3330-3334 Available from: URL: http://www.wjgnet.com/1007-9327/full/v16/i26/3330.htm DOI: http://dx.doi.org/10.3748/wjg.v16.i26.3330

INTRODUCTION

Hepatic fibrosis is the key stage in the pathological process from hepatic injury to cirrhosis or even to tumor. Transforming growth factor (TGF)-β1 is widely acknowledged as a key factor in acceleration of the hepatic fibrosis process. TGF-β1 mainly activates hepatic stellate cells (HSCs) through the TGF-β1/Smad signaling pathway, thus causing hepatic fibrosis[1-5]. TGF-β evokes diverse cellular responses by binding to and activating specific cell-surface receptors that have intrinsic serine/threonine kinase activity. The activated TGF-β receptors stimulate the phosphorylation of receptor-regulated Smad2 and Smad3 proteins (R-Smads), which in turn form complexes with Smad4. This complex translocates from the cytoplasm into the nucleus, where the Smads regulate the transcription of target genes. Inhibitory Smad7 acts in an opposing manner to the R-Smads, and downregulates TGF-β signaling[6].

Some studies have previously demonstrated that endogenous Smad-2, 3 and 4 bind to microtubules in several cell lines, and the binding provides a negative regulatory mechanism to modulate TGF-β activity. Disruption of the microtubule network by chemical agents, such as nocodazole and colchicine, leads to ligand-independent Smad nuclear accumulation and transcription of TGF-β-responsive genes, which in turn increases TGF-β-induced Smad activity[7].

The aim of this study was to assess if microtubule stabilization with low-dose paclitaxel (Taxol) could inhibit TGF-β/Smad signaling and ameliorate hepatic fibrosis in HSCs.

MATERIALS AND METHODS

Cell culture and grouping

HSCs (supplied by the Institute of Liver Diseases, the Second Xiangya Hospital, Hunan, China) were seeded in 24-hole plastic culture plates with a density of 1×10^6/mL. The cell viability was > 95% and purity was > 90%. After cell culture for 2 wk, nearly all HSCs were activated. These cells were first cultured for 3 d, followed by a cell cycle of synchronous culture for 48 h, then the HSCs were randomly divided into four groups: normal control group (treated only with Dulbecco's Modified Eagle's Medium), normal + Taxol group [200 nmol/L paclitaxel (Taxol; Sigma, St. Louis, MO, USA) was added to the cell culture], TGF-β group [5 ng/mL recombinant human TGF-β1 (R&D Systems, Minneapolis, MN, USA) was added to the cell culture], and TGF-β + Taxol group. The examinations were carried out after 48 h of culture. All the examinations were repeated three times for accuracy and consistency.

Real-time reverse transcriptase polymerase chain reaction

Total RNA was isolated using the High Pure RNA Isolation Kit according to the manufacturer's instructions (Roche, Switzerland). Contaminated DNA was removed by treating the samples with RNase-free DNase I (Promega, Madison, WI, USA). Real-time polymerase chain reaction (PCR) was performed using Bio-Rad (Hercules, CA, USA) iQ SYBR Green supermix with Opticon (MJ Research Inc., Waltham, MA, USA) by following the vendor's instructions. One hundred micrograms of total RNA was reverse-transcribed and subjected to PCR as follows: 94℃ for 2 min followed by 40 cycles of: 94℃ for 15 s, 58℃ for 30 s and 72℃ for 30 s, and a final extension at 72℃ for 10 min. The primers used were as follows. Rat Smad2, forward: 5'-TCACAGCCATCATGAGCTCAAGG-3', reverse: 5'-TGTGACGCATGGAAGGTCTCTC-3'; Smad3, forward: 5'-AGCACACAATAACTTGGACC-3', reverse: 5'-TAAGACACACTGGAACAGCGGATG-3'; collagen Ⅰ, forward: 5'-GAGCGGAGAGTACTGGATCG-3', reverse: 5'-TACTCGAACGGGAATCCATC-3'; collagen Ⅲ, forward: 5'-GTGCGGTTTGTGAAGCACCG-3', reverse: 5'-GTTCTTCTCATGCACACTT-3'; fibronectin, forward: 5'-TGACTCGCTTTGACTTCACCAC-3', reverse: 5'-TCTCCTTCCTCGCTCAGTTCGT-3'. All samples were subjected to reverse transcriptase (RT)-PCR along with the housekeeping gene GAPDH with the following primer sequences: forward: 5'-TGCTGAGTATGTCGTGGAGTCTA-3', reverse: 5'-AGTGGGAGTTGCTGTTGAAATC-3' as an internal standard. Reaction specificity was confirmed by gel electrophoresis of products after real-time PCR and melting curve analysis. Ratios for Smad2/GAPDH, Smad3/GAPDH, collagen Ⅲ/GAPDH, fibronectin/GAPDH and collagen Ⅰ/GAPDH mRNA were calculated for each sample and expressed as the mean ± SD.

Western blotting

Total protein was extracted from cells and analyzed with bicinchoninic acid protein concentration assay kit (Beijing Biosea Biotechnology Co. Ltd., China). Samples (20 μg) were fractionated by SDS-PAGE. After transfer onto nitrocellulose membrane (Amersham International, Bucks, UK), the blots were probed with a mouse monoclonal antibody to p-Smad3 (Cell Signaling Technology, Beverly, MA, USA 1:1000 dilution), a goat polyclonal antibody to p-Smad2 (Upstate Biotechnology, Billerica, MA, USA 1:1000 dilution) and rabbit polyclonal antibodies to collagen Ⅰ (Santa Cruz Biotechnology, Santa Cruz, CA, USA, 1:2000 dilution), collagen Ⅲ (Abcam, Cambridge, MA, USA 1:2000 dilution), and fibronectin (Santa Cruz Biotechnology, 1:1000 dilution). The second antibodies were peroxidase-conjugated goat anti-mouse IgG (1:20000 dilution)and the swine anti-rabbit IgG or rabbit anti-goat IgG , which be diluited in PBS that contained 1% normal goat serum or 1% fetal calf serum. β-actin was used as an internal control.

Statistical analysis

Data were calculated as the mean ± SD and the groups were compared using one-way ANOVA. Statistical significance was set at $P < 0.05$.

RESULTS

Paclitaxel inhibits extracellular matrix expression in rat HSCs

The suppressive effects of paclitaxel on mRNA and protein expression of fibronectin and collagen Ⅰ and Ⅲ were assessed by real-time RT-PCR and Western blotting. Figure 1A shows RT-PCR analysis that indicated that paclitaxel had no effect on basal mRNA expression for fibronectin and collagen Ⅰ and Ⅲ in rat HSCs. The expression of integrin-linked kinase, α-smooth muscle actin and collagen Ⅰ was reduced in cells treated with paclitaxel and TGF-β at 48 h ($P < 0.01$). Western blotting analyses revealed similar trends in mRNA expression ($P < 0.05$, $n = 6$) (Figure 2A).

Blockade of Smad2/3 activation is a key mechanism by which paclitaxel prevents hepatic fibrosis in rat HSCs

The effects of paclitaxel on expression of Smad2 and Smad3 mRNA were assessed by real-time RT-PCR. The analysis showed that paclitaxel had no effect on Smad2

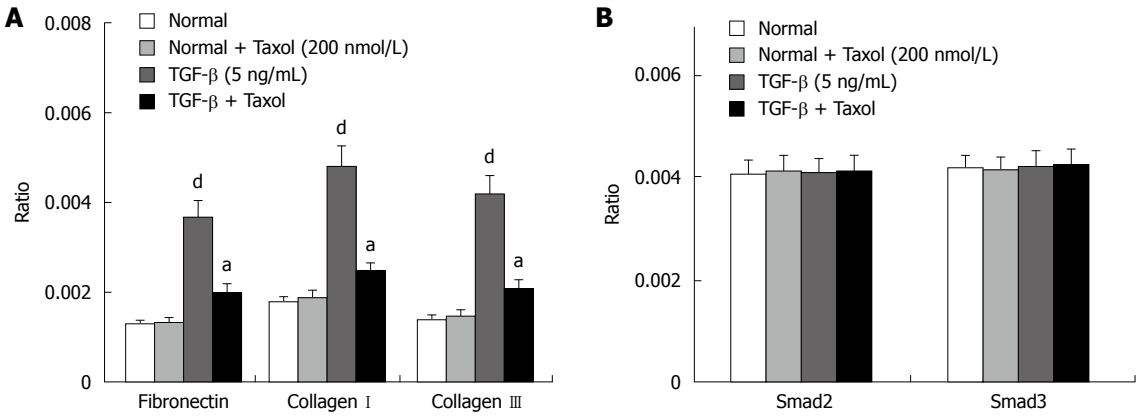

Figure 1 The mRNA levels changes *in vitro* after treatment. A: Real-time PCR depicting fibronectin and collagen Ⅰ and Ⅲ mRNA expression *in vitro* following paclitaxel treatment of hepatic stellate cells (HSCs). Fibronectin and collagen Ⅰ and Ⅲ expression was significantly higher in the TGF-β group at 48 h compared with the normal or Taxol groups ($P < 0.05$, $n = 6$). Treatment with paclitaxel resulted in a decrease in fibronection and collagen Ⅰ and Ⅲ expression ($P < 0.05$, $n = 6$). $^{a}P < 0.05$ *vs* TGF-β group; $^{d}P < 0.01$ *vs* normal or Taxol group ($n = 6$); B: Real-time PCR showing Smad2 (left) and Smad3 (right) mRNA expression *in vitro* following treatment with paclitaxel in HSCs. Smad2 and Smad3 mRNA expression was more or less similar in the normal and Taxol groups at 48 h ($P < 0.05$, $n = 6$). Densitometric analyses were performed from six independent experiments. Each bar represents the mean ± SD for six animals. PCR: Polymerase chain reaction; TGF-β: Transforming growth factor β.

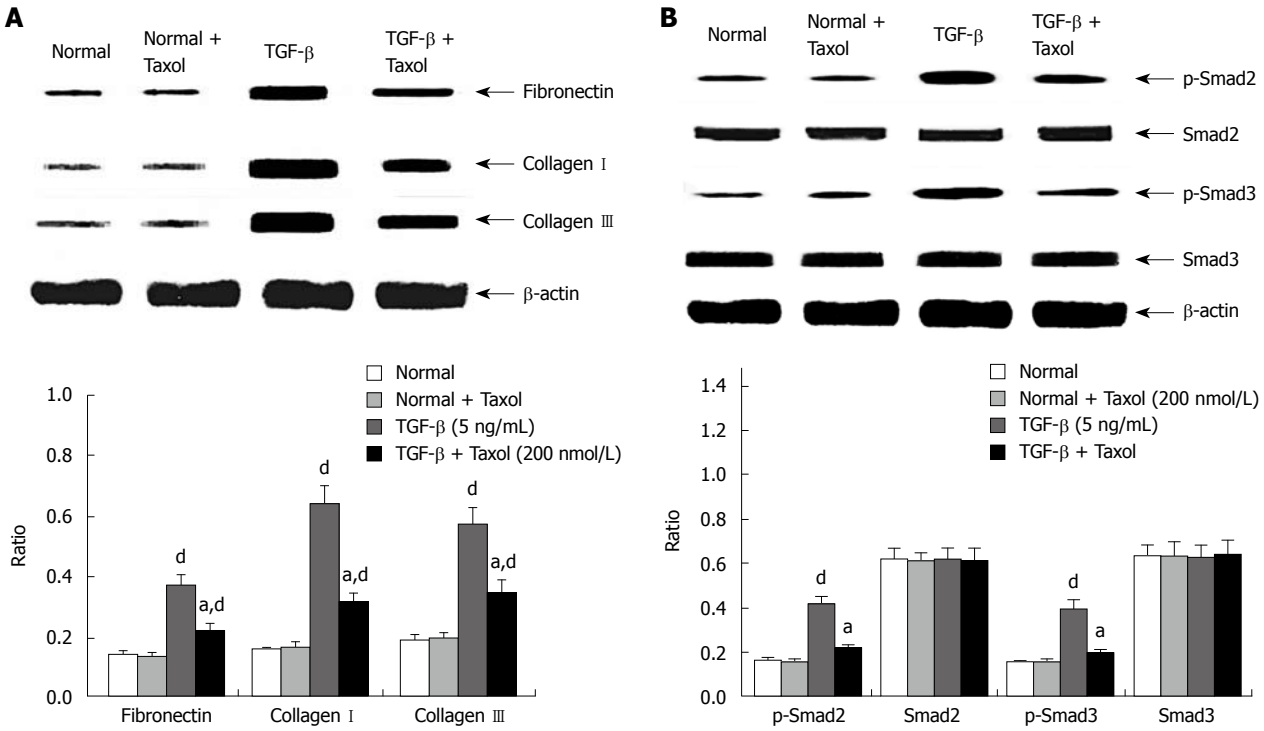

Figure 2 The protein levels changes *in vitro* after treatment. A: Western blotting analyses depicting fibronectin and collagen Ⅰ and Ⅲ mRNA expression *in vitro* following paclitaxel treatment in HSCs. Whole hepatic cell extracts were immunoblotted with the indicated antibodies. Fibronectin and collagen Ⅰ and Ⅲ expression was significantly higher in the TGF-β group at 48 h compared with the normal or Taxol group ($P < 0.05$, $n = 6$). Treatment with paclitaxel resulted in a decrease in fibronectin and collagen Ⅰ and Ⅲ expression ($P < 0.05$, $n = 6$); B: Western blotting analysis showing Smad2/3 protein expression *in vitro* following treatment with paclitaxel in HSCs. Phosphorylated Smad2 and Smad3 but not total Smad2 or Smad3 expression was significantly higher in the TGF-β group at 48 h compared with the normal or Taxol group ($P < 0.05$, $n = 6$). Treatment with paclitaxel resulted in a decrease in phosphorylation of Smad2 and Smad3 ($P < 0.05$, $n = 6$). Densitometric analyses were performed from six independent experiments. Each bar represents the mean ± SD for six animals. $^{a}P < 0.05$ *vs* TGF-β group; $^{d}P < 0.01$ *vs* normal or Taxol group ($n = 6$).

and Smad3 mRNA expression in the normal, Taxol and TGF-β + Taxol groups at 48 h (Figure 1B). Western blotting analysis showed that phosphorylated Smad2/3 but not total Smad2/3 expression was markedly reduced in HSCs treated with paclitaxel and TGF-β at 48 h ($P < 0.01$). In contrast, paclitaxel had no effect on expression and phosphorylation of Smad2/3 in the Taxol group (Figure 2B).

DISCUSSION

In the present study, we observed that fibrosis in HSCs was substantially decreased by paclitaxel, a microtubule-stabilizing agent, thus suggesting that low-dose paclitaxel has therapeutic benefits in the amelioration of hepatic fibrosis.

The TGF-β/Smad signaling pathway plays an impor-

tant role in hepatic fibrosis. In chronic hepatic injury, after HSCs are transformed into myofibroblasts, Smad2 and Smad3 are continuously phosphorylated and the inhibitory expression of Smad7 is at a low level. As a result, TGF-β1 signal transduction cannot be effectively inhibited. This might be one of the mechanisms for progression from chronic hepatic injury to hepatic fibrosis[8,9]. The worse the hepatic fibrosis and the higher the expression of TGF-β1, the higher is the Smad3 protein expression. Therefore, whatever is transferred by Smad3 might be the signal that can induce hepatic fibrosis[10-12]. Currently, TGF-β1 is the most effective fibrosis-promoting known, and it can promote activation of HSCs, and increase synthesis of extracellular matrix (ECM)[4,5]. Furthermore, it has been previously shown in several different cell lines that microtubules serve as a negative regulator for TGF-β/Smad signaling by forming a complex with endogenous Smad2, 3 and 4, thus sequestering the R-Smads away from the TGF-β receptor[7]. Therefore, it is conceivable that stabilization of microtubules by low-dose paclitaxel can dampen the exacerbated TGF-β signaling, as reported in TGF-β-induced inhibition of myogenesis in C2C12 myoblasts[13]. Similarly, in an earlier study, Liu *et al*[14] also have found that paclitaxel can significantly suppress TGF-β/Smad activity in SCID mice. In the present study, we provided evidence that low-dose paclitaxel suppressed phosphorylation of Smad2 and Smad3, two homologous Smad proteins that transduce signals from TGF-β and activin, in rat HSCs. These data support the notion that TGF-β/Smad signaling is regulated by the dynamic stability/instability of microtubules that are sensitive to low-dose microtubule-stabilizing agents, like paclitaxel.

Paclitaxel is an anticancer agent[15], which by stabilizing polymerized microtubules and enhancing microtubule assembly, arrests the cell cycle in the G0/G1 and G2/M phases, thus leading to cell death[16,17]. Prolonged treatment with paclitaxel has been associated with scleroderma-like changes or pulmonary fibrosis, albeit in only a small fraction of patients. It is noteworthy that inhibition of tumor cell proliferation can be achieved by much higher doses of paclitaxel. The inhibition of TGF-β/Smad signaling, however, can be attained with very low doses of paclitaxel. However, some of the recent studies have indicated that low-dose paclitaxel has minimal, if any, detectable effects on cell proliferation and other cellular activities, including fibrosis. Intriguingly, low-dose paclitaxel has been shown to inhibit collagen-induced arthritis and fibrosis associated with systemic sclerosis in SCID mice[14,18,19]. Type I collagen, the major ECM component of fibrotic tissue, is a heterotrimer composed of two α1 chains and one α2 chain. Increased production of type I collagen is a common hallmark of fibrotic diseases in various organs including the liver. Once stimulated by fibrogenic stimuli, HSCs are the only cells that respond by expressing increased amounts of all three different isoforms of TGF-β. As activated HSCs are the principal cells to produce type I collagen in fibrotic liver, they contribute to the development of liver fibrosis through autocrine and paracrine loops of TGF-β-stimulated collagen production[4]. In the present study, low-dose paclitaxel treatment effectively reduced expression of type I and Ⅲ collagen and fibronectin in rat HSCs.

In conclusion, we demonstrated that low-dose paclitaxel significantly suppressed the exacerbated TGF-β/Smad signaling and decreased interstitial fibrosis in rat HSCs. It is hoped that the current results will give an impetus to future investigations to explore the therapeutic potential of paclitaxel in the amelioration of hepatic fibrosis.

COMMENTS

Background

Hepatic fibrosis is the key stage in the pathological progress from hepatic injury to cirrhosis. Transforming growth factor (TGF)-β is widely acknowledged as a key factor in accelerating hepatic fibrosis. Smad proteins have been identified to play an important role in regulating the expression of extracellular matrix (ECM) proteins *via* the TGF-β signaling pathway. Aberrant TGF-β/Smad signaling can be modulated by stabilization of microtubules with paclitaxel.

Innovations and breakthroughs

In this study, the authors' research group for the first time reported that 200 nmol/L paclitaxel ameliorated fibrosis in rat hepatic stellate cells (HSCs) *via* inhibition of TGF-β/Smad activity.

Applications

In future experiments, the authors will use the hepatic fibrosis model to observe the treatment effect of paclitaxel *in vivo*.

Terminology

Paclitaxel is an anticancer agent. It is noteworthy that the inhibition of tumor cell proliferation can be achieved by much higher doses of paclitaxel. The inhibition of TGF-β/Smad signaling, however, can be attained with very low doses of paclitaxel.

Peer review

The findings that low-dose paclitaxel significantly suppressed the exacerbated TGF-β/Smad signaling and decreased interstitial fibrosis in rat HSCs are interesting and important.

REFERENCES

1 **Li YR**, Wei L. [Mechanism of transforming growth factor beta/Smad signaling and the relationship between its transduction and liver fibrosis] *Zhonghua Ganzangbing Zazhi* 2005; **13**: 476-478

2 **Wu XL**, Zeng WZ, Jiang MD, Qin JP, Xu H. Effect of Oxymatrine on the TGFbeta-Smad signaling pathway in rats with CCl4-induced hepatic fibrosis. *World J Gastroenterol* 2008; **14**: 2100-2105

3 **Parsons CJ**, Takashima M, Rippe RA. Molecular mechanisms of hepatic fibrogenesis. *J Gastroenterol Hepatol* 2007; **22** Suppl 1: S79-S84

4 **Inagaki Y**, Okazaki I. Emerging insights into Transforming growth factor beta Smad signal in hepatic fibrogenesis. *Gut* 2007; **56**: 284-292

5 **Gressner AM**, Weiskirchen R. Modern pathogenetic concepts of liver fibrosis suggest stellate cells and TGF-beta as major players and therapeutic targets. *J Cell Mol Med* 2006; **10**: 76-99

6 **Derynck R**, Zhang YE. Smad-dependent and Smad-independent pathways in TGF-beta family signalling. *Nature* 2003; **425**: 577-584

7 **Dong C**, Li Z, Alvarez R Jr, Feng XH, Goldschmidt-Clermont PJ. Microtubule binding to Smads may regulate TGF beta activity. *Mol Cell* 2000; **5**: 27-34

8 **Breitkopf K**, Godoy P, Ciuclan L, Singer MV, Dooley S. TGF-beta/Smad signaling in the injured liver. *Z Gastroenterol* 2006; **44**: 57-66

9 **Gressner AM**, Weiskirchen R, Breitkopf K, Dooley S. Roles

of TGF-beta in hepatic fibrosis. *Front Biosci* 2002; **7**: d793-d807
10 **Uemura M**, Swenson ES, Gaça MD, Giordano FJ, Reiss M, Wells RG. Smad2 and Smad3 play different roles in rat hepatic stellate cell function and alpha-smooth muscle actin organization. *Mol Biol Cell* 2005; **16**: 4214-4224
11 **Tao YY**, Cui HY, Liu CH. [Dynamic characteristics of SARA during liver fibrogenesis in rats] *Zhonghua Ganzangbing Zazhi* 2006; **14**: 909-913
12 **Tahashi Y**, Matsuzaki K, Date M, Yoshida K, Furukawa F, Sugano Y, Matsushita M, Himeno Y, Inagaki Y, Inoue K. Differential regulation of TGF-beta signal in hepatic stellate cells between acute and chronic rat liver injury. *Hepatology* 2002; **35**: 49-61
13 **Zhu S**, Goldschmidt-Clermont PJ, Dong C. Transforming growth factor-beta-induced inhibition of myogenesis is mediated through Smad pathway and is modulated by microtubule dynamic stability. *Circ Res* 2004; **94**: 617-625
14 **Liu X**, Zhu S, Wang T, Hummers L, Wigley FM, Goldschmidt-Clermont PJ, Dong C. Paclitaxel modulates TGFbeta signaling in scleroderma skin grafts in immunodeficient mice. *PLoS Med* 2005; **2**: e354
15 **Gelmon K**. The taxoids: paclitaxel and docetaxel. *Lancet* 1994; **344**: 1267-1272
16 **Donaldson KL**, Goolsby GL, Kiener PA, Wahl AF. Activation of p34cdc2 coincident with taxol-induced apoptosis. *Cell Growth Differ* 1994; **5**: 1041-1050
17 **Schiff PB**, Fant J, Horwitz SB. Promotion of microtubule assembly in vitro by taxol. *Nature* 1979; **277**: 665-667
18 **Brahn E**, Tang C, Banquerigo ML. Regression of collagen-induced arthritis with taxol, a microtubule stabilizer. *Arthritis Rheum* 1994; **37**: 839-845
19 **Cao L**, Sun D, Cruz T, Moscarello MA, Ludwin SK, Whitaker JN. Inhibition of experimental allergic encephalomyelitis in the Lewis rat by paclitaxel. *J Neuroimmunol* 2000; **108**: 103-111

S- Editor Wang YR **L- Editor** Kerr C **E- Editor** Lin YP

World Journal of Gastroenterology

Online Submissions: http://www.wjgnet.com/1007-9327office
wjg@wjgnet.com
doi:10.3748/wjg.v16.i26.3335

World J Gastroenterol 2010 July 14; 16(26): 3335-3338
ISSN 1007-9327 (print)
© 2010 Baishideng. All rights reserved.

CASE REPORT

Vanishing bile duct syndrome in human immunodeficiency virus: Nevirapine hepatotoxicity revisited

Rajan Kochar, Moises I Nevah, Frank J Lukens, Michael B Fallon, Victor I Machicao

Rajan Kochar, Moises I Nevah, Frank J Lukens, Michael B Fallon, Victor I Machicao, Division of Gastroenterology, Hepatology and Nutrition, The University of Texas Health Science Center at Houston, Houston, TX 77030, United States
Author contributions: Kochar R, Nevah MI, Lukens FJ, Fallon MB and Machicao VI contributed equally to the literature review and writing the paper.
Correspondence to: Rajan Kochar, MD, MPH, Professor, Division of Gastroenterology, Hepatology and Nutrition, The University of Texas Health Science Center at Houston, 7500 Kirby Drive, Apt 510, Houston, TX 77030, United States. rajankochar@gmail.com
Telephone: +1-713-5006677 Fax: +1-713-5006699
Received: January 30, 2010 Revised: April 27, 2010
Accepted: May 4, 2010
Published online: July 14, 2010

Abstract

Vanishing bile duct syndrome (VBDS) refers to a group of disorders characterized by prolonged cholestasis as a result of destruction and disappearance of intrahepatic bile ducts. Multiple etiologies have been indentified including infections, neoplastic disorders, autoimmune conditions and drugs. The natural history of this condition is variable and may involve resolution of cholestasis or progression with irreversible damage. VBDS is extremely rare in human immunodeficiency virus (HIV)-infected patients and anti-retroviral therapy has never been implicated as a cause. We encountered a young pregnant female with HIV and VBDS secondary to anti-retroviral therapy. Here, we report her clinical course and outcome.

© 2010 Baishideng. All rights reserved.

Key words: Vanishing bile duct syndrome; Ductopenia; Acquired immune deficiency syndrome; Cholangiopathy; Cholestasis; Drug-induced liver injury

Peer reviewers: Florencia Georgina Que, MD, Department of Surgery, Mayo Clinic, 200 First Street Southwest, Rochester, MN 55905, United States; Luis Grande, Professor, Department of Surgery, Hospital del Mar, Passeig Marítim 25-29, Barcelona 08003, Spain

Kochar R, Nevah MI, Lukens FJ, Fallon MB, Machicao VI. Vanishing bile duct syndrome in human immunodeficiency virus: Nevirapine hepatotoxicity revisited. *World J Gastroenterol* 2010; 16(26): 3335-3338 Available from: URL: http://www.wjgnet.com/1007-9327/full/v16/i26/3335.htm DOI: http://dx.doi.org/10.3748/wjg.v16.i26.3335

INTRODUCTION

The destruction and disappearance of intrahepatic bile ducts leading to "ductopenia" and cholestasis is termed "vanishing bile duct syndrome (VBDS)". The exact mechanism underlying this syndrome is unknown; however, common causes include autoimmune disorders such as primary biliary cirrhosis (PBC), neoplasms, infections and drug toxicities[1-7]. Several patients with VBDS respond to treatment of the underlying condition and/or removal of the offending agent. However, other patients progress to biliary cirrhosis and end stage liver disease. VBDS is rare in the human immunodeficiency virus (HIV)-infected population and to date, only one case has been reported in the literature[8]. In addition, none of the anti-retroviral medications have been implicated as a cause of ductopenia. We report the case of a young female with HIV and VBDS secondary to anti-retroviral therapy.

CASE REPORT

In August, 2009, a 28-year-old African American female in the 3rd trimester of pregnancy (G1P0, 31 wk) presented to the emergency room with jaundice for 3 d. She also complained of pruritus, light-colored stools and dark urine. She denied any abdominal pain, fever,

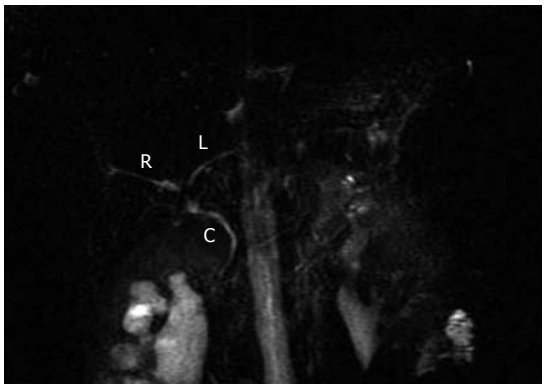

Figure 1 Magnetic resonance cholangiopancreatography. Patent biliary system without evidence of strictures or obstruction with normal caliber common bile duct (C), right hepatic duct (R), and left hepatic duct (L).

chills, vomiting or diarrhea. The patient had a history of heavy alcohol use (approximately 5 drinks/d) for 3 years discontinued at the beginning of her pregnancy. She reported no history of intravenous drug use or unprotected sexual exposure. She had no history of taking herbal supplements or over-the-counter medications. Her past medical history was significant for HIV infection diagnosed in 2000. She had not been on highly active antiretroviral therapy (HAART) since 2003 but recently started triple drug therapy to minimize risk of vertical transmission, with zidovudine, lamivudine and nevirapine 4 wk prior to presentation. She had no history of any opportunistic infections and was not taking any prophylactic medications. Her only other medications included folic acid and multivitamins. Her CD4 count and viral load prior to initiating therapy were 234 cells/μL (normal range: 410 to 1590 cells/μL) and 35 853 copies/mL [reverse transcriptase polymerase chain reaction (RT-PCR) lower limit of detection: 48 copies/mL], respectively.

Physical examination revealed icterus and gravid uterus consistent with duration of pregnancy. There were no stigmata of chronic liver disease. Abdomen was nontender and without hepatosplenomegaly or ascites. Fetal exam was normal. Her liver tests revealed total bilirubin of 10.5 mg/dL (normal range: 0.2-1.3 mg/dL), direct bilirubin 6.7 mg/dL, aspartate aminotransferase 103 U/L (normal range: 0-37 U/L), alanine aminotransferase 179 U/L (normal range: 0-40 U/L), and alkaline phosphatase 496 U/L (normal range: 39-117 U/L). Hematologic and electrolyte values were within normal range, and serum ethanol and urine drug screen were negative. Serologic testing was negative for viral and autoimmune hepatitis including hepatitis E IgM, Epstein Barr virus PCR and cytomegalovirus PCR (CMV-PCR), antinuclear antibody, antismooth muscle antibody, and antimitochondrial antibody. Her CD4 cell count and HIV-1 RNA viral load were measured as 224 cells/μL and 304 copies/mL, respectively. Fungal, mycobacterial, CMV, aerobic and anaerobic blood cultures as well as tests for *Cryptosporidium parvum*, *Microsporidium* and *Toxoplasma* were negative.

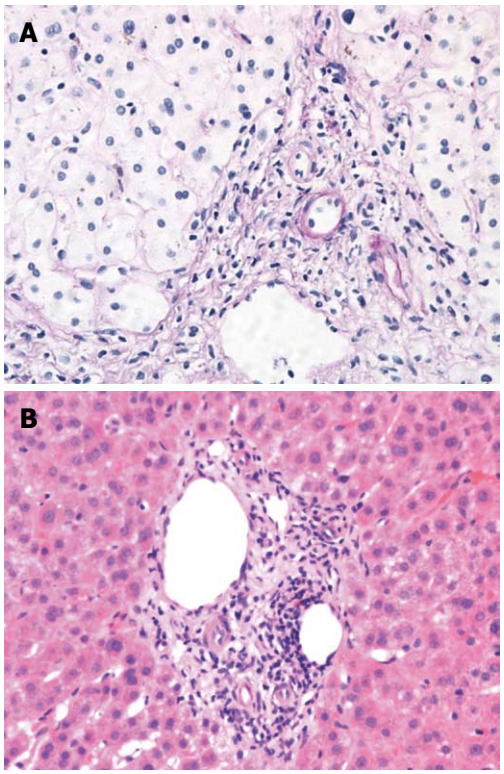

Figure 2 Liver biopsy showing portal tract with normal appearing hepatic vein and hepatic artery, and absence of bile ducts. A: PAS-D stain, × 200 magnification; B: Hematoxylin and eosin stain, × 200 magnification.

Right upper quadrant ultrasound revealed normal size liver with normal echogenicity and no focal lesions, cholelithiasis or biliary tract obstruction. Magnetic resonance cholangiopancreatography (MRCP) was performed. There was no cholangiographic evidence of extra- or intra-hepatic biliary duct dilatation (Figure 1), sclerosing cholangitis or discrete liver mass. A liver biopsy was performed which revealed marked ductopenia with cholestasis (Figure 2). Cytokeratin immunostain confirmed ductopenia and showed one irregular bile duct and scattered ductular proliferation among 11 visualized portal tracts (Figure 3). There was mild lymphocytic portal inflammation and CMV, AFB and GMS stains were negative. A diagnosis of VBDS was made.

HAART medications were withdrawn and the patient was started on ursodeoxycholic acid at 15 mg/kg per day to treat cholestasis and provide symptomatic relief. Over the next few weeks, the patient continued to have severe pruritus and worsening jaundice. Her liver tests deteriorated further with peak levels as shown in Figure 4. A second liver biopsy was performed 8 wk later which showed worsening cholestasis and persistent ductopenia. Owing to the progressive nature of her disease course, liver transplant evaluation was initiated for the patient.

DISCUSSION

VBDS refers to a group of disorders resulting in cholestasis as a consequence of progressive destruction and

Table 1 Drugs reported to cause chronic cholestasis and ductopenia

Antibiotics	Psychiatric drugs	Antiepileptic drugs	Oral hypoglycemics	Hormonal agents	Others
Ampicillin	Amitriptyline	Phenytoin	Carbutamide	Estradiol	Ibuprofen
Amoxicillin/	Chlorpromazine	Carbamazepine	Tolbutamide	Methyltestosterone	Phenylbutazone
clavulanic acid	Haloperidol	Barbiturates	Glibenclamide	Norandrostenolone	Cyproheptadine
Clindamycin	Imipramine	Diazepam			Cimetidine
Trimethoprim/	Prochlorperazine				Cromolyn sodium
sulfamethoxazole	Trifluperazine				Chlorothiazide
Flucloxacillin					
Tetracyclines					
Thiabendazole					
Erythromycin					
Troleandomycin					

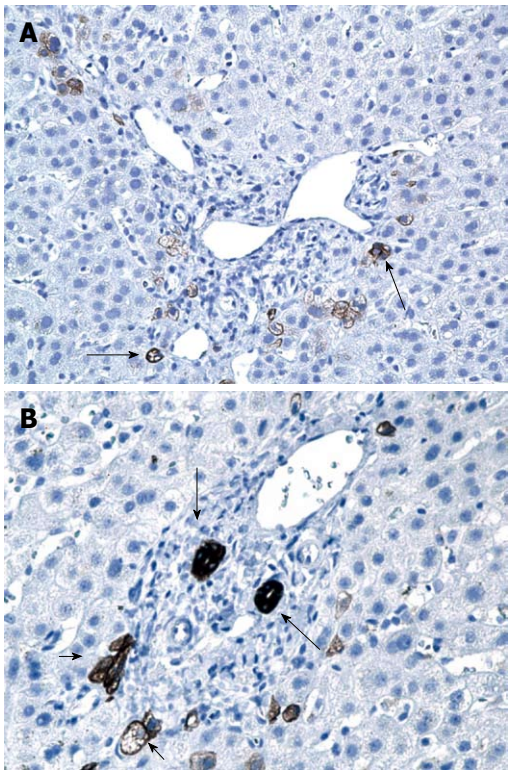

Figure 3 Liver biopsy specimen with cytokeratin staining for biliary elements. A: No bile ducts are seen, minimal ductular proliferation is apparent at the edges of the portal tract (long arrows); B: Solitary portal tract with presence of irregular bile ducts (long arrows) and ductular proliferation (short arrows).

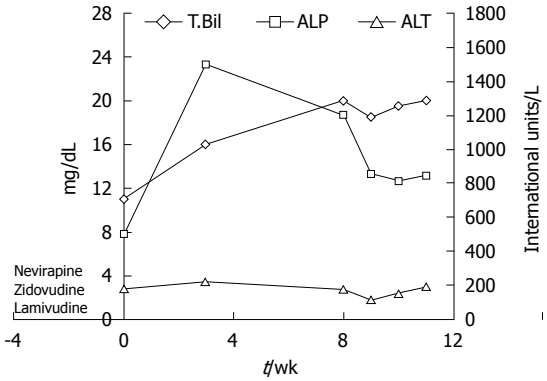

Figure 4 Trend of liver enzymes and bilirubin during the patient's clinical course.

disappearance of intrahepatic bile ducts. This condition was first described in 1988 in a case series of 3 patients by Ludwig *et al*[1] as "idiopathic adulthood ductopenia". Ductopenia is defined as the absence of interlobular bile ducts in greater than 50% of small portal tracts in a liver biopsy specimen.

Several causes of VBDS have been identified with varying mechanisms of duct injury and loss. PBC is one of the most common causes of ductopenia and is likely secondary to T-cell mediated bile duct injury[1,2]. Small duct primary sclerosing cholangitis, acute and chronic hepatic cellular rejection and sarcoidosis are other causes of VBDS with an underlying immune mechanism[3,4]. Infections and neoplastic disorders commonly implicated include CMV, reovirus 3, syphilis, cryptosporidium, Hodgkin's disease and histiocytosis X[5-7]. In addition, several drugs have been reported to cause VBDS, the most frequent ones include antibiotics and psychiatric medications (Table 1)[7].

Intrahepatic cholestasis of pregnancy was considered upon presentation as a possibility in our patient. However, this is a physiologic response to hormonal fluctuation during pregnancy and usually resolves spontaneously after delivery without persistent hyperbilirubinemia and ductopenia as seen in our patient[9]. There is no known association between pregnancy and VBDS, and the few existing case reports have been ascribed to medications such as chlorpromazine[10,11]. VBDS is even rarer in patients with HIV infection and has not been well described. Only a single case has been reported in the literature, in a patient with advanced AIDS (CD4 cell count: 7 cells/μL) and cholestasis with ductopenia presumably due to CMV infection[8]. A second case with HIV infection, low CD4 count (108 cells/μL) and idiopathic ductopenia has been reported, but does not fit the definition of VBDS since bile ducts were absent only in 6 of 15 portal tracts[12]. Cholestasis in patients with HIV infection is commonly due to sclerosing cholangitis and AIDS cholangiopathy which involves obstruction of the biliary tract due to infection-related strictures. Other causes include drug toxicity from HAART medications

and antimicrobials, neoplasms (Kaposi sarcoma and lymphoma) and opportunistic infections[13]. Our patient did not have biliary obstruction on ultrasound or MRCP, and had significantly higher levels of serum bilirubin than is commonly seen in AIDS cholangiopathy. Liver biopsy was negative for malignancy and did not show any features of sclerosing cholangitis or PBC. No strictures were seen on MRCP and tests for specific opportunistic pathogens were negative, ruling out AIDS cholangiopathy and infection.

The most likely cause of cholestasis in our patient was drug-induced liver injury. Medications used by our patient prior to onset of jaundice included zidovudine, lamivudine, nevirapine, multivitamins and folic acid. Zidovudine or lamivudine toxicity is associated with lactic acidosis, elevated lactate dehydrogenase, amylase and lipase along with abnormal liver tests[14]. None of these findings were seen in our patient. In addition, these two drugs were less likely to be the culprits since their toxic effects on the liver usually manifest after 6 mo of use. Nevirapine, a non-nucleoside reverse transcriptase inhibitor, is being increasingly used in pregnant patients owing to its favorable side effect profile and lower teratogenicity compared to protease inhibitors[14]. However, hepatotoxicity is the major adverse effect of nevirapine (5%) and most often manifests as a hypersensitivity reaction with fever, rash and elevated liver tests within the first few weeks of therapy. Late onset hepatotoxicity after several weeks of nevirapine use has also been described in several cases and may be an idiosyncratic reaction to the drug[14]. Although several case reports have demonstrated a cholestatic pattern of nevirapine toxicity, VBDS has never been reported[15,16]. Our patient did not have fever and rash, but had evidence of cholestatic hepatitis and a temporal association between nevirapine use and development of biochemical abnormalities. Therefore, nevirapine toxicity was felt to be the most likely cause of cholestasis and VBDS in our patient.

In summary, VBDS can result from multiple etiologies including autoimmune disorders, infections, neoplastic disorders, genetic abnormalities and medications. The diagnosis is suggested by abnormal liver tests and paucity of interlobular bile ducts on liver biopsy. To the best of our knowledge, this is the first reported case of nevirapine-induced cholestatic hepatitis in a patient with HIV leading to severe ductopenia and VBDS. VBDS should be considered in all HIV patients with chronic cholestasis, especially those with a history of nevirapine use.

REFERENCES

1 **Ludwig J**, Wiesner RH, LaRusso NF. Idiopathic adulthood ductopenia. A cause of chronic cholestatic liver disease and biliary cirrhosis. *J Hepatol* 1988; **7**: 193-199

2 **Kita H**, Matsumura S, He XS, Ansari AA, Lian ZX, Van de Water J, Coppel RL, Kaplan MM, Gershwin ME. Quantitative and functional analysis of PDC-E2-specific autoreactive cytotoxic T lymphocytes in primary biliary cirrhosis. *J Clin Invest* 2002; **109**: 1231-1240

3 **Ludwig J**. Small-duct primary sclerosing cholangitis. *Semin Liver Dis* 1991; **11**: 11-17

4 **Murphy JR**, Sjogren MH, Kikendall JW, Peura DA, Goodman Z. Small bile duct abnormalities in sarcoidosis. *J Clin Gastroenterol* 1990; **12**: 555-561

5 **Ballonoff A**, Kavanagh B, Nash R, Drabkin H, Trotter J, Costa L, Rabinovitch R. Hodgkin lymphoma-related vanishing bile duct syndrome and idiopathic cholestasis: statistical analysis of all published cases and literature review. *Acta Oncol* 2008; **47**: 962-970

6 **Thompson HH**, Pitt HA, Lewin KJ, Longmire WP Jr. Sclerosing cholangitis and histiocytosis X. *Gut* 1984; **25**: 526-530

7 **Reau NS**, Jensen DM. Vanishing bile duct syndrome. *Clin Liver Dis* 2008; **12**: 203-217, x

8 **Hindupur S**, Yeung M, Shroff P, Fritz J, Kirmani N. Vanishing bile duct syndrome in a patient with advanced AIDS. *HIV Med* 2007; **8**: 70-72

9 **Geenes V**, Williamson C. Intrahepatic cholestasis of pregnancy. *World J Gastroenterol* 2009; **15**: 2049-2066

10 **Moradpour D**, Altorfer J, Flury R, Greminger P, Meyenberger C, Jost R, Schmid M. Chlorpromazine-induced vanishing bile duct syndrome leading to biliary cirrhosis. *Hepatology* 1994; **20**: 1437-1441

11 **Chlumská A**, Curík R, Boudová L, Mukensnabl P, Klvana P. Chlorpromazine-induced cholestatic liver disease with ductopenia. *Cesk Patol* 2001; **37**: 118-122

12 **Aldeen T**, Davies S. Vanishing bile duct syndrome in a patient with advanced AIDS. HIV Med 2007; 8: 70-72. *HIV Med* 2007; **8**: 573-574

13 **Te HS**. Cholestasis in HIV-infected patients. *Clin Liver Dis* 2004; **8**: 213-228, viii-ix

14 **Medrano J**, Barreiro P, Tuma P, Vispo E, Labarga P, Blanco F, Soriano V. Risk for immune-mediated liver reactions by nevirapine revisited. *AIDS Rev* 2008; **10**: 110-115

15 **Prakash M**, Poreddy V, Tiyyagura L, Bonacini M. Jaundice and hepatocellular damage associated with nevirapine therapy. *Am J Gastroenterol* 2001; **96**: 1571-1574

16 **Clarke S**, Harrington P, Condon C, Kelleher D, Smith OP, Mulcahy F. Late onset hepatitis and prolonged deterioration in hepatic function associated with nevirapine therapy. *Int J STD AIDS* 2000; **11**: 336-337

S- Editor Wang JL **L- Editor** Logan S **E- Editor** Zheng XM

World Journal of Gastroenterology

Online Submissions: http://www.wjgnet.com/1007-9327office
wjg@wjgnet.com
doi:10.3748/wjg.v16.i26.3339

World J Gastroenterol 2010 July 14; 16(26): 3339-3342
ISSN 1007-9327 (print)
© 2010 Baishideng. All rights reserved.

CASE REPORT

Isolated ileal perforation due to cytomegalovirus reactivation during management of terbinafine hypersensitivity

Soichi Sano, Hiroki Ueno, Keiko Yamagami, Yosuke Yakushiji, Yoshihiro Isaka, Isao Kawasaki, Masashi Takemura, Takeshi Inoue, Masayuki Hosoi

Soichi Sano, Keiko Yamagami, Department of Internal Medicine, Osaka City General Hospital, Osaka 534-0021, Japan
Hiroki Ueno, Keiko Yamagami, Yosuke Yakushiji, Yoshihiro Isaka, Isao Kawasaki, Masayuki Hosoi, Department of Metabolism and Endocrinology, Osaka City General Hospital, Osaka 534-0021, Japan
Masashi Takemura, Department of Gastrointestinal Surgery, Osaka City General Hospital, Osaka 534-0021, Japan
Takeshi Inoue, Department of Pathology, Osaka City General Hospital, Osaka 534-0021, Japan
Author contributions: Sano S, Ueno H, Yamagami K and Yakushiji Y were involved in the total treatment of the patient; Isaka Y and Kawasaki I were involved in the diabetic treatment of the patient; Takemura M performed surgery; Inoue T contributed to the pathological examination; Sano S and Hosoi M wrote the paper.
Correspondence to: Keiko Yamagami, MD, Department of Metabolism and Endocrinology, Osaka City General Hospital, 2-13-22, Miyakojima-hon-dori, Miyakojima-ku, Osaka 534-0021, Japan. yamasanz@qb3.so-net.ne.jp
Telephone: +81-6-69291221 Fax: +81-6-69291091
Received: December 30, 2009 Revised: March 12, 2010
Accepted: March 19, 2010
Published online: July 14, 2010

Abstract

We report a case of 71-year-old man who developed a hypersensitivity syndrome associated with terbinafine. He was placed on terbinafine (250 mg/d) for the treatment of tinea pedis due to diabetes mellitus. Following the treatment with terbinafine, he developed drug-induced hypersensitivity syndrome (DIHS). Systemic corticosteroid led to transient improvement of his clinical manifestations. Three months after disease onset, he presented with panperitonitis due to ileal perforation, and underwent an emergency operation. The affected ileum was resected and ileostomy was performed in the terminal ileum. Cytomegalovirus (CMV)-specific IgG antibodies were significantly increased, high-titer CMV antigenemia was detected, and pathological examination of the resected ileum confirmed CMV infection. Based on these observations, we strongly recommend that physicians monitor reactivation of the family of herpesvirus other than herpesvirus 6, to manage DIHS properly.

© 2010 Baishideng. All rights reserved.

Key words: Terbinafine; Drug hypersensitivity; Human herpesvirus 6; Cytomegalovirus; Intestinal perforation; Ileum

Peer reviewer: NKH de Boer, MD, PhD, Gastroenterology and Hepatology, VU University Medical Center, PO Box 7057, 1007 MB, Amsterdam, The Netherlands

Sano S, Ueno H, Yamagami K, Yakushiji Y, Isaka Y, Kawasaki I, Takemura M, Inoue T, Hosoi M. Isolated ileal perforation due to cytomegalovirus reactivation during management of terbinafine hypersensitivity. *World J Gastroenterol* 2010; 16(26): 3339-3342 Available from: URL: http://www.wjgnet.com/1007-9327/full/v16/i26/3339.htm DOI: http://dx.doi.org/10.3748/wjg.v16.i26.3339

INTRODUCTION

Terbinafine has become established as a drug of choice to treat onychomycosis and other dermatomycoses. Although previously reported cases of drug-induced hypersensitivity syndrome (DIHS) are notably uncommon (anticonvulsants, salazosulfapyridine, allopurinol, minocycline, and mexiletine), the number of reported cases of DIHS induced by terbinafine has been increasing.

It is true human herpesvirus 6 (HHV-6) reactivation has been the most frequently described infection associated with this syndrome, but recent articles have suggested that certain herpesviruses other than HHV-6 might be reactivated in a sequential manner in the development of DIHS (multiple and sequential herpesvirus reactivation)[1-7].

Although rare, cytomegalovirus (CMV) is known to cause ileal perforation, not only in immunocompromised

patients such as those with the acquired immunodeficiency syndrome (AIDS) but also immunocompetent patients[8-11]. To the best of our knowledge, especially in the English-language literature, isolated cases of ileal perforation due to CMV infection have never been reported in patients with DHIS.

Here, we report a case of isolated ileal perforation due to CMV in a case of DIHS due to terbinafine, in whom reactivation of HHV-6, Epstein-Barr virus (EBV) and CMV was detected.

CASE REPORT

A 71-year-old Japanese man with diabetes mellitus with onychomycosis was treated with oral terbinafine. Other medical history was not remarkable: any anticonvulsants, mexiletine, and antibiotics such as minocycline and salazosulfapyridine, were not prescribed. One week after taking terbinafine, he developed a high fever, erythema covering the whole body, and superficial lymph node swelling. Laboratory data at that time showed leukocytosis (16 670/mm^3) with 30.2% eosinophils. Atypical lymphocytes were not present. Liver enzymes were slightly elevated: 47 IU/L alanine aminotransferase and 78 IU/L aspartate aminotransferase. DIHS was suspected and terbinafine administration was discontinued soon after the onset of illness. As a result of sustained fever and erythroderma for 1 mo, 30 mg/d systemic corticosteroid was started. After 7 d, his symptoms improved temporarily. However, tapering the corticosteroid dose to 25 mg/d led to recrudescence of his fever and generalized rash (on day 50). Other results of systemic corticosteroids were not remarkable. Retrospectively, seroconversion of anti-HHV-6 antibody was detected; the titer increased from < 10 (on day 14) to 40 (on day 90). Judging from his drug history, characteristic generalized erythematous rash and laboratory data, the diagnosis of DIHS was confirmed. He was again administrated 30 mg/d prednisolone from day 50. Then, the patient was referred to our hospital (Osaka City General Hospital).

Examination on admission revealed erythematous rash over his entire body, with partially exfoliated lesions and superficial lymphadenopathy. Laboratory data included a normal count of white blood cells without eosinophilia and normal liver enzymes. Antinuclear and antineutrophil cytoplasmic antibodies were negative. The patient was negative for human immunodeficiency virus (HIV). Histological examination of the skin was not performed. Seventy days after the onset of DIHS, the patient complained of abdominal discomfort, and occult blood tests were positive on two occasions. On day 80, colonoscopic examination was performed and no abnormality around the whole colon and terminal ileum was revealed. At that time, CMV antigenemia was strongly suggested by the direct detection of viral antigen in the peripheral blood: CMV antigenemia-1, 56 and antigenemia-2, 89. CMV IgG titer increased to 128 and IgM titer was negative (< 0.8). Intravenous administration of 500 mg/d ganciclovir was started. However, fever with abdominal pain was present on day 82, and physical examination showed muscular defense in the entire abdomen. Abdominal computed tomography (CT) revealed free air, ascites, and swelling of the ileal loop (Figure 1). He was diagnosed as having panperitonitis due to ileal perforation, and underwent an emergency operation. The affected ileum was resected and ileostomy was performed. Pathological examination of the resected ileum revealed acute inflammation with vasculitis and CMV inclusions in the macrophages and endothelial cells, and evidence of CMV on immunostaining (Figure 2). There was no evidence of cancer cells or any other pathogens. Administration of 500 mg/d ganciclovir was continued, and CMV antigenemia was not detected on day 89. Unfortunately, the patient died from pneumonia.

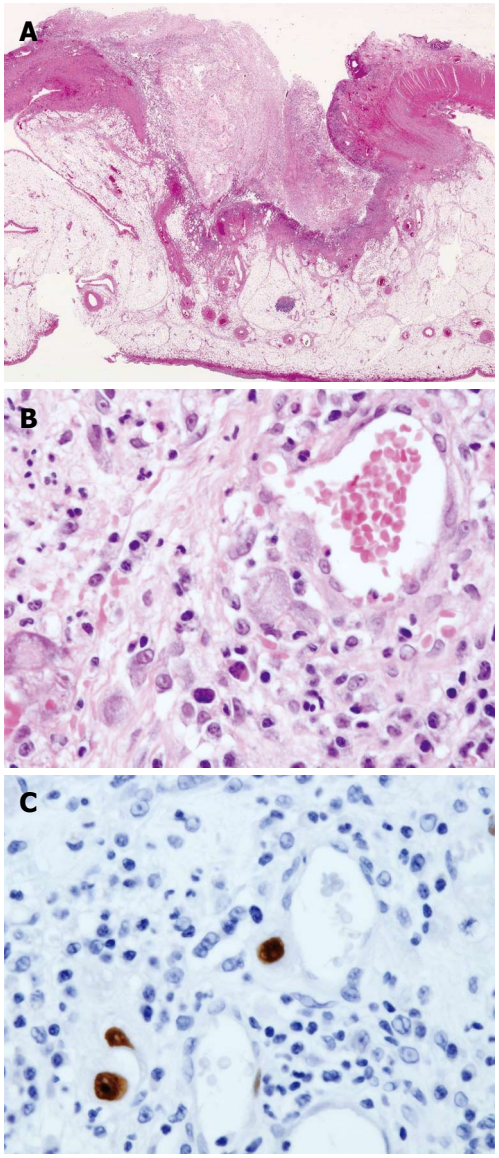

Figure 1 Histological examination of perforated ileum. A: Perforated ileal lesion (hematoxylin and eosin stain) × 40; B: × 400; C: Cytomegalovirus infection was evident in the same lesion, by immunohistochemical staining with anti-cytomegalovirus antibody (× 200).

DISCUSSION

Terbinafine has become established as a drug of choice

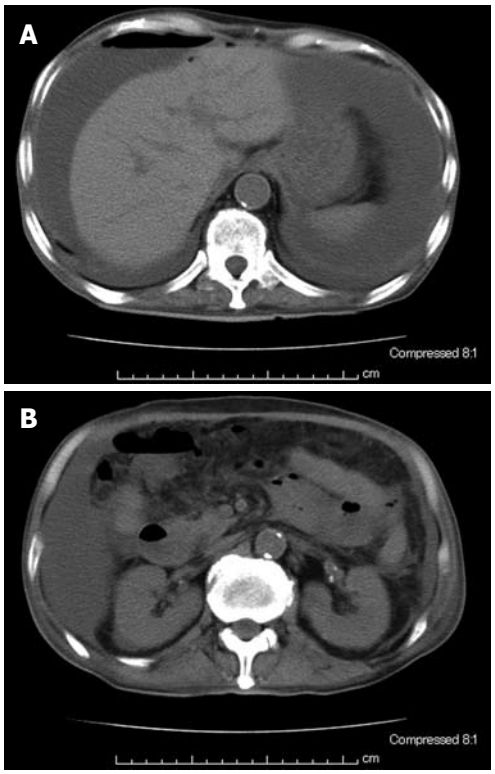

Figure 2 Abdominal computed tomography. A: Free-air, ascites; B: Swelling of the ileal loop.

to treat onychomycosis and other dermatomycoses. Although previously reported cases of DIHS are notably uncommon (anticonvulsants, salazosulfapyridine, allopurinol, minocycline, and mexiletine), the number of reported cases of DIHS induced by terbinafine has been increasing. It was thought that the present case met the criteria for DIHS because the patient had clear exposure to a given drug (in this case, terbinafine), high fever (> 39℃); erythroderma followed by exfoliative dermatitis; diffuse lymphadenopathy; and hypereosinophilia (absolute eosinophil count, 5032/mm^3). The results of a lymphocyte-stimulating test for terbinafine performed in our hospital were negative, and it was thought that treatment with prednisolone may have affected the results.

Since Aihara *et al*[2] in 2001, it has been recognized that CMV is associated with hypersensitivity syndrome. Recent studies have suggested that reactivation of members of the herpesvirus family other than HHV-6 could be associated with DIHS. Moreover, multiple herpesvirus reactivations and sequential reactivation have been reported in the case of DIHS. The list of viruses that have been documented to be reactivated include HHV-6, HHV-7, EBV and CMV[2-7]. In the present case, reactivation of HHV-6, EBV and CMV was confirmed on the basis of serological tests on paired serum samples for HHV-6 and EBV, and polymerase chain reaction for CMV. EBV reactivation was asymptomatic, which might have been due to administration of corticosteroids.

The clinical course of this patient can be divided in three phases: (1) hypersensitivity reaction with eosinophilia; (2) relapse of fever and rash due to HHV-6 reactivation; and (3) ileal perforation due to CMV reactivation. Retrospectively, the worsening of exanthema and poor control of second fever in spite of treatment with prednisolone reflect virus reactivation. We speculate that the virus responsible for this phase was HHV-6, although we could not confirm the absence of CMV infection in this period. The following abdominal pain and ileal perforation was due to CMV reactivation, as confirmed by pathological examination of the resected ileum.

Table 1 Previously reported causes of isolated ileal perforation due to CMV

AIDS
Non-Hodgkin's lymphoma with chemotherapy
Systemic lupus erythematosus
Liver transplantation
Ulcerative colitis
Recurrent gastric cancer
Blood transfusion associated with trauma
Immunocompetent elderly/neonatal
DIHS (present case)

CMV: Cytomegalovirus; AIDS: Acquired immunodeficiency syndrome; DIHS: Drug-induced hypersensitivity syndrome.

Our patient was unique in that CMV reactivation resulted in ileal perforation during the course of DIHS. Although rare, CMV is known to cause ileal perforation, especially in immunocompromised patients, such as those with AIDS. To the best of our knowledge, isolated cases of ileal perforation due to CMV infection have never been reported in a patient with DIHS (Table 1)[8-11]. Although it remains possible that systemic corticosteroid administration precipitated CMV reactivation, there is also a case report that demonstrated that a patient without any corticosteroids showed reactivation of HHV-6, HHV-7 and CMV[3]. Based on these observations, it is important for physicians to be aware of the possible reactivation of CMV and other herpesviruses in every patient with DIHS, to avoid awkward small intestinal ulcer and perforation.

In summary, we have reported a case of isolated ileal perforation due to CMV reactivation during the management of terbinafine hypersensitivity. Although the prognosis in bowel perforation related to CMV infection is extremely poor, emergency surgery saved our patient's life. However, earlier diagnosis and prompt administration of antiviral drugs could have avoided surgical treatment. Although CMV could affect multiple organ functions and might be the direct cause of death, effective medication such as ganciclovir is available. Therefore, it is strongly recommended that physicians monitor reactivation of herpesviruses other than HHV-6, to manage DIHS properly.

REFERENCES

1 **Komura K**, Hasegawa M, Hamaguchi Y, Yukami T, Nagai M, Yachie A, Sato S, Takehara K. Drug-induced hypersensitivity syndrome associated with human herpesvirus 6 and cytomegalovirus reactivation. *J Dermatol* 2005; **32**: 976-981

2 **Aihara M**, Sugita Y, Takahashi S, Nagatani T, Arata S, Takeuchi K, Ikezawa Z. Anticonvulsant hypersensitivity syndrome associated with reactivation of cytomegalovirus.

Br J Dermatol 2001; **144**: 1231-1234
3 **Kano Y**, Hiraharas K, Sakuma K, Shiohara T. Several herpesviruses can reactivate in a severe drug-induced multiorgan reaction in the same sequential order as in graft-versus-host disease. *Br J Dermatol* 2006; **155**: 301-306
4 **Aihara M**, Sugita Y, Takahashi S, Nagatani T, Arata S, Takeuchi K, Ikezawa Z. Anticonvulsant hypersensitivity syndrome associated with reactivation of cytomegalovirus. *Br J Dermatol* 2001; **144**: 1231-1234
5 **Descamps V**, Mahe E, Houhou N, Abramowitz L, Rozenberg F, Ranger-Rogez S, Crickx B. Drug-induced hypersensitivity syndrome associated with Epstein-Barr virus infection. *Br J Dermatol* 2003; **148**: 1032-1034
6 **Sekiguchi A**, Kashiwagi T, Ishida-Yamamoto A, Takahashi H, Hashimoto Y, Kimura H, Tohyama M, Hashimoto K, Iizuka H. Drug-induced hypersensitivity syndrome due to mexiletine associated with human herpes virus 6 and cytomegalovirus reactivation. *J Dermatol* 2005; **32**: 278-281
7 **Arakawa M**, Kakuto Y, Ichikawa K, Chiba J, Tabata N, Sasaki Y. Allopurinol hypersensitivity syndrome associated with systemic cytomegalovirus infection and systemic bacteremia. *Intern Med* 2001; **40**: 331-335
8 **Meza AD**, Bin-Sagheer S, Zuckerman MJ, Morales CA, Verghese A. Ileal perforation due to cytomegalovirus infection. *J Natl Med Assoc* 1994; **86**: 145-148
9 **Bang S**, Park YB, Kang BS, Park MC, Hwang MH, Kim HK, Lee SK. CMV enteritis causing ileal perforation in underlying lupus enteritis. *Clin Rheumatol* 2004; **23**: 69-72
10 **Yasunaga M**, Hodohara K, Uda K, Miyagawa A, Kitoh K, Andoh A, Okabe H, Ochi Y, Fujiyama Y, Bamba T. Small intestinal perforation due to cytomegalovirus infection in patients with non-Hodgkin's lymphoma. *Acta Haematol* 1995; **93**: 98-100
11 **Van Schaeybroeck S**, Hiele M, Miserez M, Croes R. Ileal perforation caused by cytomegalovirus infection in an immunocompetent adult. *Acta Clin Belg* 2002; **57**: 154-157

S- Editor Wang YR **L- Editor** Kerr C **E- Editor** Ma WH

World Journal of Gastroenterology

Online Submissions: http://www.wjgnet.com/1007-9327office
wjg@wjgnet.com
doi:10.3748/wjg.v16.i26.3343

World J Gastroenterol 2010 July 14; 16(26): 3343-3346
ISSN 1007-9327 (print)
© 2010 Baishideng. All rights reserved.

CASE REPORT

Abdominal separation in an adult male patient with acute abdominal pain

Bao-Lin Liu, Yang Chen, Shi-Qing Liu, Xiao-Bo Zhang, Dong-Xu Cui, Xian-Wei Dai

Bao-Lin Liu, Yang Chen, Shi-Qing Liu, Xiao-Bo Zhang, Dong-Xu Cui, Xian-Wei Dai, Hepato-Pancreato-Biliary, Oncology and Organ Transplatation Division, Department of Surgery, Shengjing Hospital, China Medical University, Shenyang, 110004, Liaoning Province, China

Author contributions: Liu BL designed and revised the article; Chen Y and Liu SQ contributed to the patient management and wrote the article; Zhang XB contributed to the patient care and reference management; Cui DX and Dai XW supervised for the patient management and revised the article.

Correspondence to: Xian-Wei Dai, MD, PhD, Professor, Hepato-Pancreato-Biliary, Oncology and Organ Transplatation Division, Department of Surgery, Shengjing Hospital, China Medical University, Shenyang 110004, Liaoning Province, China. daixianwei@hotmail.com

Telephone: +86-24-23841450 Fax: +86-24-96615-13631
Received: February 2, 2010 Revised: March 18, 2010
Accepted: March 25, 2010
Published online: July 14, 2010

Abstract

We report a male patient with prolonged post-prandial abdominal distension and a sudden onset of epigastric pain initially diagnosed as acute abdomen. The patient had no history of surgery. Physical examination revealed peritonitis and abdominal computed tomography scan showed upper abdominal mesentery intorsion. The patient then underwent surgical intervention. It was found that the descending mesocolon dorsal root was connected to the ascending colon and formed a membrane encapsulating the small intestine. The membrane also formed an orifice in the ileal pars caeca, from which a 30 cm herniated ileum formed a "C"-shaped loop which was strangulated by the orifice. An abdominal separation was diagnosed after surgery. We liberated the membranous peritoneum which incarcerated the intestinal canal from the root of ileocecal junction to Treitz ligament, and reduced the small intestinal malrotation. The patient had an uneventful recovery after operation with his abdominal distention disappeared during the follow-up. Abdominal separation is a rare situation, which may be related with embryo development. Surgery is a choice of treatment for it.

© 2010 Baishideng. All rights reserved.

Key words: Abdominal separation; Abdominal pain; Internal hernia; Malrotation; Acute abdomen

Peer reviewer: Yasuhiro Fujino, MD, PhD, Director, Department of Surgery, Hyogo Cancer Center, 13-70 Kitaoji-cho, Akashi, 673-8558, Japan

Liu BL, Chen Y, Liu SQ, Zhang XB, Cui DX, Dai XW. Abdominal separation in an adult male patient with acute abdominal pain. *World J Gastroenterol* 2010; 16(26): 3343-3346 Available from: URL: http://www.wjgnet.com/1007-9327/full/v16/i26/3343.htm DOI: http://dx.doi.org/10.3748/wjg.v16.i26.3343

INTRODUCTION

Acute abdominal pain, a common chief complaint encountered in emergency department, accounts for about 5% of all emergency department visits[1] and can be caused by a variety of conditions[2]. Many factors can result in acute abdominal pain, such as appendicitis, bowel obstruction, and cholecystitis[3]. This report describes a rare case of abdominal separation in an adult male patient with strangulated internal hernia of the terminal ileum complicating malrotation of intestine, which has not been reported in the literature.

CASE REPORT

A 43-year-old man visited the emergency department of our hospital on December 31, 2007 for a sudden onset of persistent epigastric pain for 10 h. He had a history

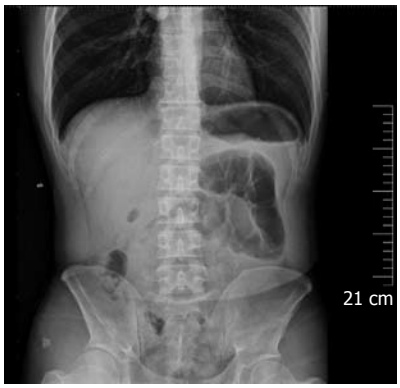

Figure 1 Plain abdominal X-ray. Mildly dilated pneumatic intestinal canal loops but no typical air-fluid level shadow in the left upper quadrant of abdomen.

of prolonged episodes of postprandial abdominal distension. The pain was associated with nausea and vomiting without any clear inducing factors, and did not radiate to the back and shoulders. The symptoms included anorexia, constipation, obstipation and poor sleep. Furthermore, he had no history of abdominal surgery or trauma. On admission, his temperature was 36.5℃, blood pressure was 127/72 mmHg, respiratory rate and pulse rate were 17 breaths/min and 70 beats/min, respectively. Physical examination showed tenderness, rebound tenderness and slight muscular rigidity in the right lower quadrant of abdomen. Laboratory findings included 86.8% of neutrophils and 116.0 U/L of hemoglobin. Plain abdominal X-ray revealed mildly dilated pneumatic intestinal canal loops but no typical air-fluid level shadow in the left upper quadrant of abdomen (Figure 1). The patient was initially diagnosed as localized peritonitis which was differentially diagnosed from acute appendicitis and intestinal mesentery intorsion.

The patient had no significant improvement after initial treatment with fluid replacement, antibiotics and gastrointestinal decompression. He developed peritonitis with the pain exacerbated. Computed tomography (CT) scan revealed suspicious upper abdominal mesentery intorsion (Figure 2). Exploratory laparoscopy demonstrated appendix in the retroileal position, descending mesocolon dorsal root that was connected to the ascending colon encapsulating the small intestine, an orifice in the ileal pars caeca from which a 30 cm herniated ileum formed a "C"-shaped loop at the root of ileocecal junction strangulating at the orifice, and a purple incarcerated intestinal canal.

We liberated the incarcerated intestinal canal by opening the membrane at the mesentery root from the ileocecal junction to Treitz ligament and reduced the mesoileal malrotation. The strangulated intestine was about 50 cm from the ileocecal junction. After liberation, the intestinal canal was recovered with its color changed from purple to pink, and vascular pulsation was obvious and peristalsis was resumed.

The patient had an uneventful recovery and was discharged on January 8, 2008. The patient was diagnosed as localized peritonitis, small intestinal malrotation, internal herniation, strangulation of small bowel and abdominal separation after operation, and followed up for 18 mo during which no complications and post prandial abdominal distention occurred.

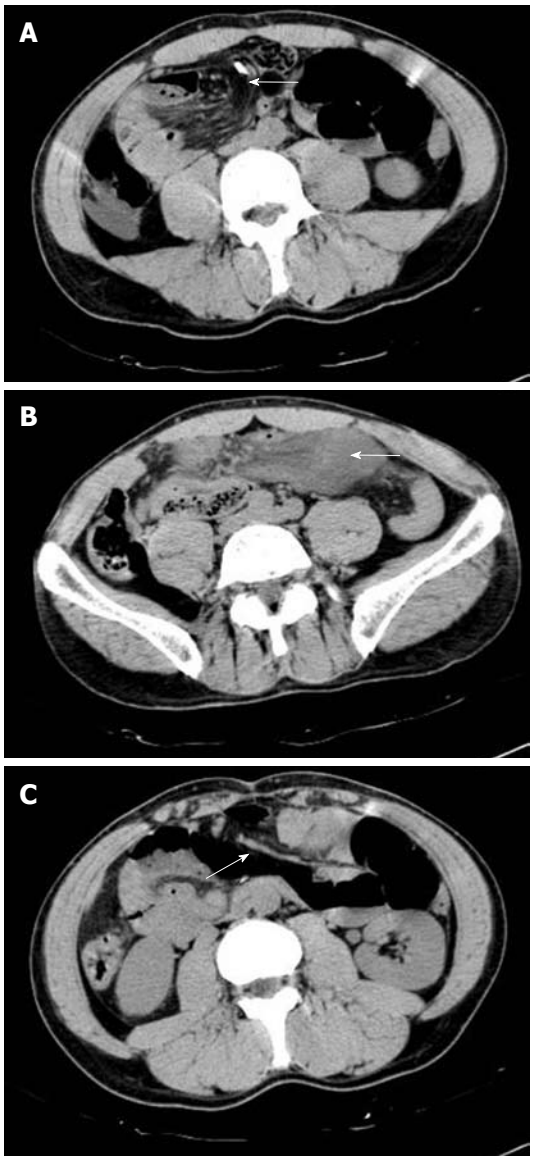

Figure 2 Computed tomography scan. Suspicious upper abdominal mesentery intorsion (A, arrow), right lower quadrant intestinal loop (B, arrow), middle abdominal line separation (C, arrow).

DISCUSSION

Since a large number of patients visiting emergency department complain of acute abdominal pain and most of them have typical symptoms and signs, appropriate evaluation can be accomplished with the aid of relevant auxiliary investigations[3]. The complaints are usually relieved after symptomatic treatment. In some rare cases, its initial diagnosis may be difficult as in our case. The incidence of internal hernia is low, accounting for less than 1% of all acute abdomen cases[4-6]. However, the overall mortality may be higher than 50% if it is not ap-

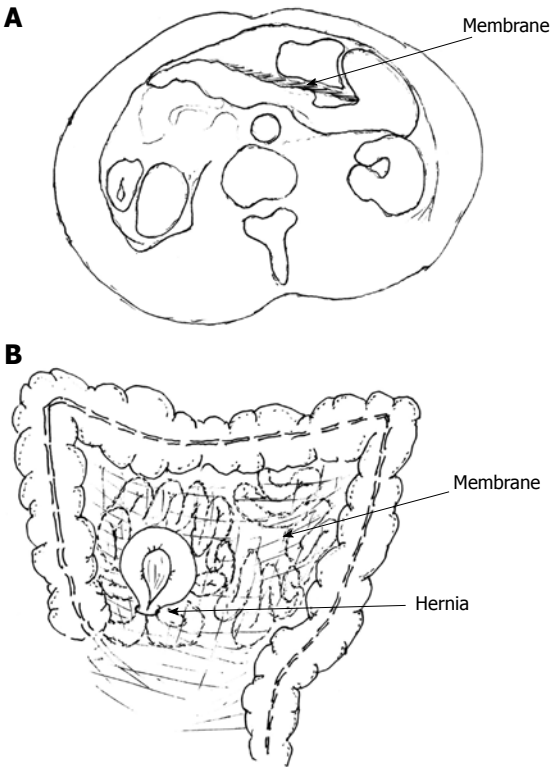

Figure 3 Schema showing a membrane separating the peritoneal cavity into two compartments (A) and descending mesocolon dorsal root connecting with the ascending colon (B).

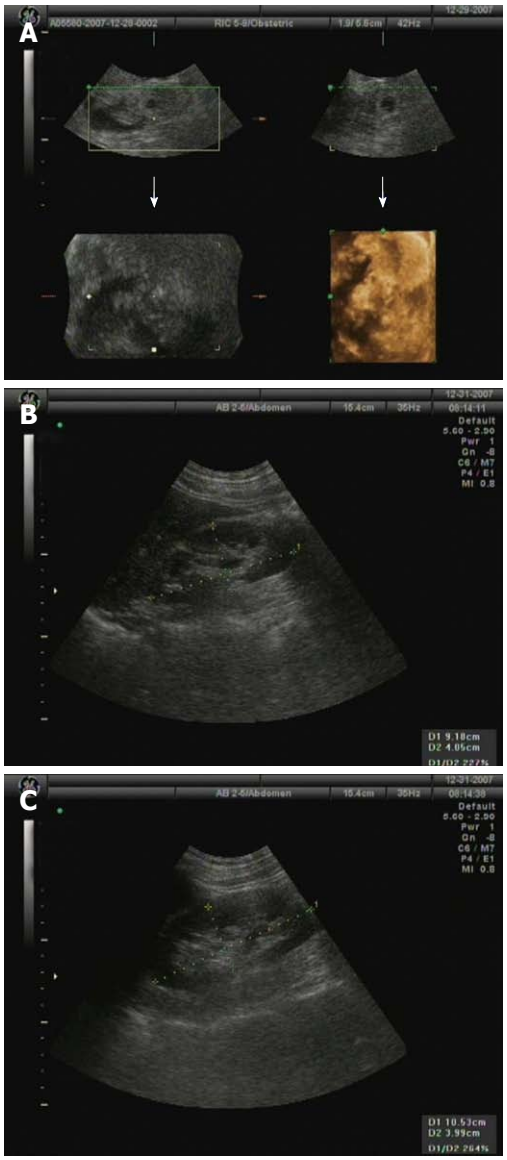

Figure 4 Abdominal and kidney ultrasonography showing no mass and fluid collection (A), left (B) and right (C) normal kidney structure.

propriately treated, especially when strangulation occurs. A fast and correct diagnosis is therefore necessary.

Our patient suffered from abdominal pain which exacerbated although it was treated with fluid resuscitation and antibiotics. Nasogastric tube decompression did not produce desirable effect and vomiting continued. Since the condition was nonspecific, its differential diagnosis was difficult from acute abdomen caused by factors such as mechanical intestinal obstruction. Plain abdominal X-ray has been recommended for patients with highly suspected obstruction[7-9] according to The Royal College of Radiologists Guidelines[10]. A single plain abdominal X-ray is not adequate to make a definitive judgment of suspected obstruction[9], and CT scan is the reasonable next step for further investigation of abdomen[2,11]. Abdominal CT scan has a good inter-observer agreement in unselected patients with acute abdominal pain at emergency department and plays an important role in diagnosis of acute intestinal obstruction and in planning of surgical treatment. Although internal hernias are uncommon, they should be included in the differential diagnosis from intestinal obstruction, especially in the absence of abdominal surgery or trauma. Recognition of the characteristic findings on CT scan may assist in identification of internal hernias in most cases of small bowel obstruction. Since the general condition of this patient deteriorated very quickly and CT revealed a mesentery intorsion, surgery was performed. The function of strangulated bowel was recovered after its loop was released and the mesenteric malrotation was reduced.

Although abdominal separation in our case could not be definitely diagnosed before operation by the radiologist and clinician[8] due to the presence of peritonitis, surgery was performed during which the otherwise rare phenomenon of abdominal separation was discovered, namely a membrane divides the abdominal cavity into two compartments. The anterior compartment contains the colon, while the posterior compartment encapsulates the small intestine, forming an orifice at the end of ileocecal junction. It is at this orifice that a 30 cm ileum is protruded and strangulates the anterior compartment, causing abdominal pain. A CT scan showed an intra-abdominal membrane-like line dividing the two compartments (Figures 2 and 3). Ultrasonography did not show specific intraabdominal evidence (Figure 4). This patient experienced episodes of post prandial abdominal distension, which supported the findings on abdominal CT scan and at operation. His symptoms were relieved after operation. We therefore recommend that abdominal sep-

aration should be differentially diagnosed from acute abdomen. Early diagnosis and operation will greatly reduce the morbidity and mortality of intestinal strangulation.

The intestine has returned to the abdominal cavity and the midgut consisting mainly of the duodenum, jejunum, ileum, ascending colon, and transverse colon has completed its 270-degree loop by weeks 10 and 20 of embryo development, respectively. With the growth of small intestine, the ascending and descending colon are pushing against the body wall in a secondary retroperitoneal location like the pancreas and duodenum[12,13]. Whether the mesentery separates abdomen into two parts of peritonum during the development is not well known. Whether there is any genetic change needs to be further investigated.

In conclusion, abdominal separation with internal hernias is a rare condition that can present as acute abdomen. Such patients can recover if they are properly treated. We strongly recommend that abdominal separation should be differentially diagnosed from acute abdomen.

ACKNOWLEDGMENTS

The authors thank Sangeeta Sharma for the help in manuscript preparation and Jin Xu for preparation of the schema.

REFERENCES

1 **Kamin RA**, Nowicki TA, Courtney DS, Powers RD. Pearls and pitfalls in the emergency department evaluation of abdominal pain. *Emerg Med Clin North Am* 2003; **21**: 61-72, vi

2 **van Randen A**, Laméris W, Nio CY, Spijkerboer AM, Meier MA, Tutein Nolthenius C, Smithuis F, Bossuyt PM, Boermeester MA, Stoker J. Inter-observer agreement for abdominal CT in unselected patients with acute abdominal pain. *Eur Radiol* 2009; **19**: 1394-1407

3 **Cartwright SL**, Knudson MP. Evaluation of acute abdominal pain in adults. *Am Fam Physician* 2008; **77**: 971-978

4 **Martin LC**, Merkle EM, Thompson WM. Review of internal hernias: radiographic and clinical findings. *AJR Am J Roentgenol* 2006; **186**: 703-717

5 **Selçuk D**, Kantarci F, Oğüt G, Korman U. Radiological evaluation of internal abdominal hernias. *Turk J Gastroenterol* 2005; **16**: 57-64

6 **Varela GG**, López-Loredo A, García León JF. Broad ligament hernia-associated bowel obstruction. *JSLS* 2007; **11**: 127-130

7 **Ahn SH**, Mayo-Smith WW, Murphy BL, Reinert SE, Cronan JJ. Acute nontraumatic abdominal pain in adult patients: abdominal radiography compared with CT evaluation. *Radiology* 2002; **225**: 159-164

8 **Thompson WM**, Kilani RK, Smith BB, Thomas J, Jaffe TA, Delong DM, Paulson EK. Accuracy of abdominal radiography in acute small-bowel obstruction: does reviewer experience matter? *AJR Am J Roentgenol* 2007; **188**: W233-W238

9 **Smith JE**, Hall EJ. The use of plain abdominal x rays in the emergency department. *Emerg Med J* 2009; **26**: 160-163

10 **Remedios D**, McCoubrie P, The Royal College Of Radiologists Guidelines Working Party. Making the best use of clinical radiology services: a new approach to referral guidelines. *Clin Radiol* 2007; **62**: 919-920

11 **Takeyama N**, Gokan T, Ohgiya Y, Satoh S, Hashizume T, Hataya K, Kushiro H, Nakanishi M, Kusano M, Munechika H. CT of internal hernias. *Radiographics* 2005; **25**: 997-1015

12 **Cochard LR**. Netter's atlas of human embryology. Teterboro: Icon Learning Systems, 2002: 140-141

13 **Israelit S**, Brook OR, Nira BR, Guralnik L, Hershko D. Left-sided perforated acute appendicitis in an adult with midgut malrotation: the role of computed tomography. *Emerg Radiol* 2009; **16**: 217-218

S- Editor Wang JL **L- Editor** Wang XL **E- Editor** Zheng XM

World Journal of Gastroenterology

Online Submissions: http://www.wjgnet.com/1007-9327office
wjg@wjgnet.com
www.wjgnet.com

World J Gastroenterol 2010 July 14; 16(26): I
ISSN 1007-9327 (print)
© 2010 Baishideng. All rights reserved.

Acknowledgments to reviewers of *World Journal of Gastroenterology*

Many reviewers have contributed their expertise and time to the peer review, a critical process to ensure the quality of *World Journal of Gastroenterology*. The editors and authors of the articles submitted to the journal are grateful to the following reviewers for evaluating the articles (including those published in this issue and those rejected for this issue) during the last editing time period.

José Liberato Ferreira Caboclo, Dr., Professor, Rua Antônio de Godoy, 4120, São José do Rio Preto, Brazil

Volker F Eckardt, MD, Professor, Chief, Department of Gastroenterology, Deutsche Klinik für Diagnostik, Aukammallee 33, 65191 Wiesbaden, Germany

Abdellah Essaid, Professor, Hospital Ibn Sina, Rabat 10100, Morocco

R Mark Ghobrial, MD, PhD, FACS, FRCS (Ed), Director, Liver Center, Chief, Liver Transplantation Surgery, Director, Immunobiology Research Center, The Methodist Hospital, 6550 Fannin Street, SM1661, Houston, TX 77030, United States

Richard Hu, MD, MSc, Division of Gastroenterology, Department of Medicine, Olive view-UCLA Medical Center, 14445 Olive View Drive, Los Angeles, CA 91342, United States

Kalpesh Jani, Dr., Consultant GI and Laparoscopic Surgeon, SIGMA Surgery, Baroda, Gujarat, India

Shogo Kikuchi, MD, PhD, Professor, Department of Public Health, Aichi Medical University School of Medicine, 21 Karimata, Yazako, Nagakute-cho, Aichi-gun, Aichi, 480-1195, Japan

Peter L Lakatos, MD, PhD, Assistant Professor, 1st Department of Medicine, Semmelweis University, Koranyi S 2A, Budapest H1083, Hungary

Laura Lladó, PhD, Department of Surgery, Liver Transplant Unit, Hospital Universitari de Bellvitge, IDIBELL, 08907 Barcelona, Spain

Francesco Luzza, Professor, MD, Department of Clinical and Experimental Medicine, University of Catanzaro "Magna Graecia", Campus Universitario di Germaneto, Viale Europa, Catanzaro 88100, Italy

Mercedes Susan Mandell, MD, PhD, Department of Anesthesiology, University of Colorado Health Sciences Ctr., 12401 E. 17th Ave, B113, Aurora, CO 80045, United States

Kotaro Miyake, MD, PhD, Department of Surgery, Institute of Health Biosciences, The University of Tokushima Graduate School, 3-18-15 Kuramoto, Tokushima 770-8503, Japan

Justin H Nguyen, MD, Division of Transplant Sugery, Mayo Clinic, 4205 Belfort Road, Suite 1100, Jacksonville, FL 32256, United States

Robert D Odze, MD, FRCPc, Chief, Gastrointestinal Pathology Service, Associate Professor of Pathology, Brigham and Women's Hospital, Harvard Medical School, Boston, MA, United States

Satoshi Osawa, MD, First Department of Medicine, Hamamatsu University School of Medicine, 1-20-1 Handayama, Hamamatsu, 431-3192, Japan

Alberto Quaglia, MD, PhD, FRCPath, Institute of Liver Studies, King's College Hospital, Denmark Hill, London SE5 9RS, United Kingdom

Juhani Sand, MD, PhD, Director, Division of Surgery, Gastroenterology and Oncology, Tampere University Hospital, PO Box 2000, 33521 Tampere, Finland

Mitchell L Shiffman, MD, Chief, Hepatology Section, Virginia Commonwealth University Medical Center, Box 980341, Richmond, VA 23298, United States

Bronislaw L Slomiany, PhD, Professor, Research Center, C-875, UMDNJ-NJ Dental School, 110 Bergen Street, PO Box 1709, Newark, NJ 07103-2400, United States

Shoichiro Sumi, MD, PhD, Associate Professor, Department of Organ Reconstruction, Institute for Frontier Medical Sciences, Kyoto University, Sakyo-ku, Kyoto, 606-8507, Japan

Zsuzsa Szondy, Professor, Department of Biochemistry and Molecular Biology, University of Debrecen, Nagyerdei krt. 98., Debrecen H-4012, Hungary

Kazunari Tominaga, MD, Department Of Gastroenterology, Osaka City University, 1-4-3 Asahimachi Abenoku, Osaka 545-8585, Japan

Masahito Uemura, MD, Associate Professor, Third Department of Internal Medicine, Nara Medical University, Shijo-cho, 840, Kashihara, Nara 634-8522, Japan

Gabor Veres, MD, Assistant Professor, First Department of Pediatrics, Semmelweis Medical University, Bókay street. 53, Budapest 1083, Hungary

World Journal of Gastroenterology

Online Submissions: http://www.wjgnet.com/1007-9327office
wjg@wjgnet.com
www.wjgnet.com

World J Gastroenterol 2010 July 14; 16(26): I
ISSN 1007-9327 (print)
© 2010 Baishideng. All rights reserved.

Meetings

Events Calendar 2010

January 25-26
Tamilnadu, India
International Conference on Medical Negligence and Litigation in Medical Practice

January 25-29
Waikoloa, HI, United States
Selected Topics in Internal Medicine

January 26-27
Dubai, United Arab Emirates
2nd Middle East Gastroenterology Conference

January 28-30
Hong Kong, China
The 1st International Congress on Abdominal Obesity

February 11-13
Fort Lauderdale, FL, United States
21th Annual International Colorectal Disease Symposium

February 26-28
Carolina, United States
First Symposium of GI Oncology at The Caribbean

March 04-06
Bethesda, MD, United States
8th International Symposium on Targeted Anticancer Therapies

March 05-07
Peshawar, Pakistan
26th Pakistan Society of Gastroenterology & Endoscopy Meeting

March 09-12
Brussels, Belgium
30th International Symposium on Intensive Care and Emergency Medicine

March 12-14
Bhubaneswar, India
18th Annual Meeting of Indian National Association for Study of the Liver

March 23-26
Cairo, Egypt
14th Pan Arab Conference on Diabetes PACD14

March 25-28
Beijing, China
The 20th Conference of the Asian Pacific Association for the Study of the Liver

March 27-28
San Diego, California, United States
25th Annual New Treatments in Chronic Liver Disease

April 07-09
Dubai, United Arab Emirates
The 6th Emirates Gastroenterology and Hepatology Conference, EGHC 2010

April 14-17
Landover, Maryland, United States
12th World Congress of Endoscopic Surgery

April 14-18
Vienna, Austria
The International Liver Congress™ 2010

April 28-May 01
Dubrovnik, Croatia
3rd Central European Congress of surgery and the 5th Croatian Congress of Surgery

May 01-05
New Orleans, LA, United States
Digestive Disease Week Annual Meeting

May 06-08
Munich, Germany
The Power of Programming: International Conference on Developmental Origins of Health and Disease

May 15-19
Minneapolis, MN, United States
American Society of Colon and Rectal Surgeons Annual Meeting

June 04-06
Chicago, IL, United States
American Society of Clinical Oncologists Annual Meeting

June 09-12
Singapore, Singapore
13th International Conference on Emergency Medicine

June 14
Kosice, Slovakia
Gastro-intestinal Models in the Research of Probiotics and Prebiotics-Scientific Symposium

June 16-19
Hong Kong, China
ILTS: International Liver Transplantation Society ILTS Annual International Congress

June 20-23
Mannheim, Germany
16th World Congress for Bronchoesophagology-WCBE

June 25-29
Orlando, FL, United States
70th ADA Diabetes Scientific Sessions

August 28-31
Boston, Massachusetts, United States
10th OESO World Congress on Diseases of the Oesophagus 2010

September 10-12
Montreal, Canada
International Liver Association's Fourth Annual Conference

September 11-12
La Jolla, CA, United States
New Advances in Inflammatory Bowel Disease

September 12-15
Boston, MA, United States
ICAAC: Interscience Conference on Antimicrobial Agents and Chemotherapy Annual Meeting

September 16-18
Prague, Czech Republic
Prague Hepatology Meeting 2010

September 23-26
Prague, Czech Republic
The 1st World Congress on Controversies in Gastroenterology & Liver Diseases

October 07-09
Belgrade, Serbia
The 7th Biannual International Symposium of Society of Coloproctology

October 15-20
San Antonio, TX, United States
ACG 2010: American College of Gastroenterology Annual Scienitfic Meeting

October 23-27
Barcelona, Spain
18th United European Gastroenterology Week

October 29-November 02
Boston, Massachusetts, United States
The Liver Meeting® 2010--AASLD's 61st Annual Meeting

November 13-14
San Francisco, CA, United States
Case-Based Approach to the Management of Inflammatory Bowel Disease

December 02-04
San Francisco, CA, United States
The Medical Management of HIV/AIDS

World Journal of Gastroenterology

Online Submissions: http://www.wjgnet.com/1007-9327office
wjg@wjgnet.com
www.wjgnet.com

World J Gastroenterol 2010 July 14; 16(26): I-IV
ISSN 1007-9327 (print)
© 2010 Baishideng. All rights reserved.

Instructions to authors

GENERAL INFORMATION

World Journal of Gastroenterology (*World J Gastroenterol*, *WJG*, print ISSN 1007-9327, DOI: 10.3748) is a weekly, open-access (OA), peer-reviewed journal supported by an editorial board of 1144 experts in gastroenterology and hepatology from 60 countries.

The biggest advantage of the OA model is that it provides free, full-text articles in PDF and other formats for experts and the public without registration, which eliminates the obstacle that traditional journals possess and usually delays the speed of the propagation and communication of scientific research results. The open access model has been proven to be a true approach that may achieve the ultimate goal of the journals, i.e. the maximization of the value to the readers, authors and society.

The role of academic journals is to exhibit the scientific levels of a country, a university, a center, a department, and even a scientist, and build an important bridge for communication between scientists and the public. As we all know, the significance of the publication of scientific articles lies not only in disseminating and communicating innovative scientific achievements and academic views, as well as promoting the application of scientific achievements, but also in formally recognizing the "priority" and "copyright" of innovative achievements published, as well as evaluating research performance and academic levels. So, to realize these desired attributes of *WJG* and create a well-recognized journal, the following four types of personal benefits should be maximized. The maximization of personal benefits refers to the pursuit of the maximum personal benefits in a well-considered optimal manner without violation of the laws, ethical rules and the benefits of others. (1) Maximization of the benefits of editorial board members: The primary task of editorial board members is to give a peer review of an unpublished scientific article via online office system to evaluate its innovativeness, scientific and practical values and determine whether it should be published or not. During peer review, editorial board members can also obtain cutting-edge information in that field at first hand. As leaders in their field, they have priority to be invited to write articles and publish commentary articles. We will put peer reviewers' names and affiliations along with the article they reviewed in the journal to acknowledge their contribution; (2) Maximization of the benefits of authors: Since *WJG* is an open-access journal, readers around the world can immediately download and read, free of charge, high-quality, peer-reviewed articles from *WJG* official website, thereby realizing the goals and significance of the communication between authors and peers as well as public reading; (3) Maximization of the benefits of readers: Readers can read or use, free of charge, high-quality peer-reviewed articles without any limits, and cite the arguments, viewpoints, concepts, theories, methods, results, conclusion or facts and data of pertinent literature so as to validate the innovativeness, scientific and practical values of their own research achievements, thus ensuring that their articles have novel arguments or viewpoints, solid evidence and correct conclusion; and (4) Maximization of the benefits of employees: It is an iron law that a first-class journal is unable to exist without first-class editors, and only first-class editors can create a first-class academic journal. We insist on strengthening our team cultivation and construction so that every employee, in an open, fair and transparent environment, could contribute their wisdom to edit and publish high-quality articles, thereby realizing the maximization of the personal benefits of editorial board members, authors and readers, and yielding the greatest social and economic benefits.

The major task of *WJG* is to report rapidly the most recent results in basic and clinical research on esophageal, gastrointestinal, liver, pancreas and biliary tract diseases, *Helicobacter pylori*, endoscopy and gastrointestinal surgery, including: gastroesophageal reflux disease, gastrointestinal bleeding, infection and tumors; gastric and duodenal disorders; intestinal inflammation, microflora and immunity; celiac disease, dyspepsia and nutrition; viral hepatitis, portal hypertension, liver fibrosis, liver cirrhosis, liver transplantation, and metabolic liver disease; molecular and cell biology; geriatric and pediatric gastroenterology; diagnosis and screening, imaging and advanced technology.

The columns in the issues of *WJG* will include: (1) Editorial: To introduce and comment on major advances and developments in the field; (2) Frontier: To review representative achievements, comment on the state of current research, and propose directions for future research; (3) Topic Highlight: This column consists of three formats, including (A) 10 invited review articles on a hot topic, (B) a commentary on common issues of this hot topic, and (C) a commentary on the 10 individual articles; (4) Observation: To update the development of old and new questions, highlight unsolved problems, and provide strategies on how to solve the questions; (5) Guidelines for Basic Research: To provide guidelines for basic research; (6) Guidelines for Clinical Practice: To provide guidelines for clinical diagnosis and treatment; (7) Review: To review systemically progress and unresolved problems in tahe field, comment on the state of current research, and make suggestions for future work; (8) Original Article: To report innovative and original findings in gastroenterology; (9) Brief Article: To briefly report the novel and innovative findings in gastroenterology and hepatology; (10) Case Report: To report a rare or typical case; (11) Letters to the Editor: To discuss and make reply to the contributions published in *WJG*, or to introduce and comment on a controversial issue of general interest; (12) Book Reviews: To introduce and comment on quality monographs of gastroenterology and hepatology; and (13) Guidelines: To introduce consensuses and guidelines reached by international and national academic authorities worldwide on basic research and clinical practice gastroenterology and hepatology.

CSSN

ISSN 1007-9327 (print)
CN 14-1219/R

Indexed and Abstracted in

Current Contents®/Clinical Medicine, Science Citation Index Expanded (also known as SciSearch®), Journal Citation Reports®, Index Medicus, MEDLINE, PubMed, PubMed Central, Digital Object Identifer, and EMBASE/Excerpta Medica. ISI, Thomson Reuters, 2009 Impact Factor: 2.092 (33/65 Gastroenterology and Hepatology).

Published by

Beijing Baishideng BioMed Scientific Co., Ltd.

SUBMISSION OF MANUSCRIPTS

Manuscripts should be typed in 1.5 line spacing and 12 pt. Book Antiqua with ample margins. Number all pages consecutively, and start each of the following sections on a new page: Title Page,

Abstract, Introduction, Materials and Methods, Results, Discussion, Acknowledgements, References, Tables, Figures, and Figure Legends. Neither the editors nor the publisher are responsible for the opinions expressed by contributors. Manuscripts formally accepted for publication become the permanent property of Beijing Baishideng BioMed Scientific Co., Ltd, and may not be reproduced by any means, in whole or in part, without the written permission of both the authors and the publisher. We reserve the right to copy-edit and put onto our website accepted manuscripts. Authors should follow the relevant guidelines for the care and use of laboratory animals of their institution or national animal welfare committee. For the sake of transparency in regard to the performance and reporting of clinical trials, we endorse the policy of the International Committee of Medical Journal Editors to refuse to publish papers on clinical trial results if the trial was not recorded in a publicly-accessible registry at its outset. The only register now available, to our knowledge, is http://www. clinicaltrials.gov sponsored by the United States National Library of Medicine and we encourage all potential contributors to register with it. However, in the case that other registers become available you will be duly notified. A letter of recommendation from each author's organization should be provided with the contributed article to ensure the privacy and secrecy of research is protected.

Authors should retain one copy of the text, tables, photographs and illustrations because rejected manuscripts will not be returned to the author(s) and the editors will not be responsible for loss or damage to photographs and illustrations sustained during mailing.

Online submissions

Manuscripts should be submitted through the Online Submission System at: http://www.wjgnet.com/1007-9327office. Authors are highly recommended to consult the ONLINE INSTRUCTIONS TO AUTHORS (http://www.wjgnet.com/1007-9327/g_info_20100315215714.htm) before attempting to submit online. For assistance, authors encountering problems with the Online Submission System may send an email describing the problem to wjg@wjgnet.com, or by telephone: +86-10-5908-0039. If you submit your manuscript online, do not make a postal contribution. Repeated online submission for the same manuscript is strictly prohibited.

MANUSCRIPT PREPARATION

All contributions should be written in English. All articles must be submitted using word-processing software. All submissions must be typed in 1.5 line spacing and 12 pt. Book Antiqua with ample margins. Style should conform to our house format. Required information for each of the manuscript sections is as follows:

Title page

Title: Title should be less than 12 words.

Running title: A short running title of less than 6 words should be provided.

Authorship: Authorship credit should be in accordance with the standard proposed by International Committee of Medical Journal Editors, based on (1) substantial contributions to conception and design, acquisition of data, or analysis and interpretation of data; (2) drafting the article or revising it critically for important intellectual content; and (3) final approval of the version to be published. Authors should meet conditions 1, 2, and 3.

Institution: Author names should be given first, then the complete name of institution, city, province and postcode. For example, Xu-Chen Zhang, Li-Xin Mei, Department of Pathology, Chengde Medical College, Chengde 067000, Hebei Province, China. One author may be represented from two institutions, for example, George Sgourakis, Department of General, Visceral, and Transplantation Surgery, Essen 45122, Germany; George Sgourakis, 2nd Surgical Department, Korgialenio-Benakio Red Cross Hospital, Athens 15451, Greece

Author contributions: The format of this section should be: Author contributions: Wang CL and Liang L contributed equally to this work; Wang CL, Liang L, Fu JF, Zou CC, Hong F and Wu XM designed the research; Wang CL, Zou CC, Hong F and Wu XM performed the research; Xue JZ and Lu JR contributed new reagents/analytic tools; Wang CL, Liang L and Fu JF analyzed the data; and Wang CL, Liang L and Fu JF wrote the paper.

Supportive foundations: The complete name and number of supportive foundations should be provided, e.g., Supported by National Natural Science Foundation of China, No. 30224801

Correspondence to: Only one corresponding address should be provided. Author names should be given first, then author title, affiliation, the complete name of institution, city, postcode, province, country, and email. All the letters in the email should be in lower case. A space interval should be inserted between country name and email address. For example, Montgomery Bissell, MD, Professor of Medicine, Chief, Liver Center, Gastroenterology Division, University of California, Box 0538, San Francisco, CA 94143, United States. montgomery.bissell@ucsf.edu

Telephone and fax: Telephone and fax should consist of +, country number, district number and telephone or fax number, e.g., Telephone: +86-10-59080039 Fax: +86-10-85381893

Peer reviewers: All articles received are subject to peer review. Normally, three experts are invited for each article. Decision for acceptance is made only when at least two experts recommend an article for publication. Reviewers for accepted manuscripts are acknowledged in each manuscript, and reviewers of articles which were not accepted will be acknowledged at the end of each issue. To ensure the quality of the articles published in *WJG*, reviewers of accepted manuscripts will be announced by publishing the name, title/position and institution of the reviewer in the footnote accompanying the printed article. For example, reviewers: Professor Jing-Yuan Fang, Shanghai Institute of Digestive Disease, Shanghai, Affiliated Renji Hospital, Medical Faculty, Shanghai Jiaotong University, Shanghai, China; Professor Xin-Wei Han, Department of Radiology, The First Affiliated Hospital, Zhengzhou University, Zhengzhou, Henan Province, China; and Professor Anren Kuang, Department of Nuclear Medicine, Huaxi Hospital, Sichuan University, Chengdu, Sichuan Province, China.

Abstract

There are unstructured abstracts (no more than 256 words) and structured abstracts (no more than 480). The specific requirements for structured abstracts are as follows:

An informative, structured abstracts of no more than 480 words should accompany each manuscript. Abstracts for original contributions should be structured into the following sections. AIM (no more than 20 words): Only the purpose should be included. Please write the aim as the form of "To investigate/study/…; MATERIALS AND METHODS (no more than 140 words); RESULTS (no more than 294 words): You should present *P* values where appropriate and must provide relevant data to illustrate how they were obtained, e.g. 6.92 ± 3.86 *vs* 3.61 ± 1.67, $P < 0.001$; CONCLUSION (no more than 26 words).

Key words

Please list 5-10 key words, selected mainly from *Index Medicus*, which reflect the content of the study.

Text

For articles of these sections, original articles, rapid communication and case reports, the main text should be structured into the following sections: INTRODUCTION, MATERIALS AND METHODS, RESULTS and DISCUSSION, and should include appropriate Figures and Tables. Data should be presented in the main text or in Figures and Tables, but not in both. The main text format of these sections, editorial, topic highlight, case

report, letters to the editors, can be found at: http://www.wjgnet.com/1007-9327/g_info_20100315215714.htm.

Illustrations

Figures should be numbered as 1, 2, 3, *etc.*, and mentioned clearly in the main text. Provide a brief title for each figure on a separate page. Detailed legends should not be provided under the figures. This part should be added into the text where the figures are applicable. Figures should be either Photoshop or Illustrator files (in tiff, eps, jpeg formats) at high-resolution. Examples can be found at: http://www.wjgnet.com/1007-9327/13/4520.pdf; http://www.wjgnet.com/1007-9327/13/4554.pdf; http://www.wjgnet.com/1007-9327/13/4891.pdf; http://www.wjgnet.com/1007-9327/13/4986.pdf; http://www.wjgnet.com/1007-9327/13/4498.pdf. Keeping all elements compiled is necessary in line-art image. Scale bars should be used rather than magnification factors, with the length of the bar defined in the legend rather than on the bar itself. File names should identify the figure and panel. Avoid layering type directly over shaded or textured areas. Please use uniform legends for the same subjects. For example: Figure 1 Pathological changes in atrophic gastritis after treatment. A:...; B:...; C:...; D:...; E:...; F:...; G: …*etc.* It is our principle to publish high resolution-figures for the printed and E-versions.

Tables

Three-line tables should be numbered 1, 2, 3, *etc.*, and mentioned clearly in the main text. Provide a brief title for each table. Detailed legends should not be included under tables, but rather added into the text where applicable. The information should complement, but not duplicate the text. Use one horizontal line under the title, a second under column heads, and a third below the Table, above any footnotes. Vertical and italic lines should be omitted.

Notes in tables and illustrations

Data that are not statistically significant should not be noted. $^{a}P < 0.05$, $^{b}P < 0.01$ should be noted ($P > 0.05$ should not be noted). If there are other series of P values, $^{c}P < 0.05$ and $^{d}P < 0.01$ are used. A third series of P values can be expressed as $^{e}P < 0.05$ and $^{f}P < 0.01$. Other notes in tables or under illustrations should be expressed as ^{1}F, ^{2}F, ^{3}F; or sometimes as other symbols with a superscript (Arabic numerals) in the upper left corner. In a multi-curve illustration, each curve should be labeled with ●, ○, ■, □, ▲, △, *etc.*, in a certain sequence.

Acknowledgments

Brief acknowledgments of persons who have made genuine contributions to the manuscript and who endorse the data and conclusions should be included. Authors are responsible for obtaining written permission to use any copyrighted text and/or illustrations.

REFERENCES

Coding system

The author should number the references in Arabic numerals according to the citation order in the text. Put reference numbers in square brackets in superscript at the end of citation content or after the cited author's name. For citation content which is part of the narration, the coding number and square brackets should be typeset normally. For example, "Crohn's disease (CD) is associated with increased intestinal permeability[1,2]". If references are cited directly in the text, they should be put together within the text, for example, "From references[19,22-24], we know that..."

When the authors write the references, please ensure that the order in text is the same as in the references section, and also ensure the spelling accuracy of the first author's name. Do not list the same citation twice.

PMID and DOI

Pleased provide PubMed citation numbers to the reference list, e.g. PMID and DOI, which can be found at http://www.ncbi.nlm.nih.gov/sites/entrez?db=pubmed and http://www.crossref.org/SimpleTextQuery/, respectively. The numbers will be used in E-version of this journal.

Style for journal references

Authors: the name of the first author should be typed in bold-faced letters. The family name of all authors should be typed with the initial letter capitalized, followed by their abbreviated first and middle initials. (For example, Lian-Sheng Ma is abbreviated as Ma LS, Bo-Rong Pan as Pan BR). The title of the cited article and italicized journal title (journal title should be in its abbreviated form as shown in PubMed), publication date, volume number (in black), start page, and end page [PMID: 11819634 DOI: 10.3748/wjg.13.5396].

Style for book references

Authors: the name of the first author should be typed in bold-faced letters. The surname of all authors should be typed with the initial letter capitalized, followed by their abbreviated middle and first initials. (For example, Lian-Sheng Ma is abbreviated as Ma LS, Bo-Rong Pan as Pan BR) Book title. Publication number. Publication place: Publication press, Year: start page and end page.

Format

Journals

English journal article (list all authors and include the PMID where applicable)

1 **Jung EM**, Clevert DA, Schreyer AG, Schmitt S, Rennert J, Kubale R, Feuerbach S, Jung F. Evaluation of quantitative contrast harmonic imaging to assess malignancy of liver tumors: A prospective controlled two-center study. *World J Gastroenterol* 2007; **13**: 6356-6364 [PMID: 18081224 DOI: 10.3748/wjg.13.6356]

Chinese journal article (list all authors and include the PMID where applicable)

2 **Lin GZ**, Wang XZ, Wang P, Lin J, Yang FD. Immunologic effect of Jianpi Yishen decoction in treatment of Pixu-diarrhoea. *Shijie Huaren Xiaohua Zazhi* 1999; **7**: 285-287

In press

3 **Tian D**, Araki H, Stahl E, Bergelson J, Kreitman M. Signature of balancing selection in Arabidopsis. *Proc Natl Acad Sci USA* 2006; In press

Organization as author

4 **Diabetes Prevention Program Research Group**. Hypertension, insulin, and proinsulin in participants with impaired glucose tolerance. *Hypertension* 2002; **40**: 679-686 [PMID: 12411462 PMCID:2516377 DOI:10.1161/01.HYP.0000035706.28494.09]

Both personal authors and an organization as author

5 **Vallancien G**, Emberton M, Harving N, van Moorselaar RJ; Alf-One Study Group. Sexual dysfunction in 1, 274 European men suffering from lower urinary tract symptoms. *J Urol* 2003; **169**: 2257-2261 [PMID: 12771764 DOI:10.1097/01.ju.0000067940.76090.73]

No author given

6 21st century heart solution may have a sting in the tail. *BMJ* 2002; **325**: 184 [PMID: 12142303 DOI:10.1136/bmj.325.7357.184]

Volume with supplement

7 **Geraud G**, Spierings EL, Keywood C. Tolerability and safety of frovatriptan with short- and long-term use for treatment of migraine and in comparison with sumatriptan. *Headache* 2002; **42** Suppl 2: S93-99 [PMID: 12028325 DOI:10.1046/j.1526-4610.42.s2.7.x]

Issue with no volume

8 **Banit DM**, Kaufer H, Hartford JM. Intraoperative frozen section analysis in revision total joint arthroplasty. *Clin Orthop Relat Res* 2002; (**401**): 230-238 [PMID: 12151900 DOI:10.1097/00003086-200208000-00026]

No volume or issue

9 Outreach: Bringing HIV-positive individuals into care. *HRSA Careaction* 2002; 1-6 [PMID: 12154804]

Books

Personal author(s)

10 **Sherlock S**, Dooley J. Diseases of the liver and billiary system. 9th ed. Oxford: Blackwell Sci Pub, 1993: 258-296

Chapter in a book (list all authors)

11 **Lam SK**. Academic investigator's perspectives of medical treatment for peptic ulcer. In: Swabb EA, Azabo S. Ulcer disease: investigation and basis for therapy. New York: Marcel Dekker, 1991: 431-450

Author(s) and editor(s)

12 **Breedlove GK**, Schorfheide AM. Adolescent pregnancy. 2nd ed. Wieczorek RR, editor. White Plains (NY): March of Dimes Education Services, 2001: 20-34

Conference proceedings

13 **Harnden P**, Joffe JK, Jones WG, editors. Germ cell tumours V. Proceedings of the 5th Germ cell tumours Conference; 2001 Sep 13-15; Leeds, UK. New York: Springer, 2002: 30-56

Conference paper

14 **Christensen S**, Oppacher F. An analysis of Koza's computational effort statistic for genetic programming. In: Foster JA, Lutton E, Miller J, Ryan C, Tettamanzi AG, editors. Genetic programming. EuroGP 2002: Proceedings of the 5th European Conference on Genetic Programming; 2002 Apr 3-5; Kinsdale, Ireland. Berlin: Springer, 2002: 182-191

Electronic journal (list all authors)

15 Morse SS. Factors in the emergence of infectious diseases. Emerg Infect Dis serial online, 1995-01-03, cited 1996-06-05; 1(1): 24 screens. Available from: URL: http//www.cdc.gov/ncidod/EID/eid.htm

Patent (list all authors)

16 **Pagedas AC**, inventor; Ancel Surgical R&D Inc., assignee. Flexible endoscopic grasping and cutting device and positioning tool assembly. United States patent US 20020103498. 2002 Aug 1

Statistical data

Write as mean ± SD or mean ± SE.

Statistical expression

Express *t* test as *t* (in italics), *F* test as *F* (in italics), chi square test as χ^2 (in Greek), related coefficient as *r* (in italics), degree of freedom as υ (in Greek), sample number as *n* (in italics), and probability as *P* (in italics).

Units

Use SI units. For example: body mass, m (B) = 78 kg; blood pressure, p (B) = 16.2/12.3 kPa; incubation time, t (incubation) = 96 h, blood glucose concentration, c (glucose) 6.4 ± 2.1 mmol/L; blood CEA mass concentration, p (CEA) = 8.6 24.5 μg/L; CO_2 volume fraction, 50 mL/L CO_2, not 5% CO_2; likewise for 40 g/L formaldehyde, not 10% formalin; and mass fraction, 8 ng/g, *etc.* Arabic numerals such as 23, 243, 641 should be read 23 243 641.

The format for how to accurately write common units and quantums can be found at: http://www.wjgnet.com/1007-9327/g_info_20100315223018.htm.

Abbreviations

Standard abbreviations should be defined in the abstract and on first mention in the text. In general, terms should not be abbreviated unless they are used repeatedly and the abbreviation is helpful to the reader. Permissible abbreviations are listed in Units, Symbols and Abbreviations: A Guide for Biological and Medical Editors and Authors (Ed. Baron DN, 1988) published by The Royal Society of Medicine, London. Certain commonly used abbreviations, such as DNA, RNA, HIV, LD50, PCR, HBV, ECG, WBC, RBC, CT, ESR, CSF, IgG, ELISA, PBS, ATP, EDTA, mAb, can be used directly without further explanation.

Italics

Quantities: *t* time or temperature, *c* concentration, *A* area, *l* length, *m* mass, *V* volume.

Genotypes: *gyrA*, *arg* 1, *c myc*, *c fos*, *etc.*

Restriction enzymes: *Eco*RI, *Hin*dI, *Bam*HI, *Kbo* I, *Kpn* I, *etc.*

Biology: *H. pylori*, *E coli*, *etc.*

RESUBMISSION OF THE REVISED MANUSCRIPTS

Please revise your article according to the revision policies of *WJG*. The revised version includes manuscript and high-resolution image figures. The author should re-submit the revised manuscript online, along with printed high-resolution color or black and white photos; Copyright transfer letter, and responses to the reviewers, and science news are sent to us *via* email.

Editorial Office

World Journal of Gastroenterology

Editorial Department: Room 903, Building D,
Ocean International Center,
No. 62 Dongsihuan Zhonglu,
Chaoyang District, Beijing 100025, China
E-mail: wjg@wjgnet.com
http://www.wjgnet.com
Telephone: +86-10-5908-0039
Fax: +86-10-85381893

Language evaluation

The language of a manuscript will be graded before it is sent for revision. (1) Grade A: priority publishing; (2) Grade B: minor language polishing; (3) Grade C: a great deal of language polishing needed; and (4) Grade D: rejected. Revised articles should reach Grade A or B.

Copyright assignment form

Please download a Copyright assignment form from http://www.wjgnet.com/1007-9327/g_info_20100315222818.htm.

Responses to reviewers

Please revise your article according to the comments/suggestions provided by the reviewers. The format for responses to the reviewers' comments can be found at: http://www.wjgnet.com/1007-9327/g_info_20100315222607.htm.

Proof of financial support

For paper supported by a foundation, authors should provide a copy of the document and serial number of the foundation.

Science news releases

Authors of accepted manuscripts are suggested to write a science news item to promote their articles. The news will be released rapidly at EurekAlert/AAAS (http://www.eurekalert.org). The title for news items should be less than 90 characters; the summary should be less than 75 words; and main body less than 500 words. Science news items should be lawful, ethical, and strictly based on your original content with an attractive title and interesting pictures.

Publication fee

Authors of accepted articles must pay a publication fee.
EDITORIAL, TOPIC HIGHLIGHTS, BOOK REVIEWS and LETTERS TO THE EDITOR are published free of charge.