World Journal of Gastroenterology®

Volume 12 Number 31
August 21, 2006

Supported by NSFC
2005-2006

National Journal Award
2005

The WJG Press

The WJG Press, Apartment 1066 Yishou Garden, 58 North
Langxinzhuang Road, PO Box 2345, Beijing 100023, China
Telephone: +86-10-85381901
Fax: +86-10-85381893
E-mail: wjg@wjgnet.com
http: //www.wjgnet.com

ISSN 1007-9327 CN 14-1219/R Local Post Offices Code No. 82-261

World Journal of Gastroenterology www.wjgnet.com Volume 12 Number 31 Aug 21 2006

ISSN 1007-9327
CN 14-1219/R

World Journal of Gastroenterology®

Indexed and Abstracted in:
Current Contents/Clinical Medicine and Science Citation Index-Expanded, Index Medicus, MEDLINE and PubMed, Chemical Abstracts, EMBASE/Excerpta Medica, Abstracts Journals, Nature Clinical Practice Gastroenterology and Hepatology, CAB Abstracts and Global Health.
ISI JCR 2003-2000 IF: 3.318, 2.532, 1.445 and 0.993.

Volume 12 Number 31
August 21, 2006

World J Gastroenterol
2006 August 21; 12(31): 4937-5100

Online Submissions
www.wjgnet.com/wjg/index.jsp
www.wjgnet.com
Printed on Acid-free Paper

A Weekly Journal of Gastroenterology and Hepatology

World Journal of Gastroenterology®

National Journal Award 2005

Volume 12 Number 31
August 21, 2006

Supported by NSFC 2005-2006

Contents

EDITORIAL

4937 Post-transcriptional regulation of vascular endothelial growth factor: Implications for tumor angiogenesis
Yoo PS, Mulkeen AL, Cha CH

TOPIC HIGHLIGHT

4943 Hereditary non-polyposis colorectal cancer: The rise and fall of a confusing term
Jass JR

REVIEW

4951 Insights on augmenter of liver regeneration cloning and function
Gatzidou E, Kouraklis G, Theocharis S

GASTRIC CANCER

4959 Differential expression of apoptosis related proteins and nitric oxide synthases in Epstein Barr associated gastric carcinomas
Begnami MD, Montagnini AL, Vettore AL, Nonogaki S, Brait M, Simoes-Sato AY, Seixas AQA, Soares FA

LIVER CANCER

4966 Dynamic alteration of telomerase expression and its diagnostic significance in liver or peripheral blood for hepatocellular carcinoma
Yao DF, Wu W, Yao M, Qiu LW, Wu XH, Su XQ, Zou L, Yao DB, Meng XY

COLORECTAL CANCER

4973 Analysis of differentially expressed proteins in cancerous and normal colonic tissues
Gam LH, Leow CH, Man CN, Gooi BH, Singh M

4981 Inhibitory effect of caffeic acid phenethyl ester on the growth of SW480 colorectal tumor cells involves β-catenin associated signaling pathway down-regulation
He YJ, Liu BH, Xiang DB, Qiao ZY, Fu T, He YH

VIRAL HEPATITIS

4986 Gene expression analysis of primary normal human hepatocytes infected with human hepatitis B virus
Ryu HM, Park SG, Yea SS, Jang WH, Yang YI, Jung G

BASIC RESEARCH

4996 Caffeic acid phenethyl ester modifies the Th1/Th2 balance in ileal mucosa after γ-irradiation in the rat by modulating the cytokine pattern
Grémy O, Benderitter M, Linard C

5005 Expression and significance of ICAM-1 and its counter receptors LFA-1 and Mac-1 in experimental acute pancreatitis of rats
Sun W, Watanabe Y, Wang ZQ

CLINICAL RESEARCH

5010 Comparison between empirical prokinetics, Helicobacter test-and-treat and empirical endoscopy in primary-care patients presenting with dyspepsia: A one-year study
Hu WHC, Lam SK, Lam CLK, Wong WM, Lam KF, Lai KC, Wong YH, Wong BCY, Chan AOO, Chan CK, Leung GM, Hui WM

RAPID COMMUNICATION

5017 Effects of chronic therapy with non-steroideal antinflammatory drugs on gastric permeability of sucrose: A study on 71 patients with rheumatoid arthritis
Maino M, Mantovani N, Merli R, Cavestro GM, Leandro G, Cavallaro LG, Corrente V, Iori V, Pilotto A , Franzè A, Di Mario F

5021 Administration of granulocyte colony stimulating factor after liver transplantation leads to an increased incidence and severity of ischemic biliary lesions in the rat model
Dirsch O, Chi H, Ji Y, Gu YL, Broelsch CE, Dahmen U

5028 Usefulness of duodenal biopsy during routine upper gastrointestinal endoscopy for diagnosis of celiac disease
Riestra S, Domínguez F, Fernández-Ruiz E, García-Riesco E, Nieto R, Fernández E, Rodrigo L

5033 Gastric cancer in a Caucasian population: Role of *pepsinogen C* genetic variants
Pinto-Correia AL, Sousa H, Fragoso M, Moreira-Dias L, Lopes C, Medeiros R, Dinis-Ribeiro M

5037 Relation between common polymorphisms in genes related to inflammatory response and colorectal cancer
Theodoropoulos G, Papaconstantinou I, Felekouras E, Nikiteas N, Karakitsos P, Panoussopoulos D, Ch Lazaris A, Patsouris E, Bramis J, Gazouli M

5044 Polymorphisms of interleukin-1R receptor antagonist genes in patients with chronic hepatitis B in Iran
Ranjbar M, Mohammad Alizadeh AH, Hajilooi M, Mousavi SM

5048 Occult hepatitis B virus infection and cryptogenic chronic hepatitis in an area with intermediate prevalence of HBV infection
Kaviani MJ, Behbahani B, Mosallaii MJ, Sari-Aslani F, Taghavi SA

5051 Differentiation of rat bone marrow stem cells in liver after partial hepatectomy
Zhan YT, Wang Y, Wei L, Liu B, Chen HS, Cong X, Fei R

5055 Preoperative risk factor analysis in orthotopic liver transplant-ation with pretransplant artificial liver support therapy
Yuan JZ, Ye QF, Zhao LL, Ming YZ, Sun H, Zhu SH, Huang ZF, Wang MM

5060 Comparison of therapeutic effectiveness of combined interventional therapy for 1126 cases of primary liver cancer
Liu YM, Qin H, Wang CB, Fang XH, Ma QY

5064 Primary pancreatic lymphoma: Report of six cases
Lin H, Li SD, Hu XG, Li ZS

5068 Indwelling catheter and conservative measures in the treatment of abdominal compartment syndrome in fulminant acute pancreatitis
Sun ZX, Huang HR, Zhou H

CASE REPORTS

5071 Transhepatic catheter-directed thrombolysis for portal vein thrombosis after partial splenic embolization in combination with balloon-occluded retrograde transvenous obliteration of splenorenal shunt
Nakai M, Sato M, Sahara S, Kawai N, Kimura M, Maeda Y, Ibata Y, Higashi K

5075 Clinical evaluation of submucosal colonic lipomas: Decision making
Tascilar O, Cakmak GK, Gün BD, Uçan BH, Balbaloglu H, Cesur A, Emre AU, Comert M, Erdem LO, Aydemir S

5078 Adverse hepatic reactions associated with calcium carbimide and disulfiram therapy: Is there still a role for these drugs?
Verge C, Lucena MI, López-Torres E, Puche-García MJ, Fraga E, Romero-Gomez M, Andrade RJ

5081 Unusual prerectal location of a tailgut cyst: A case report
Jang SH, Jang KS, Song YS, Min KW, Han HX, Lee KG, Paik SS

5084 Cytomegalovirus ileitis in an immunocompetent elderly adult
Ryu KH, Yi SY

5087 Pseudoachalasia in a patient after truncal vagotomy surgery successfully treated by subsequent pneumatic dilations
Chuah SK, Kuo CM, Wu KL, Changchien CS, Hu TH, Wang CC, Chiu YC, Chou YP, Hsu PI, Chiu KW, Kuo CH, Chiou SS, Lee CM

World Journal of Gastroenterology
Volume 12 **Number** 31 **August** 21, 2006

Contents

	5091	Diabetes mellitus with hepatic infarction: A case report with literature review *Deng YG, Zhao ZS, Wang M, Su SO, Yao XX*
LETTERS TO THE EDITOR	**5094**	Obstructive jaundice leads to accumulation of oxidized low density lipoprotein in human liver tissue *Comert M, Ustundag Y, Tekin IO, Gun BD, Barut F*
ACKNOWLEDGMENTS	**5096**	Acknowledgments to Reviewers of *World Journal of Gastroenterology*
APPENDIX	**5097**	Meetings
	5098	Instructions to authors
FLYLEAF	I-V	Editorial Board
INSIDE FRONT COVER		Online Submissions
INSIDE BACK COVER		International Subscription

COPY EDITOR FOR THIS ISSUE: Dr. Richard Rippe

World Journal of Gastroenterology (*World J Gastroenterol* , *WJG*), a leading international journal in gastroenterology and hepatology, has an established reputation for publishing first class research on esophageal cancer, gastric cancer, liver cancer, viral hepatitis, colorectal cancer, and *Helicobacter pylori* infection, providing a forum for both clinicians and scientists, and has been indexed and abstracted in Current Contents/Clinical Medicine and Science Citation Index-Expanded, *Index Medicus*, MEDLINE and PubMed, Chemical Abstracts, EMBASE/Excerpta Medica, Abstracts Journals, Nature Clinical Practice Gastroenterology and Hepatology, CAB Abstracts and Global Health. ISI JCR 2003-2000 IF: 3.318, 2.532, 1.445 and 0.993. *WJG* is a weekly journal published by The *WJG* Press. The publication date is on 7th, 14th, 21st, and 28th every month. The *WJG* is supported by The National Natural Science Foundation of China, No. 30224801 and No.30424812, which was founded with a name of *China National Journal of New Gastroenterology* on October 1,1995, and renamed as *WJG* on January 25, 1998.

HONORARY EDITORS-IN-CHIEF
Ke-Ji Chen, *Beijing*
Li-Fang Chou, *Taipei*
Dai-Ming Fan, *Xi'an*
Zhi-Qiang Huang, *Beijing*
Shinn-Jang Hwang, *Taipei*
Min-Liang Kuo, *Taipei*
Nicholas F LaRusso, *Rochester*
Jie-Shou Li, *Nanjing*
Geng-Tao Liu, *Beijing*
Lein-Ray Mo, *Tainan*
Fa-Zu Qiu, *Wuhan*
Eamonn M Quigley, *Cork*
David S Rampton, *London*
Rudi Schmid, *California*
Nicholas J Talley, *Rochester*
Guido NJ Tytgat, *Amsterdam*
Jaw-Ching Wu, *Taipei*
Meng-Chao Wu, *Shanghai*
Ming-Shiang Wu, *Taipei*
Jia-Yu Xu, *Shanghai*
Hui Zhuang, *Beijing*

PRESIDENT AND EDITOR-IN-CHIEF
Lian-Sheng Ma, *Beijing*

EDITOR-IN-CHIEF
Bo-Rong Pan, *Xi'an*

ASSOCIATE EDITORS-IN-CHIEF
Gianfranco D Alpini, *Temple*
Bruno Annibale, *Roma*
Jordi Bruix, *Barcelona*
Roger William Chapman, *Oxford*
Alexander L Gerbes, *Munich*
Shou-Dong Lee, *Taipei*
Walter Edwin Longo, *New Haven*
You-Yong Lu, *Beijing*
Masao Omata, *Tokyo*
Harry H-X Xia, *Hong Kong*

SCIENCE EDITORS
Director: Jing Wang, *Beijing*
Deputy Director: Jian-Zhong Zhang, *Beijing*

LANGUAGE EDITORS
Director: Jing-Yun Ma, *Beijing*
Deputy Director: Xian-Lin Wang, *Beijing*

MEMBERS
Gianfranco D Alpini, *Temple*
Takafumi Ando, *Nagoya*
Kim Elaine Barrett, *San Diego*
Yogesh K Chawla, *Chandigarh*
Giuseppe Chiarioni, *Valeggio*
Zong-Jie Cui, *Beijing*
Khek-Yu Ho, *Singapor*
Atif Iqbal, *Omaha*
Sherif M Karam, *Al-Ain*
Manoj Kumar, *Kathmandu*
Peter Laszlo Lakatos, *Budapest*
Patricia F Lalor, *Birmingham*
Sabine Mihm, *Göttingen*
Sri Prakash Misra, *Allahabad*
Chris JJ Mulder, *Amsterdam*
Samuel Babafemi Olaleye, *Ibadan*
Bernardino Rampone, *Siena*
Richard Rippe, *Chapel Hill*
Manuel Romero-Gómez, *Sevilla*
Andreas G Schreyer, *Regensburg*
Francis Seow-Choen, *Singapore*
Daniel Lindsay Worthley, *Bedford*
Jing-Bo Zhao, *Aalborg*
Li-Hong Zhu, *Beijing*

ELECTRONICAL EDITORS
Director: Ming Zhang, *Beijing*
Executive E-editor for this issue: Wen-Feng Liu

COPY EDITORS
Gary A Abrams, *Birmingham*
Kim Elaine Barrett, *San Diego*
Filip Braet, *Sydney*
Mairi Brittan, *London*
Jiande Chen, *Galveston*
Wang-Xue Chen, *Ottawa*
Gérard Feldmann, *Paris*
Ignacio Gil-Bazo, *New York*
Hans Gregersen, *Aalborg*
Mario Guslandi, *Milano*
Atif Iqbal, *Omaha*
Ali Keshavarzian, *Chicago*
Shiu-Ming Kuo, *Buffalo*
Patricia F Lalor, *Birmingham*
James David Luketich, *Pittsburgh*
John Frank Di Mari, *Texas*
Satdarshan Singh Monga, *Pittsburgh*
Giuseppe Montalto, *Palermo*
Richard Rippe, *Chapel Hill*
Andreas G Schreyer, *Regensburg*
Simon D Taylor-Robinson, *London*
George Y Wu, *Farmington*

EDITORIAL ASSISTANT
Yan Jiang, *Beijing*

PUBLISHED BY
The WJG Press

PRINTED BY
Printed in Beijing on acid-free paper by Beijing Kexin Printing House

COPYRIGHT
© 2006 Published by The WJG Press. All rights reserved; no part of this publication may be reproduced, stored in a retrieval system, or transmitted in any form or by any means, electronic, mechanical, photocopying, recording, or otherwise without the prior permission of The *WJG* Press. Authors are required to grant *WJG* an exclusive licence to publish.
Print ISSN 1007-9327
CN 14-1219/R.

SPECIAL STATEMENT
All articles published in this journal represent the viewpoints of the authors except where indicated otherwise.

EDITORIAL OFFICE
World Journal of Gastroenterology,
The WJG Press, Apartment 1066 Yishou Garden, 58 North Langxinzhuang Road, PO Box 2345, Beijing 100023, China
Telephone: +86-10-85381901
Fax: +86-10-85381893
E-mail: wjg@wjgnet.com
http://www.wjgnet.com

SUBSCRIPTION AND AUTHOR REPRINTS
Jing Wang
The WJG Press, Apartment 1066 Yishou Garden, 58 North Langxinzhuang Road, PO Box 2345, Beijing 100023, China
Telephone: +86-10-85381901
Fax: +86-10-85381893
E-mail: j.wang@wjgnet.com
http://www.wjgnet.com

Institutional Rates
2006 rates: USD 1500.00

Personal Rates
2006 rates: USD 700.00

INSTRUCTIONS TO AUTHORS
Full instructions are available online at http://www.wjgnet.com/wjg/help/instructions.jsp. If you do not have web access please contact the editorial office.

PO Box 2345, Beijing 100023, China
www.wjgnet.com
wjg@wjgnet.com

World J Gastroenterol 2006 August 21; 12(31): 4937-4942
World Journal of Gastroenterology ISSN 1007-9327
© 2006 The WJG Press. All rights reserved.

EDITORIAL

Post-transcriptional regulation of vascular endothelial growth factor: Implications for tumor angiogenesis

Peter S Yoo, Abby L Mulkeen, Charles H Cha

Peter S Yoo, Abby L Mulkeen, Charles H Cha, Gastrointestinal Surgery and Surgical Oncology, Yale School of Medicine, New Haven, Connecticut, United States
Correspondence to: Charles H Cha, MD, Department of Surgery, Yale School of Medicine, 330 Cedar Street, LH 118, New Haven, CT 06520-8062, United States. charles.cha@yale.edu
Telephone: +1-203-7852380 Fax: +1-203-9373845
Received: 2005-12-01 Accepted: 2006-01-14

Abstract

Vascular endothelial growth factor (VEGF) is a potent secreted mitogen critical for physiologic and tumor angiogenesis. Regulation of VEGF occurs at several levels, including transcription, mRNA stabilization, translation, and differential cellular localization of various isoforms. Recent advances in our understanding of post-transcriptional regulation of VEGF include identification of the stabilizing mRNA binding protein, HuR, and the discovery of internal ribosomal entry sites in the 5'UTR of the VEGF mRNA. Monoclonal anti-VEGF antibody was recently approved for use in humans, but suffers from the need for high systemic doses. RNA interference (RNAi) technology is being used *in vitro* and in animal models with promising results. Here, we review the literature on post-transcriptional regulation of VEGF and describe recent progress in targeting these mechanisms for therapeutic benefit.

© 2006 The WJG Press. All rights reserved.

Key words: Vascular endothelial growth factor; Vascular endothelial growth hormone; Post-transcriptional regulation; mRNA stability; HuR; ELAV1; Internal ribosomal entry; IRES; siRNA; RNAi; Bevacizumab

Yoo PS, Mulkeen AL, Cha CH. Post-transcriptional regulation of vascular endothelial growth factor: Implications for tumor angiogenesis. *World J Gastroenterol* 2006; 12(31): 4937-4942

http://www.wjgnet.com/1007-9327/12/4937.asp

INTRODUCTION

The growth of any tissue *in vivo* relies on the adequacy of its vascular supply. Moreover, the notion of tumor angiogenesis, first advanced by Folkman in the early 1970s, posits that the growth of any tumor beyond 1-2 cubic centimeters depends on the growth of new blood supply[1]. In cases of insufficient vasculature, tissues become depleted of oxygen and nutrients, leading to the secretion of angiogenic factors[2]. These factors, which include hormones, interleukins, insulin, and growth factors, spur the ingrowth of new blood vessels. Vascular endothelial growth factor (VEGF) is one such key regulator of angiogenesis. It is a secreted mitogen and the most potent angiogenic factor, specific to endothelial cells and highly expressed in areas of active angiogenesis such as solid tumors.

The upregulation of VEGF expression in response to hypoxia plays a crucial role in tumor angiogenesis. Though it is not itself an oncogene, VEGF is upregulated in tumorigenesis and is important in blood vessel formation in solid tumors[3]. VEGF levels correlate with tumor progression and invasion, and a high VEGF level in colorectal carcinoma has been found to be an independent prognostic factor for long-term survival[4,5].

Hypoxic induction of VEGF appears to occur both by transcriptional activation and through stabilization of VEGF mRNA, which is otherwise labile in normoxic conditions. Transcriptional activation of VEGF relies largely on binding to the hypoxia inducible factor-1 (HIF-1), a heterodimeric basic helix-loop-helix protein that activates transcription of the human erythropoietin gene in hypoxic cells[6]. HIF-1 binds to a sequence in the 5'-flanking region of the VEGF gene called the hypoxic response element (HRE)[7-9]. Several other molecules have been implicated in the transcriptional control of VEGF. *Sp1* stimulates transcription by binding to G/C-rich boxes present on the VEGF promoter[10]. *AP-1* is a dimeric transcription factor of the leucine zipper family that is composed of jun/jun or jun/fos subunits. Hypoxia, oxidative stress, and cytokines may increase VEGF expression through the synthesis of jun and fos proteins and increased AP-1 binding activity. A number of other transcription factors also contribute to VEGF induction and regulation, including Stat-3[11].

Alternative splicing

In humans there are five alternatively spliced isoforms of VEGF, each is named for the number of amino acids along its length (VEGF 206, -189, -165, -145, 121). While varying amounts of each VEGF isoform mRNA can be generated to produce certain or all isoforms of VEGF[12],

each is predicted to have a characteristic extracellular localization based on biochemical differences. The larger isoforms bind neuropilin, matrix, and cell surface heparin proteoglycans, and are thought to act locally. The smaller isoforms do not display the heparin proteoglycan binding region and may diffuse to sites distant from the site of synthesis[13,14].

Post-transcriptional Regulation

A body of evidence is growing rapidly to demonstrate that post-transcriptional regulation of VEGF is critically important in the fine-tuned response required for both physiologic and malignant expression. The importance of post-transcriptional regulation of VEGF is based upon several key observations about the intrinsic nature of the VEGF mRNA. First, the mRNA is labile under conditions of normal oxygen tension[15]. Second, the 5' UTR of the VEGF mRNA possesses features that make efficient ribosome scanning and initiation of translation unwieldy.

Lability

Whereas the average half-life of eukaryotic mRNAs is 10-12 h, the half-life of VEGF mRNA is less than one hour[16]. In 1995, Ikeda and colleagues first reported that although VEGF levels were elevated in cells cultured in hypoxic conditions, transcriptional activation alone could not account for the increase in VEGF mRNA levels. Nuclear run-on assays demonstrated upregulation of VEGF transcription under hypoxia that was apparent after three hours, and persisted after fifteen hours of incubation. VEGF mRNA levels were 8-10 times higher than baseline, and this persistent elevation of VEGF could only be explained by increased stability of the mRNA. They concluded that hypoxia could lengthen the half-life of VEGF mRNA by 2-3 fold[7].

The effect of stabilization is mediated by the RNA-binding protein HuR. Steitz and colleagues first established the association between mRNA degradation and HuR, a member of the Elav family of proteins found in *Drosophila*[17]. Beginning with the observation that some mRNAs are targeted for rapid degradation by the presence of AU-rich elements (AREs) in the 3' UTRs, it was determined that HuR exhibits affinity for AREs, and levels of HuR correlate with *in vitro* mRNA degradation[18].

In VEGF, it was observed that the increase in mRNA stability coincided with the binding of a protein to an ARE, forming an RNA-protein complex in a hypoxia-inducible fashion[16]. Using a tumor cell line lacking the wild type von Hippel-Lindau tumor suppressor gene and in which VEGF mRNA is constitutively stabilized, this RNA-protein complex was found to be constitutively elevated[19]. The protein was later identified as the HuR protein[15]. Inhibition of HuR expression by antisense sequences was found to inhibit the hypoxic stabilization of VEGF mRNA, demonstrating its critical role in post-transcriptional stabilization of VEGF expression. However, total cellular steady-state HuR was not altered by hypoxia, raising the possibility that HuR is a component of a hypoxia-inducible complex whose other components are regulated by oxygen tension[15].

HuR probably has a function as a nuclear-cytoplasmic shuttle as well. It is predominantly localized to the nucleus, where it likely binds newly-transcribed VEGF mRNA and transports it to the cytoplasm and protects it from the ARE-mediated degradation pathways[20].

Recent studies have suggested HuR and VEGF mRNA localize to the cytoplasm in response to cellular stress[21]. Upon hypoxic stress, HuR is found to be localized to the cytosol and bound to target mRNAs, preventing their decay. New experiments using double labeling immunofluorescence show that VEGF and HuR colocalize to the nucleus during hypoxia[22,23]. The nuclear role of VEGF mRNA, if any is unclear. Further studies to more clearly delineate the intracellular localization of VEGF mRNA and HuR are warranted.

The mechanism by which HuR protects VEGF from degradation has been further investigated. One hypothesis is that RNA binding proteins confer stability by binding directly to destabilizing sequences and making them unavailable to endonucleases. Goldberg and colleagues suggest that RNA-stabilizing factors may localize to a distinct binding site and thereby change the secondary or tertiary structure of the RNA, making a specific site unavailable to endonucleolysis. In support of this hypothesis, a 40 bp region adjacent to the HuR-binding site in the VEGF stability region has been identified that is susceptible to ribonucleases in the absence of HuR[24].

HuR's importance in carcinogenesis is underlined by a report Lopez de Silanes and colleagues[25]. Using a nude mouse model and the RKO colorectal cancer cell line, they reported that tumors modified to overexpress HuR grew significantly larger than controls, and conversely, tumors modified to repress HuR expression grew smaller. Whether this effect was brought about through stabilization of VEGF mRNA is yet unknown.

IRES

Internal ribosomal entry sites (IRESs) were first discovered in picornaviruses in which they initiate translation of naturally uncapped viral mRNA. Eukaryotic mRNA, however, possesses a 7-methylguanosine cap in the 5'UTR that is critical in the canonical model of translation. In this model, the eukaryotic initiation factors (eIFs) recognize and bind the 5' cap, and unwind the secondary structure of the 5'UTR, thereby making it sterically feasible for ribosomes to scan through the 5' UTR and translate the mRNA beginning at the AUG start codon[26].

However, perhaps 3%-5% of all cellular mRNAs are translated by a mechanism independent of the 5' cap structure[27]. Most of these mRNAs are likely to contain an internal ribosome-entry site (IRES) in the 5' untranslated region (UTR), as the ability to maintain efficient translation without utilizing the 5' cap-dependent mechanism relies on the presence of one or several IRESs. IRESs are typically found in mRNAs that possess unusually long 5'UTRs, greater than -300 nt, which consequently have significant secondary structure[28]. In eukaryotes, IRES-mediated translation bypasses the canonical initiation step by directly recruiting ribosomes to the start codon without the need for the 5' mRNA cap structure or the eukaryotic initiation

factor (eIF) complex[28,29].

The eIF-4F complex is one of the key mediators of ribosome recruitment in cap-dependent translation and the eIF-4E subunit of this complex can be rate-limiting[2]. Under normal cellular conditions, eIF-4E is bound to its binding protein 4E-BP1 and translation is limited by the availability of the unbound fraction of eIF-4E[30]. When 4E-BP1 is phosphorylated, eIF-4E is released and becomes available to bind mRNA and participate in the eIF-4F complex. This phosphorylation is instigated by the downstream effects of various mitogenic pathways. Hypoxia, however, has the opposite effect, increasing the binding of eIF-4E with 4E-BP1, which may mediate the global decrease in protein synthesis seen in stressed cells[31].

Several observations about the 5' UTR of VEGF mRNA led to the hypothesis that it may contain IRES elements. First, cap-dependent translation of VEGF is cumbersome because the 5' UTR (1038 bp in humans) is much longer than typical eukaryotic 5' UTRs (-300 nt) and does not allow efficient ribosomal scanning. Second, it has a high G+C content, predisposing it to form stable secondary structures. Third, the 5'UTR contains a short open reading frame with in-frame initiation and termination codons[32]. Furthermore, in order to maximize its effect, translation of VEGF must be upregulated during periods of stress such as cellular hypoxia, when cap-dependent protein synthesis is globally inhibited.

In 1998, VEGF mRNA was shown to possess two IRES sites (IRES A and B) in the 5' UTR[32-34]. IRES A is contained in a 293nt segment just upstream from the AUG codon and is believed to control translation initiated at the AUG codon[35]. IRES B is contained in the early portion of the 5' UTR[33]. These two sites appear to bind different proteins, and the cellular milieus in which each functions optimally are not well understood.

IRES-mediated translation *in vivo* and *in vitro* yields a distinct isoform of VEGF, called "Large VEGF" or "L-VEGF." Whereas initiation mediated by the 5' cap and IRES A is at the AUG start codon it shares with cap-dependent translation, the initiation of the L-VEGF isoform occurs at an upstream CUG start codon (nt 499) within the 5'UTR. The L-VEGF isoform contains an N-terminal extension of 180 a.a., which is cleaved to yield a C-terminal peptide that is nearly identical to VEGF 189. This N-terminal extension is highly conserved through human, bovine, and murine cells, but whether it has any function is unknown[36].

Inquiry into the control of IRES A has uncovered a complex model of translational regulation. The five classic isoforms (excluding L-VEGF) are the translation products of five distinct mature mRNAs; each of these mature mRNAs is the product of alternative splicing of the transcription product or pre-mRNA. Bornes and colleagues have reported that differences in exon content of the differentially spliced mRNA can lead to preferential activity of one IRES or the other[35].

Though it is becoming clear that the IRES mechanism in VEGF translation is a plausible pathway in normal physiology, it remains debatable whether this pathway plays a significant role in tumor angiogenesis. The controversy relies on the observation that there is a correlation between eIF-4E and protein synthesis in malignancy. This correlation has been demonstrated in breast carcinomas, head and neck squamous cell carcinomas, soft tissue sarcomas, and colon carcinoma[37-40], and is bolstered by the observation that cells that over-express eIF-4E increase secretion of VEGF by greater than 100-fold[41]. Therefore, it is conceivable that VEGF production in transformed cells relies on the cap-dependent pathway as well, though this has not been definitively demonstrated.

Whether hypoxia is a sufficient stimulus to induce IRES activity, or if other mitogenic stimuli can trigger internal ribosomal entry remains unknown. In a study comparing the IRES elements of VEGF, hypoglycemia was seen to significantly activate IRES activity[42]. In both transformed and benign cells, the balance between IRES and cap-dependent translation in VEGF requires further investigation.

Deranged expression of the *c-myc* oncogene is associated with many human malignancies, as its over-expression promotes cell growth and angiogenesis[43]. This effect is in part due to the fact that *myc* over-expression increases secretion of VEGF[44]. The mechanism behind this increase was recently described by Mezquita and colleagues[45]. They demonstrated that *myc* interacts with VEGF mRNA to upregulate initiation of translation capable of bringing about a 10-fold increase in VEGF production. They observed no increase in eIF activity and attribute the translational upregulation to VEGF-specific increase of translation initiation, either through *c-myc* or VEGF directly.

Implications for Tumor Angiogenesis

In 1993, Kim and colleagues reported that anti-VEGF antibodies had a strong inhibitory effect on the growth of several tumor types in nude mice. Since then, anti-VEGF therapies to target angiogenesis have gained further attention. Investigators have reported inhibited tumor growth with other anti-VEGF applications including anti-sense nucleotides, anti-receptor antibodies, soluble VEGF receptors, and a retrovirus-delivered Flk-1 mutant.[46-49] A recent phase three FDA trial demonstrated improved survival when patients with metastatic colorectal cancer were treated with a humanized monoclonal anti-VEGF antibody (bevacizumab) in combination with standard chemotherapy (irinotecan, 5-FU, and leucovorin), resulting in FDA approval. The FDA has also approved its use in non-small cell lung cancer. Bevacizumab is being tested in several other tumor models with and without adjunctive traditional chemotherapy agents.

Anti-angiogenic therapies have targeted the normal endothelial cell's ability to respond to angiogenic factors, either by primarily inhibiting endothelial cell proliferation or by using antibodies to prevent angiogenic factors from activating endothelial cells[50]. However, some investigators have observed resistance to this therapy due to the ability of tumor cells to upregulate the expression of VEGF and thereby negate the anti-angiogenic effect[51]. There is further evidence suggesting that high tumor levels of VEGF may promote tumor survival[52].

One potential anti-angiogenic strategy is to silence gene expression of angiogenic factors at the mRNA level.

While antisense oligonucleotides have been used for this strategy, the high concentration required and non-specific effects have limited this approach. First described in *C. elegans*, RNA interference (RNAi) is a process in which double stranded RNA (dsRNA) is processed by the enzyme Dicer, resulting in short interfering RNAs (siRNA) 21-25 nucleotides in length[53,54]. These siRNA molecules are incorporated into an RNA-induced silencing complex (RISC) that binds complementary target mRNAs, leading to their degradation[55,56].

There is great potential for using RNAi technology in therapeutic applications that target critical signaling pathways involved in cancer, due to its high specificity for targeted genes and its potency at low concentrations. However, relatively few studies have examined the use of RNAi technology to suppress VEGF production.

In 2003, three reports proved the concept. Filleur and colleagues used a rat fibrosarcoma model and systemically delivered siRNA to achieve a 66% decrease in tumor size when compared to controls[57]. Reich and colleagues used direct injection of anti-VEGF siRNA to decrease choroidal neovascularization in laser-induced retinal injury in the rat[58]. A plasmid-based siRNA delivery system driven by a Pol III promoter was used by Zhang and colleagues to show isoform-specific knockdown of VEGF[59].

These three experiments provided the conceptual basis for two further experiments to demonstrate the efficacy of RNAi inhibition of VEGF. In 2005, Yoon and colleagues injected HT1080 fibrosarcoma cells stably transfected with anti-vegf siRNA into the subcutaneous tissue of rats. They reported substantial decrease in tumor volume and vessel density in resected specimens[60]. In the same year, Kwon and colleagues described a bi-level approach to silencing VEGF. In their experiment, they combined zinc finger-mediated repression of transcription with RNAi technology to achieve knockdown of VEGF of over 90%[61].

The critical problem with RNAi-based therapy is one of delivery. Whereas *in vitro* transfection of cells is easily accomplished using lipid-based solution, *in vivo* targeting of the siRNA molecules to cancer cells is far more challenging. Systemic delivery of naked siRNA is problematic as the drugs localize poorly and the degree of dilution is often unacceptable[62]. Though synthetic vectors offer several advantages such as their relative safety and the ease of incorporating target-specific ligands, there are significant barriers to their effective use that have not yet been overcome[63]. Viral vectors may offer specific advantages as well[64].

CONCLUSION

Although much has been learned about VEGF since its discovery in 1989, much more remains to be understood. First, the relevance of hypoxic stabilization of VEGF mRNA must be established in the settings of both neoplasia and normal physiologic conditions. Does our current understanding of hypoxic stabilization provide a sufficient explanation with regard to tumor angiogenesis? Are there other mitogenic factors that can overwhelm the cell's innate response to hypoxia? Second, the balance between cap-dependent and IRES-mediated translation must be elucidated. What are the factors that mitigate the switch from cap-dependent to IRES-mediated translation? Finally, it is clear that post-transcriptional regulation of VEGF has profound clinical implications with regard to targeting tumor angiogenesis. Will RNAi technology prove to be an efficacious therapeutic modality? If so, how will we deliver the drug to achieve a safe, durable, and clinically significant outcome? It will be a challenge for coming years to determine how best to exploit these molecular mechanisms for our patients' benefit.

REFERENCES

1 **Folkman J**. Tumor angiogenesis: therapeutic implications. *N Engl J Med* 1971; **285**:1182-1186

2 **Hiremath LS**, Webb NR, Rhoads RE. Immunological detection of the messenger RNA cap-binding protein. *J Biol Chem* 1985; **260**: 7843-7849

3 **Plate KH**, Breier G, Weich HA, Risau W. Vascular endothelial growth factor is a potential tumour angiogenesis factor in human gliomas in vivo. *Nature* 1992; **359**: 845-848

4 **Cascinu S**, Staccioli MP, Gasparini G, Giordani P, Catalano V, Ghiselli R, Rossi C, Baldelli AM, Graziano F, Saba V, Muretto P, Catalano G. Expression of vascular endothelial growth factor can predict event-free survival in stage II colon cancer. *Clin Cancer Res* 2000; **6**: 2803-2807

5 **Poon RT**, Ng IO, Lau C, Zhu LX, Yu WC, Lo CM, Fan ST, Wong J. Serum vascular endothelial growth factor predicts venous invasion in hepatocellular carcinoma: a prospective study. *Ann Surg* 2001; **233**: 227-235

6 **Forsythe JA**, Jiang BH, Iyer NV, Agani F, Leung SW, Koos RD, Semenza GL. Activation of vascular endothelial growth factor gene transcription by hypoxia-inducible factor 1. *Mol Cell Biol* 1996; **16**: 4604-4613

7 **Ikeda E**, Achen MG, Breier G, Risau W. Hypoxia-induced transcriptional activation and increased mRNA stability of vascular endothelial growth factor in C6 glioma cells. *J Biol Chem* 1995; **270**: 19761-19766

8 **Shima DT**, Deutsch U, D'Amore PA. Hypoxic induction of vascular endothelial growth factor (VEGF) in human epithelial cells is mediated by increases in mRNA stability. *FEBS Lett* 1995; **370**: 203-208

9 **Laughner E**, Taghavi P, Chiles K, Mahon PC, Semenza GL. HER2 (neu) signaling increases the rate of hypoxia-inducible factor 1alpha (HIF-1alpha) synthesis: novel mechanism for HIF-1-mediated vascular endothelial growth factor expression. *Mol Cell Biol* 2001; **21**: 3995-4004

10 **Shi Q**, Le X, Abbruzzese JL, Peng Z, Qian CN, Tang H, Xiong Q, Wang B, Li XC, Xie K. Constitutive Sp1 activity is essential for differential constitutive expression of vascular endothelial growth factor in human pancreatic adenocarcinoma. *Cancer Res* 2001; **61**: 4143-4154

11 **Niu G**, Wright KL, Huang M, Song L, Haura E, Turkson J, Zhang S, Wang T, Sinibaldi D, Coppola D, Heller R, Ellis LM, Karras J, Bromberg J, Pardoll D, Jove R, Yu H. Constitutive Stat3 activity up-regulates VEGF expression and tumor angiogenesis. *Oncogene* 2002; **21**: 2000-2008

12 **Ng YS**, Rohan R, Sunday ME, Demello DE, D'Amore PA. Differential expression of VEGF isoforms in mouse during development and in the adult. *Dev Dyn* 2001; **220**: 112-121

13 **Park JE**, Keller GA, Ferrara N. The vascular endothelial growth factor (VEGF) isoforms: differential deposition into the subepithelial extracellular matrix and bioactivity of extracellular matrix-bound VEGF. *Mol Biol Cell* 1993; **4**: 1317-1326

14 **Neufeld G**, Cohen T, Gengrinovitch S, Poltorak Z. Vascular endothelial growth factor (VEGF) and its receptors. *FASEB J* 1999; **13**: 9-22

15 **Levy NS**, Chung S, Furneaux H, Levy AP. Hypoxic

stabilization of vascular endothelial growth factor mRNA by the RNA-binding protein HuR. *J Biol Chem* 1998; **273**: 6417-6423
16 **Levy AP**, Levy NS, Goldberg MA. Post-transcriptional regulation of vascular endothelial growth factor by hypoxia. *J Biol Chem* 1996; **271**: 2746-2753
17 **Robinow S**, Campos AR, Yao KM, White K. The elav gene product of Drosophila, required in neurons, has three RNP consensus motifs. *Science* 1988; **242**: 1570-1572
18 **Fan XC**, Steitz JA. Overexpression of HuR, a nuclear-cytoplasmic shuttling protein, increases the in vivo stability of ARE-containing mRNAs. *EMBO J* 1998; **17**: 3448-3460
19 **Levy AP**, Levy NS, Goldberg MA. Hypoxia-inducible protein binding to vascular endothelial growth factor mRNA and its modulation by the von Hippel-Lindau protein. *J Biol Chem* 1996; **271**: 25492-25497
20 **Fan XC**, Steitz JA. HNS, a nuclear-cytoplasmic shuttling sequence in HuR. *Proc Natl Acad Sci USA* 1998; **95**: 15293-15298
21 **Brennan CM**, Steitz JA. HuR and mRNA stability. *Cell Mol Life Sci* 2001; **58**: 266-277
22 **Leung DW**, Cachianes G, Kuang WJ, Goeddel DV, Ferrara N. Vascular endothelial growth factor is a secreted angiogenic mitogen. *Science* 1989; **246**: 1306-1309
23 **Lejbkowicz F**, Goldberg-Cohen I, Levy AP. New horizons for VEGF. Is there a role for nuclear localization? *Acta Histochem* 2005; **106**: 405-411
24 **Goldberg-Cohen I**, Furneauxb H, Levy AP. A 40-bp RNA element that mediates stabilization of vascular endothelial growth factor mRNA by HuR. *J Biol Chem* 2002; **277**: 13635-13640
25 **López de Silanes I**, Fan J, Yang X, Zonderman AB, Potapova O, Pizer ES, Gorospe M. Role of the RNA-binding protein HuR in colon carcinogenesis. *Oncogene* 2003; **22**: 7146-7154
26 **Pain VM**. Initiation of protein synthesis in eukaryotic cells. *Eur J Biochem* 1996; **236**: 747-771
27 **Johannes G**, Carter MS, Eisen MB, Brown PO, Sarnow P. Identification of eukaryotic mRNAs that are translated at reduced cap binding complex eIF4F concentrations using a cDNA microarray. *Proc Natl Acad Sci USA* 1999; **96**: 13118-13123
28 **Hellen CU**, Sarnow P. Internal ribosome entry sites in eukaryotic mRNA molecules. *Genes Dev* 2001; **15**: 1593-1612
29 **Johannes G**, Sarnow P. Cap-independent polysomal association of natural mRNAs encoding c-myc, BiP, and eIF4G conferred by internal ribosome entry sites. *RNA* 1998; **4**: 1500-1513
30 **Sonenberg N**, Gingras AC. The mRNA 5′ cap-binding protein eIF4E and control of cell growth. *Curr Opin Cell Biol* 1998; **10**: 268-275
31 **Tinton SA**, Buc-Calderon PM. Hypoxia increases the association of 4E-binding protein 1 with the initiation factor 4E in isolated rat hepatocytes. *FEBS Lett* 1999; **446**: 55-59
32 **Stein I**, Itin A, Einat P, Skaliter R, Grossman Z, Keshet E. Translation of vascular endothelial growth factor mRNA by internal ribosome entry: implications for translation under hypoxia. *Mol Cell Biol* 1998; **18**: 3112-3119
33 **Huez I**, Créancier L, Audigier S, Gensac MC, Prats AC, Prats H. Two independent internal ribosome entry sites are involved in translation initiation of vascular endothelial growth factor mRNA. *Mol Cell Biol* 1998; **18**: 6178-6190
34 **Miller DL**, Dibbens JA, Damert A, Risau W, Vadas MA, Goodall GJ. The vascular endothelial growth factor mRNA contains an internal ribosome entry site. *FEBS Lett* 1998; **434**: 417-420
35 **Bornes S**, Boulard M, Hieblot C, Zanibellato C, Iacovoni JS, Prats H, Touriol C. Control of the vascular endothelial growth factor internal ribosome entry site (IRES) activity and translation initiation by alternatively spliced coding sequences. *J Biol Chem* 2004; **279**: 18717-18726
36 **Huez I**, Bornes S, Bresson D, Créancier L, Prats H. New vascular endothelial growth factor isoform generated by internal ribosome entry site-driven CUG translation initiation. *Mol Endocrinol* 2001; **15**: 2197-2210
37 **Kerekatte V**, Smiley K, Hu B, Smith A, Gelder F, De Benedetti A. The proto-oncogene/translation factor eIF4E: a survey of its expression in breast carcinomas. *Int J Cancer* 1995; **64**: 27-31
38 **Nathan CO**, Liu L, Li BD, Abreo FW, Nandy I, De Benedetti A. Detection of the proto-oncogene eIF4E in surgical margins may predict recurrence in head and neck cancer. *Oncogene* 1997; **15**: 579-584
39 **McClusky DR**, Chu Q, Yu H, Debenedetti A, Johnson LW, Meschonat C, Turnage R, McDonald JC, Abreo F, Li BD. A prospective trial on initiation factor 4E (eIF4E) overexpression and cancer recurrence in node-positive breast cancer. *Ann Surg* 2005; **242**: 584-590; discussion 590-592
40 **Vazquez SH**, Byrnes KW, Chu Q, Cole P, Dunn G, Werner A, Grimes F, Stratton M, Sittig K, Li B. Eukaryotic initiation factor 4E (eIF4E) expression in malignant versus inflammatory colon tissue. *Annals Of Surgical Oncology* 2005; **12**: S90-S91
41 **Kevil CG**, De Benedetti A, Payne DK, Coe LL, Laroux FS, Alexander JS. Translational regulation of vascular permeability factor by eukaryotic initiation factor 4E: implications for tumor angiogenesis. *Int J Cancer* 1996; **65**: 785-790
42 **Wong ET**, Ngoi SM, Lee CG. Improved co-expression of multiple genes in vectors containing internal ribosome entry sites (IRESes) from human genes. *Gene Ther* 2002; **9**: 337-344
43 **Nesbit CE**, Tersak JM, Prochownik EV. MYC oncogenes and human neoplastic disease. *Oncogene* 1999; **18**: 3004-3016
44 **Pelengaris S**, Littlewood T, Khan M, Elia G, Evan G. Reversible activation of c-Myc in skin: induction of a complex neoplastic phenotype by a single oncogenic lesion. *Mol Cell* 1999; **3**: 565-577
45 **Mezquita P**, Parghi SS, Brandvold KA, Ruddell A. Myc regulates VEGF production in B cells by stimulating initiation of VEGF mRNA translation. *Oncogene* 2005; **24**: 889-901
46 **Gerber HP**, Kowalski J, Sherman D, Eberhard DA, Ferrara N. Complete inhibition of rhabdomyosarcoma xenograft growth and neovascularization requires blockade of both tumor and host vascular endothelial growth factor. *Cancer Res* 2000; **60**: 6253-6258
47 **Goldman CK**, Kendall RL, Cabrera G, Soroceanu L, Heike Y, Gillespie GY, Siegal GP, Mao X, Bett AJ, Huckle WR, Thomas KA, Curiel DT. Paracrine expression of a native soluble vascular endothelial growth factor receptor inhibits tumor growth, metastasis, and mortality rate. *Proc Natl Acad Sci USA* 1998; **95**: 8795-8800
48 **Millauer B**, Shawver LK, Plate KH, Risau W, Ullrich A. Glioblastoma growth inhibited in vivo by a dominant-negative Flk-1 mutant. *Nature* 1994; **367**: 576-579
49 **Prewett M**, Huber J, Li Y, Santiago A, O'Connor W, King K, Overholser J, Hooper A, Pytowski B, Witte L, Bohlen P, Hicklin DJ. Antivascular endothelial growth factor receptor (fetal liver kinase 1) monoclonal antibody inhibits tumor angiogenesis and growth of several mouse and human tumors. *Cancer Res* 1999; **59**: 5209-5218
50 **Liekens S**, De Clercq E, Neyts J. Angiogenesis: regulators and clinical applications. *Biochem Pharmacol* 2001; **61**: 253-270
51 **Viloria-Petit A**, Crombet T, Jothy S, Hicklin D, Bohlen P, Schlaeppi JM, Rak J, Kerbel RS. Acquired resistance to the antitumor effect of epidermal growth factor receptor-blocking antibodies in vivo: a role for altered tumor angiogenesis. *Cancer Res* 2001; **61**: 5090-5101
52 **Wong AK**, Alfert M, Castrillon DH, Shen Q, Holash J, Yancopoulos GD, Chin L. Excessive tumor-elaborated VEGF and its neutralization define a lethal paraneoplastic syndrome. *Proc Natl Acad Sci USA* 2001; **98**: 7481-7486
53 **Elbashir SM**, Lendeckel W, Tuschl T. RNA interference is mediated by 21- and 22-nucleotide RNAs. *Genes Dev* 2001; **15**: 188-200
54 **Fire A**, Xu S, Montgomery MK, Kostas SA, Driver SE, Mello CC. Potent and specific genetic interference by double-stranded RNA in Caenorhabditis elegans. *Nature* 1998; **391**: 806-811
55 **Bernstein E**, Caudy AA, Hammond SM, Hannon GJ. Role for a bidentate ribonuclease in the initiation step of RNA interference. *Nature* 2001; **409**: 363-366

56 **Paddison PJ**, Caudy AA, Bernstein E, Hannon GJ, Conklin DS. Short hairpin RNAs (shRNAs) induce sequence-specific silencing in mammalian cells. *Genes Dev* 2002; **16**: 948-958
57 **Filleur S**, Courtin A, Ait-Si-Ali S, Guglielmi J, Merle C, Harel-Bellan A, Clézardin P, Cabon F. SiRNA-mediated inhibition of vascular endothelial growth factor severely limits tumor resistance to antiangiogenic thrombospondin-1 and slows tumor vascularization and growth. *Cancer Res* 2003; **63**: 3919-3922
58 **Reich SJ**, Fosnot J, Kuroki A, Tang W, Yang X, Maguire AM, Bennett J, Tolentino MJ. Small interfering RNA (siRNA) targeting VEGF effectively inhibits ocular neovascularization in a mouse model. *Mol Vis* 2003; **9**: 210-216
59 **Zhang L**, Yang N, Mohamed-Hadley A, Rubin SC, Coukos G. Vector-based RNAi, a novel tool for isoform-specific knock-down of VEGF and anti-angiogenesis gene therapy of cancer. *Biochem Biophys Res Commun* 2003; **303**: 1169-1178
60 **Detwiller KY**, Fernando NT, Segal NH, Ryeom SW, D'Amore PA, Yoon SS. Analysis of hypoxia-related gene expression in sarcomas and effect of hypoxia on RNA interference of vascular endothelial cell growth factor A. *Cancer Res* 2005; **65**: 5881-5889
61 **Kwon HS**, Shin HC, Kim JS. Suppression of vascular endothelial growth factor expression at the transcriptional and post-transcriptional levels. *Nucleic Acids Res* 2005; **33**: e74
62 **Senn C**, Hangartner C, Moes S, Guerini D, Hofbauer KG. Central administration of small interfering RNAs in rats: a comparison with antisense oligonucleotides. *Eur J Pharmacol* 2005; 522: 30-37
63 **Read ML**, Logan A, Seymour LW. Barriers to Gene Delivery Using Synthetic Vectors. *Adv Genet* 2005; **53**PA: 19-46
64 **Amarzguioui M**, Rossi JJ, Kim D. Approaches for chemically synthesized siRNA and vector-mediated RNAi. *FEBS Lett* 2005; **579**: 5974-5981

S- Editor Wang J **L- Editor** Worthley DL **E- Editor** Bai SH

PO Box 2345, Beijing 100023, China
www.wjgnet.com
wjg@wjgnet.com

World J Gastroenterol 2006 August 21; 12(31): 4943-4950
World Journal of Gastroenterology ISSN 1007-9327
© 2006 The WJG Press. All rights reserved.

TOPIC HIGHLIGHT

Andrew D Clouston, MD, *Series Editors*

Hereditary non-polyposis colorectal cancer: The rise and fall of a confusing term

Jeremy R Jass

Jeremy R Jass, Department of Pathology, McGill University, Montreal, Quebec, Canada
Correspondence to: Jeremy R Jass, Department of Pathology, McGill University, Duff Medical Building, 3775 University Street, Montreal, Quebec H3A 2B4, Canada. jeremy.jass@mcgill.ca
Telephone: +1-514-3987192-00395 Fax: +1-514-3987446
Received: 2006-02-28 Accepted: 2006-03-21

Abstract

The term Hereditary Non-Polyposis Colorectal Cancer (HNPCC) is a poor descriptor of the syndrome described by Lynch. Over the last decade, the term has been applied to heterogeneous groups of families meeting limited clinical criteria, for example the Amsterdam criteria. It is now apparent that not all Amsterdam criteria-positive families have the Lynch syndrome. The term HNPCC has also been applied to clinical scenarios in which CRCs with DNA microsatellite instability are diagnosed but in which there is no vertical transmission of an altered DNA mismatch repair (MMR) gene. A term that has multiple, mutually incompatible meanings is highly problematic, particularly when it may influence the management of an individual family. The Lynch syndrome is best understood as a hereditary predisposition to malignancy that is explained by a germline mutation in a DNA MMR gene. The diagnosis does not depend in an absolute sense on any particular family pedigree structure or age of onset of malignancy. Families with a strong family history of colorectal cancer that do not have Lynch syndrome have been grouped as 'Familial Colorectal Cancer Type-X'. The first step in characterizing these cancer families is to distinguish them from Lynch syndrome. The term HNPCC no longer serves any useful purpose and should be phased out.

© 2006 The WJG Press. All rights reserved.

Key words: Hereditary Non-Polyposis Colorectal Cancer; Colon; Cancer; Hereditary

Jass JR. Hereditary non-polyposis colorectal cancer: The rise and fall of a confusing term. *World J Gastroenterol* 2006; 12(31): 4943-4950

http://www.wjgnet.com/1007-9327/12/4943.asp

INTRODUCTION

A fundamental concept in the successful practice of medicine is the recognition of a disease as a distinct entity defined by a clearly recognizable set of clinico-pathological features. Only by recognizing and diagnosing a specific disease is it possible to develop and apply an effective policy of disease management. The recognition of a distinct clinico-pathological entity does not depend on a full understanding of the underlying etiology providing that the appearance and natural history of a disease are sufficiently characteristic to set it apart from all other diseases. Many forms of cancer would fall into this category. The same arguments apply to complex syndromes, though many of these are in fact explained on the basis of a specific and heritable genetic abnormality.

A good example of a hereditary cancer syndrome due to a single gene defect is the autosomal dominant condition familial adenomatous polyposis (FAP) caused by germline mutation of the tumor suppressor gene *APC*[1]. For many years Henry Lynch and associates drew attention to a second form of familial colorectal cancer (CRC)[2,3]. Initially, this was believed to encompass two separate syndromes. Lynch Ⅰ syndrome (or Hereditary Site-Specific Colon Cancer) applied to families with colon cancer only, while Lynch Ⅱ syndrome (or Cancer Family Syndrome) included families with extra-colonic malignancies in addition to colon cancer. In 1985 Lynch introduced the term 'hereditary non-polyposis colorectal cancer' (HNPCC) to encompass Lynch syndromes Ⅰ and Ⅱ[4]. In 1991 there was further unification with the inclusion of the Muir-Torre syndrome (CRC with associated sebaceous neoplasms) within HNPCC[5]. Lynch viewed HNPCC as a syndrome characterized by an autosomal dominant pattern of inheritance, early onset of malignancy with a predilection for the proximal colon, multiple CRCs, the absence of premonitory lesions (e.g. adenomas), and the occurrence of cancer in certain extracolonic sites, notably endometrium and ovary.

The concept of a second major form of familial CRC to rival FAP was received with general skepticism, being either ignored, dismissed as an exceedingly rare disease or the chance clustering of a common disease, or interpreted as the result of a shared environmental exposure[6]. A breakthrough came with the publication of

a series of clinico-pathological investigations conducted in Finland that fully supported the observations of Lynch[7,8]. It was also shown that CRCs associated with HNPCC had particular histological features[9,10]. These included poor differentiation, abundant mucin secretion and marked lymphocytic infiltration. Additionally, CRCs developed within adenomas and it was inferred that HNPCC adenomas were more likely to undergo malignant transformation and within a shorter timeframe than conventional adenomas[9,11,12].

By the 1990s, cancer family clinics and registries for hereditary malignancy were beginning to collect and describe families with the features identified by Lynch and others. In order to standardize clinical and basic research it was suggested in 1991 by the International Collaborative Group on HNPCC that families should only be described as having HNPCC if they met strict criteria, known as the Amsterdam criteria (Table 1)[13]. Initially it was thought that the Amsterdam criteria would be highly specific for HNPCC. Nevertheless, the term HNPCC and the associated diagnostic criteria soon generated problems and confusion that have continued to this day.

Table 1 Amsterdam Ⅰ and Ⅱ criteria and Bethesda (revised) guidelines

Term	Criteria	Reference
Amsterdam Ⅰ[1]	*Three* 1st degree relatives with CRC *Two* generations affected *One* family member below age 50 yr Exclude familial adenomatous polyposis	Vasen *et al*, 1991[13]
Amsterdam Ⅱ[1]	As for Amsterdam I except that CRC may be substituted by cancer of endometrium, small bowel, or pelviureter	Vasen *et al*, 1999[14]
Bethesda (revised)[2]		Umar *et al*, 2004[44]
1	CRC below age 50 yr	
2	Multiple CRC or HNPCC-related cancers[3]	
3	CRC with MSI-related histology[4], < 60 yr	
4	CRC or HNPCC-related cancer in at least one 1st degree relative, < 50 yr	
5	CRC or HNPCC-related cancer in at least two 1st or 2nd degree relatives, any age	

[1]All criteria must be met; [2]Any criterion (1-5) can be met; [3]Includes cancer of endometrium, small bowel, pelviureter, biliary tract, stomach, ovary, pancreas, and brain (mainly glioblastoma multiforme); [4]Tumor infiltrating lymphocytes, Crohn-like reaction, mucin/signet ring cell differentation, medullary growth pattern.

THE TERM HNPCC

The term HNPCC implies a familial aggregation of CRC developing in the absence of polyps. However, patients with HNPCC have adenomas that may sometimes be multiple and frequently present with extra-colonic malignancy. For example, a patient with HNPCC could present with endometrial cancer, multiple adenomas and no family history of cancer. By restricting the Amsterdam criteria to CRC, it rapidly became evident that the criteria lacked sensitivity. The Amsterdam Ⅱ criteria (Table 1) were developed to allow particular cancers that presented in extra-colonic sites to be substituted for colorectal cancer, notably of endometrium, small intestine and pelviureter[14]. When the genetic mechanism underlying HNPCC was eventually discovered (see below) it became apparent that even the Amsterdam Ⅱ criteria lacked sensitivity. Clinical definitions were therefore relaxed in a variety of ways in different geographical regions in order to avoid missed diagnoses[15-18]. Indeed, single instances of HNPCC might be found as a consequence of new mutation, non-penetrance within small families, denial of family history, non-paternity, or adoption. These new definitions of HNPCC were not used merely to standardize research but were also employed as diagnostic tools for labeling families as having HNPCC. In summary, the term HNPCC was not only a misleading descriptor but came to encompass multiple clinical definitions while nevertheless being applied to families as a specific diagnostic label.

DNA MISMATCH REPAIR

In 1993, soon after the introduction of the Amsterdam criteria, the underlying mechanism for HNPCC was discovered. Most examples were shown to be caused by germline mutation in one of two DNA mismatch repair (MMR) genes: *MSH2* or *MLH1*[19-22]. MSH6 was implicated less frequently but showed a stronger association with endometrial cancer[23]. The MMR genes were shown to be tumor suppressor genes. Following inactivation of the wild-type allele, MMR proteins would no longer be expressed resulting in a failure to repair DNA mismatches occurring as spontaneous errors during DNA replication[24]. This failure applied most particularly within non-encoding tracts of repetitive DNA called microsatellites but could also disrupt tumor suppressor genes with short repetitive tracts within their encoding regions, for example (and in decreasing order of frequency) *ACVR2*, *PTHLH*, *TGFbetaRII*, *MARCKS*, *MSH3*, *TCF4*, *RAD50*, *CASP5*, *BAX*, *RIZ*, *MBD4*, *MSH6*, *BLM*, *IGF2R*, *PTEN*, *AXIN2*, *WISP3* and *CDX2*[25]. Deficiency of MMR therefore resulted in the distinct phenotype described as the mutator phenotype or, more specifically, as DNA microsatellite instability (MSI)[26,27].

In addition, therefore, to its distinctive clinico-pathological features, the diagnosis of HNPCC could now also be suggested through the demonstration of DNA MSI and/or through the loss of expression of DNA MMR proteins, once monoclonal antibodies to these proteins became commercially available[28,29]. The corollary that MMR deficiency was a specific biomarker for the syndrome was not however correct[30]. This is because one of the DNA MMR genes, namely *MLH1*, may be inactivated through hypermethylation of its promoter region[31]. Through this acquired epigenetic mechanism most CRCs with MSI present sporadically and not as a result of a germline mutation. Nevertheless, in families with the clinico-pathological features of HNPCC, the demonstration of MMR deficiency in one or more tumors is a very strong indicator of a germline mutation in a MMR gene (though not 100% specific, see below). In

summary, it was now possible to precisely demarcate and therefore diagnose HNPCC on the basis of the distinctive combination of clinical, pathological and molecular phenotype.

LACK OF SPECIFICITY OF CLINICAL CRITERIA FOR HNPCC

It was initially assumed that the Amsterdam criteria would be highly specific but not necessarily sensitive for HNPCC. However, the advent of testing for MSI showed that this assumption was not correct. In families meeting the Amsterdam criteria but in which CRCs did not show evidence of MSI, the classical clinical and pathological features of HNPCC were lacking[32]. Compared with Amsterdam criteria families in which CRCs showed MSI, the non-MSI-positive families comprised fewer affected subjects and CRCs were less likely to be proximally located, show mucinous or poor differentiation, be associated with positive lymph nodes, or have diploid DNA content[32]. CRCs were also less likely to be multiple or to present at a young age[32]. Additionally, when subjects from non-MSI-positive families were colonoscoped, they were more likely to have adenomas but the adenomas were less likely to be advanced than in MSI-positive families[33]. Despite these different clinicopathological findings, families continued to be diagnosed as having HNPCC merely on the basis of meeting the Amsterdam or similar clinical criteria[34-36].

At this point the question arises whether the term 'HNPCC' is the most appropriate label for a specific hereditary cancer syndrome caused by a germline mutation in a DNA MMR gene. Henceforth, for the purposes of this discussion and in accordance with a recent suggestion[6], the term 'Lynch syndrome' will be applied to the specific form of hereditary malignancy caused by germline mutation of a DNA mismatch repair gene. The term 'HNPCC' will be used merely to indicate that certain clinical criteria suggestive of a hereditary basis for CRC (excluding FAP) have been met. Families meeting one of the several clinical definitions of HNPCC may or may not have Lynch syndrome. There are three reasons why families may meet the Amsterdam criteria and yet not have the Lynch syndrome. In the first place, CRC is a common disease. Within a large sibship the finding of two affected siblings and one parent with CRC could occur by chance, even when one subject was diagnosed with CRC at the age of 49 years. Indeed, one would be appropriately skeptical of the diagnosis of Lynch syndrome if the other two affected subjects were diagnosed in their seventies or eighties. The labeling of a family with the diagnosis of Lynch syndrome on the basis of the preceding findings would be unwise, even though no 'rule' is being broken. A second reason is the possible clustering of low- or intermediate-risk genes within a family. The third reason is the possibility of family clusters occurring through known (e.g. attenuated FAP[37] or *MYH* polyposis[38]) or unknown high-risk genes. Although the lack of specificity of the Amsterdam criteria was first mooted in 1995[32], recognition that families meeting the criteria are clinically heterogeneous has come about only comparatively recently. For example, four recent studies have highlighted the lack of features of Lynch syndrome in Amsterdam criteria positive families that lack evidence of DNA MMR deficiency[39-42]. Features of particular note are the older age of onset of CRC, the reduced penetrance among relatives, the lack of predilection for the proximal colon, the lack of lymphocytic infiltration, the lack of extra-colonic malignancies, and the higher frequency of colorectal adenoma[39-42].

DIAGNOSIS AND MANAGEMENT OF LYNCH SYNDROME

The discussion above has outlined how over the last decade the Amsterdam or similar clinical criteria have often been the mainstay in reaching a purported diagnosis of Lynch syndrome. While larger, multi-case families with the classical spectrum of early onset colorectal and extra-colonic malignancies were probably diagnosed correctly in most cases using this approach, the diagnosis is less likely to have been correct in families meeting only the minimum set of clinical criteria. The effective management of Lynch syndrome includes informing and counseling affected and at-risk subjects, but this can only happen after the correct diagnosis has been reached and not before. Fortunately, a reliable working diagnosis of Lynch syndrome can usually be reached through the analysis of tissue samples prior to the discovery of a pathogenic germline mutation. Apart from confirming the diagnosis of cancer, evaluation of tissue samples provides both morphological and molecular evidence of tumorigenesis driven by defective DNA mismatch repair, the molecular hallmark of Lynch syndrome. The use of immuno-histochemistry to detect loss of expression of DNA MMR proteins can even identify the likely genetic cause and thereby simplify the ultimate diagnostic step of genetic screening[28,29].

As noted above, the Amsterdam criteria were established to provide a standard definition of HNPCC presenting within the setting of high-risk cancer family clinics and registries. The Bethesda guidelines were developed as a guide for testing MMR status in CRCs that presented in the population setting (Table 1)[43,44]. Family history, age at onset of malignancy, and pathology features were utilized as independent markers and in a way that would not only identify new cases of possible Lynch syndrome but would also exclude late-onset CRCs with MSI. The latter would in most instances be sporadic MSI-positive CRCs explicable by age-related methylation of *MLH1*. On this basis, the utilization of the Bethesda guidelines in order to diagnose Lynch syndrome should be more sensitive than the Amsterdam criteria and, through the inclusion of MMR testing within the algorithm, more specific[45,46].

The Bethesda guidelines highlight the importance of pathology review. This has not always been used in achieving a diagnosis of Lynch syndrome despite the fact that the attempt to arrive at an exclusively clinical definition of Lynch syndrome has been described as a 'search for the impossible'[47]. There are three reasons for this over-reliance on limited clinical features: (1) The Amsterdam criteria were initially thought to be highly stringent and

therefore specific for Lynch syndrome, (2) It is easier and cheaper to reach the diagnosis using clinical features alone, and (3) It has been argued that both MSI testing and immuno-histochemistry are genetic tests that should not be undertaken without the consent of the patient. With respect to the last, MSI testing and immuno-histochemistry are diagnostic tests capable of demonstrating an acquired and tumor-specific alteration that is indicative of but not conclusive with respect to germline status. Mismatch repair deficiency may be acquired exclusively at the somatic level, for example through methylation of a DNA mismatch repair gene (see above). Like all diagnostic tests of tumor phenotype, the results of MSI testing do not stand alone but must be interpreted in the light of all the available clinical and pathological features.

Because the term HNPCC was introduced as an alternative to the eponymous Lynch syndrome before that condition was fully characterized and explained on the basis of a set of genes with closely related function, it came to be applied in an overly broad sense to any form of CRC that appeared to be inherited but was not FAP (or the other rarer precancerous polyposes). However, it is not possible to use a term that has different and mutually exclusive meanings without generating confusion. The following two sections describe additional scenarios in which the term HNPCC (implying Lynch syndrome) has been used inappropriately.

GERMLINE HEMI-ALLELIC METHYLATION OF *MLH1*

Extrapolating from the Bethesda guidelines (see above), an early-onset CRC that shows MSI is likely to occur in the setting of Lynch syndrome. In 2002, Gazzoli *et al* identified an early onset CRC in which one *MLH1* allele showed methylation[48]. Intriguingly, the same allele was also methylated in the subject's lymphocytes. By elegantly exploiting the existence of a common polymorphism in the promoter region of *MLH1*, Gazzoli *et al* were able to show that the second or wild-type *MLH1* allele had been lost in the CRC. They therefore introduced the concept of germline hemi-allelic methylation of *MLH1* as a cause of HNPCC[48]. However, they were skeptical of the possibility that a methylated allele could be transmitted vertically from an affected subject to offspring and suggested that the phenomenon was both rare and sporadic. Miyakura *et al* discovered four additional examples of early onset MSI-positive CRC associated with germline hemi-allelic methylation of *MLH1*[49]. Although the patients were ascertained through cancer family clinics they did not have family histories suggestive of Lynch syndrome. They were merely young and some were affected with multiple tumors consistent with Lynch syndrome. Again, Miyakura *et al* did not infer that germline hemi-allelic methylation of *MLH1* could be transmitted vertically[49].

Suter *et al* arrived at a different conclusion with respect to germline hemi-allelic methylation of *MLH1* (which they termed 'epimutation')[50]. They documented two additional subjects carrying an *MLH1* epimutation who also met clinical criteria indicative of a diagnosis of HNPCC. Additionally, the epimutation was present in spermatozoa of one of the affected subjects. The latter finding was not only consistent with a germline defect but also provided evidence for transmission of the defect to offspring. The authors therefore advanced the concept of *MLH1* epimutation as a new cause of HNPCC (implying Lynch syndrome) in which there was vertical transmission of a methylated *MLH1* allele[50]. Nevertheless, it may be questioned if epimutations can in fact be inherited. While germline hemi-allelic methylation was indeed demonstrated in single members of two families that met certain clinical criteria for HNPCC, this is hardly surprising since the search for the epimutation was conducted exclusively in members of families registered in cancer family clinics. This ascertainment bias aside, it is now abundantly clear (see discussion above) that when a family happens to meet a particular clinical definition of HNPCC this does not automatically prove the existence of a heritable cause of cancer that is due to an altered DNA MMR gene[32,39-42]. It is true that one of the affected subjects showed methylation of *MLH1* within spermatozoa, but this was in less than 1% of spermatozoa[50]. Even if such a sperm succeeded in fertilizing an ovum, subsequent clearance of methylation during early embryogenesis would negate the effects of vertical transmission of the affected allele.

The same authors who advanced the concept of the heritability of *MLH1* epimutation subsequently demonstrated the *de novo* origin of germline hemi-allelic methylation of *MLH1* in a male subject who was shown to have inherited the methylated allele from his mother in whom the same allele was not methylated[51]. These authors nevertheless continued to claim that *MLH1* epimutation was 'weakly' heritable[51]. The fact that genetic alterations may be passed from parent to child and result in syndromes of familial cancer associated with early onset of disease and multiple neoplasia is a dismal truth for affected families and presents multiple problems with respect to the provision of medical solutions that are ethical, compassionate and effective. Therefore, the labeling of a form of cancer as heritable should be backed up by good evidence. The existing evidence does not support the heritability of germline hemi-allelic methylation of *MLH1*.

SERRATED POLYPS, DNA METHYLATION AND HNPCC

In 1997 a family was described as having HNPCC but did not meet the Amsterdam I or II criteria[52]. There were four siblings in a sibship of six with a total of eight CRCs between them. The initial CRCs presented at the ages of 44, 27, 44 and 55 years (eldest to youngest sibling respectively) and an offspring of the second eldest developed a gastric cancer at the age of 29 years. Gastric cancer is linked to Lynch syndrome but is not included in the Amsterdam II criteria. MSI testing using four markers was initially performed on the CRCs from the eldest and third eldest siblings and all four markers were unstable in both CRCs[32]. Overall, therefore, the features were consistent with a diagnosis of Lynch syndrome. Only one of the colectomy specimens, a right

hemicolectomy performed on the youngest sibling for two metachronous CRCs, was available for detailed study at the time of surgery. The pathology was atypical for Lynch syndrome insofar as there were five tubular adenomas, seven hyperplastic polyps and seven mixed polyps. The hyperplastic polyps and mixed polyps were noted to be larger than the adenomas[52]. In retrospect, the correct diagnosis would now be hyperplastic polyposis[53]. The smaller CRC showed conspicuous lymphocytic infiltration, instability at three of three microsatellite markers, and was arising from a mixed polyp. The large CRC was mucinous and showed instability at two of three microsatellite markers. One of the offspring of this subject had developed a tubulovillous adenoma and two hyperplastic polyps at around the age of 40 years and a second was found to have multiple hyperplastic polyps after the report was published. Overall, it was inferred that this family had Lynch syndrome but that there was a modifying genetic factor in the youngest sibling giving an unusual phenotype[52]. Nevertheless, no germline mutation in a DNA mismatch repair gene has been found in this family.

Now, in retrospect, it is possible to suggest a simpler and more plausible mechanism underlying this Lynch syndrome-like family. In 2005, a paper described a series of eleven Lynch syndrome-like families in which some CRCs were MSI-high but others had low-level MSI or were microsatellite stable (MSS)[54]. A more consistent finding across the CRCs and polyps in these 'MSI-variable' families was mutation of the oncogene *BRAF* and methylation of MINT31[54]. In addition, many subjects had advanced serrated polyps and two had hyperplastic polyposis. Based on these observations it was suggested that an inherited predisposition to acquired DNA methylation within somatic tissues could give rise to a 'serrated pathway syndrome'[54]. Should *MLH1* be implicated then one might observe the development of CRCs that were MSI-high. This would only apply to a subset of CRCs, but could by chance, as in the case of the family described in 1997[52], affect all CRCs tested within a single family.

What is the evidence for an inherited predisposition to CRCs with DNA methylation? In a family cancer clinic-based study that excluded families with the Lynch syndrome, subjects with CRCs showing the CpG island methylator phenotype (CIMP) had a 13-fold increased risk of having a first degree relative with cancer (not necessarily CRC) as compared with subjects without CIMP-positive CRC[55]. A hospital-based study could not confirm this finding but removed families meeting a clinical definition for HNPCC[56]. The latter exclusion clearly introduced a major bias since not all families meeting a clinical definition for HNPCC in fact carry a germline defect in a DNA MMR gene (see above). This is another example of how a loose definition of HNPCC can be confounding.

An inherent difficulty in establishing whether genetic factors may explain CIMP is the lack of an agreed definition of CIMP. It is clear, however, that mutation of *BRAF* co-segregates with extensive CIMP and may therefore be used as a surrogate for high-level CIMP. In a large population-based study, CRCs were stratified on the basis of *BRAF* mutation and DNA MSI status[57]. In the larger subset of MSS CRCs, the odds ratio for having a positive family for subjects with *BRAF* mutation-positive CRCs was 4.23 (95% CI = 1.65-10.84) (as compared with subjects with *BRAF* mutation-negative CRCs). The same finding was not observed in patients with MSI-high CRCs[57]. However, this is not surprising since the subjects with MSI-high CRCs that lacked *BRAF* mutation were relatively young and many would be expected to have Lynch syndrome.

In summary, it is likely that genetic mechanisms will be found to at least partially explain the evolution of CIMP-positive CRCs and to account for a subset of families that may mimic Lynch syndrome but in whom both colorectal polyps and cancers show extensive DNA methylation and frequent mutation of *BRAF*.

LYNCH SYNDROME VARIANTS

The more clearly one defines Lynch syndrome, the simpler it becomes to distinguish the syndrome from clinical scenarios that provide close mimicry. In the preceding two sections we encountered different clinical situations in which there was diagnosis of CRCs with DNA MSI and an inappropriate label of HNPCC. The essential feature of Lynch syndrome is that it is a *hereditary* disorder that is explained by *a germline mutation in a DNA MMR gene*. DNA MSI is a useful diagnostic hallmark but is not requisite for the diagnosis. Some mutations in DNA MMR repair genes may be tumorigenic but may not result in the mutator phenotype[58]. DNA MMR repair genes are multifunctional and certain mutations may be deleterious because they disrupt cell-cycle checkpoint control and/or apoptosis[59]. These variants may be associated with lower penetrance and a milder clinical phenotype but should probably be regarded as variants of Lynch syndrome. Mutations in the DNA MMR gene *PMS2* may result in a syndrome that is inherited as an autosomal recessive trait[60]. The combination of very early onset malignancy involving brain, colon and other sites has been described as Turcot syndrome and linked with bi-allelic mutation of *PMS2* in a small number of families[60,61]. Drawing a distinction between Turcot syndrome and Lynch syndrome becomes difficult given the fact that *PMS2* mutation has also been linked with autosomal dominant patterns of inheritance[62,63] while certain *MLH1*, *MSH2* and *MSH6* mutations may give rise to an autosomal recessive trait[61,64]. Individuals with homozygous MMR gene mutations may show features of neurofibromatosis with café-au-lait spots. This has been associated with somatic mutation of the neurofibromatosis type-1 gene[65]. The preceding examples could be considered as variants of Lynch syndrome. However, clinical scenarios in which CRCs with MMR deficiency occur in the absence of a vertically transmissable genetic alteration in a MMR gene should not be termed Lynch syndrome.

CONCLUSION

The term HNPCC is a poor descriptor of the syndrome described by Lynch. Over the last decade, the term has been applied as a specific diagnostic label to families meeting a multiplicity of clinical criteria. A subset of

Table 2 Conditions and clinical scenarios that may mimic Lynch syndrome

Attenuated Familial Adenomatous Polyposis[37] (polyps may not be numerous)
MYH polyposis[38] (polyps may not be numerous)
Juvenile polyposis[66] (polyps may not be numerous and may be adenomatous)
Germline mutation of *TGFbetaRII*[67] and *AXIN2*[68] (is not associated with DNA MSI)
Hereditary mixed polyposis syndrome[69] (polyps may not be numerous and may be adenomatous)
Hyperplastic polyposis[53] (polyps may not be numerous and may be adenomatous)
Serrated Pathway Syndrome[54] (polyps may not be numerous and may be adenomatous and CRCs may show DNA MSI)
Germline hemi-allelic methylation of *MLH1*[48-51] (multiple, early onset cancers with Lynch syndrome spectrum and having DNA MSI)
Lynch syndrome variants[61,65] (autosomal recessive Turcot syndrome due to *PMS2* mutation)
Familial Colorectal Cancer-Type X[40] (Amsterdam criteria met but Lynch syndrome and conditions listed above have been excluded)

these families will not carry a germline mutation in DNA MMR gene and will not show the clinical and pathological phenotype associated with the Lynch syndrome. Such families may meet or even exceed the Amsterdam criteria despite lacking evidence for a germline defect in a DNA mismatch repair gene. It has been suggested that these families be grouped as 'Familial Colorectal Cancer Type-X'[40]. The term HNPCC has also been applied to clinical scenarios in which CRCs with DNA MSI are diagnosed but in which there is no vertical transmission of an altered DNA MMR gene. A diagnostic term that has multiple mutually incompatible meanings is problematic. This becomes particularly evident when extrapolating from a diagnostic label to the management of an individual family.

The Lynch syndrome is best understood as a *hereditary predisposition to malignancy* that is explained by a *germline mutation in a DNA MMR gene*. The diagnosis does not depend in an absolute sense on any particular family pedigree structure or age of onset of malignancy. If present, these are merely useful clinical pointers that have been accorded undue importance when considered in isolation of other facts. No simple set of clinical criteria can serve as a diagnostic label for Lynch syndrome. At the same time, the careful appraisal of clinical, pathological and molecular features can achieve an accurate working diagnosis prior to the demonstration of a pathogenic germline mutation in a DNA mismatch repair gene. To paraphrase a recent recommendation with respect to the term HNPCC: 'Clarification of the genetic basis and full phenotypic expression of this disease mandates a more clinically useful name that gives consideration to non-colonic cancers and unifies the diagnosis around germline mutation in a DNA MMR gene. The term Lynch syndrome is proposed for the autosomal dominant disease caused by a germline mutation in a DNA MMR gene'[6]. However, in adopting the term Lynch syndrome in place of HNPCC one must also distinguish Lynch syndrome from the numerous clinical scenarios that give rise to close mimicry. By separating and naming these clinical entities (Table 2) one can begin to undo the considerable confusion that has been generated by the arbitrary use of the imprecise term HNPCC.

REFERENCES

1 **Kinzler KW**, Vogelstein B. Lessons from hereditary colorectal cancer. *Cell* 1996; **87**: 159-170

2 **Lynch HT**, Krush AJ. Cancer family "G" revisited: 1895-1970. *Cancer* 1971; **27**: 1505-1511

3 **Lynch HT**, Lynch PM, Albano WA, Lynch JF. The cancer family syndrome: a status report. *Dis Colon Rectum* 1981; **24**: 311-322

4 **Lynch HT**, Schuelke GS, Kimberling WJ, Albano WA, Lynch JF, Biscone KA, Lipkin ML, Deschner EE, Mikol YB, Sandberg AA. Hereditary nonpolyposis colorectal cancer (Lynch syndromes I and II). II. Biomarker studies. *Cancer* 1985; **56**: 939-951

5 **Lynch HT**, Lanspa S, Smyrk T, Boman B, Watson P, Lynch J. Hereditary nonpolyposis colorectal cancer (Lynch syndromes I & II). Genetics, pathology, natural history, and cancer control, Part I. *Cancer Genet Cytogenet* 1991; **53**: 143-160

6 **Boland CR**. Evolution of the nomenclature for the hereditary colorectal cancer syndromes. *Fam Cancer* 2005; **4**: 211-218

7 **Mecklin JP**, Järvinen HJ. Clinical features of colorectal carcinoma in cancer family syndrome. *Dis Colon Rectum* 1986; **29**: 160-164

8 **Mecklin JP**, Järvinen HJ, Peltokallio P. Cancer family syndrome. Genetic analysis of 22 Finnish kindreds. *Gastroenterology* 1986; **90**: 328-333

9 **Mecklin JP**, Sipponen P, Järvinen HJ. Histopathology of colorectal carcinomas and adenomas in cancer family syndrome. *Dis Colon Rectum* 1986; **29**: 849-853

10 **Jass JR**, Smyrk TC, Stewart SM, Lane MR, Lanspa SJ, Lynch HT. Pathology of hereditary non-polyposis colorectal cancer. *Anticancer Res* 1994; **14**: 1631-1634

11 **Love RR**. Adenomas are precursor lesions for malignant growth in nonpolyposis hereditary carcinoma of the colon and rectum. *Surg Gynecol Obstet* 1986; **162**: 8-12

12 **Jass JR**, Stewart SM. Evolution of hereditary non-polyposis colorectal cancer. *Gut* 1992; **33**: 783-786

13 **Vasen HF**, Mecklin JP, Khan PM, Lynch HT. The International Collaborative Group on Hereditary Non-Polyposis Colorectal Cancer (ICG-HNPCC). *Dis Colon Rectum* 1991; **34**: 424-425

14 **Vasen HF**, Watson P, Mecklin JP, Lynch HT. New clinical criteria for hereditary nonpolyposis colorectal cancer (HNPCC, Lynch syndrome) proposed by the International Collaborative group on HNPCC. *Gastroenterology* 1999; **116**: 1453-1456

15 **Bapat BV**, Madlensky L, Temple LK, Hiruki T, Redston M, Baron DL, Xia L, Marcus VA, Soravia C, Mitri A, Shen W, Gryfe R, Berk T, Chodirker BN, Cohen Z, Gallinger S. Family history characteristics, tumor microsatellite instability and germline MSH2 and MLH1 mutations in hereditary colorectal cancer. *Hum Genet* 1999; **104**: 167-176

16 **Park YJ**, Shin KH, Park JG. Risk of gastric cancer in hereditary nonpolyposis colorectal cancer in Korea. *Clin Cancer Res* 2000; **6**: 2994-2998

17 **Song YM**, Zheng S. Analysis for phenotype of HNPCC in China. *World J Gastroenterol* 2002; **8**: 837-840

18 **Fujita S**, Moriya Y, Sugihara K, Akasu T, Ushio K. Prognosis of hereditary nonpolyposis colorectal cancer (HNPCC) and the role of Japanese criteria for HNPCC. *Jpn J Clin Oncol* 1996; **26**: 351-355

19 **Leach FS**, Nicolaides NC, Papadopoulos N, Liu B, Jen J, Parsons R, Peltomäki P, Sistonen P, Aaltonen LA, Nyström-Lahti M. Mutations of a mutS homolog in hereditary nonpolyposis colorectal cancer. *Cell* 1993; **75**: 1215-1225

20 **Fishel R**, Lescoe MK, Rao MR, Copeland NG, Jenkins NA, Garber J, Kane M, Kolodner R. The human mutator gene homolog MSH2 and its association with hereditary nonpolyposis colon cancer. *Cell* 1993; **75**: 1027-1038

21 **Bronner CE**, Baker SM, Morrison PT, Warren G, Smith LG,

Lescoe MK, Kane M, Earabino C, Lipford J, Lindblom A. Mutation in the DNA mismatch repair gene homologue hMLH1 is associated with hereditary non-polyposis colon cancer. *Nature* 1994; **368**: 258-261
22 **Papadopoulos N**, Nicolaides NC, Wei YF, Ruben SM, Carter KC, Rosen CA, Haseltine WA, Fleischmann RD, Fraser CM, Adams MD. Mutation of a mutL homolog in hereditary colon cancer. *Science* 1994; **263**: 1625-1629
23 **Wijnen J**, de Leeuw W, Vasen H, van der Klift H, Møller P, Stormorken A, Meijers-Heijboer H, Lindhout D, Menko F, Vossen S, Möslein G, Tops C, Bröcker-Vriends A, Wu Y, Hofstra R, Sijmons R, Cornelisse C, Morreau H, Fodde R. Familial endometrial cancer in female carriers of MSH6 germline mutations. *Nat Genet* 1999; **23**: 142-144
24 **Aaltonen LA**, Peltomäki P, Leach FS, Sistonen P, Pylkkänen L, Mecklin JP, Järvinen H, Powell SM, Jen J, Hamilton SR. Clues to the pathogenesis of familial colorectal cancer. *Science* 1993; **260**: 812-816
25 **Yamaguchi T**, Iijima T, Mori T, Takahashi K, Matsumoto H, Miyamoto H, Hishima T, Miyaki M. Accumulation profile of frameshift mutations during development and progression of colorectal cancer from patients with hereditary nonpolyposis colorectal cancer. *Dis Colon Rectum* 2006; **49**: 399-406
26 **Ionov Y**, Peinado MA, Malkhosyan S, Shibata D, Perucho M. Ubiquitous somatic mutations in simple repeated sequences reveal a new mechanism for colonic carcinogenesis. *Nature* 1993; **363**: 558-561
27 **Thibodeau SN**, Bren G, Schaid D. Microsatellite instability in cancer of the proximal colon. *Science* 1993; **260**: 816-819
28 **Marcus VA**, Madlensky L, Gryfe R, Kim H, So K, Millar A, Temple LK, Hsieh E, Hiruki T, Narod S, Bapat BV, Gallinger S, Redston M. Immunohistochemistry for hMLH1 and hMSH2: a practical test for DNA mismatch repair-deficient tumors. *Am J Surg Pathol* 1999; **23**: 1248-1255
29 **Lindor NM**, Burgart LJ, Leontovich O, Goldberg RM, Cunningham JM, Sargent DJ, Walsh-Vockley C, Petersen GM, Walsh MD, Leggett BA, Young JP, Barker MA, Jass JR, Hopper J, Gallinger S, Bapat B, Redston M, Thibodeau SN. Immunohistochemistry versus microsatellite instability testing in phenotyping colorectal tumors. *J Clin Oncol* 2002; **20**: 1043-1048
30 **Samowitz WS**, Slattery ML, Kerber RA. Microsatellite instability in human colonic cancer is not a useful clinical indicator of familial colorectal cancer. *Gastroenterology* 1995; **109**: 1765-1771
31 **Kane MF**, Loda M, Gaida GM, Lipman J, Mishra R, Goldman H, Jessup JM, Kolodner R. Methylation of the hMLH1 promoter correlates with lack of expression of hMLH1 in sporadic colon tumors and mismatch repair-defective human tumor cell lines. *Cancer Res* 1997; **57**: 808-811
32 **Jass JR**, Cottier DS, Jeevaratnam P, Pokos V, Holdaway KM, Bowden ML, Van de Water NS, Browett PJ. Diagnostic use of microsatellite instability in hereditary non-polyposis colorectal cancer. *Lancet* 1995; **346**: 1200-1201
33 **Jass JR**, Pokos V, Arnold JL, Cottier DS, Jeevaratnam P, Van de Water NS, Browett PJ, Winship IM, Lane MR. Colorectal neoplasms detected colonoscopically in at-risk members of colorectal cancer families stratified by the demonstration of DNA microsatellite instability. *J Mol Med (Berl)* 1996; **74**: 547-551
34 **Scott RJ**, McPhillips M, Meldrum CJ, Fitzgerald PE, Adams K, Spigelman AD, du Sart D, Tucker K, Kirk J. Hereditary nonpolyposis colorectal cancer in 95 families: differences and similarities between mutation-positive and mutation-negative kindreds. *Am J Hum Genet* 2001; **68**: 118-127
35 **Bermejo JL**, Eng C, Hemminki K. Cancer characteristics in Swedish families fulfilling criteria for hereditary nonpolyposis colorectal cancer. *Gastroenterology* 2005; **129**: 1889-1899
36 **Johnson PM**, Gallinger S, McLeod RS. Surveillance colonoscopy in individuals at risk for hereditary nonpolyposis colorectal cancer: an evidence-based review. *Dis Colon Rectum* 2006; **49**: 80-93; discussion 94-95
37 **Spirio L**, Olschwang S, Groden J, Robertson M, Samowitz W, Joslyn G, Gelbert L, Thliveris A, Carlson M, Otterud B. Alleles of the APC gene: an attenuated form of familial polyposis. *Cell* 1993; **75**: 951-957
38 **Al-Tassan N**, Chmiel NH, Maynard J, Fleming N, Livingston AL, Williams GT, Hodges AK, Davies DR, David SS, Sampson JR, Cheadle JP. Inherited variants of MYH associated with somatic G:C-->T:A mutations in colorectal tumors. *Nat Genet* 2002; **30**: 227-232
39 **Ponz de Leon M**, Benatti P, Borghi F, Pedroni M, Scarselli A, Di Gregorio C, Losi L, Viel A, Genuardi M, Abbati G, Rossi G, Menigatti M, Lamberti I, Ponti G, Roncucci L. Aetiology of colorectal cancer and relevance of monogenic inheritance. *Gut* 2004; **53**: 115-122
40 **Lindor NM**, Rabe K, Petersen GM, Haile R, Casey G, Baron J, Gallinger S, Bapat B, Aronson M, Hopper J, Jass J, LeMarchand L, Grove J, Potter J, Newcomb P, Terdiman JP, Conrad P, Moslein G, Goldberg R, Ziogas A, Anton-Culver H, de Andrade M, Siegmund K, Thibodeau SN, Boardman LA, Seminara D. Lower cancer incidence in Amsterdam-I criteria families without mismatch repair deficiency: familial colorectal cancer type X. *JAMA* 2005; **293**: 1979-1985
41 **Mueller-Koch Y**, Vogelsang H, Kopp R, Lohse P, Keller G, Aust D, Muders M, Gross M, Daum J, Schiemann U, Grabowski M, Scholz M, Kerker B, Becker I, Henke G, Holinski-Feder E. Hereditary non-polyposis colorectal cancer: clinical and molecular evidence for a new entity of hereditary colorectal cancer. *Gut* 2005; **54**: 1733-1740
42 **Llor X**, Pons E, Xicola RM, Castells A, Alenda C, Piñol V, Andreu M, Castellví-Bel S, Payá A, Jover R, Bessa X, Girós A, Roca A, Gassull MA. Differential features of colorectal cancers fulfilling Amsterdam criteria without involvement of the mutator pathway. *Clin Cancer Res* 2005; **11**: 7304-7310
43 **Rodriguez-Bigas MA**, Boland CR, Hamilton SR, Henson DE, Jass JR, Khan PM, Lynch H, Perucho M, Smyrk T, Sobin L, Srivastava S. A National Cancer Institute Workshop on Hereditary Nonpolyposis Colorectal Cancer Syndrome: meeting highlights and Bethesda guidelines. *J Natl Cancer Inst* 1997; **89**: 1758-1762
44 **Umar A**, Boland CR, Terdiman JP, Syngal S, de la Chapelle A, Rüschoff J, Fishel R, Lindor NM, Burgart LJ, Hamelin R, Hamilton SR, Hiatt RA, Jass J, Lindblom A, Lynch HT, Peltomaki P, Ramsey SD, Rodriguez-Bigas MA, Vasen HF, Hawk ET, Barrett JC, Freedman AN, Srivastava S. Revised Bethesda Guidelines for hereditary nonpolyposis colorectal cancer (Lynch syndrome) and microsatellite instability. *J Natl Cancer Inst* 2004; **96**: 261-268
45 **Shia J**, Ellis NA, Paty PB, Nash GM, Qin J, Offit K, Zhang XM, Markowitz AJ, Nafa K, Guillem JG, Wong WD, Gerald WL, Klimstra DS. Value of histopathology in predicting microsatellite instability in hereditary nonpolyposis colorectal cancer and sporadic colorectal cancer. *Am J Surg Pathol* 2003; **27**: 1407-1417
46 **Gologan A**, Krasinskas A, Hunt J, Thull DL, Farkas L, Sepulveda AR. Performance of the revised Bethesda guidelines for identification of colorectal carcinomas with a high level of microsatellite instability. *Arch Pathol Lab Med* 2005; **129**: 1390-1397
47 **Berends MJ**, Wu Y, Sijmons RH, Hofstra RM, van der Zee AG, Buys CH, Kleibeuker JH. Clinical definition of hereditary non-polyposis colorectal cancer: a search for the impossible? *Scand J Gastroenterol Suppl* 2001; : 61-67
48 **Gazzoli I**, Loda M, Garber J, Syngal S, Kolodner RD. A hereditary nonpolyposis colorectal carcinoma case associated with hypermethylation of the MLH1 gene in normal tissue and loss of heterozygosity of the unmethylated allele in the resulting microsatellite instability-high tumor. *Cancer Res* 2002; **62**: 3925-3928
49 **Miyakura Y**, Sugano K, Akasu T, Yoshida T, Maekawa M, Saitoh S, Sasaki H, Nomizu T, Konishi F, Fujita S, Moriya Y, Nagai H. Extensive but hemiallelic methylation of the hMLH1 promoter region in early-onset sporadic colon cancers with microsatellite instability. *Clin Gastroenterol Hepatol* 2004; **2**: 147-156

50 **Suter CM**, Martin DI, Ward RL. Germline epimutation of MLH1 in individuals with multiple cancers. *Nat Genet* 2004; **36**: 497-501

51 **Hitchins M**, Williams R, Cheong K, Halani N, Lin VA, Packham D, Ku S, Buckle A, Hawkins N, Burn J, Gallinger S, Goldblatt J, Kirk J, Tomlinson I, Scott R, Spigelman A, Suter C, Martin D, Suthers G, Ward R. MLH1 germline epimutations as a factor in hereditary nonpolyposis colorectal cancer. *Gastroenterology* 2005; **129**: 1392-9139

52 **Jass JR**, Cottier DS, Pokos V, Parry S, Winship IM. Mixed epithelial polyps in association with hereditary non-polyposis colorectal cancer providing an alternative pathway of cancer histogenesis. *Pathology* 1997; **29**: 28-33

53 **Jass JR**. Familial colorectal cancer: pathology and molecular characteristics. *Lancet Oncol* 2000; **1**: 220-226

54 **Young J**, Barker MA, Simms LA, Walsh MD, Biden KG, Buchanan D, Buttenshaw R, Whitehall VL, Arnold S, Jackson L, Kambara T, Spring KJ, Jenkins MA, Walker GJ, Hopper JL, Leggett BA, Jass JR. Evidence for BRAF mutation and variable levels of microsatellite instability in a syndrome of familial colorectal cancer. *Clin Gastroenterol Hepatol* 2005; **3**: 254-263

55 **Frazier ML**, Xi L, Zong J, Viscofsky N, Rashid A, Wu EF, Lynch PM, Amos CI, Issa JP. Association of the CpG island methylator phenotype with family history of cancer in patients with colorectal cancer. *Cancer Res* 2003; **63**: 4805-4808

56 **Ward RL**, Williams R, Law M, Hawkins NJ. The CpG island methylator phenotype is not associated with a personal or family history of cancer. *Cancer Res* 2004; **64**: 7618-7621

57 **Samowitz WS**, Sweeney C, Herrick J, Albertsen H, Levin TR, Murtaugh MA, Wolff RK, Slattery ML. Poor survival associated with the BRAF V600E mutation in microsatellite-stable colon cancers. *Cancer Res* 2005; **65**: 6063-6069

58 **Lipkin SM**, Rozek LS, Rennert G, Yang W, Chen PC, Hacia J, Hunt N, Shin B, Fodor S, Kokoris M, Greenson JK, Fearon E, Lynch H, Collins F, Gruber SB. The MLH1 D132H variant is associated with susceptibility to sporadic colorectal cancer. *Nat Genet* 2004; **36**: 694-699

59 **Fishel R**. Mismatch repair, molecular switches, and signal transduction. *Genes Dev* 1998; **12**: 2096-2101

60 **De Rosa M**, Fasano C, Panariello L, Scarano MI, Belli G, Iannelli A, Ciciliano F, Izzo P. Evidence for a recessive inheritance of Turcot's syndrome caused by compound heterozygous mutations within the PMS2 gene. *Oncogene* 2000; **19**: 1719-1723

61 **de Vos M**, Hayward B, Bonthron DT, Sheridan E. Phenotype associated with recessively inherited mutations in DNA mismatch repair (MMR) genes. *Biochem Soc Trans* 2005; **33**: 718-720

62 **Worthley DL**, Walsh MD, Barker M, Ruszkiewicz A, Bennett G, Phillips K, Suthers G. Familial mutations in PMS2 can cause autosomal dominant hereditary nonpolyposis colorectal cancer. *Gastroenterology* 2005; **128**: 1431-1436

63 **Truninger K**, Menigatti M, Luz J, Russell A, Haider R, Gebbers JO, Bannwart F, Yurtsever H, Neuweiler J, Riehle HM, Cattaruzza MS, Heinimann K, Schär P, Jiricny J, Marra G. Immunohistochemical analysis reveals high frequency of PMS2 defects in colorectal cancer. *Gastroenterology* 2005; **128**: 1160-1171

64 **Hegde MR**, Chong B, Blazo ME, Chin LH, Ward PA, Chintagumpala MM, Kim JY, Plon SE, Richards CS. A homozygous mutation in MSH6 causes Turcot syndrome. *Clin Cancer Res* 2005; **11**: 4689-4693

65 **Bandipalliam P**. Syndrome of early onset colon cancers, hematologic malignancies & features of neurofibromatosis in HNPCC families with homozygous mismatch repair gene mutations. *Fam Cancer* 2005; **4**: 323-333

66 **Jass JR**, Williams CB, Bussey HJ, Morson BC. Juvenile polyposis--a precancerous condition. *Histopathology* 1988; **13**: 619-630

67 **Lu SL**, Kawabata M, Imamura T, Akiyama Y, Nomizu T, Miyazono K, Yuasa Y. HNPCC associated with germline mutation in the TGF-beta type II receptor gene. *Nat Genet* 1998; **19**: 17-18

68 **Lammi L**, Arte S, Somer M, Jarvinen H, Lahermo P, Thesleff I, Pirinen S, Nieminen P. Mutations in AXIN2 cause familial tooth agenesis and predispose to colorectal cancer. *Am J Hum Genet* 2004; **74**: 1043-1050

69 **Whitelaw SC**, Murday VA, Tomlinson IP, Thomas HJ, Cottrell S, Ginsberg A, Bukofzer S, Hodgson SV, Skudowitz RB, Jass JR, Talbot IC, Northover JM, Bodmer WF, Solomon E. Clinical and molecular features of the hereditary mixed polyposis syndrome. *Gastroenterology* 1997; **112**: 327-334

S- Editor Wang J **L- Editor** Rampone B **E- Editor** Bi L

PO Box 2345, Beijing 100023, China
www.wjgnet.com
wjg@wjgnet.com

World J Gastroenterol 2006 August 21; 12(31): 4951-4958
World Journal of Gastroenterology ISSN 1007-9327
© 2006 The WJG Press. All rights reserved.

REVIEW

Insights on augmenter of liver regeneration cloning and function

Elisavet Gatzidou, Gregory Kouraklis, Stamatios Theocharis

Elisavet Gatzidou, Department of Forensic Medicine and Toxicology, Second Department of Propedeutic Surgery, University of Athens, Medical School, Athens, Greece
Gregory Kouraklis, Second Department of Propedeutic Surgery, University of Athens, Medical School, Laikon General Hospital, Athens, Greece
Stamatios Theocharis, Department of Forensic Medicine and Toxicology, University of Athens, Medical School, Athens, Greece
Correspondence to: Dr Stamatios Theocharis, Department of Forensic Medicine and Toxicology, University of Athens, Medical School, 75 M. Asias str., Goudi, GR11527, Athens, Greece. theocharis@ath.forthnet.gr
Telephone: +30-210-7462413 Fax: +30-210-7716098
Received: 2005-05-19 Accepted: 2005-06-18

Abstract

Hepatic stimulator substance (HSS) has been referred to as a liver-specific but species non-specific growth factor. Gradient purification and sequence analysis of HSS protein indicated that it contained the augmenter of liver regeneration (ALR), also known as hepatopoietin (HPO). ALR, acting as a hepatotrophic growth factor, specifically stimulated proliferation of cultured hepatocytes as well as hepatoma cells *in vitro*, promoted liver regeneration and recovery of damaged hepatocytes and rescued acute hepatic failure *in vivo*. ALR belongs to the new Erv1/Alr protein family, members of which are found in lower and higher eukaryotes from yeast to man and even in some double-stranded DNA viruses. The present review article focuses on the molecular biology of ALR, examining the ALR gene and its expression from yeast to man and the biological function of ALR protein. ALR protein seems to be non-liver-specific as was previously believed, increasing the necessity to extend research on mammalian ALR protein in different tissues, organs and developmental stages in conditions of normal and abnormal cellular growth.

© 2006 The WJG Press. All rights reserved.

Key words: Hepatic stimulator substance; Augmenter of liver regeneration; Liver regeneration; Molecular biology

Gatzidou E, Kouraklis G, Theocharis S. Insights on augmenter of liver regeneration cloning and function. *World J Gastroenterol* 2006; 12(31): 4951-4958

http://www.wjgnet.com/1007-9327/12/4951.asp

INTRODUCTION

In 1975, La Brecque and Pesch first referred to the existence of a polypeptide, named hepatic stimulator substance (HSS), in the liver cytosol of weanling or adult partially hepatectomized rats[1]. HSS was able to specifically stimulate hepatocyte proliferation and support liver regeneration in an organ specific but species non-specific manner[1-2]. Since then a number of studies examined HSS levels of toxicity on animal models of liver regeneration after partial hepatectomy and post induced liver injury *in vivo*[3,4] and *in vitro*[5]. Subsequently, the effect of this growth factor in acute[6-11] and chronic[12] liver injury and decreased hepatocyte proliferative capacity[13,14] has been reported in different animal models. A novel growth factor, obtained through progressive purification (831 000x) of the crude HSS extract, was named Augmenter of Liver Regeneration (ALR)[15-20]. ALR, as well as HSS, did not affect quiescent hepatocytes but enhanced the liver proliferative response to hepatectomy in rats[1,16,21] and dogs[22] and prevented atrophy increased cell renewal caused by portacaval shunt (Eck's fistula) in dogs[23,24]. ALR recently has been the subject of intense investigation. Several different approaches have led to the identification of the respective genes from yeast, rat, mouse, and human. This review deals with the molecular biology of ALR, examining cloning of the ALR gene and its protein product from yeast to man. The biological function of this protein product is also described.

ALR GENE AND PROTEIN FROM YEAST TO MAN

Yeast scERV1

The yeast scERV1 gene was the first and best-characterized gene of a new family found in a large number of lower and higher eukaryotes[25-28] and in the genome of some double-stranded DNA viruses[29-31]. This gene encodes a small protein of 189 amino acids (22 ku) having a complex influence on different aspects of mitochondrial biogenesis[32-34] and is essential for the survival of yeast[28]. Further studies have shown that the protein (Erv1p) was essential for normal mitochondrial morphology and for the stable maintenance of these organelles. In addition, Erv1p was identified as the first FAD-linked sulfhydryl oxidase from yeast[34]. The enzymatic activity was located at the 15 ku carboxy-terminal domain of the Erv1p with the conserved Cys-X-X-Cys sequence motif (CXXC motif). This frag-

ment was able to bind FAD and to catalyze the formation of disulfide bonds but was no longer able to form dimers like the complete protein[35]. Last but not least, analysis of the complete genome sequence from *S. cerevisiae* revealed a second yeast gene with homologies and structural similarities to scERV1. This gene was termed scERV2. Its protein product (Erv2p) had a length of 196 amino acids and exhibited 30% identical amino acid residues with Erv1p in the highly conserved carboxy-terminal part of the polypeptides. However, the complex expression pattern and the high degree of variability found in the amino-terminal regions of the scERV1 and scERV2 proteins, as well as the differences found between them, indicated that the gene products might have diverse functions at different locations and critical times of cellular development[30].

Rat ALR

Hagiya *et al* in 1994, first discovered and cloned ALR in rat and then in human and mouse, proposing also its identity with HSS or hepatopoietin (HPO)[25]. They cloned and sequenced the rat ALR gene, which was considered to encode rat HSS[25]. They also presented evidence that ALR protein (Alrp) was acting as a homodimer and reported that the expression of the 1.2 kb gene transcript was elevated in rat testis and liver. The 1.2 kb cDNA included a 299 bp 5' untranslated region, a 375 bp coding region and a 550 bp 3' untranslated one. The rat Alrp consisted of 125 amino acids and its molecular weight was calculated to be 15 ku, which is consistent with its electrophoretically determined molecular weight under reducing conditions. The molecular weight of the purified native Alrp was calculated to be 30 ku under nonreducing conditions. The 125 amino acid sequence deduced from the rat ALR cDNA presented as 50% homologous to the polypeptide encoded by the scERV1, which is essential for oxidative phosphorylation, vegetative growth and life of the yeast *S. cerevisiae*[25]. The same investigators, in supplementary experiments, found a single nucleotide (G) insertion at cDNA position 266, which did not alter the results of recombinant Alrp of 125 amino acids that was originally identified. On the other hand, additional G engendered two other in-frame ATG initiation sites, which were 5' to the initiation site of the Alrp they had previously reported, thus raising the possibility of additional ALR variants[36]. Furthermore, the cloning and sequence analysis of rat genomic DNA of ALR revealed that the gene consisted of 3 exons and 2 introns and was 1508 nt long[37]. An ALR pseudogene was also found in the rat genome, implying the existence of an ALR multigene family. The length of the psedogene was calculated to be 442 nt[37]. The amino acid sequence homology between the rat ALR and its psedogene proved to be 88.8%[38]. The crystal structure of recombinant rat Alrp has been determined to 1.8 Å. The structure revealed a unique FAD binding motif, a region containing side chain rings in a stacked parallel orientation, as has recently been reported in Erv2p, and an extensive salt bridges network being unique to ALR. The abundance of disulfide and salt bridges provides the Alrp molecule with a rigid structure and probably accounts for Alrp's thermostability and resistance to some denaturants[39].

Mouse ALR

The mouse ALR gene was cloned and characterized by Giorda *et al* in 1996[26]. It was shown that the protein coding portion of the mouse ALR gene contained 3 exons. The first of them consisted of the 5' untranslated sequence and the initial 18 bases after the ATG translation initiation codon. The second exon contained 198 bases and the third one consisted of the remaining portion of the protein coding sequence. Moreover, the ALR gene mapped to mouse chromosome 17, in a region syntenic with human chromosome 16[26].

Human ALR

Giorda *et al* also published the cDNA sequence of human ALR[26]. At the same time, Yang *et al* cloned the cDNA of human HPO by functional screening of a fetal liver cDNA library demonstrating that human HPO was identical to human ALR[40]. The cDNA of human ALR encoding 125 amino acids presented identity of 87% with rat ALR and of 42% to yeast scERV1[40]. The human ALR gene was located on chromosome 16, at the cytogenetic band 16p13.3-p13.12, in the interval containing the locus for polycystic kidney disease (PKD1)[27]. The cloning and sequence analysis of human ALR genomic DNA revealed that it consisted of 3 exons and 2 introns. It was 1813 nt long, coding a protein of 125 amino acid residues. A comparison of human and mouse genomic DNA demonstrated that the 3 exons were similar in length but different in their 5'-UTR, introns and 3'-UTR in length[41,42]. Lu *et al* isolated a variant of ALR from hepatic-derived cells with a length of 205 amino acids, characterizing a novel isoform of HPO cDNA encoding a 205 amino acid open reading frame (ORF). This was named HPO-205 to distinguish it from the previously described HPO, which lacked the N-terminal 80 amino acids[43].

Therefore, two forms of the human Alrp were found to be present in hepatocytes. The shorter protein consisted of 125 amino acids (15 ku) and lacked the amino terminus and the longer protein had 205 amino acids (23 ku). The 15 ku of Alrp existed only in the nucleus and the 23 ku Alrp was mainly located in the cytosol, probably because they are synthesized from the same mRNA using different initiation codons[44]. Moreover, under normal conditions, the full-length 23 ku mammalian Alrp is predominant and localized in the mitochondrial intermembrane space[45]. As a result, ALR could be dimerized at a protein level and its gene could be alternatively spliced at the transcriptional level. Both might contribute to the existence of various Alrp complexes in hepatocytes[44].

Recent studies reported successfully cloning the genes encoding proteins that interact with Alrp, such as metallothionein and albumin, which might be related to the transportation process of Alrp in the circulation. Selenoprotein-P, an anti-oxidant protein, might also be related to Alrp function, as well as other ALR-binding proteins, such elongation factor 1-α, transitional endoplasmic reticulum ATPase, carboxypeptidase N 83 ku chain, complete factor H related 3, and NADP dehydrogenase, which are known to play important roles in energy metabolism[46].

Table 1 Augmenter of liver regeneration from yeast to man

	Homo Sapiens (Human)	Mus Musculus (Mouse)	Rattus Norvegicus (Rat)	Saccharomyces cerevisae (Yeast)
Description	Augmenter of liver regeneration (ALR)/growth factor, erv1 (S. cerevisiae)-like (augmenter of liver regeneration) (GFER)/ hepatic regenerative stimulation substance (HSS)/hepatopoietin (HPO)	Augmenter of liver regeneration (Alr)/growth factor, erv1 (S. cerevisiae)-like (augmenter of liver regeneration) (Gfer)	Augmenter of liver regeneration (ALR)/ growth factor, erv1 (S. cerevisiae)-like (augmenter of liver regeneration) (Gfer)	Saccharomyces cerevisiae ERV1 (scERV1)/flavin-linked sulfhydryl oxidase localized to the mitochondrial intermembrane space, has a role in the maturation of cytosolic iron-sulphur proteins; ortholog of human hepatopoietin (ALR)
Genomic Location	Chromosome: 16 Cytogenetic: 16p13.3-p13.12	Chromosome: 17 Cytogenetic: 17 A3.3	Chromosome: 10 Cytogenetic: 10q12 Genetic: 17 10.0 cM	Chromosome: VII
Peptide Length	205 aa (23 ku) 125 aa (15 ku)	198 aa	125 aa (15 ku)	189 aa (22 ku)
Protein Function	In liver regeneration and spermatogenesis	In liver regeneration and spermatogenesis	In liver regeneration and spermatogenesis	Essential for the biogenesis of mitochondria, cell viability and for vegetative growth
Protein Subunit	Homodimer/Heterodimer	Homodimer	Homodimer	Homodimer
Protein Similarity	Belongs to ERV1/ALR family	Belongs to ERV1/ALR family	Belongs to ERV1/ALR family	Belongs to ERV1/ALR family
Percentage of similarity to human		85.6% [The comparison with human is based on nucleic acid (GeneCard for GFER)] 87.20% [The comparison with human is based on amino acid sequence (UniGene)]	85.87% [The comparison with human is based on nucleic acid (GeneCard for GFER)] 85.60% [The comparison with human is based on amino acid sequence (UniGene)]	52.85% [The comparison with human is based on nucleic acid (GeneCard for GFER)] 46.85% [The comparison with human is based on amino acid sequence (UniGene)]
Subcellular Location	Nucleus (15 ku) Cytosol (23 ku) Mitochondrial intermembrane space (23 ku)	Mitochondrial intermembrane space	Cytosol Mitochondrial intermembrane space	Cytosol Mitochondrial intermembrane space

The ALR gene promoter has also been studied and might represent a novel architecture for core promoters. It was TATA-less and spanned position -54 to +42 relative to the transcriptional start point. Specifically, it did not contain the TATA box, a consensus A/T rich sequence [TATA (A/T) A (A/T)], which was located -25-30 nucleotides upstream of the transcriptional start site and was recognized by the TATA binding protein subunit of TFIID. TFIID is a transcription factor that was needed to bring about the initiation of transcription by RNA polymerase Ⅱ and nucleated the formation of the pre-initiation complex. In addition, the core promoter of ALR consisted of a functional initiator (Inr) and three CTGGAGGC tandem repeat elements, which were found surrounding the Inr, with all of them participating in Inr-dependent transcription. The Inr contains a pyrimidine (Y) rich core sequence [YYA+1N (T/A) YY] encompassing the transcription site. The initiator flanking element, lying either upstream or downstream from the Inr, was found to be present in many Inr-containing genes. Both the initiator and at least one of the repeats were able to bind to specific nuclear factors[47].

The similarities and differences between the structure and function of the ALR gene and its protein product in the four most important and closely related species (yeast, mouse, rat and human) are displayed in Table 1.

BIOLOGICAL FUNCTION OF ALRP

Characterization of human Alrp as a structural and functional homologue for yeast Erv1p

Alrp and Erv1p belong to a protein family, members of which are found in lower and higher eukaryotes from yeast to man[25-28] and even on the genome of some double-stranded DNA viruses[29-31]. They have essential functions in the biogenesis of mitochondria, the cell division cycle, and in the development of organs such as liver and testis in higher eukaryotes[48]. The carboxy terminus of the human Alrp was characterized as a structural and functional homologue for yeast Erv1p[27]. Especially, Lisowsky *et al* found four major similarities at the amino acid residues of carboxy termini of Erv1p and human Alrp, concluding a conservation of structure and function[27]. However, Hofhaus *et al* showed that the conserved carboxy terminus of mammalian and yeast proteins were functionally interchangeable between distantly related species such as yeast and man[49]. On the other hand, the amino terminal parts of the proteins displayed a high degree of variability and significant differences even among closely related species[49]. Specifically, Hofhaus *et al* first revealed that the yeast protein contained a leader sequence for mitochondrial localization whereas the human protein is not detectable inside the mitochondria. Moreover, they noted that, in yeast only, one form of scERV1 was found

whereas in human cells two protein isoforms were present. Therefore, these two significant differences in the amino termini between Erv1p and human Alrp suggested that the human Alrp did not appear to be functional in yeast[49].

The enzymatic activity of Alrp as sulfhydryl oxidase

The Alrp/Erv1p family belongs to flavin-linked sulfhydryl oxidase participating in disulfide bond formation[35,50]. Lisowsky *et al* identified the enzymatic activity of rat and human Alrp as sulfhydryl oxidases by their ability to oxidize thiol groups in a protein substrate, the presence of FAD moiety in the carboxy terminal domain and the formation of dimers *in vivo*[50]. In general, the sulfhydryl oxidase proteins contain a conserved CXXC motif in the carboxy terminal domain and a non-covalent FAD, which are vital for their catalytic activity[51-53]. The conserved CXXC motif in the carboxy terminus most likely represents the redox-active site of the enzyme, sharing significant homologies with human growth regulator quiescin Q6[52] and yeast Erv1p[35]. It was also reported that the two vicinal cysteines directly interact with bound FAD for the redox reaction. Furthermore, sulfhydryl oxidases form dimers *in vivo* and catalyze the formation of disulfide bonds with the reduction of molecular oxygen to hydrogen peroxide according to the following reaction: 2RS-H + O2 → RSSR + H2O2[51-53].

An interesting new aspect for mitochondrial sulfhydryl oxidase activity and the formation of disulfide bonds was the recent finding of a direct correlation between the electron transport chain and the formation of disulfide bonds in *E coli*[54,55]. A very recent study on the fundamental behavior of the short form of the human Alrp suggested that this flavoenzyme might not necessarily function as sulfhydryl oxidase in the mitochondrial intermembrane space but might be coupled with the respiration chain *via* mediation of cytochrome *c* and without the generation of hydrogen peroxide observed in oxidase reactions. Thus, cytochrome *c* should be considered as a potential oxidant for ALR *in vivo*[56].

The presence of a specific receptor for Alrp and modes of Alrp signaling

Wang *et al* showed the existence of an Alrp receptor on rat hepatocytes and human hepatoma cells with a molecular weight of about 75 ku, presenting with high affinity and specificity, reversibility and saturation[57]. Alrp binds the receptor in cell membranes initiating a corresponding signal transduction pathway and mediating its biological function on hepatocytes. This function includes specific phosphorylation and dephosphorylation of important proteins in the process of liver regeneration[57].

Yang *et al* showed that recombinant human HPO/Alrp (125 amino acids, 15 ku) could stimulate proliferation of hepatocytes as well as hepatoma cells *in vitro*, promoting regeneration and recovery of damaged hepatocytes and ameliorating acute hepatic failure *in vivo*. Such observations support the contention that Alrp is a hepatotrophic growth factor[58,59].

It was shown that HPO/Alrp was able to stimulate hepatocyte proliferation by two signaling pathways. In the first pathway, extracellular HPO autocrined from hepatocytes and hepatoma cells activated the mitogen-activated protein kinase (MAPK) signaling pathway *via* binding to an ALR receptor. Specifically, Alrp triggered MAPK activation and proliferation in hepatoma cell lines through the induction of tyrosine phosphorylation of epidermal growth factor receptor (EGFR)[60].

In the second signaling pathway, intracellular Alrp interacted with Jun activation domain-binding protein 1 (JAB1), triggering the activating protein-1 (AP-1) transcriptional activity in a MAPK independent manner, for immediate early response when its intracellular levels were increased with post-partial hepatectomy or liver injury[61]. JAB1 is the fifth subunit of COP9 signalosome (CSN), being a co-activator of c-Jun/AP-1 transcription factor, which enhances the binding capacity of c-Jun-containing AP-1 complex to their DNA consensus sites and increasing the transactivation of an AP-1 dependent promoter. It was shown that Alrp enhanced the increased phosphorylation level of c-Jun through JAB1 but had no effect on the expression of transfected c-Jun or endogenous c-Jun N-terminal kinase or on phosphorylation of c-Jun N-terminal kinase[61]. Furthermore, recent studies elucidated a novel relationship of intracellular Alrp with the whole protein complex CSN, suggesting a possible linkage between CSN and liver regeneration[62]. As a consequence, the CSN complex could represent an intracellular signal platform, where signals from the extracellular or intracellular environment are coordinated with transcriptional activation and with the regulation of the related functions of cells.

Chen *et al* presented a molecular link between the enzymatic redox function of HPO/Alrp and its role as a cytokine[63]. They displayed the necessity of cysteine residues in the CXXC catalytic centre for the intracellular potentiation of AP-1 activity. As mentioned before, Alrp interacted with JAB1 to trigger AP-1 transcription activity by phosphorylation of c-Jun in a MAPK independent fashion. This effect depended on the integrity of the CXXC enzyme active site, which could provide a novel intracellular signaling pathway shortcut by redox regulation. This implied that the enzymatic activity of Alrp might be a key regulator in the intracellular mediation of the AP-1 pathway through JAB1. On the other hand, they provided evidence that the extracellular cytokine activity of Alrp did not associate with the redox CXXC motif and consequently with its sulfhydryl oxidase activity[63].

Recently, Li *et al* demonstrated that ALR and macrophage inhibitory factor (MIF) could be considered as a pair in the course of signaling transduction[64]. Their results showed an interaction between ALR and MIF and led to the alteration of their effects on AP-1 activity. Especially, on the one hand, the binding of MIF to JAB1 was inhibited by ALR and on the other hand the potentiation of the ALR on AP-1 activity through JAB1 was inhibited by MIF. Thus, the activity of AP-1 may be determined by the coordination and balance between ALR and MIF concentration *in vivo*. This balance is crucial for the maintenance of both homeostasis and normal development of cells and tissues. In this sense, ALR serves as physiological counter-regulatory mediator that counteracts the suppressive effect of MIF[64].

Alrp biological activity

Previous studies have demonstrated that different forms of Alrp may be associated with different localizations and cellular functions[26,49,65]. Specifically, a 15 ku Alrp fragment appeared to regulate mitochondrial gene expression by inducing the transcription and translation of the nuclear-encoded mitochondrial transcription factor A (mtTFA)[66]. Polimeno *et al* found that Alrp administration induced a significant increase in mitochondrial gene expression and of nuclear-encoded mtTFA. This increase was associated with enhanced cytochrome content and oxidative phosphorylation capacity of rat liver-derived mitochondria[66]. It has also been suggested that hepatotrophic factors, such as Alrp, play an important role in liver regeneration and might mediate their activities by regional regulation of natural killer (NK) cells. However, NK cells in liver appeared to have specific cytotoxicity against regenerating hepatocytes. A recent study revealed that *in vivo* administration of Alrp induced inhibition of hepatic NK cytotoxic activities in the population of mononuclear leukocytes infiltrating rat liver but not in those derived from spleen or peripheral blood. These data suggested that Alrp might act as an immunosuppressant agent localized to the liver[67]. Moreover, Tanigawa *et al* suggested that Alrp production in the liver was enhanced during acute liver disease, especially in the initial stage[68]. It was also suggested that Alrp might protect against failure of regeneration by inhibiting hepatic NK cell activity in acute liver disease[68]. It was also demonstrated that Alrp acted as an immunoregulator by controlling, through interferon-gamma (IFN-γ) levels, the mtTFA expression and lytic activity of liver-resident NK cells. The exogenous administration Alrp in intact rats induced a reduction of IFN-γ in liver-resident NK cells, while the administration of IFN-γ in 70% of partially hepatectomized rats was followed by a significant reduction of both mtTFA expression and liver regeneration. These results demonstrated a direct link between Alrp and IFN-γ, implying IFN-γ as the main mediator of Alrp biological activity both as growth factor and immunoregulator[69]. Recent studies discussed a constructed yeast expressive vector of ALR and this was expressed in yeast cells in order to further study the biological function and mechanism of recombinant human ALR as a regulatory factor that specifically stimulates hepatic cell regeneration. This successful expression of ALR in yeast cells may pave the way for the study of clinical use and provided a good tool for further research in this field. Their results also suggested that ALR enhanced liver regeneration not only through an indirect pathway; i.e. immune regulation, but also through a direct pathway[70-71].

Recently, an ALR recombinant plasmid was constructed and tested for therapeutic effects on rat hepatic fibrosis. Specifically, the results of this study revealed that the ALR recombinant plasmid could decrease the degrading capacity of collagen types I and III, which were regarded as important parameters reflecting the metabolism of collagen. The ALR recombinant plasmid could also decrease the deposition of the extracellular matrix and the expression of tissue inhibitors of metalloproteinase-1 (TIMP-1) in pathological liver tissue and thus reverse the hepatic fibrosis induced by porcine serum administration[72].

In addition, the full-length mammalian Alrp (23 ku) was largely located in the mitochondrial intermembrane space and performed the export of iron/sulfur (Fe/S) clusters from the mitochondrial matrix, contributing to the biogenesis of cytosolic Fe/S proteins and to cellular iron homeostasis. Especially, Fe/S cluster components of the mitochondrial matrix preassembled and packaged Fe/S clusters, which could then be transported into the cytosol, a process possibly involving the ABC transporter Atm1p/ABC7[45]. Cytosolic and nuclear Fe/S proteins have important regulatory functions as enzymes or transcription factors. Therefore, participation in the assembly of cytosolic Fe/S proteins appears to be the primary essential task of mitochondrial full-length Alrp[45]. This function is crucial for all eukaryotic cell types, whereas the proposed role of 15 ku Alrp as a hepatotrophic factor is restricted to liver cells and it may be effective only after liver damage. This indicates that Alrp, like other redox-active proteins and sulfhydryl oxidases, may have diverse functions in the regulation of cell growth and differentiation[20,48,57,60,65].

Klissenbauer *et al* first characterized full-length Alrp as intratesticular sulfhydryl oxidase, a new enzyme with expression regulated during spermatogenesis[73]. Mitochondrial localization of full-length Alrp was of special interest for spermatogenesis because it was known that morphological and functional changes in mitochondria were associated with this highly complex cytodifferentiation process. They also observed the greatest amounts of this protein in spermatogonia and early spermatocytes. Expression levels of Alrp did not correlate with synthesis of components of the respiratory chain, indicating that the full-length Alrp in the mitochondria of spermatogonia and spermatocytes had another possible function in addition to its role in oxidative phosphorylation during sperm cell differentiation[73].

CONCLUSION

ALR is novel growth factor, related to HSS, participating in the regulation of liver regeneration. With the availability and description of the ALR gene and gene product, a range of questions could be addressed about the cellular mechanisms in which this growth factor participates. At the molecular level, cloning of human ALR cDNA has been completed, but transcription and post-transcriptional regulation, based on the genomic structure of ALR, remains unclear. Transcription and post-transcriptional regulation are among the most important steps in the regulation of human gene expression. Therefore, it is important and essential to investigate the structure of human ALR genomic DNA. Contrary to previous belief, variable RNA expression in nonhepatic tissues suggests that ALR is not restricted to liver tissue, as was also suggested for HSS, but could be expressed in other cell types under appropriate circumstances. It is known that Alrp acts as a FAD-linked sulfhydryl oxidase belonging to the new Erv1p/Alrp family and is the only intratesticular sulfhydryl oxidase detected in the mitochondrial intermembrane space. Possible functions of sulfhyrdyl oxidases and other redox-active proteins in the regulation of cell growth, differentiation, changes in mitochondrial and cellular morphology, and in the formation of the

extracellular matrix have already been proposed. This indicates that Alrp, like other redox-active proteins and sulfhydryl oxidases, might have diverse functions. Additionally, limited data are available on the secreted Alrp bound to a specific receptor on the hepatocyte membrane and initiation of a signal transduction pathway and mediation of its biological effect on hepatocytes. Further studies should examine the distribution of human Alrp receptors on hepatocytes and on other cell types. The secretory pathway should also be further investigated because Alrp does not contain a typical signal peptide sequence evident of its primary structure. Moreover, Alrp production, expression regulation, secretion-transportation and importance, and also its genetic function, need to be further delineated. As a consequence, there is a necessity to extend studies on mammalian Alrp to different tissues, organs and developmental processes in conditions of normal and abnormal cellular growth. It is clear that the multiple functions of Alrp are biologically and physiologically complicated and need further study.

REFERENCES

1 **LaBrecque DR**, Pesch LA. Preparation and partial characterization of hepatic regenerative stimulator substance (SS) from rat liver. *J Physiol* 1975; **248**: 273-284

2 **LaBrecque DR**. Hepatic stimulator substance. Discovery, characteristics and mechanism of action. *Dig Dis Sci* 1991; **36**: 669-673

3 **Margeli AP**, Skaltsas SD, Spiliopoulou CA, Mykoniatis MG, Theocharis SE. Hepatic stimulator substance activity in the liver of thioacetamide-intoxicated rats. *Liver* 1999; **19**: 519-525

4 **Liatsos GD**, Mykoniatis MG, Margeli A, Liakos AA, Theocharis SE. Effect of acute ethanol exposure on hepatic stimulator substance (HSS) levels during liver regeneration: protective function of HSS. *Dig Dis Sci* 2003; **48**: 1929-1938

5 **Zhou Z**, Tan R, Su S, Zhou C. Effects of human HSS on hepatocyte and hepatoma cell proliferation and D-GAL induced acute liver failure. *Chin Med Sci J* 1992; **7**: 197-200

6 **Yao ZQ**, Yang WS, Zhang WB, Chen Y, Zhou YX. Hepatic stimulator substance from human fetal liver for treatment of experimental hepatic failure. *Chin Med J (Engl)* 1992; **105**: 676-683

7 **Francavilla A**, Azzarone A, Carrieri G, Cillo U, Van Thiel D, Subbottin V, Starzl TE. Administration of hepatic stimulatory substance alone or with other liver growth factors does not ameliorate acetaminophen-induced liver failure. *Hepatology* 1993; **17**: 429-433

8 **Mei MH**, An W, Zhang BH, Shao Q, Gong DZ. Hepatic stimulator substance protects against acute liver failure induced by carbon tetrachloride poisoning in mice. *Hepatology* 1993; **17**: 638-644

9 **Theocharis SE**, Margeli AP, Agapitos EV, Mykoniatis MG, Kittas CN, Davaris PS. Effect of hepatic stimulator substance administration on tissue regeneration due to thioacetamide-induced liver injury in rats. *Scand J Gastroenterol* 1998; **33**: 656-663

10 **Zhang BH**, Gong DZ, Mei MH. Protection of regenerating liver after partial hepatectomy from carbon tetrachloride hepatotoxicity in rats: role of hepatic stimulator substance. *J Gastroenterol Hepatol* 1999; **14**: 1010-1017

11 **Margeli AP**, Papadimitriou L, Ninos S, Manolis E, Mykoniatis MG, Theocharis SE. Hepatic stimulator substance administration ameliorates liver regeneration in an animal model of fulminant hepatic failure and encephalopathy. *Liver Int* 2003; **23**: 171-178

12 **Zhang M**, Song G, Minuk GY. Effects of hepatic stimulator substance, herbal medicine, selenium/vitamin E, and ciprofloxacin on cirrhosis in the rat. *Gastroenterology* 1996; **110**: 1150-1155

13 **Theocharis SE**, Margeli AP, Spiliopoulou C, Skaltsas S, Kittas C, Koutselinis A. Hepatic stimulator substance administration enhances regenerative capacity of hepatocytes in cadmium-pretreated partially hepatectomized rats. *Dig Dis Sci* 1996; **41**: 1475-1480

14 **Jiang B**, Sawa M, Yamamoto T, Kasai S. Enhancement of proliferation of intrasplenically transplanted hepatocytes in cirrhotic rats by hepatic stimulatory substance. *Transplantation* 1997; **63**: 131-135

15 **Francavilla A**, DiLeo A, Polimeno L, Gavaler J, Pellicci R, Todo S, Kam I, Prelich J, Makowka L, Starzl TE. The effect of hepatic stimulatory substance, isolated from regenerating hepatic cytosol, and 50,000 and 300,000 subfractions in enhancing survival in experimental acute hepatic failure in rats treated with D-galactosamine. *Hepatology* 1986; **6**: 1346-1351

16 **Francavilla A**, Ove P, Polimeno L, Coetzee M, Makowka L, Rose J, Van Thiel DH, Starzl TE. Extraction and partial purification of a hepatic stimulatory substance in rats, mice, and dogs. *Cancer Res* 1987; **47**: 5600-5605

17 **Francavilla A**, Barone M, Van Thiel DH, Mazzaferro V, Prelich JG, Starzl TE. Further steps of hepatic stimulatory substance purification. *Dig Dis Sci* 1991; **36**: 674-680

18 **Francavilla A**, Azzarone A, Carrieri G, Scotti-Foglieni C, Zeng QH, Cillo U, Porter K, Starzl TE. Effect on the canine Eck fistula liver of intraportal TGF-beta alone or with hepatic growth factors. *Hepatology* 1992; **16**: 1267-1270

19 **Francavilla A**, Polimeno L, Barone M, Azzarone A, Starzl TE. Hepatic regeneration and growth factors. *J Surg Oncol Suppl* 1993; **3**: 1-7

20 **Francavilla A**, Hagiya M, Porter KA, Polimeno L, Ihara I, Starzl TE. Augmenter of liver regeneration: its place in the universe of hepatic growth factors. *Hepatology* 1994; **20**: 747-757

21 **Webber EM**, Godowski PJ, Fausto N. In vivo response of hepatocytes to growth factors requires an initial priming stimulus. *Hepatology* 1994; **19**: 489-497

22 **Terblanche J**, Porter KA, Starzl TE, Moore J, Patzelt L, Hayashida N. Stimulation of hepatic regeneration after partial hepatectomy by infusion of a cytosol extract from regenerating dog liver. *Surg Gynecol Obstet* 1980; **151**: 538-544

23 **Starzl TE**, Porter KA, Putnam CW. Intraportal insulin protects from the liver injury of portacaval shunt in dogs. *Lancet* 1975; **2**: 1241-1242

24 **Starzl TE**, Jones AF, Terblanche J, Usui S, Porter KA, Mazzoni G. Growth-stimulating factor in regenerating canine liver. *Lancet* 1979; **1**: 127-130

25 **Hagiya M**, Francavilla A, Polimeno L, Ihara I, Sakai H, Seki T, Shimonishi M, Porter KA, Starzl TE. Cloning and sequence analysis of the rat augmenter of liver regeneration (ALR) gene: expression of biologically active recombinant ALR and demonstration of tissue distribution. *Proc Natl Acad Sci USA* 1994; **91**: 8142-8146

26 **Giorda R**, Hagiya M, Seki T, Shimonishi M, Sakai H, Michaelson J, Francavilla A, Starzl TE, Trucco M. Analysis of the structure and expression of the augmenter of liver regeneration (ALR) gene. *Mol Med* 1996; **2**: 97-108

27 **Lisowsky T**, Weinstat-Saslow DL, Barton N, Reeders ST, Schneider MC. A new human gene located in the PKD1 region of chromosome 16 is a functional homologue to ERV1 of yeast. *Genomics* 1995; **29**: 690-697

28 **Lisowsky T**. Dual function of a new nuclear gene for oxidative phosphorylation and vegetative growth in yeast. *Mol Gen Genet* 1992; **232**: 58-64

29 **Coppock DL**, Cina-Poppe D, Gilleran S. The quiescin Q6 gene (QSCN6) is a fusion of two ancient gene families: thioredoxin and ERV1. *Genomics* 1998; **54**: 460-468

30 **Stein G**, Lisowsky T. Functional comparison of the yeast scERV1 and scERV2 genes. *Yeast* 1998; **14**: 171-180

31 **Yáñez RJ**, Rodríguez JM, Nogal ML, Yuste L, Enríquez C, Rodriguez JF, Viñuela E. Analysis of the complete nucleotide sequence of African swine fever virus. *Virology* 1995; **208**:

249-278
32 **Lisowsky T**. ERV1 is involved in the cell-division cycle and the maintenance of mitochondrial genomes in Saccharomyces cerevisiae. *Curr Genet* 1994; **26**: 15-20
33 **Lisowsky T**. Removal of an intron with unique 3' branch site creates an amino-terminal protein sequence directing the scERV1 gene product to mitochondria. *Yeast* 1996; **12**: 1501-1510
34 **Becher D**, Kricke J, Stein G, Lisowsky T. A mutant for the yeast scERV1 gene displays a new defect in mitochondrial morphology and distribution. *Yeast* 1999; **15**: 1171-1781
35 **Lee J**, Hofhaus G, Lisowsky T. Erv1p from Saccharomyces cerevisiae is a FAD-linked sulfhydryl oxidase. *FEBS Lett* 2000; **477**: 62-66
36 **Hagiya M**, Francavilla A, Polimeno L, Ihara I, Sakai H, Seki T, Shimonishi M, Porter KA, Starzl TE. Cloning and sequence analysis of the rat augmenter of liver regeneration (ALR) gene: expression of biologically active recombinant ALR and demonstration of tissue distribution. *Proc Natl Acad Sci USA* 1995; **92**: 3076
37 **Dong J**, Cheng J, Wang Q, Shi S, Wang G, Si C. Cloning and analysis of the genomic DNA sequence of augmenter of liver regeneration from rat. *Chin Med Sci J* 2002; **17**: 63-67
38 **Dong J**, Cheng J, Liu Y, Wang Q, Wang G, Shi S, Si C. [Cloning and sequence analysis of a pseudogene of liver regeneration augmenter in rats]. *Zhonghua Ganzangbing Zazhi* 2001; **9**: 105-107
39 **Wu CK**, Dailey TA, Dailey HA, Wang BC, Rose JP. The crystal structure of augmenter of liver regeneration: A mammalian FAD-dependent sulfhydryl oxidase. *Protein Sci* 2003; **12**: 1109-1118
40 **Yang XM**, Xie L, Qiu ZH, Wu C, He FC. Cloning and characterizing of a new type human liver regeneration augmenter. *Sci China* 1997; **6**: 642-647
41 **Cheng J**, Zhong YW, Liu Y, Dong J, Yang JZ, Chen JM. Cloning and sequence analysis of human genomic DNA of augmenter of liver regeneration. *World J Gastroenterol* 2000; **6**: 275-277
42 **Cheng J**, Zhong Y. Cloning and sequence analysis of human genomic DNA of augmenter of liver regeneration hepatitis. *Zhonghua Ganzangbing Zazhi* 2000; **8**: 12-14
43 **Lu J**, Xu WX, Zhan YQ, Cui XL, Cai WM, He FC, Yang XM. Identification and characterization of a novel isoform of hepatopoietin. *World J Gastroenterol* 2002; **8**: 353-356
44 **Li Y**, Wei K, Lu C, Li Y, Li M, Xing G, Wei H, Wang Q, Chen J, Wu C, Chen H, Yang S, He F. Identification of hepatopoietin dimerization, its interacting regions and alternative splicing of its transcription. *Eur J Biochem* 2002; **269**: 3888-3893
45 **Lange H**, Lisowsky T, Gerber J, Mühlenhoff U, Kispal G, Lill R. An essential function of the mitochondrial sulfhydryl oxidase Erv1p/ALR in the maturation of cytosolic Fe/S proteins. *EMBO Rep* 2001; **2**: 715-720
46 **Cheng J**, Wang L, Li K, Lu YY, Wang G, Liu Y, Zhong YW, Duan HJ, Hong Y, Li L, Zhang LX, Chen JM. Screening of augmenter of liver regeneration-binding proteins by yeast-two hybrid technique. *Hepatobiliary Pancreat Dis Int* 2003; **2**: 81-84
47 **Zhao Y**, Tang F, Cheng J, Li L, Xing G, Zhu Y, Zhang L, Wei H, He F. An initiator and its flanking elements function as a core promoter driving transcription of the Hepatopoietin gene. *FEBS Lett* 2003; **540**: 58-64
48 **Polimeno L**, Lisowsky T, Francavilla A. From yeast to man--from mitochondria to liver regeneration: a new essential gene family. *Ital J Gastroenterol Hepatol* 1999; **31**: 494-500
49 **Hofhaus G**, Stein G, Polimeno L, Francavilla A, Lisowsky T. Highly divergent amino termini of the homologous human ALR and yeast scERV1 gene products define species specific differences in cellular localization. *Eur J Cell Biol* 1999; **78**: 349-356
50 **Lisowsky T**, Lee JE, Polimeno L, Francavilla A, Hofhaus G. Mammalian augmenter of liver regeneration protein is a sulfhydryl oxidase. *Dig Liver Dis* 2001; **33**: 173-180
51 **Hoober KL**, Joneja B, White HB 3rd, Thorpe C. A sulfhydryl oxidase from chicken egg white. *J Biol Chem* 1996; **271**: 30510-30516
52 **Hoober KL**, Glynn NM, Burnside J, Coppock DL, Thorpe C. Homology between egg white sulfhydryl oxidase and quiescin Q6 defines a new class of flavin-linked sulfhydryl oxidases. *J Biol Chem* 1999; **274**: 31759-31762
53 **Hoober KL**, Thorpe C. Egg white sulfhydryl oxidase: kinetic mechanism of the catalysis of disulfide bond formation. *Biochemistry* 1999; **38**: 3211-3217
54 **Kobayashi T**, Ito K. Respiratory chain strongly oxidizes the CXXC motif of DsbB in the Escherichia coli disulfide bond formation pathway. *EMBO J* 1999; **18**: 1192-1198
55 **Bader M**, Muse W, Ballou DP, Gassner C, Bardwell JC. Oxidative protein folding is driven by the electron transport system. *Cell* 1999; **98**: 217-227
56 **Farrell SR**, Thorpe C. Augmenter of liver regeneration: a flavin-dependent sulfhydryl oxidase with cytochrome c reductase activity. *Biochemistry* 2005; **44**: 1532-1541
57 **Wang G**, Yang X, Zhang Y, Wang Q, Chen H, Wei H, Xing G, Xie L, Hu Z, Zhang C, Fang D, Wu C, He F. Identification and characterization of receptor for mammalian hepatopoietin that is homologous to yeast ERV1. *J Biol Chem* 1999; **274**: 11469-11472
58 **Yang XM**, Hu ZY, Xie L, Wu ZZ, Wu CT, He FC. [In vitro stimulation of HTC hepatoma cell growth by recombinant human augmenter of liver regeneration (ALR)]. *Shengli Xuebao* 1997; **49**: 557-561
59 **Yang XM**, Xie L, He H, Wei HD, Wu ZZ, He FC. Expression and Activity of Recombinant Human Augmenter of Liver Regeneration. *Shengwu Huaxue Yu Shengwu Wuli Xuebao (Shanghai)* 1997; **29**: 414-418
60 **Li Y**, Li M, Xing G, Hu Z, Wang Q, Dong C, Wei H, Fan G, Chen J, Yang X, Zhao S, Chen H, Guan K, Wu C, Zhang C, He F. Stimulation of the mitogen-activated protein kinase cascade and tyrosine phosphorylation of the epidermal growth factor receptor by hepatopoietin. *J Biol Chem* 2000; **275**: 37443-37447
61 **Lu C**, Li Y, Zhao Y, Xing G, Tang F, Wang Q, Sun Y, Wei H, Yang X, Wu C, Chen J, Guan KL, Zhang C, Chen H, He F. Intracrine hepatopoietin potentiates AP-1 activity through JAB1 independent of MAPK pathway. *FASEB J* 2002; **16**: 90-92
62 **Wang Y**, Lu C, Wei H, Wang N, Chen X, Zhang L, Zhai Y, Zhu Y, Lu Y, He F. Hepatopoietin interacts directly with COP9 signalosome and regulates AP-1 activity. *FEBS Lett* 2004; **572**: 85-91
63 **Chen X**, Li Y, Wei K, Li L, Liu W, Zhu Y, Qiu Z, He F. The potentiation role of hepatopoietin on activator protein-1 is dependent on its sulfhydryl oxidase activity. *J Biol Chem* 2003; **278**: 49022-49030
64 **Li Y**, Lu C, Xing G, Zhu Y, He F. Macrophage migration inhibitory factor directly interacts with hepatopoietin and regulates the proliferation of hepatoma cell. *Exp Cell Res* 2004; **300**: 379-387
65 **Gandhi CR**, Kuddus R, Subbotin VM, Prelich J, Murase N, Rao AS, Nalesnik MA, Watkins SC, DeLeo A, Trucco M, Starzl TE. A fresh look at augmenter of liver regeneration in rats. *Hepatology* 1999; **29**: 1435-1445
66 **Polimeno L**, Capuano F, Marangi LC, Margiotta M, Lisowsky T, Ierardi E, Francavilla R, Francavilla A. The augmenter of liver regeneration induces mitochondrial gene expression in rat liver and enhances oxidative phosphorylation capacity of liver mitochondria. *Dig Liver Dis* 2000; **32**: 510-517
67 **Francavilla A**, Vujanovic NL, Polimeno L, Azzarone A, Iacobellis A, Deleo A, Hagiya M, Whiteside TL, Starzl TE. The in vivo effect of hepatotrophic factors augmenter of liver regeneration, hepatocyte growth factor, and insulin-like growth factor-II on liver natural killer cell functions. *Hepatology* 1997; **25**: 411-415
68 **Tanigawa K**, Sakaida I, Masuhara M, Hagiya M, Okita K. Augmenter of liver regeneration (ALR) may promote liver regeneration by reducing natural killer (NK) cell activity in human liver diseases. *J Gastroenterol* 2000; **35**: 112-119
69 **Polimeno L**, Margiotta M, Marangi L, Lisowsky T, Azzarone A, Ierardi E, Frassanito MA, Francavilla R, Francavilla A. Molecular mechanisms of augmenter of liver regeneration as

immunoregulator: its effect on interferon-gamma expression in rat liver. *Dig Liver Dis* 2000; **32**: 217-225

70 **Cheng J**, Wang L, Li K, Lu YY, Liu Y, Duan HJ, Hong Y, Wang G, Li L, Zhang LX. Cloning and expression of the gene of augmeUse of liver regeneration in yeast cells. *Hepatobiliary Pancreat Dis Int* 2002; **1**: 87-91

71 **Liu Q**, Yu HF, Sun H, Ma HF. Expression of human augmenter of liver regeneration in pichia pastoris yeast and its bioactivity in vitro. *World J Gastroenterol* 2004; **10**: 3188-3190

72 **Li Q**, Liu DW, Zhang LM, Zhu B, He YT, Xiao YH. Effects of augmentation of liver regeneration recombinant plasmid on rat hepatic fibrosis. *World J Gastroenterol* 2005; **11**: 2438-2443

73 **Klissenbauer M**, Winters S, Heinlein UA, Lisowsky T. Accumulation of the mitochondrial form of the sulphydryl oxidase Erv1p/Alrp during the early stages of spermatogenesis. *J Exp Biol* 2002; **205**: 1979-1986

S- Editor Wang J **L- Editor** Lutze M **E- Editor** Bi L

PO Box 2345, Beijing 100023, China
www.wjgnet.com
wjg@wjgnet.com

World J Gastroenterol 2006 August 21; 12(31): 4959-4965
World Journal of Gastroenterology ISSN 1007-9327
© 2006 The WJG Press. All rights reserved.

Differential expression of apoptosis related proteins and nitric oxide synthases in Epstein Barr associated gastric carcinomas

Maria D Begnami, Andre L Montagnini, Andre L Vettore, Sueli Nonogaki, Mariana Brait, Alex Y Simoes-Sato, Andrea Q A Seixas, Fernando A Soares

Maria D Begnami, Fernando A Soares, Department of Pathology, Hospital do Câncer A C Camargo, São Paulo, SP, Brazil
Andre L Montagnini, Department of Abdominal Surgery, Hospital do Câncer A C Camargo, São Paulo, SP, Brazil
Andre L Vettore, Sueli Nonogaki, Mariana Brait, Alex Y Simoes-Sato, Andrea Q A Seixas, Ludwig Institute for Cancer Research, São Paulo, SP, Brazil
Supported by the Fundação de Amparo a Pesquisa do Estado de São Paulo grant 04/15650-1
Correspondence to: Maria D Begnami, MD, Laboratory of Pathology, Hospital do Câncer A C Camargo, Rua Prof Antonio Prudente 109, São Paulo, SP 01519010, Brazil. mariadirlei@gmail.com
Telephone: +55-11-21895103 Fax: +55-11-32720495
Received: 2006-03-08 Accepted: 2006-04-21

Abstract

AIM: To determine the incidence of Epstein Barr virus associated gastric carcinoma (GC) in Brazil and compare the expressions of apoptosis related proteins and nitric oxide synthases between EBV positive and negative gastric carcinoma.

METHODS: *In situ* hybridization of EBV-encoded small RNA-1 (EBER-1) and PCR was performed to identify the presence of EBV in GCs. Immunohistochemistry was used to identify expressions of bcl-2, bcl-xl, bak, bax, p53, NOS-1, NOS-2, and NOS-3 proteins in 25 EBV positive GCs and in 103 EBV negative GCS.

RESULTS: 12% of the cases of GC (25/208) showed EBER-1 and EBNA-1 expression. The cases were preferentially of diffuse type with intense lymphoid infiltrate in the stroma. EBV associated GCs showed higher expression of bcl-2 protein and lower expression of bak protein than in EBV negative GCs. Indeed, expressions of NOS-1 and NOS-3 were frequently observed in EBV associated GCs.

CONCLUSION: Our data suggest that EBV infection may protect tumor cells from apoptosis, giving them the capacity for permanent cell cycling and proliferation. In addition, EBV positive GCs show high expression of constitutive NOS that could influence tumor progression and aggressiveness.

© 2006 The WJG Press. All rights reserved.

Key words: Gastric carcinoma; EBV; Apoptosis; p53; Nitric oxide synthases

Begnami MD, Montagnini AL, Vettore AL, Nonogaki S, Brait M, Simoes-Sato AY, Seixas AQA, Soares FA. Differential expression of apoptosis related proteins and nitric oxide synthases in Epstein Barr associated gastric carcinomas. *World J Gastroenterol* 2006; 12(31): 4959-4965

http://www.wjgnet.com/1007-9327/12/4959.asp

INTRODUCTION

Gastric carcinoma (GC) is one of the most common malignant tumors in the world, although its incidence has gradually declined in recent years. In Brazil, gastric cancer remains a prevalent neoplasm with high mortality, ranked as the third highest cause of cancer-related deaths[1].

The correlation between Epstein-Barr virus (EBV) infection and GC is well known. EBV infection is found in 2%-16% of GCs[2-4]. However, the pathogenic role of EBV infection in GCs remains uncertain and little is known regarding the molecular characteristics of these tumors.

Apoptosis is a biological phenomenon of critical importance in the regulation of a number of physiological and pathological situations, such as cancer development. In general, it is thought that viral infection and its associated proteins protect against apoptosis, which would normally cause cancer regression[5]. Among the genes that regulate apoptosis are the members of the bcl-2 family. Expression of bcl-2 protein in gastric tumor cells is frequent and may differ according the histological type[6]. There are few studies that compare the relationship between EBV infection in gastric carcinomas with apoptosis related protein expression[7-9].

Nitric oxide (NO) is a short-lived biomolecule with various biological functions. It is an important bioactive agent and signaling molecule that mediates a diverse array of actions such as vasodilatation, neurotransmission, and iron metabolism. NO is also involved in the multistep process of carcinogenesis by mediating DNA damage, inducing angiogenesis, and suppressing immune responses[10]. It has been demonstrated that low concentrations of NO can protect tumor cells against apoptosis[11]; alternatively, high concentrations of NO

can induce tumor cell death[12]. This small molecule is a product of the conversion of L-arginine to L-citruline by nitric oxide synthases (NOS). There are two groups of NOS, inducible (iNOS or NOS-2) and constitutive (nNOS or NOS-1 and eNOS or NOS-3). Recent studies have examined the expression and activity of NOS in human cancer[13,14]. In gastric carcinomas, many studies addressed the issue, and most of them showed an increased activity and expression of NOS in tumor tissue when compared with normal gastric mucosa[15-18].

To the best of our acknowledgement, the relationship between NOS expression and EBV related gastric cancer has not been investigated. Thus, the aim of the present study is to determine the prevalence of EBV infection in GCs in a Brazilian population and investigate the expression of apoptosis related proteins and nitric oxide synthases in EBV positive and EBV negative gastric carcinomas.

MATERIALS AND METHODS

Materials

Two hundred and eight gastric carcinomas, surgically resected from 1995 to 1998, were analyzed for EBV status using in situ hybridization and PCR. To compare EBV positive and negative carcinomas, we selected 103 EBV negative GC, which were samples that were previously studied for expression of apoptosis related proteins and NOS. The cases were reviewed, and representative formalin-fixed, paraffin-embedded blocks from the tumors were selected. Clinicopathological findings were obtained from surgical records and pathology reports. New paraffin sections were stained with hematoxylin and eosin (H&E), and they were assessed independently by two pathologists (MDB & FAS). Histologically, the tumors were classified according to Lauren's classification system in intestinal or diffuse types[19]. Also we graded the amount of lymphoid infiltrate within or between the tumor cells as minimal/mild or moderate/intense.

In situ Hybridization (ISH)

Sections (5-6 μm thick) on glass slides were prepared for ISH with a fluorescein-conjugated oligonucleotide probe for EBER-1 (Novocastra, Newscastle- Upon- Tyne, U.K.). Briefly, after deparaffinization and dehydration the sections were treated with proteinase K (Sigma, St. Louis, MO) for 15 min at 37℃. After washing and dehydration, the FITC-conjugated probe was applied and hybridized overnight at 37℃. The hybridization was further detected by rabbit anti- FITC antibody conjugated with alkaline phosphatase (Novocastra) for 30 min at room temperature. The slides were counterstained with a light Mayer's haematoxylin. Negative controls had no EBER-1 probe applied.

Immunohistochemistry

Sections (5-6 μm thick) from the same tumor blocks, used for EBER detection, were immunohistochemically analyzed using the standard streptavidin- biotin- peroxidase method. The staining was done using the microwave antigen retrieval technique (95℃ for 30 min in citrate buffer pH 6.0) for all antibodies. Sections were incubated with antibodies against p53 (DO-7, 1:100, Dako, Copenhagen, Denmark), Bcl-2 (124, 1:50, Dako, Copenhagen, Denmark), Bax (bax, 1:50, Dako, Copenhagen, Denmark), Bcl-xl (bcl-xl, 1:50, Dako, Copenhagen, Denmark), Bak (bak, 1:400, Dako, Copenhagen, Denmark), NOS-1 (nNOS, 1:200, Transduction Laboratories, USA), NOS-2 (iNOS, 1:40, Transduction Laboratories, USA), and NOS-3 (eNOS, 1:50, Transduction Laboratories, USA) at 4℃ overnight. After reagenting them with biotinylated secondary anti-mouse antibodies, the antigen-antibody reactions were visualized using streptavidin-horseradish peroxidase conjugate (Dako LSAB Kit, Los Angeles, CA). The peroxidase activity was localized by 0.05% 3, 3'-diaminobenzidine and 0.03% hydrogen peroxide in Tris- buffered saline. The slides were counterstained with Mayer's hematoxylin. The percentage of positively stained tumor cells in each tumor section was blinded evaluated by counting at least 1000 cells in 10 randomly selected high-power fields. Brown staining for p53 protein was located in nuclei; staining for bcl-2, bcl-xl, bak, bax, NOS-1, NOS-2, and NOS-3 protein was located in cytoplasm. The section was considered as expressing the protein if cellular staining was $\geqslant$ 5%[5].

PCR studies for EBV

The DNA of cancerous tissues from 25 patients with EBV positive gastric carcinomas was obtained from paraffin-embedded surgical blocks. The DNA was extracted by prolonged proteinase K digestion. Briefly, after deparaffinization with xylene and rehydration in ethanol, the tissue was resuspended in 300 μL of SDS-Proteinase K solution (1% SDS; 9 mmol/L Tris-HCl, pH 9.0; 2.25 mmol/L EDTA; 56.5 mmol/L NaCl; 1 μg/μL Proteinase K (invitrogen) and incubated at 48℃ for 48 h. Each 12 h, 20 μL of 20 μg/μL Proteinase K were added. After extraction with an equal volume of phenol-chloroform, the aqueous layer was transferred to a new tube and the DNA was precipitated by the addition of 2 μL of 20 mg/mL glycogen, 100 μL of ammonium acetate (7.5 mol/L) and 800 μL of 100% ethanol followed by incubation overnight at -20℃. After centrifugation, the DNA was resuspended in 50 μL of water. PCR was performed in a reaction final volume of 25 μL, containing 10 μL of DNA; 2.5 μL of 10 × PCR buffer; 1.5 μL of 25 mmol/L $MgCl_2$; 2 μL of 2.5 mmol/L dNTP mix; 1 μL of 10 μmol/L EBNA1F and EBNA1R primers; and 0.3 μL of Taq DNA polymerase. The following thermal cycle conditions were used: 94℃ for 5 min, 35 cycles of 94℃ for 30 s, 60℃ for 45 s, and 72℃ for 45 s. After the last cycle, a final extension at 72℃ for 7 min was carried out. The sequences of the primers were: EBNA-1F (5'-GTCATCATCATCCGGGTCTC-3') and EBNA-1R (5'-TTCGGGTTGGAACCTCCTTG-3'). The amplified products were visualized by electrophoresis in 8% poliacrylamide gels.

Statistical analysis

Statistical comparison among groups was performed using χ^2 test and Fisher's exact test when appropriate. *P* values less than 0.05 were considered statistically significant.

Table 1 Comparison of clinicopathological data between EBV positive and EBV negative gastric carcinomas

	EBV positive gastric carcinomas (*n* = 25)	EBV negative gastric carcinomas (*n* = 103)	*P* value
Gender			NS
Male	20 (80%)	68 (66%)	
Female	5 (20%)	35 (34%)	
Age: range(mean)[1]	35-78 (60.5)	25-84 (61.2)	NS
Site of tumor			NS
Body and Cardia	8 (32%)	21 (20%)	
Antrum	17 (68%)	82 (80%)	
LN metastasis			NS
Absent	7 (28%)	43 (41%)	
Present	18 (72%)	60 (59%)	
Histological type			< 0.05
Diffuse	18 (72%)	41 (40%)	
Intestinal	7 (28%)	62 (60%)	
Lymphoid stroma			< 0.05
Minimal/mild	6 (24%)	71 (69%)	
Moderate/intense	19 (76%)	32 (31%)	

[1] Age in years; LN: Lymph node; NS: Not significant.

Table 2 Apoptosis related proteins expressions in EBV positive and EBV negative gastric carcinomas *n* (%)

	EBV positive gastric carcinoma (*n* = 25)	EBV negative gastric carcinoma (*n* = 103)	*P* value
P53			NS
Positive	11 (44)	55 (54)	
Negative	14 (56)	48 (46)	
Bcl-2			< 0.05
Positive	7 (28)	11 (11)	
Negative	18 (72)	92 (89)	
Bcl-x			NS
Positive	22 (88)	96 (93)	
Negative	3 (12)	7 (7)	
Bak			< 0.05
Positive	11 (44)	71 (69)	
Negative	14 (56)	32 (31)	
Bax			NS
Positive	24 (96)	88 (86)	
Negative	1 (4)	15 (14)	

RESULTS

EBER-1 expression and EBNA-1 products were visualized in 25 out of 208 (12%) cases of gastric carcinomas (Figure 1A).

The clinicopathological characteristics of EBV positive and negative GCs are given in Table 1. The male/female ratio in patients with EBV positive GCs and those with EBV negative GCs was 4:1 and 2:1, respectively, and no difference was seen in the average age at 60.5 and 61.2 years, respectively. 68% of EBV positive GCs were in the body and cardia and 32% of them were in the antrum. In the group of EBV negative GCs, 80% were in the body and cardia and only 20% of them were in the antrum, showing predilection for the body and cardia region in both groups. Regarding histological type, 18 of 25 (72%) EBV positive GCs were diffuse type and 7 (28%) were intestinal. 60% of EBV negative GCs were intestinal type and 41 of 103 (40%) were diffuse, resulting in a strong association between histological type and EBV infection in gastric carcinomas ($P < 0.01$). EBV associated GCs also correlated with tumor infiltrating lymphocytes. 19 of 25 (76%) EBV positive GCs showed marked lymphoid stroma evenly distributed with the malignant epithelial cells (Figure 1B). In the EBV negative GCs only 30% of the cases showed marked lymphocytic infiltration ($P < 0.01$). Metastases in lymph nodes were found in 18 of 25 (72%) EBV positive GCs and in 60 of 103 (59%) EBV negative cases. This difference was not statistically significant.

Immunohistochemical results

Table 2 shows the pattern of protein expression in EBV positive and negative GCs. P53 protein expression was observed in the nucleus of the tumor cells with a uniform staining (Figure 1C). 11 of 25 (44%) EBV positive GCs and 55 of 103 (51%) EBV negative GCs were positive for p53 and no difference was observed between the groups. Expression of bcl-2 protein was observed in 28% of EBV positive GCs and in only 11% of the EBV negative GCs (Figure 1D), showing a statistically significant correlation between EBV status and bcl-2 expression in GCs ($P < 0.05$). The rates of the bcl-xl and bax expressions in EBV positive and negative GCs were 88% and 93%, and 96% and 86%, respectively (Figures 1E and 1F). None of the differences were statistically significant. Bak expression was lower in the EBV positive GCs than in EBV negative tumors (Figure 1G) and it was detected in 11 of 25 (44%) EBV positive GCs, and in 71 of 103 (69%) EBV negative GCs. This difference was statistically significant ($P < 0.01$).

NOS were observed in the cytoplasm of the tumor, epithelial, endothelial, smooth muscle and inflammatory cells. For final analysis, we scored the expression of these enzymes only in the tumor cells (Figures 1H, 1I, and 1J). NOS expressions were significantly different in EBV positive and negative GCs. Overexpression of constitutive forms of NOS (NOS-1 and NOS-3) were more frequently observed in EBV positive than in EBV negative GCs ($P < 0.01$). The majority of GC cases were negative for an inducible form of NOS (NOS-2), independently of EBV status. Comparisons of NOS expressions and EBV status are shown in Table 3.

DISCUSSION

The relationship between Epstein-Barr virus and various epithelioid diseases has already been demonstrated. Involvement of EBV has been described in the etiopathogenesis of not only the nasopharyngeal carcinoma but other carcinomas as well, including gastric carcinomas[20-22].

It is estimated that EBV infection can be found in about 10% of GCs worldwide, especially those with marked lymphocytic infiltration[23-27]. We observed EBV infection in 12% of GCs. Previous studies showed the

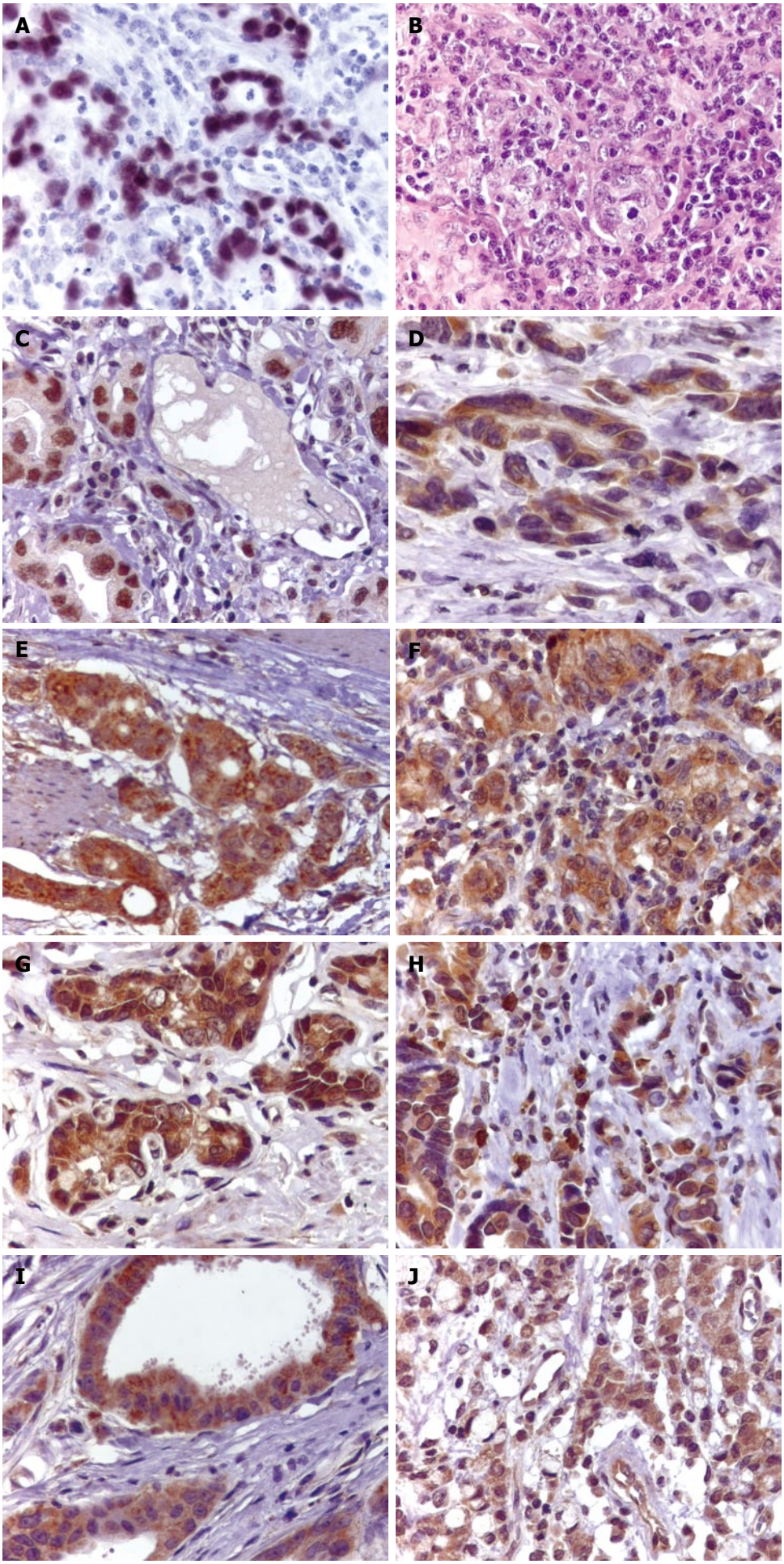

Figure 1 **A**: Gastric carcinoma showing strong positivity of EBER-1 in nuclei of the malignant cells (*in situ* hybridization,400 x); **B**: Overview of gastric carcinoma with clusters of tumor cells separated by prominent lymphoplasmacytic infiltrate (H&E, 400 x); **C**: p53 nuclear immunopositivity in gastric carcinoma cells (400 x); **D**, **E**, **F**, **G**: Immunohistochemical staining for bcl-2, bcl-xl, bax and bak. The cytoplasm of the malignant cells shows irregular brown positivity (400 x); **H**, **I**, **J**: NOS-1, NOS-2 and NOS-3 immunohistochemical staining in tumor epithelial cells, showing a high intensity of staining in the cytoplasm (400 x).

incidence of EBV infection in Brazilian GCs ranging between 5%-11.32%[28-30]. Some reports described the presence of EBV and its products as restricted on the carcinoma cells[31-33], whereas others found this virus in the precursor epithelial lesions as well as in the lymphoid cells[2,7]. In our study the virus was detected in the neoplastic cells but not in the normal, dysplastic gastric epithelium, or in inflammatory cells. This finding indicates that EBV affects the gastric epithelium at a late stage of the multistep process of gastric carcinogenesis.

The role of EBV in neoplastic transformation of gastric epithelial cells is not completely understood. It has been suggested that EBV positive GCs display specific clinicopathological features compared with EBV negative GCs. EBV associated GCs had been characterized by male predominance, preferential location in proximal stomach, and a high prevalence of diffuse types[2,34-36]. In our series, EBV positive GCs were frequently seen in males, in the body and cardia region, and in diffuse carcinomas in agreement with previous reports. Indeed we observed a strong association between EBV infection and lymphoid stroma. The presence of marked lymphoid infiltrate has already been demonstrated and there is growing evidence that extensive lymphocyte infiltration is a consistent characteristic of EBV positive carcinomas and correlates with less aggressive behavior, although no additional information is available regarding follow-up of the patients in the present study.

Molecular analysis of EBV positive carcinoma has been shown to have distinct characteristics including different chromosomal aberrations[37], different and lower frequencies of microsatellite instability[35] and allelic loss[38], and more CpG methylation[39]. However, studies have focused on the relationship between EBV and oncogenes or tumor suppressor genes in EBV associated GCs, but no conclusive results have been reported[5,7,9,40,41]. In this study, expression of apoptosis related proteins and nitric oxide synthases was examined in EBV associated and EBV negative gastric carcinomas. In this report, we observed a correlation between bcl-2 and bak expressions and EBV status. Bcl-2 protein expression was observed more frequently in EBV positive than in EBV negative GCs. On the other hand, positivity for bak protein was more common in EBV negative than in EBV positive GCs. It is already known that the balance between anti-apoptotic and pro-apoptotic members of the bcl-2 family genes determine the outcome of patients with tumors. Bak protein is shown to induce cell death, while bcl-2 can protect cells from apoptosis. Previous reports indicated that EBV infection may protect tumor cells from apoptosis inducing expression of the anti-apoptotic proteins[41]. Our results showed additional information and confirm that EBV infection and apoptosis related proteins interact to negatively influence apoptosis, through high expression of bcl-2 and low expression of bak in gastric tumor cells. Bax and bcl-xl protein expressions were found in both EBV positive and negative GCs and there was no statistical difference between the groups.

There is some indication that EBV modulates and mutates p53 for its own survival[42], however earlier reports showed contradictory results[8,38,43]. In turn, p53 gene mutations are rarely identified in EBV associated carcinomas[44]. The obtained results in our study showed disturbed function of p53 in almost all cases of EBV positive and EBV negative GCs. Although p53 expression seemed to be slightly lower in EBV positive GCs, that difference was not statistically significant. These results indicated that abnormalities in p53 observed in GCs are independent of EBV infection.

Table 3 NOS expression in EBV positive and EBV negative gastric carcinomas *n* (%)

	EBV positive gastric carcinoma (n = 25)	EBV negative gastric carcinoma (n = 103)	P value
NOS1(nNOS)			< 0.05
Positive	23 (92)	69 (67)	
Negative	2 (8)	34 (33)	
NOS2 (iNOS)			NS
Positive	5 (20)	31(30)	
Negative	20 (80)	72 (70)	
NOS3 (eNOS)			< 0.05
Positive	18 (72)	36 (35)	
Negative	7 (28)	67 (65)	

It has been reported that nitric oxide synthases are present in human tumor cell lines and solid tumor tissues[14,16,45-47]. Increased NOS expression has been observed in different tumors tissues when compared with normal tissues[14,48,49].

To the best of our knowledge, this is the first report showing NOS expression is associated with EBV infection gastric cancer. In EBV positive GCs, NOS-1 and NOS-3 proteins were more frequent positive in tumor cells than NOS-2. The results agree with previous data that showed higher activity of constitutive rather than inducible NOS in human gastric tumors[15]. In a recent study, the authors demonstrated significantly high NOS-3 expression in gastric tumors and a directly relationship with tumor angiogenesis and the overall aggressive biology of gastric cancer[50]. Our study showed higher NOS-3 expression in EBV positive GCs than in EBV negative GCs. Increasing evidence suggests that NOS-3 expression, although constitutive, can be regulated by various hormones, cytokines, and growth factors, and by genetic alterations, such as oncogene activation and tumor suppressor inactivation[51-54]. Our data indicate that EBV infection and its products can affect the regulation of this enzyme resulting in elevated NO production. It has been showed that elevated NO production enhances the growth of some tumors through the suppression of anti-tumor immune responses[55-57].

NOS-2 expression was decreased in the whole group of gastric tumors in our study. This feature has been demonstrated by immunohistochemistry in other tumors and there is a possible relationship between loss of NO and carcinogenenesis[15,16]. However, many publications showed elevated NOS expression and increased activity in gastric cancer[58-60]. Although the mechanisms for the antiviral action of NO have not been clarified, the multiplicity of host enzymes it targets makes it possible

that multiple alterations in host cell proteins are involved. An apparent role of NO in inhibiting EBV reactivation from latency was demonstrated in a study using gastric cells lines in culture[61]. This finding led us to propose that EBV latency can be directly and/or indirectly associated with NOS gene expression and also lead us to postulate that NO might also be an important factor in the host EBV relationship. Our data suggest that the increased expression of NOS-1 and NOS-3 in EBV positive GC renders a major contribution to high activity of NOS in this specific group of tumors.

In conclusion, it is clear that EBV is associated with gastric carcinomas. EBV positive GCs have a distinct protein expression profile, as well as distinct clinicopathological features. This present data suggest that EBV infection may protect tumor cells from apoptosis, giving them the capacity for permanent cell cycling and proliferation. Indeed, EBV positive GCs have high expression of constitutive NOS, which might be associated with tumor progression or aggressiveness. A larger number of cases and long-term follow-up are necessary to further investigate this possibility.

REFERENCES

1 **Brasil**. Ministério da Saúde. Secretaria Nacional de Assistência à Saúde. Instituto Nacional do Câncer. Estimativa da Incidência e Mortalidade por Câncer no Brasil. Rio de Janeiro: INCA, 2006. Available from: URL:http://www.inca.gov.br/estimativa/2006

2 **Shibata D**, Weiss LM. Epstein-Barr virus-associated gastric adenocarcinoma. *Am J Pathol* 1992; **140**: 769-774

3 **Rowlands DC**, Ito M, Mangham DC, Reynolds G, Herbst H, Hallissey MT, Fielding JW, Newbold KM, Jones EL, Young LS. Epstein-Barr virus and carcinomas: rare association of the virus with gastric adenocarcinomas. *Br J Cancer* 1993; **68**: 1014-1019

4 **Osato T**, Imai S. Epstein-Barr virus and gastric carcinoma. *Semin Cancer Biol* 1996; **7**: 175-182

5 **Ishii H**, Gobé G, Kawakubo Y, Sato Y, Ebihara Y. Interrelationship between Epstein-Barr virus infection in gastric carcinomas and the expression of apoptosis-associated proteins. *Histopathology* 2001; **38**: 111-119

6 **van der Woude CJ**, Kleibeuker JH, Tiebosch AT, Homan M, Beuving A, Jansen PL, Moshage H. Diffuse and intestinal type gastric carcinomas differ in their expression of apoptosis related proteins. *J Clin Pathol* 2003; **56**: 699-702

7 **Gulley ML**, Pulitzer DR, Eagan PA, Schneider BG. Epstein-Barr virus infection is an early event in gastric carcinogenesis and is independent of bcl-2 expression and p53 accumulation. *Hum Pathol* 1996; **27**: 20-27

8 **Ishii HH,** Gobe GC, Yoneyama J, Mukaide M, Ebihara Y. Role of p53, apoptosis, and cell proliferation in early stage Epstein-Barr virus positive and negative gastric carcinomas. *J Clin Pathol* 2004; **57**: 1306-1311

9 **Ohfuji S**, Osaki M, Tsujitani S, Ikeguchi M, Sairenji T, Ito H. Low frequency of apoptosis in Epstein-Barr virus-associated gastric carcinoma with lymphoid stroma. *Int J Cancer* 1996; **68**: 710-715

10 **Moncada S**, Palmer RM, Higgs EA. Nitric oxide: physiology, pathophysiology, and pharmacology. *Pharmacol Rev* 1991; **43**: 109-142

11 **Brüne B**, von Knethen A, Sandau KB. Nitric oxide and its role in apoptosis. *Eur J Pharmacol* 1998; **351**: 261-272

12 **Moochhala S**, Chhatwal VJ, Chan ST, Ngoi SS, Chia YW, Rauff A. Nitric oxide synthase activity and expression in human colorectal cancer. *Carcinogenesis* 1996; **17**: 1171-1174

13 **Ambs S**, Hussain SP, Harris CC. Interactive effects of nitric oxide and the p53 tumor suppressor gene in carcinogenesis and tumor progression. *FASEB J* 1997; **11**: 443-448

14 **Ambs S**, Merriam WG, Ogunfusika MO, Bennett WP, Ishibe N, Hussain SP, Tzeng EE, Geller DA, Billiar TR, Harris CC. p53 and vascular endothelial growth factor regulate tumor growth of NOS2-expressing human carcinoma cells. *Nat Med* 1998; **4**: 1371-1376

15 **Koh E,** Noh SH, Lee YD, Lee HY, Han JW, Lee HW, Hong S. Differential expression of nitric oxide synthase in human stomach cancer. *Cancer Lett* 1999; **146**: 173-180

16 **Rajnakova A,** Goh PM, Chan ST, Ngoi SS, Alponat A, Moochhala S. Expression of differential nitric oxide synthase isoforms in human normal gastric mucosa and gastric cancer tissue. *Carcinogenesis* 1997; **18**: 1841-1845

17 **Son HJ,** Kim YH, Park DI, Kim JJ, Rhee PL, Paik SW, Choi KW, Song SY, Rhee JC. Interaction between cyclooxygenase-2 and inducible nitric oxide synthase in gastric cancer. *J Clin Gastroenterol* 2001; **33**: 383-388

18 **Yamaguchi K,** Saito H, Oro S, Tatebe S, Ikeguchi M, Tsujitani S. Expression of inducible nitric oxide synthase is significantly correlated with expression of vascular endothelial growth factor and dendritic cell infiltration in patients with advanced gastric carcinoma. *Oncology* 2005; **68**: 471-478

19 **LAUREN P**. THE TWO HISTOLOGICAL MAIN TYPES OF GASTRIC CARCINOMA: DIFFUSE AND SO-CALLED INTESTINAL-TYPE CARCINOMA. AN ATTEMPT AT A HISTO-CLINICAL CLASSIFICATION. *Acta Pathol Microbiol Scand* 1965; **64**: 31-49

20 **Mori M,** Watanabe M, Tanaka S, Mimori K, Kuwano H, Sugimachi K. Epstein-Barr virus-associated carcinomas of the esophagus and stomach. *Arch Pathol Lab Med* 1994; **118**: 998-1001

21 **Leoncini L,** Vindigni C, Megha T, Funtò I, Pacenti L, Musarò M, Renieri A, Seri M, Anagnostopoulos J, Tosi P. Epstein-Barr virus and gastric cancer: data and unanswered questions. *Int J Cancer* 1993; **53**: 898-901

22 **Harn HJ,** Chang JY, Wang MW, Ho LI, Lee HS, Chiang JH, Lee WH. Epstein-Barr virus-associated gastric adenocarcinoma in Taiwan. *Hum Pathol* 1995; **26**: 267-271

23 **Burke AP**, Yen TS, Shekitka KM, Sobin LH. Lymphoepithelial carcinoma of the stomach with Epstein-Barr virus demonstrated by polymerase chain reaction. *Mod Pathol* 1990; **3**: 377-380

24 **Matsunou H**, Konishi F, Hori H, Ikeda T, Sasaki K, Hirose Y, Yamamichi N. Characteristics of Epstein-Barr virus-associated gastric carcinoma with lymphoid stroma in Japan. *Cancer* 1996; **77**: 1998-2004

25 **Cho YJ**, Chang MS, Park SH, Kim HS, Kim WH. In situ hybridization of Epstein-Barr virus in tumor cells and tumor-infiltrating lymphocytes of the gastrointestinal tract. *Hum Pathol* 2001; **32**: 297-301

26 **Kijima Y**, Hokita S, Takao S, Baba M, Natsugoe S, Yoshinaka H, Aridome K, Otsuji T, Itoh T, Tokunaga M, Eizuru Y, Aikou T. Epstein-Barr virus involvement is mainly restricted to lymphoepithelial type of gastric carcinoma among various epithelial neoplasms. *J Med Virol* 2001; **64**: 513-518

27 **Shibata D**, Tokunaga M, Uemura Y, Sato E, Tanaka S, Weiss LM. Association of Epstein-Barr virus with undifferentiated gastric carcinomas with intense lymphoid infiltration. Lymphoepithelioma-like carcinoma. *Am J Pathol* 1991; **139**: 469-474

28 **Hayashi K**, Chen WG, Chen YY, Murakami I, Chen HL, Ohara N, Nose S, Hamaya K, Matsui S, Bacchi MM, Bacchi CE, Chang KL, Weiss LM. Deletion of Epstein-Barr virus latent membrane protein 1 gene in Japanese and Brazilian gastric carcinomas, metastatic lesions, and reactive lymphocytes. *Am J Pathol* 1998; **152**: 191-198

29 **Koriyama C,** Akiba S, Iriya K, Yamaguti T, Hamada GS, Itoh T, Eizuru Y, Aikou T, Watanabe S, Tsugane S, Tokunaga M. Epstein-Barr virus-associated gastric carcinoma in Japanese Brazilians and non-Japanese Brazilians in São Paulo. *Jpn J Cancer Res* 2001; **92**: 911-917

30 **Lopes LF**, Bacchi MM, Elgui-de-Oliveira D, Zanati SG, Alvarenga M, Bacchi CE. Epstein-Barr virus infection and gastric carcinoma in São Paulo State, Brazil. *Braz J Med Biol Res* 2004;

37: 1707-1712
31 **Yamamoto N,** Tokunaga M, Uemura Y, Tanaka S, Shirahama H, Nakamura T, Land CE, Sato E. Epstein-Barr virus and gastric remnant cancer. *Cancer* 1994; **74**: 805-809
32 **Imai S,** Koizumi S, Sugiura M, Tokunaga M, Uemura Y, Yamamoto N, Tanaka S, Sato E, Osato T. Gastric carcinoma: monoclonal epithelial malignant cells expressing Epstein-Barr virus latent infection protein. *Proc Natl Acad Sci USA* 1994; **91**: 9131-9135
33 **Zur Hausen A,** van Rees BP, van Beek J, Craanen ME, Bloemena E, Offerhaus GJ, Meijer CJ, van den Brule AJ. Epstein-Barr virus in gastric carcinomas and gastric stump carcinomas: a late event in gastric carcinogenesis. *J Clin Pathol* 2004; **57**: 487-491
34 **Lee HS,** Chang MS, Yang HK, Lee BL, Kim WH. Epstein-barr virus-positive gastric carcinoma has a distinct protein expression profile in comparison with epstein-barr virus-negative carcinoma. *Clin Cancer Res* 2004; **10**: 1698-1705
35 **Chang MS,** Lee HS, Kim CW, Kim YI, Kim WH. Clinicopathologic characteristics of Epstein-Barr virus-incorporated gastric cancers in Korea. *Pathol Res Pract* 2001; **197**: 395-400
36 **van Beek J,** zur Hausen A, Klein Kranenbarg E, van de Velde CJ, Middeldorp JM, van den Brule AJ, Meijer CJ, Bloemena E. EBV-positive gastric adenocarcinomas: a distinct clinicopathologic entity with a low frequency of lymph node involvement. *J Clin Oncol* 2004; **22**: 664-670
37 **zur Hausen A,** van Grieken NC, Meijer GA, Hermsen MA, Bloemena E, Meuwissen SG, Baak JP, Meijer CJ, Kuipers EJ, van den Brule AJ. Distinct chromosomal aberrations in Epstein-Barr virus-carrying gastric carcinomas tested by comparative genomic hybridization. *Gastroenterology* 2001; **121**: 612-618
38 **van Rees BP,** Caspers E, zur Hausen A, van den Brule A, Drillenburg P, Weterman MA, Offerhaus GJ. Different pattern of allelic loss in Epstein-Barr virus-positive gastric cancer with emphasis on the p53 tumor suppressor pathway. *Am J Pathol* 2002; **161**: 1207-1213
39 **Kang GH,** Lee S, Kim WH, Lee HW, Kim JC, Rhyu MG, Ro JY. Epstein-barr virus-positive gastric carcinoma demonstrates frequent aberrant methylation of multiple genes and constitutes CpG island methylator phenotype-positive gastric carcinoma. *Am J Pathol* 2002; **160**: 787-794
40 **Leung SY,** Chau KY, Yuen ST, Chu KM, Branicki FJ, Chung LP. p53 overexpression is different in Epstein-Barr virus-associated and Epstein-Barr virus-negative carcinoma. *Histopathology* 1998; **33**: 311-317
41 **Kume T,** Oshima K, Shinohara T, Takeo H, Yamashita Y, Shirakusa T, Kikuchi M. Low rate of apoptosis and overexpression of bcl-2 in Epstein-Barr virus-associated gastric carcinoma. *Histopathology* 1999; **34**: 502-509
42 **Moritani S,** Sugihara H, Kushima R, Hattori T. Different roles of p53 between Epstein-Barr virus-positive and -negative gastric carcinomas of matched histology. *Virchows Arch* 2002; **440**: 367-375
43 **Szkaradkiewicz A**, Majewski W, Wal M, Czyzak M, Majewski P, Bierła J, Kuch A. Epstein-Barr virus (EBV) infection and p53 protein expression in gastric carcinoma. *Virus Res* 2006; **118**: 115-119
44 **Wang Y,** Luo B, Yan LP, Huang BH, Zhao P. Relationship between Epstein-Barr virus-encoded proteins with cell proliferation, apoptosis, and apoptosis-related proteins in gastric carcinoma. *World J Gastroenterol* 2005; **11**: 3234-3239
45 **Thomsen LL,** Miles DW, Happerfield L, Bobrow LG, Knowles RG, Moncada S. Nitric oxide synthase activity in human breast cancer. *Br J Cancer* 1995; **72**: 41-44
46 **Cobbs CS**, Brenman JE, Aldape KD, Bredt DS, Israel MA. Expression of nitric oxide synthase in human central nervous system tumors. *Cancer Res* 1995; **55**: 727-730
47 **Rosbe KW**, Prazma J, Petrusz P, Mims W, Ball SS, Weissler MC. Immunohistochemical characterization of nitric oxide synthase activity in squamous cell carcinoma of the head and neck. *Otolaryngol Head Neck Surg* 1995; **113**: 541-549
48 **Fujimoto H**, Ando Y, Yamashita T, Terazaki H, Tanaka Y, Sasaki J, Matsumoto M, Suga M, Ando M. Nitric oxide synthase activity in human lung cancer. *Jpn J Cancer Res* 1997; **88**: 1190-1198
49 **Radomski MW**, Jenkins DC, Holmes L, Moncada S. Human colorectal adenocarcinoma cells: differential nitric oxide synthesis determines their ability to aggregate platelets. *Cancer Res* 1991; **51**: 6073-6078
50 **Wang L,** Shi GG, Yao JC, Gong W, Wei D, Wu TT, Ajani JA, Huang S, Xie K. Expression of endothelial nitric oxide synthase correlates with the angiogenic phenotype of and predicts poor prognosis in human gastric cancer. *Gastric Cancer* 2005; **8**: 18-28
51 **Fleming I**, Busse R. Molecular mechanisms involved in the regulation of the endothelial nitric oxide synthase. *Am J Physiol Regul Integr Comp Physiol* 2003; **284**: R1-12
52 **Li H,** Wallerath T, Münzel T, Förstermann U. Regulation of endothelial-type NO synthase expression in pathophysiology and in response to drugs. *Nitric Oxide* 2002; **7**: 149-164
53 **Wu KK.** Regulation of endothelial nitric oxide synthase activity and gene expression. *Ann N Y Acad Sci* 2002; **962**: 122-130
54 **Geller DA,** Billiar TR. Molecular biology of nitric oxide synthases. *Cancer Metastasis Rev* 1998; **17**: 7-23
55 **Takahashi Y**, Bucana CD, Akagi Y, Liu W, Cleary KR, Mai M, Ellis LM. Significance of platelet-derived endothelial cell growth factor in the angiogenesis of human gastric cancer. *Clin Cancer Res* 1998; **4**: 429-434
56 **Morisaki T**, Katano M, Ikubo A, Anan K, Nakamura M, Nakamura K, Sato H, Tanaka M, Torisu M. Immunosuppressive cytokines (IL-10, TGF-beta) genes expression in human gastric carcinoma tissues. *J Surg Oncol* 1996; **63**: 234-239
57 **Bredt DS**, Snyder SH. Nitric oxide mediates glutamate-linked enhancement of cGMP levels in the cerebellum. *Proc Natl Acad Sci USA* 1989; **86**: 9030-9033
58 **Rajnakova A,** Moochhala S, Goh PM, Ngoi S. Expression of nitric oxide synthase, cyclooxygenase, and p53 in different stages of human gastric cancer. *Cancer Lett* 2001; **172**: 177-185
59 **Li LG,** Xu HM. Inducible nitric oxide synthase, nitrotyrosine and apoptosis in gastric adenocarcinomas and their correlation with a poor survival. *World J Gastroenterol* 2005; **11**: 2539-2544
60 **Wang GY,** Ji B, Wang X, Gu JH. Anti-cancer effect of iNOS inhibitor and its correlation with angiogenesis in gastric cancer. *World J Gastroenterol* 2005; **11**: 3830-3833
61 **Gao X**, Tajima M, Sairenji T. Nitric oxide down-regulates Epstein-Barr virus reactivation in epithelial cell lines. *Virology* 1999; **258**: 375- 381

S- Editor Wang J **L- Editor** Lutze M **E- Editor** Bai SH

PO Box 2345, Beijing 100023, China
www.wjgnet.com
wjg@wjgnet.com

World J Gastroenterol 2006 August 21; 12(31): 4966-4972
World Journal of Gastroenterology ISSN 1007-9327
© 2006 The WJG Press. All rights reserved.

LIVER CANCER

Dynamic alteration of telomerase expression and its diagnostic significance in liver or peripheral blood for hepatocellular carcinoma

Deng-Fu Yao, Wei Wu, Min Yao, Li-Wei Qiu, Xin-Hua Wu, Xiao-Qin Su, Li Zou, Deng-Bing Yao, Xian-Yong Meng

Deng-Fu Yao, Wei Wu, Li-Wei Qiu, Xin-Hua Wu, Research Center of Clinical Molecular Biology, Affiliated Hospital, Nantong University, Nantong 226001, Jiangsu Province, China
Min Yao, Nanjing University, Nanjing 210008, Jiangsu Province, China
Xiao-Qin Su, Li Zou, Center of Oncology, Affiliated Hospital of Nantong University, Nantong 226001, Jiangsu Province, China
Deng-Bing Yao, Institute of Neurosciences, Nantong University, Nantong 226001, Jiangsu Province, China
Xian-Yong Meng, Department of Gastroenterology, Affiliated Hospital, Nantong University, Nantong 226001, Jiangsu Province, China
Supported by grants-in-aid from the Key Project of Medical Science, No. RC2003100 and grants-in-aid from the project of Department of Health, No. H200523, Jiangsu Province, China
Correspondence to: Professor Deng-Fu Yao, MD, PhD, Research Center of Clinical Molecular Biology, Affiliated Hospital, Nantong University, 20 West Temple Road, Nantong, Jiangsu Province 226001, China. yaodf@ahnmc.com
Telephone: +86-513-83581539 Fax: +86-513-85052523
Received: 2005-08-31 Accepted: 2006-05-25

Abstract

AIM: To investigate the dynamic alteration of telomerase expression during development of hepatocellular carcinoma (HCC) and its diagnostic implications in liver tissues or peripheral blood mononuclear cells for HCC.

METHODS: Dynamic expressions of liver telomerase during malignant transformation of hepatocytes were observed in Sprague-Dawly (SD) rats fed with 0.05% of 2-fluoenyacetamide (2-FAA). Total RNA and telomerase were extracted from rat or human liver tissues. The telomerase activities in livers and in circulating blood were detected by a telomeric repeat amplification protocol-enzyme-linked immunosorbent assay (TRAP-ELISA), and its diagnostic value was investigated in patients with benign or malignant liver diseases.

RESULTS: The hepatoma model displayed the dynamic expression of hepatic telomerase during HCC development. The telomerase activities were consistent with liver total RNA levels (r = 0.83, P < 0.01) at the stages of degeneration, precancerosis, and cancerization of hepatocytes. In HCC patients, the telomerase levels in HCC tissues were significantly higher than in their adjacent non-cancerous tissues, but liver total RNA levels were lower in the former than in the latter. Although the circulating telomerase of HCC patients was abnormally expressed among patients with chronic liver diseases, the telomerase activity was a non-specific marker for HCC diagnosis, because the incidence was 15.7% in normal control, 25% in chronic hepatitis, 45.9% in liver cirrhosis, and 85.2% in HCC, respectively when absorbance value of telomerase activity was more than 0.2. If the value was over 0.6, the incidence was 60% in HCC group and 0% in any of the others (P < 0.01) except in two cases with liver cirrhosis. However, the combination of circulating telomerase with serum alpha-fetoprotein level could increase the positive rate and the accuracy (92.6%, 125 of 135) of HCC diagnosis.

CONCLUSION: The overexpression of telomerase is associated with HCC development, and its abnormality in liver tissues or in peripheral blood could be a useful marker for diagnosis and prognosis of HCC.

© 2006 The WJG Press. All rights reserved.

Key words: Hepatocellular carcinoma; Telomerase; Peripheral blood mononuclear cells; Telomeric repeat amplification protocol

Yao DF, Wu W, Yao M, Qiu LW, Wu XH, Su XQ, Zou L, Yao DB, Meng XY. Dynamic alteration of telomerase expression and its diagnostic significances in liver or peripheral blood for hepatocellular carcinoma. *World J Gastroenterol* 2006; 12(31): 4966-4972

http://www.wjgnet.com/1007-9327/12/4966.asp

INTRODUCTION

Hepatocellular carcinoma (HCC) is one of the most common and rapidly fatal malignancies worldwide[1], and has been ranked as the 2nd cancer killer in China, particularly in the eastern and southern areas, including the inshore area of the Yangtze River[2]. Major risk factors for HCC in these areas are exposure to aflatoxin B1 (AFB1) and infection with hepatitis viruses (HBV and HCV)[3]. Its prognosis is poor and early diagnosis is of utmost importance[4]. Treatment options are severely limited by the frequent presence of metastases. Although serum alpha-fetoprotein (AFP) is a useful tumor marker for the detection and monitoring of HCC development, the false-negative rate with AFP level alone may be as high as 40%

for patients with small size HCC. If hepatocyte-specific mRNAs are detected in the circulation, it is possible to infer the presence of circulating, presumably malignant liver cells and to predict the likelihood of haematogenous metastasis[5-7]. The use of telomerase assay for cancer diagnosis might be possible because telomerase is expressed in malignant lesions but rarely in normal somatic cells[8].

Telomerase, an RNA-dependent DNA polymerase, can maintain the telomeric length by acting as a reverse transcriptase[9]. In humans, tumor cells escape programmed cell senescence through reactivation of telomerase[10]. These immortalized cells can compensate for telomeric shortening at each cell division, leading to progressive neoplastic evolution[11]. Telomerase re-expression is found in 85% of human malignant tumors[12]. The expression of telomerase is important to cell proliferation, senescence, immortalization and carcinogenesis[13]. However, early expression and kinetic alteration of hepatic telomerase during development of HCC remain unclear. The objectives of this study were to observe the dynamic expression of liver telomerase in rat hepatoma model induced by oral administration of 0.05% of 2-fluoeny-acetamide (2-FAA), and investigate the telomerase activities in liver tissues and peripheral blood mononuclear cells (PBMCs) by a telomeric repeat amplification protocol-enzyme-linked immunosorbent assay (TRAP-ELISA), as well as its diagnostic implications for HCC in patients with benign or malignant liver diseases.

MATERIALS AND METHODS

Hepatoma rat models

Forty-two closed colony male Sprague-Dawly (SD) rats weighing 120-160 g were obtained from the Experimental Center of Medical Animals, Nantong University, China, and divided randomly into 7 groups, one group (n = 6) as normal control and 6 experimental groups (n = 6 in each group). All rats were housed under bio-clean conditions at a temperature-controlled (22℃ ± 2℃) environment with a 12-h light/dark cycle and 55% humidity. The control group was given basal foodstuffs and the feed of experimental rats contained 0.05% 2-FAA (Sigma, USA). Rats were then monitored daily of survival and weight loss, recorded of their clinical signs and sacrificed at different stages of hepatoma development. One group of the experimental rats and one control rat were killed in every two weeks. All surgical procedures were conducted under deep ether anaesthesia. Blood was drawn from rat's heart. The livers were collected, and histological examination was performed with hematoxylin and eosin (HE) staining. All procedures performed on the rats were conducted in accordance with the Guidelines for Experimental Animals approved by the Animal Care and Use Committee of Nantong University, China.

Patient selection and human HCC tissues

All patients with liver diseases came from the Affiliated Hospital, Nantong University, China. We evaluated 135 HCC patients (103 males and 32 females, age between 35-76 years, mean 49). Ninety-five patients (70.3%) had a history of cirrhosis, and 52 (38.5%) had a history of chronic hepatitis. Moreover, 85.2% (115/135) were hepatitis B surface antigen (HBsAg) carriers, 10.4% (14/135) had antibodies to hepatitis C virus (anti-HCV, second-generation antibody) and 8.9% (12/135) had antibodies to hepatitis G virus by an enzyme-linked immunosorbent assay (ELISA), respectively. Other cases studied included 80 patients with chronic hepatitis (CH, 58 males and 22 females), 37 patients with liver cirrhosis (LC, 30 males and 7 females), and 70 healthy individuals (35 males and 35 females, mean age 35 years) with negative hepatitis B virus markers (HBsAg, HBcAb, and HBV-DNA) and anti-HCV, and normal levels of serum alanine aminotransferase (ALT) from the Nantong Central Blood Bank as normal controls (NC). The venous blood of patients and normal controls were collected with heparin anticoagulant and stored on ice. The diagnosis of HCC and viral hepatitis was based on the criteria proposed at China National Collaborative Cancer Research Group[14] and the China National Viral Hepatitis Meeting[15], respectively.

Fifteen specimens of HCC and their corresponding non-tumor tissues as self-control were obtained from HCC patients who had undergone curative hepatectomy. These specimens were immediately frozen in liquid nitrogen and kept at -85℃. All specimens were hepatocellular cancer confirmed by pathological examination. Eleven non-cancerous tissues from those patients were atypical proliferation. The patients' ages ranged between 31-64 years (mean 51.3 years). There were 12 specimens with a tumor size larger than 3 cm, and 3 specimens smaller than 3 cm.

Isolation of total RNA

Fifty mg of each liver tissue (rat liver, human HCC, and their self-controlled non-tumor tissues) was homogenized with a Polytron homogenizer after the addition of 1.0 mL of TRIzol reagent (Promega). Then 0.2 mL of chloroform was added into the tubes, mixed by vortexing for 15 s, and placed at -20℃ for 5 min. Samples were centrifuged at 12000 r/min for 15 min at 4℃. The supernatants were collected, and equivalent isopropanol was added and then they were put into another tube and mixed gently, placed at -20℃ for 15 min, then centrifuged at 12000 r/min for 15 min at 4℃. The supernatants were removed, the RNA pellets were washed twice with 0.5 mL of 75% ethanol, mixed and centrifuged at 8000 r/min for 8 min at 4℃. The RNA pellets were air dried 5 min at room temperature and reconstituted in 20 μL of RNase-free DEPC water and incubated at 60℃ for 10 min. The purity and concentration of the RNA was estimated by the ratio of absorbance readings at 260 and 280 nm, with an $A_{260/280}$ ratio between 1.8 and 2.0 indicating sufficient purity. RNA samples were kept frozen at -85℃ until use.

Separation of PBMCs

Five milliliters of peripheral blood were collected with heparin anticoagulant from each patient. Ficoll (2.5 mL) was added to each sample. After centrifugation at 2000 r/min for 20 min, the PBMCs were collected from the Ficoll/plasma interface. Then they were washed three times in normal saline and pelleted by using low-speed cen-

trifugation. The cells were collected at 2×10^5/tube, then stored at -85℃ for telomerase assays.

TRAP reaction

A commercial telomerase TRAP-ELISA kit (Boeheringer Mannhein), based on TRAP introduced by previous methods[16], was used to assay telomerase activity in all specimens. Fifty mg liver tissue or 2×10^5 cells were suspended in 200 μL lysis reagent and incubated for 30 min, then centrifuged at 16000 r/min for 20 min at 4℃. Positive control cell extract was from immortalized telomerase-expressing human kidney cells (293 cells). Negative control cell extract was as follows: heat-treatment of the cell extract for 10 min at 65℃ prior to the TRAP reaction. The supernatant was removed to other EP tubes and kept frozen at -85℃. Telomeric repeats were added to a biotin-labeled primer for 30 min at 25℃ during the first reaction. The mixture was incubated at 94℃ for 5 min to induce telomerase inactivation, then subjected to 30 PCR cycles of 94℃ for 30 s, 50℃ for 30 s, and 72℃ for 90 s, and finally at 72℃ for 10 min. The PCR products were used for analysis of telomerase activity and gel electrophoresis.

Telomerase detection

An aliquot of the PCR product was denatured and hybridized to a digoxigenin-(DIG)-labeled, telomeric repeat-specific detection probe. The resulting product was immobilized *via* the biotin labeled primer to a streptavidin-coated microtiter plate. The detection probe and the hybridization conditions have been optimized to obtain the highest specificity and sensitivity. The immobilized PCR products were then detected with an antibody against digoxigenin (anti-DIG-POD) that was conjugated to peroxidase. Finally, the probe was visualized by use of peroxidase metabolizing tetramethyl benzidine (TMB) to form a colored reaction product. The absorbance (A) of the samples was measured at 450 nm (reference wavelength 620 nm) within 30 min of addition of the stop reagent. Telomerase activities were expressed according to absorbance difference (△A) between sample and negative control.

Telomerase by TRAP silver staining

Fifteen microliters of the PCR products were loaded to 12% polyacrylamide gel and resolved by electrophoresis at 160-180 V for 1-2 h. Then the gel was immobilized to 10% ethanol for 5 min, soaked in 1% $AgNO_3$ for 5 min, dyed in silver dye solution for 10 min, and then in developing dye for 10 min. The amplified products were of heterogeneous length and created a ladder pattern of bands each representing the addition of a hexanucleotide telomeric repeat by telomerase, and photographed by Delphin-Doc Digital Imaging System (Wealtec, USA). All samples were done in duplicate and the reproducibility was confirmed.

Statistical analysis

The livers of experimental rats according to pathological examination were divided into 4 groups: degeneration of hepatocytes (Exp-1), precancerosis of hepatocytes (Exp-2), cancerization of hepatocytes (Exp-3), and normal controls (Con). The telomerase activities in PBMCs were investigated in patients with HCC, chronic hepatitis (CH), liver cirrhosis (LC), and normal controls (NC). Human HCC tissues were divided into cancerous and their non-tumor (non-HCC) groups. Levels of telomerase and total RNA were expressed as mean ± SD. Differences between groups were assessed by the Student's *t* test or the χ^2 test, and the Fisher's exact probability test. Probability values less than 0.05 were considered significant.

Table 1 Histopathological alterations of hepatocytes at different stages of rat hepatomas induced with 2-FAA

Group	*n*	Pathological feature (HE staining)		
		Degeneration	Precancerosis	Cancerization
Control	6	0	0	0
2nd wk	6	6	0	0
4th wk	6	3	3	0
6th wk	6	0	5	1
8th wk	6	0	4	2
10th wk	6	0	1	5
12th wk	5[1]	0	0	5
Total	41	9	13	13

[1] One rat died during the experimental process; 2-FAA: 2-fluoenylacetamide.

RESULTS

Histopathological findings

The pathological changes of experimental rat livers with HE staining are shown in Table 1. The rats were administered with 0.05% of 2-FAA for two weeks. The appearance of livers turned to be grey-yellow and scabrous. The hepatocytes showed granular degeneration. Most of normal liver tissue structures remained. A few of hyperplastic oval cells, and the tendency toward nodule formation were seen at the early stage of hepatoma development. At the end of four weeks, precancerous lesions appeared in half of liver tissues. Histologically, normal liver follicles existed in most areas but hyperplastic small round cells or oval cells or hyperplastic nodules were found locally. After the 6th wk, all livers progressed into canceration stage. The structures of liver lobules were completely destroyed, and necrosis was spread over the whole livers. Large numbers of small oval cells, and cancer nests were observed. The histological features of livers showed diffuse patchy necrosis and high degree differentiation of HCC.

Expression of telomerase during rat hepatoma development

The dynamic expression of liver telomerase in rat hepatocyte degeneration (Exp-1), hepatocyte precancerosis (Exp-2), and hepatocyte cancerization (Exp-3) groups during development of hepatomas in comparison with controls (Con) are shown in Figure 1. After rats were given 2-FAA, the specific activities (△A/mg protein) of liver telomerase were significantly higher than that of controls ($P < 0.01$) at the stage of hepatocyte degeneration, kept rising at the stage of hepatocyte precancerosis, and peaked at the formation stage of hepatoma. Telomerase activities were consistent with the levels of liver total RNA ($r = 0.83$,

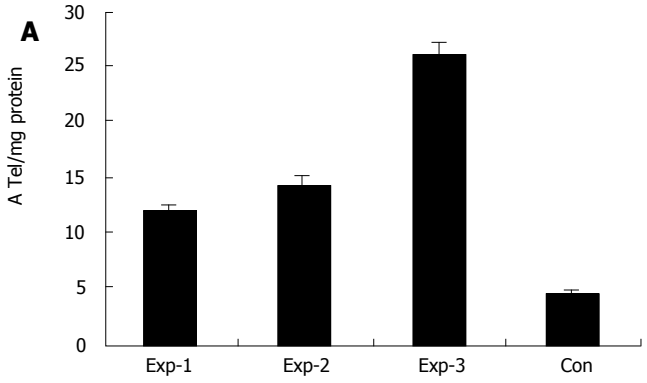

Figure 1 Alterations of hepatic telomerase at different stages of rat hepatoma model. The feed of experimental rats contained 0.05% of 2-fluoenylacetamide. Exp-1: Hepatocyte degeneration group; Exp-2: Hepatocyte precancerosis group; Exp-3: Hepatocyte cancerization group; and Con, rats given basal feed without 2-fluoenylacetamide as normal control group.

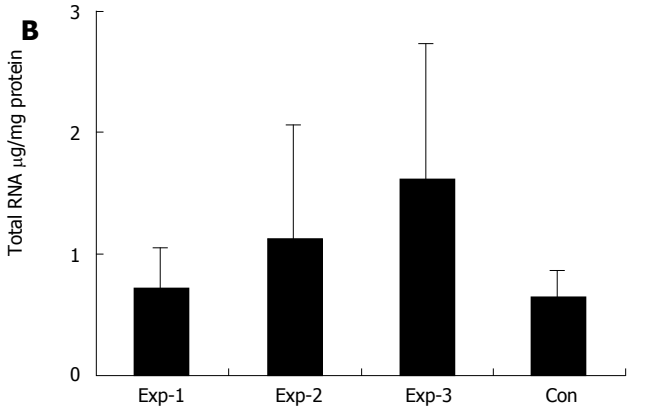

Figure 2 Alterations of liver total RNA at different stages of rat hepatoma model. The feed of experimental rats contained 0.05% of 2-fluoenylacetamide. Exp-1: Hepatocyte degeneration group; Exp-2: Hepatocyte precancerosis group; Exp-3: Hepatocyte cancerization group; and Con, rats given basal feed without 2-fluoenylacetamide as normal control group.

$P < 0.01$) at the different stages of hepatoma development of rats (Figure 2).

Expression of telomerase in human liver tissues

The levels of total RNA and telomerase expression in different human liver tissues are shown in Figure 3. The concentrations of liver total RNA and telomerase were 12.40 ± 7.34 μg/mg liver protein and 18.25 ± 15.02 A/μg RNA in HCC tissues, and 53.77 ± 52.02 μg/mg liver protein and 8.16 ± 6.22 A/μg RNA in their non-cancerous tissues, respectively. The expression of total RNA in HCC tissues was significantly lower than that in their non-cancerous tissues ($P < 0.01$); however, the expression level of telomerase was significantly higher in HCC tissues than in their non-cancerous tissues ($P < 0.05$). Stronger positive expression of telomerase was presented in HCC tissues and not in their non-cancerous tissues (Figure 4).

Significance of telomerase in PBMCs

There were different telomerase activities of PBMCs in NC, CH, LC and HCC, but the activities in HCC were significantly higher than in others ($P < 0.01$, Figure 5). The samples were regarded as telomerase-positive if the difference in absorbance (Table 2) was greater than 0.2 △A. The incidence of telomerase expression was 15.7% in NC, 25% in CH, 45.9% in LC, and 85.0% in HCC (sensitivity 68.4% and positive predictive value 75.7%), respectively. The incidence of telomerase was significantly higher in

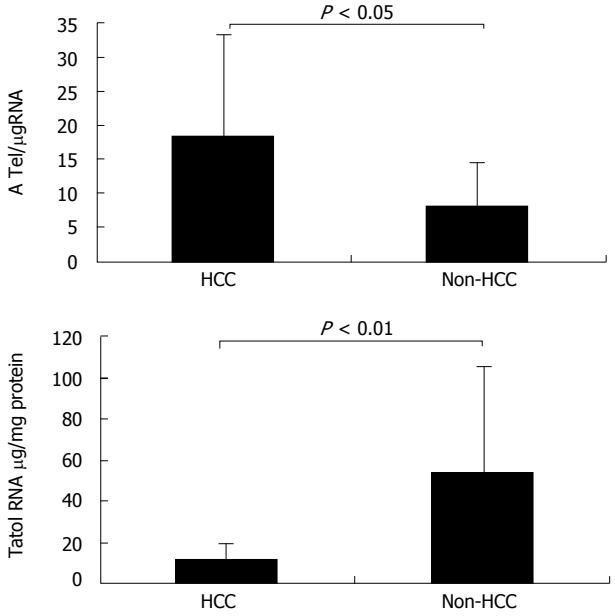

Figure 3 Comparative analysis of total RNA levels and telomerase activities in human hepatoma tissues and their non-cancerous tissues.

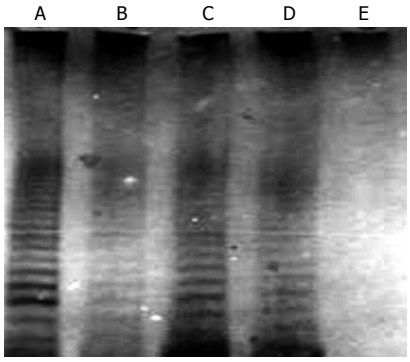

Figure 4 Electrophoresis patterns of human telomerase in polyacrylamide gel. A,C: Human hepatocellular carcinoma tissues; B,D: Non-cancerous tissues of human hepatocellular carcinoma; E: Negative control.

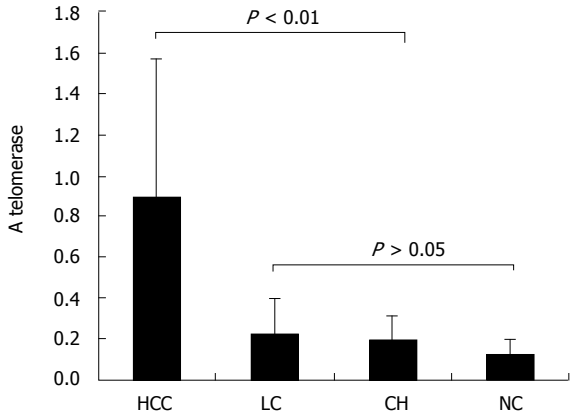

Figure 5 Comparative analyses of telomerase activities in peripheral blood mononuclear cells from patients with benign or malignant liver diseases.

Table 2 Diagnostic values of different telomerase levels in peripheral blood mononuclear cells for hepatocellular carcinoma

Group	*n*	Positive (%)		
		△A>0.2	△A>0.4	△A>0.6
HCC	135	115 (85.2)	101 (74.8)	81 (60.0)
Liver cirrhosis	37	17 (45.9)	6 (16.2)[b]	2 (5.4)[b]
Chronic hepatitis	80	20 (25.0)[b]	8 (10)[b]	0 (0)[b]
Normal control	70	11 (15.7)[b]	0 (0)[b]	0 (0)[b]

[b]$P < 0.01$ *vs* the HCC group.

Table 3 Assessment of the diagnostic values of different telomerase levels

Telomerase	Sen (%)	Spe (%)	Predictive value		Acc (%)
			Pos (%)	Neg (%)	
△A > 0.2	85.2	68.4	75.7	80.0	77.4
△A > 0.4	74.8	88.0	87.8	75.2	81.0
△A > 0.6	60.0	98.3	97.6	68.0	77.8

Sen: Sensitivity; Spe: Specificity; Pos: Positive; Neg: Negative; Acc: Accuracy.

HCC group than in any of other groups ($P < 0.01$). If the value rose up to 0.6 △A, the incidence of telomerase was 60% in HCC (sensitivity 98.3% and positive predictive value 97.6%), and 0% in any of other groups ($P < 0.01$) except two cases with liver cirrhosis (Table 3). For combined diagnostic values of telomerase and AFP for HCC, the AFP concentration in HCC patients was 1765 ± 1705 μg/L and the positive rate was 70% for a cutoff value of AFP level 200 μg/L. Total AFP detection in combination with telomerase activity could increase the accuracy of HCC diagnosis (92.6%).

DISCUSSION

Carcinogenesis of hepatocytes is a multi-factor, multi-step and complex process and has many characteristics, such as fast infiltrative growth, metastasis in early stage, high malignancy, and poor therapeutic efficacy[17]. Probably HBV infection is merely a carcinogenic factor, and is not related to the growth, infiltration and metastasis of HCC[18]. It is increasingly clear that oncogenesis is driven by the activation of telomerase, a ribonucleoprotein complex that adds telomeric repeats (hexanucleotide 5'-TTAGGG-3') to the ends of replicating chromosomes. Telomerase is a ribonucleoprotein composed of an essential RNA and a few proteins. It is expressed in embryonic cells and in adult male germ line cells, but is undetectable in normal somatic cells except proliferative cells of renewable tissues. Although the precise processes leading to HCC are still unknown, progression to a cancerous state does require the accumulation of a series of genetic alterations.

To understand the mechanisms and alterations of telomerase expression during carcinogenesis of hepatocytes, rat hepatoma models were induced with chemical carcinogen (2-FAA), and telomerase expression was studied at the different stages of degeneration, precancerosis, and cancerization of hepatocytes (Table 1). Although the histopathological examination found the oval cells and non-differentiation in morphology at the early stage of hepatoma, telomerase was significantly expressed in livers (Figure 1). This has raised two possibilities: (1) telomerase may be an important target for therapy aiming at controlling cell growth[19,20]. Telomerase activation in the critical step of tumor progression during hepatocarcinogenesis might be regulated only by hTERT, whereas increased telomerase activity in tumor progression might be regulated by both hTERT (reverse transcript) and hTERT (RNA component)[21-23]; (2) histological examination in combination with telomerase activity could increase the accuracy of diagnosis at early stage and help the staging of HCC development.

The predominant mechanism for telomere stabilization in tumor cells is the activation of the telomere-synthesizing enzyme telomerase. Both of liver telomerase activity (Figure 1) and total RNA increased (Figure 2) during hepatoma progression. This may be relevant to the cytotoxic effects of liver cells in resisting carcinogenic effect of 2-FAA. In the meantime, the telomerase level of liver tissues and sera of the experimental groups were obviously higher than the normal control group ($P < 0.01$), indicating that the oval cells could express telomerase and secrete it into blood. Telomerase activities increased continuously and reached the highest level in the experimental groups, and livers of the experimental groups in the 6th wk were seen to have canceration. Rat hepatoma is an aggressive malignancy. Both total RNAs and telomerase activity increased during HCC progression. Moreover, in the following weeks, the liver tissues continued to synthesize telomerase, which remained at a high level. These results suggest that the strong enhancement of telomerase activity may be a critical step in hepatocarcinogenesis, although the exact mechanism is not clear.

Telomerase is highly activated in human tumor tissues, whereas it is not activated in primary cell strains and tumor-adjacent tissues[24,25]. With cell division, telomerase is activated. The cells with positive telomerase activity become immortalized and further develop to carcinoma cells[26,27]. The telomerase activities in HCC and their surrounding non-tumor tissues were detected by TRAP-ELISA in this study. The telomerase expression in HCC was negatively correlated with differentiation, but was not related to tumor size or histological grade. The expression level of telomerase was significantly higher in HCC tissues than in their corresponding non-cancerous tissues ($P < 0.05$, Figure 3A). Stronger positive expression of telomerase was present in HCC and not in their non-cancerous tissues (Figure 4). No relationship could be observed between the enhancement of telomerase activity and liver total RNA in human HCC tissues (Figure 3B). In China, major risk factors for HCC are exposure to aflatoxin B1 (AFB1) and infection by hepatitis viruses, especially HBV. HBx, encoded by HBV, could block the function of *p53*, resulting in genome unstablization. Activation of telomerase could make liver cells immortalized, and microvascularization could provide nutrition for their growth and promote metastasis[17,28]. These two factors may induce carcinogenesis and have a key role in occurrence, development, infiltration and metastasis of HCC. They

may also have notable clinical values in diagnosing and treating HCC in early stage.

Telomerase was strongly activated in HCC, while weakly activated in CH and LC. Progressive shortening of telomeres during hepatocellular carcinogenesis was found from normal liver to CH to LC to HCC. The average telomere length of HCC was significantly and consistently shorter than that of adjacent CH or LC. The possible sequel of telomere shortening in regenerative, non-cancerous liver lesions (CH and LC) is that it may eventually lead to reactivation of telomerase, which in turn may contribute to the malignant conversion to HCC. Telomerase may be expressed in lymphocytes[29,30]. Lymphocytic infiltration may occur during tumor necrosis, thus the telomerase activity we measured included a proportion generated by lymphocytes and might be overestimated. Almost all HCCs are preceded by CH and/or LC. There were different degrees of telomerase activities of PBMCs in NC, CH, LC and HCC, but the telomerase activities of HCC were significantly higher than others (Figure 5, Table 2). In addition, combined diagnostic values of telomerase and AFP for HCC were investigated in this study. Detection of telomerase activity in combination with serum AFP could increase the accuracy of HCC diagnosis.

These genetic changes may lead to senescence of hepatocytes occurring in patients with advanced liver diseases probably as a result of degeneration and the subsequent regeneration of hepatocytes[31,32]. Although the mechanisms of carcinogenesis in chronic liver diseases are not known, recessive mutations may result in the reactivation of telomerase and stabilization of telomere length, as well as fixation of the additional mutations required for invasiveness and metastasis[33,34]. Moreover, the patients with telomerase-positive HCC show poorer prognosis than those with telomerase-negative tumors. Clinically although the diagnostic specificity of hepatoma is high, the positive rate of telomerase is at present much lower than that from animal model studies, and the number of bands does not coincide with that of human being either[35]. In addition, the cause of human hepatoma is associated with many factors. Telomerase could become a valuable marker for HCC diagnosis if the sensitivity of detection method is improved[36]. Further research should focus on mechanisms of carcinogenesis by HCV and HBV, development of early detection and more effective treatments. Better understanding of HCC related to hepatitis viruses should also be a major concern in future studies.

REFERENCES

1 **Peto J**. Cancer epidemiology in the last century and the next decade. *Nature* 2001; **411**: 390-395

2 **Yao D**, Jiang D, Huang Z, Lu J, Tao Q, Yu Z, Meng X. Abnormal expression of hepatoma specific gamma-glutamyl transferase and alteration of gamma-glutamyl transferase gene methylation status in patients with hepatocellular carcinoma. *Cancer* 2000; **88**: 761-769

3 **Orito E**, Mizokami M. Hepatitis B virus genotypes and hepatocellular carcinoma in Japan. *Intervirology* 2003; **46**: 408-412

4 **Qin LX**, Tang ZY. The prognostic molecular markers in hepatocellular carcinoma. *World J Gastroenterol* 2002; **8**: 385-392

5 **Thorgeirsson SS**, Grisham JW. Molecular pathogenesis of human hepatocellular carcinoma. *Nat Genet* 2002; **31**: 339-346

6 **Ijichi M**, Takayama T, Matsumura M, Shiratori Y, Omata M, Makuuchi M. alpha-Fetoprotein mRNA in the circulation as a predictor of postsurgical recurrence of hepatocellular carcinoma: a prospective study. *Hepatology* 2002; **35**: 853-860

7 **Funaki NO**, Tanaka J, Seto SI, Kasamatsu T, Kaido T, Imamura M. Hematogenous spreading of hepatocellular carcinoma cells: possible participation in recurrence in the liver. *Hepatology* 1997; **25**: 564-568

8 **Lee CM**, Hsu CY, Eng HL, Huang WS, Lu SN, Changchien CS, Chen CL, Cho CL. Telomerase activity and telomerase catalytic subunit in hepatocellular carcinoma. *Hepatogastroenterology* 2004; **51**: 796-800

9 **Mu J,** Wei LX. Telomere and telomerase in oncology. *Cell Res* 2002; **12**: 1-7

10 **Masutomi K**, Yu EY, Khurts S, Ben-Porath I, Currier JL, Metz GB, Brooks MW, Kaneko S, Murakami S, DeCaprio JA, Weinberg RA, Stewart SA, Hahn WC. Telomerase maintains telomere structure in normal human cells. *Cell* 2003; **114**: 241-253

11 **Testorelli C**. Telomerase and cancer. *J Exp Clin Cancer Res* 2003; **22**: 165-169

12 **Satyanarayana A,** Manns MP, Rudolph KL. Telomeres and telomerase: a dual role in hepatocarcinogenesis. *Hepatology* 2004; **40**: 276-283

13 **Liu YC**, Chen CJ, Wu HS, Chan DC, Yu JC, Yang AH, Cheng YL, Lee SC, Harn HJ. Telomerase and c-myc expression in hepatocellular carcinomas. *Eur J Surg Oncol* 2004; **30**: 384-390

14 **Yang BH**, Ran ZG. The Liver Cancer Committee of Chinese Anticancer Association: Diagnostic criteria of primary hepatocellular carcinoma. *Zhonghua Ganzangbing Zazhi* 2000; **8**: 135

15 **Cui ZN**, Wang JT, Tian GS. Chinese National Viral Hepatitis Meeting (1995, Beijing): Diagnosis standard for viral hepatitis. *Zhonghua Neike Zazhi* 1996; **35**: 8-16

16 **Park YM,** Choi JY, Byun BH, Cho CH, Kim HS, Kim BS. Telomerase is strongly activated in hepatocellular carcinoma but not in chronic hepatitis and cirrhosis. *Exp Mol Med* 1998; **30**: 35-40

17 **Yao DF**, Wu XH, Zhu Y, Shi GS, Dong ZZ, Yao DB, Wu W, Qiu LW, Meng XY. Quantitative analysis of vascular endothelial growth factor, microvascular density and their clinicopathologic features in human hepatocellular carcinoma. *Hepatobiliary Pancreat Dis Int* 2005; **4**: 220-226

18 **Dong ZZ**, Yao DF, Yao DB, Wu XH, Wu W, Qiu LW, Jiang DR, Zhu JH, Meng XY. Expression and alteration of insulin-like growth factor II-messenger RNA in hepatoma tissues and peripheral blood of patients with hepatocellular carcinoma. *World J Gastroenterol* 2005; **11**: 4655-4660

19 **Liu SX**, Sun WS, Cao YL, Ma CH, Han LH, Zhang LN, Wang ZG, Zhu FL. Antisense oligonucleotide targeting at the initiator of hTERT arrests growth of hepatoma cells. *World J Gastroenterol* 2004; **10**: 366-370

20 **Klingelhutz AJ.** The roles of telomeres and telomerase in cellular immortalization and the development of cancer. *Anticancer Res* 1999; **19**: 4823-4830

21 **Yokota T**, Suda T, Igarashi M, Kuroiwa T, Waguri N, Kawai H, Mita Y, Aoyagi Y. Telomere length variation and maintenance in hepatocarcinogenesis. *Cancer* 2003; **98**: 110-118

22 **Chen CJ**, Kyo S, Liu YC, Cheng YL, Hsieh CB, Chan DC, Yu JC, Harn HJ. Modulation of human telomerase reverse transcriptase in hepatocellular carcinoma. *World J Gastroenterol* 2004; **10**: 638-642

23 **Yang Y**, Chen Y, Zhang C, Huang H, Weissman SM. Nucleolar localization of hTERT protein is associated with telomerase function. *Exp Cell Res* 2002; **277**: 201-209

24 **Konnikova L**, Simeone MC, Kruger MM, Kotecki M, Cochran BH. Signal transducer and activator of transcription 3 (STAT3) regulates human telomerase reverse transcriptase (hTERT) expression in human cancer and primary cells. *Cancer Res* 2005; **65**: 6516-6520

25 **Hahn WC**, Meyerson M. Telomerase activation, cellular immortalization and cancer. *Ann Med* 2001; **33**: 123-129
26 **Takahashi S,** Kitamoto M, Takaishi H, Aikata H, Kawakami Y, Nakanishi T, Shimamoto F, Tahara E, Tahara H, Ide T, Kajiyama G. Expression of telomerase component genes in hepatocellular carcinomas. *Eur J Cancer* 2000; **36**: 496-502
27 **Shimada M**, Hasegawa H, Gion T, Utsunomiya T, Shirabe K, Takenaka K, Otsuka T, Maehara Y, Sugimachi K. The role of telomerase activity in hepatocellular carcinoma. *Am J Gastroenterol* 2000; **95**: 748-752
28 **Piao YF**, He M, Shi Y, Tang TY. Relationship between microvessel density and telomerase activity in hepatocellular carcinoma. *World J Gastroenterol* 2004; **10**: 2147-2149
29 **Waguri N**, Suda T, Nomoto M, Kawai H, Mita Y, Kuroiwa T, Igarashi M, Kobayashi M, Fukuhara Y, Aoyagi Y. Sensitive and specific detection of circulating cancer cells in patients with hepatocellular carcinoma; detection of human telomerase reverse transcriptase messenger RNA after immunomagnetic separation. *Clin Cancer Res* 2003; **9**: 3004-3011
30 **Tatsuma T**, Goto S, Kitano S, Lin YC, Lee CM, Chen CL. Telomerase activity in peripheral blood for diagnosis of hepatoma. *J Gastroenterol Hepatol* 2000; **15**: 1064-1070
31 **Liu DY**, Peng ZH, Qiu GQ, Zhou CZ. Expression of telomerase activity and oxidative stress in human hepatocellular carcinoma with cirrhosis. *World J Gastroenterol* 2003; **9**: 1859-1862
32 **Iizuka N**, Mori N, Tamesa T, Tangoku A, Oka M. Telomerase activity and Nm23-H2 protein expression in hepatocellular carcinoma. *Anticancer Res* 2003; **23**: 43-47
33 **Oh BK,** Jo Chae K, Park C, Kim K, Jung Lee W, Han KH, Nyun Park Y. Telomere shortening and telomerase reactivation in dysplastic nodules of human hepatocarcinogenesis. *J Hepatol* 2003; **39**: 786-792
34 **Farazi PA**, Glickman J, Jiang S, Yu A, Rudolph KL, DePinho RA. Differential impact of telomere dysfunction on initiation and progression of hepatocellular carcinoma. *Cancer Res* 2003; **63**: 5021-5027
35 **Onishi T**, Nouso K, Higashi T, Toshikuni N, Nakatsukasa H, Kobayashi Y, Uemura M, Yumoto E, Fujiwara K, Sato S, Nakamura S, Yokoyama J, Hanafusa T, Shiratori Y. Cellular distribution of telomerase reverse transcriptase in human hepatocellular carcinoma. *J Gastroenterol Hepatol* 2003; **18**: 1168-1174
36 **Miura N**, Maeda Y, Kanbe T, Yazama H, Takeda Y, Sato R, Tsukamoto T, Sato E, Marumoto A, Harada T, Sano A, Kishimoto Y, Hirooka Y, Murawaki Y, Hasegawa J, Shiota G. Serum human telomerase reverse transcriptase messenger RNA as a novel tumor marker for hepatocellular carcinoma. *Clin Cancer Res* 2005; **11**: 3205-3209

S- Editor Wang J **L- Editor** Zhu LH **E- Editor** Ma WH

PO Box 2345, Beijing 100023, China
www.wjgnet.com
wjg@wjgnet.com

World J Gastroenterol 2006 August 21; 12(31): 4973-4980
World Journal of Gastroenterology ISSN 1007-9327
© 2006 The WJG Press. All rights reserved.

Analysis of differentially expressed proteins in cancerous and normal colonic tissues

Lay-Harn Gam, Chiuan-Herng Leow, Che Nin Man, Boon-Hui Gooi, Manjit Singh

Lay-Harn Gam, Chiuan-Herng Leow, School of Pharmaceutical Sciences, Universiti Sains Malaysia, 11800 USM, Penang, Malaysia
Che Nin Man, National Poison Centre, Universiti Sains Malaysia, 11800 USM, Penang, Malaysia
Boon-Hui Gooi, Manjit Singh, Department of Surgery, Penang General Hospital, Penang, Malaysia
Supported by the Ministry of Science, Technology and Innovation Malaysia (06-02-05-3197EA12)
Correspondence to: Dr. Lay-Harn Gam, School of Pharmaceutical Sciences, Universiti Sains Malaysia, 11800 USM. Penang, Malaysia. layharn@usm.my
Telephone: +60-4-6533888-2208 Fax: +60-4-6570017
Received: 2006-01-23 Accepted: 2006-02-18

Abstract

AIM: To identify and analyze the differentially expressed proteins in normal and cancerous tissues of four patients suffering from colon cancer.

METHODS: Colon tissues (normal and cancerous) were homogenized and the proteins were extracted using three protein extraction buffers. The extraction buffers were used in an orderly sequence of increasing extraction strength for proteins with hydrophobic properties. The protein extracts were separated using the SDS-PAGE method and the images were captured and analyzed using Quantity One software. The target protein bands were subjected to in-gel digestion with trypsin and finally analyzed using an ESI-ion trap mass spectrometer.

RESULTS: A total of 50 differentially expressed proteins in colonic cancerous and normal tissues were identified.

CONCLUSION: Many of the identified proteins have been reported to be involved in the progression of similar or other types of cancers. However, some of the identified proteins have not been reported before. In addition, a number of hypothetical proteins were also identified.

© 2006 The WJG Press. All rights reserved.

Key words: Colon cancer; Tissue specimens; Sequential protein extraction; Proteomics

Gam LH, Leow CH, Man CN, Gooi BH, Singh M. Analysis of differentially expressed proteins in cancerous and normal colonic tissues. *World J Gastroenterol* 2006; 12(31): 4973-4980

http://www.wjgnet.com/1007-9327/12/4973.asp

INTRODUCTION

Colorectal cancer is a worldwide public health concern and also a frequent cause of mortality and morbidity in developed, developing and industrialized countries[1]. The incidence of colon cancer increases exponentially with age. Environmental factors and host immunological characteristics could contribute to initiation and progression of the disease[2]. Colorectal cancer is among the best characterized cancers with regard to the genetic progression of the disease[3].

The ability to obtain maps of the protein content of cells provides a basis for comparison of the protein expression in normal and cancer cells. This capability becomes especially important for mapping the changes that occur during cancer progression. In the transformation process, changes in protein expression may result in expression of proteins at elevated or reduced levels[4-6]. When a cell transforms from normal to malignant, changes in protein expression ultimately are reflected in the phenotype of the cell. It is also important to map the differences between different stages of cancer and between different cancer samples at the same stage of progression in order to understand the pathways involved in these processes. Ultimately, identification of important proteins involved in the transformation process may lead to the identification of early markers for detection of specific types of cancers and their treatments[7].

In the present study, proteins from normal and cancerous colon tissues were extracted in three separate fractions. The mapping of a protein profile in each fraction was carried out individually. This approach eases the comparison of protein expression in normal and cancerous tissue as it reduces the total proteins present in each fraction. Using this method, we believe that proteins from different compartments of the cells were extracted in sequential order, where the aqueous soluble proteins were first extracted followed by non-aqueous soluble proteins consisting of proteins with moderate to extreme hydrophobicity. The proteins analyzed in this study were extracted from human tissue specimens (both cancerous and normal). In proteomics study, analysis of cancerous

tissue has advantages over analysis in established cancer cell lines, as the latter may not represent the actual expression of proteins.

MATERIALS AND METHODS

Tissue specimen collection

Normal and cancerous colonic tissues were collected from patients with colon cancer. The specimens were provided by Hospital Pulau Pinang. Normal tissue was taken from the mucosal layer of the normal colon adjacent to the tumor tissue. Both the normal and cancerous tissues were confirmed by hospital pathologists. Ulceration or infected colon cancers were exclusion criteria for the study. The tissues were collected after informed consent had been obtained from the patients. The patients had different grades of colorectal cancer as shown in Table 1. The tissues were cut into similar sizes, weighed and immediately stored at -70℃ until analyzed.

Well-differentiated adenocarcinoma refers to the less aggressive type of cancer where the cancerous tissues more closely resemble the normal tissue under histopathological examination, whereas moderately differentiated adenocarcinoma refers to moderately aggressive cancer cells.

Tissue lysis and sequential extractions

The tissues were defatted and an equal weight of tissues (normal and cancerpis) was determined and subjected to analysis. The deep-frozen colon tissue specimens were disrupted by grinding in a liquid nitrogen-cooled mortar until the specimens became powder-form. The powder form-like tissues were divided into aliquots in separate eppendoft tubes. Sequential extraction of protein using three protein extraction buffers was carried out. These extraction buffers were prepared according to Molloy *et al*[8] with modifications. The extraction procedures are described in the following sections.

Tris extraction buffer

The constituent of Extraction Buffer 1 (S1 buffer) is 40 mmol/L Tris. 1000 μL of S1 buffer was added to 500 mg of homogenized tissue. The mixture was vortexed for 30 seconds and centrifuged at 20℃ with the speed of 12000 r/min for 8 min. The supernatant was collected in aliquots (50 μL) and kept at -70℃. The pellet was thoroughly washed with S1 buffer before being subjected to the second step in the sequential extraction.

Solution two extraction buffer

The extraction Buffer 2 (S2 buffer) contained 8 mol/L Urea, 50 mmol/L DTT, 40 g/L CHAPS, 2 mL/L Carrier ampholytes (pH 3-10) and 2 mg/L Bromophenol Blue. The recovered pellet was washed twice again with the T1 solution, and was then vortexed, centrifuged and the supernatant was discarded. After washing, a volume of 1000 μL S2 solution was added to the pellet. The mixture was then vortex for 30 s and then centrifuged at 20℃ with the speed of 12000 r/min for 8 min. The supernatant was collected in aliquots (50 μL) and kept at -70℃. The pellet was thoroughly washed with the same extraction buffer before being subjected to the third step in the sequential extraction.

Table 1 Clinical and pathological data of patient tissue specimens

Patient #	Age	Gender	Race	Cancer stage	Cancer grade
MMN	77	Female	Malay	Stage Ⅳ	Well differentiated adenocarcinoma
LKH	66	Male	Chinese	Stage Ⅱ	Moderately differentiated adenocarcinoma
CCH	55	Male	Chinese	Stage Ⅳ	Moderately differentiated adenocarcinoma
NSC	55	Female	Chinese	Stage Ⅲ	Moderately differentiated adenocarcinoma

Solution three extraction Buffer

The extraction Buffer 3 (S3 buffer) contained 5 M Urea, 2 mol/L Thiourea, 50 mmol/L DTT, 20g/L CHAPS, 20 mL/L Triton, 2 mL/L Carrier ampholytes (pH 3-10), 40 mmol/L Tris and 2 mg/L Bromophenol Blue. The recovered pellet from S2 extraction was washed twice with S2 buffer, it was then vortexed, centrifuged and the supernatant was discarded. After washing, 1000 μL of S3 buffer was added to the pellet. The mixture was vortexed for 30 s and then centrifuged at 20℃ with the speed of 12000 r/min for 8 min. The supernatant was collected in aliquots (50 μL) and kept at -70℃. The pellet was then discarded.

Sample preparation and electrophoresis

The preparation of protein samples for SDS-PAGE separation was carried out by adding 200 mL/L of sample buffer (0.5 mol/L Tris-HCl, 100 mL/L glycerol, 20 mg/L SDS, 100 mg/L Coomassie blue) to each fraction (5 μL) and vortexed for 30 s. The samples (normal and cancerous) and the protein molecular weights markers were then loaded into individual wells of SDS-polyacrylamide gel using a syringe. Electrophoresis was performed using a vertical electrophoresis slab gel apparatus at a constant voltage of 200 volts throughout the electrophoresis process. Electrophoresis was terminated when the dye front was 2 to 3 mm away from the bottom edge of the gel for both experiments. The gel was stained with Coomassie blue.

In-gel digestion

The SDS-Polyacrylamide gel was washed thoroughly in 100 mmol/L NH_4HCO_3 and the differentially expressed protein bands from either normal or cancerous colonic tissues were then excised from the gel. In-gel digestion was performed using trypsin according to Gam and Aishah[9] with slight modification. The gel pieces were first excised and shrunk by dehydration in acetonitrile. The solvent was then discarded and the gel pieces were dried in a vacuum centrifuge. A volume of 10 mmol/L dithiotreitol (DTT) in 100 mmol/L NH_4HCO_3 that was sufficient to cover the gel pieces was added and the protein was reduced

for 1 h at 56℃. After cooling to room temperature, the DTT solution was replaced with the same volume of 55 mmol/L iodoacetic acid in 100 mmol/L NH_4HCO_3. After 45 min incubation at ambient temperature in the dark with occasional vortexing, the gel pieces were washed with 50-100 μL of 100 mmol/L NH_4HCO_3 for 10 min, dehydrated with acetonitrile, rehydrated in 100 mM NH_4HCO_3 and dehydrated in the same volume of acetonitrile. The liquid phase was removed and the gel pieces were dried in a vacuum centrifuge. The gel pieces were swollen in digestion buffer containing 50 mmol/L NH_4HCO_3, 5 mmol/L $CaCl_2$, and 12.5 ng/μL of trypsin in an ice-cold bath. After 45 min, the supernatant was removed and replaced with 10 μL of the same buffer but without trypsin to keep the gel pieces wet during enzymatic cleavage at 37℃ overnight. Peptides were extracted from the gel matrix by adding 15 μL of 20 mmol/L NH_4HCO_3, vortexed and incubated at room temperature for 10 min and the supernatant was recovered after a brief spin. This was followed by adding (1 to 2 times the volume of gel pieces) 50 mL/L formic acid in acetonitrile:water mixture (70:30), vortex and incubated for 20 min at room temperature. It was then spun down and the supernatant was recovered. These steps were repeated 3 times. Pooled extracts were dried in a vacuum centrifuge and stored at -70℃. Each of the pooled extracts (peptides) was added with 30 μL of deionized water. Then, they were centrifuged at 500 r/min for 5 min at 15℃. The extracts were then subjected to LC/MS/MS analysis.

Mass spectrometric analysis

A volume of 5 μL of the sample was injected into a RPC-column (C_{18} 300 A, 5 μm, 1 mm × 150 mm) connected to a Hewlett Packard HPLC. A capillary pump was used to pump the mobile phase at 20 μL/min flow rate, the linear gradient used was 5% B to 95% B in 65 min. Mobile phase A was 500 μL/L formic acid in deionized water and B was 500 μL/L formic acid in ACN. The HPLC was interfaced to an ion trap mass spectrometer. The dry gas temperature was 300℃, dry gas flow rate was of 8.0 L/min, nebulizer pressure of 30.0 psi. The above parameters were used subsequently for acquiring MS data. The peptides were ionized using electrospray soft ionization technique (ESI).

The experimental method was made up of one experimental protocol consisting of 2 scan events. The first scan event was a full scan MS and the second was the data dependent MS/MS scan which is dependent on the results of the first scan event. The most intense ion in a MS scan will be automatically isolated and excited to MS/MS scan. The parameters set for data dependent scan (MS/MS scan) were default collision energy (voltage) = 1.15 V, charge state = 2, minimum threshold = 3000 counts, and the isolation width = 2 m/z.

Mascot protein identification

The protein was identified using Mascot Protein Database Search engine. The Peptide Mass Tolerance was set as ± 2 u and ± 0.8 u was set for the Fragment Mass Tolerance. Only 1 missed cleavage was allowed. This software is available at *www.matrix-science.com*. Matches were computed using a probability-based Mowse score defined as -10 × log (*P*), where *P* is the probability that the observed match was a random event.

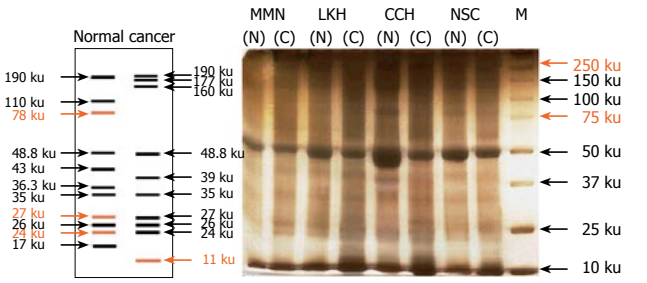

Figure 1 Proteins profiles of normal and cancer colon tissues from four different patients. The proteins were extracted using in S1 buffer. N: Normal colon tissues; C: Cancer colon tissues; M: Marker; Lanes 1 and 2: MMN samples; Lanes 3 and 4: LKH samples; Lanes 5 and 6: CCH samples and Lanes 7 and 8: NSC samples. Diagram 1 shows the consistent protein bands found in the normal and the cancer tissues of the figure.

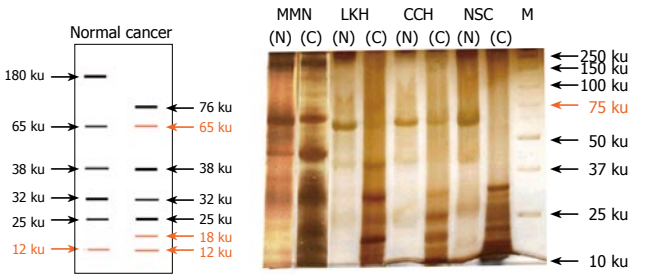

Figure 2 Proteins profiles of normal and cancer colon tissues from four different patients. The proteins were extracted using in S2 buffer. N: Normal colon tissues; C: Cancer colon tissues; M: Marker; Lanes 1 and 2: MMN samples; Lanes 3 and 4: LKH samples; Lanes 5 and 6: CCH samples and Lanes 7 and 8: NSC samples. Diagram 2 shows the consistent protein bands found in the normal and the cancer tissues of the figure.

RESULTS

Figure 1 shows the protein profiles of protein extracted using S1 buffer from normal and cancerous colon tissues of four different patients. Diagram 1 shows the consistent protein bands for both normal and cancerous tissues. The thick lines represent the protein bands that were expressed in all four tissues and the faint lines represent the protein bands that were expressed in three of the four patients. The distinct bands that were only detected in one particular tissue are ignored, as it may not represent the proteins that are involved in cancer formation. In colon cancer tissues, the protein bands that were expressed in all the four patients were at 190 ku, 177 ku, 160 ku, 48.8 ku, 39 ku, 35 ku, 27 ku, 26 ku and 24 ku. However, a protein band at 11 ku was detected in three of the four patients. In normal colon tissues, protein bands at 190 ku, 110 ku, 48.8 ku, 43 ku, 36.3 ku, 35 ku, 26 ku and 17 ku were found in all the patients' tissues while protein bands at 78 ku, 27 ku and 24 ku were found expressed only in three patients. When comparing cancerous and normal tissue, it is clear that some of the proteins were differently expressed between the two types of tissues.

Figure 2 shows the profiles of proteins extracted using S2 buffer from both normal and cancerous colonic tissues.



Figure 3 Proteins profiles of normal and cancer colon tissues from four different patients. The proteins were extracted using in S3 buffer. N: Normal colon tissues; C: Cancer colon tissues; M: Marker; Lanes 1 and 2: MMN samples; Lanes 3 and 4: LKH samples; Lanes 5 and 6: CCH samples and Lanes 7 and 8: NSC samples. Diagram 3 shows the consistent protein bands found in the normal and the cancer tissues of the figure.

Table 2 Up-regulated, down-regulated proteins extracted in S1, S2, S3 buffers from colon tissues

SWISS-PROT accession number	Down-regulated proteins (Normal tissues)	SWISS-PROT accession number	Up-regulated proteins (Cancer tissues)
P12718	Actin, gamma-enteric smooth muscle	P04262	Type Ⅱ, keratin subunit protein
P17661	Desmin	P35900	Keratin 20
P08670	Vimetin	P35908	Keratin, 67k type Ⅱ epidermal
Q9DFD0	Hypothetical protein	P13647	Keratin k5
Q7Z5W1	Hypothetical protein	Q86Y46	Keratin 6 irs 3
CAD19027	Hypothetical protein	P04264*	Keratin 1, type Ⅱ cytoskeletal
BAC87457	Hypothetical protein	P35527	Cytoskeletal 9
CAC08866	Hypothetical protein	P04264	Keratin, type Ⅱ cytoskeletal Ⅰ
CAC08835	Hypothetical protein	P35527	Keratin 9, type Ⅰ, cytoskeletal
Q8WTU6	Hypothetical protein	P08779	Keratin, type 1, cytoskeletal 16
Q01995	Transgelin	P48669	Keratin, type Ⅱ, cytoskeletal 6F
Q91706	Skeletal muscle beta-tropomyosin	P02538	Keratin 6A, type Ⅱ
P12277	Creatine kinase	P19013	Keratin, type Ⅱ, cytoskeletal 4
P00915	Actin-gamma	P08729	Keratin, type Ⅱ, cytoskeletal 7
Q96QE3	ATP[GTP]-binding protein	P12035	Keratin, type Ⅱ, cytoskeletal 3
		P05783	Keratin, type Ⅰ, cytoskeletal 18
		P13645	Keratin, type Ⅰ, cytoskeleton 10
		Q8NF17	Hypothetical protein
		CAE99935	Hypothetical protein
		P02675	Fibrinogen beta chain
		P00915	Carbonate dehydratase EC 4.2.1.1
		Q9PTK9	Kinesin-like protein 2
		P60174	Triosephosphate isomerase EC. 5.3.1.1
		Q6PJ43	ACTGI protein
		Q13733	Sodium/potassium-transporting ATPase alpha-4 chain EC 3.6.3.9

Diagram 2 represents the consistent protein bands that were expressed in the tissues analyzed. For the cancerous tissues, the protein bands at 76 ku, 38 ku, 32 ku and 25 ku were consistently expressed in all the cancerous tissues analyzed while protein bands at 65 ku, 18 ku and 12 ku were only found in the tissues of three of the four patients. For the normal tissues, the bands at 180 ku, 65 ku, 38 ku, 32 ku and 25 ku were found in the tissues of all four patients while only one band at 12 ku was detected in the tissues of three patients. Most of the proteins extracted from cancerous tissues using S2 buffer were found at the low molecular weight region, in the range of 35 ku to 10 ku. In contrast, relatively few protein bands from normal tissues were detected in this region and those that were detected were present at low protein intensity.

Figure 3 shows the protein profiles of proteins extracted using S3 buffer from normal and cancer colon tissues of the four patients. Diagram 3 represents the consistent protein bands expressed in the four tissues analyzed. Protein bands at 38 ku, 27 ku, 23 ku 20 ku and 17 ku from cancerous tissues were found in all four patients whereas only the band at 65 ku was found in three of the four patients. Normal tissues of the corresponding patients displayed bands at 38 ku, 27 ku and 20 ku whereas tissues from three patients were found to express consistent bands at 150 ku, 100 ku, 65 ku, 46 ku and 35 ku. The protein band at 65 ku was detected at the highest intensity compared to the other bands and it was uniquely expressed in all the patients except for patient #MMN, which was the only patient diagnosed with well differentiated adenocarcinoma cancer. Thus, its expression is probably related to the cancer grade. Nevertheless, this may just be an ambiguous assumption as only one patient with well differentiated cancer grade was analyzed. When comparing the protein profiles of protein extracted from tissues using S3 buffer, it is obvious that the expression of

Table 3 Unique proteins extracted in S1, S2, S3 buffers from colon tissues

SWISS-PROT accession number	Unique proteins (Normal tissues)	SWISS-PROT accession number	Unique proteins (Cancer tissues)
P32119	Peroxiredoxin 2 precursor	Q9BX84	LTRPC6 channel kinase 6
Q03001	Bullous pemphigoid antigen 1 precursor	Q9AVW8	DNA-directed RNA polymerase II largest chain EC 2.7.7.6
P01009	Alpha-1-antitrypsin precursor	P29312	14-3-3 protein zeta
P20848	Alpha-1-antitrypsin related protein presursor	P31946	14-3-3 protein beta/alpha
1QMBA	Alpha-1-antitrypsin mutant YES, chain A	S38532	Protein 14-3-3 eta chain
		S31975	14-3-3 protein epsilon

low molecular weight proteins (below 37 ku) in cancerous tissues was greater than that of the normal tissues.

Table 2 shows the list of proteins detected, with a total of 15 and 24 down-regulated and up-regulated proteins identified from normal and cancerous tissues, respectively. Table 3 shows the unique proteins that were identified form normal and cancerous tissues.

DISCUSSION

The sequential protein extraction technique consists of three types of protein extraction buffers, namely the S1 buffer, S2 buffer and S3 buffer. The S1 buffer is used mainly to extract aqueous soluble proteins, such as cytosolic proteins and nuclear proteins while the S2 and S3 buffers were used to extract proteins with intermediate to extreme hydrophobicity. The constituent of S2, which is made up of chaotropic agents and other reagents may disturb rugged protein-protein interaction found among structural, cytoskeletal proteins and aggregating proteins[10]. However, the combination of urea and thioureas in S3 was used to enhance the solubility of membrane proteins[8]. The extraction buffers were always used in the orderly sequence of S1 followed by S2 and then S3. The use of sequential protein extraction buffers was first suggested by Molloy *et al*[8] for separation of protein mixtures using 2D-gel electrophoresis. However, in our present study, the extracted proteins were separated using the SDS-PAGE technique, whereby direct comparison of protein profiles from tissues of four different patients was carried out.

In general, use of sequential extraction buffers is beneficial to this study because proteins were extracted according to their increasing hydrophobic strength, which may imply that proteins from different cellular compartments were extracted in different fractions. This method not only allows the analysis of proteins according to their localization in the cells but also reduces the number of proteins extracted in each fraction, which provides better resolution of proteins and their visualization in SDS-PAGE.

The protein profiles of the proteins extracted using the S1 and S2 buffers are significantly different, however the protein profiles of proteins extracted using S2 and S3 showed only slight differences. The significant variation between the protein profiles of S1 and S2 can be explained by the vast difference in the property of the proteins extracted, where S1 buffer extracts proteins only solubilize in aqueous solution while S2 buffer extracts the non-aqueous soluble proteins. The protein profiles displayed by proteins extracted using S2 and S3 also showed a certain degree of variation as S3 buffer was used to enhance the solubility of more stringent proteins from the tissue[11].

The differentially expressed proteins in each of the gels were then subjected to further analysis and the identity of each protein was analyzed using LC/MS/MS. Proteins were identified using the Mascot protein search engine on the basis of peptide mass matching[12] with redundancy of post-translational modification and proteolysis. The definition of "up-regulated", "down-regulated" and unique proteins in this study are solely dependent on their existence in SDS-PAGE. When analyzed using Quantity one software (BioRad), the intensity of the bands for up-regulated proteins was more intense in cancerous as compared to normal tissues while the "down-regulated" proteins were the proteins that were more intense in normal as compared to cancerous tissues. However, some of the intense protein bands in SDS-PAGE were found to contain more than one type of protein. Therefore, for the up-regulated and down-regulated protein bands, both the protein bands of the identical molecular weight from normal and cancerous tissues were excised and subjected to LC/MS/MS analysis. The proteins that were detected in both tissues were then quantified by their peptides' peak areas in selected ion chromatogram analysis. The proteins present in one tissue and not the other are reported as unique proteins.

A total of ninety-five proteins were identified from the protein bands indicated earlier for both the normal and cancerous tissues. However, some of these proteins were of serum origin, due to the embedded blood vessels in the tissues, and these proteins were excluded from the protein list. Furthermore, some of the proteins were represented by more than one band as described by heterogeneity. The heterogeneous proteins were mainly derived from structural, transport and enzyme subunits such as Actin, gamma-enteric smooth muscle, Desmin, Vimetin, Keratin, type I cytoskeletal 10, Cytoskeletal 9, and Triosephosphate isomerase EC 5.3.1.1. Phospholylation, glycosylation and limited proteolytic activities have been considered as major modification of proteins and they therefore affect the mobility of the modified proteins in SDS-PAGE[13-15].

The structural proteins were mostly extracted from the cancerous tissues using the S3 buffer. The majority of the structural proteins identified belongs to the cytokeratin family. Williams *et al*[16] reported that cytokeratin expressing tumor cells contain cytokeratins 8 and 18, but not

cytokeratin 19 or vimentin. The roles of cytokeratins are commonly known to encompass both structural and signaling capabilities. In the present study, cytokeratin 18 was found in cancerous colon tissues in S3 buffer extracts. The expression of cytokeratin 18 in colonic cancerous tissues is consistent with those reported by Leong *et al*[17]. In contrast, the expression of cytokeratin 18 was found reduced in malignant tumors of prostate carcinoma compared to benign prostatic hyperplasia[4]. The expression of cytokeratins is sometimes used as an indicator of the behavioral changes of a tissue. For instance, in breast tissue, cytokeratin 8 has been reported to be the major receptor for plasminogen on breast cells[18].

Vimentin is expressed at higher levels in the low-secreting variant. It is present in many cell lines, but normally absent from differentiated cells. Thus, lower vimentin expression in the high secretors may be indicative of a more differentiated phenotype[19]. In our present study, vimentin is a down-regulated protein found in S1 buffer extracts. Williams *et al*[16] has reported that the absence of vimentin in colon cancer tissue is due to its correlation with cytokeratin 19 or other cytokeratin expressions. However, Birchmeier *et al*[20] and Seshadri *et al*[21] reported no unequivocal correlation between a gain of vimentin and poor prognosis with primary tumors.

Hypothetical proteins were extracted in all three extraction buffers from both normal and cancerous colonic tissues. Generally, hypothetical proteins are defined as the proteins that were not described at the protein level, but were predicted from cDNA sequences[22]. As shown in Table 2, a series of hypothetical proteins were identified. Afjelhi-Sadat *et al*[23] suggested that the hypothetical proteins may serve as marker or protein vaccine candidates. Particularly when the hypothetical protein is found in cancerous tissue exclusively, it can be considered as novel and of pivotal importance. Some of the hypothetical proteins were detected as heterogeneous proteins suggesting the post-translational nature of the proteins.

Peroxiredoxin 2 is a type transport protein and it was extracted in the S1 buffer as a unique protein in normal tissues. Peroxiredoxin 2 is part of the peroxidase family, which are proteins that have been known to connect with cell proliferation, differentiation and apoptosis.

Fibrinogen is a type of channel protein and its role was reported to be supporting the binding of growth factors and promoting the cellular responses of adhesion, proliferation, migration during angiogenesis and tumor cell growth[24]. Fibrinogen was detected in the S2 buffer of cancerous tissues. The presence of fibrinogen in cancer cells was demonstrated to affect the progression of tumor cell growth and metastasis on the basis that fibrinogen alters the ability of breast cancer cells to migrate[24]. In addition, fibrinogen was also found present in lung cancer following the detection of elevated plasma fibrinogen levels in advanced stages of the disease[25] and the localization of fibrinogen in tumor tissue[26,27]. There are also reports of the deposition of fibrinogen on the surfaces of tumor cells and lymphocytes[28,29]. In primary and metastatic tumor[30], the presence of fibrinogen was regarded as an adverse event leading to tumor development. Yamaguchi *et al*[31] reported that lung cancer was developed through induction of hyperfibrinogenemia.

Transgelin (SM22-alpha) is a cytoskeletal-binding protein that was isolated in S1 buffer as a down-regulated protein. Maguire *et al*[32] has reported that loss of transgelin expression is an indication of early tumor progression and the authors suggested that transgelin may serve as a diagnostic marker for breast and colon cancer. We found that the expression of transgelin in cancerous tissue is much lower than that of normal tissue. Other cytosketal-binding proteins that were detected in S1 buffer extract were Bullous pemphigoid antigen 1 precursor and Skeletal muscle beta-tropomyosin.

Some of the enzymes that play important roles in metabolic pathways and are essential for energy production were detected as up-regulated protein in S1 buffer. These enzymes include triosephosphate isomerase and LTRPC6 channel kinase 6. LTRPC6 channel kinase 6 is an essential ion channel and serine/threonine-protein kinase is crucial for magnesium homeostasis. It plays an important role in epithelial magnesium transport and in the active magnesium absorption in the gut and kidney.

Sodium/potassium-transporting ATPase alpha-4 chain was detected as the up-regulated protein in S3 buffer. It is an integral membrane protein that is located in the cell membrane[33]. It catalyzes the hydrolysis of ATP coupled with the exchange of sodium and potassium ions across the plasma membrane.

Carbonate dehydratase is also the up-regulated protein detected in S1 and S2 buffer, it is a zinc-containing enzyme that catalyses the reversible hydration of carbon dioxide, which is significant in the transport of CO_2 from the tissues to the lungs. It was reported that over expression of the zinc enzyme carbonic dehydratase is observed in certain human cancers[34]. Its expression was reported to be elevated in the renal cancer cells as compared to the surrounding normal kidney tissue[35].

DNA-directed RNA polymerase Ⅱ largest chain is the DNA-RNA binding protein that was detected as unique protein in S1 buffer extract of cancer tissues. It was also reported in human brain tumors[36].

Proteins 14-3-3 are the protein-binding proteins that were isolated in the S1 buffer as unique proteins from colon cancer tissue. Protein 14-3-3 plays a role in the regulation of signal transduction protein pathways implicated in the control of cell proliferation, differentiation and survival[37]. This protein was reported to play multiple roles in maintaining cell survival[38,39]. Friedman *et al*[40] has reported that protein 14-3-3 in three different isoforms was expressed up to 1.7 fold in the colon tumors as compared to normal colon tissue.

Alpha-1-antitrypsin is an endopeptidase inhibitor protein that was isolated as a unique protein in S1 buffer from normal tissue only. In individuals who lack this inhibitor protein, the protease destroys the membrane system, leaving the colon and rectum vulnerable to colorectal cancer development[41]. The main role of alpha-1-antitrypsin is in defense against elastase damage that occurs in the lung under normal physiology conditions[42]. Alpha-1-antitrypsin was detected in patients with lung cancer[43] and was used as a cancer marker for cervical

cancer[44]. Contrary to our finding, Friedman *et al*[40] reported the detection of alpha-1-antitrypsin in colon cancer.

ATP (GTP)-binding protein is ATP-binding protein that was detected as down-regulated protein in S2 buffer. It is a mitochondrial membrane protein.

Kinesin is a motor activity protein that was detected as an up-regulated protein in S2 buffer extract. It is a microtubule-associated force-producing protein that may play a role in organelle transport[45]. This protein was also reported in breast cancer tissue[46]. Kinesin-like protein 2 is an immunogenic breast cancer antigen[47]. In addition, kinesin-like protein 2 was also reported in pancreatic cancer[48].

ACTG1 is another type of motor activity protein that was detected as an up-regulated protein. It is a protein involved in the formation of filaments, which is the major component of the cytoskeleton[49]. Its existence in colorectal cancer was also reported by Vadlamudi and Shin[50]. Alteration of cytoskeletal proteins may have an important role in cancer initiation or progression. Mutations affecting four major cytoskeletal components have now been identified in human neoplastic cells. Chou *et al*[51] postulated that mutated cytoskeletal genes may be members of a class of oncogenes, which are fundamentally different from both the nuclear-acting and growth factor/receptor/protein kinase-related types of oncogenes.

In this study, a number of the differentially expressed proteins extracted from the normal and cancerous colonic tissues were identified. Amongst the proteins identified, some of the proteins have their roles identified in similar or other types of cancers. There are also a series of hypothetical proteins with unknown functions. Some of these proteins have their primary location at the cell membrane, which may serve as potential antigens for drug-targeted therapy or as candidates for vaccines against colon cancer. These proteins are under further investigation in our laboratory.

ACKNOWLEDGMENTS

We would like thank the Ministry of Science, Technology and Innovation in Malaysia for providing the grant to carry out this project. We also want to extent our gratitude to the Ministry of Health in Malaysia for providing tissue specimens for the analysis.

REFERENCES

1 **Fearon ER**. Molecular biology of gastrointestinal cancers. In: De Vita VT Jr, Hellman S, Rosenberg SA, eds. Cancer: principles and practice of oncology. 6th ed. Philadelphia: Lippincott, Williams, and Wilkins Press, 2001: 1037-1049

2 **Harkins L**, Volk AL, Samanta M, Mikolaenko I, Britt WJ, Bland KI, Cobbs CS. Specific localisation of human cytomegalovirus nucleic acids and proteins in human colorectal cancer. *Lancet* 2002; **360**: 1557-1563

3 **Fearon ER**, Vogelstein B. A genetic model for colorectal tumorigenesis. *Cell* 1990; **61**: 759-767

4 **Alaiya AA**, Franzén B, Auer G, Linder S. Cancer proteomics: from identification of novel markers to creation of artifical learning models for tumor classification. *Electrophoresis* 2000; **21**: 1210-1217

5 **Stulík J**, Hernychová L, Porkertová S, Knízek J, Macela A, Bures J, Jandik P, Langridge JI, Jungblut PR. Proteome study of colorectal carcinogenesis. *Electrophoresis* 2001; **22**: 3019-3025

6 **Chong BE**, Hamler RL, Lubman DM, Ethier SP, Rosenspire AJ, Miller FR. Differential screening and mass mapping of proteins from premalignant and cancer cell lines using nonporous reversed-phase HPLC coupled with mass spectrometric analysis. *Anal Chem* 2001; **73**: 1219-1227

7 **Emmert-Buck MR**, Gillespie JW, Paweletz CP, Ornstein DK, Basrur V, Appella E, Wang QH, Huang J, Hu N, Taylor P, Petricoin EF 3rd. An approach to proteomic analysis of human tumors. *Mol Carcinog* 2000; **27**: 158-165

8 **Molloy MP**, Herbert BR, Walsh BJ, Tyler MI, Traini M, Sanchez JC, Hochstrasser DF, Williams KL, Gooley AA. Extraction of membrane proteins by differential solubilization for separation using two-dimensional gel electrophoresis. *Electrophoresis* 1998; **19**: 837-844

9 **Gam LH,** Aishah L. Identification and confirmation of urinary human chorionic gonadotropin using in-gel digestion and HPLC / MS / MS analysis. *Jurnal Biosains* 2002; **13** (1): 27-34

10 **Hjelmeland LM**. Solubilization of native membrane proteins. *Methods Enzymol* 1990; **182**: 253-264

11 **Rabilloud T**. Use of thiourea to increase the solubility of membrane proteins in two-dimensional electrophoresis. *Electrophoresis* 1998; **19**: 758-760

12 **Henzel WJ**, Billeci TM, Stults JT, Wong SC, Grimley C, Watanabe C. Identifying proteins from two-dimensional gels by molecular mass searching of peptide fragments in protein sequence databases. *Proc Natl Acad Sci USA* 1993; **90**: 5011-5015

13 **Figeys D**, Gygi SP, Zhang Y, Watts J, Gu M, Aebersold R. Electrophoresis combined with novel mass spectrometry techniques: powerful tools for the analysis of proteins and proteomes. *Electrophoresis* 1998; **19**: 1811-1818

14 **Duvet S**, Op De Beeck A, Cocquerel L, Wychowski C, Cacan R, Dubuisson J. Glycosylation of the hepatitis C virus envelope protein E1 occurs posttranslationally in a mannosylphosphoryldolichol-deficient CHO mutant cell line. *Glycobiology* 2002; **12**: 95-101

15 **Fountoulakis M**, Tsangaris G, Oh JE, Maris A, Lubec G. Protein profile of the HeLa cell line. *J Chromatogr A* 2004; **1038**: 247-265

16 **Williams K**, Chubb C, Huberman E, Giometti CS. Analysis of differential protein expression in normal and neoplastic human breast epithelial cell lines. *Electrophoresis* 1998; **19**: 333-343

17 **Leong ASY**, Cooper K, Leong FJM. Manual of diagnostic antibodies for immunohistology. London: Greenwich Medical Media Pub, 1999: 25-35

18 **Hembrough TA**, Kralovich KR, Li L, Gonias SL. Cytokeratin 8 released by breast carcinoma cells in vitro binds plasminogen and tissue-type plasminogen activator and promotes plasminogen activation. *Biochem J* 1996; **317** (Pt 3): 763-769

19 **Ludowyke RI**, Warton K, Scurr LL. Inhibition of antigen and calcium ionophore induced secretion from RBL-2H3 cells by phosphatase inhibitors. *Cell Biol Int* 1998; **22**: 855-865

20 **Birchmeier C**, Birchmeier W, Brand-Saberi B. Epithelial-mesenchymal transitions in cancer progression. *Acta Anat (Basel)* 1996; **156**: 217-226

21 **Seshadri R**, Raymond WA, Leong AS, Horsfall DJ, McCaul K. Vimentin expression is not associated with poor prognosis in breast cancer. *Int J Cancer* 1996; **67**: 353-356

22 **Solomon A**, Murphy CL, Weaver K, Weiss DT, Hrncic R, Eulitz M, Donnell RL, Sletten K, Westermark G, Westermark P. Calcifying epithelial odontogenic (Pindborg) tumor-associated amyloid consists of a novel human protein. *J Lab Clin Med* 2003; **142**: 348-355

23 **Afjehi-Sadat L**, Shin JH, Felizardo M, Lee K, Slavc I, Lubec G. Detection of hypothetical proteins in 10 individual human tumor cell lines. *Biochim Biophys Acta* 2005; **1747**: 67-80

24 **Simpson-Haidaris PJ**, Rybarczyk B. Tumors and fibrinogen. The role of fibrinogen as an extracellular matrix protein. *Ann N Y Acad Sci* 2001; **936**: 406-425

25 **Edwards RL**, Rickles FR, Moritz TE, Henderson WG,

Zacharski LR, Forman WB, Cornell CJ, Forcier RJ, O'Donnell JF, Headley E. Abnormalities of blood coagulation tests in patients with cancer. *Am J Clin Pathol* 1987; **88**: 596-602

26 **Ogura T**, Hirao F, Tsubura E, Yamamura Y. Autoradiographic study on localization of fibrinogen in rabbit lung cancer. *Gann* 1971; **62**: 367-372

27 **Wojtukiewicz MZ**, Zacharski LR, Memoli VA, Kisiel W, Kudryk BJ, Rousseau SM, Stump DC. Abnormal regulation of coagulation/fibrinolysis in small cell carcinoma of the lung. *Cancer* 1990; **65**: 481-485

28 **Cardinali M**, Uchino R, Chung SI. Interaction of fibrinogen with murine melanoma cells: covalent association with cell membranes and protection against recognition by lymphokine-activated killer cells. *Cancer Res* 1990; **50**: 8010-8016

29 **Atagi S**, Sone S, Fukuta K, Ogura T. Inhibition by fibrin coagulation of lung cancer cell destruction by human interleukin-2-activated killer cells. *Jpn J Cancer Res* 1992; **83**: 1088-1094

30 **Nagy JA**, Masse EM, Herzberg KT, Meyers MS, Yeo KT, Yeo TK, Sioussat TM, Dvorak HF. Pathogenesis of ascites tumor growth: vascular permeability factor, vascular hyperpermeability, and ascites fluid accumulation. *Cancer Res* 1995; **55**: 360-368

31 **Yamaguchi T**, Kimura H, Yokota S, Yamamoto Y, Hashimoto T, Nakagawa M, Ito M, Ogura T. Effect of IL-6 elevation in malignant pleural effusion on hyperfibrinogenemia in lung cancer patients. *Jpn J Clin Oncol* 2000; **30**: 53-58

32 **Maguire PB**, Moran N, Cagney G, Fitzgerald DJ. Application of proteomics to the study of platelet regulatory mechanisms. *Trends Cardiovasc Med* 2004; **14**: 207-220

33 **Broude NE**, Modyanov NN, Monastyrskaya GS, Sverdlov ED. Advances in Na+,K+-ATPase studies: from protein to gene and back to protein. *FEBS Lett* 1989; **257**: 1-9

34 **Whittington DA**, Waheed A, Ulmasov B, Shah GN, Grubb JH, Sly WS, Christianson DW. Crystal structure of the dimeric extracellular domain of human carbonic anhydrase XII, a bitopic membrane protein overexpressed in certain cancer tumor cells. *Proc Natl Acad Sci USA* 2001; **98**: 9545-9550

35 **Türeci O**, Sahin U, Vollmar E, Siemer S, Göttert E, Seitz G, Parkkila AK, Shah GN, Grubb JH, Pfreundschuh M, Sly WS. Human carbonic anhydrase XII: cDNA cloning, expression, and chromosomal localization of a carbonic anhydrase gene that is overexpressed in some renal cell cancers. *Proc Natl Acad Sci USA* 1998; **95**: 7608-7613

36 **Cuatico W**, Cho JR, Spiegelman S. Particles with RNA of high molecular weight and RNA-directed DNA polymerase in human brain tumors. *Proc Natl Acad Sci USA* 1973; **70**: 2789-2793

37 **Fu H**, Subramanian RR, Masters SC. 14-3-3 proteins: structure, function, and regulation. *Annu Rev Pharmacol Toxicol* 2000; **40**: 617-647

38 **Ichimura T**, Isobe T, Okuyama T, Takahashi N, Araki K, Kuwano R, Takahashi Y. Molecular cloning of cDNA coding for brain-specific 14-3-3 protein, a protein kinase-dependent activator of tyrosine and tryptophan hydroxylases. *Proc Natl Acad Sci USA* 1988; **85**: 7084-7088

39 **Masters SC**, Subramanian RR, Truong A, Yang H, Fujii K, Zhang H, Fu H. Survival-promoting functions of 14-3-3 proteins. *Biochem Soc Trans* 2002; **30**: 360-365

40 **Friedman DB**, Hill S, Keller JW, Merchant NB, Levy SE, Coffey RJ, Caprioli RM. Proteome analysis of human colon cancer by two-dimensional difference gel electrophoresis and mass spectrometry. *Proteomics* 2004; **4**: 793-811

41 **Yang P**, Cunningham JM, Halling KC, Lesnick TG, Burgart LJ, Wiegert EM, Christensen ER, Lindor NM, Katzmann JA, Thibodeau SN. Higher risk of mismatch repair-deficient colorectal cancer in alpha(1)-antitrypsin deficiency carriers and cigarette smokers. *Mol Genet Metab* 2000; **71**: 639-645

42 **Rosenberg S**, Barr PJ, Najarian RC, Hallewell RA. Synthesis in yeast of a functional oxidation-resistant mutant of human alpha-antitrypsin. *Nature* 1984; **312**: 77-80

43 **Harris CC**, Cohen MH, Connor R, Primack A, Saccomanno G, Talamo RC. Serum alpha1-antitrypsin in patients with lung cancer or abnormal sputum cytology. *Cancer* 1976; **38**: 1655-1657

44 **Govorukhina NI**, Keizer-Gunnink A, van der Zee AG, de Jong S, de Bruijn HW, Bischoff R. Sample preparation of human serum for the analysis of tumor markers. Comparison of different approaches for albumin and gamma-globulin depletion. *J Chromatogr A* 2003; **1009**: 171-178

45 **Bloom GS**, Endow SA. Motor proteins 1: kinesins. *Protein Profile* 1995; **2**: 1105-1171

46 **Venkatesh LK**, Gettemeier T, Chinnadurai G. A nuclear kinesin-like protein interacts with and stimulates the activity of the leucine-rich nuclear export signal of the human immunodeficiency virus type 1 rev protein. *J Virol* 2003; **77**: 7236-7243

47 **Scanlan MJ**, Gout I, Gordon CM, Williamson B, Stockert E, Gure AO, Jäger D, Chen YT, Mackay A, O' Hare MJ, Old LJ. Humoral immunity to human breast cancer: antigen definition and quantitative analysis of mRNA expression. *Cancer Immun* 2001; **1**: 4-21

48 **Fontijn RD**, Goud B, Echard A, Jollivet F, van Marle J, Pannekoek H, Horrevoets AJ. The human kinesin-like protein RB6K is under tight cell cycle control and is essential for cytokinesis. *Mol Cell Biol* 2001; **21**: 2944-2955

49 **Kabsch W**, Vandekerckhove J. Structure and function of actin. *Annu Rev Biophys Biomol Struct* 1992; **21**: 49-76

50 **Vadlamudi RK**, Shin J. Genomic structure and promoter analysis of the p62 gene encoding a non-proteasomal multiubiquitin chain binding protein. *FEBS Lett* 1998; **435**: 138-142

51 **Chou CC**, Davis RC, Fuller ML, Slovin JP, Wong A, Wright J, Kania S, Shaked R, Gatti RA, Salser WA. Gamma-actin: unusual mRNA 3'-untranslated sequence conservation and amino acid substitutions that may be cancer related. *Proc Natl Acad Sci USA* 1987; **84**: 2575-2579

S- Editor Wang J **L- Editor** Lutze M **E- Editor** Ma WH

PO Box 2345, Beijing 100023, China
www.wjgnet.com
wjg@wjgnet.com

World J Gastroenterol 2006 August 21; 12(31): 4981-4985
World Journal of Gastroenterology ISSN 1007-9327
© 2006 The WJG Press. All rights reserved.

Inhibitory effect of caffeic acid phenethyl ester on the growth of SW480 colorectal tumor cells involves β-catenin associated signaling pathway down-regulation

Yu-Jun He, Bao-Hua Liu, De-Bing Xiang, Zuo-Yi Qiao, Tao Fu, Yu-Hong He

Yu-Jun He, Bao-Hua Liu, Tao Fu, Department of General Surgery, Daping Hospital and Research Institute of Surgery, Third Military Medical University, Chongqing 400042, China
De-Bing Xiang, Yu-Hong He, Cancer Center, Daping Hospital and Research Institute of Surgery, Third Military Medical University, Chongqing 400042, China
Zuo-Yi Qiao, Urology Center, Chongqing Peace Hospital, Chongqing 400020, China
Supported by the National Natural Science Foundation of China, No. 30100228
Correspondence to: Yu-Jun He, Department of General Surgery, Daping Hospital and Research Institute of Surgery, Third Military Medical University, Chongqing 400042, China. heyujun69@yahoo.com.cn
Telephone: +86-23-60687466
Received: 2006-03-28 Accepted: 2006-05-25

Abstract

AIM: To study the anti-tumor effect of caffeic acid phenethyl ester (CAPE) and the influence of CAPE on β-catenin associated signaling pathway in SW480 colorectal cancer (CRC) cells.

METHODS: SW480 cells were treated with CAPE at serial concentrations. The proliferative status of cells was measured by methabenzthiazuron (MTT) assay. Cell cycle and cell apoptosis were analyzed using flow cytometry (FCM). Western blotting assay was used to evaluate the protein level of β-catenin, c-myc and cyclinD1. β-catenin localization was determined by indirect immunofluorescence.

RESULTS: CAPE displayed a strong inhibitory effect in a significant dose- and time-dependent manner on SW480 cell growth. FCM analysis showed that the ratio of G0/G1 phase cells increased, S phase ratio decreased and apoptosis rate increased after SW480 cells were exposed to CAPE for 24 h. Pretreatment of SW480 cells with CAPE significantly suppressed β-catenin, c-myc and cyclinD1 protein expression. CAPE treatment was associated with decreased accumulation of β-catenin protein in nucleus and cytoplasm, and concurrently increased its accumulation on the surface of cell membrane.

CONCLUSION: CAPE can inhibit SW480 cell proliferation by inducing cell cycle arrest and apoptosis. Decreased β-catenin and the associated signaling pathway target gene expression may mediate the anti-tumor effects of CAPE.

© 2006 The WJG Press. All rights reserved.

Key words: Caffeic acid phenethyl ester; Colorectal cancer; Proliferation; β-catenin; Signaling pathway

He YJ, Liu BH, Xiang DB, Qiao ZY, Fu T, He YH. Inhibitory effect of caffeic acid phenethyl ester on the growth of SW480 colorectal tumor cells involves β-catenin associated signaling pathway down-regulation. *World J Gastroenterol* 2006; 12(31): 4981-4985

http://www.wjgnet.com/1007-9327/12/4981.asp

INTRODUCTION

Caffeic acid phenethyl ester (CAPE) is a phenolic antioxidant. As an active component of propolis, CAPE has many biological and pharmacological functions including immunoregulation, anti-inflammatory, antiviral, antibacterial and antitumor activities. Several studies have demonstrated that CAPE has antiproliferative effect, apoptosis-inducing effect in various tumor cells *in vitro*[1-4] and *in vivo*[5,6]. CAPE also inhibited the development of azoxymethane-induced aberrant crypts in the colon of rats[7]. Furthermore, a number of studies reported that CAPE elicits apoptosis and suppresses the growth of transformed cells, and the cytotoxicity of CAPE to transformed cells is sensitive and selective[8-10]. Multiple molecular mechanisms seem to be involved in the tumor suppressive effects of CAPE. It was reported that CAPE could inhibit NFκB and induce apoptosis *via* Fas signal activation in human breast cancer MCF-7 cells[11]. Additionally, Carrasco *et al*[12] found an 85% decrease in nuclear localization of the p65 subunit of NF-kappa B. While in C6 glioma cells, the tumor suppressor proteins P53 and p38 mitogen-activated protein kinase (p38 MAPK) are involved in CAPE-induced apoptotic cell death[13].

Colorectal cancer (CRC) is the third most common cancer and the fourth most frequent cause of cancer death worldwide. Recent studies have indicated that in most of CRC, there are aberrant β-catenin associated signaling pathways[14]. The β-catenin associated signaling pathway

plays critical roles in cell proliferation and differentiation, and the β-catenin is the central component in the pathway. Aberrant β-catenin associated signaling pathway, which generally results from inactivating mutation of adenomatous polyposis coli (APC) or activating mutation of β-catenin, leads to the accumulation of β-catenin in the nucleus of cells, which is subsequently complexed with T-cell factor (TCF) and promotes transcription of a variety of target genes, such as c-myc, cyclinD1, ultimately leading to cell aberrant proliferation and tumor formation. Dysregulation of β-catenin associated signaling and hence β-catenin expression is believed to be central to the early stages of sporadic colorectal carcinogenesis in humans[15-17]. Therefore, control of β-catenin and/or control of the downstream target gene expression represents an opportunity for rational colorectal cancer therapy.

Here we report the anti-tumor effect of CAPE in association with β-catenin associated signaling in SW480 colorectal cancer cells. These studies have important implications for CAPE to be used as a potential therapeutic agent for colorectal cancer.

MATERIALS AND METHODS

Chemicals

CAPE, dimethyl sulphoxide (DMSO), PI, methabenzthiazuron (MTT), mouse anti-human β-catenin, c-myc, cyclinD1 and β-actin monoclonal antibody were purchased from Sigma-Aldrich (USA). RPMI-1640 medium, fetal calf serum and trypsin-EDTA were purchased from Hyclone (USA). FITC and horseradish peroxidase-conjugated secondary antibody were obtained from Pierce Biotechnology (USA). Annexin-V and PI double staining kit and Tripure were purchased from Roche (Germany). Protein assay kits were obtained from Bio-Rad Labs (USA). Enhanced chemiluminescence (ECL) system was purchased from Amersham Life Science (UK). CAPE was dissolved with DMSO and adjusted to final concentrations with culture medium prior to use.

Cell culture

The human CRC cell line SW480 was purchased from the American Type Culture Collection (ATCC). The cells were cultured in RPMI-1640 medium supplemented with penicillin G (100 U/mL), streptomycin (100 μg/mL) and 10% fetal calf serum. Cells were grown at 37℃ in a humidified atmosphere of 50 mL/L CO_2 and were routinely subcultured using 0.25% (w/v) trypsin-EDTA solution.

MTT assay

The logarithmically growing SW480 cells were plated into a 96-well plate at a density of 4×10^3 cells/well. After 24 h, the cells were treated with CAPE at designated concentrations (2.5, 5, 10, 20, 40 and 80 mg/L) for 24, 48, 72 and 96 h, respectively. Control wells were treated with 0.1% DMSO alone. Then, 20 μL MTT (5 g/L) was added to each well and incubated for an additional 4 h, and then culture media were discarded followed by addition of 0.15 mL DMSO and vibration for 10 min. The absorbance was measured at 490 nm. The inhibitory rates (IR) were calculated as follows: IR (%) = [(1-absorbance of the treated wells)/(absorbance of the control wells)] × 100%. The 50% inhibitory concentration (IC50) value was determined using CalcuSyn software.

Flow cytometry analysis

Cell density was adjusted to 0.3-1.0 × 10^7 cells/mL. Cells were serum-starved for 24 h and then treated with different concentrations of CAPE (2.5, 5 and 10 mg/L) for 24 h. Then the cells were harvested with trypsin-EDTA to produce a single cell suspension. The cells were pelleted by centrifugation and washed twice with phosphate-buffered saline (PBS). Then, the cell pellets were resuspended in 0.5 mL PBS and fixed in 5 mL ice-cold 70% ethanol at 4℃. The fixed cells were spun down by centrifugation and the pellets were washed with PBS. After resuspension with 1 mL PBS, the cells were incubated with RNase A (20 mg/L) and PI (50 mg/L) and shaken for 1 h at 37℃ in the dark. The stained cells were analyzed using a FACScan flow cytometer in combination with BD analysis Ⅱ software (Becton Dickinson).

Annexin-V and PI double-staining flow cytometry analysis

The cells were treated and harvested in the same way as mentioned above. Analysis of apoptosis was performed using the Annexin-V and PI double staining kit according to the manufacturer's protocol. After treatment with CAPE, the cells were immediately analyzed by flow cytometry. The apoptotic cells were localized in the right lower quadrant of a dot-plot graph by using Annexin-V-fluorescein versus PI.

Western blot analysis

Cells were placed in serum-free medium with or without CAPE (2.5, 5 and 10 mg/L) for 24 and 48 h, then were lysed in solubilization buffer containing sodium dodecyl sulfate(SDS) and β-mercaptoethanol. After centrifugation, the supernatant was collected and the protein concentration determined by the BioRad DC kit. Equal amounts of protein (50 μg) in each sample were resolved in 10% SDS polyacrylamide gel electrophoresis (SDS-PAGE) and transferred to a polyvinylidene difluoride (PVDF) membrane. After blocked with 2% skim milk, the membranes were incubated with primary antibodies at appropriate dilution (β-actin, 1/1000; β-catenin, c-myc and cyclinD1, 1/500) overnight at 4℃. Horseradish peroxidase-conjugated secondary antibody was diluted 1/5000 and incubated for 1 h at 20℃. Immunoreactive proteins were detected with an ECL system, and light emission was captured on Kodak X-ray films. Product bands were quantitated by scanning densitometry.

Indirect immunofluorescence

SW480 cells grown on glass coverslips were treated for 48 h with CAPE (2.5, 5 and 10 mg/L) or an equivalent dilution of DMSO, under standard culture conditions as described above. Then cells were washed with PBS and fixed with methanol for 20 min. Incubation with monoclonal anti-β-catenin antibody (1:200) was carried out overnight at 4℃. This was followed by incubation with FITC-

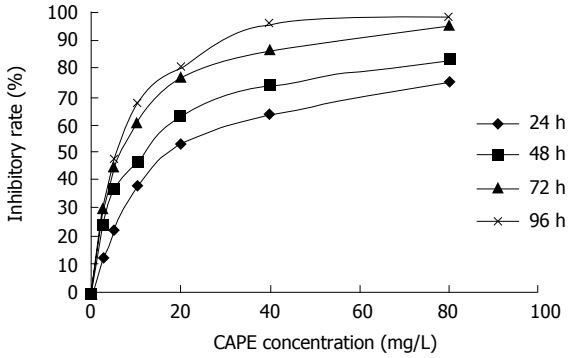

Figure 1 Effect of CAPE on SW480 cell proliferation. SW480 cells were treated with CAPE at indicated concentrations for 24, 48, 72 and 96 h. The cell viability was determined by MTT assay.

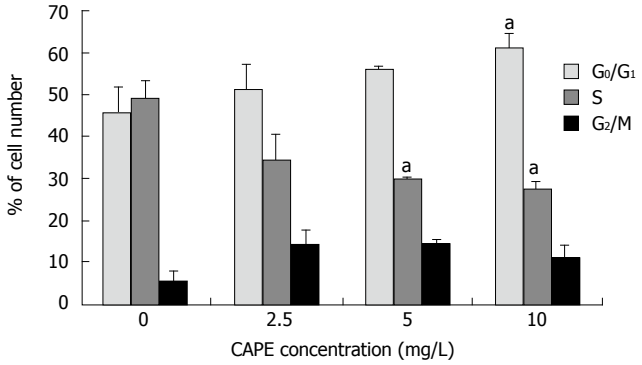

Figure 2 Effect of CAPE on SW480 cell cycle distribution. The percentage of cells in each phase of the cell cycle, G_0/G_1, S, and G2/M was determined by FCM after cells were treated with indicated concentrations (2.5, 5 and 10 mg/L) of CAPE for 24 h. $^aP < 0.05$ *vs* the control group, treated with vehicle, DMSO only.

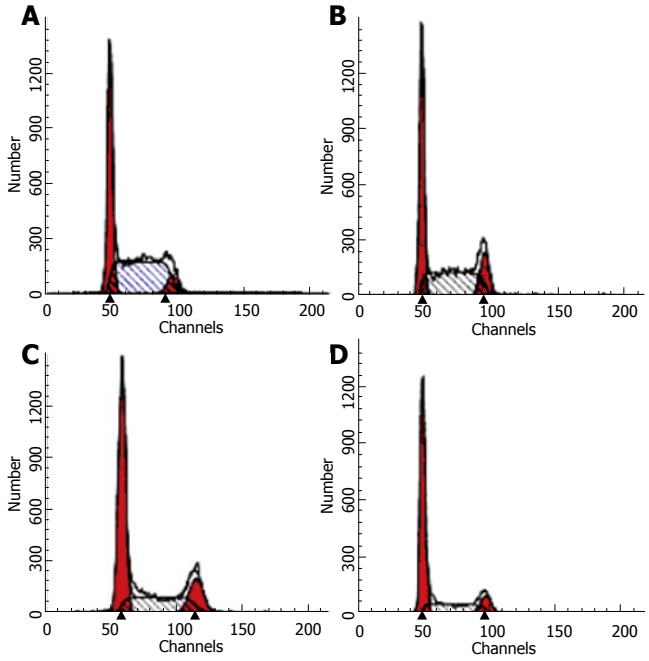

Figure 3 Flow cytometry analysis of SW480 cells following 24 h incubation with CAPE (**A**) 0 mg/L, (**B**) 2.5 mg/L, (**C**) 5 .0 mg/L, (**D**) 10 mg/L.

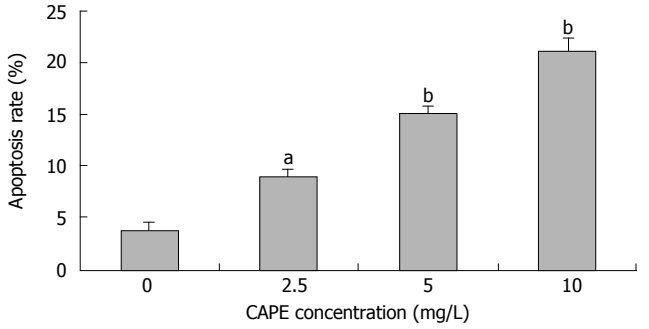

Figure 4 Effect of CAPE on SW480 cell apoptosis. After treated with CAPE at indicated concentrations for 24 h, the SW480 cell apoptosis rates were analyzed by Annexin-V and PI double-staining flow cytometry. $^aP < 0.05$, $^bP < 0.01$ *vs* the control group.

conjugated secondary antibody (1:200) for 1 h at room temperature. Omission of the primary antibody was used as a negative control. Images were collected using laser scanning confocal microscopy.

Statistical analysis

Data were expressed as mean ± SD. Analysis of data was performed using one-way ANOVA. $P < 0.05$ was considered statistically significant.

RESULTS

Effect of CAPE on cell proliferation

SW480 cells were treated with various concentrations (2.5, 5, 10, 20, 40 and 80 mg/L) of CAPE for 24, 48, 72 and 96 h, respectively. Then the cell viability was measured by MTT assay. CAPE showed a significant dose-dependent and time-dependent inhibition of cell growth (Figure 1). The IC50 value for CAPE at 24, 48, 72 and 96 h after treatment was 20.27, 11.38, 6.15 and 5.44 mg/L, respectively.

Effects of CAPE on cell cycle progression

In order to examine the effects of CAPE on cell cycle progression, SW480 cells were treated with designated concentrations of CAPE for 24 h. The distributions of cells in each of the cell cycle phases were determined by FCM. As shown in Figures 2 and 3, the percentage of cell population of the G_0/G_1 phase significantly increased, while those in S and G_2/M phase decreased. CAPE caused cell cycle arrest in G_0/G_1 phase in a dose-dependent manner.

Effect of CAPE on apoptosis

After SW480 cells were exposed to CAPE at various concentrations (2.5, 5 and 10 mg/L) for 24 h, Annexin-V and PI double-staining flow cytometry analysis showed that the apoptosis rates were 9.1% ± 0.7%, 15.23% ± 0.6% and 21.1% ± 1.44%, respectively, which were significantly higher than that in the control group (3.7% ± 0.9%). CAPE induced apoptosis of SW480 cells in a dose-dependent manner (Figures 4 and 5).

Effect of CAPE on the expression of β-catenin, c-myc and cyclinD1

To investigate the mechanisms underlying CAPE induced apoptosis, we examined the effect of CAPE on the expres-

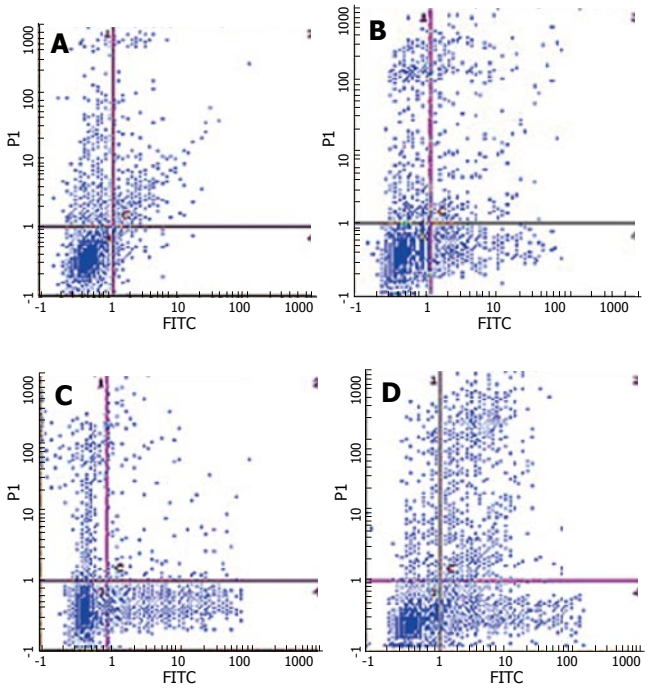

Figure 5 Annexin-V and PI double-staining flow cytometry analysis of SW480 cells following 24 h incubation with CAPE (**A**) 0 mg/L, (**B**) 2.5 mg/L, (**C**) 5.0 mg/L, (**D**) 10 mg/L.

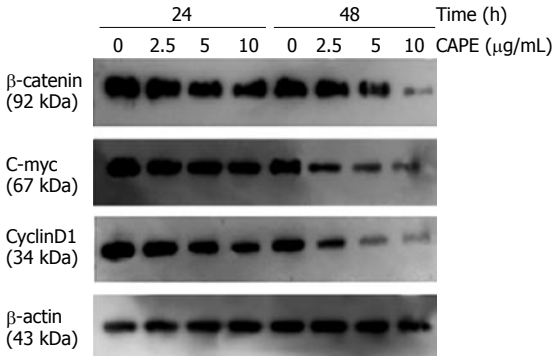

Figure 6 Western blot analysis of β-catenin, c-myc and cyclinD1 protein expression in SW480 cells following 24 and 48 h incubation with indicated concentrations of CAPE. β-actin served as a loading control.

sion of β-catenin signaling pathway related genes. After SW480 cells were exposed to CAPE (2.5, 5 and 10 mg/L) for 24 and 48 h, Western blot analysis showed that CAPE significantly suppressed β-catenin protein expression in a dose and time-dependent manner. CAPE treatment after 48 h markedly decreased the expression of c-myc and cyclin D1, two of the β-catenin associated signaling pathway target genes (Figure 6).

Indirect immunofluorescence studies of β-catenin localization in SW480 cells revealed that CAPE treatment decreased the accumulation of β-catenin protein in nucleus and cytoplasm, and concurrently increased its accumulation on the surface of cell membrane (Figure 7).

DISCUSSION

Propolis has been used since ancient times in folk medicine. Researches indicate that propolis exhibits immunoregulation, anti-bacterial, anti-inflammatory and anti-tumor activities[18-20]. As an active component of propolis, CAPE is receiving much attention in the medical research community because of its potential for the treatment of a number of disorders, including cancer. Recent studies demonstrated that CAPE has antiproliferative and apoptosis-inducing effects in various tumor cells. An *in vivo* study showed that CAPE decreased the growth of the xenografts of C6 glioma cells in nude mice[6]. Also, dietary intake of CAPE decreased tumor formation in the enterocytes of the Min/+ mouse[21].

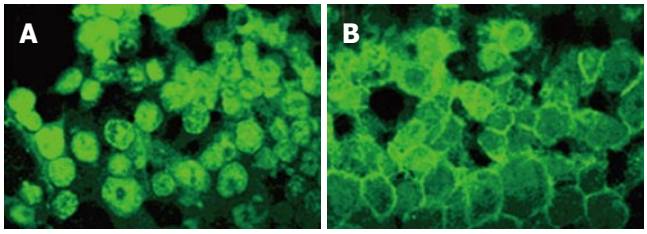

Figure 7 Indirect immunofluorescence analysis of β-catenin protein localization in SW480 cells following 48 h incubation with CAPE (**A**) 0 mg/L, (**B**) 10 mg/L.

In the present study, we investigated the effect of CAPE on cell proliferation, cell cycle and apoptosis of SW480 CRC cells. Our data demonstrated that CAPE treatment could significantly inhibit cell growth in a dose- and time-dependent manner, along with induction of G_0/G_1 arrest and apoptosis in SW480 cells.

Multiple molecular mechanisms seem to be involved in the tumor suppressive effect of CAPE. Recently, it was reported that CAPE could inhibit NFκB, inducing apoptosis *via* Fas signal activation in human tumor cells[11,12]. Hung *et al*[22] reported that down-regulation of Mcl-1 gene expression and activation of caspase-8 are associated with CAPE-triggered cell apoptosis. Moreover, tumor suppressor proteins P53 and p38 MAPK play a prominent role in the CAPE-induced apoptotic cell death in C6 glioma cells, which might contribute to the anti-tumor effect in these cells[13].

Our results suggest that the anti-tumor effects of CAPE on SW480 cells are associated with down-regulation of the β-catenin associated signaling pathways. β-catenin plays a dual role in cells. It is a structural component of cell-cell adherent junctions as well as a key player in β-catenin associated signaling pathway[23]. The signaling function of β-catenin is particularly important in colorectal cancer since mutations of APC or tumor-associated mutations of β-catenin lead to its stabilization[24,25]. Here we showed that CAPE treatment inhibited β-catenin in a dose-dependent manner in SW480 cells. More interestingly, CAPE changed the localization of β-catenin in cells. As shown in Figure 7, nuclear accumulated β-catenin in SW480 cells mainly relocalized on the cell membrane at cell-cell contacts after CAPE treatment. Two of target genes of the activated β-catenin associated signaling pathways have been reported to be c-myc and cyclin D1[26,27]. Oncogenes c-myc and cyclinD1 are a kind of effector protein of the karyomitosis signal, which can trigger and regulate the transcription of the genes related with pro-

liferation. They are frequently overexpressed in several human tumors, including colorectal cancer. Our results showed that CAPE treatment markedly decreased the expression of c-myc and cyclinD1. This indicates that CAPE induced cell cycle arrest and apoptosis might be associated with down-regulation of β-catenin associated signaling pathways.

In summary, we have shown that CAPE can inhibit the growth of human SW480 colorectal cancer cells by inducing cell cycle arrest and apoptosis. Decreased β-catenin and the β-catenin associated signaling pathway target gene expression might mediate the anti-tumor effects of CAPE. These findings have strong implications for CAPE as a potential therapeutic agent for colorectal cancer.

REFERENCES

1 **Chen YJ**, Shiao MS, Wang SY. The antioxidant caffeic acid phenethyl ester induces apoptosis associated with selective scavenging of hydrogen peroxide in human leukemic HL-60 cells. *Anticancer Drugs* 2001; **12**: 143-149

2 **Lee YJ**, Liao PH, Chen WK, Yang CY. Preferential cytotoxicity of caffeic acid phenethyl ester analogues on oral cancer cells. *Cancer Lett* 2000; **153**: 51-56

3 **Usia T**, Banskota AH, Tezuka Y, Midorikawa K, Matsushige K, Kadota S. Constituents of Chinese propolis and their antiproliferative activities. *J Nat Prod* 2002; **65**: 673-676

4 **Nagaoka T**, Banskota AH, Tezuka Y, Saiki I, Kadota S. Selective antiproliferative activity of caffeic acid phenethyl ester analogues on highly liver-metastatic murine colon 26-L5 carcinoma cell line. *Bioorg Med Chem* 2002; **10**: 3351-3359

5 **Orsolić N**, Terzić S, Mihaljević Z, Sver L, Basić I. Effects of local administration of propolis and its polyphenolic compounds on tumor formation and growth. *Biol Pharm Bull* 2005; **28**: 1928-1933

6 **Kuo HC**, Kuo WH, Lee YJ, Lin WL, Chou FP, Tseng TH. Inhibitory effect of caffeic acid phenethyl ester on the growth of C6 glioma cells in vitro and in vivo. *Cancer Lett* 2006; **234**: 199-208

7 **Borrelli F**, Izzo AA, Di Carlo G, Maffia P, Russo A, Maiello FM, Capasso F, Mascolo N. Effect of a propolis extract and caffeic acid phenethyl ester on formation of aberrant crypt foci and tumors in the rat colon. *Fitoterapia* 2002; **73** Suppl 1: S38-S43

8 **Chiao C**, Carothers AM, Grunberger D, Solomon G, Preston GA, Barrett JC. Apoptosis and altered redox state induced by caffeic acid phenethyl ester (CAPE) in transformed rat fibroblast cells. *Cancer Res* 1995; **55**: 3576-3583

9 **Liao HF**, Chen YY, Liu JJ, Hsu ML, Shieh HJ, Liao HJ, Shieh CJ, Shiao MS, Chen YJ. Inhibitory effect of caffeic acid phenethyl ester on angiogenesis, tumor invasion, and metastasis. *J Agric Food Chem* 2003; **51**: 7907-7912

10 **Lee YT**, Don MJ, Hung PS, Shen YC, Lo YS, Chang KW, Chen CF, Ho LK. Cytotoxicity of phenolic acid phenethyl esters on oral cancer cells. *Cancer Lett* 2005; **223**: 19-25

11 **Watabe M**, Hishikawa K, Takayanagi A, Shimizu N, Nakaki T. Caffeic acid phenethyl ester induces apoptosis by inhibition of NFkappaB and activation of Fas in human breast cancer MCF-7 cells. *J Biol Chem* 2004; **279**: 6017-6026

12 **Carrasco-Legleu CE**, Márquez-Rosado L, Fattel-Fazenda S, Arce-Popoca E, Pérez-Carreón JI, Villa-Treviño S. Chemoprotective effect of caffeic acid phenethyl ester on promotion in a medium-term rat hepatocarcinogenesis assay. *Int J Cancer* 2004; **108**: 488-492

13 **Lee YJ**, Kuo HC, Chu CY, Wang CJ, Lin WC, Tseng TH. Involvement of tumor suppressor protein p53 and p38 MAPK in caffeic acid phenethyl ester-induced apoptosis of C6 glioma cells. *Biochem Pharmacol* 2003; **66**: 2281-2289

14 **Gregorieff A**, Clevers H. Wnt signaling in the intestinal epithelium: from endoderm to cancer. *Genes Dev* 2005; **19**: 877-890

15 **Giles RH**, van Es JH, Clevers H. Caught up in a Wnt storm: Wnt signaling in cancer. *Biochim Biophys Acta* 2003; **1653**: 1-24

16 **Behrens J**. Control of beta-catenin signaling in tumor development. *Ann N Y Acad Sci* 2000; **910**: 21-33; discussion 33-35

17 **Behrens J**, Lustig B. The Wnt connection to tumorigenesis. *Int J Dev Biol* 2004; **48**: 477-487

18 **Orsolić N**, Saranović AB, Basić I. Direct and indirect mechanism(s) of antitumour activity of propolis and its polyphenolic compounds. *Planta Med* 2006; **72**: 20-27

19 **Burdock GA**. Review of the biological properties and toxicity of bee propolis (propolis). *Food Chem Toxicol* 1998; **36**: 347-363

20 **Orsolić N**, Knezević AH, Sver L, Terzić S, Basić I. Immunomodulatory and antimetastatic action of propolis and related polyphenolic compounds. *J Ethnopharmacol* 2004; **94**: 307-315

21 **Mahmoud NN**, Carothers AM, Grunberger D, Bilinski RT, Churchill MR, Martucci C, Newmark HL, Bertagnolli MM. Plant phenolics decrease intestinal tumors in an animal model of familial adenomatous polyposis. *Carcinogenesis* 2000; **21**: 921-927

22 **Hung MW**, Shiao MS, Tsai LC, Chang GG, Chang TC. Apoptotic effect of caffeic acid phenethyl ester and its ester and amide analogues in human cervical cancer ME180 cells. *Anticancer Res* 2003; **23**: 4773-4780

23 **Moon RT**, Bowerman B, Boutros M, Perrimon N. The promise and perils of Wnt signaling through beta-catenin. *Science* 2002; **296**: 1644-1646

24 **Bright-Thomas RM**, Hargest R. APC, beta-Catenin and hTCF-4; an unholy trinity in the genesis of colorectal cancer. *Eur J Surg Oncol* 2003; **29**: 107-117

25 **Gottardi CJ**, Wong E, Gumbiner BM. E-cadherin suppresses cellular transformation by inhibiting beta-catenin signaling in an adhesion-independent manner. *J Cell Biol* 2001; **153**: 1049-1060

26 **Shtutman M**, Zhurinsky J, Simcha I, Albanese C, D'Amico M, Pestell R, Ben-Ze'ev A. The cyclin D1 gene is a target of the beta-catenin/LEF-1 pathway. *Proc Natl Acad Sci USA* 1999; **96**: 5522-5527

27 **Karim R**, Tse G, Putti T, Scolyer R, Lee S. The significance of the Wnt pathway in the pathology of human cancers. *Pathology* 2004; **36**: 120-128

S- Editor Wang J **L- Editor** Zhu LH **E- Editor** Ma WH

PO Box 2345, Beijing 100023, China
www.wjgnet.com
wjg@wjgnet.com

World J Gastroenterol 2006 August 21; 12(31): 4986-4995
World Journal of Gastroenterology ISSN 1007-9327
© 2006 The WJG Press. All rights reserved.

VIRAL HEPATITIS

Gene expression analysis of primary normal human hepatocytes infected with human hepatitis B virus

Hyun Mi Ryu, Sung Gyoo Park, Sung Su Yea, Won Hee Jang, Young-Il Yang, Guhung Jung

Hyun Mi Ryu, Guhung Jung, School of Biological Sciences, Seoul National University, Seoul, 151-742, Korea
Sung Gyoo Park, School of Biological Sciences and Institute of Microbiology, Seoul National University, Seoul, 151-742, Korea
Sung Su Yea, Won Hee Jang, The Paik-Inje Memorial Institute for Biomedical Science, Inje University, Pusanjin-gu, Pusan 614-735, Korea
Young-Il Yang, Department of Pathology, College of Medicine, Inje University, Paik Hospital, Pusan 614-735, Korea
Supported by a grant of the Korea Health 21 R&D Project, Ministry of Health and Welfare, Republic of Korea, No. A050145
Correspondence to: Dr. Guhung Jung, Seoul National University, Seoul, 151-742, Korea. drjung@snu.ac.kr
Telephone: +82-2-8807773 Fax: +82-2-8721993
Received: 2004-10-30 Accepted: 2004-11-23

Ryu HM, Park SG, Yea SS, Jang WH, Yang YI, Jung G. Gene expression analysis of primary normal human hepatocytes infected with human hepatitis B virus. *World J Gastroenterol* 2006; 12(31): 4986-4995

http://www.wjgnet.com/1007-9327/12/4986.asp

Abstract

AIM: To find the relationship between hepatitis B virus (HBV) and hepatocytes during the initial state of infection by cDNA microarray.

METHODS: Primary normal human hepatocytes (PNHHs) were isolated and infected with HBV. From the PNHHs, RNA was isolated and inverted into complement DNA (cDNA) with Cy3- or Cy5- labeled dUTP for microarray analysis. The labeled cDNA was hybridized with microarray chip, including 4224 cDNAs. From the image of the microarray, expression profiles were produced and some of them were confirmed by RT-PCR, immunoblot analysis, and NF-κB luciferase reporter assay.

RESULTS: From the cDNA microarray, we obtained 98 differentially regulated genes. Of the 98 genes, 53 were up regulated and 45 down regulated. Interestingly, in the up regulated genes, we found the TNF signaling pathway-related genes: LT-α, TRAF2, and NIK. By using RT-PCR, we confirmed the up-regulation of these genes in HepG2, Huh7, and Chang liver cells, which were transfected with pHBV1.2×, a plasmid encoding all HBV messages. Moreover, these three genes participated in HBV-mediated NF-κB activation.

CONCLUSION: During the initial state of HBV infection, hepatocytes facilitate the activation of NF-κB through up regulation of LT-α, TRAF2, and NIK.

© 2006 The WJG Press. All rights reserved.

Key words: cDNA microarray; Primary normal human hepatocytes; LT-α; TRAF2; NIK; NF-κB

INTRODUCTION

Human hepatitis B virus (HBV) is a causative agent for liver diseases such as cirrhosis and hepatocellular carcinoma (HCC)[1]. Chronic infection of HBV affects approximately 800 million people and is the principal cause of chronic liver diseases[2]. Moreover, HBV carriers have a much higher frequency of developing liver cancer than uninfected people[3].

HBV has a small, partially double-stranded DNA genome. After viral infection of hepatocytes, the partially double-stranded DNA genome converts into covalently closed circular DNA (cccDNA) in nuclei[4-7]. Several kinds of viral transcripts are then produced by the host RNA polymerase. The transcripts encode for viral polymerase, viral oncogene HBx protein, and viral structural proteins such as surface proteins and core proteins[3].

Many efforts have been made to investigate the process of liver disease by HBV. Traditional techniques such as Northern blot and reverse transcription polymerase chain reaction (RT-PCR) for identification of genes differentially expressed by HBV infection have shown limited success, because only one gene or at best a handful of genes can be studied in one experiment. However, complementary DNA (cDNA) microarray allows the study of several thousands of genes at one time. To evaluate the relationship between HBV infection and liver diseases, recent studies have analyzed the gene expression profiles at tissue level. In these studies, the effects of HBV infection are analyzed by cDNA microarray analysis of HCC tissue samples[8-10]. Through the analyses, many differentially expressed genes can be identified[11]. The analyses, however, have mainly focused on the gene expression profiles of already transformed cells or long-term infected HBV hepatocytes. Therefore, these analyses mostly stem from the analysis of the end result of pathogenesis of HBV in hepatocytes rather than the analysis of ongoing pathogenesis of HBV infection in hepatocytes. In this report, however, we focused on the gene expression profile analysis of the early stage HBV infection, thereby excluding factors such as responses to host immune surveillance. To mimic the early

stage HBV infection of hepatocytes, we isolated primary normal human hepatocytes (PNHHs) and the cells were infected with HBV in culture. These conditions were chosen as they could represent the most similar conditions to those *in vivo*, except for the absence of other types of cells such as immunocytes. Therefore, gene expression profiles in this report could show the result of interaction only between HBV and PNHHs. In this study we have identified 45 down-regulated genes and 53 up-regulated genes.

MATERIALS AND METHODS

Construction

pHBV1.2×, a plasmid which provides all HBV transcripts, was used to infect PNHHs as previously described[12]. This construct was similar to that as described by Guidotti *et al*[13]. Mammalian expression vector for NIK and NIK DN (aa 624-947) was provided by DV Goeddel (Turarik Inc.)[14], for TRAF2 and TRAF2 DN (aa 241-501) by Dr. SY Lee[15].

HBV production and infection

We transfected HepG2 cells with pHBV1.2× constructs for generation of HBV using Fugene 6 transfection reagent (Roche) as instructed by the manufacturer. After transfection, the cells were cultured for 5 d and harvested. HBV particles in the harvested media were cleared and concentrated through ultracentrifugation using PST55Ti rotor (Hitachi) for 1 h at 220 000 g with 3 mL cushion buffer containing 20 g/L sucrose, 50 mmol/L Tris-HCl pH 7.5, and 30 mmol/L NaCl. After ultracentrifugation, the pellet was resuspended with 1 × PBS. The resuspended viral solution was filtered with a 0.2 μm pore filter (Millipore). The titer of HBV solution was adjusted to 10^9 virus genome equivalent (v.g.e.) per mL. PNHHs were infected with the above virus solution at about 100 v.g.e. per cell. Using this method, the efficiency of HBV infection to PNHHs was generally 50%[16].

Isolation and culture of PNHHs

Healthy parts of a liver from a patient who underwent hepatic resection for an intrahepatic stone at the Inje University Paik Hospital, Pusan, Korea was obtained and used as the source of hepatocytes. The removed tissue was immediately placed in Hank's balanced salt solution (HBSS) and processed for cell culture. Isolation of hepatocytes was performed using a two-step collagenase perfusion technique[17,18]. The isolated hepatocytes were resuspended in a nutrient medium containing 90 mL/L Williams' E and 10 mL/L Medium 199, supplemented with 10 μg/mL insulin, 5 μg/mL transferrin, 10^{-7} mol/L sodium selenite, and 50 mL/L FBS.

Confirmation of PNHH infection with HBV

A test was performed with the isolated DNA to determine whether the HBV- infected PNHHs formed cccDNA. Amplification with primers specific for both outside regions was performed with the isolated DNA because the region was specific for cccDNA rather than partially double-stranded DNA found in viral particles. The primers used are (5'-CTATGCTGGGTCTTCCAAATT-3') which anneals to near the codon for amino acid 80 in human HBc open reading frame (ORF) and (5'-TTTCTGTGTA-AACAATATCTG-3') which anneals to near the codon for amino acid 680 in HBV Pol ORF. Therefore, if cccDNA was present in the isolated DNA, an amplified 1 kb product could be obtained. In this test, DNA isolated from mock-infected PNHHs was used as the negative control. A PCR test was performed with RNA to confirm whether HBV transcripts were produced. Reverse transcription amplification was performed with primers specific for the epsilon regions: (5'-CAACTTTTTTTCACCTCTGCC-TA-3') which anneals to DR1 and the reverse primer (5'-GATCTCGTACTGAAAGGAAAGA-3'). In addition, to detect HBV genome, real-time PCR was also performed as previously described[12].

cDNA array analysis

RNA was isolated using TRIzol reagent (Life Technologies) according to the manufacturer's instructions. With the total isolated RNA, reverse transcription was performed with Cy5-labeled dUTP in the experimental sample and Cy3-labeled dUTP in the control. Fifty micrograms of RNA, 1.5 ng oligo dT primer, and 1 ng control RNA containing lambda DNA sequences with a poly A sequence at the 3' ends for reverse transcription, were mixed and volume of the mixture was adjusted to 20 μL. The mixture was incubated at 70℃ for 5 min. After incubation, the mixture was quickly cooled on ice. With this whole reaction mixture, the labeling reaction was performed under the following conditions: 1 × reverse transcription buffer, 0.6 mmol/L Cy3- or Cy5-dUTP, 40 U of RNase inhibitor (Roche), 50 U of AMV-RT (Roche) and a dNTP mix containing 1 mmol/L dATP, 1 mmol/L dGTP, 1 mmol/L dCTP, and 0.4 mmol/L dTTP at 42℃ for 1 h. After 1 h, 50 U of AMV-RT was added to the reaction mixture and the mixture was further incubated for 1 h for complete reverse transcription. Reverse transcription was stopped by the addition of 5 μL 0.5 mol/L EDTA. The synthesized cDNA was purified using a chromaspin column (Clonetech) as instructed by the manufacturer and precipitated with ethanol. Both Cy3- and Cy5- labeled cDNAs were resuspended with 100 μL hybridization buffer, containing 6 × standard saline citrate (SSC), 2 g/L sodium dodecyl sulfate (SDS), 5 × Denhardt solution, and 1 mg/mL salmon sperm DNA. The labeled cDNA was used for hybridization to the cDNA microarray chip at 62℃. The chip was arrayed using a GMS417 arrayer (Genetic MicroSystems Inc., Woburn, MA) with 4224 cDNAs and internal standards such as tubulin and actin and external standards such as lambda DNA. After 16-18 h of hybridization, the hybridized array was washed twice at 58℃ for 30 min with washing buffer I containing 2 × SSC and 2 g/L SDS and washed once with washing buffer Ⅱ containing 0.05 × SSC at room temperature for 5 min.

Analysis of chips

For quantification of the signals, the chips were scanned using an array scanner generation Ⅲ (Molecular Dynamics) followed by image analysis using ImaGene ver. 3.0 software (BioDiscovery Ltd., Swansea, UK). The signal intensity

of each spot was adjusted to obtain more accurate data by subtracting the background signals from the immediate surroundings. In this analysis, a difference in the ratio of more than two folds was considered significant.

Cells and transfection

HepG2, Huh7, and Chang liver cells were maintained in minimum essential media (Sigma) supplemented with 100 mL/L fetal bovine serum. For reverse transcription-polymerase chain reaction and luciferase reporter assay, cells were seeded in 12- well plates at a density of 0.2×10^6 cells per well and transfected on the following day with the aperopriate DNA and fugene 6 (Roche) as described by the manufacturer. To normalize the total DNA, pUC119 and backbone DNA of pHBV1.2× were used. The transfection efficiency for HepG2 with fugene 6 was usually 10%-20%.

RT-PCR analysis

Cells were transfected with pUC119 and pHBV1.2×. After 48 h of transfection, total RNA was extracted with TRIzol reagent (Life Technologies) as described by the manufacturer. cDNA was produced by reverse transcription using the same procedure as cDNA microarray analysis. Following reverse transcription, the synthesized cDNA was amplified with 2.5 U Hot start Taq polymerase (Takara), GAPDH specific primer set, and appropriate primer set. The sequences of the primer set are as follows: TRAF2 specific forward(5'-AGGGGACCCT-GAAAGAATAC-3'), TRAF2 specific reverse(5' -CAGGGCTTCAATCTTGTCTT-3'), NIK specific forward(5'-TACCTCCACTCACGAAGGAT-3'), NIK specific reverse(5'-CAAGGGAGGAGACTTGTTTG-3'), LT-α specific forward(5'-AGCTATCCACCCACACAGAT-3'), LT-α specific reverse(5'-GTTTATTGGGCTTCATC-GAG-3'), GAPDH specific forward(5'-ATCATCCCT-GCCTCTACTGG-3'), and GAPDH specific reverse (5' -TGGGTGTCGCTGTTGAAGTC-3'). PCR amplification was performed using Gene mp PCR system 2400 (Perkin-Elmer) with 5 min initial denaturation at 95℃ and 35 cycles of 50 s at 95℃, 50 s at 60℃, and 50 s at 72℃, followed by 7 min of extension at 72℃. To separate the PCR fragments, 15% agarose gel was used.

Immunoblot analysis

To confirm NIK and TRAF2 protein expression, we performed immunoblot analysis with anti-NIK rabbit polyclonal antibody (Santa Cruz) and anti-TRAF2 mouse monoclonal antibody (Santa Cruz). HepG2 cells were seeded in 6- well plates at a density of 0.4×10^6 cells per well. Cells were lysed with RIPA buffer containing 25 mmol/L Tris-HCl (pH 7.4), 150 mmol/L KCl, 5 mmol/L EDTA, 10 mL/L Nonidet P-40 (NP-40), 5 g/L sodium deoxycholate, and 1 g/L SDS and centrifuged at 12000 g for 10 min. The supernatants were separated by 12% SDS-PAGE protein gel for immunoblot analysis.

Luciferase reporter assay

After seeded on 12-well plates, HepG2 cells were co-transfected with appropriate DNA (Figure 5), 0.1 μg pNF-κB-luciferase and 0.1 μg pCMV-β-galactosidase. After 48 h of transfection, cell extracts were prepared and luciferase reporter assay was performed using a luciferase assay system (Promega) as described by the manufacturer. The transfection efficiency was normalized by its galactosidase activity. The assay was triplicated and repeated at least twice.

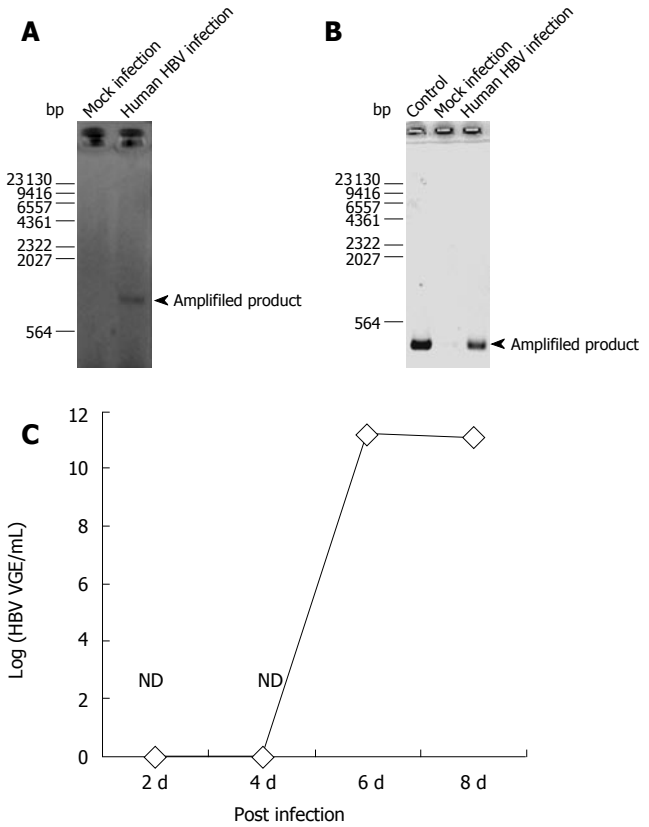

Figure 1 Confirmation of HBV infection for PNHHs using PCR for cccDNA formation and RT-PCR for production of transcripts. From PNHHs infected with HBV, RNA and DNA were extracted using TRIzol reagent as described in Materials and Methods. As a negative control, mock-infected PNHHs were used. **A**: With the extracted DNA, cccDNA was confirmed by a PCR analysis as described in Materials and Methods; **B**: With the extracted RNA, a transcript of HBV was confirmed by RT-PCR analysis as described in Materials and Methods; **C**: With the extracted RNA, a tanscript of HBV was confirmed by real-time PCR as previously described[19].

RESULTS

Confirmation of PNHH infection with HBV

To confirm HBV infection to PNHHs, DNA was isolated during the RNA purification step with TRIzol reagent as instructed by the manufacturer. Infection was confirmed through PCR-based amplification specific only for cccDNA in nuclei of the infected cells. Figure 1 shows that the amplified product appeared in HBV- infected cells, indicating that HBV did infect PNHHs and that the nucleocapsid was transported into nuclei of the infected hepatocytes (Figure 1A). RT-PCR analysis of the HBV transcripts amplified with primers specific for epsilon and polymerase regions as described in Materials and Methods confirmed the presence of HBV RNA transcripts in the infected cells (Figure 1B). Real time PCR showed that HBV was not detected until 6 d after infection (Figure 1C).

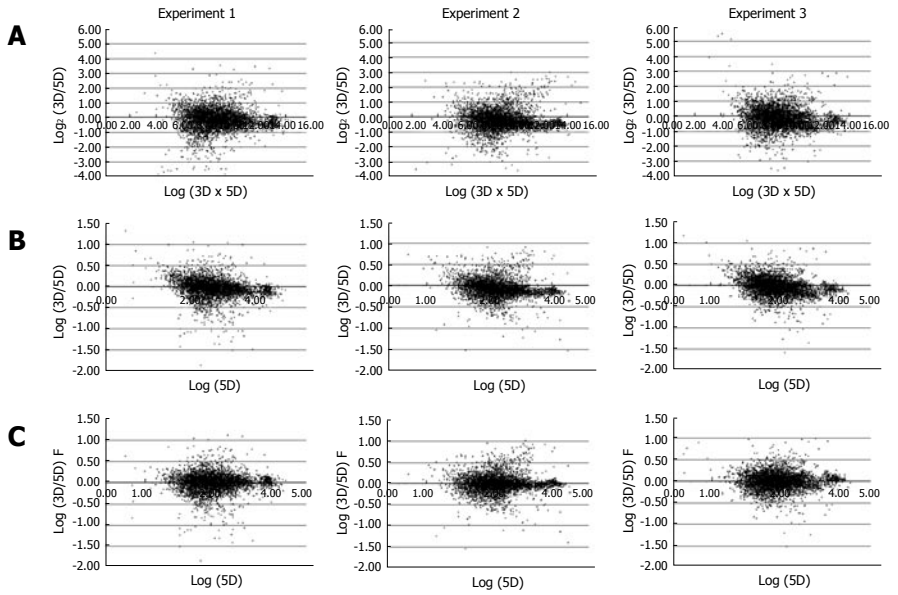

Figure 2 Scatter plot analysis. For normalization of the Cy3 (3D) and Cy5 channel signal (5D) channels, data obtained from the raw image scanning were plotted in a scatter plot using Excel software (Microsoft). **A**: The X-axis represents Log_2 (3D/5D) and the Y-axis Log_2 (3D/5D); **B**: The X-axis represents Log (5D) and the Y-axis Log (3D/5D); **C**: The X-axis represents Log (5D) and the Y-axis Log (3D/5D) F, in which "F" is the function for normalization. The bottom panel shows data with signals fitted to an exponential decay curve.

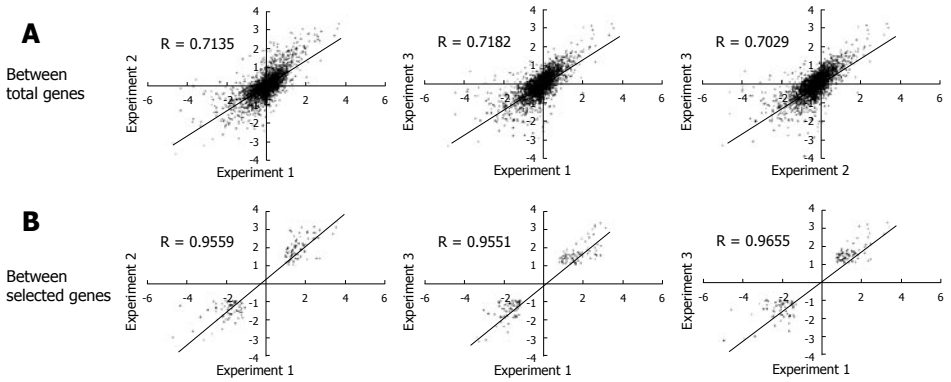

Figure 3 Correlation between three sets of PNHHs infected for eight days. **A**: With the reliable signals in obtained signals, the correlation efficient was calculated between each experiment; **B**: In addition, another correlation efficient was also calculated with only the selected genes, which were differentially expressed more than 2 folds.

Raw data analysis

The experiments were carried out in triplicate at the infection step for more certain identification of genes differentially expressed by HBV infection. From each of the HBV infected cells for over 8 d, RNA was isolated and analyzed by microarray. As a result, three sets of cDNA array images were obtained. We analyzed the intensity of the raw image through scatterplot analyses. Figure 2A shows scatterplot analyses of log (Cy3 signal × Cy5 signal) *vs* log2 (Cy3 signal/Cy5 signal). This showed that each plot tended to divert from the general small curve (Figure 2A). But, each scatterplot analysis of Log (Cy3 signal/Cy5 signal) *vs* Log (Cy5 signal) showed a curve closer to the exponential decay (Figure 2B). Therefore, the data were fitted to an exponential decay curve for Cy3 per Cy5 channel correction (Figure 2C). Through these steps, we obtained a higher confidence ratio of the Cy3 signal compared to the Cy5 signal for each chip. With the ratios obtained, we analyzed the correlation coefficient between the data of the three chips. The correlation coefficient turned out to be more than 0.7 (Figure 3A), suggesting that the relationship between each chip was significant. The correlation coefficient for genes that were differentially expressed more than two folds was more than 0.95 (Figure 3B). Selected genes that were differentially expressed more than two folds, showed a high reproducibility among the triplicate microarray analyses.

Analysis of differentially regulated genes

Through a microarray analysis of PNHHs infected with HBV, we obtained the profile of 45 genes that were down regulated more than two folds compared to the control. The 45 down-regulated genes were analyzed classified by function (Table 1). Table 1 shows that many transcription factors related to RNA polymerase II, were down-regulated by HBV infection. In contrast, transcription factors such as C/EBP, which is used for transcription of HBV genes[19,20], were not differentially expressed. That is, the C/EBP expression level was changed less than two folds.

From the analysis by cDNA microarray, 53 up-regulated genes were identified by an increase of more than two folds in their differential expression. Table 2 shows that growth- and tumor-related molecules comprised a proportion of the up-regulated genes. The positive effector genes for tumor and proliferation have found to be GDF11[21] and NOL1[22] and the negative effector genes EXTL3[23] and RAD50. The most interesting genes have found to be the TNF signaling pathway- related genes. LT-α is an inflammatory cytokine and induces the TNF signaling pathway as a ligand for TNF receptor (TNFR). LT-α binds to TNFR and recruits TRAF2. MAP3K14 (NF-κB inducing kinase, NIK) binds to TRAF2 and activates NF-κB[24].

Table 1 Forty-five differentially down-regulated genes obtained and categorized by their function

Categoty	UniGene	Gene name	Symbol	Locus	Function	Control/ HBV infection	*P*-value
Transcription/ RNA Pol Ⅱ	Hs.442675	Thyroid hormone receptor interactor 8	TRIP8	10	Transcription co-activator of Pol Ⅱ promoter	3.469	0.030
Transcription	Hs.57475	Sex comb on midleg homolog 1	SCMH1	1p34	Pol Ⅱ transcription	3.315	0.019
Transcription	Hs.119014	Zinc finger protein 175	ZNF175	19q13.4	C2H2 zinc-finger protein 175	2.942	0.017
Transcription/ RNA Pol Ⅱ	Hs.437905	Spi-B transcription factor (Spi-1/PU.1 related)	SPIB	19q13.3-q13.4	RNA polymerase Ⅱ transcription factor	2.743	0.017
Transcription/ RNA Pol Ⅱ	Hs.148427	LIM homeobox protein 3	LHX3	9q34.3	RNA Pol 2 transcription factor and activate pituitary hormone genes	2.492	0.006
Signal	Hs.17154	Dual-specificity tyrosine-(Y)-phosphorylation regulated kinase 4	DYRK4	12p13.32	Dual-specificity protein kinase 4	3.938	0.005
Signal	Hs.262886	Inositol polyphosphate-5-phosphatase, 145kD	INPP5D	2q36-q37	Modulating cytokine signaling within the hemopoietic system	3.587	0.009
Signal	Hs.75249	ADP-ribosylation factor-like 6 interacting protein	ARL6IP	16p12-p11.2	Activator of phospholipase D (PLD)	2.801	0.010
Tumor/Suppress	Hs.77793	c-src tyrosine kinase	CSK	15q23-q25	Downregulate the tyrosine kinase activity of the c-src oncoprotein	3.377	0.021
Tumor/Induce	Hs.89839	EphA1	EPHA1	7q34	Overexpression of EPH mRNA was found in a hepatoma	3.039	0.022
Tumor/Induce	Hs.79070	V-myc avian myelocytomatosis viral oncogene homolog	MYC	8q24.12-q24.13	Promotes cell proliferation and transformation	2.357	0.011
Immune response	Hs.118354	Human MHC Class I region proline rich protein mRNA	CAT56	6p21.32	Immune response	2.588	0.024
Miscellaneous	Hs.180610	Splicing factor proline/ glutamine rich	SFPQ	1p34.3	Pre-mRNA splicing factor required for pre-mRNA splicing	10.471	0.006
Miscellaneous/ Cytoskeleton	Hs.75064	Tubulin-specific chaperone c	TBCC	6pter-p12.1	Cofactor in the folding pathway of beta-tubulin	10.2	0.020
Miscellaneous	Hs.438683	BCM-like membrane protein precursor	SBB142	1q23.1	BCM-like membrane protein precursor	3.751	0.004
Miscellaneous	Hs.8203	Endomembrane protein emp70 precursor isolog	LOC56889	10q24.2	Low similarity to human endosomal protein P76	3.502	0.038
Miscellaneous	Hs.311609	Nuclear RNA helicase, DECD variant of DEAD box family	DDXL	19p13.13	Member of the DEAD/H box ATP-dependent RNA helicase family	2.868	0.026
Miscellaneous/ Energy	Hs.150922	BCS1 (yeast homolog)-like	BCS1L	2q33	Function in the assembly of complex III of the respiratory chain	2.682	0.007
Miscellaneous	Hs.6679	hHDC for homolog of Drosophila headcase	LOC51696	6q23-q24	hHDC for homolog of Drosophila headcase	2.611	0.020
Miscellaneous	Hs.5300	Bladder cancer associated protein	BLCAP	20q11.2-q12	Appears to be down-regulated during bladder cancer progression	2.459	0.028
Miscellaneous	Hs.179526	Upregulated by 1, 25-dihydroxyvitamin D-3	VDUP1	1q21.2	Upregulated by 1, 25-dihydroxyvitamin D-3	2.394	0.043
Miscellaneous	Hs.440961	Calpastatin	CAST	5q15-q21	Inhibitor of the cysteine (thiol) protease calpain	2.276	0.000
Miscellaneous	Hs.275775	Selenoprotein P, plasma, 1	SEPP1	5q31	An oxidant defense in the extracellular space	2.186	0.007
EST	Hs.371233	ESTs		Xp22.3	Moderately similar to T08795 hypothetical protein DKFZp586J1822.1	7.826	0.025
EST	Hs.229338	ESTs		X		4.687	0.007
EST	Hs.212957	ESTs		3q26.1	Moderately similar to ZN91_HUMAN ZINC FINGER PROTEIN 91	4.611	0.019
EST	Hs.211823	ESTs		2q37.1		4.519	0.030
EST	Hs.57836	ESTs		17		3.323	0.029
EST	Hs.87912	ESTs		14q24.1		3.314	0.013
EST	Hs.12429	ESTs	FLJ22479	4q26-q27	Hypothetical protein FLJ22479	3.217	0.041
EST	Hs.213586	ESTs		7		2.759	0.044
EST	Hs.2755711	ESTs		22	Weakly similar to T20379 hypothetical protein	2.723	0.019
EST	Hs.191435	ESTs		8p23.1-p22	Weakly similar to S65657 alpha-1C-adrenergic receptor splice form 2	2.638	0.023
EST	Hs.31293	ESTs		9p13.1		2.286	0.035
Predicted protein	Hs.414464	Hypothetical protein	HSD3.1	14q31.3		7.314	0.008

Predicted protein	Hs.100914	Hypothetical protein FLJ10352	FLJ10352	18p11.21		6.239	0.006
Predicted protein	Hs.181112	HSPC126 protein	HSPC126	13q14.12		3.322	0.045
Predicted protein	Hs.306711	KIAA1081 protein	ELKS	12p13.3		3.122	0.036
Predicted protein	Hs.101891	KIAA1193 protein	KIAA1193	19p13.3	Weakly similar to RPB1_HUMAN DNA-directed RNA Pol II largest subunit	3.029	0.030
Predicted protein	Hs.272759	KIAA1457 protein	KIAA1457	12q24.31		2.98	0.020
Predicted protein	Hs.172089	Homo sapiens mRNA; cDNA DKFZp586I2022		11q22.1		2.784	0.036
Predicted protein	Hs.7049	Hypothetical protein FLJ11305	FLJ11305	13q34		2.65	0.028
Predicted protein	Hs.445255	KIAA0368 protein	KIAA0368	9q32		2.423	0.016
Predicted protein	Hs.192190	KIAA0782 protein	KIAA0782	11q13.3		2.332	0.009
Predicted protein	Hs.169910	KIAA0173 gene product	KIAA0173	2p24.3-p24.1	Similar to S72482 hypothetical protein	2.171	0.014

Table 2 Fifty-three differentially up-regulated genes obtained and categorized by their function

Categoty	UniGene	Gene name	Symbol	Locus	Function	Control/HBV infection	*P*-value
Signal	Hs.82887	Protein phosphatase 1, regulatory (inhibitor) subunit 11	PPP1R11	6p21.3	Soluble protein phosphatase inhibitor(reppresor)	3.623	0.026
Signal	Hs.437575	TNF receptor-associated factor 2	TRAF2	9q34	Required for activation of NFkappaB	3.23	0.026
Signal	Hs.6527	G protein-coupled receptor 56	GPR56	16q13	Member of the G protein-coupled receptor family	2.817	0.009
Signal	Hs.29203	Homo sapiens G protein beta subunit mRNA, partial cds	GBL	16p13.3	G protein-linked receptor protein for signalling pathway	2.76	0.009
Signal/ Cytoskeleton	Hs.2157	Wiskott-Aldrich syndrome	WAS	Xp11.4-p11.21	Involved in transduction of signals from receptors on the cell surface to the actin cytoskeleton	2.446	0.018
Signal	Hs.440315	Mitogen-activated protein kinase kinase kinase 14	MAP3K14	17q21	Binds to TRAF2 and stimulates NF-kappaB activity	2.185	0.043
Tumor/ Induce	Hs.15243	Nucleolar protein 1 (120kD)	NOL1	12p13.3	Transforms NIH3T3 cells when overexpressed	5.273	0.004
Tumor/ Supress	Hs.9018	Exostoses (multiple)-like 3	EXTL3	8p21	Tumor suppressor, glycosyltransferase activity	5.07	0.093
Tumor/ Supress	Hs.41587	RAD50 (S. cerevisiae) homolog	RAD50	5q31	Associates with MRE11, nibrin (NBS1) and the tumor suppressor BRAC1	2.443	0.013
Growth/ Positive	Hs.511740	Growth differentiation factor 11	GDF11	12q13.13	Regulators of cell growth and differentiation in both embryonic and adult tissues	2.969	0.023
Cell cycle/ Negative	Hs.76364	Allograft inflammatory factor 1	AIF1	6p21.3	Involved in negative regulation of growth of vascular smooth muscle cells	3.573	0.031
Cell cycle/ Positive	Hs.25313	Microspherule protein 1	MCRS1	12q13.12	Involved in cell-cycle-dependent stabilization of ICP22 in HSV1-infected cells	3.273	0.044
Cell cycle/ Positive	Hs.371833	Nuclear receptor binding factor-2	NRBF-2	10	A possible gene activator protein interacting with nuclear hormone receptors	2.568	0.018
Cell cycle/ Positive	Hs.440606	Centrosomal protein 2	CEP2	20q11.22-q12	Regulate centriole-centriole cohesion during the cell cycle	2.422	0.022
Enzyme/ Glycosylation	Hs.4814	Mannosidase, alpha, class 1B, member 1	MAN1B1	9q34	N-linked glycosylation	3.097	0.008
Enzyme/ lysophospholipase	Hs.889	Charot-Leyden crystal protein	CLC	19q13.1	Phospholipid metabolism and anti-pathogen	3.065	0.035
Enzyme/Protease	Hs.75890	Site-1 protease	MBTPS1	16q24	A sterol-regulated subtilisin-like serine protease	2.873	0.023
Immune response	Hs.2014	T cell receptor delta locus	TRD@	14q11.2	T-cell antigen receptor, delta polypeptide	3.69	0.023
Immune response	Hs.465511	Granzyme M	GZMM	19p13.3	Serine protease for anti-pathogen response	3.201	0.023

Transcription	Hs.436871	Zinc finger protein 173	ZNF173	6p21.3	DNA/protein binding, transcriptional protein	3.411	0.002
Transcription	Hs.108139	Zinc finger protein 212	ZNF212	7q36.1	DNA/protein binding, transcriptional protein	2.341	0.045
Apoptosis	Hs.36	Lymphotoxin alpha	LTA	6p21.3	A member of the tumor necrosis factor family	14.912	0.019
Miscellaneous	Hs.434384	Titin	TTN	2q31	Large myofilament protein	4.087	0.012
Miscellaneous	Hs.58927	Nuclear VCP-like	NVL	1q41-q42.2	Member of the AAA family of ATPases	4.005	0.035
Miscellaneous	Hs.122552	G-2 and S-phase expressed 1	GTSE1	22q13.2-q13.3	Accumulates in late S/G2 phase, is phosphorylated in mitosis, and disappears in G1 phase	3.491	0.007
Miscellaneous/ Glycosylation	Hs.82921	Solute carrier family 35 (CMP-sialic acid transporter), member 1	SLC35A1	6q15	Important for normal sialylation of glycoproteins and glycolipids	3.352	0.013
Miscellaneous	Hs.410455	Unc119 (C.elegans) homolog	UNC119	17q11.2	May function in photoreceptor neurotransmission	3.328	0.030
Miscellaneous	Hs.55041	CGI-22 protein	MRPL2	6p21.3	Unknown	3.052	0.01
Miscellaneous/ Cytoskeleton	Hs.74088	Bridging integrator-3	BIN3	8q21.2	Related to actin assembly-competent state	2.677	0.018
Miscellaneous	Hs.25237	Mesenchymal stem cell protein DSCD75	LOC51337	8q24.3	Moderately similar to uncharacterized Drosophila CG4666	2.615	0.042
EST	Hs.95867	Homo sapiens EST00098 gene, last exon	EST00098	9q34.1		8.781	0.027
EST	Hs.98785	ESTs	KSP37	4p16		3.749	0.011
EST	Hs.136912	ESTs	MGC10796	3q13.13		3.435	0.003
EST	Hs.101774	ESTs	FLJ23045	20p11.23		3.387	0.032
EST	Hs.420262	ESTs		13		3.355	0.022
EST	Hs.124840	ESTs		11q13.1		3.114	0.021
EST	Hs.272299	ESTs	RP4-622L5	1p36.11-p34.2		3.008	0.034
EST	Hs.415048	ESTs		5		2.891	0.025
EST	Hs.531268	ESTs		16		2.889	0.013
EST	Hs.273830	ESTs	FLJ12742	1		2.739	0.020
EST	Hs.190162	ESTs		1p32.3		2.708	0.021
EST	Hs.303172	ESTs		18		2.578	0.04
EST	Hs.59203	ESTs		7		2.437	0.022
EST	Hs.231444	ESTs		1		2.343	0.005
Unknown sequence	Hs.284265	Homo sapiens pRGR1 mRNA, partial cds		6q27		2.966	0.043
Unknown sequence	Hs.291385	Homo sapiens clone 23664 and 23905 mRNA sequence		4p14-p12		2.439	0.041
Predicted protein	Hs.31718	Homo sapiens cDNA FLJ11034 fis, clone PLACE1004258	VRL			17.359	0.000
Predicted protein	Hs.61960	Hypothetical protein	FLJ20040	16p13.3		9.166	0.002
Predicted protein	Hs.274552	Homo sapiens cDNA FLJ10720 fis, clone NT2RP3001116	FLJ10720	5		4.751	0.015
Predicted protein	Hs.279761	HSPC134 protein	HSPC134	14q11.2		3.501	0.038
Predicted protein	Hs.283716	Hypothetical protein PRO1584	PRO1584	8p21.2		3.493	0.033
Predicted protein	Hs.464526	Homo sapiens clone 23649 and 23755 unknown mRNA, partial cds		18q11.2		3.198	0.032
Predicted protein	Hs.274412	Homo sapiens cDNA FLJ10207 fis, clone HEMBA1005475	UPF3A	17p11.2		3.076	0.012

LT-α, TRAF2, and NIK were also up-regulated in the experiment (Table 2). This means that HBV activates NF-κB through up-regulation of LT-α, TRAF2, and NIK.

RT-PCR analysis and immunoblot assay of selected genes

According to the cDNA microarray data, three genes related to the TNF signaling pathway, LT-α, TRAF2, and NIK, were up-regulated. Upregulation of these genes was confirmed by RT-PCR. For RT-PCR analysis, primer sets specific to LT-α, TRAF2, and NIK, were used and experiments were performed in hepatoma-derived cell lines, including HepG2, Huh7, and Chang liver cells. As a result, the mRNA levels of these three genes in each cell line were increased by pHBV1.2× transfection (Figure 4). In addition to RT-PCR, the expression of NIK and TRAF2 was confirmed at the protein level (Figure 5). The expression of LT-α, was confirmed by immunofluorescence staining analysis (data not shown).

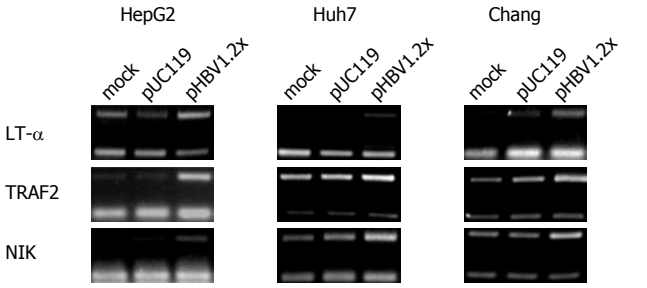

Figure 4 RT-PCR analysis of selected genes. Mock means untransfected cells. pUC119 is backbone of pHBV1.2x, so pUC119 transfected cells are the negative control for pHBV1.2x transfected cell. In the hepatoma-derived cell lines, HepG2, Huh7, and Chang liver cells, TRAF2, NIK, and LT-α mRNA level in pHBV1.2x transfected cells were up-regulated rather than mock and pUC119 transfected cells.

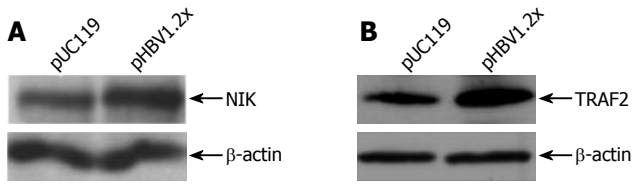

Figure 5 Immunoblot assay of TRAF2 and NIK. pUC119 is a backbone DNA about pHBV1.2x. In the HepG2 cells transfected with pHBV1.2x, the protein levels of NIK (**A**) and TRAF2 (**B**) were increased. β-actin was used to normalize total protein level.

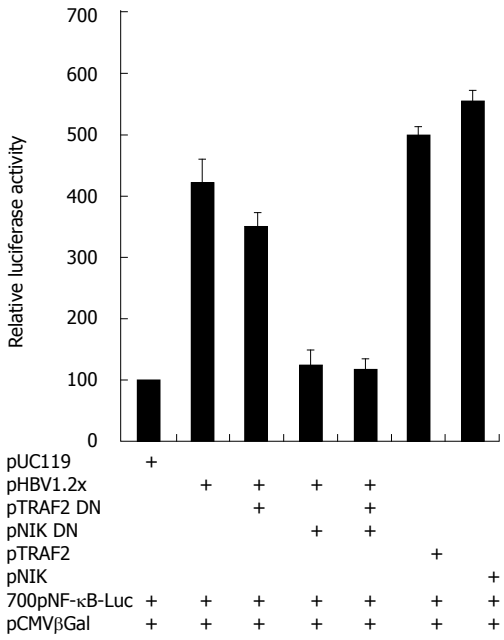

Figure 6 HBV-mediated NF-κB activation through TRAF2 and NIK. In pHBV1.2x transfected HepG2 cells, NF-κB activity was increased more than pUC119 transfected cells. But in cotransfected cells with pHBV1.2x and TRAF2 DN or NIK DN, NF-κB activity was decreased less than pHBV1.2x transfected cells.

NF-κB activation through TRAF2, NIK mRNA up regulation

According to cDNA microarray and RT-PCR analysis, mRNA expression of LT-α, TRAF2, and NIK was up-regulated by HBV. Since their expression was related to NF-κB activation. HBV-mediated NF-κB activation might be involved in the up regulation of these genes. To determine whether these genes actually are involved in HBV-mediated NF-κB activation, we performed a luciferase assay with a pNF-κB-luciferase vector as a reporter plasmid. To elucidate whether HBV-mediated NF-κB activation is dependent on TRAF2 and NIK of three genes, we cotransfected pTRAF2 DN or pNIK DN, the dominant negative form of pTRAF2 or pNIK, with pNF-κB-luciferase, pCMV β-galactosidase, and pHBV1.2× (Figure 6). The experiment for LT-α was performed with anti- LT-α, to neutralize LT-α. The pHBV1.2× produced about a 4.2 folds greater increase in NF-κB luciferase activity than pUC119. However, pHBV1.2× cotransfection with TRAF2 DN or NIK DN produced about a 3.5 or 1.2 fold relative increase (Figure 6) and treatment with anti- LT-α decreased the ratio to less than 4.2 folds (data not shown). These findings led us to think that HBV could activate NF-κB and that this HBV-mediated NF-κB activation might require LT-α, TRAF2, and NIK. DC.

DISCUSSION

In this report, we focused on the interaction between HBV and hepatocytes during the initial stage of infection. To mimic hepatocyte infection with HBV under *in vivo* conditions, we isolated PNHHs and infected them with HBV. We chose this method because cultured cell lines such as HepG2 are seldom infected with HBV[25,26], and transformed cultured cells have many physiological properties that are altered in the original state of hepatocytes[27,28]. In this experiment, the same hepatocytes were used as a control. Since they are produced under identical conditions, a pair of samples of the same genetic background could be obtained. With these samples, we were able to analyze differentially expressed genes. As a result, we obtained gene expression profiles and 98 consistently differentially expressed genes were identified by gene expression profiles. Of these genes, 53 were up-regulated and 45 down-regulated. It was reported that there are no genes uniformly correlated with HBV DNA profile during the initial host response to HBV infection[29]. However, because this study was performed on chimpanzees, there are some considerations in making a comparision between this study with our report. Our report analyzed the effect of HBV on PNHHs at cellular level without any other cell types, including immunocytes. So the influence of immunocytes was not included in this analysis. In addition, the difference in human beings and chimpanzees needs to be taken into consideration.

The results of our study showed that a proportion of the down-regulated genes was transcription factor-related genes and a proportion of the up-regulated genes was TNF signaling pathway-related genes. Down regulation of transcription factors may be helpful for the transcription of the HBV gene because the transcripts of the host cell can be repressed and the transcriptional machinery can be efficiently used for viral transcription. C/EBP, which is involved in viral genome transcription[19,20], had no substantial differential expression in this experiment. In addition to down regulation of transcription factor for virus transcription, up regulation of cell proliferation-related genes may help viral replication. Of the up-regulated genes,

LT-α, TRAF2, and NIK may induce cell proliferation *via* NF-κB activation.

In fact, LT-α is mainly related to the signal cascade for apoptosis and generally involves the host defense system[30]. However LT-α is also related to cell proliferation. Usually, TNF signaling including LT-α, can induce apoptosis and proliferation[31]. TNF signaling by LT-α has a signal cascade from TNFR to TRADD. In the case of apoptosis, TRADD-FADD interaction is needed to activate caspase 8[31]. In the case of proliferation, TRADD-TRAF2 interaction induces activation of NF-κB, a proliferation-inducing transcription factor[31]. After TRAF2 binds to TRADD, NIK binds to TRAF2 and activates NF-κB through IKK activation and IκB-α degradation[24,32-34]. In cDNA microarray data, among genes related to the two opposite effects initiated by LT-α, proliferation-related genes are upregulated. FADD is not differentially altered by more than two folds. Therefore, HBV infection may strengthen the TNF signaling pathway to cell proliferation through the induction of gene expression.

In conclusion, HBV induces NF-κB activation by upregulating LT-α, TRAF2, and NIK, and cell proliferation by activating NF-κB.

ACKNOWLEDGMENTS

The authors thank Dr. SY Lee for providing pTRAF2 and pTRAF2 DN vector.

REFERENCES

1 **Beasley RP**, Hwang LY, Lin CC, Chien CS. Hepatocellular carcinoma and hepatitis B virus. A prospective study of 22 707 men in Taiwan. *Lancet* 1981; **2**: 1129-1133

2 **Hoofnagle JH**, di Bisceglie AM. The treatment of chronic viral hepatitis. *N Engl J Med* 1997; **336**: 347-356

3 **Ganem D**, Varmus HE. The molecular biology of the hepatitis B viruses. *Annu Rev Biochem* 1987; **56**: 651-693

4 **Kann M**, Sodeik B, Vlachou A, Gerlich WH, Helenius A. Phosphorylation-dependent binding of hepatitis B virus core particles to the nuclear pore complex. *J Cell Biol* 1999; **145**: 45-55

5 **Mason WS**, Halpern MS, England JM, Seal G, Egan J, Coates L, Aldrich C, Summers J. Experimental transmission of duck hepatitis B virus. *Virology* 1983; **131**: 375-384

6 **Nassal M**, Schaller H. Hepatitis B virus replication. *Trends Microbiol* 1993; **1**: 221-228

7 **Tagawa M**, Omata M, Okuda K. Appearance of viral RNA transcripts in the early stage of duck hepatitis B virus infection. *Virology* 1986; **152**: 477-482

8 **Honda M**, Kaneko S, Kawai H, Shirota Y, Kobayashi K. Differential gene expression between chronic hepatitis B and C hepatic lesion. *Gastroenterology* 2001; **120**: 955-966

9 **Delpuech O**, Trabut JB, Carnot F, Feuillard J, Brechot C, Kremsdorf D. Identification, using cDNA macroarray analysis, of distinct gene expression profiles associated with pathological and virological features of hepatocellular carcinoma. *Oncogene* 2002; **21**: 2926-2937

10 **Iizuka N**, Oka M, Yamada-Okabe H, Mori N, Tamesa T, Okada T, Takemoto N, Hashimoto K, Tangoku A, Hamada K, Nakayama H, Miyamoto T, Uchimura S, Hamamoto Y. Differential gene expression in distinct virologic types of hepatocellular carcinoma: association with liver cirrhosis. *Oncogene* 2003; **22**: 3007-3014

11 **Song H**, Xia SL, Liao C, Li YL, Wang YF, Li TP, Zhao MJ. Genes encoding Pir51, Beclin 1, RbAp48 and aldolase b are up or down-regulated in human primary hepatocellular carcinoma. *World J Gastroenterol* 2004; **10**: 509-513

12 **Park SG**, Lee SM, Jung G. Antisense oligodeoxynucleotides targeted against molecular chaperonin Hsp60 block human hepatitis B virus replication. *J Biol Chem* 2003; **278**: 39851-39857

13 **Guidotti LG**, Matzke B, Schaller H, Chisari FV. High-level hepatitis B virus replication in transgenic mice. *J Virol* 1995; **69**: 6158-6169

14 **Song HY**, Régnier CH, Kirschning CJ, Goeddel DV, Rothe M. Tumor necrosis factor (TNF)-mediated kinase cascades: bifurcation of nuclear factor-kappaB and c-jun N-terminal kinase (JNK/SAPK) pathways at TNF receptor-associated factor 2. *Proc Natl Acad Sci USA* 1997; **94**: 9792-9796

15 **Chung YM**, Park KJ, Choi SY, Hwang SB, Lee SY. Hepatitis C virus core protein potentiates TNF-alpha-induced NF-kappaB activation through TRAF2-IKKbeta-dependent pathway. *Biochem Biophys Res Commun* 2001; **284**: 15-19

16 **Schulze-Bergkamen H**, Untergasser A, Dax A, Vogel H, Büchler P, Klar E, Lehnert T, Friess H, Büchler MW, Kirschfink M, Stremmel W, Krammer PH, Müller M, Protzer U. Primary human hepatocytes--a valuable tool for investigation of apoptosis and hepatitis B virus infection. *J Hepatol* 2003; **38**: 736-744

17 **Baccarani U**, Sanna A, Cariani A, Sainz-Barriga M, Adani GL, Zambito AM, Piccolo G, Risaliti A, Nanni-Costa A, Ridolfi L, Scalamogna M, Bresadola F, Donini A. Isolation of human hepatocytes from livers rejected for liver transplantation on a national basis: results of a 2-year experience. *Liver Transpl* 2003; **9**: 506-512

18 **Guguen-Guillouzo C**, Campion JP, Brissot P, Glaise D, Launois B, Bourel M, Guillouzo A. High yield preparation of isolated human adult hepatocytes by enzymatic perfusion of the liver. *Cell Biol Int Rep* 1982; **6**: 625-628

19 **Choi BH**, Park GT, Rho HM. Interaction of hepatitis B viral X protein and CCAAT/ enhancer-binding protein alpha synergistically activates the hepatitis B viral enhancer II/ pregenomic promoter. *J Biol Chem* 1999; **274**: 2858-2865

20 **Ott M**, Thyagarajan SP, Gupta S. Phyllanthus amarus suppresses hepatitis B virus by interrupting interactions between HBV enhancer I and cellular transcription factors. *Eur J Clin Invest* 1997; **27**: 908-915

21 **Nakashima M**, Toyono T, Akamine A, Joyner A. Expression of growth/differentiation factor 11, a new member of the BMP/ TGFbeta superfamily during mouse embryogenesis. *Mech Dev* 1999; **80**: 185-189

22 **Fonagy A**, Swiderski C, Wilson A, Bolton W, Kenyon N, Freeman JW. Cell cycle regulated expression of nucleolar antigen P120 in normal and transformed human fibroblasts. *J Cell Physiol* 1993; **154**: 16-27

23 **Van Hul W**, Wuyts W, Hendrickx J, Speleman F, Wauters J, De Boulle K, Van Roy N, Bossuyt P, Willems PJ. Identification of a third EXT-like gene (EXTL3) belonging to the EXT gene family. *Genomics* 1998; **47**: 230-237

24 **Wang Q**, Dziarski R, Kirschning CJ, Muzio M, Gupta D. Micrococci and peptidoglycan activate TLR2-->MyD88-->IRAK-->TRAF-->NIK-->IKK-->NF-kappaB signal transduction pathway that induces transcription of interleukin-8. *Infect Immun* 2001; **69**: 2270-2276

25 **Galle PR**, Hagelstein J, Kommerell B, Volkmann M, Schranz P, Zentgraf H. In vitro experimental infection of primary human hepatocytes with hepatitis B virus. *Gastroenterology* 1994; **106**: 664-673

26 **Gripon P**, Diot C, Thézé N, Fourel I, Loreal O, Brechot C, Guguen-Guillouzo C. Hepatitis B virus infection of adult human hepatocytes cultured in the presence of dimethyl sulfoxide. *J Virol* 1988; **62**: 4136-4143

27 **Otsuka M**, Aizaki H, Kato N, Suzuki T, Miyamura T, Omata M, Seki N. Differential cellular gene expression induced by hepatitis B and C viruses. *Biochem Biophys Res Commun* 2003; **300**: 443-447

28 **Okabe H**, Satoh S, Kato T, Kitahara O, Yanagawa R, Yamaoka Y, Tsunoda T, Furukawa Y, Nakamura Y. Genome-wide analysis of gene expression in human hepatocellular carcinomas using cDNA microarray: identification of genes involved in viral carcinogenesis and tumor progression. *Cancer*

Res 2001; **61**: 2129-2137
29 **Wieland S**, Thimme R, Purcell RH, Chisari FV. Genomic analysis of the host response to hepatitis B virus infection. *Proc Natl Acad Sci USA* 2004; **101**: 6669-6674
30 **VanArsdale TL**, VanArsdale SL, Force WR, Walter BN, Mosialos G, Kieff E, Reed JC, Ware CF. Lymphotoxin-beta receptor signaling complex: role of tumor necrosis factor receptor-associated factor 3 recruitment in cell death and activation of nuclear factor kappaB. *Proc Natl Acad Sci USA* 1997; **94**: 2460-2465
31 **Hsu H**, Shu HB, Pan MG, Goeddel DV. TRADD-TRAF2 and TRADD-FADD interactions define two distinct TNF receptor 1 signal transduction pathways. *Cell* 1996; **84**: 299-308
32 **Malinin NL**, Boldin MP, Kovalenko AV, Wallach D. MAP3K-related kinase involved in NF-kappaB induction by TNF, CD95 and IL-1. *Nature* 1997; **385**: 540-544
33 **Wajant H**, Scheurich P. Tumor necrosis factor receptor-associated factor (TRAF) 2 and its role in TNF signaling. *Int J Biochem Cell Biol* 2001; **33**: 19-32
34 **Tada K**, Okazaki T, Sakon S, Kobarai T, Kurosawa K, Yamaoka S, Hashimoto H, Mak TW, Yagita H, Okumura K, Yeh WC, Nakano H. Critical roles of TRAF2 and TRAF5 in tumor necrosis factor-induced NF-kappa B activation and protection from cell death. *J Biol Chem* 2001; **276**: 36530-36534

S- Editor Wang J **L- Editor** Wang XL **E- Editor** Ma WH

PO Box 2345, Beijing 100023, China
www.wjgnet.com
wjg@wjgnet.com

World J Gastroenterol 2006 August 21; 12(31): 4996-5004
World Journal of Gastroenterology ISSN 1007-9327
© 2006 The WJG Press. All rights reserved.

BASIC RESEARCH

Caffeic acid phenethyl ester modifies the Th1/Th2 balance in ileal mucosa after γ-irradiation in the rat by modulating the cytokine pattern

Olivier Grémy, Marc Benderitter, Christine Linard

Olivier Grémy, Marc Benderitter, Christine Linard, Institute for Radioprotection and Nuclear Safety, IRSN, BP n°17, F-92262 Fontenay-aux-Roses Cedex, France
Supported by Electricité de France
Correspondence to: Christine Linard, Institut de Radioprotection et de Sûreté Nucléaire, Direction de la RadioProtection de l' Homme, SRBE, BP n°17, F-92262 Fontenay-aux-Roses Cedex, France. christine.linard@irsn.fr
Telephone: +33-1-58359186
Received: 2006-02-21 Accepted: 2006-03-13

Key words: Intestinal inflammation; T cells; Irradiation; Apoptosis

Grémy O, Benderitter M, Linard C. Caffeic acid phenethyl ester modifies the Th1/Th2 balance in ileal mucosa after γ-irradiation in the rat by modulating the cytokine pattern. *World J Gastroenterol* 2006; 12(31): 4996-5004

http://www.wjgnet.com/1007-9327/12/4996.asp

Abstract

AIM: To pharmacologically modulate Th polarization in the ileum exposed to ionizing radiation by using the immuno-modulatory/apoptotic properties of Caffeic Acid Phenethyl Ester (CAPE).

METHODS: Rats received CAPE (30 mg/kg) treatment ip 15 min prior to intestinal 10 Gy γ-irradiation and once a day for a 6 d period after irradiation. Expression of genes implicated in Th differentiation in ileal mucosa (IL-23/IL-12Rβ2), Th cytokine responses (IFN-γ, IL-2, IL-4, IL-13), Th migratory behaviour (CXCR3, CCR5, CCR4), Th signalling suppressors (SOCS1, SOCS3), transcription factor (T-Bet, GATA-3) and apoptosis (FasL/Fas, TNF/TNFR, XIAP, Bax, caspase-3) was analyzed by RT-PCR 6 h and 7 d post-irradiation. $CD4^+$ and TUNEL positive cells were visualized by immunostaining.

RESULTS: The expression of Th1-related cytokine/chemokine receptors (IFN-γ, IL-2, CXCR3, CCR5) was repressed at 7 d post-irradiation while Th2 cell cytokine/chemokines (IL-4, IL-13, CCR4) were not repressed or even upregulated. The irradiation-induced Th2 profile was confirmed by the upregulation of both Th2-specific transcription factor GATA-3 and SOCS3. Although an apoptosis event occurred 6 h after 10 Gy of intestinal γ-irradiation, apoptotic mediator analysis showed a tendency to apoptotic resistance 7 d post-irradiation. CAPE amplified apoptotic events at 6h and normalized Bax/FasL expressions at 7 d.

CONCLUSION: CAPE prevented the ileal Th2 immune response by modulating the irradiation-influenced cytokine environment and apoptosis.

© 2006 The WJG Press. All rights reserved.

INTRODUCTION

Radiation-induced acute enteritis is the major dose-limiting complication in the radiotherapy for cancers in the abdominal region[1]. Irradiation injuries involve cytokine pathways[2] that trigger an inflammatory process causing clinical symptoms (diarrhea, dismotility). The immune-mediated pathologic development is the consequence of sustained local cytokine production. In particular, the modification of the $CD4^+$ helper T (Th) cell polarization induced by abdominal irradiation has not been investigated and these cells may play a primary role in irradiation injury. Crohn's disease and TNBS-induced colitis are both Th1-like forms of gut inflammation[3] whereas infection with *Schistosoma* is associated with a Th2 immune response[4].

Activated $CD4^+$ Th cells have been divided into at least two major exclusive T cell subsets according to their cytokine profile. The cytokine environment has been proposed as the major variable influencing Th development[5]. In the presence of IL-12, activated Th cells differentiate into Th1 cells, secreting predominantly IFN-γ and IL-2 which promote delayed-type hypersensitivity responses and pro-inflammatory responses. In contrast, the Th cells that are activated in the presence of IL-4 differentiate into Th2 cells, producing mainly IL-4 and IL-13 and promote humoral and allergic responses[6]. In addition, IL-4 inhibits the expression of the β_2 subunit of the IL-12 receptor, thereby preventing a Th1-type response, whereas IFN-γ stimulates it[7]. Thus, IL-12Rβ_2 expression is preferentially found in Th1 cells and maintains responsiveness to IL-12, whereas Th2 cell development is accompanied by a loss of this receptor subunit. Th1 and Th2 cells were originally distinguished from each other by their partially specific profile of cytokine expression. Analysis of such *in vivo* polarized Th cells has revealed differential sets of gene expression, including specific chemokine/chemokine recep-

tors. Typically, Th1 cells migrate to inflammatory sites in response to CXCR3 and CCR5 ligands[8]. Likewise, CCR4 is preferentially expressed on Th2 cells. The restricted expression of cytokines by polarized Th cells arises from a differential expression of transcription factors. T-Bet, expressed specifically in Th1, mediates IFN-γ production and GATA-binding protein 3 (GATA-3) plays a pivotal role in Th2 phenotype development and in Th1 phenotype inhibition[9]. However, recent studies have shown that cytokine signalling is under a negative feedback regulation by proteins called suppressors of cytokine signalling (SOCS). Thus, the differentiation toward the Th1 or Th2 pathway may be mediated in part by the selective repression of IL-12 or IL-4 signalling pathways[10].

Inhibition of pro-inflammatory molecules provides a logical therapeutic option for patients with abnormal immune cell activation[11]. This concept should be re-evaluated in light of evidence that immune activation is also regulated by apoptosis. Because programmed cell death controls the life span of cells, an apoptosis defect could result in an inappropriately long cell survival and a state of uncontrolled inflammation leading to chronic and autoimmune diseases[12]. This may be the case in Crohn disease, where abnormal mucosal T cell reactivity is well documented[11]. Medical or accidental exposure to radiation could lead to an impairment of specific immune responsiveness by apoptotic death of resting lymphocytes. The transcription factor NF-κB is a key regulator of genes implicated in the immune/inflammatory response[13]. Recently, we have shown that abdominal irradiation induced an inflammatory process involving NF-κB activation[3]. NF-κB also regulates the expression of many genes involved in the control of cell proliferation and cell death *via* extrinsic factors [TNF-α, Fas Ligand (FasL), IL-2], specific receptors [TNF and Fas receptors (TNFR, Fas)] and intrinsic mediators (XIAP, Bax)[14]. Targeting of inducible extrinsic factors has been proposed as a method for constraining immune responses by selectively killing activated T cells or inhibiting differentiation[15].

The modulation of NF-κB action by specific drugs is primarily based on cytokine synthesis. However, little is known about the effects of these drugs on Th1 or Th2-derived cytokine production patterns, on their specific transcription factors (T-Bet, GATA-3) and on chemokine receptors CXCR3/CCR5 (on Th1 cells) or CCR4 (on Th2 cells). Here, using abdominal γ-irradiation where both type-1 and type-2 cells can be activated, the pattern of gene expression was analysed in the ileum mucosa. To test the hypothesis that defective apoptosis is involved in inflammation process[16] and orients the immune response following irradiation, we used the apoptotic and immune regulation properties of Caffeic Acid Phenethyl Ester (CAPE), an active phenolic compound inhibitor of NF-κB[17] to modulate the irradiation-influenced cytokine environment and the Th polarization at the dose previously used[18]. This study was performed at 6 h post-irradiation where apoptotic events occurred, and at one week (d 7) corresponding to the restoration of the intestinal morphological structure.

MATERIALS AND METHODS

Animals and treatment

Male Wistar rats (Elevage Janvier, France), weighing 200-250 g, were housed with *ad libitum* food and water. All experiments were conducted in accordance with the French regulations for animal experimentation (Ministry of Agriculture Order No. 87-848, October 19, 1987). Anesthetized rats received a single abdominal dose of 10 Gy γ-irradiation (^{60}Co source). Control rats were sham-irradiated. Rats were divided into four groups (n = 6): controls, controls treated with CAPE, irradiated untreated, and irradiated CAPE treated. Rats were injected intraperitoneally with CAPE (30 mg/kg in saline containing 200 g/L Tween 80) 10 min before irradiation and once a day for 6 d[18]. The animals were sacrificed and the ileal tissues were dissected at 6 h and 7 d after exposure. Entire ileum specimens were taken for immunostaining and only mucosa layers, separated from the muscularis by scraping, were kept at -80℃ for protein extraction and RT-PCR.

Immunostaining

Ileal tissue samples were washed in PBS and then fixed in 40 g/L buffered formaldehyde solution. After dehydration, specimens were embedded in paraffin and sectioned (5 μm).

CD4$^+$ detection: Immunohistochemistry was performed to assess the presence of CD4 phenotype cells. Briefly, deparaffinized and rehydrated tissue sections were treated with 3 mL/L hydrogen peroxide in methanol to inhibit the endogenous peroxidase activity. Sections were incubated in protein blocking serum (Dako, USA) before treatment for 90 min at room temperature with the monoclonal anti-CD4 antibody (ab6413; 1/100 dilution, Abcam). Slides were then rinsed in 50 mmol/L Tris/HCl, 3 g/L NaCl and 1g/L Tween-20. The secondary reagent was the Vector Elite ABC kit (Dako).

Apoptotic cell detection: Apoptotic cells were visualized by the terminal deoxynucleotidyltransferase (TdT)-mediated dUTP-biotin nick-end labelling assay (TUNEL) using the *In Situ* Cell Death Detection kit (Roche Molecular Biochemicals, France) according to the manufacturer's instructions. Briefly, deparaffinized and rehydrated ileum tissue sections were incubated in proteinase K (20 mg/L in 10 mmol/L Tris-HCl, pH 7.6) for 10 min at 37℃. Endogenous peroxidase activity was quenched with blocking solution (3 g/L H_2O_2 in methanol). Sections were exposed to the TUNEL reaction mixture at 37℃ for 1 h. After washing in PBS buffer, POD (peroxidase) was added and allowed to react for 30 min at 37℃. For both staining methods, the slides were treated with a NovaRED™ kit (Vector Laboratories Inc, Burlingame, CA) for colour development and counterstained with Meyer's hemalum.

Caspase-3 activity assay

Mucosal protein extracts were prepared by a Dounce homogenization protocol from 50 mg of tissue in a hypotonic buffer (25 mmol/L HEPES, pH 7.5, 5 mmol/L $MgCl_2$, 1 mmol/L EGTA, 1 mmol/L PMSF, 5 mg/L aprotinin and leupeptin). After centrifugation of the homogenates, the supernatants were collected. Five

Table 1 Sequences of custom primers for real-time quantitative PCR

Gene	Forward primer	Reverse primer
Th1 cytokines/receptors		
IFN-γ	CACGCCGCGTCTTGGT	TCTAGGCTTTCAATGAGTGTGCC
IL-2	ATTTTCCAGGCACTGAAGATGTTT	CCCCATGATGCTCACGTTTA
IL-23	GCGTTCTCTTCTCCGTTCCA	TGCTCCGTGGGCAAAGAC
IL-12Rβ2	GGCTGCATCCTCCATTACAGA	CTGCTTATTGGATGTGAGTTTTG
Transcription factors		
T-Bet	TCCTGTCTCCAGCCGTTTCT	CGCTCACTGCTCGGAACTCT
GATA-3	GGCGGCGAGATGGTACTG	TCTGCCCATTCATTTTATGGTAGA
Chemokine receptors		
CXCR3	AGGTCAGTGAACGTCAAGTGCTAG	CAAAAAGAGGAGGCTGTAGAGGA
CCR5	CGGAACTTCTCCCCAACAAA	CTTTCTCTTCTGGACTCCCTACAACA
CCR4	GCCTCCAAGACAGACTTCCTTG	AGCGTTCGGTTCTAGTTTCCAC
Apoptotic Extrinsic factor/receptors		
TNF-α	CATCTTCTCAAAATTCGAGTGACAA	TGGGAGTAGACAAGGTACAACCC
TNFR1	TGCCACGCAGGATTCTTTCTAAG	TGGGGGTTTGTGACATTTGC
TNFR2	CCCATCATTGAACCAAGCATCAC	AAGCAGGTCGCCAGTCCTAACATC
Fas	CGAATGCAAGGGACTGATAGC	TTCTGAGCAGTTGTTGTCGGTTT
FasL	AAGGCGGCCTTGTGATCA	TTGCAAGACTGACCCCGG
CTLA-4	GTGGAACTCATGTACCCACCG	GCATGGTTCTGGATCGATGAC
Apoptotic Intrinsic factors		
XIAP	GGTGCAAGAAGCTATACGAATGG	AGTTGCTCCCAGATGTTTGGAG
Bax	GCTGACCTTGGAGCAGCC	ATGTTGTTGTCCAGTTCATCGC
Caspase-3	TGCGCCATGCTGAAACTG	CCTTCCGGTTAACACGAGTGA
Suppressors of Cytokine Signalling Proteins		
SOCS1	ACACTCACTTCCGCACCTTC	AGCAGCTCGAAAAGGCAGTC
SOCS3	CCTCCAGCATCTTTGTC-GGAAGAC	TACTGGTCCAGGAACTCCCGAATG
Housekeeping		
HPRT	GCTCGAGATGTCATGAAGGAGA	TCAGCGCTTTAATGTAATCCAGC

hundred μg of extracted protein was incubated with 100 μmol/L of the synthetic substrate Ac-DEVD-pNA in 500 μl of 25 mmol/L HEPES (pH 7.5) containing 200 ml/L glycerol and protease inhibitors. After 20 min of reaction at 37℃, the caspase-3-like activity was assayed by measuring the absorbance at 405 nm.

Quantitative real-time RT-PCR

Real-time quantitative RT-PCR was used to measure the expression of Th1 (IL-23, IL-12Rβ2, IFN-γ, IL-2, CXCR3, CCR5, T-Bet and SOCS1) or Th2-derived genes (IL-4, IL-13, CCR4, GATA-3, SOCS3), the cytokine TNF-α and its specific receptors (TNFR1, TNFR2), cytotoxic mediators (Fas/FasLigand, CTLA-4) and apoptotic genes (Bax, XIAP, caspase-3). Total RNA was prepared with the RNeasy total RNA isolation kit (Qiagen, France) according to the manufacturer's instructions. RNA integrity was confirmed by electrophoresis on a denaturing agarose gel and ethidium bromide staining. One μg of total RNA was reverse transcribed with SuperScript Ⅱ reverse transcriptase (Invitrogen, France) using random hexamers. IL-4 and IL-13 primers from the manufacturer were used to amplify first-strand cDNA with TaqMan technology (Applied Biosystems). PCR amplification of the other genes used SYBR PCR master Mix. The primer sequences (Table 1) have been designed by Primer Express software (Applied Biosystems). Optimized PCR used the ABI Prism 7000 Sequence detection system (Applied Biosystems). PCR fluorescent signals were normalized to the signal obtained from the housekeeping gene HPRT for each sample.

Immunoblot analysis

Total proteins were obtained by homogenization of ileal samples in a cold RIPA buffer containing classical protease-inhibitor cocktail. Total proteins (40 μg) were boiled in SDS and mercaptoethanol buffer; then separated on a 120 g/L polyacrylamide gel (NuPAGE gels; Invitrogen, France) and electroblotted. Polyvinylidendifluoride membranes were incubated with a blocking solution (50 g/L skim milk in TPBS containing 1 mL/L Tween 20), washed with TPBS and incubated with rabbit polyclonal primary antibody directed against T-Bet for 1h at RT (dilution 1/200; Santa Cruz) or goat polyclonal GATA-3 overnight (dilution 1/100; Santa Cruz). After washing, immunodetection was performed with the respective horseradish-linked secondary antibody (1/2000; Amersham). Chemiluminescence was detected according to manufacturer's protocol (ECL, Amersham Biosciences).

Result expression and statistical analysis

We used the comparative $\Delta\Delta C_T$-method[19] for relative mRNA quantification of target genes, normalized to an endogenous reference (HPRT) and a relevant non-irradiated control, equal to $2^{-\Delta\Delta CT}$. $\Delta\Delta C_T$ is the difference between the mean $\Delta C_{T\ (irradiated\ sample)}$ and mean $\Delta C_{T\ (non\text{-}irradiated\ sample)}$, where ΔC_T is the difference between the mean $C_{T(genes)}$ and the mean $C_{T(HPRT)}$. Each sample was monitored for fluorescent dyes, and signals were regarded as significant if the fluorescence intensity significantly exceeded (10-fold) the standard deviation of the baseline fluorescence, defined as threshold cycles (C_T).

All data are expressed as the mean ± SD error of the

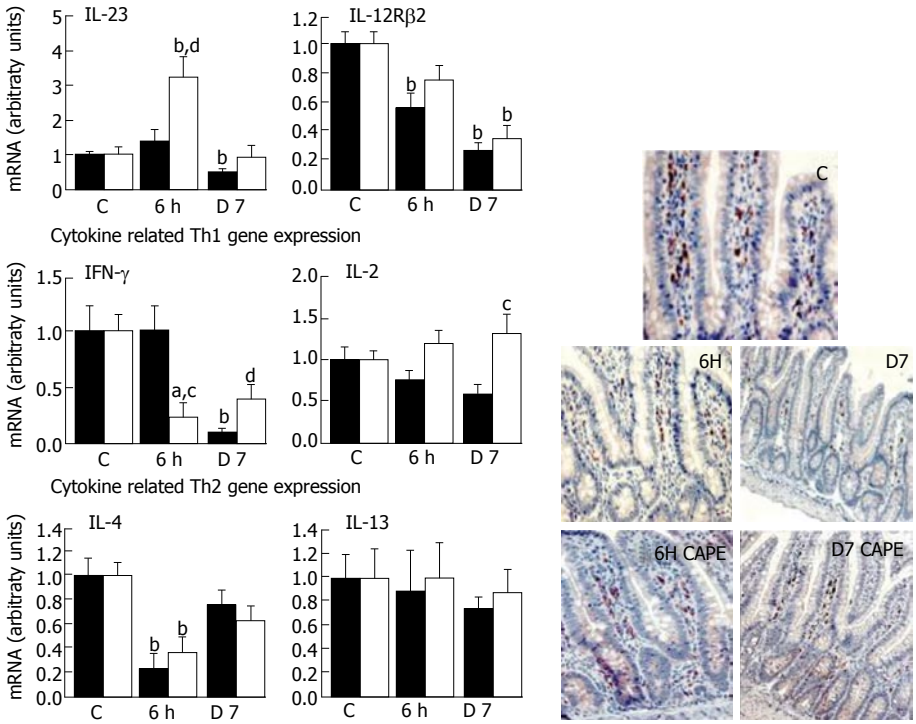

Figure 1 Th1/Th2-like pattern of gene expression in the ileal mucosal layer after γ-irradiation in rats. (■): CAPE-untreated, (□): CAPE-treated and CD4$^+$ immunostaining in control (C), 6 h and 7 d (D7) after irradiation (D (x 20) (mean ± SEM, n = 6); $^aP < 0.05$, $^bP < 0.01$ *vs* control; $^cP < 0.05$, $^dP < 0.001$ *vs* untreated.

mean (SEM) for 6 animals. Comparisons between groups used Mann-Whitney test for non-paired data.

RESULTS

Effect of CAPE on the irradiation-modified mucosal cytokine environment

Activation and polarization of CD4$^+$ Th cells was dependent on local dominant factors that control differentiation. IL-12 is a critical cytokine for polarizing naïve CD4$^+$ T cells towards a Th1 dominance[7]. Moreover, the T-cell responsiveness to this mediator depends on expression of the inducible IL-12Rβ2 subunit of the IL-12 receptor[20]. IL-12Rβ2 is preferentially expressed by Th1 cells and is lost with Th2 cell development. From the analysis of IL-23 expression, the IL-12p40 form appears to be a key step in Th1 pathogenesis[21], since irradiation repressed it ($P < 0.01$) and it fell to below the levels of IL-12Rβ2 at d 7 ($P < 0.01$) (Figure 1). Significant evidence exists for a relationship between IFN-γ expression and IL-23/IL-12R signalling since Th1 commitment is enhanced by IFN-γ[22]. Accordingly, the irradiation-induced down-regulation of IL-23/IL-12Rβ2 (-50% and -80%) was correlated with a drastically low level of IFN-γ expression (95% decrease, $P < 0.01$) at 7 d. These results suggest that irradiation did not induce the expression of a Th1 pattern of cytokines. In addition, the low IL-2 expression, the other Th1 cytokine representing one of the major growth factors for the expansion of activated T cells, observed 7 d after irradiation supports this hypothesis. Although CAPE did not significantly restore the radiation-induced decrease in IL-12Rβ2 expression, IFN-γ and IL-23 expression tended to return to normality and the IL-2 mRNA level was 1.5-fold increased as compared to controls.

To address the induction mechanism of Th2 dominance by irradiation, we examined the IL-4 and IL-13 mRNA levels. As shown in Figure 1, irradiation only repressed IL-4 expression (-75%) soon after irradiation (6 h) but had no significant effect at 7 d on either IL-4 or IL-13 expression. CAPE did not influence IL-4 and IL-13 mRNA levels.

The presence of CD4$^+$ T cells in the *lamina propria* was confirmed by immunostaining. The CD4$^+$ T cell numbers were not modified at 6 h and 7 d post- irradiation compared to the control (Figure 1). CAPE did not influence the cell frequency.

Polarization of CD4$^+$ T lymphocytes in ileal tissue following irradiation

To characterize the Th cell polarization, we exploited the fact that activated Th cells acquire and maintain at high levels a specific pattern of chemokine receptors: CXCR3/CCR5 present on Th1 or CCR4 on Th2. Irradiation modified the chemokine receptor profile. There was a 70% fall ($P < 0.01$) in CXCR3 levels at 6 h post-irradiation and a tendency for decline in CCR5, whereas CCR4 mRNA was about 2.5-fold ($P < 0.05$) up-regulated at both time-points after irradiation (Figure 2). CAPE significantly counter-balanced the CXCR3 mRNA repression ($P < 0.05$) and the CCR4 mRNA induction ($P < 0.01$) at d 7.

The transcription factor T-Bet is selectively expressed in Th1 cells whereas GATA-3 is selectively expressed in Th2 cells. Expression of these genes is rapidly induced in primary T cells triggering the Th1 or Th2 pathway[23]. Our data showed that irradiation induced an early (6 h) significant decrease of T-Bet expression, followed by an accentuation of decline down to 20% of the control level at d 7 ($P < 0.005$). In contrast, GATA-3 was significantly up-regulated at 7 d ($P < 0.01$, Figure 3). Because T-Bet is reported to represent Th1 immune responses and GATA-3 those of Th2, it has been suggested that the ratio of expression of these transcription factor could

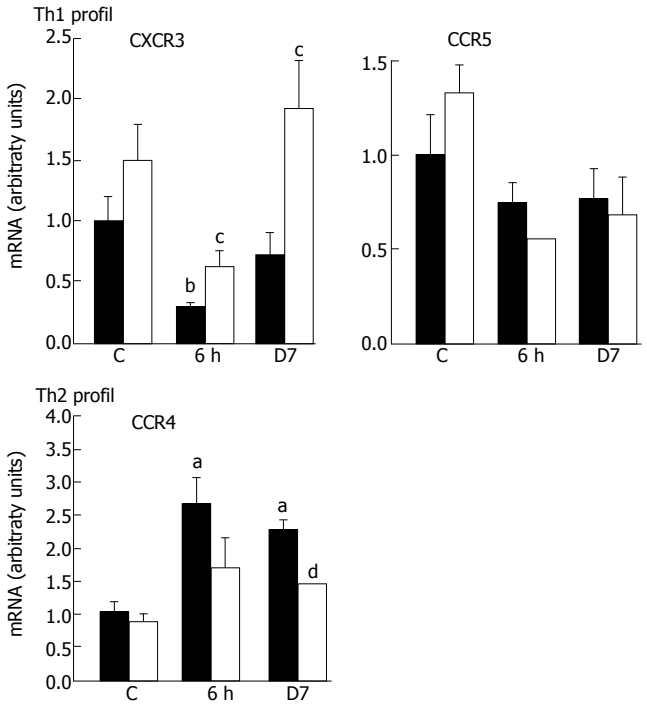

Figure 2 Expression of the chemokine receptors CXCR3/CCR5 and CCR4 post-irradiation in rats. (■): CAPE-untreated; (□): CAPE-treated (mean ± SEM, n = 6); $^aP < 0.05$, $^bP < 0.01$ *vs* control; $^cP < 0.05$, $^dP < 0.01$ *vs* untreated rats.

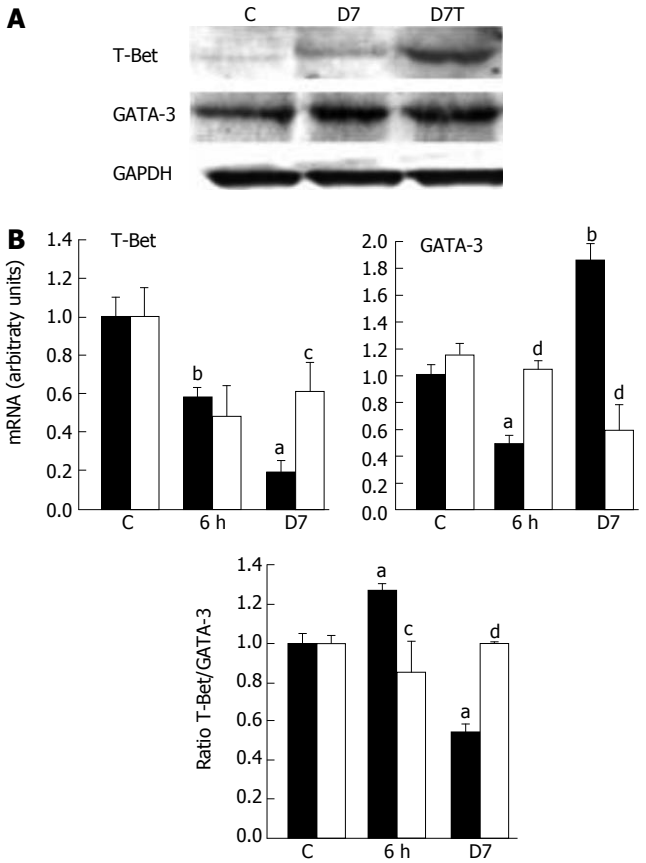

Figure 3 Expression of transcription factors of Th1/Th2 polarization after irradiation in rats. (■): CAPE-untreated; (□): CAPE-treated. **A**: Western blot analysis using T-Bet and GATA-3 polyclonal antibody, GAPDH levels are used as internal standard; **B**: Real-time RT-PCR analysis (mean ± SEM, n = 6); $^aP < 0.005$, $^bP < 0.01$ *vs* control; $^cP < 0.05$, $^dP < 0.01$ *vs* untreated rats.

be used to reflect the Th1 or Th2 status in mixed cell populations[24]. The increase in GATA-3 expression was greater than for T-Bet, which was reflected by the T-Bet/GATA-3 ratio with a 2-fold decrease at d 7 (P < 0.01). These data confirm that irradiation causes a shift toward Th2 polarization. CAPE significantly reduced (P < 0.05) the radiation-induced T-Bet repression and GATA-3 was totally down-regulated at d 7 normalizing the T-bet/GATA-3 ratio. Western blot analysis confirmed the increased T-Bet/GATA-3 ratio where the T-Bet protein level reduction detected 7 d post-irradiation was removed after CAPE treatment (Figure 3).

Polarization of CD4$^+$ regulated by SOCS proteins

Endogenous feedback regulators of cytokine activities such as SOCS proteins regulate the amplitude and duration of the polarization influenced by T-Bet or GATA-3[10]. Since Th1 cells predominantly express SOCS1 while Th2 express high levels of SOCS3, we have hypothesized that SOCS genes might contribute to the establishment of a stable Th1 or Th2 phenotype. The analysis of the SOCS expression revealed a drastic reduction of SOCS1 mRNAs at d 7, whereas SOCS3 mRNAs were significantly up-regulated at 6 h with a high level maintained (2-fold, P < 0.05) for one week (Figure 4). The functional consequences of a high level of SOCS3 expression and a relatively low abundance of SOCS1 may drive the majority of CD4$^+$ toward a Th2 pattern of cytokine expression. CAPE limited the irradiation effect on SOCS1, with a restoration to half the level of that of the controls at 7 d (P < 0.05), but had no effect on SOCS3 expression.

Early administration of CAPE modified apoptotic events in irradiated rats

Since the decision as to whether T cells survive or undergo apoptosis is of particular importance for adaptive immune responses[14], we examined the expression of genes associated with the regulation of apoptosis, in the mucosa after irradiation. Real-time PCR was used to quantify mRNA levels of extrinsic factors (TNF-α, FasL, CTLA-4), specific receptors (TNFRs, Fas) and intrinsic mediators (XIAP, Bax, caspase-3). Irradiation led to an over-expression of TNF-α (20-fold at 6 h, P < 0.001), which correlated with a significant increase in TNF receptor (R1, R2) mRNAs (Figure 5). These over-expressions remained significant at d 7. It has been demonstrated that CAPE has anti-inflammatory and apoptotic properties[3,17]. Accordingly, CAPE significantly reduced TNF-α up-regulation at 7 d post-irradiation and led to a dual effect on TNFR2 expression with an early (6 h) amplification of expression and, in contrast, a reduction of the irradiation effect at 7 d.

The engagement of the death receptor Fas by FasL plays an important role in apoptotic events. Our data have shown that irradiation has a biphasic effect with a significant increase of Fas and FasL mRNA levels at 6 h and a significant FasL repression at d 7 (P < 0.05). CAPE over-expressed Fas/FasL at 6 h with a persistent effect

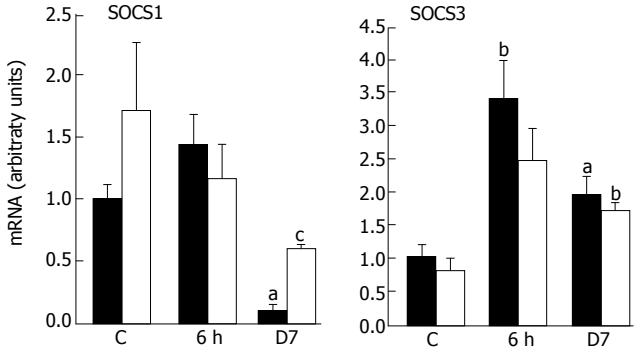

Figure 4 Expression of the regulator cytokine gene SOCS1 and SOCS3 after irradiation in rats. (■): CAPE-untreated; (□): CAPE-treated (mean ± SEM, n = 6); $^{a}P < 0.05$, $^{b}P < 0.01$ *vs* control; $^{c}P < 0.05$, $^{d}P < 0.01$ *vs* untreated.

on FasL mRNA level at d 7 (Figure 5). In association with Fas/FasL, CTLA-4 engagement could potentiate the elimination of pathogenic T cells[24]. Irradiation significantly down-regulated CTLA-4 at d 7 (90% decrease compared to controls, $P < 0.01$), which was not modified by CAPE (Figure 5). These results suggest that an absence of cytotoxic mediators occurs at 7 d post-irradiation that is minimized by CAPE-induced FasL normalization.

The modulation of the members of the IAP (apoptosis inhibitors) family, such as the anti-apoptotic protein XIAP or the pro-apoptotic protein Bax, regulates apoptosis. No significant change in XIAP mRNA was observed at 6 h whereas Bax expression rose at 6 h then progressively decreased at 7 d leading to a 70% reduction ($P < 0.01$) (Figure 6). The apoptotic event was confirmed at 6 h by an increase in caspase-3 activity that contrasted with the normal activity found at 7 d; caspase-3 expression remained invariant. CAPE reduced the XIAP expression and over-expressed Bax as compared to irradiated rats at 7 d ($P < 0.01$), resulting in a significant caspase-3 activity increase ($P < 0.01$).

The irradiation-induced apoptosis events at 6 h were confirmed by TUNEL assay (Figure 6A-E). TUNEL^{+} cells were sparse in the lamina propria of controls, and were only located at the top of the villi. Six hours post-irradiation, the number of apoptotic cells was considerably increased and localized in the crypts and the bottom of the villi compared to controls. Some apoptotic cells appeared in the lamina propria. The irradiation-induced apoptotic effect was amplified in the crypts and the bottom by CAPE at 6 h but not at d 7, as compared to controls.

DISCUSSION

In this study, we investigated whether targeting defective mucosal cell death underlies the sustained therapeutic benefit of CAPE by orienting the immune response induced by irradiation. The results show firstly that irradiation led to an earlier apoptotic process, which progressively resulted in an apoptotic resistance and secondly, that irradiation oriented the immune response to a predominance of Th2 type polarization. Overall, the emerging picture is that, in the non-inflamed gut, the T cells manifest increased spontaneous apoptosis mediated by the Fas pathway that

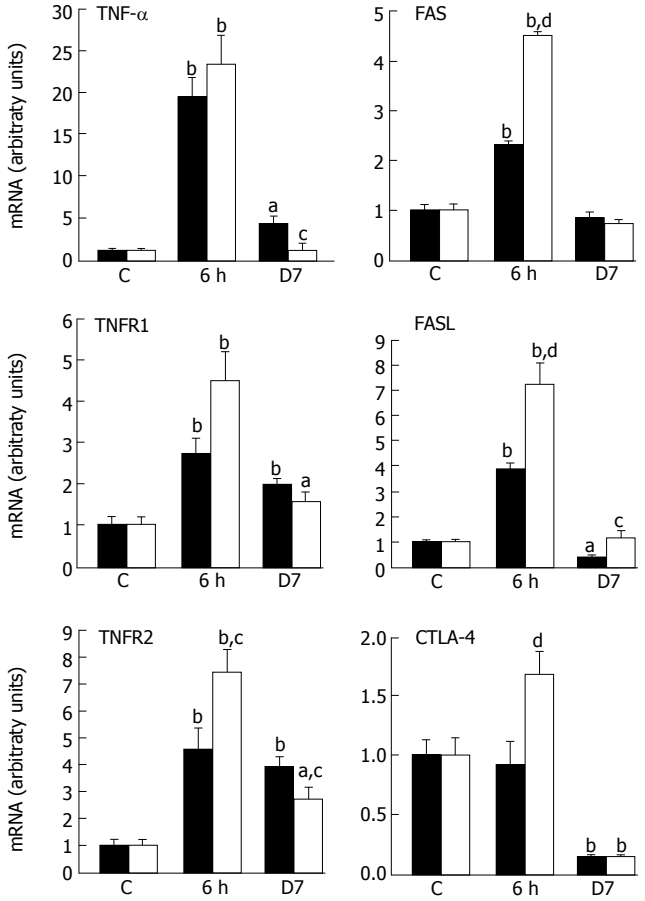

Figure 5 Irradiation effect on extrinsic apoptotic factors TNF-α, FasL and related-receptors expression post-irradiation in rats. (■): CAPE-untreated; (□): CAPE-treated (mean ± SEM, n = 6); $^{a}P < 0.05$, $^{b}P < 0.01$ *vs* control; $^{c}P < 0.05$, $^{d}P < 0.01$ *vs* untreated rats.

limited expansion of T cells. By contrast, in the inflamed tissue, resident T cells are relatively resistant to apoptosis. Thus, they exhibit an enhanced cytokine production because of prolonged survival, which significantly aggravates the inflammation. The functional importance of T cell apoptosis resistance has been emphasized by recent studies in animal models of IBD showing that IL-12 and TNF-α antibodies appear to suppress chronic intestinal inflammation by the induction of T cell apoptosis[25]. The regulation of T cell activation by immunosuppressive drugs is known to be relevant in the treatment of inflammatory disorders. Medical or accidental exposure to radiation leads to an inflammatory process[2]. Currently, the purpose of using NF-κB inhibitors as an adjuvant for cancer treatment is to increase the therapeutic index of radiotherapy and chemotherapy[26,27]. The success of this approach relies both on its ability to promote cancerous cell killing by irradiation and to spare normal cells from enhanced damage. By analysing the immunomodulatory and apoptotic properties[17], we have shown that CAPE shifts from the radiation-induced Th2-like pattern of gene expression toward Th1 gene expression by an apoptotic sensitization.

Irradiation led to the repression of genes involved in 4 key features of Th1 cell differentiation: genes involved in Th1 differentiation (IL-12, IL-12Rβ2), genes associated with Th1 cytokine responses (IFN-γ, IL-2), genes

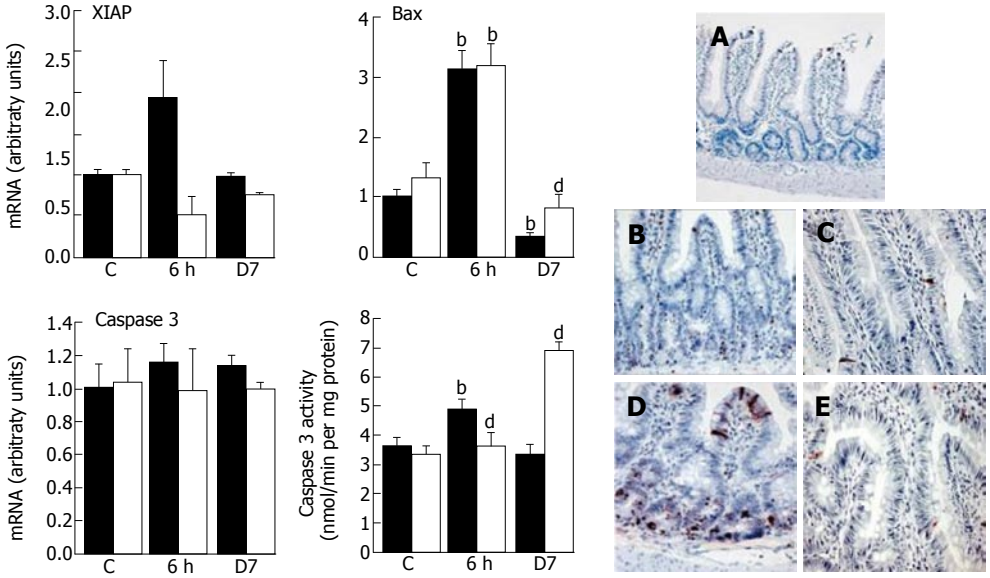

Figure 6 Irradiation effect on intrinsic apoptotic factor expression modulation and caspase activity post-irradiation in rats. (■): CAPE-untreated (□): CAPE-treated. Apoptotic cells presence was confirmed by the terminal deoxynucleo tidyltransferase (TdT)-mediated dUTP-biotin nick-end labeling (TUNEL) staining in ileum. (**A**): Control; (**B**): 6 h; (**C**): 7 d after γ-irradiation. (**D**): 6 h; (**E**): 7 d from irradiated CAPE-treated (x 20) (mean ± SEM, n = 6); $^{b}P < 0.01$ *vs* control; $^{d}P < 0.01$ *vs* untreated.

regulating cell death and apoptosis (Fas/FasL, CTLA-4) and genes controlling Th1 migratory behaviour (CXCR3, CCR5). Simultaneous to the down-regulation of Th1-associated chemokine receptors, the transcription factor T-Bet was moderately expressed while GATA-3 was up-regulated. Transcription factors such as T-Bet and GATA-3 play a critical role in the initiation of primary immune responses and skewing the response toward the Th1 or Th2 pathway[23]. The duration of the response depends on the coordination of lymphocyte responses. These aspects of the adaptive immune response are regulated by endogenous feedback regulators of cytokine activities[10]. Thus, SOCS proteins are differentially expressed: Th1 cells predominantly express SOCS1 whereas Th2 cells express very high levels of SOCS3. The restricted pattern of expression in Th1 and Th2 cells underscores the importance of SOCS members in Th cell subtypes. A preferential up-regulation of SOCS1 expression in Th1 but not Th2 after IL-12 stimulation argues for a role of cytokine signalling in SOCS regulation[10,22]. In our study, we found a differential expression of SOCS at 7 d post-irradiation with a repression of SOCS1 and an overexpression of SOCS3. The functional consequence of SOCS3 expression may be to drive the majority of $CD4^+$ toward a Th2 pattern of cytokine expression at this time. However, cytokines can override the effects of SOCS3 during Th differentiation. In fact, a major effect of IL-12 signalling in non-polarized Th cells is to down-regulate SOCS3 expression in cells committed to the Th1 lineage. In this way, Th1 differentiation requires IL-12/IL-12Rβ2 signalling[28] and SOCS1[24], and the drastic repression of IL-23, closely related to IL-12, that occurred at 7 d post-irradiation reduces the possibility of a Th1 lineage. In addition, IL-12/IL-12Rβ2 signalling supports high IFN-γ production and IFN signalling to down-regulate IL-4 and prevent Th2 dominance[29]. In this way, although IL-4 expression induced by irradiation was not elevated, the protection of Th1 dominance after irradiation could not maintained by the mere fact of the IFN-γ repression at d 7. Szabo *et al*[7] have shown that when IFN-γ production is limited, a low IL-4 production in early responses may critically inhibit IL-12Rβ2 expression with a significant effect on the development of a Th1/Th2 shift. In fact, only low IL-4 level is required in the complete absence of extrinsic Th1 signals (e.g: IL-12) to generate Th2 $CD4^+$. These results showed the same prevalence of an irradiation-induced Th2 response in the lung. In fact, enhanced lymphocyte reactivity, dominated by Th2 cells, has been shown in radiation-induced pneumonitis and subsequent pulmonary fibrosis, suggesting a critical role for Th2 $CD4^+$[30].

TUNEL staining has revealed an increase of apoptotic cells observed at the top of the villi and in the crypts. Some apoptotic cells appeared after irradiation in the lamina propria which is formed from a majority of immune cells. In fact, a differential sensitivity of lymphocyte subpopulations to irradiation-induced apoptosis has been reported; in particular, $CD4^+$ T cells are relatively radioresistant[31]. In this work, $CD4^+$ immunostaining confirmed their presence after irradiation. TUNEL positive cells increased at 6 h confirming the radiosensitization effect of CAPE but without real modification of the number of $CD4^+$ cells. In this study and in accordance with other findings[27], the earliest intestinal response to radiation injury reflects a complex series of apoptotic events involving extrinsic factors (TNF-α, FasL, IL-2), specific receptors (TNFR, Fas) and intrinsic mediators (XIAP, Bax and caspase-3). All these apoptotic events occurred rapidly after irradiation (6 h) but were amply repressed one week post-irradiation.

The extrinsic factors such as Fas and FasL are particularly important in T cell apoptotic events. The observed decrease in Fas/FasL expression may mediate T cells apoptosis and becomes especially important in the irradiation-inflammatory process at d 7, because failures of this mortality pathway can impair both autocrine and paracrine mechanisms for eliminating activated T cells. In fact, Fas is expressed by the both Th cell subsets whereas only Th1 cells express detectable amounts of FasL[29]. The differential expression of FasL by Th1 and Th2 cells is correlated with the ability of these cells to undergo to apoptosis: Th1 clones are highly sensitive to apoptosis, whereas Th2 clones are relatively resistant. In this way, the genesis of Th2 orientation may occur early (6 h) post-

irradiation. In view of the ability of CAPE to induce an apoptotic event *via* Fas activation[32], the restoration of FasL expression by CAPE may suggest a modification of the apoptosis resistance and of the Th1/Th2 balance at 7 d post-irradiation. This hypothesis must be confirmed by *in vitro* experiments. Interestingly in respect to asthma, it has been shown that intratracheal delivery of adenovirus encoding FasL could significantly suppress pulmonary Th2 immune response[33].

Fas, a member of the TNF receptor family, is inducible by TNF-α itself[34], a good correlation was observed concerning the radiation-induced expression variation between Fas/FasL and TNF-α. CAPE did not alter this high mRNA level at 6 h, but this correlation disappeared at 7 d with a repression of TNF-α and a normalization of FasL levels. The cell death signal induced by TNF-α is mediated by TNFR1. In contrast, the engagement of TNFR2 promotes cell survival by the induction of anti-apoptotic molecules[35]. Although TNF-α was repressed at 7 d, the TNFR1 up-regulation induced by irradiation was not altered by CAPE in contrast to TNFR2 which was down-regulated. This observation, associated with FasL normalization, may be an indication of a limitation of apoptosis resistance induced by CAPE at 7 d. Intrinsic gene product analysis confirmed this argument at this time when CAPE also normalized Bax expression, contributing to increased caspase-3 activity.

Cell death is a complex series of events regulated by the intrinsic propensity of individual cells, the environment and cell surface. The regulation of T-cell activation/apoptosis depends on critical cell surface molecules, in particular CTLA-4 which down-regulates T cell activation. The immune importance of CTLA-4 has been reported *in vivo* where CTLA-4 blockade exacerbates some autoimmune diseases[36] and CTLA-4-deficient mice exhibit a massive polyclonal increase in T cells. On the basis of these properties and in view of our data which showed that CTLA-4 was totally repressed at 7 d, it seems possible that an irradiation-induced T-cell activation effect may have occurred. CAPE had no effect on CTLA-4 expression, so that it seems probable that the T cell expansion/activation was maintained, but an orientation of the immune response cannot be excluded.

These results suggest that CAPE, by modulating the cytokine pattern, changed the orientation of immune responses after irradiation and favoured a Th1 response notably by the total or partial suppression of IL-12 and IFN-γ repression. Interestingly, CAPE could inhibit T-cell activation by targeting both NF-κB and the nuclear factor of activated T cells (NFAT)[37]. Diehl *et al*[38] showed that NFAT activation in $CD4^+$ is required for the development of Th2 differentiation and its inhibition in T cells prevents the Th2 immune response in a model of allergic pulmonary inflammation. The activation of NFAT by irradiation still has not been demonstrated but we cannot exclude its potential involvement in the irradiation-induced Th2-like profile.

REFERENCES

1 **Andreyev J**. Gastrointestinal complications of pelvic radiotherapy: are they of any importance? *Gut* 2005; **54**: 1051-1054

2 **Linard C**, Ropenga A, Vozenin-Brotons MC, Chapel A, Mathe D. Abdominal irradiation increases inflammatory cytokine expression and activates NF-kappaB in rat ileal muscularis layer. *Am J Physiol Gastrointest Liver Physiol* 2003; **285**: G556-G565

3 **MacDonald TT**, Monteleone G, Pender SL. Recent developments in the immunology of inflammatory bowel disease. *Scand J Immunol* 2000; **51**: 2-9

4 **Cêtre C**, Pierrot C, Cocude C, Lafitte S, Capron A, Capron M, Khalife J. Profiles of Th1 and Th2 cytokines after primary and secondary infection by Schistosoma mansoni in the semipermissive rat host. *Infect Immun* 1999; **67**: 2713-2719

5 **Constant SL**, Bottomly K. Induction of Th1 and Th2 CD4+ T cell responses: the alternative approaches. *Annu Rev Immunol* 1997; **15**: 297-322

6 **Opal SM**, DePalo VA. Anti-inflammatory cytokines. *Chest* 2000; **117**: 1162-1172

7 **Heath VL**, Showe L, Crain C, Barrat FJ, Trinchieri G, O'Garra A. Cutting edge: ectopic expression of the IL-12 receptor-beta 2 in developing and committed Th2 cells does not affect the production of IL-4 or induce the production of IFN-gamma. *J Immunol* 2000; **164**: 2861-2865

8 **Moser B**, Loetscher P. Lymphocyte traffic control by chemokines. *Nat Immunol* 2001; **2**: 123-128

9 **Ritz SA**, Cundall MJ, Gajewska BU, Swirski FK, Wiley RE, Alvarez D, Coyle AJ, Stampfli MR, Jordana M. The lung cytokine microenvironment influences molecular events in the lymph nodes during Th1 and Th2 respiratory mucosal sensitization to antigen in vivo. *Clin Exp Immunol* 2004; **138**: 213-220

10 **Egwuagu CE**, Yu CR, Zhang M, Mahdi RM, Kim SJ, Gery I. Suppressors of cytokine signaling proteins are differentially expressed in Th1 and Th2 cells: implications for Th cell lineage commitment and maintenance. *J Immunol* 2002; **168**: 3181-3187

11 **Fiocchi C**. Inflammatory bowel disease: etiology and pathogenesis. *Gastroenterology* 1998; **115**: 182-205

12 **Rathmell JC**, Thompson CB. Pathways of apoptosis in lymphocyte development, homeostasis, and disease. *Cell* 2002; **109** Suppl: S97-107

13 **Xiao C**, Ghosh S. NF-kappaB, an evolutionarily conserved mediator of immune and inflammatory responses. *Adv Exp Med Biol* 2005; **560**: 41-45

14 **Perkins ND**. The Rel/NF-kappa B family: friend and foe. *Trends Biochem Sci* 2000; **25**: 434-440

15 **Murphy FJ**, Hayes I, Cotter TG. Targeting inflammatory diseases via apoptotic mechanisms. *Curr Opin Pharmacol* 2003; **3**: 412-419

16 **Levine AD**, Fiocchi C. Regulation of life and death in lamina propria T cells. *Semin Immunol* 2001; **13**: 195-199

17 **Orban Z**, Mitsiades N, Burke TR Jr, Tsokos M, Chrousos GP. Caffeic acid phenethyl ester induces leukocyte apoptosis, modulates nuclear factor-kappa B and suppresses acute inflammation. *Neuroimmunomodulation* 2000; **7**: 99-105

18 **Fitzpatrick LR**, Wang J, Le T. Caffeic acid phenethyl ester, an inhibitor of nuclear factor-kappaB, attenuates bacterial peptidoglycan polysaccharide-induced colitis in rats. *J Pharmacol Exp Ther* 2001; **299**: 915-920

19 **Brink N**, Szamel M, Young AR, Wittern KP, Bergemann J. Comparative quantification of IL-1beta, IL-10, IL-10r, TNFalpha and IL-7 mRNA levels in UV-irradiated human skin in vivo. *Inflamm Res* 2000; **49**: 290-296

20 **Szabo SJ**, Sullivan BM, Peng SL, Glimcher LH. Molecular mechanisms regulating Th1 immune responses. *Annu Rev Immunol* 2003; **21**: 713-758

21 **Becker C**, Wirtz S, Blessing M, Pirhonen J, Strand D, Bechthold O, Frick J, Galle PR, Autenrieth I, Neurath MF. Constitutive p40 promoter activation and IL-23 production in the terminal ileum mediated by dendritic cells. *J Clin Invest* 2003; **112**: 693-706

22 **Eyles JL**, Metcalf D, Grusby MJ, Hilton DJ, Starr R. Negative regulation of interleukin-12 signaling by suppressor of cytokine signaling-1. *J Biol Chem* 2002; **277**: 43735-43740

23 **Chakir H**, Wang H, Lefebvre DE, Webb J, Scott FW. T-bet/

GATA-3 ratio as a measure of the Th1/Th2 cytokine profile in mixed cell populations: predominant role of GATA-3. *J Immunol Methods* 2003; **278**: 157-169

24 **Campanelli AP**, Martins GA, Souto JT, Pereira MS, Livonesi MC, Martinez R, Silva JS. Fas-Fas ligand (CD95-CD95L) and cytotoxic T lymphocyte antigen-4 engagement mediate T cell unresponsiveness in patients with paracoccidioidomycosis. *J Infect Dis* 2003; **187**: 1496-1505

25 **Neurath MF**, Finotto S, Fuss I, Boirivant M, Galle PR, Strober W. Regulation of T-cell apoptosis in inflammatory bowel disease: to die or not to die, that is the mucosal question. *Trends Immunol* 2001; **22**: 21-26

26 **Lin A**, Karin M. NF-kappaB in cancer: a marked target. *Semin Cancer Biol* 2003; **13**: 107-114

27 **Wang Y**, Meng A, Lang H, Brown SA, Konopa JL, Kindy MS, Schmiedt RA, Thompson JS, Zhou D. Activation of nuclear factor kappaB In vivo selectively protects the murine small intestine against ionizing radiation-induced damage. *Cancer Res* 2004; **64**: 6240-6246

28 **Sakamoto S**, Fukushima A, Ozaki A, Ueno H, Kamakura M, Taniguchi T. Mechanism for maintenance of dominant T helper 1 immune responses in Lewis rats. *Microbiol Immunol* 2001; **45**: 373-381

29 **Roberts AI**, Devadas S, Zhang X, Zhang L, Keegan A, Greeneltch K, Solomon J, Wei L, Das J, Sun E, Liu C, Yuan Z, Zhou JN, Shi Y. The role of activation-induced cell death in the differentiation of T-helper-cell subsets. *Immunol Res* 2003; **28**: 285-293

30 **Westermann W**, Schöbl R, Rieber EP, Frank KH. Th2 cells as effectors in postirradiation pulmonary damage preceding fibrosis in the rat. *Int J Radiat Biol* 1999; **75**: 629-638

31 **Seki H**, Iwai K, Kanegane H, Konno A, Ohta K, Ohta K, Yachie A, Taniguchi N, Miyawaki T. Differential protective action of cytokines on radiation-induced apoptosis of peripheral lymphocyte subpopulations. *Cell Immunol* 1995; **163**: 30-36

32 **Watabe M**, Hishikawa K, Takayanagi A, Shimizu N, Nakaki T. Caffeic acid phenethyl ester induces apoptosis by inhibition of NFkappaB and activation of Fas in human breast cancer MCF-7 cells. *J Biol Chem* 2004; **279**: 6017-6026

33 **Chuang Y**H, Fu CL, Lo YC, Chiang BL. Adenovirus expressing Fas ligand gene decreases airway hyper-responsiveness and eosinophilia in a murine model of asthma. *Gene Ther* 2004; **11**: 1497-1505

34 **Choi C**, Park JY, Lee J, Lim JH, Shin EC, Ahn YS, Kim CH, Kim SJ, Kim JD, Choi IS, Choi IH. Fas ligand and Fas are expressed constitutively in human astrocytes and the expression increases with IL-1, IL-6, TNF-alpha, or IFN-gamma. *J Immunol* 1999; **162**: 1889-1895

35 **Kaiser GC**, Polk DB. Tumor necrosis factor alpha regulates proliferation in a mouse intestinal cell line. *Gastroenterology* 1997; **112**: 1231-1240

36 **Eagar TN**, Karandikar NJ, Bluestone JA, Miller SD. The role of CTLA-4 in induction and maintenance of peripheral T cell tolerance. *Eur J Immunol* 2002; **32**: 972-981

37 **Márquez N**, Sancho R, Macho A, Calzado MA, Fiebich BL, Muñoz E. Caffeic acid phenethyl ester inhibits T-cell activation by targeting both nuclear factor of activated T-cells and NF-kappaB transcription factors. *J Pharmacol Exp Ther* 2004; **308**: 993-1001

38 **Diehl S**, Krahl T, Rinaldi L, Norton R, Irvin CG, Rincón M. Inhibition of NFAT specifically in T cells prevents allergic pulmonary inflammation. *J Immunol* 2004; **172**: 3597-3603

S- Editor Pan BR **L- Editor** Lalor PF **E- Editor** Bi L

PO Box 2345, Beijing 100023, China
www.wjgnet.com
wjg@wjgnet.com

World J Gastroenterol 2006 August 21; 12(31): 5005-5009
World Journal of Gastroenterology ISSN 1007-9327
© 2006 The WJG Press. All rights reserved.

BASIC RESEARCH

Expression and significance of ICAM-1 and its counter receptors LFA-1 and Mac-1 in experimental acute pancreatitis of rats

Wei Sun, Yasuhiro Watanabe, Zhong-Qiu Wang

Wei Sun, Department of Pediatric Surgery of Kagawa Medical University, Japan; now in the Department of General Surgery, 2nd Affiliated Hospital, China Medical University, Shenyang, 110004, Liaoning Province, China
Yasuhiro Watanabe, Zhong-Qiu Wang, Department of Pediatric Surgery, Faculty of Medicine, Kagawa University, Japan
Correspondence to: Wei Sun, Department of General Surgery, 2nd Affiliated Hospital, China Medical University, 36 Sanhao Street, Shenyang, 110004, Liaoning Province, China. sunweii@hotmail.com
Telephone: +86-24-83955063
Received: 2006-04-13 Accepted: 2006-05-25

Abstract

AIM: To investigate the role of intercellular adhesion molecule-1 (ICAM-1) and its counter receptors LFA-1 and Mac-1 in acute pancreatitis (AP).

METHODS: SD rats were allocated to AP group and control group randomly (25 rats each). AP was induced by infusion of 5% chenodeoxycholic acid into the pancreatic duct, followed by ligation of pancreatic duct. The rats were sacrificed at 1, 3, 6, 12 and 24 h after induction of pancreatitis. Five rats were sacrificed at one time point in the two groups before the blood and specimens from pancreas and lung were obtained. Serum amylase and ascitic fluid were measured at each time point. Expression of ICAM-1 at different time points was assessed by immunohistochemistry in pancreas and lung, and the expression of LAF-1 and Mac-1 on neutrophils at different time points was detected by flow cytometer.

RESULTS: Induction of AP was confirmed by the serum levels of amylase and histological studies. The expression of ICAM-1 in pancreas increased significantly than that in the control group at all time points ($P < 0.05$ or $P < 0.01$), as well as the expression in lung except at 1 h. The expression of LFA-1 and Mac-1 on neutrophil in blood increased significantly in AP group than that in control group at several time points ($P < 0.05$ or $P < 0.01$). The amount of ascitic fluid and serum amylase level of AP group increased significantly than that of control group at all time points ($P < 0.05$ or $P < 0.01$). Parallel to these results, a significant neutrophil infiltration was found in pancreas and lung tissues of AP group rats.

CONCLUSION: Our findings suggest the important role for ICAM-1, LFA-1 and Mac-1 in mediating the development of AP from a local disease to a systemic illness. Upregulation of ICAM-1, LFA-1, Mac-1 and subsequent leukocyte infiltration appear to be significant events of pancreatic and pulmonary injuries in AP.

© 2006 The WJG Press. All rights reserved.

Key words: Acute pancreatitis; ICAM-1; LAF-1; Mac-1

Sun W, Watanabe Y, Wang ZQ. Expression and significance of ICAM-1 and its counter receptors LFA-1 and Mac-1 in experimental acute pancreatitis of rats. *World J Gastroenterol* 2006; 12(31): 5005-5009

http://www.wjgnet.com/1007-9327/12/5005.asp

INTRODUCTION

Acute pancreatitis (AP) is a disease of variable severity. Approximately 80% of patients have a relatively mild attack that resolves with few or no complications. The mortality rate is low. However, 20% of patients in whom pancreatic necrosis develops may incur systemic complications with a mortality rate as high as 40%[1]. Recent investigations have established that one of the earliest pathophysiologic events in pancreatitis is the colocalization of acinar cell organelles containing digestive and lysosomal enzymes, resulting in premature intracellular activation of proteases[2,3]. The individual pancreatic cell injury becomes magnified and propagated by inducing impaired microcirculation, leukocyte adhesion, and leukocyte infiltration. These become central events in the pathogenesis of pancreatic necrosis and extrapancreatic complications[4,5]. Organ dysfunction occurs in one of four patients with acute pancreatitis, and 60% of them die from pulmonary damage[6].

Intercellular adhesion molecule-1 (ICAM-1) is expressed on endothelial cells and is responsive to numerous inflammatory mediators[7]. It mediates both leukocyte adhesion and migration through the endothelium into tissues[8]. Lymphocyte function-associated antigen 1 (LFA-1) and Mac-1 are the counter receptors of ICAM-1, both of which are expressed on leukocytes and are related with the above mediating activities of ICAM-1[9].

The aim of the present study was to analyze the mechanism of upregulation and levels of expression of

ICAM-1 in the pancreas and lung tissues of AP, to detect the expression of LFA-1 and Mac-1 on neutrophils, and to explore the role of these adhesion molecules in the development of AP from a local disease to a systemic illness.

MATERIALS AND METHODS

Animals, anesthesia and surgical procedures

Sprague-Dawley rats (250 to 300 g) were fasted 12 h before the experiment but were allowed free access to water. Fluothane, oxygen and nitrous oxide were used in surgical anesthesia (2 L/min). All rats underwent a 2-cm-long midline laparotomy, and the pancreatic duct was visualized entering the duodenum. The duct was cannulated and AP was induced by retrograde intraductal injection of 5% chenodeoxycholic bile acid (0.1 mL/kg, Wako Pure Chemical Industries, Ltd., Osaka, Japan) for 2 min. After injection, the pancreatic duct was ligated and the abdomen was closed.

Experimental design

A total of 50 rats were allocated to control group and AP group (25 rats in each). The rats of control group only received laparotomy without retrograde intraductal injection of 5% chenodeoxycholic bile acid of pancreas and the pancreatic duct ligation. Blood samples (2 mL) were drawn through inferior vena cava. Pancreatic and lung tissues were removed and processed as indicated below before the rats were killed at 1, 3, 6, 12 and 24 h after induction of pancreatitis (n = 5 per group). Ascitic fluid was quantified by estimation of weight of towels after absorption of the ascitic fluid from the abdominal cavity (assuming 1 g = 1 mL).

Amylase in serum

One milliliter blood was sampled to measure amylase in plasma using the RaBA-SUPER (Kyoto First Science Ltd., Kyoto, Japan) kit.

Tissue immunohistochemical staining

For immunohistochemical staining, pancreatic and lung tissues were immediately snap-frozen in Freon precooled in liquid nitrogen and embedded in OCT embedding medium (Tissue-Tek, Miles Inc, Elkhart, USA). Cryostat sections (5 μm) were fixed in acetone for 10 min, and endogenous peroxidase activity was quenched by incubation of methanol with 0.3% H_2O_2 for 5 min. After rinsing with 0.02 mol PBS, the sections were incubated with primary anti-ICAM-1 antibody (Santa Cruz Biotechnology, Inc., California, USA) diluted at 1:400 in antibody dilution (Dako Corporation, Carpinteria, CA, USA) for 10 min in moist chamber at room temperature. Unbound antibodies were washed from the tissue three times in PBS for 3 min, incubated for 10 min with the secondary biotinylated anti-mouse IgG antibody (LSAB Ⅱ kit, Dako Corporation, Carpinteria, CA, USA), and then washed three times for 3 min. The sections were incubated with the LSAB reagent (LSAB® 2 System, HRP KIT, DAKO Corporation, Carpinteria, CA, USA) for 10 min, washed and developed in DAB solution. Finally, the slides were fixed in alcohol, counter-stained 3 times with hematoxylin for 10 min, and covered with DAKO Glycergel. NIH Image 1.61/ppc software was used to detect the density of positive area of slides.

Flow cytometry analyses

Blood (1 mL) was anticoagulated with 2% EDTA (0.2 mL). Leukocyte-rich plasma was obtained by centrifugation for 10 min at 1500 r/min. The erythrocytes were then lysed 15 min with 4 mL of hemolysin twice. The leukocyte pellet was washed once with PBS and resuspended with 1 mL of PBS. Leukocytes suspensions (100 μL) were mixed with 20 μL of FITC-labeled monoclonal antibody anti-LFA-1 (CD11a/CD18) (BD Pharmingen, San Diego, CA, USA), FITC-labeled anti-Mac-1 (CD11b/CD18) (BD Pharmingen, San Diego, CA, USA), and FITC-labeled IgG (Sigama, Saint Louis, Missouri, USA) that acted as a nonspecific control antibody. It was then incubated at 4℃ for 30 min, washed twice in ice-cold PBS, resuspended in 1 mL of PBS and kept on ice until analyzed. Flow cytometry was performed on an FACScan (Coulter Epics XL, USA). Data were collected for forward scatter, side scatter, and fluorescence on the FL1 channel (530 nm) with Coulter Elite software. Cells were analyzed with a gate setting for neutrophils and twenty thousand cell counts were accumulated for analysis. Green fluorescence (FL1) was determined and mean fluorescence intensity (MFI) was calculated. The nonspecific binding (IgG) in control group and AP group was measured at MFI values of 2.81 (0.57) and 3.74 (0.97) units, respectively.

Statistical analysis

Results are expressed as means and standard errors of the mean. Differences between AP and control groups were judged by using the Student's t test for parametric data. P values of less than 0.05 were considered significant.

RESULTS

Serum amylase

In AP group rats, there was a marked increase in serum amylase from 1 to 24 h with a peak value after 6 h (Figure 1).

Ascitic fluid

The amount of ascitic fluid in AP group increased significantly than that in control group at the same time point (Figure 2).

Histological findings

A low level of ICAM-1 expression was observed in the pancreas and lung tissues in control rats. ICAM-1 expression in the pancreas of AP rats was significantly increased above control levels at 1 h, and continued to increase until 12 h and remained elevated at that level for the whole observation period (24 h) (Figure 3).

ICAM-1 expression in the lung of AP rats was significantly increased above control levels at 3 h, and continued to increase until 24 h (Figure 4). Immunohistochemical analysis showed that overexpression of ICAM-1 was localized in small venules and capillaries.

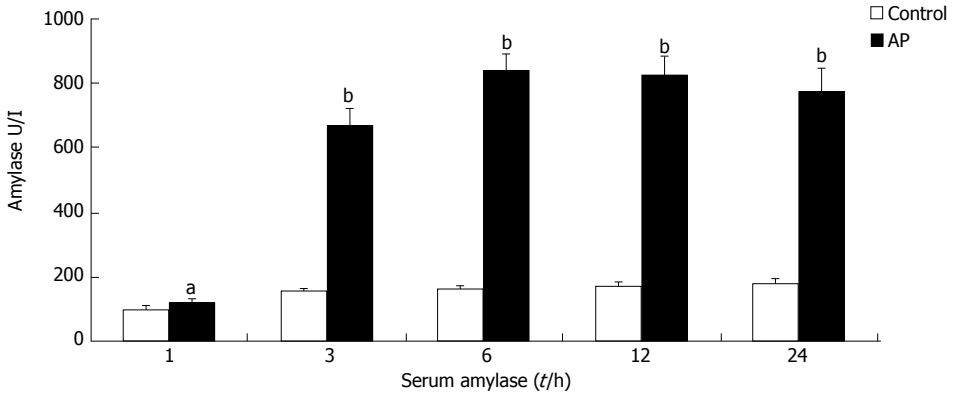

Figure 1 The time course of serum amylase. $^{a}P < 0.05$ *vs* control at the same point, $^{b}P < 0.01$ *vs* control at the same point.

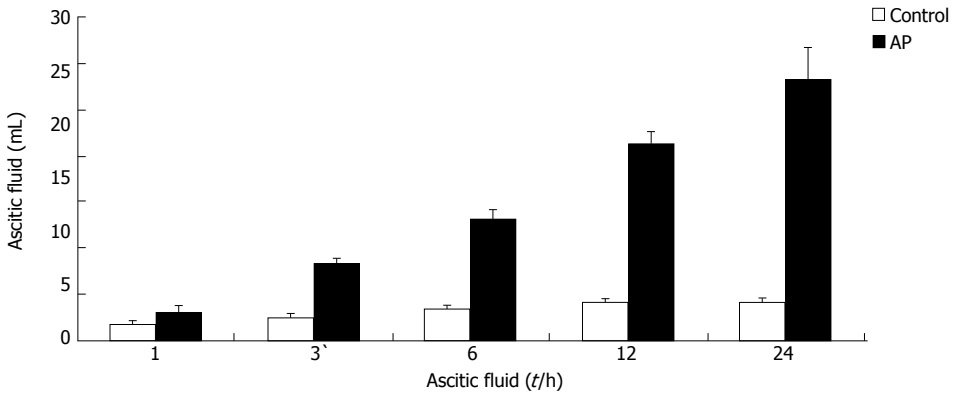

Figure 2 The time course of ascitic fluid output. $^{b}P < 0.01$ *vs* control at the same time point.

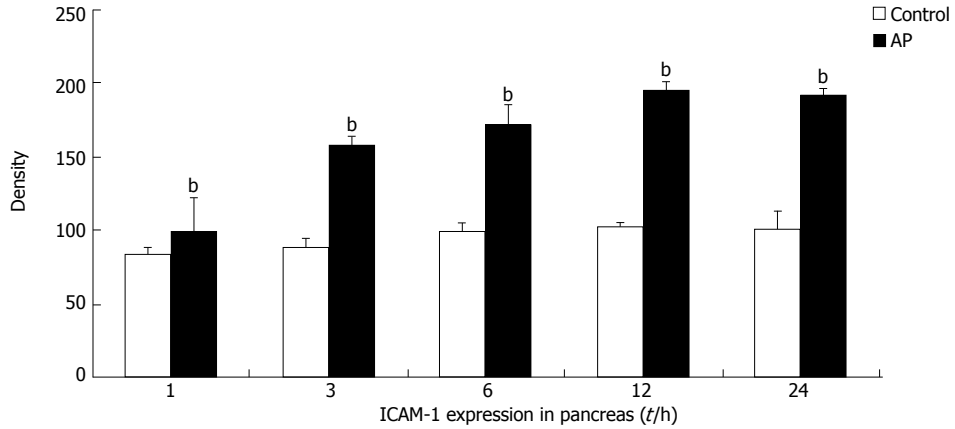

Figure 3 ICAM-1 expression in pancreas. $^{b}P < 0.01$ *vs* control at the same time point.

Expression of LFA-1 and Mac-1 on leukocytes

The expression of LFA-1 and Mac-1 on leukocytes in AP group increased significantly than that in the control group (Figure 5).

DISCUSSION

Intra-acinar cell activation of digestive enzyme zymogens is generally believed to be an early event in pancreatitis. Most researchers, however, believe that subsequent nonacinar cell phenomena, including the activation and recruitment of inflammatory cells, play a critical role in determining the ultimate severity of the disease. Nonacinar cell phenomena including the local generation and release of proinflammatory factors and activation of circulating inflammatory cells are also believed to couple pancreatic injury to distant organ complications, such as lung injury.

Leukocyte sequestration within areas of injury and inflammation is a multistep process that begins with leukocyte activation. It involves the adhesion of circulating activated inflammatory cells to microvascular endothelial surfaces, and culminates in the transmigration of those cells across the endothelial barrier and into the involved tissue. Currently available evidence indicates that the adhesion of activated leukocytes, including neutrophils, to endothelial surfaces results from the interaction of leukocyte surface proteins, such as CD11/CD18, with endothelial cell surface adhesion molecules such as ICAM-1.

Surprisingly, little attention has been paid to probing the relationship between the ICAM-1 and its counter receptors (LFA-1, Mac-1). Furthermore, the time course of LFA-1

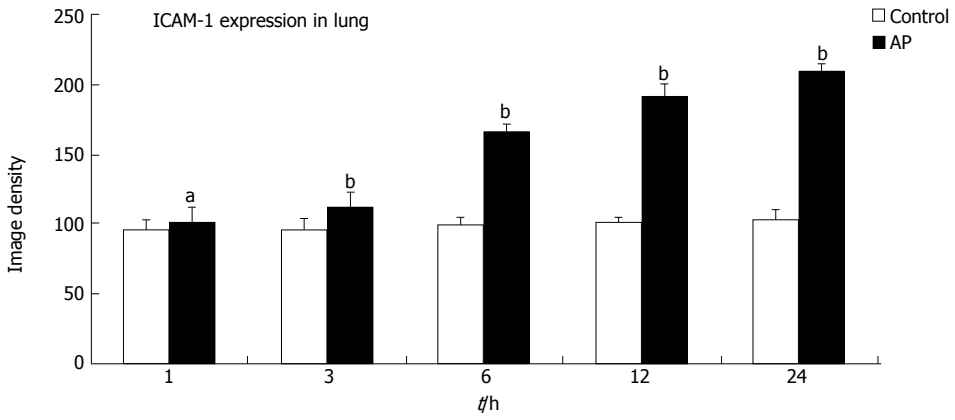

Figure 4 ICAM-1 expression in lung. $^aP < 0.05$, $^bP < 0.01$ *vs* control at the same time points.

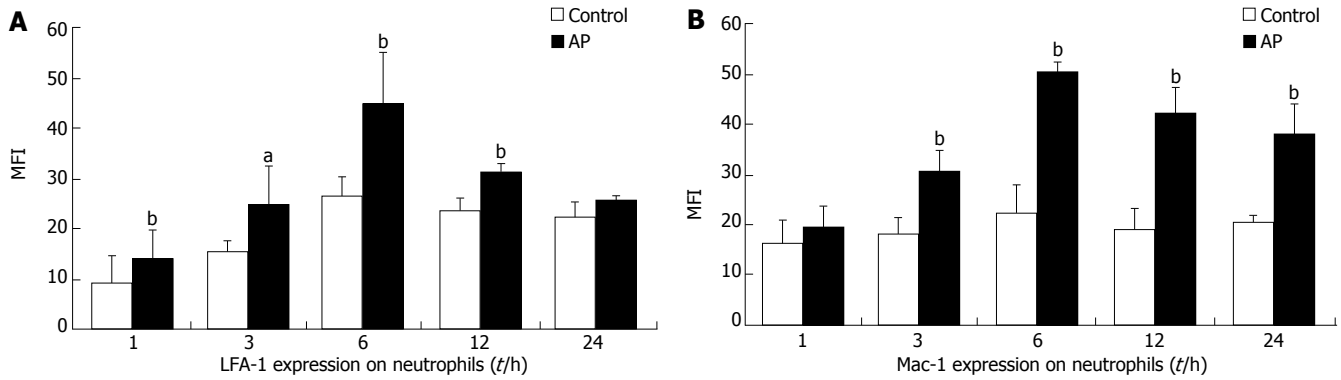

Figure 5 LFA-1 (**A**), Mac-1 (**B**) expression on neutrophils. $^aP < 0.05$, $^bP < 0.01$ *vs* control at the same time point.

and Mac-1 expression in severe acute pancreatitis has not been studied. We serially investigated LFA-1 and Mac-1 expression on circulatory neutrophils and ICAM-1 expression in pancreas and lung tissues of AP rats in the current study.

ICAM-1 is an adhesion molecule expressed on endothelial cells that mediates both firm adhesion of leukocytes to the endothelium and transmigration and infiltration of marginated leukocytes into the organs[7]. Endothelial ICAM-1 is enhanced by hypoxia[10] and cytokines, including, among others, interleukin-6, interleukin-8 and tumor necrosis factor-α[2,7]. These inflammatory mediators, oxygen free radicals, and cytokines respond early in the pathogenesis process of acute pancreatitis[2,11,12].

ICAM-1 is a counter receptor for LFA-1(CD11a/CD18) and Mac-1(CD11b/CD18). The interaction between ICAM-1 and CD11/CD18 is a major determinant of leukocyte adhesion to endothelial cells[13], a phenomenon that is itself a prelude to leukocyte transmigration across the endothelial barrier and into areas of inflammation.

The multistep model of leukocyte emigration provides a conceptual framework describing the molecular recognition mechanism that leads from cell capture to adhesion strengthening and transmigration. Neutrophils use selectins to tether to inflamed endothelium and subsequently arrest at septic sites in the vasculature through binding of the β_2-integrins[14,15]. The β_2-integrins family members LFA-1 and Mac-1 are involved in firm adhesion of neutrophils to endothelial cells[16]. Intravital microsopy in mice and rats has shown that CD11a and CD11b each contribute significantly to firm adhesion, and concurrent blocking of both β_2-integrins family is required for complete inhibition of human and canine neutrophil transmigration[17-19]. Furthermore, the adhesion complex CD11b/CD18, induced by inflammatory cytokines, has been demonstrated to play a crucial role in neutrophil-induced tissue damage by enhancing neutrophil migration and adhesiveness[20].

We probed the expression of adhesion molecules such as ICAM-1 and its counter receptors, LFA-1 and Mac-1 in AP. We found expression of ICAM-1 was markedly upregulated in AP, as well as the expression of LFA-1 and Mac-1 on neutrophils. ICAM-1 is also upregulated in organs beyond the pancreas in severe pancreatitis. Our experiments showed an increased expression of ICAM-1 in the endothelium of venules and capillaries within the lungs at 6 h in AP, followed by massive leukocyte infiltration. The results of this study imply the important roles for ICAM-1 and its counter receptors LFA-1 and Mac-1 in the pathogenesis of pancreatic and systemic injury in acute necrotizing pancreatitis. The current studies are consistent with the concept that expression of ICAM-1, LFA-1 and Mac-1 in the pancreas during AP is a critical link in the development of tissue injury and organ dysfunction. Although overexpression of inflammatory mediators do play an important role in pathogenesis but the molecular mechanisms of the whole cascade, i.e. cell surface molecules, signaling into the cell and resulting response of the cell has still not been worked out. It

may be possible to prevent tissue injury and necrosis and thereby to minimize the possibility for subsequent secondary infection by administering antibodies or other drugs in AP. Further studies are in progress to define the window of opportunity.

REFERENCES

1 **Steer ML**. Etiology and pathophysiology of acute pancreatitis. In: Go VLV, Dimagno EP, Gardner JD, Lebenthal E, Reber A, Scheele GA, eds. The pancreas：biology, pathophysiology, and disease. New York: Raven, 1993: 581-592

2 **Kingsnorth A**. Role of cytokines and their inhibitors in acute pancreatitis. *Gut* 1997; **40**: 1-4

3 **Bhatia M**. Inflammatory response on the pancreatic acinar cell injury. *Scand J Surg* 2005; **94**: 97-102

4 **Klar E**, Messmer K, Warshaw AL, Herfarth C. Pancreatic ischaemia in experimental acute pancreatitis: mechanism, significance and therapy. *Br J Surg* 1990; **77**: 1205-1210

5 **Werner J**, Dragotakes SC, Fernandez-del Castillo C, Rivera JA, Ou J, Rattner DW, Fischman AJ, Warshaw AL. Technetium-99m-labeled white blood cells: a new method to define the local and systemic role of leukocytes in acute experimental pancreatitis. *Ann Surg* 1998; **227**: 86-94

6 **Mann DV**, Hershman MJ, Hittinger R, Glazer G. Multicentre audit of death from acute pancreatitis. *Br J Surg* 1994; **81**: 890-893

7 **Springer T**A. Adhesion receptors of the immune system. *Nature* 1990; **346**: 425-434

8 **Pober JS**, Cotran RS. The role of endothelial cells in inflammation. *Transplantation* 1990; **50**: 537-544

9 **Smith CW**. Endothelial adhesion molecules and their role in inflammation. *Can J Physiol Pharmacol* 1993; **71**: 76-87

10 **Zünd G**, Uezono S, Stahl GL, Dzus AL, McGowan FX, Hickey PR, Colgan SP. Hypoxia enhances induction of endothelial ICAM-1: role for metabolic acidosis and proteasomes. *Am J Physiol* 1997; **273**: C1571-1580

11 **Schoenberg MH**, Büchler M, Gaspar M, Stinner A, Younes M, Melzner I, Bültmann B, Beger HG. Oxygen free radicals in acute pancreatitis of the rat. *Gut* 1990; **31**: 1138-1143

12 **Norman JG**, Franz MG, Fink GS, Messina J, Fabri PJ, Gower WR, Carey LC. Decreased mortality of severe acute pancreatitis after proximal cytokine blockade. *Ann Surg* 1995; **221**: 625-631; discussion 631-634

13 **Kelly KJ**, Williams WW Jr, Colvin RB, Meehan SM, Springer TA, Gutierrez-Ramos JC, Bonventre JV. Intercellular adhesion molecule-1-deficient mice are protected against ischemic renal injury. *J Clin Invest* 1996; **97**: 1056-1063

14 **Lawrence MB**, Springer TA. Leukocytes roll on a selectin at physiologic flow rates: distinction from and prerequisite for adhesion through integrins. *Cell* 1991; **65**: 859-873

15 **Konstantopoulos K**, McIntire LV. Effects of fluid dynamic forces on vascular cell adhesion. *J Clin Invest* 1997; **100**: S19-S23

16 **Smith CW**, Marlin SD, Rothlein R, Toman C, Anderson DC. Cooperative interactions of LFA-1 and Mac-1 with intercellular adhesion molecule-1 in facilitating adherence and transendothelial migration of human neutrophils in vitro. *J Clin Invest* 1989; **83**: 2008-2017

17 **Kurose I**, Anderson DC, Miyasaka M, Tamatani T, Paulson JC, Todd RF, Rusche JR, Granger DN. Molecular determinants of reperfusion-induced leukocyte adhesion and vascular protein leakage. *Circ Res* 1994; **74**: 336-343

18 **Furie MB**, Tancinco MC, Smith CW. Monoclonal antibodies to leukocyte integrins CD11a/CD18 and CD11b/CD18 or intercellular adhesion molecule-1 inhibit chemoattractant-stimulated neutrophil transendothelial migration in vitro. *Blood* 1991; **78**: 2089-2097

19 **Entman ML**, Youker K, Shoji T, Kukielka G, Shappell SB, Taylor AA, Smith CW. Neutrophil induced oxidative injury of cardiac myocytes. A compartmented system requiring CD11b/CD18-ICAM-1 adherence. *J Clin Invest* 1992; **90**: 1335-1345

20 **Jaeschke H**, Farhood A, Smith CW. Neutrophil-induced liver cell injury in endotoxin shock is a CD11b/CD18-dependent mechanism. *Am J Physiol* 1991; **261**: G1051-G1056

S- Editor Wang J **L- Editor** Zhu LH **E- Editor** Bi L

PO Box 2345, Beijing 100023, China
www.wjgnet.com
wjg@wjgnet.com

World J Gastroenterol 2006 August 21; 12(31): 5010-5016
World Journal of Gastroenterology ISSN 1007-9327
© 2006 The WJG Press. All rights reserved.

CLINICAL RESEARCH

Comparison between empirical prokinetics, Helicobacter test-and-treat and empirical endoscopy in primary-care patients presenting with dyspepsia: A one-year study

Wayne HC Hu, SK Lam, Cindy LK Lam, WM Wong, KF Lam, KC Lai, YH Wong, Benjamin CY Wong, Annie OO Chan, CK Chan, Gabriel M Leung, WM Hui

Wayne HC Hu, SK Lam, Cindy LK Lam, WM Wong, KC Lai, YH Wong, Benjamin CY Wong, Annie OO Chan, CK Chan, WM Hui, Department of Medicine, University of Hong Kong, Hong Kong, China
KF Lam, Department of Statistics and Actuarial Science, University of Hong Kong, Hong Kong, China
Gabriel M Leung, Department of Community Medicine, University of Hong Kong, Hong Kong, China
Supported by the peptic ulcer research fund and the Simon To fund for swallowing and functional gastrointestinal disorders
Correspondence to: Dr. Wayne Hu, University Department of Medicine, Queen Mary Hospital, Pokfulam Road, Hong Kong, China. hchu@hku.hk
Telephone: +852-28554742
Received: 2005-08-24 Accepted: 2005-10-26

Abstract

AIM: To investigate the optimal strategy to treat dyspeptic patients in primary care.

METHODS: Dyspeptic patients presenting to primary care outpatient clinics were randomly assigned to: (1) empirical endoscopy, (2) *H pylori* test-and-treat, and (3) empirical prokinetic treatment with cisapride. Early endoscopy was arranged if patients remained symptomatic after 2 wk. Symptom severity, quality-of-life (SF-36) as well as patient preference and satisfaction were assessed. All patients underwent endoscopy by wk 6. Patients were followed up for one year.

RESULTS: Two hundred and thirty four patients were recruited (163 female, mean age 49). 46% were *H pylori* positive. 26% of *H pylori* tested and 25% of empirical prokinetic patients showed no improvement at wk 2 follow-up and needed early endoscopy. 15% of patients receiving empirical cisapride responded well to treatment but peptic ulcer was the final diagnosis. Symptom resolution and quality-of-life were similar among the groups. Costs for the three strategies were HK$4343, $1771 and $1750 per patient. 66% of the patients preferred to have early endoscopy.

CONCLUSION: The three strategies are equally effective. Empirical prokinetic treatment was the least expensive but peptic ulcers may be missed with this treatment. The *H pylori* test-and-treat was the most cost-effective option.

© 2006 The WJG Press. All rights reserved.

Key words: Empirical endoscopy; Dyspeptic patients; *H pylori* test-and treat

Hu WHC, Lam SK, Lam CLK, Wong WM, Lam KF, Lai KC, Wong YH, Wong BCY, Chan AOO, Chan CK, Leung GM, Hui WM. Comparison between empirical prokinetics, Helicobacter test-and-treat and empirical endoscopy in primary-care patients presenting with dyspepsia: A one-year study. *World J Gastroenterol* 2006; 12(31): 5010-5016

http://www.wjgnet.com/1007-9327/12/5010.asp

INTRODUCTION

Dyspepsia, defined as pain or discomfort centered in the upper abdomen, is a common complaint, affecting 18.5% of the population in our locality[1]. Underlying pathology ranges from functional dyspepsia, peptic ulcer to gastrointestinal cancer. Among the various aetiologies, functional dyspepsia is the most common diagnosis in community-based patients[2]; Up to 79% of dyspeptic patients referred from primary care for open-access endoscopy have normal endoscopic findings[3].

Primary care medicine is the first point of presentation for dyspeptic patients. Studies have suggested that dyspepsia alone accounts for 20%-70% of all gastrointestinal consultations with general practitioners; up to one-third of these patients may eventually be referred to a gastroenterologist[4]. The financial burden for diagnosis and treatment of this common condition is therefore great.

It is unclear how dyspepsia should be investigated and treated in primary care settings, but there are several common approaches. Empirical endoscopy would theoretically be the gold standard in diagnostic accuracy, but it is expensive and invasive. Empirical H2 receptor antagonist therapy has been extensively studied, but has not been shown to have superior cost-benefit over empirical endoscopy[5]. In addition, there may be concerns that antisecretory treatment may mask symptoms of

gastric cancer and lead to a delay in diagnosis.

Another possible approach is to test for *H pylori*. The close association between *H pylori* and chronic gastritis that accompanies peptic ulcer disease and gastric cancer offers an opportunity to screen for organic disease based on the presence of the bacterium.

An alternate approach is empirical prokinetic treatment. Studies have demonstrated that cisapride and domperidone are beneficial in the treatment of functional dyspepsia over placebo[6-8]. By adopting this approach, the majority of patients with functional dyspepsia could be treated appropriately whereas the smaller number of patients with organic dyspepsia may not benefit from this treatment. Persistence of dyspepsia in this group would then lead to endoscopy and diagnosis. The small delay in diagnosis is not unreasonable since, in real life, many primary care doctors would give antacids to dyspeptic patients without alarm features and monitor symptoms on follow-up. Cisapride has been withdrawn from most markets since this study was carried out though related drugs such as mosapride are still in use in some countries.

In this study, we investigated empirical endoscopy, *H pylori* test-and-treat, and empirical prokinetic therapy as possible diagnostic and treatment strategies in primary-care patients presenting with dyspepsia.

MATERIALS AND METHODS

Patients aged 18 or older presenting with a primary complaint of previously uninvestigated dyspepsia in four government-run primary-care clinics in Hong Kong were recruited for the study. Dyspepsia was defined as pain or discomfort centered in the upper abdomen[9]. History and physical examination were carried out by the primary care physician.

Exclusion criteria for this study were current intake of drugs other than antacids for dyspepsia, previous peptic ulcer disease, history of gastric surgery, presence of malignancy within the previous five years, history of intake of aspirin or non-steroidal anti-inflammatory drugs in the previous four weeks, presence of alarm symptoms, such as weight loss and gastrointestinal haemorrhage, and clinical suspicion of an organic cause of dyspepsia. In addition, those with a family history of sudden death, history of palpitations, co-existing intake of drugs that may interact with cisapride and those with an abnormal electrocardiogram were excluded.

After obtaining written consent for the trial, a locally-validated 13-C urea breath test was administered in the primary care clinic. The details of the breath test have been described elsewhere, and had a sensitivity and specificity of 96.5% and 97.7% respectively[10]. The results were not disclosed to the patients until after the trial unless the patients were randomised into the *H pylori* test-and-treat group.

The patients were subsequently reassessed by one of the investigators in the gastroenterological unit of Queen Mary Hospital within 24 h of initial presentation. Inclusion and exclusion criteria were checked and a complete physical examination was performed. Electrocardiography was also performed on all recruited patients. A previously validated Chinese (Hong Kong) version of the SF-36 health survey[11], as well as a validated twelve-item dyspepsia symptom severity score[12] were administered. Patients were then randomised using a computer-generated sequence into one of three investigation and treatment groups as detailed below.

This study was approved by the research and ethics committee, faculty of medicine, the University of Hong Kong.

Empirical endoscopy

Patients in this group received endoscopy on the initial day attending the gastrointestinal unit. Oesophagogastrod uodenoscopy was performed by one of the investigators and an endoscopic diagnosis was made. A rapid urease test was performed if the patient had peptic ulcer disease and biopsies for histology were taken for gastric ulcers and suspicious lesions.

Patients with organic diagnoses were treated accordingly. *H pylori* eradication therapy was given to those with peptic ulcers or erosive gastritis with a positive test for the bacterium.

Dyspeptic patients with normal endoscopy or non-erosive gastritis were considered to have functional dyspepsia and were treated with cisapride 5 mg three times daily for six weeks.

Helicobacter test-and-treat

Patients who tested positive for *H pylori* in the 13C urease breath test received omeprazole 20 mg twice daily, amoxycillin 1 g twice daily, and clarithromycin 500 mg twice daily. The local eradication rate for this regimen is 87.8%[13]. Patients who tested negative for *H pylori* were treated as functional dyspepsia and given cisapride 5 mg three times daily for six weeks.

Empirical prokinetics

All patients in this group were given cisapride 5 mg three times daily for six weeks regardless of *H pylori* positivity (Figure 1).

Follow-up

Patients were followed-up at two weeks, six weeks and one year after the initial treatment. At follow-up the dyspepsia symptom score and SF-36 survey were administered by an assessor blinded to the purpose of the study. Satisfaction of patients in regard to treatment was assessed at wk 6 using a 4-point Likert scale ranging from dissatisfied to very satisfied. Patients were asked whether they prefered endoscopy or a trial of drug treatment as the initial approach to their dyspspsia.

If the symptoms had not improved after two weeks of treatment, endoscopy was performed on group 2 and 3 patients. Organic pathology discovered at endoscopy was treated appropriately. For patients who had empirical endoscopy, no further investigation was offered unless there was a change in symptoms that raised suspicion of organic disease. At the end of the study, all patients who had not previously received endoscopy received an oesoph agoduodenogastroscopy for a definitive diagnosis.

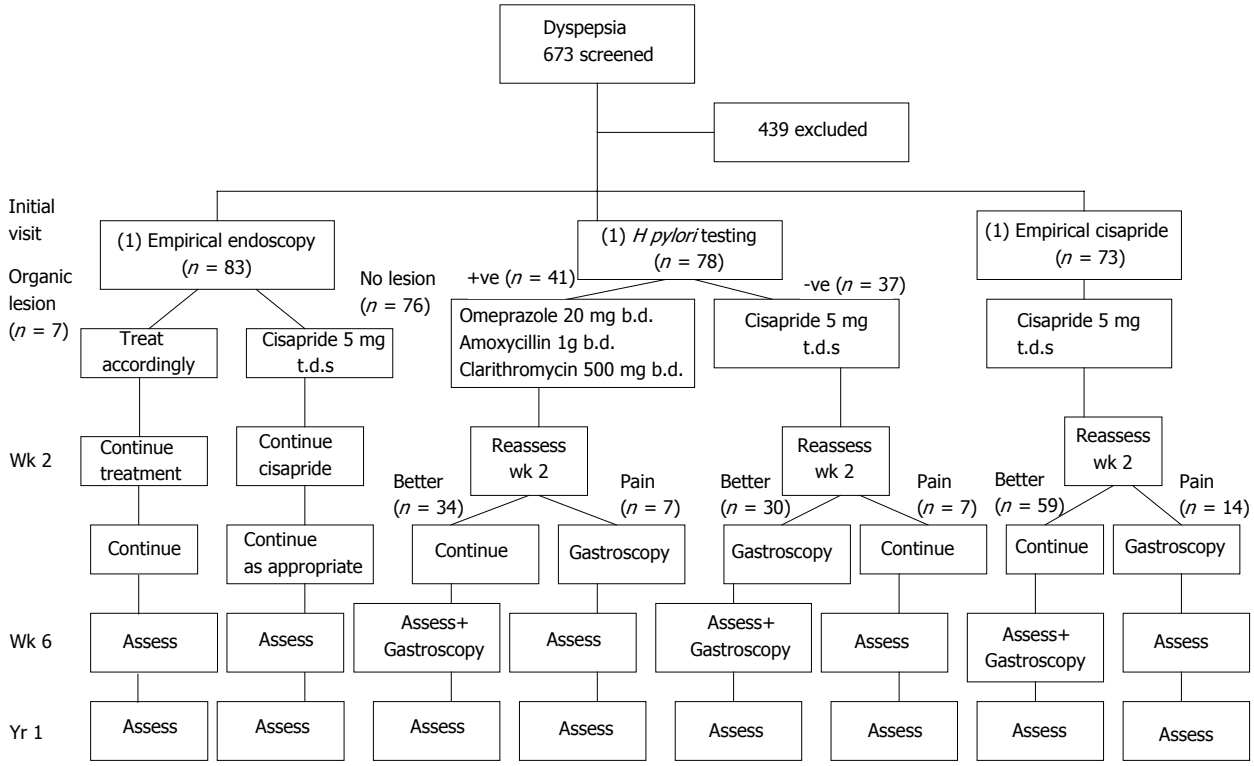

Figure 1 Flow chart for the three diagnostic and treatment arms.

Sample size

Sample size was determined using NCSS PASS 2002 (NCSS statistical software, Kaysville, Utah, USA). A previous study designed to develop dyspepsia severity scores found a mean of 20.7 and standard deviation of 3.8 in a local population of dyspeptic patients. The difference in mean symptom score between patients who felt better and those who did not was 1.2[12]. Based on this result we estimated that 70 patients in each of the three groups would report a two-point difference in the mean symptom score between one group and the other two with a power of 0.9 and significance level of 0.05.

Cost analysis

Cost analysis was performed to examine the economic implications of the three strategies studied. The analysis was carried out from the provider's perspective, given all three treatment regimens were ambulatory procedures and therefore, assumed to incur similar direct personal, indirect and intangible costs to the patients and society generally. Costs were calculated according to the gazetted list of fees and charges of the Hong Kong Hospital Authority and hospital formulary costs.

Statistical analysis

The study was analysed according to intention-to-treat. Comparison of baseline dyspepsia scores and quality-of-life domains was made using one-way ANOVA and the Kruskal-Wallis test. Correlation between baseline dyspepsia scores and quality-of-life domains was calculated using Kendall's tau. Quality-of-life and dyspepsia symptom scores after treatment were compared among the three groups using a repeated measures procedure. The null hypotheses regarding the main effects of time points and three treatment groups, and the interaction between treatment groups and different time points were tested using multivariate analysis. Age and sex were also included as covariables. Statistical analyses were performed using SPSS version 11.0 for windows (SPSS inc., Chicago, Illinois, USA).

RESULTS

Patients and demographic characteristics

Six hundred and seventy three patients were screened for inclusion in the study, of which 234 were recruited (mean age 49, range 18-79, 163 female). Reasons for exclusion included dyspepsia under treatment (257), refusal to participate (49), previous investigations for dyspepsia (51), non-steroidal antiinflammatory agent intake[25], previous gastric surgery or peptic ulcer history[34], alarm symptoms[12] abnormal electrocardiogram[6] and other malignancy[3]. Baseline characteristics of the three groups of patients are as tabulated in Table 1. All patients completed the six-week treatment assessment period. One hundred and eighty one (77.4% overall; 77.1%, 69.2% and 86.3% in the three respective groups) attended one-year follow-up.

Diagnoses

Group one patients had endoscopy before commencing treatment and provided the most accurate data of the underlying diagnoses of dyspepsia. Among the 83 patients receiving empirical endoscopy 76 (91.5%) had normal findings or non-erosive gastritis, two (2.4%) had gastric erosions, four (4.8%) had peptic ulcer and one (1.2%) had

Table 1 Baseline characteristics

Group	Mean age	Sex (M/F)	*H pylori* positive (%)	Mean baseline dyspepsia score
Empirical endoscopy (n = 83)	52.5 ± 13.2	25/58	37 (44.6%)	20.4 ± 4.0
H pylori test-and-treat (n = 78)	46.5 ± 14.2	24/54	41 (52.6%)	20.8 ± 3.8
Empirical prokinetics (n = 73)	48.6 ± 13.0	22/51	30 (41.1%)	19.6 ± 3.8
P value	0.01[a]	0.99	0.35	0.16

[a]$P < 0.05$.

Table 2 Endoscopic findings in the three groups n (%)

	Normal	Gastritis/ duodenitis	Gastric erosions	Gastric ulcer	Duodenal ulcer	Oesop-hagitis
Empirical endoscopy (n = 83)	49 (59)	27 (32.5)	2 (2.4)	3 (3.6)	1 (1.2)	1 (1.2)
H pylori test-and-treat (n = 78)	61 (78.2)	10 (12.8)	4 (5.1)	0	3 (3.9)	0
Empirical prokinetics (n = 73)	46 (63.0)	17 (23.3)	4 (5.5)	3 (4.1)	3 (4.1)	0

Table 3 Mean dyspepsia symptom score by initial diagnosis

	Baseline	Wk 6	Yr 1
Non-ulcer dyspepsia (n = 210)[1]	20.3	15.0	20.1
Duodenal Ulcer (n = 7)	19.1	13.0	13.7
Gastric ulcer (n = 6)	23.3	18.7	14.4
Oesopohagitis (n = 1)	17.0	12.0	17.0
Gastric erosion (n = 10)	29.0	15.0	12.0
All causes organic dyspepsia (n = 24)[1]	20.5	15.1	16.3

[1]P = 0.045 between the two groups with age and sex as covariables.

oesophagitis. Endoscopic findings for the three groups are summarised in Table 2. Overall, 46% of patients were *H pylori* positive.

Fourteen patients (18%) randomised to the *H pylori* test-and-treat group had persistent dyspepsia after two weeks of treatment and needed early endoscopy. None of these patients had organic dyspepsia; two had non-erosive gastritis and 12 had normal endoscopy. At six weeks, three patients with symptom resolution after treatment were found to have duodenal ulcers and three had gastroduodenal erosions. All of these patients were originally tested to be positive for *H pylori* and had received appropriate eradication therapy, but the ulcer had not completely healed by the time of endoscopy.

Fourteen patients (19%) randomised to empirical prokinetic therapy had persistent dyspepsia at two weeks follow-up and received early endoscopy. Eleven of these patients had normal endoscopy results or non-erosive gastritis, two had gastroduodenal erosions and one had a gastric ulcer. More importantly, at the final diagnostic endoscopy, two patients were found to have erosions, duodenal ulcer and gastric ulcer among those who reported symptomatic improvement after treatment. If endoscopy was not performed, these organic lesions would have likely been missed.

All gastric ulcers detected in this study were benign.

Symptom severity

The mean baseline dyspepsia severity score was 20.3 ± 3.9 and was not significantly different among the three groups studied (Table 1). After six weeks of treatment, there was a decrease in mean symptom score to 15.0 ± 2.9 (5.6, 5.6 and 4.4 for empirical endoscopy, *H pylori* testing and empirical cisapride, respectively). On one year follow-up, the mean dyspepsia score increased to 19.7 ± 7.2. Repeated measures analysis showed no significant effect of treatment group on dyspepsia severity. However, patients with organic causes of dyspepsia were less symptomatic than those with non-ulcer dyspepsia after one year (Table 3).

Quality-of-life

The SF-36 health-related quality-of-life scores for the various domains are tabulated in Table 4. At baseline, there was no difference in quality-of-life between the three groups of patients. There was a significant correlation between the severity of dyspepsia and the BP, GH, MH, RE, RP, SF and VT domains, but not the PF domain at baseline. At one-year follow-up, there was a general decline in quality-of-life when compared to 6 wk follow-up. Repeated measures analysis again showed no significant effect of treatment group on quality of life.

Cost analysis

The calculated six-week investigation and treatment costs for empirical endoscopy, *H pylori* test-and-treat and empirical prokinetic therapies are HK$4343, $1771 and $1750 per patient, respectively.

Patient satisfaction and preference

Overall, 81% of patients were either satisfied or very satisfied with treatment. There was no significant difference in satisfaction among the three diagnostic paradigms that were tested (Table 5). 66% of patients preferred to have endoscopy before taking medication; the differences in scores were again not significant among groups (Table 5).

Side effects of cisapride

No patient given cisapride reported significant palpitations or other side effects. All patients were able to complete the six-week course of treatment.

DISCUSSION

Underlying diagnoses of dyspepsia range from peptic ulcer, gastric cancer to functional dyspepsia, and it may

Table 4 Median SF-36 quality-of-life scores for the three diagnostic and treatment groups (wk 0/ wk 6/ one year). Transformed scores out of 100

	BP	GH	MH	PF	RE	RP	SF	VT
All groups	63/84/51	40/47/42	72/72/60	95/95/85	100/100/67	50/100/75	88/88/75	45/50/50
Empirical endoscopy	62/84/51	50/52/50	72/72/60	95/95/85	100/100/67	75/100/75	75/100/75	50/45/50
H pylori test-and-treat	62/84/51	40/45/36	68/72/60	95/95 80	67/100/33	50/100/75	75/88/63	45/45/45
Empirical Prokinetics	72/84/52	39/49/45	76/72/64	95/95/85	100/100/67	50/100/75	88/88/75	45/50/50

BP: bodily pain; GH: general health; MH: mental health; PF: physical functioning; RE: role-emotional; RP: role-physical; SF: social functioning; VT: vitality.

be difficult to determine cause without investigation. Age, symptom assessment and even the presence of alarm symptoms appear to be poor predictors of underlying pathology[14]. However, despite the prevalence and potential high economic cost of this condition, the optimal strategy to manage dyspepsia in primary care practice remains unclear[15].

Community-based studies have generally indicated that peptic ulcer and cancer are uncommon causes of dyspepsia[2], accounting for only 20% of patients referred to open-access endoscopy[3]. Therefore, it is reasonable that any investigative and treatment strategy should be effective in functional dyspepsia, representing the bulk of patients. The optimal approach to investigation and treatment would aim to: (1) provide the most efficacious and cost-effective treatment for functional dyspepsia, (2) allow for prompt treatment of patients with peptic ulcer, with *H pylori* eradication, if appropriate, (3) correctly diagnose malignant lesions so that definitive treatment can be given and (4) to avoid unnecessary treatment for patients with functional dyspepsia.

Several treatments have generally been shown to be better than placebo in the treatment of functional dyspepsia. Meta-analysis studies have estimated a 20% gain of H2 antagonist treatment against placebo[16], but there may not be global improvement in symptoms[17]. Proton pump inhibitors may benefit dyspeptic patients with co-existing reflux[18]; a study reported 10% therapeutic gain over placebo treatment but efficacy seems to be limited to patients with ulcer-like symptoms[19]. Cisapride has also been extensively evaluated in studies, though many studies had methodological deficiencies[20]. Meta-analyses have generally found a therapeutic gain of 36%-39% when compared to placebo[16,21] but publication bias may have contributed to these results. *H pylori* eradication is likewise controversial, with some studies showing a long-term benefit[22], and others showing no benefit[23].

Various options have been suggested in the investigation and treatment of patients presenting with dyspepsia. The American Gastroenterological Association has suggested that patients over the age of 45 years or those with alarm features should have empirical endoscopy[24]. For younger patients without alarm symptoms, there may be several options: (1) empirical medical therapy (antisecretory drugs or prokinetics) with investigation for therapeutic failures, (2) immediate diagnosis with endoscopy, (3) testing for *H pylori* and studying positive subjects, and (4) testing for *H pylori* and treating positive cases with eradication[24]. An Asian Pacific guideline also suggested a trial of antisecretory drugs or prokinetics for 2-4 wk[25]. Among the alternatives, empirical prokinetic treatment has not been evaluated in previous studies.

Table 5 Patient satisfaction and preference among the three diagnostic and treatment groups *n* (%)

	Very satisfied	Satisfied	Neutral	Dissatisfied	Prefer initial endoscopy
Empirical endoscopy (n = 83)	7 (8.4)	59 (71)	14 (17)	3 (3.6)	63 (75.9)
H pylori test-and-treat (n = 78)	6 (7.7)	53 (67.9)	14 (17.9)	5 (6.4)	48 (61.5)
Empirical prokinetics (n = 73)	6 (8.2)	56 (76.7)	8 (11.0)	3 (4.1)	43 (59.0)

Bytzer randomised 414 patients into groups receiving empirical endoscopy or ranitidine[5]. Empirical treatment was associated with higher costs of ulcer drug use and a greater number of sick days. It was also notable that 33% of patients had organic causes of dyspepsia, compared to 8% in the present study. Another study comparing *H pylori* test-and-treat with endoscopy found greater patient satisfaction with endoscopy but comparable symptoms and sick leave days between the two groups[26]. Comparative costs depend on individual centres. An American study reported similar costs between *H pylori* testing and empirical endoscopy[27] whereas another claimed lower costs for *H pylori* eradication[28]. A decision analysis supported a trial of proton pump inhibitor before endoscopy or test-and-treat[29]. Test and endoscopy in primary care has been shown to increase endoscopy rates without benefit in symptom relief or quality of life[30]. It is of note, however, that proton pump inhibitors may not be as efficacious in Asian populations; a paper using the same outcome instruments as the present study failed to show any benefit of four-week lansoperazole treatment over placebo in patients with functional dyspepsia[31].

Most of the studies comparing different diagnostic strategies concentrated on cost. Less data is available concerning symptom resolution and quality of life. Many dyspeptic patients presenting for medical care have a fear of serious disease and malignancy[32]. In addition

they are more anxious than non-presenters with similar complaints[1]. It is possible that a completely normal endoscopy may relieve some of the anxiety. Indeed a study on barium meal in dyspeptic patients who were referred from general practice showed that the examination increased management confidence and allayed patients' anxiety[33]. In this study, however, we failed to show any significant difference in symptom relief among the three groups, indicating that the comforting effect of a negative endoscopy may not be an important factor in the cure of functional dyspepsia.

We have calculated the cost of treatment and empirical endoscopy is most costly, followed by *H pylori* test-and-treat and the lowest cost was for empirical prokinetics. The high cost for empirical endoscopy in the present study is related to the relatively low rates of endoscopy for patients randomised to the other groups. In the *H pylori* test-and-treat and empirical cisapride groups, 18% and 19% of patients respectively had persistent dyspepsia after two weeks of treatment and needed early endoscopy. In Bytzer's study, 136 out of 206 patients randomised to empirical H2 blocker therapy had therapeutic failure and required endoscopy[5]. The difference may be due to differences in length of follow-up and also the lower rate of organic pathology in our study. In our population with dyspepsia, 8.5% had organic causes (empirical endoscopy group), compared with 33% prevalence of organic dyspepsia reported by Bytzer. The overall rate of organic dyspepsia is also lower than the rate in our previous study on open-access endoscopy, where 21% had organic pathology[3]. The difference probably reflects differences in referral patterns, with family physicians referring more severe cases of dyspepsia for immediate endoscopy in the previous study.

We observed a high relapse rate of dyspepsia generally, with the mean dyspepsia severity score returning to the initial level on one-year follow-up. This is due to non-ulcer/functional dyspepsia being the predominant diagnosis in 92% of patients. Functional dyspepsia is a chronic disease that persists in patients; a study reported that 74% of dyspeptic patients are still symptomatic two years after the initial diagnosis[34]. In contrast, the few patients with peptic ulcer in this study tended to remain asymptomatic after the ulcer has healed and these patients in fact have a better prognosis as far as symptom relapse is concerned.

Both empirical endoscopy and *H pylori* testing appeared to be safe options with similar patient satisfaction. All patients with organic dyspepsia were tested to be positive for *H pylori* and had appropriate eradication therapy. However, the main drawback in the study was the absence of malignancy; it was not possible to predict whether gastric cancers would have been missed by any approach. Although rare in younger patients, gastric cancers may present without sinister symptoms. A Canadian study reported a prevalence of 1.05 per thousand patients under 45 years presenting with dyspepsia without alarm symptoms[35]. We may expect higher numbers in Asia, with a higher population prevalence of gastric cancer. The possibility of missing or delay in diagnosis of gastric malignancies needs to be considered in empirical treatment approaches.

Since all patients with duodenal or gastric ulcer were positive for *H pylori*, another approach may be performing endoscopy only on those with a positive 13C urea breath test. Such an approach may prevent 54% of endoscopies. However, 60% of the patients with gastric erosions were negative for *H pylori*; inappropriate treatment of these patients may potentially lead to progression into ulcer disease.

There is limited data on empirical prokinetic treatment. Because of association with cardial arrhythmia, the drug has been withdrawn in most markets. However, related drugs, such as mosapride, are still used in some countries and this study may throw light on the effectiveness of other prokinetic agents. In the present study we found this strategy to be associated with the lowest cost but with similar outcome regarding symptomatic improvement. However, interestingly, although prokinetic treatment was not targeted for the treatment of peptic ulcers, six patients (2 gastric ulcer, 2 duodenal ulcer, 2 gastric erosions) reported symptomatic improvement after cisapride alone and would not have received definitive therapy. Because of the dangers of misdiagnosing patients with peptic ulcers, empirical cisapride therapy could not be recommended. Despite concerns over potential QT interval prolongation and ventricular arrhythmia, a relatively low dose of 5 mg three times daily was not associated with any adverse event in our sample of patients.

In conclusion, most patients presenting to primary care physicians with dyspepsia appear to have non-ulcer dyspepsia, which is associated with a high one-year relapse rate. Empirical endoscopy, *H pylori* test-and-treat and empirical prokinetic treatments appear to have similar efficacy in improvement of dyspepsia and quality-of-life. Empirical prokinetics may result in organic lesions being missed in diagnosis. Most patients preferred having endoscopy first, if given the choice, but this is the most expensive option. *H pylori* test-and-treat is the most cost-effective safe treatment.

ACKNOWLEDGMENTS

We are indebted to the doctors and nurses of the Violet Peel, Sai Ying Pun, Aberdeen and Ap Lei Chau government outpatient clinics for recruitment of patients and Ms. Monique Chong, Ms. Vera Tang, Ms. Wong Ka-Wah, Ms. Diana Chang, Ms. Wing-Ping Yung for their assistance in the endoscopy room.

REFERENCES

1 **Hu WH**, Wong WM, Lam CL, Lam KF, Hui WM, Lai KC, Xia HX, Lam SK, Wong BC. Anxiety but not depression determines health care-seeking behaviour in Chinese patients with dyspepsia and irritable bowel syndrome: a population-based study. *Aliment Pharmacol Ther* 2002; **16**: 2081-2088

2 **Bernersen B**, Johnsen R, Straume B, Burhol PG, Jenssen TG, Stakkevold PA. Towards a true prevalence of peptic ulcer: the Sørreisa gastrointestinal disorder study. *Gut* 1990; **31**: 989-992

3 **Wong BC**, Chan CK, Wong KW, Wong WM, Yuen MF, Lai KC, Hu WH, Lau GK, Lai CL, Lam SK. Evaluation of a new referral system for the management of dyspepsia in Hong Kong: role of open-access upper endoscopy. *J Gastroenterol Hepatol*

2000; **15**: 1251-1256
4 **Knill-Jones RP**. Geographical differences in the prevalence of dyspepsia. *Scand J Gastroenterol Suppl* 1991; **182**: 17-24
5 **Bytzer P**, Hansen JM, Schaffalitzky de Muckadell OB. Empirical H2-blocker therapy or prompt endoscopy in management of dyspepsia. *Lancet* 1994; **343**: 811-816
6 **Rösch W**. Cisapride in non-ulcer dyspepsia. Results of a placebo-controlled trial. *Scand J Gastroenterol* 1987; **22**: 161-164
7 **Carvalhinhos A**, Fidalgo P, Freire A, Matos L. Cisapride compared with ranitidine in the treatment of functional dyspepsia. *Eur J Gastroenterol Hepatol* 1995; **7**: 411-417
8 **Deruyttere M**, Lepoutre L, Heylen H, Samain H, Pennoit H. Cisapride in the management of chronic functional dyspepsia: a multicenter, double-blind, placebo-controlled study. *Clin Ther* 1987; **10**: 44-51
9 **Drossman DA**, Corazziari E, Talley NJ. Rome II: the functional gastrointestinal disorders: diagnosis, pathophysiology, and treatment: a multinational consensus. 2nd ed. Mc Lean, Virginia, USA: Degnon Associates, 2000
10 **Wong WM**, Wong BC, Wong KW, Fung FM, Lai KC, Hu WH, Yuen ST, Leung SY, Lau GK, Lai CL, Chan CK, Go R, Lam SK. (13)C-urea breath test without a test meal is highly accurate for the detection of Helicobacter pylori infection in Chinese. *Aliment Pharmacol Ther* 2000; **14**: 1353-1358
11 **Lam CL**, Gandek B, Ren XS, Chan MS. Tests of scaling assumptions and construct validity of the Chinese (HK) version of the SF-36 Health Survey. *J Clin Epidemiol* 1998; **51**: 1139-1147
12 **Hu WH**, Lam KF, Wong YH, Lam CL, HUIi WM, Lai KC, Wong BC, Lam SK. The Hong Kong index of dyspepsia: a validated symptom severity questionnaire for patients with dyspepsia. *J Gastroenterol Hepatol* 2002; **17**: 545-551
13 **Lai KC**, Hui WM, Wong BC, Hu WH, Lam SK. Ulcer-healing drugs are required after eradication of Helicobacter pylori in patients with gastric ulcer but not duodenal ulcer haemorrhage. *Aliment Pharmacol Ther* 2000; **14**: 1071-1076
14 **Wallace MB**, Durkalski VL, Vaughan J, Palesch YY, Libby ED, Jowell PS, Nickl NJ, Schutz SM, Leung JW, Cotton PB. Age and alarm symptoms do not predict endoscopic findings among patients with dyspepsia: a multicentre database study. *Gut* 2001; **49**: 29-34
15 **Hu WH**, Talley NJ. Functional (non-ulcer) dyspepsia: unexplained but not unmanageable. *Med J Aust* 1998; **168**: 507-512
16 **Dobrilla G**, Comberlato M, Steele A, Vallaperta P. Drug treatment of functional dyspepsia. A meta-analysis of randomized controlled clinical trials. *J Clin Gastroenterol* 1989; **11**: 169-177
17 **Talley NJ**, McNeil D, Hayden A, Piper DW. Randomized, double-blind, placebo-controlled crossover trial of cimetidine and pirenzepine in nonulcer dyspepsia. *Gastroenterology* 1986; **91**: 149-156
18 **Fennerty MB**. Use of antisecretory agents as a trial of therapy. *Gut* 2002; **50** Suppl 4: iv63-iv66
19 **Talley NJ**, Meineche-Schmidt V, Paré P, Duckworth M, Räisänen P, Pap A, Kordecki H, Schmid V. Efficacy of omeprazole in functional dyspepsia: double-blind, randomized, placebo-controlled trials (the Bond and Opera studies). *Aliment Pharmacol Ther* 1998; **12**: 1055-1065
20 **Bytzer P**. H-2 receptor antagonists and prokinetics in dyspepsia: a critical review. *Gut* 2002; **50** Suppl 4: iv58-iv62
21 **Finney JS**, Kinnersley N, Hughes M, O'Bryan-Tear CG, Lothian J. Meta-analysis of antisecretory and gastrokinetic compounds in functional dyspepsia. *J Clin Gastroenterol* 1998; **26**: 312-320
22 **McColl K**, Murray L, El-Omar E, Dickson A, El-Nujumi A, Wirz A, Kelman A, Penny C, Knill-Jones R, Hilditch T. Symptomatic benefit from eradicating Helicobacter pylori infection in patients with nonulcer dyspepsia. *N Engl J Med* 1998; **339**: 1869-1874
23 **Blum AL**, Talley NJ, O'Moráin C, van Zanten SV, Labenz J, Stolte M, Louw JA, Stubberöd A, Theodórs A, Sundin M, Bolling-Sternevald E, Junghard O. Lack of effect of treating Helicobacter pylori infection in patients with nonulcer dyspepsia. Omeprazole plus Clarithromycin and Amoxicillin Effect One Year after Treatment (OCAY) Study Group. *N Engl J Med* 1998; **339**: 1875-1881
24 American Gastroenterological Association medical position statement: evaluation of dyspepsia. *Gastroenterology* 1998; **114**: 579-581
25 **Talley NJ**, Lam SK, Goh KL, Fock KM. Management guidelines for uninvestigated and functional dyspepsia in the Asia-Pacific region: First Asian Pacific Working Party on Functional Dyspepsia. *J Gastroenterol Hepatol* 1998; **13**: 335-353
26 **Lassen AT**, Pedersen FM, Bytzer P, Schaffalitzky de Muckadell OB. Helicobacter pylori test-and-eradicate versus prompt endoscopy for management of dyspeptic patients: a randomised trial. *Lancet* 2000; **356**: 455-460
27 **Silverstein MD**, Petterson T, Talley NJ. Initial endoscopy or empirical therapy with or without testing for Helicobacter pylori for dyspepsia: a decision analysis. *Gastroenterology* 1996; **110**: 72-83
28 **Ofman JJ**, Etchason J, Fullerton S, Kahn KL, Soll AH. Management strategies for Helicobacter pylori-seropositive patients with dyspepsia: clinical and economic consequences. *Ann Intern Med* 1997; **126**: 280-291
29 **Spiegel BM**, Vakil NB, Ofman JJ. Dyspepsia management in primary care: a decision analysis of competing strategies. *Gastroenterology* 2002; **122**: 1270-1285
30 **Delaney BC**, Wilson S, Roalfe A, Roberts L, Redman V, Wearn A, Hobbs FD. Randomised controlled trial of Helicobacter pylori testing and endoscopy for dyspepsia in primary care. *BMJ* 2001; **322**: 898-901
31 **Wong WM**, Wong BC, Hung WK, Yee YK, Yip AW, Szeto ML, Fung FM, Tong TS, Lai KC, Hu WH, Yuen MF, Lam SK. Double blind, randomised, placebo controlled study of four weeks of lansoprazole for the treatment of functional dyspepsia in Chinese patients. *Gut* 2002; **51**: 502-506
32 **Howell S**, Talley NJ. Does fear of serious disease predict consulting behaviour amongst patients with dyspepsia in general practice? *Eur J Gastroenterol Hepatol* 1999; **11**: 881-886
33 **Conry BG**, McLean AM, Farthing MJ. Diagnostic and therapeutic efficacy of barium meal examination: a prospective evaluation in general practice. *BMJ* 1989; **299**: 1443-1445
34 **Jones R**, Lydeard S. Dyspepsia in the community: a follow-up study. *Br J Clin Pract* 1992; **46**: 95-97
35 **Breslin NP**, Thomson AB, Bailey RJ, Blustein PK, Meddings J, Lalor E, VanRosendaal GM, Verhoef MJ, Sutherland LR. Gastric cancer and other endoscopic diagnoses in patients with benign dyspepsia. *Gut* 2000; **46**: 93-97

S- Editor Wang J **L- Editor** Lutze M **E- Editor** Bai SH

PO Box 2345, Beijing 100023, China
www.wjgnet.com
wjg@wjgnet.com

World J Gastroenterol 2006 August 21; 12(31): 5017-5020
World Journal of Gastroenterology ISSN 1007-9327
© 2006 The WJG Press. All rights reserved.

RAPID COMMUNICATION

Effects of chronic therapy with non-steroideal antinflammatory drugs on gastric permeability of sucrose: A study on 71 patients with rheumatoid arthritis

Marta Maino, Nicola Mantovani, Roberta Merli, Giulia Martina Cavestro, Gioacchino Leandro, Lucas Giovanni Cavallaro, Vincenzo Corrente, Veronica Iori, Alberto Pilotto, Angelo Franzè, Francesco Di Mario

Marta Maino, Roberta Merli, Giulia Martina Cavestro, Lucas Giovanni Cavallaro, Veronica Iori, Francesco Di Mario, Chair of Gastroenterology, Department of Clinical Science, University of Parma, Italy
Nicola Mantovani, Gastroenterological Unit, Azienda Ospedaliera "C.Poma", Mantova, Italy
Gioacchino Leandro, IRCCS Castellana Grotte (BA), Italy
Vincenzo Corrente, Angelo Franzè, Gastroenterological Unit, Azienda Ospedaliera, Parma, Italy
Alberto Pilotto, IRCCS San Giovanni Rotondo (FG), Italy
Correspondence to: Professor Francesco Di Mario, Chair of Gastroenterology, Department of Clinical Science, University of Parma, Via Gramsci 14, Parma 43100, Italy. francesco.dimario@unipr.it
Telephone: +39-521-702772 Fax: +39-521-701582
Received: 2005-07-20 Accepted: 2005-10-26

Abstract

AIM: To evaluate the gastric permeability after both acute and chronic use of non-steroidal anti-inflammatory drugs (NSAIDs) and to assess the clinical usefulness of sucrose test in detecting and following NSAIDs- induced gastric damage mainly in asymptomatic patients and the efficacy of a single pantoprazole dose in chronic users.

METHODS: Seventy-one consecutive patients on chronic therapy with NSAIDs were enrolled in the study and divided into groups A and B (group A receiving 40 mg pantoprazole daily, group B only receiving NSAIDs). Sucrose test was performed at baseline and after 2, 4 and 12 wk, respectively. The symptoms in the upper gastrointestinal tract were recorded.

RESULTS: The patients treated with pantoprazole had sucrose excretion under the limit during the entire follow-up period. The patients without gastroprotection had sucrose excretion above the limit after 2 wk, with an increasing trend in the following weeks (P = 0.000). A number of patients in this group revealed a significantly altered gastric permeability although they were asymptomatic during the follow-up period.

CONCLUSION: Sucrose test can be proposed as a valid tool for the clinical evaluation of NSAIDs- induced gastric damage in both acute and chronic therapy. This tecnique helps to identify patients with clinically silent gastric damages. Pantoprazole (40 mg daily) is effective and well tolerated in chronic NSAID users.

© 2006 The WJG Press. All rights reserved.

Key words: Non-steroidal anti inflammatory drugs; Gastric mucosal permeability; Gastrointestinal toxicity; Sucrose test; Pantoprazole

Maino M, Mantovani N, Merli R, Cavestro GM, Leandro G, Cavallaro LG, Corrente V, Iori V, Pilotto A , Franzè A, Di Mario F. Effects of chronic therapy with non-steroideal antinflammatory drugs on gastric permeability of sucrose: A study on 71 patients with rheumatoid arthritis. *World J Gastroenterol* 2006; 12(31): 5017-5020

http://www.wjgnet.com/1007-9327/12/5017.asp

INTRODUCTION

Non-steroidal anti-inflammatory drugs (NSAIDs) are largely consumed among the general populations worldwide, representing one of the most prescribed drugs[1-6]. The main factor limiting their use is a high rate of adverse events, especially gastrointestinal toxicity[7]. Although only a small number of patients develop serious gastrointestinal complications, they represent a large number of patients due to the widespread use of NSAIDs[7-9].

Gastrointestinal toxicity is often clinically silent even in high risk groups due to the intrinsic analgesic activity of NSAIDs[10]. Therefore aspecific symptoms such as dyspepsia, heartburn, nausea, vomiting or abdominal pain are frequently ignored by patients suffering, for example, from a chronic pain due to the underlying ostheoarticular diseases.

A recent meta-analysis indicates that the association between use of NSAIDs and dyspepsia is unclear because of the variability of the terminology used in literature to report GI symptoms[11]. Taking the "strict" definition of dyspepsia into account, based solely on epigastric pain-related symptoms, NSAIDs increase the risk of dyspepsia of 36%, which is useful for creating standard definitions. Endoscopy for diagnosis of NSAIDs- induced upper gastrointestinal damage is precise, sensitive and easy to perform, but it cannot be proposed as a screening test,

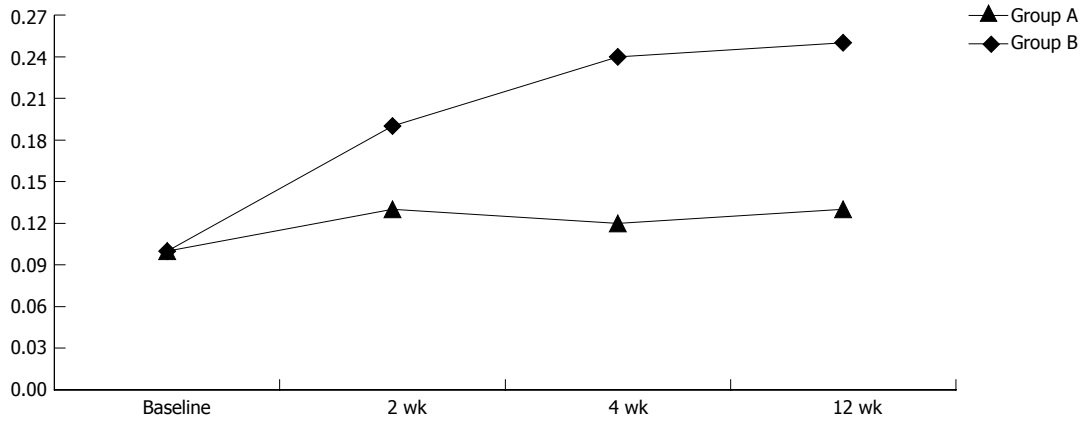

Figure 1 Sucrose test in patients of the study. Group A = pantoprazole 40 mg and Group B = no therapy.

especially in asymptomatic patients. Gastrointestinal permeability is usually tested to assess the small bowel function in many diseases such as coeliac disease and inflammatory bowel disease[12,13]. Sucrose test is a simple, economic and non-invasive test for the assessment of gastric permeability and correlates with alterations detected with histology as previously demonstrated[14]. Some authors have proposed sucrose test as an index for monitoring hypertensive gastropathy, confirming its clinical usefulness. Which is the best strategy in preventing NSAIDs-related adverse events in the gastrointestinal tract is still controversial[16].

Many clinical trials have analyzed the efficacy and safety of concurrent administration of NSAIDs and misoprostol, H_2 blockers or proton pump inhibitors (PPIs) in reducing the occurrence of serious gastrointestinal events.

Available data show that PPIs are well tolerated and effective in preventing and treating non steroideal antinflammatory drug-related mucosal lesions of the gastrointestinal tract[17-20].

The aim of this study was to establish the clinical usefulness of sucrose test in early identification of both acute and chronic gastric mucosal damage irrespective of the presence of any symptoms and to define the efficacy of a single daily PPI administration in protecting gastric mucosa in patients requiring long term treatment with NSAIDs.

MATERIALS AND METHODS

Patients

Seventy-one consecutive outpatients (38 females, 33 males, mean age 53 years, range 26-78 years) with chronic use of NSAIDs (ASA, diclofenac, celecoxib) for rheumatic diseases (rheumatoid arthritis, ostheoarthritis) were enrolled in the study. None of them consumed gastroprotective agents (PPIs, H_2-blockers, misoprostol).

All patients were asymptomatic at baseline and had no previous history of peptic ulcer, gastroesophageal surgery or malignancies.

Sucrose permeability test (40 mg of sucrose in 100 mL of water) was performed at baseline. The patients were divided in group A (31 patients receiving 40 mg pantoprazole daily) and group B (40 patients not receiving PPI therapy). Sucrose test was repeated 2, 4, and 12 wk after follow-up (Figure 1).

The patients gave their informed consent according to the principles of the Helsinki Declaration. Symptoms were recorded according to the presence of mild dyspepsia as previously defined (score 0 = absence; score 1 = mild dyspepsia)[11].

Sucrose test

To evaluate gastric permeability, the subjects were requested to ingest 40 g sucrose in 100 mL of water after fasted for 8 h. Urine samples were collected in the following 6 h into a container with the addition of 2 mL of 20% chlorohexidine to prevent bacterial degradation. No food or liquid intake (except a glass of water) was allowed during urine collection. Urine samples were refrigerated and taken to the laboratory within 24 h. An aliquot was stored at -20℃ for subsequent analysis.

Sucrose assay was based on its hydrolysation by β-fructosidase to glucose and fructose. Glucose was measured by the hexokinase method. The concentration of the reduced nicotinamide adenine dinucleotide phosphate (NADP) was measured at 340 nm. Results were expressed as the percentage of excretion of the ingested dose of sucrose and the normal range was < 0.15% sucrose.

Statistical analysis

Data were reported as mean ± SD. Values of sucrose test at baseline and after 2 and 4 wk in group B were evaluated with Wilcoxon signed-rank test. Comparison between sucrose test values in groups A and B was made with Mann-Whitney test. Statistical Program for Social Sciences (SPSS Inc., Chicago, Illinois 60606) was used for calculations. $P < 0.05$ was considered statistically significant.

RESULTS

At baseline all the patients showed a mean sucrose value of 0.10% ± 0.08%. Two weeks later, all the patients underwent an additional sucrose test which showed a mean value of 0.13% ± 0.08% in group A and 0.19% ± 0.06% in group B. At wk 4 sucrose test showed 0.12% ± 0.07% in the pantoprazole group and 0.24% ± 0.07% in the other group ($P = 0.000$). Sucrose test was then repeated after 12 wk, showing the mean values of 0.13% ± 0.10% in group A and 0.25% ± 0.07% in group B respectively ($P = 0.000$) (Figure 1). At wk 4 the mean value of sucrose

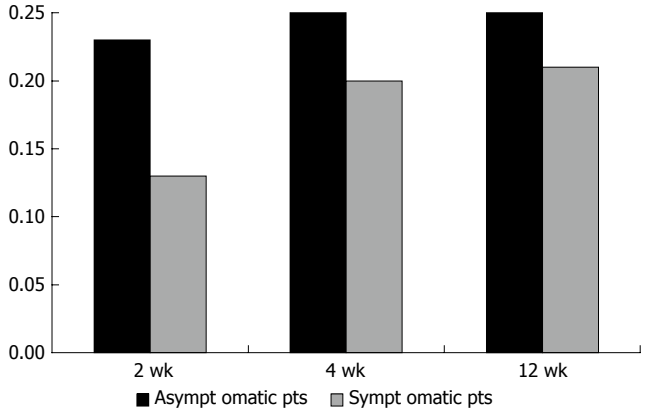

Figure 2 Sucrose test in Group B patients accordingly to their symptoms.

test decreased in 7 patients of group A and in 15 patients of group B. At wk 12 the mean value of sucrose test decreased in 3 an additional 3 patients of group A and none of group B. Forty-six patients (21 in group A and 25 in group B) completed the follow-up (wk 12).

Regarding the consumption of NSAIDs, the patients on ASA therapy and without gastroprotection showed the mean sucrose values of 0.10% ± 0.05% at baseline and 0.17% ± 0.06%, 0.24% ± 0.07%, 0.28% ± 0.06% at 2, 4 and 12 wk respectively.

In the patients consuming diclofenac and without gastroprotection, the mean sucrose values were 0.08% ± 0.03% at baseline and 0.24% ± 0.05%, 0.31% ± 0.06% and 0.30 ± 0.04% at 2, 4 and 12 wk respectively.

In the patients consuming celecoxib, the mean sucrose values were 0.08% ± 0.04% at baseline and 0.04% ± 0.05%, 0.17% ± 0.04% and 0.15% ± 0.06% at 2, 4 and 12 wk respectively. The patients with no symptoms accounted for 47.4%, 31.6% and 32.6% after 2, 4 and 12 wk respectively.

In group B, 37.5%, 32% and 28% of the patients remained asymptomatic after 2, 4 and 12 wk respectively. However, their mean sucrose values were 0.13% ± 0.08%, 0.20% ± 0.06% and 0.21% ± 0.05% during the follow-up period.

The mean sucrose values in patients complaining of mild dyspepsia in group B were 0.23% ± 0.04%, 0.25% ± 0.08% and 0.25% ± 0.07% after 2, 4 and 12 wk (Figure 2).

DISCUSSION

Sucrose test is considered as a useful tool for predicting the presence of clinically significant gastric disease after repetitive exposure to NSAIDs. Furthermore, sucrose test has been shown to be able to detect the differencies in both formulation and dose of NSAIDs[13].

NSAIDs reduce secretion of both bicarbonate and mucus, which are two of the most important gastric mucosal defensive mechanisms. In fact, bicarbonates stimulate cell renewal and repair, while mucus that coats over the mucosal lining provides a substrate for rapid restitution processes[21,22]. NSAIDs-induced damage allows permeation of macromolecules such as sucrose through the gastric mucosa.

We have previously proposed sucrose test together with serum pepsinogens as useful non-invasive methods to assess histological damages as they show a good relationship with histological findings[14].

In our study, the patients without PPI therapy showed increasing mean values of sucrose test during the acute period (0.19% after 2 wk and 0.24% after 4 wk) compared to the 0.10% at baseline with a statistically significant difference (P = 0.000), suggesting that sucrose test is able to detect gastric mucosal damages in acute ingestion of NSAIDs.

The subjects on chronic therapy showed a stable mean value of 0.25% after 12 wk, without any statistically significant difference (P = 0.39). This can be explained with the underlying mechanisms of NSAIDs-induced gastric damage involving both direct irritant action and systemic effect due to the inhibition of cyclooxigenase (COX) activity, which represents their main pharmacological effect. However, some authors suggest that COX-independent effects may be important in inducing mucosal cell apoptosis and microvascular perturbation with subsequent acute lesions[23].

Several studies have indicated that acute damage is much more widespread than damage observed after several days or weeks, indicating that the gastric mucosa has adaptive mechanisms that compensate for NSAIDs-induced injury[24]. Although the mechanisms involved in adaptation have not been defined yet, they reflect the capacity of a rapid epithelial repair, which in turn ependes on restitution and cell replication[25].

In our study, the symptomatic patients showed a urinary sucrose excretion above the normal limit, suggesting a gastric damage. However, an alteration in gastric permeability was also undetectable by endoscopy, suggesting that sucrose test represents the only available method to detect "mild to moderate" gastric damages.

In our study, a proportion of patients without gastroprotection revealed higher mean sucrose excretion than normal although they remained completely asymptomatic. These patients had a normal sucrose test at baseline and after 4 wk, but the excretion increased significantly in the following weeks, suggesting that they had mucosal damage. These results indicate an important clinical role of sucrose test which can be used to identify gastric mucosal damages irrespective of the presence of a clinical picture, which is often absent in NSAIDs-induced damage.

Sucrose test could be performed sequentially in high risk patients such as chronic users and rheumatic patients, and could identify early gastric mucosal damages.

The best strategy in preventing NSAIDs-induced damage is still controversial[13-19]. First, gastrointestinal complications may be avoided by the use of NSAID analgesics when possible. Second, using NSAIDs at their lowest effective dose decreases the risk of complications. Third, medical cotherapy could be used in patients with increased risk of complications. Finally, less injurious NSAIDs such as COX-2-specific inhibitors should developed to decrease the risk of gastrointestinal events.

Many studies have demonstrated that PPIs give a good protection against both duodenal and gastric ulcers in patients taking NSAIDs[27,28]. In addition, these drugs are safe and better tolerated as co-therapies than H_2-antagonists or prostaglandin.

Some studies have demonstrated a significant benefit of pantoprazole in preventing NSAIDs-induced peptic ulcers. There are also data regarding the efficacy of pantoprazole in preventing gastric lesions in rheumatic patients receiving long term treatment with NSAIDs. It has been reported that pantoprazole (40 mg daily) is well tolerated and more effective than placebo in preventing peptic ulcer in patients with rheumatic diseases on prolonged therapy with NSAIDs[28-30].

In our study, the patients on pantoprazole therapy showed lower mean values of sucrose test both in acute and chronic treatment compared with those without gastroprotection, confirming the efficacy of this drug in protecting gastric mucosa. The presence of upper gastrointestinal symptoms was lower in patients receiving pantoprazole during the period of observation.

In conclusion, sucrose test can be used in the follow-up of patients on chronic therapy with NSAIDs. In fact, this method is non-invasive, well tolerated and inexpensive, and can be easily performed sequentially in chronic users of NSAIDs. This approach helps identify high risk patients that should undergo an upper gastrointestinal endoscopy if economic consideration is taken into account.

REFERENCES

1 Retail & Provider Perspective, National Prescription Audit, 1999-2000. Plymouth, PA: IMS Health, 2000

2 Editoriale: Il mercato farmaceutico mondiale nel 2001. *Bollettino Informazione sui farmaci* 2001; **6**: 275-277

3 **Koutsos MI**, Shiff SJ, Rigas B. Can nonsteroidal anti-inflammatory drugs be recommended to prevent colon cancer in high risk elderly patients? *Drugs Aging* 1995; **6**: 421-425

4 **Sandler RS**, Halabi S, Baron JA, Budinger S, Paskett E, Keresztes R, Petrelli N, Pipas JM, Karp DD, Loprinzi CL, Steinbach G, Schilsky R. A randomized trial of aspirin to prevent colorectal adenomas in patients with previous colorectal cancer. *N Engl J Med* 2003; **348**: 883-890

5 **Baron JA**, Cole BF, Sandler RS, Haile RW, Ahnen D, Bresalier R, McKeown-Eyssen G, Summers RW, Rothstein R, Burke CA, Snover DC, Church TR, Allen JI, Beach M, Beck GJ, Bond JH, Byers T, Greenberg ER, Mandel JS, Marcon N, Mott LA, Pearson L, Saibil F, van Stolk RU. A randomized trial of aspirin to prevent colorectal adenomas. *N Engl J Med* 2003; **348**: 891-899

6 **Rogers J**, Kirby LC, Hempelman SR, Berry DL, McGeer PL, Kaszniak AW, Zalinski J, Cofield M, Mansukhani L, Willson P. Clinical trial of indomethacin in Alzheimer's disease. *Neurology* 1993; **43**: 1609-1611

7 **Hawkey CJ**. Nonsteroidal anti-inflammatory drug gastropathy. *Gastroenterology* 2000; **119**: 521-535

8 **Laine L**. Nonsteroidal anti-inflammatory drug gastropathy. *Gastrointest Endosc Clin N Am* 1996; **6**: 489-504

9 **Wolfe MM**, Lichtenstein DR, Singh G. Gastrointestinal toxicity of nonsteroidal antiinflammatory drugs. *N Engl J Med* 1999; **340**: 1888-1899

10 **Pounder R**. Silent peptic ulceration: deadly silence or golden silence? *Gastroenterology* 1989; **96**: 626-631

11 **Straus WL**, Ofman JJ, MacLean C, Morton S, Berger ML, Roth EA, Shekelle P. Do NSAIDs cause dyspepsia? A meta-analysis evaluating alternative dyspepsia definitions. *Am J Gastroenterol* 2002; **97**: 1951-1958

12 **Meddings JB**, Sutherland LR, Byles NI, Wallace JL. Sucrose: a novel permeability marker for gastroduodenal disease. *Gastroenterology* 1993; **104**: 1619-1626

13 **Davies NM**. Review article: non-steroidal anti-inflammatory drug-induced gastrointestinal permeability. *Aliment Pharmacol Ther* 1998; **12**: 303-320

14 Altavilla N, Moussa AM, Seghini P. Sucrose test and serum pepsinogens as markers of inflammation and damage in Helicobacter pylori related gastritis. *Gut* 2002; **51**: A1-A120

15 **Laine L**, Bombardier C, Hawkey CJ, Davis B, Shapiro D, Brett C, Reicin A. Stratifying the risk of NSAID-related upper gastrointestinal clinical events: results of a double-blind outcomes study in patients with rheumatoid arthritis. *Gastroenterology* 2002; **123**: 1006-1012

16 **Laine L**. Approaches to nonsteroidal anti-inflammatory drug use in the high-risk patient. *Gastroenterology* 2001; **120**: 594-606

17 **Silverstein FE**, Graham DY, Senior JR, Davies HW, Struthers BJ, Bittman RM, Geis GS. Misoprostol reduces serious gastrointestinal complications in patients with rheumatoid arthritis receiving nonsteroidal anti-inflammatory drugs. A randomized, double-blind, placebo-controlled trial. *Ann Intern Med* 1995; **123**: 241-249

18 **Silverstein FE**, Faich G, Goldstein JL, Simon LS, Pincus T, Whelton A, Makuch R, Eisen G, Agrawal NM, Stenson WF, Burr AM, Zhao WW, Kent JD, Lefkowith JB, Verburg KM, Geis GS. Gastrointestinal toxicity with celecoxib vs nonsteroidal anti-inflammatory drugs for osteoarthritis and rheumatoid arthritis: the CLASS study: A randomized controlled trial. Celecoxib Long-term Arthritis Safety Study. *JAMA* 2000; **284**: 1247-1255

19 **Bombardier C**, Laine L, Reicin A, Shapiro D, Burgos-Vargas R, Davis B, Day R, Ferraz MB, Hawkey CJ, Hochberg MC, Kvien TK, Schnitzer TJ. Comparison of upper gastrointestinal toxicity of rofecoxib and naproxen in patients with rheumatoid arthritis. VIGOR Study Group. *N Engl J Med* 2000; **343**: 1520-1528, 2 p following 1528

20 **Lichtenberger LM**. The hydrophobic barrier properties of gastrointestinal mucus. *Annu Rev Physiol* 1995; **57**: 565-583

21 **Slomiany BL**, Sarosiek J, Slomiany A. Gastric mucus and the mucosal barrier. *Dig Dis* 1987; **5**: 125-145

22 **Pilotto A**, Leandro G, Di Mario F, Franceschi M, Bozzola L, Valerio G. Role of Helicobacter pylori infection on upper gastrointestinal bleeding in the elderly: a case-control study. *Dig Dis Sci* 1997; **42**: 586-591

23 **Fiorucci S**, Antonelli E, Morelli A. Mechanism of non-steroidal anti-inflammatory drug-gastropathy. *Dig Liver Dis* 2001; **33** Suppl 2: S35-S43

24 **Graham DY**, Smith JL, Spjut HJ, Torres E. Gastric adaptation. Studies in humans during continuous aspirin administration. *Gastroenterology* 1988; **95**: 327-333

25 **Schmassmann A**. Mechanisms of ulcer healing and effects of nonsteroidal anti-inflammatory drugs. *Am J Med* 1998; **104**: 43S-51S; discussion 79S-80S

26 **Micklewright R**, Lane S, Linley W, McQuade C, Thompson F, Maskrey N. Review article: NSAIDs, gastroprotection and cyclo-oxygenase-II-selective inhibitors. *Aliment Pharmacol Ther* 2003; **17**: 321-332

27 **Hawkey CJ**, Karrasch JA, Szczepañski L, Walker DG, Barkun A, Swannell AJ, Yeomans ND. Omeprazole compared with misoprostol for ulcers associated with nonsteroidal antiinflammatory drugs. Omeprazole versus Misoprostol for NSAID-induced Ulcer Management (OMNIUM) Study Group. *N Engl J Med* 1998; **338**: 727-734

28 **Bianchi Porro G**, Lazzaroni M, Imbesi V, Montrone F, Santagada T. Efficacy of pantoprazole in the prevention of peptic ulcers, induced by non-steroidal anti-inflammatory drugs: a prospective, placebo-controlled, double-blind, parallel-group study. *Dig Liver Dis* 2000; **32**: 201-208

29 **Regula J**, Deckers CPM, Raps D.Comparison of 20 mg and 40 mg Pantoprazole vs 20 mg Omeprazole in the prevention of the development of gastrointestinal lesions in rheumatic patients with continuous NSAID intake. *Gut* 2001; **49**: 1229

30 **Dietrich K**, Buchner M, Carro GP. Pantoprazole 20 mg s.i.d. is superior to Misoprostol 200 aeg b.i.d. in the prevention of gastrointestinal lesions in rheumatic patients with continuous NSAID intake. *Gut* 2001; **49**: 1491

S- Editor Wang J **L- Editor** Wang XL **E- Editor** Bi L

PO Box 2345, Beijing 100023, China
www.wjgnet.com
wjg@wjgnet.com

World J Gastroenterol 2006 August 21; 12(31): 5021-5027
World Journal of Gastroenterology ISSN 1007-9327
© 2006 The WJG Press. All rights reserved.

RAPID COMMUNICATION

Administration of granulocyte colony stimulating factor after liver transplantation leads to an increased incidence and severity of ischemic biliary lesions in the rat model

Olaf Dirsch, Haidong Chi, Yuan Ji, Yan Li Gu, Christoph E Broelsch, Uta Dahmen

Olaf Dirsch, Institute of Pathology, University Hospital Cologne, Joseph-Stelzmann Strasse 9, D-50931 Cologne, Germany
Haidong Chi, Yuan Ji, Yan Li Gu, Christoph E Broelsch, Uta Dahmen, Department of General, Visceral and Transplantation Surgery, University Hospital Essen, Hufelandstrasse 55, D-45122 Essen, Germany
Supported by the Deutsche Forschungsgemeinschaft (KFO 117/1) and the IFORES Research Program, University Hospital Essen
Correspondence to: Dr. Uta Dahmen, MD, PhD, Department of General, Visceral and Transplantation Surgery, University Hospital Essen, Hufelandstrasse 55, D-45122, Essen, Germany. utadahmen@uni-due.de
Telephone: +49-201-7231121
Received: 2006-03-01 Accepted: 2006-03-27

Abstract

AIM: Recently it has been reported that granulocyte colony stimulating factor (G-CSF) can induce hypercoagulability in healthy bone marrow donors. It is conceivable that the induction of a prothrombotic state in a recipient of an organ graft with already impaired perfusion might cause further deterioration in the transplanted organ. This study evaluated whether G-CSF treatment worsens liver perfusion following liver transplantation in the rat model.

METHODS: A non-arterialized rat liver transplantation model was employed to evaluate the effect of G-CSF treatment on the liver in a syngeneic and allogeneic strain combination. Study outcomes included survival time and liver damage as investigated by liver enzymes and liver histology. Observation times were 1 d, 1 wk and 12 wk.

RESULTS: Rats treated with G-CSF had increased incidence and severity of biliary damage following liver transplantation. In these animals, hepatocellular necrosis was accentuated in the centrilobular region. These lesions are indicative of impaired perfusion in G-CSF treated animals.

CONCLUSION: G-CSF should be used with caution in recipients of liver transplantation, as treatment might enhance preexisting, undetected perfusion problems and ultimately lead to ischemia induced biliary complications.

© 2006 The WJG Press. All rights reserved.

Key words: Granulocyte colony stimulating factor; Ischemic biliary lesions; Hypercoagulability; Liver transplantation

Dirsch O, Chi H, Ji Y, Gu YL, Broelsch CE, Dahmen U. Administration of G-CSF after liver transplantation leads to an increased incidence and severity of ischemic biliary lesions in the rat model. *World J Gastroenterol* 2006; 12(31): 5021-5027

http://www.wjgnet.com/1007-9327/12/5021.asp

INTRODUCTION

In 1975 granulocyte colony stimulating factor (G-CSF) was purified from urine[1] and serum[2]. Nowadays G-CSF is in clinical use and is applied routinely for donor conditioning before stem cell transplantation due to its stem cell mobilizing property. It is also used to treat patients who suffer from infections and neutropenia[3,4] and has been used successfully in endotoxin induced septic conditions[5]. Recently G-CSF has been used in immunosuppressed patients, particularly transplant-recipients, suffering from CMV infection and severe neutropenia[6].

Several clinical studies have evaluated the safety of G-CSF for transplant patients with a special focus on acute cellular rejection[6,7]. Acute cellular rejection, however, is only one potential threat to the transplanted organ. Decreased organ perfusion can lead to impaired function and even graft failure[8]. Impaired perfusion can result from ischemia-reperfusion damage or arterial insufficiency secondary to thrombosis at the site of anastomosis.

Recently it was shown that G-CSF can induce hypercoagulability in healthy bone marrow donors[9,10]. A prothrombotic state when a grafted organ is already compromised by impaired perfusion might exacerbate ischemia and further jeopardize the function of the transplanted organ. This study was designed to establish whether G-CSF treatment aggravates impaired liver perfusion following liver transplantation in the rat model.

MATERIALS AND METHODS

Experimental design

A non-arterialized rat liver transplantation model was used

to evaluate the effect of G-CSF treatment on the liver in a syngeneic and allogeneic strain combination. Outcomes included survival time and liver damage as investigated by liver enzymes in combination with liver histology. Observation time was set to 1 d, 1 wk and 12 wk.

Animals

Female Lew and ACI rats were used as donors and male Lewis (LEW, RT[1]) rats (Charles River Wiga GmbH, Germany), as recipients. The body weight of male rats was within 250-350 g (10-14 wk old), that of female rats were within 200-300 g (11-14 wk old). The animals were housed under standard animal care conditions and fed with rat chow *ad libitum* before and after operation. All procedures and housing were carried out according to the German Animal Welfare Legislation.

Administration of G-CSF

Animals in the treatment group received G-CSF (Neupogen 48™, AMGEN GmbH, Germany) at a dose of 100 μg/kg daily by subcutaneous injection starting 5 d prior to the operation until postoperative d 21.

Surgical procedures of orthotopic liver transplantation

Orthotopic liver transplantation was performed according to the technique described by Kamada[11]. Inhalation anesthesia with Isoflurane was used during the operation.

First step of the surgical procedure was a transverse abdominal incision. The liver of the donor was freed from its ligaments. The small-for-size liver graft was generated by 70% liver resection that included removing the left lateral lobe, the left medial lobe and the middle lobe. The weight of the resected liver lobes as well as the graft itself were recorded. The liver graft was perfused through the portal vein with chilled Ringer's solution. The organ was preserved at 4℃ for a maximum of one hour until placed orthotopically in the recipient's abdomen. The donor suprahepatic vena cava was anastomosed end-to-end with the recipient suprahepatic vena cava using a continuous 7-0 polypropylene suture. The portal vein anastomosis as well as the infrahepatic vena cava anastomosis were performed by pulling the recipient's vein over a cuff which was secured with a circumferential 6-0 silk suture. Biliary continuity was restored by tying the bile duct over a stent (Klinika Medical GmbH, Germany).

Table 1 Histologic damage score of the liver after liver transplantation

Single cell necrosis	0: No necrotic hepatocyte in 5 HPF (40 X)
	1: 1-10 in 5 HPF
	2: > 10
Confluent necrosis	0
	1: Small in size and number
	2: Large size and /or large number
Hepatic mitosis	0: No mitotic hepatocyte in 5 HPF (40 X)
	1: 1-10 in 5 HPF
	2: > 10 (extensive)
Bile duct inflammation damage	0: No inflammation;
	1: A minority of the ducts are cuffed and infiltrated by inflammatory cells
	2: More than an occasional duct showing degenerative changes or focal degenerative changes; Most of the ducts infiltrated by inflammatory cells
	3: Most of the ducts showing luminal disruption, most of the ducts infiltrated by inflammatory cells
Ductular proliferation	0: None
	1: Minimal (small proliferation in a minority of portal tracts)
	2: Mild (most portal tracts but not involving the lobular parenchyma)
	3: Moderate (all portal tracts and extending along the fibrous septa)
	4: Severe (extending along the portal tracts and also slightly involving the lobular parenchyma)
	5: Very severe (diffuse proliferation in the lobular parenchyma)
Fibrosis	0: None
	1: Fibrosis slightly extending portal tracts
	2: Fibrosis extending portal tracts with incomplete septa
	3: Fibrosis with complete septa bridging portal to portal tracts
	4: Incomplete (focal) or complete cirrhosis
Activated Kupffer cells	0: No activated Kupffer cells
	1: Activated Kupffer cells
Eosinophilic globuli	0: No eosinophilic globuli
	1: 1%-5% of all hepatocytes
	2: > 5%
Small vacuolar transformation of the cytoplasm	0: No small vacuolar transformation of the cytoplasm
	1: 1%-30% of all the hepatocytes
	2: > 30%

Postoperative management

After transplantation animals were placed into clean cages, and were given free access to tap water and rat chow ad libitum. Animals were observed daily. Body weight loss and general condition including activity, jaundice and bleeding from eyes or nose were recorded. Animals with deteriorating general condition indicated by a weight loss of more than 30% were sacrificed and were classified as dying during the observation period.

Sampling procedures

After sacrifice a full autopsy was performed. Gross findings were documented using a digital camera (Nikon Coolpix 995). Blood was obtained from the infrahepatic vena cava. Tissue samples (liver, bile duct) were fixed in 4% buffered formalin. Paraffin embedding was performed using standard techniques (Tissue Processor TPC15, Medite Inc.). Paraffin sections (4 μm) were stained with Hematoxylin-Eosin (HE) and Elastic von Gieson (EvG).

Alanine aminotransferase (ALT), Aspartate aminotransferase (AST), Alkaline phosphatase (AP) and Bilirubin were measured with an Automated Chemical Analyzer (ADVIA 1650, Bayer AG, Germany).

Histological evaluation of grafts

Damage to the liver was assessed histologically using a semiquantitative scoring system (Table 1). The scoring

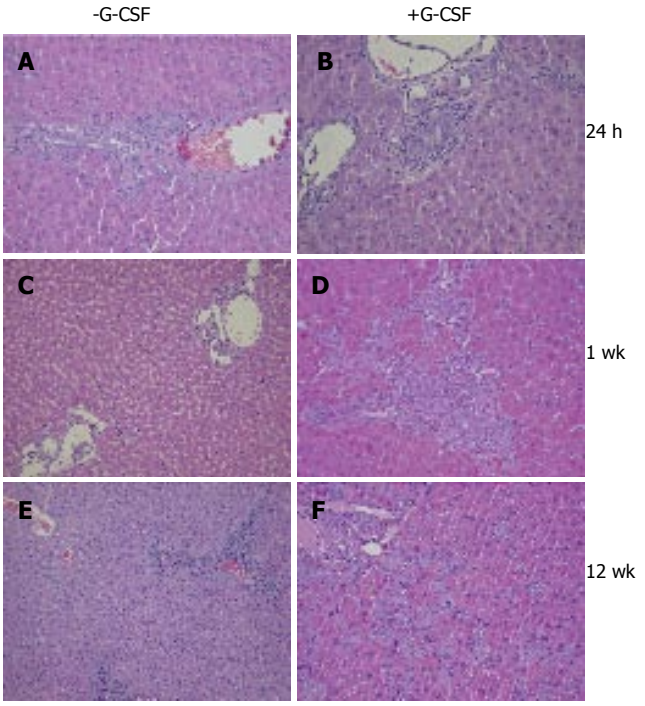

Figure 1 Histology of rat liver after 24 h (**A**, **B**), one week (**C**, **D**) and 12 wk (**E**, **F**) with and without G-CSF treatment showing varying degrees of inflammation and bile duct proliferation. HE; **A**, **D**, **F** 200 x; **B** 300 x; **C**, **E** 100 x.

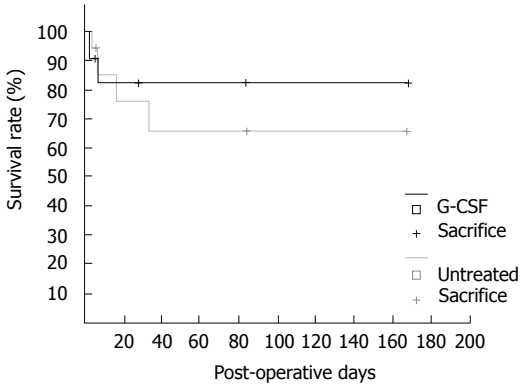

Figure 2 Kaplan-Meier chart of rats after liver transplantation with and without G-CSF treatment.

Table 2 Blood levels of ALT, AST and AP in rats after liver transplantation with and without G-CSF treatment

Group	24 h		1 wk		12 wk	
	Untreated	G-CSF	Untreated	G-CSF	Untreated	G-CSF
ALT (u/L)	616 ± 194[1]	418 ± 73[1]	192 ± 49	148 ± 81	92 ± 84	49 ± 24
AST (u/L)	344 ± 204	204 ± 48	96 ± 81	59 ± 28	35 ± 15	24 ± 13
AP (u/L)	141 ± 22[2]	455 ± 99[2]	453 ± 147	449 ± 418	473 ± 543	221 ± 68

[1] Significant difference between two groups ($P < 0.05$, *t*-test); [2] Significant difference between two groups ($P < 0.001$, *t*-test).

system included assessment of the portal and lobular inflammatory infiltrate, the extent of hepatocellular necrosis and signs of unspecific hepatocellular damage like a fine vacuolar transformation of the cytoplasm of hepatocytes. The number of mitotic figures and of eosinophilic globular structures in the cytoplasm of hepatocytes were counted. The extent of bile duct inflammation, regenerative changes of biliary epithelial cells and the number of ductules was reported.

The liver damage score was calculated as sum of the scores of all parameters, and the bile duct damage score was calculated as sum of bile duct inflammation and ductular proliferation score.

Data analysis and statistics

Data analysis and statistical procedures were performed using SPSS 10.0 (SPSS Inc. USA). All graphs were generated using *Sigmaplot* 7.0 (SPSS Inc. USA).

The survival rate was depicted as Kaplan-Meier curve. Survival rates in different groups were tested using the *log rank* test. Biochemistry results and damage scores among different groups were tested using the *Mann Whitney Rank Sum* test.

RESULTS

Normal rats

Normal rats treated with G-CSF ($n = 6$) for 5 d showed a mean leucocyte count of 22 neutrophilic cells per nl compared to 15 per nL without G-CSF treatment, indicating the biologic activity of human G-CSF in rats. An isolated increase in the blood level of alkaline phophatase was detected in 1 out of 6 animals. ALT, AST and bilirubin were within their normal range.

Histological evaluation revealed no pathologic changes; especially no alteration of the bile ducts or hepatocellular necrosis.

Rats after syngeneic liver transplantation

In both the G-CSF treated and untreated groups at 24 h, the liver macroscopically showed slight edema in the hilar region. Histologically a granulocytic infiltrate was found surrounding large hilar intrahepatic bile ducts in 50% of all G-CSF treated rats whereas in untreated rats hardly any inflammatory infiltrates in the large hilar intrahepatic bile ducts was detected (Figure 1).

Alkaline phosphatase was significantly higher in the G-CSF group compared to the untreated group (Table 2) indicating a more pronounced damage to the biliary system in the G-CSF treated animals.

Blood levels of liver enzymes were significantly lower in the G-CSF treated group compared to the untreated group (ALT: G-CSF treated group: 418.67 ± 73.08 μ/L *vs* untreated group: 634 ± 195.86 μ/L, $P = 0.041$), indicating a reduced number of damaged liver cells in G-CSF treated animals.

In both animal groups morphologic signs of minor hepatocellular damage like small vacuoles in the cytoplasm and a low number of single cell necrosis were visible.

In the treated group hepatocellular damage was mainly located in the centrilobular region. In contrast this distribution of hepatocytic injury was only observed in 2/6 animals of the untreated group. The other animals presented with single cell necrosis throughout the liver

lobule.

In the one week group with G-CSF treatment all animals survived. Survival rate without G-CSF treatment was 90% (Figure 2).

Upon gross examination, signs of limited inflammation around the common bile duct was found in all animals.

AST and ALT levels in both groups were elevated. Compared to the levels reached 24 h postoperatively, a decrease was observed, indicating recovery (Table 2). Two animals in the treatment group showed a massive increase in the AP-levels indicating severe damage to the bile ducts, whereas the other animals were within the normal range. In the untreated group, three out of six animals showed a slight increase in the AP-levels.

Histologically signs of damage to the biliary epithelial cells were visible in animals with and without G-CSF treatment. After G-CSF treatment rats showed a more pronounced proliferation of small biliary ducts suggesting a bile outflow problem.

Biliary epithelial cells showed signs of regenerative activation indicating repair of cellular damage rats with and without G-CSF treatment. Besides mitotic figures the biliary epithelial cells showed an increased nuclear polymorphism and nuclear enlargement leading to a shift of the nuclear to cytoplasmic ratio. Crowding of the biliary epithelial cells was visible. Nuclei did not show basal orientation. Furthermore signs of ongoing damage to the biliary duct were visible. In the cytoplasm of biliary epithelial cells vacuoles were discernible. A very low number of necrotic biliary epithelial cells could be detected. In the vicinity of bile ducts inflammatory cellular infiltrates were visible.

Biliary outflow obstruction is known to induce proliferation of biliary ducts leading to an increase in the number of bile ducts in the portal tracts. Proliferation of bile ducts was more pronounced in animals that underwent G-CSF treatment (Figure 1D). In one rat, the proliferated bile ducts extended into the parenchyma of the liver. In another animal a massive "biliary transformation" of the liver was observed. The biliary duct damage score was slightly higher in G-CSF treated animals at week one, but at this time point the difference did not reach statistical significance ($P = 0.074$, Mann-Whitney test).

Survival rate at 12 wk post operation was 88% in the untreated group compared to the treated group that showed a survival rate of only 64% (Figure 2).

Macroscopically concrements and sludge in large bile ducts was found slightly more frequent in G-CSF treated rats (3/6 compared to 2/6).

In the untreated group, black sludge in the bile duct was found in one rat. In another rat, a small yellow particle in the common bile duct was found, which was associated with a cystic dilatation of the bile duct.

In G-CSF treated animals a small amount of black sludge was found in 2 out of 6 rats. A 0.4 cm × 0.4 cm black stone-like particle in a dilated bile duct was found in another rat. Totally, macroscopically visible lesions of the large extrahepatic bile duct were found in 3 out of 6 rats.

Blood levels of liver enzymes and AP were increased but comparison of both groups did not show a statistically significant difference at this time point.

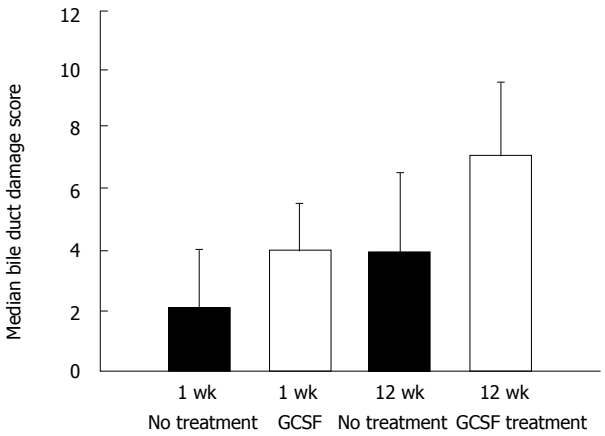

Figure 3 Median bile duct damage score at one and twelve weeks.

Microscopically the number of proliferating small biliary ducts was higher in G-CSF treated animals. The degree of liver cell damage was also higher in G-CSF treated animals. Median bile duct damage score in G-CSF treated animals reached statistical significance compared to rats without G-CSF treatment (Figure 3).

Rats after allogeneic liver transplantation

After full size liver transplantation in the ACI to Lewis strain combination animals died within 9 to 14 d. No difference in survival time was observed between animals with and without G-CSF treatment.

Animals dying spontaneously presented with morphological signs of severe rejection, as expected in this strain combination. Scoring of the histopathology according to the Banff-classification showed no difference in severity between the two groups. Portal tracts were wide and filled with activated lymphocytes and other inflammatory cells. Inflammatory cells extended into the parenchyma of the liver and hepatocellular single cell necrosis was obvious.

In addition inflammatory cells infiltrated small bile ducts that showed signs of damage and destruction. Single necrotic biliary cells and vacuolar transformation of biliary epithelium was the characteristic feature. Regenerative activation of biliary epithelial cells was detected. The number of mitotic figures in biliary epithelial cells was increased and nuclei were not evenly arranged in the vicinity of the basal membrane. In addition nuclear enlargement leading to a shift of the nuclear to cytoplasmic ratio was recorded. In addition to ductitis, there was also an inflammatory infiltrate in the luminal parts of the wall of blood vessels both in the portal tract and in the central regions of the lobules. This endothelitis was accompanied by a regenerative activation and proliferation of endothelial cells and in some vessels, minute fibrin deposits were discernible on the luminal surface.

In the G-CSF treated animals the number of granulocytes seemed to be slightly higher near the bile ducts, whilst hepatocellular single cell necrosis seemed to be slightly more prominent in centrilobular areas compared to rats receiving no G-CSF treatment. Differences were subtle and did not allow for clear discrimination between

Table 3 Signs of a hypercoaguable state after G-CSF treatment in healthy volunteers and in patients with G-CSF producing tumors

Author	*n*	Observations after G-CSF administration or in patients with G-CSF producing tumors
Topcuoglu *et al*, 2004[9]	18	Stimulation of thrombotic factors and increased endothelial markers, such as FVIII and vWF No clinical silent microembolism detected by transcranial Doppler
Sohngen *et al*, 1998[13]	25	Hypercoaguable state
LeBlanc *et al*, 1999[10]	22	Increased levels of FVIIIC and thrombin Reduced platelet aggregation.
Kuroiwa *et al*, 1996[12]	10	Significant increase of platelet aggregation induced by ADP or collagen, thromboxane B2 level and amount of thrombin-antithrombin III complex.
Canales *et al*, 2002[32]	20	Significant increase in F1 + 2 and D-dimer Significant decrease of antithrombin and protein C activity Significant increase of vWF Slightly significant decrease of angiotensin converting enzyme
Suzuki *et al*, 1992[33]	14	Thrombocytosis

the two groups. When slides were observed in a blinded fashion animals could not be clearly attributed to either group.

DISCUSSION

G-CSF is used routinely in conditioning of donors before stem cell transplantations. In donors and healthy volunteers it has been shown that G-CSF induces a prothrombotic state (Table 3). In addition to the increase in prothrombotic factors, enhanced platelet aggregation was also observed, potentially mediated by the G-CSF receptor on platelets[12]. Therefore, it was suspected that G-CSF might lead to thrombotic complications in patients already at risk for thrombosis. Thus, careful monitoring was recommended for patients with additional risk factors for thrombosis[13].

Furthermore other pathophysiological alterations induced by G-CSF may impair microcirculation. Microcirculation was disturbed in G-CSF treated rats using a free-flap model to investigate behavior of granulocytes after chemotherapy and G-CSF stimulation[14]. Leukocyte rolling and sticking was enhanced to a degree that impaired microcirculation. However, this problem became only visible in this free-flap model with its inherent impairment to microcirculation.

Ischemia-reperfusion injury causing an impairment of microcirculation is unavoidable in transplantations[15-17]. In clinical liver transplantation, impaired arterial perfusion, mostly due to arterial thrombosis in the hepatic artery, is an important cause of graft dysfunction and even failure[18-20]. In the rat, rearterialization is not essential for the survival of the recipient, but is considered by some authors to enhance liver perfusion and especially perfusion of the biliary tract, resulting in a lower rate of biliary complications[21,22]. For this study, a model with a high risk of perfusion related problems was warranted. Therefore, the non-arterialized rat liver transplantation model, as developed by Kamada[20] was employed.

In rats, subjected to liver transplantations and additional perioperative G-CSF treatment, in the early postoperative period we observed a centrilobular accentuation of necrotic hepatocytes. At the same time we also observed an increased blood level of alkaline phosphatase at 24 h. Alkaline phosphatase can be an indicator of damage to the biliary epithelial cells but an increase in the blood levels of alkaline phosphatase after G-CSF treatment is also described in some patients due to the induction of bone metabolism[23]. Especially the pronounced increase after syngeneic liver transplantations in rats treated with G-CSF compared to non-operated G-CSF treated animals suggests damage to the biliary tract leading to cholangitis as the underlying reason.

In the animals observed for 12 wk, an increase in the number and severity of biliary complications and accompanying histomorphological damage was found. In particular, the number of proliferating small biliary ducts, which is indicative of a biliary outflow problem, was more prevalent in G-CSF treated rats.

Impaired arterial perfusion of the liver parenchyma leads to variable centrilobular necrosis[24]. Impaired arterial perfusion of the bile duct leads to damage of the biliary epithelial cells indicated by the release of alkaline phosphatase. Aggressive bile seeping into the surrounding tissue can perpetuate the damage and attract inflammatory cells, causing cholangitis. Especially when larger bile ducts are affected, there can be a functional impairment of smooth muscle cells with loss of motility, which can impair bile outflow. Reduced biliary flow promotes the development of biliary sludge and concrements eventually leading to outflow obstruction. Biliary obstruction induces proliferation of small bile ducts as demonstrated experimentally in a rat liver ischemia model[25] and after bile duct ligation[26].

If this combination of morphological alterations, centrilobular hepatocellular necrosis and cholangitis with or without proliferation of small bile duct is present, as it is in our experiment, an underlying perfusion problem must be assumed. However, it might be difficult to achieve a diagnosis based on histomorphology alone since severe additional confounding alterations like rejection can be superimposed. In the allogeneic strain combination rejection was partially masking perfusion related morphologic alterations. Thus, a perfusion associated problem could only be suspected upon a detailed analysis.

Clinical studies performed to document the safety of G-CSF in transplant patients did not reveal relevant side effects in most studies. G-CSF is known to restore the compromised immune system in neutropenic patients by increasing the number of circulating granulocytes, thus it was suspected that the rejection rate might increase. In the published clinical trials[6,7,27] an influence on rejection rate or severity was not reported, which was also confirmed in our study. Other problems seem to be out of focus in these studies. In a large clinical trial analyzing potential adverse effects of G-CSF in liver transplanted

patients[7] not a single case of biliary complications was reported. Biliary problems are rather common after liver transplantations. The complete absence of any biliary problem in such a large cohort of 286 patients is rather surprising.

GCSF-related histomorphological alterations of the liver were reported in studies, where patients were exposed to high levels of circulating cytokines. Suzuki[28] reported on a small number of patients with endocrine tumors producing G-CSF as well as IL-1 and IL-8, who presented with liver dysfunction and fever in addition to marked leukocytosis. Biochemical examinations revealed high serum enzyme levels of the biliary system in contrast to normal or slight increases in transaminase levels in all patients studied. Three common pathologic changes of the liver were found: focal necrosis associated with neutrophil infiltration in the centrilobular zones[1], fibrous change and enlargement of the portal area associated with neutrophil infiltration[2], and intrahepatic cholestasis[3]. The same pathologic changes, except for cholestasis, were observed in the liver of mice transplanted with G-CSF-producing cell lines (KHC287 or CHU-2)[29]. Thus the pattern of liver lesions consisting of an impairment of bile ducts and centrilobular necrosis of hepatocytes was similar to morphologic changes observed in our experiment.

But on the other hand a beneficial effect of G-CSF on the liver after extended liver resection and toxic liver damage has been described[30,31]. Yannaki observed an accelerated recovery and improved survival after liver injury and attributed this effect to the promotion of endogenous repair programs[9], and not to stem cell transdifferentiation, as discussed recently. In the experiment presented here, the lower serum levels of AST and ALT 24 h after liver transplantation could be attributed to this beneficial G-CSF effect. In treated rats, hepatocyte necrosis was only observed in the vicinity of central veins, whereas single cell necrosis was distributed throughout the liver lobule in the untreated group, accompanied by a significantly higher release of liver enzymes. This distribution pattern of single cell necrosis gives rise to the speculation, that GCSF had a beneficial affect on hepatocytes undergoing ischemia reperfusion injury, but had a detrimental effect on perfusion leading to centrilobular necrosis of hepatocytes and necrosis and vacuolization of biliary epithelial cells.

This contradictory effect contributes to the blurring clinical picture, which hinders one from reaching definitive conclusions from these studies. Perfusion related changes are rather subtle, thus it is necessary to give special attention to this problem, which does not always happen, neither in daily clinical routine nor in clinical studies as mentioned before[7].

CONCLUSION

G-CSF should be used with caution in liver transplanted patients, as treatment might enhance preexisting, undetected perfusion problems and ultimately lead to ischemia induced biliary complications.

REFERENCES

1 **Kellar KL**, Vogler WR, Kinkade JM Jr. Colony stimulating factor (CSF) from human leukemic urine: affinity chromatography and isoelectric focusing. *Proc Soc Exp Biol Med* 1975; **150**: 766-772

2 **Metcalf D**, MacDonald HR, Chester HM, Metcalf D, MacDonald HR, Chester HM. Serum potentiation of granulocyte and macrophage colony formation in vitro. *Exp Hematol* 1975; **3**: 261-273

3 **García-Carbonero R**, Mayordomo JI, Tornamira MV, López-Brea M, Rueda A, Guillem V, Arcediano A, Yubero A, Ribera F, Gómez C, Trés A, Pérez-Gracia JL, Lumbreras C, Hornedo J, Cortés-Funes H, Paz-Ares L. Granulocyte colony-stimulating factor in the treatment of high-risk febrile neutropenia: a multicenter randomized trial. *J Natl Cancer Inst* 2001; **93**: 31-38

4 **Schaison G**, Eden OB, Henze G, Kamps WA, Locatelli F, Ninane J, Ortega J, Riikonen P, Wagner HP. Recommendations on the use of colony-stimulating factors in children: conclusions of a European panel. *Eur J Pediatr* 1998; **157**: 955-966

5 **Aoki Y**, Hiromatsu K, Kobayashi N, Hotta T, Saito H, Igarashi H, Niho Y, Yoshikai Y. Protective effect of granulocyte colony-stimulating factor against T-cell-meditated lethal shock triggered by superantigens. *Blood* 1995; **86**: 1420-1427

6 **Turgeon N**, Hovingh GK, Fishman JA, Basgoz N, Tolkoff-Rubin NE, Doran M, Cosimi AB, Rubin RH. Safety and efficacy of granulocyte colony-stimulating factor in kidney and liver transplant recipients. *Transpl Infect Dis* 2000; **2**: 15-21

7 **Winston DJ**, Foster PF, Somberg KA, Busuttil RW, Levy MF, Sheiner PA, Reddy KR, Fotheringham N, Armstrong M, Logan E. Randomized, placebo-controlled, double-blind, multicenter trial of efficacy and safety of granulocyte colony-stimulating factor in liver transplant recipients. *Transplantation* 1999; **68**: 1298-1304

8 **Colina F**, Mollejo M, Moreno E, Alberti N, García I, Gómez-Sanz R, Castellano G. Effectiveness of histopathological diagnoses in dysfunction of hepatic transplantation. Review of 146 histopathological studies from 53 transplants. *Arch Pathol Lab Med* 1991; **115**: 998-1005

9 **Topcuoglu P**, Arat M, Dalva K, Ozcan M. Administration of granulocyte-colony-stimulating factor for allogeneic hematopoietic cell collection may induce the tissue factor-dependent pathway in healthy donors. *Bone Marrow Transplant* 2004; **33**: 171-176

10 **LeBlanc R**, Roy J, Demers C, Vu L, Cantin G. A prospective study of G-CSF effects on hemostasis in allogeneic blood stem cell donors. *Bone Marrow Transplant* 1999; **23**: 991-996

11 **Kamada N**, Calne RY, Wight DG, Lines JG. Orthotopic rat liver transplantation after long-term preservation by continuous perfusion with fluorocarbon emulsion. *Transplantation* 1980; **30**: 43-48

12 **Kuroiwa M**, Okamura T, Kanaji T, Okamura S, Harada M, Niho Y. Effects of granulocyte colony-stimulating factor on the hemostatic system in healthy volunteers. *Int J Hematol* 1996; **63**: 311-316

13 **Söhngen D**, Wienen S, Siebler M, Boogen C, Scheid C, Schulz A, Kobbe G, Diehl V, Heyll A. Analysis of rhG-CSF-effects on platelets by in vitro bleeding test and transcranial Doppler ultrasound examination. *Bone Marrow Transplant* 1998; **22**: 1087-1090

14 **Peter FW**, Schuschke DA, Barker JH, Fleischer-Peter B, Hussmann J, Steinau HU. Leukocyte behavior in a free-flap model following chemotherapy and application of granulocyte colony-stimulating factor (GCSF). *Microsurgery* 1998; **18**: 290-297

15 **Angelescu M**, Hofmann W, Zapletal C, Bredt M, Kraus T, Herfarth C, Klar E. Histomorphological analysis of preservation injury as determinant of graft quality in clinical liver transplantation. *Transplant Proc* 1999; **31**: 1074-1076

16 **Manner M**, Shult W, Senninger N, Machens G, Otto G. Evaluation of preservation damage after porcine liver transplantation by assessment of hepatic microcirculation. *Transplantation* 1990; **50**: 940-943

17 **Post S**, Rentsch M, Palma P, Gonzalez AP, Menger MD.

Assessment of microhemodynamics after liver transplantation by in vivo microscopy in the rat. *Transplant Proc* 1993; **25**: 2597-2598
18 **Krishna M**, Keaveny AP, Genco PV, Rosser BG, Dickson RC, Nguyen JH, Steers JL, Nakhleh RE. Clinicopathological review of 18 cases of liver allografts lost due to bile duct necrosis. *Transplant Proc* 2005; **37**: 2221-2223
19 **Stange BJ**, Glanemann M, Nuessler NC, Settmacher U, Steinmüller T, Neuhaus P. Hepatic artery thrombosis after adult liver transplantation. *Liver Transpl* 2003; **9**: 612-620
20 **Kamada N**, Calne RY. A surgical experience with five hundred thirty liver transplants in the rat. *Surgery* 1983; **93**: 64-69
21 **Howden B**, Jablonski P, Grossman H, Marshall VC. The importance of the hepatic artery in rat liver transplantation. *Transplantation* 1989; **47**: 428-431
22 **Reck T**, Steinbauer F, Steinbauer M, Schwille PO, Wittekind C, Hohenberger W, Köckerling F. Impact of arterialization on hepatic oxygen supply, tissue energy phosphates, and outcome after liver transplantation in the rat. *Transplantation* 1996; **62**: 582-587
23 **Watanabe T**, Suzuya H, Onishi T, Kanai S, Kaneko M, Watanabe H, Nakagawa R, Kawano Y, Takaue Y, Kuroda Y, Talmadge JE. Effect of granulocyte colony-stimulating factor on bone metabolism during peripheral blood stem cell mobilization. *Int J Hematol* 2003; **77**: 75-81
24 **Khettry U**, Backer A, Ayata G, Lewis WD, Jenkins RL, Gordon FD. Centrilobular histopathologic changes in liver transplant biopsies. *Hum Pathol* 2002; **33**: 270-276
25 **Beaussier M**, Wendum D, Fouassier L, Rey C, Barbu V, Lasnier E, Lienhart A, Scoazec JY, Rosmorduc O, Housset C. Adaptative bile duct proliferative response in experimental bile duct ischemia. *J Hepatol* 2005; **42**: 257-265
26 **Lichtman SN**, Wang J, Clark RL. A microcholangiographic study of liver disease models in rats. *Acad Radiol* 1995; **2**: 515-521
27 **Foster PF**, Mital D, Sankary HN, McChesney LP, Marcon J, Koukoulis G, Kociss K, Leurgans S, Whiting JF, Williams JW. The use of granulocyte colony-stimulating factor after liver transplantation. *Transplantation* 1995; **59**: 1557-1563
28 **Suzuki A**, Takahashi T, Okuno Y, Seko S, Fukuda Y, Nakamura K, Fukumoto M, Konaka Y, Imura H. Liver damage in patients with colony-stimulating factor-producing tumors. *Am J Med* 1993; **94**: 125-132
29 **Theocharis SE**, Margeli AP, Goutas ND, Horti MG, Karkantaris CS, Kittas CN. Granulocyte colony-stimulating factor administration reverses cadmium-associated inhibition of hepatocyte regeneration. *Eur J Gastroenterol Hepatol* 1996; **8**: 805-809
30 **Theocharis SE**, Papadimitriou LJ, Retsou ZP, Margeli AP, Ninos SS, Papadimitriou JD. Granulocyte-colony stimulating factor administration ameliorates liver regeneration in animal model of fulminant hepatic failure and encephalopathy. *Dig Dis Sci* 2003; **48**: 1797-1803
31 **Yannaki E**, Athanasiou E, Xagorari A, Constantinou V, Batsis I, Kaloyannidis P, Proya E, Anagnostopoulos A, Fassas A. G-CSF-primed hematopoietic stem cells or G-CSF per se accelerate recovery and improve survival after liver injury, predominantly by promoting endogenous repair programs. *Exp Hematol* 2005; **33**: 108-119
32 **Canales MA**, Arrieta R, Gomez-Rioja R, Diez J, Jimenez-Yuste V, Hernandez-Navarro F. Induction of a hypercoagulability state and endothelial cell activation by granulocyte colony-stimulating factor in peripheral blood stem cell donors. *J Hematother Stem Cell Res* 2002; **11**: 675-681
33 **Suzuki A**, Takahashi T, Nakamura K, Tsuyuoka R, Okuno Y, Enomoto T, Fukumoto M, Imura H. Thrombocytosis in patients with tumors producing colony-stimulating factor. *Blood* 1992; **80**: 2052-2059

S- Editor Wang J **L- Editor Worthley DL** **E- Editor** Ma N

PO Box 2345, Beijing 100023, China
www.wjgnet.com
wjg@wjgnet.com

World J Gastroenterol 2006 August 21; 12(31): 5028-5032
World Journal of Gastroenterology ISSN 1007-9327
© 2006 The WJG Press. All rights reserved.

RAPID COMMUNICATION

Usefulness of duodenal biopsy during routine upper gastrointestinal endoscopy for diagnosis of celiac disease

S Riestra, F Domínguez, E Fernández-Ruiz, E García-Riesco, R Nieto, E Fernández, L Rodrigo

S Riestra, L Rodrigo, Gastroenterology Section and Gastroenterology Service, Hospital Central de Asturias, Spain
F Domínguez, Gastroenterology Section and Pathology Service, Hospital Valle del Nalón, Spain
E Fernández-Ruiz, E García-Riesco, R Nieto, E Fernández, Gastroenterology Section and Biochemistry Service, Hospital de Cabueñes, Spain
Correspondence to: Dr. Luis Rodrigo, Servicio de Aparato Digestivo, Hospital Central de Asturias, c/ Celestino Villamil, s. No. 33.006. Oviedo, Spain. lrodrigos@terra.es
Telephone: +34-985-108058 Fax: +34-985-273614
Received: 2006-03-06 Accepted: 2006-03-27

© 2006 The WJG Press. All rights reserved.

Key words: Duodenal biopsy; Upper gastrointestinal endoscopy; Celiac disease; Anemia; Chronic diarrhea

Riestra S, Domínguez F, Fernández-Ruiz E, García-Riesco E, Nieto R, Fernández E, Rodrigo L. Usefulness of duodenal biopsy during routine upper gastrointestinal endoscopy for diagnosis of celiac disease. *World J Gastroenterol* 2006; 12(31): 5028-5032

http://www.wjgnet.com/1007-9327/12/5028.asp

Abstract

AIM: To describe the trend in duodenal biopsy performance during routine upper gastrointestinal endoscopy in an adult Spanish population, and to analyze its value for the diagnosis of celiac disease in clinical practice.

METHODS: A 15 year-trend (1990 to 2004) in duodenal biopsy performed when undertaking upper gastrointestinal endoscopy was studied. We analysed the prevalence of celiac disease in the overall group, and in the subgroups with anaemia and/or chronic diarrhoea.

RESULTS: Duodenal biopsy was performed in 1033 of 13 678 upper gastrointestinal endoscopies (7.6%); an increase in the use of such was observed over the study period (1.9% in 1990-1994, 5% in 1995-1999 and 12.8% in 2000-2004). Celiac disease was diagnosed in 22 patients (2.2%), this being more frequent in women than in men (3% and 1% respectively). Fourteen out of 514 (2.7%) patients with anaemia, 12 out of 141 (8.5%) with chronic diarrhoea and 8 out of 42 (19%) with anaemia plus chronic diarrhoea had celiac disease. A classical clinical presentation was observed in 55% of the cases, 23% of the patients had associated dermatitis herpetiformis and 64% presented anaemia; 9% were diagnosed by familial screening and 5% by cryptogenetic hypertransaminasaemia.

CONCLUSION: Duodenal biopsy undertaken during routine upper gastrointestinal endoscopy in adults, has been gradually incorporated into clinical practice, and is a useful tool for the diagnosis of celiac disease in high risk groups such as those with anaemia and/or chronic diarrhoea.

INTRODUCTION

Celiac disease (CD) is a frequent immune-mediated enteropathy of worldwide distribution. It affects both children and adults and has a heterogeneous clinical presentation[1]. Even though we currently possess sensitive and specific serological methods, the duodenal biopsy continues to be the gold standard for the diagnosis of CD[2]. Knowledge of the diverse forms of presentation of CD, together with a high index of clinical suspicion and an improvement in the accessibility to endoscopy units have made it possible, in some geographical areas, that the number of diagnosed celiac patients approximates the number of patients estimated from population screening studies[3].

Endoscopic duodenal biopsy is a diagnostic tool in the management of patients with chronic diarrhoea and ferropenic anemia[4,5], these being frequent manifestations of CD[1]. Several studies have been designed in order to know the prevalence of CD among those with anemia or diarrhoea[6-13]. However, the usefulness of duodenal biopsy during upper gastrointestinal (GI) endoscopy for diagnosis of CD is less well known in daily clinical practice[14].

In Spain, the prevalence of CD in the general population is similar to other European countries (1/118 to 1/389)[15-17], we do not however possess data on the performance of duodenal biopsy in adults in clinical practice. The aims of the present study were to obtain information on the evolution of the practice of duodenal biopsy in adults over a 15-year period in a Spanish Digestive Endoscopy Unit and also to study the efficacy of such for the diagnosis of CD in high risk groups

of patients, such as those with anemia and/or chronic diarrhoea. The clinical characteristics of celiac patients diagnosed throughout the study are also described.

MATERIALS AND METHODS

Patients

The Gastroenterology Unit of Hospital Valle del Nalón (Asturias, Northern Spain) is the reference for an adult population of 75 212 people (27% > 60 years). All upper GI endoscopies were performed by three gastroenterologists (RS, F-RE and NR) and duodenal biopsies (3-5 samples per patient) were evaluated by the same pathologist (DF). A special interest in CD began in 1997, when an epidemiological study was undertaken on the prevalence of the disease in the general population of this area[15]. In clinical practice, the access to Digestive Endoscopy Unit is not open to primary care and serological testing for CD has always been available (antigliadine, antiendomysium and/or antitransglutaminase, according to the period analysed). From 1998, the genetic study of HLA-DQ2/DQ8 has also been available.

Study design

Using the computerized register of all upper GI endoscopies performed between 1990 and 2004 (13 678), we created a database of all patients who had undergone a duodenal biopsy (1033). After excluding 12 explorations in which it was not possible to reach a histological diagnosis due to technical problems and another 12 which were performed in already known celiacs, the total sample analysed was 1009 explorations. The variables included for study are as follows: year when duodenal biopsy was undertaken, age and gender of patient, indication for upper GI endoscopy and the final histological diagnosis.

We studied the evolution over time of the performance of duodenal biopsy during the upper GI endoscopies; in some cases the endoscopic exploration was made exclusively in order to perform duodenal biopsies, since a high index of suspicion of CD previously existed (for example, positive serology or malabsorption syndrome). However, in the majority of the cases, it was the endoscopist who decided, at the time of exploration, whether or not to take duodenal biopsies, when faced with the finding of anomalies in the intestinal mucosa or the presence of certain symptoms or analytical changes (diarrhoea, anemia, iron deficiency, *etc*).

We analysed those cases diagnosed as celiacs; the enteropathy was described according to the Marsh´ classification (modified by Oberhuer)[18] and a response to a gluten-free diet, was used as the diagnostic criteria for CD. We studied the frequency of CD, according to the main indication for performing the duodenal biopsy. The subgroup of patients with anemia (n = 514) included those in which the indication for endoscopic study was the presence of ferropenic anemia, microcytic anemia or iron and/or folic acid deficiency; patients with anemia due to vitamin B12 deficiency or those in whom the anemia was associated with signs or symptoms of upper GI bleeding, were excluded from the analysis. The subgroup of patients with diarrhoea (n = 141) included those with a picture of chronic diarrhoea (> 4 wk) in whom a possible origin was suspected in the small intestine.

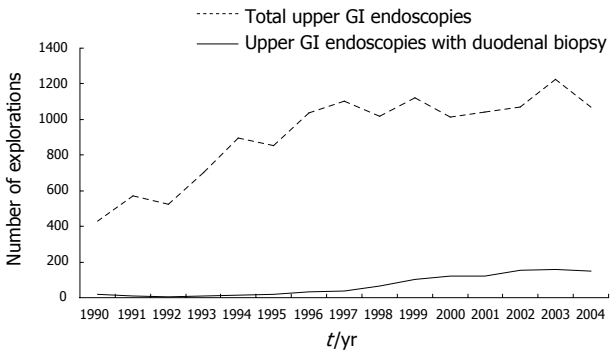

Figure 1 Fifteen-year evolution of the performance of duodenal biopsy during routine upper gastrointestinal endoscopy in an adult Spanish population.

The clinical, serological and genetic characteristics of patients diagnosed with CD over the study period are presented in this paper.

Statistical analysis

Data are expressed as percentages or absolute number for categorical variables and medians and ranges for continuous variables. The Chi-square test was used to test for differences between groups of patients with regard to their clinical and demographic features. Multivariate logistic regression analysis was performed to describe the independent association of variables, and the output was converted into adjusted likelihood ratios. A stepwise (forward) selection procedure was employed in order to prevent exclusion of important variables from the model, as a result of mutual correlations. The covariables introduced in the model were age, gender, anemia, diarrhoea, and year of performance of duodenal biopsy (stratified into three periods). The relationship between CD and the above variables was quantified as odds ratios (OR) and 95% confidence intervals are provided. All statistical analyses were performed using MedCalc®, Ver. 7.4.4.1 (MedCalc Software). A two-tailed $P < 0.05$ was considered to be statistically significant.

RESULTS

Temporal evolution of duodenal biopsy during the study period

From 1990 to 2004, duodenal biopsy was performed in 1033 out of a total of 13 678 upper GI endoscopies (7.4%). Figure 1 represents the 15-year evolution of the performance of duodenal biopsy in the final sample evaluated (1009); when a division was made into three consecutive periods of five years: 1990-1994, 1995-1999 and 2000-2004, we found a significant increase in the percentage of endoscopic explorations in which duodenal biopsy was performed: 58 out of 3121 (1.9%) in the first period, 258 out of 5128 (5%) in the second period, and 693 out of 5405 (12.8%) in the third (1.9% *vs* 5%, $P < 0.0001$; 5% *vs* 12.8%, $P < 0.001$).

Table 1 Prevalence of celiac disease in 1009 duodenal biopsies performed during upper gastrointestinal endoscopy

	Number	CD *n* (%)	95% CI
Study population	1009	22 (2.2)	1.4-3.3
Period:			
1990-1994	58	2 (3.4)	0.6-13.0
1995-1999	258	8 (3.1)	1.5-6.3
2000-2004	693	12 (1.7)	0.9-3.1
Gender:			
Female	600	18 (3)	1.8-4.8
Male	409	4 (1)	0.3-2.7
Age (yr):			
14-34	136	3 (2.2)	0.6-6.8
35-54	309	11 (3.6)[b]	1.9-6.5
55-74	365	7 (1.9)	0.8-4.1
⩾ 75	199	1 (0.5)	0.03-3.2
Patient subgroups:			
Anemia	514	14 (2.7)	1.6-4.6
Diarrhoea	141	12 (8.5)[d]	4.7-14.7
Anemia plus diarrhoea	42	8 (19)[f]	9.1-34.6

[b]$P < 0.01$ (35-54 yr *vs* ⩾ 75 yr); [d]$P < 0.01$ (diarrhea *vs* anemia); [f]$P < 0.0001$ (anemia plus diarrhoea *vs* anemia).

Up to 1997 a duodenal biopsy was not indicated by positive serology for CD and up to 1999, this was not made in first-degree relatives of celiac patients. Duodenal biopsy was performed in 7.7% of the patients with anemia as the main indication for upper GI endoscopy during the first period, in 21% during the second, and in 73% during the third period.

Prevalence of celiac disease

The total group included 600 females and 409 males with a median age of 60 years (range 14-93 years), without significant differences in gender. Twenty two patients were diagnosed with CD, which accounted for 2.2% of the duodenal biopsies performed; in 6 subjects (27%) the duodenal biopsy was indicated after knowing the presence of positive serology for CD, while in the 16 remaining patients (73%), this was performed according to the clinical suspicion of CD (based on the presence of chronic diarrhoea, non-specific digestive symptoms, *etc*) or by the finding of persistent analytical changes (anemia and/or iron deficiency). The prevalence of CD in the overall group and also in the subgroups of anemia and/or chronic diarrhoea is shown in Table 1.

In the logistic regression analysis, only the presence of anemia (OR 2.82; 95% CI 1.11-7.14) and diarrhoea (OR 10.38; 95% CI 4.22-25.50) were risk factors for CD. The clinical and immune-histological characteristics of the celiac patients diagnosed in the study are shown in Table 2. No differences were observed in the frequency of classical presentation between patients diagnosed before or after 1999 (50% versus 58%, respectively). A gluten-free diet was strictly followed-up in 20 of the 22 adult celiac patients diagnosed.

Table 2 Clinical and immune-histological characteristics of celiac patients

Gender	
Female	18 (81.8%)
Male	4 (18.2%)
Age (yr)	50 (19-77)
Clinical characteristics	
Malabsorption syndrome	12 (54.5%)
Anemia	14 (63.6%)
Dermatitis herpetiformis	5 (22.7%)
Abnormal liver function test	7 (31.8%)
Celiac relatives	2 (9.1%)
Histology (Marsh type):	
Ⅰ	3 (13.6%)
Ⅱ	1 (4.5%)
Ⅲ	18 (81.8%)
Serology[1]	
AGA	13 (86.7%)
EMA	17 (89.5%)
TTG	8 (88.9%)
HLA-DQ2[2]	18 (100%)
Autoimmune associated diseases[3]	2 (9.1%)
Mortality[4]	2 (9.1%)

n (%) are shown for categorical variables, while the median (range) is shown for age. [1]Serological analysis was performed using antigliadin (AGA) in 15, anti-endomysium (EMA) in 19 and tissue-trans-glutaminase antibodies (TTG) in 9 patients; [2]Genetic study was performed in 18 patients; [3]Addison disease (1) and juvenile arthritis (1); [4]Stroke (1) and non-Hodgkin lymphoma (1).

DISCUSSION

This study shows the changes observed over a period of 15 years (1990-2004) in the performance of duodenal biopsy in an endoscopy unit for adults in Spain. At present, the practice of duodenal biopsy during upper GI endoscopies is common. During the period 1990-1994 duodenal biopsy was made in 1.9% of the endoscopic explorations, while during the period 2000-2004 this was 12.8%.

Advancement in the knowledge of CD has led to an increase in the indications for performing duodenal biopsy. It is currently known that mild digestive symptoms (dyspepsia, abdominal discomfort, *etc*), or analytical alterations (anemia, iron deficiency or hypertransaminasaemia), could be some forms of presentation of CD[1]. We observed that during the first 5-year period, duodenal biopsy was usually made in persons with a classical or malabsorption syndrome, while in the later periods this was mainly performed in subjects with anemia (data not shown). Certain risk groups have been well characterised[19,20], which has meant that during the upper GI endoscopies practised for whatever reason in persons belonging to these risk groups, duodenal biopsy is made even in the absence of symptoms of enteropathy or without previous serological studies.

CD was diagnosed more frequently in females than in males (3% *vs* 1%), although gender was not a significant

risk factor for CD, as has been observed in other similar studies[14]. Only anemia and diarrhoea were found to be risk factors for CD. The prevalence of CD found in patients with anemia (2.7%) is included in the wide range communicated in previous studies (1.8% to 13.7%)[6-11]; the differences are due mainly to the diverse selection criteria of patients with anemia, since if ferropenic refractory patients are included[6,7] or subjects in which other causes of anemia have been ruled out[7], the frequency of CD has been higher; on the other hand, the diagnostic strategy used also influences the results, as some studies have performed serological screening prior to duodenal biopsy[6,8], while in others a duodenal biopsy has been performed in all cases[7,11] or only in those in which another cause to justify the anemia was not found during the endoscopic exploration[10].

We wish to emphasize that our study is based on clinical practice over a long period of time, for which reason various factors could have influenced the results. Thus, the percentage of patients with anemia in whom duodenal biopsy was performed has increased over the periods of time analysed as a consequence of a greater knowledge of the manifestations of the disease; although in the management guides of ferropenic anemia duodenal biopsy is recommended during the endoscopic procedure indicated in order to rule out causes of such in the upper GI tract[4], this was only undertaken at the end of the period analysed in a percentage of 73% of the cases; the degree of fulfilment of this recommendation in countries such as the USA or the UK is low (10% and 46%, respectively)[21,22], in spite of the fact that it has been shown that duodenal biopsy for CD in a patient with anemia is a cost-effective approach[23]. We also observed that there were differences in the degree of implication of the endoscopist in the diagnosis of the disease (data not shown); in this sense, differences in the performance of duodenal biopsy among digestive endoscopic services, in the same country, have been reported[21].

The generalization of serological testing in the later periods of the study, above all in the primary care level, allowed the selection for duodenal biopsy of celiac patients with anemia as the only manifestation of the disease; on the other hand, 13 out of 14 celiacs with anemia presented specific antibodies for CD (the only negative case had a mild intestinal lesion - Marsh type 1). These data support the strategies of serological screening in subjects with anemia at primary care level[24,25], in blood donors[26] or in biochemistry laboratories[27] as an effective method of increasing the number of patients diagnosed with silent CD.

We found that adults diagnosed with CD had a mainly classical clinical presentation (55% with diarrhoea) and ferropenic anemia (64%), for which reason we believe that there must still be a large part of the celiac iceberg (silent or atypical forms) remaining undiagnosed. The prevalence of CD in the adult general population in our area, has been estimated to be 1/389[15], which means that only one in nine celiacs could be diagnosed, this being similar to that reported for other geographical areas[1].

We conclude that duodenal biopsy performed during routine upper GI endoscopy, has been incorporated into the daily clinical practice in digestive endoscopic services. This has permitted a significant increase in the number of patients diagnosed with CD, although these are probably only a small percentage of the true number of celiacs in the general population. In our area, the existence of anemia and diarrhoea are the most common risk factors associated with the presence of CD. Clinicians should consider CD as a possible cause of unexplained anemia, and gastroenterologists should biopsy the duodenum when exploring patients with iron-deficiency anemia and/or chronic diarrhoea, even if biopsies are not specifically required.

REFERENCES

1 **Fasano A**, Catassi C. Current approaches to diagnosis and treatment of celiac disease: an evolving spectrum. *Gastroenterology* 2001; **120**: 636-651

2 **Hill ID**, Dirks MH, Liptak GS, Colletti RB, Fasano A, Guandalini S, Hoffenberg EJ, Horvath K, Murray JA, Pivor M, Seidman EG. Guideline for the diagnosis and treatment of celiac disease in children: recommendations of the North American Society for Pediatric Gastroenterology, Hepatology and Nutrition. *J Pediatr Gastroenterol Nutr* 2005; **40**: 1-19

3 **Collin P**, Reunala T, Rasmussen M, Kyrönpalo S, Pehkonen E, Laippala P, Mäki M. High incidence and prevalence of adult coeliac disease. Augmented diagnostic approach. *Scand J Gastroenterol* 1997; **32**: 1129-1133

4 **Goddard AF**, McIntyre AS, Scott BB. Guidelines for the management of iron deficiency anaemia. British Society of Gastroenterology. *Gut* 2000; **46** Suppl 3-4: IV1-IV5

5 **Thomas PD**, Forbes A, Green J, Howdle P, Long R, Playford R, Sheridan M, Stevens R, Valori R, Walters J, Addison GM, Hill P, Brydon G. Guidelines for the investigation of chronic diarrhoea, 2nd edition. *Gut* 2003; **52** Suppl 5: v1-v15

6 **Corazza GR**, Valentini RA, Andreani ML, D'Anchino M, Leva MT, Ginaldi L, De Feudis L, Quaglino D, Gasbarrini G. Subclinical coeliac disease is a frequent cause of iron-deficiency anaemia. *Scand J Gastroenterol* 1995; **30**: 153-156

7 **Annibale B**, Severi C, Chistolini A, Antonelli G, Lahner E, Marcheggiano A, Iannoni C, Monarca B, Delle Fave G. Efficacy of gluten-free diet alone on recovery from iron deficiency anemia in adult celiac patients. *Am J Gastroenterol* 2001; **96**: 132-137

8 **Ransford RA**, Hayes M, Palmer M, Hall MJ. A controlled, prospective screening study of celiac disease presenting as iron deficiency anemia. *J Clin Gastroenterol* 2002; **35**: 228-233

9 **Karnam US**, Felder LR, Raskin JB. Prevalence of occult celiac disease in patients with iron-deficiency anemia: a prospective study. *South Med J* 2004; **97**: 30-34

10 **Mandal AK**, Mehdi I, Munshi SK, Lo TC. Value of routine duodenal biopsy in diagnosing coeliac disease in patients with iron deficiency anaemia. *Postgrad Med J* 2004; **80**: 475-477

11 **Grisolano SW**, Oxentenko AS, Murray JA, Burgart LJ, Dierkhising RA, Alexander JA. The usefulness of routine small bowel biopsies in evaluation of iron deficiency anemia. *J Clin Gastroenterol* 2004; **38**: 756-760

12 **Wahnschaffe U**, Ullrich R, Riecken EO, Schulzke JD. Celiac disease-like abnormalities in a subgroup of patients with irritable bowel syndrome. *Gastroenterology* 2001; **121**: 1329-1338

13 **Shahbazkhani B**, Mohamadnejad M, Malekzadeh R, Akbari MR, Esfahani MM, Nasseri-Moghaddam S, Sotoudeh M, Elahyfar A. Coeliac disease is the most common cause of chronic diarrhoea in Iran. *Eur J Gastroenterol Hepatol* 2004; **16**: 665-668

14 **Collin P**, Rasmussen M, Kyrönpalo S, Laippala P, Kaukinen K. The hunt for coeliac disease in primary care. *QJM* 2002; **95**: 75-77

15 **Riestra S**, Fernández E, Rodrigo L, Garcia S, Ocio G. Prevalence of Coeliac disease in the general population of northern Spain. Strategies of serologic screening. *Scand J Gastroenterol*

2000; **35**: 398-402
16 **Cilleruelo Pascual ML**, Román Riechmann E, Jiménez Jiménez J, Rivero Martín MJ, Barrio Torres J, Castaño Pascual A, Campelo Moreno O, Fernández Rincón A. [Silent celiac disease: exploring the iceberg in the school-aged population]. *An Esp Pediatr* 2002; **57**: 321-326
17 **Castaño L**, Blarduni E, Ortiz L, Núñez J, Bilbao JR, Rica I, Martul P, Vitoria JC. Prospective population screening for celiac disease: high prevalence in the first 3 years of life. *J Pediatr Gastroenterol Nutr* 2004; **39**: 80-84
18 **Oberhuber G**, Granditsch G, Vogelsang H. The histopathology of coeliac disease: time for a standardized report scheme for pathologists. *Eur J Gastroenterol Hepatol* 1999; **11**: 1185-1194
19 **Vitoria JC**, Castaño L, Rica I, Bilbao JR, Arrieta A, García-Masdevall MD. Association of insulin-dependent diabetes mellitus and celiac disease: a study based on serologic markers. *J Pediatr Gastroenterol Nutr* 1998; **27**: 47-52
20 **Farré C**, Humbert P, Vilar P, Varea V, Aldeguer X, Carnicer J, Carballo M, Gassull MA. Serological markers and HLA-DQ2 haplotype among first-degree relatives of celiac patients. Catalonian Coeliac Disease Study Group. *Dig Dis Sci* 1999; **44**: 2344-2349
21 **Harewood GC**, Holub JL, Lieberman DA. Variation in small bowel biopsy performance among diverse endoscopy settings: results from a national endoscopic database. *Am J Gastroenterol* 2004; **99**: 1790-1794
22 **Patterson RN**, Johnston SD. Iron deficiency anaemia: are the British Society of Gastroenterology guidelines being adhered to? *Postgrad Med J* 2003; **79**: 226-228
23 **Harewood GC**. Economic comparison of current endoscopic practices: Barrett's surveillance vs. ulcerative colitis surveillance vs. biopsy for sprue vs. biopsy for microscopic colitis. *Dig Dis Sci* 2004; **49**: 1808-1814
24 **Hin H**, Bird G, Fisher P, Mahy N, Jewell D. Coeliac disease in primary care: case finding study. *BMJ* 1999; **318**: 164-167
25 **Sanders DS**, Patel D, Stephenson TJ, Ward AM, McCloskey EV, Hadjivassiliou M, Lobo AJ. A primary care cross-sectional study of undiagnosed adult coeliac disease. *Eur J Gastroenterol Hepatol* 2003; **15**: 407-413
26 **Unsworth DJ**, Lock RJ, Harvey RF. Improving the diagnosis of coeliac disease in anaemic women. *Br J Haematol* 2000; **111**: 898-901
27 **Howard MR**, Turnbull AJ, Morley P, Hollier P, Webb R, Clarke A. A prospective study of the prevalence of undiagnosed coeliac disease in laboratory defined iron and folate deficiency. *J Clin Pathol* 2002; **55**: 754-757

S- Editor Wang J **L- Editor** Zhu LH **E- Editor** Bai SH

PO Box 2345, Beijing 100023, China
www.wjgnet.com
wjg@wjgnet.com

World J Gastroenterol 2006 August 21; 12(31): 5033-5036
World Journal of Gastroenterology ISSN 1007-9327
© 2006 The WJG Press. All rights reserved.

RAPID COMMUNICATION

Gastric cancer in a Caucasian population: Role of *pepsinogen C* genetic variants

Ana L Pinto-Correia, Hugo Sousa, Maria Fragoso, Luís Moreira-Dias, Carlos Lopes, Rui Medeiros, Mário Dinis-Ribeiro

Ana L Pinto-Correia, Hugo Sousa, Molecular Oncology Group, Portuguese Institute of Oncology of Porto, Portugal
Maria Fragoso, Oncology Department, Portuguese Institute of Oncology of Porto, Portugal
Luís Moreira-Dias, Gastroenterology Department, Portuguese Institute of Oncology of Porto, Portugal
Carlos Lopes, Rui Medeiros, Molecular Oncology Group, Portuguese Institute of Oncology of Porto, Portugal; and ICBAS, Abel Salazar Institute for the Biomedical Sciences, Porto, Portugal
Mário Dinis-Ribeiro, Gastroenterology Department, Portuguese Institute of Oncology of Porto, Portugal; and CINTESIS / Faculty of Medicine University of Porto, Porto, Portugal
Supported by the Portuguese League Against Cancer (Liga Portuguesa Contra o Cancro-Núcleo Regional do Norte) and Astra Zeneca Foundation
Correspondence to: Mário Dinis-Ribeiro, Serviço de Gastrenterologia, Instituto Português de Oncologia do Porto FG EPE, Rua Dr. António Bernardino Almeida, Porto 4200-072, Portugal. mario@med.up.pt
Telephone: +351-22-5084000-3348 Fax: + 351-22-5084001
Received: 2006-04-06 Accepted: 2006-04-24

Abstract

AIM: To study the role of an insertion/deletion polymorphism in the *pepsinogen C* (*PGC*) gene, an effective marker for terminal differentiation of the stomach mucosa, in the susceptibility to the development of gastric lesions.

METHODS: The study was performed with 99 samples of known gastric lesions and 127 samples without evidence of neoplastic disease. PCR was employed and the 6 polymorphic alleles were amplified: Allele 1 (510 bp), Allele 2 (480 bp), Allele 3/4 (450/460 bp), Allele 5 (400 bp) and Allele 6 (310 bp).

RESULTS: Our results revealed that Allele 6 carriers seemed to have protection against the development of any gastric lesion (OR = 0.34; $P < 0.001$), non-dysplastic lesions associated with gastric adenocarcinoma such as atrophy or intestinal metaplasia (OR = 0.28; $P < 0.001$) or invasive GC (OR = 0.39; $P = 0.004$).

CONCLUSION: Our study reveals that the Allele 6 carrier status has a protective role in the development of gastric lesions, probably due to its association with higher expression of PGC. Moreover, the frequency of Allele 6 carriers in the control group is far higher than that obtained in Asian populations, which might represent a genetic gap between Caucasian and Asian populations.

© 2006 The WJG Press. All rights reserved.

Key words: Gastric adenocarcinoma; Pepsinogen C; Polymorphism

Pinto-Correia AL, Sousa H, Fragoso M, Moreira-Dias L, Lopes C, Medeiros R, Dinis-Ribeiro M. Gastric cancer in a caucasian population: Role of *pepsinogen C* genetic variants. *World J Gastroenterol* 2006; 12(31): 5033-5036

http://www.wjgnet.com/1007-9327/12/5033.asp

INTRODUCTION

Gastric adenocarcinoma (GC) is a major public health problem worldwide and the third cause of cancer-related mortality in Europe[1-3]. In Portugal, gastric cancer represents a sixth of all cancer related deaths, with twice the average mortality of European Union and the highest among Western European countries 25/100 000 and 12/100 000 persons × year in men and women, respectively[4,5]. Portuguese inhabitants show a life-time risk for gastric cancer of approximately 2% (95% CI 1.9-2.1), with half the decline observed at other European countries during the last decade[6].

Lauren's classification is most commonly used for gastric adenocarcinoma because of its epidemiologic importance[2,7]. It defines two main morphological types: 'diffuse type' and 'intestinal type'. The latter is characterized by a stepwise transformation from normal mucosa through atrophic gastritis, atrophy, intestinal metaplasia and dysplasia to invasive gastric adenocarcinoma[2,8]. This type shows a male:female ratio of 2:1 and it has been related mostly to environmental factors such as *H pylori* infection and diet[2,6].

However, recently several host genetic variations have been regarded as potential risk markers[9-18]. Pepsinogen is an effective marker of terminal differentiation of the stomach mucosa[19,20]. Pepsinogen C (PGC) is mainly secreted by chief cells of gastric gland, while also by cardiac, pyloric and Brunner glands. Its serum levels have been related with atrophic changes in gastric mucosa and extension of intestinal metaplasia[21,22]. The *pepsinogen C* (*PGC*) gene, localized on chromosome 6 between regions 6p11-6p21.3, encodes the PGC, also known as progastricsin, which is the precursor of pepsin C or gastricsin++[20]. Taggart *et al* have described an insertion/deletion polymorphism of about 100 bp located between exons 7 and

8[23-25], which was regarded as a susceptibility marker for the development of gastric adenocarcinoma[26]. However, the role of this polymorphism has not been completely established and it has never been measured in Caucasian populations.

The aim of this control study was to evaluate the role of the *PGC* polymorphism in the development of GC within a southern European population from the north region of Portugal.

MATERIALS AND METHODS

Patients

A cross-sectional study was performed among healthy individuals without clinical evidence of cancer (n = 127 as control group) and consecutive patients with known gastric lesions (n = 99), both from the northern region of Portugal attending at the Portuguese Institute of Oncology of Porto (Portugal).

Patients were further divided according to the type of lesions presented upon histopathological diagnosis after endoscopic multiple biopsies. It included patients who displayed lesions as severe as high-grade dysplasia and intestinal type invasive gastric adenocarcinoma (n = 52) and patients with non-dysplastic but associated lesions with gastric adenocarcinoma such as atrophy or intestinal metaplasia (n = 47), who belonged to a standardized follow-up since 2001.

All individuals included in this study gave their informed consent before their inclusion in the study, according to the Declaration of Helsinki.

Sample collection and DNA extraction

Blood samples were obtained with a standard venipuncture technique using EDTA containing tubes, and the genomic DNA was extracted from the white blood cell fraction of each sample, using a standard salting out protocol[27].

PGC polymorphism analysis

The analysis of PGC polymorphism (insertion/deletion of approximately 100 bp) located between exons 7 and 8 was carried out by polymerase chain reaction (PCR), as described by Yamagata *et al*[15]. The PCR reaction was performed with the antisense (PGCa: 5'-AGCCCTAA GCCTCTTTTTGG-3') and sense primers (PGCb: 5' -GGCCAGATCTGCGTGTTTTA-3') in a 50 μL PCR reaction mixture containing: 1 × Taq buffer, 1.5 mmol/L of $MgCl_2$, 0.2 mmol/L of dNTPs, 0.25 μmol/L of each primer and 1 U Taq DNA polymerase (Amersham Bioscience, USA). Cycling parameters are: 95℃ for 5 min for Taq DNA polymerase activation, followed by 35 cycles of denaturation for 60 s at 94℃, annealing for 60 s at 55℃, extension for 60 s at 72℃ and a final extension step at 72℃ for 7 min.

PCR amplification identified the following products: 510 bp (Allele 1), 480 bp (Allele 2), 460 bp (Allele 3), 450 bp (Allele 4), 400 bp (Allele 5) and 310 bp (Allele 6); which were analyzed by electrophoresis in a 3% MetaP® Agarose gel (Cambrex Bio Science Rockland Inc, USA) stained with 5% ethidium bromide (Figure 1).

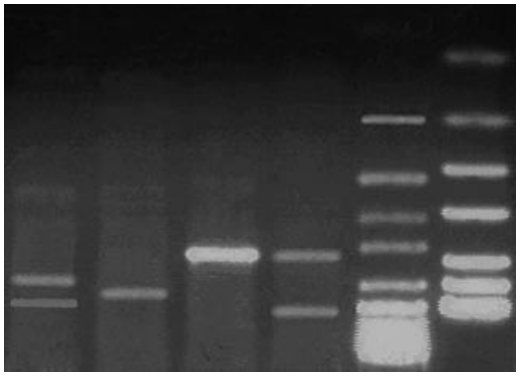

Figure 1 Analysis of *PGC* polymorphism by PCR. M1: 50 bp DNA ladder; M2: pUC DNA ladder; Allele 1 (510 bp); Allele 2 (480 bp); Allele 3/4 (450/460 bp); Allele 5 (400 bp) and Allele 6 (310 bp).

Table 1 Allelic distribution of *PGC* polymorphism according to the type of gastric lesion or its absence *n* (%)

	Allele 1 carrier	Allele 2 carrier	Allele 3/4 carrier	Allele 5 carrier	Allele 6 carrier
Controls (n = 127)	2 (1.6)	31 (24.4)	39 (30.7)	37 (19.1)	92 (72.4)
All cases (n = 99)	1 (1.0)	30 (30.3)	33 (33.3)	39 (39.4)	47 (47.5)
AIM (n = 42)	-	16 (38.1)	14 (33.3)	16 (38.1)	18 (42.9)
GC (n = 57)	1 (1.8)	14 (24.6)	19 (33.3)	23 (40.4)	29 (50.9)

AIM: Atrophy or intestinal metaplasia; GC: Gastric adenocarcinoma.

Variables

The study variables included gastric type of lesion: gastric adenocarcinoma or atrophy or intestinal metaplasia or its absence and *PGC* alleles (1-6).

Statistical analysis

Data analysis was performed using the computer software Statistical Package for Social Sciences - SPSS for Windows (version 11.5). Chi-square analysis was used to compare categorical variables, using a 5% level of significance. Logistic regression was used to estimate odds ratio (OR) and its 95% CI as a measure of the association between *PGC* Allele 6 carrier and risk for the development of gastric lesions.

RESULTS

Allelic distribution of PGC polymorphism

The allelic distribution of the PGC polymorphism is shown in Table 1. No significant differences between controls and patients with known gastric lesions were observed as far as Alleles 1 to 6 were concerned.

Risk estimates for associated lesions and invasive gastric adenocarcinoma

Table 2 describes the risk estimation for the development of different gastric lesions considering Allele 6 carrier status. Significant differences were found in controls and patients with known gastric lesions concerning Allele 6

Table 2 Association of *PGC* Allele 6 carriers and risk for development of associated lesions and invasive gastric adenocarcinoma

	Allele 6 carrier *n* (%)	*P*	OR	95% CI
Controls (*n* = 127)	92 (72.4)		1.00	Reference
All cases (*n* = 99)	47 (47.5)	< 0.001	0.34	0.20-0.60
AIM (*n* = 42)	18 (42.9)	< 0.001	0.28	0.14-0.59
GC (*n* = 57)	29 (50.9)	0.004	0.39	0.21-0.75

AIM: Atrophy or intestinal metaplasia; GC: Gastric adenocarcinoma; *P*: Pearson Chi-Square; OR: Odds ratio; CI: Confidence interval.

carrier status ($P \leqslant 0.001$). Moreover, significant differences were also found for Allele 6 carriers when comparing the different types of gastric lesions with healthy individuals ($P \leqslant 0.001$ and $P = 0.004$).

In addition, the results showed that Allele 6 carrier status had protection against the development of gastric lesions (OR = 0.34; 95% CI 0.20-0.60). This was also true when stratifying the analysis based upon the type of gastric lesions, such as atrophy or intestinal metaplasia (OR = 0.28; 95% CI 0.14-0.59) or invasive GC (OR = 0.39; 95% CI 0.21-0.75).

DISCUSSION

Gastric adenocarcinoma (GC) has distinct geographical distribution with the highest incidence rates in Asian countries, and it remains as the third cause of cancer-related mortality in Europe[1-3]. Portugal has the highest incidence and mortality rates of Western Europe[6]. On the other hand, it is well accepted that cancer is a multifactorial disease and that genetic polymorphism may influence the genetic susceptibility to the development of several cancers[9-18].

Pepsinogen, an effective marker of terminal differentiation of the stomach mucosa, has been used as a serological test for more than 20 years[21]. An insertion/deletion polymorphism in the *PGC* gene has been described as a susceptibility marker for the development of gastric adenocarcinoma. However, only a few studies have been published on pepsinogen C[24-26,28,29]. Up to our knowledge, this is the first study within a southern European population, from the north region of Portugal.

Our results suggest that Allele 6 carriers have protection against the development of gastric lesions such as atrophy, intestinal metaplasia or invasive carcinoma. These results are not in concordance with the results in Asian populations (Table 3). By comparison with the results from Asian populations we observed that carriers of this allele were more frequent in our control group, which might represent a genetic gap between Caucasian and Asian populations. However, when we compared the Allele 6 distribution in the Chinese control population, no homogeneous frequencies were reported. Furthermore, the Allele 6 distribution we found within the Portuguese population is not significantly different from one of the Chinese reports[26].

Table 3 Frequencies of *PGC* Allele 6 carriers within populations

	Population	*n*	Allele 6 Carriers *n* (%)
Our Study	Caucasian (Porto, Portugal)	127	92 (72.4)
Ohtaki et al, 1997	Asian (Fukui, Japan)	177	82 (46.3)
Liu et al, 2003	Asian (Shenyang, China)	42	24 (57.1)
	Asian (Zhuanghe, China)	113	69 (61.0)

Even though our study included a small sample of cases, both allelic distribution and risk estimate seemed to exclude a type I error. A cohort study would seem ideal to estimate accurately risks, however, only a few if any cohort studies in this field are published. The recruitment of controls and the follow-up of patients with atrophy and intestinal metaplasia and with the absence of Allele 6 will probably give us more information in the near future.

The role of the *PGC* polymorphism in the carcinogenesis of GC is not clear. It was reported that PGC was not only a digestive enzyme, but also a growth factor under strict conditions, whereby the levels of serum expression of PGC might play important roles. This *PGC* polymorphism is located between exons 7 and 8, and by the analysis of the genomic sequence (Genome USCS NM_002630; Ref. NM_002630.1) with the Discovery Studio Gene v1.5 (Accelrys Inc), it is possible to identify, within the polymorphic region, an extensive number of TATA-box sequences. TATA-box sequences are extremely important in the activation of gene expression.

We hypothesize that this insertion/deletion polymorphism interferes directly with the number of TATA-box accessible for the activation of PGC expression. Usually as many TATA-boxes are available, as many expressions we could achieve. Although, in the presence of a great number of TATA-boxes, altogether in sequence, they might function as a confounder for the transcriptional activation factors. Thus, if a deletion occurs in a site like this, it would stabilize the activation of gene expression, increasing its levels. Evidences of higher levels of PGC associated with pre-neoplastic lesions could be correlated with this gene expression stabilization[22,30].

Although further studies are required to establish the role of this polymorphism in the development of GC, our study reveals that *PGC* Allele 6 (shorter allele) is associated with protection against development of gastric lesions in a Caucasian population.

REFERENCES

1 **Parkin DM**, Läärä E, Muir CS. Estimates of the worldwide frequency of sixteen major cancers in 1980. *Int J Cancer* 1988; **41**: 184-197

2 **Stoicov C**, Saffari R, Cai X, Hasyagar C, Houghton J. Molecular biology of gastric cancer: Helicobacter infection and gastric adenocarcinoma: bacterial and host factors responsible for altered growth signaling. *Gene* 2004; **341**: 1-17

3 **Boyle P**, Ferlay J. Cancer incidence and mortality in Europe, 2004. *Ann Oncol* 2005; **16**: 481-488

4 **Levi F**, La Vecchia C, Lucchini F, Negri E. Cancer mortality in Europe, 1990-92. *Eur J Cancer Prev* 1995; **4**: 389-417

5 **Black RJ**, Bray F, Ferlay J, Parkin DM. Cancer incidence and

mortality in the European Union: cancer registry data and estimates of national incidence for 1990. *Eur J Cancer* 1997; **33**: 1075-1107

6 **Pinheiro PS**, Tyczynski JE, Bray F, Amado J, Matos E, Parkin DM. Cancer incidence and mortality in Portugal. *Eur J Cancer* 2003; **39**: 2507-2520

7 **LAUREN P**. THE TWO HISTOLOGICAL MAIN TYPES OF GASTRIC CARCINOMA: DIFFUSE AND SO-CALLED INTESTINAL-TYPE CARCINOMA. AN ATTEMPT AT A HISTO-CLINICAL CLASSIFICATION. *Acta Pathol Microbiol Scand* 1965; **64**: 31-49

8 **Correa P**. Human gastric carcinogenesis: a multistep and multifactorial process--First American Cancer Society Award Lecture on Cancer Epidemiology and Prevention. *Cancer Res* 1992; **52**: 6735-6740

9 **Medeiros R**, Morais A, Vasconcelos A, Costa S, Pinto D, Oliveira J, Lopes C. Endothelial nitric oxide synthase gene polymorphisms and genetic susceptibility to prostate cancer. *Eur J Cancer Prev* 2002; **11**: 343-350

10 **Pinto D**, Vasconcelos A, Costa S, Pereira D, Rodrigues H, Lopes C, Medeiros R. HER2 polymorphism and breast cancer risk in Portugal. *Eur J Cancer Prev* 2004; **13**: 177-181

11 **Catarino R**, Matos A, Pinto D, Pereira D, Craveiro R, Vasconcelos A, Lopes C, Medeiros R. Increased risk of cervical cancer associated with cyclin D1 gene A870G polymorphism. *Cancer Genet Cytogenet* 2005; **160**: 49-54

12 **Duarte I**, Santos A, Sousa H, Catarino R, Pinto D, Matos A, Pereira D, Moutinho J, Canedo P, Machado JC, Medeiros R. G-308A TNF-alpha polymorphism is associated with an increased risk of invasive cervical cancer. *Biochem Biophys Res Commun* 2005; **334**: 588-592

13 **Sousa H**, Santos AM, Catarino R, Pinto D, Vasconcelos A, Lopes C, Breda E, Medeiros R. Linkage of TP53 codon 72 pro/pro genotype as predictive factor for nasopharyngeal carcinoma development. *Eur J Cancer Prev* 2006; **15**: 362-366

14 **Craveiro R**, Costa S, Pinto D, Salgado L, Carvalho L, Castro C, Bravo I, Lopes C, Silva I, Medeiros R. TP73 alterations in cervical carcinoma. *Cancer Genet Cytogenet* 2004; **150**: 116-121

15 **Medeiros R**, Soares R, Vasconcelos A, Schmitt F, Lopes C. Glutathione S-transferase genotype GSTM1 as a predictor of elevated angiogenic phenotype in patients with early onset breast cancer. *Angiogenesis* 2004; **7**: 53-58

16 **Ribeiro R**, Vasconcelos A, Costa S, Pinto D, Morais A, Oliveira J, Lobo F, Lopes C, Medeiros R. Overexpressing leptin genetic polymorphism (-2548 G/A) is associated with susceptibility to prostate cancer and risk of advanced disease. *Prostate* 2004; **59**: 268-274

17 **Santos AM**, Sousa H, Portela C, Pereira D, Pinto D, Catarino R, Rodrigues C, Araújo AP, Lopes C, Medeiros R. TP53 and P21 polymorphisms: response to cisplatinum/paclitaxel-based chemotherapy in ovarian cancer. *Biochem Biophys Res Commun* 2006; **340**: 256-262

18 **Vasconcelos A**, Medeiros R, Veiga I, Pereira D, Carrilho S, Palmeira C, Azevedo C, Lopes CS. Analysis of estrogen receptor polymorphism in codon 325 by PCR-SSCP in breast cancer: association with lymph node metastasis. *Breast J* 2002; **8**: 226-229

19 **Miki K**, Ichinose M, Kawamura N, Matsushima M, Ahmad HB, Kimura M, Sano J, Tashiro T, Kakei N, Oka H. The significance of low serum pepsinogen levels to detect stomach cancer associated with extensive chronic gastritis in Japanese subjects. *Jpn J Cancer Res* 1989; **80**: 111-114

20 **Yamagata Z**, Zhang Y, Shinozaki S, Miyamura T, Iijima S, Asaka A, Kobayashi K. Influence of pepsinogen gene polymorphisms on serum pepsinogen. *Ann Hum Genet* 1997; **61** (Pt 2): 93-97

21 **Dinis-Ribeiro M**, da Costa-Pereira A, Lopes C, Barbosa J, Guilherme M, Moreira-Dias L, Lomba-Viana H, Silva R, Abreu N, Lomba-Viana R. Validity of serum pepsinogen I/II ratio for the diagnosis of gastric epithelial dysplasia and intestinal metaplasia during the follow-up of patients at risk for intestinal-type gastric adenocarcinoma. *Neoplasia* 2004; **6**: 449-456

22 **Ning PF**, Liu HJ, Yuan Y. Dynamic expression of pepsinogen C in gastric cancer, precancerous lesions and Helicobacter pylori associated gastric diseases. *World J Gastroenterol* 2005; **11**: 2545-2548

23 **Taggart RT**, Mohandas TK, Bell G. Assignment of the human preprogastricsin (PGC) to chromosome 6 and regional localization of PGC (6pter-p21.1), prolactin PRL (6pter-p21.1). *Cytogenet Cell Genet* 1987; **46**: 701-702

24 **Azuma T**, Pals G, Taggart RT. RFLP for the human pepsinogen C gene (PGC). *Nucleic Acids Res* 1988; **16**: 9372

25 **Taggart RT**, Azuma T, Wu S, Bell GI, Bowcock AM. A highly informative polymorphism of the pepsinogen C gene detected by polymerase chain reaction. *Adv Exp Med Biol* 1991; **306**: 95-99

26 **Liu HJ**, Guo XL, Dong M, Wang L, Yuan Y. Association between pepsinogen C gene polymorphism and genetic predisposition to gastric cancer. *World J Gastroenterol* 2003; **9**: 50-53

27 **Müllenbach R**, Lagoda PJ, Welter C. An efficient salt-chloroform extraction of DNA from blood and tissues. *Trends Genet* 1989; **5**: 391

28 **Ohtaka Y**, Azuma T, Konishi J, Ito S, Kuriyama M. Association between genetic polymorphism of the pepsinogen C gene and gastric body ulcer: the genetic predisposition is not associated with Helicobacter pylori infection. *Gut* 1997; **41**: 469-474

29 **Venkateshwari A**, Vidyasagar A, Prasad R, Pratap B, Pratibha N. Pepsinogen polymorphism in the Indian population and its association with duodenal ulcer. *Hum Genet* 1997; **101**: 201-204

30 **Wells M**, Brown B, Hall J. Pepsinogen C expression in intestinal IEC-6 cells. *Cell Physiol Biochem* 2003; **13**: 301-308

S- Editor Wang J **L- Editor** Zhu LH **E- Editor** Ma N

PO Box 2345, Beijing 100023, China
www.wjgnet.com
wjg@wjgnet.com

World J Gastroenterol 2006 August 21; 12(31): 5037-5043
World Journal of Gastroenterology ISSN 1007-9327
© 2006 The WJG Press. All rights reserved.

RAPID COMMUNICATION

Relation between common polymorphisms in genes related to inflammatory response and colorectal cancer

George Theodoropoulos, Ioannis Papaconstantinou, Evangelos Felekouras, Nikolaos Nikiteas, Petros Karakitsos, Dimitris Panoussopoulos, Andreas Ch Lazaris, Efstratios Patsouris, John Bramis, Maria Gazouli

George Theodoropoulos, Dimitris Panoussopoulos, John Bramis, 1st Propaideutic Surgical Department, Hippocration University Hospital, School of Medicine, University of Athens, Greece
Ioannis Papaconstantinou, 1st Surgical Department, Laikon University Hospital, University of Athens, Greece
Nikolaos Nikiteas, 2nd Propaideutic Surgical Department, Laikon University Hospital, University of Athens, Greece
Petros Karakitsos, Department of Cytopathology, University General Hospital "Attikon", University of Athens, Greece
Andreas Ch Lazaris, Efstratios Patsouris, Department of Pathology, School of Medicine, University of Athens, Greece
Maria Gazouli, Department of Biology, School of Medicine, University of Athens, Greece
Correspondence to: Maria Gazouli, PhD, Michalakopoulou 176, Goudi 11725, Athens, Greece. mgazouli@med.uoa.gr
Telephone: +30-210-7462231 Fax: +30-210-7462340
Received: 2006-02-28 Accepted: 2006-03-20

Abstract

AIM: To investigate the association between common single nucleotide polymorphisms (SNPs) in inflammatory response-related genes such as interleukin (IL)-6, IL-8, tumor necrosis factor α (TNFα), peroxisome proliferators-activated receptor γ (PPARγ), intercellular adhesion molecule-1 (ICAM-1) and the risk of colorectal cancer (CRC) in a group of Greek patients.

METHODS: The study group consisted of 222 CRC patients and 200 healthy controls. Genotyping was performed using allele-specific PCR of PRC-RFLP and the results were confirmed by sequencing. We studied the association of SNPs in the IL-6 (-174G > C), IL-8 (-251T > A), TNFα (-308G > A), ICAM-1 (R241G and K469E), and PPARγ (Pro12Ala) genes and the risk of CRC.

RESULTS: The IL-6 -174G, R241 and K469 alleles of ICAM-1 were associated with increased risk of CRC (OR = 1.77, 95% CI: 1.34-2.34; OR = 1.83, 95% CI: 1.23-2.72; and OR = 1.35, 95% CI: 1.03-1.77 respectively). The IL-8 and TNFα polymorphisms had no effect. Whereas the PPARγ Pro12 genotype was associated with increased risk of disease (OR = 1.78, 95% CI: 1.25-2.49).

CONCLUSION: The association between common SNPs in immunologic response-related genes and CRC is reported in the present study. Apart from shedding light on the mechanisms of malignancy initiation and progression, SNPs may improve appropriate screening for sub-populations at risk.

© 2006 The WJG Press. All rights reserved.

Key words: Colorectal cancer; Inflammation; Single nucleotide polymorphisms

Theodoropoulos G, Papaconstantinou I, Felekouras E, Nikiteas N, Karakitsos P, Panoussopoulos D, Ch Lazaris A, Patsouris E, Bramis J, Gazouli M. Relation between common polymorphisms in genes related to inflammatory response and colorectal cancer. *World J Gastroenterol* 2006; 12(31): 5037-5043

http://www.wjgnet.com/1007-9327/12/5037.asp

INTRODUCTION

Colorectal cancer (CRC), whether sporadic or hereditary, is caused by a defined set of molecular events[1]. A wealth of knowledge has been acquired about the precise molecular events driving CRC formation. Germline mutations in tumor-suppressor adenomatous polyposis coli (APC) genes and DNA mismatch repair (MMR) genes lead to the recognized familial adenomatous polyposis (FAP)-related CRC and the hereditary non-polyposis colorectal cancer (HNPCC), respectively[1]. These inherited cases account for about 5%-10% of CRC[1]. Hereditary factors may then contribute to an estimated further 20% of CRC, especially in patients with a strong family history of CRC[2]. So, up to a quarter of all CRC may occur due to some form of inherited susceptibility to CRC, either in the context of the recognized clinical syndrome or due to germline variants which may carry an increased risk of CRC[2]. Even without a family history of CRC, 1 in 21 of the population develops the disease, usually later in life[2]. Sporadic cases of CRC result from somatic hits to the aforementioned genes[1]. Germline mutation detection is not capable of predicting and screening for sporadic CRC. In other words, excluding inherited types of CRC, the susceptibility of a certain individual to development of sporadic CRC remains largely undetermined.

Since most CRCs arise sporadically, environmental and host immunological factors could significantly

contribute to the initiation and even the progression of this malignancy[3]. Indeed, colonic cells respond to various malignancies-contributing environmental factors based on the genotype of DNA loci associated with metabolic pathways that relate to various dietary constituents[3]. Genetic polymorphisms are thought to play a role in determining how individuals respond at the cellular level to various environmental factors[3].

Immune response undoubtedly has a significant impact on the potential for malignancy, which is highlighted by the clear association between chronic inflammatory conditions and subsequent malignant transformation in the inflamed tissue[4]. Inflammation favors tumorigenesis by stimulating angiogenesis, damaging DNA and chronically stimulating cell proliferation[4,5]. The mixture of cytokines that is produced in the tumor microenvironment plays an important role in cancer pathogenesis[6]. Cancer cells can also respond to host-derived cytokines that promote growth, attenuate apoptosis and facilitate invasion and metastasis[6]. Importantly, cytokine genetic polymorphisms have recently emerged as determinants of gastrointestinal malignant disease susceptibility and severity[4]. Although rather limited, evidence already exists linking common polymorphisms in immunologic parameters to CRC tumorigenesis[5-7].

Bacterial flora keeps the normal colon mucosa in a continuous state of low-grade inflammation, stimulating release of various pro-inflammatory cytokines by the immune cells[8]. Cytokines activate the NF-κB transcription factor signal pathway in epithelial and immune cells, leading to up-regulation of interleukin-6 (IL-6) and IL-8[8]. IL-6 and IL-8 have pro-inflammatory activity in the intestine via the STAT3 intracellular signal pathway[9]. IL-6 also acts as a potent stimulator of metastasis by up-regulating the expression of adhesion receptors on endothelial cells, such as the intercellular adhesion molecule-1 (ICAM-1)[10]. The status of a common functional single G > C base exchange in the human IL-6 gene promoter (chromosome 7p21) increases IL-6 levels[11,12]. It has been found that the A-allele of the -251 T > A SNP in the IL-8 gene is related to higher *in vitro* IL-8 levels after stimulation with lipopolysaccharide and respiratory syncytial bronchiolitis in children[13].

Tumor necrosis factor α (TNFα) is a pro-inflammatory cytokine whose role has been established in the pathogenesis of rheumatoid arthritis and inflammatory bowel disease (IBD)[14]. Its binding to two specific receptors sets up signal transduction mechanisms leading to cell apoptosis and gene regulation, via the MAPKinase and NFκB pathways[14]. The TNFα pro-cancerous effect has recently been established[14]. A SNP within the TNFα locus (-308) has been identified in lymphoma patients[15]. The presence of TNFα -308A allele involved in gene transcription is associated with higher levels of TNFα related to chemotherapy failure and worse overall prognosis[15].

ICAM-1 is expressed on vascular endothelium and plays a key role in the transendothelial migration of neutrophils and T-cell activation[16,17]. It functions as a ligand for β2 integrin molecules present on leukocytes (LFA-1)[17]. The human ICAM-1 gene is a single-copy gene and contains two polymorphic sites in codons 241 (G/R241; Gly/Arg; exon 4) and 469 (K/E469; Lys/Glu; exon 6)[18]. Several immunologic disorders, including inflammatory bowel disease are associated with distinct polymorphisms of ICAM-1[19].

Peroxisome proliferators-activated receptor γ (PPARγ) is a ligand-activated nuclear transcription factor, which plays a central role in orchestrating gene expression in response to exogenous ligands like other PPARs, such as non-steroidal anti-inflammatory agents (NSAIDs)[20-22]. Its implication in immunologic mechanisms and carcinogenesis has been strongly speculated. Natural ligands and drug agonists of PPARγ reduce intestinal inflammation in IBD patients via inhibition of the NF-κB and STAT3 pathways[23], while inactivating PPARγ mutations have been found in sporadic CRC[24]. PPARγ has a polymorphism in the coding region 34C > G that results in the aminoacid change of Pro12Ala[25].

This study focused on the investigation of the aforementioned SNPs as host risk factors for sporadic CRC, using a Greek population cohort.

MATERIALS AND METHODS

Subjects

Two hundred and twenty-two consecutive Greek patients with CRC without previous diagnosis of IBD or any of the known hereditary cancer syndromes (128 males, mean age at diagnosis 66.21 ± 10.67 years and 94 females, mean age at diagnosis 63.12 ± 11.52 years) and 200 healthy sex and age matched controls (120 males, mean age 64.73 ± 15.32 years and 80 females, mean age 60.58 ± 12.35 years) were genotyped. The vast majority of the studied group consisted of truly sporadic cases (198 patients, 89.2%), while 24 patients (10.8%) reported CRC occurrence in at least one first degree relative. Overall, 35.1% of CRC patients had a family history of malignancy.

Genotypic analysis

DNA was extracted from peripheral blood using the QIAamp blood kit (Qiagen, Germany). To confirm the integrity of DNA, a 430-bp sequence in the human glyceraldehyde-3-phosphatate dehydrogenase (GAPDH) gene was amplified.

The IL-6 polymorphism at position 174 was analyzed by allele specific PCR as previously described[26]. Briefly, we used primers framing a 347-bp region surrounding the G-174C allele to amplify the genomic DNA isolated from patients and controls by PCR (sense, 5'-TTGTCA AGACATGCCAAGTGC-3'; anti-sense, 5'-CAGAATG AGCCTCAGAGACATCTCC-3'). In addition, each PCR reaction contained two additional primers designed to detect the G-174G allele (anti-sense, 5'-GCAATGACGT CCTTTAGCATCG-3') and another primer designed to detect the G-174C allele (sense, 5'-CCCCCTAGTTGTG TCTTGCCA-3'). We performed multiplex PCR with all the four primers in one tube. PCR products were isolated on 3% agarose gels and visualized with ethidium bromide staining. Individuals with the IL-6-174 C/C genotype were considered low producers and those with the IL-6 -174 G/C or G/G genotype were considered high producers[27]. Single nucleotide polymorphism-251 T > A in the IL-8 gene was determined using allele specific PCR[13]. The

allele specific primers were 5'-CCACAATTTGGTGAA TTATCAAT-3' (-251A) or 5'-CCACAATTTGGTGAA TTATCAAA-3' (-251T). The consensus primer was 5'-TGCCCCTTCACTCTGTTAAC-3', giving a PCR product of 336 bp. PCR products were isolated on 2% agarose gels and visualized with ethidium bromide staining.

The A-allele of a single nucleotide polymorphism in the promoter region of the TNFα gene (-308G > A) was determined by PCR-RFLP. The primer sequences used were: forward 5'-AGGCAATAGGTTTTGAGGGCCA T-3' and reverse 5'-TCCTCCCTGCTCCGATTCCG-3', which could amplify a 107 bp sequence. PCR products with a G at position -308 were digested by *Nco* I to give two fragments of 87 bp and 20 bp. Those with an A-allele at position -308 were not digested by *Nco* I as previously described[28].

Single base polymorphism at codon 241 (R241G) in exon 4 was determined using allele specific PCR as previously described[29]. We used the primers (5'-GTGG TCTGTTCCCTGGACG-3' and 5'-GTGGTCTGTTCC CTGGACA-3') with the last nucleotide complementary to the allelic variant substitution base on the point mutation in question of the gene ICAM-1, and a common primer (5'-GCGGTCACACTGACTGAGGCCT-3'). The amplified PCR products of 137 bp were analyzed by 2% agarose gel electrophoresis followed by ethidium bromide staining and ultraviolet visualization. The second amino acid polymorphism at codon 469 (K469E) in exon 6 was detected as described by Matsuzawa *et al*[30]. The K469E polymorphism was amplified using primers 5'-CCARCGGGGAATCAGTG-3' and 5'-ACA GAGCACATTCACGGTC-3'. The PCR products were identified by enzyme digestion with *Bst* UI which cuts the E469 allele but not the K469 allele.

Exon 2 of PPARγ was amplified using PCR and the primers G2F (5'-CTGATGTCTTGACTCATGGG-3') and G2R (5'-GGAAGACAAACTACAAGAGC-3') as previously described[31]. The 295 bp PCR product was digested overnight with *Hga* I, which cleaves the Ala allele to generate DNA fragments 178 and 117 bp in size. The DNA fragments were separated on 3% agarose gel.

In all cases, the mutations were confirmed by sequencing analysis using a dye terminator cycle sequencing ready reaction kit (Applied Biosystems), and an ABI 377 automated sequencer. As negative control of the PCR amplifications, we used distilled water instead of genomic DNA and confirmed the fidelity of the reactions.

Statistical analysis

Frequency and susceptibilities of mutations among CRC patients and controls were compared with the chi-square (χ^2) distribution test. Odds ratios (OR) for association were estimated using logistical regression accounting for possible covariates: age, sex and for influence by the remaining genotype loci. Hardy-Weinberg equilibrium for the genotypes was tested using the χ^2 distribution test for the difference in the observed and expected frequencies. All tests were 2-tailed and $P < 0.05$ was considered statistically significant. Inference was aided by SPSS (version 11.0.1, SPSS Inc., Chicago, IL).

Table 1 Tumor parameters in colorectal cancer patients

Parameters	Patients (*n*)
Tumor location	
Rectum	70
Left colon	104
Right colon	48
Tumor size	
≤ 3 cm	69
> 3 cm	153
Growth pattern	
Ulcerative	89
Protruding	133
Differentiation	
Good	43
Moderate	147
Poor	32
TNM stage	
Ⅰ	32
Ⅱ	96
Ⅲ	68
Ⅳ	26

RESULTS

Tumor characteristics are depicted in Table 1. Among the CRC patients, the distribution of the IL-6 genotypes was as follows: GG in 111 patients (50%), CG in 76 patients (34.23%) and CC in 35 patients (15.76%). The distribution of genotypes differed significantly from that in the healthy individuals (Table 2). Additionally, the allele IL-6 -174G was associated with increased risk of CRC, since it was found to be overrepresented among CRC patients (67.1% *vs* 53.5%, $P < 0.0001$, $\chi^2 = 16.35$, OR = 1.77, 95% CI: 1.34-2.34).

Concerning the A allele and AA genotype frequencies of IL-8 at position -251, no significant differences were observed between CRC patients and healthy controls (Table 2). Similarly, no effect of the TNFα (-308G > A) polymorphism was found (Table 2).

Table 2 also summarizes the allelic frequencies and genotypes of the ICAM-1 gene in CRC patient group and controls. No significant differences were observed in the RR (for the R241G) or in the KK (for the K469E) genotype frequencies between CRC patients and controls. Nevertheless, the allelic frequency of both R241 and K469 was significantly higher in CRC patients than in controls ($P = 0.002$, $\chi^2 = 9.24$, OR = 1.83, 95% CI: 1.23-2.72; and $P = 0.031$, $\chi^2 = 4.62$, OR = 1.35, 95% CI: 1.03-1.77, respectively).

As also indicated in Table 2, the C allele (Pro12) of PPARγ was significantly associated with an increased risk of CRC since it was found to be overrepresented among CRC patients compared to controls (84.7% *vs* 76.5% respectively; $P = 0.001$, $\chi^2 = 9.08$, OR = 1.78, 95% CI: 1.25-2.49). Consequently, the CC genotype appeared as the major risk genotype for CRC ($P < 0.001$, $\chi^2 = 16.43$, OR = 2.01, 95% CI: 1.32-3.09).

When co-carriage rates of the offending alleles (IL-6 -174G, ICAM-1 R241, ICAM-1 K469) were compared

Table 2 Allele and genotype frequencies of the polymorphisms under investigation in CRC patients and healthy controls

	Alleles				Genotypes				
IL-6									
	C	G	G allele frequencies (%)	*P*; OR (95% CI)	CC	CG	GG	GG genotype frequencies (%)	*P*; OR (95% CI)
CRC	146	298	67.1	< 0.0001; 1.77 (1.34-2.34)	35	76	111	50	< 0.0005; 2.10 (1.40-3.16)
Controls	186	214	53.5		50	86	64	32	
IL-8									
	A	T	T allele frequencies (%)	*P*; OR (95% CI)	AA	AT	TT	TT genotype frequencies (%)	*P*; OR (95% CI)
CRC	186	258	58.11	0.467; 1.10	40	106	76	34.23	0.256; 0.77
Controls	174	218	54.5	(0.84-1.45)	42	90	64	32	(0.49-1.20)
TNFα									
	G	A	A allele frequencies (%)	*P*; OR (95% CI)	GG	GA	AA	AA genotype frequencies (%)	*P*; OR (95% CI)
CRC	360	84	18.92	0.265; 1.18	152	56	14	6.31	0.586; 1.28
Controls	336	64	16	(0.83-1.68)	146	44	10	5	(0.53-3.1)
ICAM-1 R241G									
	G	R	R allele frequencies (%)	*P*; OR (95% CI)	GG	GR	RR	RR genotype frequencies (%)	*P*; OR (95% CI)
CRC	362	82	18.47	0.002; 1.83	144	74	4	1.8	0.652; 1.50
Controls	356	44	11	(1.23-2.72)	158	40	2	1	(0.26-8.7)
ICAM-1 K469E									
	E	K	K allele frequencies (%)	*P*; OR (95% CI)	EE	EK	KK	KK genotype frequencies (%)	*P*; OR (95% CI)
CRC	236	208	46.85	0.031; 1.35	70	96	56	25.22	0.221; 1.33
Controls	242	158	39.5	(1.03-1.77)	77	88	35	17.5	(0.83-2.12)
PPARγ									
	C	G	C allele frequencies (%)	*P*; OR (95% CI)	CC	CG	GG	CC genotype frequencies (%)	*P*; OR (95% CI)
CRC	376	68	84.7	0.001; 1.78	164	48	10	73.8	< 0.001; 2.01
Controls	306	94	76.5	(1.25-2.49)	118	70	12	59	(1.32-3.09)

between CRC patients and controls, no statistical differences were found. The distribution of genotypes was consistent with Hardy-Weinberg equilibrium only in IL-8 and ICAM-1 cases ($P > 0.05$). Deviation was observed in IL-6, TNFα, and PPARγ cases ($P < 0.05$).

No allele frequency difference was observed when sex and age of either patients or controls were taken into account in the statistical analysis. In addition, stratification of cases by site, tumor stage and the rest of the examined histopathological parameters did not reveal any significant association with the studied polymorphisms.

DISCUSSION

The most compelling evidence for the role of inflammation in gastrointestinal (GI) malignancy comes from studies showing that pro-inflammatory cytokine gene SNPs increase the risk of cancer and its precursors. A number of pro-inflammatory genotypes related to known cytokines (IL-1B, TNFα, IL-10) increase the risk of *H pylori*-induced gastric atrophy and gastric cancer[32,33]. At present, relatively limited information exists on the relationship between colorectal malignancies and cytokine polymorphisms[5,7,34]. Polymorphisms in the IL-6 gene promoter and the R241 and K469 ICAM-1 polymorphic sites were associated with a significantly increased risk of CRC, whereas the PPARγ CC genotype and C allele were both related to reduced risk in the present study.

Our results contrast with the findings of Landi *et al*[5] in terms of the influence of IL-6 SNPs on CRC predisposition, but parallel their results as far as the potential protective role of the PPARγ Ala12 variant. The researchers concluded that the IL-6-174 C genotype confers an increased risk of CRC[5], but in our study, a similar outcome was related to the presence of the G allele in the respective gene. The biological role of the substitution 174G > C has not been fully elucidated by functional studies. Although the C-174 allele is associated with both lower and higher levels of IL-6 expression in various conditions[35-37], one study[7] has been conducted to evaluate the effect of -174G > C SNP on IL-6 serum levels in CRC patients, and found that the GG genotype and absence of the C allele are related to significantly increased levels of IL-6, particularly in the presence of hepatic metastasis. Accordingly, *in vitro*, macrophages from C-negative subjects produce higher IL-6 levels than those from C-positive subjects[38]. Moreover, the fact that high levels of circulating IL-6 are observed in patients with different tumor types and the finding of different levels of IL-6 expression in relation to genetic variants suggest that this cytokine is mainly produced by host cells rather than by cancer cells[7]. We could speculate that the IL-6 G allelic variant might influence the increased cytokine production by immune cells, which in turn induces its stimulatory effect in tumorigenesis. Interestingly as well, Landi *et al*[5] reported that the C genotype is associated with an increased risk of CRC only in those subjects who do not habitually take NSAIDs[5]. A possible cause for the conflicts and mismatches, like those observed here and the earlier study in allele and genotype distributions, may be the differences in ethnic backgrounds. The IL-8 A-251 allele's protective role against CRC, as having been demonstrated by Landi *et al*[5] could not be replicated in our study. It is true that the function of this polymorphism and the role of IL-8 in intestinal inflammation have not yet been

adequately studied[5].

Previous reports support that there is no significant association between the TNFα -308A allele and CRC development like in our study[5,39]. The latter possibly precludes any hypothetical involvement of TNFα-308A in CRC tumorigenesis. In contrast to the aforementioned lack of relevance, the examined TNFα SNP has been found to participate in a genetic profile associated with a high risk for gastric cancer[32,40]. The pro-inflammatory and acid inhibiting properties of TNFα seem to enhance *H pylori* oncogenic or other effects on gastric mucosa[32,40]. Although a similar extrapolation regarding certain large bowel–colonizing bacteria could be made, such a hypothesis would not be supported based at least on our results. Recent studies on SNPs at the TNFα-308 locus have not found any difference between prostate and breast cancer patients or controls[41,42]. In contrast and at least for breast cancer, assays for germline SNPs in TNFβ instead of TNFα may prove useful, since at least for breast cancer, the TNFβ G/G genotype increases the risk of tumorigenesis, while the A allele inhibits that risk[42].

The present study is the first study investigating ICAM-1 SNPs in CRC and reporting the increased allelic frequency of R241 and K469 polymorphisms in this cancer. Previous studies also reported that both R and K allelic variants are associated with IBD[16,19,30], which adds to the mounting molecular evidence about the similarities between IBD-associated cancer and sporadic cancer[8]. Based on ample data concerning the molecular mechanisms involved in colonic mucosal inflammation effects, it is reasonable to speculate that even sporadic cancer might be largely secondary to inflammation[8]. The normal colon could be viewed as being in a perpetual state of inflammation, where cytokine profiles, glycosylation changes, other inflammatory molecule (i.e. prostaglandins) regulation and mucosa-associated bacteria play a central role[8]. Adhesion molecule activity may also have a serious impact on immunologic response. R241 and K469 amino acid changes in the ICAM-1 gene may influence its functional role, as both are located on the Mac-1 binding domain and in the immunoglobin-like domain 5, respectively. The relevance of these specific SNPs could be explained by the functional alteration of the gene product[19]. Some of the inhibitors of HMG-CoA reductase (statins) have also been shown to bind to the ICAM-1 binding domain of LFA-1[43]. The regulation of interaction mediated by adhesion molecules may provide a new target for controlling inflammatory and immune responses.

In keeping with Landi *et al*[5], the PPARγ Ala12 variant is associated with reduced CRC risk. In our study, the PPARγ CC genotype (Pro12) had the strongest relative risk for CRC among the examined genes. The protective effect of the Ala12 variant of PPARγ gene has been recently confirmed by Gong *et al*[44] in sporadic colorectal adenomas. Similarly the polymorphic allele Ala12 is significantly overrepresented in glioblastoma multiform patients, but such an association could not be verified in prostate cancer[25,45]. The PPARγ Ala12 is associated with increased tissue sensitivity to insulin, a decrease in insulin plasma level and reduced release of free fatty acids by adipocytes, which in turn are associated with reduced CRC risk[46,47]. Other plausible mechanisms accounting for this protective effect may lie in PPARγ involvement in regulation and interactions with other colonic cell functions. Activation of PPARγ by ligands inhibits the NF-κB and STAT3 pathways attenuating IBD and related conditions, induces differentiation and apoptosis of CRC cells and decreases DNA synthesis in CRC cell lines[23,48-50]. The recently investigated transcriptional regulation of the tumor suppressor PTEN gene via PPARγ may provide a mechanism for phosphatidylinositol 3-kinase (PI-3kinase)-mediated signaling cascades[51]. Disruption of PPARγ expression seems to prevent the upregulation of PTEN leading to resistance of tumor cells (i.e. pancreatic cancer cells) and macrophages to apoptosis[52]. The latter may open a new dimension in fully understanding the complex mechanisms involved in the interaction of PPARγ and various tumorigenesis elements.

PPARγ activation can lead to altered expression of COX-2, while NSAIDs have been reported to be capable of activating PPARγ[21]. NSAIDs can also alter synthesis of eicosanoids that may bind to and act as ligands for PPARγ through their effects on COX activity[21,22]. Acetylsalicylic acid causes an approximate halving of risk for sporadic CRC[53]. In an era of ongoing attempts to identify suitable target population groups for chemoprevention with anti-inflammatory agents, such SNP analysis and mapping of suitable loci may prove invaluable.

It is noteworthy that other immunology-unrelated genes may also carry an increased risk of developing CRC. It was reported that the Harvey ras-1 variable number tandem repeat (HRAS1-VNTR) polymorphism, the methylenetetrahydrofolate reductase (MTHFR) valine/valine polymorphism and missense mutations in CDH1 (E-cadherin) gene all are associated with an increased risk of CRC tumorigenesis[2]. Apart from shedding light on the mechanisms of sporadic malignancy initiation and progression, SNPs may provide appropriate screening recommendations in intermediate-risk patients, such as those with family history. Only a limited subset of our cohort consisted of such patients and no significant differences were derived in our analysis. Although rather difficult and possibly imprecise during the process of similar studies, taking relevant dietary and lifestyle habits into account is of paramount importance. Simultaneous genotyping and combined analysis of different SNPs in large numbers of patients and controls, stratified by ethnicity, gender and tumor location may make it possible to describe the exact relations between polymorphisms and CRC susceptibility with higher power and may open the way for population-wide genetic screening in the future.

REFERENCES

1 **Tejpar S**, Van Cutsem E. Molecular and genetic defects in colorectal tumorigenesis. *Best Pract Res Clin Gastroenterol* 2002; **16**: 171-185

2 **Fearnhead NS**, Wilding JL, Bodmer WF. Genetics of colorectal cancer: hereditary aspects and overview of colorectal tumorigenesis. *Br Med Bull* 2002; **64**: 27-43

3 **Allen JI**. Molecular biology of colon polyps and colon cancer. *Semin Surg Oncol* 1995; **11**: 399-405

4 **Macarthur M**, Hold GL, El-Omar EM. Inflammation and Cancer II. Role of chronic inflammation and cytokine gene poly-

morphisms in the pathogenesis of gastrointestinal malignancy. *Am J Physiol Gastrointest Liver Physiol* 2004; **286**: G515-G520
5 **Landi S**, Moreno V, Gioia-Patricola L, Guino E, Navarro M, de Oca J, Capella G, Canzian F. Association of common polymorphisms in inflammatory genes interleukin (IL)6, IL8, tumor necrosis factor alpha, NFKB1, and peroxisome proliferator-activated receptor gamma with colorectal cancer. *Cancer Res* 2003; **63**: 3560-3566
6 **Dranoff G**. Cytokines in cancer pathogenesis and cancer therapy. *Nat Rev Cancer* 2004; **4**: 11-22
7 **Belluco C**, Olivieri F, Bonafè M, Giovagnetti S, Mammano E, Scalerta R, Ambrosi A, Franceschi C, Nitti D, Lise M. -174 G>C polymorphism of interleukin 6 gene promoter affects interleukin 6 serum level in patients with colorectal cancer. *Clin Cancer Res* 2003; **9**: 2173-2176
8 **Rhodes JM**, Campbell BJ. Inflammation and colorectal cancer: IBD-associated and sporadic cancer compared. *Trends Mol Med* 2002; **8**: 10-16
9 **Nusrat A**, Sitaraman SV, Neish A. Interaction of bacteria and bacterial toxins with intestinal epithelial cells. *Curr Gastroenterol Rep* 2001; **3**: 392-398
10 **Hutchins D**, Steel CM. Regulation of ICAM-1 (CD54) expression in human breast cancer cell lines by interleukin 6 and fibroblast-derived factors. *Int J Cancer* 1994; **58**: 80-84
11 **Olomolaiye O**, Wood NA, Bidwell JL. A novel NlaIII polymorphism in the human IL-6 promoter. *Eur J Immunogenet* 1998; **25**: 267
12 **Bonafè M**, Olivieri F, Cavallone L, Giovagnetti S, Mayegiani F, Cardelli M, Pieri C, Marra M, Antonicelli R, Lisa R, Rizzo MR, Paolisso G, Monti D, Franceschi C. A gender--dependent genetic predisposition to produce high levels of IL-6 is detrimental for longevity. *Eur J Immunol* 2001; **31**: 2357-2361
13 **Hull J**, Thomson A, Kwiatkowski D. Association of respiratory syncytial virus bronchiolitis with the interleukin 8 gene region in UK families. *Thorax* 2000; **55**: 1023-1027
14 **Waterston A**, Bower M. TNF and cancer: good or bad? *Cancer therapy* 2004; **2**: 131-148
15 **Warzocha K**, Salles G, Bienvenu J, Bastion Y, Dumontet C, Renard N, Neidhardt-Berard EM, Coiffier B. Tumor necrosis factor ligand-receptor system can predict treatment outcome in lymphoma patients. *J Clin Oncol* 1997; **15**: 499-508
16 **Braun C**, Zahn R, Martin K, Albert E, Folwaczny C. Polymorphisms of the ICAM-1 gene are associated with inflammatory bowel disease, regardless of the p-ANCA status. *Clin Immunol* 2001; **101**: 357-360
17 **Hubbard AK**, Rothlein R. Intercellular adhesion molecule-1 (ICAM-1) expression and cell signaling cascades. *Free Radic Biol Med* 2000; **28**: 1379-1386
18 **Vora DK**, Rosenbloom CL, Beaudet AL, Cottingham RW. Polymorphisms and linkage analysis for ICAM-1 and the selectin gene cluster. *Genomics* 1994; **21**: 473-477
19 **Yang H**, Vora DK, Targan SR, Toyoda H, Beaudet AL, Rotter JI. Intercellular adhesion molecule 1 gene associations with immunologic subsets of inflammatory bowel disease. *Gastroenterology* 1995; **109**: 440-448
20 **Jackson L**, Wahli W, Michalik L, Watson SA, Morris T, Anderton K, Bell DR, Smith JA, Hawkey CJ, Bennett AJ. Potential role for peroxisome proliferator activated receptor (PPAR) in preventing colon cancer. *Gut* 2003; **52**: 1317-1322
21 **Lehmann JM**, Lenhard JM, Oliver BB, Ringold GM, Kliewer SA. Peroxisome proliferator-activated receptors alpha and gamma are activated by indomethacin and other non-steroidal anti-inflammatory drugs. *J Biol Chem* 1997; **272**: 3406-3410
22 **Yu K**, Bayona W, Kallen CB, Harding HP, Ravera CP, McMahon G, Brown M, Lazar MA. Differential activation of peroxisome proliferator-activated receptors by eicosanoids. *J Biol Chem* 1995; **270**: 23975-23983
23 **Wada K**, Nakajima A, Blumberg RS. PPARgamma and inflammatory bowel disease: a new therapeutic target for ulcerative colitis and Crohn's disease. *Trends Mol Med* 2001; **7**: 329-331
24 **Sarraf P**, Mueller E, Smith WM, Wright HM, Kum JB, Aaltonen LA, de la Chapelle A, Spiegelman BM, Eng C. Loss-of-function mutations in PPAR gamma associated with human colon cancer. *Mol Cell* 1999; **3**: 799-804
25 **Zhou XP**, Smith WM, Gimm O, Mueller E, Gao X, Sarraf P, Prior TW, Plass C, von Deimling A, Black PM, Yates AJ, Eng C. Over-representation of PPARgamma sequence variants in sporadic cases of glioblastoma multiforme: preliminary evidence for common low penetrance modifiers for brain tumour risk in the general population. *J Med Genet* 2000; **37**: 410-414
26 **Gazouli M**, Zavos G, Papaconstantinou I, Lukas JC, Zografidis A, Boletis J, Kostakis A. The interleukin-6-174 promoter polymorphism is associated with a risk of development of Kaposi's sarcoma in renal transplant recipients. *Anticancer Res* 2004; **24**: 1311-1314
27 **Klauke S**, Schoefer H, Althoff PH, Michels B, Helm EB. Sex hormones as a cofactor in the pathogenesis of epidemic Kaposi's sarcoma. *AIDS* 1995; **9**: 1295-1296
28 **Wilson AG**, di Giovine FS, Blakemore AI, Duff GW. Single base polymorphism in the human tumour necrosis factor alpha (TNF alpha) gene detectable by NcoI restriction of PCR product. *Hum Mol Genet* 1992; **1**: 353
29 **Viganò P**, Infantino M, Lattuada D, Lauletta R, Ponti E, Somigliana E, Vignali M, DiBlasio AM. Intercellular adhesion molecule-1 (ICAM-1) gene polymorphisms in endometriosis. *Mol Hum Reprod* 2003; **9**: 47-52
30 **Matsuzawa J**, Sugimura K, Matsuda Y, Takazoe M, Ishizuka K, Mochizuki T, Seki SS, Yoneyama O, Bannnai H, Suzuki K, Honma T, Asakura H. Association between K469E allele of intercellular adhesion molecule 1 gene and inflammatory bowel disease in a Japanese population. *Gut* 2003; **52**: 75-78
31 **Hara M**, Alcoser SY, Qaadir A, Beiswenger KK, Cox NJ, Ehrmann DA. Insulin resistance is attenuated in women with polycystic ovary syndrome with the Pro(12)Ala polymorphism in the PPARgamma gene. *J Clin Endocrinol Metab* 2002; **87**: 772-775
32 **El-Omar EM**, Rabkin CS, Gammon MD, Vaughan TL, Risch HA, Schoenberg JB, Stanford JL, Mayne ST, Goedert J, Blot WJ, Fraumeni JF Jr, Chow WH. Increased risk of noncardia gastric cancer associated with proinflammatory cytokine gene polymorphisms. *Gastroenterology* 2003; **124**: 1193-1201
33 **Figueiredo C**, Machado JC, Pharoah P, Seruca R, Sousa S, Carvalho R, Capelinha AF, Quint W, Caldas C, van Doorn LJ, Carneiro F, Sobrinho-Simões M. Helicobacter pylori and interleukin 1 genotyping: an opportunity to identify high-risk individuals for gastric carcinoma. *J Natl Cancer Inst* 2002; **94**: 1680-1687
34 **Saito S**, Kasai Y, Nomoto S, Fujiwara M, Akiyama S, Ito K, Nakao A. Polymorphism of tumor necrosis factor in esophageal, gastric or colorectal carcinoma. *Hepatogastroenterology* 2001; **48**: 468-470
35 **Fishman D**, Faulds G, Jeffery R, Mohamed-Ali V, Yudkin JS, Humphries S, Woo P. The effect of novel polymorphisms in the interleukin-6 (IL-6) gene on IL-6 transcription and plasma IL-6 levels, and an association with systemic-onset juvenile chronic arthritis. *J Clin Invest* 1998; **102**: 1369-1376
36 **Terry CF**, Loukaci V, Green FR. Cooperative influence of genetic polymorphisms on interleukin 6 transcriptional regulation. *J Biol Chem* 2000; **275**: 18138-18144
37 **Vickers MA**, Green FR, Terry C, Mayosi BM, Julier C, Lathrop M, Ratcliffe PJ, Watkins HC, Keavney B. Genotype at a promoter polymorphism of the interleukin-6 gene is associated with baseline levels of plasma C-reactive protein. *Cardiovasc Res* 2002; **53:** 1029-1034
38 **Olivieri F**, Bonafè M, Cavallone L, Giovagnetti S, Marchegiani F, Cardelli M, Mugianesi E, Giampieri C, Moresi R, Stecconi R, Lisa R, Franceschi C. The -174 C/G locus affects in vitro/in vivo IL-6 production during aging. *Exp Gerontol* 2002; **37**: 309-314
39 **Park KS**, Mok JW, Rho SA, Kim JC. Analysis of TNFB and TNFA NcoI RFLP in colorectal cancer. *Mol Cells* 1998; **8:** 246-249
40 **Machado JC**, Figueiredo C, Canedo P, Pharoah P, Carvalho R, Nabais S, Castro Alves C, Campos ML, Van Doorn LJ, Caldas C, Seruca R, Carneiro F, Sobrinho-Simões M. A proinflammatory genetic profile increases the risk for chronic atrophic gastritis

and gastric carcinoma. *Gastroenterology* 2003; **125:** 364-371

41 **McCarron SL**, Edwards S, Evans PR, Gibbs R, Dearnaley DP, Dowe A, Southgate C, Easton DF, Eeles RA, Howell WM. Influence of cytokine gene polymorphisms on the development of prostate cancer. *Cancer Res* 2002; **62**: 3369-3372

42 **Park KS**, Mok JW, Ko HE, Tokunaga K, Lee MH. Polymorphisms of tumour necrosis factors A and B in breast cancer. *Eur J Immunogenet* 2002; **29**: 7-10

43 **Nishibori M**, Takahashi HK, Mori S. The regulation of ICAM-1 and LFA-1 interaction by autacoids and statins: a novel strategy for controlling inflammation and immune responses. *J Pharmacol Sci* 2003; **92**: 7-12

44 **Gong Z**, Xie D, Deng Z, Bostick RM, Muga SJ, Hurley TG, Hebert JR. The PPAR{gamma} Pro12Ala polymorphism and risk for incident sporadic colorectal adenomas. *Carcinogenesis* 2005; **26**: 579-585

45 **Paltoo D**, Woodson K, Taylor P, Albanes D, Virtamo J, Tangrea J. Pro12Ala polymorphism in the peroxisome proliferator-activated receptor-gamma (PPAR-gamma) gene and risk of prostate cancer among men in a large cancer prevention study. *Cancer Lett* 2003; **191**: 67-74

46 **Altshuler D**, Hirschhorn JN, Klannemark M, Lindgren CM, Vohl MC, Nemesh J, Lane CR, Schaffner SF, Bolk S, Brewer C, Tuomi T, Gaudet D, Hudson TJ, Daly M, Groop L, Lander ES. The common PPARgamma Pro12Ala polymorphism is associated with decreased risk of type 2 diabetes. *Nat Genet* 2000; **26**: 76-80

47 **Kaaks R,** Toniolo P, Akhmedkhanov A, Lukanova A, Biessy C, Dechaud H, Rinaldi S, Zeleniuch-Jacquotte A, Shore RE, Riboli E. Serum C-peptide, insulin-like growth factor (IGF)-I, IGF-binding proteins, and colorectal cancer risk in women. *J Natl Cancer Inst* 2000; **92**: 1592-1600

48 **Sarraf P**, Mueller E, Jones D, King FJ, DeAngelo DJ, Partridge JB, Holden SA, Chen LB, Singer S, Fletcher C, Spiegelman BM. Differentiation and reversal of malignant changes in colon cancer through PPARgamma. *Nat Med* 1998; **4**: 1046-1052

49 **Kitamura S**, Miyazaki Y, Shinomura Y, Kondo S, Kanayama S, Matsuzawa Y. Peroxisome proliferator-activated receptor gamma induces growth arrest and differentiation markers of human colon cancer cells. *Jpn J Cancer Res* 1999; **90:** 75-80

50 **Toyota M**, Miyazaki Y, Kitamura S, Nagasawa Y, Kiyohara T, Shinomura Y, Matsuzawa Y. Peroxisome proliferator-activated receptor gamma reduces the growth rate of pancreatic cancer cells through the reduction of cyclin D1. *Life Sci* 2002; **70**: 1565-1575

51 **Patel L**, Pass I, Coxon P, Downes CP, Smith SA, Macphee CH. Tumor suppressor and anti-inflammatory actions of PPARgamma agonists are mediated via upregulation of PTEN. *Curr Biol* 2001; **11**: 764-768

52 **Farrow B**, Evers BM. Activation of PPARgamma increases PTEN expression in pancreatic cancer cells. *Biochem Biophys Res Commun* 2003; **301**: 50-53

53 **Dubois RN**. Review article: cyclooxygenase--a target for colon cancer prevention. *Aliment Pharmacol Ther* 2000; **14** Suppl 1: 64-67

S- Editor Wang J **L- Editor** Wang XL **E- Editor** Bai SH

PO Box 2345, Beijing 100023, China
www.wjgnet.com
wjg@wjgnet.com

World J Gastroenterol 2006 August 21; 12(31): 5044-5047
World Journal of Gastroenterology ISSN 1007-9327
© 2006 The WJG Press. All rights reserved.

RAPID COMMUNICATION

Polymorphisms of interleukin-1R receptor antagonist genes in patients with chronic hepatitis B in Iran

Mitra Ranjbar, Amir Houshang Mohammad Alizadeh, Mehrdad Hajilooi, Seyed Mohsen Mousavi

Mitra Ranjbar, Hamadan University of Medical Sciences and Health Services, Sina Hospital, Infectious ward, Hamedan, Iran
Amir Houshang Mohammad Alizadeh, Seyed Mohsen Mousavi, Research Center for Gastroenterology and Liver Diseases, Shaheed Beheshti University of Medical Sciences, Tehran, Iran
Mehrdad Hajilooi, Hamadan University of Medical Sciences and Health Services, Sina Hospital, Infectious ward, Hamedan, Iran
Correspondence to: Mitra Ranjbar, Infectious disease specialist, Hamedan University of Medical Sciences and Health Services, Sina Hospital, Infectious ward, Hamedan, Iran. ahmaliver@yahoo.com
Telephone: +98-912-5049951 Fax: +98-811-8267043
Received: 2005-12-10 Accepted: 2006-01-14

© 2006 The WJG Press. All rights reserved.

Key words: Polymorphism; Interleukin-1R receptor antagonist; Chronic hepatitis B

Ranjbar M, Mohammad Alizadeh AH, Hajilooi M, Mousavi SM. Polymorphisms of interleukin-1R receptor antagonist genes in patients with chronic hepatitis B in Iran. *World J Gastroenterol* 2006; 12(31): 5044-5047

http://www.wjgnet.com/1007-9327/12/5044.asp

Abstract

AIM: To investigate the relationships between polymorphisms of interleukin-1R receptor antagonist genes and susceptibility to chronic hepatitis B in Iran population.

METHODS: Genomic DNA was extracted from the peripheral blood of 80 patients with chronic hepatitis B (57 males, 23 females) aged 12-77 years (mean 36.1 ± 13.8 years) and 147 normal controls (96 males, 51 females) aged 6-75 years (mean 41 ± 18.7 years) who referred to a liver clinic of Tehran and then subjected to polymerase chain reaction (PCR) amplification. PCR products were resolved on a 3% agarose gel and stained with ethidium bromide.

RESULTS: Only three of the five kinds of polymorphism (2/2, 2/4, and 4/4) were found in this study. The frequencies of 2/2, 2/4, and 4/4 were 12.5%, 17.5%, 70% respectively in chronic hepatitis B patients and 6.8%, 24.5%, and 68.7% respectively in controls. IL-1 R allele 2 was detected in 30% of chronic hepatitis B patients and in 31.3% of controls, while IL-1 R allele 4 was detected in 87.5% of chronic hepatitis B patients and in 93.2% of controls. The frequency of IL-1R alleles 2 and 4 was detected in 21.25% and 78.75% of the patients and 19.04% and 80.96% of the controls, respectively.

CONCLUSION: Our results suggest that the carriage of IL-1R receptor antagonist alleles 2, 4, 6 may not play any role in the development of HBV infection. Large population-based studies are needed to investigate the role of IL-1 polymorphisms in the pathogenesis of developing chronic hepatitis B.

INTRODUCTION

Hepatitis B virus (HBV) infection is one of the most important chronic viral diseases in the world. An estimated 400 million people worldwide are carriers of HBV, and approximately 250 000 deaths occur each year as a consequence of fulminant hepatic failure, cirrhosis, and hepatocellular carcinoma[1]. According to the last health and disease survey held in Iran in1999[2], the prevalence of HBV carriers is 1.7%. Therefore over one million people in Iran are HBV carriers. When HBV is acquired in adulthood, the majority of infections are cleared, with chronic infection occurring in 5%-10% of cases. However, the dynamic interaction of the host inflammatory response to HBV and the subsequent impact of this interaction on the clinical outcome of HBV infection, are not yet fully understood, nor are the underlying mechanisms for persistence of the virus.

Cytokines play an important role in defense against viral infection, indirectly through determination of the predominant pattern of the host response and directly through inhibition of viral replication[3]. Interleukin (IL)-1 is one of the most pro-inflammatory agents and has a central role in inflammation and destruction[4]. The most important members of the IL-1 family are the IL-1α, IL-1β, and IL-1 receptor antagonists (ra). IL-1ra is an IL-1 natural competitive inhibitor, acting by occupancy of cell surface receptor without triggering signal transduction[5]. IL-1ra plays a role as an important regulator of inflammation and is currently evaluated in clinical trials. Genes encoding IL-1 are located on the 430 kb region of chromosome 2q13-21, consisting of three homologous genes: IL-1A, IL1B and IL-1ra (IL-1RN)[6]. Biallelic polymorphisms at positions IL-1A -889, IL-1B -511, and

Table 1 Comparison of IL-1R intron 2 polymorphism between chronic hepatitis B patients and controls

	n	Genotyping (%)						Allele frequency (%)			
		2,2	*P*	2,4	*P*	4,4	*P*	2	*P*	4	*P*
IL-1R											
Controls	147	6.8	0.148	24.5	0.225	68.7	0.840	19.04	0.840	80.96	0.148
Chronic hepatitis	80	12.5		17.5		70.0		21.25		78.75	

+ 3953 have been described, all representing a C/T single nucleotide polymorphism (SNP). IL-1RN contains an 86 bp variable number tandem repeat (VNTR) polymorphism in intron 2[7]. These polymorphisms are located within the regulatory regions of the genes and have a potentially functional importance by modulating IL-1 protein production, and are related with the development of some diseases[8].

This study was to discuss the relationship between polymorphisms of IL-1R gene and susceptibility to HBV in the Iranian population, and to reveal the correlation between the genotype and phenotype distributions, in order to provide a certain scientific basis for prevention and treatment of chronic hepatitis B.

MATERIALS AND METHODS

Subjects

A total of 80 patients with chronic hepatitis B (57 males, 23 females) aged 12-77 years (mean 36.1 ± 13.8 years) were recruited in a liver clinic of Tehran. The diagnosis of all the patients was confirmed according to the criteria for chronic hepatitis B, and the patients did not have other viral hepatitis. One hundred and forty-seven control subjects (96 males, 51 females) aged 6-75 years (mean 41 ± 18.7 years) were selected in a liver clinic of Tehran (HBsAg negative, anti-HBe negative, and anti-HBc negative). Liver, renal, endocrine and cardiovascular disorders were excluded. There was no statistical difference in sex between case and control groups, and we also saw a statistically significant difference in age between two groups ($P = 0.026$) but it was not clinically important. AST was over 40 U/L in 24.1% of cases and none of controls, and over 40 U/ L in 31.6% of cases and none of controls, respectively.

PCR preparation

Two microliter peripheral venous blood was collected in an EDTA tube. Genomic DNA was extracted from peripheral blood leukocytes as previously described[9]. Each PCR was carried out in 25 μL reaction mixture containing 100-200 ng genomic DNA, 100 μmol/L dNTP, 25 mmol/L MgC_2, 20 pmol/L primers and 1U TaqDNA polymerase (DNA Technology)[10].

The sequence of the forward primer is 5'-CTCAGCAACACTCCTAT-3'. The reverse primer sequence is 5'-TCCTGGTCTGCAGGTAA-3'. PCR conditions included an initial denaturing step at 94℃ for 5 min, followed by 30 cycles at 94℃ for 1 min, at 60℃ for 1 min, at 70℃ for 2 min, and a final extension at 70℃ for 4 min. Using this PCR strategy, the common allele (allele 1) generated a 410-bp band (including four copies of an 86-bp repeat). The uncommon alleles generated a 240-bp band (two copies of the same repeat, allele 2), a 500-bp band (five copies of the same repeat, allele 3), and a 325-bp band (allele 4). The PCR products were resolved on a 3% agarose gel and stained with ethidium bromide.

HBV-DNA measurement

Serum HBV-DNA levels in patients with chronic hepatitis B were detected with the real-time fluorescent quantitative PCR method (reagents supplied by Sinagen Co. Ltd.). Results were considered abnormal when HBV-DNA > 200 copies/mL.

Statistical analysis

IL-1R (2-6) allele and genotype frequencies were calculated in patients with chronic hepatitis B and control subjects. Comparison of allele and genotype frequencies between groups, and association of IL-1R polymorphisms with HBV-DNA replication and other variables were examined for statistical significance with chi-square test. Analysis was completed with SPSS11.5. $P < 0.05$ was considered statistically significant.

RESULTS

IL-1R (2-6) allele frequencies were measured. IL-1R 3, 5, 6 were negative in all cases and controls. Therefore we deleted them in our results.

IL-1R genotypes

The intron 2 of IL-1RN polymorphism contained VNTR of 86 bp. There were five alleles in humans, including allele 1 (four repeats, 410 bp), allele 2 (two repeats, 240 bp), allele 3 (five repeats, 500 bp), and allele 4 (four repeats, 325 bp). Only three of the five kinds of polymorphism of IL-1R (2/2, 2/4, and 4/4) were found in this study.

Frequencies of IL-1R genotypes in both groups

The genotype and allele frequencies of IL-1RN in patients with chronic hepatitis B and control subjects were determined, and explored with 2 × 2 chi- square test (Table 1).

Only three of the five kinds of polymorphism of IL-1R (2/2, 2/4, and 4/4) were found in this study. The frequencies of 2/2, 2/4, and 4/4 were 12.5%, 17.5%, 70% respectively in chronic hepatitis B patients, and 6.8%, 24.5%, and 68.7% respectively in controls. IL-1R allele 2 was detected in 30% of chronic hepatitis B patients and 31.3% of controls, while IL-1R allele 4 was detected in 87.5% of chronic hepatitis B patients and 93.2% of controls. Allele frequency of IL-1R alleles 2 and

4 was detected in 21.25% and 78.75% of the patients and 19.04% and 80.96% of controls respectively.

There were no significant differences between patients and controls in these regards. However, the 2, 2 and 2, 4 and 4, 4 genotypes were not significantly different between patients and controls, which were 6.8% versus 12.5% (P = 0.148), 24.5% *vs* 17.5% (P = 0.225), and 68.7% *vs* 70% (P = 0.840) respectively. The genotype distribution in controls was also consistent with the Hardy-Weinberg equilibrium (P = 0.215).

DISCUSSION

HBV infection is a major global health problem with an estimated 300 million people chronically infected worldwide[11,12]. Individuals with an inadequate primary immune response to HBV are at increased risk of developing chronic hepatitis B. Age is the strongest host feature associated with chronic infection with 90% infants and 5%-10% of adults developing chronic hepatitis B after exposure to HBV. In addition, people with the same age, sex and ethnical group are exposed to the same HBV strain, which could cause a broad spectrum ranging from no infection to different clinical outcomes[13]. These data suggest that host genetic factors are responsible for the clinical outcomes of HBV infection. Clearance of HBV requires a coordinated innate and adaptive humor- and cell-mediated immune response. Cytokines are soluble polypeptide molecules that mediate cell-to-cell communication and regulate the intensity and duration of the immune response. Previous studies have shown that the maximal capacity of cytokine production varies among individuals and correlates with SNP in the promoter region of various cytokine genes[14,15]. Furthermore, cytokine gene polymorphisms are associated with liver disease severity in patients with viral hepatitis[16]. In the present study, we compared the distributions of interleukin-1R receptor antagonist gene polymorphisms between patients with chronic B and control subjects.

Interleukin-1R receptor antagonist gene is one of the IL-1 gene family members, and located in the proximal region of chromosome 2q13-21. Different polymorphisms have been described in interleukin-1R receptor antagonist genes, and at least two of them could influence the protein production. The IL-1ra gene is also polymorphic due to a variable number (2-6) of tandem repeats of 86 bp (VNTR) within its second intron[17]. This polymorphism has been shown to be unambiguously functional at the level of secreted protein, as monocytes from individuals homo- or heterozygous for allele 2 (IL-1Ra A2 1, IL-1RN * 2, 2 repeats) produce significantly more IL-1ra in response to GM-CSF[18].

Pociot *et al*[19] reported that IL-1B polymorphisms are correlated with IL-1β expression. IL-1B allele T carrier has higher productions of IL-1β than IL-1B allele C carrier. In the present study, genotype distributions and allele frequencies for IL-1B (-511) promoter polymorphisms in patients with chronic hepatitis B and control subjects were not statistically different. Further analysis of the relationship between IL-1B polymorphism and HBV-DNA replication in patients with chronic hepatitis B showed that IL-1B (-511) genotype CC was associated with HBV-DNA replication.

IL-1Ra is a naturally occurring anti-inflammatory protein, competitively blocks the binding of IL-1α and IL-1β type I and type II IL-1 receptors, but exerts no agonist activity, despite sharing 30% amino acid sequence homology with IL-1β, and 19% with IL-1α. IL-1ra has been shown to inhibit the effects of IL-1 both *in vitro* and *in vivo*[20]. There is increasing evidence that IL-1RN polymorphisms are related with susceptibility to individual diseases, including psoriasis, systemic lupus erthematosus, and inflammatory bowel disease[4]. By the study of interleukin-1R receptor antagonist gene intron 2 polymorphisms, our results suggested that the distributions of interleukin-1R receptor antagonist gene 2/2, 2/4, 4/4 genotype in patients with chronic hepatitis B were not significantly different from those in control subjects. A possible explanation of this result could be provided by the fact that carriage of Il-1R allele of each of these polymorphisms may be related with other production of IL-1β[21], which may augment the production of other cytokines, such as IL-2, IL-6 and TNF-α, and trigger the complex immunological processes to eliminate the virus and its complex. It may be also due to the low sample size of our study (The power of study was 68%).

In summary, our results suggest that the carriage of IL-1R receptor antagonist alleles 2, 4, 6 may not play any role in the development of HBV infection. Large population-based studies are needed to investigate the role of IL-1 polymorphisms in the pathogenesis of developing chronic hepatitis B.

ACKNOWLEDGMENTS

The authors acknowledge the contribution of managers of liver clinic of Tehran in this study.

REFERENCES

1 **Perrillo RP**. How will we use the new antiviral agents for hepatitis B? *Curr Gastroenterol Rep* 2002; **4**: 63-71
2 **Noorbala AA,** Kazem M. Health and Disease survey in Iran 1999. *Ministry of Health and Medical Services, Research Deputy* 2000; **6**: 155-183
3 **Koziel MJ**. Cytokines in viral hepatitis. *Semin Liver Dis* 1999; **19**: 157-169
4 **Hutyrová B**, Pantelidis P, Drábek J, Zůrková M, Kolek V, Lenhart K, Welsh KI, Du Bois RM, Petrek M. Interleukin-1 gene cluster polymorphisms in sarcoidosis and idiopathic pulmonary fibrosis. *Am J Respir Crit Care Med* 2002; **165**: 148-151
5 **Ma P,** Chen D, Pan J, Du B. Genomic polymorphism within interleukin-1 family cytokines influences the outcome of septic patients. *Crit Care Med* 2002; **30**: 1046-1050
6 **Nemetz A**, Nosti-Escanilla MP, Molnár T, Köpe A, Kovács A, Fehér J, Tulassay Z, Nagy F, García-González MA, Peña AS. IL1B gene polymorphisms influence the course and severity of inflammatory bowel disease. *Immunogenetics* 1999; **49**: 527-531
7 **Garcia-Gonzalez MA**, Lanas A, Santolaria S, Crusius JB, Serrano MT, Peña AS. The polymorphic IL-1B and IL-1RN genes in the aetiopathogenesis of peptic ulcer. *Clin Exp Immunol* 2001; **125**: 368-375
8 **Moos V**, Rudwaleit M, Herzog V, Höhlig K, Sieper J, Müller B. Association of genotypes affecting the expression of interleu-

kin-1beta or interleukin-1 receptor antagonist with osteoarthritis. *Arthritis Rheum* 2000; **43**: 2417-2422

9 **Miller SA**, Dykes DD, Polesky HF. A simple salting out procedure for extracting DNA from human nucleated cells. *Nucleic Acids Res* 1988; **16**: 1215

10 **Zhang PA,** Li Y, Xu P, Wu JM. Polymorphisms of interleukin-1B and interleukin-1 receptor antagonist genes in patients with chronic hepatitis B. *World J Gastroenterol* 2004; **10**: 1826-1829

11 **Wang FS.** Current status and prospects of studies on human genetic alleles associated with hepatitis B virus infection. *World J Gastroenterol* 2003; **9**: 641-644

12 **Cacciola I**, Cerenzia G, Pollicino T, Squadrito G, Castellaneta S, Zanetti AR, Mieli-Vergani G, Raimondo G. Genomic heterogeneity of hepatitis B virus (HBV) and outcome of perinatal HBV infection. *J Hepatol* 2002; **36**: 426-432

13 **Rapicetta M,** Ferrari C, Levrero M. Viral determinants and host immune responses in the pathogenesis of HBV infection. *J Med Virol* 2002; **67**: 454-457

14 **Miyazoe S,** Hamasaki K, Nakata K, Kajiya Y, Kitajima K, Nakao K, Daikoku M, Yatsuhashi H, Koga M, Yano M, Eguchi K. Influence of interleukin-10 gene promoter polymorphisms on disease progression in patients chronically infected with hepatitis B virus. *Am J Gastroenterol* 2002; **97**: 2086-2092

15 **Pociot F,** Mølvig J, Wogensen L, Worsaae H, Nerup J. A TaqI polymorphism in the human interleukin-1 beta (IL-1 beta) gene correlates with IL-1 beta secretion in vitro. *Eur J Clin Invest* 1992; **22**: 396-402

16 **Ben-Ari Z,** Mor E, Papo O, Kfir B, Sulkes J, Tambur AR, Tur-Kaspa R, Klein T. Cytokine gene polymorphisms in patients infected with hepatitis B virus. *Am J Gastroenterol* 2003; **98**: 144-150

17 **Tarlow JK,** Blakemore AI, Lennard A, Solari R, Hughes HN, Steinkasserer A, Duff GW. Polymorphism in human IL-1 receptor antagonist gene intron 2 is caused by variable numbers of an 86-bp tandem repeat. *Hum Genet* 1993; **91**: 403-404

18 **Danis VA,** Millington M, Hyland VJ, Grennan D. Cytokine production by normal human monocytes: inter-subject variation and relationship to an IL-1 receptor antagonist (IL-1Ra) gene polymorphism. *Clin Exp Immunol* 1995; **99**: 303-310

19 **Kanemoto K,** Kawasaki J, Miyamoto T, Obayashi H, Nishimura M. Interleukin (IL)1beta, IL-1alpha, and IL-1 receptor antagonist gene polymorphisms in patients with temporal lobe epilepsy. *Ann Neurol* 2000; **47**: 571-574

20 **Gabay C,** Smith MF, Eidlen D, Arend WP. Interleukin 1 receptor antagonist (IL-1Ra) is an acute-phase protein. *J Clin Invest* 1997; **99**: 2930-2940

21 **Santtila S,** Savinainen K, Hurme M. Presence of the IL-1RA allele 2 (IL1RN*2) is associated with enhanced IL-1beta production in vitro. *Scand J Immunol* 1998; **47**: 195-198

S- Editor Wang J **L- Editor** Wang XL **E- Editor** Bai SH

PO Box 2345, Beijing 100023, China
www.wjgnet.com
wjg@wjgnet.com

World J Gastroenterol 2006 August 21; 12(31): 5048-5050
World Journal of Gastroenterology ISSN 1007-9327
© 2006 The WJG Press. All rights reserved.

RAPID COMMUNICATION

Occult hepatitis B virus infection and cryptogenic chronic hepatitis in an area with intermediate prevalence of HBV infection

Mohammad Javad Kaviani, Behzad Behbahani, Mohammad Jafar Mosallaii, Fatemeh Sari-Aslani, Seyed Alireza Taghavi

Mohammad Javad Kaviani, Seyed Alireza Taghavi, Gastroenterohepatology research center, Department of Internal medicine, Namazee Hospital, Shiraz University of medical sciences, Shiraz, Iran
Behzad Behbahani, Professor Abdolvahhab Alborzi's pediatric clinical microbiology research center, Namazee Hospital, Shiraz University of medical sciences, Shiraz, Iran
Mohammad Jafar Mosallaii, Fatemeh Sari-Aslani, Department of pathology, Shiraz University of medical sciences, Shiraz, Iran
Correspondence to: Mohammad Javad Kaviani, MD, Department of Internal Medicine, Nemazee hospital, Nemazee square, Shiraz, Iran. kavianim@sums.ac.ir
Telephone: +98-71-16261089
Received: 2005-11-19 Accepted: 2005-12-22

Abstract

AIM: To assess the possible role of occult HBV infection in the pathogenesis of chronic hepatitis in Iranian patients.

METHODS: After exclusion of autoimmune, metabolic and viral etiologies, 104 consecutive adult patients with histologic and biochemical features of chronic hepatitis and negative HBsAg were enrolled in the study. Qualitative PCR with a sensitivity of 150 × 10^3 copies/L, using two primers for Pre-S and core regions was applied to measure presence of HBV DNA in serum of the patients.

RESULTS: All 104 patients completed the study. Qualitative HBV DNA was positive in two patients (1.9%).

CONCLUSION: Occult HBV infection has negligible role in the pathogenesis of cryptogenic chronic hepatitis in Iranian patients.

© 2006 The WJG Press. All rights reserved.

Key words: Hepatitis B; Cryptogenic chronic hepatitis; PCR

Kaviani MJ, Behbahani B, Mosallaii MJ, Sari-Aslani F, Taghavi SA. Occult hepatitis B virus infection and cryptogenic chronic hepatitis in an area with intermediate prevalence of HBV infection. *World J Gastroenterol* 2006; 12(31): 5048-5050

http://www.wjgnet.com/1007-9327/12/5048.asp

INTRODUCTION

Several lines of evidence suggest that hepatitis B virus (HBV) may persist in the serum many years after clearance of hepatitis B surface antigen (HBsAg). These evidences include HBV transmission from liver donors even when HBsAg had been negative and the only positive serologic test was hepatitis B core antibody (HBcAb)[1-3] and appearance of HBsAg and even overt hepatitis in previously HBsAg-negative patients after cancer chemotherapy or immunosuppression[4,5]. It appears that low-level HBV infection may be the source of viral reactivation that is unmasked by immunosuppression. It is speculated that these occult infections may cause chronic hepatitis[6,7], increase the rate of cirrhosis[8,9] and eventually hepatocellular carcinoma[10] and may transmit *via* blood transfusion.

The causes of undetectability of HBsAg in serum (in the presence of persistent HBV infection) may include mutations in the pre-S or S regions (mostly in "a" determinant region) of the virus genome[11-14], decrease in viral load[15] or insufficient sensitivity of the tests used to detect the HBsAg[15]. In some regions with high endemicity (such as China), about 1/3 or more of cirrhotic patients with negative HBsAg may harbor HBV infection[15].

The rate of HBV infection in Iran is unknown but it is the most frequent cause of chronic hepatitis, cirrhosis and hepatocellular carcinoma. It appears that Iran is in a region with intermediate or even low endemicity and the rate of positivity of HBsAg and HBcAb in the general population is 1.8%-5% and over 35% respectively[16].

The goal of the present study was to determine whether a negative test for HBsAg in the serum is sufficient to rule out the possibility of chronic HBV hepatits in Iranian patients with chronic liver disease and to assess the possible role of "a" determinant mutations in Iranian patients with chronic HBV hepatitis. We conducted a prospective study to determine the presence of HBV-DNA in serum of patients with chronic hepatitis and negative HBsAg.

MATERIALS AND METHODS

Patients

After completion of a questionnaire and physical examination, serum samples were collected from 104 adult (> 16 years old) patients (69 males and 35 females) with

chronic (6 mo or more) high alanine amino-transferase (ALT) and negative HBsAg who were referred for liver biopsy to endoscopy wards of Faghihi and Nemzee Hospitals, Shiraz University of Medical Sciences, Shiraz, Fars province, south of Iran, between February 1997 to December 2001.

Diagnosis of chronic hepatitis was based on a minimum of 6 mo or more persistent elevation of ALT (more than 60 or 1.5 times of upper limit of normal value) and grade of necro-inflammation of more than 3/18 of Ishak (modified Knodell) classification in liver histology. All active alcohol users (drinking of more than 20 g alcohol per day), patients with biliary obstruction, cardiac failure, active cancer or chronic infection (such as tuberculosis) and cirrhosis (shrunken liver in ultrasonography and regenerative nodules in histology and one of these features: history compatible with grade 2 of hepatic encephalopathy, endoscopically confirmed esophageal or fundal varices, ascites, hypersplenism), positive HBsAg, positive anti-smooth muscle antibody, positive anti-nuclear antibody, positive anti-mitochondrial antibody, low titers of alpha-one-anti-trypsin or ceruloplasmin, abnormal iron or cupper levels, predominant steatohepatitis, biliary duct injury or congestion (Budd-Chiari syndrome) in liver histology were excluded from the study.

Demographic, biochemical and serological data, histological findings and results of PCR of our patients are shown in Table 1.

Table 1 Demographic, biochemical and serological data and histological findings

Variable	Result
Sex (M/F)	69/35
Age (yr)	Mean: 34.8 ± 10.3, Min: 17, Max: 71
Mean AST nkat/L (± SD)[1]	2312.1 (± 373.4)
Mean ALT nkat/L (± SD)[1]	2525.5 (± 430.1)
Mean ALK Ph[2] nkat/L (± SD)[3]	6656.3 (± 943.5)
HCV Ab (+/-)	68/36
Serum HBV-DNA (+/-)	2/102
Mean grade of necro-inflammation (of 18) (± SD)	8.2 (± 3.4)
Mean stage of fibrosis (of 6) (± SD)	3.1 (± 1.7)

[1]Normal < 667 nkat/L, [2]Alk Ph means alkaline phosphatase, [3]Normal: 1084-5251 nkat/L.

Serological assays and PCR

All serological tests including HBsAg, IgG-anti HBcAb, second generation of anti-hepatitis C virus antibody (HCVAb), hepatitis B e antigen (HBeAg) and IgG-antibody to hepatitis B e antigen (HBeAb) were performed using ELISA based on manufacturers' instructions.

PCR-assay

In order to prevent any contamination, we strictly adhered to the standard guideline of PCR procedure. Fifty microliters of serum were diluted 1:5 with 250 μL NaOH (50 mmol/L) for DNA denaturation and RNA inactivation. Samples were then heated at 95℃ for 20 min to denature proteins. Forty microliters of Tris 1 mmol/L (pH = 7.3) was then added and centrifuged at 14000 r/min for 7 min. Forty microliters of phenols-chloroform (1:1) were added and centrifuged at 14000 r/min for 7 min. Ten microliters of sodium acetate (3 mol/L) and 300 μL absolute ethanol were added to each tube. After incubation at -70℃ for 40-60 min, tubes were centrifuged at 14000 r/min for 10 min. Supernatant was removed and 50-100 μL of TE buffer (pH = 7.8) was added to the pellets. PCR-amplification was performed using published oligonucleotide primers[17] selected from highly conserved HBV surface gene, whereby primer 1 and primer 2 flank 597 base-pair fragment.

Five microliters of sample were added to 45 μL of reaction mixture (2.5 U Tag polymerase, 22.5 μmol/L of each primer, 200 μmol/L of each deoxynucleotide triphosphate, 5 μL of reaction buffer [50 mmol/L KCl, 10 mmol/L Tris-HCl pH = 8.3 and 1.5 mmol/L $MgCl_2$). Samples were denatured for 5 min at 94℃ and then subjected to 40 cycles of 1 min at 58℃, 1 min at 72℃ and 1 min at 94℃ in an Eppendorf thermal cycler (Master cycler 5330).

Ten microliters of reaction product was electrophoresed in a 18 g/L agarose gel made in Tris-acetate-EDTA (TAE) buffer (pH = 8-8.5) and visualized by ultra-violet illumination after ethidium bromide (10 mg/L) staining. Positive and negative controls were also treated as samples.

PCR amplification was also performed using HBV-PCR detection kit (Cinna Gen Inc., Teheran, Iran). According to manufacturer's instruction, 5 μL of extracted DNA was added to 20 μL of a PCR mixture, which contained primers amplifying 353 bp of the region of the core gene. Samples were denatured for 2 min at 94℃ and then subjected to 40 cycles of 93℃ for 40 min, 62℃ for 40 min, 72℃ for 40 min and finally 72℃ for 10 min. The sensitivity of PCR assay was 150×10^3 copies/mL.

RESULTS

Only two patients had HBV DNA in their sera. Demographic, biochemical data, serological data, and histological findings of these patients are shown in Table 2. Both patients had major thalassemia and were on regular blood transfusion for many years.

DISCUSSION

There is much controversy and suspicion about the possible role of hepatitis B infection in pathogenesis of cryptogenic chronic parenchymal liver diseases especially in areas with intermediate or high infection rates of hepatitis B. Although the exact mechanism for active viral infection with undetectable HBsAg in the serum is not clear, both mutations in S region of the viral genome as well as low-titer infections (including possible burned-out infections) are proposed as possible explanations. It is however obvious with either of these two mechanisms being true, there should be detectable viral genome in serum of a majority of such patients using sensitive amplification techniques.

In this study, only less than 2% of our patients had HBV-DNA in their sera and it appears that HBV infection had a minimal role in causing chronic hepatitis in HBsAg negative Iranian patients with chronic hepatitis. Because of lack of a control group of normal individuals to which

Table 2 Demographic, biochemical, serological and histological data of patients with positive HBV-DNA

Variable	Patient No. 18	Patient No. 47
Age (yr)	21	27
Sex	M	F
AST nkat/L (± SD)[1]	1617	2917.3
ALT nkat/L (± SD)[1]	1667	2334
Alk Ph[2] nkat/L (± SD)[3]	2133.8	8568.4
Grade of necro-inflammation (of 18)	4	18
Stage of fibrosis (of 6)	3	5
HBsAb	-	+
HBcAb	+	-
HBeAg	+	+
HBeAb	-	-
HCV-Ab	+	+

[1]Normal < 667 nkat/L; [2]Alk Ph means alkaline phosphatase; [3]Normal: 1084-5251 nkat/L.

the incidence of positive HBV DNA in serum can be compared, the possible role of occult HBV infection in etiology of cryptogenic liver disease in this country cannot be totally excluded, nevertheless, it can be certainly stated that this role if, exist at all will be of minimal, negligible impact.

This data is the same as that found by western researchers but in contradiction with findings in high incidence areas of the world[15]. The possible explanation for these different results may lie in the different incidences as well as different genotypes of hepatitis B prevalence in these areas.

It should be further emphasized that two patients with positive HBV DNA in this study were both known cases of major thalassemia with a history of multiple transfusions and also had concomitant HCV infection. It is therefore can be concluded that the incidence of occult HBV infection in those with no history of high risk conditions for blood borne infections will be much lower.

Based on the findings of this study, we conclude that there is no need for HBV DNA PCR in routine work up for the chronic liver disease patients with negative HBsAg in Iran.

REFERENCES

1 **Chazouillères O**, Mamish D, Kim M, Carey K, Ferrell L, Roberts JP, Ascher NL, Wright TL. "Occult" hepatitis B virus as source of infection in liver transplant recipients. *Lancet* 1994; **343**: 142-146

2 **Tai DI**, Chung ZJ, Chen CL, Eng HL. Reappearance of HBsAg with compartmentalized different HBV strains in allograft versus PBMC of the recipient. *J Gastroenterol* 2001; **36**: 200-205

3 **Ghany MG**, Ayola B, Villamil FG, Gish RG, Rojter S, Vierling JM, Lok AS. Hepatitis B virus S mutants in liver transplant recipients who were reinfected despite hepatitis B immune globulin prophylaxis. *Hepatology* 1998; **27**: 213-222

4 **Iannitto E**, Minardi V, Calvaruso G, Mulè A, Ammatuna E, Di Trapani R, Ferraro D, Abbadessa V, Craxí A, Di Stefano R. Hepatitis B virus reactivation and alemtuzumab therapy. *Eur J Haematol* 2005; **74**: 254-258

5 **Davis CL**, Gretch DR, Carithers RL Jr. Hepatitis B and transplantation. *Infect Dis Clin North Am* 1995; **9**: 925-941

6 **Huo TI**, Wu JC, Lee PC, Chau GY, Lui WY, Tsay SH, Ting LT, Chang FY, Lee SD. Sero-clearance of hepatitis B surface antigen in chronic carriers does not necessarily imply a good prognosis. *Hepatology* 1998; **28**: 231-236

7 **Zhang YY**, Nordenfelt E, Hansson BG. Increasing heterogeneity of the 'a' determinant of HBsAg found in the presumed late phase of chronic hepatitis B virus infection. *Scand J Infect Dis* 1996; **28**: 9-15

8 **Liang TJ**, Baruch Y, Ben-Porath E, Enat R, Bassan L, Brown NV, Rimon N, Blum HE, Wands JR. Hepatitis B virus infection in patients with idiopathic liver disease. *Hepatology* 1991; **13**: 1044-1051

9 **Chung HT**, Lai CL, Lok AS. Pathogenic role of hepatitis B virus in hepatitis B surface antigen-negative decompensated cirrhosis. *Hepatology* 1995; **22**: 25-29

10 **Paterlini P**, Gerken G, Nakajima E, Terre S, D'Errico A, Grigioni W, Nalpas B, Franco D, Wands J, Kew M. Polymerase chain reaction to detect hepatitis B virus DNA and RNA sequences in primary liver cancers from patients negative for hepatitis B surface antigen. *N Engl J Med* 1990; **323**: 80-85

11 **Seddigh-Tonekaboni S**, Waters JA, Jeffers S, Gehrke R, Ofenloch B, Horsch A, Hess G, Thomas HC, Karayiannis P. Effect of variation in the common "a" determinant on the antigenicity of hepatitis B surface antigen. *J Med Virol* 2000; **60**: 113-121

12 **Weinberger KM**, Bauer T, Böhm S, Jilg W. High genetic variability of the group-specific a-determinant of hepatitis B virus surface antigen (HBsAg) and the corresponding fragment of the viral polymerase in chronic virus carriers lacking detectable HBsAg in serum. *J Gen Virol* 2000; **81**: 1165-1174

13 **Chung HT**, Lee JS, Lok AS. Prevention of posttransfusion hepatitis B and C by screening for antibody to hepatitis C virus and antibody to HBcAg. *Hepatology* 1993; **18**: 1045-1049

14 **Kato J**, Hasegawa K, Torii N, Yamauchi K, Hayashi N. A molecular analysis of viral persistence in surface antigen-negative chronic hepatitis B. *Hepatology* 1996; **23**: 389-395

15 **Chan HL**, Tsang SW, Leung NW, Tse CH, Hui Y, Tam JS, Chan FK, Sung JJ. Occult HBV infection in cryptogenic liver cirrhosis in an area with high prevalence of HBV infection. *Am J Gastroenterol* 2002; **97**: 1211-1215

16 **Merat S**, Malekzadeh R, Rezvan H, Khatibian M. Hepatitis B in Iran. Archives of Iranian Medicine 2000; 4 (http://www.ams.ac.ir/AIM/0034/merat0034.html)

17 **Gish RG**, Lau JY, Brooks L, Fang JW, Steady SL, Imperial JC, Garcia-Kennedy R, Esquivel CO, Keeffe EB. Ganciclovir treatment of hepatitis B virus infection in liver transplant recipients. *Hepatology* 1996; **23**: 1-7

S- Editor Pan BR **L- Editor** Zhu LH **E- Editor** Bi L

PO Box 2345, Beijing 100023, China
www.wjgnet.com
wjg@wjgnet.com

World J Gastroenterol 2006 August 21; 12(31): 5051-5054
World Journal of Gastroenterology ISSN 1007-9327
© 2006 The WJG Press. All rights reserved.

RAPID COMMUNICATION

Differentiation of rat bone marrow stem cells in liver after partial hepatectomy

Yu-Tao Zhan, Yu Wang, Lai Wei, Bin Liu, Hong-Song Chen, Xu Cong, Ran Fei

Yu-Tao Zhan, Bin Liu, Department of Gastroenterology, Beijing Tongren Hospital, Capital Medical University, Beijing 100730, China
Yu Wang, Lai Wei, Hong-Song Chen, Xu Cong, Ran Fei, Hepatology Institute, Beijing University People's Hospital, Beijing 100044, China
Supported by the National High Technology Research And Development Program of China (863 Program), No. 2001AA217151
Co-first-author: Yu Wang
Correspondence to: Yu-Tao Zhan, Department of Gastroenterology, Beijing Tongren Hospital, Capital Medical University, Beijing 100730, China. yutaozhan@263.net
Telephone: +86-10-58268473
Received: 2005-09-23 Accepted: 2005-10-26

Abstract

AIM: To investigate the differentiation of rat bone marrow stem cells in liver after partial hepatectomy.

METHODS: Bone marrow cells were collected from the tibia of rat with partial hepatectomy, the medial and left hepatic lobes were excised. The bone marrow stem cells ($Thy^+CD3^-CD45RA^-$ cells) were enriched from the bone marrow cells by depleting red cells and fluorescence-activated cell sorting. The sorted bone marrow stem cells were labeled by PKH26-GL *in vitro* and autotransplanted by portal vein injection. After 2 wk, the transplanted bone marrow stem cells in liver were examined by the immunohistochemistry of albumin (hepatocyte-specific marker).

RESULTS: The bone marrow stem cells ($Thy^+CD3^-CD45RA^-$ cells) accounted for 2.8% of bone marrow cells without red cells. The labeling rate of 10 μM PKH26-GL on sorted bone marrow stem cells was about 95%. There were sporadic PKH26-GL-labeled cells among hepatocytes in liver tissue section, and some of the cells expressed albumin.

CONCLUSION: Rat bone marrow stem cells can differentiate into hepatocytes in regenerative environment and may participate in liver regeneration after partial hepatectomy.

© 2006 The WJG Press. All rights reserved.

Key words: Bone marrow stem cells; Liver regeneration; Differentiation

Zhan YT, Wang Y, Wei L, Liu B, Chen HS, Cong X, Fei R. Differentiation of rat bone marrow stem cells in liver after partial hepatectomy. *World J Gastroenterol* 2006; 12(31): 5051-5054

http://www.wjgnet.com/1007-9327/12/5051.asp

INTRODUCTION

Recent studies indicate that mice and human bone marrow cells can differentiate into hepatocytes in normal liver and rat bone marrow cells can turn into hepatocytes in severely damaged liver with the suppression of hepatocyte proliferation[1-6]. However, whether rat bone marrow stem cells can differentiate into hepatocytes in liver after partial hepatectomy remains unclear. The aim of this study was to investigate the differentiation of rat bone marrow cells in regenerative environment after partial hepatectomy.

MATERIALS AND METHODS

Animals

Male Sprague-Dawley rats weight 170-190 g were obtained from the Animal Center of Peking University People's Hospital. They were allowed to have free access to standard laboratory chow and kept in a 12 h light/dark cycle.

Materials

Erythrolysin, phycoerythrin-conjugated mouse anti-rat CD45RA and phycoerythrin-conjugated mouse anti-rat CD3 were purchased from Becton Dickinson Inc. Fluorescein isothiocyanate-conjugated mouse anti-rat Thy-1.1 was obtained from Pharmingen Inc. PKH26-GL was purchased from Sigma Inc. Mouse anti- albumin antibody was obtained from Dako Inc. FITC-labeled anti- mouse IgG was supplied by Zhongshan Inc. RPMI 1640 was from Gibco Inc.

Partial hepatectomy rat model

The rats were anesthetized with intraperitioneal injection of sodium pentobarbital (35 mg/kg body weight). Local skin was sterilized by routine method. Partial hepatectomy rat model was established by resecting medial and left liver lobes.

Bone marrow stem cell enrichment

Under general anesthesia, bone marrow was aspirated

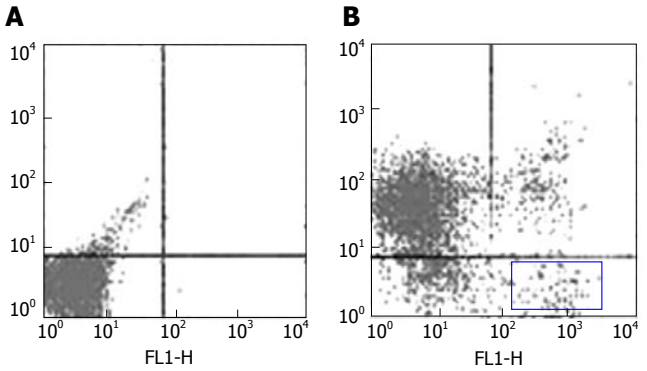

Figure 1 Bone marrow stem cells sorted by flow-cytometry. **A**: Control; **B**: Percentage of Thy$^+$CD3$^-$CD45RA$^-$ cells in bone marrow cells without erythrocytes (about 2.8%).

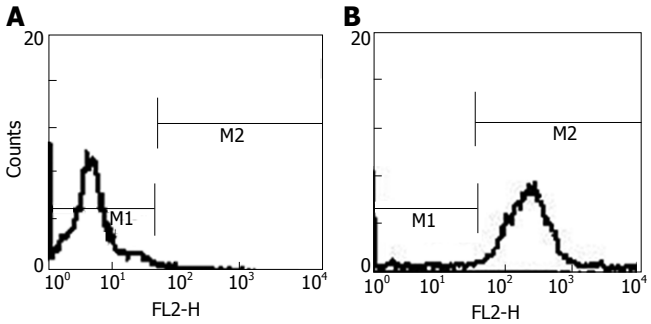

Figure 2 PKH26-GL labeling of Thy$^+$CD3$^-$CD45RA$^-$ cells. **A**: Control; **B**: Percentage of PKH26-GL-labeled cells in Thy$^+$CD3$^-$CD45RA$^-$ cells. (M1: unlabeled cells; M2: labeled cells).



Figure 3 Red Thy$^+$CD3$^-$CD45RA$^-$ cells with PKH26-GL under fluorescence microscope.

from tibia with a syringe containing 1 mL heparin with an 18-gauge needle. The marrow cells were transferred to a sterile tube and mixed with 10 mL culture medium (RPM1640 supplemented with 10% fetal bovine serum, 100 μ/mL penicillin G and 100 μg/mL streptomycin). Red blood cells in bone marrow were depleted by erythrolysin. After washed three times with phosphate-buffered saline (PBS), the cells were incubated at 4℃ for 30 min with fluorescein isothiocyanate-conjugated anti-Thy, phycoerythrin-conjugated anti-CD3 and phycoerythrin-conjugated anti-CD45RA. The cells were washed three times and resuspended in medium. Labeled cells were analyzed and separated with FASC-vantage (Becton Dickinson, San Jose, CA). Gating was based on Thy-positive, CD3-negtive and CD45RA-negtive.

Bone marrow stem cell staining with PKH26-GL

The sorted Thy$^+$CD3$^-$CD45RA$^-$ cells were labeled by 10 μM PKH26-GL. Labeling conditions employed were essentially as described by the manufacturer. Briefly, cells were suspended in Diluent C at a density of 2×10^6 cells/mL and mixed with an equal volume of the PHk26-GL dye in Diluent C to give a final dye concentration of 10 μmol/L. Labeling was carried out at room temperature for 3 min. The labeling reaction was terminated by the addition of an equal volume of fetal bovine serum. Labeled cells were diluted with culture medium containing serum and washed three times.

Bone marrow stem Cell transplantation

The PKH26-GL-labeled bone marrow stem cells were suspended in 300 μL of RPM1640 without serum at a concentration of 1×10^6 cells and autotransplanted by portal vein injection.

Immunochemistry

The liver tissue was obtained at two weeks after partial hepatectomy. Frozen sections were made and incubated overnight at 4℃ in 50 μL anti-albumin antibody (1:50), then washed three times in PBS and incubated for 1 h at 37℃ in 50 μL FITC-labeled second antibody. After washed three times with PBS, the slides were occluded by glycerin buffer and observed under confocal laser scanning microscope.

RESULTS

Bone marrow stem cell enrichment

After erythrocytes were depleted in tibia bone marrow cells from rats after partial hepatectomy. Bone marrow stem cells were enriched by sorting the Thy$^+$CD3$^-$CD45RA$^-$ cells. The sorted cells accounted for about 2.8 % (Figure 1).

Enriched bone marrow stem cell staining with PKH26-GL

The Thy$^+$CD3$^-$CD45RA$^-$ cells were labeled with 10 μM PKH26-GL. The percentage of labeled cells was about 95% (Figure 2). The labeled Thy$^+$CD3$^-$CD45RA$^-$ cells were red under fluorescence microscope (Figure 3). PKH26-GL had no obvious effect on bone marrow cell viability. Trypan blue staining assay showed that the cell viability of PKH26-GL-labeled bone marrow cells was higher than 85%.

Immunohistochemistry staining for albumin

PKH26-Gl could emit red fluorescence at the wavelength of 567 nm, while FITC could emit green fluorescence at the wavelength of 494 nm. We tested liver tissue sections under confocal laser scanning microscope at the two wavelengths respectively. There were sporadic cells with red fluorescence among hepatocytes in liver sections (Figure 4A), suggesting that PKH26-GL- labeled bone marrow

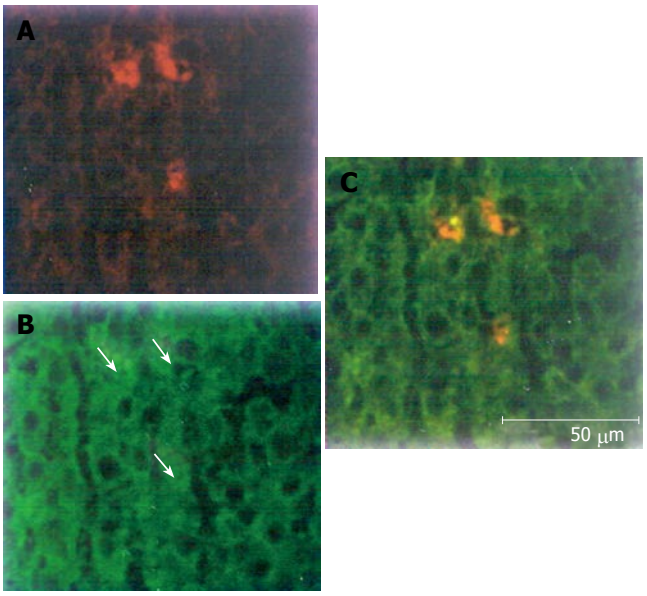

Figure 4 Red sporadic PKH26-GL-labeled cells (**A**), green hepatocytes (**B**), and yellow PKH26-GL-labeled cells expressing albumin (**C**).

stem cells could migrate into liver. Hepatocytes showing green fluorescence suggested that hepatocytes expressed albumin (Figure 4B). Yellow was mixed with red and green. Yellow cells derived from PKH26-GL labeled *in vitro* bone marrow stem cells expressed albumin (Figure 4C). The findings indicated that bone marrow stem cells could differentiate into hepatocytes in regenerative hepatic environment after partial hepatectomy.

DISCUSSION

Seventy percent hepatectomy rat model is a classical animal model to study liver regeneration. The remaining hepatic lobes of the model rat can restore the liver mass at 2 wk after partial hepatectomy. It has been considered that the regeneration process is due to the proliferation of residual mature hepatocytes. Recently, important developments have been achieved in the field of stem cell study. Petersen *et al*[3] used 3 separate approaches to follow transplanted bone marrow cells and found an extrahepatic source for the liver cells. In a careful histological analysis of irradiated female mice that received male donor cells, the Y chromosome could be detected in some hepatocytes 2 to 6 mo after transplantation in the absence of any intentional liver injury[7]. In human female recipients of male bone marrow, some hepatocytes contain the Y chromosome[8]. These findings suggest that there is a linkage between bone marrow cells and liver. It is hypothesized that, similar to other organ systems, the liver has 3 levels of cells: "mature" hepatocyte, original tissue-determined stem cells represented in the adult organ by cells in the terminal bile ductules (canals of Hering), and a multipotent stem cells in the liver derived from circulating bone marrow stem cells[9]. However, whether circulating bone marrow stem cells can differentiate into hepatocytes in regenerative liver after partial hepatectomy remains unclear.

PKH26-GL shows little or no toxicity except for some phototoxicity following prolonged exposure of PKH26-GL labeled cells to excitation light and can be used to track lymphocyte migration for weeks to months[10,11]. It is the dye of choice for cell migration and proliferation studies. PKH26-GL has been used to *in situ* label mouse spleen cells and peripheral blood neutrophils, and is particularly effective in monitoring the *in vivo* homing and proliferation of haemopoietic stem cells[12-14]. Our study showed that 10 μmol/L PKH26-GL could effectively label rat bone marrow cells and has no obvious effect on cell viability. PKH26-GL-labeled bone marrow cells were autotransplanted in rats during partial hepatectomy. After 2 wk, there were PKH26-GL-labeled cells in liver, and the cells expressed hepatocyte-specific marker albumin. The result showed that bone marrow cells could differentiate into hepatocytes in regenerative hepatic environment. Bone marrow cells consist of white cells, erythrocyte, a few stem cells, *etc*. Only stem cells could differentiate into other type cells. As a result, the experiment indicated that circulating bone marrow stem cells could differentiate into hepatocytes in liver after partial hepatectomy and bone marrow stem cells might participate in hepatic regeneration. Fujii[15] examined the differentiation of mice bone marrow cells in liver regeneration after partial hepatectomy and found that bone marrow cells participate in liver sinusoid. They believe the bone marrow cells participation in liver regeneration after hepatectomy, where the majorities were committed to sinusoidal endothelial cells probably through endothelial progenitor cell mobilization.

It has been accepted that the hepatocyte regeneration process after partial hepatectomy is associated with the proliferation of remaining hepatocytes. We hold that the mechanism of hepatocyte regeneration after partial hepatectomy includes at least two ways. That is, the remaining mature hepatocytes proliferate and circulating bone marrow stem cells migrate into residual liver and differentiate into hepatocytes. With the development and application of stem cell technique, it is possible to obtain stem cells from bone marrow or blood and to make the stem cells proliferate in a great deal. Stem cell autotransplantation may become a new method to promote liver regeneration.

REFERENCES

1 **Lagasse E**, Connors H, Al-Dhalimy M, Reitsma M, Dohse M, Osborne L, Wang X, Finegold M, Weissman IL, Grompe M. Purified hematopoietic stem cells can differentiate into hepatocytes in vivo. *Nat Med* 2000; **6**: 1229-1234

2 **Alison MR**, Poulsom R, Jeffery R, Dhillon AP, Quaglia A, Jacob J, Novelli M, Prentice G, Williamson J, Wright NA. Hepatocytes from non-hepatic adult stem cells. *Nature* 2000; **406**: 257

3 **Petersen BE**, Bowen WC, Patrene KD, Mars WM, Sullivan AK, Murase N, Boggs SS, Greenberger JS, Goff JP. Bone marrow as a potential source of hepatic oval cells. *Science* 1999; **284**: 1168-1170

4 **Allen KJ**, Cheah DM, Lee XL, Pettigrew-Buck NE, Vadolas J, Mercer JF, Ioannou PA, Williamson R. The potential of bone marrow stem cells to correct liver dysfunction in a mouse model of Wilson's disease. *Cell Transplant* 2004; **13**: 765-773

5 **Zhan YT**, Wei L, Chen HS, Cong X, Fei R, Wang Y. [Differentiation of bone marrow stem cells in rat hepatic fibrogenesis environment]. *Zhonghua Ganzangbing Zazhi* 2003;

11: 673-675
6 **Liu ZC**, Chang TM. Coencapsulation of hepatocytes and bone marrow stem cells: in vitro conversion of ammonia and in vivo lowering of bilirubin in hyperbilirubemia Gunn rats. *Int J Artif Organs* 2003; **26**: 491-497
7 **Theise ND**, Badve S, Saxena R, Henegariu O, Sell S, Crawford JM, Krause DS. Derivation of hepatocytes from bone marrow cells in mice after radiation-induced myeloablation. *Hepatology* 2000; **31**: 235-240
8 **Theise ND**, Nimmakayalu M, Gardner R, Illei PB, Morgan G, Teperman L, Henegariu O, Krause DS. Liver from bone marrow in humans. *Hepatology* 2000; **32**: 11-16
9 **Sell S**. Heterogeneity and plasticity of hepatocyte lineage cells. *Hepatology* 2001; **33**: 738-750
10 **Wallace PK**, Palmer LD, Perry-Lalley D, Bolton ES, Alexander RB, Horan PK, Yang JC, Muirhead KA. Mechanisms of adoptive immunotherapy: improved methods for in vivo tracking of tumor-infiltrating lymphocytes and lymphokine-activated killer cells. *Cancer Res* 1993; **53**: 2358-2367
11 **Johnsson C**, Festin R, Tufveson G, Tötterman TH. Ex vivo PKH26-labelling of lymphocytes for studies of cell migration in vivo. *Scand J Immunol* 1997; **45**: 511-514
12 **Hendrikx PJ**, Martens CM, Hagenbeek A, Keij JF, Visser JW. Homing of fluorescently labeled murine hematopoietic stem cells. *Exp Hematol* 1996; **24**: 129-140
13 **Khalaf AN**, Wolff-Vorbeck G, Bross K, Kerp L, Petersen KG. In vivo labelling of the spleen with a red-fluorescent cell dye. *J Immunol Methods* 1993; **165**: 121-125
14 **Albertine KH**, Gee MH. In vivo labeling of neutrophils using a fluorescent cell linker. *J Leukoc Biol* 1996; **59**: 631-638
15 **Fujii H**, Hirose T, Oe S, Yasuchika K, Azuma H, Fujikawa T, Nagao M, Yamaoka Y. Contribution of bone marrow cells to liver regeneration after partial hepatectomy in mice. *J Hepatol* 2002; **36**: 653-659

S- Editor Wang J **L- Editor** Wang XL **E- Editor** Bi L

PO Box 2345, Beijing 100023, China
www.wjgnet.com
wjg@wjgnet.com

World J Gastroenterol 2006 August 21; 12(31): 5055-5059
World Journal of Gastroenterology ISSN 1007-9327
© 2006 The WJG Press. All rights reserved.

RAPID COMMUNICATION

Preoperative risk factor analysis in orthotopic liver transplantation with pretransplant artificial liver support therapy

Jin-Zhong Yuan, Qi-Fa Ye, Ling-Ling Zhao, Ying-Zi Ming, Hong Sun, Shai-Hong Zhu, Zu-Fa Huang, Min-Min Wang

Jin-Zhong Yuan, Qi-Fa Ye, Ling-Ling Zhao, Yin-Zi Ming, Hong Sun, Shai-Hong Zhu, Zu-Fa Huang, Min-Min Wang, Blood Purification Center, Xiangya Transplantation Institute , Third Xiangya Hospital of Central South University, Changsha 410013, Hunan Province, China
Supported by the Provincial Natural Science Foundation of Hunan, China, No. 04JJ6017
Correspondence to: Dr. Jin-Zhong Yuan, Blood Purification Center, Xiangya Transplantation Institute , Third Xiangya Hospital of Central South University, Changsha 410013, Hunan Province, China. yuanjz1229@vip.sina.com
Telephone: +86-13875876591
Received: 2005-11-16 Accepted: 2005-12-12

Abstract

AIM: To assess the value of pre-transplant artificial liver support in reducing the pre-operative risk factors relating to early mortality after orthotopic liver transplantation (OLT).

METHODS: Fifty adult patients with various stages and various etiologies undergoing OLT procedures were treated with molecular adsorbent recycling system (MARS) as preoperative liver support therapy. The study included two parts, the first one is to evaluate the medical effectiveness of single MARS treatment with some clinical and laboratory parameters, which were supposed to be the therapeutical pre-transplant risk factors, the second part is to study the patients undergoing OLT using the regression analysis on preoperative risk factors relating to early mortality (30 d) after OLT.

RESULTS: In the 50 patients, the statistically significant improvement in the biochemical parameters was observed (pre-treatment and post-treatment). Eight patients avoided the scheduled Ltx due to significant relief of clinical condition or recovery of failing liver function, 8 patients died, 34 patients were successfully bridged to Ltx, the immediate outcome of this 34 patients within 30d observation was: 28 kept alive and 6 patients died.

CONCLUSION: Pre-operative SOFA, level of creatinine, INR, TNF-α, IL-10 are the main preoperative risk factors that cause early death after operation, MARS treatment before transplantion can relieve these factors significantly.

© 2006 The WJG Press. All rights reserved.

Key words: Liver transplantation; Artificial liver; Sequential Organ Failure Assessment; Risk factors analysis

Yuan JZ, Ye QF, Zhao LL, Ming YZ, Sun H, Zhu SH, Huang ZF, Wang MM. Preoperative risk factor analysis in orthotopic liver transplantation with pretransplant artificial liver support therapy. *World J Gastroenterol* 2006; 12(31): 5055-5059

http://www.wjgnet.com/1007-9327/12/5055.asp

INTRODUCTION

Orthotopic liver transplantion(OLT) is an accepted mode of therapy for selected patients with advanced liver diseases, however, the early mortality after OLT remains relatively high due to the poor selection of candidates with serious conditions. The immediate outcome of OLT is dependent on many factors including pre-transplantion conditions such as renal function and some other organ functions, which indicate that the better preparation for stability or improvement of the previous OLT support, the better immediate outcome for the OLT. It is now widely accepted that the artificial liver support can be of the optional therapy to stabilize patients with liver failure and to gain time for recovery or re-compensation of the liver or to get a suitable donor available[1]. Although the hybrid biologic method seems theoretically rational, criticism of and arguments against the concept in fear of rejection, transmission of porcine viruses and inducing release of cytokines such as TNF-α and IL-10 probably hinder these methods from gaining a prominent role in future liver support strategies[2]. A new innovated blood purification system based on hemodialysis named molecular adsorbent recycling system (MARS) has been applied to a wide variety of hepatic failure patients and represents positive effects, the method was shown to be efficient in removing both hydrosoluble substances and strongly albumin-bound substances. The remarkable removal of strongly albumin-bound substances and kinds of metabolic toxins during MARS could therefore reduce the toxic effects and higher concentrations of these compounds exert on liver and kidney, thus could contribute to improvement in encephalopathy, renal and hepatic function and probably survival[3,4].

The aim of this study is to assess the value of pre-transplant artificial liver support in reducing the preoperative risk factors relating to early mortality after OLT.

MATERIALS AND METHODS

Patients and design

Fifty adult patients undergoing OLT procedures with MARS preoperative liver support therapy in our transplantation institute from September 2002 to June 2003 were studied. The study population consisted of 28 men and 22 women with a mean age of 52.24 years (range 46-68). The indications for liver transplantation were post-hepatitic cirrhosis (n = 11), fulminant hepatic failure (n = 6), alcoholic cirrhosis (n = 5), primary liver cancer (n = 7), primary biliary cirrhosis (n = 12), Wilsons disease (n = 6) and post-operative rejection (n = 3).

The study contains two parts, the first one is to evaluate the medical effectiveness of single MARS therapy with some clinical and laboratory parameters which were supposed to be the therapeutical pre-transplantation risk factors, the second part is to study the patients undergoing OLT using the regression analysis in preoperative risk factors relating to early mortality (30 d) after OLT.

Our trial was approved by the Ethical Committee of Human Experimentation in China, and was in accordance with the Helsinki Declaration of 1975. All procedures were performed after informed and written consent had been obtained from the patients or their kins.

Treatment and monitoring of clinical and laboratory parameters

Initially, patients were given conventional medical therapy and intensive monitoring or supportive treatment. They were evaluated biochemically and clinically with the prognostic scoring systems including Sequential Organ Failure Assessment (SOFA) score, Glascow coma score and Hepatic encephalopathy (HE) grade before and after the treatment, no sedatives were administered during treatment, the laboratory variables as Tumor Necrosis Factor α (TNF-α), and Interleukin-10 (IL-10) levels were detected with the flow cytometer (FACSCalibur, Becton, Dickinson and Company, USA).

Those patients who were bridged to OLT were divided into two groups: survival group (survival time ⩾ 30 d) and death group (survival time ⩽ 30 d). There were different possible risk factors relating to early mortality after liver transplant including pre-operative, inter-operative and post-operative ones. Pre-operative information consisted of age, SOFA, mean artery pressure (MAP), serum Aspartate Transaminase (AST), serum albumin, International Normalized Ratio (INR), serum creatinine level (Cr), serum total bilirubin level, bile acid, serum ammonia, TNF-α, and IL-10.

The extracorporeal liver support system (MARS)

The MARS system (MARS monitor, Teraklin AG, Rostock, Germany) was used with a continuous veno-venous hemofiltration (CVVH) machine (GAMBRO AK 200), The MARS treatment was performed according to the recently published guidelines[3], a vascular access via a double-lumen jugular central vein line was created, low molecular weight heparine (LMWH) was used for blood anticoagulation for the maintenance of the extracorporeal circuit. The blood flow from the dialysis machine and the albumin dialysate circuit flow were equal at a rate of 80-120 mL/min, while the dialysate flow was set accordingly. The time length of each therapeutic session was 6-8 h.

Table 1 Comparison of clinical and biochemical data pre-and post MARS treatment

Parameter	Pre-treatment	Post-treatment	P value
Prognostic scores			
SOFA score (points)	9.72 ± 1.89	6.98 ± 2.34	< 0.01
Glasgow coma score (points)	7.23 ± 1.21	13.34 ± 2.33	< 0.01
Clinical and biochemical parameters			
MAP (mmHg)	70.5 ± 12.1	85.1 ± 10.4	< 0.001
TNF-α (pg/mL)	2.83 ± 1.7	1.80 ± 1.39	< 0.01
IL-10 (pg/mL)	7.80 ± 6.0	4.5 ± 4.5	< 0.05
ALT	295.7 ± 1125.4	237.14 ± 91.82	< 0.036
TBIL (μmol/L)	341.16 ± 94.93	232.74 ± 169.29	< 0.04
TBA (mmol/L)	162 ± 104	73 ± 51	< 0.001
Albumin (g/L)	35.5 ± 35.7	35.7 ± 6.8	> 0.05
INR	4.66 ± 3.35	3.98 ± 3.16	> 0.05
Cr (μmol/L)	128.67 ± 87.73	33.21 ± 22.26	< 0.045
Ammonia (mmol/L)	151.31 ± 88.99	28.28 ± 20.19	< 0.028

Statistical analysis

Experiment data were presented as mean ± SD, independent 2-tailed t tests were used to determine whether there were significant differences between the survival and dead group of OLT patients. Pearson's Chi-square statistics were used to test differences in all frequencies. Data with significant difference were entered into a stepwise logistic regression analysis.

RESULTS

In the 50 patients, 80 MARS treatments were performed. Patients who underwent the intended MARS treatment were all remarkably stable without any adverse events or complications except slight chill. All patients showed positive response to the therapy, with respect to remarkable release of severe meteorism, active diet, and significant improvement of liver and kidney functions. SOFA, GSH, MAP, TNF-α and IL-10 were improved significantly, the total bilirubin (TBIL), total bile acid (TBA), ammonia and creatinine (Cr) were shown decreased markedly, however, no difference was found in the markers of alanine-amino-transferase (ALT), albumin and INR before and after the MARS treatments (Table 1). Eight patients avoided the scheduled Ltx due to significant relief of clinical condition or recovery of failing liver function, 8 patients died, 34 patients were successfully bridged to Ltx, the immediate outcome of these 34 patients within 30d observation was: 28 kept alive and 6 patients died.

Comparison between the survival group and the death group showed significant differences in terms of age, SOFA, GSH, MAP, TNF-α, IL-10, INR and serum creatinine level (P < 0.05, Table 2). The stepwise logistic regression was used to create the best statistical model

Table 2 Risk factors relating to early mortality after liver transplantation

Group	*n*	Age[a]	SOFA[b]	GSH[a]	MAP[a]	TNF-α[a]	IL-10[a]	INR[a]	Creatinine[b]
Survival	28	34.34 ± 2.45	8.18 ± 1.23	12.45 ± 2.26	83.7 ± 10.01	1.99 ± 1.4	5.5 ± 2.0	3.34 ± 1.89	45.45 ± 12.12
Death	6	45.56 ± 2.36	9.88 ± 1.09	9.88 ± 2.43	75.0 ± 12.46	2.34 ± 1.05	6.2 ± 2.9	4.77 ± 2.07	110.34 ± 23.65

[a]$P < 0.05$, [b]$P < 0.01$.

Table 3 Stepwise logistic regression analysis

Variables	B	SE	Wald	Df	Sig	R
SOFA	2.638	0.879	5.879	1	0.018	0.224
Creatinine	5.822	1.351	8.345	1	0.002	0.315
TNF-A-α	2.131	0.775	5.664	1	0.019	0.192
IL-10	2.014	0.766	4.784	1	0.025	0.188
INR	3.455	1.335	8.025	1	0.002	0.309

relating to early mortality after transplantation. The factors that had significant independent associations with early mortality after the stepwise procedure were serum creatinine level, INR, SOFA, TNF-α and IL-10, with regression coefficients of 0.315, 0.309, 0.224, 0.192 and 0.188, respectively (Table 3).

DISCUSSION

OLT is a treatment for end-stage liver disease. Early post-operative mortality was below 10% in the world. The mortality remains high in our country. The serious preoperative condition of recipient and the late timing for operation may account for this result. The serious preoperative conditions are due to the poor detoxification ability of the liver, the accumulation of large amounts of toxic substances including hydro-soluble and lipid soluble and various metabolic products, which causing further damage to the heart, brain, kidney and vessels leading to MODS. The accumulation will increase the mortality of OLT[5]. So, in order to increase the successful rate of OLT, the toxic substances shall be removed as much as possible before operation. The removal of the toxins will help block the vicious cycle and benefit the organ function.

The albumin dialysis MARS is currently the novelest cell-free liver support system which enables the selective removal of water-soluble and albumin-bound substances, in which human serum albumin serves as a shuttle based on facilitated diffusion between a blood-sided dialysis membrane on one side and a remove set of sorbent columns and a conventional dialysis unit on the other[2,3]. MARS has avoided the drawbacks of conventional and bio-artificial liver. It combines the functions of molecular adsorption, hemo-filtration and hemo-dialysis, and can remove the albumin combined toxins quickly and selectively. The hemo-filtration can do nothing to the albumin combined toxins. The hemo-perfusion, whose adsorbents such as carbon or resin will contact with blood directly, cause fibrolysis or activation of complements and systemic inflammation due to the bio-incompatibility, and also, cause the loss of hepatic cytokines and a large amount of hormones such as T3, T4 and insulin. The plasma exchange has very weak ability to remove toxins and causes loss of useful substances. Attempts to develop an artificial liver were started in the 1950s, today both mechanical devices and hybrid biologic-mechanical devices such as cell-free detoxification methods, whole organ perfusion, hepatocytes transplantation and bioreactor approaches using hepatocytes, however, are with inherent defectiveness and limitations respectively. Although the hybrid biologic methods seem theoretically rational, criticism of and arguments against the concept in fear of rejection, transmission of porcine viruses and inducing release of cytokines as TNF-α and IL-6 probably hinder these methods from gaining a prominent role in future liver support strategies. Many randomized, controlled trials were performed, all reported with statistically significant increases in survival in the MARS group compared with standard care, indications for treatment were hepato-renal syndrome, decompensated chronic disease with intrahepatic cholestasis, post-operative liver failure after heart surgery and cirrhosis with superimposed acute liver injury. The laboratory data of pre- and post-treatment in the 80 sessions on the 50 patients has proved the conclusion of some other researchers. The conclusion is that MARS can remove various toxins and cytokines caused by liver failure, decrease SOFA score and improve multi-organ function.

In this study, we are trying to explore the effects of MARS treatment in post-operative early survival rate. Aiming at this purpose, we analyzed multiple factors which may be related to the post-operative mortality rate. It is different with the bygones. We only analyzed some pre-operative factors which are operable, measurable and curable although the factors are related to the post-operative mortality comprise of not only post-operative factors, but also intra- and post-operative ones such as ischemia time, ahepatic time, bleeding volume and rejection or various complications. Some factors, though very important, can't be controlled or cured, which are not drawn into our study, such as the pathology, former related operation or former transplantion history, ABO blood group, *etc.* The early mortality rate is 17% in the 34 patients in this study. We adopts Logistic regression analysis. The results show that preoperative SOFA, levels of creatinine, INR, TNF-α and IL-10 are the main preoperative risk factors causing early death after operation.

Renal dysfunction is a common dangerous complication in patients with end-stage liver disease. It results from acute tubular necrosis and caused by

hepatorenal syndrome. Literature shows a significant decrease of 43% in glomerular filtration rate (GFR) during transplantation in patients with normal renal function. Both high pre-operative serum creatinine level and inter-operative veno-venous bypass can lead to renal hemodynamic unstability during operation. The post-operative nephrotoxic immuno-suppressants can also contribute to the irreversible renal insufficiency, leading to renal failure after liver transplantation. In our study, 2 of 10 patients died of renal failure, who were all along with high preoperative serum creatinine level and hepatorenal syndrome before transplantation. A significant difference found between the survival group and the death group was shown in serum creatinine level ($P < 0.001$), with a mean of 45.45 ± 12.12 and 110 ± 23.65, respectively. The stepwise logistic regression analysis also showed a statistical independent association with early mortality after liver transplantation, with a regression co-efficient of 0.315. It is also a main risk factor which predicts early mortality after OLT. It is very important to improve renal malfunction before transplantation. If there are indications for hemodialysis, it should be performed without delay, trying to relieve the renal function before operation[6]. The MARS is a recommended strategy for this kind of case. Because, not only can MARS lower the level of blood creatinine, but also raise mean artery pressure (MAP) and systemic vascular resistance (SVR), for it can lower the blood level of NO which is a vessel dilator to the liver failure patients [7].

SOFA is currently a popular system applied in ICU for the assessment of multi organ function. SOFA covers the function of multi-system completely including respiratory, hemostastics, hepatic, circulatory, and of brain and kidney. Comparing with the widely used Acute Physiology and Chronic Health Evaluation (APACHE), SOFA has the advantage of daily sequential assessment, and is better than APACHE which is not specific enough to liver function and also better than Child-Turcotte-Pugh (CTP) system which is too specific to liver function[8]. In this study, the SOFA score is 9.88 ± 1.09, which is significantly higher than 8.18 ± 1.23 in the survival group ($P < 0.001$). Logistic regression analysis showed that SOFA is related to early mortality in certain extent, its regression coefficient is 0.224. SOFA is one of the main risk factors. It can be regarded as a reference index in choosing operation time.

Though the association between pre- and post-operative level of TNF-α and IL-10 is not so significant as the other risk factors, it still deserves much consideration. A lot of studies show that the systemic inflammatory responses syndrome (SIRS) caused by TNF-α and IL-10 is an important tache to the aggravation of liver failure leading to MODS. Not only does SIRS play an important role in the development of liver failure, but also makes a hormone-like effect, causing hypotension, lung injury, brain edema *etc.* So SIRS may be the common body fluid causing multi-organ injury. If we can remove these factors, theoretically, the MODS caused by the strike of the operation can be relieved, which is benefitial to increasing the success rate of operation. In this study, three patients died of MOF (multi-organ failure). The study showed that the values of preoperative parameters were lower in the survival group, which may be due to being removed of the cytokine and being blocked of injury to organs by SIRS. The relief of oxygenation of the body will also do benefit to preventing MODS[9]. Recent studies show that the TNF-α and IL-10 play important roles in mediating the inflammation and immune response caused by rejection. The variability of the cytokine initiator is a risk factor which is related to rejection. Whether the removal of preoperative TNF-α and IL-10 will be of benefit to relieve post-operative rejection is awaits further studies[10].

In this study, we find that MARS can improve multi-organ function both before and after operation. The improvement is presented as the decreased SOFA score. This is in agreement with some reports in the world. The mechanism may be that MARS has selectively removed a large amount of albumin bound toxins and hydrosoluble toxins including cytokines such as TNF-α, IL-10 and endo-toxin, and repressed or relieved the pathological progress, and also improved the body blood circulation, organ blood dynamics and tissue oxygenation, benefiting the intervention on MODS. Regarding the risk factors, this preoperative MARS treatment will ensure a low post-operative MODS rate and increase the success rate of operation.

Furthermore, INR is an important risk factor related to post-operative early mortality. High preoperative INR is related to disfunction of blood clotting, leading to interoperative bleeding. Large amounts of blood transfusion may develop hemodynamic unsteadiness or even DIC. The long-term hypotention will aggravate the renal failure which has already existed before operation. INR acts as the medium of blood clotting mechanism. Abnormal INR accompanied with previous upper abdominal surgery, or extensive abdominal adhesions, portal hypertension and hypersplenism may develop severe bleeding. It is reported that intra-operative bleeding quantity is related to early mortality after liver transplantation[11,12]. In this study, INR is not significantly improved by single MARS treatment, possibly because single MARS treatment is not enough to significantly improve of the synthesizing ability of the liver. But it will be improved after sequential treatment. Unlike the other artificial liver treatment, MARS is featured by high bio-compatibility and stable hemo-dynamics. It will not do harm to or initiate the disorder of blood clotting. MARS is very useful in stabilizing INR which is related to the prognosis.

Some other factors such as Glascow Score (GSH) and mean artery pressure (MAP) showed associations with early mortality after liver transplantation, but the significance is not as high as SOFA and creatinine.

CONCLUSION

After studying the laboratory data of pre- and post-treatment in the 80 sessions on the 50 patients, we think that MARS can be used in transition to OLT. Preoperative SOFA, level of creatinine, INR, TNF-α and IL-10 are the main preoperative risk factors that cause early death after

operation. MARS treatment before transplant operation can relieve these factors significantly.

REFERENCES

1 **Bismuth H**, Farges O, Castaing D, Samuel D, Adam R, Johann M, Azoulay D, Feray C, Astarcioglu I, Saliba F. [Evaluation of results of liver transplantation: experience based on a series of 1052 transplantations]. *Presse Med* 1995; **24**: 1106-1114

2 **Parrilla P**, Sánchez-Bueno F, Figueras J, Jaurrieta E, Mir J, Margarit C, Lázaro J, Herrera L, Gómez-Fleitas M, Varo E, Vicente E, Robles R, Ramirez P. Analysis of the complications of the piggy-back technique in 1,112 liver transplants. *Transplantation* 1999; **67**: 1214-1217

3 **Stange J**, Mitzner S, Ramlow W, Gliesche T, Hickstein H, Schmidt R. A new procedure for the removal of protein bound drugs and toxins. *ASAIO J* 1993; **39**: M621-M625

4 **Guo LM**, Liu JY, Xu DZ, Li BS, Han H, Wang LH, Zhang WY, Lu LH, Guo X, Sun FX, Zhang HY, Liu XD, Zhang JP, Yao Y, He ZP, Wang MM. Application of Molecular Adsorbents Recirculating System to remove NO and cytokines in severe liver failure patients with multiple organ dysfunction syndrome. *Liver Int* 2003; **23** Suppl 3: 16-20

5 **Huang J**, He X, Chen G, Zhu X, Lu M, Wang G, Fu Y, Yang Y, Guan X. Liver transplantation at the Sun Yat-Sen University of Medical Sciences in China. *Chin Med J (Engl)* 2002; **115**: 543-548

6 **Alvares-da-Silva MR**, Waechter FL, Francisconi CF, Barros E, Thome F, Traiber C, Fonseca DL, Zingani JM, Sampaio JA, Pinto RD, Pereira-Lima L. Risk factors for postoperative acute renal failure at a new orthotopic liver transplantation program. *Transplant Proc* 1999; **31**: 3050-3052

7 **Stange J**, Hassanein TI, Mehta R, Mitzner SR, Bartlett RH. The molecular adsorbents recycling system as a liver support system based on albumin dialysis: a summary of preclinical investigations, prospective, randomized, controlled clinical trial, and clinical experience from 19 centers. *Artif Organs* 2002; **26**: 103-110

8 **Ricci P**, Therneau TM, Malinchoc M, Benson JT, Petz JL, Klintmalm GB, Crippin JS, Wiesner RH, Steers JL, Rakela J, Starzl TE, Dickson ER. A prognostic model for the outcome of liver transplantation in patients with cholestatic liver disease. *Hepatology* 1997; **25**: 672-677

9 **Awad SS**, Sawada S, Soldes OS, Rich PB, Klein R, Alarcon WH, Wang SC, Bartlett RH. Can the clearance of tumor necrosis factor alpha and interleukin 6 be enhanced using an albumin dialysate hemodiafiltration system? *ASAIO J* 1999; **45**: 47-49

10 **Baquerizo A**, Mhoyan A, Kearns-Jonker M, Arnaout WS, Shackleton C, Busuttil RW, Demetriou AA, Cramer DV. Characterization of human xenoreactive antibodies in liver failure patients exposed to pig hepatocytes after bioartificial liver treatment: an ex vivo model of pig to human xeno-transplantation. *Transplantation* 1999; **67**: 5-18

11 **Hughes RD**, Nicolaou N, Langley PG, Ellis AJ, Wendon JA, Williams R. Plasma cytokine levels and coagulation and complement activation during use of the extracorporeal liver assist device in acute liver failure. *Artif Organs* 1998; **22**: 854-858

12 **Lin E**, Calvano SE, Lowry SF. Inflammatory cytokines and cell response in surgery. *Surgery* 2000; **127**: 117-126

S- Editor Wang J **L- Editor** Ma JY **E- Editor** Ma WH

PO Box 2345, Beijing 100023, China
www.wjgnet.com
wjg@wjgnet.com

World J Gastroenterol 2006 August 21; 12(31): 5060-5063
World Journal of Gastroenterology ISSN 1007-9327
© 2006 The WJG Press. All rights reserved.

RAPID COMMUNICATION

Comparison of therapeutic effectiveness of combined interventional therapy for 1126 cases of primary liver cancer

Ya-Min Liu, Hao Qin, Chong-Bao Wang, Xiao-Hong Fang, Qing-Yong Ma

Ya-Min Liu, Hao Qin, Chong-Bao Wang, Xiao-Hong Fang, Department of Interventional Medicine, First Hospital, Xi'an Jiaotong University, Xi'an 710061, Shaanxi Province, China
Qing-Yong Ma, Department of Hepatobiliary Surgery, First Hospital, Xi'an Jiaotong University, Xi'an 710061, Shaanxi Province, China
Correspondence to: Ya-Min Liu, Department of Interventional Medicine, First Hospital, Xi'an Jiaotong University, Xi'an 710061, Shaanxi Province, China. super2000haohao@163.com
Telephone: +86-29-85323519 Fax: +86-29-85323519
Received: 2006-03-28 Accepted: 2006-04-24

Abstract

AIM: To verify the effect of combined interventional therapy for hepatocellular carcinoma (HCC).

METHODS: The clinical data of 1126 HCC patients who received combined interventional therapy for transcatheter arterial chemoembolization (TACE) before or after hepatectomy, TACE and radio-frequency ablation (RFA), Chinese medicine treatment and biotherapy after TACE or transcatheter arterial infusion (TAI), were reviewed according to the results of their liver function, alpha-fetoprotein, image data, color-ultrosonography finding and survival rate.

RESULTS: A total of 874 patients were followed up for a period of 2 to 63 mo. The overall 1-, 3- and 5-year survival rates were 67.8%, 28.7% and 18.8% respectively. The 1- 3- and 5- year survival rates of patients who received TACE were 74.7%, 41.4%, 36.9% before hepatectomy and 78.9%, 40.4%, 37.5% after hepatectomy. The effective rate (PR + NC) after TACE and RFA was 93.4%, the 1- and 3- year survival rates were 74.5% and 36.8% after TACE and RFA. The effective rate of PR + NC after TACE was 83.2%. The 1-, 3- and 5- year survival rates were 69.3%, 21.7%, 8.4% after TACE. The effective rate of PR + NC after TAI was 27.5%, the 1- and 2- year survival rates were 11.6% and 0% after TAI. The liver function, color-ultrosonography finding and alpha-fetoprotein after TACE + RFA, TACE and TAI were compared. There was no significant difference in each index between TACE and RFA or TACE as well as in liver function between TACE and RFA or between TACE and TAI.

CONCLUSION: The therapeutic effectiveness of TACE before or after hepatectomy is most significant, while the effect of TACE and RFA is better than that of TACE, and the effect of TAI is minimal.

© 2006 The WJG Press. All rights reserved.

Key words: Hepatocellular carcinoma; Transcatheter arterial chemoembolization; Combined interventional therapy; Survival analysis

Liu YM, Qin H, Wang CB, Fang XH, Ma QY. Comparison of therapeutic effectiveness of combined interventional therapy for 1126 cases of primary liver cancer. *World J Gastroenterol* 2006; 12(31): 5060-5063

http://www.wjgnet.com/1007-9327/12/5060.asp

INTRODUCTION

Transcatheter arterial interventional therapy is extensively used in treating hepatocellular carcinoma (HCC). To reduce the intra-hepatic recurrence and improve the protective efficacy after treatment for HCC, some scholars have proposed combined interventional therapy as a choice of treatment for HCC[1]. We analyzed the therapeutic effectiveness of different combined interventional therapies for HCC according to the survival rate, liver function, image data and indications of tumor.

MATERIALS AND METHODS

Patients

A total of 1126 patients were retrospectively studied from January 1994 to October 2003. Of them, 873 were males and 253 were females (aged 32-76 years, mean 56.2 years). The patients were treated following the HCC Clinical Diagnosis and Staging Standard stipulated at the 8th National Academic Conference of Liver Cancer in September 2001. Among these patients, 78 had a family history of liver cancer, 985 had a medical history of serum hepatitis, 48 had a medical history of hepatitis C, 342 had cardinal symptoms of right upper quadrant pain, 336 felt epigastric distention after dinner or suffered from anorexia, 162 had low fever accompanied with progressing wasting, 286 exhibited no overt symptoms. Prior to the treatment, AFP was greater than 20 ng/mL in 735 cases, greater than 400 ng/mL in 521, negative in 227, unknown in 164. A total of 874 patients were followed up for 2

Table 1 Clinical data of 1126 patients

Group	Cases	Size of tumor (cm)			Clinical staging			Liver function level		
	(*n*)	< 5	5-10	> 10	Ⅰ	Ⅱ	Ⅲ	A	B	C
Preop. TACE	258	20	145	93	104	154	0	155	103	0
Postop.TACE	154	9	76	69	16	138	0	83	71	0
TACE + RFA	126	3	57	66	48	57	21	92	34	0
TACE	469	31	239	199	156	251	62	252	197	20
TAI	119	11	47	61	28	47	44	14	73	32
Total	1126	74	564	488	352	647	127	596	478	52

Table 2 Clinical data of 1126 patients

Group	Cases	Karnofsky scores		HBsA	AVF		Embolus in PV	
	(*n*)	0-80	80-100	(+)	HV	PV	Right	Left
Preop. TACE	258	172	86	221	9	19	67	73
Postop.TACE	154	98	56	124	4	10	21	16
TACE + RFA	126	83	43	107	12	27	32	26
TACE	469	291	178	412	76	125	106	92
TAI	119	78	41	101	22	34	32	28
Total	1126	722	404	965	123	215	258	235

to 63 mo (averaged 26.3 mo). Combined interventional therapy was given, including transcatheter arteria hepatica chemoembolization (TACE) before or after hepatectomy, radio-frequency ablation (RFA) after TACE, Chinese medicine treatment and biotherapy after TACE or transcatheter arteria hepatica infusion (TAI). The clinical data of various kinds of combined interventional therapy for HCC are shown in Tables 1 and 2.

TACE

Twelve mg mitomycin (MMC) and 1.0 g 5-FU were diluted in 60 mL sodium chloride solution respectively and infused through a catheter. Then 50 mg epirubicin (EPI) and iodinated oil were compounded into a mixed emulsifier and infused into the blood-supply artery of the tumor through a catheter. Then, the artery was embolized with granules of spongia gelatinosa.

TAI

Fifty mg EPI, 12 mg MMC, and 1.0 g 5-FU were diluted in 60 mL sodium chloride solution respectively and infused through a catheter into the blood-supply artery of tumor. HCC patients treated 3-4 times with TACE at 1-2 mo intervals after hepatectomy, if pathological report showed remnant cancer cells on the cutting edge or AFP > 20 ng/mL or the image showed remnant tumor. Those who lost the chance of one-stage operation were treated with TACE and underwent re-examination of CT after 1-2 mo. If iodinated oil deposited in the tumor was reported to be coarctate, the volume of tumor was decreased or the normal liver had compensatory hyperplasia, the patients underwent hepatectomy after their recuperation. Those who did not recuperate or rejected hepatectomy were treated with RFA 3-4 wk after TACE. On the first day after TACE or TAI, the patients were treated with the following Chinese herbal medicines: 30 g Milkvetch Root, 20 g Dangshen, 15 g Largehead Atractylodes Rhizome, 15 g Indian Bread, 30 g Huaishan, 15 g Finger Citron, 15 g Bupleurum chinense, 15 g Danshen Root, 3 g Radix Notoginseng, 15 g Virgate Wormwood Herb, 20 g Tianjihuang, 20 g Canton Love-Pea Vine, 5 g Radix Glycyrrhizae. The herbal medicines were decocted in water for oral dose once daily for 3-4 wk as a course of treatment. After 3-5 d, the patients received intramuscular injection of 1000 U interferon once a day for 20 d as a course of treatment.

Table 3 Accumulated survival rate for 874 HCC patients after various kinds of interventional therapy

Group	Cases (*n*)	1 yr		3 yr		5 yr	
		Cases (*n*)	Survival rate (%)	Cases (*n*)	Survival rate (%)	Cases (*n*)	Survival rate (%)
Preop. TACE	198	148/198	74.7	82/198	41.4	58/157	36.9
Postop.TACE	114	90/114	78.9	46/114	40.4	33/88	37.5
TACE + RFA	106	79/106	74.5	39/106	36.8	-	-
TACE	387	268/387	69.3	84/387	21.7	26/309	8.4
TAI	69	8/69	11.6	0/69	0	0/69	0
Total	874	593/874	67.8	251/874	28.7	117/623	18.8

Follow-up

The liver and renal function, AFP, blood RT, KPS scores were re-examined, and sonography, CT, chest X-Ray were performed once a month, and then every 3 mo during the follow-up period. The date on which the patients lost their follow-up was regarded as the date of death. According to the WHO evaluation standard of therapeutic effect of solid tumor (1981), the patients who were treated with TACE + RFA, TACE and TAI were categorized into 4 degrees: complete remission (CR), partial remission (PR), no change (NC) and progression (PD). The first 3 degrees were considered efficient and the last degree was considered inefficient.

Statistical analysis

SPSS12.0 was used for statistical analysis. The survival rate was evaluated by adopting probability ratio multiplication theorem, and chi- square test was used for comparison between the 2 groups. $P < 0.05$ was considered statistically significant.

RESULTS

A total of 874 cases were followed up for 1-7 years. Comparison of the accumulated survival rate after various kinds of combined interventional therapy is shown in Table 3. The therapeutic effect of interventional therapy in 562 patients is shown in Table 4. Changes of liver function, tumor blood-supply and AFP in 562 cases after interventional therapy were compared. Fifteen days after combined interventional therapy, color Doppler was used to detect the blood flow around and inside the tumor. The change in recovery rate of AFP before and after TACE + RAF, TACE and TAI was compared. The results are shown in Table 5.

Table 4 Therapeutic effect of TACE+RAF, TACE and TAI in 562 patients

Group	Cases (*n*)	PR	NC	PD	Effective rate (%)
TACE + RFA	106	73	26	7	93.4
TACE	387	276	46	65	83.2
TAI	69	8	11	50	27.5
Total	562	357	83	122	81.5

Table 5 Changes of indexes before and after interventional therapy *n* (%)

Group	Index			
	Degrade of Child liver function	Blackout of blood flow inside tumor	Blackout of blood flow around tumor	Recovery of AFP
TACE + RFA	33/106 (31.1)	59/106 (55.7)	54/106 (50.9)	49/106 (46.2)
TACE	119/387 (30.7)	212/387 (54.8)	189/387 (48.8)	174/387 (45.0)
TAI	23/69 (33.3)	0/69 (0)	0/69 (0)	0/69 (0)
Total	175/562 (31.1)	271/562 (48.2)	243/562 (43.2)	223/562 (39.7)

DISCUSSION

At present, hepatectomy remains the preferred method to treat primary liver cancer. Second-stage hepatectomy after TACE is a great breakthrough in the field of liver cancer treatment after hepatectomy of marco-hepatoma in the 1950-1960s and micro-hepatoma in the 1970s[3]. TACE after radical excision of hepatoma can efficiently kill remnant cancer cells, decrease recurrence and increase survival rate remarkably[4,5]. However; it was reported that TACE can damage hepatic and immunologic function, thus deceasing the survival rate[6]. Zheng *et al*[4] retrospectively analyzed the therapeutic results of 420 HCC patients after combined therapy, and found that the 1- and 3-year survival rates of non-angioencroached HCC patients after treated with TACE are 100% and 60% before radical excision, 77.8% and 22.2% before palliative excision, respectively, higher than those of the patients not treated with TACE before hepatectomy, and there is no significant difference between TACE before and after hepatectomy. Wang *et al*[7] reported that the 1-, 3-, 5- year survival rates of 20 HCC patients after treated with combined therapy are 95.0%, 63.5%, 32.9% after second-stage hepatectomy, suggesting that the 1-, 3-, 5- year survival rates after TACE before or after hepatectomy are the highest. The reasons may be as follows: some of the 1126 cases treated with TACE before or after hepatectomy had hepatic AVF and embolus of hepatic portal vein, only interventional therapy was given before hepatectomy, and TACE treatment did not continue with double-chemoembolization or internal radiation. All these indicate that cancer cells can extend to distal ramulus along homonymous portal vein during operation procedures. Though macroscopic circumscription of hepatectomy is satisfactory, there are remnant cancer cells on the cutting edge, and liver cancer complicating hepatic cirrhosis limits circumscription of hepatectomy. The above-mentioned factors are the major reasons for recurrence which is an important reason for the low survival rate after hepatectomy. For this reason, it is necessary to treat HCC patients with TACE combined with Chinese medicine and biotherapy to increase their immunologic function after hepatectomy. To effectively increase the survival rate, HCC patients should be treated with double-chemoembolization or internal radiation before hepatectomy.

Combined interventional therapy including TACE, TAI, RAF, percutaneous intra-tumor absolute alcohol injection (PEI), percutaneous intra-tumor acetic acid injection (PAAI), percutaneous intra-tumor hot saline water injection (PSI), percutaneous cryotherapy (PCT), is dominantly used in non-surgical treatment of HCC. Except for TACE and TAI, extra-hemal and circumscriptus "interstitial substance therapy"[8] can treat HCC through different mechanisms. It was reported that chemoembolization can reduce the number of newly generated tumor vessels and the remnant tumor may generate new vessels through various ways[9]. To increase the life span, we believe that HCC patients should be treated with RFA, PEI, PAAI, PSI, and PCT on the basis of TACE to kill remnant cancer cells. Liu *et al*[10] reported that the 1-, 2-, 3- year survival rates of HCC patients after treated with TACE are 59.52%, 22.06% and 14.34% , while the 1- and 3- year survival rates of HCC patients after treated with TAI are 27.94% and 0%. In our study, the 1-, 2-, 3- year survival rates of 387 patients after treated with TACE were 69.3%, 21.7% and 8.4% respectively, and the 1- and 3- year survival rates of 69 after treated with TAI were 11.6% and 0%, suggesting that combined interventional therapy for HCC is influenced by many factors.

REFERENCES

1 **Wang JH**, Zhou KR. Normalized Program of Combined Interventional Therapy for Treating HCC. *Xiandai Shiyong Yixue* 2003; **15**: 62-64

2 **Liu LM**, Yang YF, *Gan`ai*. Beijing: People's Medical Publishing House, 2002: 52-53

3 **Li H**, Hu YL, Zhang DS, Jiang FX, Ge Z. Second-stage hepatectomy for unresectable large hepatocellular carcinoma. *Zhonghua Gandan Waike Zazhi* 2002; **8**: 188-189

4 **Zheng SS**, Wu YS, Liang YB. The comprehensive therapy for primary liver cancer. *Zhonghua Putong Waike Zazhi* 2003; **18**: 709-711

5 **Cammà C**, Schepis F, Orlando A, Albanese M, Shahied L, Trevisani F, Andreone P, Craxì A, Cottone M. Transarterial chemoembolization for unresectable hepatocellular carcinoma: meta-analysis of randomized controlled trials. *Radiology* 2002; **224**: 47-54

6 **Zhou JP**, Zhou WP, Fu SY, Shan YF, Yao XP, Wu MC. Influence of preoperative transcather arterial chenmoembolization on liver function in patients with resectable large hepatocellular carcinoma. *Gandan Waike Zazhi* 2003; **11**: 256-258

7 **Wang J**, Ou JQ, Chen JS, Deng MH, Li X, Zhou XJ, Jiang RJ, Luo BM, Jiang NY,Chen YJ, Liu XP, Liu C, Li HH, Zhou XJ. Clinical analysis of second stage resection for primary liver cancer. *Aizheng* 2000; **19**: 159-161

8 **Du YA**, Guo JM, Cheng XD, Qian CW, Yu YP, Zhou LX. A clinical study on sequential treatment of advanced primary liver cancer with vessel intervention and interstitial intervention.

Zhonghua Shiyan Waike Zazhi 2003; **20**: 843-844

9 **Liu Q**, Jia YC, Jia H, Wang ZT, Tian JM, Ye H, Lu JP, Wang F, Yang JJ, Sun F, Chen D,Lin L. Chemoembolization of Hepatocellular Carcinoma with Portal Vein Thrombosis. *Zhonghua Fangshexue Zazhi* 1995; **29**: 239-241

10 **Wang B**, Xu H, Cao GW, Sun YQ, Yu DX, Ning HF. The effect of transcatheter arterial chanoanbolization on angiogenesis and the expression of vascular endothelial growth factor in hepatocellular carcinoma. *Zhonghua Fangshexue Zazhi* 2005; **39**: 204 -206

S- Editor Wang J **L- Editor** Wang XL **E- Editor** Ma WH

PO Box 2345, Beijing 100023, China
www.wjgnet.com
wjg@wjgnet.com

World J Gastroenterol 2006 August 21; 12(31): 5064-5067
World Journal of Gastroenterology ISSN 1007-9327
© 2006 The WJG Press. All rights reserved.

RAPID COMMUNICATION

Primary pancreatic lymphoma: Report of six cases

Hai Lin, Shu-De Li, Xian-Gui Hu, Zhao-Shen Li

Hai Lin, Department of Gastroenterology, Zhejiang Qu-Hua Hospital, Quzhou 324004, Zhejiang Province, China
Shu-De Li, Zhao-Shen Li, Department of Gastroenterology, Changhai Hospital, Second Military Medical University, Shanghai 200433, China
Xian-Gui Hu, Department of Surgery, Changhai Hospital, Second Military Medical University, Shanghai 200433, China
Correspondence to: Dr.Shu-De Li, Department of Gastroentology, Changhai Hospital, Second Military Medical University, Shanghai 200433, China. lishude57@126.com
Telephone: +86-21-25074719 Fax: +86-21-25074635
Received: 2006-07-04 Accepted: 2006-07-07

Abstract

AIM: To heighten recognition of primary pancreatic lymphoma (PPL) in clinical practice.

METHODS: A retrospective review of the clinical presentation, imaging characteristics and pathological features of PPL patients were presented, as well as their diagnosis and treatment, in combination with literature review.

RESULTS: Histological diagnosis was made in four patients by surgery and in two patients by EUS-FNA. The six PPL patients (5 males and 1 female; age range, 16-65 years; mean age, 46 years) had the duration of symptoms for two weeks to three months. The primary presenting symptoms, though not characteristic, were abdominal pain, abdominal masses, weight loss, jaundice, nausea and vomiting. One of the patients developed acute pancreatitis. In one patient, the level of serum CA19-9 was 76.3 μg/L. Abdominal CT scan showed that three of the six tumors were located in the head of pancreas, two in the body and tail, and one throughout the pancreas. Diameter of the tumors in the pancreas in four cases was more than 6 cm, with homogeneous density and unclear borders. Enhanced CT scan showed that only the tumor edges were slightly enhanced. The pancreatic duct was irregularly narrowed in two cases whose tumors were located in the pancreatic head and body, in which endoscopic retrograde cholangiopancreatography (ERCP) showed that the proximal segment was slightly dilated. Two patients underwent Whipple operation, one patient underwent pancreatectomy, and another patient underwent operative biliary decompression. PPL was in stage ⅠE in 2 patients and in stage ⅡE in 4 patients according to the Ann Arbor classification system. The diagnosis of B-cell non-Hodgkin's lymphoma was made in all patients histopathologically. All six patients underwent systemic chemotherapy, one of whom was also treated with gamma radiometry. One patient died two weeks after diagnosis, two patients lost follow-up, two patients who received chemotherapy survived 49 and 37 mo, and the remaining patient is still alive 21 mo, after diagnosis and treatment.

CONCLUSION: PPL is a rare form of extranodal lymphoma originating from the pancreatic parenchyma. Clinical and imaging findings are otherwise not specific in the differentiation of pancreatic lymphoma and pancreatic cancer, which deserves attention. EUS-guided fine-needle aspiration (EUS-FNA) of the pancreas requires experienced cytopathologists as well as advanced immunohistochemical assays to obtain a final diagnosis on a small amount of tissue. Surgery and adjuvant chemotherapy or radiotherapy can produce fairly good outcomes.

© 2006 The WJG Press. All rights reserved.

Key words: Pancreatic malignant tumor; Lymphoma; non-Hodgkin's lymphoma; Diagnosis

Lin H, Li SD, Hu XG, Li ZS. Primary pancreatic lymphoma: Report of six cases. *World J Gastroenterol* 2006; 12(31): 5064-5067

http://www.wjgnet.com/1007-9327/12/5064.asp

INTRODUCTION

Lymphoma includes Hodgkin's and non-Hodgkin's forms. Hodgkin's lymphomas rarely disseminate to extra-lymphatic organs, while non-Hodgkin's lymphomas often invade extra-lymphatic organs. Most primary pancreatic lymphomas (PPL) are non-Hodgkin's Lymphomas. More than 25 percent of non-Hodgkin's lymphomas originate from extra-lymphatic organs, about 30 percent of which may involve the pancreas[1]. Isolated PPL is quite rare, less than 1 percent[2]. In a review of 207 cases of malignant pancreatic tumors, there were only three cases (1.5%) of pancreatic lymphoma[3]. In fine-needle aspiration (FNA) of 1050 cases of pancreatic lesions, Volmar *et al*[4] only found 14 cases (1.3%) of PPL. Clinically, PPL is most likely to be misdiagnosed as pancreatic cancer. The present article is a retrospective review of six cases of PPL, based on which the clinical presentation, imageologic characteristics and pathologic features of PPL are discussed in the context of the world literature in an attempt to heighten clinicians' awareness of the condition.

MATERIALS AND METHODS

Patients

Six cases of PPL were identified and treated in Department of Gastroenterology, Changhai Hospital, Second Military Medical University, Shanghai, China, during a 15-year period from January 1990 to June 2005. The clinical characteristics of all the patients were consistent with the criteria for the diagnosis of PPL defined by Behrns *et al*[1]. On physical examination, no enlarged superficial lymph nodes were found; no enlarged diaphragmatic lymph nodes on chest X-ray films were found either. There was no change of WBC classification on hemograms; there were no significant hepatic and splenic focuses. However, there was evidence of a pancreatic mass on laparotomy, and the lymph nodes involved were confined to areas around the pancreas.

Methods

A retrospective review of the clinical data revealed that malignant lymphoma was unanimously the initial diagnosis of all the six cases. Immunohistochemical analysis by EnVision-methods included leukocyte common antigen (LCA), CD20, CD34, CD68, Chr, CD45RO and Ki-67, of which LCA indicates that tumor cells come from lymphocytes, CD20 is the marker of B-cell, and CD45RO is the marker of T-cell.

All patients were staged according to the Ann Arbor staging system for non-Hodgkin's lymphomas, stage Ⅰ: invasion of lymphoma is confined to the pancreas; stage Ⅱ: apart from pancreatic invasion, there is also invasion of local lymph nodes; stage Ⅲ: apart from pancreatic invasion, the focus also infiltrates the upper diaphragm; and stage Ⅳ: apart from pancreatic invasion, there is generalized infiltration[5].

RESULTS

Clinical presentation

The six PPL patients included five males and one female who ranged in age from 16 to 65 years with a mean of 46 years, and whose duration of symptoms ranged from two weeks to three months. The primary presenting symptoms were abdominal pain, an abdominal mass, weight loss, jaundice, nausea and vomiting, which were similar to what were reported in the overseas literatures[6-9], except that there were no lower back pain, fever and chill, ascites and hemorrhage of the upper digestive tract (Table 1).

Laboratory and imaging findings

WBC count was within the normal range in all six cases. In four patients aspartate aminotransferase (ALT) was 80-265 U/L and alkaline phosphatase (AKP) was 120-216 U/L; in three patients, the level of serum bilirubin was 42-216 μmol/L and CA19-9 was 76.3 μg/L. Liver function was otherwise normal. Abdominal CT scan demonstrated that the tumor was located in the head of pancreas in three cases, in the body and tail in two cases, and in the whole pancreas in the remaining case. The tumors were larger than 6 cm in four cases, with almost homogeneous density and unclear edges. Enhanced CT scan only enhanced the edges slightly. ERCP in two cases revealed that the pancreatic duct at the body of the head was irregularly narrowed, the proximal segment of which was slightly dilated.

Table 1 Clinical presentation of PPL *n* (%)

Data	This report	Overseas report[5]	Overseas CDI[9]
Case number	6	11	85
Abdominal pain	5 (83)	9 (82)	62 (73)
Weight loss	3 (50)	4 (36)	43 (51)
Abdominal mass	2 (33)	-	-
Jaundice	2 (33)	2 (18)	36 (42)
Nausea	2 (33)	2 (18)	29 (34)
Vomiting	1 (17)	-	15 (18)
Lower backache	-	3 (27)	-
Fever	-	2 (18)	6 (7)
Ascites	-	1 (9)	-
Hemorrhage of UDT	-	-	2 (2)

CDI: Compositive details index; UDT: Upper digestive tract.

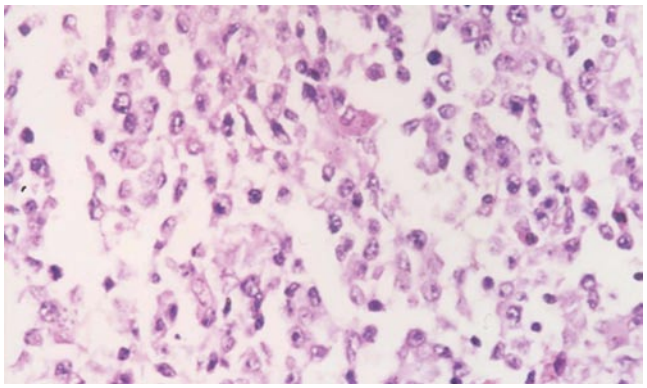

Figure 1 Cytologically, lymphoma cells are round, oval, with prominent and large nucleus, arranged diffusely with obvious heterogeneity (Hematoxylin-eosin stain; original magnification × 200).

Histopathologic study

The specimens were obtained from pancreatic resection in fours cases, and from EUS-guided fine-needle aspiration (EUS-FNA) in the remaining two cases. Microscopic examination showed that the lymphoma cells were round or elliptic, and arranged diffusely, with little plasma, thick karyotheca, thick chromatin and clear nuclei. Immunohistochemical analysis showed LCA (+), CD20 (+), CD34 (-) and CD68 (-). Histopathological examination confirmed the diagnosis of the six cases as B cell pancreatic lymphoma (Figures 1-3).

Diagnosis, treatment and prognosis

Of the six patients, diagnosis was confirmed by pathological study of the pancreatic tissue resected by EUS-FNA in two patients, by my cytological study in one patient, and by general skeleton ECT scan in another patient. One patient underwent biliary-intestinal anastomosis. According to Ann Arbor classification, two cases belonged to Ⅰ E stage, and the remaining four cases to Ⅱ E stage. All six patients underwent chemotherapy, one of whom also underwent linear accelerator radio-

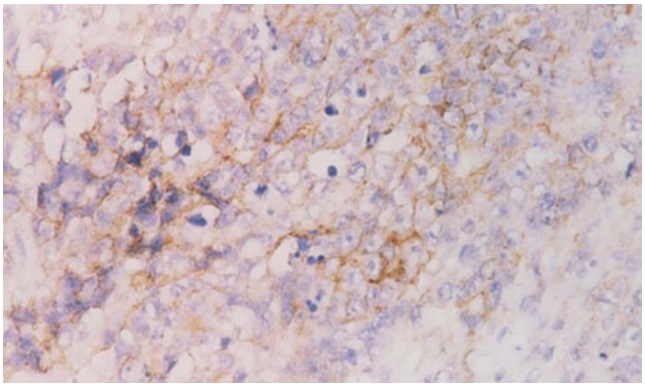

Figure 2 Immunohistochemical analysis showing CD20 (+) (EnVision's stain; original magnification × 200).

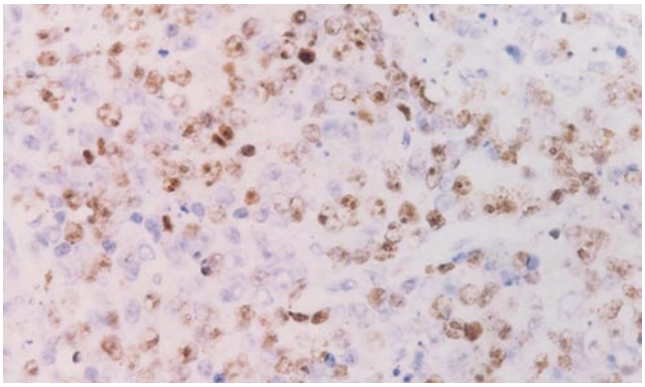

Figure 3 Immunohistochemical analysis showing Ki-67 (+) (EnVision's stain; original magnification × 200).

therapy, and another underwent stereotaxic γ-knife radiotherapy. One patient died two weeks after the diagnosis was confirmed; two patients were lost to follow-up; two patients survived for 49 and 37 mo, and the remaining one patient is still being followed up.

DISCUSSION

Primary pancreatic lymphoma(PPL) is an extremely rare disease which occurs in pancreatic situ, with or without involvement of peripancreatic lymph nodes. The clinical manifestation and imaging result of PPL resemble other pancreatic occupying lesions like pancreatic carcinoma. However, unlike carcinomas, PPLs are potentially treatable even if not found at early stage. PPL only accounts for fewer than 2% of extra-nodal malignant lymphomas and 0.5% of cases of pancreatic masses[10,11]. To date, only fewer than 150 and 20 cases of PPL have been reported in English literature[12] and Chinese medical literature, respectively. In China, from 1995 to 2003 there were totally 16 cases of PPL reported[13]. The data show a strong male predominance (male to female ratio of 13:3) and increased trend with age (median age of 57.5 years), which is similar to the present study. However whether the mean age of PPL is older than that of pancreatic carcinoma remains controversial.

Although the clinical presentation of PPL is varied, some findings may support PPL rather than pancreatic cancer. Bellyache and abdominal mass are two major symptoms which present in 83% and 58% of PPL cases, respectively[12]. Two of six of our patients (33%) presented abdominal mass while Yu *et al* reported that only 1.3% of patients with adenocarcinoma presented abdominal mass[14]. The other symptoms are jaundice, reflux, weight loss, bowel obstruction and diarrhea[6,15]. Interestingly there are almost 12% of PPL mimicking acute pancreatitis. It is noticeable that one in six of our patients presented acute pancreatitis. Obstructive jaundice was found to be less frequent than in pancreatic cancer[16]. While the common symptoms in non-Hodgkin's lymphoma like fever, chills and night sweats were rare in PPL, making it hard to diagnose only depending on the signs[17]. The majority PPLs occur in the head of pancreas, though tumor could also be found in the body and tail regions[7]. It was reported that over half of PPL patients presented with an epigastric mass and the diameter was bigger than 6 cm in 70% of patients of PPL[18]. The laboratory test is non-specific for diagnosis of PPL. Our data reveal that serum carbohydrate antigen 19-9 (CA19-9) level in PPL patients was normal or slightly elevated. This is different from pancreatic adenocarcinoma, in which almost eighty percent of patients get a higher CA19-9 level. The abnormality of serum ALT, AKP, and bilirubin was secondary to the bile duct obstruction.

Imaging results play a key role in diagnosis of PPL. Percutaneous ultrasound(US), endoscopic ultrasonography(EUS), computed tomography(CT) and MRI are well-established procedures to evaluate pancreatic masses[19,20]. Previously 16 Chinese PPL cases could all be found pancreatic masses by CT or US before therapy, with or without signs of peripancreatic lymph node invasion. CT is by far the most common imaging technique used in the detection and characterization of pancreatic tumors. The picture of PPL on CT resembled that of pancreatic carcinoma, including enlargement of pancreatic head and density changes. However, there are fewer signs of invaded large vessel and metastasis of the liver and spleen. There are fewer chances to find pancreatic duct dilation in PPL when compared with pancreatic cancer. Merkle *et al*[9] reported the combination of a bulky localized tumor in the pancreas without significant dilation of the main pancreatic duct strengthens a diagnosis of pancreatic lymphoma over adenocarcinoma. Furthermore, if enlarged lymph nodes are encountered below the level of the renal veins, virtual exclusion of adenocarcinoma is possible. While Arcari *et al*[17] insisted that imaging techniques could suggest the suspicion of PPL but are unable to distinguish PPL from pancreatic adenocarcinoma. Therefore, the final diagnosis of PPL should depend on histopathologic examination. In four of six PPL patients in current study the tissue was obtained during operation and in the other two cases the tissue was obtained by EUS- FNA. Most reported Chinese PPL cases were finally diagnosed by surgeons while there will be more studies using FNA in the future. However, when compared with surgery, it is difficult to obtain enough specimen by FNA to perform immuno-histochemical analysis and may lead to false-negative result[7]. Di Stasi *et al*[21] reported that CT or US guided FNA is a safe and rapid technique to make

histological diagnosis by which we could get more tissues than by EUS. However during CT scan it is difficult for operators to supervise the needle path. EUS-guided tissue sampling of pancreatic masses is the superior method because it is dynamic and real-time. EUS can clearly reveal the boundary of tumor and color doppler flow imaging(CDFI) can show the vein path, sequentially guide the needle aspiration and avoid the vessel damage[22,23]. O' Toole *et al*[24] reported the complication rate of EUS-FNA was as low as 1.6%, indicating it is a safe method. Most importantly, FNA depending methods should be further applied because it is helpful to avoid unnecessary surgery.

Totally four in six of our patients underwent operation. Among them two cases were treated with Whipple surgery, one by distal pancreatectomy and another by operative biliary decompression. The reason for operation is that the definitive diagnosis was not made before surgery. If these patients had been detected using FNA, the exploration could have been skipped. Thus the treatment strategy could have been direct chemotherapy or radiotherapy. Unfortunately, all published 16 Chinese PPL cases were treated with surgery, which made the final diagnosis. It can be predicted that the more frequent usage of FNA, including either CT or EUS guided-FNA may minimize the number of operations for PPL. Bouvet *et al*[8] reported ten in eleven PPL patients, have been performed explorative surgery, only in three of them the tumor could be fully resected. Among eight unresected cases, seven cases were treated with combined CHOP chemotherapy and radiotherapy with dosage of 30 to 45 Gy. The median survival time was 67 mo (11-191 mo). Behrns *et al*[1] reported that the median survival time for single chemotherapy and radiotherapy-treated PPL patients was 13 and 22 mo, respectively. While the survival time could be improved to 26 mo if combining medication with radiotherapy. Therefore, the first choice for PPL treatment should be combination of chemotherapy and radiotherapy, rather than surgery. With the advancement of techniques, surgery seems to be only effective when FNA is not available or diagnosis can not be made on histology. It has already been proved that single pancreas resection could not improve the survival rate of PPL but cause more complications. However, the PPL patient with biliary tract or gastrointestinal obstruction should be performed biliary or gastric bypass to relieve the symptoms.

In conclusion, PPL is a rare disease with non-specific symptoms, laboratory tests and imaging examination results. Cytology or tissue histology is fundamental for diagnosis and chemo- or radiotherapy is preferred for treatment. FNA technique is recommended as a routine examination, while total pancreatectomy is considered to have no impact on survival and with its associated morbidities, is not generally recommended for diagnosis and treatment of PPL. As a result, PPL will not be such a disease with poor prognosis in the future.

REFERENCES

1 **Behrns KE**, Sarr MG, Strickler JG. Pancreatic lymphoma: is it a surgical disease? *Pancreas* 1994; **9**: 662-667

2 **Freeman C**, Berg JW, Cutler SJ. Occurrence and prognosis of extranodal lymphomas. *Cancer* 1972; **29**: 252-260

3 **Reed K**, Vose PC, Jarstfer BS. Pancreatic cancer: 30 year review (1947 to 1977). *Am J Surg* 1979; **138**: 929-933

4 **Volmar KE**, Routbort MJ, Jones CK, Xie HB. Primary pancreatic lymphoma evaluated by fine-needle aspiration: findings in 14 cases. *Am J Clin Pathol* 2004; **121**: 898-903

5 National Cancer Institute sponsored study of classifications of non-Hodgkin's lymphomas: summary and description of a working formulation for clinical usage. The Non-Hodgkin's Lymphoma Pathologic Classification Project. *Cancer* 1982; **49**: 2112-2135

6 **Nayer H**, Weir EG, Sheth S, Ali SZ. Primary pancreatic lymphomas: a cytopathologic analysis of a rare malignancy. *Cancer* 2004; **102**: 315-321

7 **Islam S**, Callery MP. Primary pancreatic lymphoma--a diagnosis to remember. *Surgery* 2001; **129**: 380-383

8 **Bouvet M**, Staerkel GA, Spitz FR, Curley SA, Charnsangavej C, Hagemeister FB, Janjan NA, Pisters PW, Evans DB. Primary pancreatic lymphoma. *Surgery* 1998; **123**: 382-390

9 **Merkle EM**, Bender GN, Brambs HJ. Imaging findings in pancreatic lymphoma: differential aspects. *AJR Am J Roentgenol* 2000; **174**: 671-675

10 **Zucca E**, Roggero E, Bertoni F, Cavalli F. Primary extranodal non-Hodgkin's lymphomas. Part 1: Gastrointestinal, cutaneous and genitourinary lymphomas. *Ann Oncol* 1997; **8**: 727-737

11 **Boni L**, Benevento A, Dionigi G, Cabrini L, Dionigi R. Primary pancreatic lymphoma. *Surg Endosc* 2002; **16**: 1107-1108

12 **Saif MW.** Primary pancreatic lymphomas. *JOP* 2006; **7:** 262-273

13 **Zhu KL,** Wang RB, Xu M, Guo YH, Gong HY, LI JL, Sun HY. One case report of primary pancreatic lymphoma and literature review. *Zhonghua Xiandai Neikexue Zazhi* 2006; **3:** 104-107

14 **Yu ZL,** Li ZS, Zhou GZ, Zou XP, He J, Cai QC, Hu XG, Wang Q. Analysis of clinical symptoms of pancreatic cancer: a report 1027 cases. *Jiefangjun Yixue Zazhi* 2002; **27:** 286-288

15 **Nishimura R**, Takakuwa T, Hoshida Y, Tsujimoto M, Aozasa K. Primary pancreatic lymphoma: clinicopathological analysis of 19 cases from Japan and review of the literature. *Oncology* 2001; **60**: 322-329

16 **James JA**, Milligan DW, Morgan GJ, Crocker J. Familial pancreatic lymphoma. *J Clin Pathol* 1998; **51**: 80-82

17 **Arcari A**, Anselmi E, Bernuzzi P, Bertè R, Lazzaro A, Moroni CF, Trabacchi E, Vallisa D, Vercelli A, Cavanna L. Primary pancreatic lymphoma. Report of five cases. *Haematologica* 2005; **90**: ECR09

18 **Tuchek JM**, De Jong SA, Pickleman J. Diagnosis, surgical intervention, and prognosis of primary pancreatic lymphoma. *Am Surg* 1993; **59**: 513-518

19 **McNulty NJ**, Francis IR, Platt JF, Cohan RH, Korobkin M, Gebremariam A. Multi--detector row helical CT of the pancreas: effect of contrast-enhanced multiphasic imaging on enhancement of the pancreas, peripancreatic vasculature, and pancreatic adenocarcinoma. *Radiology* 2001; **220**: 97-102

20 **Kelekis NL**, Semelka RC. MRI of pancreatic tumors. *Eur Radiol* 1997; **7**: 875-886

21 **Di Stasi M**, Lencioni R, Solmi L, Magnolfi F, Caturelli E, De Sio I, Salmi A, Buscarini L. Ultrasound-guided fine needle biopsy of pancreatic masses: results of a multicenter study. *Am J Gastroenterol* 1998; **93**: 1329-1333

22 **Mallery JS**, Centeno BA, Hahn PF, Chang Y, Warshaw AL, Brugge WR. Pancreatic tissue sampling guided by EUS, CT/US, and surgery: a comparison of sensitivity and specificity. *Gastrointest Endosc* 2002; **56**: 218-224

23 **Ribeiro A**, Vazquez-Sequeiros E, Wiersema LM, Wang KK, Clain JE, Wiersema MJ. EUS-guided fine-needle aspiration combined with flow cytometry and immunocytochemistry in the diagnosis of lymphoma. Gastrointest Endosc 2001; **53**: 485-491

24 **O'Toole D**, Palazzo L, Arotçarena R, Dancour A, Aubert A, Hammel P, Amaris J, Ruszniewski P. Assessment of complications of EUS-guided fine-needle aspiration. *Gastrointest Endosc* 2001; **53**: 470-474

S- Editor Wang J **L- Editor** Zhu LH **E- Editor** Ma WH

PO Box 2345, Beijing 100023, China
www.wjgnet.com
wjg@wjgnet.com

World J Gastroenterol 2006 August 21; 12(31): 5068-5070
World Journal of Gastroenterology ISSN 1007-9327
© 2006 The WJG Press. All rights reserved.

RAPID COMMUNICATION

Indwelling catheter and conservative measures in the treatment of abdominal compartment syndrome in fulminant acute pancreatitis

Zhao-Xi Sun, Hai-Rong Huang, Hong Zhou

Zhao-Xi Sun, Department of General Surgery, Affiliated Hospital of Hainan Medical College, Haikou 570102, Hainan Province, China
Hai-Rong Huang, Hong Zhou, Epidemiology Section, Department of Preventive Medicine, Hainan Medical College, Haikou 571101, Hainan Province, China
Correspondence to: Professor Zhao-Xi Sun, Department of General Surgery, Affiliated Hospital of Hainan Medical College, Haikou 570102, Hainan Province, China. jialidog@tom.com
Telephone: +86-13648665696
Received: 2006-02-22 Accepted: 2006-03-10

Abstract

AIM: To study the effect of combined indwelling catheter, hemofiltration, respiration support and traditional Chinese medicine (e.g. Dahuang) in treating abdominal compartment syndrome of fulminant acute pancreatitis.

METHODS: Patients with fulminant acute pancreatitis were divided randomly into 2 groups of combined indwelling catheter celiac drainage and intra-abdominal pressure monitoring and routine conservative measures group (group 1) and control group (group 2). Routine non-operative conservative treatments including hemofiltration, respiration support, gastrointestinal TCM ablution were also applied in control group patients. Effectiveness of the two groups was observed, and APACHE Ⅱ scores were applied for analysis.

RESULTS: On the second and fifth days after treatment, APACHE Ⅱ scores of group 1 and 2 patients were significantly different. Comparison of effectiveness (abdominalgia and burbulence relief time, hospitalization time) between groups 1 and 2 showed significant difference, as well as incidence rates of cysts formation. Mortality rates of groups 1 and 2 were 10.0% and 20.7%, respectively. For patients in group 1, celiac drainage quantity and intra-abdominal pressure, and hospitalization time were positively correlated (r = 0.552, 0.748, 0.923, P < 0.01) with APACHE Ⅱ scores.

CONCLUSION: Combined indwelling catheter celiac drainage and intra-abdominal pressure monitoring, short veno-venous hemofiltration (SVVH), gastrointestinal TCM ablution, respiration support have preventive and treatment effects on abdominal compartment syndrome of fulminant acute pancreatitis.

© 2006 The WJG Press. All rights reserved.

Key words: Fulminant acute pancreatitis; Abdominal compartment syndrome; Indwelling catheter; Disposable central venous catherization; Celiac drainage; Intra-abdominal pressure monitoring; Combined treatment

Sun ZX, Huang HR, Zhou H. Indwelling catheter and conservative measures in the treatment of abdominal compartment syndrome in fulminant acute pancreatitis. *World J Gastroenterol* 2006; 12(31): 5068-5070

http://www.wjgnet.com/1007-9327/12/5068.asp

INTRODUCTION

There are certain guidelines for treatment of severe acute pancreatitis (SAP). However, about 11% of SAP patients suffer from the complication of abdominal compartment syndrome (ACS), and about 25% of SAP patients are fulminant acute pancreatitis (FAP). Incidence rate of ACS is higher in FAP, and its mortality rate is as high as 60%. Up till now, there have been no standard treatments for ACS[1,2]. In the present study, we used combination of celiac indwelling catheter drainage and intra-abdominal pressure monitoring, several short veno-venous hemofiltration (SVVH), respiration support and gastrointestinal TCM ablution for treatment and predicting patient's conditions of ACS in FAP. Through comparison with the control group, we demonstrate that the combined therapy is effective for treatment of ACS.

MATERIALS AND METHODS

Patients

A total of 110 FAP patients were received and treated in First Aid Center and Hepato-biliary Surgery Department of Affiliated Hospital of Guiyang Medical College[3,4]. When they were hospitalized, the cumulative scorings of CT serious index (CTSI), APACHE Ⅱ and SAP were 7.85 ± 1.10, 17.51 ± 4.51 and grade Ⅱ respectively.

Methods

Patients were divided randomly into groups of indwell-

Figure 1 Indwelling catheter. (↙) Celiac drainage; (↖)Intra-abdominal pressure detection.

ing catheter celiac drainage and intra-abdominal pressure monitoring and routine non-operative conservative treatment measures (Figure 1) group (group 1, 45 cases) and control group (group 2, 65 cases). There was no significant difference ($P > 0.05$) in gender, age, cumulative scorings of CTSI and APACHE Ⅱ between the two groups. Routine non-operative conservative treatment measures, including SVVH, gastrointestinal TCM ablution, respiration support and drug therapy, were conducted in group 2 patients. For group 1 patients centesis in right side or two sides of abdominal cavity, installation of indwelling catheter for continuous drainage (drain quantity was recorded daily) were conducted on the first day of hospitalization, and intra-abdominal pressure was monitored and recorded on the first, second and fifth days since installation of indwelling catheter. The decision of time for hemofiltration was based on the indications of systemic inflammatory response syndrome (SIRS). On the day of hospitalization Dahuang or Qingyitang was infused by gastric canal or anus drip (3 times daily).

Observation of clinical effectiveness: Abdominalgia, burbulence time, hospitalization time for groups 1 and 2 were observed. Celiac drainage and intra-abdominal pressure were monitored for group 1; APACHE Ⅱ cumulative scores before treatment, on the second and fifth days after treatment in groups 1 and 2 were recorded.

Statistical analysis

Data are expressed as mean ± SD. SPSS 12.0 was used for statistical analysis. $P < 0.05$ means significant.

RESULTS

Patients' conditions

During hospitalization and treatment period, there was no significant difference in the two groups for cumulative scorings of CTSI and APACHE Ⅱ. On the second and fifth days after treatment with combined indwelling catheter drainage, gastrointestinal TCM ablution, SVVH, respiration support and drugs, the cumulative scorings of APACHE Ⅱ in group 1 were significantly lower than in group 2 ($P < 0.01$); cumulative scorings of APACHE Ⅱ were significantly decreased compared with before treatment ($P < 0.01$, Table 1).

Table 1 Patient's conditions of severity transformation (mean ± SD)

Group	State of illness when hospitalized		Change of APACHE Ⅱ during treament	
	CTSI scoring	APACHE Ⅱ scoring	2 d after treament	5 d after treament
1	7.61 ± 0.67	16.44 ± 2.28	9.66 ± 1.88[b]	4.63 ± 1.46[b]
2	7.59 ± 0.86	15.74 ± 1.91	13.46 ± 1.93	10.78 ± 2.01

[b]$P = 0.000$ *vs* group 2.

Table 2 Celiac drainage and intra-abdominal pressure (mean ± SD)

	1st	2nd	3rd	*P*
Drain quantity (mL)	1817 ± 639	815 ± 423[a]	85 ± 40[a]	0.000
IAP (cmH_2O)	29.29 ± 5.53	13.95 ± 4.05[b]	6.71 ± 1.68[b]	0.000
APACHE Ⅱ scorings	16.44 ± 2.28	9.66 ± 1.88	4.63 ± 1.46	0.000

[a]$r = 0.55$ *vs* IAP , [b]$r = 0.92$ *vs* APACHE Ⅱ scorings.

Table 3 Local symptoms and treatment effect (mean ± SD)

Group	Relief time		Treament effect		
	Abdominalgia (d)	Burbulence (d)	Hospitalization (d)	Mortality rate (%)	Rate of cyst (%)
1	3.27 ± 0.87[b]	6.90 ± 1.18[b]	15.59 ± 3.89[b]	10.0[b]	8.9[b]
2	14.13 ± 2.14	23.36 ± 3.76	28.28 ± 4.61	20.7	37.9

[b]$P < 0.01$ *vs* group 2.

Celiac drainage and intra-abdominal pressure

Drains of 45 cases in group 1 were all dematiaceous bloody liquid. Drainage period was 3.5 ± 0.85 d; drain quantity was positively correlated ($r = 0.552$, $P < 0.01$) with intra-abdominal pressure (IAP) ($r = 0.552$, $P < 0.01$). While IAP was positively correlated with cumulative scorings of APACHE Ⅱ ($r = 0.748$, $P < 0.01$, Table 2).

Relief time for abdominalgia and burbulence, and hospitalization time

The relief time of abdominalgia, burbulence, and hospitalization time in group 1 were significantly shorter than those in group 2 ($P < 0.01$). Mortality rates in group 1 were decreased compared to group 2, with no significant difference. Incidence rates of cysts in group 1 were significantly decreased compared to group 2 ($P < 0.01$, Table 3).

DISCUSSION

FAP is characterized by rapid deterioration of patient's conditions. Multi-organ (specially pancreas and gastrointestinal tract) dysfunction appeared in early stage.

ACS in FAP is divided into four grades according to IAP: first grade is 10-14 cm H_2O, second grade is 15-24 cm H_2O, third grade is 25-35 cm H_2O, and fourth grade is > 35 cm H_2O. In group 1 of our experiment, celiac intra-abdominal pressure of 45 cases was 29.29 ± 5.53 cm H_2O, diagnosed as ACS clinically[4-6]. Currently, ACS is detected mainly by bladder manometry method, which is an indirect

method. However, there are certain influencing factors. Therefore we used indwelling catheter celiac laying canal to directly detect intra-abdominal pressure, and performed canal drainage. It could prevent celiac dropsy ACS, avoid disturbance of celiac function when operating, and the effect of anesthesia on laparotomy and celiac operation, and consequently prevent ACS[7-12]. In our study, the combined approach of indwelling catheter drainage, SVVH and gastrointestinal TCM ablution, respiration support and use of other drugs was employed to treat ACS in FAP. We found that drain quantity was positively correlated with intra-abdominal pressure (r = 0.55), and intra-abdominal pressure was correlated with hospitalization time and APACHE Ⅱ cumulative scorings (r = 0.75, 0.92). In comparison of effectiveness, that of the group 1 was significantly better than that of group 2 regarding abdominalgia disappearing time, burbulence relief time, and hospitalization time (P = 0.000); mortality rates were 10% and 20.7% in group 1 and 2, respectively; incidence rates of cysts between the two groups were significantly different (P = 0.001). The reasons for the better effect of group 1 might be that: (1) indwelling catheter drainage eliminated ACS caused by celiac dropsy; (2) hemofiltration or drainage improved paralysis of gastrointestinal tract caused by a variety of inflammatory cytokines, inflammation mediators, all kinds of enzymes and necrosis materials (including large, moderate and small molecular weight materials). As a consequence, damage of tissues and organs in dropsy (mesentery, epiploon, gastrointestinal and parietal peritoneal membrane) type of ACS was greatly reduced; (3) It was eliminated that the celiac disturbance and the effect on systemic multi-organs (especially gastrointestinal tract) caused by laparoscopic operation or laparotomy and anesthesia; (4) TCM, eg. Dahuang could effectively reduce intestinal tract endotoxin and bacterial shift, alleviate intestinal mucosal membrane damage, and facilitate gastrointestinal movement and emptying[9,13-16]. As far as we know, such study has not been reported.

In summary, combined indwelling catheter celiac drainage, intra-abdominal pressure monitoring, multi-SVVH, gastrointestinal TCM ablution, respiration support and use of drugs can prevent and treat ACS in FAP effectively. However, the problem of slow speed of indwelling catheter celiac drainage has still to be resolved[13].

REFERENCES

1 **Isenmann R**, Rau B, Beger HG. Early severe acute pancreatitis: characteristics of a new subgroup. *Pancreas* 2001; **22**: 274-278

2 **Bosscha K**, Hulstaert PF, Hennipman A, Visser MR, Gooszen HG, van Vroonhoven TJ, v d Werken C. Fulminant acute pancreatitis and infected necrosis: results of open management of the abdomen and "planned" reoperations. *J Am Coll Surg* 1998; **187**: 255-262

3 Pancreatopathy group, Surgery Branch, Chinese Medical Association. Clinical diagnosis and grades criterion of Acute Pancreatitis (second scheme in 1996). *Zhonghua Waike Zahi* 1997; **35**: 773-774

4 **Sun JB**. Problems that should be paid close attention to in diagnosis and treatment of severe acute pancreatitis. *Zhonghua Gandan Waike Zahi* 2005; **11**: 289-292

5 **Ogawa M**. Acute pancreatitis and cytokines: "second attack" by septic complication leads to organ failure. *Pancreas* 1998; **16**: 312-315

6 **Mauricio FL**, Ernesto CG, Benjamin GA, Michael A, Jeff MD. Hipertension intra-abdominal Y sindrome compartamental abdomina en pacientes con pancreatitis aguda. *Cir Ciru* 2003; **71**: 107-111

7 **Cheatham ML**, Safcsak K. Intraabdominal pressure: a revised method for measurement. *J Am Coll Surg* 1998; **186**: 594-595

8 **Appelros S**, Lindgren S, Borgström A. Short and long term outcome of severe acute pancreatitis. *Eur J Surg* 2001; **167**: 281-286

9 **Gecelter G**, Fahoum B, Gardezi S, Schein M. Abdominal compartment syndrome in severe acute pancreatitis: an indication for a decompressing laparotomy? *Dig Surg* 2002; **19**: 402-404; discussion 404-405

10 **Morken J**, West MA. Abdominal compartment syndrome in the intensive care unit. *Curr Opin Crit Care* 2001; **7**: 268-274

11 **Ertel W**, Oberholzer A, Platz A, Stocker R, Trentz O. Incidence and clinical pattern of the abdominal compartment syndrome after "damage-control" laparotomy in 311 patients with severe abdominal and/or pelvic trauma. *Crit Care Med* 2000; **28**: 1747-1753

12 **Kirkpatrick AW**, Brenneman FD, McLean RF, Rapanos T, Boulanger BR. Is clinical examination an accurate indicator of raised intra-abdominal pressure in critically injured patients? *Can J Surg* 2000; **43**: 207-211

13 **Sun ZX**, Sun CY. Combined treatment for abdominal compartment syndrome of fulminant acute pancreatitis in 45 cases. *Shijie Huaren Xiaohua Zahi* 2005; **13**: 1797-1799

14 **Sugerman HJ**, Bloomfield GL, Saggi BW. Multisystem organ failure secondary to increased intraabdominal pressure. *Infection* 1999; **27**: 61-66

15 **Ivatury RR**, Porter JM, Simon RJ, Islam S, John R, Stahl WM. Intra-abdominal hypertension after life-threatening penetrating abdominal trauma: prophylaxis, incidence, and clinical relevance to gastric mucosal pH and abdominal compartment syndrome. *J Trauma* 1998; **44**: 1016-1021; discussion 1021-1023

16 **Mayberry JC**, Goldman RK, Mullins RJ, Brand DM, Crass RA, Trunkey DD. Surveyed opinion of American trauma surgeons on the prevention of the abdominal compartment syndrome. *J Trauma* 1999; **47**: 509-513; discussion 513-514

S- Editor Pan BR **L- Editor** Zhu LH **E- Editor** Ma WH

PO Box 2345, Beijing 100023, China
www.wjgnet.com
wjg@wjgnet.com

World J Gastroenterol 2006 August 21; 12(31): 5071-5074
World Journal of Gastroenterology ISSN 1007-9327
© 2006 The WJG Press. All rights reserved.

CASE REPORT

Transhepatic catheter-directed thrombolysis for portal vein thrombosis after partial splenic embolization in combination with balloon-occluded retrograde transvenous obliteration of splenorenal shunt

Motoki Nakai, Morio Sato, Shinya Sahara, Nobuyuki Kawai, Masashi Kimura, Yoshimasa Maeda, Yumiko Ibata, Katsuhiko Higashi

Motoki Nakai, Morio Sato, Shinya Sahara, Nobuyuki Kawai, Masashi Kimura, Department of Radiology, Wakayama Medical University, 811-1, Kimiidera, Wakayama Shi, Wakayama 641-8510, Japan
Yoshimasa Maeda, Yumiko Ibata, Katsuhiko Higashi, the First Department of Internal Medicine, Hidaka General Hospital, 116-2 Sono, Gobo Shi, Wakayama 644-8655, Japan
Correspondence to: Motoki Nakai, Department of Radiology, Hidaka General Hospital, 116-2 Sono, Gobo Shi, Wakayama 644-8655, Japan. nakai@hidakagh.gobo.wakayama.jp
Telephone: +81-738-221111 Fax: +81-738-232253
Received: 2006-04-07 Accepted: 2006-04-27

Abstract

A 66-year-old woman underwent partial splenic embolization (PSE) for hypersplenism with idiopathic portal hypertension (IPH). One week later, contrast-enhanced CT revealed extensive portal vein thrombosis (PVT) and dilated portosystemic shunts. The PVT was not dissolved by the intravenous administration of urokinase. The right portal vein was canulated *via* the percutaneous transhepatic route under ultrasonic guidance and a 4 Fr. straight catheter was advanced into the portal vein through the thrombus. Transhepatic catheter-directed thrombolysis was performed to dissolve the PVT and a splenorenal shunt was concurrently occluded to increase portal blood flow, using balloon-occluded retrograde transvenous obliteration (BRTO) technique. Subsequent contrast-enhanced CT showed good patency of the portal vein and thrombosed splenorenal shunt.

Transhepatic catheter-directed thrombolysis combined with BRTO is feasible and effective for PVT with portosystemic shunts.

© 2006 The WJG Press. All rights reserved.

Key words: Portal vein thrombosis; Idiopathic portal hypertension; Partial splenic embolization; Portosystemic shunts; Transhepatic catheter-directed thrombolysis; Balloon-occluded retrograde transvenous obliteration

Nakai M, Sato M, Sahara S, Kawai N, Kimura M, Maeda Y, Ibata Y, Higashi K. Transhepatic catheter-directed thrombolysis for portal vein thrombosis after partial splenic embolization in combination with balloon-occluded retrograde transvenous obliteration of splenorenal shunt. *World J Gastroenterol* 2006; 12(31): 5071-5074

http://www.wjgnet.com/1007-9327/12/5071.asp

INTRODUCTION

Acute portal vein thrombosis (PVT) after partial splenic embolization (PSE) in portal hypertension is a rare event[1-3]. Stagnant splenic blood flow after PSE appears to result in PVT[4,5]. Surgical treatment is generally ineffective and yields poor results. Consequently, direct percutaneous intervention is increasing in popularity as a therapeutic alternative. Portal systemic shunts (PSS) are frequently formed due to portal hypertension in patients with chronic liver diseases such as liver cirrhosis or idiopathic portal hypertension (IPH). Balloon-occluded retrograde transvenous obliteration (BRTO) is an effective treatment for gastric varices and encephalopathy with PSS[6-8].

We report a patient with portal vein thrombosis after PSE in IPH with extensive portal systemic shunts treated with transhepatic catheter-directed thrombolysis combined with BRTO restoring portal blood flow.

CASE REPORT

A 66-year-old woman with a medical history of IPH was hospitalized with continuously bloody stool (melena). The HBV and HCV markers were all negative. IPH was diagnosed by liver biopsy and CT scan. Upper endoscopy was performed after admission and small esophageal varices without bleeding were pointed out. Telangiectasia was found in the transverse colon by colonoscopy and hemostasis was accomplished by endoscopic high-frequency coagulation. Despite repeated transfusion of red blood cells and platelets, laboratory examination revealed significant pancytopenia, with a white blood cell count of 1.1×10^9/L, red blood cell count of 2.71×10^{12}/L, and platelet count of 2.5×10^{10}/L. US and CT revealed splenomegaly.

The patient underwent PSE to reduce hypersplenism and portal hypertension. The splenic artery was catheter-

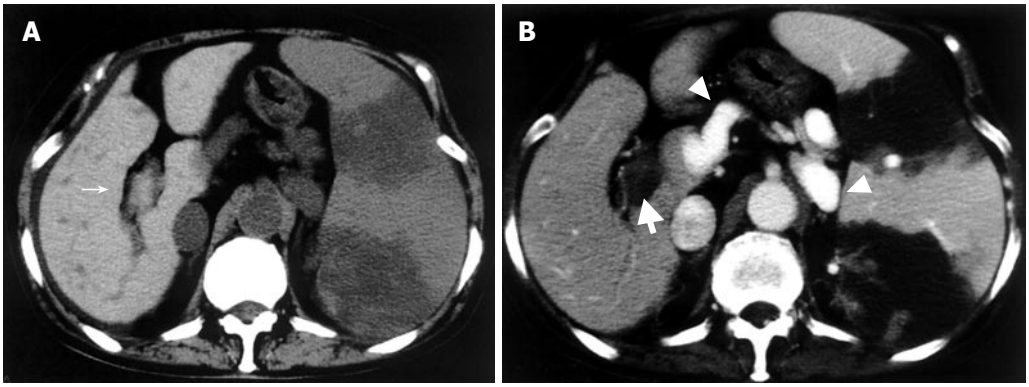

Figure 1 Abdominal CT one week after PSE. **A**: Plain CT showing high density lesions in the main portal vein and the 1st right branch (narrow arrow); **B**: Contrast-enhanced CT revealing no enhancement of portal vein indicating portal thrombosis (thick arrow) and portosystemic shunts (arrow head). Splenic infarction after PSE was also visualized.

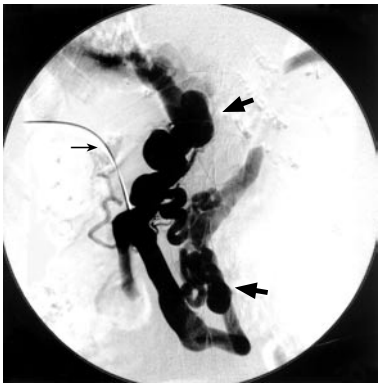

Figure 2 No visualization of main portal vein due to extensive thrombosis (narrow arrow) and visualization of portosystemic shunts such as dilated left gastric vein and splenorenal shunt draining into left renal vein (thick arrow) on percutaneous transhepatic portography.

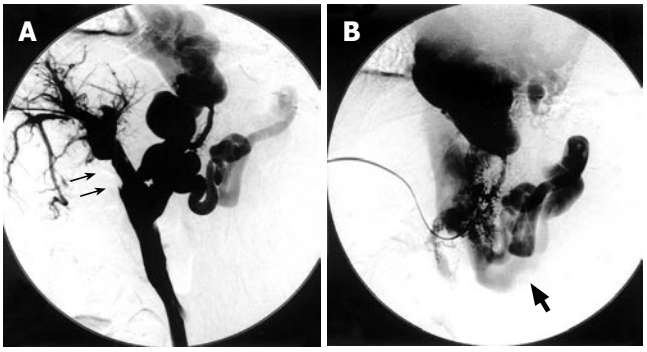

Figure 3 Percutaneous transhepatic portography after catheter-directed thrombolysis. **A**: Dissolution of the thrombus in portal vein (narrow arrow); **B**: Hepatofugal flow into dilated portosystemic shunts (thick arrow: left renal vein).

ized selectively *via* the femoral route, and the tip of microcatheter was inserted in a peripheral branch of the splenic artery. Small particles (1 mm × 1 mm × 1 mm) of gelatin sponge soaked in antibiotics were injected to achieve PSE. The platelet count rose to 14×10^{10}/L on the 7th d after PSE. Plain CT revealed a low-density area in the spleen and high-density thrombus in the main portal vein and the 1st right and left branches (Figure 1A), and contrast-enhanced CT revealed no enhancement of the portal vein indicating extensive portal thrombosis (Figure 1B). Portosystemic shunts including a dilated left gastric vein to the paraesophageal vein and splenorenal shunt draining into the left renal vein were also visualized. Thrombolytics and anticoagulants were initiated, urokinase (240 000 U/d) and heparin (10 000 U/d) were given intravenously for 3 d. However, CT after systemic thrombolysis revealed that the thrombosis did not resolve.

It was therefore decided to attempt catheter-directed thrombolysis. With the patient under local anesthesia, a branch of the right portal vein was punctured with an 18-gauge needle under ultrasonic guidance. A 0.035-inch guidewire was advanced into the portal vein through the thrombus. A 4 Fr. straight catheter (Cook, Bloomington, IN) was advanced into the splenic vein and portography was performed. Percutaneous transhepatic portography (PTP) yielded no visualization of the main portal vein but did show large collaterals of the dilated gastric vein and splenorenal shunt (Figure 2). Urokinase at a dosage of 320 000 U was initially infused directly into the thrombus for 30 min. However, because immediate resolution of the thrombus was not observed, an hourly dose of 20 000 U of urokinase and a daily dose of 10 000 U of heparin

Figure 4 PTP after BRTO. BRTO was attempted to occlude splenorenal shunt in order to increase portal blood flow. A 7Fr balloon catheter (arrow) was advanced into the outflow pathway of the splenorenal shunt. A total of 10 mL of 5% ethanolamine oleate iopamidol (EOI) was injected and remained stagnant for a day during balloon occlusion.

were continuously infused into the thrombus. Two days later, PTP revealed total resolution of the thrombus in the portal vein and recirculation of portal blood flow to liver parenchyma (Figure 3A). However, there was still marked hepatofugal flow into the dilated PSS, inducing stagnation of portal blood flow (Figure 3B). BRTO was then attempted to occlude the splenorenal shunt in order to increase portal blood flow. An 8 Fr. J-type sheath (J Sheath; Medikidt, Tokyo, Japan) was inserted into the left renal vein *via* the right femoral vein. A 7 Fr. balloon catheter (Selecon Cobra-shape MP catheter with 13 mm diameter balloon; Clinical Supply, Gifu, Japan) was advanced through the sheath into the outflow pathway of the splenorenal shunt (Figure 4). Balloon-occluded retrograde venography was carried out to identify the splenorenal shunt and the other outflowing vessels. The amount of sclerosing solution was

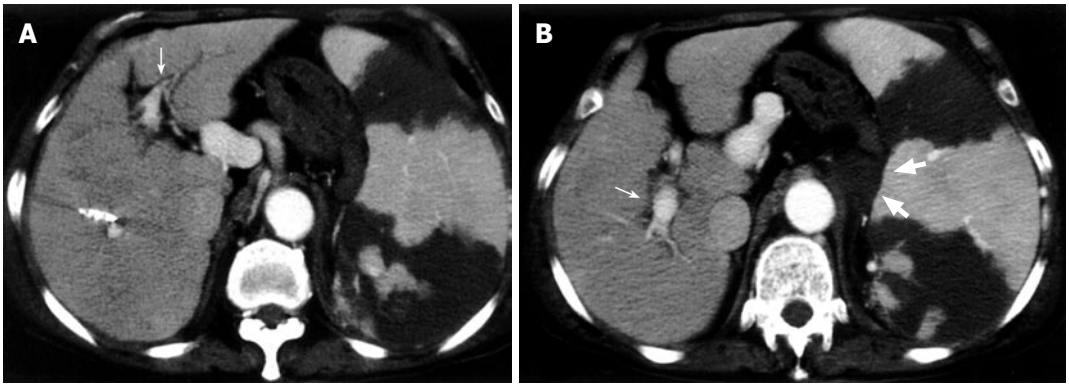

Figure 5 Contrast-enhanced CT 1 wk after catheter-directed thrombolysis and BRTO. **A**: Good patency of the portal vein (narrow arrow); **B**: Thrombosed splenorenal shunt (thick arrow).

determined from the volume of contrast material needed to fill these vessels. Preoperatively, 4000 U of haptoglobin (Mitsubishi Pharma, Osaka, Japan) was administered intravenously by drip infusion for the purpose of preventing a renal damage by hemolysis. A total of 10 mL of 5% (50 g/L) ethanolamine oleate iopamidol (EOI) was injected and remained stagnant in these vessels for a day during balloon occlusion. The following day, the balloon catheter was withdrawn after thrombosis of the splenorenal shunt was confirmed on contrast-enhanced CT (Figures 5A and B). The transhepatic catheter was subsequently removed using hemostatic microcoils for the transparenchymal tract without hemorrhagic complications. Six-month follow-up CT revealed good patency in the main portal vein.

DISCUSSION

Maddison[9] first reported splenic embolization for hypersplenism in 1973. Spigos *et al*[10] advocated partial splenic embolization (PSE) as an alternative method for the treatment of portal hypertension in 1979. PSE has been widely used for the treatment of portal hypertension and hypersplenism caused by IPH and liver cirrhosis since then[1-3,9-11]. The aim of PSE is to decrease splenic blood flow and prevent platelet destruction in the spleen. An optimal increase in platelet count could be observed if a single procedure induces an infarct size of at least 60%-80% of the total spleen volume[2,11]. Complications of PSE listed in the literature include local pain, ascites, pleural effusion, splenic abscess and also portal vein thrombosis (PVT) secondary to reduced blood flow in the splenic vein[1-3]. Romano *et al*[2] reported that no cases of PVT have been observed after PSE in patients with IPH. N'Kontchou *et al*[3] reported that the incidence of PVT after PSE is 6.3% in patients with cirrhosis. Eguchi *et al*[4] reported that the incidence of PVT after splenectomy is 25.0% in patients with IPH. PVT can occur with a higher incidence after splenectomy than after PSE.

PVT can occur due to other conditions including liver cirrhosis, IPH, direct invasion of neoplasm, hypercoagulable states, and inflammatory diseases such as pancreatitis and ulcerative colitis[5,12,13]. PVT can result in intestinal ischemia and venous infarction in the acute stage. In the chronic stage, signs of portal hypertension such as esophageal varices, ascites, intestinal bleeding, liver atrophy, and liver failure become prominent[12,13]. Management of acute portal vein thrombosis is thus important. In our case, reduction of splenic blood flow due to PSE and outflow of the superior mesenteric vein (SMV) into the dilated PSS caused portal vein thrombosis.

The standard treatment for PVT is systemic thrombolysis with anticoagulants and local thrombolysis using interventional radiology (IVR) procedures[13]. Urokinase (UK) has been used as a thrombolytic agent for PVT, but an enormous amount of UK is required for systemic use[14], and often has no effect, as in our case. There are two IVR procedures to treat PVT: trans-arterial thrombolysis *via* the superior mesenteric artery (SMA) and catheter-directed thrombolysis[15]. The angiographic method of trans-arterial thrombolysis is easy and involves only placement of a catheter into the SMA *via* the femoral artery[16-18]. However, in our patient with remarkable portosystemic collaterals, UK would drain into hepatofugal collaterals and would not reach PVT easily. Local thrombolysis should be more effective for patients with PSS, since high concentrations of UK are directly infused into the PVT through a catheter. Access to catheter-directed thrombolysis is divided into two routes: the transhepatic route[19-21] and the transjugular route[22-24]. Uflacker[24] emphasizes the advantages such as reduction of the possibility of intraabdominal bleeding and creation of adequate portal vein outflow by transjugular intrahepatic portosystemic shunt (TIPS) procedure. However, in our patient with complete portal vein occlusion and large PSS, additional and new creation of a portosystemic shunt can cause complications such as hepatic encephalopathy and hepatic failure[25,26]. We therefore decided to use a transhepatic approach to treat PVT. The transhepatic approach is technically simpler than transjugular approach. This approach allows direct guidewire recanalization of the occluded portion and instillation of high concentrations of UK directly into the thrombus, and reduces the risks of systemic fibrinolysis. In this transhepatic approach there is a risk of uncontrollable bleeding through the transparenchymal tract after removal of the catheter especially in patients with coagulopathy[27]. Avoiding such complications, complete transparenchymal tract embolization with microcoils or gelatin sponge after removal of the catheter is necessary to overcome intraabdominal bleeding. In our case, the transparenchymal tract was embolized with microcoils, and PVT was dissolved completely by transhepatic catheter-directed thrombolysis without hemorrhagic complications. We believe that local

thrombolytic therapy *via* transhepatic route should be considered as a feasible, efficacious and safe treatment.

In the present case, even after recanalization of the portal vein, the patient had stagnancy of portal blood flow with outflow of the SMV into the large PSS. Unless the blood flow to PSS is decreased to increase the portal blood flow, PVT may recur after dissolution. Concurrent BRTO was therefore performed to occlude the splenorenal shunt in our patient, and achieved long-term patency of the portal vein. There is no previous report describing the necessity for concurrent occlusion of portosystemic shunt after recanalization of PVT.

In conclusion, catheter-directed thrombolysis combined with BRTO is feasible and useful for recanalizing PVT and maintaining stable patency of the portal vein in patients with PVT.

REFERENCES

1 **Sangro B**, Bilbao I, Herrero I, Corella C, Longo J, Beloqui O, Ruiz J, Zozaya JM, Quiroga J, Prieto J. Partial splenic embolization for the treatment of hypersplenism in cirrhosis. *Hepatology* 1993; **18**: 309-314

2 **Romano M**, Giojelli A, Capuano G, Pomponi D, Salvatore M. Partial splenic embolization in patients with idiopathic portal hypertension. *Eur J Radiol* 2004; **49**: 268-273

3 **N'Kontchou G**, Seror O, Bourcier V, Mohand D, Ajavon Y, Castera L, Grando-Lemaire V, Ganne-Carrie N, Sellier N, Trinchet JC, Beaugrand M. Partial splenic embolization in patients with cirrhosis: efficacy, tolerance and long-term outcome in 32 patients. *Eur J Gastroenterol Hepatol* 2005; **17**: 179-184

4 **Eguchi A**, Hashizume M, Kitano S, Tanoue K, Wada H, Sugimachi K. High rate of portal thrombosis after splenectomy in patients with esophageal varices and idiopathic portal hypertension. *Arch Surg* 1991; **126**: 752-755

5 **Valla DC**, Condat B. Portal vein thrombosis in adults: pathophysiology, pathogenesis and management. *J Hepatol* 2000; **32**: 865-871

6 **Kanagawa H**, Mima S, Kouyama H, Gotoh K, Uchida T, Okuda K. Treatment of gastric fundal varices by balloon-occluded retrograde transvenous obliteration. *J Gastroenterol Hepatol* 1996; **11**: 51-58

7 **Kawanaka H**, Ohta M, Hashizume M, Tomikawa M, Higashi H, Kishihara F, Sugimachi K, Tokumatsu M. Portosystemic encephalopathy treated with balloon-occluded retrograde transvenous obliteration. *Am J Gastroenterol* 1995; **90**: 508-510

8 **Kato T**, Uematsu T, Nishigaki Y, Sugihara J, Tomita E, Moriwaki H. Therapeutic effect of balloon-occluded retrograde transvenous obliteration on portal-systemic encephalopathy in patients with liver cirrhosis. *Intern Med* 2001; **40**: 688-691

9 **Maddison FE**. Embolic Therapy of Hypersplenism. *Invest Radiol* 1973; **8**: 280

10 **Spigos DG**, Jonasson O, Mozes M, Capek V. Partial splenic embolization in the treatment of hypersplenism. *AJR Am J Roentgenol* 1979; **132**: 777-782

11 **Hirota S**, Ichikawa S, Matsumoto S, Motohara T, Fukuda T, Yoshikawa T. Interventional radiologic treatment for idiopathic portal hypertension. *Cardiovasc Intervent Radiol* 1999; **22**: 311-314

12 **Cohen J**, Edelman RR, Chopra S. Portal vein thrombosis: a review. *Am J Med* 1992; **92**: 173-182

13 **Hidajat N**, Stobbe H, Griesshaber V, Schroder RJ, Felix R. Portal vein thrombosis: etiology, diagnostic strategy, therapy and management. *Vasa* 2005; **34**: 81-92

14 **Suzuki S**, Nakamura S, Baba S, Sakaguchi S, Ohnuki Y, Yokoi Y, Nishiyama R. Portal vein thrombosis after splenectomy successfully treated by an enormous dosage of fibrinolytic agent in a short period: report of two cases. *Surg Today* 1992; **22**: 464-469

15 **Hollingshead M**, Burke CT, Mauro MA, Weeks SM, Dixon RG, Jaques PF. Transcatheter thrombolytic therapy for acute mesenteric and portal vein thrombosis. *J Vasc Interv Radiol* 2005; **16**: 651-661

16 **Henao EA**, Bohannon WT, Silva MB Jr. Treatment of portal venous thrombosis with selective superior mesenteric artery infusion of recombinant tissue plasminogen activator. *J Vasc Surg* 2003; **38**: 1411-1415

17 **Poplausky MR**, Kaufman JA, Geller SC, Waltman AC. Mesenteric venous thrombosis treated with urokinase via the superior mesenteric artery. *Gastroenterology* 1996; **110**: 1633-1635

18 **Antoch G**, Taleb N, Hansen O, Stock W. Transarterial thrombolysis of portal and mesenteric vein thrombosis: a promising alternative to common therapy. *Eur J Vasc Endovasc Surg* 2001; **21**: 471-472

19 **Miyazaki Y**, Shinomura Y, Kitamura S, Hiraoka S, Tomoda K, Nezu R, Kamiike W, Nakamura H, Matsuzawa Y. Portal vein thrombosis associated with active ulcerative colitis: percutaneous transhepatic recanalization. *Am J Gastroenterol* 1995; **90**: 1533-1534

20 **Guglielmi A**, Fior F, Halmos O, Veraldi GF, Rossaro L, Ruzzenente A, Cordiano C. Transhepatic fibrinolysis of mesenteric and portal vein thrombosis in a patient with ulcerative colitis: a case report. *World J Gastroenterol* 2005; **11**: 2035-2038

21 **Bilbao JI**, Rodriguez-Cabello J, Longo J, Zornoza G, Páramo J, Lecumberri FJ. Portal thrombosis: percutaneous transhepatic treatment with urokinase--a case report. *Gastrointest Radiol* 1989; **14**: 326-328

22 **Blum U**, Haag K, Rössle M, Ochs A, Gabelmann A, Boos S, Langer M. Noncavernomatous portal vein thrombosis in hepatic cirrhosis: treatment with transjugular intrahepatic portosystemic shunt and local thrombolysis. *Radiology* 1995; **195**: 153-157

23 **Aytekin C**, Boyvat F, Kurt A, Yologlu Z, Coskun M. Catheter-directed thrombolysis with transjugular access in portal vein thrombosis secondary to pancreatitis. *Eur J Radiol* 2001; **39**: 80-82

24 **Uflacker R**. Applications of percutaneous mechanical thrombectomy in transjugular intrahepatic portosystemic shunt and portal vein thrombosis. *Tech Vasc Interv Radiol* 2003; **6**: 59-69

25 **Brown RS Jr**, Lake JR. Transjugular intrahepatic portosystemic shunt as a form of treatment for portal hypertension: indications and contraindications. *Adv Intern Med* 1997; **42**: 485-504

26 **Somberg KA**, Riegler JL, LaBerge JM, Doherty-Simor MM, Bachetti P, Roberts JP, Lake JR. Hepatic encephalopathy after transjugular intrahepatic portosystemic shunts: incidence and risk factors. *Am J Gastroenterol* 1995; **90**: 549-555

27 **Allison DJ**, Adam A. Percutaneous liver biopsy and track embolization with steel coils. *Radiology* 1988; **169**: 261-263

S- Editor Pan BR **L- Editor** Wang XL **E- Editor** Bai SH

PO Box 2345, Beijing 100023, China
www.wjgnet.com
wjg@wjgnet.com

World J Gastroenterol 2006 August 21; 12(31): 5075-5077
World Journal of Gastroenterology ISSN 1007-9327
© 2006 The WJG Press. All rights reserved.

CASE REPORT

Clinical evaluation of submucosal colonic lipomas: Decision making

Oge Tascilar, Güldeniz Karadeniz Cakmak, Banu Dogan Gün, Bülent Hamdi Uçan, Hakan Balbaloglu, Ali Cesur, Ali Ugur Emre, Mustafa Comert, Lütfü Oktay Erdem, Selim Aydemir

Oge Tascilar, Güldeniz Karadeniz Cakmak, Bülent Hamdi Uçan, Hakan Balbaloglu, Ali Cesur, Ali Ugur Emre, Mustafa Comert, Department of Surgery, Zonguldak Karaelmas University, School of Medicine, Kozlu-Zonguldak, Turkey
Banu Dogan Gün, Department of pathology, Zonguldak Karaelmas University, School of Medicine, Kozlu-Zonguldak, Turkey
Lütfü Oktay Erdem, Department of Radiology, Zonguldak Karaelmas University, School of Medicine, Kozlu-Zonguldak, Turkey
Selim Aydemir, Department of Gastroenterology, Zonguldak Karaelmas University, School of Medicine, Kozlu-Zonguldak, Turkey
Correspondence to: Dr. Güldeniz Karadeniz Cakmak, Zonguldak Karaelmas Universitesi, Arastirma ve Uygulama Hastanesi Bashekimligi, Kozlu-Zonguldak 67600, Turkey. gkkaradeniz@yahoo.com
Telephone: +90-372-2610159
Received: 2005-12-12 Accepted: 2006-01-18

Abstract

Even lipomas are the most common mesenchymal benign tumors of the gastrointestinal tract, symptomatic colonic presentation is rare. Herein, we evaluated four patients suffering from various size of colonic lipomas and approached by different therapeutic modalities.

© 2006 The WJG Press. All rights reserved.

Key words: Colon; Lipoma; Complication; Management

Tascilar O, Cakmak GK, Gün BD, Uçan BH, Balbaloglu H, Cesur A, Emre AU, Comert M, Erdem LO, Aydemir S. Clinical evaluation of submucosal colonic lipomas: Decision making. *World J Gastroenterol* 2006; 12(31): 5075-5077

http://www.wjgnet.com/1007-9327/12/5075.asp

INTRODUCTION

Lipomas are the most common nonepithelial benign tumors of the gastrointestinal tract. Nevertheless symptoms of a colonic lipoma are rare generally with a silent clinical course. When colonic lipomas achieve a proper size, they have manifestations such as change in bowel habits, rectal bleeding, abdominal pain or more disastrous consequences like obstruction and intussusception requiring urgent interventions. Herein, we report four patients suffering from various sizes of colonic lipoma who were treated with different theraupatic modalities.

CASE REPORT

The first patient was a 77-year old female who presented with recurrent episodes of right upper quadrant abdominal cramping. Her physical examination and previous medical history were unremarkable except for a cholecystectomy. Standard laboratory values were within normal ranges. Abdominal computed tomography (CT) revealed a regular contoured 4 cm × 3 cm mass lesion with fatty density localized in the midportion of ascending colon causing a luminal narrowing defect (Figure 1A). In double contrast enema, a filling defect of the protruded polypoid lesion was detected at the same location (Figure 1B). Colonoscopy demonstrated a mass lesion with a broad base and normal overlying mucosa (about 4 cm in diameter) adjacent to the hepatic flexura. The patient was diagnosed having a symptomatic colonic lipoma during surgery. Following colotomy, mucosa overlying the mass lesion was dissected and a tumor with a macroscopic appearance similar to lipoma was enucleated (Figure 1C). Histopathologic examination verified the diagnosis of lipoma localized in the submucosal layer and the patient remained asymptomatic through a 2-year follow-up period.

The second patient was a 41-year old male admitted to our clinic with similar complaints of the first patient. Physical and laboratory examinations were natural only with a positive fecal occult blood test. He denied any significant medical or surgical history. Abdominal CT demonstrated a regular contoured 3 cm × 2 cm mass lesion with fatty density localized in the hepatic flexura causing a filling defect which was confirmed by double contrast enema (Figure 2A). A segmental resection was performed with the diagnosis of lipoma, pathological evaluation of the specimen showed that it was a benign submucosal lipoma (Figure 2B).

The third patient was a 77-year old female presented with recurrent abdominal pain in the left lower quadrant for a year, bloody defecation for 6 mo and constipation for 4 wk. Physical examination revealed no pathological change except for left lower quadrant distention. Blood biochemical analysis, sedimentation rate and complete blood count were normal. Colonoscopy revealed a broad-

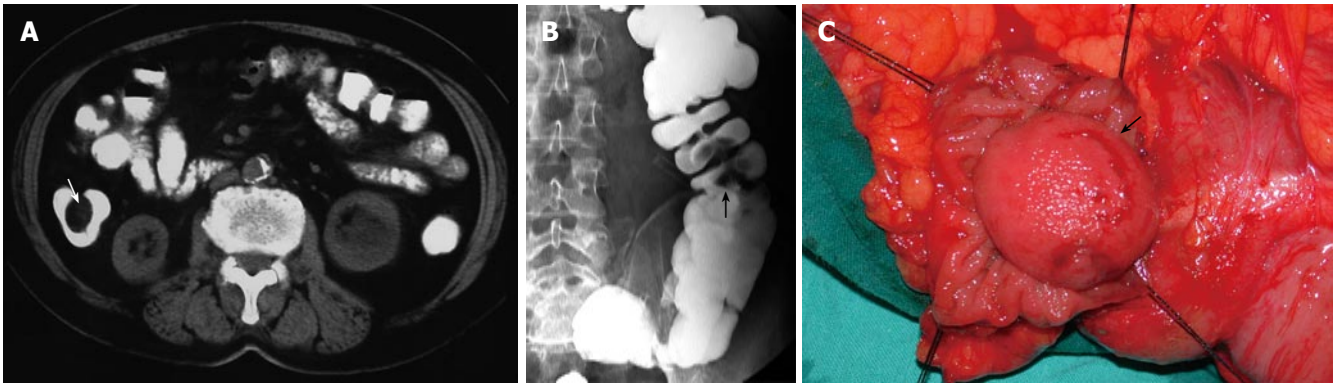

Figure 1 Computed tomography (CT) scan showing a regular contoured 4 cm x 3 cm lesion with fatty density localised in midportion of ascending colon causing a luminal narrowing defect (**A**), double contrast barium enema showing a filling defect of the protruded polipoid lesion at the hepatic flexura of colon (**B**), and appearance of the colonic submucosal lipoma during the operation (**C**).

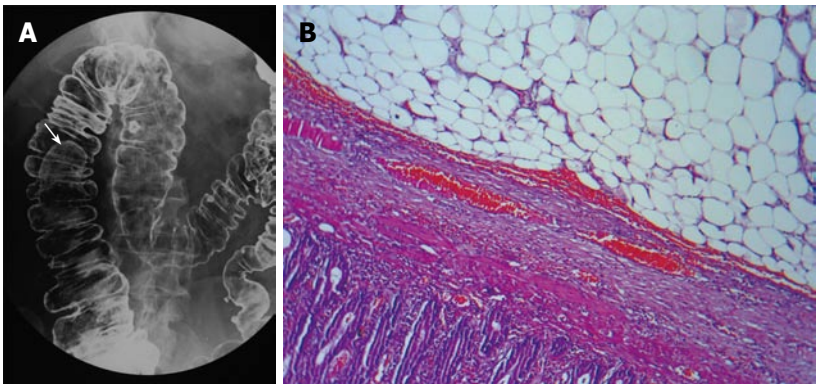

Figure 2 A mass lesion located in the hepatic flexura causing filling defect shown by double contrast enema (**A**), resected biopsy specimen showing a submucosal benign lipoma composed of mature lipocytes by hematoxylin and eosin staining (**B**) (x 400).

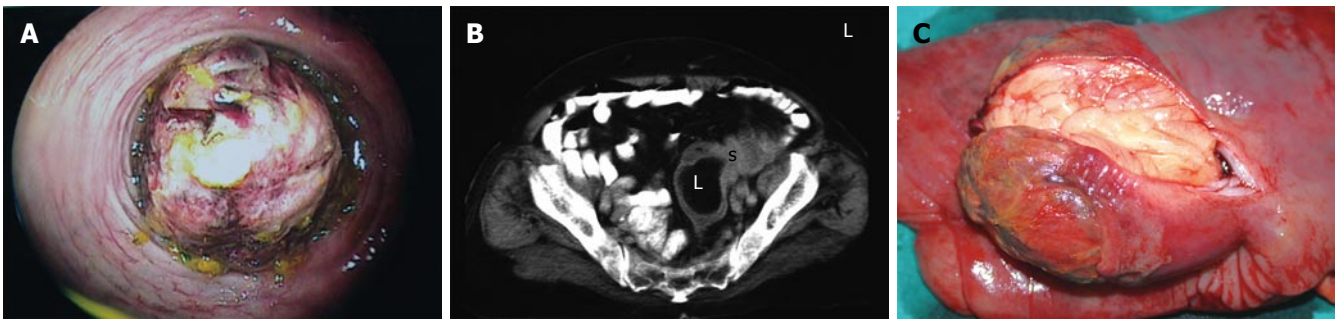

Figure 3 Colonoscopic appearance of a broad- based giant mass acquiring spontaneous hemorrhagic areas and obstructing more than 75% of the lumen of sigmoid colon (**A**); abdominal computed tomography scans showing the diffuse thickening of sigmoid colon wall, invagination and a distal intraluminal giant mass with fat density with a size of approximately 6 cm x 7 cm (**B**); macroscopic appearance of the giant sigmoid colon lipoma (**C**).

based giant mass acquiring spontaneous hemorrhagic areas and obstructing more than 75% of the colonic lumen (Figure 3A). Punch biopsy exhibited benign colonic mucosa showing inflammatory granulation. Abdominal CT showed diffuse thickening of the sigmoid colon wall, invagination and an intraluminal mass with a size of approximately 6 cm × 7 cm having density values equal to fat (Figure 3B). An evident sigmoid redundancy and a mass lesion nearly obliterating colonic lumen were detected during surgery. A segmenter resection of the sigmoid colon was the operative procedure of choice (Figure 3C). Microscopic examination confirmed that the lesion was a submucosal lipoma with a size of 6 cm × 7 cm.

The fourth patient was a 44-year old male presented with tenesmus. Physical examination revealed nothing significant. A pedinculated polypoid mass lesion projecting into the lumen with an approximate diameter of 2.5 cm was discovered at the 15th cm of the rectum by colonoscopy. An endoscopic snare polypectomy and rectal biopsy were performed during the same intervention. The histopathologic examination revealed normal rectal mucosa and underlocated lipoma.

DISCUSSION

Lipoma of the gastrointestinal tract was first described by

Bauer *et al*[1] in 1757. Lipoma is the second most common benign colonic tumor following adenomatous polyps and the incidence has been reported to range between 0.2% and 4.4%[2,3]. Colonic lipoma is more common in elderly women and tends to derive from right hemicolon with a decreasing frequency from cecum to sigmoid colon[2-5]. Approximately in 90% of cases, lipoma is defined to arise from the submucosal layer and the subserosal or intermucosal layer accounting for the remaining 10%[1,6]. They are usually solitary with varying sizes and may be sessile or pedunculated. Although the majority of these lesions are asymptomatic and detected incidentally during the examination of symptoms like abdominal pain, change in bowel habits, and rectal bleeding or in surgical specimen removed for various other reasons, on rare occasions colonic lipoma may present with massive hemorrhage, obstruction, perforation, intussusception, or prolapse[7-11]. Severity of the signs and symptoms is attributed to the size of the lesions. Lipomas larger than 2 cm in diameter may cause symptoms such as constipation, diarrhea, abdominal pain, or rectal bleeding[1,3,5]. Colicky pain may be due to intermittent intussusception whereas rectal bleeding can occur as a result of ulceration of the overlying mucosa. One of the greatest clinical significances of lipoma is its potential to be confused with colonic malignancies according to the similarity in both symptomatology, fortunately sarcomatous changes in colonic lipomas have not been reported yet[1]. Colonoscopy, CT and barium enema are considered to be the diagnostic tools, but pyhsicians should be aware that colonoscopic biopsies usually possess no histopathologic value as the lesion is beneath the normal mucosa and biopsy often can not promote diagnosis[12]. The radiographic appearance of colonic lipomas may resemble that of carcinomas. The "squeeze sign" is told to be pathognomonic for colonic lipomas, and is characterized by the elongation of a spherical filling defect during peristalsis on barium enema examination[1,13]. Despite recent diagnostic innovations in radiology, histopathologic evaluation is the gold standard in precise diagnosis. However, most colonic lipomas are asymptomatic incidental entities, the decision of removal is based on the criteria including those with suspicion of malignancy, and symptomatic lipomas. A wide range of treatment modalities have been suggested. The way of removal depends on the presentation of the case as an elective or an emergency. Surgical intervention is mandatory in surgical emergencies such as obstruction, intussusception, perforation, or very rarely massive hemorrhage. Elective endoscopic removal of submucosal lipoma up to 2 cm in diameter is reported to be safe and appropriate, however in larger lesions the risk of associated complications like uncontrolled hemorrhage and perforation makes the procedure controversial[1,14-16]. Conventional laparotomy including enucleation, colotomy and excision, and segmental colonic resection has been described as a choice of treatment as well as minilaparotomy or transanal resection of lesions mimicking rectal prolapse[1,7,16]. Minimally invasive surgeries such as laparoscopy -assisted resection under colonoscopic guidance has also been defined for selected cases[15,17].

In the literature, the general consensus on colonic lipomas is that local enucleation is an appropriate and effective procedure of choice for the management of these lesions possessing no malignant potantial. Colonoscopic removal can be safely performed for submucosal lipomas smaller than 2.5 cm in diameter, however larger or subserosal tumors associated with complication risks of obstruction, intussusception, hemorrhage and even perforation deserve extended interventions. Surgical approach should be established through the features of each case on individual basis.

REFERENCES

1 **Bardají M**, Roset F, Camps R, Sant F, Fernández-Layos MJ. Symptomatic colonic lipoma: differential diagnosis of large bowel tumors. *Int J Colorectal Dis* 1998; **13**: 1-2

2 **Rogy MA**, Mirza D, Berlakovich G, Winkelbauer F, Rauhs R. Submucous large-bowel lipomas--presentation and management. An 18-year study. *Eur J Surg* 1991; **157**: 51–55

3 **Vecchio R**, Ferrara M, Mosca F, Ignoto A, Latteri F. Lipomas of the large bowel. *Eur J Surg* 1996; **162**: 915-919

4 **Bahadursingh AM**, Robbins PL, Longo WE. Giant submucosal sigmoid colon lipoma. *Am J Surg* 2003; **186**: 81-82

5 **Taylor BA**, Wolff BG. Colonic lipomas. Report of two unusual cases and review of the Mayo Clinic experience, 1976-1985. *Dis Colon Rectum* 1987; **30**: 888-893

6 **Balducci G**, Bocchetti T, Petrocca S, Meli L. [Intestinal occlusion due to a giant lipoma of the cecum]. *G Chir* 2000; **21**: 17-19

7 **Tzilinis A**, Fessenden JM, Ressler KM, Clarke LE. Transanal resection of a colonic lipoma, mimicking rectal prolapse. *Curr Surg* 2003; **60**: 313-314

8 **Rodriguez DI**, Drehner DM, Beck DE, McCauley CE. Colonic lipoma as a source of massive hemorrhage. Report of a case. *Dis Colon Rectum* 1990; **33**: 977-979

9 **Creasy TS**, Baker AR, Talbot IC, Veitch PS. Symptomatic submucosal lipoma of the large bowel. *Br J Surg* 1987; **74**: 984-986

10 **Kaushik R**, Yadav TD, Dabra A. A case of sigmoid lipoma presenting with intussusception. *Trop Gastroenterol* 2001; **22**: 97-98

11 **Zamboni WA**, Fleisher H, Zander JD, Folse JR. Spontaneous expulsion of lipoma per rectum occurring with colonic intussusception. *Surgery* 1987; **101**: 104-107

12 **Zhang H**, Cong JC, Chen CS, Qiao L, Liu EQ. Submucous colon lipoma: a case report and review of the literature. *World J Gastroenterol* 2005; **11**: 3167-3169

13 **Marra B**. [Intestinal occlusion due to a colonic lipoma. Apropos 2 cases]. *Minerva Chir* 1993; **48**: 1035-1039

14 **Tamura S**, Yokoyama Y, Morita T, Tadokoro T, Higashidani Y, Onishi S. "Giant" colon lipoma: what kind of findings are necessary for the indication of endoscopic resection? *Am J Gastroenterol* 2001; **96**: 1944-1946

15 **Ladurner R**, Mussack T, Hohenbleicher F, Folwaczny C, Siebeck M, Hallfeld K. Laparoscopic-assisted resection of giant sigmoid lipoma under colonoscopic guidance. *Surg Endosc* 2003; **17**: 160

16 **Nakagoe T**, Sawai T, Tsuji T, Tanaka K, Nanashima A, Shibasaki S, Yamaguchi H, Yasutake T. Minilaparotomy approach for removal of a large colonic lipoma: report of two cases. *Surg Today* 2004; **34**: 72-75

17 **Gracia E**, Targarona EM, Garriga J, Pujol J, Trias M. [Laparoscopic treatment of colorectal polyps]. *Gastroenterol Hepatol 2000*; **23**: 224-227

S- Editor Wang J **L- Editor** Wang XL **E- Editor** Bai SH

PO Box 2345, Beijing 100023, China
www.wjgnet.com
wjg@wjgnet.com

World J Gastroenterol 2006 August 21; 12(31): 5078-5080
World Journal of Gastroenterology ISSN 1007-9327
© 2006 The WJG Press. All rights reserved.

CASE REPORT

Adverse hepatic reactions associated with calcium carbimide and disulfiram therapy: Is there still a role for these drugs?

Carmen Verge, M Isabel Lucena, Enrique López-Torres, M José Puche-García, Enrique Fraga, Manuel Romero-Gomez, Raúl J Andrade

Carmen Verge, M Isabel Lucena, Enrique López-Torres, M José Puche-García, Clinical Pharmacology Service, Virgen de la Victoria University Hospital, School of Medicine, Málaga, Spain
Enrique Fraga, Gastroenterology Service, University Hospital Reina Sofia, Córdoba, Spain
Manuel Romero-Gómez, Gastroenterology Service, University Hospital Virgen de Valme, Sevilla, Spain
Raúl J Andrade, Liver Unit, Department of Gastroenterology, University Hospital, Málaga, Spain
Supported by a research grant from the Agencia Española del Medicamento and a FIS grant, No.041688
Correspondence to: M Isabel Lucena, Department of Clinical Pharmacology, Facultad de Medicina, E-29071-Málaga, Spain. lucena@uma.es
Telephone: +34-952-131572
Received: 2006-03-06 Accepted: 2006-03-27

Abstract

Disulfiram and calcium carbimide are two alcohol deterrants widely used in alcoholism treatment, however, there exist great concerns over their safety. Reports on hepatotoxicity, mainly related to disulfiram therapy, have been published. The hepatotoxic potential of calcium carbimide is less well characterized. Here, we describe four cases of liver damage related to this therapeutic group that were submitted to a Registry of hepatotoxicity and point out the limitations that we face when prescribing these compounds. A reassessment of the role of these compounds in the management of alcohol dependence is clearly needed.

© 2006 The WJG Press. All rights reserved.

Key words: Calcium carbimide; Disulfiram; Hepatotoxicity

Verge C, Lucena MI, López-Torres E, Puche-García MJ, Fraga E, Romero-Gomez M, Andrade RJ. Adverse hepatic reactions associated with calcium carbimide and disulfiram therapy: Is there still a role for these drugs? *World J Gastroenterol* 2006; 12(31): 5078-5080

http://www.wjgnet.com/1007-9327/12/5078.asp

INTRODUCTION

Disulfiram (tetraethylthiuram disulphide), an alcohol deterrent, is widely used in alcoholism treatment. Another drug, calcium carbimide is less frequently prescribed and not on the market in many European countries, being commercialized in Australia, Canada, South Africa, Austria, Netherlands, Sweden and Spain, among others. These drugs produce physiological changes after ethanol consumption, which are sufficiently unpleasant to dissuade most alcoholics from further drinking. However, there exist great concerns over their safety. Both agents share a similar profile of adverse effects including dermatological and haematological reactions[1]. Reports on hepatotoxicity, mainly related to disulfiram therapy and leading in some cases to fulminant liver failure, have been described[2,3]. Indeed, in a recently published study by Björnsson & Ollson (2005) aimed to analyse the outcome of patients with severe drug-induced liver injury, disulfiram stood out as the second most commonly reported drug associated with mortality[4]. Conversely, the hepatotoxic potential of the less prescribed calcium carbimide is not well recognized. We describe four cases of liver damage related to this therapeutic group that were submitted to a Registry of hepatotoxicity in work since 1994. The operational structure of the Registry, data recording and case ascertainment have been summarily reported elsewhere[5]. Only cases considered drug-related by experts' clinical judgment were assessed by the Council for International Organizations of Medical Sciences scale (CIOMS scale)[6], that provides a standardized scoring system according to the type of liver injury and based on six axes of decision-taking.

CASE REPORT

A 23-year-old man (patient 1) was prescribed calcium carbimide (120 mg/d) in July 1997. He was admitted to the hospital in August 1997 because of a week's history of fatigue, dark urine, and pruritus. Physical examination showed a pruriginous exanthema, marked jaundice, without any signs of chronic liver disease although he admitted an alcohol consumption of 80-100 g/d, and laboratory findings at presentation are shown in Table 1. Serology ruled out viral causes, screening for autoantibodies was negative and findings of an abdominal ultrasonographic examination were normal. A liver biopsy showed perivenular cholestasis and mild hepatobiliary damage. Liver tests were normal on 49 d after drug withdrawal. This case yielded 11 points when applying the CIOMS scale which fell into the category of highly probable.

A 39-year-old man (patient 2) on chronic alcohol con-

Table 1 Serum concentrations at time of presentation with calcium carbimide or disulfiram induced liver damage

Patient	Bilirubinbin (mg/L)		ALT (U/L)	AP (× ULN)	Type of liver injury
	Total	Direct			
1	22.4	14.4	553	× 3.4	Cholestatic hepatitis[1]
2	0.9	0.2	59	× 0.56	PAS-positive ground glass hepatitis[1]
3	11.8	8.43	713	× 1.4	Hepatocellular
4	27.1	16.72	1288	× 1.49	Septal fibrosis and active Chronic hepatitis[1]

[1] Liver biopsy findings. Abbreviations: ALT, alanine aminotransferase (n < 40 U/L); AP, alkaline phospaatase; ULN, upper limit of normality; total bilirubin (n < 1.2 mg/dL). The ALT and AP values are these at presentation where as bilirubin values are the hightest recorded.

sumption (110 g/d) was prescribed calcium carbimide (75 mg/d) for aversion therapy in February 1995. After 25 wk of treatment he was admitted to hospital because of an increase in serum transaminases, with a ratio of alanine aspartate and alanine aminotransferase of 1.05 (62/59, UL) (Table 1). The patient admitted alcohol abstinence for the previous 6 mo and during the course of the medical treatment. Physical examination disclosed hepatomegaly without any signs of chronic liver disease. Serology tests ruled out viral causes. Screening for autoantibodies produced negative results, and the results of an abdominal ultrasonographic examination were normal. A liver biopsy elicited ground-glass inclusion bodies in the hepatocytes associated with portal inflammation and fibrosis. The patient did not attend any further appointments.

A 42-year-old woman (patient 3) was prescribed venlafaxine (75 mg/d) and alprazolam (1.5 mg/d) for depression, and calcium carbimide (75 mg/d) since December 2002. Mean daily alcohol ingestion was 120 g/d that was stopped 45 d prior to admission. The results of prior liver function tests were normal. After 75 d of treatment she was admitted to hospital because of asthenia and fever, and a diagnosis of spontaneous bacterial peritonitis was made. Physical examination showed a jaundiced patient without stigmata of chronic liver disease. Serum chemistry indicated hepatocellular injury (Table 1) without evidence of viral causes. Over the next days she developed fulminant hepatic failure unresponsive to molecular adsorbent recirculating system (MARS) therapy which was unsuccessfully instituted three times and died on d 31 after hospitalization. This case yielded 6 points when applying the CIOMS scales which fell into the category of probable.

A 48-year-old man (patient 4) was admitted to hospital in August 2003 because of a five-day history of fatigue and dark urine one month after automedication with disulfiram (1000 mg/d). He had been taking phenytoin 200 mg/d for epilepsy for 5 years. He was a heavy alcohol drinker (> 80 g/d) and although he denied alcohol intake in the previous month he was actually an active consumer. Physical examination showed marked jaundice with signs of chronic liver disease. Serum chemistry indicated hepatocellular injury (Table 1). Screening for viral disease was negative and abdominal ultrasonographic examination showed normal biliary ducts and moderate ascites. Liver biopsy revealed a chronic active hepatitis and septal fibrosis. Laboratory findings returned to previous baseline values 9 mo after drug withdrawal.

We described four cases of adverse liver reactions related to the use of calcium carbimide (3 cases) and disulfiram (1 case) because there was a temporal relationship between the administration of the drugs and the onset of hepatic abnormalities as well as between withdrawal of the drugs and improvement in liver dysfunction, the only exception being patient 3 who developed fulminant liver failure. In patient 2 de-challenge could not be ascertained because the patient was lost to follow up. Indeed, in this patient the increase in alanine aminotransferase was less than two times the upper limit of normal and since the biochemical expression of liver injury according to the International consensus criteria[7] was a biological damage, causality assessment with the CIOMS scale was not performed. However, he presented in the liver specimen the hepatocyte inclusions seen only with calcium carbimide therapy along with fibrosis and lymphocyte portal inflammation characteristic of a chronic form of liver damage[2,8].

On the other hand, causes of liver damage (viral, inmunologic and metabolic) were ruled out. In patient 4, liver biopsy ruled out a diagnosis of alcoholic hepatitis. Patient 3 was prescribed venlafaxine which has been associated with non fatal cases of hepatotoxicity[9].

The mechanism of aversion therapy-induced hepatotoxicity is presumed to be idiosyncratic. The absence of clinical features of hypersensitivity in these cases suggests that a toxic metabolite may be responsible, although an immune mechanism has been implicated in some cases[3]. Both compounds are extensively metabolized in the liver and block the oxidation of alcohol at acetaldehyde stage increasing acetaldehyde blood levels. Therefore, their administration requires the agreement of the patient to stop drinking. In our series patient 4 self administered disulfiram while continuing drinking which could have rendered him at risk of severe medical complications. Furthermore, another concern related to the use of alcohol deterrents is the possibility of drug interactions. Actually, they may inhibit the metabolism of drugs such as phenytoin (CYP 2C19) and an interaction with the antidepressant venlafaxine cannot be discarded. Coadministration of aversive therapy with other drugs (antibiotics, amitryptiline, *etc.*) could aggravate/precipitate the disulfiram-alcohol reaction. It is not yet known whether associate medications might contribute to the hepatotoxic effect of these drugs[1]. It is also important to highlight that since these compounds may be prescribed to patients with underlying alcoholic liver disease such as liver cirrhosis and alcoholic hepatitis (although they should be cautiously prescribed if at all in this population), the diagnosis of hepatotoxicity may go unrecognised.

In summary, these cases exemplify the main limitations of use that these two principal alcohol-sensitizing drugs present. Furthermore, since the efficacy of aversive therapy remains to be proved[10], a reassessment of the role of these compounds in the management of alcohol dependence is clearly needed.

REFERENCES

1 **Peachey JE**, Brien JF, Roach CA, Loomis CW. A comparative review of the pharmacological and toxicological properties of disulfiram and calcium carbimide. *J Clin Psychopharmacol* 1981; **1**: 21-26

2 **Moreno A**, Vazquez JJ, Ruizdel Arbol L, Guillen FJ, Colina F. Structural hepatic changes associated with cyanamide treatment: cholangiolar proliferation, fibrosis and cirrhosis. *Liver* 1984; **4**: 15-21

3 **Mason NA**. Disulfiram-induced hepatitis: case report and review of the literature. *DICP* 1989; **23**: 872-875

4 **Björnsson E**, Nordlinder H, Olsson R. Clinical characteristics and prognostic markers in disulfiram-induced liver injury. *J Hepatol* 2006; **44**: 791-797

5 **Andrade RJ**, Lucena MI, Fernández MC, Pelaez G, Pachkoria K, García-Ruiz E, García-Muñoz B, González-Grande R, Pizarro A, Durán JA, Jiménez M, Rodrigo L, Romero-Gomez M, Navarro JM, Planas R, Costa J, Borras A, Soler A, Salmerón J, Martin-Vivaldi R. Drug-induced liver injury: an analysis of 461 incidences submitted to the Spanish registry over a 10-year period. *Gastroenterology* 2005; **129**: 512-521

6 **Lucena MI**, Camargo R, Andrade RJ, Perez-Sanchez CJ, Sanchez De La Cuesta F. Comparison of two clinical scales for causality assessment in hepatotoxicity. *Hepatology* 2001; **33**: 123-130

7 **Bénichou C**. Criteria of drug-induced liver disorders. Report of an international consensus meeting. *J Hepatol* 1990; **11**: 272-276

8 **Bruguera M**, Parés A, Heredia D, Rodés J. Cyanamide hepatotoxicity. Incidence and clinico-pathological features. *Liver* 1987; **7**: 216-222

9 **Horsmans Y**, De Clercq M, Sempoux C. Venlafaxine-associated hepatitis. *Ann Intern Med* 1999; **130**: 944

10 **Kenna GA**, McGeary JE, Swift RM. Pharmacotherapy, pharmacogenomics, and the future of alcohol dependence treatment, part 1. *Am J Health Syst Pharm* 2004; **61**: 2272-2279

S- Editor Wang J **L- Editor** Zhu LH **E- Editor** Ma WH

PO Box 2345, Beijing 100023, China
www.wjgnet.com
wjg@wjgnet.com

World J Gastroenterol 2006 August 21; 12(31): 5081-5083
World Journal of Gastroenterology ISSN 1007-9327
© 2006 The WJG Press. All rights reserved.

CASE REPORT

Unusual prerectal location of a tailgut cyst: A case report

Si-Hyong Jang, Ki-Seok Jang, Young-Soo Song, Kyueng-Whan Min, Hong-Xiu Han, Kyeong-Geun Lee, Seung-Sam Paik

Si-Hyong Jang, Ki-Seok Jang, Young-Soo Song, Kyueng-Whan Min, Hong-Xiu Han, Kyeong-Geun Lee, Seung-Sam Paik, Departments of Pathology and Surgery, College of Medicine, Hanyang University, Seoul, Korea
Correspondence to: Seung-Sam Paik, MD, Department of Pathology, College of Medicine, Hanyang University, 17 Haengdang-Dong, Seongdong-Gu, Seoul 133-792, Korea. sspaik@hanyang.ac.kr
Telephone: +82-2-22908252 Fax: +82-2-22967502
Received: 2006-02-03 Accepted: 2006-03-13

Abstract

Tailgut cyst is a rare congenital cystic lesion arising from the remnants of the embryonic postanal gut. It occurs exclusively within the retrorectal space and rarely in the perirenal area or in the subcutaneous tissue. A prerectal and retrovesical location of tailgut cyst is extremely rare. To the best of our knowledge, only three cases have been reported in the English literature. We experienced an unusual case of tailgut cyst developed in the prerectal and retrovesical space in a 14-year-old boy. Abdominal computed tomography demonstrated a prerectal cyst which was located at the anterolateral portion to the rectum. The cyst contained yellowish inspissated mucoid material. Microscopically, the cyst was lined by squamous, columnar, cuboidal and transitional epithelia and the wall was fibrotic with dispersed smooth muscle cells. Although tailgut cyst arising in prerectal area is extremely rare, its possibility should be considered in differential diagnosis of a prerectal and retrovesical cystic mass.

© 2006 The WJG Press. All rights reserved.

Key words: Tailgut cyst; Prerectal mass; Retrovesical mass; Developmental cyst

Jang SH, Jang KS, Song YS, Min KW, Han HX, Lee KG, Paik SS. Unusual prerectal location of a tailgut cyst: A case report. *World J Gastroenterol* 2006; 12(31): 5081-5083

http://www.wjgnet.com/1007-9327/12/5081.asp

INTRODUCTION

Tailgut cyst, known as a retrorectal cystic hamartoma, is a rare congenital multicystic lesion arising from the remnants of the embryonic postanal gut[1-3]. It almost exclusively occurs within the retrorectal or presacral space[4] and rarely in the perirenal area[2,3,5], the subcutaneous tissue in the anorectal region[6-9] and anterior to the rectum[4,10]. The prerectal location of a tailgut cyst is extremely rare. To the best of our knowledge, only three cases have been reported in the English literature. Here we report an additional case of tailgut cyst arising in the prerectal and retrovesical space and review the relevant literature.

CASE REPORT

A 14-year-old boy presented with abdominal pain and dysuria for 2 d. Physical examination revealed suprapubic pain and tenderness. Routine laboratory tests including a complete blood count, electrolytes, and routine urine analysis were within normal limits. Abdominal computerized tomography demonstrated a well-demarcated oval-shaped cystic mass which was located at the prerectal and retrovesical space (Figure 1). He underwent explorative laparotomy for the definite diagnosis and treatment. Intra-operative finding showed that the cyst did not communicate with the prostate, bladder or rectum. Complete mass excision was performed. Macroscopic examination revealed an unilocular cyst measured 5 cm × 3 cm in cross diameter. The cyst showed a thickened fibrous wall and focal adhesion to the adjacent fibroadipose tissue. The cyst contained yellowish inspissated mucoid material. Microscopically, the cyst showed a variety of the lining epithelia including glandular, cuboidal, transitional and squamous epithelia (Figure 2). The cyst wall contained disorganized bundles of smooth muscle cells. The underlying stroma showed mild infiltration of chronic inflammatory cells. On immunohistochemical staining, prostate specific antigen (PSA) and neuroendocrine markers including chromogranin A were negative in the lining of the epithelial cells. The patient's recovery remained uneventful for 10 mo postoperation.

DISCUSSION

Tailgut cyst or retrorectal hamartoma, is a rare congenital multicystic lesion and is believed to originate from the remnant of the tailgut which is a primitive gut temporarily present at the caudal portion of the embryo[2,3,8]. During its development the embryo possesses a true tail, reaching its largest diameter on the 35th d of gestation. The anus develops above the tail on the 56th d of gestation, by which time the latter has completely regressed. Remnants of the tailgut or neuroenteric cord may be the origin of tailgut

Figure 1 Abdominal computed tomography revealing an oval-shaped cyst with a thickened wall in anterolateral to the rectum.

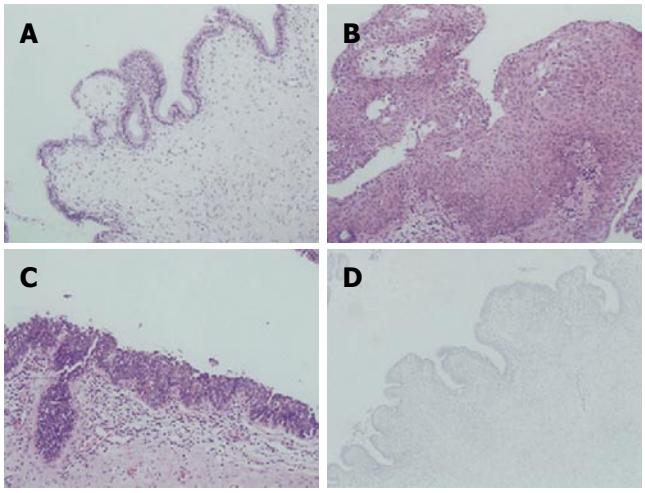

Figure 2 Microscopically, the cyst wall showing a variety of lining epithelia including tall columnar or cuboidal (**A**), squamous (**B**), and transitional (**C**) epithelium (HE, x 200), the underlying stroma showing a mild infiltrate of chronic inflammatory cells, immunohistochemical staining showing negative prostate specific antigen in the lining of epithelial cells (**D**) (PAP, x 200).

cysts[3,11].

Tailgut cyst can affect at any age but predominantly middle aged women. The female to male ratio is about 3:1. Half of them are asymptomatic and are frequently found on routine physical examination[1,4]. Symptomatic patients present with abdominal pain, rectal bleeding, and rectal fullness[2]. Complete surgical excision is necessary for accurate diagnosis and treatment, and prevents complications of the tailgut cyst, including infection, recurrence, and malignant transformation[1]. Tailgut cyst is usually a well-circumscribed, soft, and multicystic or multilocated mass with adherent surrounding fibroadipose tissue. The varying-sized cysts contain clear serous or translucent mucoid fluids. Microscopically, the cysts are lined by a wide variety of epithelia varying from cyst to cyst, or even within the same cyst. Epithelia can be divided into the following types, such as the stratified squamous type, transitional and cuboidal type, stratified columnar type, ciliated pseudostratified columnar and gastric type. In most cases the cyst wall contains well-formed disorganized focal bundles of bland smooth muscle cells[2,3].

Tailgut cyst occurs almost exclusively in the retrorectal or presacral space. Infrequently, the cysts extend from the presacral space to involve the rectal wall and rarely extend laterally from the mid-line or into the postsacral space or lateral and anterior to the rectum[4], but occur rarely in the perirenal area, the subcutaneous tissue in the anorectal region and anterior to the rectum[2-10]. The prerectal location of tailgut cyst was noted in our patient. To the best of our knowledge, only three cases have been reported in the English literature[4,10].

The main differential diagnoses of the prerectal tailgut cyst include the utricle cyst in the prostate, the rectal duplication and the simple cyst in the seminal vesicle. The prostatic utricle cyst, known as mullerian duct remnant, is a midline cyst of the prostate and also occurs in the prerectal or retrovesical area. Histologically, the cyst is lined with stratified columnar or cuboidal epithelium and continuous with the utricular wall. Immunohistochemically, the cyst lining epithelial cells show immunoreactivity for PSA and the neuroendocrine cells show immunoreactivity for chromogranin A[12]. Duplication cyst is lined by epithelium similar to that of the gastrointestinal and respiratory tracts. The epithelium simulates normal mucosa of the gut. The main distinctive feature is a well-formed muscular wall overlying two layers of muscular bundles containing a nerve plexus[2,3]. The simple cyst in the seminal vesicle is an unilocular cystic lesion located at lateral to the midline in the retrovesical area. The cyst is lined with a cuboidal or flattened epithelium with a fibrous wall of variable thickness. Characteristically, the fluid within the cyst contains sperm or sperm fragments[13].

In conclusion, we report an unusual case of tailgut cyst arising in prerectal and retrovesical area in a 14-year-old boy. Although tailgut cyst arising in prerectal area is extremely rare, its possibility should be considered in differential diagnosis of a prerectal and retrovesical cystic mass.

REFERENCES

1 **Killingsworth C**, Gadacz TR. Tailgut cyst (retrorectal cystic hamartoma): report of a case and review of the literature. *Am Surg* 2005; **71**: 666-673
2 **Sung MT**, Ko SF, Niu CK, Hsieh CS, Huang HY. Perirenal tailgut cyst (cystic hamartoma). *J Pediatr Surg* 2003; **38**: 1404-1406
3 **Kang JW**, Kim SH, Kim KW, Moon SK, Kim CJ, Chi JG. Unusual perirenal location of a tailgut cyst. *Korean J Radiol* 2002; **3**: 267-270
4 **Hjermstad BM**, Helwig EB. Tailgut cysts. Report of 53 cases. *Am J Clin Pathol* 1988; **89**: 139-147
5 **Mills SE**, Walker AN, Stallings RG, Allen MS Jr. Retrorectal cystic hamartoma. Report of three cases, including one with a perirenal component. *Arch Pathol Lab Med* 1984; **108**: 737-740
6 **Sidoni A**, Bucciarelli E. Ciliated cyst of the perineal skin. *Am J Dermatopathol* 1997; **19**: 93-96
7 **Rafindadi AH**, Shehu SM, Ameh EA. Retrorectal cystic harmatoma (tailgut cyst) in an infant: case report. *East Afr Med J* 1998; **75**: 726-727
8 **Murao K**, Fukui Y, Numoto S, Urano Y. Tailgut cyst as a subcutaneous tumor at the coccygeal region. *Am J Dermatopathol* 2003; **25**: 275-277
9 **Song DE**, Park JK, Hur B, Ro JY. Carcinoid tumor arising in a tailgut cyst of the anorectal junction with distant metastasis: a case report and review of the literature. *Arch Pathol Lab Med* 2004; **128**: 578-580
10 **Gips M**, Melki Y, Wolloch Y. Cysts of the tailgut. Two cases. *Eur J Surg* 1994; **160**: 459-460

11 **Levert LM**, Van Rooyen W, Van Den Bergen HA. Cysts of the tailgut. *Eur J Surg* 1996; **162**: 149-152
12 **Kato H**, Komiyama I, Maejima T, Nishizawa O. Histopathological study of the müllerian duct remnant: clarification of disease categories and terminology. *J Urol* 2002; **167**: 133-136
13 **Petersen RO**. Urologic pathology, 2nd ed. Philadelphia: Lippincott, 1992: 648-651

S- Editor Wang J **L- Editor** Wang XL **E- Editor** Ma N

PO Box 2345, Beijing 100023, China
www.wjgnet.com
wjg@wjgnet.com

World J Gastroenterol 2006 August 21; 12(31): 5084-5086
World Journal of Gastroenterology ISSN 1007-9327
© 2006 The WJG Press. All rights reserved.

CASE REPORT

Cytomegalovirus ileitis in an immunocompetent elderly adult

Kum Hei Ryu, Sun Young Yi

Kum Hei Ryu, Sun Young Yi, Department of Internal Medicine, Ewha Womans University College of Medicine, Seoul, Korea
Correspondence to: Kum Hei Ryu, Department of Internal Medicine, Ewha Womans University College of Medicine, Seoul, Korea. kumheiryu@hanmail.net
Telephone: +82-2-26502796 Fax: +82-2-26552076
Received: 2006-05-20 Accepted: 2006-06-15

Abstract

Cytomegalovirus enteritis is most usually associated with patients positive for human immunodeficiency virus or immunosuppressed transplant patients. The gastrointestinal tract may be affected anywhere from the esophagus to the colon, but the small bowel involvement is rare. We report a case of cytomegalovirus ileitis in an immunocompetent adult, which was confirmed by histopathologic findings through colonoscopic biopsy.

© 2006 The WJG Press. All rights reserved.

Key words: Cytomegalovirus; Ileitis; Immunocompetent

Ryu KH, Yi SY. Cytomegalovirus ileitis in an immunocompetent elderly adult. *World J Gastroenterol* 2006; 12(31): 5084-5086

http://www.wjgnet.com/1007-9327/12/5084.asp

INTRODUCTION

Cytomegalovirus (CMV) is a β-group herpes virus and produces latent infection like other herpes viruses. Clinically significant CMV infection usually occurs in patients with immunosuppression, transplantations and acquired immune deficiency syndrome[1]. In immunocompetent subjects, active infection is apparently rare, and the virus exhibits relatively low pathogenicity[2]. We here describe a case of CMV ileitis without colon involvement in an immunocompetent subject.

CASE REPORT

A 63-year-old woman, with a one-day history of epigastric pain, was hospitalized at Ewha Womans University Hospital on Feb 16, 2006. She is a non-smoker and denied any medication or drug abuse.

On physical examination, the patient appeared to be acutely ill, with a blood pressure of 130/80 mmHg, heart rate of 70 beats/min, respiratory rate of 20 breaths/min, and temperature of 37℃. The abdominal examination was notable for the presence of pain on the epigastric and the right lower quadrant areas with mild guarding but bowel sounds were normal. Laboratory values on admission were in normal range except elevated C-reactive protein.

The chest X-ray was normal. Abdominal computed tomography showed layering appearance of bowel wall and luminal dilatation from the distal jejunum to the pelvic ileal loop (Figure 1). The colonoscopy revealed scattered regions of geographic deep ulcerations and hyperemic edematous mucosa upon a background of normal mucosa in terminal ileum (Figure 2). We made differential diagnosis including nonspecific ileitis, Crohn's disease, tuberculosis induced ileitis and ischemic ileitis. Histological examination showed mild inflammation with lymphocytic infiltration without specific feature.

After the initial clinical and laboratory evaluation, the patient began therapy with intravenous antibiotics and fluids for the most probable diagnosis of nonspecific ileitis. During the admission, her clinical condition improved, and abdominal pain disappeared. Two weeks later, the follow up colonoscopy was performed. The ulcerations and hyperemic edematous lesions, which were previously noted on the terminal ileum, were much improved (Figure 3). The histological findings showed intranuclear and intracytoplasmic inclusions. Immunohistochemical stain for CMV showed scattered positive cells at the ulcer base (Figure 4). She was discharged without medication on March 7, 2006.

DISCUSSION

CMV is a member of the herpes virus family and is a prevalent pathogen, with 40 to 90 percent of the general population showing prior exposure by serology[3]. Human CMV infection can be seen at all stages of life but most often affects those who are immunosuppressed and can commonly cause retinitis, pneumonitis or enteritis[4]. Most primary CMV infections in immunologically healthy adults do not cause symptoms or are associated with a mild mononucleosis like syndrome[5].

Gastrointestinal involvement in CMV infection is well known among immunocompromised patients. It is usually seen in advanced acquired immune deficiency syndrome with CD4 lymphocyte count less than 50 cells/mm^3 and among transplant recipients as a reactivation of latent infection or rarely during primary infection[6]. CMV colitis in immunocompetent individuals has been reported mainly in older patients, particularly those with other

Figure 1 Abdominal computed tomography on admission revealed layering appearance of bowel wall and luminal dilatation from the distal jejunum to the pelvic ileal loop.

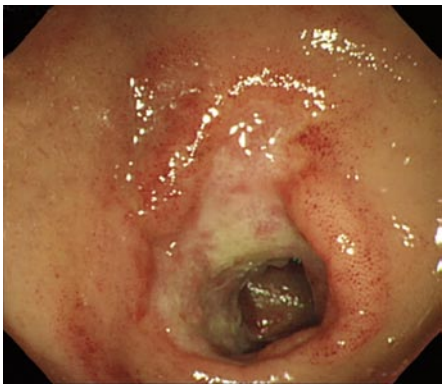

Figure 2 Colonoscopy, performed on admission, revealed scattered regions of geographic ulcers and hyperemic edematous mucosa on the terminal ileum.

comorbidities, and is mostly community-acquired. This is likely a reflection of a weakened immune system, as a consequence of aging. Age-related dysfunctions of B and T cell lymphocytes, impaired cytokine, and perturbation of mucosal immunity are thought to contribute to a relative immunodeficiency in the elderly, predisposing them to various infectious and inflammatory diseases[7].

Gastrointestinal tract may be affected anywhere from the mouth to the anus with the esophagus and colon being most common and small bowel relatively rare. The clinical manifestations of gastrointestinal CMV infection include gastrointestinal bleeding, abdominal pain, vomiting and diarrhea[1,8]. Endoscopic findings of gastrointestinal CMV disease include erosions, ulceration and mucosal hemorrhage. The prototypical ulceration has a well-defined punched out appearance. The pathogenesis of CMV-induced ulceration is thought to involve ischemic mucosal injury secondary to infection of the vascular endothelial cells[8,9].

CMV enteritis is remarkable for its ability to mimic many diseases, such as colitis caused by *C. diffile*, ischemia, malignant diseases of the colon and inflammatory bowel diseases. The diagnosis is made by the demonstration of the presence of CMV by routine histologic examination, culture or staining for CMV antigen or DNA[10,11].

The primary therapy for clinically significant CMV

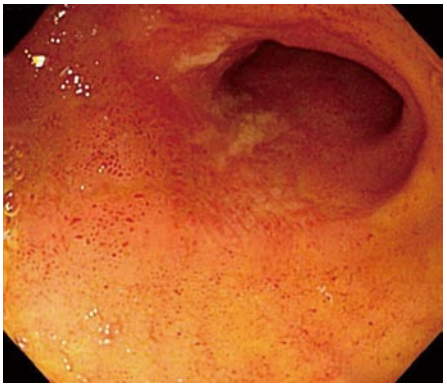

Figure 3 Follow up colonoscopy was performed. The previously noted ulcers and hyperemic edematous lesion were improved.

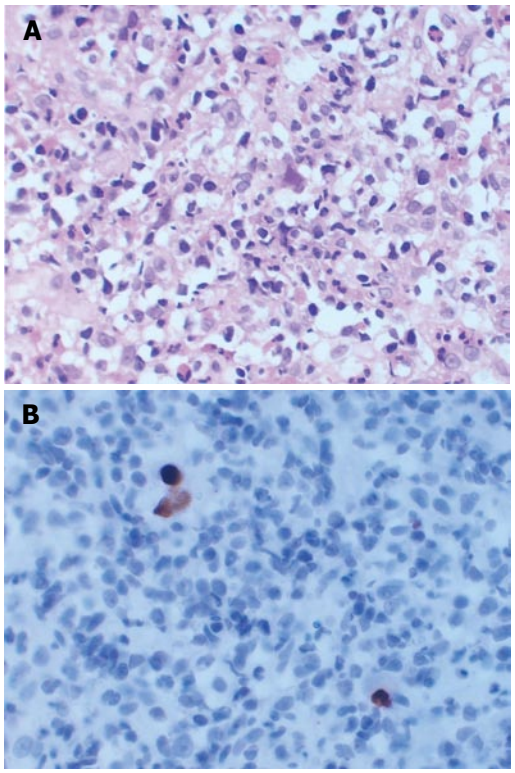

Figure 4 Pathologic findings. **A**: Enlargement of infected cells and intranuclear inclusions were noted (HE stain, × 100); **B**: Immunohistochemical stain for CMV showed scattered positive cells.

infection is use of the antiviral drugs such as ganciclovir and foscarnet[6,12]. Galiastsatos *et al*[7] reported that spontaneous resolution occurred mainly in patients younger than 55 years of age, with no other comorbidities. They suggested that young, otherwise healthy, well-selected patients can improve without the need for antiviral therapy but immunocompromised patients and patients older than 55 years of age with comorbidities need antiviral therapy. Sakamoto *et al*[13] thought that the administration of the antiviral agents is not always necessary for immunocompetent individuals.

In conclusion, we report a case of CMV ilieitis not involving colon in an immunocompetent elderly adult who recovered without antiviral therapy.

REFERENCES

1 **Cheung AN**, Ng IO. Cytomegalovirus infection of the gastrointestinal tract in non-AIDS patients. *Am J Gastroenterol* 1993; **88**: 1882-1886

2 **Oku T**, Maeda M, Waga E, Wada Y, Nagamachi Y, Fujita M, Suzuki Y, Nagashima K, Niitsu Y. Cytomegalovirus cholangitis and pancreatitis in an immunocompetent patient. *J Gastroenterol* 2005; **40**: 987-992

3 **Emery VC**. Cytomegalovirus and the aging population. *Drugs Aging* 2001; **18**: 927-933

4 **Page MJ**, Dreese JC, Poritz LS, Koltun WA. Cytomegalovirus enteritis: a highly lethal condition requiring early detection and intervention. *Dis Colon Rectum* 1998; **41**: 619-623

5 **Taylor GH**. Cytomegalovirus. *Am Fam Physician* 2003; **67**: 519-524

6 **Klauber E**, Briski LE, Khatib R. Cytomegalovirus colitis in the immunocompetent host: an overview. *Scand J Infect Dis* 1998; **30**: 559-564

7 **Galiatsatos P**, Shrier I, Lamoureux E, Szilagyi A. Meta-analysis of outcome of cytomegalovirus colitis in immunocompetent hosts. *Dig Dis Sci* 2005; **50**: 609-616

8 **Taniwaki S**, Kataoka M, Tanaka H, Mizuno Y, Hirose M. Multiple ulcers of the ileum due to Cytomegalovirus infection in a patient who showed no evidence of an immunocompromised state. *J Gastroenterol* 1997; **32**: 548-552

9 **Keates J**, Lagahee S, Crilley P, Haber M, Kowalski T. CMV enteritis causing segmental ischemia and massive intestinal hemorrhage. *Gastrointest Endosc* 2001; **53**: 355-359

10 **Siegal DS**, Hamid N, Cunha BA. Cytomegalovirus colitis mimicking ischemic colitis in an immunocompetent host. *Heart Lung* 2005; **34**: 291-294

11 **Caroline DF**, Hilpert PL, Russin VL. CMV colitis mimicking Crohn's disease in a patient with acquired immune deficiency syndrome (AIDS). *Can Assoc Radiol J* 1987; **38**: 227-228

12 **Karakozis S**, Gongora E, Caceres M, Brun E, Cook JW. Life-threatening cytomegalovirus colitis in the immunocompetent patient: report of a case and review of the literature. *Dis Colon Rectum* 2001; **44**: 1716-1720

13 **Sakamoto I**, Shirai T, Kamide T, Igarashi M, Koike J, Ito A, Takagi A, Miwa T, Kajiwara H. Cytomegalovirus enterocolitis in an immunocompetent individual. *J Clin Gastroenterol* 2002; **34**: 243-246

S- Editor Wang J **L- Editor** Zhu LH **E- Editor** Bi L

PO Box 2345, Beijing 100023, China
www.wjgnet.com
wjg@wjgnet.com

World J Gastroenterol 2006 August 21; 12(31): 5087-5090
World Journal of Gastroenterology ISSN 1007-9327
© 2006 The WJG Press. All rights reserved.

CASE REPORT

Pseudoachalasia in a patient after truncal vagotomy surgery successfully treated by subsequent pneumatic dilations

Seng-Kee Chuah, Chung-Mou Kuo, Keng-Liang Wu, Chi-Sin Changchien, Tsung-Hui Hu, Chi-Chih Wang, Yi-Chun Chiu, Yeh-Pin Chou, Pin-I Hsu, King-Wah Chiu, Chung-Huang Kuo, Shue-Shian Chiou, Chuan-Mo Lee

Seng-Kee Chuah, Chung-Mou Kuo, Keng-Liang Wu, Chi-Sin Changchien, Tsung-Hui Hu, Yi-Chun Chiu, King-Wah Chiu, Chung-Huang Kuo, Shue-Shian Chiou, Chuan-Mo Lee, Gastrointestinal Motility Unit, Division of Hepatogastroenterology, Department of Internal Medicine, Chang Gung Memorial Hospital, Chang Gung University, College of Medicine, Kaohsiung, Taiwan, China
Chi-Chih Wang, Department of Surgery, Chang Gung Memorial Hospital, Chang Gung University, College of Medicine, Kaohsiung, Taiwan, China
Pin-I Hsu, Kaohsiung Veteran General Hospital, Taiwan, China
Correspondence to: Chi-Sin Changchien, MD, Division of Hepatogastroenterology, Department of Internal Medicine, Chang Gung Memorial Hospital, Kaoshiung, 123, Ta-Pei Road, Niao-sung Hsiang, Kaohsiung Hsien, ROC 833, Taiwan, China. paulchuah@hotmail.com
Telephone: +886-7-7317123-8301 Fax: +886-7-7322402
Received: 2006-04-28 Accepted: 2006-06-15

Abstract

Pseudoachalasia is a difficult condition for the clinician to differentiate from idiopathic achalasia even by manometry, radiological studies or endoscopy. Its etiology is usually associated with tumors. In most cases, the diagnosis is made after surgical explorations. The proposed pathogenesis of the disease is considered as mechanical obstruction of the distal esophagus or infiltration of the malignancy that affects the inhibitory neurons of the meyenteric plexus in the majority of cases. Surgery has been reported as a cause of pseudoachalasia. We report a 70-year-old man who suffered from deglutination disorder caused by pseudo-achalasia after truncal vagotomy. The patient was symptom-free after a nine-year follow-up and complete recovery of esophageal motility status from pseudoachalasia after pneumatic dilations. We also reviewed the literature of pseudoachalasia.

© 2006 The WJG Press. All rights reserved.

Key words: Truncal vagotomy; Pseudo-achalasia; Deglutination disorder; Pneumatic dilations; Sustain reversed esophageal motility

Chuah SK, Kuo CM, Wu KL, Changchien CS, Hu TH, Wang CC, Chiu YC, Chou YP, Hsu PI, Chiu KW, Kuo CH, Chiou SS, Lee CM. Pseudoachalasia in a patient after truncal vagotomy surgery successfully treated by subsequent pneumatic dilations. *World J Gastroenterol* 2006; 12(31): 5087-5090

http://www.wjgnet.com/1007-9327/12/5087.asp

INTRODUCTION

Pseudoachalasia is a disease entity usually associated with tumors causing obstruction at the gastroesophageal junction and producing abnormal esophageal motility mimicking an idiopathic achalasia[1]. Idiopathic achalasia is a motility disorder of the esophagus characterized by aperistalsis and failure of the lower esophageal relaxation, resulting in symptoms such as dysphagia, regurgitation, chest pain and weight loss. The pathogenesis of idiopathic achalasia is due to the selective loss of inhibitory neuron of the myenteric plexus which produces vasoactive intestinal polypeptide (VIP), nitric oxide and inflammatory infiltration and is responsible for the unopposed excitation of lower esophageal sphincter (LES)[2-4], thereby causing dysfunction or failure of the LES relaxation in response to each swallow[4,5]. The pathogenesis of pseudoachalasia is different from idiopathic achalasia. In pseudoachalasia, the proposed pathogenesis is considered as a mechanical obstruction of the distal esophagus or an infiltration of the malignancy that affects the inhibitory neurons of the meyenteric plexus. Endoscopy and radiologic tests are often important in distinguishing between them, although the eventual diagnosis is made only by surgical explorations in the most cases. These both types of achalasia share the same manometric phenomenon of aperistalsis of the esophageal body and incomplete LES relaxation. However, one report suggested that patients with achalasia have autonomic nerve dysfunction in the vagal nerve outside the esophagus[6]. Trauma to the gastroesophageal junction may potentially damage the vagus nerve, thereby leading to secondary achalasia. Most case reports on pseudoachalasia were tumor related, but implicated vagal nerve injury following surgery as a cause of achalasia[8-10] still occurred. We report herein a reversible pseudoachalasia following the truncal vagotomy for pyloric obstruction, which was successfully treated by pneumatic dilations.

CASE REPORT

A 70-year-old male, suffered from repeated peptic ulcer bleeding for at least 10 years, developed progressive symptoms of post-prandial vomiting in October 1996.

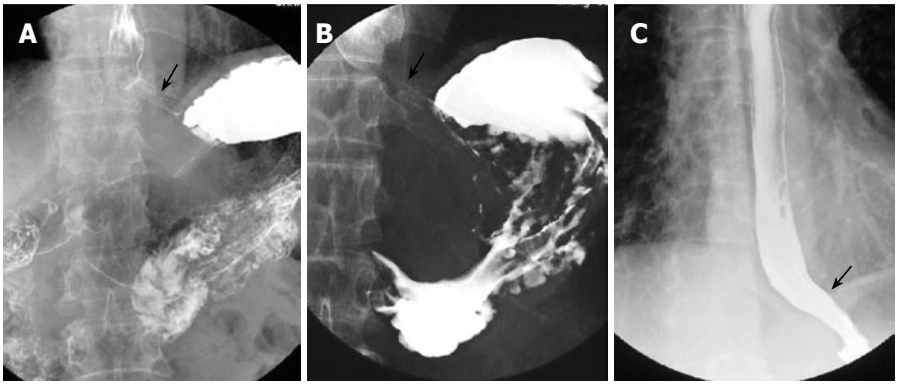

Figure 1 **A**: Barium esophagography and upper gastrointestinal series showing an intact gastroesophageal junction; **B**: dilated distal esophageal lumen with food retention and narrowing of gastroesophageal junction after truncal vagotomy; **C**: barium esophagography showing a non-dilated esophageal lumen with smooth passage of contrast medium through gastroesophageal junction after pneumodilations.

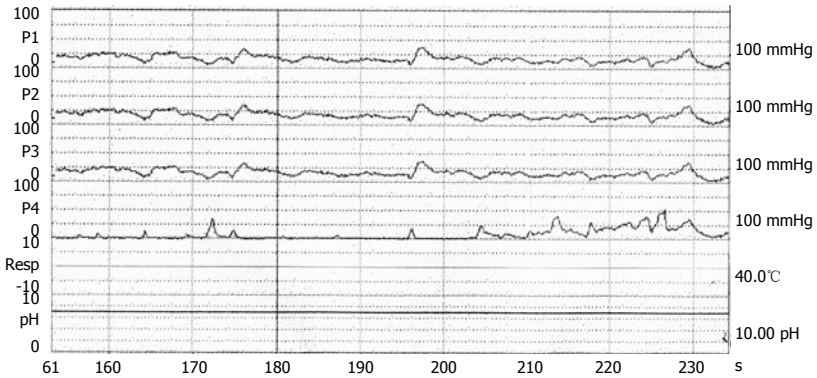

Figure 2 Confirmation of achalasia by manometric findings of esophageal aperistalsis and incomplete relaxation of the lower esophageal sphincter during wet swallowing.

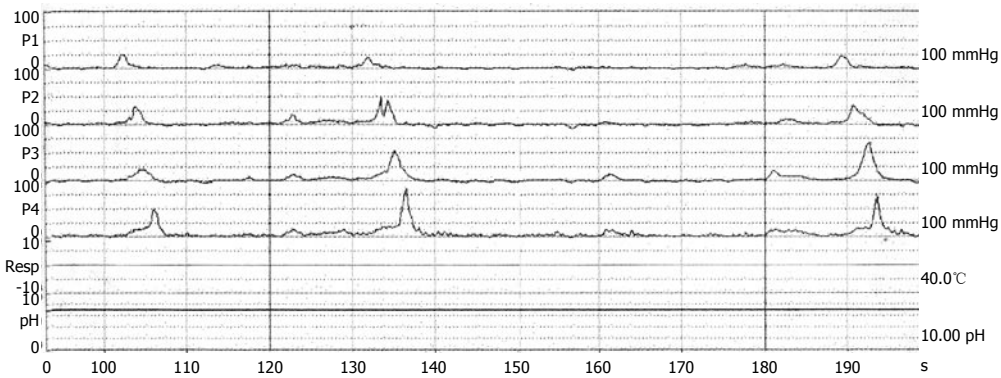

Figure 3 Manomteric studies showing restoration of esophageal motility with normal peristalsis as a healthy subject after dilations.

A barium esophagogram and upper gastrointestinal series demonstrated an intact gastroesophageal junction (Figure 1A) and good esophageal peristalsis, but deformed gastric antrum and a deep ulceration. Malignancy was excluded by endoscopy biopsy. Under the condition of pyloric obstruction, he received a truncal vagotomy and pyloroplasty surgery. The month following surgery, the patient developed dysphagia, regurgitation of food. Endoscopy revealed food retention in the esophageal lumen and a tight gastroesophageal junction, thereby suggesting an achalasia. Barium esophagography showed a dilated distal esophageal lumen with food retention and narrowing of gastroesophageal junction (Figure 1B). Achalasia was confirmed using manometric findings of esophageal aperistalsis and incomplete relaxation of the lower esophageal sphincter during wet swallowing (Figure 2). Although the residual pressure was about 12 mmHg but the basal LES pressure was only about 25 mmHg. Achalasia caused by tumors was excluded by computed tomography and endoscopic ultrasonography. The patient received two episodes of pneumatic dilatation. The symptoms gradually resolved within 4 mo after dilatation and the manometric studies showed restoration of esophageal peristalsis and normal swallowing relaxation (Figure 3). Barium esophagography showed a non-dilated esophageal lumen with smooth passage of contrast medium through gastroesophageal junction (Figure 1C). After nine years, the patient still remains symptom-free with a normal esophageal motility studies.

DISCUSSION

Pseudoachalasia or secondary achalasia is a motility disorder of the esophagus, and usually cannot be distinguished from primary achalasia[1]. Approximately 2-4% of achalasia patients who fulfill the manometric criteria may develop in a malignant disease[11]. The clinical spectrum of psudoachalasia is almost the same

as idiopathic achalasia; both have progressive dysphagia, retrosternal pain, food regurgitation and weight loss. While the radiological findings show a dilated esophagus with "beak-like" distal end, there is aperistalsis of the esophageal body with an incomplete or non-relaxing lower esophageal sphincter on manometry studies in both groups of patients. Therefore, it is difficult for the clinician to distinguish pseudoachalasia from idiopathic achalasia. Pseudoachalasia has many etiologies, including tumor. Most of the patients with pseudoachalasia reported in the literature suffered from a primary or metastatic malignancy around the esophagogastric junction. Some are from benign diseases, such as pancreatic pseudocysts, mesenchymal tumors of the esophagus and mediastinal fibrosis[11-15]. In rare instances, pseudoachalasia may be a complication of various surgeries, the majority being anti-reflux procedures, gastric banding and gastrectomy[9,16,17]. Our case resulted as a complication from truncal vagotomy for pyloric obstrction.

The mechanisms of esophageal motor dysfunction in pseudoachalasia have been proposed as follows[17]: (1) circumferential obstruction of the lower esophagus and/or LES; (2) infiltration of inhibitory neurons of the esophageal myenteric plexus by tumor cells; (3) neuronal degeneration distant from the primary tumor site with reduction in ganglion cells in the dorsal nucleus of the vagal nerve or in the vagal nerve itself; and (4) an interaction of tumor factors with the esophageal neuronal plexus without a direct infiltration of the esophagogastric junction (paraneoplastic).

Achalasia has been described following fundoplication and was attributed to vagal nerve damage during surgery[18]. In patients who are found to have an achalasia-type motor dysfunction following anti-reflux surgery, Poulin *et al*[7] suggested three additional explanations. In type 1, primary achalasia had been misdiagnosed, and dysphagia became obvious only after surgery. An alternative explanation for this type of achalasia may be the assumption of Spechler *et al*[19] that achalasia may occasionally develop from underlying gastroesophageal reflux disease. Type 2 may be due to extensive development of scar tissue and/or an overly tight fundic wrap. In most instances, the motor abnormality disappears following dilation therapy or reconstruction of the fundoplication, as in our patient. Finally, in type 3, achalasia follows anti-reflux surgery after a more prolonged interval. In contrast to type 2, there is no stenosis or fibrosis of the esophagus or the periesophageal tissue, and myotomy is always an effective therapeutic strategy.

Shah *et al*[20] reported that 25% of patients diagnosed with achalasia had a history of operative or non-operative trauma to the chest and/or upper gastrointestinal tract, compared with 9.5% of patients with dysphagia and normal manometry, thereby suggesting that, in some cases, operative and non-operative trauma may result in vagal disruption and lead to neuropathic dysfunction with the resultant development of achalasia[20]. The mechanism of damage may not be the same as vagal transaction. Vagal efferent fibers, with their cell bodies in the dorsal motor nucleus of the vagus nerve, have a crucial role in initiating and modulating esophageal peristalsis and lower esophageal sphincter relaxation. Pathological analyses of operative and postmortem specimens from patients with achalasia have demonstrated abnormalities of both extrinsic and intrinsic innervations of the esophagus and LES. The majority of studies revealed a loss of ganglion cells from the dorsal motor nucleus of the vagus and demyelination of the vagal afferent fibers suggesting denervation[21,22].

Neural control of the LES includes cholinergic and noncholinergic (or nonadrenergic) inhibitory pathways involving the presentation of nitric oxide, acetylcholine, and VIP. Nitric oxide plays an important role in mediating LES relaxation. Nitrergic neurons are present in the dorsal motor nucleus of the vagus, as the source of preganglionic motor neurons to the LES[23]. Experimental inhibition of nitric oxide may produce a picture mimicking achalasia on manometry. An alternative explanation for post-traumatic achalasia may involve nitrergic pathways. By some mechanisms, trauma may impair the generation of nitric oxide, resulting in decreased inhibition of the lower esophageal sphincter and an abnormality in sequential relaxation of the body of the esophagus[24].

Pneumatic dilation provides a safe, effective and relatively inexpensive option for achalasia treatment[25,26]. The major adverse event caused by pneumatic dilations is esophageal perforation, with a 2%-6% cumulative rate[25-27]. Less common complications are intramural hematoma, diverticula at gastric cardia, mucosal tears, reflux esophagitis, prolonged post-procedure chest pain, hematemesis without change in hematocrit, fever and angina[25,26,28]. Pneumatic dilation for a malignancy-induced pseudoachalasia stenosis not only provides an ineffective treatment, but also delays adequate therapy of the underlying disorder. Surgery is the best treatment modality but the use of metallic stents is another therapeutic option for the unresectable ones[29].However, pneumatic dilation may improve the pseudoachalasia caused by benign etiology and may provide a complete recovery from stenosis as in our patient.

In summary, implicated vagal nerve injury following surgery can cause pseudoachalasia. The motor normality usually resolved following a therapeutic procedure, such as pneumatic dilation on the gastroesophageal junction. Further studies on comparing esophageal manometry and vagal integrity before and after surgery are required.

REFERENCES

1 **Gockel I**, Eckardt VF, Schmitt T, Junginger T. Pseudoachalasia: a case series and analysis of the literature. *Scand J Gastroenterol* 2005; **40**: 378-385

2 **Champion JK**, Delise N, Hunt T. Myenteric plexus in spastic motility disorders. *J Gastrointest Surg* 2001; **5**: 514-516

3 **Park W**, Vaezi MF. Etiology and pathogenesis of achalasia: the current understanding. *Am J Gastroenterol* 2005; **100**: 1404-1414

4 **Paterson WG**. Etiology and pathogenesis of achalasia. *Gastrointest Endosc Clin N Am* 2001; **11**: 249-266, vi

5 **Hashemi N**, Banwait KS, DiMarino AJ, Cohen S. Manometric evaluation of achalasia in the elderly. *Aliment Pharmacol Ther* 2005; **21**: 431-434

6 **Ohlsson B**, Ekberg O, Sundkvist G. Achalasia: a vagal disease. *Scand J Gastroenterol* 2004; **39**: 527-530

7 **Poulin EC**, Diamant NE, Kortan P, Seshadri PA, Schlachta CM, Mamazza J. Achalasia developing years after surgery

for reflux disease: case reports, laparoscopic treatment, and review of achalasia syndromes following antireflux surgery. *J Gastrointest Surg* 2000; **4**: 626-631
8 **Duntemann TJ**, Dresner DM. Achalasia-like syndrome presenting after highly selective vagotomy. *Dig Dis Sci* 1995; **40**: 2081-2083
9 **Stylopoulos N**, Bunker CJ, Rattner DW. Development of achalasia secondary to laparoscopic Nissen fundoplication. *J Gastrointest Surg* 2002; **6**: 368-376; discussion 377-378
10 **Tracey JP**, Traube M. Difficulties in the diagnosis of pseudoachalasia. *Am J Gastroenterol* 1994; **89**: 2014-2018
11 **Liu W**, Fackler W, Rice TW, Richter JE, Achkar E, Goldblum JR. The pathogenesis of pseudoachalasia: a clinicopathologic study of 13 cases of a rare entity. *Am J Surg Pathol* 2002; **26**: 784-788
12 **Campos CT**, Ellis FH Jr, LoCicero J 3rd. Pseudoachalasia: a report of two cases with comments on possible causes and diagnosis. *Dis Esophagus* 1997; **10**: 220-224
13 **el-Newihi HM**, Dellinger GW, Mihas AA, Achord JL. Gastric cancer and pernicious anemia appearing as pseudoachalasia. *South Med J* 1996; **89**: 906-910
14 **Ponce J**, Garrigues V, Nos P, García E, Siles S, del Val A. [Esophageal pseudoachalasia related to a neoplasm]. *Rev Esp Enferm Dig* 1993; **83**: 1-4
15 **Song CW**, Chun HJ, Kim CD, Ryu HS, Hyun JH, Kahrilas PJ. Association of pseudoachalasia with advancing cancer of the gastric cardia. *Gastrointest Endosc* 1999; **50**: 486-491
16 **Moonka R**, Patti MG, Feo CV, Arcerito M, De Pinto M, Horgan S, Pellegrini CA. Clinical presentation and evaluation of malignant pseudoachalasia. *J Gastrointest Surg* 1999; **3**: 456-461
17 **Yeoman LJ**, Grundy A, Parker MC, Fiennes AG. Pseudo-achalasia after radical gastrectomy. *Br J Surg* 1989; **76**: 97-98
18 **López-Cepero Andrada JM**, Jiménez Arjona J, Amaya Vidal A, Rubio Garrido J, Navas Relinque C, Soria de la Cruz MJ, Benítez Roldán A. [Pseudoachalasia and secondary amyloidosis in a patient with rheumatoid arthritis]. *Gastroenterol Hepatol* 2002; **25**: 398-400
19 **Spechler SJ**, Souza RF, Rosenberg SJ, Ruben RA, Goyal RK. Heartburn in patients with achalasia. *Gut* 1995; **37**: 305-308
20 **Shah RN**, Izanec JL, Friedel DM, Axelrod P, Parkman HP, Fisher RS. Achalasia presenting after operative and nonoperative trauma. *Dig Dis Sci* 2004; **49**: 1818-1821
21 **Smith B**. The neurological lesion in achalasia of the cardia. *Gut* 1970; **11**: 388-391
22 **Csendes A**, Smok G, Braghetto I, Ramirez C, Velasco N, Henriquez A. Gastroesophageal sphincter pressure and histological changes in distal esophagus in patients with achalasia of the esophagus. *Dig Dis Sci* 1985; **30**: 941-945
23 **Hornby PJ**, Abrahams TP, Partosoedarso ER. Central mechanisms of lower esophageal sphincter control. *Gastroenterol Clin North Am* 2002; **31**: S11-20, v-vi
24 **Balaji NS**, Crookes PF, Banki F, Hagen JA, Ardill JE, DeMeester TR. A safe and noninvasive test for vagal integrity revisited. *Arch Surg* 2002; **137**: 954-958; discussion 958-959
25 **Mikaeli J**, Bishehsari F, Montazeri G, Yaghoobi M, Malekzadeh R. Pneumatic balloon dilatation in achalasia: a prospective comparison of safety and efficacy with different balloon diameters. *Aliment Pharmacol Ther* 2004; **20**: 431-436
26 **Kadakia SC**, Wong RK. Pneumatic balloon dilation for esophageal achalasia. *Gastrointest Endosc Clin N Am* 2001; **11**: 325-346, vii
27 **Bhatnagar MS**, Nanivadekar SA, Sawant P, Rathi PM. Achalasia cardia dilatation using polyethylene balloon (Rigiflex) dilators. *Indian J Gastroenterol* 1996; **15**: 49-51
28 **Leeuwenburgh I**, Van Dekken H, Scholten P, Hansen BE, Haringsma J, Siersema PD, Kuipers EJ. Oesophagitis is common in patients with achalasia after pneumatic dilatation. *Aliment Pharmacol Ther* 2006; **23**: 1197-1203
29 **Cheng YS**, Li MH, Chen WX, Chen NW, Zhuang QX, Shang KZ. Temporary partially-covered metal stent insertion in benign esophageal stricture. *World J Gastroenterol* 2003; **9**: 2359-2361

S- Editor Wang J **L- Editor** Kumar M **E- Editor** Liu WF

PO Box 2345, Beijing 100023, China
www.wjgnet.com
wjg@wjgnet.com

World J Gastroenterol 2006 August 21; 12(31): 5091-5093
World Journal of Gastroenterology ISSN 1007-9327
© 2006 The WJG Press. All rights reserved.

CASE REPORT

Diabetes mellitus with hepatic infarction: A case report with literature review

Yong-Gui Deng, Zhan-Sheng Zhao, Mian Wang, Sheng-Ou Su, Xi-Xian Yao

Yong-Gui Deng, Zhan-Sheng Zhao, Mian Wang, Sheng-Ou Su, Xi-Xian Yao, Department of Endocrinology, The Second Hospital of Hebei Medical University, Shijiazhuang 050000, Hebei Province, China
Correspondence to: Yong-Gui Deng, Department of Endocrinology, The Second Hospital of Hebei Medical University, 215 Hepingxilu, Shijiazhuang 050000, Hebei Province, China. dcyongguideng@yahoo.com.cn
Telephone: +86-311-87222953
Received: 2006-04-13 Accepted: 2006-06-14

Abstract

Hepatic infarction rarely occurs due to the double supply of arterial and portal inflow. A 53-year-old man with diabetes mellitus developed multiple hepatic infarctions after an episode of fever and diarrhea. The infarction was documented by pathology after partial liver resection. Several causes of hepatic infarction may present in this patient: dehydration and hypotension caused by fever and diarrhea, type 2 diabetes and administration of glibenclamide, diabetic ketoacidosis and widespread atherosclerosis. We suggest that diabetic patient with elevated liver enzyme should be considered the possibility of hepatic infarction.

© 2006 The WJG Press. All rights reserved.

Key words: Diabetes mellitus; Hepatic infarction; Computerized tomography

Deng YG, Zhao ZS, Wang M, Su SO, Yao XX. Diabetes mellitus with hepatic infarction: A case report with literature review. *World J Gastroenterol* 2006; 12(31): 5091-5093

http://www.wjgnet.com/1007-9327/12/5091.asp

INTRODUCTION

Hepatic infarction is a rare event because of the dual blood supply of the portal vein and hepatic artery, and extensive hepatic arterial collateral system. It is characterized by parenchymal necrosis involving at least two entire lobules, companied by a local circulation insufficiency[1].

Case reports of hepatic infarction in diabetes mellitus (DM) involved ketoacidosis[2] and nephrotic syndrome[3], in which upper abdominal pain was developed. We report a case of multiple hepatic infarction in diabetic patient, who was misdiagnosed with hepatic carcinoma.

CASE REPORT

A 53-year-old man was admitted to the hospital because of fever complicated with diarrhea for 4 d. There was a 4-year history of diabetes mellitus without proper control, although he was treated with glibenclamide 2.5 mg bid. His past medical history included hypertension for 2 years with the highest blood pressure of 150/100 mmHg. The patient did not complain of upper abdominal pain.

At first, he was admitted to the emergency ward. Blood routine examinations showed: hemoglobin 142 g/L, red blood count 4.58×10^{12}/L, white blood count 11.7×10^{9}/L with neutrophils 93.1%, platelet count 71×10^{9}/L, mean corpuscular hemoglobin concentration 402 g/L; urine tests: ketone (+), protein (±), glucose (++++); stool routine examination: white blood cell 2-4/HP. He was treated with antibiotics because of suspicion of intestinal infection. After his condition became relative stable, he was transferred to the general ward.

On admission, physical examination revealed no abnormalities except for a slight fever (37.3℃). A second blood routine examination revealed: hemoglobin 144 g/L, white blood count 8.4×10^{9}/L, platelet count 77×10^{9}/L; urine routine examination: ketone and protein were negative, glucose (++++); stool routine examination: white blood cell 2-4/HP; liver and renal function tests and blood lipid were normal; blood glucose 13.9 mmol/L; blood potassium 3.1 mmol/L, blood sodium 127.8 mmol/L, blood chlorine 98.9 mmol/L, CO_2 19.7 mmol/L; coagulation function was normal. The chest X-ray and electrocardiogram showed normal.

Treatment was instituted with insulin, antibiotics, and other drugs to correct microcirculation and electrolyte disturbance. After admission into the general ward for 3 d, the patient had a normal temperature and stool. But abnormalities of liver function tests were found: aspartate aminotransferase 50 U/L (normal value, < 40 U/L) and alanine aminotransferase 65 U/L (normal value, < 40 U/L). Doppler ultrasound disclosed an enhanced echo in the liver, suggesting angioma or carcinoma. Liver computerized tomography showed an abnormal signal in the right lobe (Figure 1). On the ninth day, right hepatic wedge resection was performed and the pathologic diagnosis was multiple hepatic infarction with infection (Figure 2). One month after the operation, the patient had a good recovery.

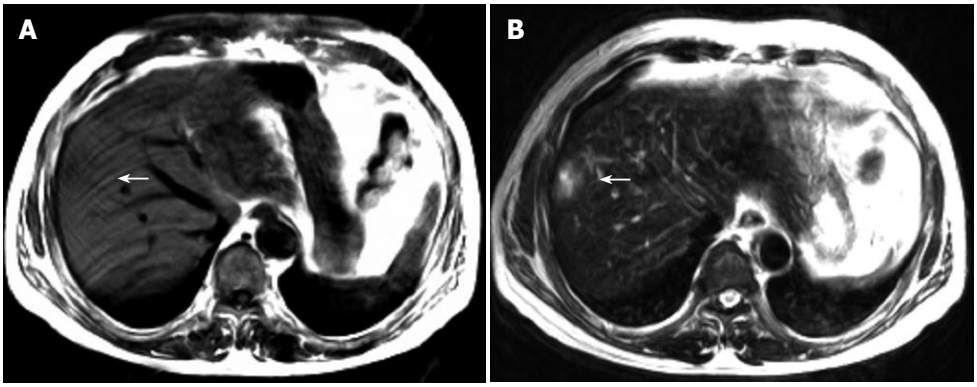

Figure 1 **A**: Between the Ⅴ and Ⅷ segments, the right hepatic lobe near the surface has an abnormal signal which seems ellipse. In T_1WI, its center shows long T_1 and slight long T_1 intensity in row; **B**: In T_2WI, its center shows long T_2 and slightly long T_2 intensity in a row. It shows slight mass effect.

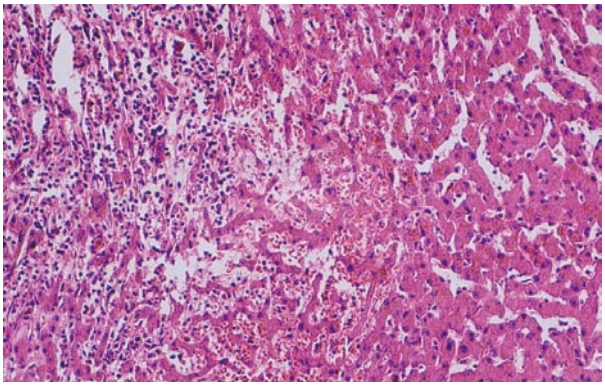

Figure 2 Pathologic section shows hepatic cell necrosis. Vasodilatation and infiltration of inflammatory cells are seen at the junction of necrosis and normal tissues (HE × 100).

DISCUSSION

The hepatic artery supplies about 35% of hepatic blood flow and 50% of the oxygen required by the liver, while the portal vein supplies the remainder[3]. In addition, an extensive collateral system with 26 possible collateral arteries, and the hepatic arteries do not appear to be end arteries. These factors may explain why hepatic infarction is rare and usually requires impairment of both hepatic arterial and portal venous systems.

Hepatic infarction usually occurs when the hepatic artery or its branches are occluded or when the portal vein is thrombosed. Common cause of hepatic infarction is portal venous thrombosis, and hepatic infarction induced by isolated hepatic artery thrombosis is rare. Apart from vascular occlusion, other factors such as shock, sepsis, anaesthesia, biliary disease and diabetic ketoacidosis may result in hepatic infarction. Surgical factors, including abdominal surgery, laparoscopic surgery, liver transplantation, intra-arterial invasive procedures, transjugular intrahepatic portosystemic shunt, may be common causes of hepatic infarction in clinic[3,4].

The mechanism of hepatic infarction in this case is unclear. The following factors may contribute to infarction: (1) An episode of fever and diarrhea should be considered to induce dehydration and hypotension, which further decreased both portal and hepatic arterial inflows. (2) Elevated level of catecholamine in diabetic ketoacidosis might induce vasoconstriction causing ischemia and infarction[2]. (3) Oral antidiabetic agent glibenclamide taken by the patient exerted splanchnic vasoconstricting effects, which might reduce portal venous inflow or impair hepatic arterial buffer response[1]. (4) Widespread atherosclerosis is commonly seen in diabetic and hypertensive patients, and it may cause the thickening of blood vessels and arteriostenosis. Abnormalities of hemodynamics, endothelial dysfunction and hypercoagulable state possibly leading to increased thrombosis and decreased fibrinolysis have been found in diabetic patients with angiopathy. These factors could contribute to the hepatic infarction in diabetes.

Hepatic infarction is usually companied by the outbreak of sudden upper abdominal pain, fever, elevated white blood cell count, and markedly elevated liver enzymes[5]. Hyperglycemia may result in visceral automatic nerve lesion and contribute to the insensitiveness to ischemic pain. This may explain why the patient did not feel abdominal pain.

Computerized tomography scan of upper abdomen in patients with hepatic infarction usually show a well-marginated peripheral zone without any contrast capture in the corresponding hepatic lobe, wedge-shaped and extending to the liver capsule[4]. But in this case, liver computerized tomography scan exhibited untypical presentations, which led to the misdiagnosis of hepatic carcinoma and surgical operation and the diagnosis of hepatic infarction was finally established by liver pathology. MRI is the perfect method for the diagnosis of hepatic infarction because of its high resolution. In the early stage, the lesion shows slight long T_1 and slight long T_2 intensity. In the middle and late stages, it shows long T_1 and long T_2 intensity. The intensity is heterogenous due to various degrees of ischemia and infarction in the lesion. Generally speaking, the center of lesion is more apparent than the rim and shows prominent abnormal intensity as in the present case. The lesion shows no apparent enhancement and slight mass effect, which is the primary differentiation feature from hepatic mass.

In summary, we suggest that the diabetic patient with elevated liver enzymes should be suspected much of hepatic infarction and further liver computerized tomography scan should be considered to exclude the diagnosis.

REFERENCES

1 **Francque S**, Condat B, Asselah T, Vilgrain V, Durand F, Moreau R, Valla D. Multifactorial aetiology of hepatic infarction: a case report with literature review. *Eur J Gastroenterol Hepatol* 2004; **16**: 411-415

2 **Ng RC**, Sigmund CJ Jr, Lagos JA, Chernin M. Hepatic infarction and diabetic ketoacidosis. *Gastroenterology* 1977; **73**: 804-807

3 **Martinez Vea A**, Garcia Ruiz C, Sauri Conejero A, Mayayo Artal E, Oliver Rotellar J. Hepatic infarction: an unusual complication of nephrotic syndrome in a patient with diabetes mellitus. *Postgrad Med J* 1990; **66**: 968-970

4 **Shou Y**, Wang X, Cheng HY, Xu AM, Chen D. Imaging analysis of hepatic infarction. *Zhongguo Yixue Yingxiang Jishu* 2004; **20**: S58-60

5 **Wu Z**, Lu Y, Zhang XG, Wang HW, Li J. Liver infarction: analysis of two cases. *Gandan Waike Zazhi* 2002; **10**: 288-290

S- Editor Wang J **L- Editor** Wang XL **E- Editor** Bi L

PO Box 2345, Beijing 100023, China
www.wjgnet.com
wjg@wjgnet.com

World J Gastroenterol 2006 August 21; 12(31): 5094-5095
World Journal of Gastroenterology ISSN 1007-9327
© 2006 The WJG Press. All rights reserved.

LETTERS TO THE EDITOR

Obstructive jaundice leads to accumulation of oxidized low density lipoprotein in human liver tissue

Mustafa Comert, Yucel Ustundag, Ishak Ozel Tekin, Banu Dogan Gun, Figen Barut

Mustafa Comert, Department of Surgery, School of Medicine, Zonguldak Karaelmas University, Turkey
Yucel Ustundag, Department of Gastroenterology, School of Medicine, Zonguldak Karaelmas University, Kozlu-Zonguldak, Turkey
Ishak Ozel Tekin, Department of Immunology, School of Medicine, Zonguldak Karaelmas University, Kozlu-Zonguldak, Turkey
Banu Dogan Gun, Figen Barut, Department of Pathology, School of Medicine, Zonguldak Karaelmas University, Kozlu-Zonguldak, Turkey
Correspondence to: Mustafa Comert, MD, ZKU, Arastirma ve Uygulama Hastanesi Bashekimligi, Kozlu-Zonguldak 67600, Turkey. mustafacomert@hotmail.com
Telephone: +90-372-2610159 Fax: +90-372-2610159
Received: 2006-04-25 Accepted: 2006-05-22

Abstract

Oxidized low density lipoprotein (ox-LDL) molecule is one of the most important modified lipoproteins produced during the oxidative stress. Modified lipoproteins have been defined as being part of the immune inflammatory mechanisms in association with oxidant stress. We have reported the accumulation of ox-LDL in Balb/c mice liver after bile duct ligation previously. Here, we investigated this finding in human beings with obstructive jaundice. Our study demonstrates that obstructive jaundice results in tremendous accumulation of ox-LDL in the liver tissue of patients.

© 2006 The WJG Press. All rights reserved.

Key words: Obstructive jaundice; Liver; Oxidative stress; Oxidized low density lipoprotein

Comert M, Ustundag Y, Tekin IO, Gun BD, Barut F. Obstructive jaundice leads to accumulation of oxidized low density lipoprotein in human liver tissue. *World J Gastroenterol* 2006; 12(31): 5094-5095

http://www.wjgnet.com/1007-9327/12/5094.asp

TO THE EDITOR

Oxidized low density lipoprotein (ox-LDL) molecule is one of the most important modified lipoproteins. Its popularity has arisen after our understanding about its key role in the pathogenesis of atherosclerosis[1]. These molecules have been defined as being part of the immune inflammatory mechanisms in association with oxidant stress[2]. Hepatocyte injury during obstructive jaundice is involved in such pathways associated with oxidant stress. This association has been testified also by us in Balb/c mice. Moreover, our study demonstrated that tremendous ox-LDL is accumulated in the liver after bile duct ligation in mice[3]. Furthermore, we have investigated this finding in human beings with obstructive jaundice.

The study was composed of two groups. One group enrolled 11 patients with various causes of obstructive jaundice, 5 percutaneous and 6 intraoperative wedge-resection liver biopsies were taken from these patients. The other group included 7 patients undergoing elective abdominal operations without primary hepatobiliary pathologies. Wedge-resection type liver biopsies were taken from all these patients. Routine liver biochemical parameters including cholestatic liver enzymes were studied. In liver biopsies stained with hematoxylin and eosin, we investigated cholestatic findings. Moreover, a special immunofluorescent staining was done for investigation of ox-LDL in the liver tissue by fluorescent microscopy. All patients in group 1 demonstrated various degrees of cholestasis. The patients in group 2 showed neither cholestasis nor any histopathologic abnormality in the liver biopsy samples. First anti-ox-LDL antibody and fluorescence - stained anti-anti ox-LDL antibody were applied on liver tissue samples as previously described[3]. The patients in group 1 were found to have enormous accumulation of ox-LDL in the liver (Figure 1A). No patient in group 2 demonstrated ox-LDL deposition (Figure 1B).

In this investigation, we clearly demonstrated retention of ox-LDL molecules in the liver tissue of human beings with obstructive jaundice, which was also found in our mice study. As demonstrated in our mice study, enhanced lipid peroxidation in the liver due to oxidative stress in association with obstructive jaundice has been clearly notified by many authors[4,5]. A major and early lipid peroxidation product is ox-LDL which is mainly filtered by liver macrophages and Kupffer cells[6]. During the jaundice period after biliary obstruction, ox-LDL accumulates in the liver either because of its decreased secretion into the bile or because of enhanced production due to lipid peroxidation as the filtration capacity of Kupffer cells becomes insufficient. It is well known that ox-LDL molecules have specific receptors on hepatocytes, Kupffer

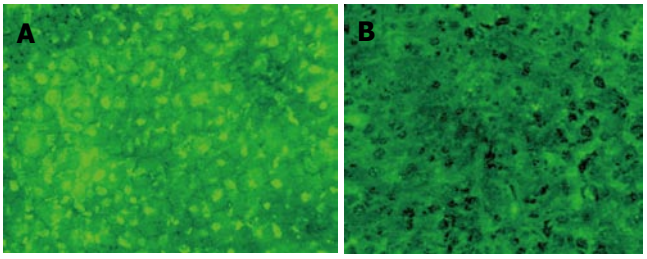

Figure 1 Enormous accumulation of oxidized low-density lipoprotein in patients of group 1 (**A**) and no oxidized low-density lipoprotein deposition in patients of group 2 (**B**) (x 100).

and stellate cells[2,7]. The interaction of ox-LDL with these cells can lead to apoptosis of hepatocytes, enhancement of tumor necrosis factor-alpha and secretion of transforming growth factor-beta by Kupffer cells, as well as transformation of stellate cells into collagen secreting myofibroblasts[2,7,8]. Thus, it seems theoretically possible that the main lipid peroxidation byproduct, ox-LDL, may have important roles in liver consequences of biliary jaundice. Our study results indicate a concrete fact that ox-LDL accumulates in human liver tissue during obstructive jaundice. Nevertheless, further investigation should be done for more detailed analysis of such accumulation and its role in liver outcomes of obstructive jaundice.

REFERENCES

1 **Tsimikas S**, Witztum JL. The oxidative modification hypothesis of atherosclerosis. In: Keaney JF, ed. Oxidative stress and vascular disease. Boston: Kluwer Acad Pub, 2000: 49-74

2 **Hsu HY**, Chiu SL, Wen MH, Chen KY, Hua KF. Ligands of macrophage scavenger receptor induce cytokine expression via differential modulation of protein kinase signaling pathways. *J Biol Chem* 2001; **276**: 28719-28730

3 **Cömert M**, Tekin IO, Acikgöz S, Ustündağ Y, Uçan BH, Acun Z, Barut F, Sümbüloğlu V. Experimental bile-duct ligation resulted in accumulation of oxidized low-density lipoproteins in BALB/c mice liver. *J Gastroenterol Hepatol* 2004; **19**: 1052-1057

4 **López PM**, Fiñana IT, De Agueda MC, Sánchez EC, Muñoz MC, Alvarez JP, De La Torre Lozano EJ. Protective effect of melatonin against oxidative stress induced by ligature of extra-hepatic biliary duct in rats: comparison with the effect of S-adenosyl-L-methionine. *J Pineal Res* 2000; **28**: 143-149

5 **Nakano H**, Fujiwara Y, Kitamura N, Kumada K, Matsumiya A, Sakai H, Hatakeyama T, Yamaguchi M, Jaeck D. Susceptibility to lipopolysaccharide of cholestatic rat liver produced with bile duct ligation: assessments of the mitochondrial glutathione pool and the effects of N-acetylcysteine. *Eur Surg Res* 2000; **32**: 148-154

6 **Pieters MN**, Esbach S, Schouten D, Brouwer A, Knook DL, Van Berkel TJ. Cholesteryl esters from oxidized low-density lipoproteins are in vivo rapidly hydrolyzed in rat Kupffer cells and transported to liver parenchymal cells and bile. *Hepatology* 1994; **19**: 1459-1467

7 **Schneiderhan W**, Schmid-Kotsas A, Zhao J, Grünert A, Nüssler A, Weidenbach H, Menke A, Schmid RM, Adler G, Bachem MG. Oxidized low-density lipoproteins bind to the scavenger receptor, CD36, of hepatic stellate cells and stimulate extracellular matrix synthesis. *Hepatology* 2001; **34**: 729-737

8 **Feng Y**, Schreiner GF, Chakravarty S, Liu DY, Joly AH. Inhibition of the mitogen activated protein kinase, p38 alpha, prevents proinflammatory cytokine induction by human adherent mononuclear leukocytes in response to lipid loading. *Atherosclerosis* 2001; **158**: 331-338

S- Editor Pan BR **L- Editor** Wang XL **E- Editor** Bi L

PO Box 2345, Beijing 100023, China
www.wjgnet.com
wjg@wjgnet.com

World J Gastroenterol 2006 August 21; 12(31): 5096
World Journal of Gastroenterology ISSN 1007-9327
© 2006 The WJG Press. All rights reserved.

ACKNOWLEDGMENTS

Acknowledgments to Reviewers of *World Journal of Gastroenterology*

Many reviewers have contributed their expertise and time to the peer review, a critical process to ensure the quality of *World Journal of Gastroenterology*. The editors and authors of the articles submitted to the journal are grateful to the following reviewers for evaluating the articles (including those were published and those were rejected in this issue) during the last editing period of time.

Gianfranco D Alpini, Professor
Internao Medicine and Medical Physiology, Scoh Whot Hospital, 702 SW H.K. dod genloop MRB rm316B, Temple 76504, United States

Domenico Alvaro, MD
Division of Gastroenterology, Department of Clinical Medicine, University of Rome La Sapienza, Viale Università 37, Rome 00185, Italy

Vito Annese, MD
Department of Internal Medicine, Unit of Gastroenterology, Hospital, Viale Cappuccini, 1, San Giovanni Rotondo 71013, Italy

Masahiro Arai, MD, PhD
Department of Gastroenterology, Toshiba General Hospital, 6-3-22 Higashi-ooi, Shinagawa-ku,Tokyo 140-8522, Japan

Lee Bouwman, Dr
Leiden University Medical Centre, department of surgery, Albinusdreef 2 PO Box 9600, 230 RC Leiden, The Netherlands

Michael F Byrne, MD
Clinical Associate Professor, Division of Gastroenterology Vancouver General Hospital, 100-2647 Willow Street Vancouver BC V5Z 3P1, Canada

Tamara Cacev, MSc
Division of Molecular Medicine, Rudjer Boskovic Institute, Bijenicka c. 54, Zagreb 10000, Croatia

Yogesh K Chawla, Dr, Professor
Department of Hepatology, Postgraduate Institute of Medical Education and Research, Chandigarh 160012, India

Xian-Ming Chen, MD
Center for Basic Research in Digestive Diseases, Division of Gastroenterology and Hepatology, Mayo Clinic College of Medicine, 200 First Street, SW, Rochester, MN 55905, United States

Gino Roberto Corazza, Professor
Department of Internal Medicine, University of Pavia, Gastroenterology Unit - I.R.C.C.S. Policlinico San Matteo - Piazzale Golgi n.5, Pavia 27100, Italy

Francesco Costa, Dr
Dipartimento di Medicina Interna – U.O. di Gastroenterologia
Università di Pisa – Via Roma, 67 – 56122 - Pisa, Italy

Olivier Detry, Dr
Department of Abdominal Surgery and Transplantation, University of Liège, CHU Sart Tilman B35, B-4000 Liège, Belgium

Xue-Gong Fan, Professor
Department of Infectious Diseases, Xiangya Hospital, Central South University, Changsha 410008, China

Vicent Felipo, Dr
Laboratory of Neurobiology, Centro de Investigación Príncipe, Avda del Saler, 16, 46013 Valencia, Spain

Takahiro Fujimori, MD, PhD, Professor
Department of Surgical and Molecular Pathology, Dokkyo Univesity School of Medicine, 880 Kitakobayashi, Mibu, Shimotsuga, Tochigi 321-0293, Japan

Xupeng Ge, MD, PhD
Division of Transplantation Surgery, CLINTEC, Karolinska Institute, Karolinska University Hospital-Huddinge, Stockholm 14186, Sweden

Hallgrimur Gudjonsson, MD
Gastroenterolog, University Hospital, University Hospital, Landspitali,Hringbraut, Reykjavik 101, Iceland

Anna S Gukovskaya, Professor
VA Greater Los Angeles Health Care System ,University of California, Los Angeles, 11301 Wilshire Blvd, Los Angeles 91301, United States

Kazuhiro Hanazaki, MD
Department of Surgery, Shinonoi General Hospital, 666-1 Ai, Shinonoi, Nagano 388-8004, Japan

Tetsuo Hayakawa, Emeritus Professor
Director general, Meijo Hospital, Meijo Hospital, Sannomaru 1-3-1, Naka-ku, Nagoya 460-0001, Japan

Khek-Yu Ho, Professor
Department of Medicine, National University Hospital, 119074, Singapore

Guang-Cun Huang, PhD
Department of Pathology, Shanghai Medical College, Fudan University, 138 Yixueyuan Road, Shanghai 200032, China

Fumio Imazeki, MD
Department of Medicine and Clinical Oncology, Chiba University, 1-8-1 Inohana, Chuo-ku, Chiba 260-8670, Japan

Seigo Kitano, Professor
Department of Surgery I, Oita University Faculty of Medicine, 1-1 Idaigaoka Hasama-machi, Oita 879-5593, Japan

Robert J Korst, MD
Department of Cardiothoracic Surgery, Weill Medical College of Cornell University, Room M404, 525 East 68th Street, New York 10032, United States

Richard A Kozarek, MD
Department of Gastroenterology, Virginia Mason Medical Center, 1100 Ninth Avenue, PO Box 900, Seattle 98111-0900, United States

Peter Laszlo Lakatos, MD, PhD, Assistant Professor
1st Department of Medicine, Semmelweis University, Koranyi S 2A, Budapest H1083, Hungary

Rene Lambert, Professor
International Agency for Research on Cancer, 150 Cours Albert Thomas, Lyon 69372 cedex 8, France

Frederick H Leibach, Professor
Department of Biochemistry and Molecular Biology, Medical College of Georgia, 1120 15th Street, Augusta 30912-2100, United States

Ming Li, Associate Professor
Tulane University Health Sciences Center, 1430 Tulane Ave Sl-83, New Orleans 70112, United States

John M Mariadason, PhD, Assistant Professor
Department of Oncology, Albert Einstein College of Medicine, Montefiore Medical Center, Hofheimer Bldg. 413, 111 East 210th Street, Bronx, NY 10467, United States

SØren MØller, Chief Physician
Department of Clinical Physiology 239, Hvidovre Hospital, Kettegaard alle 30, DK-2650 Hvidovre, Denmark

Eun-Yi Moon, Dr
Laboratory of Human Genomics, Korea Research Institute of Bioscience and Biotechnology, Daejeon 305-333, South Korea

Yoshiharu Motoo, Professor
Department of Medical Oncology, Kanazawa Medical University, 1-1 Daigaku, Uchinada, Ishikawa 920-0293, Japan

Douglas B Neison, Dr
Department of Gastroenterology, Minneapalis VA Medical Cencer, One Veterons Dive(111-D), Minneapalis 55417, United States

Masayuki Ohta, MD
Department of Surgery I, Oita University Faculty of Medicine, 1-1 Idaigaoka, Hasama-machi, Oita 879-5593, Japan

Mark S Pearce, Dr
Sir James Spence Institute, University of Newcastle Upon Tyne, Royal Victoria Infirmary, Newcastle Upon Tyne, NE1 4LP, United Kingdom

Paolo Del Poggio, Dr
Hepatology Unit, Department of Internal Medicine, Treviglio Hospital, Piazza Ospedale 1, Treviglio Bg 24047, Italy

Vasiliy Ivanovich Reshetnyak, Professor
Institute of General Reanimatology, 25-2, Petrovka Str., Moscow 107031, Russian

Richard A Rippe, Dr
Department of Medicine, The University of North Carolina at Chapel Hill, Chapel Hill, NC 27599-7038, United States

Ian C Roberts-Thomson, Professor
Department of Gastroenterology and Hepatology, The Queen Elizabeth Hospital, 28 Woodville Road, Woodville South 5011, Australia

Luis Rodrigo, Professor
Gastroenterology Service, Hospital Central de Asturias, c/ Celestino Villamil, s.n., Oviedo 33.006, Spain

Francis Seow-Choen, Professor
Seow-Choen Colorectal Centre, Mt Elizabeth Medical Centre, Singapore, 3 Mt Elizabeth Medical Centre #09-10 , 228510, Singapore

Bruno Stieger, Professor
Department of Medicine, Division of Clinical Pharmacology and Toxicology,University Hospital, Zurich 8091, Switzerland

Kyuichi Tanikawa, Professor
International Institute for Liver Research, 1-1 Hyakunen Kouen, Kurume 839-0864, Japan

Anton Vavrecka, MD
Clinic of Gastroenterology, SZU, NSP SV.CAM, Antolska 11, Bratislava 85107, Slovakia

Ian David Wallace, MD
Shakespeare Specialist Group, 181 Shakesperare Rd, Milford, Auckland 1309, New Zealand

Jens Werner, MD, Associate Professor
Department of General and Visceral Surgery, University of Heidelberg, INF 110, Heidelberg 69120, Germany

Daniel Lindsay Worthley, Dr
Department of Gastroenterology and Hepatology, Flinders Medical Centre, Room 3D230, Bedford Park, SA 5042, Australia

Karen Leslie Wright, Dr
Department of Pharmacy and Pharmacology, University of Bath, Claverton Down, Bath BA2 7AY, United Kingdom

Norimasa Yoshida, Associate Professor
Molecular Gastroenterology and Hepatology, Kyoto Prefectural University of Medicine, 465 Kajiicho, Kawaramachi-Hirokoji, Kamigyoku, Kyoto 602-8566, Japan

PO Box 2345, Beijing 100023, China
www.wjgnet.com
wjg@wjgnet.com

World J Gastroenterol 2006 August 21; 12(31): 5097
World Journal of Gastroenterology ISSN 1007-9327
© 2006 The WJG Press. All rights reserved.

Meetings

MAJOR MEETINGS COMING UP

First Biennial Congress of the Asian-Pacific Hepato-Pancreato-Biliary Association
March, 2007
Fukuoka, Japan
http://www.congre.co.jp/1st-aphpba

American College of Gastroenterology Annual Scientific
20-25 October 2006
Las Vegas, NV

14th United European Gastroenterology Week, UEGW
21-25 October 2006
Berlin, Germany

APDW 2006: Asian Pacific Digestive Week 2006
26-29 November 2006
Lahug Cebu City, Philippines

EVENTS AND MEETINGS IN THE UPCOMING 6 MONTHS

Falk Symposium 151: Emerging Issues in Inflammatory Bowel Diseases
24-25 March 2006
Sydney - NSW
Falk Foundation e.V.
symposia@falkfoundation.de

10th International Congress of Obesity
3-8 September 2006
Sydney
Event Planners Australia
enquiries@ico2006.com
www.ico2006.com

Easl 2006 - the 41st annual
26-30 April 2006
Vienna, Austria
Kenes International

Prague hepatology 2006
14-16 September 2006
Prague
Foundation of the Czech Society of Hepatology
veronika.revicka@congressprague.cz
www.czech-hepatology.cz/phm2006

12th International Symposium on Viral Hepatitis and Liver Disease
1-5 July 2006
Paris
MCI France
isvhld2006@mci-group.com
www.isvhld2006.com

Falk Symposium 152: Intestinal Disease Part I, Endoscopy 2006 - Update and Live Demonstration
4-5 May 2006
Berlin
Falk Foundation e.V.
symposia@falkfoundation.de

Falk Symposium 153: Intestinal Disease Part II, Immunoregulation in Inflammatory Bowel Disease - Current Understanding and Innovation
6-7 May 2006
Berlin
Falk Foundation e.V.
symposia@falkfoundation.de

ILTS 12th Annual International Congress
3-6 May 2006
Milan
ILTS
www.ilts.org

Internal Medicine: Gastroenterology
22 July 2006-1 August 2006
Amsterdam
Continuing Education Inc
jbarnhart@continuingeducation.net
6th Annual Gastroenterology And Hepatology
15-18 March 2006
Rio Grande
Office of Continuing Medical Education
cmenet@jhmi.edu
www.hopkinscme.net

World Congress on Gastrointestinal Cancer
28 June 2006-1 July 2006
Barcelona, Spain
c.chase@imedex.com

International Conference on Surgical Infections, ICSI2006
6-8 September 2006
Stockholm
European Society of Clinical Microbiology and Infectious Diseases
icsi2006@stocon.se
www.icsi2006.se/9/23312.asp

7th World Congress of the International Hepato-Pancreato-Biliary Association
3-7 September 2006
Edinburgh
Edinburgh Convention Bureau
convention@edinburgh.org
www.edinburgh.org/conference

Society of American Gastrointestinal Endoscopic Surgeons
26-29 April 2006
Dallas - TX
www.sages.org

Digestive Disease Week 2006
20-25 May 2006
Los Angeles
www.ddw.org

Annual Postgraduate Course
25-26 May 2006
Los Angeles, CA
American Society of Gastrointestinal Endoscopy
www.asge.org/education

American Society of Colon and Rectal Surgeons
3-7 June 2006
Seatlle - Washington
www.fascrs.org

EVENTS AND MEETINGS IN 2006

10th World Congress of the International Society for Diseases of the Esophagus
22-25 February 2006
Adelaide
isde@sapmea.asn.au
www.isde.net

Falk Symposium 151: Emerging Issues in Inflammatory Bowel Diseases
24-25 March 2006
Sydney - NSW
Falk Foundation e.V.
symposia@falkfoundation.de

10th International Congress of Obesity
3-8 September 2006
Sydney
Event Planners Australia
enquiries@ico2006.com
www.ico2006.com

Easl 2006 - the 41st annual
26-30 April 2006
Vienna, Austria
Kenes International

VII Brazilian Digestive Disease Week
19-23 November 2006
www.gastro2006.com.br

International Gastrointestinal Fellows Initiative
22-24 February 2006
Banff, Alberta
Canadian Association of Gastroenterology
cagoffice@cag-acg.org
www.cag-acg.org

Canadian Digestive Disease Week
24-27 February 2006
Banff, Alberta
Digestive Disease Week Administration
cagoffice@cag-acg.org
www.cag-acg.org

Prague Hepatology 2006
14-16 September 2006
Prague
Foundation of the Czech Society of Hepatology
veronika.revicka@congressprague.cz
www.czech-hepatology.cz/phm2006

12th International Symposium on Viral Hepatitis and Liver Disease
1-5 July 2006
Paris
MCI France
isvhld2006@mci-group.com
www.isvhld2006.com/

Falk Seminar: XI Gastroenterology Seminar Week
4-8 February 2006
Titisee
Falk Foundation e.V.
symposia@falkfoundation.de

European Multidisciplinary Colorectal Cancer Congress 2006
12-14 February 2006
Berlin
Congresscare
info@congresscare.com
www.colorectal2006.org

Falk Symposium 152: Intestinal Disease Part I, Endoscopy 2006 - Update and Live Demonstration
4-5 May 2006
Berlin
Falk Foundation e.V.
symposia@falkfoundation.de

Falk Symposium 153: Intestinal Disease Part II, Immunoregulation in Inflammatory Bowel Disease - Current Understanding and Innovation
6-7 May 2006
Berlin
Falk Foundation e.V.
symposia@falkfoundation.de

14th United European Gastroenterology Week
21-25 October 2006
Berlin
United European Gastroenterology Federation
www.uegw2006.de

World Congress on Controversies in Obesity, Diabetes and Hypertension
25-28 October 2006
Berlin
comtec international
codhy@codhy.com
www.codhy.com

Asia Pacific Obesity Conclave
1-5 March 2006
New Delhi
info@apoc06.com
www.apoc06.com/

ILTS 12th Annual International Congress
3-6 May 2006
Milan
ILTS
www.ilts.org

XXX Panamerican Congress of Gastroenterology
11-16 November 2006
Cancun
www.panamericano2006.org.mx

Internal Medicine: Gastroenterology
22 July 2006-1 August 2006
Amsterdam
Continuing Education Inc
jbarnhart@continuingeducation.net

6th Annual Gastroenterology And Hepatology
15-18 March 2006
Rio Grande
Office of Continuing Medical Education
cmenet@jhmi.edu
www.hopkinscme.net

Hepatitis 2006
25 February 2006-5 March 2006
Dakar
hepatitis2006@mangosee.com
mangosee.com/mangosteen/hepatitis2006/hepatitis2006.htm

World Congress on Gastrointestinal Cancer
28 June 2006-1 July 2006
Barcelona, Spain
c.chase@imedex.com

International Conference on Surgical Infections, ICSI2006
6-8 September 2006
Stockholm
European Society of Clinical Microbiology and Infectious Diseases
icsi2006@stocon.se
www.icsi2006.se/9/23312.asp

5th International Congress of The African Middle East Association of Gastroenterology
24-26 February 2006
Sharjah
InfoMed Events
infoevent@infomedweb.com
www.infomedweb.com

7th World Congress of the International Hepato-Pancreato-Biliary Association
3-7 September 2006
Edinburgh
Edinburgh Convention Bureau
convention@edinburgh.org
www.edinburgh.org/conference

13th International Symposium on Pancreatic & Biliary Endoscopy
20-23 January 2006
Los Angeles - CA
laner@cshs.org

2006 Gastrointestinal Cancers Symposium
26-28 January 2006
San Francisco - CA
Gastrointestinal Cancers Symposium Registration Center
giregistration@jspargo.com

Society of American Gastrointestinal Endoscopic Surgeons
26-29 April 2006
Dallas - TX
www.sages.org

Digestive Disease Week 2006
20-25 May 2006
Los Angeles
www.ddw.org

Annual Postgraduate Course
25-26 May 2006
Los Angeles, CA
American Society of Gastrointestinal Endoscopy
www.asge.org/education

American Society of Colon and Rectal Surgeons
3-7 June 2006
Seatlle - Washington
www.fascrs.org

71st ACG Annual Scientific and Postgraduate Course
20-25 October 2006
Venetian Hotel, Las Vegas, Neveda
The American College of Gastroenterology

AASLD 57th Annual - The Liver Meeting™
27-31 October 2006
Boston, MA
AASLD

New York Society for Gastrointestinal Endoscopy
13-16 December 2006
New York
www.nysge.org

EVENTS AND MEETINGS IN 2007

9th World Congress on Gastrointestinal Cancer
20-23 June 2007
Barcelona
Imedex
meetings@imedex.com

Gastro 2009, World Congress of Gastroenterology and Endoscopy London, United Kingdom 2009

PO Box 2345, Beijing 100023, China
www.wjgnet.com
wjg@wjgnet.com

World J Gastroenterol 2006 August 21; 12(31): 5098-5100
World Journal of Gastroenterology ISSN 1007-9327
© 2006 The WJG Press. All rights reserved.

Instructions to authors

GENERAL INFORMATION

World Journal of Gastroenterology (*WJG, World J Gastroenterol* ISSN 1007-9327 CN 14-1219/R) is a weekly journal of more than 48 000 circulation, published on the 7th, 14th, 21st and 28th of every month.

Original Research, Clinical Trials, Reviews, Comments, and Case Reports in esophageal cancer, gastric cancer, colon cancer, liver cancer, viral liver diseases, *etc.*, from all over the world are welcome on the condition that they have not been published previously and have not been submitted simultaneously elsewhere.

Indexed and abstracted in

Current Contents/Clinical Medicine and Science Citation Index-Expanded, *Index Medicus*, MEDLINE and PubMed, Chemical Abstracts, EMBASE/Excerpta Medica, Abstracts Journals, Nature Clinical Practice Gastroenterology and Hepatology, CAB Abstracts and Global Health.ISI JCR 2003-2000 IF: 3.318, 2.532, 1.445 and 0.993.

Published by

The WJG Press

SUBMISSION OF MANUSCRIPTS

Manuscripts should be typed double-spaced on A4 (297 mm × 210 mm) white paper with outer margins of 2.5 cm. Number all pages consecutively, and start each of the following sections on a new page: Title Page , Abstract, Introduction, Materials and Methods, Results, Discussion, acknowledgements, References, Tables, Figures and Figure Legends. Neither the editors nor the Publisher is responsible for the opinions expressed by contributors. Manuscripts formally accepted for publication become the permanent property of The WJG Press, and may not be reproduced by any means, in whole or in part without the written permission of both the authors and the Publisher. We reserve the right to put onto our website and copy-edit accepted manuscripts. Authors should also follow the guidelines for the care and use of laboratory animals of their institution or national animal welfare committee.

Authors should retain one copy of the text, tables, photographs and illustrations, as rejected manuscripts will not be returned to the author(s) and the editors will not be responsible for the loss or damage to photographs and illustrations in mailing process.

Online submission

Online submission is strongly advised. Manuscripts should be submitted through the Online Submission System at: http://www.wjgnet.com/index.jsp. Authors are highly recommended to consult the ONLINE INSTRUCTIONS TO AUTHORS (http://www.wjgnet.com/wjg/help/instructions.jsp) before attempting to submit online. Authors encountering problems with the Online Submission System may send an email you describing the problem to wjg@wjgnet.com for assistance. If you submit your manuscript online, do not make a postal contribution. A repeated online submission for the same manuscript is strictly prohibited.

Postal submission

Send 3 duplicate hard copies of the full-text manuscript typed double-spaced on A4 (297 mm × 210 mm) white paper together with any original photographs or illustrations and a 3.5 inch computer diskette or CD-ROM containing an electronic copy of the manuscript including all the figures, graphs and tables in native Microsoft Word format or *.rtf format to:

Editorial Office

World Journal of Gastroenterology
Editorial Department: Apartment 1066, Yishou Garden,
58 North Langxinzhuang Road,
PO Box 2345, Beijing 100023, China
E-mail: wjg@wjgnet.com
http: //www.wjgnet.com
Telephone: +86-10-85381901
Fax: +86-10-85381893

MANUSCRIPT PREPARATION

All contributions should be written in English. All articles must be submitted using a word-processing software. All submissions must be typed in 1.5 line spacing and in word size 12 with ample margins. The letter font is Tahoma. For authors from China, one copy of the Chinese translation of the manuscript is also required (excluding references). Style should conform to our house format. Required information for each of the manuscript sections is as follows:

Title page

Full manuscript title, running title, all author(s) name(s), affiliations, institution(s) and/or department(s) where the work was accomplished, disclosure of any financial support for the research, and the name, full address, telephone and fax numbers and email address of the corresponding author should be included. Titles should be concise and informative (removing all unnecessary words), emphasize what is new, and avoid abbreviations. A short running title of less than 40 letters should be provided. List the author(s)' name(s) as follows: initial and/or first name, middle name or initial(s) and full family name.

Abstract

An informative, structured abstract of no more than 250 words should accompany each manuscript. Abstracts for original contributions should be structured into the following sections: AIM: Only the purpose should be included. METHODS: The materials, techniques, instruments and equipments, and the experimental procedures should be included. RESULTS: The observatory and experimental results, including data, effects, outcome, *etc.* should be included. Authors should present *P* value where necessary, and the significant data should accompany. CONCLUSION: Accurate view and the value of the results should be included.

The format of structured abstracts is at: http://www.wjgnet.com/wjg/help/11.doc

Key words

Please list 6-10 key words that could reflect content of the study mainly from *Index Medicus*.

Text

For most article types, the main text should be structured into the following sections: INTRODUCTION, MATERIALS AND METHODS, RESULTS and DISCUSSION, and should include in appropriate Figures and Tables. Data should be presented in the body text or in Figures and Tables, but not in both.

Illustrations

Figures should be numbered as 1, 2, 3 and so on, and mentioned clearly in the main text. Provide a brief title for each figure on a separate page. No detailed legend should be involved under the figures. This part should be added into the text where the figures are applicable. Digital images: black and white photographs should be scanned and saved in TIFF format at a resolution of 300 dpi; color images should be saved as CMYK (print files) but not as RGB (screen-viewing files). Place each photograph in a separate file. Print images: supply images of size no smaller than 126 mm × 76 mm printed on smooth surface paper; label the image by writing the Figure number and orientation using an arrow. Photomicrographs: indicate the original magnification and stain in the legend. Digital Drawings: supply files in EPS if created by freehand and illustrator, or TIFF from photoshops. EPS files must be accompanied by a version in native file format for editing purposes. Existing line drawings should be scanned at a resolution of 1200 dpi and as close as possible to the size where they will appear when printed. Please use uniform legends for the same subjects. For example: Figure 1 Pathological changes of atrophic gastritis after treatment. A: ...; B: ...; C: ...; D: ...; E: ...; F: ...; G: ...

Tables

Three-line tables should be numbered as 1, 2, 3 and so on, and mentioned clearly in the main text. Provide a brief title for each table. No detailed legend should be included under the tables. This part should be added into the text where the tables are applicable. The information should complement but not duplicate that contained in the text. Use one horizontal line under the title, a second under the column heads, and a third below the Table, above any footnotes. Vertical and italic lines should be omitted.

Notes in tables and illustrations

Data that are not statistically significant should not be noted. $^{a}P<0.05$, $^{b}P<0.01$ should be noted ($P>0.05$ should not be noted). If there are other series of *P* values, $^{c}P<0.05$ and $^{d}P<0.01$ are used. Third series of *P* values can be expressed as $^{e}P<0.05$ and $^{f}P<0.01$. Other notes in tables or under illustrations should be expressed as ^{1}F, ^{2}F, ^{3}F; or some other symbols with

a superscript (Arabic numerals) in the upper left corner. In a multi-curve illustration, each curve should be labeled with ●, ○, ■, □, ▲, △, *etc.* in a certain sequence.

Acknowledgments
Brief acknowledgments of persons who have made genuine contributions to the manuscripts and who endorse the data and conclusions are included. Authors are responsible for obtaining written permission to use any copyrighted text and/or illustrations.

REFERENCES

Coding system
The author should code the references according the citation order in text in Arabic numerals, put references codes in square brackets, superscript it at the end of citation content or the author name of the citation. For those citation content as the narrate part, the coding number and square brackets should be typeset normally. For example, Crohn's disease (CD) is associated with increased intestinal permeability[1,2]. If references are directly cited in the text, they would be put together with the text, for example, from references [19,22-24], we know that...

When the authors code the references, please ensure that the order in text is the same as in reference part and also insure the spelling accuracy of the first author's name. Do not code the same citation twice.

PMID requirement
PMID roots in the abstract serial number indexed by PubMed (http://www.ncbi.nlm.nih.gov/entrez/query.fcgi?db=PubMed). The author should supply the PMID for journal citation. For those references that have not been indexed by PubMed, a printed copy of the first page of the full reference should be submitted.

The accuracy of the information of the journal citations is very important. Through reference testing system (http://www.wjgnet.com/cgi-bin/index.pl), the authors and editor could check the authors name, title, journal title, publication date, volume number, start page, and end page. We will interlink all references with PubMed in ASP file so that the readers can read the abstract of the citations online immediately.

Style for journal references
Authors: the first author should be typed in bold-faced letter. The surname of all authors should be typed with the initial letter capitalized and followed by their name in abbreviation (For example, Lian-Sheng Ma is abbreviated as Ma LS, Bo-Rong Pan as Pan BR). Title of the cited article and italicized journal title (Journal title should be in its abbreviation form as shown in PubMed), publication date, volume number (in black), start page, and end page [PMID: 11819634]

Note: The author should test the references through reference testing system (http://www.aushome.cn/cgi-bin/index.pl)

Style for book references
Authors: the first author should be typed in bold-faced letter. The surname of all authors should be typed with the initial letter capitalized and followed by their name in abbreviation (For example, Lian-Sheng Ma is abbreviated as Ma LS, Bo-Rong Pan as Pan BR) Book title. Publication number. Publication place: Publication press, Year: start page and end page.

Format
Journals

English journal article (list all authors and include the PMID where applicable)

1 **Grover VP**, Dresner MA, Forton DM, Counsell S, Larkman DJ, Patel N, Thomas HC, Taylor-Robinson SD. Current and future applications of magnetic resonance imaging and spectroscopy of the brain in hepatic encephalopathy. *World J Gastroenterol* 2006; **12**: 2969-2978 [PMID: 16718775]

Chinese journal article (list all authors and include the PMID where applicable)

2 **Lin GZ**, Wang XZ, Wang P, Lin J, Yang FD. Immunologic effect of Jianpi Yishen decoction in treatment of Pixu-diarrhoea. *Shijie Huaren Xiaohua Zazhi* 1999; **7**: 285-287

In press

3 **Tian D**, Araki H, Stahl E, Bergelson J, Kreitman M. Signature of balancing selection in Arabidopsis. *Proc Natl Acad Sci U S A* 2006; In press

Organization as author

4 **Diabetes Prevention Program Research Group**. Hypertension, insulin, and proinsulin in participants with impaired glucose tolerance. *Hypertension* 2002; **40**: 679-686 [PMID: 12411462]

Both personal authors and an organization as author

5 **Vallancien G**, Emberton M, Harving N, van Moorselaar RJ; Alf-One Study Group. Sexual dysfunction in 1, 274 European men suffering from lower urinary tract symptoms. *J Urol* 2003; **169**: 2257-2261 [PMID: 12771764]

No author given

6 21st century heart solution may have a sting in the tail. *BMJ* 2002; **325**: 184 [PMID: 12142303]

Volume with supplement

7 **Geraud G**, Spierings EL, Keywood C. Tolerability and safety of frovatriptan with short- and long-term use for treatment of migraine and in comparison with sumatriptan. *Headache* 2002; **42** Suppl 2: S93-99 [PMID: 12028325]

Issue with no volume

8 **Banit DM**, Kaufer H, Hartford JM. Intraoperative frozen section analysis in revision total joint arthroplasty. *Clin Orthop Relat Res* 2002; (**401**): 230-238 [PMID: 12151900]

No volume or issue

9 Outreach: bringing HIV-positive individuals into care. *HRSA Careaction* 2002; 1-6 [PMID: 12154804]

Books

Personal author(s)

10 **Sherlock S**, Dooley J. Diseases of the liver and billiary system. 9th ed. Oxford: Blackwell Sci Pub, 1993: 258-296

Chapter in a book (list all authors)

11 **Lam SK**. Academic investigator's perspectives of medical treatment for peptic ulcer. In: Swabb EA, Azabo S. Ulcer disease: investigation and basis for therapy. New York: Marcel Dekker, 1991: 431-450

Author(s) and editor(s)

12 **Breedlove GK**, Schorfheide AM. Adolescent pregnancy. 2nd ed. Wieczorek RR, editor. White Plains (NY): March of Dimes Education Services, 2001: 20-34

Conference proceedings

13 **Harnden P**, Joffe JK, Jones WG, editors. Germ cell tumours V. Proceedings of the 5th Germ Cell Tumour Conference; 2001 Sep 13-15; Leeds, UK. New York: Springer, 2002: 30-56

Conference paper

14 **Christensen S**, Oppacher F. An analysis of Koza's computational effort statistic for genetic programming. In: Foster JA, Lutton E, Miller J, Ryan C, Tettamanzi AG, editors. Genetic programming. EuroGP 2002: Proceedings of the 5th European Conference on Genetic Programming; 2002 Apr 3-5; Kinsdale, Ireland. Berlin: Springer, 2002: 182-191

Electronic journal (list all authors)

Morse SS. Factors in the emergence of infectious diseases. Emerg Infect Dis serial online, 1995-01-03, cited 1996-06-05; 1(1): 24 screens. Available from: URL: http//www.cdc.gov/ncidod/EID/eid.htm

Patent (list all authors)

16 **Pagedas AC**, inventor; Ancel Surgical R&D Inc., assignee. Flexible endoscopic grasping and cutting device and positioning tool assembly. United States patent US 20020103498. 2002 Aug 1

Inappropriate references
Authors should always cite references that are relevant to their article, and avoid any inappropriate references. Inappropriate references include those that are linked with a hyphen and the difference between the two numbers at two sides of the hyphen is more than 5. For example, [1-6], [2-14] and [1, 3, 4-10, 22] are all considered as inappropriate references. Authors should not cite their own unrelated published articles.

Statistical data
Present as mean ± SD or mean ± SE.

Statistical expression
Express *t* test as *t* (in italics), *F* test as *F* (in italics), chi square test as χ^2 (in Greek), related coefficient as *r* (in italics), degree of freedom as γ (in Greek), sample number as *n* (in italics), and probability as *P* (in italics).

Units
Use SI units. For example: body mass, m (B) = 78 kg; blood pressure, *p*(B) = 16.2/12.3 kPa; incubation time, t (incubation) = 96 h, blood glucose concentration, c (glucose) 6.4 ± 2.1 mmol/L; blood CEA mass concentration, ρ (CEA) = 8.6 24.5 μg/L; CO_2 volume fraction, 50 mL/L CO_2 not 5% CO_2; likewise for 40 g/L formaldehyde, not 10% formalin; and mass fraction, 8 ng/g, *etc.* Arabic numerals such as 23, 243, 641 should be read 23 243 641.

The format about how to accurately write common units and quantum is at: http://www.wjgnet.com/wjg/help/15.doc

Abbreviations

Standard abbreviations should be defined in the abstract and on first mention in the text. In general, terms should not be abbreviated unless they are used repeatedly and the abbreviation is helpful to the reader. Permissible abbreviations are listed in Units, Symbols and Abbreviations: A Guide for Biological and Medical Editors and Authors (Ed. Baron DN, 1988) published by The Royal Society of Medicine, London. Certain commonly used abbreviations, such as DNA, RNA, HIV, LD50, PCR, HBV, ECG, WBC, RBC, CT, ESR, CSF, IgG, ELISA, PBS, ATP, EDTA, mAb, can be used directly without further mention.

Italics

Quantities: *t* time or temperature, *c* concentration, *A* area, *l* length, *m* mass, *V* volume.
Genotypes: *gyr*A, *arg* 1, *c myc*, *c fos*, *etc.*
Restriction enzymes: *Eco*RI, *Hin*dI, *Bam*HI, *Kbo* I, *Kpn* I, *etc.*
Biology: *H pylori, E coli, etc.*

SUBMISSION OF THE REVISED MANUSCRIPTS AFTER ACCEPTED

Please revise your article according to the revision policies of *WJG*. The revised version including manuscript and high-resolution image figures (if any) should be copied on a floppy or compact disk. Author should send the revised manuscript, along with printed high-resolution color or black and white photos, copyright transfer letter, the final check list for authors, and responses to reviewers by a courier (such as EMS) (submission of revised manuscript by e-mail or on the *WJG* Editorial Office Online System is NOT available at present).

Language evaluation

The language of a manuscript will be graded before sending for revision. (1) Grade A: priority publishing; (2) Grade B: minor language polishing; (3) Grade C: a great deal of language polishing; (4) Grade D: rejected. The revised articles should be in grade B or grade A.

Copyright assignment form

Please downloaded CAF from http://www.wjgnet.com/wjg/help/9.doc.

We certify that the material contained in this manuscript:

Ms:

Title:

is original, except when appropriately referenced to other sources, and that written permission has been granted by any existing copyright holders. We agree to transfer to WJG all rights of our manuscript, including: (1) all copyright ownership in all print and electronic formats; (2) the right to grant permission to republish or reprint the stated material in whole or in part, with or without a fee; (3) the right to print copies for free distribution or sale; (4) the right to republish the stated material in a collection of articles or in any other format. We also agree that our article be put on the Internet.

Criteria for authorship: The WJG requests and publishes information about contributions of each author named to the submitted study. Authorship credit should be based on (1)direct participation in the study, including substantial contributions to conception and design of study, or acquisition of data, or analysis and interpretation of data; (2) manuscript writing, including drafting the article, or revising it critically for important intellectual content; (3)supportive work, including statistical analysis of data, or acquisition of funding, or administration, technology and materials support, or supervision, or supportive contributions. Authors should meet at least one of the three conditions. The WJG does not publish co-first authors and co-corresponding authors.

We hereby assign copyright transfer to WJG if this paper is accepted.

Author Name in full (Full names should be provided, with first name first, followed by middle names and family name at the last, eg, Eamonn MM Quigley). Handwritten names are not accepted.

Author Name in abbreviation (Family name is put first in full, followed by middle names and first name in abbreviation with first letter in capital, eg, Quigley EMM). Handwritten names are not accepted.

1 Full Name: _____
Abbreviation Name: _____
Signed: _____
Date: _____

2 Full Name: _____
Abbreviation Name: _____
Signed: _____
Date: _____

3 Full Name: _____
Abbreviation Name: _____
Signed: _____
Date: _____

4 Full Name: _____
Abbreviation Name: _____
Signed: _____
Date: _____

5 Full Name: _____
Abbreviation Name: _____
Signed: _____
Date: _____

6 Full Name: _____
Abbreviation Name: _____
Signed: _____
Date: _____

7 Full Name: _____
Abbreviation Name: _____
Signed: _____
Date: _____

8 Full Name: _____
Abbreviation Name: _____
Signed: _____
Date: _____

9 Full Name: _____
Abbreviation Name: _____
Signed: _____
Date: _____

10 Full Name: _____
Abbreviation Name: _____
Signed: _____
Date: _____

Final check list for authors

The format is at: http://www.wjgnet.com/wjg/help/13.doc

Responses to reviewers

Please revise your article according to the comments/suggestions of reviewers. The format for responses to the reviewers' comments is at: http://www.wjgnet.com/wjg/help/10.doc

Proof of financial support

For paper supported by a foundation, authors should provide a copy of the document and serial number of the foundation.

Publication fee

Authors of accepted articles must pay publication fee.
EDITORIAL and LETTERS TO THE EDITOR are free of change.