

# World Journal of *Gastroenterology*

*World J Gastroenterol* 2017 August 14; 23(30): 5451-5644





## Editorial Board

2014-2017

The *World Journal of Gastroenterology* Editorial Board consists of 1375 members, representing a team of worldwide experts in gastroenterology and hepatology. They are from 68 countries, including Algeria (2), Argentina (7), Australia (31), Austria (9), Belgium (11), Brazil (20), Brunei Darussalam (1), Bulgaria (2), Cambodia (1), Canada (25), Chile (4), China (165), Croatia (2), Cuba (1), Czech (6), Denmark (2), Egypt (9), Estonia (2), Finland (6), France (20), Germany (58), Greece (31), Guatemala (1), Hungary (14), Iceland (1), India (33), Indonesia (2), Iran (10), Ireland (9), Israel (18), Italy (194), Japan (149), Jordan (1), Kuwait (1), Lebanon (7), Lithuania (1), Malaysia (1), Mexico (11), Morocco (1), Netherlands (5), New Zealand (4), Nigeria (3), Norway (6), Pakistan (6), Poland (12), Portugal (8), Puerto Rico (1), Qatar (1), Romania (10), Russia (3), Saudi Arabia (2), Singapore (7), Slovenia (2), South Africa (1), South Korea (69), Spain (51), Sri Lanka (1), Sudan (1), Sweden (12), Switzerland (5), Thailand (7), Trinidad and Tobago (1), Tunisia (2), Turkey (55), United Kingdom (49), United States (180), Venezuela (1), and Vietnam (1).

### EDITORS-IN-CHIEF

Stephen C Strom, *Stockholm*  
Andrzej S Tarnawski, *Long Beach*  
Damian Garcia-Olmo, *Madrid*

### ASSOCIATE EDITORS

Yung-Jue Bang, *Seoul*  
Vincent Di Martino, *Besancon*  
Daniel T Farkas, *Bronx*  
Roberto J Firpi, *Gainesville*  
Maria Gazouli, *Athens*  
Chung-Feng Huang, *Kaohsiung*  
Namir Katkhouda, *Los Angeles*  
Anna Kramvis, *Johannesburg*  
Wolfgang Kruis, *Cologne*  
Peter L Lakatos, *Budapest*  
Han Chu Lee, *Seoul*  
Christine McDonald, *Cleveland*  
Nahum Mendez-Sanchez, *Mexico City*  
George K Michalopoulos, *Pittsburgh*  
Suk Woo Nam, *Seoul*  
Shu-You Peng, *Hangzhou*  
Daniel von Renteln, *Montreal*  
Angelo Sangiovanni, *Milan*  
Hildegard M Schuller, *Knoxville*  
Dong-Wan Seo, *Seoul*  
Adrian John Stanley, *Glasgow*  
Jurgen Stein, *Frankfurt*  
Bei-Cheng Sun, *Nanjing*  
Yoshio Yamaoka, *Yufu*

### GUEST EDITORIAL BOARD MEMBERS

Jia-Ming Chang, *Taipei*  
Jane CJ Chao, *Taipei*

Kuen-Feng Chen, *Taipei*  
Tai-An Chiang, *Tainan*  
Yi-You Chiou, *Taipei*  
Seng-Kee Chuah, *Kaohsiung*  
Wan-Long Chuang, *Kaohsiung*  
How-Ran Guo, *Tainan*  
Ming-Chih Hou, *Taipei*  
Po-Shiuan Hsieh, *Taipei*  
Ching-Chuan Hsieh, *Chiayi county*  
Jun-Te Hsu, *Taoyuan*  
Chung-Ping Hsu, *Taichung*  
Chien-Ching Hung, *Taipei*  
Chao-Hung Hung, *Kaohsiung*  
Chen-Guo Ker, *Kaohsiung*  
Yung-Chih Lai, *Taipei*  
Teng-Yu Lee, *Taichung City*  
Wei-Jei Lee, *Taoyuan*  
Jin-Ching Lee, *Kaohsiung*  
Jen-Kou Lin, *Taipei*  
Ya-Wen Lin, *Taipei*  
Hui-kang Liu, *Taipei*  
Min-Hsiung Pan, *Taipei*  
Bor-Shyang Sheu, *Tainan*  
Hon-Yi Shi, *Kaohsiung*  
Fung-Chang Sung, *Taichung*  
Dar-In Tai, *Taipei*  
Jung-Fa Tsai, *Kaohsiung*  
Yao-Chou Tsai, *New Taipei City*  
Chih-Chi Wang, *Kaohsiung*  
Liang-Shun Wang, *New Taipei City*  
Hsiu-Po Wang, *Taipei*  
Jaw-Yuan Wang, *Kaohsiung*  
Yuan-Huang Wang, *Taipei*  
Yuan-Chuen Wang, *Taichung*

Deng-Chyang Wu, *Kaohsiung*  
Shun-Fa Yang, *Taichung*  
Hsu-Heng Yen, *Changhua*

### MEMBERS OF THE EDITORIAL BOARD



#### Algeria

Saadi Berkane, *Algiers*  
Samir Rouabhia, *Batna*



#### Argentina

N Tolosa de Talamoni, *Córdoba*  
Eduardo de Santibanes, *Buenos Aires*  
Bernardo Frider, *Capital Federal*  
Guillermo Mazzolini, *Pilar*  
Carlos Jose Pirola, *Buenos Aires*  
Bernabé Matías Quesada, *Buenos Aires*  
María Fernanda Troncoso, *Buenos Aires*



#### Australia

Golo Ahlenstiel, *Westmead*  
Minoti V Apte, *Sydney*  
Jacqueline S Barrett, *Melbourne*  
Michael Beard, *Adelaide*  
Filip Braet, *Sydney*  
Guy D Eslick, *Sydney*  
Christine Feinle-Bisset, *Adelaide*  
Mark D Gorrell, *Sydney*  
Michael Horowitz, *Adelaide*

Gordon Stanley Howarth, *Roseworthy*  
 Seungha Kang, *Brisbane*  
 Alfred King Lam, *Gold Coast*  
 Ian C Lawrance, *Perth/Fremantle*  
 Barbara Anne Leggett, *Brisbane*  
 Daniel A Lemberg, *Sydney*  
 Rupert W Leong, *Sydney*  
 Finlay A Macrae, *Victoria*  
 Vance Matthews, *Melbourne*  
 David L Morris, *Sydney*  
 Reme Mountifield, *Bedford Park*  
 Hans J Netter, *Melbourne*  
 Nam Q Nguyen, *Adelaide*  
 Liang Qiao, *Westmead*  
 Rajvinder Singh, *Adelaide*  
 Ross Cyril Smith, *St Leonards*  
 Kevin J Spring, *Sydney*  
 Debbie Trinder, *Fremantle*  
 Daniel R van Langenberg, *Box Hill*  
 David Ian Watson, *Adelaide*  
 Desmond Yip, *Garran*  
 Li Zhang, *Sydney*



#### **Austria**

Felix Aigner, *Innsbruck*  
 Gabriela A Berlakovich, *Vienna*  
 Herwig R Cerwenka, *Graz*  
 Peter Ferenci, *Wien*  
 Alfred Gangl, *Vienna*  
 Kurt Lenz, *Linz*  
 Markus Peck-Radosavljevic, *Vienna*  
 Markus Raderer, *Vienna*  
 Stefan Riss, *Vienna*



#### **Belgium**

Michael George Adler, *Brussels*  
 Benedicte Y De Winter, *Antwerp*  
 Mark De Ridder, *Jette*  
 Olivier Detry, *Liege*  
 Denis Dufrane Dufrane, *Brussels*  
 Sven M Francque, *Edegem*  
 Nikos Kotzampassakis, *Liège*  
 Geert KMM Robaey, *Genk*  
 Xavier Sagaert, *Leuven*  
 Peter Starkel, *Brussels*  
 Eddie Wisse, *Keerbergen*



#### **Brazil**

SMP Balzan, *Santa Cruz do Sul*  
 JLF Caboclo, *Sao Jose do Rio Preto*  
 Fábio Guilherme Campos, *Sao Paulo*  
 Claudia RL Cardoso, *Rio de Janeiro*  
 Roberto J Carvalho-Filho, *Sao Paulo*  
 Carla Daltro, *Salvador*  
 José Sebastiao dos Santos, *Ribeirão Preto*  
 Eduardo LR Mello, *Rio de Janeiro*  
 Stihela Maria Murad-Regadas, *Fortaleza*  
 Claudia PMS Oliveira, *Sao Paulo*  
 Júlio C Pereira-Lima, *Porto Alegre*  
 Marcos V Perini, *Sao Paulo*  
 Vietla Satyanarayana Rao, *Fortaleza*

Raquel Rocha, *Salvador*  
 AC Simoes e Silva, *Belo Horizonte*  
 Mauricio F Silva, *Porto Alegre*  
 Aytan Miranda Sipahi, *Sao Paulo*  
 Rosa Leonôra Salerno Soares, *Niterói*  
 Cristiane Valle Tovo, *Porto Alegre*  
 Eduardo Garcia Vilela, *Belo Horizonte*



#### **Brunei Darussalam**

Vui Heng Chong, *Bandar Seri Begawan*



#### **Bulgaria**

Tanya Kirilova Kadiyska, *Sofia*  
 Mihaela Petrova, *Sofia*



#### **Cambodia**

Francois Rouet, *Phnom Penh*



#### **Canada**

Brian Bressler, *Vancouver*  
 Frank J Burczynski, *Winnipeg*  
 Wangxue Chen, *Ottawa*  
 Francesco Crea, *Vancouver*  
 Jane A Foster, *Hamilton*  
 Hugh J Freeman, *Vancouver*  
 Shahrokh M Ghobadloo, *Ottawa*  
 Yuewen Gong, *Winnipeg*  
 Philip H Gordon, *Quebec*  
 Rakesh Kumar, *Edmonton*  
 Wolfgang A Kunze, *Hamilton*  
 Patrick Labonte, *Laval*  
 Zhikang Peng, *Winnipeg*  
 Jayadev Raju, *Ottawa*  
 Maitreyi Raman, *Calgary*  
 Giada Sebastiani, *Montreal*  
 Maida J Sewitch, *Montreal*  
 Eldon A Shaffer, *Alberta*  
 Christopher W Teshima, *Edmonton*  
 Jean Sévigny, *Québec*  
 Pingchang Yang, *Hamilton*  
 Pingchang Yang, *Hamilton*  
 Eric M Yoshida, *Vancouver*  
 Bin Zheng, *Edmonton*



#### **Chile**

Marcelo A Beltran, *La Serena*  
 Flavio Nervi, *Santiago*  
 Adolfo Parra-Blanco, *Santiago*  
 Alejandro Soza, *Santiago*



#### **China**

Zhao-Xiang Bian, *Hong Kong*  
 San-Jun Cai, *Shanghai*  
 Guang-Wen Cao, *Shanghai*  
 Long Chen, *Nanjing*  
 Ru-Fu Chen, *Guangzhou*  
 George G Chen, *Hong Kong*

Li-Bo Chen, *Wuhan*  
 Jia-Xu Chen, *Beijing*  
 Hong-Song Chen, *Beijing*  
 Lin Chen, *Beijing*  
 Yang-Chao Chen, *Hong Kong*  
 Zhen Chen, *Shanghai*  
 Ying-Sheng Cheng, *Shanghai*  
 Kent-Man Chu, *Hong Kong*  
 Zhi-Jun Dai, *Xi'an*  
 Jing-Yu Deng, *Tianjin*  
 Yi-Qi Du, *Shanghai*  
 Zhi Du, *Tianjin*  
 Hani El-Nezami, *Hong Kong*  
 Bao-Ying Fei, *Hangzhou*  
 Chang-Ming Gao, *Nanjing*  
 Jian-Ping Gong, *Chongqing*  
 Zuo-Jiong Gong, *Wuhan*  
 Jing-Shan Gong, *Shenzhen*  
 Guo-Li Gu, *Beijing*  
 Yong-Song Guan, *Chengdu*  
 Mao-Lin Guo, *Luoyang*  
 Jun-Ming Guo, *Ningbo*  
 Yan-Mei Guo, *Shanghai*  
 Xiao-Zhong Guo, *Shenyang*  
 Guo-Hong Han, *Xi'an*  
 Ming-Liang He, *Hong Kong*  
 Peng Hou, *Xi'an*  
 Zhao-Hui Huang, *Wuxi*  
 Feng Ji, *Hangzhou*  
 Simon Law, *Hong Kong*  
 Yan-Chang Lei, *Hangzhou*  
 Yu-Yuan Li, *Guangzhou*  
 Meng-Sen Li, *Haikou*  
 Shu-De Li, *Shanghai*  
 Zong-Fang Li, *Xi'an*  
 Qing-Quan Li, *Shanghai*  
 Kang Li, *Lasa*  
 Han Liang, *Tianjin*  
 Xing'e Liu, *Hangzhou*  
 Zheng-Wen Liu, *Xi'an*  
 Xiao-Fang Liu, *Yantai*  
 Bin Liu, *Tianjin*  
 Quan-Da Liu, *Beijing*  
 Hai-Feng Liu, *Beijing*  
 Fei Liu, *Shanghai*  
 Ai-Guo Lu, *Shanghai*  
 He-Sheng Luo, *Wuhan*  
 Xiao-Peng Ma, *Shanghai*  
 Yong Meng, *Shantou*  
 Ke-Jun Nan, *Xi'an*  
 Siew Chien Ng, *Hong Kong*  
 Simon SM Ng, *Hong Kong*  
 Zhao-Shan Niu, *Qingdao*  
 Di Qu, *Shanghai*  
 Ju-Wei Mu, *Beijing*  
 Rui-Hua Shi, *Nanjing*  
 Bao-Min Shi, *Shanghai*  
 Xiao-Dong Sun, *Hangzhou*  
 Si-Yu Sun, *Shenyang*  
 Guang-Hong Tan, *Haikou*  
 Wen-Fu Tang, *Chengdu*  
 Anthony YB Teoh, *Hong Kong*  
 Wei-Dong Tong, *Chongqing*  
 Eric Tse, *Hong Kong*  
 Hong Tu, *Shanghai*



Rong Tu, *Haikou*  
 Jian-She Wang, *Shanghai*  
 Kai Wang, *Jinan*  
 Xiao-Ping Wang, *Xianyang*  
 Xiu-Yan Wang, *Shanghai*  
 Dao-Rong Wang, *Yangzhou*  
 De-Sheng Wang, *Xi'an*  
 Chun-You Wang, *Wuhan*  
 Ge Wang, *Chongqing*  
 Xi-Shan Wang, *Harbin*  
 Wei-hong Wang, *Beijing*  
 Zhen-Ning Wang, *Shenyang*  
 Wai Man Raymond Wong, *Hong Kong*  
 Chun-Ming Wong, *Hong Kong*  
 Jian Wu, *Shanghai*  
 Sheng-Li Wu, *Xi'an*  
 Wu-Jun Wu, *Xi'an*  
 Qing Xia, *Chengdu*  
 Yan Xin, *Shenyang*  
 Dong-Ping Xu, *Beijing*  
 Jian-Min Xu, *Shanghai*  
 Wei Xu, *Changchun*  
 Ming Yan, *Jinan*  
 Xin-Min Yan, *Kunming*  
 Yi-Qun Yan, *Shanghai*  
 Feng Yang, *Shanghai*  
 Yong-Ping Yang, *Beijing*  
 He-Rui Yao, *Guangzhou*  
 Thomas Yau, *Hong Kong*  
 Winnie Yeo, *Hong Kong*  
 Jing You, *Kunming*  
 Jian-Qing Yu, *Wuhan*  
 Ying-Yan Yu, *Shanghai*  
 Wei-Zheng Yang, *Chengdu*  
 Zong-Ming Zhang, *Beijing*  
 Dian-Liang Zhang, *Qingdao*  
 Ya-Ping Zhang, *Shijiazhuang*  
 You-Cheng Zhang, *Lanzhou*  
 Jian-Zhong Zhang, *Beijing*  
 Ji-Yuan Zhang, *Beijing*  
 Hai-Tao Zhao, *Beijing*  
 Jian Zhao, *Shanghai*  
 Jian-Hong Zhong, *Nanning*  
 Ying-Qiang Zhong, *Guangzhou*  
 Ping-Hong Zhou, *Shanghai*  
 Yan-Ming Zhou, *Xiamen*  
 Tong Zhou, *Nanchong*  
 Li-Ming Zhou, *Chengdu*  
 Guo-Xiong Zhou, *Nantong*  
 Feng-Shang Zhu, *Shanghai*  
 Jiang-Fan Zhu, *Shanghai*  
 Zhao-Hui Zhu, *Beijing*



#### **Croatia**

Tajana Filipec Kanizaj, *Zagreb*  
 Mario Tadic, *Zagreb*



#### **Cuba**

Damian Casadesus, *Havana*



#### **Czech**

Jan Bures, *Hradec Kralove*  
 Marcela Kopacova, *Hradec Kralove*

Otto Kucera, *Hradec Kralove*  
 Marek Minarik, *Prague*  
 Pavel Soucek, *Prague*  
 Miroslav Zavoral, *Prague*



#### **Denmark**

Vibeke Andersen, *Odense*  
 E Michael Danielsen, *Copenhagen*



#### **Egypt**

Mohamed MM Abdel-Latif, *Assiut*  
 Hussein Atta, *Cairo*  
 Ashraf Elbahrawy, *Cairo*  
 Mortada Hassan El-Shabrawi, *Cairo*  
 Mona El Said El-Raziky, *Cairo*  
 Elrashdy M Redwan, *New Borg Alrab*  
 Zeinab Nabil Ahmed Said, *Cairo*  
 Ragaa HM Salama, *Assiut*  
 Maha Maher Shehata, *Mansoura*



#### **Estonia**

Margus Lember, *Tartu*  
 Tamara Vorobjova, *Tartu*



#### **Finland**

Marko Kalliomäki, *Turku*  
 Thomas Kietzmann, *Oulu*  
 Kaija-Leena Kolho, *Helsinki*  
 Eija Korkeila, *Turku*  
 Heikki Makisalo, *Helsinki*  
 Tanja Pessi, *Tampere*



#### **France**

Armando Abergel Clermont, *Ferrand*  
 Elie K Chouillard, *Polssy*  
 Pierre Cordelier, *Toulouse*  
 Pascal P Crenn, *Garches*  
 Catherine Daniel, *Lille*  
 Fanny Daniel, *Paris*  
 Cedric Dray, *Toulouse*  
 Benoit Foligne, *Lille*  
 Jean-Noel Freund, *Strasbourg*  
 Hervé Guillou, *Toulouse*  
 Nathalie Janel, *Paris*  
 Majid Khatib, *Bordeaux*  
 Jacques Marescaux, *Strasbourg*  
 Jean-Claude Marie, *Paris*  
 Driffa Moussata, *Pierre Benite*  
 Hang Nguyen, *Clermont-Ferrand*  
 Hugo Perazzo, *Paris*  
 Alain L Servin, *Chatenay-Malabry*  
 Chang Xian Zhang, *Lyon*



#### **Germany**

Stavros A Antoniou, *Monchengladbach*  
 Erwin Biecker, *Siegburg*  
 Hubert E Blum, *Freiburg*

Thomas Bock, *Berlin*  
 Katja Breitkopf-Heinlein, *Mannheim*  
 Elke Cario, *Essen*  
 Güralp Onur Ceyhan, *Munich*  
 Angel Cid-Arregui, *Heidelberg*  
 Michael Clemens Roggendorf, *München*  
 Christoph F Dietrich, *Bad Mergentheim*  
 Valentin Fuhrmann, *Hamburg*  
 Nikolaus Gassler, *Aachen*  
 Andreas Geier, *Wuerzburg*  
 Markus Gerhard, *Munich*  
 Anton Gillissen, *Muenster*  
 Thorsten Oliver Goetze, *Offenbach*  
 Daniel Nils Gotthardt, *Heidelberg*  
 Robert Grützmann, *Dresden*  
 Thilo Hackert, *Heidelberg*  
 Claus Hellerbrand, *Regensburg*  
 Harald Peter Hoensch, *Darmstadt*  
 Jens Hoeppner, *Freiburg*  
 Richard Hummel, *Muenster*  
 Jakob Robert Izbicki, *Hamburg*  
 Gernot Maximilian Kaiser, *Essen*  
 Matthias Kapischke, *Hamburg*  
 Michael Keese, *Frankfurt*  
 Andrej Khandoga, *Munich*  
 Jorg Kleeff, *Munich*  
 Alfred Koenigsrainer, *Tuebingen*  
 Peter Christopher Konturek, *Saalfeld*  
 Michael Linnebacher, *Rostock*  
 Stefan Maier, *Kaufbeuren*  
 Oliver Mann, *Hamburg*  
 Marc E Martignoni, *Munic*  
 Thomas Minor, *Bonn*  
 Oliver Moeschler, *Osnabrueck*  
 Jonas Mudter, *Eutin*  
 Sebastian Mueller, *Heidelberg*  
 Matthias Ocker, *Berlin*  
 Andreas Ommer, *Essen*  
 Albrecht Piiper, *Frankfurt*  
 Esther Raskopf, *Bonn*  
 Christoph Reichel, *Bad Brückenau*  
 Elke Roeb, *Giessen*  
 Udo Rolle, *Frankfurt*  
 Karl-Herbert Schafer, *Zweibrücken*  
 Peter Schemmer, *Heidelberg*  
 Andreas G Schreyer, *Regensburg*  
 Manuel A Silva, *Penzberg*  
 Georgios C Sotiropoulos, *Essen*  
 Ulrike S Stein, *Berlin*  
 Dirk Uhlmann, *Leipzig*  
 Michael Weiss, *Halle*  
 Hong-Lei Weng, *Mannheim*  
 Karsten Wursthorn, *Hamburg*



#### **Greece**

Alexandra Alexopoulou, *Athens*  
 Nikolaos Antonakopoulos, *Athens*  
 Stelios F Assimakopoulos, *Patras*  
 Grigoris Chatzimavroudis, *Thessaloniki*  
 Evangelos Cholongitas, *Thessaloniki*  
 Gregory Christodoulidis, *Larisa*  
 George N Dalekos, *Larisa*  
 Urania Georgopoulou, *Athens*  
 Eleni Gigi, *Thessaloniki*



Stavros Gourgiotis, *Athens*  
 Leontios J Hadjileontiadis, *Thessaloniki*  
 Thomas Hyphantis, *Ioannina*  
 Ioannis Kanellos, *Thessaloniki*  
 Stylianos Karatapanis, *Rhodes*  
 Michael Koutsilieris, *Athens*  
 Spiros D Ladas, *Athens*  
 Theodoros K Liakakos, *Athens*  
 Emanuel K Manesis, *Athens*  
 Spiliot Manolakopoulos, *Athens*  
 Gerassimos John Mantzaris, *Athens*  
 Athanasios D Marinis, *Piraeus*  
 Nikolaos Ioannis Nikiteas, *Athens*  
 Konstantinos X Papamichael, *Athens*  
 George Sgourakis, *Athens*  
 Konstantinos C Thomopoulos, *Patras*  
 Konstantinos Triantafyllou, *Athens*  
 Christos Triantos, *Patras*  
 Georgios Zacharakis, *Athens*  
 Petros Zezos, *Alexandroupolis*  
 Demosthenes E Ziogas, *Ioannina*



#### **Guatemala**

Carlos Maria Parellada, *Guatemala*



#### **Hungary**

Mihaly Boros, *Szeged*  
 Tamás Decsi, *Pécs*  
 Gyula Farkas, *Szeged*  
 Andrea Furka, *Debrecen*  
 Y vette Mandi, *Szeged*  
 Peter L Lakatos, *Budapest*  
 Pal Miheller, *Budapest*  
 Tamás Molnar, *Szeged*  
 Attila Olah, *Gyor*  
 Maria Papp, *Debrecen*  
 Ferenc Sipos, *Budapest*  
 Miklós Tanyi, *Debrecen*  
 Tibor Wittmann, *Szeged*



#### **Iceland**

Tryggvi Bjorn Stefánsson, *Reykjavík*



#### **India**

Brij B Agarwal, *New Delhi*  
 Deepak N Amarapurkar, *Mumbai*  
 Shams ul Bari, *Srinagar*  
 Sriparna Basu, *Varanasi*  
 Runu Chakravarty, *Kolkata*  
 Devendra C Desai, *Mumbai*  
 Nutan D Desai, *Mumbai*  
 Suneela Sunil Dhaneshwar, *Pune*  
 Radha K Dhiman, *Chandigarh*  
 Pankaj Garg, *Mohali*  
 Uday C Ghoshal, *Lucknow*  
 Kalpesh Jani, *Vadodara*  
 Premashis Kar, *New Delhi*  
 Jyotdeep Kaur, *Chandigarh*  
 Rakesh Kochhar, *Chandigarh*  
 Pradyumna K Mishra, *Mumbai*

Asish K Mukhopadhyay, *Kolkata*  
 Imtiyaz Murtaza, *Srinagar*  
 P Nagarajan, *New Delhi*  
 Samiran Nundy, *Delhi*  
 Gopal Pande, *Hyderabad*  
 Benjamin Perakath, *Vellore*  
 Arun Prasad, *New Delhi*  
 D Nageshwar Reddy, *Hyderabad*  
 Lekha Saha, *Chandigarh*  
 Sundeep Singh Saluja, *New Delhi*  
 Mahesh Prakash Sharma, *New Delhi*  
 Sadiq Saleem Sikora, *Bangalore*  
 Sarman Singh, *New Delhi*  
 Rajeev Sinha, *Jhansi*  
 Rupjyoti Talukdar, *Hyderabad*  
 Rakesh Kumar Tandon, *New Delhi*  
 Narayanan Thirumoorthy, *Coimbatore*



#### **Indonesia**

David Handoyo Muljono, *Jakarta*  
 Andi Utama, *Jakarta*



#### **Iran**

Arezo Aghakhani, *Tehran*  
 Seyed Mohsen Dehghani, *Shiraz*  
 Ahad Eshraghian, *Shiraz*  
 Hossein Khedmat, *Tehran*  
 Sadegh Massarrat, *Tehran*  
 Marjan Mohammadi, *Tehran*  
 Roja Rahimi, *Tehran*  
 Farzaneh Sabahi, *Tehran*  
 Majid Sadeghizadeh, *Tehran*  
 Farideh Siavoshi, *Tehran*



#### **Ireland**

Gary Alan Bass, *Dublin*  
 David J Brayden, *Dublin*  
 Ronan A Cahill, *Dublin*  
 Glen A Doherty, *Dublin*  
 Liam J Fanning, *Cork*  
 Barry Philip McMahon, *Dublin*  
 RossMcManus, *Dublin*  
 Dervla O'Malley, *Cork*  
 Sinead M Smith, *Dublin*



#### **Israel**

Dan Carter, *Ramat Gan*  
 Jorge-Shmuel Delgado, *Metar*  
 Eli Magen, *Ashdod*  
 Nitsan Maharshak, *Tel Aviv*  
 Shaul Mordechai, *Beer Sheva*  
 Menachem Moshkowitz, *Tel Aviv*  
 William Bahij Nseir, *Nazareth*  
 Shimon Reif, *Jerusalem*  
 Ram Reifen, *Rehovot*  
 Ariella Bar-Gil Shitrit, *Jerusalem*  
 Noam Shussman, *Jerusalem*  
 Igor Sukhotnik, *Haifa*  
 Nir Wasserberg, *Petach Tikva*  
 Jacob Yahav, *Rehovot*

Doron Levi Zamir, *Gedera*  
 Shira Zelber-Sagi, *Haifa*  
 Romy Zemel, *Petach-Tikva*



#### **Italy**

Ludovico Abenavoli, *Catanzaro*  
 Luigi Elio Adinolfi, *Naples*  
 Carlo Virginio Agostoni, *Milan*  
 Anna Alisi, *Rome*  
 Piero Luigi Almasio, *Palermo*  
 Donato Francesco Altomare, *Bari*  
 Amedeo Amedei, *Florence*  
 Pietro Andreone, *Bologna*  
 Imerio Angriman, *Padova*  
 Vito Annese, *Florence*  
 Paolo Aurello, *Rome*  
 Salvatore Auricchio, *Naples*  
 Gian Luca Baiocchi, *Brescia*  
 Gianpaolo Balzano, *Milan*  
 Antonio Basoli, *Rome*  
 Gabrio Bassotti, *San Sisto*  
 Mauro Bernardi, *Bologna*  
 Alberto Biondi, *Rome*  
 Ennio Biscaldi, *Genova*  
 Massimo Bolognesi, *Padua*  
 Luigi Bonavina, *Milano*  
 Aldo Bove, *Chieti*  
 Raffaele Bruno, *Pavia*  
 Luigi Bruscianno, *Napoli*  
 Giuseppe Cabibbo, *Palermo*  
 Carlo Calabrese, *Bologna*  
 Daniele Calistri, *Meldola*  
 Vincenza Calvaruso, *Palermo*  
 Lorenzo Camellini, *Reggio Emilia*  
 Marco Candela, *Bologna*  
 Raffaele Capasso, *Naples*  
 Lucia Carulli, *Modena*  
 Renato David Caviglia, *Rome*  
 Luigina Cellini, *Chieti*  
 Giuseppe Chiarioni, *Verona*  
 Claudio Chiesa, *Rome*  
 Michele Cicala, *Roma*  
 Rachele Ciccocioppo, *Pavia*  
 Sandro Contini, *Parma*  
 Gaetano Corso, *Foggia*  
 Renato Costi, *Parma*  
 Alessandro Cucchetti, *Bologna*  
 Rosario Cuomo, *Napoli*  
 Giuseppe Currò, *Messina*  
 Paola De Nardi, *Milano*  
 Giovanni D De Palma, *Naples*  
 Raffaele De Palma, *Napoli*  
 Giuseppina De Petro, *Brescia*  
 Valli De Re, *Aviano*  
 Paolo De Simone, *Pisa*  
 Giuliana Decorti, *Trieste*  
 Emanuele Miraglia del Giudice, *Napoli*  
 Isidoro Di Carlo, *Catania*  
 Matteo Nicola Dario Di Minno, *Naples*  
 Massimo Donadelli, *Verona*  
 Mirko D'Onofrio, *Verona*  
 Maria Pina Dore, *Sassari*  
 Luca Elli, *Milano*  
 Massimiliano Fabozzi, *Aosta*  
 Massimo Falconi, *Ancona*

Ezio Falletto, *Turin*  
 Silvia Fargion, *Milan*  
 Matteo Fassan, *Verona*  
 Gianfranco Delle Fave, *Roma*  
 Alessandro Federico, *Naples*  
 Francesco Feo, *Sassari*  
 Davide Festi, *Bologna*  
 Natale Figura, *Siena*  
 Vincenzo Formica, *Rome*  
 Mirella Fraquelli, *Milan*  
 Marzio Frazzoni, *Modena*  
 Walter Fries, *Messina*  
 Gennaro Galizia, *Naples*  
 Andrea Galli, *Florence*  
 Matteo Garcovich, *Rome*  
 Eugenio Gaudio, *Rome*  
 Paola Ghorzo, *Genoa*  
 Edoardo G Giannini, *Genova*  
 Luca Gianotti, *Monza*  
 Maria Cecilia Giron, *Padova*  
 Alberto Grassi, *Rimini*  
 Gabriele Grassi, *Trieste*  
 Francesco Greco, *Bergamo*  
 Luigi Greco, *Naples*  
 Antonio Grieco, *Rome*  
 Fabio Grizzi, *Rozzano*  
 Laurino Grossi, *Pescara*  
 Simone Guglielmetti, *Milan*  
 Tiberiu Hershcovici, *Jerusalem*  
 Calogero Iacono, *Verona*  
 Enzo Ierardi, *Bari*  
 Amedeo Indriolo, *Bergamo*  
 Raffaele Iorio, *Naples*  
 Paola Iovino, *Salerno*  
 Angelo A Izzo, *Naples*  
 Loretta Kondili, *Rome*  
 Filippo La Torre, *Rome*  
 Giuseppe La Torre, *Rome*  
 Giovanni Latella, *L'Aquila*  
 Salvatore Leonardi, *Catania*  
 Massimo Libra, *Catania*  
 Anna Licata, *Palermo*  
 Carmela Loguercio, *Naples*  
 Amedeo Lonardo, *Modena*  
 Carmelo Luigiano, *Catania*  
 Francesco Luzzo, *Catanzaro*  
 Giovanni Maconi, *Milano*  
 Antonio Macrì, *Messina*  
 Mariano Malaguarnera, *Catania*  
 Francesco Manguso, *Napoli*  
 Tommaso Maria Manzia, *Rome*  
 Daniele Marrelli, *Siena*  
 Gabriele Masselli, *Rome*  
 Sara Massironi, *Milan*  
 Giuseppe Mazzarella, *Avellino*  
 Michele Milella, *Rome*  
 Giovanni Milito, *Rome*  
 Antonella d'Arminio Monforte, *Milan*  
 Fabrizio Montecucco, *Genoa*  
 Giovanni Monteleone, *Rome*  
 Mario Morino, *Torino*  
 Vincenzo La Mura, *Milan*  
 Gerardo Nardone, *Naples*  
 Riccardo Nascimbeni, *Brescia*  
 Gabriella Nesi, *Florence*  
 Giuseppe Nigri, *Rome*

Erica Novo, *Turin*  
 Veronica Ojetti, *Rome*  
 Michele Orditura, *Naples*  
 Fabio Pace, *Seriate*  
 Lucia Pacifico, *Rome*  
 Omero Alessandro Paoluzi, *Rome*  
 Valerio Pazienza, *San Giovanni Rotondo*  
 Rinaldo Pellicano, *Turin*  
 Adriano M Pellicelli, *Rome*  
 Nadia Peparini, *Ciampino*  
 Mario Pescatori, *Rome*  
 Antonio Picardi, *Rome*  
 Alberto Pilotto, *Padova*  
 Alberto Piperno, *Monza*  
 Anna Chiara Piscaglia, *Rome*  
 Maurizio Pompili, *Rome*  
 Francesca Romana Ponziani, *Rome*  
 Cosimo Prantero, *Rome*  
 Girolamo Ranieri, *Bari*  
 Carlo Ratto, *Tome*  
 Barbara Renga, *Perugia*  
 Alessandro Repici, *Rozzano*  
 Maria Elena Riccioni, *Rome*  
 Lucia Ricci-Vitiani, *Rome*  
 Luciana Rigoli, *Messina*  
 Mario Rizzetto, *Torino*  
 Ballarin Roberto, *Modena*  
 Roberto G Romanelli, *Florence*  
 Claudio Romano, *Messina*  
 Luca Roncucci, *Modena*  
 Cesare Ruffolo, *Treviso*  
 Lucia Sacchetti, *Napoli*  
 Rodolfo Sacco, *Pisa*  
 Lapo Sali, *Florence*  
 Romina Salpini, *Rome*  
 Giulio Aniello, *Santoro Treviso*  
 Armando Santoro, *Rozzano*  
 Edoardo Savarino, *Padua*  
 Marco Senzolo, *Padua*  
 Annalucia Serafino, *Rome*  
 Giuseppe S Sica, *Rome*  
 Pierpaolo Sileri, *Rome*  
 Cosimo Sperti, *Padua*  
 Vincenzo Stanghellini, *Bologna*  
 Cristina Stasi, *Florence*  
 Gabriele Stocco, *Trieste*  
 Roberto Tarquini, *Florence*  
 Mario Testini, *Bari*  
 Guido Torzilli, *Milan*  
 Guido Alberto Massimo, *Tiberio Brescia*  
 Giuseppe Toffoli, *Aviano*  
 Alberto Tommasini, *Trieste*  
 Francesco Tonelli, *Florence*  
 Cesare Tosetti Porretta, *Terme*  
 Lucio Trevisani, *Cona*  
 Guglielmo M Trovato, *Catania*  
 Mariapia Vairetti, *Pavia*  
 Luca Vittorio Valenti, *Milano*  
 Mariateresa T Ventura, *Bari*  
 Giuseppe Verlato, *Verona*  
 Marco Vivarelli, *Ancona*  
 Giovanni Li Volti, *Catania*  
 Giuseppe Zanotti, *Padua*  
 Vincenzo Zara, *Lecce*  
 Gianguglielmo Zehender, *Milan*  
 Anna Linda Zignego, *Florence*  
 Rocco Antonio Zoccali, *Messina*

Angelo Zullo, *Rome*



## Japan

Yasushi Adachi, *Sapporo*  
 Takafumi Ando, *Nagoya*  
 Masahiro Arai, *Tokyo*  
 Makoto Arai, *Chiba*  
 Takaaki Arigami, *Kagoshima*  
 Itaru Endo, *Yokohama*  
 Munechika Enjoji, *Fukuoka*  
 Shunji Fujimori, *Tokyo*  
 Yasuhiro Fujino, *Akashi*  
 Toshiyoshi Fujiwara, *Okayama*  
 Yosuke Fukunaga, *Tokyo*  
 Toshio Fukusato, *Tokyo*  
 Takahisa Furuta, *Hamamatsu*  
 Osamu Handa, *Kyoto*  
 Naoki Hashimoto, *Osaka*  
 Yoichi Hiasa, *Toon*  
 Masatsugu Hiraki, *Saga*  
 Satoshi Hirano, *Sapporo*  
 Keiji Hirata, *Fukuoka*  
 Toru Hiyama, *Higashihiroshima*  
 Akira Hokama, *Nishihara*  
 Shu Hoteya, *Tokyo*  
 Masao Ichinose, *Wakayama*  
 Tatsuya Ide, *Kurume*  
 Masahiro Iizuka, *Akita*  
 Toshiro Iizuka, *Tokyo*  
 Kenichi Ikejima, *Tokyo*  
 Tetsuya Ikemoto, *Tokushima*  
 Hiroyuki Imaeda, *Saitama*  
 Atsushi Imagawa, *Kan-onji*  
 Hiroo Imazu, *Tokyo*  
 Shuji Isaji, *Tsu*  
 Toru Ishikawa, *Niigata*  
 Toshiyuki Ishiwata, *Tokyo*  
 Soichi Itaba, *Kitakyushu*  
 Yoshiaki Iwasaki, *Okayama*  
 Tatehiro Kagawa, *Isehara*  
 Satoru Kakizaki, *Maebashi*  
 Naomi Kakushima, *Shizuoka*  
 Terumi Kamisawa, *Tokyo*  
 Akihide Kamiya, *Isehara*  
 Osamu Kanauchi, *Tokyo*  
 Tatsuo Kanda, *Chiba*  
 Shin Kariya, *Okayama*  
 Shigeyuki Kawa, *Matsumoto*  
 Takumi Kawaguchi, *Kurume*  
 Takashi Kawai, *Tokyo*  
 Soo Ryang Kim, *Kobe*  
 Shinsuke Kiriya, *Gunma*  
 Tsuneo Kitamura, *Urayasu*  
 Masayuki Kitano, *Osakasayama*  
 Hirotoshi Kobayashi, *Tokyo*  
 Hironori Koga, *Kurume*  
 Takashi Kojima, *Sapporo*  
 Satoshi Kokura, *Kyoto*  
 Shuhei Komatsu, *Kyoto*  
 Tadashi Kondo, *Tokyo*  
 Yasuteru Kondo, *Sendai*  
 Yasuhiro Kuramitsu, *Yamaguchi*  
 Yukinori Kurokawa, *Osaka*  
 Shin Maeda, *Yokohama*  
 Koutarou Maeda, *Toyoake*

Hitoshi Maruyama, *Chiba*  
 Atsushi Masamune, *Sendai*  
 Hiroyuki Matsubayashi, *Suntogun*  
 Akihisa Matsuda, *Inzai*  
 Hirofumi Matsui, *Tsukuba*  
 Akira Matsumori, *Kyoto*  
 Yoichi Matsuo, *Nagoya*  
 Y Matsuzaki, *Ami*  
 Toshihiro Mitaka, *Sapporo*  
 Kouichi Miura, *Akita*  
 Shinichi Miyagawa, *Matumoto*  
 Eiji Miyoshi, *Suita*  
 Toru Mizuguchi, *Sapporo*  
 Nobumasa Mizuno, *Nagoya*  
 Zenichi Morise, *Nagoya*  
 Tomohiko Moriyama, *Fukuoka*  
 Kunihiko Murase, *Tusima*  
 Michihiro Mutoh, *Tsukiji*  
 Akihito Nagahara, *Tokyo*  
 Hikaru Nagahara, *Tokyo*  
 Hidenari Nagai, *Tokyo*  
 Koichi Nagata, *Shimotsuke-shi*  
 Masaki Nagaya, *Kawasaki*  
 Hisato Nakajima, *Nishi-Shinbashi*  
 Toshifusa Nakajima, *Tokyo*  
 Hiroshi Nakano, *Kawasaki*  
 Hiroshi Nakase, *Kyoto*  
 Toshiyuki Nakayama, *Nagasaki*  
 Takahiro Nakazawa, *Nagoya*  
 Shoji Natsugoe, *Kagoshima City*  
 Tsutomu Nishida, *Suita*  
 Shuji Nomoto, *Naogya*  
 Sachiyo Nomura, *Tokyo*  
 Takeshi Ogura, *Takatsukishi*  
 Nobuhiro Ohkohchi, *Tsukuba*  
 Toshifumi Ohkusa, *Kashiwa*  
 Hirohide Ohnishi, *Akita*  
 Teruo Okano, *Tokyo*  
 Satoshi Osawa, *Hamamatsu*  
 Motoyuki Otsuka, *Tokyo*  
 Michitaka Ozaki, *Sapporo*  
 Satoru Saito, *Yokohama*  
 Naoaki Sakata, *Sendai*  
 Ken Sato, *Maebashi*  
 Toshiro Sato, *Tokyo*  
 Tomoyuki Shibata, *Toyoake*  
 Tomohiko Shimatani, *Kure*  
 Yukihiro Shimizu, *Nanto*  
 Tadashi Shimoyama, *Hirosaki*  
 Masayuki Sho, *Nara*  
 Ikuo Shoji, *Kobe*  
 Atsushi Sofuni, *Tokyo*  
 Takeshi Suda, *Niigata*  
 M Sugimoto, *Hamamatsu*  
 Ken Sugimoto, *Hamamatsu*  
 Haruhiko Sugimura, *Hamamatsu*  
 Shoichiro Sumi, *Kyoto*  
 Hidekazu Suzuki, *Tokyo*  
 Masahiro Tajika, *Nagoya*  
 Hitoshi Takagi, *Takasaki*  
 Toru Takahashi, *Niigata*  
 Yoshihisa Takahashi, *Tokyo*  
 Shinsuke Takeno, *Fukuoka*  
 Akihiro Tamori, *Osaka*  
 Kyosuke Tanaka, *Tsu*  
 Shinji Tanaka, *Hiroshima*

Atsushi Tanaka, *Tokyo*  
 Yasuhito Tanaka, *Nagoya*  
 Shinji Tanaka, *Tokyo*  
 Minoru Tomizawa, *Yotsukaido City*  
 Kyoko Tsukiyama-Kohara, *Kagoshima*  
 Takuya Watanabe, *Niigata*  
 Kazuhiro Watanabe, *Sendai*  
 Satoshi Yamagiwa, *Niigata*  
 Takayuki Yamamoto, *Yokkaichi*  
 Hiroshi Yamamoto, *Otsu*  
 Kosho Yamanouchi, *Nagasaki*  
 Ichiro Yasuda, *Gifu*  
 Yutaka Yata, *Maebashi-city*  
 Shin-ichi Yokota, *Sapporo*  
 Norimasa Yoshida, *Kyoto*  
 Hiroshi Yoshida, *Tama-City*  
 Hitoshi Yoshiji, *Kashihara*  
 Kazuhiko Yoshimatsu, *Tokyo*  
 Kentaro Yoshioka, *Toyoake*  
 Nobuhiro Zaima, *Nara*



#### **Jordan**

Khaled Ali Jadallah, *Irbid*



#### **Kuwait**

Islam Khan, *Kuwait*



#### **Lebanon**

Bassam N Abboud, *Beirut*  
 Kassem A Barada, *Beirut*  
 Marwan Ghosn, *Beirut*  
 Iyad A Issa, *Beirut*  
 Fadi H Mourad, *Beirut*  
 AIA Sharara, *Beirut*  
 Rita Slim, *Beirut*



#### **Lithuania**

Antanas Mickevicius, *Kaunas*



#### **Malaysia**

Huck Joo Tan, *Petaling Jaya*



#### **Mexico**

Richard A Awad, *Mexico City*  
 Carlos R Camara-Lemarroy, *Monterrey*  
 Norberto C Chavez-Tapia, *Mexico City*  
 Wolfgang Gaertner, *Mexico City*  
 Diego Garcia-Compean, *Monterrey*  
 Arturo Panduro, *Guadalajara*  
 OT Teramoto-Matsubara, *Mexico City*  
 Felix Tellez-Avila, *Mexico City*  
 Omar Vergara-Fernandez, *Mexico City*  
 Saúl Villa-Trevino, *Cuidad de México*



#### **Morocco**

Samir Ahboucha, *Khouribga*



#### **Netherlands**

Robert J de Knegt, *Rotterdam*  
 Tom Johannes Gerardus Gevers, *Nijmegen*  
 Menno Hoekstra, *Leiden*  
 BW Marcel Spanier, *Arnhem*  
 Karel van Erpecum, *Utrecht*



#### **New Zealand**

Leo K Cheng, *Auckland*  
 Andrew Stewart Day, *Christchurch*  
 Jonathan Barnes Koea, *Auckland*  
 Max Petrov, *Auckland*



#### **Nigeria**

Olufunmilayo Adenike Lesi, *Lagos*  
 Jesse Abiodun Otegbayo, *Ibadan*  
 Stella Ifeanyi Smith, *Lagos*



#### **Norway**

Trond Berg, *Oslo*  
 Trond Arnulf Buanes, *Krokkleiva*  
 Thomas de Lange, *Rud*  
 Magdy El-Salhy, *Stord*  
 Rasmus Goll, *Tromso*  
 Dag Arne Lihaug Hoff, *Aalesund*



#### **Pakistan**

Zaigham Abbas, *Karachi*  
 Usman A Ashfaq, *Faisalabad*  
 Muhammad Adnan Bawany, *Hyderabad*  
 Muhammad Idrees, *Lahore*  
 Saeed Sadiq Hamid, *Karachi*  
 Yasir Waheed, *Islamabad*



#### **Poland**

Thomas Brzozowski, *Cracow*  
 Magdalena Chmiela, *Lodz*  
 Krzysztof Jonderko, *Sosnowiec*  
 Anna Kasicka-Jonderko, *Sosnowiec*  
 Michal Kukla, *Katowice*  
 Tomasz Hubert Mach, *Krakow*  
 Agata Mulak, *Wroclaw*  
 Danuta Owczarek, *Kraków*  
 Piotr Socha, *Warsaw*  
 Piotr Stalke, *Gdansk*  
 Julian Teodor Swierczynski, *Gdansk*  
 Anna M Zawilak-Pawlik, *Wroclaw*



#### **Portugal**

Marie Isabelle Cremers, *Setubal*  
 Ceu Figueiredo, *Porto*  
 Ana Isabel Lopes, *Lisbon*  
 M Paula Macedo, *Lisboa*  
 Ricardo Marcos, *Porto*  
 Rui T Marinho, *Lisboa*  
 Guida Portela-Gomes, *Estoril*



Filipa F Vale, *Lisbon*



**Puerto Rico**

Caroline B Appleyard, *Ponce*



**Qatar**

Abdulbari Bener, *Doha*



**Romania**

Mihai Ciocirlan, *Bucharest*

Dan Lucian Dumitrascu, *Cluj-Napoca*

Carmen Fierbinteanu-Braticevici, *Bucharest*

Romeo G Mihaila, *Sibiu*

Lucian Negreanu, *Bucharest*

Adrian Saftoiu, *Craiova*

Andrada Seicean, *Cluj-Napoca*

Ioan Sporea, *Timisoara*

Letitia Adela Maria Streba, *Craiova*

Anca Trifan, *Iasi*



**Russia**

Victor Pasechnikov, *Stavropol*

Vasiliy Ivanovich Reshetnyak, *Moscow*

Vitaly Skoropad, *Obninsk*



**Saudi Arabia**

Abdul-Wahed N Meshikhes, *Dammam*

M Ezzedien Rabie, *Khamis Mushait*



**Singapore**

Brian KP Goh, *Singapore*

Richie Soong, *Singapore*

Ker-Kan Tan, *Singapore*

Kok-Yang Tan, *Singapore*

Yee-Joo Tan, *Singapore*

Mark Wong, *Singapore*

Hong Ping Xia, *Singapore*



**Slovenia**

Matjaz Homan, *Ljubljana*

Martina Perse, *Ljubljana*



**South Korea**

Sang Hoon Ahn, *Seoul*

Seung Hyuk Baik, *Seoul*

Soon Koo Baik, *Wonju*

Soo-Cheon Chae, *Iksan*

Byung-Ho Choe, *Daegu*

Suck Chei Choi, *Iksan*

Hoon Jai Chun, *Seoul*

Yeun-Jun Chung, *Seoul*

Young-Hwa Chung, *Seoul*

Ki-Baik Hahm, *Seongnam*

Sang Young Han, *Busan*

Seok Joo Han, *Seoul*

Seung-Heon Hong, *Iksan*

Jin-Hyeok Hwang, *Seoungnam*

Jeong Won Jang, *Seoul*

Jin-Young Jang, *Seoul*

Dae-Won Jun, *Seoul*

Young Do Jung, *Kwangju*

Gyeong Hoon Kang, *Seoul*

Sung-Bum Kang, *Seoul*

Koo Jeong Kang, *Daegu*

Ki Mun Kang, *Jinju*

Chang Moo Kang, *Seodaemun-gu*

Gwang Ha Kim, *Busan*

Sang Soo Kim, *Goyang-si*

Jin Cheon Kim, *Seoul*

Tae Il Kim, *Seoul*

Jin Hong Kim, *Suwon*

Kyung Mo Kim, *Seoul*

Kyongmin Kim, *Suwon*

Hyung-Ho Kim, *Seongnam*

Seoung Hoon Kim, *Goyang*

Sang Il Kim, *Seoul*

Hyun-Soo Kim, *Wonju*

Jung Mogg Kim, *Seoul*

Dong Yi Kim, *Gwangju*

Kyun-Hwan Kim, *Seoul*

Jong-Han Kim, *Ansan*

Sang Wun Kim, *Seoul*

Ja-Lok Ku, *Seoul*

Kyu Taek Lee, *Seoul*

Hae-Wan Lee, *Chuncheon*

Inchul Lee, *Seoul*

Jung Eun Lee, *Seoul*

Sang Chul Lee, *Daejeon*

Song Woo Lee, *Ansan-si*

Hyuk-Joon Lee, *Seoul*

Seong-Wook Lee, *Yongin*

Kil Yeon Lee, *Seoul*

Jong-Inn Lee, *Seoul*

Kyung A Lee, *Seoul*

Jong-Baeck Lim, *Seoul*

Eun-Yi Moon, *Seoul*

SH Noh, *Seoul*

Seung Woon Paik, *Seoul*

Won Sang Park, *Seoul*

Sung-Joo Park, *Iksan*

Kyung Sik Park, *Daegu*

Se Hoon Park, *Seoul*

Yoonkyung Park, *Gwangju*

Seung-Wan Ryu, *Daegu*

Il Han Song, *Cheonan*

Myeong Jun Song, *Daejeon*

Yun Kyoung Yim, *Daejeon*

Dae-Yeul Yu, *Daejeon*



**Spain**

Mariam Aguas, *Valencia*

Raul J Andrade, *Málaga*

Antonio Arroyo, *Elche*

Josep M Bordas, *Barcelona*

Lisardo Boscá, *Madrid*

Ricardo Robles Campos, *Murcia*

Jordi Camps, *Reus*

Carlos Cervera, *Barcelona*

Alfonso Clemente, *Granada*

Pilar Codoner-Franch, *Valencia*

Fernando J Corrales, *Pamplona*

Fermin Sánchez de Medina, *Granada*

Alberto Herreros de Tejada, *Majadahonda*

Enrique de-Madaria, *Alicante*

JE Dominguez-Munoz, *Santiago de Compostela*

Vicente Felipo, *Valencia*

CM Fernandez-Rodriguez, *Madrid*

Carmen Frontela-Saseta, *Murcia*

Julio Galvez, *Granada*

Maria Teresa García, *Vigo*

MI Garcia-Fernandez, *Málaga*

Emilio Gonzalez-Reimers, *La Laguna*

Marcel Jimenez, *Bellaterra*

Angel Lanas, *Zaragoza*

Juan Ramón Larrubia, *Guadalajara*

Antonio Lopez-Sanroman, *Madrid*

Vicente Lorenzo-Zuniga, *Badalona*

Alfredo J Lucendo, *Tomelloso*

Vicenta Soledad Martinez-Zorzano, *Vigo*

José Manuel Martin-Villa, *Madrid*

Julio Mayol, *Madrid*

Manuel Morales-Ruiz, *Barcelona*

Alfredo Moreno-Egea, *Murcia*

Albert Pares, *Barcelona*

Maria Pellise, *Barcelona*

José Perea, *Madrid*

Miguel Angel Plaza, *Zaragoza*

María J Pozo, *Cáceres*

Enrique Quintero, *La Laguna*

Jose M Ramia, *Madrid*

Francisco Rodriguez-Frias, *Barcelona*

Silvia Ruiz-Gaspa, *Barcelona*

Xavier Serra-Aracil, *Barcelona*

Vincent Soriano, *Madrid*

Javier Suarez, *Pamplona*

Carlos Taxonera, *Madrid*

M Isabel Torres, *Jaén*

Manuel Vazquez-Carrera, *Barcelona*

Benito Velayos, *Valladolid*

Silvia Vidal, *Barcelona*



**Sri Lanka**

Arjuna Priyadarsin De Silva, *Colombo*



**Sudan**

Ishag Adam, *Khartoum*



**Sweden**

Roland G Andersson, *Lund*

Bergthor Björnsson, *Linköping*

Johan Christopher Bohr, *Örebro*

Mauro D'Amato, *Stockholm*

Thomas Franzen, *Norrköping*

Evangelos Kalaitzakis, *Lund*

Riadh Sadik, *Gothenburg*

Per Anders Sandstrom, *Linköping*

Ervin Toth, *Malmö*

Konstantinos Tsimogiannis, *Vasteras*

Apostolos V Tsolakis, *Uppsala*

**Switzerland**

Gieri Cathomas, *Liestal*  
Jean Louis Frossard, *Geneve*  
Christian Toso, *Geneva*  
Stephan Robert Vavricks, *Zurich*  
Dominique Velin, *Lausanne*

**Thailand**

Thawatthai Akaraviputh, *Bangkok*  
P Yoysungnoen Chintana, *Pathumthani*  
Veerapol Kukongviriyapan, *Muang*  
Vijitra Leardkamolkarn, *Bangkok*  
Varut Lohsiriwat, *Bangkok*  
Somchai Pinlaor, *Khaon Kaen*  
D Wattanasirichaigoon, *Bangkok*

**Trinidad and Tobago**

B Shivananda Nayak, *Mount Hope*

**Tunisia**

Ibtissem Ghedira, *Sousse*  
Lilia Zouiten-Mekki, *Tunis*

**Turkey**

Inci Alican, *Istanbul*  
Mustafa Altindis, *Sakarya*  
Mutay Aslan, *Antalya*  
Oktar Asoglu, *Istanbul*  
Yasemin Hatice Balaban, *Istanbul*  
Metin Basaranoglu, *Ankara*  
Yusuf Bayraktar, *Ankara*  
Süleyman Bayram, *Adiyaman*  
Ahmet Bilici, *Istanbul*  
Ahmet Sedat Boyacioglu, *Ankara*  
Züleyha Akkan Cetinkaya, *Kocaeli*  
Cavit Col, *Bolu*  
Yasar Colak, *Istanbul*  
Cagatay Erden Daphan, *Kirikkale*  
Mehmet Demir, *Hatay*  
Ahmet Merih Dobrucali, *Istanbul*  
Gülüm Ozlem Elpek, *Antalya*  
Ayse Basak Engin, *Ankara*  
Eren Ersoy, *Ankara*  
Osman Ersoy, *Ankara*  
Yusuf Ziya Erzin, *Istanbul*  
Mukaddes Esrefoglu, *Istanbul*  
Levent Filik, *Ankara*  
Ozgur Harmanaci, *Ankara*  
Koray Hekimoglu, *Ankara*  
Abdurrahman Kadayifci, *Gaziantep*  
Cem Kalayci, *Istanbul*  
Selin Kapan, *Istanbul*  
Huseyin Kayadibi, *Adana*  
Sabahattin Kaymakoglu, *Istanbul*  
Metin Kement, *Istanbul*  
Mevlut Kurt, *Bolu*  
Resat Ozaras, *Istanbul*  
Elvan Ozbek, *Adapazari*

Cengiz Ozcan, *Mersin*  
Hasan Ozen, *Ankara*  
Halil Ozguc, *Bursa*  
Mehmet Ozturk, *Izmir*  
Orhan V Ozkan, *Sakarya*  
Semra Paydas, *Adana*  
Ozlem Durmaz Suoglu, *Istanbul*  
Ilker Tasci, *Ankara*  
Müge Tecder-ünal, *Ankara*  
Mesut Tez, *Ankara*  
Serdar Topaloglu, *Trabzon*  
Murat Toruner, *Ankara*  
Gokhan Tumgor, *Adana*  
Oguz Uskudar, *Adana*  
Mehmet Yalniz, *Elazig*  
Mehmet Yaman, *Elazig*  
Veli Yazisiz, *Antalya*  
Yusuf Yilmaz, *Istanbul*  
Ozlem Yilmaz, *Izmir*  
Oya Yucel, *Istanbul*  
Ilhami Yuksel, *Ankara*

**United Kingdom**

Nadeem Ahmad Afzal, *Southampton*  
Navneet K Ahluwalia, *Stockport*  
Yeng S Ang, *Lancashire*  
Ramesh P Arasaradnam, *Coventry*  
Ian Leonard Phillip Beales, *Norwich*  
John Beynon, *Swansea*  
Barbara Braden, *Oxford*  
Simon Bramhall, *Birmingham*  
Geoffrey Burnstock, *London*  
Ian Chau, *Sutton*  
Thean Soon Chew, *London*  
Helen G Coleman, *Belfast*  
Anil Dhawan, *London*  
Sunil Dolwani, *Cardiff*  
Piers Gatenby, *London*  
Anil T George, *London*  
Pasquale Giordano, *London*  
Paul Henderson, *Edinburgh*  
Georgina Louise Hold, *Aberdeen*  
Stefan Hubscher, *Birmingham*  
Robin D Hughes, *London*  
Nusrat Husain, *Manchester*  
Matt W Johnson, *Luton*  
Konrad Koss, *Macclesfield*  
Anastasios Koulaouzidis, *Edinburgh*  
Simon Lal, *Salford*  
John S Leeds, *Aberdeen*  
JK K Limdi, *Manchester*  
Hongxiang Liu, *Cambridge*  
Michael Joseph McGarvey, *London*  
Michael Anthony Mendall, *London*  
Alexander H Mirnezami, *Southampton*  
J Bernadette Moore, *Guildford*  
Claudio Nicoletti, *Norwich*  
Savvas Papagrigoriadis, *London*  
Sylvia LF Pender, *Southampton*  
David Mark Pritchard, *Liverpool*  
James A Ross, *Edinburgh*  
Kamran Rostami, *Worcester*  
Xiong Z Ruan, *London*  
Frank I Tovey, *London*  
Dhiraj Tripathi, *Birmingham*

Vamsi R Velchuru, *Great Yarmouth*  
Nicholas T Ventham, *Edinburgh*  
Diego Vergani, *London*  
Jack Westwood Winter, *Glasgow*  
Terence Wong, *London*  
Ling Yang, *Oxford*

**United States**

Daniel E Abbott, *Cincinnati*  
Ghassan K Abou-Alfa, *New York*  
Julian Abrams, *New York*  
David William Adelson, *Los Angeles*  
Jonathan Steven Alexander, *Shreveport*  
Tauseef Ali, *Oklahoma City*  
Mohamed R Ali, *Sacramento*  
Rajagopal N Aravalli, *Minneapolis*  
Hassan Ashktorab, *Washington*  
Shashi Bala, *Worcester*  
Charles F Barish, *Raleigh*  
P Patrick Basu, *New York*  
Robert L Bell, *Berkeley Heights*  
David Bentrem, *Chicago*  
Henry J Binder, *New Haven*  
Joshua Bleier, *Philadelphia*  
Wojciech Blonski, *Johnson City*  
Kenneth Boorum, *Corvallis*  
Brian Boulay, *Chicago*  
Carla W Brady, *Durham*  
Kyle E Brown, *Iowa City*  
Adeel A Butt, *Pittsburgh*  
Weibiao Cao, *Providence*  
Andrea Castillo, *Cheney*  
Fernando J Castro, *Weston*  
Adam S Cheifetz, *Boston*  
Xiaoxin Luke Chen, *Durham*  
Ramsey Cheung, *Palo Alto*  
Parimal Chowdhury, *Little Rock*  
Edward John Ciccio, *New York*  
Dahn L Clemens, *Omaha*  
Yingzi Cong, *Galveston*  
Laura Iris Cosen-Binker, *Boston*  
Joseph John Cullen, *Iowa*  
Mark J Czaja, *Bronx*  
Mariana D Dabeva, *Bronx*  
Christopher James Damman, *Seattle*  
Isabelle G De Plaen, *Chicago*  
Punita Dhawan, *Nashville*  
Hui Dong, *La Jolla*  
Wael El-Rifai, *Nashville*  
Sukru H Emre, *New Haven*  
Paul Feuerstadt, *Hamden*  
Josef E Fischer, *Boston*  
Laurie N Fishman, *Boston*  
Joseph Che Forbi, *Atlanta*  
Temitope Foster, *Atlanta*  
Amy E Foxx-Orenstein, *Scottsdale*  
Daniel E Freedberg, *New York*  
Shai Friedland, *Palo Alto*  
Virgilio George, *Indianapolis*  
Ajay Goel, *Dallas*  
Oliver Grundmann, *Gainesville*  
Stefano Guandalini, *Chicago*  
Chakshu Gupta, *St. Joseph*  
Grigoriy E Gurvits, *New York*

Xiaonan Han, *Cincinnati*  
 Mohamed Hassan, *Jackson*  
 Martin Hauer-Jensen, *Little Rock*  
 Koichi Hayano, *Boston*  
 Yingli Hee, *Atlanta*  
 Samuel B Ho, *San Diego*  
 Jason Ken Hou, *Houston*  
 Lifang Hou, *Chicago*  
 K-Qin Hu, *Orange*  
 Jamal A Ibdah, *Columbia*  
 Robert Thomas Jensen, *Bethesda*  
 Huanguang "Charlie" Jia, *Gainesville*  
 Rome Jutabha, *Los Angeles*  
 Andreas M Kaiser, *Los Angeles*  
 Avinash Kambadakone, *Boston*  
 David Edward Kaplan, *Philadelphia*  
 Randeep Kashyap, *Rochester*  
 Rashmi Kaul, *Tulsa*  
 Ali Keshavarzian, *Chicago*  
 Amir Maqbul Khan, *Marshall*  
 Nabeel Hasan Khan, *New Orleans*  
 Sahil Khanna, *Rochester*  
 Kusum K Kharbanda, *Omaha*  
 Hyun Sik Kim, *Pittsburgh*  
 Joseph Kim, *Duarte*  
 Jae S Kim, *Gainesville*  
 Miran Kim, *Providence*  
 Timothy R Koch, *Washington*  
 Burton I Korelitz, *New York*  
 Betsy Kren, *Minneapolis*  
 Shiu-Ming Kuo, *Buffalo*  
 Michelle Lai, *Boston*  
 Andreas Larentzakis, *Boston*  
 Edward Wolfgang Lee, *Los Angeles*  
 Daniel A Leffler, *Boston*  
 Michael Leitman, *New York*  
 Suthat Liangpunsakul, *Indianapolis*  
 Joseph K Lim, *New Haven*  
 Elaine Y Lin, *Bronx*  
 Henry C Lin, *Albuquerque*  
 Rohit Loomba, *La Jolla*  
 James David Luketich, *Pittsburgh*

Li Ma, *Stanford*  
 Mohammad F Madhoun, *Oklahoma City*  
 Thomas C Mahl, *Buffalo*  
 Ashish Malhotra, *Bettendorf*  
 Pranoti Mandrekar, *Worcester*  
 John Marks, *Wynnewood*  
 Wendy M Mars, *Pittsburgh*  
 Julien Vahe Matricon, *San Antonio*  
 Craig J McClain, *Louisville*  
 Tamir Miloh, *Phoenix*  
 Ayse Leyla Mindikoglu, *Baltimore*  
 Huanbiao Mo, *Denton*  
 Klaus Monkemuller, *Birmingham*  
 John Morton, *Stanford*  
 Adnan Muhammad, *Tampa*  
 Michael J Nowicki, *Jackson*  
 Patrick I Okolo, *Baltimore*  
 Giusepp Orlando, *Winston Salem*  
 Natalia A Osona, *Omaha*  
 Virendra N Pandey, *Newark*  
 Mansour A Parsi, *Cleveland*  
 Michael F Picco, *Jacksonville*  
 Daniel S Pratt, *Boston*  
 Xiaofa Qin, *Newark*  
 Janardan K Reddy, *Chicago*  
 Victor E Reyes, *Galveston*  
 Jon Marc Rhoads, *Houston*  
 Giulia Roda, *New York*  
 Jean-Francois Armand Rossignol, *Tampa*  
 Paul A Rufo, *Boston*  
 Madhusudana Girija Sanal, *New York*  
 Miguel Saps, *Chicago*  
 Sushil Sarna, *Galveston*  
 Ann O Scheimann, *Baltimore*  
 Bernd Schnabl, *La Jolla*  
 Matthew J Schuchert, *Pittsburgh*  
 Ekihiro Seki, *La Jolla*  
 Chanjuan Shi, *Nashville*  
 David Quan Shih, *Los Angeles*  
 Shadab A Siddiqi, *Orlando*  
 William B Silverman, *Iowa City*  
 Shashideep Singhal, *New York*

Bronislaw L Slomiany, *Newark*  
 Steven F Solga, *Bethlehem*  
 Byoung-Joon Song, *Bethesda*  
 Dario Sorrentino, *Roanoke*  
 Scott R Steele, *Fort Lewis*  
 Branko Stefanovic, *Tallahassee*  
 Arun Swaminath, *New York*  
 Kazuaki Takabe, *Richmond*  
 Naoki Tanaka, *Bethesda*  
 Hans Ludger Tillmann, *Durham*  
 George Triadafilopoulos, *Stanford*  
 John Richardson Thompson, *Nashville*  
 Andrew Ukleja, *Weston*  
 Miranda AL van Tilburg, *Chapel Hill*  
 Gilberto Vaughan, *Atlanta*  
 Vijayakumar Velu, *Atlanta*  
 Gebhard Wagener, *New York*  
 Kasper Saonun Wang, *Los Angeles*  
 Xiangbing Wang, *New Brunswick*  
 Daoyan Wei, *Houston*  
 Theodore H Welling, *Ann Arbor*  
 C Mel Wilcox, *Birmingham*  
 Jacqueline Lee Wolf, *Boston*  
 Laura Ann Woollett, *Cincinnati*  
 Harry Hua-Xiang Xia, *East Hanover*  
 Wen Xie, *Pittsburgh*  
 Guang Yu Yang, *Chicago*  
 Michele T Yip-Schneider, *Indianapolis*  
 Sam Zakhari, *Bethesda*  
 Kezhong Zhang, *Detroit*  
 Huiping Zhou, *Richmond*  
 Xiao-Jian Zhou, *Cambridge*  
 Richard Zubarik, *Burlington*



**Venezuela**

Miguel Angel Chiurillo, *Barquisimeto*



**Vietnam**

Van Bang Nguyen, *Hanoi*



**EDITORIAL**

- 5451** Wilson's disease: Prospective developments towards new therapies

*Ranucci G, Polishchuck R, Iorio R*

- 5457** Are our endoscopy patients at risk for pyogenic liver abscess?

*Cerwenka H, Schemmer P*

**REVIEW**

- 5460** Pancreatitis: Preventing catastrophic haemorrhage

*Evans RPT, Mourad MM, Pall G, Fisher SG, Bramhall SR*

**MINIREVIEWS**

- 5469** Treating children with inflammatory bowel disease: Current and new perspectives

*Guariso G, Gasparetto M*

- 5486** Influence of gut microbiota on neuropsychiatric disorders

*Cenit MC, Sanz Y, Codoñer-Franch P*

**ORIGINAL ARTICLE****Basic Study**

- 5499** Everolimus halts hepatic cystogenesis in a rodent model of polycystic-liver-disease

*Temmerman F, Chen F, Libbrecht L, Vander Elst I, Windmolders P, Feng Y, Ni Y, De Smedt H, Nevens F, van Pelt J*

- 5508** MicroRNA profile in neosquamous esophageal mucosa following ablation of Barrett's esophagus

*Sreedharan L, Mayne GC, Watson DI, Bright T, Lord RV, Ansar A, Wang T, Kist J, Astill DS, Hussey DJ*

- 5519** Expression of Interleukin-26 is upregulated in inflammatory bowel disease

*Fujii M, Nishida A, Imaeda H, Ohno M, Nishino K, Sakai S, Inatomi O, Bamba S, Kawahara M, Shimizu T, Andoh A*

- 5530** Autophagic cell death induced by reactive oxygen species is involved in hyperthermic sensitization to ionizing radiation in human hepatocellular carcinoma cells

*Yuan GJ, Deng JJ, Cao DD, Shi L, Chen X, Lei JJ, Xu XM*

- 5538** Yangzheng Sanjie decoction regulates proliferation and apoptosis of gastric cancer cells by enhancing let-7a expression

*Deng HX, Yu YY, Zhou AQ, Zhu JL, Luo LN, Chen WQ, Hu L, Chen GX*

**Case Control Study**

- 5549 Crohn's disease environmental factors in the developing world: A case-control study in a statewide catchment area in Brazil

*Salgado VCL, Luiz RR, Boechat N, Schorr BC, Leão IS, Nunes T, Zaltman C*

**Retrospective Cohort Study**

- 5557 Postoperative bleeding in patients on antithrombotic therapy after gastric endoscopic submucosal dissection

*Sato C, Hirasawa K, Koh R, Ikeda R, Fukuchi T, Kobayashi R, Kaneko H, Makazu M, Maeda S*

**Retrospective Study**

- 5567 Serous pancreatic neoplasia, data and review

*Dietrich CF, Dong Y, Jenssen C, Ciaravino V, Hocke M, Wang WP, Burmester E, Möller K, Atkinson NSS, Capelli P, D'Onofrio M*

- 5579 Pancreaticoduodenectomy for duodenal papilla carcinoma: A single-centre 9-year retrospective study of 112 patients with long-term follow-up

*Lian PL, Chang Y, Xu XC, Zhao Z, Wang XQ, Xu KS*

**Clinical Trials Study**

- 5589 Efficacy and safety of Xiangsha Liujunzi granules for functional dyspepsia: A multi-center randomized double-blind placebo-controlled clinical study

*Lv L, Wang FY, Ma XX, Li ZH, Huang SP, Shi ZH, Ji HJ, Bian LQ, Zhang BH, Chen T, Yin XL, Tang XD*

**Observational Study**

- 5602 Combination of acoustic radiation force impulse imaging, serological indexes and contrast-enhanced ultrasound for diagnosis of liver lesions

*Sun XL, Yao H, Men Q, Hou KZ, Chen Z, Xu CQ, Liang LW*

**Prospective Study**

- 5610 Incidents and adverse events of endoscopic ultrasound-guided fine-needle aspiration for pancreatic cystic lesions

*Du C, Chai NL, Linghu EQ, Li HK, Sun YF, Xu W, Wang XD, Tang P, Yang J*

**SYSTEMATIC REVIEWS**

- 5619 Systematic review of giant gastric lipomas reported since 1980 and report of two new cases in a review of 117110 esophagogastroduodenoscopies

*Cappell MS, Stevens CE, Amin M*

- 5634 Acute colonic pseudo-obstruction: A systematic review of aetiology and mechanisms

*Wells CI, O'Grady G, Bissett IP*

**ABOUT COVER**

Editorial board member of *World Journal of Gastroenterology*, Piero Luigi Almasio, MD, Associate Professor, Biomedical Department of Internal and Specialist Medicine, University of Palermo, 90127 Palermo, Italy

**AIMS AND SCOPE**

*World Journal of Gastroenterology* (*World J Gastroenterol*, *WJG*, print ISSN 1007-9327, online ISSN 2219-2840, DOI: 10.3748) is a peer-reviewed open access journal. *WJG* was established on October 1, 1995. It is published weekly on the 7<sup>th</sup>, 14<sup>th</sup>, 21<sup>st</sup>, and 28<sup>th</sup> each month. The *WJG* Editorial Board consists of 1375 experts in gastroenterology and hepatology from 68 countries.

The primary task of *WJG* is to rapidly publish high-quality original articles, reviews, and commentaries in the fields of gastroenterology, hepatology, gastrointestinal endoscopy, gastrointestinal surgery, hepatobiliary surgery, gastrointestinal oncology, gastrointestinal radiation oncology, gastrointestinal imaging, gastrointestinal interventional therapy, gastrointestinal infectious diseases, gastrointestinal pharmacology, gastrointestinal pathophysiology, gastrointestinal pathology, evidence-based medicine in gastroenterology, pancreatology, gastrointestinal laboratory medicine, gastrointestinal molecular biology, gastrointestinal immunology, gastrointestinal microbiology, gastrointestinal genetics, gastrointestinal translational medicine, gastrointestinal diagnostics, and gastrointestinal therapeutics. *WJG* is dedicated to become an influential and prestigious journal in gastroenterology and hepatology, to promote the development of above disciplines, and to improve the diagnostic and therapeutic skill and expertise of clinicians.

**INDEXING/ABSTRACTING**

*World Journal of Gastroenterology* (*WJG*) is now indexed in Current Contents<sup>®</sup>/Clinical Medicine, Science Citation Index Expanded (also known as SciSearch<sup>®</sup>), Journal Citation Reports<sup>®</sup>, Index Medicus, MEDLINE, PubMed, PubMed Central and Directory of Open Access Journals. The 2017 edition of Journal Citation Reports<sup>®</sup> cites the 2016 impact factor for *WJG* as 3.365 (5-year impact factor: 3.176), ranking *WJG* as 29<sup>th</sup> among 79 journals in gastroenterology and hepatology (quartile in category Q2).

**FLYLEAF**

**I-IX Editorial Board**

**EDITORS FOR THIS ISSUE**

**Responsible Assistant Editor:** *Xiang Li*  
**Responsible Electronic Editor:** *Fen-Fen Zhang*  
**Proofing Editor-in-Chief:** *Lian-Sheng Ma*

**Responsible Science Editor:** *Yuan Qi*  
**Proofing Editorial Office Director:** *Jin-Lei Wang*

**NAME OF JOURNAL**  
*World Journal of Gastroenterology*

**ISSN**  
ISSN 1007-9327 (print)  
ISSN 2219-2840 (online)

**LAUNCH DATE**  
October 1, 1995

**FREQUENCY**  
Weekly

**EDITORS-IN-CHIEF**  
**Damian Garcia-Olmo, MD, PhD, Doctor, Professor, Surgeon**, Department of Surgery, Universidad Autonoma de Madrid; Department of General Surgery, Fundacion Jimenez Diaz University Hospital, Madrid 28040, Spain

**Stephen C Strom, PhD, Professor**, Department of Laboratory Medicine, Division of Pathology, Karolinska Institutet, Stockholm 141-86, Sweden

**Andrzej S Tarnawski, MD, PhD, DSc (Med), Professor of Medicine, Chief Gastroenterology**, VA Long Beach Health Care System, University of California, Irvine, CA, 5901 E. Seventh Str., Long Beach,

CA 90822, United States

**EDITORIAL BOARD MEMBERS**  
All editorial board members resources online at <http://www.wjgnet.com/1007-9327/editorialboard.htm>

**EDITORIAL OFFICE**  
Jin-Lei Wang, Director  
Yuan Qi, Vice Director  
Ze-Mao Gong, Vice Director  
*World Journal of Gastroenterology*  
Baishideng Publishing Group Inc  
7901 Stoneridge Drive, Suite 501,  
Pleasanton, CA 94588, USA  
Telephone: +1-925-2238242  
Fax: +1-925-2238243  
E-mail: [editorialoffice@wjgnet.com](mailto:editorialoffice@wjgnet.com)  
Help Desk: <http://www.f6publishing.com/helpdesk>  
<http://www.wjgnet.com>

**PUBLISHER**  
Baishideng Publishing Group Inc  
7901 Stoneridge Drive, Suite 501,  
Pleasanton, CA 94588, USA  
Telephone: +1-925-2238242  
Fax: +1-925-2238243  
E-mail: [bpoffice@wjgnet.com](mailto:bpoffice@wjgnet.com)  
Help Desk: <http://www.f6publishing.com/helpdesk>

<http://www.wjgnet.com>

**PUBLICATION DATE**  
August 14, 2017

**COPYRIGHT**  
© 2017 Baishideng Publishing Group Inc. Articles published by this Open-Access journal are distributed under the terms of the Creative Commons Attribution Non-commercial License, which permits use, distribution, and reproduction in any medium, provided the original work is properly cited, the use is non commercial and is otherwise in compliance with the license.

**SPECIAL STATEMENT**  
All articles published in journals owned by the Baishideng Publishing Group (BPG) represent the views and opinions of their authors, and not the views, opinions or policies of the BPG, except where otherwise explicitly indicated.

**INSTRUCTIONS TO AUTHORS**  
Full instructions are available online at <http://www.wjgnet.com/bpg/gerinfo/204>

**ONLINE SUBMISSION**  
<http://www.f6publishing.com>



## Wilson's disease: Prospective developments towards new therapies

Giusy Ranucci, Roman Polishchuck, Raffaele Iorio

Giusy Ranucci, Raffaele Iorio, Department of Translational Medical Science, Section of Pediatric, University Federico II, 80131 Naples, Italy

Roman Polishchuck, Telethon Institute of Genetics and Medicine, 80078 Pozzuoli (NA), Italy

**Author contributions:** Ranucci G, Polishchuck R and Iorio R contributed equally to the article's design, conception and writing.

**Conflict-of-interest statement:** All authors declare they have no conflicts of interest.

**Open-Access:** This article is an open-access article which was selected by an in-house editor and fully peer-reviewed by external reviewers. It is distributed in accordance with the Creative Commons Attribution Non Commercial (CC BY-NC 4.0) license, which permits others to distribute, remix, adapt, build upon this work non-commercially, and license their derivative works on different terms, provided the original work is properly cited and the use is non-commercial. See: <http://creativecommons.org/licenses/by-nc/4.0/>

**Manuscript source:** Invited manuscript

**Correspondence to:** Raffaele Iorio, MD, Associate Professor, Department of Translational Medical Science, Section of Pediatrics, University Federico II, Via Pansini 5, 80131 Naples, Italy. [riorio@unina.it](mailto:riorio@unina.it)  
Telephone: +39-081-7464337  
Fax: +39-081-7464337

Received: February 3, 2017  
Peer-review started: February 8, 2017  
First decision: March 6, 2017  
Revised: April 11, 2017  
Accepted: July 22, 2017  
Article in press: July 24, 2017  
Published online: August 14, 2017

### Abstract

Wilson's disease (WD) is an autosomal recessive

disorder of copper metabolism, caused by mutations in the *ATP7B* gene. A clear demand for novel WD treatment strategies has emerged. Although therapies using zinc salts and copper chelators can effectively cure WD, these drugs exhibit limitations in a substantial pool of WD patients who develop intolerance and/or severe side effects. Several lines of research have indicated intriguing potential for novel strategies and targets for development of new therapies. Here, we review these new approaches, which comprise correction of *ATP7B* mutants and discovery of new compounds that circumvent *ATP7B*-deficiency, as well as cell and gene therapies. We also discuss whether and when these new therapeutic strategies will be translated into clinical use, according to the key requirements for clinical trials that remain to be met. Finally, we discuss the hope for the current rapidly developing research on molecular mechanisms underlying WD pathogenesis and for the related potential therapeutic targets to provide a solid foundation for the next generation of WD therapies that may lead to an effective, tolerable and safe cure.

**Key words:** *ATP7B*; Stem cell-derived hepatocyte like cells; Methanobactin; Heat shock protein 70; p38; JNK; Correctors; Translational medicine; Precision medicine

© **The Author(s) 2017.** Published by Baishideng Publishing Group Inc. All rights reserved.

**Core tip:** Hepatocytes derived from human-induced pluripotent stem cells hold great promise for the drug discovery process, especially for Wilson's disease (WD). Therapeutic approaches offering correction of the *ATP7B* mutant function and/or less toxic suppression of copper accumulation are promising and could be available shortly. In particular, protein quality control components and their regulatory networks represent attractive new targets for WD-causing mutant correction. Cell and gene therapies, however, will require more studies before they can be considered for clinical trials. A key goal for WD advancement is international cooperation of specialized centers to overcome limited

availability of patients for study.

Ranucci G, Polishchuck R, Iorio R. Wilson's disease: Prospective developments towards new therapies. *World J Gastroenterol* 2017; 23(30): 5451-5456 Available from: URL: <http://www.wjgnet.com/1007-9327/full/v23/i30/5451.htm> DOI: <http://dx.doi.org/10.3748/wjg.v23.i30.5451>

## INTRODUCTION

Wilson's disease (WD) is an autosomal recessive disorder of copper (Cu) metabolism, caused by mutations in the *ATP7B* gene, which encodes Cu-translocating ATPase expressed primarily in the liver<sup>[1]</sup>. *ATP7B* resides in the trans-Golgi membrane compartment and loads Cu onto newly synthesized apoceruloplasmin. In the case of Cu overload, *ATP7B* traffics to the canalicular membrane of hepatocytes and the associated cytoplasmic vesicular compartment, where it removes excess Cu through the bile. Therefore, all mutations that affect synthesis of *ATP7B*, its stability, correct localization in the trans-Golgi region and capacity of trafficking in the condition of intracellular Cu excess, determine toxic accumulation of Cu in hepatocytes, thereby leading to cell damage and subsequent release of Cu into the blood and ultimately affecting other organs<sup>[2]</sup>.

The main clinical presentations of WD are liver and neuropsychiatric diseases. Existing therapies comprise treatment with either zinc salts or Cu chelators. While these drugs allow for sufficient control of the symptoms, they do not cure the disease. Additionally, chelators induce multiple severe toxicities, requiring discontinuation in approximately 30% of patients; these include hypersensitivity reactions, significant bone marrow suppression, degenerative changes in skin, nephrotoxicity and autoimmune disease<sup>[3]</sup>. Zinc therapy seems to fail in large cohorts of adult patients with liver disease when applied for very long periods, and its use in symptomatic Wilson's patients with liver disease remains controversial<sup>[4,5]</sup>. Generally, the psychiatric symptoms of WD are poorly controlled by available drugs<sup>[6]</sup>. Furthermore, an Italian study showed that, more than 36% of Italian pediatric WD patients responder to the available drugs, did not exhibit normalization of liver enzymes<sup>[7]</sup>. Finally, among adults with WD there are substantial rates of non-adherence to medication regimens (30%-50%), corresponding to both a high index of patients who suffer liver failure and who develop potentially irreversible neurologic or psychiatric symptoms<sup>[8]</sup>.

Liver transplantation (LT) is a treatment option for the most severe (life-threatening) cases of WD. LT is a curative therapy, with biliary Cu excretion being restored, neurologic and psychiatric disease stabilizing or improving, and Kayser-Fleischer rings

disappearing over time<sup>[9]</sup>. Unfortunately, LT does not represent a general therapeutic strategy, given the high rate of complications and the need for long-life immunosuppressive therapy<sup>[9]</sup>. Thus, there remains a clear need for novel treatment strategies aimed at curing WD through correction of the cellular defect.

During the last few years, the perspective on alternative WD therapeutic strategies has been completely revolutionized, as summarized in this review. And, the field of WD translational research and clinical management is currently experiencing an unexpected burst that hopefully will lead to an expanded range of therapies available to patients.

## DISEASE MODELING

The four animal models of WD - the Long-Evans Cinnamon (LEC) rat, the inbred mouse models (toxic milk, the Jackson Laboratory toxic milk) and the *Atp7B* knockout (*Atp7b*<sup>-/-</sup>) mouse - lose *ATP7B* function and manifest liver disease due to Cu accumulation<sup>[2]</sup>. Surprisingly, *Atp7b*<sup>-/-</sup> mice does not exhibit susceptibility to neurological disease and LEC rats and toxic milk mouse develop only a mild neurologic involvement. Yet, no mice models carrying the most frequent missense mutations of *ATP7B* (H1069Q or R778L) are available. On the other hand, the metabolic pathways of rodents are frequently vastly different from those of man, and this is the pivotal reason that efforts persist to develop a platform of human cells.

Hepatocytes obtained *via* liver biopsy cannot be considered as a good model system for WD studies. Indeed, it is extremely difficult to keep human hepatocytes from biopsies in culture, as they do not proliferate and rapidly undergo apoptosis. In addition, these cells are generally already damaged at the moment of liver biopsy execution.

The recent development of stem cell-derived hepatocyte-like cells (HLCs) has circumvented this problem and opens new avenues for gene- and/or drug-based therapy to treat liver diseases. This new "*in vitro* model" better mimics patient cell biology. HLCs can be fairly easily derived from induced pluripotent stem cells (iPSCs) that are generated through the reprogramming of human fibroblasts<sup>[10]</sup>. In this context, it would be particularly helpful to obtain HLCs from WD patients. Some steps have already been taken in this direction, with HLCs derived from patients with missense *ATP7B* mutation having been developed<sup>[11]</sup>.

iPSCs harbor the same unique characteristics of embryonic stem cells, *i.e.*, they can be indefinitely expanded *in vitro* and differentiated in all cells types derived from the three germ layers. Thus, iPSC technology features the potential benefits of embryonic stem cells while addressing their major ethical and scientific concerns: embryo destruction and immune-incompatibility. In this manner, human iPSCs represent an unlimited source of human hepatocytes for

translational research and hold great promise for drug screening and liver disease modeling in particular. In addition to their HLC differentiation capacity, iPSCs can differentiate into neurons, providing a serious advantage in studying whether and how certain *ATP7B* mutations contribute to neurologic dysfunction in WD patients.

## CORRECTION OF DYSFUNCTIONAL *ATP7B*

Alternative therapeutic approaches offering correction of *ATP7B* mutant function and/or less toxic suppression of Cu import have been investigated in recent years. It is worth noting that most of the *ATP7B* mutations belong to the missense (58%) or small deletion/insertion (27%) categories, thereby resulting in aberrant protein products that frequently exhibit residual Cu-transporting activity but which undergo strong degradation due to misfolding and retention within the endoplasmic reticulum (ER)<sup>[12]</sup>. This is the case for the most frequent *ATP7B* mutants, H1069Q (in 50%-60% of European and North American WD patients) and R778L (in 40% of East Asian patients). Thus, manipulating their translocation from the ER to ensure correct localization in the cell would be beneficial for a sizable portion of WD patients.

Correction strategy has been widely explored for the most frequent mutant in cystic fibrosis, the  $\Delta$ F508 mutation of the cystic fibrosis transmembrane conductance regulator (CFTR)<sup>[13]</sup>. Like the *ATP7B* mutant,  $\Delta$ F508-CFTR exhibits residual ion-transporting activity but undergoes strong retention and degradation in the ER. Considering these similarities, several labs have tested the potential of  $\Delta$ F508-CFTR correctors, such as curcumin and 4-phenylbutyrate, for *ATP7B* mutant rescue. Both correctors were demonstrated as capable of reducing degradation of *ATP7B* mutants expressed in HEK293 cells<sup>[14]</sup>; however, curcumin failed to do so in HLCs expressing the R778L variant of *ATP7B*<sup>[11]</sup>. It remains unclear to what extent these drugs rescue localization and function of *ATP7B* mutant<sup>[14]</sup>. Curcumin has been reported to correct localization of *ATP7B*-R778L and to facilitate Cu efflux from patient-derived HLCs. However, in phase 1 clinical trials for CFTR correction, dietary curcumin was found to have very poor bioavailability and very low serum concentration<sup>[15]</sup>. Thus, the efficacy of this corrector for WD treatment remains questionable.

In order to identify new drugs and targets for *ATP7B* mutant correction, it will be important to first identify the quality control mechanisms that drive ER retention and degradation of the mutants. A few proteins (*i.e.*, COMMD1, clusterin) and peptides (*i.e.*, alpha-crystallin B peptides) control *ATP7B* mutants retention in the ER and/or their degradation<sup>[16,17]</sup>. However, these molecules do not belong to the "druggable" category and their potential for creation of drugs to cure WD remains

largely unknown.

On the other hand, a recent analysis of global gene expression in hepatic HepG2 cell lines expressing either wild type *ATP7B* or *ATP7B*-H1069Q mutant revealed that suppression of p38 and JNK reduces retention of H1069Q and a few other *ATP7B* mutants in the ER, inhibits their degradation, and facilitates Cu excretion from mutant-expressing cells<sup>[18]</sup>. Therefore, p38 and JNK have become attractive targets for exploring approaches to mutant correction. Indeed, it has been recently reported<sup>[19]</sup> that p38 and JNK control a cluster of ER quality control genes that promote *ATP7B*-H1069Q degradation. This cluster comprises a well-known chaperone, heat shock protein 70 (HSP70), whose silencing protects the *ATP7B* mutant from degradation and facilitates its export from the ER to the Golgi complex where *ATP7B* normally works.

The recognition of HSP70 and its upstream regulators p38 and JNK as attractive new targets for *ATP7B* mutant correction has also elucidated their potential for normalization of Cu homeostasis in WD. Considering the importance of these proteins for several critical processes of the normal physiologic state, such as protein quality control, stress response, signal transduction and apoptosis, safe (condition-specific) inhibitors of HSP70, p38 and JNK must be identified in the context of preexisting drug-approved libraries to avoid significant impact on overall cell/organism health. Nonetheless, these new modulators represent a great opportunity for repurposing safe drugs for WD treatment.

## NEW COMPOUNDS WITH THERAPEUTIC POTENTIAL

The current pharmacological treatments have largely failed in rescue of Cu homeostasis in WD patients with acute liver failure, leaving LT as the only viable option for treatment. A recent study using the LEC rat model of WD offered an extra option for such patients called methanobactin (MB), a peptide produced by *Methylosinus trichosporium* with an extremely high affinity for Cu<sup>[20]</sup>. Short-term MB treatment efficiently reversed acute liver damage due to Cu accumulation. This beneficial effect was associated with disposal of intracellular Cu, in particular from the mitochondria. Interestingly, the regular Cu chelators penicillamine and tetrathiomolybdate failed to clean toxic metal from the mitochondrial stores. As a consequence, MB treatment prevented hepatocyte death and the subsequent liver failure, elongating the life span of the LEC rat. Therefore this peptide seems to be a potential therapeutic agent for acute WD.

Findings from another recent study have suggested that liver X receptor (LXR)/retinoid X receptor agonist may be used to combat Cu toxicity in WD<sup>[21]</sup>. This approach does not require Cu chelation. Careful investigation of the transcriptional and metabolic changes in



samples from WD patients and *Atp7b*<sup>-/-</sup> mice revealed dysregulation of LXR as one of the key events in the pathogenesis of WD. Treatment with the LXR agonist T0901317 improved disease manifestations in the *Atp7b*<sup>-/-</sup> mice despite substantial Cu overload. Moreover, liver fibrosis and inflammation significantly decreased in LXR agonist-treated animals, while lipid profiles normalized and liver function and histology improved. Thus, the potential of T0901317 for WD cure is likely to be further explored.

## CELL THERAPY

Cell therapy, as well as gene therapy, targets the liver, which does not express functional *ATP7B* protein, aiming to restore hepatobiliary Cu excretion<sup>[22]</sup>. Cell therapy in WD seems feasible because transplanted hepatocytes can integrate in liver parenchyma and restore deficient functions, including the transport of Cu into bile. Animal WD models, especially the LEC rat, has facilitated cell transplantation research in WD<sup>[22]</sup>. It was through this animal model that it was found necessary to repopulate less than half of the liver with healthy hepatocytes in order to achieve sufficient Cu removal and therapeutic efficacy. However, in that study, not every animal subjected to cell therapy showed equivalent benefits<sup>[22]</sup>.

Extrahepatic cell therapy using engineering applications (*i.e.*, transplantation of liver tissue into small intestine or the abdominal cavity) is currently considered insufficient because Cu removal requires an intact bile excretion system. Thus, in the case of either cell or gene therapy in WD, liver is the first target considering the physiological restriction of *ATP7B* expression to hepatocytes as well as the availability of mechanisms to eliminate Cu from the body<sup>[23]</sup>. Fortunately, transplantation studies using donor cells have confirmed the ability for biliary excretion, providing the first clue that biliary Cu transport is a feasible target for cell therapy in WD<sup>[24]</sup>.

IPSC-derived HLCs can repopulate the liver but they support only some hepatocyte functions, which are restricted to fetal-like stages<sup>[10]</sup>. Therefore, transplanted cells can proliferate in the presence of native cells, having a low rate of proliferation. This happens when native liver cells have extensive DNA damage (as induced by toxins, ischemia and/or hepatectomy). Obviously these preconditioning regimens are undesirable in the setting of existing liver injury in WD. The ability of transplanted HLCs to express *ATP7B* was evaluated in liver of LEC mice, in which the transplanted cells did not increase in number over an observational period of several months<sup>[25]</sup>. Therefore, liver repopulation over a very long period implies that therapeutic correction in WD will require significant time<sup>[22]</sup>.

## GENE THERAPY

Gene therapy aims to correct the defect in native hepatocytes by providing healthy copies of *ATP7B* via introduction of a transgene by vectors capable of indefinitely integrating and/or persisting in cells. The proof-of-principle for gene therapy in WD came from adenoviral and lentiviral vector expression of *ATP7B* in the liver of rodent models, which achieved transient correction of Cu excretion and incorporation of Cu into ceruloplasmin<sup>[26]</sup>.

Recently, these initial observations were confirmed with an adeno-associated vector serotype 8 (AAV8) encoding the human *ATP7B* cDNA placed under control of the liver-specific  $\alpha$ 1-antitrypsin promoter (AAV8-AAT-*ATP7B*). Expression of AAV8-AAT-*ATP7B* in *ATP7B*-deficient mice resulted in reductions of liver enzymes and recovery of physiological biliary Cu excretion<sup>[27]</sup>. This study showed a solid background for future translational studies. AAV-mediated gene therapy should allow *ATP7B* to be permanently expressed in WD patient liver and, hence, would eliminate a need for lifelong intake of Cu-reducing drugs. On the other hand, such risks as immune response, tumor biogenesis and poor integration into damaged cells<sup>[28]</sup> have to be weighted before AAV-mediated gene transfer therapy and will be a critical component of the repertoire of WD treatments. Furthermore, studies investigating the fate of genetically modified native cells within the liver in WD are still required<sup>[22]</sup>.

## TRANSLATING NEW THERAPIES TO PATIENT BEDSIDE

To establish whether and when these new therapies will be appropriate for clinical trials, a number of key requirements must be met. First, the particular reference population must be identified for treatment. It is likely that potential candidates for this population will include asymptomatic or presymptomatic WD patients with an early disease, people with liver failure or severe neurologic deterioration who could benefit from rapid removal of Cu, and those with severe adverse reaction to preexisting therapy<sup>[22]</sup>. Considering the potential latency of some treatments before they become effective and the severe risks linked to suspension of preexisting treatment in WD patients, it seems possible to consider the combination of existing drugs and new therapies to mobilize Cu for early clinical trials. Moreover, it will be important to define appropriate tests and effective endpoints that, in addition to clinical parameters, may be useful for demonstrating therapeutic efficacy, considering that drug monitoring necessitates use of noninvasive assays and biomarkers. In this context, the discovery of new biomarkers in WD will be of great significance to enable new effective treatment.

## CONCLUSION

Emerging strategies for cure of WD foster new challenges that should be addressed by "precision" medicine, which takes in account the best available knowledge about disease mechanisms to establish approaches that yield an effective cure rate. Some compounds (tested in WD cell or animal models) seem to be close to translation into safe drugs and/or personalized treatments for WD patients. Advancing a WD cure will require an international cooperation to overcome the limited availability of affected patients who can be enrolled into clinical trials for development of new therapies. We hope that joint efforts between academia, industry, government and patient advocacy groups will allow for rapid progress and bring WD patient welfare to the forefront.

## REFERENCES

- Ala A, Walker AP, Ashkan K, Dooley JS, Schilsky ML. Wilson's disease. *Lancet* 2007; **369**: 397-408 [PMID: 17276780 DOI: 10.1016/S0140-6736(07)60196-2]
- de Bie P, Muller P, Wijmenga C, Klomp LW. Molecular pathogenesis of Wilson and Menkes disease: correlation of mutations with molecular defects and disease phenotypes. *J Med Genet* 2007; **44**: 673-688 [PMID: 17717039 DOI: 10.1136/jmg.2007.052746]
- European Association for Study of Liver. EASL Clinical Practice Guidelines: Wilson's disease. *J Hepatol* 2012; **56**: 671-685 [PMID: 22340672 DOI: 10.1016/j.jhep.2011.11.007]
- Weiss KH, Gotthardt DN, Klemm D, Merle U, Ferenci-Foerster D, Schaefer M, Ferenci P, Stremmel W. Zinc monotherapy is not as effective as chelating agents in treatment of Wilson disease. *Gastroenterology* 2011; **140**: 1189-1198.e1 [PMID: 21185835 DOI: 10.1053/j.gastro.2010.12.034]
- Ranucci G, Di Dato F, Spagnuolo MI, Vajro P, Iorio R. Zinc monotherapy is effective in Wilson's disease patients with mild liver disease diagnosed in childhood: a retrospective study. *Orphanet J Rare Dis* 2014; **9**: 41 [PMID: 24661374 DOI: 10.1186/1750-1172-9-41]
- Zimbrea PC, Schilsky ML. The spectrum of psychiatric symptoms in Wilson's disease: treatment and prognostic considerations. *Am J Psychiatry* 2015; **172**: 1068-1072 [PMID: 26575449 DOI: 10.1176/appi.ajp.2015.15030371]
- Iorio R, D'Ambrosio M, Marcellini M, Barbera C, Maggiore G, Zancan L, Giacchino R, Vajro P, Marazzi MG, Francavilla R, Michielutti F, Resti M, Frediani T, Pastore M, Vegnente A. Persistence of elevated aminotransferases in Wilson's disease despite adequate therapy. *Hepatology* 2004; **39**: 1173-1174 [PMID: 15057922 DOI: 10.1002/hep.20165]
- Roy-Chowdhury J, Schilsky ML. Gene therapy of Wilson disease: A "golden" opportunity using rAAV on the 50th anniversary of the discovery of the virus. *J Hepatol* 2016; **64**: 265-267 [PMID: 26639392 DOI: 10.1016/j.jhep.2015.11.017]
- Schilsky ML. Liver transplantation for Wilson's disease. *Ann N Y Acad Sci* 2014; **1315**: 45-49 [PMID: 24820352 DOI: 10.1111/nyas.12454]
- Takahashi K, Yamanaka S. A decade of transcription factor-mediated reprogramming to pluripotency. *Nat Rev Mol Cell Biol* 2016; **17**: 183-193 [PMID: 26883003 DOI: 10.1038/nrm.2016.8]
- Zhang S, Chen S, Li W, Guo X, Zhao P, Xu J, Chen Y, Pan Q, Liu X, Zychlinski D, Lu H, Tortorella MD, Schambach A, Wang Y, Pei D, Esteban MA. Rescue of ATP7B function in hepatocyte-like cells from Wilson's disease induced pluripotent stem cells using gene therapy or the chaperone drug curcumin. *Hum Mol Genet* 2011; **20**: 3176-3187 [PMID: 21593220 DOI: 10.1093/hmg/ddr223]
- Huster D, Kühne A, Bhattacharjee A, Raines L, Jantsch V, Noe J, Schirrmeister W, Sommerer I, Sabri O, Berr F, Mössner J, Stieger B, Caca K, Lutsenko S. Diverse functional properties of Wilson disease ATP7B variants. *Gastroenterology* 2012; **142**: 947-956.e5 [PMID: 22240481 DOI: 10.1053/j.gastro.2011.12.048]
- Schmidt BZ, Haaf JB, Leal T, Noel S. Cystic fibrosis transmembrane conductance regulator modulators in cystic fibrosis: current perspectives. *Clin Pharmacol* 2016; **8**: 127-140 [PMID: 27703398 DOI: 10.2147/CPAA.S100759]
- van den Berghe PV, Stapelbroek JM, Krieger E, de Bie P, van de Graaf SF, de Groot RE, van Beurden E, Spijker E, Houwen RH, Berger R, Klomp LW. Reduced expression of ATP7B affected by Wilson disease-causing mutations is rescued by pharmacological folding chaperones 4-phenylbutyrate and curcumin. *Hepatology* 2009; **50**: 1783-1795 [PMID: 19937698 DOI: 10.1002/hep.23209]
- Dey I, Shah K, Bradbury NA. Natural Compounds as Therapeutic Agents in the Treatment Cystic Fibrosis. *J Genet Syndr Gene Ther* 2016; **7**: pii: 284 [PMID: 27081574 DOI: 10.4172/2157-7412.1000284]
- Materia S, Cater MA, Klomp LW, Mercer JF, La Fontaine S. Clusterin and COMMD1 independently regulate degradation of the mammalian copper ATPases ATP7A and ATP7B. *J Biol Chem* 2012; **287**: 2485-2499 [PMID: 22130675 DOI: 10.1074/jbc.M111.302216]
- D'Agostino M, Lemma V, Chesi G, Stornaiuolo M, Cannata Serio M, D'Ambrosio C, Scaloni A, Polishchuk R, Bonatti S. The cytosolic chaperone  $\alpha$ -crystallin B rescues folding and compartmentalization of misfolded multispan transmembrane proteins. *J Cell Sci* 2013; **126**: 4160-4172 [PMID: 23843626 DOI: 10.1242/jcs.125443]
- Chesi G, Hegde RN, Iacobacci S, Concilli M, Parashuraman S, Festa BP, Polishchuk EV, Di Tullio G, Carissimo A, Montefusco S, Canetti D, Monti M, Amoresano A, Pucci P, van de Sluis B, Lutsenko S, Luini A, Polishchuk RS. Identification of p38 MAPK and JNK as new targets for correction of Wilson disease-causing ATP7B mutants. *Hepatology* 2016; **63**: 1842-1859 [PMID: 26660341 DOI: 10.1002/hep.28398]
- Concilli M, Iacobacci S, Chesi G, Carissimo A, Polishchuk R. A systems biology approach reveals new endoplasmic reticulum-associated targets for the correction of the ATP7B mutant causing Wilson disease. *Metallomics* 2016; **8**: 920-930 [PMID: 27714068 DOI: 10.1039/c6mt00148c]
- Summer KH, Lichtmanegger J, Bandow N, Choi DW, DiSpirito AA, Michalke B. The biogenic methanobactin is an effective chelator for copper in a rat model for Wilson disease. *J Trace Elem Med Biol* 2011; **25**: 36-41 [PMID: 21242075 DOI: 10.1016/j.jtemb.2010.12.002]
- Hamilton JP, Koganti L, Muchenditsi A, Pendyala VS, Huso D, Hankin J, Murphy RC, Huster D, Merle U, Mangels C, Yang N, Potter JJ, Mezey E, Lutsenko S. Activation of liver X receptor/retinoid X receptor pathway ameliorates liver disease in Atp7B(-/-) (Wilson disease) mice. *Hepatology* 2016; **63**: 1828-1841 [PMID: 26679751 DOI: 10.1002/hep.28406]
- Gupta S. Cell therapy to remove excess copper in Wilson's disease. *Ann N Y Acad Sci* 2014; **1315**: 70-80 [PMID: 24820353 DOI: 10.1111/nyas.12450]
- Jaber FL, Sharma Y, Gupta S. Demonstrating Potential of Cell Therapy for Wilson's Disease with the Long-Evans Cinnamon Rat Model. *Methods Mol Biol* 2017; **1506**: 161-178 [PMID: 27830552 DOI: 10.1007/978-1-4939-6506-9\_11]
- Gupta S, Rajvanshi P, Lee CD. Integration of transplanted hepatocytes into host liver plates demonstrated with dipeptidyl peptidase IV-deficient rats. *Proc Natl Acad Sci USA* 1995; **92**: 5860-5864 [PMID: 7597042 DOI: 10.1073/pnas.92.13.5860]
- Shafritz DA, Oertel M. Model systems and experimental conditions that lead to effective repopulation of the liver by transplanted cells. *Int J Biochem Cell Biol* 2011; **43**: 198-213 [PMID: 20080205 DOI: 10.1016/j.biocel.2010.01.013]
- Roybal JL, Endo M, Radu A, Gray L, Todorow CA, Zoltick PW, Lutsenko S, Flake AW. Early gestational gene transfer with

- targeted ATP7B expression in the liver improves phenotype in a murine model of Wilson's disease. *Gene Ther* 2012; **19**: 1085-1094 [PMID: 22158007 DOI: 10.1038/gt.2011.186]
- 27 **Murillo O**, Luqui DM, Gazquez C, Martinez-Espartosa D, Navarro-Blasco I, Monreal JI, Guembe L, Moreno-Cermeño A, Corrales FJ, Prieto J, Hernandez-Alcoceba R, Gonzalez-Aseguinolaza G. Long-term metabolic correction of Wilson's disease in a murine model by gene therapy. *J Hepatol* 2016; **64**: 419-426 [PMID: 26409215 DOI: 10.1016/j.jhep.2015.09.014]
- 28 **Auman JT**. Gene therapy: Have the risks associated with viral vectors been solved? *Curr Opin Mol Ther* 2010; **12**: 637-638 [PMID: 21280375]

**P- Reviewer:** Chen C, da Silva FP, Nemeth D    **S- Editor:** Gong ZM

**L- Editor:** A    **E- Editor:** Huang Y



## Are our endoscopy patients at risk for pyogenic liver abscess?

Herwig Cerwenka, Peter Schemmer

Herwig Cerwenka, Peter Schemmer, Department of Surgery, Medical University of Graz, 8036 Graz, Austria

**Author contributions:** All authors discussed the article and contributed to the writing of the comment; each of them approved the final manuscript.

**Conflict-of-interest statement:** The authors declare no conflict of interest for this editorial comment.

**Open-Access:** This article is an open-access article which was selected by an in-house editor and fully peer-reviewed by external reviewers. It is distributed in accordance with the Creative Commons Attribution Non Commercial (CC BY-NC 4.0) license, which permits others to distribute, remix, adapt, build upon this work non-commercially, and license their derivative works on different terms, provided the original work is properly cited and the use is non-commercial. See: <http://creativecommons.org/licenses/by-nc/4.0/>

**Manuscript source:** Invited manuscript

**Correspondence to:** Dr. Herwig Cerwenka, Professor, Department of Surgery, Medical University of Graz, Auenbruggerplatz 29, 8036 Graz, Austria. [herwig.cerwenka@medunigraz.at](mailto:herwig.cerwenka@medunigraz.at)  
Telephone: +43-316-38512755  
Fax: +43-316-38513418

Received: May 25, 2017

Peer-review started: May 28, 2017

First decision: June 23, 2017

Revised: June 27, 2017

Accepted: July 22, 2017

Article in press: July 24, 2017

Published online: August 14, 2017

### Abstract

This is an editorial comment on a recent publication reporting an increased rate of pyogenic liver abscesses (PLAs) after upper gastrointestinal panendoscopy. Its aim is to critically highlight the findings, limitations and

potential clinical implications of this study. Issues of the mucosal barrier, the microbial flora, administration of antibiotics and underlying diseases are discussed. The probability of PLAs after endoscopies is not exactly known and the length of the "incubation period" remains unclear, but a possible causality should already suffice to make us think how to avoid them. Especially in patients with risk factors such as diabetes mellitus, end-stage renal disease, liver cirrhosis, biliary tract infection, and malignancies, the potential risk for PLAs should be considered. Unnecessary insufflation during endoscopy (causing mucosal stretching and microscopic tears) as well as mucosal damage (by direct abrasion with the scope) should be avoided in order to limit the invasiveness of the procedure as much as possible. And, in everyday routine, it should be kept in mind that in patients after endoscopy, especially in those with a breach of the mucosal barrier and significant comorbidities, PLAs can potentially develop and require timely administration of antibiotics as well as further diagnostic and therapeutic steps.

**Key words:** Endoscopy; Pyogenic liver abscess; Mucosal barrier; Gastrointestinal microbial flora; Comorbidities

© **The Author(s) 2017.** Published by Baishideng Publishing Group Inc. All rights reserved.

**Core tip:** An increased rate of pyogenic liver abscesses after upper gastrointestinal endoscopy has been reported in a recent publication, leaving clinicians in some kind of predicament. Are we really exposing our endoscopy patients to a considerable danger? In an invited editorial comment on this study, the background, limitations and potential clinical implications of the findings are discussed.

Cerwenka H, Schemmer P. Are our endoscopy patients at risk for pyogenic liver abscess? *World J Gastroenterol* 2017; 23(30): 5457-5459 Available from: URL: <http://www.wjgnet.com>



## INTRODUCTION

In the study published by Tsai *et al*<sup>[1]</sup> on 2135 patients with a first diagnosis of pyogenic liver abscess (PLA) and 10675 patients without PLA selected as reference controls, a higher rate of PLAs was found in those who had recently undergone an upper gastrointestinal panendoscopy. The authors concluded that clinical physicians should not ignore this. In spite of some limitations, especially related to the use of retrospective registry data, this study leaves us in some kind of predicament. Are we really exposing our endoscopy patients to a considerable danger?

## MUCOSAL BARRIER

Theoretically, every endoscopy may cause a breach of the mucosal barrier and post-endoscopy bacteremia has indeed been reported<sup>[2-4]</sup>. However, PLA is known not to develop very easily and to affect predominantly patients with comorbidities and a weakened immune system<sup>[5,6]</sup>. In addition to the patient's condition, the extent of mucosal damage could also play a role. Are microscopic leaks relevant in immunocompetent persons? The study by Tsai *et al*<sup>[1]</sup> does not comprise the diagnoses made at the endoscopies. It would be important to know how many patients had pathologies leading to an obvious disruption of the continuity of the mucosal barrier like ulcers or erosive inflammation. Another point of easy entrance for bacteria causing PLA (in this case *via* the biliary route) would be the papilla of Vater after endoscopic papillotomy. Patients with recent ERCP were excluded in this study, but the authors provide no information on papillotomies made longer ago.

## MICROBIAL FLORA

The mucosal surface of the gastrointestinal tract is colonized by 400 different bacterial species and subspecies<sup>[7]</sup>. In general, pathogens are part of a transient flora emerging under abnormal conditions, but some autochthonous germs may also become pathogenic under certain circumstances. The stomach, the duodenum and the jejunum contain only low numbers of microorganisms (103 to 104 bacteria/mL), notably acid-tolerant lactobacilli and streptococci, whereas the colon is the main site of microbial colonization<sup>[7]</sup>. It is, therefore, surprising, that, in this study, the risk of developing PLAs was higher for patients with upper gastrointestinal endoscopies than for those with colonoscopies. Likewise, a higher and not a lower rate of PLAs would have been expected

in those with interventional endoscopic procedures associated with a more severe mucosal damage. As for the colonoscopies, the authors argue that the colon is further away from the portal venous and lymphatic circulations to the liver than the esophagus, stomach, and duodenum, and that it has a potent mesenteric lymphatic defense system<sup>[1]</sup>. Nevertheless, it is well known, that underlying pathologies in the whole gastrointestinal tract can be found in patients with manifest cryptogenic PLAs<sup>[8,9]</sup>. In terms of the interventional procedures, a possible explanation given, but not proven, by the authors is that more patients in these groups may have had antimicrobial treatment<sup>[1]</sup>.

## ANTIBIOTICS

In fact, the use of antibiotics is an essential point. Although they are not given routinely as a prophylaxis for endoscopy patients, some of the study patients will have been on current antibiotic regimens for various reasons. In general, PLAs respond well to the administration of antibiotics and the microbial spectrum of these abscesses is covered by many of them. For a clearer picture on the pathogenesis of the PLAs and of the role of antibiotics in this study, it would also be necessary to know the results of microbial cultures of the aspirates from the abscess cavities as well as details on the use of antimicrobial substances.

## COINCIDENCES

Another issue requiring clarification is if some of the endoscopy patients already had concomitant incipient PLAs not yet diagnosed at the time of the examination. The presenting symptoms of PLAs may be vague and indeed, unspecific pain associated with undiagnosed PLA could even have been the motive for performing the endoscopy. In one of the study patients, the PLA was diagnosed as early as one day after the panendoscopy<sup>[1]</sup>. Here a coincidence seems most likely. The length of the "incubation time" for PLA after panendoscopy remains an unanswered question.

## CONSEQUENCES

In conclusion, we do not exactly know the probability of PLAs after endoscopies, but a possible causality should already suffice to make us think how to avoid them. What can be done? It will not be advisable to renounce at endoscopies in patients requiring them for therapeutic, diagnostic or prophylactic purposes nor will it be reasonable to make these patients afraid. It will also still be indicated to do endoscopies in order to identify underlying diseases in patients with manifest cryptogenic PLAs<sup>[10]</sup> without fearing to aggravate the abscesses. However, especially in patients with risk factors such as diabetes mellitus, end-stage renal disease, liver cirrhosis, biliary tract infection, and

malignancies, the potential risk for PLAs should be considered. Strict disinfection processes are a matter of course. Unnecessary insufflation during endoscopy (causing mucosal stretching and microscopic tears) as well as mucosal damage (by direct abrasion with the scope) should be avoided in order to limit the invasiveness of the procedure as much as possible. And, in everyday routine, it should be kept in mind that in patients after endoscopy, especially in those with a breach of the mucosal barrier and significant comorbidities, PLAs can potentially develop and require timely administration of antibiotics as well as further diagnostic and therapeutic steps.

## REFERENCES

- 1 **Tsai MJ**, Lu CL, Huang YC, Liu CH, Huang WT, Cheng KY, Chen SC. Recent upper gastrointestinal panendoscopy increases the risk of pyogenic liver abscess. *World J Gastroenterol* 2017; **23**: 2948-2956 [PMID: 28522912 DOI: 10.3748/wjg.v23.i16.2948]
- 2 **ASGE Standards of Practice Committee.**, Khashab MA, Chithadi KV, Acosta RD, Bruining DH, Chandrasekhara V, Eloubeidi MA, Fanelli RD, Faulx AL, Fonkalsrud L, Lightdale JR, Muthusamy VR, Pasha SF, Saltzman JR, Shaikat A, Wang A, Cash BD. Antibiotic prophylaxis for GI endoscopy. *Gastrointest Endosc* 2015; **81**: 81-89 [PMID: 25442089 DOI: 10.1016/j.gie.2014.08.008]
- 3 **ASGE Standards of Practice Committee.**, Ben-Menachem T, Decker GA, Early DS, Evans J, Fanelli RD, Fisher DA, Fisher L, Fukami N, Hwang JH, Ikenberry SO, Jain R, Jue TL, Khan KM, Krinsky ML, Malpas PM, Maple JT, Sharaf RN, Dominitz JA, Cash BD. Adverse events of upper GI endoscopy. *Gastrointest Endosc* 2012; **76**: 707-718 [PMID: 22985638 DOI: 10.1016/j.gie.2012.03.252]
- 4 **ASGE Standards of Practice Committee.**, Fisher DA, Maple JT, Ben-Menachem T, Cash BD, Decker GA, Early DS, Evans JA, Fanelli RD, Fukami N, Hwang JH, Jain R, Jue TL, Khan KM, Malpas PM, Sharaf RN, Shergill AK, Dominitz JA. Complications of colonoscopy. *Gastrointest Endosc* 2011; **74**: 745-752 [PMID: 21951473 DOI: 10.1016/j.gie.2011.07.025]
- 5 **Cerwenka H.** Pyogenic liver abscess: differences in etiology and treatment in Southeast Asia and Central Europe. *World J Gastroenterol* 2010; **16**: 2458-2462 [PMID: 20503444 DOI: 10.3748/wjg.v16.i20.2458]
- 6 **Cerwenka H**, Bacher H, Werkgartner G, El-Shabrawi A, Kornprat P, Bernhardt GA, Mischinger HJ. Treatment of patients with pyogenic liver abscess. *Chemotherapy* 2005; **51**: 366-369 [PMID: 16227693]
- 7 **Hao WL**, Lee YK. Microflora of the gastrointestinal tract: a review. *Methods Mol Biol* 2004; **268**: 491-502 [PMID: 15156063]
- 8 **Cerwenka H.** Liver abscesses, elevated carbohydrate antigen 19-9 and concomitant malignancies. *J Hepatobiliary Pancreat Sci* 2015; **22**: E47 [PMID: 26199178 DOI: 10.1002/jhbp.266]
- 9 **Cerwenka H.** Pyogenic liver abscess and silent pathologies of the digestive tract. *Gastroenterol Hepatol (N Y)* 2008; **4**: 819-820 [PMID: 21960905]
- 10 **Cerwenka H.** Colorectal neoplasia and pyogenic liver abscess. *Scand J Infect Dis* 2013; **45**: 336 [PMID: 23113711 DOI: 10.3109/00365548.2012.733957]

**P- Reviewer:** Fujimori S, Sivandzadeh GR **S- Editor:** Qi Y  
**L- Editor:** A **E- Editor:** Zhang FF



## Pancreatitis: Preventing catastrophic haemorrhage

Richard PT Evans, Moustafa Mabrouk Mourad, Gunraj Pall, Simon G Fisher, Simon R Bramhall

Richard PT Evans, Gunraj Pall, Russel's Hall Hospital, Dudley DY1 2HQ, United Kingdom

Published online: August 14, 2017

Moustafa Mabrouk Mourad, Simon G Fisher, Simon R Bramhall, Department of Surgery, the Wye Valley NHS Trust, Hereford HR1 2ER, United Kingdom

**Author contributions:** Evans RPT designed the study; Evans RPT, Mourad MM and Pall G collected, analysed, interpreted the data, and drafted the article; Fisher SG and Bramhall SR designed the conception, critically revised the manuscript for important intellectual content, and made the final approval of the version to be published.

**Conflict-of-interest statement:** None of the authors has any potential conflicting financial interests relevant to this article.

**Open-Access:** This article is an open-access article which was selected by an in-house editor and fully peer-reviewed by external reviewers. It is distributed in accordance with the Creative Commons Attribution Non Commercial (CC BY-NC 4.0) license, which permits others to distribute, remix, adapt, build upon this work non-commercially, and license their derivative works on different terms, provided the original work is properly cited and the use is non-commercial. See: <http://creativecommons.org/licenses/by-nc/4.0/>

**Manuscript source:** Invited manuscript

**Correspondence to:** Dr. Simon R Bramhall, Department of Surgery, the Wye Valley NHS Trust, Stonebow Rd, Hereford HR1 2ER, United Kingdom. [simon.bramhall@wvt.nhs.uk](mailto:simon.bramhall@wvt.nhs.uk)  
Telephone: +44-7976-278549  
Fax: +44-1432-364102

**Received:** March 14, 2017

**Peer-review started:** March 18, 2017

**First decision:** April 5, 2017

**Revised:** May 3, 2017

**Accepted:** July 12, 2017

**Article in press:** July 12, 2017

### Abstract

Pancreatitis represents nearly 3% of acute admissions to general surgery in United Kingdom hospitals and has a mortality of around 1%-7% which increases to around 10%-18% in patients with severe pancreatitis. Patients at greatest risk were those identified to have infected pancreatic necrosis and/or organ failure. This review seeks to highlight the potential vascular complications associated with pancreatitis that despite being relatively uncommon are associated with mortality in the region of 34%-52%. We examine the current evidence base to determine the most appropriate method by which to image and treat pseudo-aneurysms that arise as the result of acute and chronic inflammation of pancreas. We identify how early recognition of the presence of a pseudo-aneurysm can facilitate expedited care in an expert centre of a complex pathology that may require angiographic, percutaneous, endoscopic or surgical intervention to prevent catastrophic haemorrhage.

**Key words:** Complication of pancreatitis; Splenic artery; Pancreatitis; Haemorrhage; Pseudoaneurysm

© **The Author(s) 2017.** Published by Baishideng Publishing Group Inc. All rights reserved.

**Core tip:** Pancreatitis represents nearly 3% of acute admissions to general surgery in United Kingdom hospitals. The presence of a fluid collection, necrosis and infection can directly contribute to such vascular complications which are associated with a significant morbidity and mortality. Early recognition of the presence of a pseudo-aneurysm can facilitate expedited care in an expert centre of a complex pathology that

may require angiographic, percutaneous, endoscopic or surgical intervention to prevent catastrophic haemorrhage.

Evans RPT, Mourad MM, Pall G, Fisher SG, Bramhall SR. Pancreatitis: Preventing catastrophic haemorrhage. *World J Gastroenterol* 2017; 23(30): 5460-5468 Available from: URL: <http://www.wjgnet.com/1007-9327/full/v23/i30/5460.htm> DOI: <http://dx.doi.org/10.3748/wjg.v23.i30.5460>

## INTRODUCTION

Pancreatitis represents nearly 3% of acute admissions to general surgery in United Kingdom hospitals<sup>[1]</sup>. Although this may seem like a relatively small proportion of patients the impact of the pancreatic patient has a significant influence on hospital services due to the sizeable morbidity and mortality associated with pancreatitis. The annual incidence of acute pancreatitis ranges from 13 to 45 per 100000 persons worldwide and is around 13-45 per 100000 people in the United Kingdom which is increasing at a rate of 2.7% each year<sup>[2-6]</sup>. The number of admissions due to pancreatitis in the US has doubled since 1988. There are now nearly 275000 admissions each year due to pancreatitis<sup>[7,8]</sup>. It is estimated that between 20%-30% of patients will have a further episode of acute pancreatitis and 10% of patients will go on to develop chronic pancreatitis<sup>[9-12]</sup>. The current incidence rates of chronic pancreatitis are around 5-23 per 100000 people<sup>[5,13,14]</sup>. Pancreatitis has a mortality of around 1%-7% which increases to around 10%-18% in patients with severe pancreatitis<sup>[1-4,15]</sup>. Patients at greatest risk were those identified to have infected pancreatic necrosis and/or organ failure<sup>[16]</sup>.

In order to appropriately manage patients with pancreatitis multiple scoring systems have been created to try to determine the severity of pancreatitis and the risk of morbidity and mortality including the Glasgow score, Ransom score, Balthazar score, Apache 2 score, and the modified Marshall score<sup>[17-19]</sup>. Many continue to be used routinely in clinical practice to improve the treatment of patients with pancreatitis. Understanding that certain patients with more severe pancreatitis have a higher risk of morbidity and mortality allows clinicians to maintain a high index of suspicion in order to identify early the complications of pancreatitis. The revised Atlanta guidelines identify two key phases to acute pancreatitis. In early phase it is associated with systemic disturbances as the result of the host response to local pancreatic injury<sup>[17]</sup> (Table 1). The cytokine cascade as the result of pancreatic inflammation can be clinically manifested as a systemic inflammatory response syndrome which in turn may precipitate organ failure. The presence and duration of organ failure is a key determinant in defining severity

of acute pancreatitis (Table 2). Late phase pancreatic inflammation is defined by the presence of ongoing systemic symptoms of inflammation such as persistent organ failure or local complications.

Local complications of pancreatitis often cause patients to develop a late phase pancreatitis. Interstitial oedematous pancreatitis with or without necrosis may be complicated by the presence of pancreatic and peri-pancreatic collections. The presence of such collections can be broadly divided into five categories. Acute peri-pancreatic fluid collections usually arise in the acute phase of pancreatitis and are confined with normal anatomical planes. They commonly remain sterile however if they persist for greater than 4 wk they commonly form into a pseudocyst. A pancreatic pseudocyst is formed beyond 4 wk and demonstrates a walled off fluid collection in the absence of necrosis. The presence of necrosis can be categorised as either an acute necrotic collection (ANC) or a walled off necrosis (WON). Infected necrosis may occur in either ANC or WON and will present with the presence of gas within the collection on imaging or positive microbiological samples taken directly from the area of necrosis (Table 3). Acute and chronic inflammation as a result of pancreatitis can cause both thrombotic and haemorrhagic complications. The presence of a fluid collection, necrosis and infection can directly contribute to such vascular complications which are associated with a significant morbidity and mortality.

## ARTERIAL COMPLICATIONS IN ACUTE PANCREATITIS

### *Incidence, causes, and presentations*

Vascular complications are relatively uncommon and occur in between 1%-23% of patients with pancreatitis. Venous complications are significantly more common than arterial complications. Arterial complications occur in around 1.3%-10% of patients<sup>[20-28]</sup>. Thrombosis of the portal and splenic vein has been shown to occur up to 23% and 22% of patients with pancreatitis respectively<sup>[23,29]</sup>. Portal vein thrombosis increases to 30% in those with peri-pancreatic collection and as high as 57% in patients with necrotising pancreatitis (Table 4)<sup>[29]</sup>.

It is important to identify arterial complications early and treat aggressively as they are associated with a mortality of between 34%-52%<sup>[26,28,30-35]</sup>. Sixty percent of all acute haemorrhage in the presence of pancreatitis occurs as the result of ruptured pseudo-aneurysms in the presence of necrotising pancreatitis. Haemorrhagic pseudocysts without pseudoaneurysms and capillary, venous or small vessel haemorrhage only account for approximately 20% of cases<sup>[22]</sup>.

Arterial complications often arise as the result of arterial wall disruption in the presence of free lipolytic and proteolytic enzymes. Severe pancreatic inflammation and necrosis leads to the disruption



**Table 1 Early vs late pancreatitis**

Early phase pancreatitis	Late phase pancreatitis
Systemic disturbances result from the host response to local pancreatic injury.	Persistence of systemic signs of inflammation.
Clinical manifestation with associated SIRS response.	Presence of local complications.
Usually lasts less than one week but may extend into the second week.	Compensatory inflammatory response syndrome.
Severity determined by presence of organ failure. Transient < 48 h. Persistent > 48 h.	

**Table 2 Defining pancreatic severity**

Mild acute pancreatitis	No organ failure No local complications
Moderately severe acute pancreatitis	Organ failure that resolves within 48 h (transient organ failure) and/or Local or systemic complications without persistent organ failure
Severe acute pancreatitis	Persistent organ failure (single/multiple) > 48 h

**Table 3 Defining pancreatic and peri-pancreatic collections**

Acute peri-pancreatic fluid collection	Do not have well defined walls Homogenous, confined to normal fascial planes in retroperitoneum May be multiple Likely to develop into a pseudocyst if they persist > 4 wk
Pancreatic pseudocyst	Fluid collection in peri-pancreatic tissues Occasionally partly/totally intra-pancreatic Well defined wall with essentially no solid material Occur typically after 4 wk
Acute necrotic collection	Fluid collection within the first 4 wk containing necrotic tissue and fluid. Presence of necrosis differentiates it from APFC
Walled off necrosis	Necrotic tissue contained within an enhancing wall of reactive tissue Usually occurs > 4 wk after the onset of necrotising pancreatitis
Infected necrosis	Presence of gas within collection Positive cultures post FNA

APFC: Acute peri-pancreatic fluid collection.

of pancreatic tissue and subsequent pancreatic fluid release which has a high enzymatic content. These disruptive processes are further proliferated by the cytokine cascade that develops due to pancreatitis. Such processes in combination with pressure necrosis can lead to pseudo-aneurysm formation or spontaneous arterial rupture. Bleeding may also develop from the disruption of the wall of a pseudocyst or WON.

The presence of radiologically inserted drains can also cause direct trauma to vessels. Drains can perpetuate local inflammation which in turn can further diminish arterial wall integrity. Surgical intervention in the form of necrosectomy can disrupt arterial integrity

**Table 4 Different types and incidence of vascular complications in pancreatitis**

Vascular complications of pancreatitis	Incidence
Arterial complications	1.3%-10% of patients with pancreatitis
Ruptured pseudo-aneurysm	60% of all acute haemorrhage in pancreatitis
Haemorrhagic pseudocysts without pseudoaneurysms	20% of all acute haemorrhage in pancreatitis
Capillary, venous or small vessel haemorrhage	20% of all acute haemorrhage in pancreatitis
Venous complications	1%-23% of patients with pancreatitis
Portal vein thrombosis	23% of patients with pancreatitis
Splenic vein thrombosis	22% of patients with pancreatitis
Superior mesenteric vein thrombosis	19% of patients with pancreatitis

and lead to the development of arterial complications. Multi organ failure, necrosis, peri-pancreatic infection, long-term anticoagulation and underlying vasculitis all increase the risk of vascular complications<sup>[35]</sup>. Pancreatic necrosis is specifically associated with an increased risk of major haemorrhage<sup>[28]</sup>. There is no evidence to confirm that fungal infections confer an increased risk of pseudoaneurysm formation in pancreatitis as compared to bacterial infection, however anecdotally in immunosuppressed patients fungal infections are closely associated with pseudoaneurysm formation. Due to the significant structural integrity of arteries the time taken for a pseudo-aneurysm to form can vary greatly from weeks to even years<sup>[22,29,36]</sup>.

Although we are aware of certain risk factors for haemorrhage associated with pseudo-aneurysms it is challenging to quantify the impact that acute vs chronic inflammation has on vessel stability. Current evidence on acute haemorrhage is predominantly small volume case series of a mixed population of patients who have been treated for acute haemorrhage. However Zyromski *et al*<sup>[37]</sup> identified 24 patients with a pseudoaneurysm associated with pancreatitis of which 22 patients had acute on chronic pancreatitis and 2 patients presented during their first episode of acute pancreatitis. Twenty-one patients had a collection or pseudocyst and 2 had identifiable necrosis. Sethi *et al*<sup>[38]</sup> demonstrated that of those undergoing mesenteric angiography for bleeding associated with pancreatitis 8 had acute pancreatitis and 8 had chronic pancreatitis. Within the acute population three patients were diagnosed with necrotising pancreatitis and one required necrosectomy. Seven of the eight patients with chronic pancreatitis had confirmed pseudocyst formation and one developed acute necrosis on a background of chronic pancreatitis. Udd *et al*<sup>[21]</sup> looked at 33 patients with chronic pancreatitis and bleeding pancreatic pseudoaneurysms. They showed that 1.7% of admissions related to chronic pancreatitis

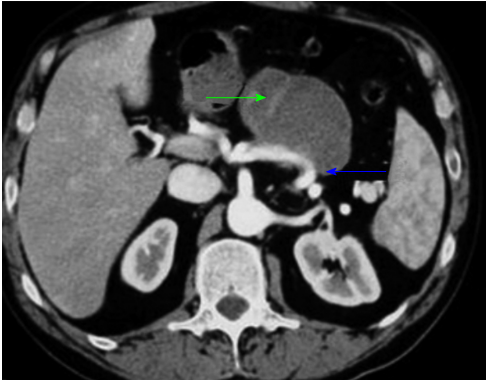


Figure 1 Computed tomography arterial and venous phase showing a pseudocyst (green arrows) eroding the splenic artery (blue arrows)<sup>[90]</sup>.

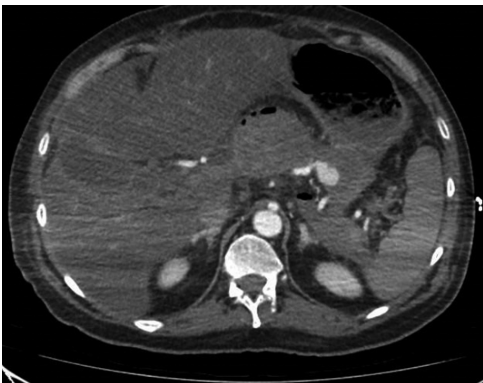

Figure 2 Computed tomography arterial and venous phases showing a pseudoaneurysm in a patient with necrotizing pancreatitis.

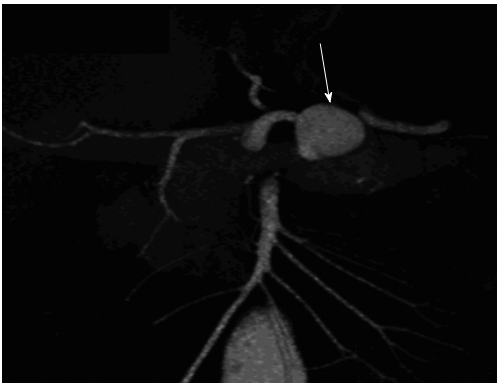


Figure 3 Three-D coronal maximum-intensity-projection computed tomography image in a 45-year-old man who had remote history of pancreatitis presented with back pain showing 2.0-cm pseudoaneurysm (arrow) arising from splenic artery<sup>[91]</sup>.

were due to haemorrhage. They found that within the study population seven had pseudocysts two of which required percutaneous drainage and six patients had undergone a previous operation. There is no definitive evidence to show that patients with chronic pancreatitis and pseudocyst formation are at greater risk of developing arterial complications as compared to patients with severe acute pancreatitis with necrosis

yet both are at high risk.

Symptomatic pseudo-aneurysms can present in varying ways however the most common symptom described is abdominal pain. Around 29.5% of patients will have abdominal pain which may reflect bleeding in the retroperitoneum. However there is a degree of ambiguity in the cause of such symptoms as pancreatitis in itself is painful. Bleeding into the gastrointestinal tract can occur in around 26.5% with haemosuccus pancreaticus (haemorrhage into pancreatic duct) being present in 20% of patients and also bleeding in pancreatic pseudocyst (Figure 1)<sup>[39]</sup>. Symptomatology is also dependent on the anatomical location of the pseudo-aneurysm.

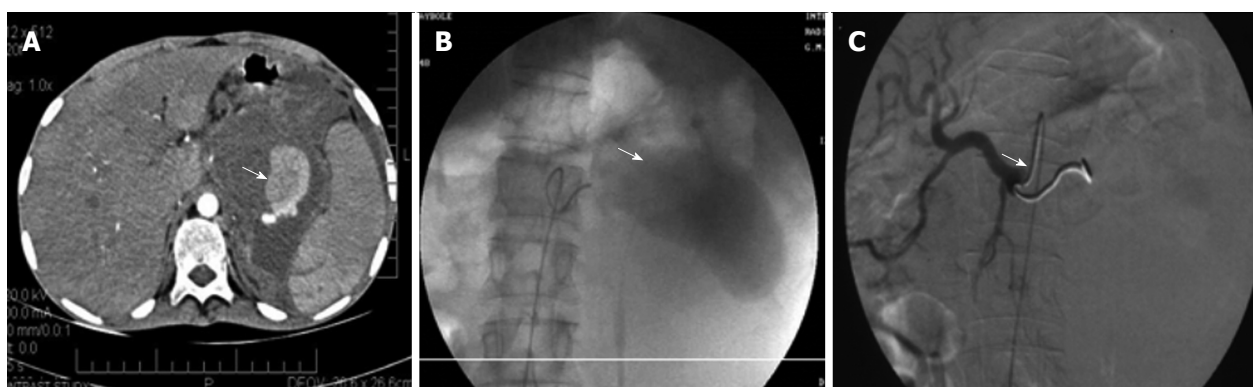
#### Site of pseudoaneurysm

The most common site for pseudo-aneurysms is the splenic artery which occurs 35%-50% of occasions (Figures 2 and 3). The gastroduodenal and pancreaticoduodenal vessels each account for 20%-25% of pseudo-aneurysms. Mesenteric, colic and hepatic vessels commonly make up the remaining sites<sup>[20,31,40-50]</sup>. Aortic involvement can occur in up to 0.5% of cases<sup>[51,52]</sup>. Case reports have also identified individual cases of the left sub-capsular renal artery and the left phrenic artery<sup>[53,54]</sup>. Vessels in close proximity to the gastrointestinal tract have a greater risk of manifesting as luminal bleeding.

#### Imaging diagnosis

Identification of a pseudo-aneurysm is typically by CT imaging however the indication for imaging can vary<sup>[22,30,55]</sup>. Ultrasound has been shown to be less sensitive than CT in identifying such complications however, still has an important role in identifying venous complications such as portal vein thrombosis<sup>[29,56]</sup>. It may also have a limited role in those allergic to iodine and certain cases of renal insufficiency<sup>[57]</sup>. Current guidance for patients with complicated pancreatitis with evidence of significant inflammation, infection and/or organ dysfunction is to undergo planned cross-sectional imaging in order to determine whether there is a complication of pancreatitis. Cross-sectional imaging for pancreatitis should occur a minimum of 72 h after the onset of symptoms unless there is diagnostic ambiguity<sup>[58]</sup>. At present there is no strong evidence to differentiate between the use of CT and MRI however MRI may show greater detail in differentiating the different types of peri- and intra-pancreatic collections, such as necrosis with pus, necrosis without pus and fluid collection without necrosis; these findings may be better defined by MRI<sup>[17,59]</sup>.

Present evidence supports contrast enhanced triple phase CT as the best imaging modality for vascular complications<sup>[34,60,61]</sup>. When a pseudo-aneurysm is identified subsequent management can be planned accordingly with the aid of both CT and angiographic guidance<sup>[62,63]</sup>. Due to the greater accessibility and



**Figure 4** Splenic artery pseudoaneurysm before and after embolization. A: Post contrast computed tomography scan showing the pseudoaneurysm rising from the splenic artery; B: Pre embolization selective splenic arterial DSA angiography image showing pseudoaneurysm; C: Post embolization DSA image showing the coils inside the splenic artery with its resultant embolization<sup>[92]</sup>.

improved vascular imaging triple phase contrast CT has become the imaging modality of choice in severe pancreatitis. Cross-sectional imaging may identify local pancreatic complications that may benefit from antibiotics, radiological intervention or very rarely surgery which in turn will aim to potentially speed the recovery of the patient. Less frequently pseudo-aneurysms will rupture causing acute haemodynamic compromise and emergency imaging is performed to determine the underlying cause. There is currently little evidence to specify the timing of follow up imaging and this should be guided by clinical assessment.

## MANAGEMENT OF ACUTE HAEMORRHAGE

Historically the management of pseudo-aneurysm was primarily surgical however over the past two decades the first line intervention is now interventional radiology. Since there have been marked improvements in the field of interventional radiology the spectrum of pathologies that can be treated successfully has expanded greatly. In the United Kingdom the provision of interventional radiology services varies significantly and is concentrated in tertiary centres. This is particularly evident out of hours where few hospitals have a 24-h on call interventional radiology service. A study of the provision of services for acute upper GI haemorrhage has shown that of hospitals in the United Kingdom 46% were able to offer out of hours interventional radiology services whether that be at the hospital in question or *via* a network<sup>[64]</sup>. Acute haemorrhage in district general hospitals is therefore unlikely to be treated with interventional radiology and certainly the mortality of acute haemorrhage from pseudo-aneurysm secondary to pancreatitis may reflect this. Some patients in the acute setting may be suitable for transfer depending on haemodynamic stability. In a semi-elective setting appropriate patients can be transferred to regional centres with greater expertise in managing pseudo-aneurysms where they would have

greater facilities to manage such complicated patients.

Trans-arterial embolisation of pseudo-aneurysms is commonly achieved by the placement of stainless steel or complex helical coils in the proximal and distal feeding vessel in order to isolate inflow and prevent back filling *via* collaterals (Figure 4). Haemostasis can be augmented by *N*-butylcyanoacrylate glue, ethiodised oil, gelfoam, thrombin, polyvinyl alcohol and other particles<sup>[21,37,38,41,43,65-69]</sup>. Increasingly in visceral aneurysm treatment covered stents have been used to exclude inflow to the aneurysm however they are less commonly used in the treatment of pseudo-aneurysms. Complications can arise both in failed and successful procedures. Access related complications might occur in the form of haematoma, dissection, pseudo-aneurysm and emboli. Complications may arise local to the pseudo-aneurysm including rupture, end vessel infarction, dissection and coil migration.

Mortality of pseudo-aneurysms secondary to pancreatitis has been shown to be between 34%-52%<sup>[26,28,30-35]</sup>, however the literature shows significant improvement in case series of those who have undergone radiological intervention. It is important to note that a proportion of patients will have been too unstable for intervention and therefore this mortality may not be reported as widely in the studies of radiological or surgical intervention. Kim *et al*<sup>[65]</sup> in 2015 demonstrated that of 37 patients undergoing angiographic embolisation it was unsuccessful in only three patients. Two of whom re-bleed from the primary pseudo-aneurysm and one developed a new pseudo-aneurysm. Of the 34 patients who underwent successful angiographic embolisation there were no episodes of re-bleeding with a mean follow up of 38 wk. Two patients died as a result of splenic abscesses and subsequent sepsis due to procedure related splenic infarction giving a mortality of 5%.

Udd *et al*<sup>[21]</sup> in 2007 identified 33 patients who were identified to have pancreatitis related pseudo-aneurysms at angiography however only 23 were suitable for embolization. Four of the 23 re-bleed and

only three of those patients received successful repeat radiological intervention. Radiological intervention was successful in 22/33 patients (67%). The remaining 10 patients went on to require surgical cessation of bleeding. One patient who underwent interventional radiology and one patient who underwent surgery died giving a mortality of 6%. Bergert *et al*<sup>[20]</sup> 2005 identified 35 patients with bleeding secondary to pancreatitis related pseudo-aneurysms. Twenty six patients were identified to have pseudo-aneurysms at angiography however angiographic embolisation was the primary treatment in only 16. Two patients re-bleed post-angiographic embolization. Nineteen patients required surgery to potentially stop bleeding. Three patients undergoing radiological intervention and four patients undergoing surgery died giving a mortality of 20%. The discrepancies in the number of patients undergoing radiological intervention and the mortality between Bergert *et al*<sup>[20]</sup> and Kim *et al*<sup>[65]</sup> may be reflected in the improvement of clinical practices from the related study dates of 1993-2004 and 2000-2012 respectively. Over the past two decades radiological provision, equipment and technical skills have improved significantly.

Tulsyan *et al*<sup>[68]</sup> in 2007 identified a mixed demographic of elective and non-elective patients (48 patients) with both visceral artery aneurysms and pseudo-aneurysms (28 patients) which showed marked success of radiological intervention. Forty seven of the 48 patients were embolised radiologically however three patients re-bleed. Four patients died in the perioperative period all of whom were among the 22 patients who required urgent or emergent intervention because of hemodynamic instability giving a mortality of 18% in the non-elective group. Zyromski *et al*<sup>[37]</sup> in 2007 identified 37 patients with visceral pseudo-aneurysms 24 as the result of pancreatitis and 13 as the result of pancreatic surgery. Within the pancreatitis group 23 of the 24 patients underwent embolization and in each case it was successful at arresting haemorrhage. Initially in one patient a pseudo-aneurysm could not be identified at angiography but was confirmed after a repeat procedure. Twelve patients underwent surgery in an attempt to resolve the on-going pancreatic inflammatory process but not for treatment of a pseudo-aneurysm. One patient died as a result of a stroke unrelated to pseudo-aneurysm treatment.

Smaller studies assessing the management of pseudo-aneurysms secondary to pancreatitis have shown similar outcomes. Hsu *et al*<sup>[41]</sup> in 2006 (9 patients), Beattie *et al*<sup>[66]</sup> in 2003 (19 patients), Gambiez *et al*<sup>[67]</sup> in 1997 (14 patients) and Sethi *et al*<sup>[38]</sup> in 2010 (16 patients) identified that of a total of 58 patients radiological intervention was successful in only 35 patients (60%). Twenty patients subsequently underwent surgery (34%) and seven patients died (12%).

Angiographic embolisation of pancreatitis related

pseudo-aneurysm has been shown to be very successful however there are occasions where the pseudo-aneurysm is inaccessible and therefore embolisation is not feasible. Increasingly in these circumstance image guided thrombin injection has been shown to have a role. The current literature identifies a number of case reports detailing successful embolization of a pseudo-aneurysm with percutaneous thrombin<sup>[62,70-84]</sup>. Of the 23 patients identified who underwent percutaneous thrombin injections four patients re-bleed and required further intervention. Two patients had repeated thrombin injections, one underwent angiographic coiling and one is unknown. Other than re-bleeding no significant complications were documented. Evidence is increasing to show that percutaneous therapy is a viable alternative to angiographic therapy. The delivery of thrombin has been successfully used angiographically and percutaneously however in certain scenarios neither can provide appropriate access to allow for successful embolisation. Endoscopic ultrasound has been shown in case reports to provide appropriate access for thrombin injection of pancreatitis related pseudo-aneurysms. Both aneurysms of the gastro-duodenal and splenic artery have been embolised endoscopically without the need for re-intervention<sup>[85-89]</sup>.

Surgery in patients with pancreatitis is known to be associated with significant morbidity and mortality which only increases in the presence of acute haemorrhage. With the improvement of minimally invasive techniques the role of surgery has diminished as angiographic, percutaneous and endoscopic techniques can appropriately exclude pseudo-aneurysms. However in spite of the technological advances in radiology and endoscopy, surgery will continue to play an important role in haemorrhage control where other techniques are not technically possible or available. There is currently no consensus on the surveillance of pseudo-aneurysms and the need for follow up. Patients with pancreatitis of a severity that leads to the formation of a pseudo-aneurysm will often undergo follow up imaging to ensure the resolution of local pancreatitis complications and in turn individually designed imaging follow up can be determined in coordination with the clinician and radiologist to ensure that the future re-bleed risks are mediated.

## CONCLUSION

Pancreatitis has a number of aetiologies and many more potential complications which leads to it being a common pathology seen in every surgical department. Arterial complications of pancreatitis although rare are associated with a high morbidity and mortality. It is important to maintain a high level of suspicion for pseudo-aneurysm as they can be easily missed despite cross-sectional imaging. Early recognition of the presence of a pseudo-aneurysm can facilitate expedited care of this complex pathology that may require



angiographic, percutaneous, endoscopic or surgical intervention to prevent catastrophic haemorrhage.

## REFERENCES

- 1 McLean R, Jones M, Kanakala V, Dixon S, McCallum I. PWE-204 Acute pancreatitis: incidence, management and outcome trends over 15 years. *Gut* 2015; **64**: A301-A302 [DOI: 10.1136/gutjnl-2015-309861.651]
- 2 Roberts SE, Akbari A, Thorne K, Atkinson M, Evans PA. The incidence of acute pancreatitis: impact of social deprivation, alcohol consumption, seasonal and demographic factors. *Aliment Pharmacol Ther* 2013; **38**: 539-548 [PMID: 23859492 DOI: 10.1111/apt.12408]
- 3 Hamada S, Masamune A, Kikuta K, Hirota M, Tsuji I, Shimosegawa T; Research Committee of Intractable Diseases of the Pancreas. Nationwide epidemiological survey of acute pancreatitis in Japan. *Pancreas* 2014; **43**: 1244-1248 [PMID: 25084001 DOI: 10.1097/MPA.0000000000000200]
- 4 Shen HN, Lu CL, Li CY. Epidemiology of first-attack acute pancreatitis in Taiwan from 2000 through 2009: a nationwide population-based study. *Pancreas* 2012; **41**: 696-702 [PMID: 22699142 DOI: 10.1097/MPA.0b013e31823db941]
- 5 Yadav D, Whitcomb DC. The role of alcohol and smoking in pancreatitis. *Nat Rev Gastroenterol Hepatol* 2010; **7**: 131-145 [PMID: 20125091 DOI: 10.1038/nrgastro.2010.6]
- 6 Vidarsdottir H, Möller PH, Vidarsdottir H, Thorarinsdottir H, Björnsson ES. Acute pancreatitis: a prospective study on incidence, etiology, and outcome. *Eur J Gastroenterol Hepatol* 2013; **25**: 1068-1075 [PMID: 23839162 DOI: 10.1097/MEG.0b013e3283640fc8]
- 7 Peery AF, Dellon ES, Lund J, Crockett SD, McGowan CE, Bulsiewicz WJ, Gangarosa LM, Thiny MT, Stizenberg K, Morgan DR, Ringel Y, Kim HP, Dibonaventura MD, Carroll CF, Allen JK, Cook SF, Sandler RS, Kappelman MD, Shaheen NJ. Burden of gastrointestinal disease in the United States: 2012 update. *Gastroenterology* 2012; **143**: 1179-1187.e1-e3 [PMID: 22885331 DOI: 10.1053/j.gastro.2012.08.002]
- 8 Yang AL, Vadavakar S, Singh G, Omary MB. Epidemiology of alcohol-related liver and pancreatic disease in the United States. *Arch Intern Med* 2008; **168**: 649-656 [PMID: 18362258 DOI: 10.1001/archinte.168.6.649]
- 9 Takeyama Y. Long-term prognosis of acute pancreatitis in Japan. *Clin Gastroenterol Hepatol* 2009; **7**: S15-S17 [PMID: 19896091 DOI: 10.1016/j.cgh.2009.08.022]
- 10 Lankisch PG, Breuer N, Bruns A, Weber-Dany B, Lowenfels AB, Maisonneuve P. Natural history of acute pancreatitis: a long-term population-based study. *Am J Gastroenterol* 2009; **104**: 2797-2805; quiz 2806 [PMID: 19603011 DOI: 10.1038/ajg.2009.405]
- 11 Nøjgaard C, Becker U, Matzen P, Andersen JR, Holst C, Bendtsen F. Progression from acute to chronic pancreatitis: prognostic factors, mortality, and natural course. *Pancreas* 2011; **40**: 1195-1200 [PMID: 21926938 DOI: 10.1097/MPA.0b013e318221f569]
- 12 Yadav D, O'Connell M, Papachristou GI. Natural history following the first attack of acute pancreatitis. *Am J Gastroenterol* 2012; **107**: 1096-1103 [PMID: 22613906 DOI: 10.1038/ajg.2012.126]
- 13 Mayerle J, Hoffmeister A, Werner J, Witt H, Lerch MM, Mössner J. Chronic pancreatitis--definition, etiology, investigation and treatment. *Dtsch Arztebl Int* 2013; **110**: 387-393 [PMID: 23826027]
- 14 Hirota M, Shimosegawa T, Masamune A, Kikuta K, Kume K, Hamada S, Kihara Y, Satoh A, Kimura K, Tsuji I, Kuriyama S; Research Committee of Intractable Pancreatic Diseases. The sixth nationwide epidemiological survey of chronic pancreatitis in Japan. *Pancreatol* 2012; **12**: 79-84 [PMID: 22487515 DOI: 10.1016/j.pan.2012.02.005]
- 15 Gullo L, Migliori M, Oláh A, Farkas G, Levy P, Arvanitakis C, Lankisch P, Beger H. Acute pancreatitis in five European countries: etiology and mortality. *Pancreas* 2002; **24**: 223-227 [PMID: 11893928 DOI: 10.1097/00006676-200204000-00003]
- 16 Petrov MS, Shanbhag S, Chakraborty M, Phillips AR, Windsor JA. Organ failure and infection of pancreatic necrosis as determinants of mortality in patients with acute pancreatitis. *Gastroenterology* 2010; **139**: 813-820 [PMID: 20540942 DOI: 10.1053/j.gastro.2010.06.010]
- 17 Banks PA, Bollen TL, Dervenis C, Gooszen HG, Johnson CD, Sarr MG, Tsotos GG, Vege SS; Acute Pancreatitis Classification Working Group. Classification of acute pancreatitis--2012: revision of the Atlanta classification and definitions by international consensus. *Gut* 2013; **62**: 102-111 [PMID: 23100216 DOI: 10.1136/gutjnl-2012-302779]
- 18 Bollen TL, Singh VK, Maurer R, Repas K, van Es HW, Banks PA, Mortele KJ. A comparative evaluation of radiologic and clinical scoring systems in the early prediction of severity in acute pancreatitis. *Am J Gastroenterol* 2012; **107**: 612-619 [PMID: 22186977 DOI: 10.1038/ajg.2011.438]
- 19 Thoeni RF. The revised Atlanta classification of acute pancreatitis: its importance for the radiologist and its effect on treatment. *Radiology* 2012; **262**: 751-764 [PMID: 22357880 DOI: 10.1148/radiol.11110947]
- 20 Bergert H, Hinterseher I, Kersting S, Leonhardt J, Bloomenthal A, Saeger HD. Management and outcome of hemorrhage due to arterial pseudoaneurysms in pancreatitis. *Surgery* 2005; **137**: 323-328 [PMID: 15746787 DOI: 10.1016/j.surg.2004.10.009]
- 21 Udd M, Leppäniemi AK, Bidel S, Keto P, Roth WD, Haapiainen RK. Treatment of bleeding pseudoaneurysms in patients with chronic pancreatitis. *World J Surg* 2007; **31**: 504-510 [PMID: 17322972 DOI: 10.1007/s00268-006-0209-z]
- 22 Balthazar EJ. Complications of acute pancreatitis: clinical and CT evaluation. *Radiol Clin North Am* 2002; **40**: 1211-1227 [PMID: 12479707 DOI: 10.1016/S0033-8389(02)00043-X]
- 23 Agarwal AK, Raj Kumar K, Agarwal S, Singh S. Significance of splenic vein thrombosis in chronic pancreatitis. *Am J Surg* 2008; **196**: 149-154 [PMID: 18585674 DOI: 10.1016/j.amjsurg.2007.07.039]
- 24 Eckhauser FE, Stanley JC, Zelenock GB, Borlaza GS, Freier DT, Lindenauer SM. Gastroduodenal and pancreaticoduodenal artery aneurysms: a complication of pancreatitis causing spontaneous gastrointestinal hemorrhage. *Surgery* 1980; **88**: 335-344 [PMID: 6968101]
- 25 Kiviluoto T, Kivisaari L, Kivilaakso E, Lempinen M. Pseudocysts in chronic pancreatitis. Surgical results in 102 consecutive patients. *Arch Surg* 1989; **124**: 240-243 [PMID: 2916944 DOI: 10.1001/archsurg.1989.01410020114019]
- 26 White AF, Baum S, Buranasiri S. Aneurysms secondary to pancreatitis. *AJR Am J Roentgenol* 1976; **127**: 393-396 [PMID: 183522 DOI: 10.2214/ajr.127.3.393]
- 27 de Castro SM, Kuhlmann KF, Busch OR, van Delden OM, Laméris JS, van Gulik TM, Obertop H, Gouma DJ. Delayed massive hemorrhage after pancreatic and biliary surgery: embolization or surgery? *Ann Surg* 2005; **241**: 85-91 [PMID: 15621995]
- 28 Flati G, Andrén-Sandberg A, La Pinta M, Porowska B, Carboni M. Potentially fatal bleeding in acute pancreatitis: pathophysiology, prevention, and treatment. *Pancreas* 2003; **26**: 8-14 [PMID: 12499910 DOI: 10.1097/00006676-200301000-00002]
- 29 Dörffel T, Wruck T, Rückert RI, Romaniuk P, Dörffel Q, Wermke W. Vascular complications in acute pancreatitis assessed by color duplex ultrasonography. *Pancreas* 2000; **21**: 126-133 [PMID: 10975705 DOI: 10.1097/00006676-200008000-00004]
- 30 Balthazar EJ, Fisher LA. Hemorrhagic complications of pancreatitis: radiologic evaluation with emphasis on CT imaging. *Pancreatol* 2001; **1**: 306-313 [PMID: 12120209 DOI: 10.1159/000055829]
- 31 Mortelé KJ, Mergo PJ, Taylor HM, Wiesner W, Cantisani V, Ernst MD, Kalantari BN, Ros PR. Peripancreatic vascular abnormalities complicating acute pancreatitis: contrast-enhanced helical CT findings. *Eur J Radiol* 2004; **52**: 67-72 [PMID: 15380848 DOI: 10.1016/j.ejrad.2003.10.006]
- 32 Bergert H, Dobrowolski F, Caffier S, Bloomenthal A, Hinterseher

- I, Saeger HD. Prevalence and treatment of bleeding complications in chronic pancreatitis. *Langenbecks Arch Surg* 2004; **389**: 504-510 [PMID: 15173947 DOI: 10.1007/s00423-004-0478-7]
- 33 **Xiao B**, Zhang XM, Tang W, Zeng NL, Zhai ZH. Magnetic resonance imaging for local complications of acute pancreatitis: a pictorial review. *World J Gastroenterol* 2010; **16**: 2735-2742 [PMID: 20533593 DOI: 10.3748/wjg.v16.i22.2735]
- 34 **Kirby JM**, Vora P, Midia M, Rawlinson J. Vascular complications of pancreatitis: imaging and intervention. *Cardiovasc Intervent Radiol* 2008; **31**: 957-970 [PMID: 17680304 DOI: 10.1007/s00270-007-9138-y]
- 35 **Sharma PK**, Madan K, Garg PK. Hemorrhage in acute pancreatitis: should gastrointestinal bleeding be considered an organ failure? *Pancreas* 2008; **36**: 141-145 [PMID: 18376304 DOI: 10.1097/MPA.0b013e318158466e]
- 36 **Bretagne JF**, Heresbach D, Darnault P, Raoul JL, Gosselin M, Carsin M, Gastard J. Pseudoaneurysms and bleeding pseudocysts in chronic pancreatitis: radiological findings and contribution to diagnosis in 8 cases. *Gastrointest Radiol* 1990; **15**: 9-16 [PMID: 2404825 DOI: 10.1007/BF01888725]
- 37 **Zyromski NJ**, Vieira C, Stecker M, Nakeeb A, Pitt HA, Lillemoe KD, Howard TJ. Improved outcomes in postoperative and pancreatitis-related visceral pseudoaneurysms. *J Gastrointest Surg* 2007; **11**: 50-55 [PMID: 17390186 DOI: 10.1007/s11605-006-0038-2]
- 38 **Sethi H**, Peddu P, Prachalias A, Kane P, Karani J, Rela M, Heaton N. Selective embolization for bleeding visceral artery pseudoaneurysms in patients with pancreatitis. *Hepatobiliary Pancreat Dis Int* 2010; **9**: 634-638 [PMID: 21134834]
- 39 **Tessier DJ**, Stone WM, Fowl RJ, Abbas MA, Andrews JC, Bower TC, Glociczki P. Clinical features and management of splenic artery pseudoaneurysm: case series and cumulative review of literature. *J Vasc Surg* 2003; **38**: 969-974 [PMID: 14603202]
- 40 **de Perrot M**, Berney T, Bühler L, Delgadillo X, Menth G, Morel P. Management of bleeding pseudoaneurysms in patients with pancreatitis. *Br J Surg* 1999; **86**: 29-32 [PMID: 10027355 DOI: 10.1046/j.1365-2168.1999.00983.x]
- 41 **Hsu JT**, Yeh CN, Hung CF, Chen HM, Hwang TL, Jan YY, Chen MF. Management and outcome of bleeding pseudoaneurysm associated with chronic pancreatitis. *BMC Gastroenterol* 2006; **6**: 3 [PMID: 16405731 DOI: 10.1186/1471-230X-6-3]
- 42 **Vander Mijnsbrugge W**, Laleman W, Van Steenberghe W, Heye S, Verslype C, Maleux G. Long-term clinical and radiological outcome of endovascular embolization of pancreatitis-related pseudoaneurysms. *Acta Radiol* 2017; **58**: 316-322 [PMID: 27178033 DOI: 10.1177/0284185116648502]
- 43 **Mendelson RM**, Anderson J, Marshall M, Ramsay D. Vascular complications of pancreatitis. *ANZ J Surg* 2005; **75**: 1073-1079 [PMID: 16398814 DOI: 10.1111/j.1445-2197.2005.03607.x]
- 44 **Boudghène F**, L'Herminé C, Bigot JM. Arterial complications of pancreatitis: diagnostic and therapeutic aspects in 104 cases. *J Vasc Interv Radiol* 1993; **4**: 551-558 [PMID: 8353353 DOI: 10.1016/S1051-0443(93)71920-X]
- 45 **Walter JF**, Chuang VP, Bookstein JJ, Reuter SR, Cho KJ, Pulmano CM. Angiography of massive hemorrhage secondary to pancreatic diseases. *Radiology* 1977; **124**: 337-342 [PMID: 301642 DOI: 10.1148/124.2.337]
- 46 **Nosher JL**, Chung J, Brevetti LS, Graham AM, Siegel RL. Visceral and renal artery aneurysms: a pictorial essay on endovascular therapy. *Radiographics* 2006; **26**: 1687-1704; quiz 1687 [PMID: 17102044 DOI: 10.1148/rg.266055732]
- 47 **Kim JH**, Kim JS, Kim CD, Lee HS, Cho YJ, Lee JS, Choi DW, Han WS, Kim YH, Yeon JE, Park JJ, Byun KS, Bak YT. [Clinical features of pseudoaneurysms complicating pancreatitis: single center experience and review of Korean literature]. *Korean J Gastroenterol* 2007; **50**: 108-115 [PMID: 17928754]
- 48 **Mallik IH**, Winslet MC. Vascular complications of pancreatitis. *JOP* 2004; **5**: 328-337 [PMID: 15365199]
- 49 **Mauro MA**, Jaques P. Transcatheter management of pseudoaneurysms complicating pancreatitis. *J Vasc Interv Radiol* 1991; **2**: 527-532 [PMID: 1797219 DOI: 10.1016/S1051-0443(91)72236-7]
- 50 **Tsiotos GG**, Munoz Juarez MM, Sarr MG. Intraabdominal hemorrhage complicating surgical management of necrotizing pancreatitis. *Pancreas* 1996; **12**: 126-130 [PMID: 8720657 DOI: 10.1097/00006676-199603000-00003]
- 51 **Giles RA**, Pevec WC. Aortic pseudoaneurysm secondary to pancreatitis. *J Vasc Surg* 2000; **31**: 1056-1059 [PMID: 10805901 DOI: 10.1067/mva.2000.102850]
- 52 **Balachandra S**, Siriwardena AK. Systematic appraisal of the management of the major vascular complications of pancreatitis. *Am J Surg* 2005; **190**: 489-495 [PMID: 16105542 DOI: 10.1016/j.amjsurg.2005.03.009]
- 53 **Nitin J**, Reddy DN, Singh JR. A Rare Location of Pseudoaneurysm in Chronic Pancreatitis: Left Sub-Capsular Renal Artery. *J Gastrointest Dig Syst* 2016; **6**: 474 [DOI: 10.4172/2161-069X.1000474]
- 54 **Arora A**, Tyagi P, Gupta A, Arora V, Sharma P, Kumar M, Goyal M, Kumar A. Pseudoaneurysm of the inferior phrenic artery presenting as an upper gastrointestinal bleed by directly rupturing into the stomach in a patient with chronic pancreatitis. *Ann Vasc Surg* 2012; **26**: 860.e9-860.11 [PMID: 22794342 DOI: 10.1016/j.avsg.2011.12.017]
- 55 **Marshall GT**, Howell DA, Hansen BL, Amberson SM, Abourjaily GS, Bredenber CE. Multidisciplinary approach to pseudoaneurysms complicating pancreatic pseudocysts. Impact of pretreatment diagnosis. *Arch Surg* 1996; **131**: 278-283 [PMID: 8611093 DOI: 10.1001/archsurg.1996.01430150056012]
- 56 **Fukatsu K**, Ueda K, Maeda H, Yamashita Y, Itonaga M, Mori Y, Moribata K, Shingaki N, Deguchi H, Enomoto S, Inoue I, Maekita T, Iguchi M, Tamai H, Kato J, Ichinose M. A case of chronic pancreatitis in which endoscopic ultrasonography was effective in the diagnosis of a pseudoaneurysm. *World J Gastrointest Endosc* 2012; **4**: 335-338 [PMID: 22816016 DOI: 10.4253/wjge.v4.i7.335]
- 57 **Cai DM**, Parajuly SS, Ling WW, Li YZ, Luo Y. Diagnostic value of contrast enhanced ultrasound for splenic artery complications following acute pancreatitis. *World J Gastroenterol* 2014; **20**: 1088-1094 [PMID: 24574783 DOI: 10.3748/wjg.v20.i4.1088]
- 58 **Balthazar EJ**, Freeny PC, vanSonnenberg E. Imaging and intervention in acute pancreatitis. *Radiology* 1994; **193**: 297-306 [PMID: 7972730 DOI: 10.1148/radiology.193.2.7972730]
- 59 **Xiao B**, Zhang XM. Magnetic resonance imaging for acute pancreatitis. *World J Radiol* 2010; **2**: 298-308 [PMID: 21160684 DOI: 10.4329/wjr.v2.i8.298]
- 60 **Koo BC**, Chinogureyi A, Shaw AS. Imaging acute pancreatitis. *Br J Radiol* 2010; **83**: 104-112 [PMID: 20139261 DOI: 10.1259/bjr/13359269]
- 61 **Hyare H**, Desigan S, Nicholl H, Guiney MJ, Brookes JA, Lees WR. Multi-section CT angiography compared with digital subtraction angiography in diagnosing major arterial hemorrhage in inflammatory pancreatic disease. *Eur J Radiol* 2006; **59**: 295-300 [PMID: 16542810 DOI: 10.1016/j.ejrad.2006.02.006]
- 62 **Nicholson AA**, Patel J, McPherson S, Shaw DR, Kessel D. Endovascular treatment of visceral aneurysms associated with pancreatitis and a suggested classification with therapeutic implications. *J Vasc Interv Radiol* 2006; **17**: 1279-1285 [PMID: 16923974 DOI: 10.1097/01.RVI.0000231948.08617.04]
- 63 **Yoon W**, Jeong YY, Shin SS, Lim HS, Song SG, Jang NG, Kim JK, Kang HK. Acute massive gastrointestinal bleeding: detection and localization with arterial phase multi-detector row helical CT. *Radiology* 2006; **239**: 160-167 [PMID: 16484350 DOI: 10.1148/radiol.2383050175]
- 64 **Nedjat-Shokouhi B**, Glynn M, Denton ERE, Greenfield SM. Provision of out-of-hours services for acute upper gastrointestinal bleeding in England: results of the 2014-2015 BSG/NHS England national survey. *Fron Gastroenterol* 2016; flgastro-2016-100706 [DOI: 10.1136/flgastro-2016-100706]
- 65 **Kim J**, Shin JH, Yoon HK, Ko GY, Gwon DI, Kim EY, Sung KB. Endovascular intervention for management of pancreatitis-related bleeding: a retrospective analysis of thirty-seven patients at a

- single institution. *Diagn Interv Radiol* 2015; **21**: 140-147 [PMID: 25616269 DOI: 10.5152/dir.2014.14085]
- 66 **Beattie GC**, Hardman JG, Redhead D, Siriwardena AK. Evidence for a central role for selective mesenteric angiography in the management of the major vascular complications of pancreatitis. *Am J Surg* 2003; **185**: 96-102 [PMID: 12559436 DOI: 10.1016/S0002-9610(02)01199-6]
- 67 **Gambiez LP**, Ernst OJ, Merlier OA, Porte HL, Chambon JP, Quandalle PA. Arterial embolization for bleeding pseudocysts complicating chronic pancreatitis. *Arch Surg* 1997; **132**: 1016-1021 [PMID: 9301616 DOI: 10.1001/archsurg.1997.01430330082014]
- 68 **Tulsyan N**, Kashyap VS, Greenberg RK, Sarac TP, Clair DG, Pierce G, Ouriel K. The endovascular management of visceral artery aneurysms and pseudoaneurysms. *J Vasc Surg* 2007; **45**: 276-283; discussion 283 [PMID: 17264002 DOI: 10.1016/j.jvs.2006.10.049]
- 69 **Bhasin DK**, Rana SS, Sharma V, Rao C, Gupta V, Gupta R, Kang M, Singh K. Non-surgical management of pancreatic pseudocysts associated with arterial pseudoaneurysm. *Pancreatol* 2013; **13**: 250-253 [PMID: 23719596 DOI: 10.1016/j.pan.2013.02.011]
- 70 **Chauhan U**, Puri SK, Jain N, Garg L, Kapoor A, Gupta N, Goel V. Percutaneous thrombin injection under sonographic guidance for exclusion of non-catheterizable post-pancreatitis pseudoaneurysm of the superior mesenteric artery: a minimally invasive and expeditious treatment option. *J Med Ultrason* (2001) 2016; **43**: 295-299 [PMID: 26590924 DOI: 10.1007/s10396-015-0687-4]
- 71 **Shrivastava A**, Rampal JS, Reddy DN, Rao GV. Direct Needle Puncture and Embolization of Splenic Artery Pseudoaneurysm in Case of Chronic Atrophic Calcific Pancreatitis. *Pol J Radiol* 2016; **81**: 462-464 [PMID: 27757174 DOI: 10.12659/PJR.898000]
- 72 **Pacheco Jiménez M**, Moreno Sánchez T, Moreno Rodríguez F, Guillén Rico M. [Pancreatic tail pseudoaneurysm: percutaneous treatment by thrombin injection]. *Radiologia* 2014; **56**: 167-170 [PMID: 21944714 DOI: 10.1016/j.rx.2011.04.009]
- 73 **Barbiero G**, Battistel M, Susac A, Miotto D. Percutaneous thrombin embolization of a pancreaticoduodenal artery pseudoaneurysm after failing of the endovascular treatment. *World J Radiol* 2014; **6**: 629-635 [PMID: 25170402 DOI: 10.4329/wjr.v6.i8.629]
- 74 **De Rosa A**, Gomez D, Pollock JG, Bungay P, De Nunzio M, Hall RI, Thurley P. The radiological management of pseudoaneurysms complicating pancreatitis. *JOP* 2012; **13**: 660-666 [PMID: 23183395]
- 75 **Fankhauser GT**, Stone WM, Naidu SG, Oderich GS, Ricotta JJ, Bjarnason H, Money SR; Mayo Vascular Research Center Consortium. The minimally invasive management of visceral artery aneurysms and pseudoaneurysms. *J Vasc Surg* 2011; **53**: 966-970 [PMID: 21216559 DOI: 10.1016/j.jvs.2010.10.071]
- 76 **McErlean A**, Looby S, Lee MJ. Percutaneous ultrasound-guided thrombin injection as first-line treatment of pancreatic pseudoaneurysm. *Cardiovasc Intervent Radiol* 2007; **30**: 526-528 [PMID: 17131209 DOI: 10.1007/s00270-006-0174-9]
- 77 **Laganà D**, Carrafiello G, Mangini M, Dionigi G, Caronno R, Castelli P, Fugazzola C. Multimodal approach to endovascular treatment of visceral artery aneurysms and pseudoaneurysms. *Eur J Radiol* 2006; **59**: 104-111 [PMID: 16597492 DOI: 10.1016/j.ejrad.2006.02.004]
- 78 **Williams M**, Alderson D, Virjee J, Callaway M. CT-guided percutaneous thrombin injection for treatment of an inferior pancreaticoduodenal artery pseudoaneurysm. *Cardiovasc Intervent Radiol* 2006; **29**: 669-671 [PMID: 16604412 DOI: 10.1007/s00270-004-0274-3]
- 79 **Ghassemi A**, Javit D, Dillon EH. Thrombin injection of a pancreaticoduodenal artery pseudoaneurysm after failed attempts at transcatheter embolization. *J Vasc Surg* 2006; **43**: 618-622 [PMID: 16520183 DOI: 10.1016/j.jvs.2005.11.051]
- 80 **Szopiński P**, Ciostek P, Pleban E, Iwanowski J, Serafin-Król M, Marianowska A, Noszczyk W. Percutaneous thrombin injection to complete SMA pseudoaneurysm exclusion after failing of endograft placement. *Cardiovasc Intervent Radiol* 2005; **28**: 509-514 [PMID: 16010511 DOI: 10.1007/s00270-004-0160-z]
- 81 **Geoghegan T**, Tuite D, McAuley G, O'Keeffe S, Torreggiani WC. Percutaneous thrombin injection for the treatment of a post-pancreatitis pseudoaneurysm of the gastroduodenal artery. *Eur Radiol* 2004; **14**: 2144-2145 [PMID: 15278409 DOI: 10.1007/s00330-004-2399-9]
- 82 **Sparrow P**, Asquith J, Chalmers N. Ultrasonic-guided percutaneous injection of pancreatic pseudoaneurysm with thrombin. *Cardiovasc Intervent Radiol* 2003; **26**: 312-315 [PMID: 14562987 DOI: 10.1007/s00270-003-0008-y]
- 83 **Manazer JR**, Monzon JR, Dietz PA, Moglia R, Gold M. Treatment of pancreatic pseudoaneurysm with percutaneous transabdominal thrombin injection. *J Vasc Surg* 2003; **38**: 600-602 [PMID: 12947284 DOI: 10.1016/S0741-5214(03)00454-3]
- 84 **Armstrong EM**, Edwards A, Kingsnorth AN, Freeman S, Roobottom CA. Ultrasound guided thrombin injection to treat a pseudoaneurysm secondary to chronic pancreatitis. *Eur J Vasc Endovasc Surg* 2003; **26**: 448-449 [PMID: 14512011 DOI: 10.1016/S1078-5884(03)00075-3]
- 85 **Rai P**, Mohan S, Sharma M. Endoscopic ultrasound-guided thrombin injection in a large splenic artery aneurysm: first report in a patient with tropical chronic pancreatitis. *Endoscopy* 2014; **46** Suppl 1 UCTN: E355-E356 [PMID: 25121631 DOI: 10.1055/s-0034-1377357]
- 86 **Gamanagatti S**, Thingujam U, Garg P, Nongthombam S, Dash NR. Endoscopic ultrasound guided thrombin injection of angiographically occult pancreatitis associated visceral artery pseudoaneurysms: Case series. *World J Gastrointest Endosc* 2015; **7**: 1107-1113 [PMID: 26421108 DOI: 10.4253/wjge.v7.i13.1107]
- 87 **Roach H**, Roberts SA, Salter R, Williams IM, Wood AM. Endoscopic ultrasound-guided thrombin injection for the treatment of pancreatic pseudoaneurysm. *Endoscopy* 2005; **37**: 876-878 [PMID: 16116543 DOI: 10.1055/s-2005-870201]
- 88 **Robinson M**, Richards D, Carr N. Treatment of a splenic artery pseudoaneurysm by endoscopic ultrasound-guided thrombin injection. *Cardiovasc Intervent Radiol* 2007; **30**: 515-517 [PMID: 17171306 DOI: 10.1007/s00270-006-0081-0]
- 89 **Chaves DM**, Costa FF, Matuguma S, Lera Dos Santos ME, de Moura EG, Maluf Filho F, Sakai P. Splenic artery pseudoaneurysm treated with thrombin injection guided by endoscopic ultrasound. *Endoscopy* 2012; **44** Suppl 2 UCTN: E99-100 [PMID: 22473579 DOI: 10.1055/s-0030-1256740]
- 90 **Massani M**, Brida A, Caratozzolo E, Bonariol L, Antoniutti M, Bassi N. Hemosuccus pancreaticus due to primary splenic artery aneurysm: a diagnostic and therapeutic challenge. *JOP* 2009; **10**: 48-52 [PMID: 19129615]
- 91 **Horton KM**, Smith C, Fishman EK. MDCT and 3D CT angiography of splanchnic artery aneurysms. *AJR Am J Roentgenol* 2007; **189**: 641-647 [PMID: 17715112 DOI: 10.2214/AJR.07.2210]
- 92 **Taori K**, Rathod J, Disawal A, Mundhada R, Rewatkar A, Bakare V, Wavare P, Puria RP. Endovascular Embolization of Pseudoaneurysms Complicating Pancreatitis Using Microcoils: Case Series. *Open J Radiol* 2013; **3**: 33-40 [DOI: 10.4236/ojrad.2013.31005]

**P- Reviewer:** Du YQ, Fujino Y, Gonzalez-Ojeda A

**S- Editor:** Gong ZM **L- Editor:** A **E- Editor:** Zhang FF





## Treating children with inflammatory bowel disease: Current and new perspectives

Graziella Guariso, Marco Gasparetto

Graziella Guariso, University of Padova, 35100 Padova, Italy

Marco Gasparetto, Department of Paediatric Gastroenterology, Cambridge University Hospitals CUH-FT, Cambridge CB2 0QQ, United Kingdom

**Author contributions:** Guariso G and Gasparetto M contributed equally to this work in respect to designing the review, contributing to the manuscript with intellectual content, writing the paper and final approval of the version to be published.

**Conflict-of-interest statement:** No potential conflicts of interest. No financial support.

**Open-Access:** This article is an open-access article which was selected by an in-house editor and fully peer-reviewed by external reviewers. It is distributed in accordance with the Creative Commons Attribution Non Commercial (CC BY-NC 4.0) license, which permits others to distribute, remix, adapt, build upon this work non-commercially, and license their derivative works on different terms, provided the original work is properly cited and the use is non-commercial. See: <http://creativecommons.org/licenses/by-nc/4.0/>

**Manuscript source:** Invited manuscript

**Correspondence to:** Graziella Guariso, Professor, Paediatric Gastroenterologist, University Lecturer, University of Padova, Via 8 Febbraio 1848, 2, 35100 Padova, Italy. [graziella.guariso@gmail.com](mailto:graziella.guariso@gmail.com)  
Telephone: +39-49-8625753  
Fax: +39-49-8625753

Received: February 26, 2017

Peer-review started: February 28, 2017

First decision: April 7, 2017

Revised: June 2, 2017

Accepted: July 22, 2017

Article in press: July 24, 2017

Published online: August 14, 2017

### Abstract

Inflammatory bowel disease (IBD) is a chronic

inflammatory condition of the gut characterised by alternating periods of remission and relapse. Whilst the mechanism underlying this disease is yet to be fully understood, old and newer generation treatments can only target selected pathways of this complex inflammatory process. This narrative review aims to provide an update on the most recent advances in treatment of paediatric IBD. A MEDLINE search was conducted using "paediatric inflammatory bowel disease", "paediatric Crohn's disease", "paediatric ulcerative colitis", "treatment", "therapy", "immunosuppressant", "biologic", "monitoring" and "biomarkers" as key words. Clinical trials, systematic reviews, and meta-analyses published between 2014 and 2016 were selected. Studies referring to earlier periods were also considered in case the data was relevant to our scope. Major advances have been achieved in monitoring the individual metabolism, toxicity and response to relevant medications in IBD including thiopurines and biologics. New biologics acting on novel mechanisms such as selective interference with lymphocyte trafficking are emerging treatment options. Current research is investing in the development of reliable prognostic biomarkers, aiming to move towards personalised treatments targeted to individual patients.

**Key words:** Paediatric inflammatory bowel disease; Crohn's disease; Ulcerative colitis; Treatment; Therapy; Immunosuppressant; Biologic; Monitoring; Biomarker

© **The Author(s) 2017.** Published by Baishideng Publishing Group Inc. All rights reserved.

**Core tip:** This narrative review summarises the current practice in treating children with inflammatory bowel disease (IBD) and explores the new advances and future aims. A particular focus of the review are the peculiarities of the paediatric age in respect to the standard practice in adult patients with IBD. Whilst the cause of this condition remains only partly understood, a significant proportion of children does not respond to the treatment options currently available. Developing



new treatments is therefore a key target. Major advances have already been achieved in therapeutic drug monitoring.

Guariso G, Gasparetto M. Treating children with inflammatory bowel disease: Current and new perspectives. *World J Gastroenterol* 2017; 23(30): 5469-5485 Available from: URL: <http://www.wjgnet.com/1007-9327/full/v23/i30/5469.htm> DOI: <http://dx.doi.org/10.3748/wjg.v23.i30.5469>

## INTRODUCTION

Inflammatory bowel disease (IBD) is a chronic inflammatory condition of the gut characterized by alternating periods of remission and relapse<sup>[1]</sup>.

It comprises Crohn's disease (CD), ulcerative colitis (UC) and IBD-Unclassified (IBD-U), and its incidence has increased steadily worldwide, particularly in Western countries<sup>[2-4]</sup>. The disease affects both children and adults, with current estimated prevalence of 2.6 million people in Europe and 1.2 million in North America<sup>[5]</sup>. Approximately 25% of IBD patients are diagnosed before the age of 18<sup>[6]</sup>. Given that a cure for IBD hasn't been developed so far, treatments currently available are mainly aimed to induce and maintain remission. Therapeutic options include corticosteroids which have shown up to 80% efficacy in inducing remission in patients with CD. Other immunomodulators used for the treatment of IBD include thiopurines [*i.e.*, azathioprine (AZA) and 6-mercaptopurine], methotrexate (MTX) and biological treatments such as anti-tumour necrosis factor (anti-TNF $\alpha$ ) therapies like infliximab (IFX) and adalimumab (ADA)<sup>[5]</sup>.

CD is characterized by focal, patchy, transmural and granulomatous inflammation and it can affect any part of the intestinal tract as well as extra-intestinal tissue<sup>[4]</sup>. Peak age of diagnosis of CD is between 12 and 25<sup>[7]</sup>.

Due to its typical onset in the young age and to the chronicity of the disease, medical treatment remains the cornerstone in CD, with most patients requiring lifelong therapy<sup>[4]</sup>. Whilst for CD surgery is generally an option restricted to patients resistant to maximised medical treatments or with specific complications, approximately 75% of patients with CD will eventually undergo surgical resection<sup>[4,8]</sup>. Nevertheless, according to the current epidemiology data available, up to 73% of these patients will experience endoscopic recurrence of disease at one year post surgery and 22% to 55% will have a clinical relapse at five years<sup>[8]</sup>.

UC mainly involves the large bowel mucosa, with inflammation extending proximally from the rectum in a continuous fashion. In approximately 80% of children, the disease extent is proximal to the splenic flexure, whereas in adults it's more frequently left sided. Prolonged severe inflammation of the colonic

mucosa is a known risk factor for the development of colorectal carcinoma<sup>[9]</sup>.

Currently, proven medical treatment of paediatric UC is limited to a few options, including amino-salicylates, corticosteroids and thiopurines. More recently, anti-TNF agents have been established for the management of patients with UC who are refractory to conventional medical treatment<sup>[10]</sup>. Choice of therapy is mainly based on disease extension and severity of inflammation. Up to 25% of the total patients with UC currently require a colectomy because of ongoing, severe inflammation, unresponsive to medical therapy, or when the disease is steroid-dependent<sup>[11]</sup>.

When a child is diagnosed with IBD, achieving early remission has a positive impact on normal child growth and development, long-term remission and quality of life, thus reducing the psychological burden<sup>[2]</sup>. Children tend to present with a more aggressive course of IBD, therefore immunomodulators and biological treatments are used extensively<sup>[2]</sup>.

Achieving satisfactory nutritional status and reaching growth target should be one of the focuses in paediatric IBD. In fact, nutritional concerns are still common in children with CD (up to 65%-75% of cases) who are often underweight at presentation<sup>[3,6,12]</sup>. Even in the longer term, despite current treatment strategies for CD including biologics, short stature and slow growth are still encountered in paediatric CD.

Whilst an early diagnosis is pivotal to minimize growth deficiency, the signs of CD onset vary and can easily go unnoticed, causing growth deficiency and pubertal delay to precede the intestinal manifestations of the disease<sup>[12]</sup>.

Poor bone health, delayed puberty, and growth failure may go on to complicate these patients' clinical management<sup>[2,6,12]</sup>.

The pharmacokinetics (PK) and pharmacodynamics of drugs in children are different from those in adults and the approach to paediatric drug dosing needs to be based on the physiological characteristics of the child and the pharmacokinetic parameters of the drug<sup>[13]</sup>.

Current European Medicines Agency (EMA) and United States Food and Drug Administration (FDA) guidance recommends that dose selection for paediatric studies is based on extensive and detailed prior information, starting with what has been learnt in adult populations<sup>[14]</sup>. Paediatric pharmacometric approaches are increasingly being applied to drugs already in use, but that remain unlicensed and off-label in children<sup>[14]</sup>. There are multiple factors contributing towards the pathogenesis of IBD, and the whole mechanism is yet to be entirely defined in its complexity. Current hypotheses suggest the host's genetic profile, immune system and environmental factors such as the gut microbiota as possible key factors<sup>[3]</sup>.

IBD may develop from a chain of events involving alteration in the microbiome, increase in intestinal permeability leading to bacterial translocation, and

subsequent activation of the adaptive immune response to cause tissue damage (a model known as “bacterial penetration cycle hypothesis”)<sup>[15]</sup>.

As a result of the uncontrolled activation of the mucosal immune system, the pro-inflammatory cytokines released cause chronic inflammation of the gastrointestinal tract<sup>[5]</sup>. In consideration of the crucial role played by cytokines in the development of intestinal inflammation, all current treatments for IBD target downstream events in the host inflammatory response<sup>[15]</sup>.

Given the complexity and heterogeneity of IBD, a holy grail of current research is to be able to customize therapy to a patient’s predictive biomarker profile, in order to personalise treatment and to maximise response<sup>[11]</sup>.

Studies in adult patients with CD have shown that treatments capable of inducing and maintaining endoscopic mucosal healing (MH) have a positive impact on the disease course, by reducing the number of clinical relapses, hospitalizations and surgical interventions<sup>[16]</sup>. Therefore, the current aim in the care of IBD for all ages is achieving intestinal MH, *i.e.*, beyond the simple resolution of symptoms<sup>[3]</sup>.

Based on this evidence, the strategy of early introduction of immunomodulators and biological therapies (“top-down”) to induce deep remission (long-term intestinal healing) is increasingly used in high-risk paediatric patients (*e.g.*, children with extensive disease distribution, severe perianal disease, no response to standard medical options, growth retardation and delayed puberty) as an attempt to modify the clinical course of the disease by inducing and maintaining remission, reducing hospitalizations, surgeries, use of corticosteroids, as well as promoting growth and pubertal development<sup>[3]</sup>.

Based on the recommendations above, the conventional “step up” approach for paediatric CD, based on amino-salicylates, corticosteroids, and immunomodulators, is increasingly outdated for patients at high risk of complicated disease<sup>[17,18]</sup>.

This narrative review aims to summarise the most recent advances in treating children with IBD and to provide with an overview of the new treatments in this field.

## LITERATURE SEARCH

A Medline search using the keywords “paediatric inflammatory bowel disease”, “paediatric Crohn’s disease”, “paediatric ulcerative colitis”, “treatment”, “therapy”, “immunosuppressant”, “biologic”, “monitoring” and “biomarkers” was carried out.

Retrospective and prospective clinical studies, systematic reviews and meta-analyses published between 2014 and 2016 were selected for this narrative review. Studies conducted earlier were also taken into consideration whenever the data outline was considered

relevant to the scope of the review.

## DIET, MICROBIOTA AND FAECAL TRANSPLANT

Diet has an impact on the composition of the intestinal microbiome and gut immune status and currently there is growing evidence that the microbiota has a relevant role in the pathogenesis of IBD<sup>[15]</sup>.

“Dysbiosis”, an imbalanced intestinal microbiota with pro-inflammatory microorganisms prevailing on the protecting ones, has been repeatedly reported in patients with IBD<sup>[19]</sup>.

Dietary interventions in children with active CD have proved evidence of a link between diet and the disease<sup>[15]</sup>. Exclusive enteral nutrition (EEN) using a polymeric formula for 6-8 wk, is the first-line therapy to induce remission in children with active CD<sup>[20,21]</sup>. EEN is effective in inducing remission in approximately 80% of patients, with a clinical remission rate similar to corticosteroids<sup>[3]</sup>. However, as opposed to steroids, EEN provides significant nutritional benefit and is superior in achieving MH<sup>[3]</sup>.

EEN also leads to early MH, and long-term benefits of EEN-induced MH are currently being looked into<sup>[16]</sup>. Grover *et al.*<sup>[16]</sup> conducted a prospective cohort study on 54 children with new diagnosis of CD, to evaluate the impact of early EEN-induced MH on predicting sustained remission (SR) on immunomodulators, without need for additional therapy like steroids, biologics or surgery. Paediatric CD Activity Index (PCDAI), C-reactive protein (CRP) and endoscopic assessment at diagnosis were paired with those post 6 wk of EEN. Complete MH was observed in 33%, and near complete in 19%. SR was superior in children with complete MH vs those with active endoscopic disease at 1, 3 and 5 years of follow-up, therefore the authors conclude that following induction of remission with EEN, complete MH is superior to clinical and biochemical remission in predicting SR over and beyond 3 years on maintenance immunomodulators<sup>[16]</sup> (Table 1).

Partial enteral nutrition with allowance of free diet hasn’t been proved effective yet. It is unclear whether this depends on the supply of specific nutrients within the polymeric formula or on the exclusion of dietary factors during the course of exclusive polymeric diet<sup>[15]</sup>.

Recent studies have aimed to evaluate which of the excluded dietary components in EEN may be responsible for the effect, in order to look into ways to allow a safe whole food diet<sup>[15]</sup>.

Sigall-Boneh *et al.*<sup>[15]</sup> validated a dietary intervention that allows whole foods but reduces exposure to dietary components that have been shown to induce inflammation, affect the microbiome and the mucous layer, increase gut permeability or the adherence and translocation of bacteria in mouse or cell line models.

**Table 1 Summary of the cohort studies mentioned in the review including reference, study design and population, main results, conclusions**

Ref.	Study design	Population	Main results	Conclusion
Nutrition Sigall-Boneh <i>et al</i> <sup>[15]</sup> <i>Inflamm Bowel Dis</i> 2014	Prospective cohort study	47 patients = 34 children + 13 young adults  Mean age 16.1 ± 5.6 yr  Active CD (PCDAI > 7.5 or Harvey-Bradshaw Index ≥ 4)	Post treatment with 6-wk exclusion diet: access to specific foods + 50% of calories from polymeric formula Response in 37 (78.7%) Remission in 33 (70.2%) Decrease in CRP and ESR  Normalisation of CRP in 70% of patients entering remission Post EEN: Clinical remission (PCDAI < 10) in 45/54 (83%) Biochemical remission (PCDAI < 10, CRP < 5) in 39/54 (72%) Complete MH in 18/54 (33%) Nearly complete MH in 10/54 (19%) SR superior in children with MH <i>vs</i> active endoscopic disease: P 0.003 at 1 yr P 0.008 at 2 yr P 0.005 at 3 yr	Dietary therapy involving PEN with an exclusion diet seems to lead to high remission rates in early mild-to-moderate luminal CD in children and young adults
Grover <i>et al</i> <sup>[16]</sup> <i>J Crohns Colitis</i> 2016	Prospective cohort study	54 children with CD Age < 16 At least 6 wk EEN	Complete MH in 18/54 (33%) Nearly complete MH in 10/54 (19%) SR superior in children with MH <i>vs</i> active endoscopic disease: P 0.003 at 1 yr P 0.008 at 2 yr P 0.005 at 3 yr	Only complete MH post EEN induction predicts more favourable SR for up to 3 yr
Thiopurines Stocco <i>et al</i> <sup>[23]</sup> <i>World J Gastroenterol</i> 2015	Retrospective cohort study	12 paediatric patients = 6 CD + 6 UC	NAT1 genotypes (fast enzymatic activity) were associated with reduced TGN concentration The effect of NAT1 on TGN persists even 1 mo after the interruption of the aminosalicilate No effect of the NAT2 polymorphism was observed	NAT1 genotype affects TGN levels in patients treated with thiopurines and aminosalicylates and could therefore influence the toxicity and efficacy of these drug
Biologics and biosimilars Sharma <i>et al</i> <sup>[7]</sup> <i>Inflamm Bowel Dis</i> 2015	IMaGINE-1 study	Paediatric CD population = 192	Strong positive association between serum ADA concentration and disease remission/response to treatment	Positive association between serum ADA concentration and remission/response in paediatric patients with moderate/severe CD
	Phase-3, randomized,		Higher body weight, baseline CRP, lower albumin, previous treatment with anti-TNF and presence of anti-IFX antibody were associated with increased ADA clearance	
	Multicentre, double-blind			
Nuti <i>et al</i> <sup>[18]</sup> <i>J Crohns Colitis</i> 2016	Prospective cohort study	37 biologic-naïve paediatric patients with CD	Biological therapy with IFX + AZA was effective in achieving MH (based on change in PCDAI and SES-CD)  Combination of biologics + immunomodulators was more effective than biological monotherapy Improvement of mucosal lesions at 2 yr follow-up was predictive of favourable outcomes	Biologics improve mucosal lesions, more effectively if given in combination with immunomodulators. MH predicts a better disease course
Fumery <i>et al</i> <sup>[33]</sup> <i>J Pediatr Gastroenterol Nutr</i> 2015	Retrospective population based study (EPIMAD registry)	27 paediatric patients with CD experiencing IFX failure	Effectiveness and safety of ADA: Clinical benefit: 19 (70%) measured by the physical global assessment score Significant decrease in CRP in children responding to ADA (9 <i>vs</i> 15 mg/L) Cumulative probability of failure to ADA treatment: 38% at 6 mo, 55% at 1 yr Primary failure: 8 (30%) Secondary failure: 5 (26%) Adverse effects: 11 (40%)	Treatment with ADA was safe and effective in two-thirds of patients with pediatric-onset CD and IFX failure

Frymoyer <i>et al</i> <sup>[38]</sup> <i>J Pediatr Gastroenterol Nutr</i> 2016	Monte Carlo simulation analysis constructed using a published population pharmacokinetic model based on data from 112 children in the REACH trial	1000 simulated children	Trough IFX concentration > 3 mg/mL was achieved at week 14 in 21% for albumin level of 3 g/dL vs 41% for albumin of 4 g/dL	Standard IFX maintenance dosing in children with CD is predicted to frequently result in inadequate exposure, especially when albumin levels are low.
Dziechciarz <i>et al</i> <sup>[34]</sup> <i>J Crohns Colitis</i> 2016	Systematic review of 14 studies	Efficacy and safety of ADA I paediatric patients with CD	Pooled remission rates: At 4 wk: 30% ( <i>n</i> = 93/309) At 3 mo: 54% ( <i>n</i> = 79/145) At 4 mo: 45% ( <i>n</i> = 18/40) At 6 mo: 42% ( <i>n</i> = 146/345) At 8 mo: 57% ( <i>n</i> = 20/35) At 12 mo: 44% ( <i>n</i> = 169/383) Primary non-responders: 6% (13/207) Severe adverse events: 12% (69/599) Clinical response post treatment with vedolizumab: 6/19 (31.6%) at week 6 11/19 (57.9%) at week 22 Steroid-free remission in 1/20 (5%) at week 6, 3/20 (15%) at week 14 and 4/20 (20%) at week 22.	According to low-quality evidence based mainly on case series, approximately half of children with CD on ADA therapy achieve remission during the first year of the therapy with reasonable safety profile
Conrad <i>et al</i> <sup>[39]</sup> <i>Inflamm Bowel Dis</i> 2016	Observational, single-centre, prospective cohort study	21 paediatric patients (16 CD, 5 UC) with refractory IBD who had previously failed anti-TNFα therapy	Week 14 remission rates: 76% for UC, 42% for CD, 80% of anti-TNF naïve IBD Week 22 remission rates: 100% anti-TNF naïve vs 45% anti-TNF exposed Clinical remission: 88% for CD 57% for UC	Clinical response to vedolizumab in children with moderate/severe CD increases from week 14 to week 22 No differences in treatment efficacy, after switching from IFX originator to its biosimilar
Singh <i>et al</i> <sup>[44]</sup> <i>Inflamm Bowel Dis</i> 2016	Retrospective review on the experience with vedolizumab	52 paediatric patients with IBD, 90% of whom had failed ≥ 1 anti-TNF agent		
Sieczkowska <i>et al</i> <sup>[46]</sup> <i>J Crohns Colitis</i> 2016	Prospective cohort study	39 paediatric patients: 32 with CD, 7 with UC  Children were switched from IFX originator to its biosimilar All patients had PCDAI ≥ 25 at the time of switching		
Thalidomide Lazzerini <i>et al</i> <sup>[50]</sup> <i>JAMA</i> 2013	Double-blind, placebo-controlled, randomized clinical trial	56 paediatric patients with active CD, randomised to receive either thalidomide or placebo Almost all had not responded to thiopurines and 35% had not responded to biologics	Clinical remission achieved by 13/28 (46.4%) of the children treated with thalidomide vs 3/26 (11.5%) of those who received placebo ( <i>P</i> = 0.01) Responses were not different at 4 wk, but greater improvement was observed at 8 wk in the thalidomide group [75% response in 13/28 (46.4%)] vs 3/26 (11.5%) ( <i>P</i> 0.01) Of the non-responders to placebo who began receiving thalidomide, 11 of 21 (52.4%) subsequently reached remission at week 8 ( <i>P</i> = 0.01). Overall, 31 of 49 children treated with thalidomide (63.3%) achieved clinical remission Mean duration of clinical remission in the thalidomide group was 181.1 wk vs 6.3 wk in the placebo group ( <i>P</i> < 0.001).	Thalidomide compared with placebo resulted in improved clinical remission at 8 wk of treatment and longer-term maintenance of remission.
Lazzerini <i>et al</i> <sup>[50]</sup> <i>Inflamm Bowel Dis</i> 2015	Multicenter, double-blind, placebo-controlled, randomized clinical trial	26 paediatric patients with active UC, randomised to receive thalidomide or placebo All patients had had thiopurines and 35% had received prior IFX treatment	Clinical remission at week in 10/12 (83.3%) of the children treated with thalidomide vs 2/11 (18.8%) of those who received placebo ( <i>P</i> = 0.005) Of the non-responders to placebo who were switched to thalidomide, 8 of 11 (72.7%) subsequently reached remission at week 8 ( <i>P</i> = 0.01) Clinical remission in the thalidomide group was 135 wk compared with 8 wk in the placebo group ( <i>P</i> < 0.0001).	Thalidomide compared with placebo resulted in improved clinical remission at 8 wk of treatment and in longer term maintenance of remission.



New treatments Tew <i>et al</i> <sup>[11]</sup> <i>Gastroenterology</i> 2016	Retrospective analysis of two cohorts: 1. phase 2 placebo-controlled trial; 2. observational study at a separate site	110 patients with UC (cohort 1) and 21 patients including UC and controls (cohort 2)	Increased expression of T-cell associated genes in baseline biopsies of anti-TNF naïve patients who achieved clinical remission in response to etrolizumab  Patients with high colonic integrin $\alpha$ E expression showed greater benefit  GZMA expression was different post-treatment	Levels of GZMA and ITGAE mRNAs in colon tissues can identify patients with UC who are most likely to benefit from etrolizumab  GZMA is a promising biomarker for etrolizumab response
Sandborn <i>et al</i> <sup>[51]</sup> <i>N Engl J Med</i> 2016	Double-blind, placebo-controlled, phase-2 trial	197 adult patients with moderate-severe UC	Clinical remission at 8 wk:  16% of patients who received 1 mg of Ozanimod <i>vs</i> 14% who received 0.5 mg <i>vs</i> 6% of those who received placebo Clinical remission t 32 wk: 21% <i>vs</i> 26% <i>vs</i> 6% respectively Drop in absolute lymphocyte count at week 8: 49% from baseline in the group who received 1 mg of Ozanimod 32% from baseline in the group who received 0.5 mg	Ozanimod at a daily dose of 1 mg resulted in a slightly higher rate of clinical remission of UC than placebo
Allez <i>et al</i> <sup>[52]</sup> <i>Gut</i> 2016	Randomised, double-blind, parallel group trial	78 adult patients with CD  Age 18-75  Disease duration $\geq 3$ mo  CDAI 220-450 CRP $\geq 10$ mg/L Endoscopic evidence of inflammation	No significant difference in change in CDAI from baseline to week 4, between NKG2D group and placebo group Significant difference in change in CDAI at week 12 (delta CDAI -55, $P \leq 0.1$ ) between NKG2D group and placebo group Significant improvement noted in the non-failure to biologic subgroup treated with anti-NKG2D from week 1	A single s.c. dose of 2 mg/kg anti-NKG2D did not reduce disease activity at week 4 <i>vs</i> placebo, but the difference was significant at week 12

ADA: Adalimumab; CD: Crohn's disease; CDAI: Crohn's disease activity index; CRP: C-reactive protein; EEN: Exclusive enteral nutrition; GZMA: Granzyme A; IFX: Infliximab; ITGAE: Integrin  $\alpha$ E gene; MH: Mucosal healing; NAT: N-acetyl transferase; PCDAI: Paediatric Crohn's disease activity index; PEN: Partial enteral nutrition; s.c.: Subcutaneous; SES-CD: Simple Endoscopic Score for Crohn's Disease; SR: Sustained remission; TGN: Thioguanine nucleotides; UC: Ulcerative colitis.

They recruited 47 patients including 34 children and 13 young adults with active disease, who were treated with a 6-wk exclusion diet that allowed access to specific foods and up to 50% of dietary calories from a polymeric formula.

The diet consisted in elimination of or reduction in animal fat, dairy products, gluten, and emulsifiers whereas fibre from fruits and vegetables was allowed. Clinical response was observed in 78.7% and remission in 70.2%, alongside improvement in CRP (normalized in approximately 70%) and ESR. On the basis of these results, the Authors recommend the use of this elimination diet in patients with mild-moderate disease, as it allows access to specific foods improving palatability and compliance<sup>[15]</sup> (Table 1).

So far, efficacy of microbiome-based therapies like probiotics or antibiotics has been limited in IBD<sup>[19]</sup>. Nevertheless, the recent focus on dysbiosis as a plausible key factor in IBD pathogenesis, has led to a growing interest in faecal microbiota transplantation (FMT) as a novel potential treatment option in IBD.

FMT is the administration of faecal material from a donor into the intestinal tract of a recipient, with the aim to change the microbiota composition and restore mucosal health. Over the past few years, FMT has been used successfully for the treatment of recurrent *Clostridium difficile* infection (CDI) (efficacy of 80%-95%), and is now being evaluated in other diseases possibly driven by the microbiota, including IBD<sup>[19]</sup>.

There are several studies and case reports on the use of FMT in UC, but only two randomized control studies published to date<sup>[19,20,22]</sup>.

The success rate of FMT in treating UC has been much more limited (clinical remission in 35%) in respect to its success in treating recurrent CDI. However, studies so far have been small and heterogeneous, therefore clear conclusions are difficult to make<sup>[19]</sup>.

Even less data is available for FMT in CD, with only isolated cases or heterogeneous small series reporting overall clinical remission in 60%-75%<sup>[19]</sup>.

At present, evidence on FMT in IBD is not strong

enough to recommend its use as part of routine treatment. Preliminary results are promising and more studies are needed to define the best indications, optimal timing, frequency, mode of delivery, and the most appropriate donor for each patient<sup>[19]</sup>.

## AMINOSALICYLATES

5-aminosalicylic acid (mesalazine, 5-ASA) acts topically on the gastrointestinal mucosa, with minimal systemic effect. Even though its exact mechanism of action is yet to be understood in its complexity, the pathways that are known to be involved include the blockade of IL-1 production and TNF- $\alpha$  receptor, the inhibition of cyclooxygenase and 5-lipoxygenase, and the blockade of the pro-inflammatory prostaglandin E2 and leukotrienes. On top of the inhibition of multiple inflammatory pathways and the suppression of the nuclear factor kappa B as a main result, aminosalicylates also possess potent anti-oxidant and free-radical-scavenger properties<sup>[4]</sup>. Amino-salicylates are mainly used in the induction and maintenance of remission in UC<sup>[23]</sup>.

In CD, their use is no longer recommended in view of limited efficacy. However, there are studies suggesting a possible role in the postoperative maintenance of remission, as well as in the subgroup of children with mild, localised ileal disease. In addition, adult studies suggest a protective role of 5-ASA in IBD against colon cancer in patients with colonic location<sup>[23]</sup>.

Given that sulfasalazine is not tolerated in 30%-40% of patients, particularly slow acetylators, the use of its therapeutically active component 5-ASA has led to the development of new formulations, that deliver higher concentrations of 5-ASA without the dose-limiting side effects of sulfasalazine. A wide range of these formulations is available and comprises pH-dependent release coated drugs (targeting the ileum), time-dependent release micro-granules enclosed within a semi-permeable membrane of ethyl-cellulose (released in the whole small and large intestine), and azo-bonded formulations released throughout the colon<sup>[4]</sup>.

## CORTICOSTEROIDS

Corticosteroids are used as first-line therapy for induction of remission in UC, particularly in patients with non-response to 5-ASA or with severe presentation, as well as to induce remission in CD when EEN is not possible<sup>[3,9,24]</sup>.

The mechanism of action of corticosteroids consists in inhibiting protein synthesis and transcription, which ultimately results in down-regulation of pro-inflammatory cytokines, such as NF-kappa B, TNF- $\alpha$ , interleukin-1 and interleukin-6<sup>[9]</sup>.

Clinical remission rates for CD are up to 80%, similarly to EEN, whereas MH rates are significantly lower<sup>[3]</sup>. Corticosteroids improve rapidly and effectively the signs and symptoms of disease in CD, however

they are ineffective, and inappropriate, for maintenance therapy<sup>[17]</sup>.

In children with moderate-severe active luminal CD, oral prednisolone is given at 1 mg/kg, with a maximum of 40 mg/d, followed by a weaning course over 8-10 wk. Intravenous steroids may be initially needed for severe disease and include methylprednisolone (1-1.5 mg/kg, maximum: 60 mg/d) and hydrocortisone (2-4 mg/kg per dose, maximum 100 mg/dose, four times a day)<sup>[3]</sup>.

Adverse effects like adrenal suppression, growth failure, cosmetic and behavioural effects, are dependent on dose and duration<sup>[3]</sup>.

Budesonide (maximum of 12 mg/d, followed by weaning course over 2-4 wk) is a topically acting corticosteroid with high first pass hepatic metabolism, which reduces the likelihood of adverse effects<sup>[3,9]</sup>.

Budesonide is particularly recommended for patients with mild to moderate CD involving the distal ileum and/or right colon, as it has been shown to be non-inferior to conventional oral steroids for inducing remission in this specific group. It has also proved to be an effective therapeutic option as enema formulation for distal UC<sup>[9]</sup>.

There are currently three formulations of budesonide: two standard formulations including a controlled-release capsule and a pH-dependent capsule both designed to target the ileum and right colon; and a more recent Budesonide-MMX<sup>®</sup> capsule that releases the drug throughout the entire colon<sup>[9]</sup>.

## THIOPURINES

Thiopurines are purine analogues used for the maintenance of disease remission in patients with CD and UC; they include the prodrug AZA and the antimetabolite 6-MP<sup>[25,26]</sup>.

AZA is non-enzymatically degraded to 6-MP which is then metabolised to its active component, 6-thioguanine nucleotide (6-TGN)<sup>[8]</sup>. 6-TGN inhibits the proliferation of T and B lymphocytes, which results in a decrease in the numbers of cytotoxic T cells and plasma cells<sup>[8]</sup>.

These drugs are able to block the rapid cell proliferation involved in inflammatory processes, which results in immunosuppression<sup>[26]</sup>.

For the treatment of IBD, thiopurines are used at relatively low dosages, so their anti-inflammatory effect is mainly produced by the inhibition of the small GTPase Rac1, leading to apoptosis of activated T-lymphocytes. When given at higher dosages, as in oncological treatments, thiopurines mainly inhibit DNA synthesis<sup>[26]</sup>.

Thiopurines are steroid sparing agents and have been proven effective maintenance treatment in paediatric IBD: studies have shown significantly lower cumulative steroid doses and relapse rates at 18 mo in children on 6-MP compared with placebo (9% vs 47%) as well as a reduced need for surgery in CD<sup>[3,23]</sup>. Recommended doses are 1.0 to 2.5 mg/kg per day for AZA and 1 mg/d for 6-MP<sup>[25]</sup>.

Thiopurines are also used effectively to maintain surgically-induced remission in CD, even though a systematic review by Gordon *et al*<sup>[8]</sup> pointed out that the results for efficacy outcomes between thiopurines and 5-ASA in this group of patients are uncertain.

Testing the activity of the enzyme thiopurine-S-methyltransferase (TPMT) is recommended to guide thiopurine dosing avoiding adverse events<sup>[26]</sup>.

Genetic polymorphisms in the TPMT gene are associated with a reduced enzymatic activity and an increased production of the active metabolites TGNs<sup>[23]</sup>.

A large prospective study with 1000 individuals established TPMT activity reference intervals, with normal activity associated with a level  $\geq 25$  nmol/h per gram Hgb<sup>[27]</sup>.

According to the current data available, 1 in 300 patients have a very low to absent TPMT activity (homozygous mutant TPMT), 11% have intermediate TPMT activity (heterozygous) and 89% have normal to elevated activity (homozygous wild type TPMT)<sup>[27]</sup>.

The use of thiopurines is limited by an extensive spectrum of adverse events in up to almost half of patients, particularly within the first twelve months of treatment. Adverse effects include myelotoxicity, hepatotoxicity, pancreatitis and gastrointestinal complaints<sup>[26]</sup>.

Measuring TPMT activity levels (phenotype) or determining TPMT genotype before initiating thiopurine therapy, is recommended by the FDA to limit the likelihood of side effects<sup>[27]</sup>. However, it still remains possible to develop significant myelotoxicity despite normal TPMT activity.

The use of TPMT activity and 6-TGN level monitoring has the potential to avoid nearly a quarter of episodes of myelosuppression<sup>[27]</sup>. In addition, 6-TGN monitoring is helpful to detect non-compliance, under-dosing, and drug resistance or refractory states<sup>[27]</sup>.

Blood levels of thiopurine metabolites correlate with the efficacy and toxicity of these drugs as follows: TGN levels higher than  $235 \text{ pmol}/8 \times 10^8$  red blood cells reflect an adequate therapeutic level, whereas methyl mercaptopurine nucleotides levels above  $5700 \text{ pmol}/8 \times 10^8$  red blood cells are indicative of hepatotoxicity<sup>[23]</sup>.

AZA or 6-MP can be started at the full recommended dose of 2-2.5 mg/kg per day or 1-1.5 mg/kg per day, respectively, in patients with normal to high TPMT activity level. Patients with an intermediate TPMT activity should start, instead, with a daily dose reduced by 30%-70%. Alternative therapy should be offered to individuals with low or absent TPMT activity, or they should be started at 10% of the suggested dosing, given three times per week<sup>[27]</sup>.

The results of a recent retrospective study by Benmassaoud *et al*<sup>[27]</sup> evaluating the safety and efficacy of starting thiopurines at low dose vs full dose in adult patients with CD and normal TPMT, suggest that AZA should be started on full dose in patients

with normal TPMT, rather than starting on a lower dose and increasing slowly. This is mainly due to the fact that patients with normal TPMT level may still be exposed to side effects that are unrelated to the enzymatic activity<sup>[27]</sup>. Overall, almost half of the adults treated with thiopurines discontinue their treatment due to ineffectiveness or intolerance<sup>[26]</sup>. It has been hypothesized that prescribing thioguanine (TG) therapy instead of AZA/6-MP reduces the release of potentially toxic metabolites, as its metabolism is less complex with a more direct conversion to the therapeutically active metabolite 6-TGN<sup>[1]</sup>.

In a systematic review, Meijer *et al*<sup>[1]</sup> describe how TG therapy can represent a valuable option in adult IBD patients intolerant to conventional thiopurine therapy, with efficacy in 65% of patients and short term adverse events in 20%. However, TG is currently only used as experimental or rescue therapy and should not be used outside highly controlled situations<sup>[1]</sup>. Thiopurines and amino-salicylates are often used in combination in the treatment of IBD<sup>[23]</sup>.

An increase in mean TGN blood levels has been reported in patients on concomitant treatment with thiopurines and 5-ASA. Moreover, a higher rate of myelotoxicity was observed in this group of patients compared with those treated with the thiopurine alone<sup>[22]</sup>. A plausible explanation comes from *in vitro* studies showing that amino-salicylates and their metabolites can inhibit the activity of TPMT, even though this observation has not been yet replicated *in vivo*<sup>[23]</sup>.

The enzymes N-acetyltransferases (NAT1 and NAT2, EC 2.3.1.5) are responsible for the N-acetylation of multiple drugs including the amino-salicylates. Subjects are classified as rapid, intermediate or slow acetylators based on the activity of NAT1 and NAT2 that is genetically determined<sup>[23]</sup>.

Stocco *et al*<sup>[23]</sup> evaluated the variation of the level of TGN after 5-ASA cessation and the role of genetic polymorphisms of NAT 1 and 2, in a group of 12 children recruited at two tertiary level paediatric gastroenterology units (6 CD and 6 UC) (Table 1).

Rapid acetylators with NAT1 genotypes were found to have reduced TGN concentration, and the effect of NAT1 activity on TGN persisted up to one month after discontinuation of the 5-ASA. NAT2 polymorphism, instead, did not produce any effect. These results, though limited by the small number of patients, show that the NAT1 genotype affects TGN levels in patients treated with thiopurines and 5-ASA and it may therefore impact on the efficacy and toxicity of these drugs<sup>[23]</sup> (Table 1).

## MTX

MTX, a dihydrofolate reductase inhibitor, has long been used effectively to treat rheumatoid arthritis until it was brought into the field of IBD to treat patients with

refractory CD. Nowadays, it has become one of the principal alternatives to thiopurines as maintenance treatment<sup>[28,29]</sup>.

Efficacy of MTX, given at 15 mg/m<sup>2</sup> once a week for a maximum of 25 mg/wk subcutaneously, is reported as 50%-80% by retrospective cohort studies in children who failed to respond or were intolerant to thiopurines<sup>[3]</sup>. MTX is a first-line treatment option in patients who have concomitant inflammatory arthritis and it represents a valuable alternative to maintenance treatment with anti-TNF<sup>[3,29]</sup>. Adverse events associated with MTX include flu-like symptoms, transaminitis and, less frequently, myelosuppression, which may require dosage adjustment or drug withdrawal<sup>[3]</sup>. Nausea and vomiting have been reported in 11%-24% of patients, the majority of whom respond to antiemetic medication. Significant hepatocellular liver disease is rare. Contraception is essential<sup>[3]</sup>.

Systematic reviews performed by MacDonald JW and by Patel *et al.*<sup>[29]</sup> to assess the efficacy and safety of MTX for the treatment of active refractory CD in adults, show that intramuscular MTX is effective in inducing remission and acts as a steroid sparing agent allowing complete withdrawal from steroids<sup>[28,30,31]</sup>. Lower dose oral MTX does not appear to provide any significant benefit in respect to placebo or active comparator<sup>[28,31-33]</sup>. Though limited by the small size of the studies analysed, this review could not identify any additional benefit from combining MTX and IFX over IFX monotherapy<sup>[28,31]</sup>.

## BIOLOGICS AND BIOSIMILARS

TNF is produced by macrophages, adipocytes, fibroblasts and T cells and acts as a pleiotropic, pro-inflammatory cytokine by triggering a cascade of events that lead to tissue damage<sup>[5,7]</sup>.

IFX, ADA and other anti-TNF agents act by suppressing downstream pathways mediated by TNF including angiogenesis, increase in T-helper cell 1 (Th1) cytokine production (interleukin-12 and interferon- $\gamma$ ), death of intestinal epithelial cells and T-cell resistance to apoptosis<sup>[5]</sup>.

Anti-TNF medications are able to achieve and maintain MH, with growing evidence of a change in the natural history of the disease. Importantly, as opposed to a few years ago when clinical response and remission were the main goals in treating patients with IBD, MH has recently been emphasized as a stronger therapeutic goal, as it predicts sustained clinical remission. Therefore, a new concept of "deep remission" has been coined, including MH alongside clinical and/or biochemical remission<sup>[18]</sup>. Also thiopurines and EEN with polymeric diet have been previously reported to achieve MH, albeit less rapidly and to a lower degree than biologics<sup>[18]</sup>. According to the studies performed on adult populations, scheduled maintenance therapy with IFX maintains MH in up to 68% of patients, and

the subgroup of patients achieving MH show decreased rate of surgeries and hospitalizations<sup>[18]</sup>.

### IFX

IFX is a chimeric monoclonal antibody and was the first biologic approved for the treatment of moderate to severe paediatric CD<sup>[34]</sup>. The advent of biological therapies has drastically modified the treatment strategies and disease course of IBD in children and the role of IFX and ADA in the management of paediatric IBD was recently updated in the Consensus guidelines of ECCO/ESPGHAN<sup>[6]</sup>. In CD, anti-TNF therapies are currently well established in moderate to severe disease with lack of response to conventional therapy including corticosteroids and immunomodulators, or with contraindications or intolerance to it<sup>[34]</sup>. Anti-TNF agents are also used as a primary induction option for children with active perianal fistulising disease, in combination with targeted surgical intervention, as well as in children at risk of poor outcomes (top-down treatment)<sup>[3,20]</sup>. One year response and remission rates for IFX in luminal disease are reported as up to 90% and 55%-60% respectively<sup>[35,36]</sup>. Repeated administration of IFX can lead to immunogenicity in some patients, with possible loss of efficacy and delayed-type hypersensitivity<sup>[34]</sup>. A low proportion of children with CD (10%-25%) are primary anti-TNF non-responders, *i.e.*, they fail to respond after the 6 wk induction course. More commonly, however, the formation of antibody against the drug over time can result in secondary loss of response. Concomitant treatment with either thiopurines or MTX has been shown to contain this process<sup>[3]</sup>. A key step in managing IFX therapy over the more recent years is the increasing availability of therapeutic drug monitoring (TDM), that has improved response rates and has become a most effective tool for the management of secondary failure to IFX<sup>[37]</sup>.

Increasing evidence has shown that trough IFX concentrations < 3 mg/mL during maintenance therapy are associated with treatment failure. Also, children with lower albumin levels have higher IFX clearance and lower drug exposures<sup>[38]</sup>. Therefore, standard IFX maintenance dosing of 5 mg/kg every 8 wk may not be adequate for all children with CD to achieve sufficient concentration level and thus minimise loss of response (Table 1). Unfortunately, patients who don't respond to one anti-TNF are more likely to also fail a second agent<sup>[39]</sup>. Researchers hypothesized that a combination therapy of an anti-TNF antibody and another immunomodulator (*i.e.*, thiopurines or MTX) will increase the efficacy and reduce the risk of loss of response<sup>[40]</sup>.

There are several adult trials showing higher treatment efficacy (especially for induction of remission) in patients receiving combination therapy. In particular, concomitant immunomodulators increase IFX levels and reduce immunogenicity<sup>[40]</sup>. On the other hand, combination therapy in adults exposes patients to the



individual toxicity of both drugs and also seems to increase the risk of malignancy<sup>[40]</sup>. In paediatric IBD, the safety of combined treatment has been questioned after several cases of hepatosplenic T-cell lymphoma (HSTCL) in young patients with IBD so treated were reported.

Nevertheless, a review by Cozijnsen *et al*<sup>[40]</sup> points out that almost all studies in paediatric patients with IBD have failed to prove increased benefit from combination therapy compared to monotherapy. Given the controversial aspects above, the Authors suggest to target the use of combination therapy to children with a high risk of serious disease-related complications, such as growth delay, stricturing or fistulising CD phenotype, or panenteric CD<sup>[40]</sup>.

In order to assess the risk of malignancies associated to immunosuppressive treatments in IBD, a retrospective multinational survey of malignancy and mortality in paediatric IBD was conducted over a 6 years period (2006-2011) by the Porto Pediatric IBD working group of ESPGHAN<sup>[41]</sup>. The most common malignancies identified were hematopoietic tumors ( $n = 11$ ), of which 3 were HSTCL and 3 Ebstein-Barr virus-associated lymphomas<sup>[41]</sup>. These 6 patients had all been treated with thiopurines until diagnosis of cancer and only 1 patient had also received 3 IFX infusions, 5 years before the diagnosis of cancer<sup>[41]</sup>. All 3 patients who developed HSTCL were males and had exposure to thiopurines ranging from 32 to 108 mo; none of them received a biologic<sup>[41]</sup>.

## ADA

ADA is a fully human IgG1 $\kappa$  monoclonal antibody which is similar to IFX in the mode of action, but it differs from it as the mouse-derived sequence is removed, in order to reduce the immunogenic reactions induced by chimeric antibodies<sup>[23,34]</sup>. ADA is therefore to consider as an alternative treatment option in patients who have lost response or are intolerant to IFX, or in some primary non-responders to IFX<sup>[34]</sup>.

ADA was recently approved in Europe and the United States for the treatment of paediatric patients with CD, based on the results from the IMaGINE-1 study<sup>[7,42,43]</sup>.

IMaGINE-1 study is a phase-3, randomized, double-blind study conducted by Sharma *et al*<sup>[7]</sup> aimed to analyse the PK of ADA in a paediatric CD population ( $n = 192$ ), and to evaluate the effect of various factors, including demographics (body weight, sex), laboratory measurements (CRP, albumin), previous IFX use, concomitant immunomodulators, and baseline PCDAI, on ADA PK in paediatric patients with moderate-to-severe CD (Table 1). Furthermore, the relationship between serum ADA concentration and remission/response was explored<sup>[24]</sup>.

Trough serum ADA (measured at 5 time points from baseline up to 52 wk) and serial anti-ADA antibody measurements were performed. The study confirmed a strong positive association between serum ADA

concentration and clinical remission/response to treatment<sup>[24]</sup>. Higher body weight, baseline CRP, and lower baseline albumin levels were associated with greater clearance of ADA (lower trough levels)<sup>[7]</sup>. Previous treatment with other anti-TNF therapy, presence of antibodies to previous IFX therapy, and absence of concomitant use of immunomodulators were also associated with increased clearance of ADA<sup>[7]</sup>. According to the published experiences from tertiary centres, in anti-TNF antibody naïve children the 1 year remission rate for ADA is 45%<sup>[42]</sup>, and its efficacy has been documented in nearly two-thirds of patients who failed IFX<sup>[33]</sup>. A retrospective study was conducted by Fumery *et al*<sup>[33]</sup> who used the population-based EPIMAD registry to evaluate the effectiveness and safety of ADA in children with CD experiencing IFX failure (Table 1).

Twenty-seven children with CD who received ADA before 18 years because of IFX failure or intolerance were included. Clinical response measured by the physician global assessment score after a median follow-up of 16 (8-26) mo was observed in 19 patients (70%). Cumulative probability of failure to ADA treatment at 6 mo and 1 year was 38% and 55%, respectively. Overall, the results from this population-based cohort of paediatric-onset CD with IFX failure show that treatment with ADA was safe and effective in two-thirds of patients. More specifically, ADA was effective in 100% of children intolerant to IFX, 68% of children with secondary failure to IFX, and only 25% of children with primary failure to IFX<sup>[33]</sup>. A systematic review on the same topic was performed by Dziechciarz *et al*<sup>[34]</sup>. Who assessed the published evidence on the efficacy and safety of ADA for CD in children (Table 1).

Randomised controlled trials and observational studies (cohort studies, case series of more than 5 patients) were included. A total of 14 studies (1 randomised controlled trial, 13 case series), altogether including 664 patients (age range 1.9-21 years) were available for analysis. The pooled remission rates were: 30% at 4 wk, 42% at 6 mo and 44% at 12 mo. Of the total patients, 6% were primary non-responders and 12% had severe adverse events reported. However, studies differed with respect to patients' characteristics, including percentage of IFX-naïve patients, disease duration, disease localisation, ADA doses, treatment duration, and follow-up period<sup>[34]</sup>.

The Authors' conclusion, though limited by the low-quality evidence based mainly on case series, is that approximately half of the children with CD on ADA therapy achieve remission during the first year of treatment with reasonable safety profile<sup>[34]</sup>.

## Vedolizumab

Vedolizumab is a recent biologic treatment, approved for adult patients with IBD in 2014. It is an anti-integrin therapy that blocks the  $\alpha 4\beta 7$  integrin receptor molecule

present on the surface of lymphocytes, and thus inhibits the migration of intestinal T-lymphocytes into the tissue<sup>[39,44,45]</sup>. As this mechanism of action is restricted to the gastrointestinal tract, the risk of systemic immunosuppression (*i.e.*, infections and malignancies) seen with other IBD therapies is mitigated<sup>[39]</sup>.

Its predecessor, natalizumab, acts with a non-specific binding to the  $\alpha 4$  chain which causes interference with the lymphocyte trafficking in the central nervous system and led to the concern for reactivation of John Cunningham (JC) virus and subsequent development of progressive multifocal leukoencephalopathy (PML)<sup>[45]</sup>. Vedolizumab, being gut specific, does not interfere with immune surveillance in the central nervous system, therefore there is no risk of PML as assessed by the placebo-controlled GEMINI studies<sup>[44]</sup>. Anti-adhesion therapy appears to have a favourable safety profile, though the experience in children is still extremely limited<sup>[17]</sup>. Due to its mechanism of action of targeting gut-specific T-cell interactions, it is thought that Vedolizumab may not sufficiently treat the extra-intestinal manifestations of IBD. A dual therapy with therapeutic doses of immune-suppressants may therefore be needed to treat extra-intestinal manifestations<sup>[39]</sup>. So far, Vedolizumab has been particularly effective amongst UC patients, with a clinical response rate of 50% during induction<sup>[39]</sup>. Whilst the use of Vedolizumab has been approved for the treatment of CD and UC in adults, there is increasing off-label use in paediatric IBD<sup>[44]</sup>.

Singh *et al.*<sup>[44]</sup> conducted a retrospective review to describe the experience with Vedolizumab in 52 children with IBD (58% CD and 42% UC) at 3 tertiary IBD centres and to examine predictors of remission. Ninety percent of the patients had failed at least one anti-TNF agent. Week 14 remission rates for UC and CD were 76% and 42%, respectively ( $P < 0.05$ ). At week 4, eighty percent of anti-TNF-naïve patients were in remission. At week 22, anti-TNF-naïve patients had higher remission rates than those previously exposed to anti-TNF (100% vs 45%,  $P = 0.04$ ). There were no safety concerns.

These results support Vedolizumab as an effective and safe treatment in children with IBD, with UC patients experiencing earlier and higher rates of remission than children with CD. Also, the data reviewed shows that anti-TNF-naïve patients had higher remission rates compared to those with previous anti-TNF exposure<sup>[44]</sup>.

Conrad *et al.*<sup>[39]</sup> conducted an observational single-centre prospective cohort study aimed to determine the impact of Vedolizumab on clinical response and on achieving steroid-free remission over 22 wk of therapy. They recruited 21 children with refractory IBD (16 with CD), who had previously failed anti-TNF therapy.

Clinical response was observed in 31.6% and in 57.9% by week 6 and by week 22, respectively. Steroid-free remission was seen in 1 patient at week 6 and in 4 (20%) at week 22. No infusion reactions

were observed. Vedolizumab was discontinued in 2 patients because of severe colitis, requiring surgical intervention<sup>[39]</sup>. These results, though limited by the small sample size, describe a number of children with severe disease who achieve clinical response in the first 6 wk and a further increase in remission rate by week 22<sup>[39]</sup>. Overall, the data currently available on Vedolizumab from adult and paediatric studies suggests its use as an option to achieve clinical improvement in the most severe paediatric IBD patients (both CD and UC).

### Biosimilars

Biosimilars are defined as biological agents that are highly similar to another reference drug already authorized for use<sup>[37,46]</sup>. This definition also implies that the quality, safety and efficacy of the biosimilar should not be affected by any molecular and/or structural dissimilarities or any potential differences in the underlying mechanisms<sup>[37]</sup>.

Despite keeping the same aminoacid sequence as their reference drug, biosimilars end up being a different final product due to manufacturing process (including cell line, growth condition and purification processes), storage and transport, and subsequent various post-translational modifications (*e.g.*, glycosylation, phosphorylation, sulfation)<sup>[37]</sup>. Therefore, some uncertainty still exists regarding the exact drug efficacy, immunogenicity and pharmacology of biosimilars in IBD.

In 2013, the EMA authorized two IFX biosimilars, based on two randomized trials on CT-P13 (clinical development name for the biosimilar of Remicade): Remsima (Celltrion Inc., Incheon, South Korea) and Inflectra (Celltrion Inc., Hospira UK Ltd). Because both trials showed equivalent efficacy, tolerance and safety, EMA extended the approval to all indications for which the reference product is labelled, including both adult and paediatric CD and UC<sup>[37,46]</sup>. At present, a number of IFX biosimilars are licensed for treatment of CD and UC also in the paediatric population. Cost containment remains one of the predominant reasons for development of biosimilars, with a reduction in costs of anti-TNF therapy for IBD by up to 70%<sup>[37]</sup>.

Sieczkowska *et al.*<sup>[46]</sup> conducted a prospective study on 32 children diagnosed with CD and 7 children with UC at 3 academic hospitals in Poland; these patients were switched from IFX originator to its biosimilar (Remsima) (Table 1). Analysis of biosimilar efficacy revealed rates of clinical remission of 88 and 57% for CD and UC patients, respectively, so, in conclusion, switching from IFX originator to its biosimilar was a safe option in this cohort and after the switch, the biosimilar was just as effective as the originator<sup>[46]</sup>.

To date, preliminary results on CT-P13 in IBD are only available from small post-marketing registries and case series with a relatively short-term follow-up period. Although this data suggests comparable efficacy and safety to IFX, more robust post-marketing

studies and pharmacovigilance are warranted to evaluate the bioequivalence of CT-P13 in the coming years<sup>[37]</sup>. In Europe, at present, in order to switch patients with IBD from IFX originator to its biosimilar, the supervision of the treating physician and the patient's consent are both required<sup>[46]</sup>.

## THALIDOMIDE

Thalidomide is an immunosuppressant drug used rarely in the treatment of refractory CD and UC<sup>[47]</sup>. Its mechanism of action includes several pathways such as inhibition of TNF, IFN- $\gamma$  and IL-12, stimulation of IL-4 and IL-5 production and, more broadly, a shift in the pattern of lymphocyte cytokine from a Th1 (IFN- $\gamma$ , IL-12) to Th2 (IL-4, IL-5) type<sup>[5]</sup>. Thalidomide also interferes with integrin expression, decreases circulating helper T-cells and inhibits angiogenesis<sup>[5]</sup>.

After its suspension due to major teratogenic effects, thalidomide has been more recently re-introduced under FDA approval as an effective treatment for multiple myeloma and severe erythema nodosum leprosum. It is also extensively used off-label for immune-mediated and neoplastic conditions like discoid lupus erythematosus, erythema nodosum leprosum, Behcet's syndrome, aphthous stomatitis, juvenile idiopathic arthritis, brain tumors, graft-vs-host disease and IBD<sup>[5,18,48]</sup>.

Thalidomide is used infrequently in the management of paediatric CD, nevertheless it represents a helpful option in treating children who lose response to one or more conventional agents such as thiopurines, MTX, and anti-TNF<sup>[48]</sup>.

Thalidomide (administered from 50 to 400 mg/d in adults and 1.5 to 2.5 mg/kg per day in children<sup>[47]</sup>) has been shown to induce clinical remission and possibly MH<sup>[48]</sup>. A systematic review by Yang *et al.*<sup>[5]</sup> selected twelve studies (2 RCTs and 10 case series) where thalidomide was used to induce remission in 248 patients with IBD of all age groups (10 with UC, 238 with CD), 92 of whom were children. Remission rate was 49% and 25%, in adult luminal and perianal CD respectively. In adults with UC, 50% achieved remission and 10% had a partial response. One case series reported 21 patients (17 CD, 4 UC) who maintained remission for 6 mo<sup>[5]</sup>. Amongst the adverse effects associated with thalidomide and reported in this review, the most common was sedation, in 32.3% of all patients, followed by peripheral neuropathy in 19.8% which was also the main cause of discontinuation<sup>[5]</sup>. Amongst the studies in this review, one high quality RCT showed that thalidomide is effective in inducing remission in paediatric CD<sup>[49]</sup>. Based on the evidence reviewed and given the limited data available, the Authors support the use of Thalidomide in the most severe cases of IBD for induction or maintenance of remission<sup>[5]</sup>.

Lazzerini *et al.*<sup>[49,50]</sup> conducted randomized placebo-controlled trials of thalidomide in both paediatric CD

and UC (Table 1). In their CD trial, they randomized 52 children to receive thalidomide or placebo; almost all patients had not responded to thiopurines, and about 35% had also not responded to biologics. The majority of children had luminal disease and few had perianal disease. Although no significant response was noted at 4 wk, by 8 wk 46% of children treated with thalidomide had a reduction in their PCDAI greater than 75%, compared with 12% amongst patients treated with placebo<sup>[49]</sup>.

Their UC trial enrolled 26 children with active UC who were randomized to receive thalidomide or placebo. All patients had active disease despite thiopurines, and about 35% had received previous IFX treatment. The UC children treated with thalidomide achieved higher remission rates at 8 wk (83% vs 19% for placebo) than those in the CD trial<sup>[50]</sup>.

Both trials showed that thalidomide does not work quickly, as there were no significant differences between placebo and thalidomide at 4 wk, whereas major differences were seen by 8 wk<sup>[49,50]</sup>. These trials also support the use of Thalidomide as a maintenance agent in cases of refractory CD or UC, for example patients with secondary loss of response to biologics<sup>[49,50]</sup>. Another more recent systematic review conducted by Bramuzzo *et al.*<sup>[47]</sup> analysed 722 papers, including two randomized controlled trials and 29 uncontrolled studies for a total of 489 patients, 135 (28.4%) of whom were children.

Overall, thalidomide appeared to be a promising therapy for IBD: induction of clinical remission was achieved in 51.4% of cases, and in 69.3% a clinical response was observed in the first months of treatment. In almost 50% of the cases in which endoscopy was performed, complete MH was observed and a further 15% of patients showed an improvement in their endoscopy score<sup>[47]</sup>. IBD remission was maintained in 72.2% after 12 mo and in 54.5% after 2 years<sup>[47]</sup>.

Adverse events leading to drug suspension had a cumulative incidence of 19.7/1000 patients-month, with neurological symptoms being the main cause<sup>[48]</sup>. This review highlights that thalidomide is an effective alternative in patients who fail biologic treatment, which is most likely due to the different mechanism of action of Thalidomide compared to anti-TNF agents<sup>[47]</sup>. Careful precautions must be taken to avoid its use in pregnant women. No case of teratogenicity has been observed in 124000 patients enrolled in the thalidomide distribution risk management program for more than 6 years<sup>[49,50]</sup>. Other reported side effects of thalidomide include peripheral neuropathy (clinical or subclinical, primarily with axonal damage) followed by sedation, constipation, mood disturbances, skin rash, pedal oedema, neutropenia and deep vein thrombosis<sup>[5,48]</sup>.

## STUDIES ON NEW TREATMENTS

New biologics and other agents are being tested

in phase II and III trials on adult patients with IBD and are therefore on the horizon within the field of paediatric gastroenterology as well. Examples are the IL-23 inhibitor risankizumab and the IL-12/IL-23 inhibitor ustekinumab. Drug therapies that interfere selectively with lymphocyte trafficking are also emerging treatment options for UC<sup>[11,51]</sup>. Etrolizumab is a humanized monoclonal antibody against the  $\beta 7$  integrin subunit that acts by reducing the homing of leukocytes to the gut mucosa and the retention of lymphocytes in the epithelium<sup>[11]</sup>. It has recently been tested in a phase 2 study showing efficacy in patients with moderate to severe UC, compared to placebo<sup>[11]</sup>. Levels of granzyme A (GZMA) and integrin  $\alpha E$  (ITGAE) mRNAs in colon tissues can identify patients with UC who are most likely to benefit from etrolizumab<sup>[11]</sup> (Table 1).

Another agent recently developed is Ozanimod (RPC1063), an oral agonist of the sphingosine-1-phosphate receptor subtypes 1 and 5 that induces sequestration of peripheral lymphocytes, and as a consequence a decrease in the number of activated lymphocytes circulating to the gastrointestinal tract<sup>[51]</sup>. Its agonists induce internalization and degradation of the S1P1 receptor, which makes B and T lymphocytes incapable of migrating from secondary lymphoid organs, with subsequent reduction in circulating lymphocytes<sup>[51]</sup>. Being an oral formulation, Ozanimod represents an alternative to infusions of monoclonal antibodies for the treatment of UC, with no risk of sensitization and formation of antidrug antibodies. On the other hand, this product can be less selective than monoclonal antibodies, which may expose to adverse effects<sup>[51]</sup>.

Sandborn *et al.*<sup>[51]</sup> performed a double-blind, placebo-controlled phase 2 trial of Ozanimod in 197 adults with moderate-to-severe UC. Clinical remission at 8 wk was observed in 16% of the patients who received 1 mg of Ozanimod and in 14% of those who received 0.5 mg, as compared with 6% of those who received placebo ( $P = 0.048$ ,  $P = 0.14$ , respectively) (Table 1).

At week 32, the rate of clinical remission was 21% in the group that received 1 mg of Ozanimod, 26% in the group that received 0.5 mg of Ozanimod, and 6% in the group that received placebo; the rate of clinical response was 51%, 35%, and 20%, respectively<sup>[51]</sup>.

At week 8, absolute lymphocyte counts dropped by 49% from baseline in the group that received 1 mg of Ozanimod and by 32% from baseline in the group that received 0.5 mg<sup>[51]</sup>. The most common adverse events overall were anemia and headache<sup>[52]</sup>.

From this preliminary trial, the Authors conclude that Ozanimod at a daily dose of 1 mg is more effective than placebo in inducing clinical remission of UC. However, complete assessment of clinical efficacy and safety could not be achieved by this trial due to limitations in size and duration<sup>[51]</sup>. Another monoclonal antibody recently

investigated is the anti-natural killer group 2 member D (NKG2D), which acts by antagonising the human immunoglobulin G4 that binds to NKG2D receptors.

The interaction between intestinal epithelial cells and T-cells in the gut mucosa has a key role in T-cell regulation. NKG2D receptors are expressed by T cells and innate lymphoid cells, and exhibit pro-inflammatory properties. Upregulated NKG2D ligands on epithelial cells in the inflamed tissue of patients with IBD may activate the proliferation of several subsets of effector T-cells, leading to increased production of pro-inflammatory cytokines and enhanced cytotoxicity<sup>[52]</sup>. Previous trials have demonstrated an increase in effector T cells as well as in the expression of NK receptors on T cells in patients with CD<sup>[52]</sup>. Also, neutralising anti-NKG2D antibodies have been shown to reduce inflammatory-induced colitis in murine models<sup>[52]</sup>.

Allez *et al.*<sup>[52]</sup> performed a randomised, double-blind, parallel group trial of a single subcutaneous dose of 2 mg/kg anti-NKG2D or placebo in 78 adult patients with active CD (Table 1).

Change in CDAI from baseline to week 4 was the primary end-point, and was not found to differ significantly between anti-NKG2D and placebo; however, a significant difference was observed by week 12 ( $P \leq 0.10$ )<sup>[52]</sup>. The group of patients who hadn't previously failed biologics and were treated with anti-NKG2D ( $n = 28$ ) showed the most significant improvement from week 1 onward. Most adverse events were mild (49%) or moderate (43%). No antidrug antibodies were detected<sup>[52]</sup>.

Based on the results of this trials, the Authors conclude that a single s.c. dose of 2 mg/kg anti-NKG2D did not reduce disease activity at week 4, but it showed significant response rate at week 12. Therefore, there is evidence to consider further investment in anti-NKG2D in IBD<sup>[52]</sup>.

## DISCUSSION

Though major progress has been achieved in treating IBD patients of all ages, there are still significant limitations in what is currently available to manage this condition. The advent of new biologics and other medications targeting pathways previously unexplored (e.g., leukocyte trafficking through the gut mucosa) has provided clinicians with more hope for patients who fail to respond to current treatments. Nevertheless, whilst the causative mechanisms underlying IBD are not yet fully understood, treatment options can only target downstream components of this inflammatory chain.

IBD, and CD in particular, are difficult to categorise as distinct disease entities, as the spectrum of its clinical phenotype is very broad and variable, with mild disease responding to standard treatments, and severe disease often developing to structuring or penetrating



**Table 2 Summary and take home messages**

1. The pathogenesis of IBD is not completely understood yet, and all therapies currently available are aimed at downstream steps of the complex inflammatory process. Specific targets when treating children with IBD are achieving satisfactory growth and nutritional status.
2. Paediatric pharmacometric approaches are increasingly applied to drugs already in use but that remain unlicensed and off-label in children due to missing information on age appropriate dosing, efficacy and safety.
3. Corticosteroids can be used to induce remission in CD (when exclusive enteral nutrition is not possible) and are first-line therapy for induction of remission in UC, particularly in case of non-response to 5-ASA or with severe presentation.
4. One of the targets of current research is to customise therapy to a patient's predictive biomarker profile in order to personalise treatments and to maximise response.
5. 5-ASA are used in induction and maintenance of remission in UC. They are not recommended in CD except from post-operative maintenance of remission.
6. Thiopurines include AZA and 6-MP and are steroid sparing agents. They are effective in maintaining disease remission in patients with CD and UC as well as post-surgical remission in CD. The use of TPMT activity and 6-TGN level measurements helps avoiding nearly a quarter of episodes of myelosuppression as well as to monitor non-compliance, under-dosing, drug-resistance or refractory state.
7. An increase in mean 6-TGN blood level has been reported in patients on 6-MP or AZA co-treated with 5-ASA, with a higher rate of myelotoxicity in respect to patients treated with the thiopurine alone.
8. MTX is effective in 50%-80% of the children who fail to respond or are intolerant to thiopurines. It is particularly suitable to patients who have coexistent inflammatory arthritis.
9. In CD, anti-TNF agents are used to treat moderate to severe disease with inadequate response, or contraindication to, or intolerance to, conventional therapy including corticosteroids and immunomodulators. They are also indicated in children with active perianal fistulising disease. Therapeutic drug monitoring of IFX has improved response rates and is increasingly used in clinical practice as a tool for the management of secondary failure to IFX.
10. ADA is a fully human IgG1k monoclonal antibody, which represents a treatment option in patients who have lost response or are intolerant to IFX. ADA achieves remission rates of 45% at 1 yr in anti-TNF naïve children and is effective in nearly 2/3 of patients with IFX failure.
11. Vedolizumab is an anti-integrin therapy which inhibits the migration of intestinal T lymphocytes. The mechanism of action of Vedolizumab is restricted to the GI tract, mitigating the risks of systemic immunosuppression such as infections and malignancies. The clinical response rate for induction with vedolizumab is 50% in UC patients. Vedolizumab is approved for treatment of CD and UC in adults and there is increasing off-label use in children.
12. Thalidomide is an immunosuppressant drug used infrequently off-label in the treatment of refractory CD and UC. Induction of remission is achieved in around 50% cases and clinical response in 70%.
13. Drug therapies that interfere selectively with lymphocyte trafficking (*e.g.*, etrolizumab, ozanimod) are emerging treatment options for UC.

UC: Ulcerative colitis; IBD: Inflammatory bowel disease; ADA: Adalimumab; IFX: Infliximab; TPMT: Thiopurine methyl transferase; 5-ASA: Aminosalicylates; CD: Crohn's disease; 6-MP: 6-mercaptopurine; AZA: Azathioprine; MTX: Methotrexate; GI: Gastrointestinal.

phenotypes that require surgery, despite the use of multiple treatment escalations<sup>[53]</sup>. Once significant chronic bowel damage occurs in IBD, the chances of recovery with medical treatments alone are limited. Therefore, the ideal treatment should be offered before complications develop<sup>[53]</sup>. Step-up and top-down approaches have been debated for different risk groups of children with IBD. The management of paediatric IBD has evolved significantly over recent years with evidence-based guidelines in place to provide uniform and solid guidance in clinical practice. Nevertheless, a long-term response is only observed in less than half of the patients with CD<sup>[3,52]</sup>. Although new biologics are continuously being developed, primarily monoclonal antibodies targeting the trafficking of immune cells, we certainly are in need of more therapies with novel mechanisms of action<sup>[52]</sup>. More significant advances have been achieved in monitoring drug administration and the response to medications, in particular the clinical availability of AZA metabolites, IFX and ADA trough levels and anti-IFX antibody measurements in clinical practice (*i.e.*, TDM). This has allowed a major step forward in monitoring and targeting patients' treatments with a more personalised approach.

Despite routine use of solid clinical scores (*e.g.*, PCDAI, PUCAI) and biochemical parameters (blood-based and stool-based), we are currently still depending on invasive reassessments (*i.e.*, endoscopic

procedures) for an adequate monitoring of the disease course. One next goal on the horizon is therefore the development of reliable biomarkers to be used for prediction of prognostic outcomes in IBD. The ability to stratify individual patients' risk would allow clinicians to personalise treatment from disease presentation, tailoring more potent drugs (possibly in combination) to patients with a high risk of severe disease, using more standard options for patients who are destined for a milder disease course<sup>[53]</sup>. This individualised approach requires reliable prognostic biomarkers and hence major efforts are being made in the development of such markers. Risk stratification models would allow clinicians to treat patients effectively before complications arise, and to optimise majorly the management of patients with IBD as improve the cost effectiveness of their care<sup>[53]</sup>.

## CONCLUSION

Our narrative review summarises some of the recent advances in treating children with IBD (Table 2). Whilst the mechanisms underlying this condition are yet to be fully understood, both old and new generation treatments can still only target known pathways of what is a very complex pathogenesis. A significant proportion of children with IBD does not respond to currently available treatments, either at diagnosis

or during disease course, therefore new treatment options are urgently needed. Major advances have been achieved in monitoring the individual metabolism, toxicity and response to treatments in IBD. Amongst the priorities in current research is the development of reliable prognostic biomarkers, an essential step towards the personalised treatment of patients with IBD.

## REFERENCES

- Meijer B, Mulder CJ, Peters GJ, van Bodegraven AA, de Boer NK. Efficacy of thioguanine treatment in inflammatory bowel disease: A systematic review. *World J Gastroenterol* 2016; **22**: 9012-9021 [PMID: 27833392 DOI: 10.3748/wjg.v22.i40.9012]
- Kolho KL, Ainamo A. Progress in the treatment and outcome of pediatric inflammatory bowel disease patients. *Expert Rev Clin Immunol* 2016; **12**: 1337-1345 [PMID: 27322874 DOI: 10.1080/1744666X.2016.1201422]
- Kammermeier J, Morris MA, Garrick V, Furman M, Rodrigues A, Russell RK; BSPGHAN IBD Working Group. Management of Crohn's disease. *Arch Dis Child* 2016; **101**: 475-480 [PMID: 26553907 DOI: 10.1136/archdischild-2014-307217]
- Lim WC, Wang Y, MacDonald JK, Hanauer S. Aminosaliclates for induction of remission or response in Crohn's disease. *Cochrane Database Syst Rev* 2016; **7**: CD008870 [PMID: 27372735 DOI: 10.1002/14651858.CD008870.pub2]
- Yang C, Singh P, Singh H, Le ML, El-Matary W. Systematic review: thalidomide and thalidomide analogues for treatment of inflammatory bowel disease. *Aliment Pharmacol Ther* 2015; **41**: 1079-1093 [PMID: 25858208 DOI: 10.1111/apt.13181]
- Corica D, Romano C. Biological Therapy in Pediatric Inflammatory Bowel Disease: A Systematic Review. *J Clin Gastroenterol* 2017; **51**: 100-110 [PMID: 27636407 DOI: 10.1097/MCG.0000000000000696]
- Sharma S, Eckert D, Hyams JS, Mensing S, Thakkar RB, Robinson AM, Rosh JR, Ruemmele FM, Awni WM. Pharmacokinetics and exposure-efficacy relationship of adalimumab in pediatric patients with moderate to severe Crohn's disease: results from a randomized, multicenter, phase-3 study. *Inflamm Bowel Dis* 2015; **21**: 783-792 [PMID: 25723614 DOI: 10.1097/MIB.0000000000000327]
- Gordon M, Taylor K, Akobeng AK, Thomas AG. Azathioprine and 6-mercaptopurine for maintenance of surgically-induced remission in Crohn's disease. *Cochrane Database Syst Rev* 2014; **(8)**: CD010233 [PMID: 25081347 DOI: 10.1002/14651858.CD010233.pub2]
- Sherlock ME, MacDonald JK, Griffiths AM, Steinhart AH, Seow CH. Oral budesonide for induction of remission in ulcerative colitis. *Cochrane Database Syst Rev* 2015; **(10)**: CD007698 [PMID: 26497719 DOI: 10.1002/14651858.CD007698.pub3]
- Bousvaros A. Thalidomide Treatment of Pediatric Ulcerative Colitis: A New Use for an Old Drug. *Inflamm Bowel Dis* 2015; **21**: 1750-1751 [PMID: 26199988 DOI: 10.1097/MIB.0000000000000430]
- Tew GW, Hackney JA, Gibbons D, Lamb CA, Luca D, Egen JG, Diehl L, Eastham Anderson J, Vermeire S, Mansfield JC, Feagan BG, Panes J, Baumgart DC, Schreiber S, Dotan I, Sandborn WJ, Kirby JA, Irving PM, De Hertogh G, Van Assche GA, Rutgeerts P, O'Byrne S, Hayday A, Keir ME. Association Between Response to Etrolizumab and Expression of Integrin  $\alpha$ E and Granzyme A in Colon Biopsies of Patients With Ulcerative Colitis. *Gastroenterology* 2016; **150**: 477-487.e9 [PMID: 26522261 DOI: 10.1053/j.gastro.2015.10.041]
- Gasparetto M, Guariso G. Crohn's disease and growth deficiency in children and adolescents. *World J Gastroenterol* 2014; **20**: 13219-13233 [PMID: 25309059 DOI: 10.3748/wjg.v20.i37.13219]
- Bartelink IH, Rademaker CM, Schobben AF, van den Anker JN. Guidelines on paediatric dosing on the basis of developmental physiology and pharmacokinetic considerations. *Clin Pharmacokinet* 2006; **45**: 1077-1097 [PMID: 17048973 DOI: 10.2165/00003088-200645110-00003]
- Vinks AA, Emoto C, Fukuda T. Modeling and simulation in pediatric drug therapy: Application of pharmacometrics to define the right dose for children. *Clin Pharmacol Ther* 2015; **98**: 298-308 [PMID: 26073179 DOI: 10.1002/cpt.169]
- Sigall-Boneh R, Pfeffer-Gik T, Segal I, Zangen T, Boaz M, Levine A. Partial enteral nutrition with a Crohn's disease exclusion diet is effective for induction of remission in children and young adults with Crohn's disease. *Inflamm Bowel Dis* 2014; **20**: 1353-1360 [PMID: 24983973 DOI: 10.1097/MIB.0000000000000110]
- Grover Z, Burgess C, Muir R, Reilly C, Lewindon PJ. Early Mucosal Healing with Exclusive Enteral Nutrition is Associated with Improved Outcomes in Newly Diagnosed Children with Luminal Crohn's disease. *J Crohns Colitis* 2016; **10**: 1159-1164 [PMID: 26980840 DOI: 10.1093/ecco-jcc/jjw075]
- Grossi V, Hyams JS. The safety of treatment options for pediatric Crohn's disease. *Expert Opin Drug Saf* 2016; **15**: 1383-1390 [PMID: 27367297 DOI: 10.1080/14740338.2016.1203418]
- Nuti F, Civitelli F, Bloise S, Oliva S, Aloï M, Latorre G, Viola F, Cucchiara S. Prospective Evaluation of the Achievement of Mucosal Healing with Anti-TNF- $\alpha$  Therapy in a Paediatric Crohn's Disease Cohort. *J Crohns Colitis* 2016; **10**: 5-12 [PMID: 26188350 DOI: 10.1093/ecco-jcc/jjv126]
- Pigneur B, Sokol H. Fecal microbiota transplantation in inflammatory bowel disease: the quest for the holy grail. *Mucosal Immunol* 2016; **9**: 1360-1365 [PMID: 27461176 DOI: 10.1038/mi.2016.67]
- Moayyedi P, Surette MG, Kim PT, Libertucci J, Wolfe M, Onischi C, Armstrong D, Marshall JK, Kassam Z, Reinisch W, Lee CH. Fecal Microbiota Transplantation Induces Remission in Patients With Active Ulcerative Colitis in a Randomized Controlled Trial. *Gastroenterology* 2015; **149**: 102-109.e6 [PMID: 25857665 DOI: 10.1053/j.gastro.2015.04.001]
- Ruemmele FM, Veres G, Kolho KL, Griffiths A, Levine A, Escher JC, Amil Dias J, Barabino A, Braegger CP, Bronsky J, Buderus S, Martin-de-Carpi J, De Ridder L, Fagerberg UL, Hugot JP, Kierkus J, Kolacek S, Koletzko S, Lionetti P, Miele E, Navas López VM, Paerregaard A, Russell RK, Serban DE, Shaoul R, Van Rheenen P, Veereman G, Weiss B, Wilson D, Dignass A, Eliakim A, Winter H, Turner D. ECCO/ESPGHAN. Consensus guidelines of ECCO/ESPGHAN on the medical management of pediatric Crohn's disease. *J Crohns Colitis* 2014; **8**: 1179-1207 [PMID: 24909831]
- Rossen NG, Fuentes S, van der Spek MJ, Tijssen JG, Hartman JH, Duflou A, Löwenberg M, van den Brink GR, Mathus-Vliegen EM, de Vos WM, Zoetendal EG, D'Haens GR, Ponsioen CY. Findings From a Randomized Controlled Trial of Fecal Transplantation for Patients With Ulcerative Colitis. *Gastroenterology* 2015; **149**: 110-118.e4 [PMID: 25836986 DOI: 10.1053/j.gastro.2015.03.045]
- Stocco G, Cuzzoni E, De Iudicibus S, Favretto D, Malusà N, Martelossi S, Pozzi E, Lionetti P, Ventura A, Decorti G. Thiopurine metabolites variations during co-treatment with aminosaliclates for inflammatory bowel disease: effect of N-acetyl transferase polymorphisms. *World J Gastroenterol* 2015; **21**: 3571-3578 [PMID: 25834322 DOI: 10.3748/wjg.v21.i12.3571]
- Ford AC, Bernstein CN, Khan KJ, Abreu MT, Marshall JK, Talley NJ, Moayyedi P. Glucocorticosteroid therapy in inflammatory bowel disease: systematic review and meta-analysis. *Am J Gastroenterol* 2011; **106**: 590-599; quiz 600 [PMID: 21407179 DOI: 10.1038/ajg.2011.70]
- Roberts RL, Barclay ML. Update on thiopurine pharmacogenetics in inflammatory bowel disease. *Pharmacogenomics* 2015; **16**: 891-903 [PMID: 26067482 DOI: 10.2217/pgs.15.29]
- Chande N, Patton PH, Tsoulis DJ, Thomas BS, MacDonald JK. Azathioprine or 6-mercaptopurine for maintenance of remission in Crohn's disease. *Cochrane Database Syst Rev* 2015; **(10)**:

- CD000067 [PMID: 26517527 DOI: 10.1002/14651858.CD000067.pub3]
- 27 **Benmassaoud A**, Xie X, AlYafi M, Theoret Y, Bitton A, Afif W, Bessissow T. Thiopurines in the Management of Crohn's Disease: Safety and Efficacy Profile in Patients with Normal TPMT Activity-A Retrospective Study. *Can J Gastroenterol Hepatol* 2016; **2016**: 1034834 [PMID: 27446822 DOI: 10.1155/2016/1034834]
  - 28 **McDonald JW**, Wang Y, Tsoulis DJ, MacDonald JK, Feagan BG. Methotrexate for induction of remission in refractory Crohn's disease. *Cochrane Database Syst Rev* 2014; **(8)**: CD003459 [PMID: 25099640 DOI: 10.1002/14651858.CD003459.pub4]
  - 29 **Patel V**, Wang Y, MacDonald JK, McDonald JW, Chande N. Methotrexate for maintenance of remission in Crohn's disease. *Cochrane Database Syst Rev* 2014; **(8)**: CD006884 [PMID: 25157445 DOI: 10.1002/14651858.CD006884.pub3]
  - 30 **Feagan B**. A multicentre trial of methotrexate (MTX) for chronically active Crohn's disease (CD). *Gut* 1994; **35** Suppl 4: A121
  - 31 **Oren R**, Moshkowitz M, Odes S, Becker S, Keter D, Pomeranz I, Shirin H, Reissfeld I, Broide E, Lavy A, Fich A, Eliakim R, Patz J, Villa Y, Arber N, Gilat T. Methotrexate in chronic active Crohn's disease: a double-blind, randomized, Israeli multicenter trial. *Am J Gastroenterol* 1997; **92**: 2203-2209 [PMID: 9399753]
  - 32 **Arora S**, Katkov W, Cooley J, Kemp JA, Johnston DE, Schapiro RH, Podolsky D. Methotrexate in Crohn's disease: results of a randomized, double-blind, placebo-controlled trial. *Hepatogastroenterology* 1999; **46**: 1724-1729 [PMID: 10430331]
  - 33 **Fumery M**, Jacob A, Sarter H, Michaud L, Spyckerelle C, Mouterde O, Savoye G, Colombel JF, Peyrin-Biroulet L, Gower-Rousseau C, Turck D; EPIMAD Group. Efficacy and safety of adalimumab after infliximab failure in pediatric Crohn disease. *J Pediatr Gastroenterol Nutr* 2015; **60**: 744-748 [PMID: 26000887 DOI: 10.1097/MPG.0000000000000713]
  - 34 **Dziechciarz P**, Horvath A, Kierkus J. Efficacy and Safety of Adalimumab for Paediatric Crohn's Disease: A Systematic Review. *J Crohns Colitis* 2016; **10**: 1237-1244 [PMID: 26995184 DOI: 10.1093/ecco-jcc/jjv077]
  - 35 **Hyams J**, Crandall W, Kugathasan S, Griffiths A, Olson A, Johanns J, Liu G, Travers S, Heuschkel R, Markowitz J, Cohen S, Winter H, Veereman-Wauters G, Ferry G, Baldassano R; REACH Study Group. Induction and maintenance infliximab therapy for the treatment of moderate-to-severe Crohn's disease in children. *Gastroenterology* 2007; **132**: 863-873; quiz 1165-1166 [PMID: 17324398 DOI: 10.1053/j.gastro.2006.12.003]
  - 36 **Ruemmele FM**, Lachaux A, Cézard JP, Morali A, Maurage C, Giniès JL, Viola S, Goulet O, Lamireau T, Scaillon M, Breton A, Sarles J; Groupe Francophone d'Hépatologie, Gastroentérologie et Nutrition Pédiatrique. Efficacy of infliximab in pediatric Crohn's disease: a randomized multicenter open-label trial comparing scheduled to on demand maintenance therapy. *Inflamm Bowel Dis* 2009; **15**: 388-394 [PMID: 19023899 DOI: 10.1002/ibd.20788]
  - 37 **Papamichael K**, Van Stappen T, Jairath V, Gecse K, Khanna R, D'Haens G, Vermeire S, Gils A, Feagan BG, Levesque BG, Vande Castele N. Review article: pharmacological aspects of anti-TNF biosimilars in inflammatory bowel diseases. *Aliment Pharmacol Ther* 2015; **42**: 1158-1169 [PMID: 26365281 DOI: 10.1111/apt.13402]
  - 38 **Frymoyer A**, Piester TL, Park KT. Infliximab Dosing Strategies and Predicted Trough Exposure in Children With Crohn Disease. *J Pediatr Gastroenterol Nutr* 2016; **62**: 723-727 [PMID: 26890885 DOI: 10.1097/MPG.0000000000001123]
  - 39 **Conrad MA**, Stein RE, Maxwell EC, Albenberg L, Baldassano RN, Dawany N, Grossman AB, Mamula P, Piccoli DA, Kelsen JR. Vedolizumab Therapy in Severe Pediatric Inflammatory Bowel Disease. *Inflamm Bowel Dis* 2016; **22**: 2425-2431 [PMID: 27598742 DOI: 10.1097/MIB.0000000000000918]
  - 40 **Cozijnsen MA**, Escher JC, Griffiths A, Turner D, de Ridder L. Benefits and Risks of Combining Anti-tumor Necrosis Factor with Immunomodulator Therapy in Pediatric Inflammatory Bowel Disease. *Inflamm Bowel Dis* 2015; **21**: 951-961 [PMID: 25723615 DOI: 10.1097/MIB.0000000000000245]
  - 41 **de Ridder L**, Turner D, Wilson DC, Koletzko S, Martin-de-Carpi J, Fagerberg UL, Spray C, Sladek M, Shaoul R, Roma-Giannikou E, Bronsky J, Serban DE, Cucchiara S, Veres G, Ruemmele FM, Hojsak I, Kolho KL, Davies IH, Aloï M, Lionetti P, Veereman-Wauters G, Braegger CP, Trindade E, Wewer AV, Hauer A, Levine A; Porto IBD Working Group of ESPGHAN. Malignancy and Mortality in Pediatric Patients with Inflammatory Bowel Disease: A Multinational Study from the Porto Pediatric IBD Group. *Inflamm Bowel Dis* 2014; **20**: 291-300 [PMID: 24374875 DOI: 10.1097/01.MIB.0000439066.69340.3c]
  - 42 **Hyams JS**, Griffiths A, Markowitz J, Baldassano RN, Faubion WA Jr, Colletti RB, Dubinsky M, Kierkus J, Rosh J, Wang Y, Huang B, Bittle B, Marshall M, Lazar A. Safety and efficacy of adalimumab for moderate to severe Crohn's disease in children. *Gastroenterology* 2012; **143**: 365-374.e2 [PMID: 22562021 DOI: 10.1053/j.gastro.2012.04.046]
  - 43 **Patel AS**, Suarez LD, Rosh JR. Adalimumab in pediatric Crohn's disease. *Immunotherapy* 2016; **8**: 127-133 [PMID: 26787222 DOI: 10.2217/imt.15.114]
  - 44 **Singh N**, Rabizadeh S, Jossen J, Pittman N, Check M, Hashemi G, Phan BL, Hyams JS, Dubinsky MC. Multi-Center Experience of Vedolizumab Effectiveness in Pediatric Inflammatory Bowel Disease. *Inflamm Bowel Dis* 2016; **22**: 2121-2126 [PMID: 27542130 DOI: 10.1097/MIB.0000000000000865]
  - 45 **Sands B**, Dubinsky MC, Vermeire S. Effects of increased vedolizumab dosing frequency on disease activity in ulcerative colitis. *United Eur Gastro J* 2014; **2** suppl 1: A1-A131
  - 46 **Sieczkowska J**, Jarzębicka D, Banaszkiewicz A, Plocek A, Gawronska A, Toporowska-Kowalska E, Oracz G, Meglicka M, Kierkus J. Switching Between Infliximab Originator and Biosimilar in Paediatric Patients with Inflammatory Bowel Disease. Preliminary Observations. *J Crohns Colitis* 2016; **10**: 127-132 [PMID: 26721942 DOI: 10.1093/ecco-jcc/jjv233]
  - 47 **Bramuzzo M**, Ventura A, Martelossi S, Lazzarini M. Thalidomide for inflammatory bowel disease: Systematic review. *Medicine (Baltimore)* 2016; **95**: e4239 [PMID: 27472695 DOI: 10.1097/MD.00000000000004239]
  - 48 **Liew WK**, Pacak CA, Visyak N, Darras BT, Bousvaros A, Kang PB. Longitudinal Patterns of Thalidomide Neuropathy in Children and Adolescents. *J Pediatr* 2016; **178**: 227-232 [PMID: 27567409 DOI: 10.1016/j.jpeds.2016.07.040]
  - 49 **Lazzarini M**, Martelossi S, Magazzù G, Pellegrino S, Lucanto MC, Barabino A, Calvi A, Arrigo S, Lionetti P, Lorusso M, Mangiantini F, Fontana M, Zuin G, Palla G, Maggiore G, Bramuzzo M, Pellegrin MC, Maschio M, Villanacci V, Manenti S, Decorti G, De Iudicibus S, Paparazzo R, Montico M, Ventura A. Effect of thalidomide on clinical remission in children and adolescents with refractory Crohn disease: a randomized clinical trial. *JAMA* 2013; **310**: 2164-2173 [PMID: 24281461 DOI: 10.1001/jama.2013.280777]
  - 50 **Lazzarini M**, Martelossi S, Magazzù G, Pellegrino S, Lucanto MC, Barabino A, Calvi A, Arrigo S, Lionetti P, Lorusso M, Mangiantini F, Fontana M, Zuin G, Palla G, Maggiore G, Bramuzzo M, Pellegrin MC, Maschio M, Villanacci V, Manenti S, Decorti G, De Iudicibus S, Paparazzo R, Montico M, Ventura A. Effect of Thalidomide on Clinical Remission in Children and Adolescents with Ulcerative Colitis Refractory to Other Immunosuppressives: Pilot Randomized Clinical Trial. *Inflamm Bowel Dis* 2015; **21**: 1739-1749 [PMID: 26185909 DOI: 10.1097/MIB.0000000000000437]
  - 51 **Sandborn WJ**, Feagan BG, Wolf DC, D'Haens G, Vermeire S, Hanauer SB, Ghosh S, Smith H, Cravets M, Frohna PA, Aranda R, Gujrathi S, Olson A; TOUCHSTONE Study Group. Ozanimod Induction and Maintenance Treatment for Ulcerative Colitis. *N Engl J Med* 2016; **374**: 1754-1762 [PMID: 27144850 DOI: 10.1056/NEJMoa1513248]
  - 52 **Allez M**, Skolnick BE, Wisniewska-Jarosinska M, Petryka R, Overgaard RV. Anti-NKG2D monoclonal antibody (NNC0142-0002) in active Crohn's disease: a randomised

controlled trial. *Gut* 2016; Epub ahead of print [PMID: 27489241 DOI: 10.1136/gutjnl-2016-311824]

- 53 **Siegel CA**, Horton H, Siegel LS, Thompson KD, Mackenzie T, Stewart SK, Rice PW, Stempak JM, Dezfoli S, Haritunians T, Levy A, Baek M, Milgrom R, Dulai PS, Targan SR, Silverberg

MS, Dubinsky MC, McGovern DP. A validated web-based tool to display individualised Crohn's disease predicted outcomes based on clinical, serologic and genetic variables. *Aliment Pharmacol Ther* 2016; **43**: 262-271 [PMID: 26567467 DOI: 10.1111/apt.13460]

**P- Reviewer:** Matowicka-Karna J, Tambuwala M, Zhang MZ

**S- Editor:** Qi Y **L- Editor:** A **E- Editor:** Zhang FF





## Influence of gut microbiota on neuropsychiatric disorders

María Carmen Cenit, Yolanda Sanz, Pilar Codoñer-Franch

María Carmen Cenit, Yolanda Sanz, Microbial Ecology, Nutrition and Health Research Group, Institute of Agrochemistry and Food Technology, National Research Council (IATA-CSIC), Paterna, 46980 Valencia, Spain

Pilar Codoñer-Franch, Department of Pediatrics, Dr. Peset University Hospital, 46017 Valencia, Spain

María Carmen Cenit, Pilar Codoñer-Franch, Department of Pediatrics, Obstetrics and Gynecology, University of Valencia, 46010 Valencia, Spain

**Author contributions:** Cenit MC wrote the first draft of the manuscript; Sanz Y and Codoñer-Franch P have contributed substantially to the writing and revising of the manuscript; Codoñer-Franch P designed the aim of the editorial; all the authors have made substantial intellectual contributions, take responsibility to the paper and give final approval of the version to be submitted.

**Supported by** Spanish Ministry of Economy and Competitiveness (MINECO), No. AGL2014-52101-P; A Sara Borrell postdoctoral fellowship from the Instituto de Salud Carlos III at the Spanish Ministry of Health (Spain), No. CD14/00237 (Cenit MC).

**Conflict-of-interest statement:** All the authors declare no conflict of interest related to this publication.

**Open-Access:** This article is an open-access article which was selected by an in-house editor and fully peer-reviewed by external reviewers. It is distributed in accordance with the Creative Commons Attribution Non Commercial (CC BY-NC 4.0) license, which permits others to distribute, remix, adapt, build upon this work non-commercially, and license their derivative works on different terms, provided the original work is properly cited and the use is non-commercial. See: <http://creativecommons.org/licenses/by-nc/4.0/>

**Manuscript source:** Invited manuscript

**Correspondence to:** Pilar Codoñer-Franch, MD, PhD, Department of Pediatrics, Dr. Peset University Hospital, Avenida Gaspar Aguiar 90, Valencia 46017, Spain. [pilar.codoner@uv.es](mailto:pilar.codoner@uv.es)  
Telephone: +34-963-864170  
Fax: +34-963-864815

Received: February 8, 2017

Peer-review started: February 9, 2017

First decision: April 17, 2017

Revised: May 8, 2017

Accepted: July 4, 2017

Article in press: July 4, 2017

Published online: August 14, 2017

### Abstract

The last decade has witnessed a growing appreciation of the fundamental role played by an early assembly of a diverse and balanced gut microbiota and its subsequent maintenance for future health of the host. Gut microbiota is currently viewed as a key regulator of a fluent bidirectional dialogue between the gut and the brain (gut-brain axis). A number of preclinical studies have suggested that the microbiota and its genome (microbiome) may play a key role in neurodevelopmental and neurodegenerative disorders. Furthermore, alterations in the gut microbiota composition in humans have also been linked to a variety of neuropsychiatric conditions, including depression, autism and Parkinson's disease. However, it is not yet clear whether these changes in the microbiome are causally related to such diseases or are secondary effects thereof. In this respect, recent studies in animals have indicated that gut microbiota transplantation can transfer a behavioral phenotype, suggesting that the gut microbiota may be a modifiable factor modulating the development or pathogenesis of neuropsychiatric conditions. Further studies are warranted to establish whether or not the findings of preclinical animal experiments can be generalized to humans. Moreover, although different communication routes between the microbiota and brain have been identified, further studies must elucidate all the underlying mechanisms involved. Such research is expected to contribute to the design of strategies to modulate the gut microbiota and its functions with a view to improving mental health, and thus provide opportunities to improve the management of psychiatric diseases. Here, we review

the evidence supporting a role of the gut microbiota in neuropsychiatric disorders and the state of the art regarding the mechanisms underlying its contribution to mental illness and health. We also consider the stages of life where the gut microbiota is more susceptible to the effects of environmental stressors, and the possible microbiota-targeted intervention strategies that could improve health status and prevent psychiatric disorders in the near future.

**Key words:** Microbiota; Microbiome; Dysbiosis; Brain-gut axis; Mental health; Psychiatric conditions

© **The Author(s) 2017.** Published by Baishideng Publishing Group Inc. All rights reserved.

**Core tip:** The gut microbiota has been revealed as an additional regulator of the gut-brain axis, which may be involved in many neurodevelopmental and neurodegenerative disorders. The modulation of this axis is currently being explored, targeting the gut microbiota in endeavors to improve mental health, especially in early and late life. So far, most of our knowledge is based on animal trials, in which interventions with pro and prebiotics have shown promising results regarding efficacy. Nevertheless, we require further understanding of how the microbiota regulates gut-brain communication and function in order to establish the rationale behind microbiota-based interventions.

Cenit MC, Sanz Y, Codoñer-Franch P. Influence of gut microbiota on neuropsychiatric disorders. *World J Gastroenterol* 2017; 23(30): 5486-5498 Available from: URL: <http://www.wjgnet.com/1007-9327/full/v23/i30/5486.htm> DOI: <http://dx.doi.org/10.3748/wjg.v23.i30.5486>

## INTRODUCTION

Research into the influence of human genetics on numerous conditions, including neuropsychiatric disorders, has been underway for many years; however, the etiology of most of these conditions has yet to be unraveled. As in other multifactorial conditions, there is considerable discordance in the development of neuropsychiatric disorders between monozygotic twins, indicating that non-genetic factors are also involved<sup>[1,2]</sup>. Nowadays we know that both the human genome and the genome of the gut microbiota (microbiome) are essential for maintaining health, since the latter also plays a crucial role in regulating important aspects of host physiology, including brain development and function<sup>[3,4]</sup>. Indeed, different studies have reported that gut microbiota is able to shape brain physiology and thus behavior through the gut-microbiota-brain axis and have suggested gut microbiota as a key trigger factor in the development of many neuropsychiatric conditions<sup>[5]</sup>.

Most of the neuropsychiatric disorders are considered as multifactorial disorders prompted by certain environmental factors in genetically susceptible individuals. However, there is a need of further work to elucidate the exact complex gene-environment interactions and gut microbiota alterations that precede the onset of the different neuropsychiatric diseases and their manifestations in order to decipher the etiology of the neuropsychiatric disorders.

It is noteworthy that the microbiota is more “medically” accessible and modifiable than the human genome. This fact provides a promising opportunity for preventing or treating neuropsychiatric conditions<sup>[6]</sup>. In this respect, studies in animal models, where the intestinal microbiota can easily be manipulated, have shed light on how the microbiota may be involved in the development of certain mental diseases. In fact, different communication routes between the microbiota and brain have already been identified<sup>[7]</sup> although further studies are required to elucidate the underlying mechanisms. Various studies also indicate that the activity of the gut microbiota can modify the host epigenome impacting on gene expression<sup>[8]</sup>; furthermore, epigenetic mechanisms are involved in neurogenesis, neuronal plasticity, learning and memory, and in disorders such as depression, addiction, schizophrenia and cognitive dysfunction<sup>[3]</sup>. Consequently, it has been suggested that gut microbiota may be involved in the pathogenesis and risk of developing neuropsychiatric disorders through epigenetic modifications, which are highly dynamic and reversible<sup>[3]</sup>. Thus, it is tempting to speculate that modulating the microbiota and its metabolic products will enable us to modulate the epigenome and, thereby, prevent or treat mental illness. In this respect, metabolites produced by the microbiota from fiber fermentation are known to inhibit histone deacetylases (HDACs) and reduce inflammation through epigenetic modifications<sup>[9]</sup>.

Currently it is well accepted that our gut microbiota is critical for brain processes such as myelination, neurogenesis and microglial activation and can effectively modulate behavior and influence psychological processes such as mood and cognition<sup>[10]</sup>. Indeed, very recently gut microbiota have been shown essential for the maintenance of microglia in a healthy functional state<sup>[11]</sup>, which is necessary for the prevention of neurodevelopmental and neurodegenerative disorders<sup>[12]</sup>.

The early assembly of a well-balanced microbiota composition and its subsequent maintenance is considered crucial for human health as perturbations negatively impact health and increase host susceptibility to a wide variety of diseases, including behavioral and neuropsychiatric disorders<sup>[3,4]</sup>. In this respect, three critical time windows have been proposed including infancy, adolescence and ageing, when the gut microbiota is more vulnerable to external influence<sup>[13]</sup>. Therefore, strategies aiming to target the

**Table 1** Preclinical evidences of the role of gut microbiota on behavior

Germ-free (GF) mice have shown impaired social behavior <sup>[39]</sup>
GF mice have displayed exaggerated stress response <sup>[21]</sup> and differences in anxiety-like behavior <sup>[22,23]</sup>
GF mice have showed crucial changes in multiple neurotransmitters and their receptors in different brain regions <sup>[23]</sup>
GF animals have exhibited an impaired neurogenesis <sup>[25]</sup> and structural and functional changes in the amygdala <sup>[26]</sup>
GF mice have shown prefrontal cortical hypermyelination <sup>[27]</sup>
Microglial function impaired in GF animals is rescued by the oral treatment with short chain fatty acids <sup>[11]</sup>
Gut microbiota has been shown to modulate brain-derived neurotrophic factor, oxytocin and vasopressin brain levels <sup>[20]</sup>
Different probiotic preparations for administration to rats and mice have shown to achieve a reduction in anxiety-like and depressive-like behaviors <sup>[6,58]</sup>

gut microbiota might have a greater impact at those stages of life, *i.e.*, newborn, adolescence and elderly populations.

Many factors, including human genetics, influence the gut microbiota composition; therefore the microbiota constitutes a highly dynamic ecosystem, with high inter-individual variability<sup>[14,15]</sup> and this indeed hampers the understanding of the role of gut microbiota in the etiology and progress of neuropsychiatric diseases.

Nowadays, each adult individual is believed to harbor a unique gut microbiota composition, as personal as a fingerprint, and certain early life events may be important contributors to the individual's microbiota, including mode of delivery, type of feeding, medication, stress and infections<sup>[15]</sup>. The critical gut microbiota developmental period occurs in parallel to growth, maturation and sprouting of neurons in the young brain. In fact, childhood and adolescence represent the most dynamic and vulnerable periods for both gut microbiota composition and neuronal development<sup>[16]</sup>. Furthermore, although the symbiotic link between the host and the microbiota seems to be established early in life, the gut microbiota composition may still experience changes in adulthood despite its greater resilience to the effect of detrimental environmental factors. Likewise, it is also well recognized that ageing is associated with reduced microbial diversity and that healthy ageing correlates with a diverse microbiota<sup>[17]</sup>. Furthermore, research shows that as we age there is a decline in microbiota complexity parallel to a decrease in neuronal complexity and, altogether, those changes may lead to an increased risk of neurodegenerative disorders<sup>[18]</sup>. Nowadays, it is well recognized that the onset of most of the neuropsychiatric disease really often is close to a period where the gut microbiota is more unstable and, therefore, at risk of suffering microbiota alterations. Despite these findings, there is currently a need for longitudinal studies in humans to assess the impact of the gut microbiota dynamics on the maintenance or decline of neurocognitive function and to understand to what extent results in animal models can be generalized to humans<sup>[19]</sup>.

In this review, first we summarize the current evidence for a role of the gut microbiota in brain development and function, and also summarize the state of the art on the different mechanisms involved.

Thereafter, we provide an update on research into specific neuropsychiatric disorders. We also refer to the different stages of gut microbiota development and maturation, identifying the periods where the gut microbiota is more unstable and, therefore, at greater risk of suffering microbiota alterations due to exposure to stressors. Lastly, we briefly highlight different microbiome intervention strategies that might be implemented to improve the management of psychiatric diseases.

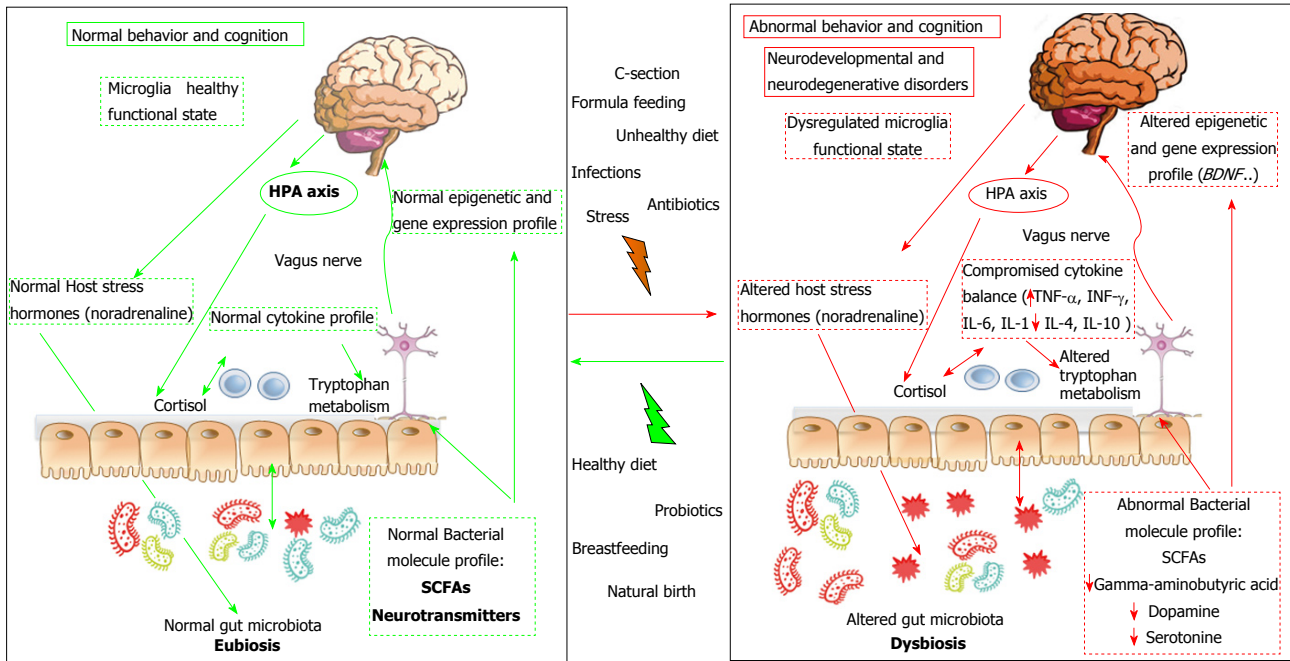
## MICROBIOTA, BRAIN DEVELOPMENT, FUNCTION AND BEHAVIOR

To investigate the role of the gut microbiota in the gut-brain axis, numerous approaches have been taken using animal models, including the study of microbiota deficient animals, known as germ-free (GF) mice, and of animals treated with antibiotics or with specific bacterial species. Such studies have provided new insights into how the microbiota is involved in regulating brain development and function (Table 1)<sup>[20,21]</sup>.

Recently, different studies using GF mice have demonstrated that animals completely lacking microbiota have impaired social behavior, as well as other types of behaviors such as anxiety and stress response<sup>[22-24]</sup>. Furthermore, it has been observed that certain behaviors induced by the absence of gut microbiota correlate with neurochemical changes in the brain<sup>[24]</sup>. Said studies have also shown crucial changes in multiple neurotransmitters and their receptors in different brain regions of GF mice. Moreover, the ability to transfer behavioral traits using fecal microbiota transplantation has also been demonstrated, suggesting that some microbiota changes could be rather a cause than a consequence of behavioral alterations<sup>[25]</sup>.

Recent data obtained using GF animals have shown that neurogenesis, a process that plays a critical role in modulating learning and memory, is also regulated by the microbiome<sup>[26]</sup>. Furthermore, the gut microbiota is reported to modulate structural and functional changes in the amygdala, a critical brain area for social and fear-related behaviors, which are associated with a variety of neuropsychiatric disorders<sup>[27]</sup>.

Another aspect of neurodevelopment shown to be critically regulated by the microbiome is prefrontal cortical myelination<sup>[28]</sup>. A recent study also showed that depletion of the gut microbiota as of early adolescence



**Figure 1** Schematic representation of the mechanisms involved in the relationship between microbiota and brain development and function: Cytokine balance and microglia activation (immune pathway), cortisol (endocrine pathway) and vagus and enteric nervous system (neural pathway). The axis plays an important role in homeostasis and has been linked to several disorders. Altered gut microbiota composition enhances the risk of neurodevelopmental and neurodegenerative disorders possibly from microbiota-derived products such as small chain fatty acids and neurotransmitters. HPA: Hypothalamic-pituitary-adrenal.

in mice alters their behavior and significantly reduces brain-derived neurotrophic factor (BDNF), oxytocin and vasopressin expression in the adult brain<sup>[21]</sup>.

Very recently it has been demonstrated that the maturation and activation of microglia, the macrophages of the brain crucial for maintaining brain tissue homeostasis, are also regulated by the gut microbiota<sup>[11]</sup>. The same study demonstrated that treatment with microbial-produced short-chain fatty acids (SCFAs) could rescue microglial function impaired in GF animals<sup>[11]</sup>. In addition, various studies have shown that probiotic administration to healthy rats and mice can alter behavior, achieving a reduction in anxiety-like and depressive-like behaviors and thus highlighting the beneficial effects of probiotics on stress-related behaviors<sup>[6]</sup>. All these findings indicate that probiotics may have broader therapeutic applications than previously considered, particularly in the area of anxiety and depression<sup>[6]</sup>.

## GUT MICROBIOTA MECHANISMS MODULATING BRAIN DEVELOPMENT AND FUNCTION

Recent studies have provided insights into the possible pathways and mechanisms that connect the microbiota to the brain. In fact, recent evidence largely suggests that there are several mechanisms by which microbiota may modulate brain development, function and behavior including immune (cytokines), endocrine (cortisol) and neural (vagus and enteric nervous system) pathways (Figure 1). Likewise, different mechanism

have been identified by which also brain can influence the gut microbiota composition<sup>[7]</sup>. Results of animal studies show that stress and emotions cause the brain to influence the microbial composition of the gut through the release of hormones or neurotransmitters, which influence gut physiology and alter the habitat of the microbiota, resulting in preferential growth of certain communities. Indeed, host stress hormones such as noradrenaline might influence bacterial gene expression or signaling between bacteria, and this might change the microbial composition and activity of the microbiota. In addition, the microbiota has a substantial impact on the metabolomics profile of the host. It is important to highlight that a large array of crucial molecules with neuroactive functions is produced by microbes<sup>[7]</sup>. Nowadays it is clear that certain bacteria are strain-specifically able to produce different essential neurotransmitters and specific neuromodulators. Indeed, several neurotransmitters such as gamma-aminobutyric acid (GABA), serotonin, catecholamines and acetylcholine are produced by bacteria, some of which are inhabitants of the human gut. Indeed, researchers report that *Lactobacillus* spp. and *Bifidobacterium* spp. produce GABA<sup>[29]</sup>; *Escherichia* spp., *Bacillus* spp. and *Saccharomyces* spp. produce noradrenalin; *Candida* spp., *Streptococcus* spp., *Escherichia* spp. and *Enterococcus* spp. produce serotonin; *Bacillus* spp. produce dopamine; and *Lactobacillus* spp. produce acetylcholine<sup>[6]</sup>. Neurotransmitters secreted from bacteria in the intestinal lumen may induce epithelial cells to release molecules that, in turn, have the ability to modulate neural signaling within the enteric nervous system



and subsequently control brain function and behavior. Various bacterial strains have also been shown to mediate behavioral effects *via* the vagus nerve in some animal studies although vagotomy does not seem to mediate all microbiota-mediated effects on brain function and behavior<sup>[30]</sup>.

Tryptophan is an essential amino acid precursor to many biologically active molecules, including the neurotransmitter serotonin and metabolites of the kynurenine pathway. Only around 5% of systemic tryptophan is metabolized into serotonin and the rest is metabolized along the kynurenine pathway. This depends on the expression of two enzymes, indoleamine 2,3-dioxygenase, which is found in all tissues, and tryptophan 2,3-dioxygenase, which is localized within the liver. The activity of both enzymes is strongly controlled by inflammatory mediators such as cytokines and corticosteroids. The increased activation of these two enzymes could induce serotonin depletion and depressive mood. Furthermore, the downstream metabolites of the kynurenine pathway are neuroactive metabolites, which can also modulate neurotransmission. In addition, the oral ingestion of *Bifidobacterium infantis* led to increased levels of the serotonin precursor, tryptophan, in the plasma of rats, suggesting that this specific strain may be a potential antidepressant. Other studies have also demonstrated the effect of the gut microbiota on the levels of other metabolites related with tryptophan metabolism<sup>[31]</sup>.

Other important molecules, which are produced in the colon by microbial fermentation of dietary fiber, are SCFAs such as butyrate, acetate and propionate. SCFAs are known to have neuroactive properties; for instance, the administration of a high dose of propionate in rats induced a neuroinflammatory response and behavioral alterations related with neurodevelopmental disorders<sup>[32]</sup>. Propionate is also a common preservative in food products that has been demonstrated to exacerbate autism spectrum disorder symptomatology. Moreover, butyrate decreases depressive-like behavior with parallel changes in histone deacetylation and BDNF expression. SCFAs also regulate the gut immune system and this may have consequences on the central nervous system. As mentioned above, the maturation and activation of microglia is also regulated by the gut microbiota<sup>[11]</sup> and oral treatment with microbial produced SCFAs can rescue microglial function impaired in GF animals<sup>[11]</sup>. However, it is still unclear whether SCFAs produced in the gut can cross the blood-brain barrier.

## EPIGENETICS, GUT MICROBIOTA AND NEUROLOGICAL CONDITIONS

It is currently well recognized that there are many changes in gene expression not caused by variations in sequence or genotype. Those changes are rather triggered by epigenetic modifications, such as methylation, acetylation or non-coding RNAs (ncRNAs),

which modulate chromatin remodeling and the final translation of coding mRNA into proteins. Several types of epigenetic-modifying enzymes together with ncRNAs are involved in epigenetic regulation and have been demonstrated highly sensitive to environmental changes. Therefore, epigenetic modifications associated to many diseases have been recognized as possible pieces missing in the puzzle linking the human genome, environment and phenotype development<sup>[33]</sup>. Epigenetic mechanisms are currently known to be involved in neurogenesis, neuronal plasticity, learning and memory, and in disorders such as depression, addiction, schizophrenia and cognitive dysfunction<sup>[3,34]</sup>. Many of the environmental factors apparently playing a crucial role in the etiology of neuropsychiatric disorders might be related with the risk of developing the condition through epigenetic mechanisms.

Changes in histone modifications and DNA methylation have been found at the promoters of genes involved in neuropsychiatric conditions<sup>[3]</sup>. For instance, chromatin remodeling at the BDNF gene promoter has been associated with neuronal activity and stress and likely affects many more genes involved in brain function and behavior<sup>[35]</sup>. In fact, there is now a great deal of evidence for the role of epigenetic regulation in shaping brain function and behavior, even though the underlying molecular mechanisms by which epigenetics might be leading to the behavioral and biochemical alterations observed in neuropsychiatric disorders are still not well understood<sup>[36]</sup>.

Gut microbiota has been shown to impact host gene expression by modulating epigenetic processes which are highly dynamic and reversible<sup>[33]</sup>. Therefore, it is tempting to speculate that modulating the microbiota will enable us to shape our epigenome in the near future. Indeed, the methylation levels of specific genes involved in metabolism and inflammatory responses have been associated with gut microbiota profiles<sup>[37]</sup>. Furthermore, various studies have described a link between microRNAs, a group of small ncRNAs, and microbiota<sup>[38]</sup>. Histone deacetylations by HDACs are also critical in epigenomic regulation and are related with condensed chromatin and, consequently, the inhibition of the gene expression. Indeed, SCFAs have the capacity to inhibit HDACs, thus activating the gene expression of previously deacetylated genes<sup>[33]</sup>.

Aging is associated with profound epigenetic changes resulting in alterations in gene expression and also with a wide range of human disorders, including neurodegenerative diseases. Therefore, the reversibility of epigenetic changes that occur as a hallmark of aging offers exciting opportunities to treat age-related diseases<sup>[39]</sup>.

## GUT MICROBIOTA AND NEUROPSYCHIATRIC CONDITIONS

So far many evidences derived from multiple studies performed in both animal models and humans have

**Table 2** Current evidences linking gut microbiota to neuropsychiatric disorders

Autism
Increase in microbiota diversity is associated with autism <sup>[43]</sup>
Abundance of Bacteroidetes has found to be linked with severe autistic cases <sup>[43]</sup>
Increase in short chain fatty acids has been found in fecal samples from autistic children <sup>[44]</sup>
A specific strain of the species <i>Lactobacillus reuteri</i> has shown to modulate oxytocin levels and reverse autism-related behavior <sup>[41]</sup>
Schizophrenia
Dopamine, the key neurotransmitter associated with schizophrenia pathophysiology, is produced by components of the microbiota <sup>[53]</sup>
Increased gastrointestinal inflammation is associated with schizophrenia <sup>[53]</sup>
Intake of antibiotics is associated with the risk of schizophrenia <sup>[54]</sup>
Attention deficit hyperactivity disorder
The risk of developing ADHD has been suggested to be associated with many perinatal risk factors, including delivery mode, gestational age, type of feeding, maternal health and early life stressors, all of them linked to gut microbiota alterations <sup>[56]</sup>
Dietary components modulating gut microbiota may influence ADHD development or symptoms <sup>[56]</sup>
Depression
Increase in gut microbiota alpha diversity is associated with depression <sup>[59,63]</sup>
Lower numbers of Bifidobacterium and Lactobacillus have been found in individuals with depression <sup>[60]</sup>
Increases in the genus <i>Eggerthella</i> , <i>Holdemania</i> , <i>Gelria</i> , <i>Turicibacter</i> , <i>Paraprevotella</i> and <i>Anaerofilum</i> , and reductions in <i>Prevotella</i> and <i>Dialister</i> have been found in individuals with depression <sup>[61]</sup>
A negative correlation between <i>Faecalibacterium</i> spp. and severity of depressive symptoms has been reported <sup>[61]</sup>
Role of diet on depression onset is suggested (Mediterranean diet seems to protect, whereas Western diet seems to be associated with an increased risk) <sup>[64]</sup>
Different strains of <i>Lactobacillus rhamnosus</i> , <i>Lactobacillus helveticus</i> , <i>Bifidobacterium longum</i> , <i>Bifidobacterium breve</i> and <i>Bifidobacterium infantis</i> have been shown to attenuate depression and anxiety-related behavior in rodents <sup>[58]</sup>
A probiotic combination ( <i>Lactobacillus helveticus</i> R0052 and <i>Bifidobacterium longum</i> R0175) has proven effective in increasing the subject's resilience to stress in humans <sup>[57]</sup>
Parkinson's disease
Alterations in bowel function, mainly constipation, often precede the onset of motor symptoms associated with PD <sup>[76]</sup>
Reduction in the levels of Prevotellaceae has been found in PD patients <sup>[80]</sup>
Positive correlation between levels of Enterobacteriaceae and the severity of postural instability and gait difficulty was proven in PD patients <sup>[80]</sup>
Reduction in short chain fatty acids <sup>[78]</sup> and butyrate-producing bacteria ( <i>Blautia</i> , <i>Coprococcus</i> , <i>Faecalibacterium</i> spp and <i>Roseburia</i> ) <sup>[79]</sup> were found in fecal samples from PD patients
GF mice overexpressing human $\alpha$ -synuclein ( $\alpha$ Syn) display reduced microglia activation, $\alpha$ Syn aggregates and motor deficits (treatment with short chain fatty acids restored all major features of PD in GF mice) <sup>[77]</sup>
Gut microbiota transfer from PD patients into GF mice overexpressing human $\alpha$ -synuclein ( $\alpha$ Syn) enhances physical impairments whereas gut microbiota transfer from healthy human donor does not enhances those deficiencies <sup>[77]</sup>
Alzheimer's disease
Risk factors for AD such as metabolic syndrome, type 2 diabetes and obesity are associated with gut microbiota alterations <sup>[86,87]</sup>
Gut microbiota seems to be involved in the accumulation of amyloid plaques according to the results of a study using a mouse model of AD <sup>[88]</sup>

AD: Alzheimer's disease; PD: Parkinson's disease; ADHD: Attention deficit hyperactivity disorder.

strongly suggested a link between gut microbiota and development and/or manifestation of different neuropsychiatric conditions (Table 2).

### **Microbiota and impairment of social behavior (autism), schizophrenia and attention deficit hyperactivity disorder**

Studies using GF mice have demonstrated that animals completely lacking microbiota exhibit deficiencies in social behavior. In particular, John Cryan's research team examined the behavior of GF mice in the three-chamber test and observed that GF mice spent as much time with the familiar as with the novel mouse in contrast to the behavior of conventionally colonized mice, which spent more time with the novel than the familiar mouse<sup>[40]</sup>. They also observed that GF mice spent longer with an object or an empty chamber than with another mouse, which is considered abnormal behavior for a sociable animal. Research has also demonstrated that colonization of the GF mice partially normalizes these behavioral impairments<sup>[40]</sup>.

Oxytocin is well known to influence social behavior<sup>[41]</sup>

and evidence indicates that its levels are closely regulated by the gut microbiota<sup>[42]</sup>. In fact, last year Desbonnet *et al.*<sup>[21]</sup> showed that depletion of the gut microbiota as of early adolescence reduces oxytocin expression in the adult brain. Furthermore another recent study demonstrated that a single probiotic bacteria (a strain of the species *Lactobacillus reuteri*) can modulate oxytocin levels and reverse autism-related behavior, raising the possibility of influencing social behavior by targeting the gut microbiota<sup>[42]</sup>.

Autism spectrum disorder (ASD) is often associated with gastrointestinal co-morbidities and recent studies have shown changes in the gut microbiota of autistic children, including shifts in levels of Bacteroidetes and Firmicutes phyla with the abundance of Clostridium, establishing a strong link between gut microbiota and ASD<sup>[43,44]</sup>. Research also reports an increase in microbiota diversity associated with autism in children with the abundance of Bacteroidetes found to be linked with severe autistic cases<sup>[44]</sup>. Other gut commensals found to be altered in autism belong to *Bifidobacterium*, *Lactobacillus*, *Prevotella* and

*Ruminococcus* genera<sup>[44]</sup> although these associations do not necessarily imply causality. In addition, a significant increase in SCFAs in fecal samples from autistic children has been recorded, providing a further indication for a role of an altered microbiota composition or function in this neurodevelopmental disorder<sup>[45]</sup>. However, the role of SCFAs in ASD is not fully understood. For instance, administration of butyrate has been shown to improve repetitive symptoms in a murine model of ASD<sup>[46]</sup> whereas intra cerebroventricular infusions of propionic acid induces autistic-like behaviors in rats<sup>[47]</sup>, thus suggesting SCFAs play differential roles in mediating ASD behavior. Therefore, further research is warranted to delve further into the role of SCFAs in autism.

In humans, prenatal exposure to the mood stabilizer valproate is a major risk-factor for autism<sup>[48]</sup> and de Theije *et al.*<sup>[49]</sup> have shown that the autism-like behavioral changes that occur in mouse models of valproate exposure are coincident with changes in microbiota composition.

In addition, maternal obesity is associated with neurodevelopmental disorders in offspring, including autism spectrum disorder<sup>[50]</sup> and, in line with this observation, mice with induced obesity by a maternal high-fat diet (MHFD) show social behavioral deficits due to alterations in the gut microbiota<sup>[51]</sup>. Buffington *et al.*<sup>[51]</sup> recently observed that the diversity of the microbiota in MHFD offspring was reduced, showing a remarkable reduction in *Lactobacillus* spp. compared with the abundance found in the offspring of animals from mothers on a regular diet. Furthermore, it was demonstrated that treatment with a *Lactobacillus reuteri* strain not only augmented levels of oxytocin, improving social behavior, but also ameliorated synaptic dysfunction in MHFD offspring<sup>[51]</sup>.

Schizophrenia is another complex heterogeneous behavioral disorder characterized by abnormal social behavior, often associated with additional mental health problems such as anxiety disorders and major depression<sup>[52]</sup>. To date the genomic analysis of schizophrenia has been limited, with the replicated genetic findings representing just a fraction of schizophrenia heritability<sup>[53]</sup>. Furthermore, there is evidence for the important role that different environmental factors play in its development. In fact, several epigenetic mechanisms, in particular methylation of genes involved in neurotransmission, histone modifications and the action of ncRNAs, may also predispose individuals to schizophrenia. There are indications, such as the fact that dopamine, the key neurotransmitter associated with schizophrenia pathophysiology and treatment, is produced by microbes, and the increased gastrointestinal inflammation associated with schizophrenia, which strongly suggest that gut microbiota are involved in the risk of development schizophrenia or its manifestations<sup>[54]</sup>. In addition, several studies have found an association between the intake of antibiotics and an increased incidence of

psychiatric disorders such as schizophrenia, perhaps due to alterations in the microbiota<sup>[55]</sup>. However, to date there are not any published studies investigating the role of the gut microbiome in schizophrenia.

Attention deficit hyperactivity disorder (ADHD) is a neurodevelopmental disorder characterized by inappropriate levels of hyperactivity, difficulty in controlling behavior and/or attention problems. Although ADHD is currently one of the most frequently studied disorders in children and adolescents, the exact mechanisms that predispose individuals are still unknown, though both genetic and environmental factors seem to be involved<sup>[56]</sup>. Various factors associated with the risk of developing ADHD and/or linked to different ADHD manifestations have also been linked to shifts in gut microbiota composition, suggesting a link between the microbiota and the disorder. In addition, evidence from preliminary human studies suggests that dietary components modulating gut microbiota may also influence ADHD development or symptoms. Therefore, recently, after reviewing the literature, we argue<sup>[57]</sup> that genomic studies in ADHD should include studies of the gut microbiota.

### **Microbiota, stress response and depression**

Most organisms are equipped with biological machinery able to muster a defensive response to stressful stimuli. In response to stress, the hypothalamic-pituitary-adrenal (HPA) axis is activated and corticosterone releasing factor (CRF) is released from paraventricular neurons of the hypothalamus. CRF stimulates the release of adrenocorticotrophic hormone (ACTH) from the anterior pituitary, which in turn induces the synthesis and release of glucocorticoids from the adrenal cortex: cortisol in humans and corticosterone in animals. Studies in GF mice have revealed that the microbiota influences the development of the HPA axis and thus the stress response. Animals raised in a sterile environment from birth exhibit inflated HPA axis activity with elevated ACTH and corticosterone levels in response to a stressor<sup>[22]</sup>. Interestingly, HPA axis activity is normalized after colonization with commensal bacteria from control mice<sup>[25]</sup>.

Although studies investigating the effects of prebiotic or probiotic supplements on stress behavior in humans are limited, they indicate the role of gastrointestinal microbiota in stress and emotional responses. Likewise, a probiotic combination (*Lactobacillus helveticus* R0052 and *Bifidobacterium longum* R0175)<sup>[58]</sup> and a prebiotic (galactooligosaccharide)<sup>[59]</sup> have proven effective in increasing the subject's resilience to stress and improved emotional responses in healthy subjects.

Depression is a stress-related mood disorder associated with a disrupted HPA axis, and evidence suggests that the gut microbiota play a key role in modulating depression<sup>[60]</sup>. In fact, an increase in alpha diversity of the gut microbiota has been reported in individuals with depression compared to a healthy

control group. Furthermore, patients with depression show significantly lower numbers of *Bifidobacterium* and *Lactobacillus* compared to control subjects<sup>[61]</sup>. In addition, a more recent study shows that patients with major depression have altered microbiota compared to normal subjects, with a significant increase in the genus *Eggerthella*, *Holdemania*, *Gelria*, *Turicibacter*, *Paraprevotella* and *Anaerofilm*, whereas reductions in *Prevotella* and *Dialister* were observed<sup>[62]</sup>. Another recent study also reported a negative correlation between *Faecalibacterium* spp. and the severity of depressive symptoms<sup>[62]</sup>. Moreover, researchers have demonstrated that when the microbiota from patients with major depression is transferred to microbiota-depleted animals, the behavioral and physiological features characteristic of depression are also transferred, supporting a link between dysbiotic microbiota and depression<sup>[63]</sup>. A recent study published in *Science* reported a correlation between a more diverse gut microbiota composition and depression in humans after investigating the gut microbiomes of 1135 participants from a Dutch population cohort using deep sequencing<sup>[64]</sup>.

Different diets have been suggested to have either positive or negative effects on depression. For instance, a Western diet seems to be associated with an increased risk of depression, whereas the Mediterranean diet seems to reduce the onset of depression. Furthermore, studies in human and animal models have shown an association between depletion of omega-3 polyunsaturated fatty acids and major depression, suggesting the role of diet in depression onset<sup>[65]</sup>.

Different probiotic treatments have displayed efficacy in the reduction of depressive-like behaviors in animal models. For instance, administration of a probiotic cocktail comprising of *Lactobacillus rhamnosus* and *Lactobacillus helveticus* strains have been shown to ameliorate depressive-like behavior and normalize corticosterone levels in a maternal-separation animal model. Moreover, administration of *Lactobacillus rhamnosus* reduced depression and anxiety-related behavior. Also there is evidence for the association between different strains of the genus *Bifidobacterium* and potential antidepressant-like behavior in animals. Treatment with a strain of *Bifidobacterium infantis* attenuated depression, showing increased mobile episodes during the forced swim test in maternally separated rats. A similar effect was also observed with strains of *Bifidobacterium longum* and *Bifidobacterium breve* on depression and anxiety-related behavior in rodents<sup>[60]</sup>.

### Gut microbiota and neurodegenerative conditions

Over a century ago, the Nobel Prize Elie Metchnikoff already suggested that the microbial communities within the gastrointestinal tract had an influence on human health. The Russian scientist Metchnikoff observed that people lived longer in parts of Bulgaria

and Eastern Europe because of the high consumption of fermented dairy products containing lactic acid bacteria, and suggested that complementing the diet with lactic acid bacteria would have health benefits, including longevity<sup>[66]</sup>. The finding that germ-free mice live longer than their conventionalized controls was also reported many years ago<sup>[67,68]</sup>, supporting a link between microbiota and senescence. Nowadays, we know that the gut microbiota undergoes a dynamic change during aging<sup>[69]</sup>. It is of interest that bifidobacteria numbers decrease with age, while those of clostridia increase<sup>[70]</sup>. Age-related gut microbiota composition changes have also been correlated with health outcomes in the elderly, such as frailty<sup>[71]</sup>, with microbial diversity being an important feature linked to health maintenance as we age<sup>[18]</sup>. However, major shifts in diet of the elderly could partly be responsible for the dramatic changes in microbiota composition and their association with health-related outcomes<sup>[72]</sup>. This also suggests there is a chance of redressing the balance by dietary-based interventions in the elderly.

Aging can weaken gastrointestinal barrier function and promote a proinflammatory phenotype involving the microbiota<sup>[73]</sup>. Another consequence of ageing is the progressive leakiness of the blood-brain-barrier (BBB), whose integrity also seems to be dependent on gut microbiota composition<sup>[74]</sup>. SCFAs produced by gut microbiota components are considered key metabolites mediating such effects. Stress is one of the lifestyle factors that can negatively impact BBB permeability<sup>[75]</sup> and accelerate the "inflamm-aging" processes linked to age-related diseases<sup>[76]</sup>. Therefore, understanding how the gut microbiota or their components influence such processes is now worthy of attention.

Parkinson's disease (PD) is a neurodegenerative disorder that represents a growing health concern in the elderly. It is characterized by neuroinflammation and loss of midbrain dopaminergic neurons, as well as by a characteristic pattern of abnormal movements with a number of non-motor symptoms<sup>[77]</sup>. It has also been observed that alterations in bowel function, mainly constipation, often precede the onset of prototypical motor symptoms associated with PD. While genetics plays an important role in the risk of developing the disease, environmental factors and gene-environment interactions also contribute to the risk for developing the disorder<sup>[78]</sup>. In fact, evidence suggests that gut microbiota is an important environmental factor related to the risk of PD<sup>[78-81]</sup>.

Interestingly, a recent study sequenced the gut microbiota in patients with PD and controls<sup>[81]</sup>. The authors of this study compared 72 patients and 72 matched controls, confirming a major reduction in the levels of Prevotellaceae in PD patients. They also observed and described a positive correlation between the levels of Enterobacteriaceae and the severity of postural instability and gait difficulty<sup>[81]</sup>, suggesting the role of the gut microbiota in the PD phenotype. Another study showed that at the taxonomic level of genus,



putative “anti-inflammatory” butyrate-producing bacteria from the genera *Blautia*, *Coproccoccus*, and *Roseburia* were significantly more abundant in feces of controls than PD patients. On the other side, in this study it was also reported that bacteria from the genus *Faecalibacterium* were significantly found more abundant in the mucosa of controls than PD patients, whereas putative “pro-inflammatory”. Proteobacteria of the genus *Ralstonia* were significantly more abundant in mucosa of PD patients than controls<sup>[81]</sup>.

Intriguingly, another recent study confirmed the recently reported association between PD and the reduced abundance of butyrate-producing bacteria, and also demonstrated a reduction in the relative SCFAs concentration in PD compared with the abundance observed in controls, suggesting a role for SCFAs in PD<sup>[78]</sup>. However, prospective longitudinal studies in subjects at risk of PD are still required to further elucidate the causal role of the gut microbiota and microbial products in the development of PD and its manifestations.

Very recently it has been reported that gut microbiota is involved in motor deficits and neuroinflammation in a model of PD, suggesting that the changes in the gut microbiota represent a risk factor for PD<sup>[78]</sup>. This study revealed that under GF conditions, or antibiotic-related bacterial depletion, transgenic animals overexpressing human  $\alpha$ -synuclein ( $\alpha$ Syn) (an abundant protein in the human brain involved in neurotransmitter release) displayed reduced microglia activation,  $\alpha$ Syn aggregates and motor deficits (neuropathological features of PD) compared to animals with a complex microbiota. Conversely, they showed that treatment with SCFAs restored all major features of PD in GF mice. Furthermore, this study demonstrated that transplanting gut microbiota from PD patients into genetically susceptible mice ( $\alpha$ Syn-overexpressing mice) enhances physical impairments when compared to microbiota transplant from healthy human donors<sup>[78]</sup>.

Alzheimer’s disease (AD) and vascular dementias are the most common causes of cognitive decline in ageing populations in Western countries<sup>[82]</sup>. The deficit in synaptic plasticity is one of the many changes occurring with age. Specifically, the typical model of plasticity shows a reduction in the hippocampus long-term potentiation (LTP) of the middle-aged, but most dramatically in aging rats<sup>[83]</sup>. A recent study has investigated whether the age-related deficit in LTP might be attenuated by changing the composition of intestinal microbiota with VSL#3, a probiotic mixture comprising 8 Gram-positive bacterial strains. The study showed that the age-related deficit in LTP was attenuated in VSL#3-treated aged rats and this was accompanied by a modest decrease in markers of microglial activation and an increase in expression of BDNF and synapsin<sup>[84]</sup>. However, although these findings support the fact that intestinal microbiota can

be manipulated in order to positively impact neuronal function modulating microglial activation, at the moment we still need to be cautious and to investigate further the different probiotics that could be used to modify the microglial maturation and function.

Surprisingly, so far there is a lack of detailed analyses of the microbiota of patients with AD<sup>[85]</sup>. However, in metabolic syndrome, type 2 diabetes and obesity, which are risk factors for AD<sup>[86]</sup>, there is an alteration in the gut microbiota<sup>[87,88]</sup>. More recently, a research study using a mouse model of AD has implicated the microbiota in the accumulation of amyloid plaques<sup>[89]</sup>, and there is also evidence suggesting that gut microbiota might be directly linked to dementia pathogenesis by triggering metabolic diseases and low-grade inflammation<sup>[90]</sup>. Different mechanisms may explain the link between gut microbiota alterations in obesity and T2D and the development of AD. For example, different studies have indicated that an altered gut microbiota linked to obesity increases intestinal permeability and contributes to systemic inflammation leading to insulin resistance and T2DM<sup>[91]</sup>. In turn, insulin resistance and T2DM is a risk factor for development of AD. Furthermore, the vascular effects of obesity and T2D, related to changes on the gut microbiota, also appear to play an important role in the development of AD<sup>[92]</sup>. A leading hypothesis on the pathophysiology of AD is the mis-metabolism of amyloid precursor protein. The A $\beta$  peptide is derived from amyloid precursor protein by sequential cleavages of different proteases. The activity of these proteases involved in the generation of A $\beta$  peptide is highly regulated by the inflammation, being the latter modulate as already mentioned by the gut microbiota. In fact, BACE1 enzyme is essential for the generation of  $\beta$ -amyloid and Interleukin 1 $\beta$ , considered as a risk factor for AD development, has been observed to aggravate plaque formation by induction of BACE1 expression<sup>[93]</sup>.

However, although it has been suggested that alterations on gut microbiota observed in diabetes and obesity may be linked to the risk of developing AD, there is a need of further work to elucidate the specific gut’s microbes and the mechanisms involved in the link between obesity, T2D and AD.

Dysregulation of normal microglial functions such as synaptic pruning and regulation is increasingly found to be implicated in diseases associated with cognitive deficits<sup>[12,94]</sup>. Microglia cells are also essential for clearance of debris, plaques and aggregates, thereby playing a fundamental role in neurodegenerative amyloid disorders, including Alzheimer’s, Huntington’s and Parkinson’s diseases, each associated with a distinct amyloid protein. Therefore, targeting dysregulated microglial functions represents a therapeutic opportunity for treating these disorders<sup>[95,96]</sup>. Although the mechanisms that ultimately lead to neurodegeneration are different in each neurodegenerative disease, chronic inflammation that may be modulated by the gut

microbiota is typically a prominent feature in the progressive nature of neurodegeneration<sup>[12]</sup>.

## CONCLUSION

It is becoming evident that brain development and function are dependent on the diversity and structure of the gut microbiota and may, therefore, influence mental health. This hypothesis is based mainly on animal trials and a few observational human studies associating gut microbiota alterations with mental disorders, including depression, autism and PD. This notion has been further supported by recent transplantation experiments where the gut microbiota has been shown to transfer a behavioral phenotype or the disease features to the recipient animal, providing stronger evidence for a causal relationship. However, longitudinal studies in humans are still needed to investigate whether the gut microbiota changes in subjects with different neuropsychiatric disorder can contribute to disease onset and the role of other interacting factors such as the diet. So far various communication routes between the microbiota and brain have been identified, including immune, endocrine and neural pathways. Thus, interventions with pro and pre-biotics in animal models have shown that the microbiota could play a role in mental health by regulating inflammatory and endocrine secretions, synthesizing neuroactive compounds and interacting with the vagal nerve. Greater understanding of the precise underlying mechanisms is required to develop a clear rationale for conducting microbiota-based interventions in humans. In particular, inflammation seems to be a critical pathophysiological feature of mental disorders and, therefore, a potential target for microbiota-based interventions. Nonetheless, further knowledge is needed on how microbiota signals generated in the gut can impact on microglial activation and neuroinflammation.

## REFERENCES

- 1 Cannon JR, Greenamyre JT. The role of environmental exposures in neurodegeneration and neurodegenerative diseases. *Toxicol Sci* 2011; **124**: 225-250 [PMID: 21914720 DOI: 10.1093/toxsci/kfr239]
- 2 van Loo KM, Martens GJ. Genetic and environmental factors in complex neurodevelopmental disorders. *Curr Genomics* 2007; **8**: 429-444 [PMID: 19412416 DOI: 10.2174/138920207783591717]
- 3 Stilling RM, Dinan TG, Cryan JF. Microbial genes, brain & amp; behaviour - epigenetic regulation of the gut-brain axis. *Genes Brain Behav* 2014; **13**: 69-86 [PMID: 24286462 DOI: 10.1111/gbb.12109]
- 4 O'Hara AM, Shanahan F. The gut flora as a forgotten organ. *EMBO Rep* 2006; **7**: 688-693 [PMID: 16819463 DOI: 10.1038/sj.embor.7400731]
- 5 Cryan JF, Dinan TG. More than a gut feeling: the microbiota regulates neurodevelopment and behavior. *Neuropsychopharmacology* 2015; **40**: 241-242 [PMID: 25482171 DOI: 10.1038/npp.2014.224]
- 6 Dinan TG, Stanton C, Cryan JF. Psychobiotics: a novel class of psychotropic. *Biol Psychiatry* 2013; **74**: 720-726 [PMID: 23759244 DOI: 10.1016/j.biopsych.2013.05.001]
- 7 Cryan JF, Dinan TG. Mind-altering microorganisms: the impact of the gut microbiota on brain and behaviour. *Nat Rev Neurosci* 2012; **13**: 701-712 [PMID: 22968153 DOI: 10.1038/nrn3346]
- 8 Majnik AV, Lane RH. The relationship between early-life environment, the epigenome and the microbiota. *Epigenomics* 2015; **7**: 1173-1184 [PMID: 26585860 DOI: 10.2217/epi.15.74]
- 9 Alenghat T, Artis D. Epigenomic regulation of host-microbiota interactions. *Trends Immunol* 2014; **35**: 518-525 [PMID: 25443494 DOI: 10.1016/j.it.2014.09.007]
- 10 Dinan TG, Cryan JF. Mood by microbe: towards clinical translation. *Genome Med* 2016; **8**: 36 [PMID: 27048547 DOI: 10.1186/s13073-016-0292-1]
- 11 Erny D, Hrabě de Angelis AL, Jaitin D, Wieghofer P, Staszewski O, David E, Keren-Shaul H, Makhlovi T, Jakobshagen K, Buch T, Schwierzeck V, Utermöhlen O, Chun E, Garrett WS, McCoy KD, Diefenbach A, Staeheli P, Stecher B, Amit I, Prinz M. Host microbiota constantly control maturation and function of microglia in the CNS. *Nat Neurosci* 2015; **18**: 965-977 [PMID: 26030851 DOI: 10.1038/nn.4030]
- 12 Harry GJ. Microglia during development and aging. *Pharmacol Ther* 2013; **139**: 313-326 [PMID: 23644076 DOI: 10.1016/j.pharmthera.2013.04.013]
- 13 Salazar N, Arboleya S, Valdés L, Stanton C, Ross P, Ruiz L, Gueimonde M, de Los Reyes-Gavilán CG. The human intestinal microbiome at extreme ages of life. Dietary intervention as a way to counteract alterations. *Front Genet* 2014; **5**: 406 [PMID: 25484891 DOI: 10.3389/fgene.2014.00406]
- 14 Bonder MJ, Kurilshikov A, Tigchelaar EF, Mujagic Z, Imhann F, Vila AV, Deelen P, Vatanen T, Schirmer M, Smeekens SP, Zhernakova DV, Jankipersadsing SA, Jaeger M, Oosting M, Cenit MC, Masclee AA, Swertz MA, Li Y, Kumar V, Joosten L, Harmsen H, Weersma RK, Franke L, Hofker MH, Xavier RJ, Jonkers D, Netea MG, Wijmenga C, Fu J, Zhernakova A. The effect of host genetics on the gut microbiome. *Nat Genet* 2016; **48**: 1407-1412 [PMID: 27694959 DOI: 10.1038/ng.3663]
- 15 Penders J, Thijs C, Vink C, Stelma FF, Snijders B, Kummeling I, van den Brandt PA, Stobberingh EE. Factors influencing the composition of the intestinal microbiota in early infancy. *Pediatrics* 2006; **118**: 511-521 [PMID: 16882802 DOI: 10.1542/peds.2005-2824]
- 16 Borre YE, O'Keefe GW, Clarke G, Stanton C, Dinan TG, Cryan JF. Microbiota and neurodevelopmental windows: implications for brain disorders. *Trends Mol Med* 2014; **20**: 509-518 [PMID: 24956966 DOI: 10.1016/j.molmed.2014.05.002]
- 17 Biagi E, Franceschi C, Rampelli S, Severgnini M, Ostan R, Turroni S, Consolandi C, Quercia S, Scurti M, Monti D, Capri M, Brigidi P, Candela M. Gut Microbiota and Extreme Longevity. *Curr Biol* 2016; **26**: 1480-1485 [PMID: 27185560 DOI: 10.1016/j.cub.2016.04.016]
- 18 Leung K, Thuret S. Gut Microbiota: A Modulator of Brain Plasticity and Cognitive Function in Ageing. *Healthcare (Basel)* 2015; **3**: 898-916 [PMID: 27417803 DOI: 10.3390/healthcare3040898]
- 19 MacQueen G, Surette M, Moayyedi P. The gut microbiota and psychiatric illness. *J Psychiatry Neurosci* 2017; **42**: 75-77 [PMID: 28245172 DOI: 10.1503/jpn.170028]
- 20 Luczynski P, McVey Neufeld KA, Oriach CS, Clarke G, Dinan TG, Cryan JF. Growing up in a Bubble: Using Germ-Free Animals to Assess the Influence of the Gut Microbiota on Brain and Behavior. *Int J Neuropsychopharmacol* 2016; **19**: pii: pyw020 [PMID: 26912607 DOI: 10.1093/ijnpp/pyw020]
- 21 Desbonnet L, Clarke G, Traplin A, O'Sullivan O, Crispie F, Moloney RD, Cotter PD, Dinan TG, Cryan JF. Gut microbiota depletion from early adolescence in mice: Implications for brain and behaviour. *Brain Behav Immun* 2015; **48**: 165-173 [PMID: 25866195 DOI: 10.1016/j.bbi.2015.04.004]
- 22 Sudo N, Chida Y, Aiba Y, Sonoda J, Oyama N, Yu XN, Kubo C, Koga Y. Postnatal microbial colonization programs the hypothalamic-pituitary-adrenal system for stress response in mice.

- J Physiol* 2004; **558**: 263-275 [PMID: 15133062 DOI: 10.1113/jphysiol.2004.063388]
- 23 **Diaz Heijtz R**, Wang S, Anuar F, Qian Y, Björkholm B, Samuelsson A, Hibberd ML, Forssberg H, Pettersson S. Normal gut microbiota modulates brain development and behavior. *Proc Natl Acad Sci USA* 2011; **108**: 3047-3052 [PMID: 21282636 DOI: 10.1073/pnas.1010529108]
- 24 **Neufeld KM**, Kang N, Bienenstock J, Foster JA. Reduced anxiety-like behavior and central neurochemical change in germ-free mice. *Neurogastroenterol Motil* 2011; **23**: 255-264, e119 [PMID: 21054680 DOI: 10.1111/j.1365-2982.2010.01620.x]
- 25 **Collins SM**, Kassam Z, Bercik P. The adoptive transfer of behavioral phenotype via the intestinal microbiota: experimental evidence and clinical implications. *Curr Opin Microbiol* 2013; **16**: 240-245 [PMID: 23845749 DOI: 10.1016/j.mib.2013.06.004]
- 26 **Ogbonnaya ES**, Clarke G, Shanahan F, Dinan TG, Cryan JF, O'Leary OF. Adult Hippocampal Neurogenesis Is Regulated by the Microbiome. *Biol Psychiatry* 2015; **78**: e7-e9 [PMID: 25700599 DOI: 10.1016/j.biopsych.2014.12.023]
- 27 **Stilling RM**, Ryan FJ, Hoban AE, Shanahan F, Clarke G, Claesson MJ, Dinan TG, Cryan JF. Microbes & neurodevelopment-Absence of microbiota during early life increases activity-related transcriptional pathways in the amygdala. *Brain Behav Immun* 2015; **50**: 209-220 [PMID: 26184083 DOI: 10.1016/j.bbi.2015.07.009]
- 28 **Hoban AE**, Stilling RM, Ryan FJ, Shanahan F, Dinan TG, Claesson MJ, Clarke G, Cryan JF. Regulation of prefrontal cortex myelination by the microbiota. *Transl Psychiatry* 2016; **6**: e774 [PMID: 27045844 DOI: 10.1038/tp.2016.42]
- 29 **Barrett E**, Ross RP, O'Toole PW, Fitzgerald GF, Stanton C.  $\gamma$ -Aminobutyric acid production by culturable bacteria from the human intestine. *J Appl Microbiol* 2012; **113**: 411-417 [PMID: 22612585 DOI: 10.1111/j.1365-2672.2012.05344.x]
- 30 **Bercik P**, Denou E, Collins J, Jackson W, Lu J, Jury J, Deng Y, Blennerhassett P, Macri J, McCoy KD, Verdu EF, Collins SM. The intestinal microbiota affect central levels of brain-derived neurotrophic factor and behavior in mice. *Gastroenterology* 2011; **141**: 599-609, 609.e1-3 [PMID: 21683077 DOI: 10.1053/j.gastro.2011.04.052]
- 31 **O'Mahony SM**, Clarke G, Borre YE, Dinan TG, Cryan JF. Serotonin, tryptophan metabolism and the brain-gut-microbiome axis. *Behav Brain Res* 2015; **277**: 32-48 [PMID: 25078296 DOI: 10.1016/j.bbr.2014.07.027]
- 32 **Foley KA**, MacFabe DF, Vaz A, Ossenkopp KP, Kavaliers M. Sexually dimorphic effects of prenatal exposure to propionic acid and lipopolysaccharide on social behavior in neonatal, adolescent, and adult rats: implications for autism spectrum disorders. *Int J Dev Neurosci* 2014; **39**: 68-78 [PMID: 24747144 DOI: 10.1016/j.jdevneu.2014.04.001]
- 33 **Obata Y**, Furusawa Y, Hase K. Epigenetic modifications of the immune system in health and disease. *Immunol Cell Biol* 2015; **93**: 226-232 [PMID: 25666097 DOI: 10.1038/icb.2014.114]
- 34 **Tsankova N**, Renthal W, Kumar A, Nestler EJ. Epigenetic regulation in psychiatric disorders. *Nat Rev Neurosci* 2007; **8**: 355-367 [PMID: 17453016 DOI: 10.1038/nrn2132]
- 35 **Boulle F**, van den Hove DL, Jakob SB, Rutten BP, Hamon M, van Os J, Lesch KP, Lanfume L, Steinbusch HW, Kenis G. Epigenetic regulation of the BDNF gene: implications for psychiatric disorders. *Mol Psychiatry* 2012; **17**: 584-596 [PMID: 21894152 DOI: 10.1038/mp.2011.107]
- 36 **Woo V**, Alenghat T. Host-microbiota interactions: epigenomic regulation. *Curr Opin Immunol* 2017; **44**: 52-60 [PMID: 28103497 DOI: 10.1016/j.coi.2016.12.001]
- 37 **Kumar H**, Lund R, Laiho A, Lundelin K, Ley RE, Isolauri E, Salminen S. Gut microbiota as an epigenetic regulator: pilot study based on whole-genome methylation analysis. *MBio* 2014; **5**: pii: e02113-14 [PMID: 25516615 DOI: 10.1128/mBio.02113-14]
- 38 **Singh N**, Shirdel EA, Waldron L, Zhang RH, Jurisica I, Comelli EM. The murine caecal microRNA signature depends on the presence of the endogenous microbiota. *Int J Biol Sci* 2012; **8**: 171-186 [PMID: 22211115 DOI: 10.7150/ijbs.8.171]
- 39 **Lardenoije R**, Iatrou A, Kenis G, Kompotis K, Steinbusch HW, Mastroeni D, Coleman P, Lemere CA, Hof PR, van den Hove DL, Rutten BP. The epigenetics of aging and neurodegeneration. *Prog Neurobiol* 2015; **131**: 21-64 [PMID: 26072273 DOI: 10.1016/j.pneurobio.2015.05.002]
- 40 **Desbonnet L**, Clarke G, Shanahan F, Dinan TG, Cryan JF. Microbiota is essential for social development in the mouse. *Mol Psychiatry* 2014; **19**: 146-148 [PMID: 23689536 DOI: 10.1038/mp.2013.65]
- 41 **Chini B**, Leonzino M, Braida D, Sala M. Learning about oxytocin: pharmacologic and behavioral issues. *Biol Psychiatry* 2014; **76**: 360-366 [PMID: 24120095 DOI: 10.1016/j.biopsych.2013.08.029]
- 42 **Erdman SE**, Poutahidis T. Microbes and Oxytocin: Benefits for Host Physiology and Behavior. *Int Rev Neurobiol* 2016; **131**: 91-126 [PMID: 27793228 DOI: 10.1016/bs.irm.2016.07.004]
- 43 **Tomova A**, Husarova V, Lakatosova S, Bakos J, Vlkova B, Babinska K, Ostatnikova D. Gastrointestinal microbiota in children with autism in Slovakia. *Physiol Behav* 2015; **138**: 179-187 [PMID: 25446201 DOI: 10.1016/j.physbeh.2014.10.033]
- 44 **Finegold SM**, Dowd SE, Gontcharova V, Liu C, Henley KE, Wolcott RD, Youn E, Summanen PH, Granpeesheh D, Dixon D, Liu M, Molitoris DR, Green JA 3rd. Pyrosequencing study of fecal microflora of autistic and control children. *Anaerobe* 2010; **16**: 444-453 [PMID: 20603222 DOI: 10.1016/j.anaerobe.2010.06.008]
- 45 **Wang L**, Christophersen CT, Sorich MJ, Gerber JP, Angley MT, Conlon MA. Elevated fecal short chain fatty acid and ammonia concentrations in children with autism spectrum disorder. *Dig Dis Sci* 2012; **57**: 2096-2102 [PMID: 22535281 DOI: 10.1007/s10620-012-2167-7]
- 46 **Kratsman N**, Getselter D, Elliott E. Sodium butyrate attenuates social behavior deficits and modifies the transcription of inhibitory/excitatory genes in the frontal cortex of an autism model. *Neuropharmacology* 2016; **102**: 136-145 [PMID: 26577018 DOI: 10.1016/j.neuropharm.2015.11.003]
- 47 **Thomas RH**, Meeking MM, Mepharm JR, Tichenoff L, Possmayer F, Liu S, MacFabe DF. The enteric bacterial metabolite propionic acid alters brain and plasma phospholipid molecular species: further development of a rodent model of autism spectrum disorders. *J Neuroinflammation* 2012; **9**: 153 [PMID: 22747852 DOI: 10.1186/1742-2094-9-153]
- 48 **Christensen J**, Grønberg TK, Sørensen MJ, Schendel D, Parner ET, Pedersen LH, Vestergaard M. Prenatal valproate exposure and risk of autism spectrum disorders and childhood autism. *JAMA* 2013; **309**: 1696-1703 [PMID: 23613074 DOI: 10.1001/jama.2013.2270]
- 49 **de Theije CG**, Wopereis H, Ramadan M, van Eijndthoven T, Lambert J, Knol J, Garssen J, Kraneveld AD, Oozeer R. Altered gut microbiota and activity in a murine model of autism spectrum disorders. *Brain Behav Immun* 2014; **37**: 197-206 [PMID: 24333160 DOI: 10.1016/j.bbi.2013.12.005]
- 50 **Li YM**, Ou JJ, Liu L, Zhang D, Zhao JP, Tang SY. Association Between Maternal Obesity and Autism Spectrum Disorder in Offspring: A Meta-analysis. *J Autism Dev Disord* 2016; **46**: 95-102 [PMID: 26254893 DOI: 10.1007/s10803-015-2549-8]
- 51 **Buffington SA**, Di Prisco GV, Auchtung TA, Ajami NJ, Petrosino JF, Costa-Mattioli M. Microbial Reconstitution Reverses Maternal Diet-Induced Social and Synaptic Deficits in Offspring. *Cell* 2016; **165**: 1762-1775 [PMID: 27315483 DOI: 10.1016/j.cell.2016.06.001]
- 52 **Owen MJ**, Sawa A, Mortensen PB. Schizophrenia. *Lancet* 2016; **388**: 86-97 [PMID: 26777917 DOI: 10.1016/S0140-6736(15)01121-6]
- 53 **Fabi E**, Fusco A, Valiante M, Celli R. [Genetics and epigenetics of schizophrenia]. *Clin Ter* 2013; **164**: e319-e324 [PMID: 24045531 DOI: 10.7417/CT.2013.1596]
- 54 **Dinan TG**, Borre YE, Cryan JF. Genomics of schizophrenia: time to consider the gut microbiome? *Mol Psychiatry* 2014; **19**: 1252-1257 [PMID: 25288135 DOI: 10.1038/mp.2014.93]
- 55 **Dickerson F**, Severance E, Yolken R. The microbiome, immunity, and schizophrenia and bipolar disorder. *Brain Behav Immun* 2017;



- 62: 46-52 [PMID: 28003152 DOI: 10.1016/j.bbi.2016.12.010]
- 56 **Thapar A**, Cooper M, Eyre O, Langley K. What have we learnt about the causes of ADHD? *J Child Psychol Psychiatry* 2013; **54**: 3-16 [PMID: 22963644 DOI: 10.1111/j.1469-7610.2012.02611.x]
- 57 **Cenit MC**, Nuevo IC, Codoñer-Franch P, Dinan TG, Sanz Y. Gut microbiota and attention deficit hyperactivity disorder: new perspectives for a challenging condition. *Eur Child Adolesc Psychiatry* 2017; Epub ahead of print [PMID: 28289903 DOI: 10.1007/s00787-017-0969-z]
- 58 **Messaoudi M**, Violle N, Bisson JF, Desor D, Javelot H, Rougeot C. Beneficial psychological effects of a probiotic formulation (Lactobacillus helveticus R0052 and Bifidobacterium longum R0175) in healthy human volunteers. *Gut Microbes* 2011; **2**: 256-261 [PMID: 21983070 DOI: 10.4161/gmic.2.4.16108]
- 59 **Hughes C**, Davoodi-Semiromi Y, Colee JC, Culpepper T, Dahl WJ, Mai V, Christman MC, Langkamp-Henken B. Galactooligosaccharide supplementation reduces stress-induced gastrointestinal dysfunction and days of cold or flu: a randomized, double-blind, controlled trial in healthy university students. *Am J Clin Nutr* 2011; **93**: 1305-1311 [PMID: 21525194 DOI: 10.3945/ajcn.111.014126]
- 60 **Dinan TG**, Cryan JF. Melancholic microbes: a link between gut microbiota and depression? *Neurogastroenterol Motil* 2013; **25**: 713-719 [PMID: 23910373 DOI: 10.1111/nmo.12198]
- 61 **Aizawa E**, Tsuji H, Asahara T, Takahashi T, Teraishi T, Yoshida S, Ota M, Koga N, Hattori K, Kunugi H. Possible association of Bifidobacterium and Lactobacillus in the gut microbiota of patients with major depressive disorder. *J Affect Disord* 2016; **202**: 254-257 [PMID: 27288567 DOI: 10.1016/j.jad.2016.05.038]
- 62 **Jiang H**, Ling Z, Zhang Y, Mao H, Ma Z, Yin Y, Wang W, Tang W, Tan Z, Shi J, Li L, Ruan B. Altered fecal microbiota composition in patients with major depressive disorder. *Brain Behav Immun* 2015; **48**: 186-194 [PMID: 25882912 DOI: 10.1016/j.bbi.2015.03.016]
- 63 **Kelly JR**, Borre Y, O'Brien C, Patterson E, El Aidy S, Deane J, Kennedy PJ, Beers S, Scott K, Moloney G, Hoban AE, Scott L, Fitzgerald P, Ross P, Stanton C, Clarke G, Cryan JF, Dinan TG. Transferring the blues: Depression-associated gut microbiota induces neurobehavioural changes in the rat. *J Psychiatr Res* 2016; **82**: 109-118 [PMID: 27491067 DOI: 10.1016/j.jpsychires.2016.07.019]
- 64 **Zhernakova A**, Kurilshikov A, Bonder MJ, Tigchelaar EF, Schirmer M, Vatanen T, Mujagic Z, Vila AV, Falony G, Vieira-Silva S, Wang J, Imhann F, Brandsma E, Jankipersadsing SA, Joossens M, Cenit MC, Deelen P, Swertz MA; LifeLines cohort study, Weersma RK, Feskens EJ, Netea MG, Gevers D, Jonkers D, Franke L, Aulchenko YS, Huttenhower C, Raes J, Hofker MH, Xavier RJ, Wijmenga C, Fu J. Population-based metagenomics analysis reveals markers for gut microbiome composition and diversity. *Science* 2016; **352**: 565-569 [PMID: 27126040 DOI: 10.1126/science.aad3369]
- 65 **Grosso G**, Pajak A, Marventano S, Castellano S, Galvano F, Bucolo C, Drago F, Caraci F. Role of omega-3 fatty acids in the treatment of depressive disorders: a comprehensive meta-analysis of randomized clinical trials. *PLoS One* 2014; **9**: e96905 [PMID: 24805797 DOI: 10.1371/journal.pone.0096905]
- 66 **Stambler IS**. [Elie Metchnikoff--The Founder Of Longevity Science And A Founder Of Modern Medicine: In Honor Of The 170th Anniversary]. *Adv Gerontol* 2015; **28**: 207-217 [PMID: 26856081]
- 67 **Glimstedt G**. The germfree animal as a research tool. *Ann N Y Acad Sci* 1959; **78**: 281-284 [PMID: 13828472]
- 68 **Gustafsson B**. Germ-free rearing of rats. *Acta Anat (Basel)* 1946-1947; **2**: 376-391 [PMID: 20256962]
- 69 **Claesson MJ**, Cusack S, O'Sullivan O, Greene-Diniz R, de Weerd H, Flannery E, Marchesi JR, Falush D, Dinan T, Fitzgerald G, Stanton C, van Sinderen D, O'Connor M, Harnedy N, O'Connor K, Henry C, O'Mahony D, Fitzgerald AP, Shanahan F, Twomey C, Hill C, Ross RP, O'Toole PW. Composition, variability, and temporal stability of the intestinal microbiota of the elderly. *Proc Natl Acad Sci USA* 2011; **108** Suppl 1: 4586-4591 [PMID: 20571116 DOI: 10.1073/pnas.1000097107]
- 70 **Rondanelli M**, Giacosa A, Faliva MA, Perna S, Allieri F, Castellazzi AM. Review on microbiota and effectiveness of probiotics use in older. *World J Clin Cases* 2015; **3**: 156-162 [PMID: 25685762 DOI: 10.12998/wjcc.v3.i2.156]
- 71 **O'Toole PW**, Jeffery IB. Gut microbiota and aging. *Science* 2015; **350**: 1214-1215 [PMID: 26785481 DOI: 10.1126/science.aac8469]
- 72 **David LA**, Maurice CF, Carmody RN, Gootenberg DB, Button JE, Wolfe BE, Ling AV, Devlin AS, Varma Y, Fischbach MA, Biddinger SB, Dutton RJ, Turnbaugh PJ. Diet rapidly and reproducibly alters the human gut microbiome. *Nature* 2014; **505**: 559-563 [PMID: 24336217 DOI: 10.1038/nature12820]
- 73 **Kelly JR**, Kennedy PJ, Cryan JF, Dinan TG, Clarke G, Hyland NP. Breaking down the barriers: the gut microbiome, intestinal permeability and stress-related psychiatric disorders. *Front Cell Neurosci* 2015; **9**: 392 [PMID: 26528128 DOI: 10.3389/fncel.2015.00392]
- 74 **Braniste V**, Al-Asmakh M, Kowal C, Anuar F, Abbaspour A, Tóth M, Korecka A, Bakocovic N, Ng LG, Kundu P, Gulyás B, Halldin C, Hultenby K, Nilsson H, Hebert H, Volpe BT, Diamond B, Pettersson S. The gut microbiota influences blood-brain barrier permeability in mice. *Sci Transl Med* 2014; **6**: 263ra158 [PMID: 25411471 DOI: 10.1126/scitranslmed.3009759]
- 75 **Esposito P**, Chandler N, Kandere K, Basu S, Jacobson S, Connolly R, Tutor D, Theoharides TC. Corticotropin-releasing hormone and brain mast cells regulate blood-brain-barrier permeability induced by acute stress. *J Pharmacol Exp Ther* 2002; **303**: 1061-1066 [PMID: 12438528 DOI: 10.1124/jpet.102.038497]
- 76 **Köhler CA**, Maes M, Slyepchenko A, Berk M, Solmi M, Lanctôt KL, Carvalho AF. The Gut-Brain Axis, Including the Microbiome, Leaky Gut and Bacterial Translocation: Mechanisms and Pathophysiological Role in Alzheimer's Disease. *Curr Pharm Des* 2016; **22**: 6152-6166 [PMID: 27604604 DOI: 10.2174/1381612822666160907093807]
- 77 **Kalia LV**, Lang AE. Parkinson's disease. *Lancet* 2015; **386**: 896-912 [PMID: 25904081 DOI: 10.1016/S0140-6736(14)61393-3]
- 78 **Sampson TR**, Debelius JW, Thron T, Janssen S, Shastri GG, Ilhan ZE, Challis C, Schretter CE, Rocha S, Gradinaru V, Chesselet MF, Keshavarzian A, Shannon KM, Krajmalnik-Brown R, Wittung-Stafshede P, Knight R, Mazmanian SK. Gut Microbiota Regulate Motor Deficits and Neuroinflammation in a Model of Parkinson's Disease. *Cell* 2016; **167**: 1469-1480.e12 [PMID: 27912057 DOI: 10.1016/j.cell.2016.11.018]
- 79 **Unger MM**, Spiegel J, Dillmann KU, Grundmann D, Philippeit H, Bürmann J, Faßbender K, Schwiertz A, Schäfer KH. Short chain fatty acids and gut microbiota differ between patients with Parkinson's disease and age-matched controls. *Parkinsonism Relat Disord* 2016; **32**: 66-72 [PMID: 27591074 DOI: 10.1016/j.parkreldis.2016.08.019]
- 80 **Keshavarzian A**, Green SJ, Engen PA, Voigt RM, Naqib A, Forsyth CB, Mutlu E, Shannon KM. Colonic bacterial composition in Parkinson's disease. *Mov Disord* 2015; **30**: 1351-1360 [PMID: 26179554 DOI: 10.1002/mds.26307]
- 81 **Scheperjans F**, Aho V, Pereira PA, Koskinen K, Paulin L, Pekkonen E, Haapaniemi E, Kaakkola S, Eerola-Rautio J, Pohja M, Kinnunen E, Murros K, Auvinen P. Gut microbiota are related to Parkinson's disease and clinical phenotype. *Mov Disord* 2015; **30**: 350-358 [PMID: 25476529 DOI: 10.1002/mds.26069]
- 82 **Scheltens P**, Blennow K, Breteler MM, de Strooper B, Frisoni GB, Salloway S, Van der Flier WM. Alzheimer's disease. *Lancet* 2016; **388**: 505-517 [PMID: 26921134 DOI: 10.1016/S0140-6736(15)01124-1]
- 83 **Lynch MA**. Long-term potentiation and memory. *Physiol Rev* 2004; **84**: 87-136 [PMID: 14715912 DOI: 10.1152/physrev.00014.2003]
- 84 **Distruetti E**, O'Reilly JA, McDonald C, Cipriani S, Renga B, Lynch MA, Fiorucci S. Modulation of intestinal microbiota by the probiotic VSL#3 resets brain gene expression and ameliorates the age-related deficit in LTP. *PLoS One* 2014; **9**: e106503 [PMID: 25202975 DOI: 10.1371/journal.pone.0106503]
- 85 **Alam MZ**, Alam Q, Kamal MA, Abuzenadah AM, Haque A. A



- possible link of gut microbiota alteration in type 2 diabetes and Alzheimer's disease pathogenicity: an update. *CNS Neurol Disord Drug Targets* 2014; **13**: 383-390 [PMID: 24059311 DOI: 10.2174/18715273113126660151]
- 86 **van Dijk G**, van Heijningen S, Reijne AC, Nyakas C, van der Zee EA, Eisel UL. Integrative neurobiology of metabolic diseases, neuroinflammation, and neurodegeneration. *Front Neurosci* 2015; **9**: 173 [PMID: 26041981 DOI: 10.3389/fnins.2015.00173]
- 87 **Festi D**, Schiumerini R, Eusebi LH, Marasco G, Taddia M, Colecchia A. Gut microbiota and metabolic syndrome. *World J Gastroenterol* 2014; **20**: 16079-16094 [PMID: 25473159 DOI: 10.3748/wjg.v20.i43.16079]
- 88 **Cani PD**. Gut microbiota and obesity: lessons from the microbiome. *Brief Funct Genomics* 2013; **12**: 381-387 [PMID: 23616309 DOI: 10.1093/bfpg/elt014]
- 89 **Harach T**, Jammes F, Muller C, Duthilleul N, Cheatham V, Zufferey V, Cheatham D, Lukasheva YA, Lasser T, Bolmont T. Administrations of human adult ischemia-tolerant mesenchymal stem cells and factors reduce amyloid beta pathology in a mouse model of Alzheimer's disease. *Neurobiol Aging* 2017; **51**: 83-96 [PMID: 28056358 DOI: 10.1016/j.neurobiolaging.2016.11.009]
- 90 **Alkasir R**, Li J, Li X, Jin M, Zhu B. Human gut microbiota: the links with dementia development. *Protein Cell* 2017; **8**: 90-102 [PMID: 27866330 DOI: 10.1007/s13238-016-0338-691]
- 91 **Everard A**, Cani PD. Diabetes, obesity and gut microbiota. *Best Pract Res Clin Gastroenterol* 2013; **27**: 73-83 [PMID: 23768554 DOI: 10.1016/j.bpg.2013.03.007]
- 92 **Ochoa-Repáraz J**, Kasper LH. The Second Brain: Is the Gut Microbiota a Link Between Obesity and Central Nervous System Disorders? *Curr Obes Rep* 2016; **5**: 51-64 [PMID: 26865085 DOI: 10.1007/s13679-016-0191-1]
- 93 **Cole SL**, Vassar R. The Alzheimer's disease beta-secretase enzyme, BACE1. *Mol Neurodegener* 2007; **2**: 22 [PMID: 18005427 DOI: 10.1186/1750-1326-2-22]
- 94 **Chen Z**, Trapp BD. Microglia and neuroprotection. *J Neurochem* 2016; **136** Suppl 1: 10-17 [PMID: 25693054 DOI: 10.1111/jnc.13062]
- 95 **Dumont M**, Beal MF. Neuroprotective strategies involving ROS in Alzheimer disease. *Free Radic Biol Med* 2011; **51**: 1014-1026 [PMID: 21130159 DOI: 10.1016/j.freeradbiomed.2010.11.026]
- 96 **Sanchez-Guajardo V**, Tentillier N, Romero-Ramos M. The relation between  $\alpha$ -synuclein and microglia in Parkinson's disease: Recent developments. *Neuroscience* 2015; **302**: 47-58 [PMID: 25684748 DOI: 10.1016/j.neuroscience.2015.02.008]

**P- Reviewer:** Cibor D, Dutta AK, Li HD **S- Editor:** Ma YJ  
**L- Editor:** A **E- Editor:** Huang Y



## Basic Study

# Everolimus halts hepatic cystogenesis in a rodent model of polycystic-liver-disease

Frederik Temmerman, Feng Chen, Louis Libbrecht, Ingrid Vander Elst, Petra Windmolders, Yuanbo Feng, Yicheng Ni, Humbert De Smedt, Frederik Nevens, Jos van Pelt

Frederik Temmerman, Ingrid Vander Elst, Petra Windmolders, Frederik Nevens, Jos van Pelt, Laboratory of Hepatology, Department of Clinical and Experimental Medicine, Faculty of Medicine, University of Leuven, B 3000 Leuven, Belgium

Frederik Temmerman, Ingrid Vander Elst, Petra Windmolders, Frederik Nevens, Jos van Pelt, Department of Gastroenterology and Hepatology, University Hospitals KU Leuven, B 3000 Leuven, Belgium

Feng Chen, Department of Radiology, The first Affiliated Hospital School of Medicine, Zhejiang University, Hangzhou 310003, Zhejiang Province, China

Louis Libbrecht, Department of Pathology, Ghent University Hospital, B 9000 Ghent, Belgium

Yuanbo Feng, Yicheng Ni, Department of Imaging and Pathology, Faculty of Medicine, KU Leuven, B 3000 Leuven, Belgium

Humbert De Smedt, Laboratory of Molecular and Cellular Signalling, KU Leuven, B 3000 Leuven, Belgium

Jos van Pelt, Unit of Clinical Digestive Oncology, Department of Oncology, KU Leuven and Leuven Cancer Institute (LKI), Leuven, B 3000 Leuven, Belgium

**Author contributions:** Temmerman F performed the majority of experiments; Chen F, Feng Y and Ni Y performed the MRI and liver volume calculations; Libbrecht L performed histological interpretation; Vander Elst I and Windmolders P assisted with the animal experiments, performed molecular and protein analysis and processed tissue for histology; De Smedt H assisted in protein data analysis; Temmerman F, Nevens F and van Pelt J designed and coordinated the research, analyzed the data and wrote the paper.

**Institutional animal care and use committee statement:** All animal experiments were approved by the Ethical Committee for animal welfare (KU Leuven, P164/2010).

**Conflict-of-interest statement:** None of the authors report a potential conflict of interest regarding this work.

**Data sharing statement:** No additional data are available.

**Open-Access:** This article is an open-access article which was selected by an in-house editor and fully peer-reviewed by external reviewers. It is distributed in accordance with the Creative Commons Attribution Non Commercial (CC BY-NC 4.0) license, which permits others to distribute, remix, adapt, build upon this work non-commercially, and license their derivative works on different terms, provided the original work is properly cited and the use is non-commercial. See: <http://creativecommons.org/licenses/by-nc/4.0/>

**Manuscript source:** Unsolicited manuscript

**Correspondence to:** Dr. Jos van Pelt, Professor, Laboratory of Hepatology, Department of Clinical and Experimental Medicine, Faculty of Medicine, University of Leuven, Geb. Onderwijs and Navorsing 1, 7e verd, bus 703, Herestraat 49, B 3000 Leuven, Belgium. [jos.vanpelt@kuleuven.be](mailto:jos.vanpelt@kuleuven.be)  
Telephone: +32-16-330694  
Fax: +32-16-330701

**Received:** February 27, 2017

**Peer-review started:** March 2, 2017

**First decision:** April 5, 2017

**Revised:** May 16, 2017

**Accepted:** June 1, 2017

**Article in press:** June 1, 2017

**Published online:** August 14, 2017

## Abstract

### AIM

To develop a MRI-based method for accurate determination of liver volume (LV) and to explore the effect of long-term everolimus (EVR) treatment on LV in PCK

rats with hepatomegaly.

## METHODS

Thirty-one female PCK rats (model for polycystic-liver-disease: PCLD) were randomized into 3 groups and treatment was started at 16 wk, at the moment of extensive hepatomegaly (comparable to what is done in the human disease). Animals received: controls ( $n = 14$ ), lanreotide (LAN: 3 mg/kg per 2 wk) ( $n = 10$ ) or everolimus (EVR: 1 mg/kg per day) ( $n = 7$ ). LV was measured at week 16, 24, 28. At week 28, all rats were sacrificed and liver tissue was harvested. Fibrosis was evaluated using quantitative image analysis. In addition, gene (quantitative RT-PCR) and protein expression (by Western blot) of the PI3K/Akt/mTOR signaling pathway was investigated.

## RESULTS

LV determination by MRI correlated excellent with the *ex vivo* measurements ( $r = 0.99$ ,  $P < 0.001$ ). The relative changes in LV at the end of treatment were: (controls) +31.8%; (LAN) +5.1% and (EVR) +8.8%, indicating a significantly halt of LV progression compared with controls (respectively,  $P = 0.01$  and  $P = 0.04$ ). Furthermore, EVR significantly reduced the amount of liver fibrosis ( $P = 0.004$ ) thus might also prevent the development of portal hypertension. There was no difference in phosphorylation of Akt (Threonine 308) between LAN-treated PCK rats control PCK rats, whereas S6 was significantly more phosphorylated in the LAN group. Phosphorylation of Akt was not different between controls and EVR treated rats, however, for S6 there was significantly less phosphorylation in the EVR treated rats. Thus, both drugs interact with the PI3K/Akt/mTOR signaling cascade but acting at different molecular levels.

## CONCLUSION

Everolimus halts cyst growth comparable to lanreotide and reduces the development of fibrosis. mTOR-inhibition should be further explored in PCLD patients especially those that need immunosuppression.

**Key words:** Fibrocystic liver disease; mTOR inhibitor; Somatostatin analogue; Liver volume measurement; Magnetic resonance imaging

© The Author(s) 2017. Published by Baishideng Publishing Group Inc. All rights reserved.

**Core tip:** The continuous increase of liver cysts volume in polycystic-liver-disease (PCLD) leads to extensive hepatomegaly and portal hypertension, an indication for liver transplantation. The effect of mTOR-inhibition on liver volume (LV) in PCLD is unclear. We developed an accurate, non-invasive, MRI-based method to determine LV in a PCLD rat model. When treatment is started at the moment of extensive hepatomegaly (as in humans), the mTOR inhibitor everolimus halt disease progression and also of the development of fibrosis in this model. We speculate that everolimus, given after kidney

transplantation in patients with PCLD, can prevent the development of symptomatic hepatomegaly.

Temmerman F, Chen F, Libbrecht L, Vander Elst I, Windmolders P, Feng Y, Ni Y, De Smedt H, Nevens F, van Pelt J. Everolimus halts hepatic cystogenesis in a rodent model of polycystic-liver-disease. *World J Gastroenterol* 2017; 23(30): 5499-5507 Available from: URL: <http://www.wjgnet.com/1007-9327/full/v23/i30/5499.htm> DOI: <http://dx.doi.org/10.3748/wjg.v23.i30.5499>

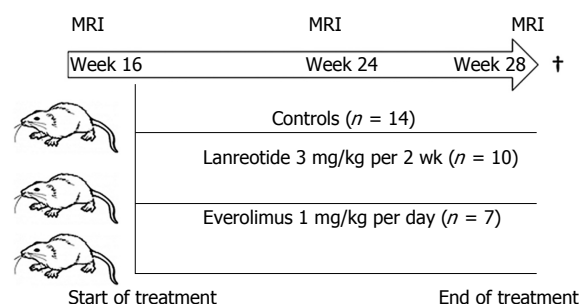
## INTRODUCTION

Polycystic liver disease (PCLD) is a fibrocystic liver diseases, a group of genetic disorders in which cysts occur either only in the liver, like in autosomal dominant PCLD, or in liver and the kidneys as in autosomal dominant polycystic kidney disease (ADPKD)<sup>[1,2]</sup>. In these patients due to the continuous increase in volume and number of cysts, the liver enlarges and may become disabling and in advanced stages, the patients develop portal hypertension<sup>[3]</sup>.

The rat *Pck* gene is orthologous to the human *PKHD1* gene and responsible for Autosomal Recessive Polycystic Kidney Disease. The animals have a splicing mutation in the *Pkhd1* gene encoding fibrocystin/polyductin (FPC). FPC and polycystin-1 and -2, -proteins mutated in human ADPKD-, are co-localized to the primary cilium of the cholangiocytes. The PCK rat is used worldwide as model to study PCLD<sup>[4-7]</sup>.

Two key signaling pathways have been implicated in the increased proliferation of PCK cholangiocytes leading to cyst formation. First, the defective ciliary structure in the cholangiocytes and integrated sensory/transducing functions result in a decreased intracellular  $Ca^{2+}$  and increased cytosolic cyclic adenosine monophosphate [cAMP]<sub>cyt</sub>, causing cholangiocyte proliferation, abnormal cell-matrix interactions, and altered fluid secretion. Basal levels of cAMP are maintained by the orchestration of multiple factors in which somatostatin receptors (*SSTRs*) play an important role. Octreotide, a somatostatin analogue, with high binding affinity for *SSTR2* and *5*, decreases [cAMP]<sub>cyt</sub> and reduces liver-cyst volume in the PCK rat. Both lanreotide (LAN) and octreotide reduce liver volume (LV) in patients with PCLD<sup>[8-13]</sup>.

The other important pathway involves the mammalian target of Rapamycin (*mTOR*). *mTOR* is a serine/threonine kinase present in two distinct complexes. The first is *mTOR* complex 1 (*mTORC1*), composed of *mTOR*, *Rptor* (*Raptor*: Regulatory Associated Protein of mTOR, Complex 1), *GβL*, and *DEPTOR*. It is a master growth-regulator that senses and integrates diverse nutritional and environmental factors. The second complex, *mTOR* complex 2 (*mTORC2*), is composed of *mTOR*, *Rictor*, *GβL*, *Sin1*,



**Figure 1 Study design.** Female PCK rats were obtained at age week 10. At week 16, a first MRI was performed to calculate the liver volume. Animals were randomly assigned to one of the groups and treatment was started. At week 24 and week 28 a new MRI was performed, after the last measurement the animals were sacrificed and tissue collected for protein and gene assay.

*PRR5/Protor-1*, and *DEPTOR*. mTORC2 promotes cellular survival by activating *Akt*, regulates cytoskeletal dynamics and controls ion transport and growth<sup>[14,15]</sup>. Increased activation of the Phosphatidylinositol-4,5-bisphosphate 3-kinase/*Akt*/ mTOR (*PI3K/Akt/mTOR*) pathway has also been shown to be involved in the cystic proliferation of cholangiocytes of the PCK rat. Sirolimus, an mTOR inhibitor, delayed cyst growth in the Han:SPRD rat model and in a mouse model of ADPKD<sup>[16,17]</sup>. In human ADPKD patients, sirolimus reduced LV in patients who underwent kidney transplantation in one study<sup>[18]</sup>. However, the evidence of a beneficial effect of mTOR inhibitors to reduce LV in the PCK rat and in prospective studies in humans is not robust<sup>[19,20]</sup>.

From preclinical studies performed in the PCK rat and from human PCLD data, it is clear that the hepatic cystic disease progression shows large inter-individual variability. To overcome this we explored the value of non-invasive repeated measurements of LV by MRI in the PCK rat.

The aims of the present study were therefore: (1) to develop an MRI-based method to evaluate accurately changes in LV in a rat model of PCLD; and (2) to investigate the long-term efficacy of everolimus (EVR) on liver disease when administered starting at the moment of already marked hepatomegaly, a situation mimicking the clinical situation.

## MATERIALS AND METHODS

### Experimental protocol

Thirty-one 10-wk-old female PCK rats (Charles River, France) were used for this study. This rat model is derived from a Crj:CD (Sprague Dawley) rat strain, originating in Japan<sup>[4-7]</sup>. The animals were housed in an environment with normal humidity and a 12/12 daylight cycle receiving a normal diet. They were randomly assigned to three groups: (1) controls; (2) LAN as positive control; or (3) EVR. At week 16, when the animals had developed extensive hepatomegaly, baseline MRI was performed. The next day, therapy

was started and continued for a period of 3 mo. No animals died or were excluded for other reasons over the entire study period. At indicated times (week 16, 24 and 28), serial MRI were performed (Figure 1). All rats were sacrificed the day after their last MRI at week 28 using Nembutal anesthesia. After vertical laparotomy, the hepatic hilum and hepatic veins were clipped simultaneously to avoid change in LV by loss of blood. Livers were removed, weighted and the *ex vivo* LV was determined using a graduated glass cylinder filled with saline 0.9% at 37 °C (accuracy of 1 mL). Tissue samples were stored for molecular analysis in Trizol (Invitrogen/Life Technologies, United States), snap-frozen for protein analysis and fixed with formalin for histology.

All animal experiments were approved by the Ethical Committee for animal welfare (KU Leuven, P164/2010).

### Study drugs

Lanreotide 3 mg/kg was administered every 2 wk intramuscular (somatuline, gift from Ipsen Pharma; Merelbeke, Belgium). Everolimus oral solution 1 mg/kg per day (Certican®; gift from Novartis Pharma; Basel, Switzerland) was administered *via* the drinking water without further additives. Dosages were chosen based on previous published data<sup>[10,12,20]</sup>. We used black drinking bottles to ensure light protection in the EVR group. Drug solutions were freshly prepared every morning and adjusted to body weight and fluid intake once weekly.

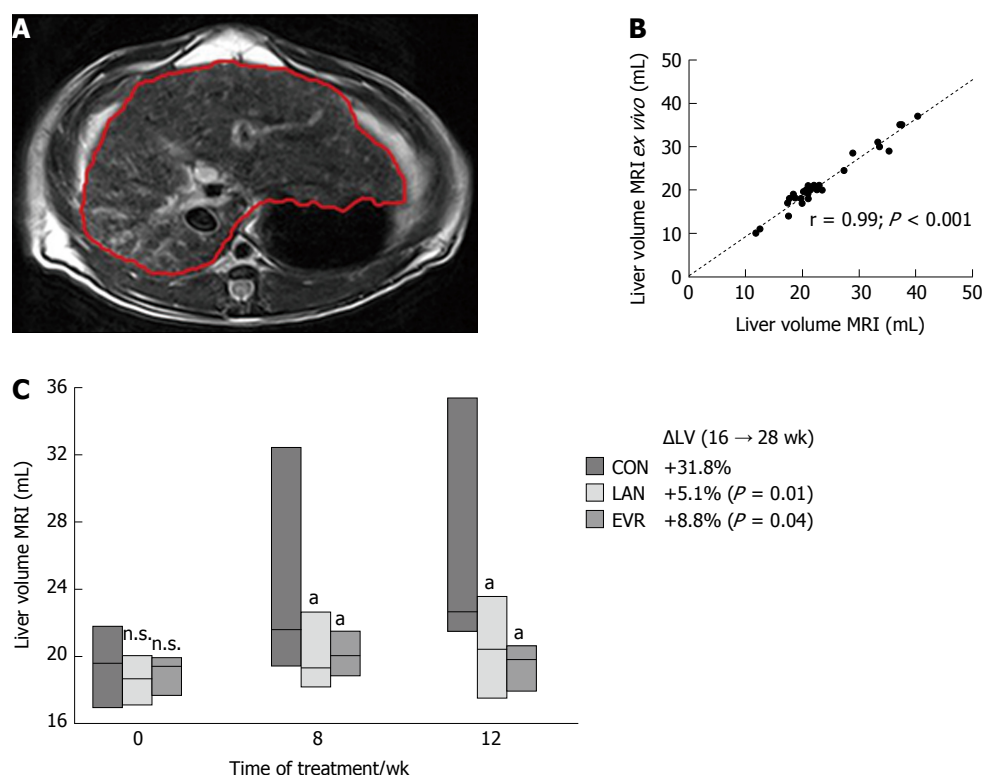
### Liver volumetry

The PCK rats were anaesthetized with Isoflurane 2% and placed in a human wrist coil. MRI scanning (1.5T MRI scanner; slice thickness 0.3 cm; inter-slice gap: 0.03 cm) for liver volumetry was performed by 3 radiologists, blinded for the study groups; on the day before the start of treatment (week 16), at week 24 and at week 28 (*i.e.*, 8 and 12 wk after the start of therapies). T1 and T2 weighted MR images were acquired. Liver area was measured and summed for all slices of T2 weighted images by using a built-in freehand region of interest (Figure 2A). Then, the LV was calculated using the following formula: LV =  $\sum$  liver area on each slice  $\times$  (slice thickness + gap).

### Fibrosis

Liver samples were fixed in buffered formalin (4%), washed in PBS and embedded in paraffin. Picrosirius red collagen staining was performed to measure fibrosis. All liver biopsies were analyzed by an expert liver pathologist, blinded for the groups. Fibrosis was assessed using Olympus Stream image analysis software 1.9 Software following image acquisition using a light microscope and color digital camera (Olympus CMOS camera SC30 Münster, Germany). Fibrosis was scored by 2 independent researchers and





**Figure 2 Liver volume measurements.** A: Demonstration of liver volume measured by MRI on each liver-containing slice of T2 weighted images. The liver margin is contoured manually with the red line; B: Correlation between liver volume calculated from MRI scan and liver volume measured *ex vivo*. Pearson correlation ( $r$ ) is given together with significance; C: Liver volume (mean  $\pm$  SE) determined by MRI for the different groups: CON (controls,  $n = 14$ ), LAN ( $n = 10$ ) and EVR ( $n = 7$ ), measured at start of treatment, and after 8 and 12 wk.  $^aP < 0.05$  vs animals in control group at corresponding time, NS: Not significant, vs control. The percentual change in LV ( $\Delta$ LV) over the 12 wk experimental period is shown together with the  $P$  value vs control group. LAN: Lanreotide; EVR: Everolimus.

expressed as percentage of total liver parenchyma from 4 random selected samples per animal.

### Western blotting

Liver samples stored at  $-80^\circ\text{C}$  were homogenized using Tissue Lyzer LT (Qiagen) in RIPA buffer at  $4^\circ\text{C}$  (50 mmol/L Tris pH 8.0, 150 mmol/L NaCl, 0.01% sodium dodecyl sulfate, 1% NP-40 (nonionic polyoxyethylene surfactant), 0.5% sodium desoxycholate, 1 mmol/L 1-phenylmethylsulfonyl fluoride) containing protease inhibitor mix (Complete Protease Inhibitor Cocktail, Roche Applied Science, Penzberg, Germany). Protein concentrations were assessed with the BCA-kit (Abcam, Cambridge United Kingdom) and the protein in the lysates were adjusted to the same concentration (40  $\mu\text{g}/20\ \mu\text{L}$ ). SDS sample buffer (62.5 mmol/L Tris, 10% glycerol, 2% sodium dodecyl sulfate, 0.05% Bromophenol blue and  $\beta$ -mercaptoethanol) was added, samples were boiled for 5 min and separated on miniprotein TGX anykD gel from Biorad (Biorad, Hercules, CA, United States). After electrotransfer to nitrocellulose membrane and blocking in Phosphate-buffered saline (PBS) containing 0.1% Tween and 5% non-fat dried milk, the membranes were overnight incubated with the primary antibody in PBS supplemented with 0.1% Tween and 5% non-fat dry milk powder. Antibodies used were: anti-P-S6Rp (Ser235/236, #4858), anti-Tot S6Rp (#2217), anti-

P-Akt (Thr308,#) anti-Tot Akt (#2967), all purchased from Cell Signaling Technology (Beverly, Massachusetts, United States), and  $\beta$ -actin (Sigma-Aldrich, St. Louis, MO, United States) as loading control. Thereafter, the corresponding secondary horseradish peroxidase-coupled antibodies were applied to the membranes for one hour (Dako, Heverlee, Belgium). After addition of enhanced chemiluminescence reagent (Pierce ECL Western Blotting Substrate, #32106, Thermo Scientific/Life Technologies, Carlsbad, CA, United States), digital detection was performed using ChemoDoc™ imaging system with Image Lab™ image acquisition software (Biorad). Expression of P-S6Rp, total S6Rp, P-Akt, and total Akt was normalized to  $\beta$ -actin levels. For comparison of different blots, a pool of liver homogenates of 28-wk-old Sprague Dawley rat livers was placed on each gel as internal control.

### Quantitative Real-Time polymerase chain reaction

Gene expression was assessed by quantitative reverse transcriptase polymerase chain reaction (qRT-PCR). RNA was isolated from tissue stored in Trizol with the RNeasy Kit (Qiagen, Chatsworth, CA, United States) according to the manufacturer's instructions. One microgram of cellular RNA was transcribed into cDNA using SuperScript II reverse transcriptase and random hexamer primers (Invitrogen/Life Technologies, United States). The PCR reaction was carried out in a mixture

**Table 1 Real-time polymerase chain reaction primer probes used in this study**

Gene	Full name	Assay ID applied biosystems
<i>SSTR2</i>	somatostatin receptor 2	Rn01464950_g1
<i>SSTR5</i>	somatostatin receptor 5	Rn02535169_s1
<i>mTOR</i>	mechanistic target of rapamycin (serine/threonine kinase)	Rn00693900_m1
<i>Rptor</i>	regulatory associated protein of mTOR, complex 1	Rn01464431_m1
<i>B2M</i>	beta-2 microglobulin	Rn00560865_m1

that contained appropriate sense- and anti-sense primers and a probe in Taqman Universal PCR Master Mixture (Applied Biosystems, Foster City, United States) (Table 1).  $\beta$ -2 microglobulin (*B2M*) was used as house-keeping gene. Each sample was assayed in duplicate on an A7500 Fast Real-Time PCR System (Applied Biosystems). The mean  $\Delta C_t$  value (with SE) vs the reference (*B2M*) was calculated.

### Statistical analysis

Data were analyzed using MedCalc version 14.12.0 (Medcalc, Ostend, Belgium: <http://www.medcalc.org>). Descriptive statistics including mean and SE for continuous variables were computed or median with IQR (interquartile range) (25%-75%) as appropriate. Differences in continuous variables between treated and non-treated rats were investigated using, One Way ANOVA, *t*-test for independent samples or the Mann Whitney *U* test, as appropriate. Repeated measurements ANOVA and serial measurements were used to compare paired observations between groups, as appropriate. To assess correlations, non-parametric testing Pearson correlation coefficient was determined. Bland-Altman plots assessed agreement in accuracy of the techniques. To compare percentages between groups,  $\chi^2$  was used. All *P* values resulted from two-sided statistical tests, and *P* < 0.05 is considered significant.

## RESULTS

### Liver volume

To validate MRI as a tool, we determined LV by two methods. (1) *In vivo* LV was determined by MRI (Figure 2A); and (2) To measure the LV *ex vivo*, we removed the liver at the end of the experiment (week 28, corresponding with 3 mo of treatment). Pearson correlation between *in vivo* LV (MRI) and *ex vivo* LV was excellent ( $r = 0.99$ ,  $P < 0.001$ ) (Figure 2B) and that allows us to use MRI as a reliable method to explore LV. At baseline rat body weight (gram) in the 3 groups: controls, LAN and EVR were not different, respectively: 316 (SE: 3.2); 318 (SE: 5.6) and 299 (SE: 2.7). Also at baseline, the median LV's (range) for controls, LAN and EVR, were not different, respectively: 19.6 mL

(17.0; 21.7); 18.7 mL (17.0; 20.0); 19.4 mL (17.8; 20.6) ( $P = 0.754$ ). The mean of the relative increase in LV (95%CI) in the 3 groups after 12 wk of treatment (from week 16 to week 28) was respectively: +31.8% (19.0;44.0); +5.1% (-12.0; 23.0) and +8.8% (-1.7; 19.0). Both treatment groups (LAN, EVR) significantly halted LV progression compared with controls ( $P = 0.01$  and  $P = 0.04$ ). The absolute LVs at different times are given in Figure 2C. There was no significant difference in effect on LV between LAN and EVR after 8 wk or 12 wk of treatment.

### Fibrosis

Fibrosis, scored independently by 2 researchers, showed excellent agreement with a difference of 0.5% (95%CI: -0.2-1.3). In the 14 control PCK rats [mean percentage fibrosis: 14.7% (SE: 1.8)], we found a strong Pearson correlation (*r*) between LV (MRI) and the relative amount of fibrosis ( $r = 0.93$ ;  $P < 0.0001$ ) (Figure 3A). EVR significantly suppressed the development of fibrosis in PCK rats ( $P = 0.004$ ) whereas LAN showed a trend to reduction ( $P = 0.095$ ) (Figure 3B). Representative histological images of picrosirius red staining are shown in Figure 3C.

### Protein expression

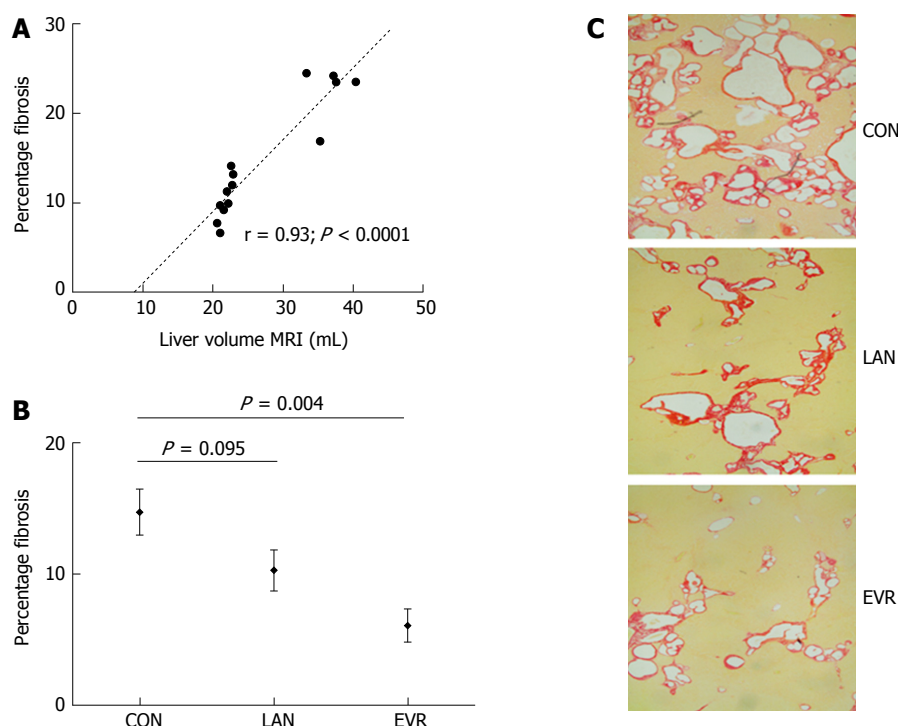
Expression of components of the PI3K/Akt/mTOR pathway was investigated. In the control animals, we observed a very strong correlation between the p-Akt/Akt phosphorylation ratio and the LV ( $r = 0.7$ ,  $P < 0.003$ ) while the p-S6/S6 ratio correlated only moderately ( $r = 0.47$ ,  $P = 0.088$ ) (Figure 4A).

There was no difference in phosphorylation of Akt (Threonine 308) between LAN-treated PCK rats control PCK rats, whereas S6 was significantly more phosphorylated in the LAN group. The p-S6/S6 ratios for LAN and controls were respectively: 2.01 (0.98; 2.53) and 0.33 (0.16; 0.76) ( $P < 0.001$ ). The level of phosphorylation of Akt at Threonine 308 was not different between controls and EVR treated rats. However, S6 was significantly less phosphorylated in the EVR treated rats (Figure 4C and D).

These observations indicate that both drugs interact with the PI3K/Akt/mTOR signaling cascade but acting at different molecular levels (Figure 4B), both mechanisms leading to halting of the disease in this model of PCLD.

### Gene expression

LAN and EVR treated rats showed a significant lower gene expression of *SSTR2* while expression of *SSTR5* was increased (borderline significant) in the LAN treated rats (Figure 5). EVR treatment resulted in a decreased *SSTR5* gene expression compared to LAN treated animals. After 12 wk of treatment, we observed an increased gene expression of *mTOR* but not of *Rptor* in the EVR treated rats vs controls. LAN treatment did not affect gene expression of *mTOR*. Demonstrating again that both drugs have different



**Figure 3** Liver fibrosis in PCK rats and effect of treatment with lanreotide or everolimus. Picosirius red collagen staining was performed on formalin fixed, paraffin embedded liver tissue, staining was assessed using Olympus Stream image analysis software 1.9 Software. Fibrosis was expressed as percentage of total liver parenchyma from 4 random selected samples per animal. A: Pearson correlation ( $r$ ) and significance for liver volume with fibrosis in control animals; B: Amount of fibrosis relative to total parenchyma in the livers of PCK rats after 12 wk of treatment with LAN or EVR and in controls. Results are given as mean and SE; C: Representative images of the amount of fibrosis by picosirius red staining in the 3 groups (original magnification  $\times 40$ ). CON: Control; LAN: Lanreotide; EVR: Everolimus.

mechanisms of action on cyst growth.

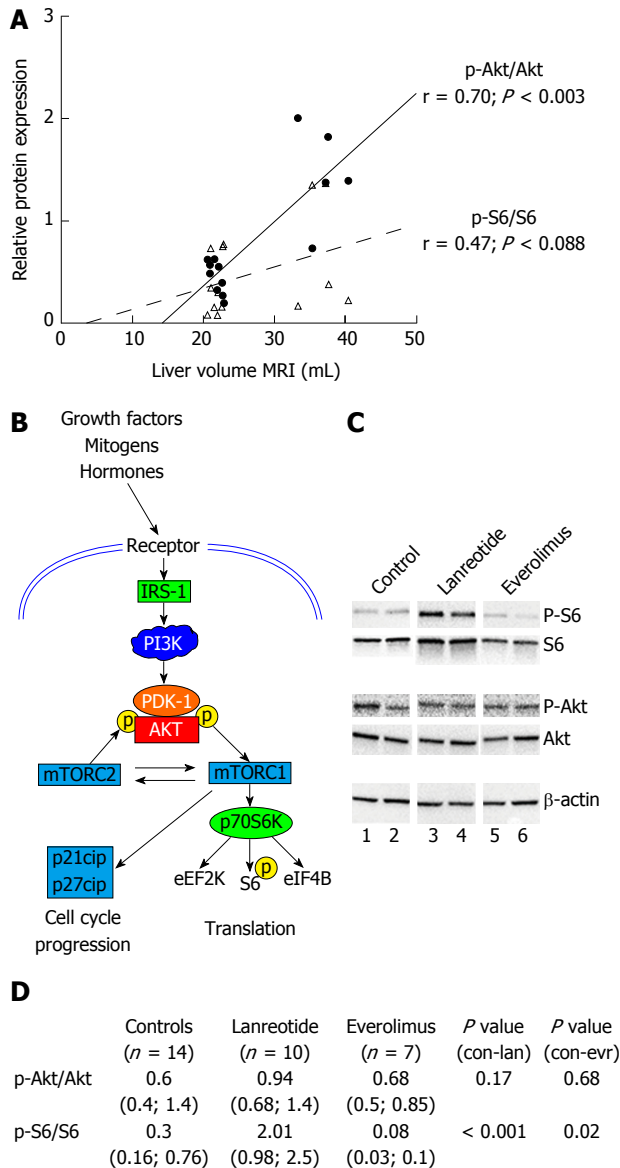
## DISCUSSION

Similar to what is observed in human PCLD patients; we found a large inter- and intra-litter variation of the severity of hepatic polycystic disease in the PCK model, which had previously also been found by Mason *et al.*<sup>[21]</sup>. Therefore, there is a great need for a reliable technique that can accurately assess LV in this animal model and further that allows repeated measurements during drug treatment. High Resolution Ultrasonography has recently been used to assess renal cysts in the PCK rats<sup>[22]</sup>. Also, as an indirect assessment method, T1 relaxation time was proposed as an imaging marker of liver disease for the PCK model<sup>[23]</sup> but neither of these was used to determine LV. For the current study, we explored MRI T2 weighted images to longitudinally measure LV and to investigate individual responses. We validated this method in the PCK model. We showed that it is accurate and reproducible, with an excellent correlation between LV determined by MRI and *ex vivo* LV determination. The assessment with MRI allowed us to detect changes in the same animal in time accurately. Treatment with LAN was used as positive treatment control and as expected, we observed an increase in LV with placebo and a stabilization with LAN, an observation similar to what is seen in patients with PCLD<sup>[10-13]</sup>.

Important to note is that no animals died or were excluded for other reasons over the entire study period. Using this non-invasive technique, we could drastically reduce the number of animals necessary for this study.

In the present study, we investigated the effect of the mTOR inhibitor EVR on cyst growth since its effect in humans or in the corresponding animal model, is still unclear and controversial due to the limited number of available studies<sup>[20,24]</sup>. We found that EVR prevented cyst enlargement in the PCK rat model, using a clinical relevant experimental design in which we started the treatment at the moment of severe hepatomegaly, mimicking the clinical situation in humans. The study was restricted to female rats since symptomatic PCLD mainly affects mostly women and because it has been demonstrated that female PCK rats display a more progressive liver enlargement compared to male PCK rats.

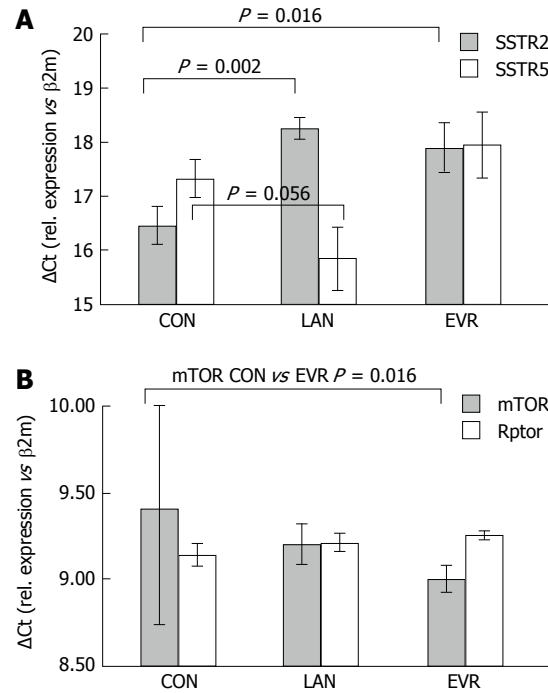
Treatment with LAN induced a reduction of *SSTR2* gene expression (in agreement with the expected molecular effect of LAN). In line with previous findings of Masyuk *et al.*<sup>[8]</sup> with octreotide and pasireotide, we also observed upon treatment with LAN a mild reduction in fibrosis compared to untreated animals that might be an indirect effect of lower growth of the liver cysts. With EVR however, we observed a significant reduction of the amount of fibrosis, which may be explained by the well-known direct effect



**Figure 4** Analysis of protein expression of components of PI3K/AKT/mTOR pathway by Western blot in livers of PCK rats after 12 wk of treatment. A: phosphorylation ratio in untreated animals: correlation between p-Akt/Akt ratio and p-S6/S6 ratio with liver volume. Pearson correlation ( $r$ ) is given together with significance; B: Simplified schematic presentation of PI3K/AKT/mTOR signaling pathway; C: shows two representative samples from each experimental group; D: shows relative expression mean (range) of phosphorylated Akt vs total Akt (p-Akt/Akt) and S6 vs total S6 (p-S6/S6) with  $n$  as number of animals analyzed. Expression of proteins was normalized to  $\beta$ -actin levels.

of mTOR inhibition on fibrosis progression<sup>[25]</sup>. Since PCLD, belonging to the fibrocystic liver diseases, is complicated in a later stage by portal hypertension, the present observations further support an additional potential clinical benefit of this drug on portal hypertension by reducing the amount of fibrosis.

The molecular observations made in this model (the combination of protein and gene expression) indicate a dysregulation of the PI3K/Akt/mTOR signaling cascade by both LAN and EVR, each acting at a different level and both mechanisms leading to halting of the disease.



**Figure 5** Liver gene expression of target genes for LAN treatment (SSTR2, SSTR5) and for PI3K/Akt/mTOR pathway (mTOR, Rptor). A: expression of the Somatostatin receptors SSTR2 and SSTR5; B: expression of mTOR and of Rptor. The mean for delta Ct value (with SE) is given vs that for the reference (housekeeping gene)  $\beta 2M$ . To be noted, a higher value means a lower expression. CON: Control; LAN: Lanreotide; EVR: Everolimus.

mTOR is a serine/threonine kinase and can form two protein complexes: mTORC1 (mTOR, Rptor), which is inhibited EVR, and mTORC2 (mTOR, Rictor). Ribosomal protein S6 kinase (S6K) is the direct downstream target of mTORC1 and regulates the downstream translational initiation machinery to control cell growth, proliferation and autophagy. mTORC 2 controls actin cytoskeleton and resistance to apoptosis. In animals treated with EVR, we observed an increased mTOR gene expression which is probably due to the prolonged administration of EVR in an attempt of the cell to compensate for the inhibitory effects of EVR on mTOR. S6-protein, downstream of mTOR, was less phosphorylated in EVR-treated animals compared to control PCK rats. Renken and colleagues investigated sirolimus in PCK rats, the time-dependent effect was assessed by using different groups sacrificed at different time points. No longitudinal follow-up of LV in the same animal was performed their study. They could only observe subtle effects of sirolimus on mTOR-specific S6 kinase in the liver<sup>[26]</sup>. The large inter- and intra-litter variability of hepatic disease progression may explain why they in their study could not observe a beneficial effect on liver disease progression. Further studies on the molecular mechanisms involved in PCLD in (pre)clinical models are needed.

In conclusion, our method of LV measurement with MRI is shown to be highly sensitive and allowed us to detect accurately changes in time in a non-invasive way. Long-term everolimus treatment halts liver cyst



growth and reduces the development of fibrosis in this rat model. Our observations support the rational to explore further everolimus for the prevention of the development of symptomatic liver disease, such as in patients with ADPKD after kidney transplantation who are in need of an immunosuppressive drug.

## COMMENTS

### Background

The polycystic liver diseases (PCLD) represent a group of genetic disorders, in which cysts occur in the liver (ADPLD), or occur as well in the liver as in the kidneys (ADPKD). In PCLD, the liver becomes polycystic at a late stage, e.g., in ADPKD patients, the prevalence is 85%, and 94% in subgroups of age (resp. 25 to 34, and 35 to 46 year). Most of the patients with PCLD are asymptomatic; however, in a subpopulation of 1%-3%, expansion of liver cysts cause invalidating abdominal symptoms furthermore, symptomatic ADPLD patients are mainly females. The most common complication in patients with PCLD is extensive hepatomegaly, which may lead to malnutrition and can be lethal and cyst-related complications include hemorrhage, infections, and rupture. There is no medical treatment approved for PCLD and to date, the only definitive treatment in those patients with large liver volumes (LV) is liver transplantation (LT).

### Research frontiers

Octreotides and lanreotides have been shown to reduce LV in patients with PCLD, beneficial effects of mTOR-inhibition in patients is still a matter of debate. This was investigated in these experiments in the PCK-rat model of PCLD as preclinical evaluation. The authors designed the study representative for the hospital situation and started treatment at the moment of marked hepatomegaly (representing the symptomatic female patient). They developed and validated a MRI-based method to determine LV that can be used for longitudinal follow-up of disease progression and supported the observations with molecular analysis.

### Innovations and breakthroughs

The authors developed a unique MRI-based method that was shown to be sensitive and statistically reliable. Repeat measurements allowed for monitoring individual responses and reducing the number of animals required for this type of study. This method is a great step forward for it allows preclinical testing of drugs for PCLD under controlled conditions. Everolimus looks beneficial to reduce the cyst volume in PCLD with a secondary benefit on fibrosis.

### Applications

The imaging technique that they describe can be used to study drugs or drug combinations in preclinical setting in the representative animal model of PCK rats that for logistic reasons (number of symptomatic patients, slow progress of the disease, inter-individual variation of progression) is difficult to organize in patients. Ultimately, this approach can lead to a reduction of patients that require a transplantation. Polycystic liver and kidney diseases are closely related. Kidney transplantation is a frequent treatment for autosomal dominant polycystic kidney disease (ADPKD, autosomal dominant PKD or adult-onset PKD), and this study gives arguments to use everolimus in patients that need immunosuppression as it can have beneficial effects for the livers at risk in ADPKD patients and complications due to progressive fibrosis.

### Peer-review

In this study, authors have shown that everolimus halts hepatic cystogenesis in a rodent model of PCLD. They have developed a MRI-based method for accurate determination of LV and investigated that everolimus halted cyst growth comparable to lanreotide and reduced the development of fibrosis, mTOR-inhibition should be further explored in PCLD patients especially those that need immunosuppression. The study has been well performed.

## REFERENCES

1 Desmet VJ. Ludwig symposium on biliary disorders--part I.

- Pathogenesis of ductal plate abnormalities. *Mayo Clin Proc* 1998; **73**: 80-89 [PMID: 9443684 DOI: 10.1016/S0025-6196(11)63624-0]
- 2 Temmerman F, Missiaen L, Bammens B, Laleman W, Cassiman D, Verslype C, van Pelt J, Nevens F. Systematic review: the pathophysiology and management of polycystic liver disease. *Aliment Pharmacol Ther* 2011; **34**: 702-713 [PMID: 21790682 DOI: 10.1111/j.1365-2036.2011.04783.x]
- 3 Van Keimpema L, De Koning DB, Van Hoek B, Van Den Berg AP, Van Oijen MG, De Man RA, Nevens F, Drenth JP. Patients with isolated polycystic liver disease referred to liver centres: clinical characterization of 137 cases. *Liver Int* 2011; **31**: 92-98 [PMID: 20408955 DOI: 10.1111/j.1478-3231.2010.02247.x]
- 4 Katsuyama M, Masuyama T, Komura I, Hibino T, Takahashi H. Characterization of a novel polycystic kidney rat model with accompanying polycystic liver. *Exp Anim* 2000; **49**: 51-55 [PMID: 10803363 DOI: 10.1538/expanim.49.51]
- 5 Lager DJ, Qian Q, Bengal RJ, Ishibashi M, Torres VE. The pck rat: a new model that resembles human autosomal dominant polycystic kidney and liver disease. *Kidney Int* 2001; **59**: 126-136 [PMID: 11135065 DOI: 10.1046/j.1523-1755.2001.00473.x]
- 6 Ward CJ, Hogan MC, Rossetti S, Walker D, Sneddon T, Wang X, Kubly V, Cunningham JM, Bacallao R, Ishibashi M, Milliner DS, Torres VE, Harris PC. The gene mutated in autosomal recessive polycystic kidney disease encodes a large, receptor-like protein. *Nat Genet* 2002; **30**: 259-269 [PMID: 11919560 DOI: 10.1038/ng833]
- 7 Banales JM, Masyuk TV, Gradilone SA, Masyuk AI, Medina JF, LaRusso NF. The cAMP effectors Epac and protein kinase a (PKA) are involved in the hepatic cystogenesis of an animal model of autosomal recessive polycystic kidney disease (ARPKD). *Hepatology* 2009; **49**: 160-174 [PMID: 19065671 DOI: 10.1002/hep.22636]
- 8 Masyuk TV, Masyuk AI, Torres VE, Harris PC, Larusso NF. Octreotide inhibits hepatic cystogenesis in a rodent model of polycystic liver disease by reducing cholangiocyte adenosine 3',5'-cyclic monophosphate. *Gastroenterology* 2007; **132**: 1104-1116 [PMID: 17383431 DOI: 10.1053/j.gastro.2006.12.039]
- 9 Hogan MC, Masyuk TV, Page LJ, Kubly VJ, Bergstralh EJ, Li X, Kim B, King BF, Glockner J, Holmes DR, Rossetti S, Harris PC, LaRusso NF, Torres VE. Randomized clinical trial of long-acting somatostatin for autosomal dominant polycystic kidney and liver disease. *J Am Soc Nephrol* 2010; **21**: 1052-1061 [PMID: 20431041 DOI: 10.1681/ASN.2009121291]
- 10 van Keimpema L, Nevens F, Vanslambrouck R, van Oijen MG, Hoffmann AL, Dekker HM, de Man RA, Drenth JP. Lanreotide reduces the volume of polycystic liver: a randomized, double-blind, placebo-controlled trial. *Gastroenterology* 2009; **137**: 1661-1668.e1-2 [PMID: 19646443 DOI: 10.1053/j.gastro.2009.07.052]
- 11 Gevers TJ, Inthout J, Caroli A, Ruggerenti P, Hogan MC, Torres VE, Nevens F, Drenth JP. Young women with polycystic liver disease respond best to somatostatin analogues: a pooled analysis of individual patient data. *Gastroenterology* 2013; **145**: 357-365.e1-2 [PMID: 23665274 DOI: 10.1053/j.gastro.2013.04.055]
- 12 Temmerman F, Gevers T, Ho TA, Vanslambrouck R, Coudyzer W, van Pelt J, Bammens B, Pirson Y, Drenth JP, Nevens F. Safety and efficacy of different lanreotide doses in the treatment of polycystic liver disease: pooled analysis of individual patient data. *Aliment Pharmacol Ther* 2013; **38**: 397-406 [PMID: 23799922 DOI: 10.1111/apt.12384]
- 13 Temmerman F, Ho TA, Vanslambrouck R, Coudyzer W, Billen J, Dobbels F, van Pelt J, Bammens B, Pirson Y, Nevens F. Lanreotide Reduces Liver Volume, But Might Not Improve Muscle Wasting or Weight Loss, in Patients With Symptomatic Polycystic Liver Disease. *Clin Gastroenterol Hepatol* 2015; **13**: 2353-2359.e1 [PMID: 26073493 DOI: 10.1016/j.cgh.2015.05.039]
- 14 Laplante M, Sabatini DM. mTOR signaling in growth control and disease. *Cell* 2012; **149**: 274-293 [PMID: 22500797 DOI: 10.1016/j.cell.2012.03.017]
- 15 Ren XS, Sato Y, Harada K, Sasaki M, Furubo S, Song JY, Nakanuma Y. Activation of the PI3K/mTOR pathway is involved

- in cystic proliferation of cholangiocytes of the PCK rat. *PLoS One* 2014; **9**: e87660 [PMID: 24498161 DOI: 10.1371/journal.pone.0087660]
- 16 **Wahl PR**, Serra AL, Le Hir M, Molle KD, Hall MN, Wüthrich RP. Inhibition of mTOR with sirolimus slows disease progression in Han: SPRD rats with autosomal dominant polycystic kidney disease (ADPKD). *Nephrol Dial Transplant* 2006; **21**: 598-604 [PMID: 16221708 DOI: 10.1093/ndt/gfi181]
  - 17 **Zafar I**, Ravichandran K, Belibi FA, Doctor RB, Edelstein CL. Sirolimus attenuates disease progression in an orthologous mouse model of human autosomal dominant polycystic kidney disease. *Kidney Int* 2010; **78**: 754-761 [PMID: 20686448 DOI: 10.1038/ki.2010.250]
  - 18 **Qian Q**, Du H, King BF, Kumar S, Dean PG, Cosio FG, Torres VE. Sirolimus reduces polycystic liver volume in ADPKD patients. *J Am Soc Nephrol* 2008; **19**: 631-638 [PMID: 18199797 DOI: 10.1681/ASN.2007050626]
  - 19 **Walz G**, Budde K, Manna M, Nürnberger J, Wanner C, Sommerer C, Kunzendorf U, Banas B, Hörl WH, Obermüller N, Arns W, Pavenstädt H, Gaedeke J, Büchert M, May C, Gschaidmeier H, Kramer S, Eckardt KU. Everolimus in patients with autosomal dominant polycystic kidney disease. *N Engl J Med* 2010; **363**: 830-840 [PMID: 20581392 DOI: 10.1056/NEJMoa1003491]
  - 20 **Chrispijn M**, Gevers TJ, Hol JC, Monshouwer R, Dekker HM, Drenth JP. Everolimus does not further reduce polycystic liver volume when added to long acting octreotide: results from a randomized controlled trial. *J Hepatol* 2013; **59**: 153-159 [PMID: 23499726 DOI: 10.1016/j.jhep.2013.03.004]
  - 21 **Mason SB**, Liang Y, Sindors RM, Miller CA, Eggleston-Gulyas T, Crisler-Roberts R, Harris PC, Gattone VH. Disease stage characterization of hepatorenal fibrocystic pathology in the PCK rat model of ARPKD. *Anat Rec (Hoboken)* 2010; **293**: 1279-1288 [PMID: 20665806 DOI: 10.1002/ar.21166]
  - 22 **Kapoor S**, Rodriguez D, Mitchell K, Wüthrich RP. High Resolution Ultrasonography for Assessment of Renal Cysts in the PCK Rat Model of Autosomal Recessive Polycystic Kidney Disease. *Kidney Blood Press Res* 2016; **41**: 186-196 [PMID: 26981631 DOI: 10.1159/000443420]
  - 23 **Gao Y**, Erokwu BO, DeSantis DA, Croniger CM, Schur RM, Lu L, Mariappuram J, Dell KM, Flask CA. Initial evaluation of hepatic T1 relaxation time as an imaging marker of liver disease associated with autosomal recessive polycystic kidney disease (ARPKD). *NMR Biomed* 2016; **29**: 84-89 [PMID: 26608869 DOI: 10.1002/nbm.3442]
  - 24 **Khan S**, Dennison A, Garcea G. Medical therapy for polycystic liver disease. *Ann R Coll Surg Engl* 2016; **98**: 18-23 [PMID: 26688394 DOI: 10.1308/acsann.2016.0023]
  - 25 **Patsenker E**, Schneider V, Ledermann M, Saegesser H, Dorn C, Hellerbrand C, Stickel F. Potent antifibrotic activity of mTOR inhibitors sirolimus and everolimus but not of cyclosporine A and tacrolimus in experimental liver fibrosis. *J Hepatol* 2011; **55**: 388-398 [PMID: 21168455 DOI: 10.1016/j.jhep.2010.10.044]
  - 26 **Renken C**, Fischer DC, Kundt G, Gretz N, Haffner D. Inhibition of mTOR with sirolimus does not attenuate progression of liver and kidney disease in PCK rats. *Nephrol Dial Transplant* 2011; **26**: 92-100 [PMID: 20615907 DOI: 10.1093/ndt/gfq384]

P- Reviewer: Dang SS S- Editor: Gong ZM L- Editor: A  
E- Editor: Zhang FF



## Basic Study

# MicroRNA profile in neosquamous esophageal mucosa following ablation of Barrett's esophagus

Loveena Sreedharan, George C Mayne, David I Watson, Timothy Bright, Reginald V Lord, Alfiya Ansar, Tingting Wang, Jakob Kist, David StJ Astill, Damian J Hussey

Loveena Sreedharan, George C Mayne, David I Watson, Timothy Bright, Alfiya Ansar, Tingting Wang, Jakob Kist, Damian J Hussey, Department of Surgery, Flinders Medical Centre, Flinders University, Adelaide, SA 5042, Australia

Reginald V Lord, St Vincent's Centre for Applied Medical Research, Sydney, NSW 2011, Australia

David StJ Astill, Department of Anatomical Pathology, Flinders Medical Centre, Adelaide, SA 5042, Australia

**Author contributions:** Watson DI, Bright T, Lord RV and Hussey DJ designed and coordinated the research; Watson DI, Lord RV and Hussey DJ obtained the funding that supported this research; Watson DI and Bright T collected patient samples; Sreedharan L, Ansar A, Wang T and Kist J prepared the tissue samples and performed the molecular studies; Sreedharan L, Mayne GC and Hussey DJ analyzed the data; Astill DS performed the histopathology; Sreedharan L, Mayne GC and Hussey DJ wrote the first draft of the paper; all authors contributed to revision of the manuscript in its final version.

**Supported by** National Health and Medical Research Council, Australia, No. APP1008337.

**Institutional review board statement:** This study was reviewed and approved by the Southern Adelaide Clinical Human Research Ethics Committee.

**Conflict-of-interest statement:** The authors have no conflicts of interest to declare.

**Data sharing statement:** Datasets have been made available on the Gene Expression Omnibus (GEO) website, Accession number GSE94854. The data can be downloaded from <https://www.ncbi.nlm.nih.gov/geo/info/download.html>.

**Open-Access:** This article is an open-access article which was selected by an in-house editor and fully peer-reviewed by external reviewers. It is distributed in accordance with the Creative Commons Attribution Non Commercial (CC BY-NC 4.0) license, which permits others to distribute, remix, adapt, build upon this

work non-commercially, and license their derivative works on different terms, provided the original work is properly cited and the use is non-commercial. See: <http://creativecommons.org/licenses/by-nc/4.0/>

**Manuscript source:** Invited manuscript

**Correspondence to:** Damian J Hussey, PhD, Department of Surgery, Flinders Medical Centre, Flinders University, Bedford Park, Adelaide, SA 5042, Australia. [damian.hussey@flinders.edu.au](mailto:damian.hussey@flinders.edu.au)  
**Telephone:** +61-8-82046091  
**Fax:** +61-8-82046130

**Received:** February 27, 2017

**Peer-review started:** February 28, 2017

**First decision:** April 16, 2017

**Revised:** May 18, 2017

**Accepted:** July 4, 2017

**Article in press:** July 4, 2017

**Published online:** August 14, 2017

## Abstract

### AIM

To investigate the microRNA expression profile in esophageal neosquamous epithelium from patients who had undergone ablation of Barrett's esophagus.

### METHODS

High throughput screening using TaqMan® Array Human MicroRNA quantitative PCR was used to determine expression levels of 754 microRNAs in distal esophageal mucosa (1 cm above the gastro-esophageal junction) from 16 patients who had undergone ablation of non-dysplastic Barrett's esophagus using argon plasma coagulation *vs* pretreatment mucosa, post-treatment proximal normal non-treated esophageal mucosa, and esophageal mucosal biopsies from 10

controls without Barrett's esophagus. Biopsies of squamous mucosa were also taken from 5 cm above the pre-ablation squamo-columnar junction. Predicted mRNA target pathway analysis was used to investigate the functional involvement of differentially expressed microRNAs.

## RESULTS

Forty-four microRNAs were differentially expressed between control squamous mucosa *vs* post-ablation neosquamous mucosa. Nineteen microRNAs were differentially expressed between post-ablation neosquamous and post-ablation squamous mucosa obtained from the more proximal non-treated esophageal segment. Twelve microRNAs were differentially expressed in both neosquamous *vs* matched proximal squamous mucosa and neosquamous *vs* squamous mucosa from healthy patients. Nine microRNAs (miR-424-5p, miR-127-3p, miR-98-5p, miR-187-3p, miR-495-3p, miR-34c-5p, miR-223-5p, miR-539-5p, miR-376a-3p, miR-409-3p) were expressed at higher levels in post-ablation neosquamous mucosa than in matched proximal squamous and healthy squamous mucosa. These microRNAs were also more highly expressed in Barrett's esophagus mucosa than matched proximal squamous and squamous mucosa from controls. Target prediction and pathway analysis suggests that these microRNAs may be involved in the regulation of cell survival signalling pathways. Three microRNAs (miR-187-3p, miR-135b-5p and miR-31-5p) were expressed at higher levels in post-ablation neosquamous mucosa than in matched proximal squamous and healthy squamous mucosa. These miRNAs were expressed at similar levels in pre-ablation Barrett's esophagus mucosa, matched proximal squamous and squamous mucosa from controls. Target prediction and pathway analysis suggests that these microRNAs may be involved in regulating the expression of proteins that contribute to barrier function.

## CONCLUSION

Neosquamous mucosa arising after ablation of Barrett's esophagus expresses microRNAs that may contribute to decreased barrier function and microRNAs that may be involved in the regulation of survival signaling pathways.

**Key words:** Neosquamous; Barrett's esophagus; Ablation

© The Author(s) 2017. Published by Baishideng Publishing Group Inc. All rights reserved.

**Core tip:** We report that the microRNA profile of esophageal neosquamous mucosa developing after ablation of Barrett's esophagus is different to normal squamous epithelium, and that the differentially expressed microRNAs in neosquamous mucosa may regulate survival signalling pathways and contribute to decreased barrier function in the esophagus.

Sreedharan L, Mayne GC, Watson DI, Bright T, Lord RV, Ansar A, Wang T, Kist J, Astill DS, Hussey DJ. MicroRNA profile in neosquamous esophageal mucosa following ablation of Barrett's esophagus. *World J Gastroenterol* 2017; 23(30): 5508-5518 Available from: URL: <http://www.wjgnet.com/1007-9327/full/v23/i30/5508.htm> DOI: <http://dx.doi.org/10.3748/wjg.v23.i30.5508>

## INTRODUCTION

The incidence of esophageal adenocarcinoma has increased rapidly in the western world over recent decades, with overall 5-year survival rates of approximately 15%<sup>[1]</sup>. A strategy to improve survival outcome is early detection of cancer, or detection at the pre-malignant stage - high grade dysplasia. Barrett's esophagus is the precursor to adenocarcinoma<sup>[2]</sup>, and results from a metaplastic change of normal esophageal squamous epithelium to columnar epithelium with intestinal differentiation<sup>[3,4]</sup>. This is a consequence of chronic gastro-esophageal reflux, and it can be identified in 1%-2% of individuals aged over 60<sup>[4]</sup>. Barrett's esophagus progresses to cancer in a sequential manner through low and then high grade dysplasia<sup>[2]</sup>. The risk of progression of non-dysplastic Barrett's esophagus to adenocarcinoma has been reported to be 0.2%-0.5% per patient year for patients enrolled in surveillance programs<sup>[1]</sup>.

Endoscopic surveillance remains the mainstay of cancer prevention in individuals with Barrett's esophagus, and definitive management by surgery or endoscopy is reserved for individuals who develop high grade dysplasia or cancer<sup>[5]</sup>. Several endoscopic treatments are widely used for the treatment of high grade dysplasia or early cancer in Barrett's esophagus, including radiofrequency ablation, argon plasma coagulation, and endoscopic mucosal resection.

Generally, endoscopic therapy for Barrett's esophagus aims to completely eradicate any columnar mucosa, although persistent genomic alterations at tumour suppressor loci have been found after ablation<sup>[6]</sup>. Even though endoscopic removal of Barrett's esophagus by ablative therapies is possible in the majority of patients<sup>[7]</sup>, there is still a risk of recurrence and progression to adenocarcinoma following complete eradication of Barrett's esophagus. As a result endoscopically treated patients are maintained under surveillance<sup>[4]</sup>.

There have also been concerns about the risk of recurrence associated with residual sub-squamous glandular tissue which is not visible with a white light endoscope. However, Basu *et al*<sup>[8]</sup> reported that sub-squamous glandular tissue was not associated with recurrence of Barrett's esophagus in patients with effective acid suppression after argon plasma



coagulation ablation, and newer ablation modalities such as radio frequency ablation appear to have largely eliminated this problem<sup>[9]</sup>, due to increased control of depth and uniformity of tissue ablation<sup>[10]</sup>. There have been several reports of patients progressing to cancer in whom Barrett's esophagus has been completely eradicated<sup>[11-13]</sup>, and this has brought into question the "normality" of the regenerated neosquamous epithelium. In a previous study we observed that the expression levels of cytokeratins CK-8 and CK-14, and microRNA-205, are similar in post-ablation neosquamous epithelium and more proximal normal squamous epithelium from patients with Barrett's esophagus. However, microRNA-143 expression, which is elevated in Barrett's esophagus<sup>[14]</sup>, was elevated in post-ablation neosquamous mucosa and in squamous mucosa above the metaplastic segment compared to squamous epithelium from healthy patients, suggesting that the regenerated neosquamous mucosa might not be "normal"<sup>[15]</sup>.

MicroRNAs are short (about 22 nucleotides) non-coding RNA molecules that regulate gene expression. Because a single microRNA can target several mRNAs, dysregulated microRNA expression can impact on key biological pathways and contribute to cancer development<sup>[16]</sup>. Dysregulated microRNA expression along the squamous - Barrett's - dysplasia - adenocarcinoma pathway has been reported by several groups<sup>[3,14,17-19]</sup>. In the current study we profiled global microRNA expression in esophageal mucosa before and after ablation of Barrett's esophagus using Argon plasma coagulation. Our aim was to further investigate differences in microRNA expression between neosquamous and normal squamous mucosa, and to investigate how these differences might contribute to altered biology using predicted targets and pathway analysis.

## MATERIALS AND METHODS

The methods used for the tissue collection and processing are described in our previous study<sup>[15]</sup>, and reproduced here for completion.

### Tissue collection

Esophageal mucosal tissue was collected before and after Argon plasma coagulation ablation of Barrett's esophagus from 16 individuals of median age 54.2 years (range 28.9-68.1) who were enrolled in the treatment arms of previously reported randomised controlled trials of Barrett's esophagus ablation vs endoscopic surveillance<sup>[20]</sup>. Barrett's esophagus was defined as columnar epithelium in the distal esophagus with histological confirmation of the presence of intestinal metaplasia. All patients were free of reflux symptoms following treatment of gastro-esophageal reflux, by either high dose proton pump inhibitors ( $n = 8$ ) or a laparoscopic fundoplication ( $n = 8$ ); before

enrolment in the trial, at pre and post-treatment sample collection, and at Barrett's esophagus ablation.

All patients underwent baseline endoscopy and biopsies from the distal esophageal mucosa were collected as described below. Biopsies were assessed by standard histopathological techniques. The presence of intestinal metaplasia and the absence of dysplasia within the Barrett's esophagus segment were confirmed in all patients. The pre-ablation length of Barrett's esophagus ranged from 1-10 cm in length (median 3 cm). Patients underwent endoscopic Argon plasma coagulation ablation following baseline endoscopy. The details of the ablation protocol have been described in detail previously<sup>[20]</sup>. Of the patients contributing tissues to the current study, complete ablation of the Barrett's esophagus was achieved in 13 of 16 (82%). In the other 3, 95%, 99% and 95% ablation was achieved. Patient-matched post ablation neosquamous and proximal squamous samples were included in the study.

### Biopsy collection

Four quadrant esophageal biopsies were taken commencing from 1 cm above the gastro-esophageal junction and then every 2 cm proximally for the length of the Barrett's segment and sent for histopathology. An additional three biopsies were collected for research purposes from each sampled level of the Barrett's esophagus, and stored in RNeasy<sup>®</sup> (Ambion, Austin, Texas, United States) as per the manufacturer's protocol.

Repeat endoscopy was performed at a median of 6 wk (inter quartile range 4.96-6.5 wk) after the last ablation treatment and biopsies were collected from the post-ablation neosquamous esophageal mucosa using the same biopsy collection protocol. Additional biopsies were collected 5 cm above the proximal margin of the pre-ablation Barrett's mucosa, and the corresponding site post-ablation for use as patient-matched non-regenerated squamous esophageal mucosa.

Biopsies collected from patients who had undergone Barrett's esophagus ablation were selected for analysis from the following sites: (1) pre-ablation Barrett's esophagus mucosa (columnar mucosa with intestinal metaplasia), 1 cm above the gastro-esophageal junction; (2) post-ablation neosquamous mucosa, 1 cm above the gastro-esophageal junction; and (3) post-ablation squamous mucosa, 5 cm above the level of the pre-ablation squamo-columnar junction.

Endoscopic esophageal mucosal biopsies were also collected at endoscopy from fourteen control individuals of median age 51.9 (range 24.1-71.0) with no known esophageal disease. These biopsies were taken from the distal esophagus, at an equivalent distance from the gastro-esophageal junction to the neosquamous mucosal biopsies, to allow direct comparison of the biopsies from normal squamous mucosa from the

control patients to the biopsies of neosquamous mucosa from the patients who underwent ablation. The inclusion criteria for the control patients were: (1) no reflux symptoms; (2) endoscopy was not undertaken for the investigation of reflux; (3) no macroscopic esophagitis seen at endoscopy; (4) gastro-esophageal junction closed when viewed from within the esophagus; and (5) gastro-esophageal junction snug around the endoscope when viewed with the retroflexed endoscope.

### **Biopsy processing and RNA extraction**

All biopsy samples for the study were immediately stored in RNeasy<sup>®</sup> (Ambion, Austin, Texas, United States) as per the manufacturer's protocol at -20 °C until required. When required, the samples were thawed and RNeasy removed. Twenty-five percent of each tissue sample was fixed in formalin and embedded in paraffin for histopathology to confirm that the sample contained the required epithelium. This protocol has been described in detail previously<sup>[21]</sup>. There were no buried sub-squamous columnar glands detected by histopathology in any of the biopsies of neosquamous mucosa used in this study. The remaining tissue was used for gene expression analysis. RNA was extracted using Trizol (Invitrogen, Carlsbad, CA, United States), and RNA concentration was determined using a Biophotometer (Eppendorf AG, Hamburg, Germany).

### **Taqman<sup>®</sup> open array<sup>®</sup> Micro-RNA profiling**

TaqMan<sup>®</sup> Array Human MicroRNA Card Set (A and B) v3.0 was used to profile the expression of 754 microRNAs<sup>[22]</sup>. The extracted RNA was reverse transcribed using Megaplex<sup>™</sup> RT Primers Pool A and B. Each reverse transcription reaction had a final volume of 7.5 µL, and contained 45 ng of total RNA in 3 µL, and 4.5 µL of RT reaction mix containing reverse transcriptase, Megaplex<sup>™</sup> RT Primers Pool A and B, and other reverse transcription agents. The recommended RT thermal cycling conditions were used: (16 °C, 2 min; 42 °C, 1 min; 50 °C, 1 s for 40 cycles); 85 °C, 5 min; 4 °C hold. 2.5 µL of RT product (cDNA) was added to 22.5 µL of PreAmp Reaction mix, containing Megaplex<sup>™</sup> RT Primers Pool A or B and TaqMan<sup>®</sup> PreAmp Master Mix to increase the quantity of cDNA prior to PCR on the Taqman<sup>®</sup> Open Array<sup>®</sup> Micro-RNA Panels. The final volume (25 µL) of preamplification reaction mix underwent the following thermo cycling conditions: 95 °C 10 min; 55 °C, 2 min; 72 °C, 2 min; (95 °C, 15 s, 60 °C, 4 min for 12 cycles), 99.9 °C, 10 min; 4 °C hold. Four microlitres of each preamplified product was diluted in ultrapure water (156 µL) to give a final dilution of 1:40 as per recommended protocol. For the real-time PCR 22.5 µL of Taqman<sup>®</sup> Open Array<sup>®</sup> Real-Time PCR Master Mix was added to 22.5 µL of preamplification product to give a total volume of 45 µL. Five microlitres of each PCR Reaction mix was added to 8 wells on an OpenArray<sup>®</sup> 384-Well-sample

plate. The Taqman<sup>®</sup> Open Array<sup>®</sup> Micro-RNA Panel was loaded with the samples from the 384-Well-sample plate using the standard AccuFill<sup>™</sup> method. Open Array<sup>®</sup> Real-Time qPCR was performed on the loaded Taqman<sup>®</sup> Open Array<sup>®</sup> Micro-RNA Panel using an Open Array<sup>®</sup> Real-Time PCR instrument and recommended software.

### **Analysis of microRNA expression data**

Raw fluorescence data was exported from the Open-Array<sup>®</sup> Real-Time qPCR Analysis Software (BioTrove<sup>™</sup>, version 1.0.4) to a comma delimited text file. A Ct (cycle threshold) value was determined for each individual qPCR assay by using the statistical software R (version 3.0.2) to fit a 3-parameter logistic curve, assuming an amplification efficiency of 2, to the raw fluorescence data of each microRNA, and the Ct of each qPCR was determined using the second derivative maximum of the fitted logistic curve. PCR reactions that did not amplify were assigned a Ct value of 40.

To investigate whether any of the samples had low quality data we used the "detector profiling across samples" module in the RealTime PCR Statminer<sup>®</sup> software analysis program (v4.5, Integromics) to examine the correlations of Ct values between samples from the same epithelial tissue type across all of the amplified microRNAs. Samples that had multiple outliers were excluded from further analysis.

For normalisation of the OpenArray<sup>®</sup> microRNA expression data we selected 14 microRNAs using the following criteria: (1) they were expressed in all samples and at high levels (median Ct < 30); (2) they were not statistically different in epithelial tissue type comparisons (Welch's *t*-test, *P* > 0.1); and (3) they were the least variable miRNAs (coefficient of variation < 1.0 for relative levels in each epithelial tissue type). The values for these selection criteria for each of the 14 microRNAs used for normalisation, plus mature nucleic acid sequences and Accession numbers, are presented in Supplementary Table 1.

The relative levels of the microRNAs were determined using the formula  $2^{(40-Ct)}$ , and were normalized using the geometric mean of the relative levels of the 14 House Keeping Genes. The data was pre-filtered using the following criteria to include microRNAs that were more likely to be informative: (1) each microRNA had to have at least 50% of samples amplified in one of the comparison groups; and (2) the differential expression between groups had to be greater than 1.4 fold. Mann Whitney *U* tests were then used to discover differentially expressed microRNAs in control squamous mucosa vs post-ablation neosquamous mucosa, and in post-ablation squamous mucosa vs post-ablation neosquamous mucosa. False discovery rates (the proportions of false positives) were estimated for each epithelial tissue type comparison. MicroRNAs that had *P* < 0.05 in both of these epithelial tissue type comparisons were termed "overlapping miRNAs".

Subset analyses were subsequently performed for these overlapping microRNAs in 2 sub-groups: (1) patients who were treated either medically or surgically for reflux; and (2) patients in whom complete ablation was achieved vs all patients. This was done by averaging the differential expression and the Mann Whitney *U* test *P* values in each patient subgroup for the overlapping microRNAs. Differences between the groups in (1) differential expression; and (2) Mann Whitney *U* test *P* values were tested using Welch's *t*-test. The statistical methods of this study were reviewed by Professor Richard Woodman from Flinders University.

The overlapping miRNAs were further investigated to compare the direction of differential expression of these microRNAs in post-ablation neosquamous mucosa vs control squamous mucosa and post-ablation squamous mucosa, to the direction of differential expression in Barrett's esophagus mucosa vs control squamous mucosa and post-ablation squamous mucosa. The potential roles of the overlapping miRNAs in regulating cellular processes were investigated using biological pathway enrichment analysis (described in next section).

### **Biological pathway enrichment analysis of overlapping microRNAs**

To identify highly predicted mRNA targets of the differentially expressed microRNAs in neosquamous mucosa, we used the Predicted Target Module of miRWalk v2<sup>[23]</sup> (<http://zmf.umm.uni-heidelberg.de/apps/zmf/mirwalk2/>). To generate the putative target genes list we used a minimum seed length of 7 and/or *P* value < 0.05, from position 1 of the 3' UTR, and included extra databases: RNA22 (<https://cm.jefferson.edu/rna22/>), miRanda (<http://www.microrna.org/microrna/home.do>) and Targetscan ([http://www.targetscan.org/vert\\_71/](http://www.targetscan.org/vert_71/)). The predicted lists for each microRNA were then screened to identify mRNAs that were predicted to be the targets of at least two different microRNAs.

To identify pathways containing a statistically significant number of predicted targets, we used a publicly available, manually curated signalling pathway database<sup>[24]</sup> (<http://www.innatedb.com/redirect.do?go=batchPw>). The target list was subjected to a Pathway Enrichment Analysis which groups target genes according to function, and identifies further components and associated networks. The target list (in REFSeq ID format) was analysed using InnateDB, which identifies statistically enriched pathways by testing for over-representation using the Hypergeometric distribution (by default; other distributions are available), and by using the Benjamini Hochberg correction for multiple tests (by default). InnateDB uses multiple curated databases for the pathway analysis: Reactome (<http://www.reactome.org/>), KEGG (<http://www.genome.jp/kegg/>), PID Biocarta and PID NCI (<http://www.home.ndexbio.org/>), NetPath (<http://www.netpath.org/>), INOH (only

available within InnateDB).

## **RESULTS**

### **Post-ablation neosquamous vs control squamous mucosa comparison**

Forty-four microRNAs were differentially expressed at *P* < 0.05 between control squamous mucosa and post-ablation neosquamous mucosa (Supplementary Table 2). Thirty-three of these microRNAs had higher expression in post-ablation neosquamous mucosa vs control squamous mucosa, and 25 of these had a fold difference greater than 2. There were 11 microRNAs that had lower expression in post-ablation neosquamous mucosa vs control squamous mucosa, although only 2 of these were expressed at levels of 50% or less.

### **Post-ablation neosquamous vs post-ablation squamous mucosa comparison**

Nineteen microRNAs were differentially expressed at *P* < 0.05 between post-ablation neosquamous and post-ablation squamous mucosa (Supplementary Table 3). Fourteen microRNAs had higher expression and 5 microRNAs had lower expression in post-ablation neosquamous mucosa compared with post-ablation squamous mucosa.

### **MicroRNAs that were different in both control squamous vs post-ablation neosquamous mucosa and post-ablation neosquamous vs post-ablation squamous mucosa**

Due to the large number of microRNAs that were assayed it is possible that some differentially expressed microRNAs occurred by chance alone and are thus false positives. We therefore estimated the false discovery rate (FDR) in each epithelial tissue type comparison: in control squamous vs post-ablation neosquamous mucosa the FDR was 11%, and in the post-ablation squamous vs post-ablation neosquamous mucosa the FDR was 19%. The post-ablation squamous vs post-ablation neosquamous comparison could also identify microRNAs associated with differential expression along the length of the esophagus<sup>[25]</sup>. In order to address these issues we investigated whether there were microRNAs that were differentially expressed in both epithelial tissue type comparisons. We reasoned that because the control squamous mucosa samples were obtained from different patients to the post-ablation squamous mucosa, any differentially expressed microRNAs found in both mucosal comparisons were much less likely to be due to chance alone. This approach identified 12 microRNAs that were present in both control squamous vs post-ablation neosquamous mucosa and the post-ablation squamous vs post-ablation neosquamous mucosa groups (Table 1). Scatter plots for the 12 overlapping microRNAs are in Supplementary Figure 2. OpenArray assay identifiers, miRBase names and accession numbers, and mature nucleotide sequences for these overlapping microRNAs

**Table 1** Fold differences in gene expression and Mann Whitney *U* test *P* values for the microRNAs that were differentially expressed in both post-NS *vs* control-S and post-NS *vs* post-S mucosa comparisons

Mature miRNA	Post-NS/control-S	<i>P</i> value	Post-NS/ Post-S	<i>P</i> value	Higher in pre-BE <i>vs</i> post-NS
miR-424-5p	485.2	0.00002	233.7	0.00053	Yes
miR-135b-5p	2.0	0.00071	1.7	0.00363	No
miR-376c-3p	6.4	0.00145	3.1	0.02673	Yes
miR-135a-5p	3.0	0.00224	2.5	0.00821	Yes
miR-187-3p	208.1	0.00414	2.7	0.01196	No
miR-409-3p	6.8	0.00502	4.6	0.00272	Yes
miR-214-5p	47.0	0.00502	46.1	0.02673	Yes
miR-31-5p	1.44	0.00869	1.5	0.00632	No
miR-199a-5p	396.3	0.01223	512.9	0.04478	Yes
miR-223-5p	230.9	0.02306	204.5	0.01350	Yes
miR-127-3p	4.8	0.02675	3.8	0.03305	Yes
miR-136-3p	7.2	0.02675	201.2	0.03305	Yes

**Table 2** Predicted molecular pathways of the mRNA targets of differentially expressed microRNAs that are increased in neosquamous but not Barrett's esophagus mucosa

Pathway name	Pathway uploaded gene count	Genes in InnateDB for this entity	Pathway <i>P</i> value	Pathway <i>P</i> value (corrected)
Ion transport by P-type ATPases	5	43	1.57E-05	0.005
Transmembrane transport of small molecules	14	606	1.31E-04	0.022
Ion channel transport	7	169	2.56E-04	0.028
Calcium signaling pathway	7	183	4.15E-04	0.035

Predicted molecular pathways using miRWalk to generate predicted mRNA targets of the microRNAs differentially expressed in both Neosquamous *vs* healthy control and Neosquamous *vs* Proximal squamous comparisons, and InnateDB to identify pathways in which the mRNA targets are over-represented.

are in Supplementary Table 4. All of these microRNAs were more highly expressed in post-ablation neosquamous tissues, and 10 of the 12 overlapping microRNAs had similar fold differences in the two groups. In both comparisons miR-424-5p was the most significantly differentially expressed microRNA (Table 1). We further investigated these overlapping miRNAs in subsets of the data (patients with complete ablation *vs* all patients, and patients who were medically treated *vs* surgically treated for reflux) and did not find significant differences in differential expression between these subset groups (Supplementary Tables 7 and 8).

The 12 overlapping microRNAs were further investigated to determine their levels of expression in pre-ablation Barrett's esophagus mucosa. The expression levels of 9 of the 12 overlapping microRNAs were higher in Barrett's esophagus mucosa than in the squamous mucosa, and for all of these 9 microRNAs their expression in post-ablation neosquamous mucosa was in the same direction (*i.e.*, higher) as in the Barrett's esophagus mucosa (Table 1; Figure 1A for a representative example). For the remaining 3 microRNAs the levels in the Barrett's esophagus mucosa were not different to the non-neosquamous mucosa (Figure 1B for a representative example).

#### Target prediction and pathway analysis of the overlapping microRNAs

For the 3 overlapping microRNAs that were found not

to be increased in Barrett's esophagus mucosa relative to non-neosquamous mucosa mirWalk predicted 1566 mRNA targets, and 163 mRNAs with 2 or more microRNAs targeting them (Supplementary Table 5). Pathway analysis using InnateDB indicated that the predicted target mRNAs are involved in active membrane transport and in calcium signalling (Table 2). For the 9 microRNAs that are increased in both neosquamous and Barrett's esophagus mucosa relative to squamous mucosa mirWalk predicted 3297 mRNA targets, and 839 mRNAs with 2 or more microRNAs targeting them (Supplementary Table 6). Pathway analysis using InnateDB indicated that the predicted target mRNAs are involved in hemostasis and in cell survival pathways (Table 3).

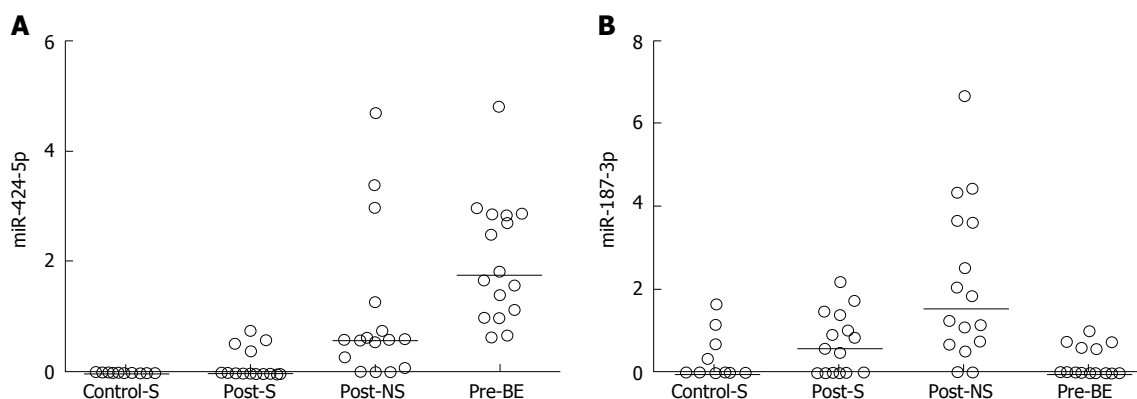
## DISCUSSION

Over the last decade, endoscopic treatment of high grade dysplasia and early cancer arising in Barrett's esophagus has largely superseded surgical resection, because of the perception of reduced morbidity, and the lower risk of lymph node metastases when cancer stage is limited to no worse than stage T1a<sup>[26,27]</sup>. Consensus guidelines for endoscopic therapy suggest that complete eradication of all Barrett's esophagus mucosa is required to eliminate the risk of metachronous and covert synchronous neoplasia<sup>[28,29]</sup>. However, increasing evidence suggests that complete



**Table 3** Predicted molecular pathways of the mRNA targets of differentially expressed microRNAs that are increased in both neosquamous and Barrett's esophagus mucosa

Pathway name	Pathway uploaded gene count	Genes in InnateDB for this entity	Pathway <i>P</i> value	Pathway <i>P</i> value (corrected)
JAK/STAT pathway and regulation	28	273	5.41E-06	0.005
Hemostasis	41	508	1.68E-05	0.005
Regulation of bad phosphorylation	7	23	2.36E-05	0.006

**Figure 1** Normalised relative expression levels in control squamous mucosa (control-S), post-ablation squamous mucosa (post-S), post-ablation neosquamous mucosa (post-NS) and pre-ablation Barrett's esophagus mucosa (pre-BE) of representative microRNAs, miR-424-5p (A) and miR-187-3p (B). Horizontal bars are medians.

eradication of Barrett's esophagus might not eliminate the risk of cancer in some patients. For example, Templeton *et al.*<sup>[11]</sup> (2014) reported three patients who progressed to invasive adenocarcinoma despite prior complete eradication of Barrett's esophagus using endoscopic therapy. Even after re-treatment and complete endoscopic eradication of the post-ablation recurrences of Barrett's esophagus, Guthikonda *et al.*<sup>[12]</sup> (2016) reported a progression rate to invasive cancer of 2.1% per year, and predicted that 5.1% (Kaplan Meier model estimate; 95%CI: 0.0-11.3) of re-treated patients would experience invasive cancer progression by 5 years after complete eradication of Barrett's esophagus<sup>[12]</sup>. In a meta-analysis of 21 radiofrequency ablation studies that reported 603 cases of Barrett's esophagus recurrence from 3186 patients, pooled incidence ratios (IR's) of recurrent Barrett's esophagus, dysplastic Barrett's esophagus, and HGD/EAC were 9.5% (95%CI: 6.7-12.3), 2.0% (95%CI: 1.3-2.7), and 1.2% (95%CI: 0.8-1.6) per patient-year, respectively<sup>[13]</sup>. Ongoing endoscopic surveillance has therefore been recommended after eradication of Barrett's esophagus to monitor for recurrence and disease progression.

It has been suggested that residual sub-squamous glandular tissue after ablation may contribute to the progression of Barrett's esophagus to high grade dysplasia and adenocarcinoma<sup>[30,31]</sup>. For example, it has been reported that after argon plasma coagulation ablation buried glandular tissue underneath neosquamous mucosa had higher levels of cancer associated biomarkers (Ki67, COX-2, BCL-2) than

normal esophageal epithelium<sup>[32]</sup>. However, Basu *et al.*<sup>[8]</sup> (2002) reported that the presence of buried Barrett's glands was not associated with recurrence in patients with effective acid suppression after argon plasma coagulation ablation. Furthermore, neosquamous epithelium has been reported not to contain genetic abnormalities after radio frequency ablation in patients who had pre-ablation Barrett's esophagus containing early cancer or high-grade dysplasia<sup>[9]</sup>.

In an earlier study we investigated neo-squamous mucosa in patients who had undergone argon plasma coagulation ablation of non-dysplastic Barrett's esophagus, and observed that expression levels of miR-143 were elevated in neosquamous epithelium and biopsies from squamous epithelium above the metaplastic segment, compared to squamous epithelium from controls without Barrett's esophagus<sup>[15]</sup>. miR-143 has also been shown to have increased expression in Barrett's esophagus mucosa. This study suggested that post-ablation neosquamous epithelium might not be normal, and might express persistent molecular markers consistent with the original Barrett's esophagus.

In our current study we used post-ablation mucosa from patients who did not have dysplasia or early cancer to further investigate the biology of the neosquamous epithelium, and it is unlikely that these biopsies would have contained residual dysplasia associated biomarkers<sup>[32]</sup>, or be effected by DNA mutations that are commonly found in dysplastic tissues<sup>[6]</sup>.

We sought to strengthen our approach by restricting the list of microRNAs to those that are differentially

expressed in both neosquamous vs independent squamous mucosa from control individuals, and in neosquamous vs paired proximal squamous mucosa comparisons. This approach should minimise the issues associated with inter-individual variation, epithelial repair, and tissue proximity to the gastro-esophageal junction as possible causes of differences in microRNA expression. This approach produced 12 microRNAs that were differentially expressed in both of the squamous mucosa comparisons.

To investigate the potential biological effects of the differential expression of these 12 microRNAs we utilized miRWalk to predict their mRNA targets, and InnateDB to assess which potential signalling pathways these mRNAs are involved in. This approach identified signalling pathways which the differentially expressed miRNAs might be regulating.

Nine microRNAs were expressed at higher levels in both neosquamous and pre-ablation Barrett's mucosa, vs both squamous mucosa from controls and proximal squamous mucosa collected after ablation from the ablation patients. The predicted mRNA targets of these microRNAs are involved in the JAK-STAT signalling pathway, and in the regulation of the anti-apoptotic family member, Bad. Three of the discovered microRNAs have been reported to have targets involved in hemostasis<sup>[33-35]</sup>.

The JAK-STAT signalling pathway transmits information from extracellular signals directly to the cell nucleus, and results in expression of genes involved in proliferation, differentiation, apoptosis and oncogenesis. The JAK-STAT3 pathway is activated by IL-6 in Barrett's esophagus, and this promotes survival of the metaplastic intestinal cells<sup>[36,37]</sup>. However, activated JAK-STAT has been reported to be undetectable in normal esophageal squamous mucosa<sup>[38]</sup>, so the effect of altered regulation of this pathway in neosquamous mucosa is not clear.

Three microRNAs were increased in neosquamous, but not pre-ablation Barrett's esophagus mucosa, vs both healthy squamous and post-squamous mucosa. The predicted mRNA targets of these microRNAs are potentially involved in regulating pathways involved in transmembrane transport of small molecules, in ion channel transport, and in ion and lipid transport by P-type ATPases (which includes the calcium pump, Ca<sup>2+</sup>-ATPase). Jovov *et al.*<sup>[39]</sup> (2013) found that post-ablation neosquamous epithelium has decreased barrier function, measured as persistent paracellular permeability to ions and uncharged molecules<sup>[39]</sup>, so these active transporter targets are likely to be involved in the regulation of barrier protection. This is an important consideration because acid reflux injury has been implicated in the development of intestinal metaplasia, and decreased barrier function may therefore contribute to recurrence in patients with uncontrolled reflux following successful ablation.

The mucosal biopsies used in this study were

from patients treated with Argon Plasma Coagulation ablation. These were collected as part of clinical trials previously established in our institution and were therefore readily available to us<sup>[20]</sup>. The use of biopsies from patients treated with argon plasma coagulation ablation is a potential limitation of our study, since radiofrequency ablation is now the standard technique for ablation of Barrett's esophagus due to its ease of use and consistent depth of tissue destruction<sup>[40]</sup>. However, some patients in whom complete eradication has been achieved following radiofrequency ablation have still progressed to invasive cancer, which suggests that post radiofrequency ablation neosquamous epithelium may also not be normal. It is worth noting that the above described report of decreased barrier function in neosquamous mucosa was associated with radiofrequency ablation<sup>[39]</sup>. Future studies of neosquamous epithelium miRNA profile should therefore include other endoscopic methods such as radiofrequency ablation and endomucosal resection, and validation in independent cohorts.

The observed decrease in barrier function in neosquamous mucosa is consistent with reports of an association between recurrence after ablation and persistent reflux, and with reduced proton pump inhibitor dosing. Kahaleh *et al.*<sup>[41]</sup> (2002) found that persistence of acid reflux and greater length of diseased segment were the major factors associated with a recurrence after successful initial reversal with argon plasma coagulation ablation. Basu *et al.*<sup>[8]</sup> (2002) reported that patients who reduced their dose of the proton pump inhibitor omeprazole to 20 mg once daily or less after argon plasma coagulation ablation had significantly greater recurrence of intestinal metaplasia<sup>[8]</sup>. Conversely, in patients with complete squamous regeneration after argon plasma coagulation ablation who took a high dose of omeprazole (40 mg three times a day) there were no relapses or evidence of dysplasia under continuous acid suppression during a median follow-up of 12 mo (range 2 to 51 mo)<sup>[42]</sup>.

Three (miR-424-5p, miR-223-5p, miR-409-3p) of the microRNAs that are increased in neosquamous mucosa relative to post-squamous and control-squamous mucosa have been reported to be up-regulated in esophageal adenocarcinoma relative to Barrett's esophagus and normal squamous tissues. Wu *et al.*<sup>[18]</sup> (2013) observed progressively increased expression of miR-424-5p, miR-223-5p and miR-409-3p from normal squamous epithelium to Barrett's to adenocarcinoma. MiR-223-5p and miR-409-3p have also been reported to be overexpressed in serum exosomes from patients with esophageal adenocarcinoma<sup>[43]</sup>.

In conclusion, this study demonstrates that the miRNA expression profile in neosquamous mucosa, following argon plasma coagulation ablation of Barrett's esophagus, is significantly different from normal squamous mucosa. The main strength of this study is that the mucosal

biopsies were not from patients who were treated for dysplasia or cancer. Our results suggest that altered miRNA expression may contribute to the previously reported defective barrier function in neosquamous epithelium, and this may place the mucosa at increased risk of disease progression relative to normal esophageal squamous mucosa. Further research to explore the roles of miRNAs in the response to ablation of Barrett's esophagus, and the long term behaviour of neosquamous epithelium may lead to improvements in clinical management of this condition.

## ACKNOWLEDGMENTS

We thank the SA Pathology anatomical pathology laboratory for assistance with preparation of histopathology slides.

## COMMENTS

### Background

Overall 5 year survival of patients with esophageal adenocarcinoma is around 15%, but survival can be improved via early detection using endoscopic surveillance of patients with Barrett's esophagus, and endoscopic ablative therapy for the treatment of early stage disease.

### Research frontiers

Some patients still experience disease progression after complete ablation of Barrett's esophagus, which suggests that the neosquamous mucosa formed after ablation may be at increased risk of disease progression. Improved understanding of the biological properties of post-ablation neosquamous mucosa might improve the clinical management of patients who undergo ablative therapy.

### Innovations and breakthroughs

Previous studies have investigated whether post ablation mucosa has genetic alterations in, or increased expression of cancer associated genes. Neither of these approaches directly addresses whether the non-cancer associated biology of neosquamous mucosa is different. Previous studies have reported reduced barrier function in neosquamous mucosa, and this may have implications for clinical management.

### Applications

Altered microRNA expression in neosquamous mucosa might result in reduced barrier function, thereby placing the mucosa at increased susceptibility to reflux induced disease. MicroRNAs might therefore have the potential to be developed into a biomarker with clinical utility to improve the management of patients who have been treated endoscopically for early stage disease.

### Terminology

Post-ablation neosquamous mucosa: post-treatment regenerated esophageal squamous mucosa that was Barrett's intestinal metaplasia prior to treatment, with biopsies taken 1 cm above the gastro-esophageal junction. Post-ablation squamous mucosa: post-treatment proximal normal non-treated esophageal mucosa, with biopsies collected 5 cm above the proximal margin of the pre-ablation Barrett's mucosa. Healthy squamous mucosa: squamous mucosa from patients without esophageal disease, with biopsies taken from the same level relative to the gastro-esophageal junction as the post-ablation neosquamous mucosa.

### Peer-review

This manuscript evaluates a topic of real interest. The analysis of the subject has been done in an appropriate way. The background of the problem was evaluated in a comprehensive way, the hypothesis was clearly stated, and the

materials, methods and results are presented in an understandable way (I will add minor comments).

## REFERENCES

- 1 **Chisholm JA**, Mayne GC, Hussey DJ, Watson DI. Molecular biomarkers and ablative therapies for Barrett's esophagus. *Expert Rev Gastroenterol Hepatol* 2012; **6**: 567-581 [PMID: 23061708 DOI: 10.1586/egh.12.39]
- 2 **Phillips WA**, Lord RV, Nancarrow DJ, Watson DI, Whiteman DC. Barrett's esophagus. *J Gastroenterol Hepatol* 2011; **26**: 639-648 [PMID: 21166712 DOI: 10.1111/j.1440-1746.2010.06602.x]
- 3 **Fassan M**, Volinia S, Palatini J, Pizzi M, Baffa R, De Bernard M, Battaglia G, Parente P, Croce CM, Zaninotto G, Ancona E, Rugge M. MicroRNA expression profiling in human Barrett's carcinogenesis. *Int J Cancer* 2011; **129**: 1661-1670 [PMID: 21128279 DOI: 10.1002/ijc.25823]
- 4 **Shaheen NJ**, Richter JE. Barrett's oesophagus. *Lancet* 2009; **373**: 850-861 [PMID: 19269522 DOI: 10.1016/S0140-6736(09)60487-6]
- 5 **Haidry RJ**, Dunn JM, Butt MA, Burnell MG, Gupta A, Green S, Miah H, Smart HL, Bhandari P, Smith LA, Willert R, Fullarton G, Morris J, Di Pietro M, Gordon C, Penman I, Barr H, Patel P, Boger P, Kapoor N, Mahon B, Hoare J, Narayanasamy R, O' Toole D, Cheong E, Direkze NC, Ang Y, Novelli M, Banks MR, Lovat LB. Radiofrequency ablation and endoscopic mucosal resection for dysplastic Barrett's esophagus and early esophageal adenocarcinoma: outcomes of the UK National Halo RFA Registry. *Gastroenterology* 2013; **145**: 87-95 [PMID: 23542069 DOI: 10.1053/j.gastro.2013.03.045]
- 6 **Hage M**, Siersema PD, Vissers KJ, Dinjens WN, Steyerberg EW, Haringsma J, Kuipers EJ, van Dekken H. Genomic analysis of Barrett's esophagus after ablative therapy: persistence of genetic alterations at tumor suppressor loci. *Int J Cancer* 2006; **118**: 155-160 [PMID: 16032707 DOI: 10.1002/ijc.21302]
- 7 **Hage M**, Siersema PD, Vissers KJ, Steyerberg EW, Haringsma J, Kuipers EJ, van Dekken H. Molecular evaluation of ablative therapy of Barrett's oesophagus. *J Pathol* 2005; **205**: 57-64 [PMID: 15586364 DOI: 10.1002/path.1685]
- 8 **Basu KK**, Pick B, Bale R, West KP, de Caestecker JS. Efficacy and one year follow up of argon plasma coagulation therapy for ablation of Barrett's oesophagus: factors determining persistence and recurrence of Barrett's epithelium. *Gut* 2002; **51**: 776-780 [PMID: 12427775]
- 9 **Pouw RE**, Gondrie JJ, Rygiel AM, Sondermeijer CM, ten Kate FJ, Odze RD, Vieth M, Krishnadath KK, Bergman JJ. Properties of the neosquamous epithelium after radiofrequency ablation of Barrett's esophagus containing neoplasia. *Am J Gastroenterol* 2009; **104**: 1366-1373 [PMID: 19491850 DOI: 10.1038/ajg.2009.88]
- 10 **Ganz RA**, Utley DS, Stern RA, Jackson J, Batts KP, Termin P. Complete ablation of esophageal epithelium with a balloon-based bipolar electrode: a phased evaluation in the porcine and in the human esophagus. *Gastrointest Endosc* 2004; **60**: 1002-1010 [PMID: 15605025]
- 11 **Templeton A**, Bodnar A, Gan SI, Irani S, Ross A, Low D. Occurrence of invasive cancer after endoscopic treatment of Barrett's esophagus with high-grade dysplasia and intramucosal cancer in physiologically fit patients: time for a review of surveillance and treatment guidelines. *Gastrointest Endosc* 2014; **79**: 839-844 [PMID: 24447341 DOI: 10.1016/j.gie.2013.11.024]
- 12 **Guthikonda A**, Cotton CC, Madanick RD, Spacek MB, Moist SE, Ferrell K, Dellon ES, Shaheen NJ. Clinical Outcomes Following Recurrence of Intestinal Metaplasia After Successful Treatment of Barrett's Esophagus With Radiofrequency Ablation. *Am J Gastroenterol* 2017; **112**: 87-94 [PMID: 27725648 DOI: 10.1038/ajg.2016.451]
- 13 **Krishnamoorthi R**, Singh S, Ragunathan K, A Katzka D, K Wang K, G Iyer P. Risk of recurrence of Barrett's esophagus after successful endoscopic therapy. *Gastrointest Endosc* 2016; **83**:

- 1090-1106.e3 [PMID: 26902843 DOI: 10.1016/j.gie.2016.02.009]
- 14 **Wijnhoven BP**, Hussey DJ, Watson DI, Tsykin A, Smith CM, Michael MZ, South Australian Oesophageal Research Group. MicroRNA profiling of Barrett's oesophagus and oesophageal adenocarcinoma. *Br J Surg* 2010; **97**: 853-861 [PMID: 20301167 DOI: 10.1002/bjs.7000]
- 15 **Dijkmeester WA**, Wijnhoven BP, Watson DI, Leong MP, Michael MZ, Mayne GC, Bright T, Astill D, Hussey DJ. MicroRNA-143 and -205 expression in neosquamous esophageal epithelium following Argon plasma ablation of Barrett's esophagus. *J Gastrointest Surg* 2009; **13**: 846-853 [PMID: 19190970 DOI: 10.1007/s11605-009-0799-5]
- 16 **Calin GA**, Croce CM. MicroRNA-cancer connection: the beginning of a new tale. *Cancer Res* 2006; **66**: 7390-7394 [PMID: 16885332 DOI: 10.1158/0008-5472.CAN-06-0800]
- 17 **Smith CM**, Watson DI, Michael MZ, Hussey DJ. MicroRNAs, development of Barrett's esophagus, and progression to esophageal adenocarcinoma. *World J Gastroenterol* 2010; **16**: 531-537 [PMID: 20128019 DOI: 10.3748/wjg.v16.i5.531]
- 18 **Wu X**, Ajani JA, Gu J, Chang DW, Tan W, Hildebrandt MA, Huang M, Wang KK, Hawk E. MicroRNA expression signatures during malignant progression from Barrett's esophagus to esophageal adenocarcinoma. *Cancer Prev Res (Phila)* 2013; **6**: 196-205 [PMID: 23466817 DOI: 10.1158/1940-6207.CAPR-12-0276]
- 19 **Feber A**, Xi L, Luketich JD, Pennathur A, Landreneau RJ, Wu M, Swanson SJ, Godfrey TE, Little VR. MicroRNA expression profiles of esophageal cancer. *J Thorac Cardiovasc Surg* 2008; **135**: 255-260; discussion 260 [PMID: 18242245 DOI: 10.1016/j.jtcvs.2007.08.055]
- 20 **Sie C**, Bright T, Schoeman M, Game P, Tam W, Devitt P, Watson D. Argon plasma coagulation ablation versus endoscopic surveillance of Barrett's esophagus: late outcomes from two randomized trials. *Endoscopy* 2013; **45**: 859-865 [PMID: 24019134 DOI: 10.1055/s-0033-1344584]
- 21 **Beck P**, Mayne GC, Astill D, Irvine T, Watson DI, Dijkmeester WA, Wijnhoven BP, Hussey DJ. Accuracy of identification of tissue types in endoscopic esophageal mucosal biopsies used for molecular biology studies. *Clin Exp Gastroenterol* 2009; **2**: 1-7 [PMID: 21694820]
- 22 **McAlinden A**, Varghese N, Wirthlin L, Chang LW. Differentially expressed microRNAs in chondrocytes from distinct regions of developing human cartilage. *PLoS One* 2013; **8**: e75012 [PMID: 24040378 DOI: 10.1371/journal.pone.0075012]
- 23 **Dweep H**, Gretz N. miRWalk2.0: a comprehensive atlas of microRNA-target interactions. *Nat Methods* 2015; **12**: 697 [PMID: 26226356 DOI: 10.1038/nmeth.3485]
- 24 **Breuer K**, Foroushani AK, Laird MR, Chen C, Sribnaia A, Lo R, Winsor GL, Hancock RE, Brinkman FS, Lynn DJ. InnateDB: systems biology of innate immunity and beyond—recent updates and continuing curation. *Nucleic Acids Res* 2013; **41**: D1228-D1233 [PMID: 23180781 DOI: 10.1093/nar/gks1147]
- 25 **Ali I**, Rafiee P, Hogan WJ, Jacob HJ, Komorowski RA, Haasler GB, Shaker R. Dickkopf homologs in squamous mucosa of esophagitis patients are overexpressed compared with Barrett's patients and healthy controls. *Am J Gastroenterol* 2006; **101**: 1437-1448 [PMID: 16863544 DOI: 10.1111/j.1572-0241.2006.00584.x]
- 26 **Dunbar KB**, Spechler SJ. The risk of lymph-node metastases in patients with high-grade dysplasia or intramucosal carcinoma in Barrett's esophagus: a systematic review. *Am J Gastroenterol* 2012; **107**: 850-862; quiz 863 [PMID: 22488081 DOI: 10.1038/ajg.2012.78]
- 27 **Fuchs HF**, Harnsberger CR, Broderick RC, Chang DC, Sandler BJ, Jacobsen GR, Bouvet M, Horgan S. Mortality after esophagectomy is heavily impacted by center volume: retrospective analysis of the Nationwide Inpatient Sample. *Surg Endosc* 2017; **31**: 2491-2497 [PMID: 27660245 DOI: 10.1007/s00464-016-5251-9]
- 28 **Fitzgerald RC**, di Pietro M, Ragunath K, Ang Y, Kang JY, Watson P, Trudgill N, Patel P, Kaye PV, Sanders S, O'Donovan M, Bird-Lieberman E, Bhandari P, Jankowski JA, Attwood S, Parsons SL, Loft D, Lagergren J, Moayyedi P, Lyratzopoulos G, de Caestecker J, British Society of Gastroenterology. British Society of Gastroenterology guidelines on the diagnosis and management of Barrett's oesophagus. *Gut* 2014; **63**: 7-42 [PMID: 24165758 DOI: 10.1136/gutjnl-2013-305372]
- 29 **Spechler SJ**, Sharma P, Souza RF, Inadomi JM, Shaheen NJ; American Gastroenterological Association. American Gastroenterological Association technical review on the management of Barrett's esophagus. *Gastroenterology* 2011; **140**: e18-e52; quiz e13 [PMID: 21376939 DOI: 10.1053/j.gastro.2011.01.031]
- 30 **Titi M**, Overhiser A, Uluarac O, Falk GW, Chak A, Wang K, Sharma P. Development of subsquamous high-grade dysplasia and adenocarcinoma after successful radiofrequency ablation of Barrett's esophagus. *Gastroenterology* 2012; **143**: 564-566.e1 [PMID: 22561053 DOI: 10.1053/j.gastro.2012.04.051]
- 31 **Lee JK**, Cameron RG, Binmoeller KF, Shah JN, Shergill A, Garcia-Kennedy R, Bhat YM. Recurrence of subsquamous dysplasia and carcinoma after successful endoscopic and radiofrequency ablation therapy for dysplastic Barrett's esophagus. *Endoscopy* 2013; **45**: 571-574 [PMID: 23592390 DOI: 10.1055/s-0032-1326419]
- 32 **Lewis CJ**, Thrumurthy SG, Pritchard S, Armstrong G, Attwood SE. Comparison of COX-2, Ki-67, and BCL-2 expression in normal esophageal mucosa, Barrett's esophagus, dysplasia, and adenocarcinoma with postablation mucosa and implications for ablative therapies. *Surg Endosc* 2011; **25**: 2564-2569 [PMID: 21359892 DOI: 10.1007/s00464-011-1587-3]
- 33 **Fort A**, Borel C, Migliavacca E, Antonarakis SE, Fish RJ, Neerman-Arbez M. Regulation of fibrinogen production by microRNAs. *Blood* 2010; **116**: 2608-2615 [PMID: 20570858 DOI: 10.1182/blood-2010-02-268011]
- 34 **Landry P**, Plante I, Ouellet DL, Perron MP, Rousseau G, Provost P. Existence of a microRNA pathway in anucleate platelets. *Nat Struct Mol Biol* 2009; **16**: 961-966 [PMID: 19668211 DOI: 10.1038/nsmb.1651]
- 35 **Edelstein LC**, Simon LM, Montoya RT, Holinstat M, Chen ES, Bergeron A, Kong X, Nagalla S, Mohandas N, Cohen DE, Dong JF, Shaw C, Bray PF. Racial differences in human platelet PAR4 reactivity reflect expression of PCTP and miR-376c. *Nat Med* 2013; **19**: 1609-1616 [PMID: 24216752 DOI: 10.1038/nm.3385]
- 36 **Zhang HY**, Zhang Q, Zhang X, Yu C, Huo X, Cheng E, Wang DH, Spechler SJ, Souza RF. Cancer-related inflammation and Barrett's carcinogenesis: interleukin-6 and STAT3 mediate apoptotic resistance in transformed Barrett's cells. *Am J Physiol Gastrointest Liver Physiol* 2011; **300**: G454-G460 [PMID: 21148399 DOI: 10.1152/ajpgi.00458.2010]
- 37 **Dvorak K**, Chavarria M, Payne CM, Ramsey L, Crowley-Weber C, Dvorakova B, Dvorak B, Bernstein H, Holubec H, Sampliner RE, Bernstein C, Prasad A, Green SB, Garewal H. Activation of the interleukin-6/STAT3 antiapoptotic pathway in esophageal cells by bile acids and low pH: relevance to barrett's esophagus. *Clin Cancer Res* 2007; **13**: 5305-5313 [PMID: 17875759 DOI: 10.1158/1078-0432.ccr-07-0483]
- 38 **You Z**, Xu D, Ji J, Guo W, Zhu W, He J. JAK/STAT signal pathway activation promotes progression and survival of human oesophageal squamous cell carcinoma. *Clin Transl Oncol* 2012; **14**: 143-149 [PMID: 22301404 DOI: 10.1007/s12094-012-0774-6]
- 39 **Jovov B**, Shaheen NJ, Orlando GS, Djukic Z, Orlando RC. Defective barrier function in neosquamous epithelium. *Am J Gastroenterol* 2013; **108**: 386-391 [PMID: 23318477 DOI: 10.1038/ajg.2012.440]
- 40 **Haidry R**, Lovat L, Sharma P. Radiofrequency ablation for Barrett's dysplasia: past, present and the future? *Curr Gastroenterol Rep* 2015; **17**: 13 [PMID: 25740248 DOI: 10.1007/s11894-015-0433-5]
- 41 **Kahaleh M**, Van Laethem JL, Nagy N, Cremer M, Devière J. Long-term follow-up and factors predictive of recurrence in Barrett's esophagus treated by argon plasma coagulation and acid suppression. *Endoscopy* 2002; **34**: 950-955 [PMID: 12471537 DOI: 10.1055/s-2002-35847]
- 42 **Schulz H**, Miehke S, Antos D, Schentke KU, Vieth M, Stolte M, Bayerdörffer E. Ablation of Barrett's epithelium by endoscopic



argon plasma coagulation in combination with high-dose omeprazole. *Gastrointest Endosc* 2000; **51**: 659-663 [PMID: 10840296]

43 **Warnecke-Eberz U**, Chon SH, Hölscher AH, Drebber U,

Bollschweiler E. Exosomal onco-miRs from serum of patients with adenocarcinoma of the esophagus: comparison of miRNA profiles of exosomes and matching tumor. *Tumour Biol* 2015; **36**: 4643-4653 [PMID: 25631748 DOI: 10.1007/s13277-015-3112-0]

**P- Reviewer:** Durand L, Garcia-Olmo D **S- Editor:** Qi Y

**L- Editor:** A **E- Editor:** Li D



## Basic Study

# Expression of Interleukin-26 is upregulated in inflammatory bowel disease

Makoto Fujii, Atsushi Nishida, Hirotsugu Imaeda, Masashi Ohno, Kyohei Nishino, Shigeki Sakai, Osamu Inatomi, Shigeki Bamba, Masahiro Kawahara, Tomoharu Shimizu, Akira Andoh

Makoto Fujii, Atsushi Nishida, Hirotsugu Imaeda, Masashi Ohno, Kyohei Nishino, Shigeki Sakai, Osamu Inatomi, Shigeki Bamba, Masahiro Kawahara, Akira Andoh, Department of Medicine, Shiga University of Medical Science, Seta-Tsukinowa, Otsu 520-2192, Japan

Tomoharu Shimizu, Department of Surgery, Shiga University of Medical Science, Seta-Tsukinowa, Otsu 520-2192, Japan

**Author contributions:** Fujii M and Nishida A performed the majority of experiments and analyzed the data; Imaeda H, Nishino K, Sakai S, Inatomi O, Bamba S, Kawahara M, Shimizu T and Andoh A coordinated the research and provided technical support; Fujii M, Nishida A and Andoh A wrote the paper.

**Institutional review board statement:** This study was reviewed and approved by the local ethics committee of the Shiga University of Medical Science (Permit number: 27-27).

**Conflict-of-interest statement:** The authors declare that they have no competing interests.

**Data sharing statement:** No additional data are available.

**Open-Access:** This article is an open-access article which was selected by an in-house editor and fully peer-reviewed by external reviewers. It is distributed in accordance with the Creative Commons Attribution Non Commercial (CC BY-NC 4.0) license, which permits others to distribute, remix, adapt, build upon this work non-commercially, and license their derivative works on different terms, provided the original work is properly cited and the use is non-commercial. See: <http://creativecommons.org/licenses/by-nc/4.0/>

**Manuscript source:** Unsolicited manuscript

**Correspondence to:** Atsushi Nishida, MD, PhD, Department of Medicine, Shiga University of Medical Science, Seta Tsukinowa, Otsu 520-2192, Japan. [atsuda@belle.shiga-med.ac.jp](mailto:atsuda@belle.shiga-med.ac.jp)  
Telephone: +81-77-5482217  
Fax: +81-77-5482219

Received: April 7, 2017

Peer-review started: April 10, 2017

First decision: June 8, 2017

Revised: June 26, 2017

Accepted: July 12, 2017

Article in press: July 12, 2017

Published online: August 14, 2017

## Abstract

### AIM

To investigate interleukin (IL)-26 expression in the inflamed mucosa of patients with inflammatory bowel disease (IBD) and the function of IL-26.

### METHODS

Human colonic subepithelial myofibroblasts (SEMFs) were isolated from colon tissue surgically resected. The expression of IL-26 protein and its receptor complex was analyzed by immunohistochemistry. The gene expression induced by IL-26 was evaluated by real-time polymerase chain reaction. Intracellular signaling pathways were evaluated by immunoblotting and specific small interfering (si) RNA transfection.

### RESULTS

The mRNA and protein expression of IL-26 were significantly enhanced in the inflamed mucosa of patients with IBD. IL-26 receptor complex was expressed in colonic SEMFs *in vivo* and *in vitro*. IL-26 stimulated the mRNA expression of IL-6 and IL-8 in colonic SEMFs. The inhibitors of mitogen-activated protein kinases and phosphoinositide 3-kinase, and siRNAs for signal transducers and activator of transcription 1/3, nuclear factor-kappa B and activator protein-1 significantly reduced the mRNA expression of IL-6 and IL-8 induced by IL-26.

**CONCLUSION**

These results suggest that IL-26 plays a role in the pathophysiology of IBD through induction of inflammatory mediators.

**Key words:** Inflammatory bowel disease; Interleukin-26; Myofibroblasts

© **The Author(s) 2017.** Published by Baishideng Publishing Group Inc. All rights reserved.

**Core tip:** We investigated interleukin (IL)-26 expression in the inflamed mucosa of patients with inflammatory bowel disease (IBD) and characterized the biological function of IL-26 using human colonic subepithelial myofibroblasts. To our knowledge, this is the first report to state that IL-26 activates STAT1/3 and leads to the induction of IL-6 and IL-8 expression in non-transformed cells derived from human colon. We suggest that IL-26 plays a role in the pathophysiology of IBD through the induction of inflammatory mediators.

Fujii M, Nishida A, Imaeda H, Ohno M, Nishino K, Sakai S, Inatomi O, Bamba S, Kawahara M, Shimizu T, Andoh A. Expression of Interleukin-26 is upregulated in inflammatory bowel disease. *World J Gastroenterol* 2017; 23(30): 5519-5529 Available from: URL: <http://www.wjgnet.com/1007-9327/full/v23/i30/5519.htm> DOI: <http://dx.doi.org/10.3748/wjg.v23.i30.5519>

**INTRODUCTION**

Inflammatory bowel diseases (IBD) comprise two major phenotypes, Crohn's disease (CD) and ulcerative colitis (UC). Recent studies suggest that the chronic inflammation in IBD is mediated by uncontrolled immune responses against a subset of luminal bacteria and dietary factors<sup>[1-3]</sup>. This hypothesis is supported by the recent finding that the genes encoding innate immune responses are responsible for the susceptibility to IBD<sup>[4-6]</sup>. However, the precise etiology of IBD still remains unclear.

Interleukin (IL)-26 is a member of the IL-10 cytokine family. IL-26 was first discovered in *herpesvirus saimiri*-transformed T-cell lines by subtractive hybridization<sup>[7]</sup>. IL-26 has been reported to be co-expressed with IL-17 and IL-22 by Th17 cells<sup>[8-10]</sup>, and recent studies have reported that natural killer cells<sup>[11,12]</sup>, macrophages<sup>[13]</sup>, and fibroblast-like cells<sup>[14,15]</sup> are sources of IL-26. A murine IL-26 homologue has not been identified<sup>[16,17]</sup>, limiting the experimental opportunities to study the phenotypic consequences of IL-26 gene knockout and IL-26-mediated functions in murine models *in vivo*.

Although IL-19, IL-20, and IL-24, members of IL-10 cytokine family, are located in proximity to the IL-10 gene on human chromosome 1q32, IL-26 is located on chromosome 12q15 between the genes encoding

IFN- $\gamma$  and IL-22<sup>[18]</sup>. For its signaling, IL-26 requires the heterodimeric receptors composed of IL-20R1 and IL-10R2<sup>[19]</sup>. The transmembrane protein IL-20R1 has been shown to possess the specific ligand-binding site for IL-26, whereas the IL-10R2 subunit acts as an essential second chain that completes the assembly of its active receptor complex and signaling<sup>[20]</sup>. IL-22, IL-26, IL-28A/B and IL-29 also use IL-10R2 for their signaling. IL-10R2 is ubiquitously expressed in various tissues, but the expression of IL-20R1 is absent in hematopoietic cells and is restricted within non-hematopoietic cells<sup>[19,21]</sup>.

Previous reports have suggested that intracellular signaling of IL-26 is mediated by the Janus kinase-signal transducer and activator of transcription (STAT) pathway<sup>[16,20]</sup>. Additionally, IL-26 has been reported to activate extracellular signal-related kinase (ERK)-1/2, stress-activated protein kinase/c-Jun N-terminal kinase (SAPK/JNK), p38 mitogen-activated protein kinase and phosphoinositide 3-kinase (PI3K) in various kinds of cells<sup>[7,16,20,22]</sup>.

Human colonic subepithelial myofibroblasts (SEMFs) are located immediately subjacent to the basement membrane in the normal intestinal mucosa, juxtaposed against the bottom of the epithelial cells<sup>[23-25]</sup>. These cells are considered to play a role in the regulation of a number of epithelial cell functions, such as epithelial proliferation and differentiation. Isolated SEMFs retain their representative and differentiated phenotypes<sup>[23]</sup>.

Recent studies have demonstrated that IL-26 is involved in the pathophysiology of chronic inflammatory disorders, such as rheumatoid arthritis<sup>[15]</sup> and chronic hepatitis C infection<sup>[26]</sup>. Concerning IBD, the pathological role of IL-26 has been reported in CD, but remains unclear in UC<sup>[16]</sup>. In addition, functional analysis of IL-26 has been studied using a transformed cell line, but there are no reports using primary culture cells. In the present study, to explore the potential role of IL-26 in IBD, we investigated the expression of IL-26 in the inflamed mucosa of UC and CD patients. Furthermore, the biological functions and the intracellular signal pathways activated by IL-26 were investigated in human colonic SEMFs.

**MATERIALS AND METHODS****Reagents**

All reagents and antibiotics used in this study were commercially purchased as shown in Supplementary Table 1.

**Tissue samples**

The diagnosis of IBD was based on conventional clinical and endoscopic criteria. Surgically-resected specimens and biopsy specimens from 49 patients with UC and 19 patients with CD were used after obtaining written informed consent. All experiments were approved by the local ethics committee of the Shiga University of Medical Science (Permit number: 27-27).

**Table 1** Oligonucleotides used in this study

Gene name	Accession number		Primers
IL-26	NM_018402.1	Sense	5'-GGCAGAAATTGAGCCACTGT-3'
		Antisense	5'-TCCAGTTCACATGATGGCTTTG-3'
IL-10R2	NM_000628.4	Sense	5'-GGCTGAATTTGCAGATGAGCA-3'
		Antisense	5'-GAAGACCGAGGCCATGAGG-3'
IL-20R1	NM_014432.3	Sense	5'-TACACCCCTCAGCTCCAAGACT-3'
		Antisense	5'-GAAGGAATTACACAGCCTGCCAG-3'
IL-6	NM_000600.4	Sense	5'-GGTACATCCTCGACGGCATCT-3'
		Antisense	5'-GTGCTCTTTGCTGCTTTTAC-3'
IL-8	NM_000584.3	Sense	5'-ATGACTTCCAAGCTGGCCGTGGCT-3'
		Antisense	5'-TCTCAGCCCTCTTCAAAAATTCTC-3'
$\beta$ -actin	NM_001101.3	Sense	5'-TGACCCAGATCATGTTTGAGACCT-3'
		Antisense	5'-CCACGTCACACTTCATGATGGAG-3'
STAT1	NM_139266	Sense	5'-GGAAGGGGCCATCACATTCA-3'
		Antisense	5'-GTAGGGTTCAACCGCATGGA-3'
STAT3	NM_003150.3	Sense	5'-GGAGGAGTTGCAGCAAAAAG-3'
		Antisense	5'-GGAGGAGTTGCAGCAAAAAG-3'
c-jun	NM_002228.3	Sense	5'-CAGGTGGCACAGCTTAAACA-3'
		Antisense	5'-GTTTGCAACTGCTGCGTTAG-3'
NF- $\kappa$ Bp65	NM_003998.3	Sense	5'-CGCATCCAGACCAACAACAA-3'
		Antisense	5'-GCATTCAGGTCGTAGTCCCC-3'

The clinical activity of IBD was determined according to the colitis activity index for UC<sup>[27]</sup> and CD activity index<sup>[28]</sup>. Normal colonic tissues were obtained from the distal part of the surgically resected sample of colon cancer ( $n = 3$ ) and using colonoscopy ( $n = 17$ ).

### Immunohistochemistry

Immunohistochemical analyses were performed according to the method described in our previous report<sup>[29]</sup>. Briefly, goat anti-IL-26, goat anti-IL-20R1 and rabbit anti-IL-10R2 were used as the primary antibodies. After incubation with the primary antibodies, the sections were treated with HRP-labeled anti-goat or anti-rabbit antibodies. Diaminobenzidine was used as a substrate for color development.

For double-staining procedures, anti-IL-20R1 or anti-IL-10R2 antibodies were applied and incubated overnight in a humidified chamber. Subsequently, anti- $\alpha$ -smooth muscle actin (SMA) antibodies were applied and incubated overnight. Dylight488-labeled anti-goat IgG, Dylight549-labeled anti-mouse IgG, or Dylight549-labeled anti-mouse IgG were used as secondary antibodies. Images were obtained with a digital confocal laser scanning microscope LSM510 version 3.0 (Carl Zeiss Microscopy, Tokyo, Japan).

### Culture of human colonic SEMFs

Primary cultures of colonic SEMFs were prepared according to the method reported by Mahida *et al.*<sup>[30]</sup>. The cellular characteristics and culture conditions have also been described in our previous report<sup>[31]</sup>. The studies were performed on passages 3-6 of SEMFs.

### Reverse transcription-polymerase chain reaction and Real-time polymerase chain reaction

The expression of mRNA in the samples was assessed by reverse transcription polymerase chain reaction

(RT-PCR) and real-time PCR analysis. RT-PCR was performed according to the methods described in our previous report<sup>[32]</sup>. Total RNA was extracted using the TRIzol reagent (Invitrogen, Carlsbad, CA, United States) and was reverse transcribed using SuperScript II (Invitrogen). Subsequently, cDNAs were generated using SYBR Premix Ex Taq (TAKARA, Shiga, Japan), and real-time PCR was performed using a LightCycler480 System II (Roche Diagnostics, Basel, Switzerland) with specific primers for target genes. The PCR primers used in this study are shown in Table 1.

### Enzyme-linked immunosorbent assay

Concentrations of IL-6 and IL-8 in cell culture supernatants were determined using ELISA kits (R&D systems, Minneapolis, MN, United States).

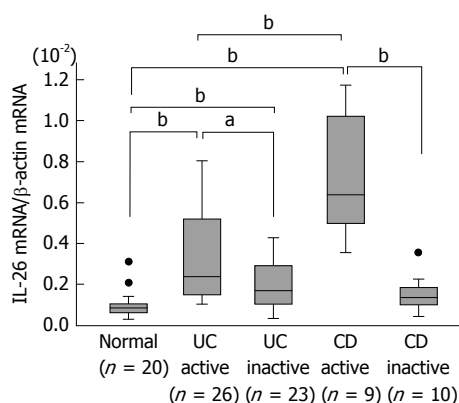
### Silencing gene expression in human colonic SEMFs

Human colonic SEMFs were transfected with siRNA specific for STAT1, STAT3, nuclear factor (NF)- $\kappa$ Bp65, and c-Jun according to the instructions for Lipofectamine RNAiMAX (Invitrogen). Briefly, human colonic SEMFs were cultured in complete medium without antibiotics in the presence of a mixture of an RNAi duplex and Lipofectamine RNAiMAX for 24 h, and were then stimulated with or without IL-26 for 3 h.

### Nuclear and cytoplasmic protein extraction and immunoblot analysis

Nuclear proteins were extracted using the CellLytic NuCLEAR Extraction Kit (Sigma-Aldrich, St. Louis, MO, United States). Extracted nuclear proteins were subjected to immunoblotting with rabbit anti-NF- $\kappa$ Bp65 (C-20) antibody or mouse anti-phospho (P)-c-Jun (KM-1) antibody, followed by incubation with HRP-labeled anti-rabbit antibody or HRP-labeled anti-mouse antibody. Immunoblots were performed according to a





**Figure 1 Expression of interleukin-26 mRNA in the inflamed mucosa of patients with inflammatory bowel disease.** Total RNA was extracted from biopsied samples, and the mRNA expression of IL-26 was evaluated using real-time PCR. IL-26 mRNA expression was converted to a value relative to  $\beta$ -actin mRNA expression and presented as fold-increase relative to the results for normal mucosa. Data are expressed as mean  $\pm$  SE. Normal mucosa,  $n = 20$ ; active UC,  $n = 26$ ; inactive UC,  $n = 23$ ; active CD,  $n = 9$ ; inactive CD,  $n = 10$ . <sup>a</sup> $P < 0.05$  UC active vs UC inactive, <sup>b</sup> $P < 0.01$  Normal vs UC active, Normal vs UC inactive, Normal vs CD active, UC active vs CD active, CD active vs CD inactive. IL: Interleukin; CD: Crohn's disease; UC: Ulcerative colitis.

method previously described<sup>[33,34]</sup>. Signal detection was performed using the enhanced chemiluminescence Western blot system (GE Healthcare, Little Chalfont, United Kingdom).

Cytoplasmic protein was extracted using a lysis buffer [50 mmol/L Tris pH 8.0, 0.5% Nonidet P-40, 1 mmol/L EDTA, 150 mmol/L NaCl, 2 mmol/L  $\text{Na}_3\text{VO}_4$ , 1 mmol/L NaF, 20 mmol/L  $\text{Na}_4\text{P}_2\text{O}_7$ , 1 mmol/L PMSF, 10% glycerol and complete Mini Protease Inhibitor Cocktail (Roche Diagnostics)]. Extracted protein was subjected to immunoblotting with antibodies against phospho-p44/42 MAPK (ERK1/2), p38 MAPK, or SAPK/JNK, Akt, STAT1, or STAT3 followed by incubation with HRP-labeled anti-rabbit antibody or HRP-labeled anti-mouse antibody. After detection as described above, the membrane was stripped using Restore Western Blot Stripping Buffer (Thermo Scientific Inc., Waltham, MA) and was then incubated with antibodies against total-p44/42 MAPK (ERK1/2), p38 MAPK, SAPK/JNK, Akt, STAT1, or STAT3.

### Statistical analysis

Single comparisons were analyzed using the non-parametric Mann-Whitney  $U$  test. Differences resulting in  $P$  values of less than 0.05 were considered to be statistically significant. The statistical methods of this study were reviewed by a biomedical statistician from Shiga University of Medical Science.

## RESULTS

### IL-26 expression in IBD mucosa

The mRNA expression of IL-26 in the inflamed mucosa of IBD patients was evaluated using real-time PCR. As shown in Figure 1, IL-26 mRNA expression was

faintly detected in normal mucosa. The mucosal mRNA expression of IL-26 was significantly higher in active UC patients than in the inactive UC mucosa and normal mucosa. Similar findings were also observed in the inflamed mucosa of CD patients. The average level of IL-26 mRNA expression was significantly higher in active CD mucosa than in active UC mucosa.

IL-26 protein expression was evaluated by immunohistochemical analysis. IL-26 positive cells were not detected in normal mucosa, but the number of IL-26 positive cells markedly increased in the inflamed mucosa of UC and CD patients (Figure 2A). Moreover, the number of IL-26 positive cells more increased in the inflamed mucosa of CD patients as compared to in the inflamed mucosa of UC patients (Figure 2A). This result was confirmed by the results from Figure 1. Furthermore, to identify the cellular source of IL-26, double staining was performed. As shown in Figure 2B, double staining studies indicated that IL-26-positive cells were positive for CD4 (T cell), CD56 (NK cell), or CD68 (macrophage). These findings indicated that CD4<sup>+</sup> T cells, NK cells, and macrophages were the cellular sources of IL-26 in the inflamed mucosa of UC and CD patients.

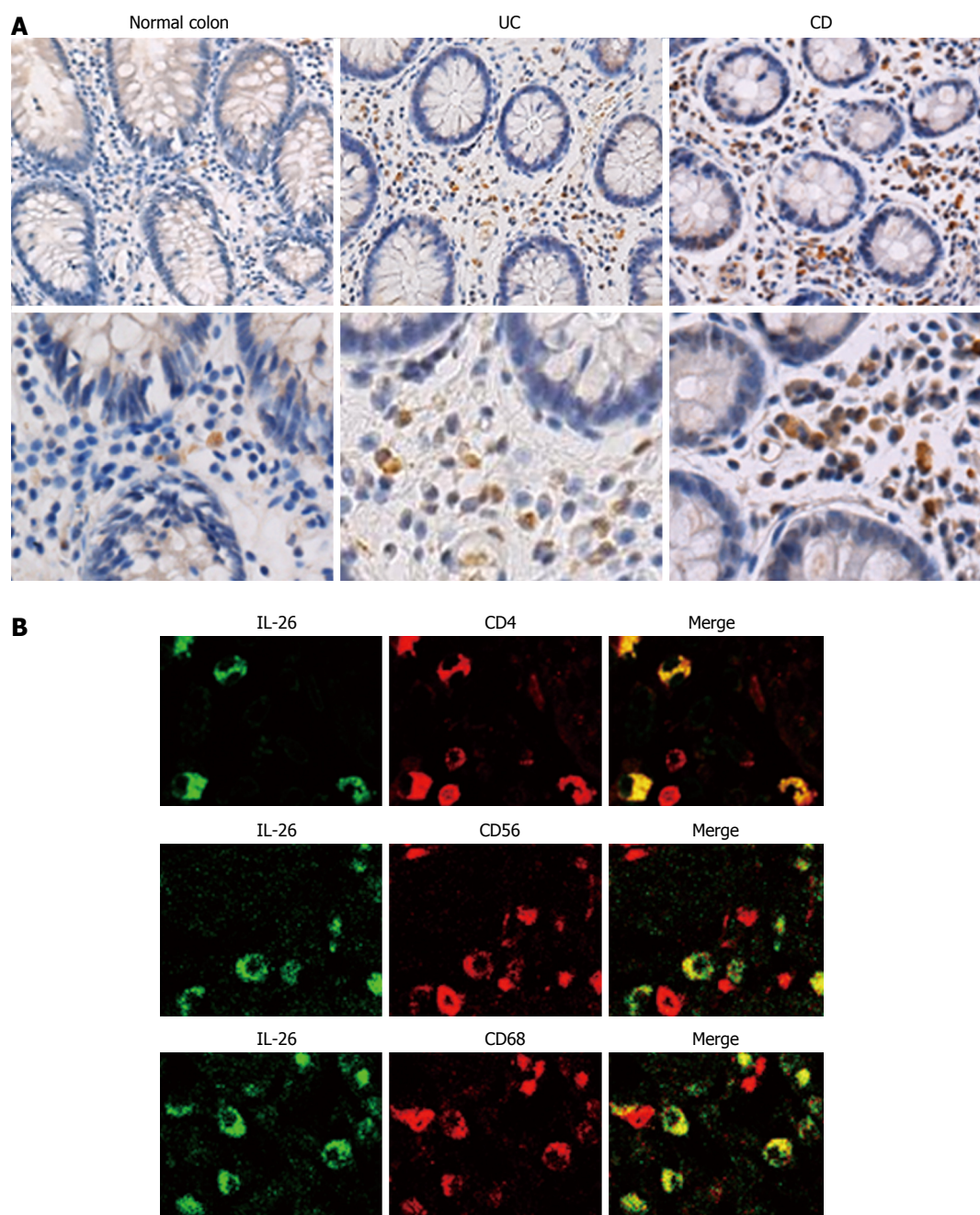
### IL-26 receptor expression in SEMFs

We looked for the presence of either IL-20R1 or IL-10R2 in the inflamed mucosa of IBD patients. It has been reported that the expression of IL-20R1 is restricted in non-hematopoietic cells, while IL-10R2 is ubiquitously expressed<sup>[19,35]</sup>. The tissue samples from the normal, the active IBD and inactive IBD were double stained with anti- $\alpha$ -SMA, a marker for myofibroblasts, and IL-20R1 or IL-10R2. As shown in Figure 3A, IL-20R1 was expressed in epithelial cells and in some of the other cells in the submucosa, and the cells in the subepithelial region also stained with  $\alpha$ -SMA. IL-10R2 expression was detected in various cells including epithelial cells and leukocytes, and the cells at the subepithelial region also stained with  $\alpha$ -SMA. The expression levels of IL-20R1 and IL-10R2 were not different between in the mucosa from the normal and in the active or inactive mucosa from IBD patients. These results suggested that human colonic SEMFs are expressing the IL-26 receptor.

We also confirmed the IL-20R1 and IL-10R2 expression in isolated human colonic SEMFs. As shown in Figure 3B, isolated human colonic SEMFs expressed IL-20R1 and IL-10R2 mRNAs.

### Effects of IL-26 in SEMFs

Based on the expression of IL-26 receptor in colonic SEMFs, we examined the biological effect of IL-26 on human colonic SEMFs *in vitro*. The cells were incubated with IL-26 (100 ng/mL) for 12 h, and then IL-6 and IL-8 levels in supernatants were evaluated using ELISA. As shown Figure 4A, IL-26 induced a significant increase in the secretion of IL-6 and IL-8.



**Figure 2** Immunohistochemical analyses of interleukin-26 in the inflamed mucosa of inflammatory bowel disease patients. A: Immunostaining for IL-26 in normal mucosa and inflamed mucosa of UC and CD. Pictures are shown from one of four independent samples with similar results. Magnification; upper panel × 200, lower panel × 400; B: Dual-colored immunofluorescence was used to determine the expression of IL-26 (green fluorescence) and CD4, CD56 and CD68 (red fluorescence) in inflamed mucosa of UC patients. Double-positive cells were detected by yellow fluorescence. Pictures are shown from one of four independent samples with similar results. IL: Interleukin; CD: Crohn's disease; UC: Ulcerative colitis.

These responses were also confirmed at the mRNA levels. IL-26 dose- and time-dependently induced the mRNA expression of IL-6 and IL-8 (Figure 4B and C).

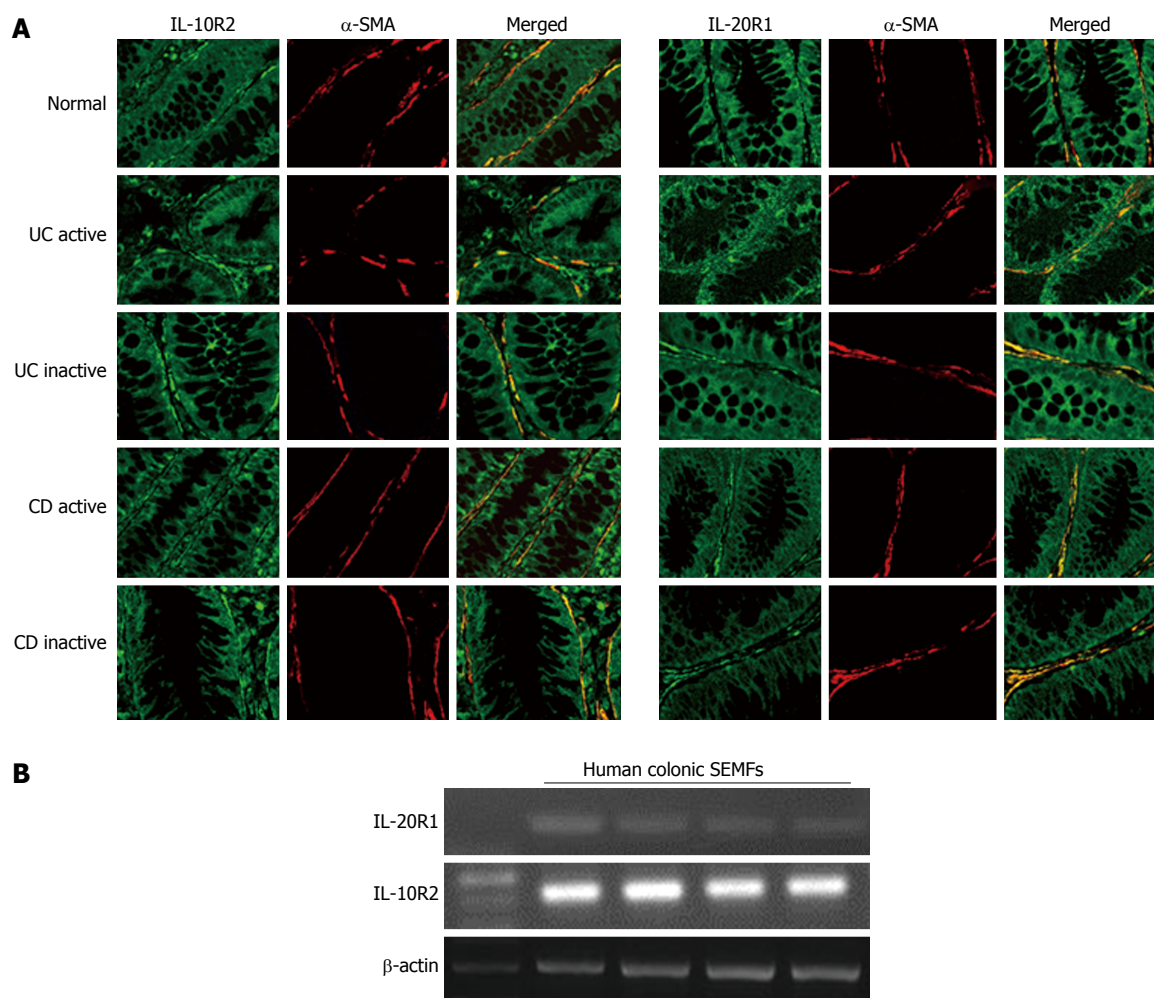
#### **Activation of STAT1 and STAT3 by IL-26 in human colonic SEMFs**

It has been previously reported that the activation of STAT1 and STAT3 is induced by IL-26<sup>[16,22]</sup>. Therefore, we examined whether IL-26 induced the phosphorylation of STAT1 and STAT3 in human colonic

SEMFs. IL-26 induced the phosphorylation of STAT1 and STAT3 as early as 5 min after stimulation with IL-26 (Figure 5A).

Involvement of STAT1 and STAT3 activation in IL-26-induced IL-6 and IL-8 was tested using siRNA specific for STAT1 and STAT3. As shown in Figure 5B, the siRNA specific for STAT1 and STAT3 significantly suppressed IL-26-induced mRNA expression of IL-6 and IL-8 effectiveness of siRNA for STAT1 and STAT3 is presented in Figure 6A. These findings indicated that





**Figure 3** Immunohistochemical analyses of interleukin-26 receptor expression in normal and active/inactive inflammatory bowel disease mucosa. **A:** Dual-colored immunofluorescence was used to localize α-SMA (red fluorescence) and IL-26 receptor, IL-10R2 and IL-20R1 (green fluorescence). Dual positive immunostaining can be seen as yellow fluorescence in the merged images. Pictures are shown from one of four independent samples with similar results. Magnification  $\times 200$ ; **B:** The expression of IL-26 receptor in human colonic SEMFs isolated from four different surgical samples. The expression of IL-26 receptor was evaluated by RT-PCR. SMA: Smooth muscle actin; IL: Interleukin; SEMFs: Subepithelial myofibroblasts.

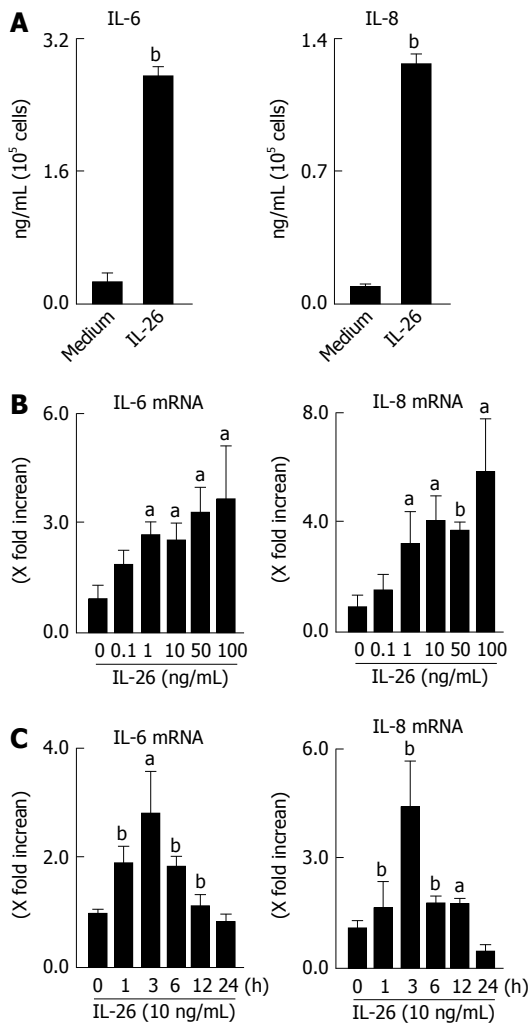
the activation of STAT1 and STAT3 is involved in the induction of IL-6 and IL-8 by the stimulation of IL-26 in human colonic SEMFs.

#### Activation of ERK1/2, SAPK/JNK1/2 and Akt by IL-26 in colonic SEMFs

The MAPKs and Akt are involved in the cytokine signaling in various kinds of cells. We examined whether IL-26 activates MAPKs and Akt using immunoblot analysis. As shown in Figure 5C, IL-26 induced a phosphorylation of MAPKs, including p42/44MAPK, SAPK/JNK, and p38MAPK, and Akt as early as 5 min after stimulation with IL-26. Moreover, MEK1/2 inhibitors (PD098059 and U0216), a p38 MAPK inhibitor (SB203580), a JNK inhibitor (JNK inhibitor 1) and a PI3K inhibitor (LY294002) significantly suppressed IL-26-induced IL-6 and IL-8 mRNA expression (Figure 5D). These findings indicate that the activation of MAPKs and the PI3K/Akt pathway is involved in the IL-26-induced IL-6 and IL-8 expression in human colonic SEMFs.

#### Activation of NF-κB and AP-1 by IL-26

The expression of a number of inflammatory genes is regulated by the activation of transcription factors such as NF-κB and AP-1<sup>[36]</sup>. In the nuclear proteins, the expression of NF-κB and phosphorylated c-Jun was clearly detected after IL-26 stimulation (Figure 7A). The siRNAs specific for NF-κBp65 and c-Jun (AP-1) significantly suppressed the mRNA expression of IL-6 and IL-8 effectiveness of siRNA for NF-κBp65 and c-Jun (AP-1) is presented in Figure 6B, (Figure 7B). These findings indicate an involvement of NF-κB and AP-1 activation in IL-26-induced IL-6 and IL-8 expression. As shown in Figure 7C, IL-26-induced NF-κBp65 phosphorylation was suppressed by PI3K inhibitor (LY294002), but was not affected by MAPKs. On the other hand, IL-26-induced AP-1 (c-Jun) phosphorylation was suppressed by both MAPKs and PI3K inhibitor. These findings indicate that PI3K, but not MAPKs, plays a role in IL-26-induced NF-κB activation, but that both MAPKs and PI3K activation are involved in IL-26-



**Figure 4** Secretion of interleukin-6 and interleukin-8 in response to interleukin-26 stimulation in human colonic subepithelial myofibroblasts. A: The cells were stimulated for 12 h with 100 ng/mL of IL-26, and the secretion of IL-6 and IL-8 in supernatants were determined using ELISA; B: Dose-dependent effects of IL-26 on IL-6 and IL-8 mRNA expression. Cells were stimulated for 3 h with increasing concentrations of IL-26, and the mRNA expression of IL-6 and IL-8 was then determined using real-time PCR. The mRNA expression of IL-6 and IL-8 was converted to a value relative to  $\beta$ -actin mRNA expression and presented as fold-increase relative to the results for medium alone; C: The kinetics of IL-6 and IL-8 induction by IL-26. Human colonic SEMFs were stimulated with 100 ng/mL of IL-26 for the indicated predetermined times, and the mRNA expression of IL-6 and IL-8 was then determined using real-time PCR. The mRNA expression of IL-6 and IL-8 was converted to a value relative to  $\beta$ -actin mRNA expression and presented as fold-increase relative to the results for medium alone (no stimulation). Data are expressed as mean  $\pm$  SE of four independent experiments. <sup>a</sup> $P < 0.05$ , <sup>b</sup> $P < 0.01$  vs control. IL: Interleukin; SEMFs: Subepithelial myofibroblasts.

induced AP-1 activation.

## DISCUSSION

In the present study, we demonstrated that: (1) the expression of IL-26 is enhanced in the inflamed mucosa of UC and CD patients; (2) human colonic SEMFs express IL-26 receptor complex IL-10R2/IL-20R1 *in vivo* and *in vitro*; (3) human colonic SEMFs secrete inflammatory mediators in response to IL-26

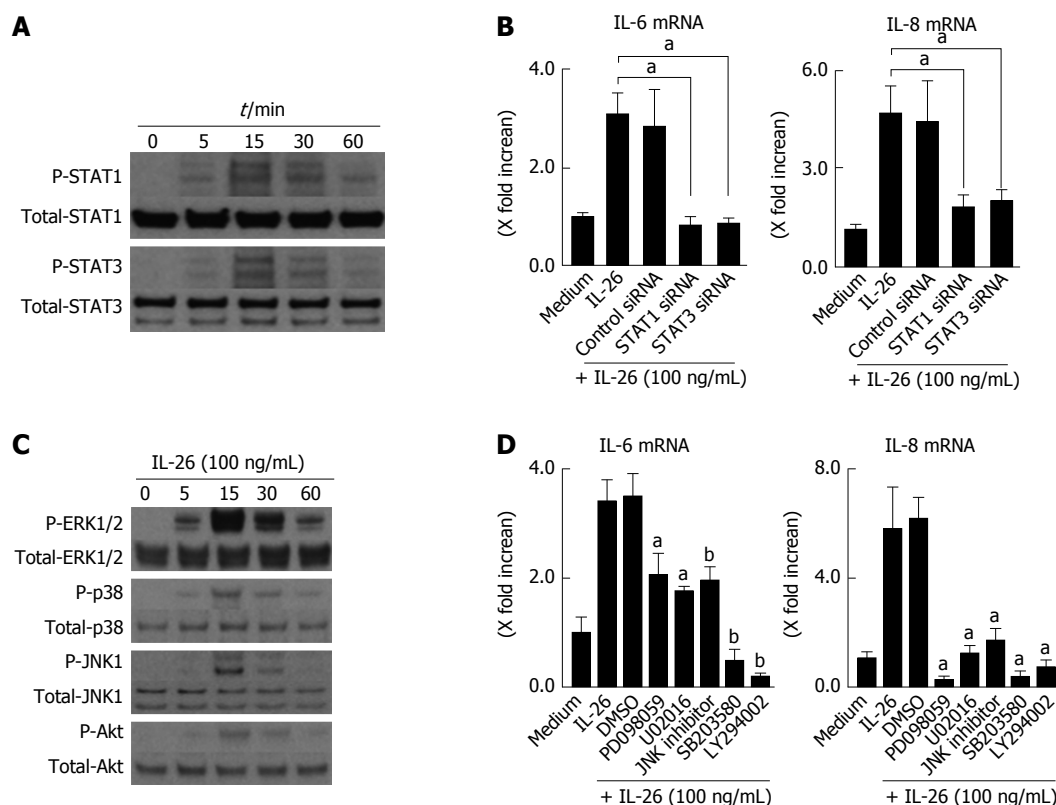
stimulation; and (4) IL-26 induced inflammatory mediators *via* the activation of STAT1/3 and MAPKs/PI3K followed by the activation of NF- $\kappa$ B/AP-1. These observations suggest that IL-26 plays a role in the pathophysiology of IBD.

In this study, we found that IL-26 mRNA expression was enhanced in the inflamed mucosa of UC and CD patients. Its expression was higher in the active mucosa of CD patients than in the active mucosa of UC patients. These findings are similar to our previous observation that mucosal mRNA expression of Th17 cytokines, such as IL-17 and IL-22, was enhanced in the inflamed mucosa of UC and CD patients<sup>[29,37]</sup>. The mRNA expression of either IL-17 or IL-22 was higher in CD patients than UC patients<sup>[29,37]</sup>. Th17 cells are now recognized as one of the cellular sources of IL-26<sup>[15]</sup>. These findings suggest that the IL-26-expressing CD4<sup>+</sup> T cells in this study are probably Th17 cells and that Th17 cells are more closely associated with the pathophysiology of CD patients than UC patients.

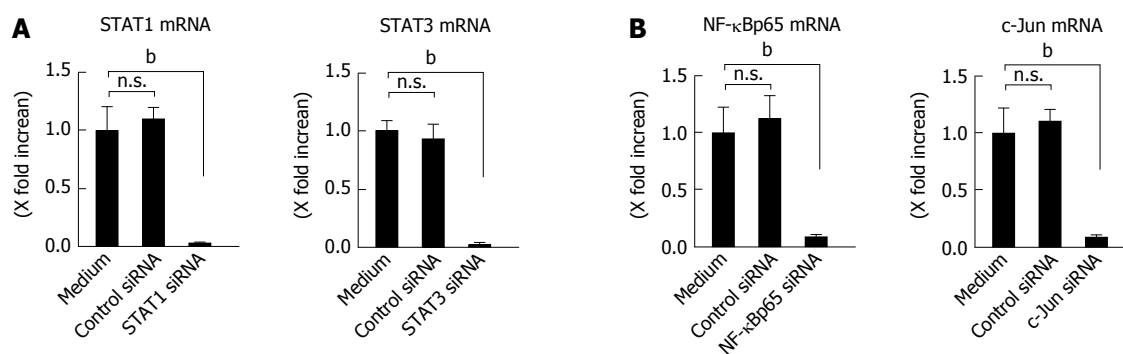
In the intestinal mucosa, CD56<sup>+</sup>NCR<sup>+</sup> type 3 innate lymphoid cells (ILC3s), a subclass of CD56<sup>+</sup>NKp44<sup>+</sup> NK cells, have been reported to concomitantly express IL-22 and IL-26, especially following stimulation with IL-23<sup>[11]</sup>. This suggests that the IL-26-producing CD56<sup>+</sup> cells in our study may be NCR<sup>+</sup> ILC3s. Our observation of IL-26 expression by CD68<sup>+</sup> macrophages is supported by the recent report that CD68<sup>+</sup> macrophages are the main IL-26-producing cells in joints with rheumatoid arthritis<sup>[15]</sup>. Thus, our observations in this study indicate that various types of immune cells are producing IL-26 in the inflamed mucosa of IBD. Further investigation using more precise cellular markers should be performed to more clearly identify the cellular source of IL-26 in the inflamed mucosa of IBD.

There are some reports concerning the *in vivo* expression of IL-26 under normal and pathological conditions. Corvaisier *et al.*<sup>[15]</sup> demonstrated a pathogenic role of IL-26 in rheumatoid arthritis on the basis of its capacity to induce pro-inflammatory cytokines. IL-23-induced IL-26 plays a role in the pathophysiology of psoriasis<sup>[8]</sup>. Moreover, Dambacher *et al.*<sup>[16]</sup> have reported that IL-26 modulated proliferation and pro-inflammatory gene expression in colon cancer cells and that IL-26 expression was upregulated in active CD, suggesting a role of IL-26 in the innate host cell response during intestinal inflammation. In addition, a genome-wide association study identified IL-26 as one of the susceptibility genes associated with UC<sup>[38]</sup>, suggesting a pathophysiological role of IL-26 in patients with UC. However, previous studies of the clinical role of IL-26 mainly focused on CD rather than UC<sup>[16]</sup>. In this study, we found that IL-26 was enhanced in the inflamed mucosa of patients with UC, as well as patients with CD. In addition, human colonic SEMFs were expressing functionally-active IL-10R2 and IL-20R1 and secreted inflammatory cytokines

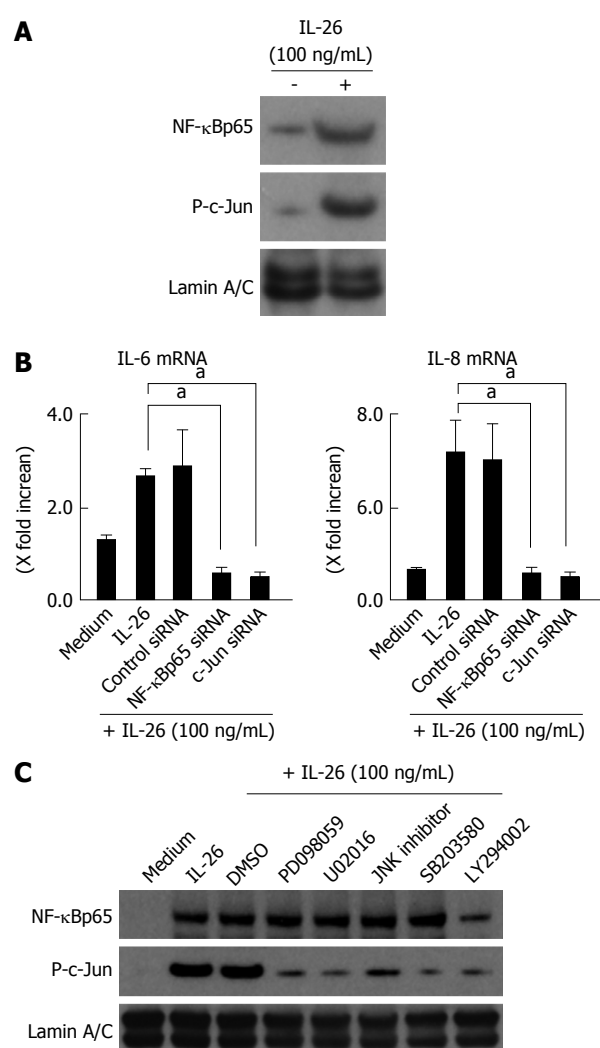




**Figure 5** Involvement of STAT1, STAT3, MAPKs and PI3K/Akt activation in interleukin-26-stimulated interleukin-6 and interleukin-8 induction. A: STAT1 and STAT3 activation in response to IL-26. Human colonic SEMFs were stimulated with 100 ng/mL of IL-26 for the indicated pre-determined times, and the phosphorylation (P-) of STAT1 and STAT3 was evaluated by immunoblot analyses. The data are representative of two independent experiments; B: The effects of siRNAs for STAT1 and STAT3 on IL-26-induced mRNA expression of IL-6 and IL-8. Cells were transfected with siRNA for STAT1 and STAT3 or control siRNA, and were incubated for 3 h with or without 100 ng/mL of IL-26. The mRNA expression of IL-6 and IL-8 was then evaluated using real-time PCR. The mRNA expression of IL-6 and IL-8 was converted to a value relative to  $\beta$ -actin mRNA expression and presented as fold-increase relative to the results for medium alone (no stimulation); C: MAPKs and PI3K/Akt activation in response to IL-26. Human colonic SEMFs were stimulated with 100 ng/mL of IL-26 for the indicated pre-determined times, and the phosphorylation (P-) of MAPKs and PI3K was evaluated by immunoblot analyses. The data are representative of two independent experiments; D: Effects of inhibitors of MAPKs and PI3K/Akt on IL-6 and IL-8 induction by IL-26 in human colonic SEMFs. The cells were pretreated with 10  $\mu$ mol/L of a p38 MAPK inhibitor (SB203580) or an MEK1/2 inhibitor (U0216 or PD098059), or with 3  $\mu$ mol/L of a JNK inhibitor (JNK inhibitor I) or 25  $\mu$ mol/L of a PI3K inhibitor (LY294002) for 30 min, and were then incubated with or without 100 ng/mL of IL-26 for 3 h. The mRNA expression of IL-6 and IL-8 was converted to a value relative to  $\beta$ -actin mRNA expression and presented as fold-increase relative to the results for medium alone. Data are expressed as mean  $\pm$  SE of four independent experiments. <sup>a</sup> $P < 0.05$ , <sup>b</sup> $P < 0.01$  vs IL-26 stimulation. IL: Interleukin; SEMFs: Subepithelial myofibroblasts.



**Figure 6** Effect of siRNA. A: Effect of siRNAs specific for STAT1 and STAT3 in human colonic subepithelial myofibroblasts. The cells were transfected with siRNAs specific for STAT1 and STAT3. A control siRNA was also used. The effect of siRNAs was evaluated using real-time PCR. The expression of STAT1 and STAT3 was significantly suppressed by specific siRNAs as compared to a control siRNA. STAT1 and STAT3 mRNA expression was converted to a value relative to  $\beta$ -actin mRNA expression and presented as fold-increase relative to the results for medium alone (no stimulation); B: Effect of siRNAs specific for NF- $\kappa$ Bp65 and c-Jun (AP-1) in human colonic subepithelial myofibroblasts. The cells were transfected with siRNAs specific for NF- $\kappa$ Bp65 and c-Jun (AP-1). A control siRNA was also used. The effect of siRNAs was evaluated using real-time PCR. The expression of NF- $\kappa$ Bp65 and c-Jun (AP-1) was significantly suppressed by specific siRNAs as compared to a control siRNA. The mRNA expression of NF- $\kappa$ Bp65 and c-Jun (AP-1) mRNA was converted to a value relative to  $\beta$ -actin mRNA expression and presented as fold-increase relative to the results for medium alone (no stimulation). Data are expressed as mean  $\pm$  SE of four independent experiments. <sup>b</sup> $P < 0.01$  vs medium. n.s.: Not significant.



**Figure 7** Involvement of nuclear factor- $\kappa$ B and AP-1 activation in the induction of inflammatory mediators induced by interleukin-26. **A:** Activation of NF- $\kappa$ B and AP-1 (c-Jun) in response to IL-26 in human colonic SEMFs. The cells were stimulated with 100 ng/mL of IL-26 for 15 min, following which nuclear proteins were extracted and analyzed by immunoblotting for NF- $\kappa$ B (p65) and phosphorylated (P-) c-Jun. Lamin A/C was used as a loading control. The data are representative of two individual experiments; **B:** The effects of siRNAs specific for NF- $\kappa$ Bp65 and c-Jun (AP-1) on IL-26-induced expression of IL-6 and IL-8 in human colonic SEMFs. The cells were transfected with siRNA specific for NF- $\kappa$ Bp65, c-Jun (AP-1) or a control siRNA, and were incubated for 24 h with or without 100 ng/mL of IL-26. The mRNA expression of IL-6 and IL-8 was evaluated using real-time PCR. The mRNA expression of IL-6 and IL-8 mRNA was converted to a value relative to  $\beta$ -actin mRNA expression and presented as fold-increase relative to the results for medium alone (no stimulation). Data are expressed as mean  $\pm$  SE of four independent experiments.  $^aP < 0.05$  vs IL-26 stimulation; **C:** The effect of MAPKs and PI3K/Akt on the activation of NF- $\kappa$ Bp65 and c-Jun (AP-1). The cells were pretreated with 10  $\mu$ mol/L of a p38 MAPK inhibitor (SB203580) or an MEK1/2 inhibitor (U0216 or PD098059), or with 3  $\mu$ mol/L of a JNK inhibitor (JNK inhibitor I) or 25  $\mu$ mol/L of a PI3K inhibitor (LY294002) for 30 min, and were then incubated with or without 100 ng/mL of IL-26 for 15 min. Nuclear proteins were then extracted and analyzed by immunoblotting for NF- $\kappa$ Bp65 and phosphorylated (P-) c-Jun. Lamin A/C was used as a loading control. The data are representative of two individual experiments. IL: Interleukin.

in response to IL-26. This phenomenon is supported by previous reports that the expression of IL-20R1 is restricted within non-hematopoietic cells<sup>[19,21]</sup>. These

observations suggest an interaction between IL-26 and colonic SEMFs in inflammatory responses in the colonic mucosa. IL-26 may stimulate the induction of inflammatory mediators from colonic SEMFs and possibly contributes to the inflammatory responses in IBD mucosa. However, recent studies have revealed that Th17-derived cytokines, such as IL-17 and IL-22, possess conflicting (pro-inflammatory and protective) roles in the mucosa<sup>[39]</sup>. So, further investigations to determine whether IL-26 production is ultimately tissue protective or a significant source of tissue damage in IBD mucosa are required in the future.

There are a few reports concerning the signaling pathway of IL-26 in the colonic tissue. A previous report using transformed epithelial cell lines suggested that IL-26 induces activation of STAT1/3, ERK1/2, SAPK/JNK1/2 and Akt<sup>[16]</sup>. To our knowledge, this is the first report to state that IL-26 activates STAT1/3 and leads to the induction of IL-6 and IL-8 expression in non-transformed cells derived from human colon. We have also revealed that IL-26 induced the activation of MAPKs, including ERK1/2, p38MAPK and SAPK/JNK1/2, and PI3K/Akt. Furthermore, we found that PI3K, but not MAPKs, plays a role in IL-26-induced NF- $\kappa$ B activation, but that both MAPKs and PI3K activation were required in IL-26-induced AP-1 activation. These results indicate that IL-26-induced inflammatory responses in the colonic mucosa are mediated by various signaling pathways including STAT1/3, MAPKs and PI3K/Akt, followed by the activation of NF- $\kappa$ B and AP-1.

In conclusion, we demonstrated that the expression of IL-26 is increased in the inflamed mucosa of IBD patients. In human SEMFs, IL-26 induced an activation of STAT1/3 and MAPKs/PI3K, leading to an activation of NF- $\kappa$ B and AP-1. Since the IL-26 gene has not been identified in rodents, the experiments using human colonic SEMFs will contribute to the investigation of the true role of IL-26 in gut inflammation.

## COMMENTS

### Background

Recent studies have reported that interleukin (IL)-26 is involved in the pathophysiology of chronic inflammatory disorders. Concerning inflammatory bowel disease (IBD), the pathological role of IL-26 has been reported in Crohn's disease (CD), but remains unclear in ulcerative colitis. Moreover, functional analysis of IL-26 has been studied using a transformed cell line, but there are no reports using primary culture cells.

### Research frontiers

The authors found that the expression of IL-26 was enhanced in the inflamed mucosa of IBD as compared to in the normal mucosa. The cellular source of IL-26 in the inflamed mucosa are CD4<sup>+</sup> T cells, NK cells, and macrophages. Human colonic subepithelial myofibroblasts (SEMFs) are target cells of IL-26 in the mucosa of IBD.

### Innovations and breakthroughs

This study revealed that IL-26 enhanced the induction of inflammatory mediators, IL-6 and IL-8, in the human colonic SEMFs. The inhibitors of IL-26

signaling pathway significantly suppressed the induction of IL-6 and IL-8. The inhibition of IL-26 signaling may lead to the suppression of intestinal inflammation.

### Applications

The results of this study indicated that IL-26 may an important role in the pathogenesis of IBD. The authors suggested that IL-26 can a therapeutic candidate for IBD.

### Terminology

IL-26 is a member of the IL-10 cytokine family. IL-26 is located on chromosome 12q5. IL-26 requires the heterodimeric receptors composed of IL-20R1 and IL-10R2.

### Peer-review

The authors demonstrated that an increased expression of IL-26 in the inflamed mucosa of IBD patients and explored its possible pathway in IBD pathology. The study is well designed and the demonstration seems sufficient.

## REFERENCES

- 1 Goldsmith JR, Sartor RB. The role of diet on intestinal microbiota metabolism: downstream impacts on host immune function and health, and therapeutic implications. *J Gastroenterol* 2014; **49**: 785-798 [PMID: 24652102 DOI: 10.1007/s00535-014-0953-z]
- 2 Sheehan D, Moran C, Shanahan F. The microbiota in inflammatory bowel disease. *J Gastroenterol* 2015; **50**: 495-507 [PMID: 25808229 DOI: 10.1007/s00535-015-1064-1]
- 3 Sun M, Wu W, Liu Z, Cong Y. Microbiota metabolite short chain fatty acids, GPCR, and inflammatory bowel diseases. *J Gastroenterol* 2017; **52**: 1-8 [PMID: 27448578 DOI: 10.1007/s00535-016-1242-9]
- 4 Franke A, Balschun T, Karlsen TH, Svntoraityte J, Nikolaus S, Mayr G, Domingues FS, Albrecht M, Nothnagel M, Ellinghaus D, Sina C, Onnie CM, Weersma RK, Stokkers PC, Wijmenga C, Gazouli M, Strachan D, McArdle WL, Vermeire S, Rutgeerts P, Rosenstiel P, Krawczak M, Vatn MH; IBSEN study group, Mathew CG, Schreiber S. Sequence variants in IL10, ARPC2 and multiple other loci contribute to ulcerative colitis susceptibility. *Nat Genet* 2008; **40**: 1319-1323 [PMID: 18836448 DOI: 10.1038/ng.221]
- 5 Fuyuno Y, Yamazaki K, Takahashi A, Esaki M, Kawaguchi T, Takazoe M, Matsumoto T, Matsui T, Tanaka H, Motoya S, Suzuki Y, Kiyohara Y, Kitazono T, Kubo M. Genetic characteristics of inflammatory bowel disease in a Japanese population. *J Gastroenterol* 2016; **51**: 672-681 [PMID: 26511940 DOI: 10.1007/s00535-015-1135-3]
- 6 Mizoguchi A, Takeuchi T, Himuro H, Okada T, Mizoguchi E. Genetically engineered mouse models for studying inflammatory bowel disease. *J Pathol* 2016; **238**: 205-219 [PMID: 26387641 DOI: 10.1002/path.4640]
- 7 Knappe A, Hör S, Wittmann S, Fickenscher H. Induction of a novel cellular homolog of interleukin-10, AK155, by transformation of T lymphocytes with herpesvirus saimiri. *J Virol* 2000; **74**: 3881-3887 [PMID: 10729163 DOI: 10.1128/JVI.74.8.3881-3887.2000]
- 8 Wilson NJ, Boniface K, Chan JR, McKenzie BS, Blumenschein WM, Mattson JD, Basham B, Smith K, Chen T, Morel F, Lecron JC, Kastelein RA, Cua DJ, McClanahan TK, Bowman EP, de Waal Malefyt R. Development, cytokine profile and function of human interleukin 17-producing helper T cells. *Nat Immunol* 2007; **8**: 950-957 [PMID: 17676044 DOI: 10.1038/ni1497]
- 9 Pène J, Chevalier S, Preisser L, Vénéreau E, Guilleux MH, Ghannam S, Molès JP, Danger Y, Ravon E, Lesaux S, Yssel H, Gascan H. Chronically inflamed human tissues are infiltrated by highly differentiated Th17 lymphocytes. *J Immunol* 2008; **180**: 7423-7430 [PMID: 18490742 DOI: 10.4049/jimmunol.180.11.7423]
- 10 Manel N, Unutmaz D, Littman DR. The differentiation of human T(H)-17 cells requires transforming growth factor-beta and induction of the nuclear receptor RORgamma. *Nat Immunol* 2008; **9**: 641-649 [PMID: 18454151 DOI: 10.1038/ni.1610]
- 11 Cella M, Fuchs A, Vermi W, Facchetti F, Otero K, Lennerz JK, Doherty JM, Mills JC, Colonna M. A human natural killer cell subset provides an innate source of IL-22 for mucosal immunity. *Nature* 2009; **457**: 722-725 [PMID: 18978771 DOI: 10.1038/nature07537]
- 12 Hughes T, Becknell B, McClory S, Briercheck E, Freud AG, Zhang X, Mao H, Nuovo G, Yu J, Caligiuri MA. Stage 3 immature human natural killer cells found in secondary lymphoid tissue constitutively and selectively express the TH 17 cytokine interleukin-22. *Blood* 2009; **113**: 4008-4010 [PMID: 19244159 DOI: 10.1182/blood-2008-12-192443]
- 13 Che KF, Tengvall S, Levänen B, Silverpil E, Smith ME, Awad M, Vikström M, Palmberg L, Qvarfordt I, Sköld M, Lindén A. Interleukin-26 in antibacterial host defense of human lungs. Effects on neutrophil mobilization. *Am J Respir Crit Care Med* 2014; **190**: 1022-1031 [PMID: 25291379 DOI: 10.1164/rccm.201404-0689OC]
- 14 Sziksz E, Pap D, Lippai R, Béres NJ, Fekete A, Szabó AJ, Vannay Á. Fibrosis Related Inflammatory Mediators: Role of the IL-10 Cytokine Family. *Mediators Inflamm* 2015; **2015**: 764641 [PMID: 26199463 DOI: 10.1155/2015/764641]
- 15 Corvaisier M, Delneste Y, Jeanvoine H, Preisser L, Blanchard S, Garo E, Hoppe E, Barré B, Audran M, Bouvard B, Saint-André JP, Jeannin P. IL-26 is overexpressed in rheumatoid arthritis and induces proinflammatory cytokine production and Th17 cell generation. *PLoS Biol* 2012; **10**: e1001395 [PMID: 23055831 DOI: 10.1371/journal.pbio.1001395]
- 16 Dambacher J, Beigel F, Zitzmann K, De Toni EN, Göke B, Diepolder HM, Auernhammer CJ, Brand S. The role of the novel Th17 cytokine IL-26 in intestinal inflammation. *Gut* 2009; **58**: 1207-1217 [PMID: 18483078 DOI: 10.1136/gut.2007.130112]
- 17 Wang T, Diaz-Rosales P, Martin SA, Secombes CJ. Cloning of a novel interleukin (IL)-20-like gene in rainbow trout *Oncorhynchus mykiss* gives an insight into the evolution of the IL-10 family. *Dev Comp Immunol* 2010; **34**: 158-167 [PMID: 19755128 DOI: 10.1016/j.dci.2009.09.003]
- 18 Jones EA, Flavell RA. Distal enhancer elements transcribe intergenic RNA in the IL-10 family gene cluster. *J Immunol* 2005; **175**: 7437-7446 [PMID: 16301651 DOI: 10.4049/jimmunol.175.11.7437]
- 19 Pestka S, Krause CD, Sarkar D, Walter MR, Shi Y, Fisher PB. Interleukin-10 and related cytokines and receptors. *Annu Rev Immunol* 2004; **22**: 929-979 [PMID: 15032600 DOI: 10.1146/annurev.immunol.22.012703.104622]
- 20 Sheikh F, Baurin VV, Lewis-Antes A, Shah NK, Smirnov SV, Anantha S, Dickensheets H, Dumoutier L, Renauld JC, Zdanov A, Donnelly RP, Kotenko SV. Cutting edge: IL-26 signals through a novel receptor complex composed of IL-20 receptor 1 and IL-10 receptor 2. *J Immunol* 2004; **172**: 2006-2010 [PMID: 14764663 DOI: 10.4049/jimmunol.172.4.2006]
- 21 Blumberg H, Conklin D, Xu WF, Grossmann A, Brender T, Carollo S, Eagan M, Foster L, Haldeman BA, Hammond A, Haugen H, Jelinek L, Kelly JD, Madden K, Maurer MF, Parrish-Novak J, Prunkard D, Sexson S, Sprecher C, Waggie K, West J, Whitmore TE, Yao L, Kuechle MK, Dale BA, Chandrasekhar YA. Interleukin 20: discovery, receptor identification, and role in epidermal function. *Cell* 2001; **104**: 9-19 [PMID: 11163236 DOI: 10.1016/S0092-8674(01)00187-8]
- 22 Hör S, Pirzer H, Dumoutier L, Bauer F, Wittmann S, Sticht H, Renauld JC, de Waal Malefyt R, Fickenscher H. The T-cell lymphokine interleukin-26 targets epithelial cells through the interleukin-20 receptor 1 and interleukin-10 receptor 2 chains. *J Biol Chem* 2004; **279**: 33343-33351 [PMID: 15178681 DOI: 10.1074/jbc.M405000200]
- 23 Andoh A, Bamba S, Brittan M, Fujiyama Y, Wright NA. Role of intestinal subepithelial myofibroblasts in inflammation and regenerative response in the gut. *Pharmacol Ther* 2007; **114**:

- 94-106 [PMID: 17328956 DOI: 10.1016/j.pharmthera.2006.12.004]
- 24 **Powell DW**, Mifflin RC, Valentich JD, Crowe SE, Saada JI, West AB. Myofibroblasts. I. Paracrine cells important in health and disease. *Am J Physiol* 1999; **277**: C1-C9 [PMID: 10409103]
  - 25 **Powell DW**, Mifflin RC, Valentich JD, Crowe SE, Saada JI, West AB. Myofibroblasts. II. Intestinal subepithelial myofibroblasts. *Am J Physiol* 1999; **277**: C183-C201 [PMID: 10444394]
  - 26 **Miot C**, Beaumont E, Duluc D, Le Guillou-Guillemette H, Preisser L, Garo E, Blanchard S, Hubert Fouchard I, Créminon C, Lamourette P, Fremaux I, Calès P, Lunel-Fabiani F, Boursier J, Braum O, Fickenscher H, Roingeard P, Delneste Y, Jeannin P. IL-26 is overexpressed in chronically HCV-infected patients and enhances TRAIL-mediated cytotoxicity and interferon production by human NK cells. *Gut* 2015; **64**: 1466-1475 [PMID: 25183206 DOI: 10.1136/gutjnl-2013-306604]
  - 27 **Rachmilewitz D**. Coated mesalazine (5-aminosalicylic acid) versus sulphasalazine in the treatment of active ulcerative colitis: a randomised trial. *BMJ* 1989; **298**: 82-86 [PMID: 2563951]
  - 28 **Best WR**, Becktel JM, Singleton JW. Rederived values of the eight coefficients of the Crohn's Disease Activity Index (CDAI). *Gastroenterology* 1979; **77**: 843-846 [PMID: 467941]
  - 29 **Fujino S**, Andoh A, Bamba S, Ogawa A, Hata K, Araki Y, Bamba T, Fujiyama Y. Increased expression of interleukin 17 in inflammatory bowel disease. *Gut* 2003; **52**: 65-70 [PMID: 12477762 DOI: 10.1136/gut.52.1.65]
  - 30 **Mahida YR**, Beltinger J, Makh S, Göke M, Gray T, Podolsky DK, Hawkey CJ. Adult human colonic subepithelial myofibroblasts express extracellular matrix proteins and cyclooxygenase-1 and -2. *Am J Physiol* 1997; **273**: G1341-G1348 [PMID: 9435560]
  - 31 **Andoh A**, Fujino S, Bamba S, Araki Y, Okuno T, Bamba T, Fujiyama Y. IL-17 selectively down-regulates TNF-alpha-induced RANTES gene expression in human colonic subepithelial myofibroblasts. *J Immunol* 2002; **169**: 1683-1687 [PMID: 12165487 DOI: 10.4049/jimmunol.169.4.1683]
  - 32 **Nishida A**, Andoh A, Imaeda H, Inatomi O, Shiomi H, Fujiyama Y. Expression of interleukin 1-like cytokine interleukin 33 and its receptor complex (ST2L and IL1RAcP) in human pancreatic myofibroblasts. *Gut* 2010; **59**: 531-541 [PMID: 19996325 DOI: 10.1136/gut.2009.193599]
  - 33 **Nishida A**, Nagahama K, Imaeda H, Ogawa A, Lau CW, Kobayashi T, Hisamatsu T, Preffer FI, Mizoguchi E, Ikeuchi H, Hibi T, Fukuda M, Andoh A, Blumberg RS, Mizoguchi A. Inducible colitis-associated glycome capable of stimulating the proliferation of memory CD4+ T cells. *J Exp Med* 2012; **209**: 2383-2394 [PMID: 23209314 DOI: 10.1084/jem.20112631]
  - 34 **Shimada M**, Andoh A, Hata K, Tasaki K, Araki Y, Fujiyama Y, Bamba T. IL-6 secretion by human pancreatic periacinar myofibroblasts in response to inflammatory mediators. *J Immunol* 2002; **168**: 861-868 [PMID: 11777983 DOI: 10.4049/jimmunol.168.2.861]
  - 35 **Andoh A**, Shioya M, Nishida A, Bamba S, Tsujikawa T, Kim-Mitsuyama S, Fujiyama Y. Expression of IL-24, an activator of the JAK1/STAT3/SOCS3 cascade, is enhanced in inflammatory bowel disease. *J Immunol* 2009; **183**: 687-695 [PMID: 19535621 DOI: 10.4049/jimmunol.0804169]
  - 36 **Risbud MV**, Shapiro IM. Role of cytokines in intervertebral disc degeneration: pain and disc content. *Nat Rev Rheumatol* 2014; **10**: 44-56 [PMID: 24166242 DOI: 10.1038/nrrheum.2013.160]
  - 37 **Andoh A**, Zhang Z, Inatomi O, Fujino S, Deguchi Y, Araki Y, Tsujikawa T, Kitoh K, Kim-Mitsuyama S, Takayanagi A, Shimizu N, Fujiyama Y. Interleukin-22, a member of the IL-10 subfamily, induces inflammatory responses in colonic subepithelial myofibroblasts. *Gastroenterology* 2005; **129**: 969-984 [PMID: 16143135 DOI: 10.1053/j.gastro.2005.06.071]
  - 38 **Silverberg MS**, Cho JH, Rioux JD, McGovern DP, Wu J, Annese V, Achkar JP, Goyette P, Scott R, Xu W, Barmada MM, Klei L, Daly MJ, Abraham C, Bayless TM, Bossa F, Griffiths AM, Ippoliti AF, Lahaie RG, Latiano A, Paré P, Proctor DD, Regueiro MD, Steinhart AH, Targan SR, Schumm LP, Kistner EO, Lee AT, Gregersen PK, Rotter JI, Brant SR, Taylor KD, Roeder K, Duerr RH. Ulcerative colitis-risk loci on chromosomes 1p36 and 12q15 found by genome-wide association study. *Nat Genet* 2009; **41**: 216-220 [PMID: 19122664 DOI: 10.1038/ng.275]
  - 39 **Dige A**, Støy S, Rasmussen TK, Kelsen J, Hvas CL, Sandahl TD, Dahlerup JF, Deleuran B, Agnholt J. Increased levels of circulating Th17 cells in quiescent versus active Crohn's disease. *J Crohns Colitis* 2013; **7**: 248-255 [PMID: 22784949 DOI: 10.1016/j.crohns.2012.06.015]

**P- Reviewer:** Marzaban R, Pastorelli R, Reyes VE, Wu ZQ, Zimmer V  
**S- Editor:** Ma YJ **L- Editor:** A **E- Editor:** Zhang FF





Basic Study

# Autophagic cell death induced by reactive oxygen species is involved in hyperthermic sensitization to ionizing radiation in human hepatocellular carcinoma cells

Guang-Jin Yuan, Jun-Jian Deng, De-Dong Cao, Lei Shi, Xin Chen, Jin-Ju Lei, Xi-Ming Xu

Guang-Jin Yuan, Department of Oncology, Nationality Hospital of Qianjiang, Chongqing 409000, China

Jun-Jian Deng, De-Dong Cao, Lei Shi, Xin Chen, Jin-Ju Lei, Xi-Ming Xu, Cancer Center, Renmin Hospital of Wuhan University, Wuhan 430060, Hubei Province, China

**Author contributions:** Yuan GJ designed the study and wrote the manuscript; Deng JJ performed the majority of experiments; Cao DD, Shi L, Chen X and Lei JJ performed some experiments of the study and data analysis; Xu XM provided partial financial support for this work and was involved in editing the manuscript.

**Supported by** Science and Technology Program of Chongqing, No. 2013-2-179.

**Institutional review board statement:** HepG2 cells were used in the study, and no specimens were taken clinically. Therefore, the ethic approval was not required.

**Conflict-of-interest statement:** No conflict of interest exists.

**Data sharing statement:** No additional data are available.

**Open-Access:** This article is an open-access article which was selected by an in-house editor and fully peer-reviewed by external reviewers. It is distributed in accordance with the Creative Commons Attribution Non Commercial (CC BY-NC 4.0) license, which permits others to distribute, remix, adapt, build upon this work non-commercially, and license their derivative works on different terms, provided the original work is properly cited and the use is non-commercial. See: <http://creativecommons.org/licenses/by-nc/4.0/>

**Manuscript source:** Unsolicited manuscript

**Correspondence to:** Xi-Ming Xu, Professor, PhD, Cancer Center, Renmin Hospital of Wuhan University, Wuhan 430060, No. 9 Ziyang road, Hubei Province, China. [rm001271@whu.edu.cn](mailto:rm001271@whu.edu.cn)  
Telephone: +86-27-88041911  
Fax: +86-27-88042292

Received: March 15, 2017

Peer-review started: March 17, 2017

First decision: May 16, 2017

Revised: May 26, 2017

Accepted: July 4, 2017

Article in press: July 4, 2017

Published online: August 14, 2017

## Abstract

### AIM

To investigate whether autophagic cell death is involved in hyperthermic sensitization to ionizing radiation in human hepatocellular carcinoma cells, and to explore the underlying mechanism.

### METHODS

Human hepatocellular carcinoma cells were treated with hyperthermia and ionizing radiation. MTT and clonogenic assays were performed to determine cell survival. Cell autophagy was detected using acridine orange staining and flow cytometric analysis, and the expression of autophagy-associated proteins, LC3 and p62, was determined by Western blot analysis. Intracellular reactive oxygen species (ROS) were quantified using the fluorescent probe DCFH-DA.

### RESULTS

Treatment with hyperthermia and ionizing radiation significantly decreased cell viability and surviving fraction as compared with hyperthermia or ionizing radiation alone. Cell autophagy was significantly increased after ionizing radiation combined with hyperthermia treatment, as evidenced by increased formation of acidic vesicular organelles, increased expression of LC3II and decreased expression of p62. Intracellular ROS were also increased after combined

treatment with hyperthermia and ionizing radiation. Pretreatment with N-acetylcysteine, an ROS scavenger, markedly inhibited the cytotoxicity and cell autophagy induced by hyperthermia and ionizing radiation.

### CONCLUSION

Autophagic cell death is involved in hyperthermic sensitization of cancer cells to ionizing radiation, and its induction may be due to the increased intracellular ROS.

**Key words:** Autophagic cell death; Hyperthermia; Ionizing radiation; Hepatocellular carcinoma; Reactive oxygen species

© The Author(s) 2017. Published by Baishideng Publishing Group Inc. All rights reserved.

**Core tip:** Increased cell autophagy and intracellular reactive oxygen species (ROS), accompanied by decreased cell viability and surviving fraction, were observed in HepG2 cells treated with hyperthermia and ionizing radiation. Pretreatment with N-acetylcysteine, an ROS scavenger, markedly inhibited the above cytotoxicity and cell autophagy. The results suggest that autophagic cell death is involved in the hyperthermic sensitization to ionizing radiation, and its induction may be due to the increased intracellular ROS.

Yuan GJ, Deng JJ, Cao DD, Shi L, Chen X, Lei JJ, Xu XM. Autophagic cell death induced by reactive oxygen species is involved in hyperthermic sensitization to ionizing radiation in human hepatocellular carcinoma cells. *World J Gastroenterol* 2017; 23(30): 5530-5537 Available from: URL: <http://www.wjgnet.com/1007-9327/full/v23/i30/5530.htm> DOI: <http://dx.doi.org/10.3748/wjg.v23.i30.5530>

## INTRODUCTION

Hepatocellular carcinoma (HCC) is the third most common cancer and the second leading cause of cancer-associated mortality in China<sup>[1]</sup>. A majority of patients with HCC present unresectable or advanced disease at the time of diagnosis; the choice of treatment is limited and the prognosis is poor<sup>[2]</sup>. With the development of radiotherapy techniques, including intensity-modulated radiotherapy (IMRT) and stereotactic body radiation therapy (SBRT), the use of radiotherapy has increasingly been adopted for the treatment of HCC<sup>[3]</sup>. Hyperthermia, elevation of temperature inside tumor up to 40-42 °C, is an effective treatment modality for cancer<sup>[4]</sup>. Hyperthermia is a potent radiation sensitizer<sup>[5]</sup>, and its combination with radiotherapy is a promising method for cancer treatment. Several studies have demonstrated the efficacy of combined treatment with radiotherapy and hyperthermia against HCC, head and neck cancer, breast cancer, and melanoma<sup>[6-9]</sup>. Hyperthermia can

increase tumor perfusion and oxygenation, and inhibit repair of DNA damage in tumor cells, all of which may enhance tumor radiosensitivity<sup>[10,11]</sup>. However, the underlying mechanisms of the radio-sensitizing effect of hyperthermia are not fully elucidated.

Autophagy is an evolutionarily conserved process in which cellular organelles and long-lived proteins are sequestered into double-membrane vesicles, the autophagosomes, and subsequently delivered to the lysosomes to be degraded or recycled<sup>[12]</sup>. It can be induced by a variety of stimuli, such as nutrient deprivation, hypoxia, reactive oxygen species (ROS), protein aggregates, and damaged organelles<sup>[13]</sup>. Anticancer therapies, such as chemotherapy, radiotherapy and hyperthermia, are also shown to induce autophagy within tumor cells<sup>[14-16]</sup>. Studies have shown that increased basal autophagy is required for cells to survive after physical or chemical damage<sup>[17]</sup>. However, excessive autophagy can induce type II programmed cell death (autophagic cell death), a form of nonapoptotic cell death<sup>[18]</sup>. In the present study, we showed that autophagic cell death is involved in hyperthermic sensitization to ionizing radiation in human HCC cells, and its induction may be due to the increased intracellular ROS.

## MATERIALS AND METHODS

### Cell culture

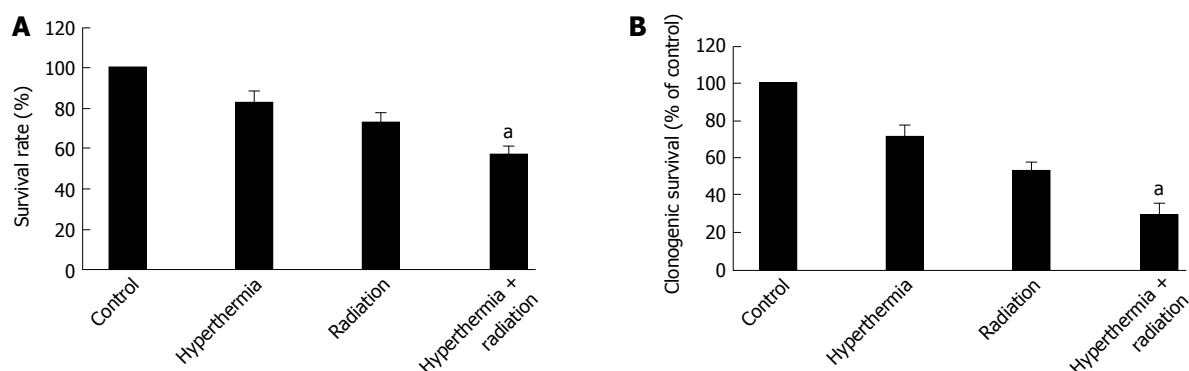
Human HCC cell line HepG2 was obtained from Wuhan University Cell Center. Cells were cultured in RPMI 1640 medium supplemented with 10% fetal bovine serum, 100 U/mL streptomycin and 100 U/mL penicillin in a humidified 5% CO<sub>2</sub> atmosphere at 37 °C.

### Treatment of cells with hyperthermia and ionizing radiation

Water-bath warming was performed and the temperature was controlled at 43 °C. Cell culture bottles were packaged and put into the water at 43 °C for 0.5 h. Then cells were irradiated with 4 Gy of 6 MV X-ray beam (field, 10 cm × 10 cm; source-to-surface distance, 100 cm; dose rate, 0.8 Gy/min), using a Varian Clinac 23iX (Varian Medical Systems, Inc.) at room temperature. The period between the two treatments was less than 1 h. After irradiation, the cells were immediately returned to the cell incubator and incubated at 37 °C for 72 h.

### MTT assay

MTT [3-(4,5-dimethylthiazol-2-yl)-2,5-diphenyl-tetrazolium bromide] colorimetric assay was used to determine the survival rate of cells. After the above treatment, the cells were washed with phosphate buffered saline (PBS), and incubated with 1 × MTT at 37 °C for 4 h. Then the absorbance at 570 nm was measured, and the survival rate of the cells was calculated according to the following equation: survival rate = (experimental absorbance



**Figure 1** Hyperthermia enhances the cytotoxicity of ionizing radiation to hepatocellular carcinoma cells. HepG2 cells were treated with hyperthermia (43 °C for 0.5 h) followed by ionizing radiation (4 Gy). After 72 h of incubation, the cells were assessed for cell viability using MTT assay (A), or plated in dishes and incubated for clonogenic survival assay (B). The results are presented as the mean  $\pm$  SD of three different experiments. <sup>a</sup> $P < 0.05$  vs treatment of ionizing radiation alone.

value/control absorbance value)  $\times$  100%.

### Clonogenic assay

After treatment with hyperthermia or ionizing radiation, the cells were trypsinized into single-cell suspension, plated in 60-mm dishes and incubated for 14 d to allow for colony growth. Then, the cells were fixed and stained with crystal violet, and colonies having at least 50 cells were counted using a microscope.

### Acridine orange staining and flow cytometric analysis

Formation of acidic vesicular organelles, a morphological characteristic of autophagy, was detected using acridine orange staining. Cells were incubated with acridine orange (Invitrogen) at 1  $\mu$ g/mL for 15 min. Red (650 nm, stained cytoplasmic vesicles) vs green (510-530 nm, stained nuclei) fluorescence (FL3/FL1) from cells illuminated with blue (488 nm) excitation light was measured with a FACScan flow cytometer (Beckman Coulter, Brea, CA, United States). The data are presented as the fold changes with an arbitrary setting of autophagy in cells without treatment of drug, hyperthermia or radiation.

### Western blot analysis

Protein lysates were prepared using a total protein extraction kit (ProMab, SJ-200501), and stored at -20 °C until assay. The protein concentrations were assayed using the Bradford method. Equivalent aliquots of protein were separated by 10% SDS-PAGE, and transferred onto nitrocellulose membranes. The membranes were blocked with 5% nonfat dry milk in PBS for 2 h at 37 °C, washed with PBST (PBS with Tween 20) and incubated with rabbit polyclonal antibody against LC3 (dilution 1:500, CST) or p62 (dilution 1:500, CST) or mouse polyclonal antibody against GAPDH (glyceraldehyde 3-phosphate dehydrogenase, dilution 1:800, SANTA) at 4 °C overnight. After washing with PBST four times, the membranes were incubated with a secondary antibody (HRP-conjugated goat anti-rabbit IgG, SANTA, dilution 1:40000, for LC3 and p62; goat anti-mouse

IgG, ZYMED, dilution 1:80000, for GAPDH) for 1 h at room temperature. The immunoreactive proteins were detected using an enhanced chemiluminescent detection system.

### Determination of intracellular ROS

Intracellular ROS were measured using a ROS assay kit. After the above designated treatment, the cells were harvested and incubated with 10  $\mu$ mol/L of DCFH-DA (a fluorescent probe, which may be oxidized by ROS in viable cells to 2',7'-dichlorofluorescein, DCF) for 30 min at 37 °C. After washing three times with PBS, DCF fluorescence was quantified with a multi-detection microplate reader (485 nm excitation and 535 nm emission).

### Treatment of cells with N-acetylcysteine

N-acetylcysteine is an ROS scavenger. Cells were pretreated with N-acetylcysteine (10 mmol/L) for 1 h and then treated with hyperthermia or ionizing radiation as above.

### Statistical analysis

Data were pooled from at least three independent experiments, and presented as mean  $\pm$  SD unless otherwise indicated. Differences between groups were analyzed using one-way analysis of variance (ANOVA). All the statistical analyses were performed with SPSS13.0.  $P$  values less than 0.05 were considered statistically significant.

## RESULTS

### Hyperthermia enhances radiation cytotoxicity to HCC cells

The cytotoxicity induced by ionizing radiation with or without hyperthermia was assessed by MTT and clonogenic survival assays. As shown in Figure 1A, cell viability was decreased when the cells were treated with ionizing radiation or hyperthermia. The cell viability was significantly decreased after combined treatment with ionizing radiation and hyperthermia when

compared with each treatment alone. Furthermore, the clonogenic survival of the cells was also significantly decreased after ionizing radiation with hyperthermia as compared with radiation alone (Figure 1B).

#### ***Hyperthermia increases cell autophagy induced by ionizing radiation in HCC cells***

Cell autophagy is characterized by the formation of numerous acidic vesicular organelles, which can be detected using acridine orange staining<sup>[19]</sup>. The acridine orange staining was quantified using flow cytometry. No obvious increase in cell autophagy was observed in HepG2 cells following 2 Gy ionizing radiation, or until 48 h after 4 Gy ionizing radiation. Therefore, in the present study, 4 Gy ionizing radiation was given to cells, and the cells were tested 72 h after ionizing radiation. As shown in Figure 2A and B, cell autophagy was significantly increased after combined treatment with ionizing radiation and hyperthermia compared with each treatment alone.

The expression of autophagy-related proteins was also detected by Western blot, among which the increase of LC3II protein and reduction of p62 protein are the hallmarks of the induction of autophagy<sup>[19]</sup>. A significant increase in LC3II expression and a reduction of p62 expression were observed in cells undergoing combined treatment as compared with those receiving ionizing radiation or hyperthermia treatment alone (Figure 2C).

#### ***N-acetylcysteine inhibits cytotoxicity and cell autophagy induced by hyperthermia and ionizing radiation in HCC cells***

The intracellular ROS in ionizing radiation or hyperthermia-treated HepG2 cells were measured using a fluorescent probe, DCFH-DA. Treatment with ionizing radiation or hyperthermia induced an increase in intracellular ROS content, which was further increased by the combined treatment; however, the increase was completely inhibited by N-acetylcysteine, an ROS scavenger (Figure 3A).

To evaluate whether ionizing radiation or hyperthermia-induced autophagic cell death is related to intracellular ROS in HepG2 cells, pretreatment with N-acetylcysteine was performed. N-acetylcysteine pretreatment significantly improved cell viability in ionizing radiation or hyperthermia-treated HepG2 cells using MTT assay (Figure 3B). Furthermore, the autophagy rate was decreased (Figure 3C), and the expression of autophagy-related proteins, LC3II and p62, was reversed by N-acetylcysteine pretreatment in the ionizing radiation or hyperthermia-treated HepG2 cells (Figure 3D), suggesting that cell autophagy was inhibited.

## **DISCUSSION**

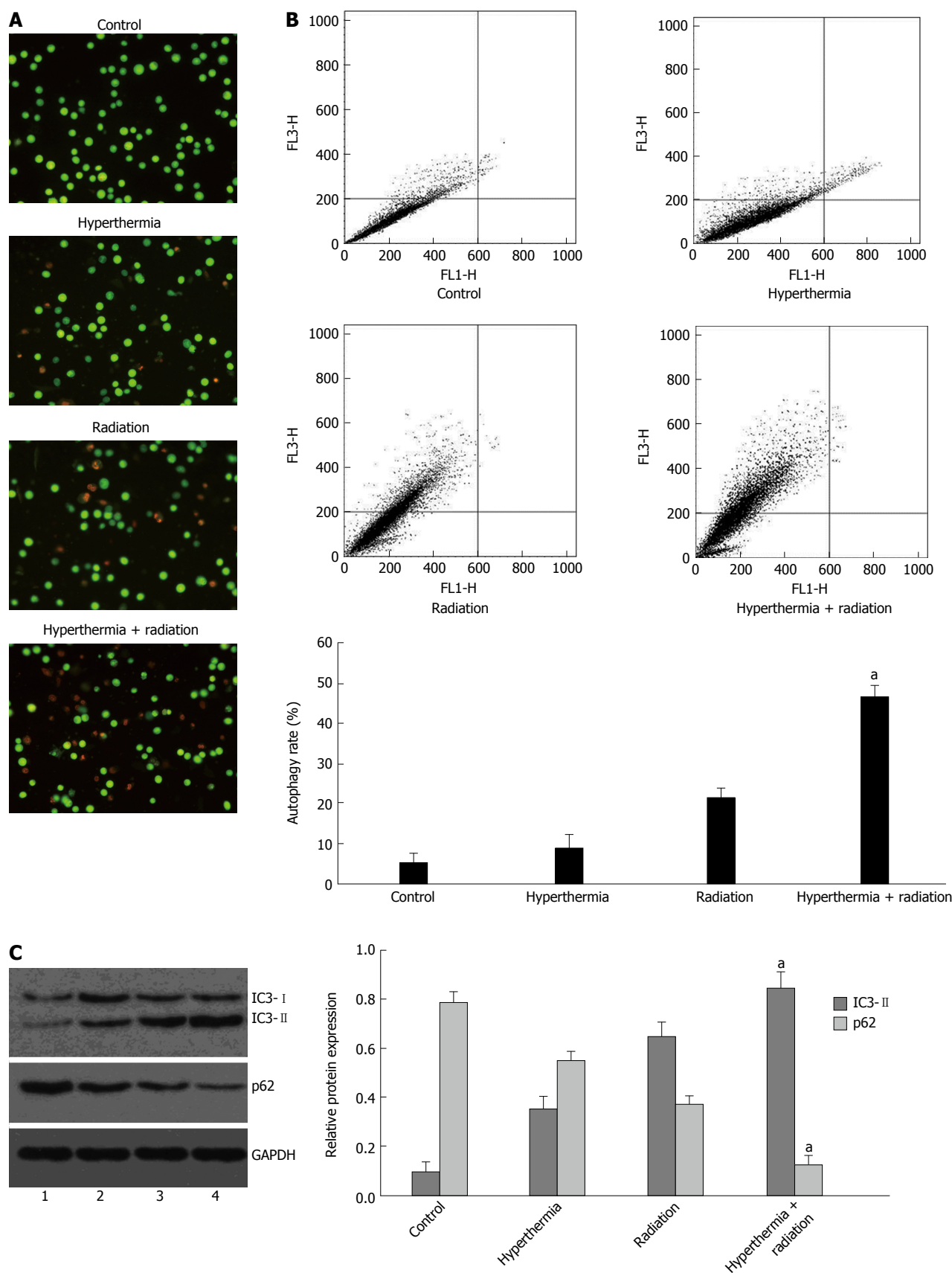
In the past, radiotherapy was less considered in the

treatment of HCC due to the belief that HCC is not a "radiosensitive" tumor and that radiotherapy is too "toxic" for the liver. However, recent studies have demonstrated that HCC is a radiosensitive tumor and its radiosensitivity is equivalent to poorly differentiated squamous cell carcinomas<sup>[20]</sup>. With the development of radiotherapy techniques, including IMRT and SBRT, a high radiation dose can be delivered to the tumor while the dose to the normal tissues can be simultaneously reduced. Therefore, at present radiotherapy is increasingly used for the treatment of HCC<sup>[3]</sup>. In the present study, we observed that the cell viability and clonogenic survival of HCC cells were decreased following ionizing radiation, suggesting that HCC cells are sensitive to radiation. Hyperthermia is a potent radiation sensitizer<sup>[5]</sup>, and combined treatment with radiotherapy and hyperthermia has been shown to be efficacious against HCC<sup>[6]</sup>. Our study also showed that ionizing radiation combined with hyperthermia led to a significant decrease in the cell viability and clonogenic survival of HCC cells as compared with each treatment alone.

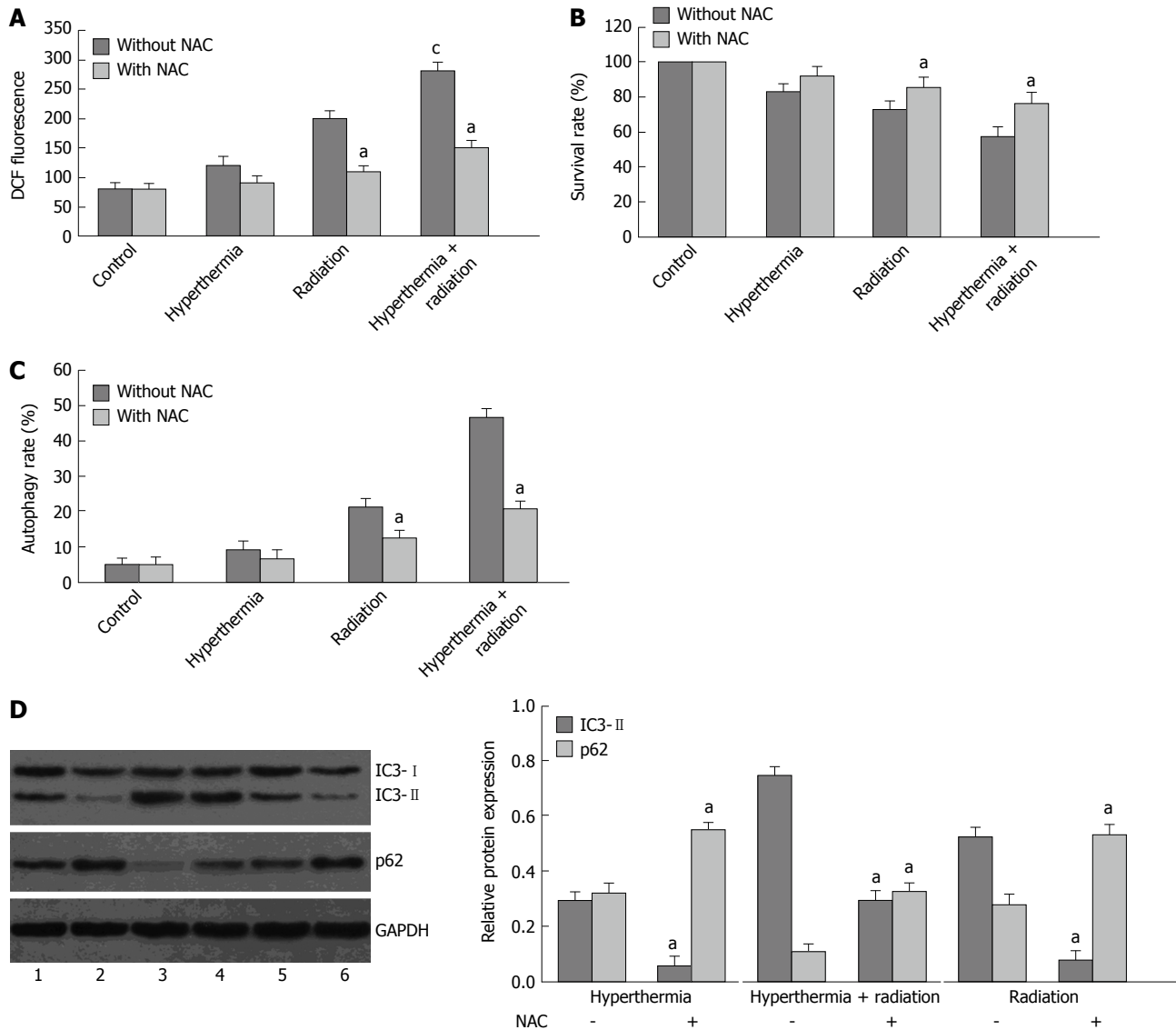
Autophagy is a major intracellular degradation mechanism for long-lived proteins and cytoplasmic organelles, the products of which are recycled to maintain cellular homeostasis. Increased basal autophagy is a cell survival mechanism in response to several stresses, such as nutrient deprivation, hypoxia, damaged mitochondria, protein aggregation and pathogens<sup>[17,21]</sup>. However, excessive autophagy may result in cell death, which is designated as type II programmed cell death (autophagic cell death)<sup>[18]</sup>. Autophagy is frequently activated in tumor cells following anticancer therapies, such as chemotherapy, radiotherapy and hyperthermia<sup>[14-16]</sup>. Although several studies showed that induction of autophagy after irradiation acts as a protective and prosurvival mechanism and contributes to radioresistance in breast tumor cells and glioma cells<sup>[22,23]</sup>, most experimental data have suggested that radiation-induced autophagy in cancer cell lines is related to cell death mechanisms and that autophagy-inducing agents may act as radiosensitizers<sup>[24]</sup>. In the present study, radiation-induced autophagy was significantly increased after combined treatment with hyperthermia in HCC cells, as evidenced by increased formation of acidic vesicular organelles, increased expression of LC3II and decreased expression of p62. The increased autophagy was accompanied with decreased cell viability and clonogenic survival in HCC cells, suggesting that autophagic cell death is involved in the enhancement of cellular radiosensitivity by hyperthermia.

ROS are small and highly reactive molecules that can oxidize proteins, DNA and lipids. They are generated as by-products of cellular metabolism primarily in mitochondria, and can also be produced in response to a variety of stimuli such as growth factors, inflammatory cytokines, ionizing radiation,





**Figure 2** Hyperthermia increases ionizing radiation-induced autophagy in hepatocellular carcinoma cells. HepG2 cells were treated with hyperthermia (43 °C for 0.5 h) followed by ionizing radiation (4 Gy). After 72 h of incubation, the cells were assessed for autophagy by flow cytometry using acridine orange staining (A and B), or by Western blot analysis of LC3II and p62 expression (C) (Lane 1: Control; 2: Hyperthermia; 3: Radiation; 4: Hyperthermia + radiation). Results are presented as the mean  $\pm$  SD of three different experiments, or representative of three different experiments. <sup>a</sup> $P < 0.05$  vs treatment of ionizing radiation alone.



**Figure 3** Intracellular reactive oxygen species formation and effect of N-acetylcysteine on the cytotoxicity and cell autophagy in hepatocellular carcinoma cells after treatment with ionizing radiation or hyperthermia. HepG2 cells were treated with hyperthermia (43 °C for 0.5 h) followed by ionizing radiation (4 Gy). After 72 h of incubation, the cells were assessed for intracellular ROS contents using DCFH-DA (A). HepG2 cells were pretreated with N-acetylcysteine (NAC, 10 mmol/L) for 1 h, and then treated with hyperthermia or ionizing radiation as above. After 72 h of incubation, the cells were assessed for cell viability using MTT assay (B), or for autophagy by flow cytometry using acridine orange staining (C) and by Western blot analysis of LC3II and p62 expression (D) (Lane 1: Hyperthermia; 2: Hyperthermia + NAC; 3: Hyperthermia + radiation; 4: Radiation; 5: Hyperthermia + radiation + NAC; 6: Radiation + NAC). Results are presented as the mean  $\pm$  SD of three different experiments, or representative of three different experiments. <sup>c</sup> $P < 0.05$  vs treatment of ionizing radiation or hyperthermia alone. <sup>a</sup> $P < 0.05$  vs no pretreatment of NAC (e.g., radiation vs NAC + radiation).

chemotherapy agents and toxins<sup>[25]</sup>. Hyperthermia has been also shown to induce production of ROS. A sharp increase in ROS generation has been observed after hyperthermia in a cellular model, using electron paramagnetic resonance spin trapping<sup>[26]</sup>. In the present study, we showed that intracellular ROS content was increased after treatment with ionizing radiation or hyperthermia, and was further increased by their combined treatment. Once ROS are produced, they act as signaling molecules that trigger diverse physiological and pathological responses, including induction of autophagy. Accumulating evidence has shown that oxidative stress is the converging point of

many different inducers of autophagy, such as nutrient deprivation, viral infection and genotoxic stress<sup>[27]</sup>. In the present study, we found that pretreatment with N-acetylcysteine, an ROS scavenger, abolished the induction of autophagy by ionizing radiation or hyperthermia, and improved cell viability of HepG2 cells after the above treatment. These facts suggest that the induction of autophagic cell death by ionizing radiation and hyperthermia treatment in HCC cells is due to the increased intracellular ROS.

In conclusion, autophagic cell death is involved in hyperthermic sensitization of cancer cells to ionizing radiation, and its induction may be due to the increased

intracellular ROS.

## COMMENTS

### Background

With the development of radiotherapy techniques, radiotherapy has increasingly been used for the treatment of hepatocellular carcinoma (HCC). Hyperthermia is a useful adjuvant to radiation therapy in the treatment of many cancers, and it is a potent radiation sensitizer. However, the underlying mechanisms of the radio-sensitizing effect of hyperthermia are not fully elucidated. Autophagy is a major intracellular degradation mechanism for long-lived proteins and cytoplasmic organelles, and excessive autophagy may result in cell death, which is designated as type II programmed cell death (autophagic cell death). The role autophagic cell death in hyperthermic sensitization to ionizing radiation has not been explored.

### Research frontiers

Many studies have shown that radiation-induced autophagy is related to cell death mechanisms in cancer cell lines and that autophagy-inducing agents may act as radiosensitizers. Oxidative stress has been proven to be the converging point of many different inducers of autophagy, such as nutrient deprivation, viral infection and genotoxic stress.

### Innovations and breakthroughs

The novel findings of this study are that autophagic cell death is involved in hyperthermic sensitization to ionizing radiation, and its induction may be due to the increased intracellular reactive oxygen species.

### Applications

The study provides a novel theoretical basis for hyperthermia in the treatment of malignant tumors, especially combined with radiotherapy.

### Terminology

Autophagy is an evolutionarily conserved process in which cellular organelles and long-lived proteins are sequestered into double-membrane vesicles, the autophagosomes, and subsequently delivered to the lysosomes to be degraded or recycled. Autophagic cell death is a kind of nonapoptotic programmed cell death (also known as type II programmed cell death), characterized by using autophagosome to degrade cell content in dying cells.

### Peer-review

HCC is still the object of research and this paper provides some information on the mechanism of hyperthermic sensitization of cancer cells to ionizing radiation.

## REFERENCES

- Chen W, Zheng R, Zeng H, Zhang S. The incidence and mortality of major cancers in China, 2012. *Chin J Cancer* 2016; **35**: 73 [PMID: 27484217 DOI: 10.1186/s40880-016-0137-8]
- Balogh J, Victor D 3rd, Asham EH, Burroughs SG, Boktour M, Saharia A, Li X, Ghobrial RM, Monsour HP Jr. Hepatocellular carcinoma: a review. *J Hepatocell Carcinoma* 2016; **3**: 41-53 [PMID: 27785449]
- Park SH, Kim JC, Kang MK. Technical advances in external radiotherapy for hepatocellular carcinoma. *World J Gastroenterol* 2016; **22**: 7311-7321 [PMID: 27621577 DOI: 10.3748/wjg.v22.i32.7311]
- Hurwitz M, Stauffer P. Hyperthermia, radiation and chemotherapy: the role of heat in multidisciplinary cancer care. *Semin Oncol* 2014; **41**: 714-729 [PMID: 25499632 DOI: 10.1053/j.seminoncol.2014.09.014]
- Horsman MR, Overgaard J. Hyperthermia: a potent enhancer of radiotherapy. *Clin Oncol (R Coll Radiol)* 2007; **19**: 418-426 [PMID: 17493790 DOI: 10.1016/j.clon.2007.03.015]
- Dong Y, Wu G. Analysis of short and long term therapeutic effects of radiofrequency hyperthermia combined with conformal radiotherapy in hepatocellular carcinoma. *J BUON* 2016; **21**: 407-411 [PMID: 27273951]
- Datta NR, Rogers S, Ordóñez SG, Puric E, Bodis S. Hyperthermia and radiotherapy in the management of head and neck cancers: A systematic review and meta-analysis. *Int J Hyperthermia* 2016; **32**: 31-40 [PMID: 26928474 DOI: 10.3109/02656736.2015.1099746]
- Datta NR, Puric E, Klingbiel D, Gomez S, Bodis S. Hyperthermia and Radiation Therapy in Locoregional Recurrent Breast Cancers: A Systematic Review and Meta-analysis. *Int J Radiat Oncol Biol Phys* 2016; **94**: 1073-1087 [PMID: 26899950 DOI: 10.1016/j.ijrobp.2015.12.361]
- Werthmüller N, Frey B, Rückert M, Lotter M, Fietkau R, Gaipl US. Combination of ionising radiation with hyperthermia increases the immunogenic potential of B16-F10 melanoma cells in vitro and in vivo. *Int J Hyperthermia* 2016; **32**: 23-30 [PMID: 26754406 DOI: 10.3109/02656736.2015.1106011]
- Sen A, Capitano ML, Sperryak JA, Schueckler JT, Thomas S, Singh AK, Evans SS, Hylander BL, Repasky EA. Mild elevation of body temperature reduces tumor interstitial fluid pressure and hypoxia and enhances efficacy of radiotherapy in murine tumor models. *Cancer Res* 2011; **71**: 3872-3880 [PMID: 21512134 DOI: 10.1158/0008-5472.CAN-10-4482]
- Oei AL, Vriend LE, Crezee J, Franken NA, Krawczyk PM. Effects of hyperthermia on DNA repair pathways: one treatment to inhibit them all. *Radiat Oncol* 2015; **10**: 165 [PMID: 26245485 DOI: 10.1186/s13014-015-0462-0]
- Lin L, Baehrecke EH. Autophagy, cell death, and cancer. *Mol Cell Oncol* 2015; **2**: e985913 [PMID: 27308466 DOI: 10.4161/23723556.2014.985913]
- McEwan DG, Dikic I. The Three Musketeers of Autophagy: phosphorylation, ubiquitylation and acetylation. *Trends Cell Biol* 2011; **21**: 195-201 [PMID: 21277210 DOI: 10.1016/j.tcb.2010.12.006]
- Notte A, Leclerc L, Michiels C. Autophagy as a mediator of chemotherapy-induced cell death in cancer. *Biochem Pharmacol* 2011; **82**: 427-434 [PMID: 21704023 DOI: 10.1016/j.bcp.2011.06.015]
- Gewirtz DA, Hilliker ML, Wilson EN. Promotion of autophagy as a mechanism for radiation sensitization of breast tumor cells. *Radiother Oncol* 2009; **92**: 323-328 [PMID: 19541381 DOI: 10.1016/j.radonc.2009.05.022]
- Zhao Y, Gong S, Shunmei E, Zou J. Induction of macroautophagy by heat. *Mol Biol Rep* 2009; **36**: 2323-2327 [PMID: 19152020 DOI: 10.1007/s11033-009-9451-4]
- Anding AL, Baehrecke EH. Autophagy in Cell Life and Cell Death. *Curr Top Dev Biol* 2015; **114**: 67-91 [PMID: 26431564 DOI: 10.1016/bs.ctdb.2015.07.012]
- Kang C, Avery L. To be or not to be, the level of autophagy is the question: dual roles of autophagy in the survival response to starvation. *Autophagy* 2008; **4**: 82-84 [PMID: 17952023]
- Zhang Z, Singh R, Aschner M. Methods for the Detection of Autophagy in Mammalian Cells. *Curr Protoc Toxicol* 2016; **69**: 20.12.1-20.12.26 [PMID: 27479363 DOI: 10.1002/cptx.11]
- Wigg AJ, Palumbo K, Wigg DR. Radiotherapy for hepatocellular carcinoma: systematic review of radiobiology and modeling projections indicate reconsideration of its use. *J Gastroenterol Hepatol* 2010; **25**: 664-671 [PMID: 20074152 DOI: 10.1111/j.1440-1746.2009.06126.x]
- Song C, Song C, Tong F. Autophagy induction is a survival response against oxidative stress in bone marrow-derived mesenchymal stromal cells. *Cytotherapy* 2014; **16**: 1361-1370 [PMID: 24980657 DOI: 10.1016/j.jcyt.2014.04.006]
- Chaachouay H, Ohneseit P, Toulany M, Kehlbach R, Multhoff G, Rodemann HP. Autophagy contributes to resistance of tumor cells to ionizing radiation. *Radiother Oncol* 2011; **99**: 287-292 [PMID: 21722986 DOI: 10.1016/j.radonc.2011.06.002]
- Lomonaco SL, Finniss S, Xiang C, Decarvalho A, Umansky F, Kalkanis SN, Mikkelsen T, Brodie C. The induction of autophagy

- by gamma-radiation contributes to the radioresistance of glioma stem cells. *Int J Cancer* 2009; **125**: 717-722 [PMID: 19431142 DOI: 10.1002/ijc.24402]
- 24 **Zois CE**, Koukourakis MI. Radiation-induced autophagy in normal and cancer cells: towards novel cytoprotection and radiosensitization policies? *Autophagy* 2009; **5**: 442-450 [PMID: 19164950]
  - 25 **Cui H**, Kong Y, Zhang H. Oxidative stress, mitochondrial dysfunction, and aging. *J Signal Transduct* 2012; **2012**: 646354 [PMID: 21977319 DOI: 10.1155/2012/646354]
  - 26 **Slimen IB**, Najar T, Ghram A, Dabbebi H, Ben Mrad M, Abdrabbah M. Reactive oxygen species, heat stress and oxidative-induced mitochondrial damage. A review. *Int J Hyperthermia* 2014; **30**: 513-523 [PMID: 25354680 DOI: 10.3109/02656736.2014.971446]
  - 27 **Filomeni G**, De Zio D, Cecconi F. Oxidative stress and autophagy: the clash between damage and metabolic needs. *Cell Death Differ* 2015; **22**: 377-388 [PMID: 25257172 DOI: 10.1038/cdd.2014.150]

**P- Reviewer:** Desiderio J, Sun BC **S- Editor:** Qi Y  
**L- Editor:** Wang TQ **E- Editor:** Zhang FF





## Basic Study

# Yangzheng Sanjie decoction regulates proliferation and apoptosis of gastric cancer cells by enhancing let-7a expression

Hai-Xia Deng, Ya-Ya Yu, Ao-Qiang Zhou, Jing-Li Zhu, Li-Na Luo, Wan-Qun Chen, Ling Hu, Geng-Xin Chen

Hai-Xia Deng, Ya-Ya Yu, Ao-Qiang Zhou, Jing-Li Zhu, Li-Na Luo, Geng-Xin Chen, The Second Affiliated Hospital, Guangzhou University of Chinese Medicine, Guangzhou 510120, Guangdong Province, China

Wan-Qun Chen, Ling Hu, Institute of Gastroenterology, Guangzhou University of Chinese Medicine, Guangzhou 510405, Guangdong Province, China

Wan-Qun Chen, Ling Hu, The First Affiliated Hospital, Guangzhou University of Chinese Medicine, Guangzhou 510405, Guangdong Province, China

Geng-Xin Chen, Discipline of Integrated Chinese and Western Medicine in Guangzhou University of Chinese Medicine, Guangzhou 510006, Guangdong Province, China

**Author contributions:** Deng HX performed the majority of experiments and drafted the manuscript; Yu YY conducted the molecular assays and assisted in writing the manuscript; Zhou AQ, Zhu JL and Chen WQ participated in the animal experiments and prepared the drug-containing serum; Luo LN performed the high-performance liquid chromatography analysis; Chen WQ and Hu L collected medical records and tissue specimens; Deng HX and Chen GX designed and coordinated the research, analyzed the data and revised the manuscript.

**Supported by** the National Natural Science Foundation of China, No. 81273735 and No. 81373563; Science and Technology Planning Project of Guangdong Province, China, No. 2016A020215135 and No. 2013B021800169; and The Specific Research Fund for TCM Science and Technology of Guangdong Provincial Hospital of Chinese Medicine, China, No. YN2014ZH05.

**Institutional animal care and use committee statement:** All procedures involving animals were reviewed and approved by the Institutional Animal Care and Use Committee of the Second Affiliated Hospital of Guangzhou University of Chinese Medicine (No. 2013050). All operations were performed according to international guidelines concerning the care and

treatment of experimental animals.

**Institutional review board statement:** This study was reviewed and approved by the Institutional Review Board of the First Affiliated Hospital of Guangzhou University of Chinese Medicine.

**Informed consent statement:** All study participants provided written informed consent prior to study enrolment.

**Conflict-of-interest statement:** The authors declare that there are no conflicts of interest related to this study.

**Data sharing statement:** No additional data are available.

**Open-Access:** This article is an open-access article which was selected by an in-house editor and fully peer-reviewed by external reviewers. It is distributed in accordance with the Creative Commons Attribution Non Commercial (CC BY-NC 4.0) license, which permits others to distribute, remix, adapt, build upon this work non-commercially, and license their derivative works on different terms, provided the original work is properly cited and the use is non-commercial. See: <http://creativecommons.org/licenses/by-nc/4.0/>

**Manuscript source:** Unsolicited manuscript

**Correspondence to:** Geng-Xin Chen, MD, PhD, Professor, The Second Affiliated Hospital, Guangzhou University of Chinese Medicine, 111 Dade Road, Guangzhou 510120, Guangdong Province, China. [gxchen@gzucm.edu.cn](mailto:gxchen@gzucm.edu.cn)  
**Telephone:** +86-20-81887233-31011  
**Fax:** +86-20-81887233-31011

**Received:** April 22, 2017

**Peer-review started:** April 25, 2017

**First decision:** June 1, 2017

**Revised:** June 20, 2017

**Accepted:** July 4, 2017

**Article in press:** July 4, 2017

**Published online:** August 14, 2017

## Abstract

### AIM

To explore the let-7a-mediated anti-cancer effect of Yangzheng Sanjie decoction (YZSJD) in gastric cancer (GC) cells.

### METHODS

YZSJD-containing serum (YCS) was prepared using traditional Chinese medicine serum pharmacology methods. After YCS treatment, cell proliferation and apoptosis were assessed by cell counting kit-8 assay and flow cytometry, respectively, and miRNA expression profiles were determined using qPCR arrays. Let-7a expression was examined by *in situ* hybridization in GC tissues and by qPCR in GC cells. c-Myc protein expression was detected by immunohistochemistry in GC tissues, and by Western blot in cell lines.

### RESULTS

YZSJD significantly inhibited proliferation and induced apoptosis in AGS and HS-746T GC cells. After treatment with YCS, the miRNA expression profiles were altered and the reduced let-7a levels in both cell lines were up-regulated, accompanied by a decrease in c-Myc expression. Moreover, decreased let-7a expression and increased c-Myc expression were observed during the progression of gastric mucosa cancerization.

### CONCLUSION

YZSJD inhibits proliferation and induces apoptosis of GC cells by restoring the aberrant expression of let-7a and c-Myc.

**Key words:** Gastric cancer; Let-7a; c-Myc; Proliferation; Apoptosis; Yangzheng Sanjie decoction

© The Author(s) 2017. Published by Baishideng Publishing Group Inc. All rights reserved.

**Core tip:** Let-7a reduction plays an important role in gastric tumorigenesis through the derepression of c-Myc expression. Our data demonstrate that Yangzheng Sanjie decoction (YZSJD) inhibits proliferation and induces apoptosis in gastric cancer (GC) cells by regulating the aberrant expression of let-7a and c-Myc. These findings provide new evidence that YZSJD has therapeutic potential in GC treatment and that miRNA regulation may be a novel molecular mechanism through which Chinese herbal medicine exhibits anti-cancer activity.

Deng HX, Yu YY, Zhou AQ, Zhu JL, Luo LN, Chen WQ, Hu L, Chen GX. Yangzheng Sanjie decoction regulates proliferation and apoptosis of gastric cancer cells by enhancing let-7a expression. *World J Gastroenterol* 2017; 23(30): 5538-5548 Available from: URL: <http://www.wjgnet.com/1007-9327/full/v23/i30/5538.htm> DOI: <http://dx.doi.org/10.3748/wjg.v23.i30.5538>

## INTRODUCTION

Gastric cancer (GC) is one of the leading causes of cancer-related deaths in the world<sup>[1]</sup>. The low early diagnosis rate of GC and the limited treatment options for advanced GC are the major reasons for the high mortality rate in GC patients. Considering the narrow therapeutic window, long-term drug resistance and toxic side effects of chemotherapeutic agents, safer and more effective therapies should be developed to improve the prognosis of GC.

As an important source of novel agents with pharmaceutical potential, Chinese herbal medicines have become increasingly popular in cancer treatment as alternative and complementary therapy modalities<sup>[2-6]</sup>. One Chinese medicine formula, Yangzheng Sanjie decoction (YZSJD), which contains the ingredients *Astragali Radix*, *Scutellariae Barbatae Herba*, *Arisaematis Rhizoma Preparatum*, *Citri Sarcodactylis Fructus*, *Cremastrae Pseudobulbus* and *Curcuma Longae Rhizoma*, has shown good clinical effects in the treatment of chronic atrophic gastritis with precancerous lesions<sup>[7]</sup>. Several components of YZSJD have recently been reported to exert antiproliferative effects in several cancer cell lines<sup>[8-10]</sup>. However, the potential role of YZSJD in the treatment of GC and the precise mechanisms that may be involved in the proliferation and apoptosis of GC cells have not yet been clearly addressed.

Increasing evidence has revealed that microRNAs (miRNAs) play critical roles in the initiation, progression and aggressiveness of human cancers and may be potential therapeutic targets for malignancies. MiRNAs are a class of small noncoding RNAs of 21-23 nucleotides that negatively regulate gene expression by base-pairing with the 3'-untranslated regions of their target messenger RNAs<sup>[11,12]</sup>. The miRNA let-7 is down-regulated in many cancer types compared with normal tissue, indicating that the let-7 family serves as tumour suppressors<sup>[13,14]</sup>. Involved in the complex regulation of c-Myc, let-7a participates in the genesis and maintenance of c-Myc-dysregulated cancers<sup>[15]</sup>. Kim *et al.*<sup>[16]</sup> demonstrated that let-7 inhibits c-Myc expression by targeting the c-Myc 3'-UTR in a HuR-let-7 interdependent manner. Let-7b increased drug sensitivity in chemotherapy-resistant GC cells by targeting c-Myc<sup>[17]</sup>. A more recent study revealed that let-7a down-regulates the expression of PKM2 by regulating the expression of c-Myc and hnRNPA1 and therefore inhibits the proliferation, migration and invasion of GC cells<sup>[18]</sup>.

In a previous clinical study, we found that YZSJD can effectively slow, block or reverse the progression of GC precancerous lesions<sup>[19]</sup>. In this study, we aimed to explore the miRNA-mediated anticancer effect of YZSJD *in vitro*. The present study was therefore designed to evaluate cell proliferation and apoptosis in

GC cells treated with YZSJD-containing serum (YCS) and to screen and verify the potential miRNA targets. Furthermore, we detected the expression of let-7a and its target gene c-Myc in GC tissues, matched gastric precancerous tissues and normal gastric mucosa tissues to investigate the role of let-7a in the progression of gastric mucosa cancerization.

## MATERIALS AND METHODS

### Preparation and quality control of YZSJD

YZSJD, a Chinese herbal compound prescribed by Dr. Geng-Xin Chen at the Second Affiliated Hospital of Guangzhou University of Chinese Medicine, is composed of *Astragali Radix* 15 g, *Codonopsis Radix* 15 g, *Scutellariae Barbatae Herba* 15 g, *Arisaematis Rhizoma Preparatum* 10 g, *Citri Sarcodactylis Fructus* 10 g, *Cremastrae Pseudobulbus* 10 g, *Curcumae Longae Rhizoma* 10 g and *Curcumae Rhizoma* 15 g. All the medicinal materials used to prepare formulae were purchased from Kangmei Pharmaceutical Co., Ltd. (Guangzhou, China) and were identified by two pharmacognosy experts. The herbs (100 g) were soaked in distilled water (1000 mL) and boiled for 30 min twice, and then the extracts were filtered, mixed and centrifuged. The upper layer was concentrated to 0.9 g crude extract per millilitre in a rotary evaporator (SENCO, China) and stored at -20 °C for future use. To establish quality control standards for YZSJD, the crude extract preparation and subsequent high-performance liquid chromatography (HPLC) determination were repeated ten times. The similarity of the HPLC fingerprints of 10 batches of YZSJD samples was assessed using the Computer-Aided Similarity Evaluation System for Chromatographic Fingerprint of TCM (Chinese Pharmacopoeia Commission, version 2004A).

### Preparation of YCS

Forty male SD rats (SPF grade, weighing 250 ± 20 g) were purchased from the laboratory animal centre of Southern Medical University. The animals were acclimatized to laboratory conditions (23 °C, 12 h/12 h light/dark, 50% humidity, *ad libitum* access to food and water) for two weeks prior to experimentation. Subsequently, the rats were randomly and equally divided into a YZSJD group and a Control group. Animals in the YZSJD group were gavaged with an equivalent dose of YZSJD (9 g/kg), while those in the Control group were administered the same volume of normal saline once daily. On the seventh day, blood was drawn from the abdominal aorta 1 h after feeding, and the serum was isolated. Each group of sera was mixed, sterilized by filtration and inactivated at 56 °C before being stored at -20 °C. These experiments were approved by the Institutional Animal Care and Use Committee of the Second Affiliated Hospital of Guangzhou University of Chinese Medicine, and efforts were made to minimize animal suffering.

### Cell culture

The human GC cell lines AGS and HS-746T were purchased from the American Type Culture Collection (Manassas, VA, United States), the cell lines MKN-45 and SGC-7901 were obtained from the Type Culture Collection of Chinese Academy of Sciences (Shanghai, China), and the human immortalized gastric mucosa cell line GES-1 was provided by the Beijing Institute for Cancer Research. The cells were cultured in RPMI-1640 medium (HyClone, United States) supplemented with 10% foetal bovine serum (HyClone, United States) and maintained in a humidified incubator with 5% CO<sub>2</sub> at 37 °C.

### Cell groups and cell treatments

AGS and HS-746T cells were suspended and seeded in 96-well plates at a density of 6000 cells/well or in 6-well plates at a density of 20000 cells/well. The cells were divided into a YZSJD group and a Control group. After 12 h of culture, the cells in the YZSJD group were treated with 10% YCS, while those in the Control group were treated with 10% normal rat serum.

### Cell proliferation assay

The effects of YZSJD on AGS and HS-746T cell proliferation were estimated using the Cell Counting Kit-8 (CCK-8) assay (Jingxin, China). After 24, 48 or 72 h of incubation with YCS or normal rat serum, 10 µL of CCK-8 solution was added to each well of a 96-well plate, followed by a 2-h incubation in the dark. Cell proliferation was evaluated by the absorbance of each well at 450 nm, which was measured with a VICTOR X5 Multilabel Plate Reader (PerkinElmer, United States).

### Cell apoptosis assay

The effects of YZSJD on apoptosis were determined by flow cytometry using an Annexin V-FITC Apoptosis Detection Kit (BD Pharmingen, United States). After 48 h of incubation with YCS or normal rat serum, cells in 6-well plates were harvested and resuspended in 1 × binding buffer at a concentration of 1 × 10<sup>6</sup> cells/mL. Then, 5 µL of Annexin V-FITC and 10 µL of propidium iodide were added to 100 µL of the cell suspension. The cells were incubated for 15 min in the dark before 400 µL of 1 × binding buffer was added. The samples were analysed by flow cytometry within 1 h.

### MiRNA PCR array

Total RNA was extracted using Trizol reagent (Invitrogen, Carlsbad, CA, United States) following the manufacturer's instructions. Contaminating DNA in the RNA preparations was removed with DNase I, and the RNA was purified using an RNeasy MinElute Cleanup Kit (Qiagen, Germany). The RNA quantity and purity were assessed using a NanoDrop ND-1000 spectrophotometer (NanoDrop Technologies, Wilmington, DE, United States), and RNA integrity was examined by denaturing

**Table 1 Clinical and pathological characteristics of gastric cancer patients**

Characteristic	n (%)
Age (yr)	
< 60	6 (54.5)
≥ 60	5 (45.5)
Sex	
Male	8 (72.7)
Female	3 (27.3)
Lymph node metastasis	
Negative	6 (54.5)
Positive	5 (45.5)
Histopathology	
Adenocarcinoma	11 (100)
Others	0 (0)
Grade	
Well/moderately differentiated	5 (45.5)
Poorly differentiated	6 (54.5)
Stage	
Early	2 (18.2)
Advanced	9 (81.8)
Surgical therapy	
Negative	0 (0)
Positive	11 (100)

agarose gel electrophoresis.

The expression of mature miRNAs was detected using ExiLent SYBR Green master mix (Exiqon, Denmark) and the microRNA Ready-to-Use PCR, Human panel I + II (V4.M) (Exiqon, Denmark), according to the manufacturer's instructions. Briefly, the template RNA was reverse transcribed using a Universal cDNA Synthesis Kit (Exiqon, Denmark), and the reverse transcription products were then amplified and detected on a 7900 Real-Time PCR System (Applied Biosystems, United States) using the following thermocycler conditions: denaturation at 95 °C for 10 min, followed by 40 cycles of 95 °C for 10 s and 60 °C for 1 min.

Data analysis was performed with the GenEx qPCR analysis software (www.exiqon.com/mirna-pcranalysis). U6 snRNA was used as an endogenous control. The fold change for each miRNA was calculated as  $2^{-\Delta\Delta C_t}$ . We filtered out raw data for which the cycle threshold values were greater than 30 from the 372 total human miRNAs, and the differentially expressed miRNAs with a fold-change  $\geq 1.5$  in at least one cell line were included in the further analyses.

#### qRT-PCR

Total RNA was isolated from AGS and HS-746T cells with Trizol reagent (Invitrogen, CA, United States). The RNA concentration and purity were assessed using a NanoDrop 2000C spectrophotometer (Thermo Fisher Scientific, United States). Mature let-7a was reverse transcribed to cDNA using a PrimeScript RT reagent kit (TaKaRa, Japan), and the specific cDNA was amplified using a SYBR Premix Ex Taq II kit (TaKaRa, Japan) according to the manufacturer's instructions. The Bulge-Loop hsa-let-7a-5p qRT-PCR Primer Set

for reverse transcription and quantitative PCR was purchased from Ribobio Biotechnology (Guangzhou, China). The reverse transcription conditions consisted of an initial incubation at 42 °C for 15 min followed by 85 °C for 5 s in a T100 PCR instrument (Bio-Rad, United States). The qPCR amplification was performed as follows: 95 °C for 30 s, followed by 40 cycles of 95 °C for 5 s and 60 °C for 30 s on a 7500 Real-Time PCR System (Applied Biosystems, United States). U6 was used as an endogenous control, and the  $\Delta\Delta C_t$  method was used for let-7a quantification.

#### Western blot

Cells were lysed in RIPA buffer (Beyotime, China) to extract total cellular proteins. Equal amounts of protein for each sample were separated by 10% sodium dodecyl sulfate-polyacrylamide gel electrophoresis and transferred onto polyvinylidene difluoride membranes (Millipore, United States). After being blocked with WB blocking solution (Beyotime, China) for 1 h, the membranes were incubated with a rabbit c-Myc monoclonal antibody (Cell Signaling Technology, United States) or a mouse  $\beta$ -actin monoclonal antibody (Boster, China) at 4 °C overnight. The next day, the membranes were incubated with either a goat anti-rabbit IgG or a goat anti-mouse IgG horseradish peroxidase-conjugated secondary antibody (Boster, China) at 37 °C for 1 h. Immunoreactivity was visualized using an enhanced chemiluminescence reagent (Beyotime, China).

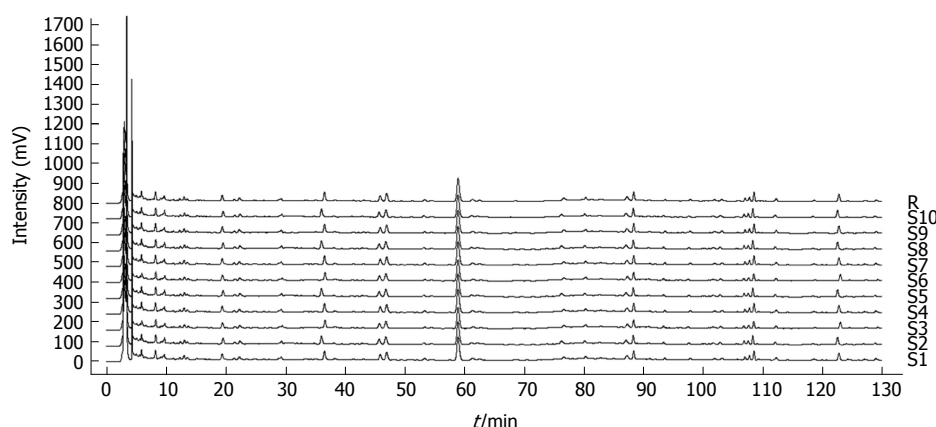
#### Tissue specimens

Tissue from 11 patients with pathologically diagnosed GC who underwent radical resection without radiotherapy and chemotherapy at the First Affiliated Hospital of Guangzhou University of Chinese Medicine (Guangzhou, Guangdong province, China) from May 2014 to November 2014 was collected. The diagnosis and histopathologic type of GC were determined according to the rules of the Japanese Gastric Cancer Association<sup>[20]</sup>. The clinical and pathological characteristics of the patients are shown in Table 1. All study participants provided written informed consent and donated a piece of GC tissue, matched tissue adjacent to the carcinoma and distal normal gastric tissue. The samples were fixed in 4% paraformaldehyde immediately after surgery and then embedded in paraffin. Histopathology was confirmed independently by two experienced pathologists unaware of the patients' clinical history. The present study was approved by the ethics committee of the First Affiliated Hospital of Guangzhou University of Chinese Medicine.

#### In situ hybridization

*In situ* hybridization was performed to detect let-7a in paraffin-embedded tissue sections using the Enhanced Sensitive ISH Detection Kit (Boster, China)





**Figure 1 Yangzheng Sanjie decoction high-performance liquid chromatography fingerprints.** High-performance liquid chromatography (HPLC) analysis was performed to determine the chromatographic fingerprints of Yangzheng Sanjie decoction. Analysed with a Computer-Aided Similarity Evaluation System, the similarity scores of the HPLC fingerprints of 10 batches of samples were above 0.95.

and DIG-labelled hsa-let-7a miRCURY LNA Detection probe (Exiqon, Denmark). After pretreatment and enzymatic digestion, slides were incubated with let-7a hybridization solution overnight at 4 °C. After a 30 min blocking step, the slides were treated with an anti-digoxigenin antibody for 1 h. Then, SABC-POD solution was added to the slides for 20 min at 37 °C. Next, the slides were treated with biotin peroxidase for 20 min and diaminobenzidine (DAB) chromogenic reagent (Boster, China) for 20 min. Counterstaining was performed with haematoxylin. Images were taken on an Olympus BX53 microscope equipped with a digital camera.

Signals were semi-quantitatively evaluated based on the cytoplasmic staining intensity and the percentage of positive cells. Staining intensity was divided into four levels: 0 (negative), 1 (weak), 2 (moderate) and 3 (strong); the percentage of positive cells was graded as 0 (none), 1 (< 10%), 2 (10%-50%), 3 (50%-80%) and 4 (> 80%). A total *in situ* hybridization (ISH) score was calculated by multiplying the scores of intensity and percentage. According to the scores, signals were assessed as follows: - ( $\leq 1$ ), + (2 to 4), ++ (4 to 8) and +++ ( $\geq 9$ ).

### Immunohistochemistry

Immunohistochemistry (IHC) was performed on paraffin sections using a ready-to-use rabbit anti-human c-Myc monoclonal antibody (MXB, China). The sections were first deparaffinized in xylene and rehydrated through a graded alcohol series. Endogenous peroxidase was blocked with 3% H<sub>2</sub>O<sub>2</sub> for 10 min, and antigen retrieval was carried out with sodium citrate buffer at 0.1 MPa and 121 °C for 5 min. After a blocking step using 5% BSA, slides were separately incubated with 50 µL of primary antibody at 4 °C overnight. Then, they were visualized by incubation with a biotin-conjugated secondary antibody followed by streptavidin and DAB (Boster, China). Counterstaining was performed with haematoxylin. The c-Myc score of each sample

was based on the nuclear staining. The data were evaluated as described above.

### Statistical analysis

All reactions were performed in triplicate. Measurement data are expressed as the mean  $\pm$  SD, and statistical analyses were performed using one-way analysis of variance. Ordinal data were analysed by Radit analysis.  $P < 0.05$  was considered statistically significant.

## RESULTS

### YZSJD HPLC fingerprints

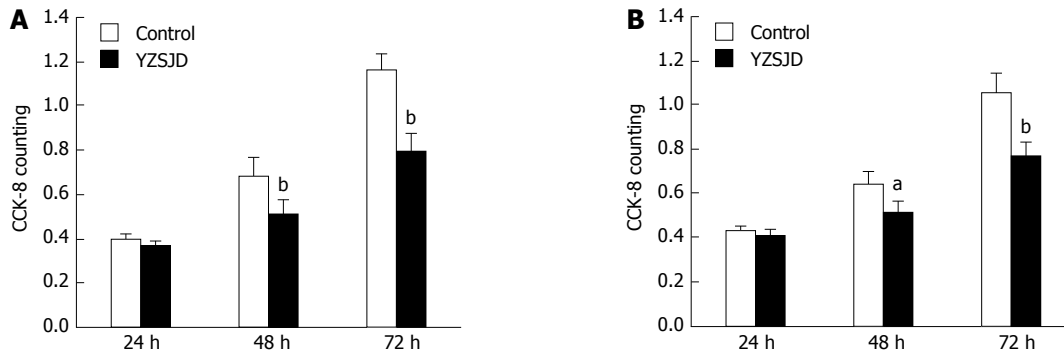
To establish quality control standards for YZSJD, HPLC was used to analyse 10 batches of YZSJD samples. As illustrated in Figure 1, the YZSJD HPLC fingerprints consisted of 22 characteristic peaks. The similarity scores of the fingerprinting profiles of the 10 batches of samples were above 0.95, which indicated the consistency and stability of the extracts and the preparation procedure.

### YZSJD inhibits GC cell proliferation

To investigate the biological effect of YZSJD on GC progression *in vitro*, AGS and HS-746T GC cells were treated with YCS. We evaluated cell proliferation using the CCK-8 assay. As shown in Figure 2, YCS significantly decreased the viability of AGS and HS-746T cells in a time-dependent manner.

### YZSJD induces apoptosis of GC cells

Next, we assessed cell apoptosis using flow cytometry. The early apoptosis rates of the two cell lines were significantly increased after treatment with YCS ( $P < 0.01$ ). After 48 h treatment with YCS, the early apoptosis rates reached  $9.97\% \pm 2.35\%$  (AGS) and  $10.9\% \pm 0.85\%$  (HS-746T), while in the Control groups, the proportions of Annexin V<sup>+</sup>/PI<sup>-</sup> cells were only  $1.67\% \pm 0.23\%$  (AGS) and  $1.8\% \pm 0.27\%$  (HS-746T) (Figure 3).



**Figure 2** Yangzheng Sanjie decoction inhibits gastric cancer cell proliferation in a time-dependent manner. The viability of AGS (A) and HS-746T cells (B) after treatment with YCS was measured using a CCK-8 assay. <sup>a</sup> $P < 0.05$  vs the control group; <sup>b</sup> $P < 0.01$  vs the control group. YCS: YZSJD-containing serum; YZSJD: Yangzheng Sanjie decoction; CCK-8: Cell Counting Kit-8.

**Table 2** Differentially expressed microRNAs in gastric cancer cells treated with Yangzheng Sanjie decoction

miRNA ID	Fold change (YZSJD/control)	
	AGS	HS-746T
hsa-let-7a-5p	1.54	1.80
hsa-let-7d-3p	1.66	1.53
hsa-let-7f-5p	1.68	2.70
hsa-miR-7-5p	1.56	2.03
hsa-miR-15a-5p	1.66	2.04
hsa-miR-15b-5p	1.62	3.26
hsa-miR-21-3p	1.86	1.75
hsa-miR-22-3p	1.58	1.78
hsa-miR-22-5p	1.74	1.60
hsa-miR-25-3p	1.74	1.76
hsa-miR-26b-5p	1.64	1.80
hsa-miR-27a-3p	2.07	1.59
hsa-miR-27b-3p	1.55	1.66
hsa-miR-30a-5p	1.71	4.65
hsa-miR-30b-5p	1.55	1.73
hsa-miR-30d-5p	1.67	1.98
hsa-miR-30e-3p	1.52	1.77
hsa-miR-32-5p	1.60	1.83
hsa-miR-92b-3p	1.58	1.95
hsa-miR-98-5p	1.51	1.55
hsa-miR-99a-5p	1.73	1.56
hsa-miR-105-5p	1.57	2.59
hsa-miR-125a-5p	1.67	1.72
hsa-miR-139-5p	2.35	1.91
hsa-miR-181b-5p	1.78	2.68
hsa-miR-186-5p	1.65	1.71
hsa-miR-192-5p	-2.27	-4.17
hsa-miR-193b-3p	3.33	1.53
hsa-miR-212-3p	1.81	1.67
hsa-miR-215-5p	-2.94	-4.76
hsa-miR-361-5p	1.83	1.84
hsa-miR-374a-5p	1.83	2.06
hsa-miR-450a-5p	1.59	1.65
hsa-miR-452-5p	1.61	2.58
hsa-miR-454-3p	1.59	2.44
hsa-miR-484	1.65	2.18
hsa-miR-514a-3p	1.60	3.34

miRNAs with a fold change  $\geq 1.5$  in both cell lines are listed. YZSJD: Yangzheng Sanjie decoction; miRNAs: MicroRNAs.

### YZSJD regulates the miRNA expression profile in GC cells

To explore the molecular mechanism involved in

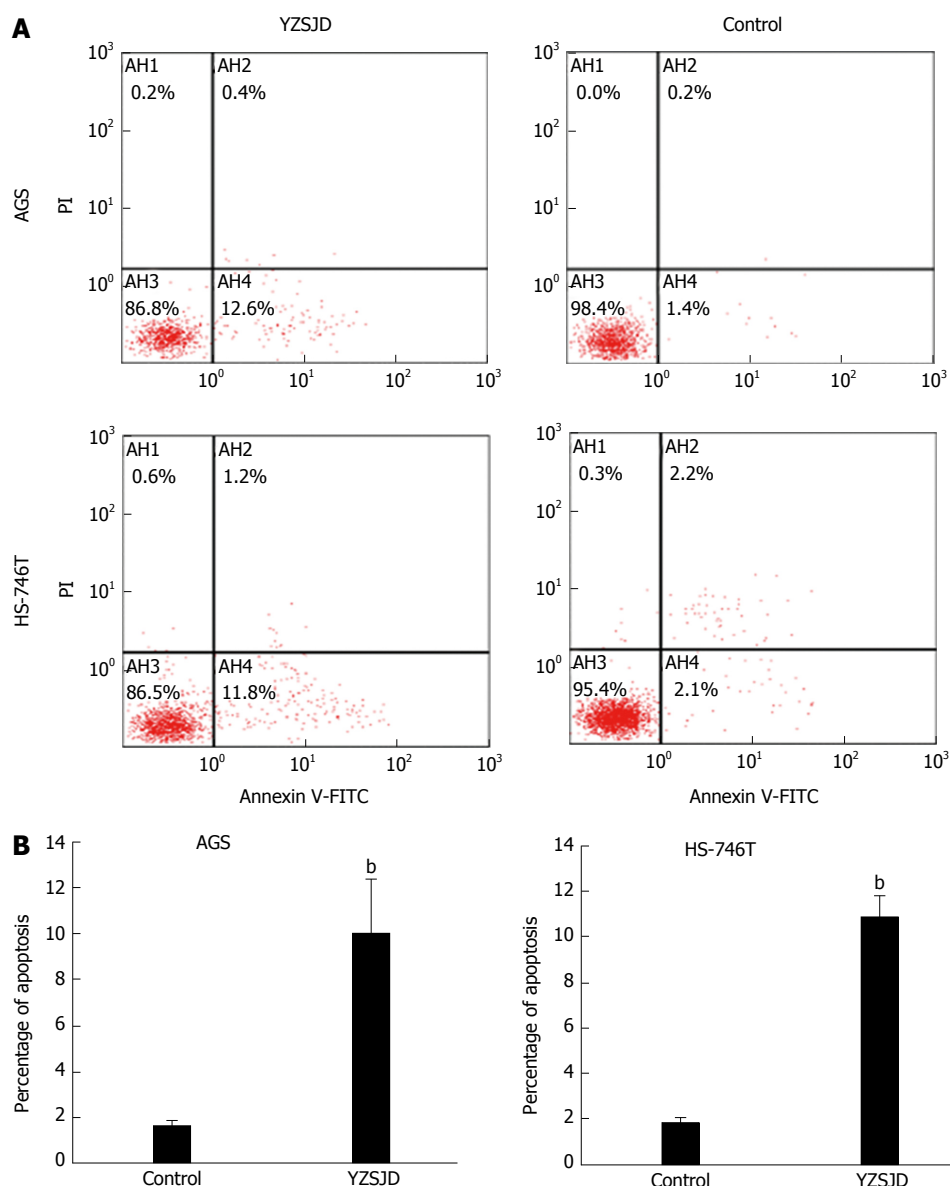
YZSJD-induced anticancer activity, we employed qPCR arrays to determine the changes in the miRNA expression profile in AGS and HS-746T GC cells treated with YCS. As shown in Figure 4A and B, the expression levels of a large number of miRNAs were altered. Using a recommended cut-off of 30 Ct, we identified 54 differentially expressed miRNAs in AGS cells and 60 in HS-746S cells. In both cell lines, 37 miRNAs showed the same expression alteration trend, 35 of which were up-regulated and 2 of which were down-regulated (Figure 4C and Table 2). Notably, almost all of the members of the let-7 family were altered: hsa-let-7a-5p, hsa-let-7d-3p, hsa-let-7f-5p and hsa-miR-98-5p were consistently up-regulated in both cell lines (Table 2), hsa-let-7g-5p was up-regulated only in AGS cells, and hsa-let-7b-5p, hsa-let-7c-5p, hsa-let-7d-5p, hsa-let-7e-5p and hsa-let-7i-5p were up-regulated only in HS-746T cells (data not shown).

### YZSJD regulates the expression of let-7a/c-Myc in GC cells

We performed qRT-PCR to detect let-7a expression in GC cell lines with different genetic backgrounds. Significant down-regulation of let-7a expression was found in AGS, HS-746T, MKN-45 and SGC-7901 cells ( $P < 0.01$ ) (Figure 5A). Next, the let-7a expression in AGS and HS-746T cells treated with YCS was further verified. As shown in Figure 5B, the levels of let-7a were significantly up-regulated ( $P < 0.01$ ). We then conducted Western blot analysis to determine the c-Myc expression. The c-Myc protein expression was lower in the YZSJD groups than in the Control groups (Figure 5C and D). These results indicate that YZSJD increased the expression of let-7a and decreased c-Myc protein expression in AGS and HS-746T cells.

### Abnormal expression of let-7a/c-Myc in the progression of gastric mucosa cancerization

We examined let-7a expression using ISH and detected c-Myc expression by IHC in GC tissues, matched paracarcinoma tissues and distal normal gastric mucosal tissues. A significant reduction of let-7a expression was



**Figure 3** Effects of Yangzheng Sanjie decoction on apoptosis of gastric cancer cells. A: After 48 h treatment with 10% YCS (left) or 10% normal rat serum (right), the apoptotic cells were determined by flow cytometry. Early apoptotic cells are shown in the lower right-hand quadrant. Representative dot plots of cell apoptosis are shown. Upper: AGS; Lower: HS-746T; B: Statistical analysis of FCM data. <sup>b</sup> $P < 0.01$  vs the control group. YCS: YZSJD-containing serum; YZSJD: Yangzheng Sanjie decoction.

observed in GC tissues, while let-7a was predominantly expressed in distal normal gastric mucosa tissues. Conversely, the IHC-based assessment of c-Myc expression demonstrated a decreasing trend from GC tissues and adjacent para-cancerous tissues to distal normal gastric tissues (Figure 6). There were significant differences in the expression of let-7a and c-Myc among the three different grades of gastric mucosa tissues ( $P < 0.05$ ) (Table 3).

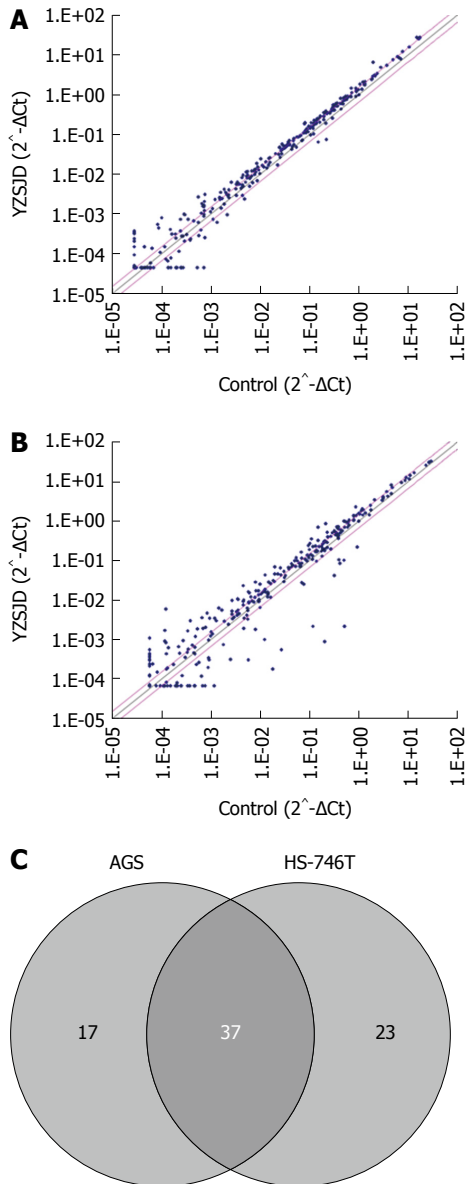
## DISCUSSION

Our results show that let-7a expression was significantly lower in GC tissues than in the matched precancerous tissues and normal gastric mucosa epithelium, while c-Myc expression exhibited an opposite trend. YZSJD

significantly inhibited proliferation and induced apoptosis in AGS and HS-746T cells, and YCS treatment resulted in up-regulation of let-7a and down-regulation of c-Myc in both cell types.

Currently, chemotherapy, endoscopic and surgical treatment are the major treatment modalities for GC. Since chemotherapeutics have the insurmountable problems of multi-drug resistance and negative side effects, and endoscopic and surgical treatments rely to a large extent on early detection of GC, the quality of life and 5-year overall survival rate for GC patients remain low. However, due to clear curative effects and low toxicity, traditional Chinese medicine has been recognized to have health and well-being benefits in cancer treatment<sup>[21,22]</sup>.

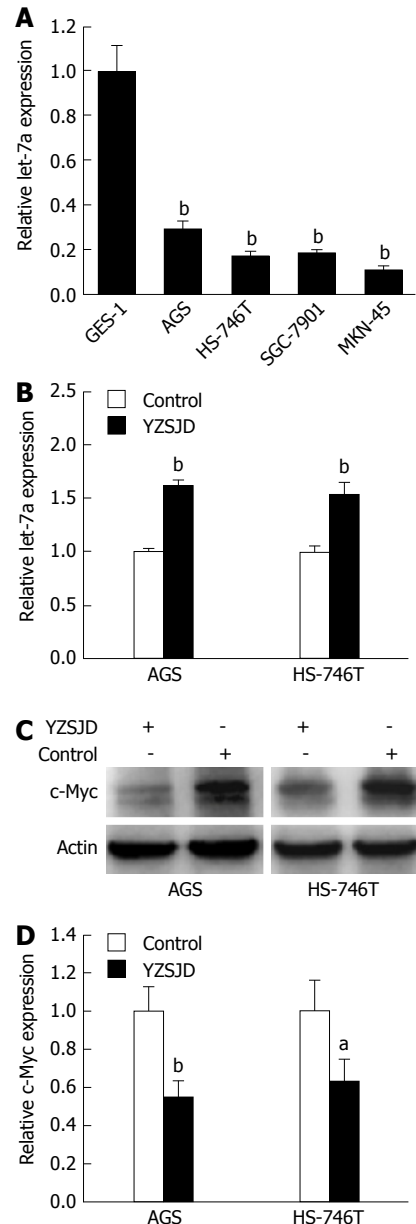
YZSJD, a Chinese herbal compound prescribed



**Figure 4** Effects of Yangzheng Sanjie decoction on miRNA profiles in gastric cancer cells. Scatter plot analysis of miRNA PCR array data from AGS (A) and HS-746T (B) cells treated with 10% Yangzheng Sanjie decoction-containing serum. The pink lines indicate 1.5-fold changes. C: Venn diagram analysis of differentially expressed miRNAs unique to each cell line or shared between AGS and HS-746T cells.

by Dr. Geng-Xin Chen, has been used to treat gastric precancerous lesions at the Second Affiliated Hospital of Guangzhou University of Chinese Medicine for more than a decade. In our previous clinical study, we found that YZSJD has a definite therapeutic effect on the precancerous lesions of patients with chronic atrophic gastritis by targeting EGF and EGFR<sup>[7,19]</sup>. In this study, we explored the anti-cancer effects of YZSJD in two GC cell lines and investigated the underlying mechanism. YZSJD significantly inhibited proliferation and induced apoptosis in AGS and HS-746T cells.

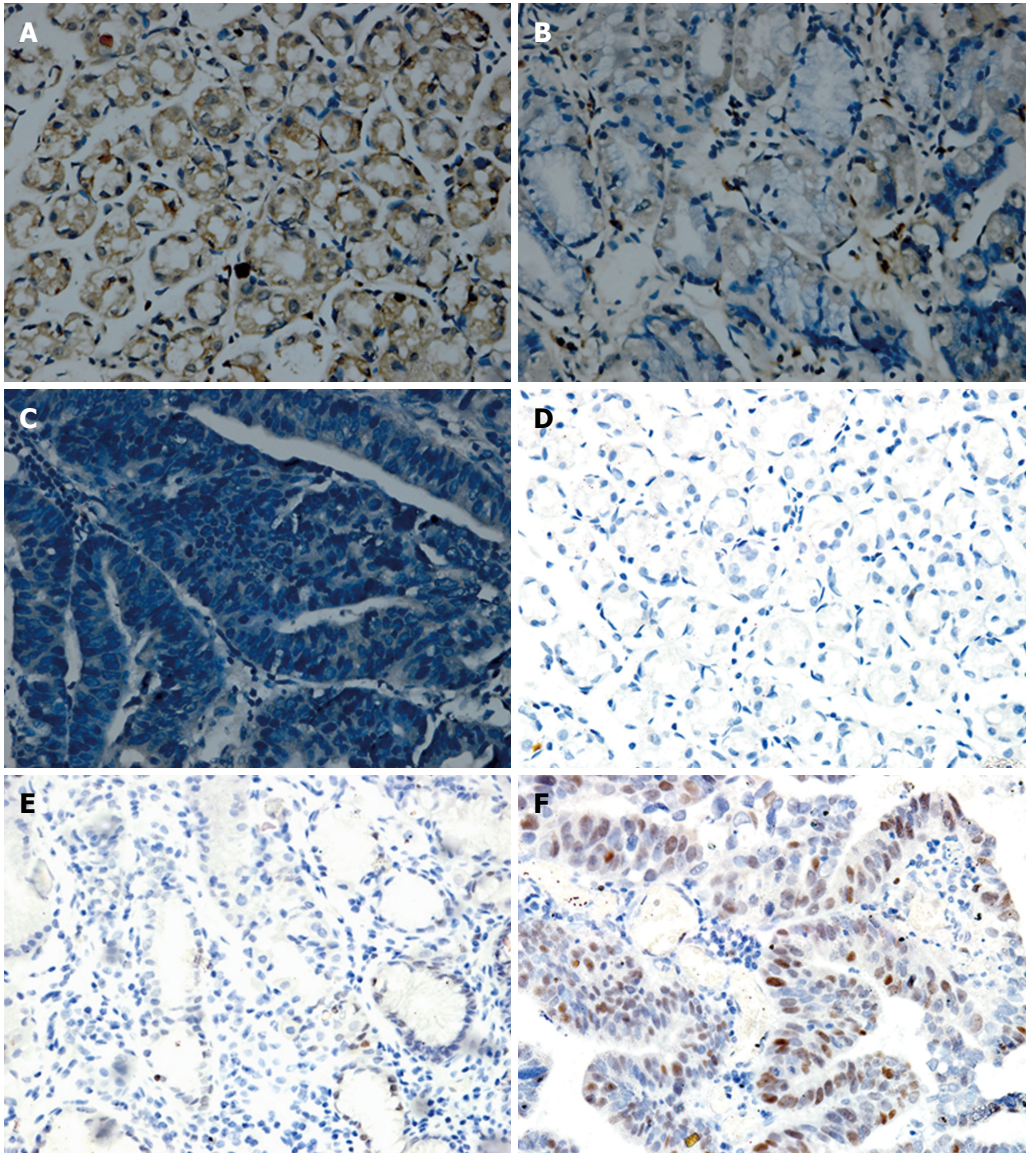
To explore the molecular mechanism involved in YZSJD-induced anticancer activity, we employed qPCR arrays to determine the changes that occurred



**Figure 5** Effects of Yangzheng Sanjie decoction on let-7a and c-Myc expression in gastric cancer cells. A: Down-regulation of let-7a expression in GC cells; B and C: AGS and HS-746T GC cells were treated with 10% YCS or 10% normal rat serum for 48 h, and quantitative RT-PCR was performed to determine the expression levels of let-7a (B), while c-Myc expression was measured by Western blot (C); D: Statistical analysis of Western blot data. <sup>a</sup>*P* < 0.05 vs the control group; <sup>b</sup>*P* < 0.01 vs the control group. YCS: YZSJD-containing serum; YZSJD: Yangzheng Sanjie decoction.

in the miRNA expression profile in AGS and HS-746T GC cells upon YCS treatment. The expression levels of a large number of miRNAs were altered. Notably, almost all of the members of the let-7 family were up-regulated by YZSJD. Of these, hsa-let-7a-5p, hsa-let-7d-3p, hsa-let-7f-5p and hsa-miR-98-5p were consistently up-regulated in both cell lines. Because of its high abundance, we focused on let-7a in this study. Subsequent verification experiments confirmed the influence of YZSJD on let-7a expression. To monitor the downstream effectors induced by the differential





**Figure 6** Expression levels of let-7a and c-Myc in gastric cancer tissues. A-C: Expression of let-7a miRNA (ISH, × 400): high in distal normal gastric tissues (A), moderate in matched para-carcinoma tissues (B) and low in GC tissues (C). D-F: Expression of c-Myc protein (IHC, × 400): low in distal normal tissues (D), moderate in adjacent tissues (E) and high in GC tissues (F). GC: Gastric cancer; ISH: *In situ* hybridization; IHC: Immunohistochemistry.

Table 3 Let-7a and c-Myc expression in gastric cancer tissue samples										
Tissue	Let-7a					c-Myc				
	(-)	(+)	(++)	(+++)	P value	(-)	(+)	(++)	(+++)	P value
Ca	3	7	1	0	< 0.05	0	2	4	5	< 0.05
Pc	0	8	3	0		1	6	3	1	
N	0	1	6	4		4	6	1	0	

Staining intensity was described as negative (-), weak (+), moderate (++) and strong (+++) staining. Ca: Gastric cancer tissues; Pc: Matched para-carcinoma tissues; N: Matched distal normal gastric tissues.

expression of let-7a, we analysed the expression of c-Myc, a classical target gene of the let-7 family, and found obvious down-regulation of the protein.

Let-7 was the first human miRNA discovered and is known as a classical anti-oncomiR<sup>[23]</sup>. Pairing between let-7 and its target genes, such as Myc, RAS or HMGA2, has been shown to be pivotal in

tumourigenesis<sup>[15,24,25]</sup>. Although some conflicting data have emerged indicating that let-7 may have diverse functions in different forms of cancer<sup>[26]</sup>, there is evidence showing the significance of let-7 loss in GC oncogenesis and metastasis<sup>[27-30]</sup>. In this study, we further investigated the association between let-7 and the risk of GC in matched tissue samples. Consistent

with previous studies, our results indicate that let-7a expression diminished progressively during the progression of gastric mucosa cancerization.

The c-Myc oncogene is highly amplified in many cancer types and contributes to tumourigenesis<sup>[31,32]</sup>. Functioning as an important transcription factor, c-Myc protein also plays a crucial role in gastric carcinogenesis<sup>[33]</sup>. Chen *et al.*<sup>[34]</sup> found that targeting c-Myc strongly inhibited cell growth and induced apoptosis in SGC7901 GC cells. Our data showed that c-Myc expression was increased markedly in GC tissues compared with matched precancerous tissues and normal gastric mucosae. Our data suggest that the reduction of let-7a may play an important role in GC occurrence and development through the derepression of c-Myc protein expression.

Several studies have revealed that let-7 inhibits the proliferation, migration, invasion and tumour metastasis of GC cells both *in vitro* and *in vivo*<sup>[28-30,35]</sup>. Let-7 miRNAs target the c-Myc 3'-UTR and negatively regulate its protein expression<sup>[15,16]</sup>. More recently, it was reported that let-7a inhibits the proliferation, migration and invasion of GC cells by suppressing the c-Myc/hnRNPA1/PKM2 pathway<sup>[18]</sup>. Given that reduced let-7a is involved in GC oncogenesis and that its expression increased in both AGS and HS-746T cells treated with YCS, we speculate that YZSJD suppressed proliferation and induced apoptosis in GC cells possibly by regulating the let-7a-c-Myc pathway.

In conclusion, the reduction of let-7a expression may play an important role in gastric tumourigenesis through c-Myc derepression. YZSJD inhibits proliferation and induces apoptosis by enhancing let-7a expression in GC cells. These findings provide new evidence that YZSJD has therapeutic potential in the treatment of GC and that miRNA expression regulation may be a novel molecular mechanism through which Chinese herbal medicine exhibits anti-cancer activity.

## ACKNOWLEDGMENTS

We thank the First Affiliated Hospital of Guangzhou University of Chinese Medicine for providing human GC samples.

## COMMENTS

### Background

Chinese herbal medicine has become an increasingly popular cancer therapy modality. Yangzheng Sanjie decoction (YZSJD) showed beneficial effects in the treatment of precancerous lesions of gastric cancer (GC) patients according to our published data. However, its therapeutic effect and underlying mechanism associated with GC remain unknown.

### Research frontiers

Let-7 miRNAs have been shown to act as tumour suppressors in GC by targeting c-Myc and are promising therapeutic targets for cancer treatment. In this study, the authors explored the let-7a-mediated anticancer effect of YZSJD *in vitro*. These data demonstrate that YZSJD inhibits proliferation and induces apoptosis by regulating the aberrant expression of let-7a and c-Myc in GC cells.

## Innovations and breakthroughs

In the present manuscript, the authors present the novel findings that reduction of let-7a expression could play an important role in gastric tumourigenesis through the derepression of c-Myc expression and that YZSJD inhibits proliferation and induces apoptosis in GC cells by regulating the let-7a-c-Myc pathway.

## Applications

These findings provide new evidence that YZSJD has therapeutic potential in the treatment of GC and that miRNA expression regulation may be a novel molecular mechanism through which Chinese herbal medicine exhibits anti-cancer activity, laying a new foundation for further research into the molecular mechanisms of GC treatment with Chinese herbal medicine.

## Terminology

The let-7 family (let-7a/b/c/d/e/f/g/i and miR-98) is a cluster of broadly conserved miRNAs. By targeting numerous oncogenes and signalling pathways (c-Myc, Ras, HMGA2, cyclin D, cyclin A, CDK4/6, Lin28, etc.), let-7 blocks tumour formation, progression and metastasis and induces cell apoptosis through post-transcriptional regulation.

## Peer-review

This is an interesting basic study on new traditional Chinese medicine in regulation of the proliferation and apoptosis of GC cells. The authors present the novel findings that reduction of let-7a expression could play an important role in gastric tumourigenesis through the derepression of c-Myc expression and that YZSJD inhibits proliferation and induces apoptosis in GC cells by regulating the let-7a-c-Myc pathway. These findings provide new evidence that YZSJD has therapeutic potential in the treatment of GC and that miRNA expression regulation may be a novel molecular mechanism through which Chinese herbal medicine exhibits anti-cancer activity.

## REFERENCES

- 1 Torre LA, Bray F, Siegel RL, Ferlay J, Lortet-Tieulent J, Jemal A. Global cancer statistics, 2012. *CA Cancer J Clin* 2015; **65**: 87-108 [PMID: 25651787 DOI: 10.3322/caac.21262]
- 2 Sun Y. The role of Chinese medicine in clinical oncology. *Chin J Integr Med* 2014; **20**: 3-10 [PMID: 24126976 DOI: 10.1007/s11655-013-1551-2]
- 3 Guo Z, Jia X, Liu JP, Liao J, Yang Y. Herbal medicines for advanced colorectal cancer. *Cochrane Database Syst Rev* 2012; (5): CD004653 [PMID: 22592697 DOI: 10.1002/14651858.CD004653.pub2]
- 4 Li SG, Chen HY, Ou-Yang CS, Wang XX, Yang ZJ, Tong Y, Cho WC. The efficacy of Chinese herbal medicine as an adjunctive therapy for advanced non-small cell lung cancer: a systematic review and meta-analysis. *PLoS One* 2013; **8**: e57604 [PMID: 23469033 DOI: 10.1371/journal.pone.0057604]
- 5 Hu Y, Wang S, Wu X, Zhang J, Chen R, Chen M, Wang Y. Chinese herbal medicine-derived compounds for cancer therapy: a focus on hepatocellular carcinoma. *J Ethnopharmacol* 2013; **149**: 601-612 [PMID: 23916858 DOI: 10.1016/j.jep.2013.07.030]
- 6 Li B, Gan R, Yang Q, Huang J, Chen P, Wan L, Guo C. Chinese Herbal Medicines as an Adjunctive Therapy for Unresectable Pancreatic Cancer: A Systematic Review and Meta-Analysis. *Evid Based Complement Alternat Med* 2015; **2015**: 350730 [PMID: 26681966 DOI: 10.1155/2015/350730]
- 7 Chen G, Mou T, Li H. Clinical observation on treatment of chronic atrophic gastritis before canceration with Yangzheng Sanjie Tang in 55 cases. *Jilin Zhongyiyao* 2007; **27**: 17-18
- 8 Cho WC, Leung KN. In vitro and in vivo anti-tumor effects of *Astragalus membranaceus*. *Cancer Lett* 2007; **252**: 43-54 [PMID: 17223259 DOI: 10.1016/j.canlet.2006.12.001]
- 9 Dai Z, Liu X, Ji Z, Liu L, Kang H, Wang X, Diao Y. The effect-enhancing and toxicity-reducing action of the extract of *herba Scutellariae barbatae* for chemotherapy in hepatoma H22 tumor-bearing mice. *J Tradit Chin Med* 2008; **28**: 205-210 [PMID: 18511111 DOI: 10.1007/s11523-008-9111-1]



- 19004205]
- 10 **Wang T**, Xuan X, Li M, Gao P, Zheng Y, Zang W, Zhao G. Astragalus saponins affect proliferation, invasion and apoptosis of gastric cancer BGC-823 cells. *Diagn Pathol* 2013; **8**: 179 [PMID: 24152941 DOI: 10.1186/1746-1596-8-179]
  - 11 **Esquela-Kerscher A**, Slack FJ. Oncomirs - microRNAs with a role in cancer. *Nat Rev Cancer* 2006; **6**: 259-269 [PMID: 16557279 DOI: 10.1038/nrc1840]
  - 12 **Calin GA**, Croce CM. MicroRNA signatures in human cancers. *Nat Rev Cancer* 2006; **6**: 857-866 [PMID: 17060945 DOI: 10.1038/nrc1997]
  - 13 **Thomson JM**, Parker J, Perou CM, Hammond SM. A custom microarray platform for analysis of microRNA gene expression. *Nat Methods* 2004; **1**: 47-53 [PMID: 15782152 DOI: 10.1038/nmeth704]
  - 14 **Park SM**, Shell S, Radjabi AR, Schickel R, Feig C, Boyerinas B, Dinulescu DM, Lengyel E, Peter ME. Let-7 prevents early cancer progression by suppressing expression of the embryonic gene HMGA2. *Cell Cycle* 2007; **6**: 2585-2590 [PMID: 17957144 DOI: 10.4161/cc.6.21.4845]
  - 15 **Sampson VB**, Rong NH, Han J, Yang Q, Aris V, Soteropoulos P, Petrelli NJ, Dunn SP, Krueger LJ. MicroRNA let-7a down-regulates MYC and reverts MYC-induced growth in Burkitt lymphoma cells. *Cancer Res* 2007; **67**: 9762-9770 [PMID: 17942906 DOI: 10.1158/0008-5472.CAN-07-2462]
  - 16 **Kim HH**, Kuwano Y, Srikanthan S, Lee EK, Martindale JL, Gorospe M. HuR recruits let-7/RISC to repress c-Myc expression. *Genes Dev* 2009; **23**: 1743-1748 [PMID: 19574298 DOI: 10.1101/gad.1812509]
  - 17 **Yang X**, Cai H, Liang Y, Chen L, Wang X, Si R, Qu K, Jiang Z, Ma B, Miao C, Li J, Wang B, Gao P. Inhibition of c-Myc by let-7b mimic reverses multidrug resistance in gastric cancer cells. *Oncol Rep* 2015; **33**: 1723-1730 [PMID: 25633261 DOI: 10.3892/or.2015.3757]
  - 18 **Tang R**, Yang C, Ma X, Wang Y, Luo D, Huang C, Xu Z, Liu P, Yang L. MiR-let-7a inhibits cell proliferation, migration, and invasion by down-regulating PKM2 in gastric cancer. *Oncotarget* 2016; **7**: 5972-5984 [PMID: 26745603 DOI: 10.18632/oncotarget.6821]
  - 19 **Chen G**, Li H. Influences of Yangzheng Sanjie decoction on EGF and EGFR of gastric mucosa at precancerosis of chronic atrophic gastritis. *Guiding Journal of TCM* 2007; **13**: 20-22
  - 20 **Santiago JM**, Sasako M, Osorio J. [TNM-7th edition 2009 (UICC/AJCC) and Japanese Classification 2010 in Gastric Cancer. Towards simplicity and standardisation in the management of gastric cancer]. *Cir Esp* 2011; **89**: 275-281 [PMID: 21256476 DOI: 10.1016/j.ciresp.2010.10.011]
  - 21 **Feng Y**, Wu C, Li J. Promising Role and Probable Molecular Mechanisms of TCM in Gastric Cancer Treatment. *Liaoning Zhongyi Zazhi* 2017; **44**: 200-203 [DOI: 10.13192/j.issn.1000-1719.2017.01.068]
  - 22 **He P**, Shen K, Hu B. Progress of Traditional Chinese Medicine in Treating Gastric Cancer. *Zhongguo Zhongyiyao Xuekan* 2012; **30**: 280-282 [DOI: 10.13193/j.archtcm.2012.02.58.hep.013]
  - 23 **Sun X**, Liu J, Xu C, Tang SC, Ren H. The insights of Let-7 miRNAs in oncogenesis and stem cell potency. *J Cell Mol Med* 2016; **20**: 1779-1788 [PMID: 27097729 DOI: 10.1111/jcmm.12861]
  - 24 **Johnson SM**, Grosshans H, Shingara J, Byrom M, Jarvis R, Cheng A, Labourier E, Reinert KL, Brown D, Slack FJ. RAS is regulated by the let-7 microRNA family. *Cell* 2005; **120**: 635-647 [PMID: 15766527 DOI: 10.1016/j.cell.2005.01.014]
  - 25 **Mayr C**, Hemann MT, Bartel DP. Disrupting the pairing between let-7 and Hmga2 enhances oncogenic transformation. *Science* 2007; **315**: 1576-1579 [PMID: 17322030 DOI: 10.1126/science.1137999]
  - 26 **Tsang WP**, Kwok TT. Let-7a microRNA suppresses therapeutics-induced cancer cell death by targeting caspase-3. *Apoptosis* 2008; **13**: 1215-1222 [PMID: 18758960 DOI: 10.1007/s10495-008-0256-z]
  - 27 **Zhu YM**, Zhong ZX, Liu ZM. Relationship between let-7a and gastric mucosa cancerization and its significance. *World J Gastroenterol* 2010; **16**: 3325-3329 [PMID: 20614490 DOI: 10.3748/wjg.v16.i26.3325]
  - 28 **Yang Q**, Jie Z, Cao H, Greenlee AR, Yang C, Zou F, Jiang Y. Low-level expression of let-7a in gastric cancer and its involvement in tumorigenesis by targeting RAB40C. *Carcinogenesis* 2011; **32**: 713-722 [PMID: 21349817 DOI: 10.1093/carcin/bgr035]
  - 29 **Han X**, Chen Y, Yao N, Liu H, Wang Z. MicroRNA let-7b suppresses human gastric cancer malignancy by targeting ING1. *Cancer Gene Ther* 2015; **22**: 122-129 [PMID: 25613480 DOI: 10.1038/cgt.2014.75]
  - 30 **Yu J**, Feng J, Zhi X, Tang J, Li Z, Xu Y, Yang L, Hu Z, Xu Z. Let-7b inhibits cell proliferation, migration, and invasion through targeting Cthrc1 in gastric cancer. *Tumour Biol* 2015; **36**: 3221-3229 [PMID: 25510669 DOI: 10.1007/s13277-014-2950-5]
  - 31 **Dang CV**. MYC on the path to cancer. *Cell* 2012; **149**: 22-35 [PMID: 22464321 DOI: 10.1016/j.cell.2012.03.003]
  - 32 **Gabay M**, Li Y, Felsner DW. MYC activation is a hallmark of cancer initiation and maintenance. *Cold Spring Harb Perspect Med* 2014; **4**: a014241 [PMID: 24890832 DOI: 10.1101/cshperspect.a014241]
  - 33 **Calcagno DQ**, Leal MF, Assumpcao PP, Smith MA, Burbano RR. MYC and gastric adenocarcinoma carcinogenesis. *World J Gastroenterol* 2008; **14**: 5962-5968 [PMID: 18932273 DOI: 10.3748/wjg.14.5962]
  - 34 **Chen JP**, Lin C, Xu CP, Zhang XY, Fu M, Deng YP, Wei Y, Wu M. Molecular therapy with recombinant antisense c-myc adenovirus for human gastric carcinoma cells in vitro and in vivo. *J Gastroenterol Hepatol* 2001; **16**: 22-28 [PMID: 11206311 DOI: 10.1046/j.1440-1746.2001.02361.x]
  - 35 **Liang S**, He L, Zhao X, Miao Y, Gu Y, Guo C, Xue Z, Dou W, Hu F, Wu K, Nie Y, Fan D. MicroRNA let-7f inhibits tumor invasion and metastasis by targeting MYH9 in human gastric cancer. *PLoS One* 2011; **6**: e18409 [PMID: 21533124 DOI: 10.1371/journal.pone.0018409]

**P- Reviewer:** Bernal G, Eleftheriadis NP **S- Editor:** Gong ZM  
**L- Editor:** Wang TQ **E- Editor:** Zhang FF



## Case Control Study

# Crohn's disease environmental factors in the developing world: A case-control study in a statewide catchment area in Brazil

Valéria Cristina Loureiro Salgado, Ronir Raggio Luiz, Neio Boechat, Bianca C Schorr, Isabella S Leão, Tiago Nunes, Cyrla Zaltman

Valéria Cristina Loureiro Salgado, Bianca C Schorr, Isabella S Leão, Cyrla Zaltman, Division of Gastroenterology, Department of Internal Medicine, Clementino Fraga Filho Hospital, Federal University of Rio de Janeiro, Rio de Janeiro 21941-913, Brazil

Ronir Raggio Luiz, Institute for Studies in Public Health, Federal University of Rio de Janeiro, Rio de Janeiro 21941-913, Brazil

Neio Boechat, Multidisciplinary Research Laboratory, Clementino Fraga Filho University Hospital, Institute of Thoracic Diseases, Faculty of Medicine, Federal University of Rio de Janeiro, Rio de Janeiro 21941-913, Brazil

Tiago Nunes, Gastrointestinal Physiology, Institute of Nutritional Science, Nestle Research Center, Route du Jorat 57, 1000 Lausanne, Switzerland

**Author contributions:** Zaltman C provided financial support for this work; Salgado VCL, Boechat N and Zaltman C designed the study; Salgado VCL and Zaltman C coordinated and provided the collection of all data; Leão IS, Schorr BC and Salgado VCL made the structured interviews and collected patient's data from clinical reports if needed; Salgado VCL and Luiz RR organized and analyzed the data; Nunes T, Salgado VCL and Zaltman C were involved in writing and editing the manuscript; all authors read and approved the final manuscript.

**Institutional review board statement:** The Study was reviewed and approved by the Comitê de Ética em Pesquisa em Seres Humanos do HUCFF/UFRJ, the Institutional Review board.

**Informed consent statement:** On behalf of all co-authors I declare that all study participants, or their legal guardian, provided informed written consent prior to study enrolment.

**Conflict-of-interest statement:** Nunes T is an employee of Nestec SA, Switzerland. The remaining authors disclose no conflicts.

**Data sharing statement:** No additional data are available.

**Open-Access:** This article is an open-access article which was selected by an in-house editor and fully peer-reviewed by external reviewers. It is distributed in accordance with the Creative Commons Attribution Non Commercial (CC BY-NC 4.0) license, which permits others to distribute, remix, adapt, build upon this work non-commercially, and license their derivative works on different terms, provided the original work is properly cited and the use is non-commercial. See: <http://creativecommons.org/licenses/by-nc/4.0/>

**Manuscript source:** Unsolicited manuscript

**Correspondence to:** Dr. Cyrla Zaltman, Division of Gastroenterology, Department of Internal Medicine, Clementino Fraga Filho Hospital, Federal University of Rio de Janeiro, Rua Prof. Rodolpho Paulo Rocco 255, Ilha do Fundão, Rio de Janeiro 21941-913, Brazil. [c.zaltman@gmail.com](mailto:c.zaltman@gmail.com)  
Telephone: +55-21-39382669  
Fax: +55-21-39382669

Received: March 14, 2017  
Peer-review started: March 14, 2017  
First decision: April 20, 2017  
Revised: May 10, 2017  
Accepted: July 4, 2017  
Article in press: July 4, 2017  
Published online: August 14, 2017

## Abstract

### AIM

To identify environmental risk factors associated with the development of Crohn's disease (CD) in order to reassess the hygiene hypothesis.

### METHODS

A hospital-based, case-control study was carried out with CD patients ( $n = 145$ ) and controls ( $n = 163$ )



representing a socioeconomically diverse statewide catchment area in Brazil. Controls were recruited from caregivers of patients seen in different outpatient clinics at the same hospital. A multi-item survey with 94 questions regarding family history of CD, perinatal and childhood circumstances, living conditions, tobacco use and familial socioeconomic status was carried out by interviewers.

## RESULTS

On the univariate analysis, predictive variables for CD included being male, under age of 40, a high education level, urban dweller, smaller family size, exposure to enteric pathogens and user of treated water ( $P < 0.005$ ). On the multivariate analysis, variables significantly associated with CD were male gender (OR = 2.09), under age 40 (OR = 3.10), white (OR = 2.32), from a small family in childhood (OR = 2.34) and adulthood (OR = 3.02), absence of viral infections in childhood (OR = 2.23), exposure to enteric pathogens (OR = 2.41), having had an appendectomy (OR = 2.47) and prior or current smoker (OR = 2.83/1.12).

## CONCLUSION

Most variables supporting the "hygiene hypothesis" are associated with the development of CD but are not independent predictors of the diagnosis.

**Key words:** Crohn's disease; Environment; Hygiene hypothesis; Risk factors

© The Author(s) 2017. Published by Baishideng Publishing Group Inc. All rights reserved.

**Core tip:** This case-control study aimed to revisit the hygiene hypothesis in inflammatory bowel disease with the inclusion of Crohn's disease (CD) patients and healthy controls representing a socioeconomically diverse statewide catchment area in Brazil. Subjects completed an extensive 94-item survey regarding perinatal and childhood circumstances, living conditions, smoking and familial socioeconomic status. Most variables supporting the hygiene hypothesis were associated with CD but were not independent predictors of the diagnosis. These findings suggest that, albeit there is an association, the influence that these variables might have on disease development is not as strong as other classic environmental factors (smoking) found to be closely related to disease onset and progression.

Salgado VCL, Luiz RR, Boechat N, Schorr BC, Leão IS, Nunes T, Zaltman C. Crohn's disease environmental factors in the developing world: A case-control study in a statewide catchment area in Brazil. *World J Gastroenterol* 2017; 23(30): 5549-5556 Available from: URL: <http://www.wjgnet.com/1007-9327/full/v23/i30/5549.htm> DOI: <http://dx.doi.org/10.3748/wjg.v23.i30.5549>

## INTRODUCTION

The etiology of Crohn's disease (CD) remains not fully understood, being probably multifactorial, due to a complex interplay between genetic susceptibility and environmental factors<sup>[1-4]</sup>. In the United States and Europe, the rise in CD incidence was associated with the effects of industrialization and concomitant environmental and lifestyle changes<sup>[3,4]</sup>. These findings point toward the notion that environmental factors might play an important role in CD susceptibility and prevalence in the developed regions of the globe.

In this regard, the hygiene hypothesis postulates that better hygienic conditions would reduce the incidence of infections and favor the development of immune-mediated diseases<sup>[5-8]</sup>. In this hypothesis, exposure to different microbial agents could play a protective role in promoting immune system maturation by balancing pro-inflammatory Th1 response and regulatory T cell tolerance. This mechanism would provide protection against subsequent exposure to allergens and antigens and less prevalence of conditions like inflammatory bowel disease (IBD)<sup>[9]</sup>. Lack of experimental evidence, however, persists with regard to the association between the hygiene hypothesis and the increase in CD prevalence<sup>[10]</sup>.

Incidence and prevalence of CD in Brazil vary according to geographical differences<sup>[11]</sup>. In the Brazilian State of Rio de Janeiro, the presence of extreme income inequality and the existence of both urban and rural areas provide an interesting case study to further understand the role of environmental factors in CD development. Specifically, the hygiene hypothesis can be tested by taking into consideration these extreme geographical differences present in this relatively small state. Therefore, the objective of the present study is to assess the environmental factors that might be associated with CD development prompted by the great inter-regional differences present in this statewide single center catchment area.

## MATERIALS AND METHODS

### Study design and patient inclusion

This is a case-control study including CD patients and healthy individuals. Patients were recruited at the IBD outpatient clinic of the Federal University of Rio de Janeiro (UFRJ) Hospital (HUCFF), Brazil. Healthy individuals were recruited from caregivers of patients seen in different outpatient clinics at the same hospital, with no family ties to the cases. The Ethics Committee of the Institute of Public Health Studies/UFRJ approved this study. All patients and control subjects gave written informed consent before enrolment. Data was analyzed anonymously to preserve patient's privacy

### Patient selection and data collection

All included patients fulfilled the following criteria:

active follow up at the IBD outpatient clinic, established diagnosis of CD by clinical, radiological, endoscopic and histological parameters, 18 to 80 years of age, males and females. Patients and controls with established psychiatric illness or disorders that compromise the level of awareness or understanding were excluded. The sample size was based on a convenience sample according to the number of patients diagnosed with CD recorded in the HUCFF outpatient clinic.

Structured interviews were done by three interviewers trained uniformly using a prepared interview guide aiming to avoid biased information and ensuring compliance with the protocol. The 94-item questionnaire utilized in the present study was a Brazilian Portuguese translation of a previously developed Canadian questionnaire<sup>[8]</sup> with a few adaptations to the local reality. The questionnaire is mainly focused on risk factors for the development of CD as demographics aspects (sex, age, ethnicity, economic/social status, household area, family size), living conditions (housing conditions and sanitation, number of cohabitants, contact with pets and quality of water intake), smoking habits, family history (first-degree relatives), vaccinations and diseases (childhood immunizations, worms history, intestinal infections and viral diseases in childhood and appendectomy). Most of these variables were evaluated both in childhood and adulthood, before CD diagnosis. Age refers to current age at the moment the questionnaire was applied. Data was then categorized into two groups: 18 to 39 and 40 to 80 years of age.

Study subjects were racially stratified into two categories: white and non-white. Economic/social status was categorized based on the educational level and family income. Educational level was divided into three categories: elementary, high school and college degree. Family income was organized taking into consideration the household's gross monthly income according to multiples of the minimum wage: group 1 covered monthly household income of 0 to 3 minimum wages (up to about US \$285 per household per month); group 2 covered household income of 3 to 5 minimum wages (US \$855 to US \$1425 per month) and group 3 covered increments up to more than 5 minimum wages (above US \$1425 per month).

The household area was classified as urban or rural according to the Brazilian Institute of Geography and Statistics (IBGE). Definition of urban areas included cities (municipal seats), villages (district headquarters) or isolated urban areas; the areas outside of these parameters were considered rural (Ministry of Planning, Budget and Management Brazilian Institute of Geography and Statistics - IBGE 2010 Census). The assessment of housing conditions and adequate sanitation included: the presence of garbage collection, running water, and sewage drainage. Family size was characterized according to the number of inhabitants: 1 inhabitants, 2 to 3 inhabitants, and 4 to 8 inhabitants.

Exposure to tobacco also was considered and three classes were defined: never (never consumed tobacco daily), previous (currently non-smokers/ex-smokers) or current tobacco user (current daily smokers) (Global Adult Tobacco Survey - GATS, 2a Edition. Atlanta, United States, 2011).

### **Ethical statement**

The study was approved by the Ethics Committee of the University Hospital Clementino Fraga Filho of the Federal University of Rio de Janeiro, Brazil (HUCFF-UFRJ). Informed consent was obtained from all subjects prior their enrollment.

### **Statistical analysis**

To verify differences between the two study groups (CD and controls), we used Pearson's  $\chi^2$ . Univariate and multivariate logistic regression analyses were performed to identify variables associated with the development of CD. In the first multivariate analysis, all variables of interest were included in the model (analysis 1). A second multivariate analysis was then performed in which the model comprised only variables that (A) reached statistical significance or (B) had an OR higher than 2 at the first multivariate analysis (analysis 2). Significance level was set at  $P \leq 0.05$ . Statistical analyses were performed using Package for the Social Sciences (SPSS) for Windows version 17.0.

## **RESULTS**

The study population included 308 individuals: 145 (47%) CD patients and 163 (53%) controls. Significant differences between groups were evident when analyzing variables comprising demographic characteristics, hygiene, and others environmental factors before the diagnosis as summarized in Table 1.

### **Univariate analysis**

The variables associated with CD are shown in Table 2. In this analysis, risk factors such as being male, under 40 years old, high educational level, urban living, smaller family size in childhood, exposure to enteric pathogens and user of treated water were significantly associated with CD ( $P < 0.05$ ).

### **Multivariate analysis**

The logistic regression analysis was performed initially on all the variables studied (multivariate analysis 1) demonstrating that males, being under 40 years of age and white are associated with a greater likelihood to develop CD compared with controls (Table 3). Smaller families in childhood and adulthood, exposure to enteric pathogens and appendectomy prior to CD diagnosis were confirmed to be risk factors for CD development. Prior or current tobacco exposure were also identified as risk factors for developing the

**Table 1** Demographics and environmental factors from Crohn's disease and control groups (*n* = 308) *n* (%)

	Groups CD <sup>1</sup> ( <i>n</i> = 145)	Controls ( <i>n</i> = 163)	<i>P</i> value <sup>1</sup>
Sex			
Male	62 (42.8)	43 (26.4)	0.002
Female	83 (57.2)	120 (73.6)	
Age (yr)			
18-39	79 (54.5)	50 (30.7)	< 0.0001
40-80	66 (45.5)	113 (69.3)	
Race			
White	74 (51)	65 (39.9)	0.050
Non-white	71 (49)	98 (60.1)	
Educational level			
Elementary	45 (31)	79 (48.5)	0.006
High school	79 (54.5)	70 (42.9)	
Graduate school	21 (14.5)	14 (8.6)	
Family income <sup>2</sup>			
< 3	46 (31.7)	54 (33.1)	0.730
3-5	44 (30.3)	55 (33.7)	
> 5	40 (27.6)	36 (22.1)	
No information	15 (10.3)	18 (11)	
Rural area			
No	114 (78.6)	106 (65)	0.008
Yes	31 (21.4)	57 (35)	
Housing conditions			
Inadequate	12 (8.3)	12 (7.4)	0.765
Adequate	133 (91.7)	151 (92.6)	
Family size in adulthood ( <i>n</i> )			
Until 1	23 (15.9)	47 (28.8)	0.024
2-3	85 (58.6)	83 (50.9)	
4-8	37 (25.5)	33 (20.2)	
Family size in childhood ( <i>n</i> )			
1-3	45 (31)	35 (21.5)	0.006
4-6	61 (42.1)	56 (34.4)	
> 7	39 (26.9)	72 (44.2)	
Pets			
No	30 (20.7)	21 (12.9)	0.066
Yes	115 (79.3)	142 (87.1)	
Breastfeeding			
No	12 (8.3)	13 (8)	0.289
Yes	125 (86.2)	133 (81.6)	
Unknown	8 (5.5)	17 (10.4)	
Exposure to untreated water			
No	43 (29.7)	71 (43.6)	0.012
Yes	102 (70.3)	92 (56.4)	
Vaccine (childhood)			
No	12 (8.3)	20 (12.3)	0.252
Yes	133 (91.7)	143 (87.7)	
Viral diseases (childhood)			
No	17 (11.7)	11 (6.7)	0.129
Yes	128 (88.3)	152 (93.3)	
Helminthic infections			
No	45 (31)	45 (27.6)	0.509
Yes	100 (69)	118 (72.4)	
Exposure to enteric pathogens			
No	67 (46.2)	106 (65)	0.001
Yes	78 (53.8)	57 (35)	
Previous appendectomy			
No	133 (91.7)	153 (93.9)	0.466
Yes	12 (8.3)	10 (6.1)	
Tobacco exposure			
Never	86 (59.3)	106 (65)	0.190
Prior	42 (29)	33 (20.2)	
Current	17 (11.7)	24 (14.7)	

Family history			
No	132 (91)	153 (93.9)	0.346
Yes	13 (9)	10 (6.1)	

<sup>1</sup> $\chi^2$  test; <sup>2</sup>Minimum wage. CD: Crohn's disease.

disease. Considering only variables reaching statistical significance or having an OR higher than 2 in the first multivariate analysis (multivariate analysis 2), a strong risk association was found for male sex, under age of 40, white, from smaller families in childhood and adulthood, absence of viral infections in childhood, exposure to enteric pathogens, appendectomy and prior and current smoking.

## DISCUSSION

There is a slow but steady increase in CD prevalence worldwide, mainly in developing countries from Eastern Europe, Latin America and Asia, although the prevalence remains lower in comparison with Western Europe and North America<sup>[12-18]</sup>. The hygiene hypothesis has been proposed as a possible explanation for the significant increase in CD incidence in the last decades<sup>[19]</sup>. The present report assessed the hygiene hypothesis and other environmental factors in a cohort of CD patients and control subjects living in a statewide single center catchment area with great social and environmental inter-regional differences.

Considering the demographic aspects of CD, the literature presents controversial results regarding gender, although some studies have reported a slight predominance in males, which was confirmed in our study<sup>[20]</sup>. We identified a predominance of the disease in young individuals with a peak prevalence between 18 and 39 years of age, which was also comparable to previous reports<sup>[16,18,19]</sup>. The Brazilian population is characterized by a mixed race ancestry, with a genetic background originated from three main parental populations - Europeans, Brazilian Native Amerindians and Africans<sup>[21]</sup>. Interestingly, our study showed a predominance of white individuals in the CD group; this finding is in keeping with the higher incidence of IBD found in people with European ancestry.

In the univariate analysis, several important variables supporting the hygiene hypothesis were associated with CD development in the present study: access to treated water, higher educational level, smaller family size and being an urban dweller. Theoretically, the presence of these variables could be associated with less infectious diseases during the first years of life and more immune-mediated conditions at a later stage<sup>[5,6]</sup>. The relationship between access to treated water and less infections is straightforward, but the same might not be true for the other factors. In this regard, having a higher educational level or

**Table 2** Univariate analysis of associations between demographics, environmental factors in Crohn's disease patients

Characteristics	Logistic univariate models		
	OR	95%CI	P value <sup>2</sup>
Sex			
Male	2.09	1.29-3.37	0.003
Female	1.00		
Age (yr)			
18-39	2.71	1.70-4.31	< 0.001
40-80	1.00		
Race			
White	1.57	1.00-2.47	0.050
Non-white	1.00		
Educational level			
Elementary	1.00		
High school	1.98	1.22-3.22	0.006
Graduate school	2.63	1.21-5.68	0.014
Family income <sup>1</sup>			
< 3	1.00		
3-5	0.94	0.54-1.64	0.826
> 5	1.30	0.72-2.37	0.384
No information	0.98	0.44-2.15	0.957
Rural area			
No	1.98	1.19-3.29	0.009
Yes	1.00		
Housing conditions			
Inadequate	1.14	0.49-2.61	0.765
Adequate	1.00		
Family size in adulthood (n)			
Until 1	1.00		
2-3	2.09	1.17-3.75	0.013
4-8	2.29	1.15-4.54	0.018
Family size in childhood (n)			
1-3	2.37	1.31-4.27	0.004
4-6	2.01	1.18-3.42	0.010
> 7	1.00		
Pets			
No	1.76	0.96-3.24	0.068
Yes	1.00		
Breastfeeding			
No	1.00		
Yes	1.02	0.45-2.31	0.966
Unknown	0.51	0.16-1.61	0.251
Exposure to untreated water			
No	1.00		
Yes	1.83	1.14-2.93	0.012
Vaccine (childhood)			
No	1.00		
Yes	1.55	0.73-3.29	0.254
Viral diseases (childhood)			
No	1.84	0.83-4.06	0.134
Yes	1.00		
Helminthic infections			
No	1.18	0.72-1.93	0.509
Yes	1.00		
Exposure to enteric pathogens			
No	1.00		
Yes	2.16	1.37-3.42	0.001
Previous appendectomy			
No	1.00		
Yes	1.38	0.57-3.29	0.468
Tobacco exposure			
Never	1.00		
Prior	1.57	0.92-2.60	0.101
Current	0.87	0.44-1.73	0.697

Family history			
No	1.00		
Yes	1.51	0.64-3.54	0.348

<sup>1</sup>Minimum wage, <sup>2</sup> $\chi^2$  test. CD: Crohn's disease.

a smaller family size might function as a surrogate marker for a higher socioeconomic status, with subsequent less exposure to infectious diseases in early childhood. Likewise, being an urban dweller might lead to less exposure to livestock, decreasing the risk of parasitic infections that could modulate the immune system<sup>[10,22-24]</sup>. Despite these univariate associations supporting the hygiene hypothesis in this case-control setting, only having a smaller family size maintained statistical significance in the multivariate analysis.

Even though previous reports have indicated that pet ownership during childhood could be a risk factor for infectious diseases with subsequent reduction of immune-mediated conditions, we did not observe this association<sup>[8,14]</sup>. In fact, the association between having a pet during childhood and CD development is not entirely clear. In this regard, a Canadian case-control study has observed that contact with pets during childhood might have the opposite expected effect. In this study, pet ownership was associated with an increased risk to develop CD later on<sup>[25]</sup>. Further studies are still needed to establish a clear association between pet ownership in early childhood and an increased risk to develop CD.

The hygiene hypothesis suggests that improved sanitation and reduced exposure to enteric organisms during childhood might lead to inappropriate immunological responses later in life and higher risk of CD<sup>[26]</sup>. We observed, however, that a greater exposure to enteric pathogens was associated with a higher risk for the development of CD, a finding also confirmed by others<sup>[27]</sup>. These authors have shown that the increased risk occurs mainly in the first year after the diagnosis of infection, suggesting the existence of a detection bias. Another possible explanation for these results could be an incorrect diagnosis of intestinal infection at CD onset<sup>[27]</sup>. The same might explain the association between CD susceptibility and appendectomy. A significant association between previous appendectomy at diagnosis and the presence of CD was observed in this study. This finding, however, can be due to a misdiagnosis of appendicitis in initial cases of CD, especially in disease phenotypes with appendicular or ileocecal involvement.

The current study and several other reports have implicated smoking as a risk factor for the development of CD<sup>[28]</sup>. The pathophysiology behind the effects of smoking on CD is not well understood, but it is hypothesized that there are influences from nicotine and the participation of increased oxidative stress in the



**Table 3 Multiple linear regression to assess independent factors associated with the development of Crohn's disease**

Characteristics	Multivariate analysis 1			Multivariate analysis 2		
	<sup>1</sup> OR <sub>adj</sub>	95%CI	P value	<sup>1</sup> OR <sub>adj</sub>	95%CI	P value
Sex						
Male	2.08	1.18-3.68	0.011	2.09	1.22-3.59	0.007
Female	1.00			1.00		
Age (yr)						
18-39	2.83	1.51-5.32	0.001	3.10	1.71-5.63	< 0.001
40-80	1.00			1.00		
Race						
White	2.30	1.31-4.02	0.004	2.32	1.36-3.97	0.002
Non-white	1.00			1.00		
Educational level						
Elementary	1.00					
High school	1.44	0.75-2.75	0.266			
Graduate school	1.45	0.52-4.04	0.470			
Family income <sup>1</sup>						
< 3	1.00					
3-5	0.83	0.42-1.64	0.609			
> 5	0.90	0.40-2.00	0.807			
No information	1.74	0.67-4.51	0.254			
Rural area						
No	1.32	0.65-2.68	0.432			
Yes	1.00					
Housing conditions						
Inadequate	1.36	0.49-3.79	0.548			
Adequate	1.00					
Family size in adulthood (n)						
Until 1	1.00			1.00		
2-3	3.26	1.59-6.68	0.001	3.02	1.52-5.99	0.002
4-8	3.16	1.36-7.34	0.007	2.87	1.26-6.50	0.012
Family size in childhood (n)						
1-3	1.28	0.57-2.84	0.541	1.66	0.81-3.40	0.159
4-6	2.08	1.06-4.08	0.032	2.34	1.27-4.32	0.006
> 7	1.00			1.00		
Pets						
No	1.45	0.69-3.05	0.323			
Yes	1.00					
Breastfeeding						
No	1.00					
Yes	0.77	0.28-2.09	0.616			
Unknown	0.48	0.12-1.89	0.296			
Exposure to untreated water						
No	1.00					
Yes	1.54	0.80-2.93	0.188			
Vaccine (childhood)						
No	1.00					
Yes	0.57	0.20-1.58	0.284			
Viral diseases (childhood)						
No	2.42	0.90-6.48	0.078	2.23	0.88-5.62	0.088
Yes	1.00			1.00		
Helminthic infections						
No	0.91	0.51-1.65	0.776			
Yes	1.00					
Exposure to enteric pathogens						
No	1.00			1.00		
Yes	2.89	1.62-5.17	< 0.001	2.23	1.41-4.10	0.001
Previous appendectomy						
No	1.00			1.00		
Yes	2.71	0.93-7.83	0.065	2.47	0.89-6.83	0.080
Tobacco exposure						
Never	1.00			1.00		
Prior	3.13	1.57-6.26	0.001	2.83	1.46-5.47	0.002
Current	1.13	0.50-2.54	0.768	1.12	0.51-2.44	0.775
Family history						
No	1.00					
Yes	1.27	0.45-3.53	0.644			

<sup>1</sup>OR<sub>adj</sub> = Odd Ratio adjusted. In the final model only the variables included were statistically significant (95%CI not including value 1). P value Hosmer-Lemeshow statistic for setting the final model = 0.406.

intestinal mucosa<sup>[29]</sup>. Smoking cessation and smoking prevention might positively influence the development and evolution of CD<sup>[30]</sup>. Interestingly, the studies on smoking are not consistent across all ethnics groups, demonstrating the potential for interactions between smoking and others environmental or genetic factors to influence disease occurrence, course or phenotype<sup>[28]</sup>.

Importantly, interpretation of the present results should be performed with the perspective that there are some methodological limitations, including the possibility of reporting bias, which are common in case-controlled studies. Nonetheless, information obtained through structured questionnaires collected by graduate students, who were trained in a uniform protocol, tend to minimize this possibility. It was not possible, however, to control the recall bias, as some variables addressed issues related to early life.

Overall, in this case-control study, several factors associated with the development of CD in the univariate analysis (high education level, urban dweller, smaller family size, user of treated water) support the role of the hygiene hypothesis in the pathogenesis of CD. However, more importantly, most variables were not found to be independent predictors for the development of CD. This suggests that, albeit there is an association, the influence that these variables might have on disease development is not as strong as other classic environmental factors (smoking) found to be closely related to disease onset and progression.

## COMMENTS

### Background

Developing countries currently face an increase in the incidence of Crohn's disease (CD) in parallel with greater urbanization. Brazil, therefore, represents a good case study to revisit the hygiene hypothesis.

### Research frontiers

The hygiene hypothesis and the contribution of each environmental factor to disease development and progression need further investigation. A better understanding of the environmental factors associated with CD can potentially have preventive or therapeutic implications.

### Innovations and breakthroughs

Most case-control studies looking at environmental factors of CD took place in developed countries with a less diverse population regarding its socio-economic status and hygienic conditions. The present study used a socioeconomically diverse Brazilian population to adequately assess the influence of key factors related to the hygiene hypothesis on disease development.

### Applications

These results highlight the importance of key environmental factors associated with the hygiene hypothesis but also suggest that these factors are not disease predictors, being very unlikely that they have an independent causative role.

### Terminology

The hygiene hypothesis postulates that better hygienic conditions would reduce the incidence of infections and favor the development of immune-mediated diseases. In this hypothesis, exposure to different microbial agents could play a protective role in promoting immune system maturation.

## Peer-review

This manuscript offers new evidence to support the hygiene hypothesis, an interesting topic which has drawn increasing attention in recent years considering this potential role in the development of CD. This case-control study was well carried out, especially the well-designed questionnaire containing most of interested environmental factors, making the data analysis reliable and convincing. The relationship between several important variables supporting the hygiene hypothesis and CD development has been clearly demonstrated in the discussion section, even taking into consideration the extreme geographical differences in Brazil. Meanwhile, the structure of this manuscript is complete and the language is perfect.

## REFERENCES

- 1 **Strober W**, Fuss I, Mannon P. The fundamental basis of inflammatory bowel disease. *J Clin Invest* 2007; **117**: 514-521 [PMID: 17332878 DOI: 10.1172/JCI30587]
- 2 **Chamberlin WM**, Naser SA. Integrating theories of the etiology of Crohn's disease. On the etiology of Crohn's disease: questioning the hypotheses. *Med Sci Monit* 2006; **12**: RA27-RA33 [PMID: 16449960]
- 3 **Shanahan F**. Crohn's disease. *Lancet* 2002; **359**: 62-69 [PMID: 11809204 DOI: 10.1016/S0140-6736(02)07284-7]
- 4 **Ko Y**, Butcher R, Leong RW. Epidemiological studies of migration and environmental risk factors in the inflammatory bowel diseases. *World J Gastroenterol* 2014; **20**: 1238-1247 [PMID: 24574798 DOI: 10.3748/wjg.v20.i5.1238]
- 5 **Ruysers NE**, De Winter BY, De Man JG, Loukas A, Herman AG, Pelckmans PA, Moreels TG. Worms and the treatment of inflammatory bowel disease: are molecules the answer? *Clin Dev Immunol* 2008; **2008**: 567314 [PMID: 18509490 DOI: 10.1155/2008/567314]
- 6 **Lakatos PL**. Environmental factors affecting inflammatory bowel disease: have we made progress? *Dig Dis* 2009; **27**: 215-225 [PMID: 19786744 DOI: 10.1159/000228553]
- 7 **García Rodríguez LA**, González-Pérez A, Johansson S, Wallander MA. Risk factors for inflammatory bowel disease in the general population. *Aliment Pharmacol Ther* 2005; **22**: 309-315 [PMID: 16097997 DOI: 10.1111/j.1365-2036.2005.02564.x]
- 8 **Bernstein CN**, Rawsthorne P, Cheang M, Blanchard JF. A population-based case control study of potential risk factors for IBD. *Am J Gastroenterol* 2006; **101**: 993-1002 [PMID: 16696783 DOI: 10.1111/j.1572-0241.2006.00381.x]
- 9 **Lashner BA**, Loftus EV Jr. True or false? The hygiene hypothesis for Crohn's disease. *Am J Gastroenterol* 2006; **101**: 1003-1004 [PMID: 16696784 DOI: 10.1111/j.1572-0241.2006.00563.x]
- 10 **Koloski NA**, Bret L, Radford-Smith G. Hygiene hypothesis in inflammatory bowel disease: a critical review of the literature. *World J Gastroenterol* 2008; **14**: 165-173 [PMID: 18186549 DOI: 10.3748/wjg.14.165]
- 11 **Zaltman C**. Inflammatory bowel disease: how relevant for Brazil? *Cad Saude Publica* 2007; **23**: 992-993 [PMID: 17486222 DOI: 10.1590/S0102-311X2007000500001]
- 12 **Molodecky NA**, Kaplan GG. Environmental risk factors for inflammatory bowel disease. *Gastroenterol Hepatol (N Y)* 2010; **6**: 339-346 [PMID: 20567592]
- 13 **Ponder A**, Long MD. A clinical review of recent findings in the epidemiology of inflammatory bowel disease. *Clin Epidemiol* 2013; **5**: 237-247 [PMID: 23922506]
- 14 **Ananthakrishnan AN**. Epidemiology and risk factors for IBD. *Nat Rev Gastroenterol Hepatol* 2015; **12**: 205-217 [PMID: 25732745 DOI: 10.1038/nrgastro.2015.34]
- 15 **Victoria CR**, Sassak LY, Nunes HR. Incidence and prevalence rates of inflammatory bowel diseases, in midwestern of São Paulo State, Brazil. *Arq Gastroenterol* 2009; **46**: 20-25 [PMID: 19466305 DOI: 10.1590/S0004-28032009000100009]
- 16 **Parente JM**, Coy CS, Campelo V, Parente MP, Costa LA, da Silva RM, Stephan C, Zeitune JM. Inflammatory bowel disease

- in an underdeveloped region of Northeastern Brazil. *World J Gastroenterol* 2015; **21**: 1197-1206 [PMID: 25632193 DOI: 10.3748/wjg.v21.i4.1197]
- 17 **Farrukh A**, Mayberry JF. Inflammatory bowel disease in Hispanic communities: a concerted South American approach could identify the aetiology of Crohn's disease and ulcerative colitis. *Arg Gastroenterol* 2014; **51**: 271-275 [PMID: 25591153 DOI: 10.1590/S0004-28032014000400002]
  - 18 **Guo AY**, Stevens BW, Wilson RG, Russell CN, Cohen MA, Sturgeon HC, Thornton A, Giallourakis C, Khalili H, Nguyen DD, Sauk J, Yajnik V, Xavier RJ, Ananthakrishnan AN. Early life environment and natural history of inflammatory bowel diseases. *BMC Gastroenterol* 2014; **14**: 216 [PMID: 25510175 DOI: 10.1186/s12876-014-0216-8]
  - 19 **Castiglione F**, Diaferia M, Morace F, Labianca O, Meucci C, Cuomo A, Panarese A, Romano M, Sorrentini I, D'Onofrio C, Caporaso N, Rispo A. Risk factors for inflammatory bowel diseases according to the "hygiene hypothesis": a case-control, multi-centre, prospective study in Southern Italy. *J Crohns Colitis* 2012; **6**: 324-329 [PMID: 22405169 DOI: 10.1016/j.crohns.2011.09.003]
  - 20 **Zeng Z**, Zhu Z, Yang Y, Ruan W, Peng X, Su Y, Peng L, Chen J, Yin Q, Zhao C, Zhou H, Yuan S, Hao Y, Qian J, Ng SC, Chen M, Hu P. Incidence and clinical characteristics of inflammatory bowel disease in a developed region of Guangdong Province, China: a prospective population-based study. *J Gastroenterol Hepatol* 2013; **28**: 1148-1153 [PMID: 23432198 DOI: 10.1111/jgh.12164]
  - 21 **Lins TC**, Vieira RG, Abreu BS, Grattapaglia D, Pereira RW. Genetic composition of Brazilian population samples based on a set of twenty-eight ancestry informative SNPs. *Am J Hum Biol* 2010; **22**: 187-192 [PMID: 19639555]
  - 22 **Weinstock JV**, Summers R, Elliott DE. Helminths and harmony. *Gut* 2004; **53**: 7-9 [PMID: 14684567 DOI: 10.1136/gut.53.1.7]
  - 23 **Frolkis A**, Dieleman LA, Barkema HW, Panaccione R, Ghosh S, Fedorak RN, Madsen K, Kaplan GG; Alberta IBD Consortium. Environment and the inflammatory bowel diseases. *Can J Gastroenterol* 2013; **27**: e18-e24 [PMID: 23516681 DOI: 10.1155/2013/102859]
  - 24 **Berg AM**, Dam AN, Farraye FA. Environmental influences on the onset and clinical course of Crohn's disease-part 2: infections and medication use. *Gastroenterol Hepatol* (N Y) 2013; **9**: 803-810 [PMID: 24772046]
  - 25 **Amre DK**, Lambrette P, Law L, Krupoves A, Chotard V, Costea F, Grimard G, Israel D, Mack D, Seidman EG. Investigating the hygiene hypothesis as a risk factor in pediatric onset Crohn's disease: a case-control study. *Am J Gastroenterol* 2006; **101**: 1005-1011 [PMID: 16573775 DOI: 10.1111/j.1572-0241.2006.00526.x]
  - 26 **Porter CK**, Tribble DR, Aliaga PA, Halvorson HA, Riddle MS. Infectious gastroenteritis and risk of developing inflammatory bowel disease. *Gastroenterology* 2008; **135**: 781-786 [PMID: 18640117 DOI: 10.1053/j.gastro.2008.05.081]
  - 27 **Jakobsen C**, Paerregaard A, Munkholm P, Wewer V. Environmental factors and risk of developing paediatric inflammatory bowel disease -- a population based study 2007-2009. *J Crohns Colitis* 2013; **7**: 79-88 [PMID: 22748696 DOI: 10.1016/j.crohns.2012.05.024]
  - 28 **To N**, Gracie DJ, Ford AC. Systematic review with meta-analysis: the adverse effects of tobacco smoking on the natural history of Crohn's disease. *Aliment Pharmacol Ther* 2016; **43**: 549-561 [PMID: 26749371 DOI: 10.1111/apt.13511]
  - 29 **Parkes GC**, Whelan K, Lindsay JO. Smoking in inflammatory bowel disease: impact on disease course and insights into the aetiology of its effect. *J Crohns Colitis* 2014; **8**: 717-725 [PMID: 24636140 DOI: 10.1016/j.crohns.2014.02.002]
  - 30 **Nunes T**, Etchevers MJ, García-Sánchez V, Ginard D, Martí E, Barreiro-de Acosta M, Gomollón F, Arroyo M, Bastida G, Gonzalez B, Monfort D, Garcia-Planella E, Figueroa C, Panés J, Sans M. Impact of Smoking Cessation on the Clinical Course of Crohn's Disease Under Current Therapeutic Algorithms: A Multicenter Prospective Study. *Am J Gastroenterol* 2016; **111**: 411-419 [PMID: 26856753 DOI: 10.1038/ajg.2015.401]

**P- Reviewer:** Garcia-Olmo D, Zhu WM **S- Editor:** Qi Y

**L- Editor:** A **E- Editor:** Zhang FF



## Retrospective Cohort Study

# Postoperative bleeding in patients on antithrombotic therapy after gastric endoscopic submucosal dissection

Chiko Sato, Kingo Hirasawa, Ryonho Koh, Ryosuke Ikeda, Takehide Fukuchi, Ryosuke Kobayashi, Hiroaki Kaneko, Makomo Makazu, Shin Maeda

Chiko Sato, Kingo Hirasawa, Ryonho Koh, Ryosuke Ikeda, Takehide Fukuchi, Ryosuke Kobayashi, Hiroaki Kaneko, Makomo Makazu, Endoscopy Division, Yokohama City University Medical Center, Yokohama 232-0024, Japan

Shin Maeda, Department of Gastroenterology, Yokohama City University Graduate School of Medicine, Yokohama 236-0004, Japan

**Author contributions:** Sato C and Hirasawa K contributed to conception and design; Sato C, Hirasawa K, Koh R, Ikeda R, Fukuchi T, Kobayashi R, Kaneko H and Makazu M contributed to acquisition of data; Sato C and Hirasawa K contributed to analysis and interpretation of data; Hirasawa K contributed to drafting of the article; Hirasawa K and Maeda S contributed to critical revision of the article; Sato C and Hirasawa K contributed to statistical analysis; Hirasawa K and Maeda S final approved the article; all authors listed have contributed substantially to the design, data collection and analysis, and editing of the manuscript.

**Institutional review board statement:** This research was approved by the research ethics committee in our hospital (Approval number: D1602024).

**Informed consent statement:** Patients were not required to provide informed consent to the study because the analysis used anonymous clinical data that were obtained after each patient agreed to treatment by written consent.

**Conflict-of-interest statement:** All the authors have no conflict of interest related to the manuscript.

**Data sharing statement:** No additional data are available.

**Open-Access:** This article is an open-access article which was selected by an in-house editor and fully peer-reviewed by external reviewers. It is distributed in accordance with the Creative Commons Attribution Non Commercial (CC BY-NC 4.0) license, which permits others to distribute, remix, adapt, build upon this work non-commercially, and license their derivative works on different terms, provided the original work is properly cited and the use is non-commercial. See: <http://creativecommons.org/licenses/by-nc/4.0/>

licenses/by-nc/4.0/

**Manuscript source:** Unsolicited manuscript

**Correspondence to:** Kingo Hirasawa, MD, PhD, Endoscopy Division, Yokohama Medical University Center Hospital, 4-57, Urafune-cho, Minami-ku, Yokohama 232-0024, Japan. [kingo-h@urahp.yokohama-cu.ac.jp](mailto:kingo-h@urahp.yokohama-cu.ac.jp)  
Telephone: +81-45-2615656  
Fax: +81-45-2535382

**Received:** May 17, 2017

**Peer-review started:** May 19, 2017

**First decision:** June 8, 2017

**Revised:** June 26, 2017

**Accepted:** July 12, 2017

**Article in press:** July 12, 2017

**Published online:** August 14, 2017

## Abstract

### AIM

To investigate the relationship between postoperative bleeding following gastric endoscopic submucosal dissection (ESD) and individual antithrombotic agents.

### METHODS

A total of 2488 gastric neoplasms in 2148 consecutive patients treated between May 2001 and June 2016 were studied. The antithrombotic agents were categorized into antiplatelet agents, anticoagulants, and other antithrombotic agents, and we included combination therapies [e.g., dual antiplatelet therapy (DAPT)]. The risk factors associated with post-ESD bleeding, namely, antithrombotic agents overall, individual antithrombotic agents, withdrawal or continuation of antithrombotic agents, and bleeding onset period (during the first six days or thereafter), were analyzed using univariate and multivariate analyses.



## RESULTS

The en bloc resection and complete curative resection rates were 99.2% and 91.9%, respectively. Postoperative bleeding occurred in 5.1% cases. Bleeding occurred in 10.3% of the patients administered antithrombotic agents. Being male ( $P = 0.007$ ), specimen size ( $P < 0.001$ ), and antithrombotic agent used ( $P < 0.001$ ) were independent risk factors for postoperative bleeding. Heparin bridging therapy (HBT) ( $P = 0.002$ ) and DAPT/multidrug combinations ( $P < 0.001$ ) were independent risk factors associated with postoperative bleeding. The bleeding rate of the antithrombotic agent continuation group was significantly higher than that of the withdrawal group ( $P < 0.01$ ). Bleeding within postoperative day (POD) 6 was significantly higher in warfarin ( $P = 0.015$ ), and bleeding after POD 7 was significantly higher in DAPT/multidrug combinations ( $P = 0.007$ ). No thromboembolic events were reported.

## CONCLUSION

We must closely monitor patients administered HBT and DAPT/multidrug combinations after gastric ESD, particularly those administered multidrug combinations after discharge.

**Key words:** Gastric cancer; Endoscopic submucosal dissection; Postoperative hemorrhages; Antithrombotic agent; Heparin

© The Author(s) 2017. Published by Baishideng Publishing Group Inc. All rights reserved.

**Core tip:** The major complication of gastric endoscopic submucosal dissection (ESD) is postoperative bleeding. Previous studies reported the relationship between postoperative bleeding and antithrombotic agents. We aimed to investigate postoperative bleeding following gastric ESD in relation to specific antithrombotic agents. We showed that antithrombotic agents, in particular heparin bridging therapy and dual antiplatelet therapy/multidrug combination, were independent risk factors for delayed bleeding. Furthermore, bleeding in the early period was significantly higher for warfarin, and bleeding in the late period was significantly higher for multidrug combination. We must strictly observe multidrug combination users especially after discharge.

Sato C, Hirasawa K, Koh R, Ikeda R, Fukuchi T, Kobayashi R, Kaneko H, Makazu M, Maeda S. Postoperative bleeding in patients on antithrombotic therapy after gastric endoscopic submucosal dissection. *World J Gastroenterol* 2017; 23(30): 5557-5566 Available from: URL: <http://www.wjgnet.com/1007-9327/full/v23/i30/5557.htm> DOI: <http://dx.doi.org/10.3748/wjg.v23.i30.5557>

## INTRODUCTION

Endoscopic submucosal dissection (ESD) for early gastric cancer is routinely performed worldwide,

because it is minimally invasive and effective<sup>[1-3]</sup>. The most common complication associated with gastric ESD is postoperative bleeding, which has a frequency of 3.1%-6.5%<sup>[4-6]</sup>.

The number of individuals administered antithrombotic agents has increased over recent years. The Japan Gastrointestinal Endoscopy Society (JGES) guidelines indicate that withdrawal or continuation of antithrombotic agents depends on whether the patient is at a high or low risk of thromboembolism during ESD<sup>[7]</sup>. The risk of postoperative bleeding increases when gastric ESD is performed on patients on antithrombotic agent therapy<sup>[8-10]</sup>, and antithrombotic agent therapy is an independent risk factor for postoperative bleeding<sup>[11]</sup>. Heparin bridging therapy (HBT) is recommended for patients who are on anticoagulant therapy and are at a high risk of thromboembolism<sup>[7]</sup>, and postoperative bleeding associated with gastric ESD worsens with HBT<sup>[12-14]</sup>. Furthermore, the preventive effect of HBT on thromboembolism is low<sup>[15]</sup>. By contrast, the risk of thromboembolism following antithrombotic agent withdrawal is 0.6%-4.2%<sup>[16-18]</sup>. Thus, caution is required when deciding whether to withdraw or continue antithrombotic agents in preparation for endoscopic treatment.

Few studies have investigated the incidence of thromboembolism following gastric ESD in relation to the different types of antithrombotic agent. Moreover, the safety and validity of HBT remain controversial. This study aimed to evaluate postoperative bleeding, the washout periods, and the thromboembolism incidence in relation to different antithrombotic agents following gastric ESD performed on patients administered antithrombotic agents.

## MATERIALS AND METHODS

Between May 2001 and June 2016, ESD was performed on 2148 patients and 2488 early gastric cancer lesions. Of these patients, 50 with cancer in their remnant stomachs and four with gastric tubes were excluded; thus, 2094 patients and 2434 lesions were evaluated. Multiple lesions resected en bloc were included in this study, and since the analysis was based on ESD-induced ulcers, 2094 patients and 2378 ulcers were investigated. We retrospectively reviewed the clinical records of all patients after obtaining approval from the institutional review board.

ESD is indicated for differentiated mucosal cancer lesions without ulcers (UL[-]), regardless of size, differentiated mucosal cancer lesions  $\leq 3$  cm with ulcers (UL[+]), UL[-] undifferentiated mucosal cancer  $\leq 2$  cm in size<sup>[19-21]</sup>, and for lymph node metastasis-free and distant metastasis-free lesions that have been confirmed by preoperative computed tomography.

The antithrombotic agents were categorized into antiplatelet agents (low-dose aspirin and thienopyridine), anticoagulants [warfarin and direct oral anticoagulants (DOAC)], and other antithrombotic

agents, and we included combination therapies, for example, dual antiplatelet therapy (DAPT). Of the patients who received HBT, 94.9% were switched from warfarin; therefore, the warfarin group was called the non-HBT warfarin monotherapy group and it was analyzed separately from the group administered HBT.

The risk factors associated with postoperative bleeding were investigated in relation to age, sex, the size of the specimen, the tumor's morphology, the tumor's depth, the presence or absence of ulcerative findings, antithrombotic agent use, and the treatment outcomes. The postoperative bleeding risk was investigated in relation to the aforementioned drug categories. The time to bleeding with respect to each drug was separated into an early period, that is, before postoperative day (POD) 6, and a late period, that is, after POD 7. The withdrawal and continuation of the antithrombotic agents, including HBT, were investigated.

### Management and procedure

If a patient was taking an oral antithrombotic agent, we consulted the attending physician before the procedure began and determined the feasibility of treatment withdrawal and the duration of the withdrawal period using the JGES guidelines. If patients were taking DAPT or multiple antithrombotic agents, we changed their treatment to low-dose aspirin monotherapy following preprocedural consultations with their attending physicians.

The patients in the antithrombotic agent continuation and withdrawal groups were hospitalized the day before the ESD. Patients switched to HBT from anticoagulant therapy were hospitalized three days before the ESD, and continuous intravenous drip infusions of unfractionated heparin were initiated. In the HBT group, we adjusted the dose to increase the activated partial thromboplastin time to 1.5–2-times that of the pretreatment value. We confirmed that the prothrombin time (PT)–international normalized ratio (INR) was not excessively prolonged on the day of the ESD. We interrupted the HBT 6 h before the ESD, and after the ESD, we confirmed adequate hemostasis at the ulcer's base and restarted the HBT 3 h later. Anticoagulant therapy was reinstated from POD 2 following second-look endoscopy (SLE) on POD 1 to confirm hemostasis. To reach the peak plasma concentrations rapidly, the patients received twice their usual doses of anticoagulant therapy on POD 2, 1.5-times their doses on POD 3, and their usual doses from POD 4 onwards. In the HBT group, we stopped treatment after confirming that the PT–INR had reached its optimum range following the reinstatement of oral treatment. We also reinstated oral treatment in the withdrawal group from POD 2 onwards following SLE. All of the patients received omeprazole drip infusions (40 mg/d) on POD 1. From POD 2 onwards, they received an oral proton pump inhibitor (PPI) that,

until 2014, comprised omeprazole (20 mg/d) and after 2015, comprised esomeprazole (20 mg/d); this treatment continued for at least eight weeks after ESD.

The gastric ESDs were performed using a conventional procedure<sup>[11,22]</sup>. After making the incision, a coagulation procedure was performed on the exposed blood vessels that remained in the ulcer's base using hemostatic forceps (Coagrasper; Olympus Medical Systems Corporation, Tokyo, Japan). A mixture containing aluminum hydroxide gel, liquid magnesium hydroxide, and 10000 U thrombin (approximately 100 mL) was dispersed.

SLE was performed on all patients on POD 1 to check the bleeding from the ulcers' bases, and if exposed blood vessels were detected, prophylactic hemostasis using a clip or coagulation hemostasis was performed. After confirming hemostasis, fluid intakes were resumed, and liquid meals were reinstated from POD 2. Solid meals, oral antithrombotic agents, and PPIs were reinstated simultaneously.

### Postoperative bleeding definitions

Postoperative bleeding was defined as clinical evidence of bleeding in ESD-induced ulcers, which included the occurrence of overt hematemesis, the presence of melena, the presence of blood or clots in the stomach, spots of bleeding observed endoscopically, or a reduction in the hemoglobin level of > 2 g/dL. Preventive hemostasis of visible vessels without evidence of bleeding during SLE was not included in the analysis. Most patients were hospitalized for six days after the ESD; hence, bleeding that occurred during hospitalization was defined as early-phase postoperative bleeding, and that which occurred after discharge was defined as late-phase postoperative bleeding.

### Statistical analysis

Some of the patients had more than one gastric neoplasm and underwent one or more ESDs. For the statistical analyses, the data from different ESD-induced ulcers were considered to represent statistically independent observations. The patients' characteristics are expressed as the means and the standard deviations. The groups' mean quantitative values were compared using analyses of variance followed by *t* tests. To investigate the potential risk factors associated with post-ESD bleeding, we analyzed the following variables: age; sex; the use of antithrombotic agents, including aspirin, thienopyridine, warfarin, DOACs, HBT, other antithrombotic agents, and DAPT/multidrug combinations; the resected specimen's maximum diameter; the tumor's location; pathological factors, including the macroscopic type, histological depth, and lymphovascular invasion; the ulcer's characteristics; the procedure time; complications, including perforations, postoperative perforations, postoperative bleeding, and thromboembolism; drug withdrawal or

**Table 1** Clinicopathological features and treatment outcomes of all 2094 patients (2434 lesions and 2378 ulcers) *n* (%)

Age (mean $\pm$ SD, yr)	72 $\pm$ 6.9
Gender	
Male	1786 (75.1)
Female	592 (24.9)
Location	
U	412 (17.5)
M	742 (31.2)
L	122 (51.5)
Morphology	
Protruded	1042 (43.8)
Flat/depressed	1336 (56.2)
Specimen size, (mean $\pm$ SD, mm)	39 $\pm$ 9.8
Depth of invasion	
M	2227 (93.7)
SM	151 (6.3)
Ulcerative findings	
(+)	203 (8.5)
(-)	2175 (91.5)
Anticoagulant agents	
(+)	447 (18.8)
(-)	1931 (81.2)
En-bloc resection	99.2%
R0+curative resection	91.9%
Mean procedure time $\pm$ SD (min)	49 $\pm$ 30.1
Complications	
Perforation	74 (3.1)
Delayed perforation	2 (0.8)
Delayed bleeding	122 (5.1)
Thromboembolism	0

continuation; and the bleeding time frame. For the univariate analyses, the categorical variables were compared using the  $\chi^2$  test and Fisher's exact test, as appropriate, followed by Fisher's least significant difference post hoc test, and those variables with *P* values < 0.05 were included in the multivariate analyses. The ORs and 95% CIs were calculated using logistic regression analyses to identify the factors associated with postoperative bleeding. *P* values < 0.05 were considered statistically significant. All of the statistical analyses were conducted using SPSS, version 13.0 (SPSS Inc., Chicago, IL, United States).

## RESULTS

The ESD procedures were well tolerated by the patients, and their cardiac and respiratory parameters remained stable throughout the procedures. Table 1 presents the clinicopathological characteristics of and the treatment outcomes from the 2094 patients (2434 lesions and 2378 ulcers).

The en-bloc resection and complete curative resection rates were 99.2% and 91.9%, respectively. There were 74 (3.1%) cases with perforations, two (0.08%) postoperative perforations, and 122 (5.1%) cases of postoperative bleeding. No thromboembolic events occurred.

### Risk factors associated with postoperative bleeding

To investigate the risk factors associated with postoperative bleeding, the ulcers (*n* = 2378) were divided

into a bleeding group (*n* = 122) and a non-bleeding group (*n* = 2256). Overall, 447 ulcers (18.8%) occurred in the patients administered antithrombotic agents, and the rate of bleeding was 10.3% (46/447). The univariate analysis showed that being male (*P* = 0.002), a large specimen (*P* < 0.001), submucosal invasive cancer (*P* = 0.045), and antithrombotic agent use (*P* < 0.001) were significantly associated with post-ESD bleeding (Table 2). The multivariate analysis revealed that being male (OR = 2.103, 95%CI: 1.224-3.611, *P* = 0.007), the specimen size (OR = 1.025, 95%CI: 1.013-1.037, *P* < 0.001), and antithrombotic agent use (OR = 2.643, 95%CI: 1.796-3.889, *P* < 0.001) were independent risk factors for postoperative bleeding (Table 3).

### Risk factors for post-ESD bleeding according to the drug(s) administered

The antithrombotic agent group comprised 447 ulcers, and postoperative bleeding occurred in 211 (47.2%) cases on low-dose aspirin, 19 (4.3%) cases on thienopyridine, 17 (3.8%) cases on warfarin, 18 (4.0%) cases on DOACs, 70 (15.7%) cases on other antithrombotic monotherapies, 39 (8.7%) cases on HBT, and 75 (16.8%) cases on DAPT/multidrug combinations (Table 4). In addition, 94.9% (37 cases) of the HBT cases were warfarin users who were switched to HBT.

The bleeding rates were 5.7% (12/211 cases, *P* = 0.224) in the low-dose aspirin group, 0% (0/19 cases, *P* = 0.379) in the thienopyridine group, 5.9% (1/17 cases, *P* = 0.498) in the warfarin group, 5.6% (1/18 cases, *P* = 0.725) in the DOAC group, 4.3% (3/70 cases, *P* = 0.883) in the other antithrombotic monotherapy group, 15.4% (6/39 cases, *P* < 0.01) in the HBT group, and 30.7% (23/75 cases, *P* < 0.01) in the DAPT/multidrug combination group. The multivariate analysis determined that HBT and DAPT/multidrug combinations were independent risk factors for post-ESD bleeding [HBT: OR = 4.244, 95%CI: (1.736-10.380), *P* = 0.002; DAPT/multidrug combinations: OR = 10.325, 95%CI: (6.060-17.593), *P* < 0.001] (Table 5).

### Rates of bleeding associated with antithrombotic agent withdrawal or continuation

The postoperative bleeding rates in the control (1931 ulcers) and withdrawal (401 ulcers) groups were 3.9% (76/1931 ulcers) and 8.0% (32/401 ulcers), respectively, a difference that was significant (*P* < 0.01) (Table 6). The postoperative bleeding rates in the withdrawal (401 ulcers) and continuation (46 ulcers) groups were 8.0% (32/401 ulcers) and 30.4% (14/46 ulcers), respectively, a difference that was significant (*P* < 0.01) (Table 6).

### Bleeding times according to the drug(s) administered

Bleeding during the early period (up to POD 6) was common among the patients administered warfarin (*P*

**Table 2** Univariate analysis of risk factors of delayed bleeding *n* (%)

	<i>n</i> = 2378	Delayed bleeding		<i>P</i> value	OR	95%CI
		(+) <i>n</i> = 122	(-) <i>n</i> = 2256			
Age (mean ± SD, yr)		71.5 ± 8.7	71.1 ± 8.8	0.622 <sup>2</sup>	1.005	0.984-1.027
Gender						
Male	1786 (75.1)	106 (5.9)	1680 (94.1)	0.002 <sup>1</sup>	2.271	1.331-3.875
Female	24.9 (592)	16 (2.7)	576 (97.3)			
Location					Reference	1.0
U	412 (17.3)	17 (4.1)	395 (95.9)			
M	742 (31.2)	40 (5.4)	702 (94.6)	0.342	1.303	0.755-2.250
L	1224 (51.5)	65 (5.3)	1159 (94.7)	0.344	1.324	0.741-2.366
Morphology						
Protruded	1042 (43.8)	49 (4.7)	993 (95.3)	0.404 <sup>1</sup>	0.854	0.589-1.238
Flat/depressed	1336 (56.2)	73 (5.5)	1263 (94.5)			
Specimen size (mean ± SD, mm)	38.9 ± 2.2	44.4 ± 15.1	38.9 ± 13.1	< 0.001 <sup>2</sup>	1.025	1.014-1.037-
Depth of invasion						
M	2227 (93.7)	109 (4.9)	2118 (95.1)	0.045 <sup>1</sup>	1.830	1.004-3.336
SM	151 (6.3)	13 (8.6)	138 (91.4)			
Ulcerative findings						
(+)	203 (8.5)	12 (5.9)	191 (94.1)	0.598 <sup>1</sup>	1.179	0.638-2.179
(-)	2175 (91.5)	110 (5.1)	2065 (94.9)			
Anticoagulant agents						
(+)	447 (18.8)	46 (10.3)	401 (89.7)	< 0.001 <sup>1</sup>	2.800	1.911-4.101
(-)	1931 (81.2)	76 (3.9)	1855 (96.1)			
En-bloc resection rate	99.2%	99.1%	99.2%	0.979	0.973	0.129-7.329
R0+curative resection rate	91.9%	95.1%	97.1%	0.198	1.744	0.740-4.017
Median procedure time (min)	49 ± 30.1	50 ± 30.8	50 ± 32.2	0.885 <sup>2</sup>	1.033	0.840-2.354

<sup>1</sup>  $\chi^2$  test; <sup>2</sup> *t*-test.**Table 3** Multivariate analysis of risk factors of delayed bleeding

	<i>P</i> value	OR	95%CI
Male	0.007	2.103	1.224-3.611
Median specimen size	< 0.001	1.025	1.013-1.037
SM	0.187	1.516	0.817-2.812
Anticoagulant agents (+)	< 0.001	2.643	1.796-3.889

= 0.015), and bleeding during the late period (from POD 7 onwards) was common among the patients administered DAPT/multidrug combinations (*P* = 0.007) (Table 7). Bleeding was commonly observed during the early period in patients administered HBT, a difference that was not significant compared with the other treatments.

## DISCUSSION

In this study, we investigated the risk of bleeding associated with gastric ESD, the bleeding time, and the risk of bleeding associated with treatment withdrawal or continuation according to the antithrombotic agent(s) administered. We determined that being male, a large specimen, and antithrombotic agent use were independent risk factors for postoperative bleeding. Previous reports revealed that the prevalence of ischemic heart disease and stroke is higher for male than for female<sup>[23-25]</sup>. Furthermore, since ischemic heart disease and stroke are closely related to antithrombotic therapy, we considered that male sex is an

independent risk factor.

Furthermore, HBT and DAPT/multidrug combinations were independent risk factors for postoperative bleeding. This study's findings showed that postoperative bleeding was significantly higher in the group that continued antithrombotic agents compared with the group that withdrew antithrombotic agents. Our findings also showed that early-phase bleeding was more frequent in association with HBT and that late-phase bleeding was more frequent in association with DAPT/multidrug combinations.

The bleeding rate for patients on antithrombotic agents is high at 23.3%-35.5%<sup>[26,27]</sup>, that associated with HBT is higher at 23.8%-61.5%, and it is even higher in association with multidrug combinations<sup>[12-14,28,29]</sup>. We found that HBT and DAPT/multidrug combinations were independent risk factors associated with postoperative bleeding, which concurs with previous reports. However, until now, the risk of post-ESD bleeding and the bleeding time frames in the context of individual antithrombotic agents had not been investigated in a large number of subjects. Furthermore, this is the first study to compare the risk of bleeding in a control group and a treatment withdrawal group, and in a withdrawal group and treatment continuation group.

In this investigation, 94.9% (37/39) of the patients treated with HBT were switched from warfarin therapy. When HBT patients are administered warfarin, they will be affected by the HBT; hence, the effect of warfarin alone on postoperative bleeding cannot be analyzed. Consequently, this study's analysis involved assigning the patients to an HBT group or a non-HBT warfarin



**Table 4** Univariate analysis of risk factors for delayed bleeding by each antithrombotic agent *n* (%)

	Delayed bleeding		<i>P</i> value <sup>1</sup>	OR	95%CI
	(+)	(-)			
Aspirin					
(+) ( <i>n</i> = 211)	12 (5.7)	199 (94.3)	0.224	1.472	0.787-2.753
(-) ( <i>n</i> = 1931)	76 (3.9)	1855 (96.1)			
Thienopyridine					
(+) ( <i>n</i> = 19)	0 (0)	19 (100)	0.379	0.990	0.985-0.994
(-) ( <i>n</i> = 1931)	76 (3.9)	1855 (96.1)			
Warfarin					
(+) ( <i>n</i> = 17)	1 (5.9)	16 (94.1)	0.498	1.525	0.200-11.653
(-) ( <i>n</i> = 1931)	76 (3.9)	1855 (96.1)			
DOAC					
(+) ( <i>n</i> = 18)	1 (5.6)	17 (94.4)	0.725	1.436	0.189-10.930
(-) ( <i>n</i> = 1931)	76 (3.9)	1855 (96.1)			
Others					
(+) ( <i>n</i> = 70)	3 (4.3)	67 (95.7)	0.883	1.093	0.336-3.554
(-) ( <i>n</i> = 1931)	76 (3.9)	1855 (96.1)			
HBT					
(+) ( <i>n</i> = 39)	6 (15.4)	33 (84.6)	< 0.01	4.438	1.805-10.911
(-) ( <i>n</i> = 1931)	76 (3.9)	1855 (96.1)			
DAPT/multidrug combination					
(+) ( <i>n</i> = 75)	23 (30.7)	52 (69.3)	< 0.01	10.796	6.280-18.558
(-) ( <i>n</i> = 1931)	76 (3.9)	1855 (96.1)			

<sup>1</sup> $\chi^2$  test. DOAC: Direct oral anticoagulants; HBT: Heparin bridging therapy; DAPT: Dual antiplatelet therapy.

**Table 5** Multivariate analysis of risk factors for delayed bleeding by each antithrombotic agent

	<i>P</i> value	OR	95%CI
HBT	0.002	4.244	1.736-10.380
DAPT/multidrug combination	< 0.001	10.325	6.060-17.593

HBT: Heparin bridging therapy; DAPT: Dual antiplatelet therapy.

monotherapy group. In the warfarin group, 94% (16/17) of the patients continued their treatment, but there was no significant difference in relation to bleeding, a finding that has never been reported before.

The postoperative bleeding rate was high in the antithrombotic agent continuation group compared with the control and withdrawal groups. Therefore, to reduce the bleeding risk, antithrombotic agent withdrawal is preferable. However, between 1% and 4.2% of patients at a high risk of thromboembolism develop thromboembolisms following drug withdrawal<sup>[15-18]</sup>. Thus, drug withdrawal may trigger serious life-threatening complications. In contrast, another report states that the prognosis is significantly worse following the onset of gastrointestinal bleeding after percutaneous coronary intervention<sup>[30]</sup>. Regarding therapy withdrawal or continuation, physicians should examine a patient's thromboembolism risk and the drug type, and consider implementing tailor-made treatment for each case.

The JGES guidelines recommend that for patients at a high risk of thromboembolism during endoscopic procedures that are associated with a high risk of

bleeding, including ESD, it is preferable to administer aspirin alone with no treatment withdrawal. The guidelines from the United States and Europe also recommend continuing aspirin therapy<sup>[7,31,32]</sup>. Therefore, the continuation of aspirin therapy was permitted in this study. However, the times at which drug treatments other than aspirin are resumed in DAPT and combination therapy regimens to reduce the risk of bleeding must be investigated. On the other hand, withdrawing anticoagulants, for example, warfarin, will likely induce serious thromboembolism. Therefore, HBT after withdrawal is recommended for endoscopic procedures<sup>[7]</sup>. Patients administered warfarin and periprocedural HBT are at a higher risk of bleeding compared with those who are not administered HBT<sup>[33,34]</sup>. Currently, insufficient evidence exists that supports the prevention of thromboembolism by HBT, and reports have been published that state that it either has no effect on or it has an equivalent efficacy at preventing arterial thromboembolism and reducing the risk of bleeding<sup>[15,33]</sup>. In this study, perioperative thromboembolism did not occur in any of the patients; hence, the prophylactic effect of HBT on blood clots could not be verified. This study's results demonstrated that HBT is an independent risk factor associated with bleeding, and considering previous reports, we recommend that patients on warfarin should either be switched to DOAC rather than HBT, or that they should continue warfarin treatment when ESD is indicated.

The times at which HBT and antithrombotic agent treatments are reinstated are determined once hemostasis has been confirmed; however, definitive timings have not been established. We reinstated heparin treatment from 3 h after ESD, after performing

**Table 6 Investigation of rate of bleeding based on withdrawal or continuation of antithrombotic agent *n* (%)**

	Delayed bleeding		<i>P</i> value <sup>1</sup>	OR	95%CI
	(+)	(-)			
Control group/withdrawal group					
Control ( <i>n</i> = 1931)	76 (3.9)	1855 (96.1)	< 0.01	0.472	0.308-0.725
Withdrawal ( <i>n</i> = 401)	32 (8.0)	369 (92.0)			
Withdrawal group/continuation group					
Withdrawal ( <i>n</i> = 401)	32 (8.0)	369 (92.0)	< 0.01	5.045	2.445-10.411
Continuation ( <i>n</i> = 46)	14 (30.4)	32 (69.6)			

<sup>1</sup> $\chi^2$  test.**Table 7 Investigation of bleeding time by each drug**

	Bleeding (+) <i>n</i> = 46		<i>P</i> value <sup>1</sup>	OR	95%CI
	Early phase	Late phase			
Aspirin ( <i>n</i> = 12)	6	6	0.477	0.619	0.164-2.332
Thienopyridine ( <i>n</i> = 0)	0	0	-	-	-
Warfarin ( <i>n</i> = 7)	6	1	0.015	0.083	0.009-0.767
DOAC ( <i>n</i> = 1)	0	1	1.000	1.038	0.964-1.118
Others ( <i>n</i> = 3)	2	1	0.561	0.327	0.027-3.892
HBT ( <i>n</i> = 6)	5	1	0.068	0.108	0.011-1.015
DAPT/multidrug combination ( <i>n</i> = 23)	5	18	0.007	5.600	1.530-20.492

<sup>1</sup>Fisher's exact test. DOAC: Direct oral anticoagulants; HBT: Heparin bridging therapy; DAPT: Dual antiplatelet therapy.

adequate hemostasis of the ulcer base and accounting for the thromboembolism risk. Furthermore, we performed SLE on the day after ESD, and we performed preventive hemostasis on the exposed blood vessels in the ulcers' bases, even if there was no bleeding. Early bleeding was common before POD 6 in the HBT group. This may have been caused by the synergistic pharmacological effects of the heparin and the anticoagulants, which were reinstated from POD 2 onwards, reaching their peak plasma concentrations. In contrast, in the DAPT/multidrug combination group, the plasma concentrations of the respective antithrombotic agents were stable and required time to reach their peak ranges, and late bleeding became common from POD 7 onwards.

Many reports describe post-ESD bleeding prevention, and coagulation immediately after ESD is commonly used and is effective<sup>[5]</sup>. Applying a polyglycolic acid sheet to and spreading fibrin glue on ESD-induced ulcer bases are novel, easy, and effective approaches to the management of post-ESD bleeding in patients on antithrombotic agents<sup>[35-37]</sup>, and they will be useful for patients who are at a high risk of bleeding.

The findings from a multicenter prospective randomized study of SLE undertaken by Mochizuki *et al.*<sup>[38]</sup> showed that the postoperative bleeding rates did not differ significantly between the SLE and the non-SLE groups. These investigators reported that scheduled SLE could not be expected to reduce bleeding. However, another report states that SLE and third-look esophago-gastroduodenoscopy are useful for preventing post-ESD bleeding in patients on antithrombotic agents<sup>[39]</sup>. Further investigations into these approaches are warranted.

The limitations of this study are as follows. First, this is a single-center retrospective cohort study. Second, the relationship between *Helicobacter pylori* (*H. pylori*) and postoperative bleeding after gastric ESD was not investigated. We could not confirm the information about *H. pylori* infection and eradication, particularly in the initial cases, because of the long research period. As a result, only about 60% of the total information of *H. pylori* could be obtained; thus, the state of *H. pylori* infection was excluded as a factor for postoperative bleeding in this study.

This study's findings demonstrated that HBT and DAPT/multidrug combinations are independent risk factors for postoperative bleeding in patients on antithrombotic agents who undergo gastric ESD. Adequate management that considers the prevention of bleeding and thromboembolism is important.

#### **What is already known on this topic**

Antithrombotic agent therapy increases the risk of bleeding after ESD. Serious thromboembolism may occur following antithrombotic agent withdrawal.

#### **What this study adds to our knowledge**

HBT and DAPT/multidrug combinations are independent risk factors for bleeding post-ESD. Early-phase bleeding was more frequently associated with HBT, and late-phase bleeding was more frequently associated with DAPT/multidrug combinations. When patients on warfarin monotherapy and those who are switched from warfarin to HBT are investigated separately, HBT alone becomes a risk factor.

## COMMENTS

### Background

The most common complication associated with gastric endoscopic submucosal dissection (ESD) is postoperative bleeding. An increasing number of reports have revealed that antithrombotic agent therapy is a risk factor after ESD. Withdrawal or continuation of antithrombotic agents is decided depending on the patient's risk of thromboembolism. However, many reports showed that antithrombotic agents promote the risk of postoperative bleeding and withdrawal promotes thrombosis. Although it is clinically questionable whether all types of antithrombotic agents can be equally treated, detailed investigation has not yet been performed and the risk and benefit of continuation or withdrawal remain controversial. Thus, this study aimed to evaluate postoperative bleeding, the washout periods, and the thromboembolism incidence in relation to different antithrombotic agents following gastric ESD performed on patients administered antithrombotic agents.

### Research frontiers

A previous retrospective study showed that the bleeding rate for gastric ESD patients on antithrombotic agents is high at 23.3%-35.5%, that associated with heparin bridge therapy (HBT) is higher, and it is even higher in association with multidrug combinations. The Japan Gastrointestinal Endoscopy Society (JGES) guidelines indicate that withdrawal or continuation of antithrombotic agents depends on whether the patient is at a high or low risk of thromboembolism during ESD. The JGES guidelines recommend that for patients at a high risk of thromboembolism during ESD, administration of aspirin alone with no treatment withdrawal is preferred, and the guidelines from the United States and Europe also recommend continuing aspirin therapy. Although HBT after withdrawal is also recommended for endoscopic procedures in the JGES guidelines, patients administered warfarin and periprocedural HBT are reported at a higher risk of bleeding compared with those who are not administered HBT. Furthermore, only few reports are available on the relationship with direct oral anticoagulants or dual antiplatelet therapy (DAPT). Studies on drug continuation or withdrawal, by each drug, and the period to bleeding also remain unreported.

### Innovations and breakthroughs

The authors determined that being male, a large specimen, and antithrombotic agent use were independent risk factors for postoperative bleeding; this finding is almost the same as previously reported. Furthermore, HBT and DAPT/multidrug combinations were independent risk factors for postoperative bleeding. These study's findings showed that postoperative bleeding was significantly higher in the group that continued antithrombotic agents compared with the group that withdrew antithrombotic agents. These findings also showed that early-phase bleeding was more frequent in association with HBT and that late-phase bleeding was more frequent in association with DAPT/multidrug combinations. The authors recommend paying strict attention to observe multidrug combination users, especially after discharge. However, until now, the risk of post-ESD bleeding and the bleeding time frames in the context of individual antithrombotic agents have not been investigated in a large number of subjects. The present study is the first to compare the risk of bleeding in a control group and a treatment withdrawal group, and in a withdrawal group and a treatment continuation group.

### Applications

The results of this study serve as additional evidence to support the calculation of the risk of postoperative bleeding after gastric ESD posed by each antithrombotic agent based on continuation or withdrawal of the antithrombotic agent. Based on the present research, more robust evidence can be obtained in a prospective study.

### Terminology

ESD is one of the endoscopic treatment procedures for superficial gastrointestinal cancer, which can be resected in en-bloc manner.

### Peer-review

This original research paper investigates retrospectively postoperative bleeding in patients on antithrombotic therapy after gastric ESD from the clinical records

of patients in a large cohort. The authors showed that antithrombotic agent in particular heparin bridging therapy and DAPT/multidrug combination were independent risk factors for delayed bleeding, and furthermore, bleeding in the early period was significantly higher for warfarin, and bleeding in the late period was significantly higher for multidrug combination. They recommend to pay attention strictly to observe multidrug combination users especially after discharge. The structure of the manuscript is complete. The scientific question and the aim of the study was stressed clearly in the introduction. The study is well-designed, and all methods and techniques were explained in details. The results add new findings and information to current knowledge. The results were discussed comprehensively.

## REFERENCES

- 1 **Fujishiro M.** Endoscopic submucosal dissection for stomach neoplasms. *World J Gastroenterol* 2006; 12: 5108-5112 [PMID: 16937520 DOI: 10.3748/wjg.v12.i32.5108]
- 2 **Gotoda T, Yamamoto H, Soetikno RM.** Endoscopic submucosal dissection of early gastric cancer. *J Gastroenterol* 2006; 41: 929-942 [PMID: 17096062 DOI: 10.1007/s00535-006-1954-3]
- 3 **Gotoda T.** Endoscopic resection of early gastric cancer: the Japanese perspective. *Curr Opin Gastroenterol* 2006; 22: 561-569 [PMID: 16891890 DOI: 10.1097/01.mog.0000239873.06243.00]
- 4 **Akasaka T, Nishida T, Tsutsui S, Michida T, Yamada T, Ogiyama H, Kitamura S, Ichiba M, Komori M, Nishiyama O, Nakanishi F, Zushi S, Nishihara A, Iijima H, Tsujii M, Hayashi N.** Short-term outcomes of endoscopic submucosal dissection (ESD) for early gastric neoplasm: multicenter survey by osaka university ESD study group. *Dig Endosc* 2011; 23: 73-77 [PMID: 21198921 DOI: 10.1111/j.1443-1661.2010.01062.x]
- 5 **Takizawa K, Oda I, Gotoda T, Yokoi C, Matsuda T, Saito Y, Saito D, Ono H.** Routine coagulation of visible vessels may prevent delayed bleeding after endoscopic submucosal dissection--an analysis of risk factors. *Endoscopy* 2008; 40: 179-183 [PMID: 18322872 DOI: 10.1055/s-2007-995530]
- 6 **Okada K, Yamamoto Y, Kasuga A, Omae M, Kubota M, Hirasawa T, Ishiyama A, Chino A, Tsuchida T, Fujisaki J, Nakajima A, Hoshino E, Igarashi M.** Risk factors for delayed bleeding after endoscopic submucosal dissection for gastric neoplasm. *Surg Endosc* 2011; 25: 98-107 [PMID: 20549245 DOI: 10.1007/s00464-010-1137-4]
- 7 **Fujimoto K, Fujishiro M, Kato M, Higuchi K, Iwakiri R, Sakamoto C, Uchiyama S, Kashiwagi A, Ogawa H, Murakami K, Mine T, Yoshino J, Kinoshita Y, Ichinose M, Matsui T; Japan Gastroenterological Endoscopy Society.** Guidelines for gastroenterological endoscopy in patients undergoing antithrombotic treatment. *Dig Endosc* 2014; 26: 1-14 [PMID: 24215155]
- 8 **Ono S, Fujishiro M, Kodashima S, Takahashi Y, Minatsuki C, Mikami-Matsuda R, Asada-Hirayama I, Konno-Shimizu M, Tsuji Y, Mochizuki S, Niimi K, Yamamichi N, Kaneko M, Yatomi Y, Koike K.** Evaluation of safety of endoscopic biopsy without cessation of antithrombotic agents in Japan. *J Gastroenterol* 2012; 47: 770-774 [PMID: 22350697 DOI: 10.1007/s00535-012-0538-7]
- 9 **Iwatsuka K, Gotoda T, Kusano C, Fukuzawa M, Sugimoto K, Itoi T, Kawai T, Moriyasu F.** Clinical management of esophagogastroduodenoscopy by clinicians under the former guidelines of the Japan Gastroenterological Endoscopy Society for patients taking anticoagulant and antiplatelet medications. *Gastric Cancer* 2014; 17: 680-685 [PMID: 24399493 DOI: 10.1007/s10120-013-0333-z]
- 10 **Fujita M, Shiotani A, Murao T, Ishii M, Yamanaka Y, Nakato R, Matsumoto H, Tarumi K, Manabe N, Kamada T, Hata J, Haruma K.** Safety of gastrointestinal endoscopic biopsy in patients taking antithrombotics. *Dig Endosc* 2015; 27: 25-29 [PMID: 24766557 DOI: 10.1111/den.12303]
- 11 **Koh R, Hirasawa K, Yahara S, Oka H, Sugimori K, Morimoto M, Numata K, Kokawa A, Sasaki T, Nozawa A, Taguri M, Morita S, Maeda S, Tanaka K.** Antithrombotic drugs are risk factors for

- delayed postoperative bleeding after endoscopic submucosal dissection for gastric neoplasms. *Gastrointest Endosc* 2013; **78**: 476-483 [PMID: 23622974 DOI: 10.1016/j.gie.2013.03.008]
- 12 **Matsumura T**, Arai M, Maruoka D, Okimoto K, Minemura S, Ishigami H, Saito K, Nakagawa T, Katsuno T, Yokosuka O. Risk factors for early and delayed post-operative bleeding after endoscopic submucosal dissection of gastric neoplasms, including patients with continued use of antithrombotic agents. *BMC Gastroenterol* 2014; **14**: 172 [PMID: 25280756 DOI: 10.1186/1471-230X-14-172]
  - 13 **Yoshio T**, Nishida T, Kawai N, Yuguchi K, Yamada T, Yabuta T, Komori M, Yamaguchi S, Kitamura S, Iijima H, Tsutsui S, Michida T, Mita E, Tsujii M, Takehara T. Gastric ESD under Heparin Replacement at High-Risk Patients of Thromboembolism Is Technically Feasible but Has a High Risk of Delayed Bleeding: Osaka University ESD Study Group. *Gastroenterol Res Pract* 2013; **2013**: 365830 [PMID: 23843783 DOI: 10.1155/2013/365830]
  - 14 **Shindo Y**, Matsumoto S, Miyatani H, Yoshida Y, Mashima H. Risk factors for postoperative bleeding after gastric endoscopic submucosal dissection in patients under antithrombotics. *World J Gastrointest Endosc* 2016; **8**: 349-356 [PMID: 27076874 DOI: 10.4253/wjge.v8.i7.349]
  - 15 **Douketis JD**, Spyropoulos AC, Kaatz S, Becker RC, Caprini JA, Dunn AS, Garcia DA, Jacobson A, Jaffer AK, Kong DF, Schulman S, Turpie AG, Hasselblad V, Ortel TL; BRIDGE Investigators. Perioperative Bridging Anticoagulation in Patients with Atrial Fibrillation. *N Engl J Med* 2015; **373**: 823-833 [PMID: 26095867 DOI: 10.1056/NEJMoa1501035]
  - 16 **Garcia DA**, Regan S, Henault LE, Upadhyay A, Baker J, Othman M, Hylek EM. Risk of thromboembolism with short-term interruption of warfarin therapy. *Arch Intern Med* 2008; **168**: 63-69 [PMID: 18195197 DOI: 10.1001/archinternmed.2007.23]
  - 17 **Blacker DJ**, Wijdicks EF, McClelland RL. Stroke risk in anticoagulated patients with atrial fibrillation undergoing endoscopy. *Neurology* 2003; **61**: 964-968 [PMID: 14557569]
  - 18 **Maulaz AB**, Bezerra DC, Michel P, Bogousslavsky J. Effect of discontinuing aspirin therapy on the risk of brain ischemic stroke. *Arch Neurol* 2005; **62**: 1217-1220 [PMID: 16087761 DOI: 10.1001/archneur.62.8.1217]
  - 19 **Japanese Gastric Cancer Association**. Japanese gastric cancer treatment guidelines 2010 (ver. 3). *Gastric Cancer* 2011; **14**: 113-123 [PMID: 21573742 DOI: 10.1007/s10120-011-0042-4]
  - 20 **Japanese Gastric Cancer Association**. Japanese gastric cancer treatment guidelines 2014 (ver. 4). *Gastric Cancer* 2017; **20**: 1-19 [PMID: 27342689 DOI: 10.1007/s10120-016-0622-4]
  - 21 **Japanese Gastric Cancer Association**. Japanese Classification of Gastric Carcinoma - 2nd English Edition -. *Gastric Cancer* 1998; **1**: 10-24 [PMID: 11957040]
  - 22 **Hirasawa K**, Kokawa A, Oka H, Yahara S, Sasaki T, Nozawa A, Morimoto M, Numata K, Taguri M, Morita S, Maeda S, Tanaka K. Risk assessment chart for curability of early gastric cancer with endoscopic submucosal dissection. *Gastrointest Endosc* 2011; **74**: 1268-1275 [PMID: 22015001 DOI: 10.1016/j.gie.2011.07.067]
  - 23 **Kannel WB**, Hjortland MC, McNamara PM, Gordon T. Menopause and risk of cardiovascular disease: the Framingham study. *Ann Intern Med* 1976; **85**: 447-452 [PMID: 970770]
  - 24 **Yusuf S**, Hawken S, Ounpuu S, Dans T, Avezum A, Lanas F, McQueen M, Budaj A, Pais P, Varigos J, Lisheng L; INTERHEART Study Investigators. Effect of potentially modifiable risk factors associated with myocardial infarction in 52 countries (the INTERHEART study): case-control study. *Lancet* 2004; **364**: 937-952 [PMID: 15364185 DOI: 10.1016/S0140-6736(04)17018-9]
  - 25 **Michel P**, Odier C, Rutgers M, Reichhart M, Maeder P, Meuli R, Wintermark M, Maghraoui A, Faouzi M, Croquelois A, Ntaios G. The Acute STroke Registry and Analysis of Lausanne (ASTRAL): design and baseline analysis of an ischemic stroke registry including acute multimodal imaging. *Stroke* 2010; **41**: 2491-2498 [PMID: 20930152 DOI: 10.1161/STROKEAHA.110.596189]
  - 26 **Takeuchi T**, Ota K, Harada S, Edogawa S, Kojima Y, Tokioka S, Umegaki E, Higuchi K. The postoperative bleeding rate and its risk factors in patients on antithrombotic therapy who undergo gastric endoscopic submucosal dissection. *BMC Gastroenterol* 2013; **13**: 136 [PMID: 24010587 DOI: 10.1186/1471-230X-13-136]
  - 27 **Tounou S**, Morita Y, Hosono T, Harada H, Hayasaka K, Katsuyama Y, Suehiro S, Nagano S, Shimizu T. Endoscopic submucosal dissection for early gastric cancer without interruption of warfarin and aspirin. *Endosc Int Open* 2015; **3**: E307-E310 [PMID: 26357675 DOI: 10.1055/s-0034-1392018]
  - 28 **Toyoda K**, Yasaka M, Iwade K, Nagata K, Koretsune Y, Sakamoto T, Uchiyama S, Gotoh J, Nagao T, Yamamoto M, Takahashi JC, Minematsu K; Bleeding with Antithrombotic Therapy (BAT) Study Group. Dual antithrombotic therapy increases severe bleeding events in patients with stroke and cardiovascular disease: a prospective, multicenter, observational study. *Stroke* 2008; **39**: 1740-1745 [PMID: 18388341 DOI: 10.1161/STROKEAHA.107.504993]
  - 29 **Hallas J**, Dall M, Andries A, Andersen BS, Aalykke C, Hansen JM, Andersen M, Lassen AT. Use of single and combined antithrombotic therapy and risk of serious upper gastrointestinal bleeding: population based case-control study. *BMJ* 2006; **333**: 726 [PMID: 16984924 DOI: 10.1136/bmj.38947.697558.AE]
  - 30 **Nikolsky E**, Stone GW, Kirtane AJ, Dangas GD, Lansky AJ, McLaurin B, Lincoff AM, Feit F, Moses JW, Fahy M, Manoukian SV, White HD, Ohman EM, Bertrand ME, Cox DA, Mehran R. Gastrointestinal bleeding in patients with acute coronary syndromes: incidence, predictors, and clinical implications: analysis from the ACUITY (Acute Catheterization and Urgent Intervention Triage Strategy) trial. *J Am Coll Cardiol* 2009; **54**: 1293-1302 [PMID: 19778672 DOI: 10.1016/j.jacc.2009.07.019]
  - 31 **ASGE Standards of Practice Committee**, Acosta RD, Abraham NS, Chandrasekhara V, Chathadi KV, Early DS, Eloubeidi MA, Evans JA, Faulx AL, Fisher DA, Fonkalsrud L, Hwang JH, Khashab MA, Lightdale JR, Muthusamy VR, Pasha SF, Saltzman JR, Shaikat A, Shergill AK, Wang A, Cash BD, DeWitt JM. The management of antithrombotic agents for patients undergoing GI endoscopy. *Gastrointest Endosc* 2016; **83**: 3-16 [PMID: 26621548 DOI: 10.1016/j.gie.2015.09.035]
  - 32 **European Atrial Fibrillation Trial Study Group**. Optimal oral anticoagulant therapy in patients with nonrheumatic atrial fibrillation and recent cerebral ischemia. *N Engl J Med* 1995; **333**: 5-10 [PMID: 7776995]
  - 33 **Siegal D**, Yudin J, Kaatz S, Douketis JD, Lim W, Spyropoulos AC. Periprocedural heparin bridging in patients receiving vitamin K antagonists: systematic review and meta-analysis of bleeding and thromboembolic rates. *Circulation* 2012; **126**: 1630-1639 [PMID: 22912386 DOI: 10.1161/CIRCULATIONAHA.112.105221]
  - 34 **Li HK**, Chen FC, Rea RF, Asirvatham SJ, Powell BD, Friedman PA, Shen WK, Brady PA, Bradley DJ, Lee HC, Hodge DO, Slusser JP, Hayes DL, Cha YM. No increased bleeding events with continuation of oral anticoagulation therapy for patients undergoing cardiac device procedure. *Pacing Clin Electrophysiol* 2011; **34**: 868-874 [PMID: 21410724 DOI: 10.1111/j.1540-8159.2011.03049.x]
  - 35 **Tsuji Y**, Fujishiro M, Kodashima S, Ono S, Niimi K, Mochizuki S, Asada-Hirayama I, Matsuda R, Minatsuki C, Nakayama C, Takahashi Y, Sakaguchi Y, Yamamichi N, Koike K. Polyglycolic acid sheets and fibrin glue decrease the risk of bleeding after endoscopic submucosal dissection of gastric neoplasms (with video). *Gastrointest Endosc* 2015; **81**: 906-912 [PMID: 25440679 DOI: 10.1016/j.gie.2014.08.028]
  - 36 **Fukuda H**, Yamaguchi N, Isomoto H, Matsushima K, Minami H, Akazawa Y, Ohnita K, Takeshima F, Shikuwa S, Nakao K. Polyglycolic Acid Felt Sealing Method for Prevention of Bleeding Related to Endoscopic Submucosal Dissection in Patients Taking Antithrombotic Agents. *Gastroenterol Res Pract* 2016; **2016**: 1457357 [PMID: 27022390 DOI: 10.1155/2016/1457357]
  - 37 **Tan ES**, Wang H, Lua GW, Liu F, Shi XG, Li ZS. Fibrin Glue Spray as a Simple and Promising Method to Prevent Bleeding after Gastric Endoscopic Submucosal Dissection. *Dig Surg* 2016; **33**:



- 455-461 [PMID: 27220883 DOI: 10.1159/000446252]
- 38 **Mochizuki S**, Uedo N, Oda I, Kaneko K, Yamamoto Y, Yamashina T, Suzuki H, Kodashima S, Yano T, Yamamichi N, Goto O, Shimamoto T, Fujishiro M, Koike K; SAFE Trial Study Group. Scheduled second-look endoscopy is not recommended after endoscopic submucosal dissection for gastric neoplasms (the SAFE trial): a multicentre prospective randomised controlled non-inferiority trial. *Gut* 2015; **64**: 397-405 [PMID: 25301853 DOI: 10.1136/gutjnl-2014-307552]
- 39 **Tano S**, Horiki N, Omata F, Tanaka K, Hamada Y, Katsurahara M, Ninomiya K, Nishikawa K, Nojiri K, Yamada R, Inoue H, Gabazza EC, Katayama N, Takei Y. Second and third-look endoscopy for the prevention of post-ESD bleeding. *Medicine* (Baltimore) 2015; **94**: e491 [PMID: 25674738 DOI: 10.1097/MD.0000000000000491]

**P- Reviewer:** Arigami T, Kadayifci A **S- Editor:** Ma YJ  
**L- Editor:** A **E- Editor:** Zhang FF



## Retrospective Study

# Serous pancreatic neoplasia, data and review

Christoph F Dietrich, Yi Dong, Christian Jenssen, Valentina Ciaravino, Michael Hocke, Wen-Ping Wang, Eike Burmester, Kathleen Moeller, Nathan SS Atkinson, Paola Capelli, Mirko D'Onofrio

Christoph F Dietrich, Medizinische Klinik 2, Caritas-Krankenhaus Bad Mergentheim, 97980 Bad Mergentheim, Germany

Christoph F Dietrich, Ultrasound Department, First Affiliated Hospital of Zhengzhou University, Zhengzhou 450052, Henan Province, China

Yi Dong, Wen-Ping Wang, Department of Ultrasound, Zhongshan Hospital, Fudan University, Shanghai 200032, China

Christian Jenssen, Department of Internal Medicine, Krankenhaus Märkisch Oderland Strausberg/Wriezen, 15344 Strausberg, Germany

Valentina Ciaravino, Department of Radiology, G.B. Rossi University Hospital, University of Verona, 37129 Verona, Italy

Michael Hocke, Department of Internal Medicine 2, Helios Hospital Meiningen GmbH, 98617 Meiningen, Germany

Eike Burmester, Department of Internal Medicine I, Sana Kliniken, 23560 Luebeck, Germany

Kathleen Moeller, Sana Klinikum Lichtenberg, 10365 Berlin, Germany

Nathan SS Atkinson, Translational Gastroenterology Unit, Oxford University Hospitals NHS Foundation Trust, Oxford OX3 9DU, United Kingdom

Paola Capelli, Department of Pathology, G.B. Rossi University Hospital, University of Verona, 37134 Verona, Italy

Mirko D'Onofrio, Department of Radiology, GB Rossi University Hospital, University of Verona, 37134 Verona, Italy

**Author contributions:** Dietrich CF is accepting full responsibility for the conduct of the study, he and all others had access to the data, all had control of the decision to publish; all authors planning the study, conducting the study, collecting and/or interpreting data, drafting the manuscript, and critical revision of the manuscript for important intellectual content Statistical analysis; each author made a statement that they approved the final draft

submitted.

**Conflict-of-interest statement:** No potential conflicts of interest relevant to this article were reported.

**Data sharing statement:** Each author gives permission to the graphic designers to alter the visual aspect of figures, tables, or graphs.

**Open-Access:** This article is an open-access article which was selected by an in-house editor and fully peer-reviewed by external reviewers. It is distributed in accordance with the Creative Commons Attribution Non Commercial (CC BY-NC 4.0) license, which permits others to distribute, remix, adapt, build upon this work non-commercially, and license their derivative works on different terms, provided the original work is properly cited and the use is non-commercial. See: <http://creativecommons.org/licenses/by-nc/4.0/>

**Manuscript source:** Invited manuscript

**Correspondence to:** Christoph F Dietrich, MD, PhD, MBA, Professor of Medicine, Chief, Medizinische Klinik 2, Caritas-Krankenhaus Bad Mergentheim, Uhlandstr 7, 97980 Bad Mergentheim, Germany. [christoph.dietrich@ckbm.de](mailto:christoph.dietrich@ckbm.de)  
Telephone: +49-7931-582201  
Fax: 49-7931-582290

**Received:** March 5, 2017

**Peer-review started:** March 7, 2017

**First decision:** April 11, 2017

**Revised:** June 8, 2017

**Accepted:** July 22, 2017

**Article in press:** July 24, 2017

**Published online:** August 14, 2017

## Abstract

### AIM

To describe the imaging features of serous neoplasms of the pancreas using ultrasound, endoscopic ultrasound, computed tomography and magnetic resonance imaging.

## METHODS

This multicenter international collaboration enhances a literature review to date, reporting features of 287 histologically confirmed cases of serous pancreatic cystic neoplasms (SPNs).

## RESULTS

Female predominance is seen with most SPNs presenting asymptotically in the 5<sup>th</sup> through 7<sup>th</sup> decade. Mean lesion size was 38.7 mm, 98% were single, 44.2% cystic, 46% mixed cystic and solid, and 94% hypoechoic on B-mode ultrasound. Vascular patterns and contrast-enhancement profiles are described as hypervascular and hyperenhancing.

## CONCLUSION

The described ultrasound features can aid differentiation of SPN from other neoplastic lesions under most circumstances.

**Key words:** Guideline; Cancer; Ultrasound; Endoscopic ultrasound; Elastography

© The Author(s) 2017. Published by Baishideng Publishing Group Inc. All rights reserved.

**Core tip:** Serous pancreatic cystic neoplasms are infrequent neoplasms of the pancreas. Ultrasound features including single cystic or mixed cystic and solid hypoechoic lesions, hypervascular and hyperenhancing profiles as described can aid differentiation from other neoplastic lesions under most circumstances.

Dietrich CF, Dong Y, Jenssen C, Ciaravino V, Hocke M, Wang WP, Burmester E, Möller K, Atkinson NSS, Capelli P, D'Onofrio M. Serous pancreatic neoplasia, data and review. *World J Gastroenterol* 2017; 23(30): 5567-5578 Available from: URL: <http://www.wjgnet.com/1007-9327/full/v23/i30/5567.htm> DOI: <http://dx.doi.org/10.3748/wjg.v23.i30.5567>

## INTRODUCTION

Pancreatic ductal adenocarcinoma (PDAC) is the most common malignancy of the pancreas, accounting for about 90% of malignant pancreatic neoplasms. The most important imaging diagnosis to differentiate from PDAC are neuroendocrine tumours<sup>[1,2]</sup>. Most pancreatic cystic neoplasms are mucin producing including intraductal pancreatic mucinous neoplasia (IPMN) and mucinous cystic neoplasia (MCN)<sup>[3]</sup>. Other important pancreatic lesions to differentiate include metastases (e.g., of renal cell cancer), lymphoma and ectopic spleen. Comparatively less is known about serous pancreatic neoplasia (SPN) which is a rare (less than 1%-2% of pancreatic neoplasia) and predominantly cystic appearing tumor of the pancreas. Critically SPN is considered benign in comparison to the majority of

other common cystic tumors and all solid tumors of the pancreas. SPN has been previously termed serous pancreatic cystic neoplasia and serous pancreatic cystadenoma<sup>[4]</sup>. Approximately 75% of SPNs are found in women at an average age of 50-60 years, however SPN may also be found in much younger patients<sup>[5]</sup>. Typically located in the body-tail of the pancreas and solitary, the majority are detected incidentally<sup>[4,6-8]</sup>. In the largest series published to date ( $n = 2622$ ), 61% of patients were asymptomatic and 27% reported non-specific abdominal complaints, whilst only 9% presented with pancreatobiliary symptoms, and 9% with other symptoms<sup>[5]</sup>.

Histopathologically, SPNs are cyst-forming epithelial neoplasms composed of cuboidal, glycogen-rich, epithelial cells, without cellular atypia. The cyst content is defined as "clear watery". SPNs lack the genetic alterations typical of PDAC, pancreatic neuroendocrine tumors, and mucinous cystic neoplasms of the pancreas (MCN and IPMN). Rather, they are characterized by molecular alterations of the von-Hippel-Lindau (VHL) gene and overexpression of vascular endothelial factor (VEGF), glucose transporter 1, and other markers of clear-cell tumorigenesis (HIF1- $\alpha$ , CAIX)<sup>[9]</sup>. VHL patients have a high prevalence of pancreatic lesions (unclassified benign cysts, neuroendocrine tumors, SPNs) and often multiple tumors in the gland. A systematic review found SPN in 11% of VHL patients<sup>[10]</sup>. However, the majority of SPNs are sporadic.

Most serous neoplasms are benign and defined as serous cystadenomas (SCAs). More aggressive subtypes occur, demonstrated in a series of 257 resected SCAs; 5.1% of SPNs were locally aggressive, with invasion of surrounding structures or vasculature or direct extension into peripancreatic lymph nodes, while 0.8% were frankly malignant, given the presence of metastases<sup>[5]</sup>. Another series of 193 SPNs reported infiltration of adjacent organs and structures in 3% of cases, but called into question the term "malignancy" for cases of very large SPNs<sup>[11]</sup>. Rare cases of synchronous or metachronous hepatic SPNs may represent multifocal occurrence rather than metastatic spread<sup>[9]</sup>. Frankly malignant behavior with metastases seems to be very rare. In a multinational study of 2622 patients with SPNs, only 3 serous cystadenocarcinomas (SCACs) were recorded (0.1%)<sup>[8]</sup>. Therefore, SCAC is represented predominantly by a few sporadic case reports in the recent literature. Follow-up studies have not demonstrated proof of an adenoma-carcinoma sequence in SPN<sup>[8,9,11-15]</sup>.

The growth rate of SPNs is variably reported. In the largest series ( $n = 2622$ ) it was found to be only 4 mm/year, and size was stable or decreased in as many as 63% of patients<sup>[8]</sup>. This was supported by another series ( $n = 214$ ), where the doubling time was estimated at approximately 12 years, and was independent of tumour size<sup>[14]</sup>. In contrast, in another case series ( $n = 106$ ) growth rate was reported to vary by tumor

size, with the fastest growth (20 mm/year) observed in tumors  $\geq 40$  mm, compared to tumors  $< 40$  mm (increasing 12 mm/year)<sup>[16]</sup>. Finally, a fourth series ( $n = 145$ ) found the fastest growth 7-10 years after diagnosis (60 mm/year) compared to the first 7 years (10 mm/year). Oligocystic or macrocystic appearance, a history of other tumors, and patient age were all significant predictors of more rapid tumor growth<sup>[13]</sup>.

Diagnosis of SPN primarily is based on imaging [computed tomography (CT); magnetic resonance imaging (MRI); ultrasound (US); endoscopic ultrasound (EUS)]. The classical microcystic SPN consists of innumerable very small cysts separated by thin, vessel-containing fibrous septae. Cysts may be microscopic or measure up to 10 mm. These features cause a honeycomb or sponge-like appearance with hypervascularity and distinct, sometimes lobulated, margins. Pertinent negatives include communication with the pancreatic duct, vascularized mural nodules, and a hypervascular capsule on contrast-enhanced imaging, whilst a central scar is visible in a third of cases and may contain calcifications<sup>[17-25]</sup>. Pitfalls may arise from several factors: the macro- and oligo-cystic types of SPN can appear similar to pseudocysts or MCN. Rarely the solid form of SPN may be confused with other hypervascular well-circumscribed pancreatic tumors, in particular neuroendocrine tumors and solid pseudopapillary neoplasms<sup>[18,19,26-28]</sup>. In contrast to the mentioned reports, an atypical appearance on CT was found in 61.1% of cases in a study of 72 confirmed SPNs<sup>[28]</sup>.

A correct diagnosis of SPN is challenging. The pre-operative diagnosis was wrong in 63% of resected cases in a Japanese series<sup>[12]</sup>, and in a large multinational study the indication for surgery was an uncertainty of diagnosis in 60% of cases<sup>[8]</sup>. To date, no large series describing typical and atypical US- and EUS-features of SPNs has been reported.

The aim of this retrospective study was to describe the imaging features of serous neoplasms of the pancreas using US, EUS, CT and MRI. The frequency of atypical imaging aspects by different imaging modalities will be estimated and the most common atypical features will be reported, particularly of US which is often the initial imaging modality employed.

## MATERIALS AND METHODS

### Patients

An international multicenter retrospective data collection of 287 histologically confirmed cases of SPNs was performed. The cohort was not uniform according to the resection criteria. No other exclusion criteria have been defined.

### Examination technique

Conventional ultrasound and contrast enhanced ultrasound (CEUS) were performed in all patients with one of six ultrasound systems: Philips iU22 unit (Philips

Bothell, WA, United States; C5-1 convex array probes, 1-5 MHz), or LOGIQ E9 (GE Healthcare, Milwaukee, WI, United States; C1-5 convex array probes, 1-5 MHz) or Hitachi (Hi vision EUB-6500, Preirus, Ascendus; C715 convex array probes, 1-5 MHz), or SIEMENS (Acuson Sequoia or S2000), or Toshiba (Aplio platinum 500; Aplio CV, convex array probes 3-6 MHz). CEUS was performed using contrast harmonic real-time imaging at a low MI 0.05-0.30. The ultrasound contrast agent Sonovue was used at a dose of 1.5-2.4 mL, immediately followed by an injection of 10 mL sodium chloride solution. Images were recorded for 3 min after contrast agent injection.

Contrast enhanced EUS was performed using longitudinal echoendoscopes EG-3870 UTK and Hitachi platforms (Hitachi HI vision EUB-6500, Hitachi Preirus, Hitachi Ascendus)<sup>[29-32]</sup>.

### Imaging Evaluation (TUS, EUS, CEUS, ceEUS)

After identification of the pancreatic lesion by conventional B-mode US or EUS, contrast enhanced imaging was immediately performed. All examinations were interpreted according to the 2011 EFSUMB guidelines<sup>[1]</sup>. CEUS features of pancreatic lesions were compared to the surrounding normal pancreatic parenchyma.

### Final diagnoses, treatment and clinical follow up

Most patients ( $n = 249$ , 86.7%) were diagnosed as SPNs by post-operative histopathology. 31 (10.8%) cases were confirmed by EUS FNA and 7 (2.5%) by transabdominal (percutaneous) ultrasound-guided core needle biopsy (18-gauge 20-cm single-use biopsy needles; Temno, Germany, or BioPince, Pflugbeil, Germany). Clinical follow-up for a minimum of 12 mo was established for all patients with SPN diagnosed by biopsy. Additional information on outcome data was not requested.

### Statistical analysis

Statistical analyses were performed using SPSS Statistics 17.0 (SPSS Inc., Chicago, IL, United States). The  $\chi^2$  test and Fisher's exact test were used to compare categorical parameters between the groups. Continuous parameters were presented as the mean  $\pm$  SD, and Student's *t* test was used. A *P* value of less than 0.05 was considered statistically significant.

## RESULTS

### Epidemiology

The average age of included patients was  $57.3 \pm 14.2$  years (18-85 years). Fifty-eight patients were male and 229 were female (Table 1).

### Conventional ultrasound

On conventional B mode ultrasound (BMUS) most SPN lesions ( $n = 113$ , 39.3%) were detected in the head/neck of the pancreas. Most SPN lesions (97.9%) were



**Table 1** Baseline characteristics of serous pancreatic neoplasia patients

Characteristic	SPN patients (n = 287)
Age (yr)	
mean ± SD	57.3 ± 14.2
Range	18-85
Female/Male	229/58
Symptoms	
Pancreatitis	5
Weight loss	9
Anemia	1
Incidental finding	272
Histological results	
Surgery	249
EUS FNA (22G)	31
TUS-Bx (18 G)	7

SPN: Serous pancreatic neoplasia; EUS: Endoscopic ultrasound; FNA: Fine needle aspiration; TUS-Bx: Transabdominal biopsy.

**Table 2** Conventional B mode ultrasound findings of serous pancreatic neoplasia n (%)

Characteristic	SPN lesions (n = 287)
Location	
Head/neck	113 (39.3)
Body	89 (31.0)
Tail	85 (29.6)
Size of lesions (mm)	
mean ± SD	38.7 ± 26.2
Range	4-160
Number of lesions	
Single	281 (97.9)
Multiple	6 (2.1)
B mode aspect	
Microcystic mix	31 (10.8)
Macrocytic	96 (33.4)
Solid and cystic	133 (46.3)
Solid	27 (9.4)
B mode echogenicity	
Anechoic	10 (3.4)
Hypoechoic	271 (94.4)
Hyperechoic	6 (2.2)
CDI vessel detectable	
Avascular	228 (79.4)
Macrovasculature detectable	59 (20.6)
CDI vascular pattern (n = 59 with macrovasculature)	
Central artery	26 (44.1)
Typical spoke wheel appearance	21 (35.6)
No specifics	12 (20.3)

SPN: Serous pancreatic neoplasia; CDI: Color Doppler imaging.

single, though 6 (2.1%) patients had multiple lesions, and most lesions (97.9%) were hypoechoic on BMUS. With colour Doppler imaging (CDI), macrovessels were detected in 20.6% of lesions, among which the typical "spoke wheel" appearance was identified in 35.6% of lesions (Table 2).

### CEUS

Transabdominal CEUS was performed in 173 (60.3%) lesions. After contrast agent injection, most SPN lesions displayed hyper- (36.5%) or iso-enhancement

**Table 3** Contrast enhanced ultrasound imaging features of serous pancreatic neoplasia lesions n (%)

Characteristic	SPN lesions (n = 173)
Arterial phase	
Hyperenhancement	63 (36.5)
Isoenhancement	107 (61.8)
Hypo-enhancement	3 (1.7)
Late phase	
Hyperenhancement	39 (22.5)
Isoenhancement	129 (74.6)
Hypo-enhancement	5 (2.9)

CEUS: Contrast enhanced ultrasound; SPN: Serous pancreatic neoplasia.

(61.8%) in the arterial phase. During the late phase, most SPN lesions were hyper-enhancing (22.5%) or iso-enhancing (74.9%) (Table 3).

### EUS and contrast enhanced EUS

EUS was performed in 61 patients diagnosed with SPN. Using CDI, macrovessels were detected in all 61 cases. Contrast enhanced endoscopic ultrasound (CE-EUS) was performed in 54 SPN lesions, demonstrating hyper-enhancement in all cases (Table 4).

## DISCUSSION

SPNs are less frequent than common pancreatic tumors such as solid ductal adenocarcinoma and cystic IPMN but recent estimates suggest SCAs represent about 20% of all cystic pancreatic lesions<sup>[33,34]</sup>. SPN typically present as a solitary multilocular microcystic lesion with a honeycomb architecture due to the presence of multiple microcysts. Thin walls and multiple thin septa orient toward the centre/scar of the lesion, without communication with the main pancreatic duct. In typical cases an imaging diagnosis can be made confidently. However, atypical presentations are commonly encountered in everyday clinical practice. Specifically, extremely microcystic SPNs are considered rare, resembling a solid lesion in conventional US, but in fact a solid component was seen in the 55.7% of cases in our multicentre study. After contrast administration, these solid SPNs may resemble hypervascular solid lesions with homogeneous hyperenhancement, making differentiation from neuroendocrine neoplasms as difficult as it is crucial<sup>[35,36]</sup>. MRI may reveal a lesion's true cystic nature<sup>[37]</sup>. The macrocystic variant must be differentiated from other macrocystic pancreatic lesions, such as pseudocyst, mucinous cystic neoplasms, side-branch and mixed type IPMNs, solid tumors (either adenocarcinomas or neuroendocrine) with cystic degeneration, and lymphangiomas<sup>[38-40]</sup>.

### Epidemiology

The mostly asymptomatic SPN is often a solitary lesion with multilocular cysts predominantly in the corpus and tail of the pancreas. SPNs are usually diagnosed

**Table 4 Endoscopic ultrasound and contrast enhanced endoscopic ultrasound imaging features of serous pancreatic neoplasia lesions *n* (%)**

Characteristic	SPN lesions ( <i>n</i> = 61)
EUS	
Anechoic	2 (3.3)
Hypoechoic	56 (91.8)
Isoechoic	3 (4.9)
EUS-CDI vessel detectable	
Avascular	0
Macrovasculs detectable	61 (100)
EUS-CDI vascular pattern ( <i>n</i> = 61)	
Central artery	26 (42.6)
Typical spoke wheel appearance	15 (24.6)
No specifics	20 (32.8)
CE-EUS ( <i>n</i> = 54)	
Hyperenhancement	54 (100)
Isoenhancement	0
Hypoenhancement	0
Final EUS-Diagnosis	
“Eyecatcher”	49 (80.3)
Typical SCA	5 (8.2)
Unclear macrocyst	6 (9.8)

EUS: Endoscopic ultrasound; EUS-CDI: Endoscopic ultrasound color Doppler Imaging; CE-EUS: Contrast enhanced endoscopic ultrasound; SPN: Serous pancreatic neoplasia; SCA: Serous cystadenoma.

in females in the 5<sup>th</sup> to 7<sup>th</sup> decade (female to male ratio 2-3:1) but with improved imaging methods the neoplasia may be diagnosed much earlier<sup>[3]</sup>. Multiple lesions, including involvement of the entire organ, have been observed in patients with Von Hippel-Lindau disease<sup>[6,7,10,23]</sup>. SPNs may present up to 20% of cystic pancreatic lesions<sup>[3,33,41]</sup>.

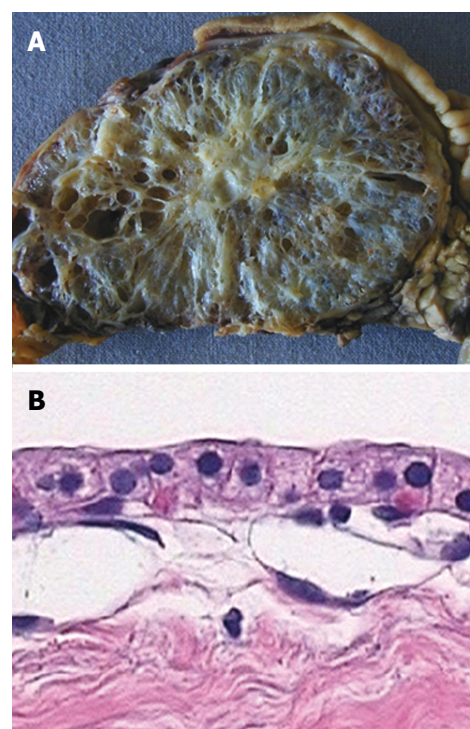
### Clinical symptoms

Sporadic and benign SPNs are most often an incidental finding without symptoms; jaundice is particularly uncommon. In our series only 5.2% of SPNs presented with symptoms. During the course of the disease, symptoms may be caused by growth of the lesion. The main pancreatic duct and or common bile duct may become entrapped in the lesion, especially if large in dimension. The reported growth rate has been estimated at 4 mm per year<sup>[39]</sup>.

### Pathology

The solitary well demarcated and multicystic SPN is a multilobular cyst forming epithelial neoplasia with a somewhat “honeycomb” architecture (Figure 1) without communication with the pancreatic duct.

Histologically, monostratified cuboidal, glycogen rich epithelial cells typically without mitoses are observed. Centrally located fibrous tissue (a so called “scar”) with or without calcifications can be found, similar to focal nodular hyperplasia of the liver; therefore the lesion has been referred to as “FNH of the pancreas”<sup>[4]</sup>. SPNs are typically hypervascular lesions, where septa are characterized by abundant subepithelial micro- and macro-vessels<sup>[6,7]</sup>.



**Figure 1 Macro- and micro-pathology (histology, cytology) of microcystic pancreatic adenoma.** A: Typical microcystic appearance of serous cystadenoma with “honeycomb” architecture, and central scar with small calcification; B: Histology demonstrates the typical single layer of clear cuboidal epithelial cells lining the cysts.

### Size of single cysts

According to the size of the cysts, SPNs can be classified as real solid lesions (< 5%), pseudo-solid SPNs (cysts only detectable by microscopic evaluation), microcystic (< 10 mm), oligocystic (< 20 mm), and macrocystic appearance (30%)<sup>[4,6,7,42,43]</sup>. The cystic appearance can be described by thin multiple septa oriented toward the center of the lesion. Mixed forms (microcystic and macrocystic) are typical in large SPNs. Macrocystic giant SPNs are more commonly located in the pancreatic head, and a male preponderance was observed. The macrocystic variant may be indistinguishable from other macrocystic tumors of the pancreas<sup>[44]</sup>.

### Malignant transformation

SPN is typically a benign neoplasia but in a series of 257 resected SPNs, local expansion (5.1%) and malignant transformation with metastases (0.8%) have been described<sup>[5]</sup>. Therefore, follow-up is recommended by means of ultrasound or MRI. Surgical treatment is recommended only for symptomatic patients or patients with growing lesions, usually larger than 4 cm<sup>[16]</sup>.

### Imaging

**Ultrasound:** Sonographically, SPN is a typically lobular cyst forming isoechoic neoplasia with centrally oriented thin walls (thin septae) without communication with the main pancreatic duct. A central hypoechoic spot (central fibrovascular scar) is characteristic<sup>[3,45-47]</sup>. In

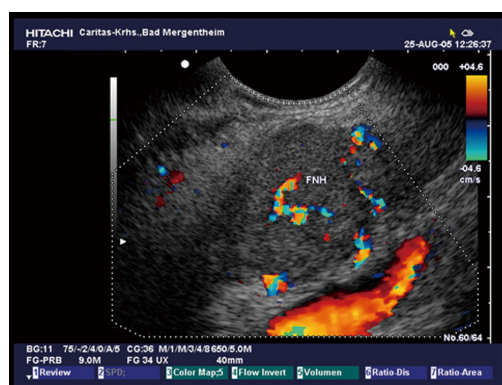


Figure 2 Typical microcystic serous pancreatic neoplasia using colour Doppler imaging. Note the centrally located artery.

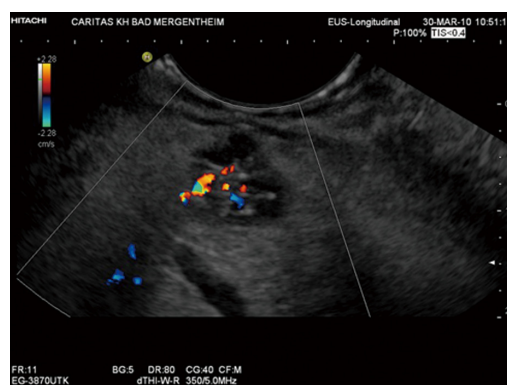


Figure 4 Typical oligocystic serous pancreatic neoplasia using endoscopic ultrasound.

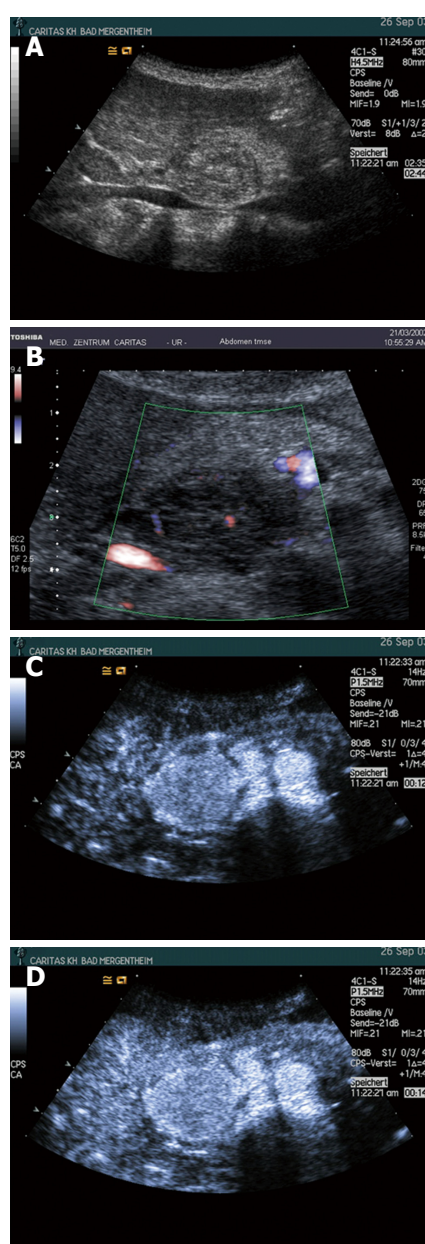


Figure 3 Typical microcystic serous pancreatic neoplasia using B-mode (A), colour Doppler imaging (B), and contrast enhanced ultrasound (C and D). Note the centrally located artery and the typical hyperenhancement.

the case of depictable cysts the content is anechoic. SPNs are typically hypervascular lesions since the septa are composed by abundant subepithelial micro- and macro-vessels<sup>[6,7]</sup> (Figures 2 and 3).

As has been shown in a prospective study ( $n = 12$ ) using CE-EUS, hypervascularity, sharp delineation, fibrotic strands and typical vessel architecture are the predominant features of serous microcystic adenoma<sup>[47]</sup> (Figures 4 and 5).

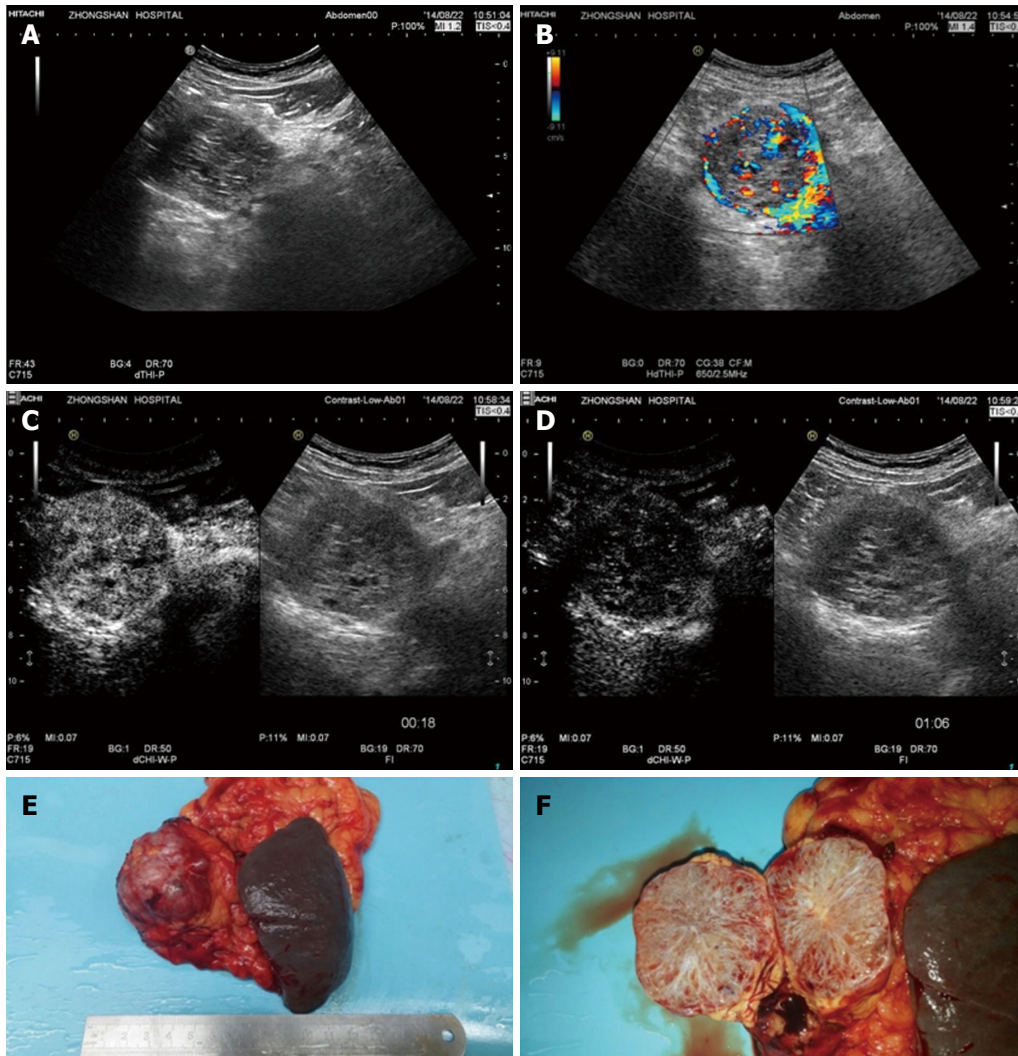
Solid SPNs may mimic neuroendocrine tumours, renal metastases, intrapancreatic accessory spleens and other hypervascular pancreatic tumours<sup>[35,36,45,48]</sup>. Solid and pseudosolid SPNs are typically hypervascular and, therefore, hyperenhancing using CEUS<sup>[45,48,49,50]</sup>.

**EUS:** EUS is an accurate imaging modality to diagnose and exclude neoplasia of the pancreas<sup>[1,51-53]</sup>. The features are the same as described for conventional ultrasound<sup>[54]</sup>. SPN do not communicate with the main pancreatic duct but may show proximal duct dilatation due to compression, whereas IPMN usually showed distal or whole pancreatic duct dilatation<sup>[50,55]</sup>. CE-EUS has been proven to be of value for many indications<sup>[29-32,56-60]</sup>. In our study EUS was able to detect macrovessels and hypervascularity by CDI contrast-enhanced imaging in 100% of cases, whereas percutaneous US with CDI delineated macrovessels only in 20.6% of cases.

#### Endoscopic ultrasound fine needle aspiration:

Endoscopic ultrasound fine needle aspiration (EUS-FNA) of SPN should target the largest cyst for fluid analysis<sup>[61,62]</sup>. The cyst fluid is watery (non-viscous) and colorless<sup>[63]</sup>. The cellularity is low with few cuboidal glycogen positive and mucin negative epithelial cells. CEA levels are usually but not always low ( $< 20$  ng/mL). In the majority of cases, aspirated fluid will be hypocellular with few groups of bland cuboidal epithelial cells embedded in granular debris<sup>[64-67]</sup>. Round to cuboid serous epithelial cells with clear cytoplasm and small, round nuclei forming loose clusters or monolayered sheets are identified in only 20%-25% of cases<sup>[64,66,68]</sup>. Positive  $\alpha$ -inhibin immunocytochemistry





**Figure 5** Histopathologically proven serous microcystic serous pancreatic neoplasia. A: A solid-cystic lesion was detected in the head of pancreas with B-mode ultrasound; B: Multiple interlesional color flow signals were detected using colour Doppler imaging; C: Contrast enhanced ultrasound showed the lesion to hyperenhance in the arterial phase; D: Isoenhance in the late phase; E and F: Surgical pathology shows the typical honeycomb structure.

may enhance the diagnostic accuracy of EUS-FNA in SPN<sup>[66]</sup>. Promising cyst fluid markers with high sensitivity and specificity for SPN include VEGF-A and a molecular assay for KRAS, GNAS and VHL mutations. In one study, VEGF-A was markedly elevated in SPN when compared to pseudocysts and mucinous neoplastic cysts<sup>[69,70]</sup>. The presence of KRAS and GNAS mutations is highly specific for IPMN and is never observed in SPN, whereas VHL deletions are found in almost all SPN<sup>[69,71-74]</sup>.

**Core biopsy:** In solid and pseudosolid lesion we prefer histological evaluation which allows definite diagnosis<sup>[51,52,75]</sup>.

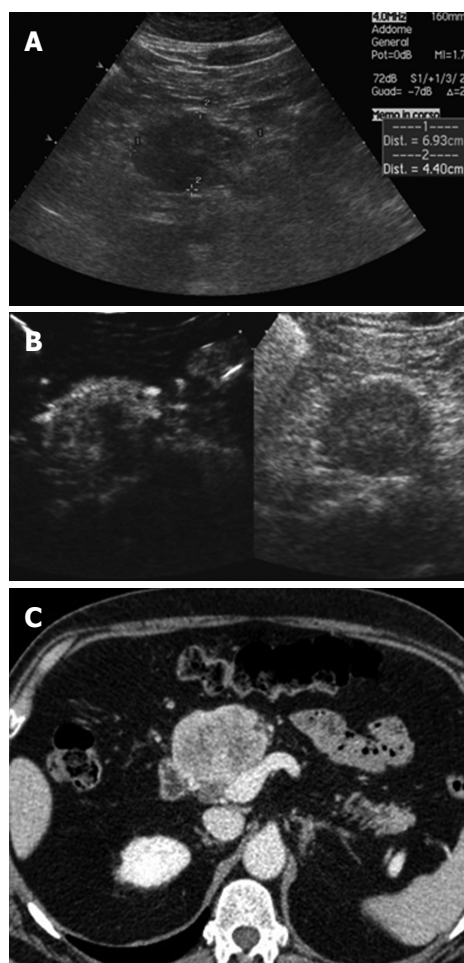
**MRI:** The MRI features of SPNs are also represented by a typical lobular “honeycomb” shaped contour and architecture with thin walls less than 2 mm, in contrast to other cystic neoplasia of the pancreas. SPNs are homogeneously hypointense on T1-weighted

MRI sequences. The cystic nature of the lesion can be easily demonstrated by a typical hyperintense signal on T2-weighted images. The hyperintense cysts are surrounded by hypointense septa and sometimes by a hypointense (pathognomonic) central scar. The central scar is a less sensitive (15%) but specific sign of SPN<sup>[39,45,76-79]</sup>.

In contrast to EUS, the individual vessels cannot be displayed but contrast enhanced MRI using gadolinium chelates also reveal the hypervascular nature by diffuse hyperenhancement in pseudosolid SPN. However also in pseudosolid SPN, MRI remains highly accurate in showing the cystic nature of the lesion on T2-weighted images<sup>[50]</sup>. The macrocystic types present features similar to other macrocystic tumors of the pancreas, but the lobulated contours, together with the absence of wall enhancement and wall thickness less than 2 mm, should suggest the correct diagnosis<sup>[39,46,76,79]</sup>.

**CT:** CT is sometimes helpful for detection of SPN but





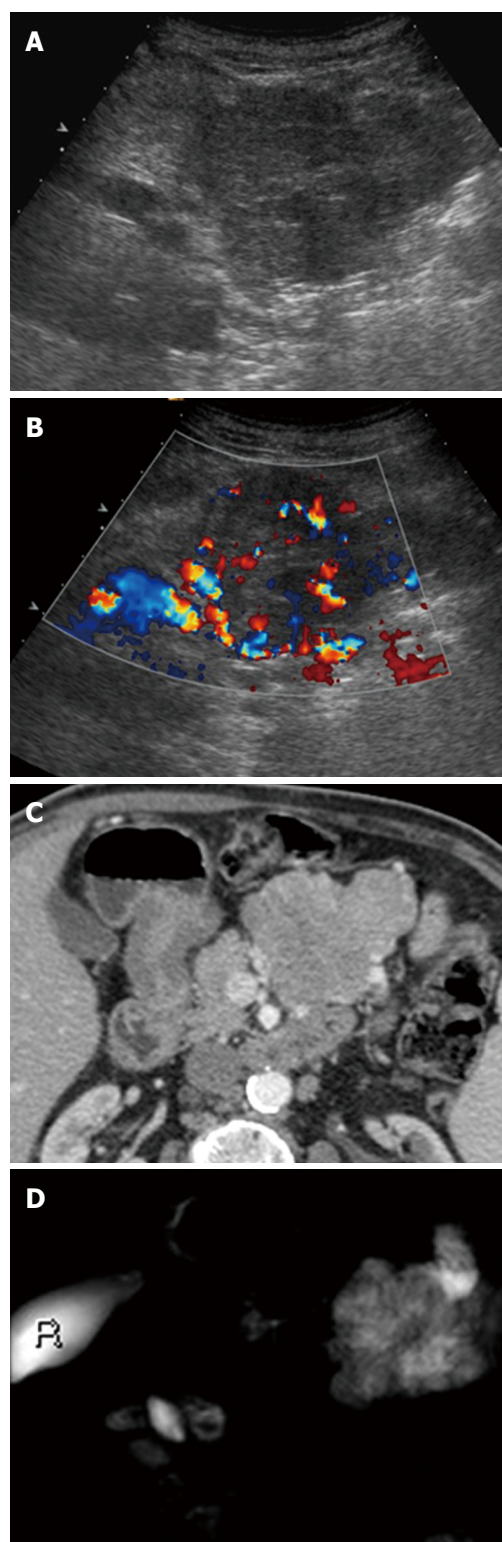
**Figure 6** Pseudo-solid serous pancreatic neoplasia, histologically demonstrated to have a microcystic structure. A: B-mode ultrasound shows a solid hypoechoic mass in the neck of the pancreas; B: Contrast enhanced ultrasound shows the lesion to hyperenhance with a hypoechoic defect in the center; C: Computed tomography shows the lesion as solid and inhomogeneously hyperenhancing.

should in general not be used for the evaluation and differential diagnosis of cystic pancreatic lesions. CT might be helpful in the visualization of a centrally located calcified scar. SPN may mimic a hypervascular lesion<sup>[17,39,46]</sup>.

### Differential diagnosis

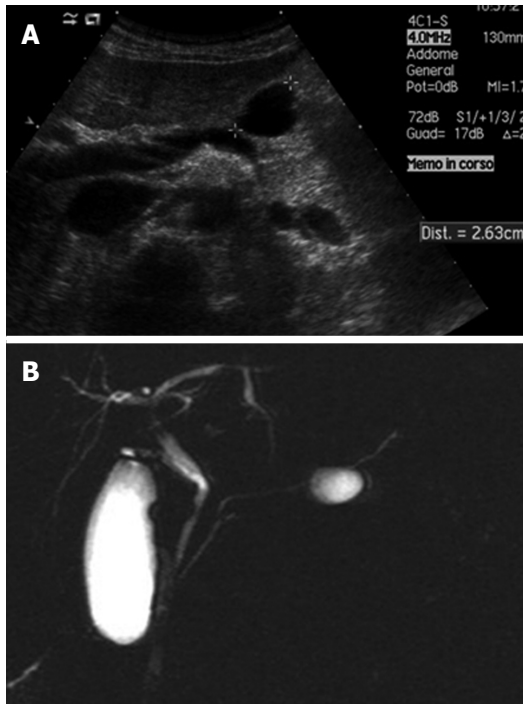
The presence of a unilocular lobulated cyst located in the pancreatic head with anechoic fluid and wall thickness less than 2 mm are indicative of SPN using all imaging methods and should be considered as a unilocular macrocystic SCA, until otherwise proven (Figures 6-8)<sup>[80]</sup>.

**Pancreatitis:** A clinical history of pancreatitis is crucial for differentiating pseudocysts. Imaging findings of pancreatitis derived pseudocysts include signs of inflammation in the acute setting, calcifications, thin-walled duct dilation, pancreaticolithiasis, and atrophy and typical dilation of the pancreatic duct<sup>[39,51,81,82]</sup>.



**Figure 7** Large pseudosolid serous pancreatic neoplasia. A: With B-mode ultrasound a huge mass is visible appearing solid and inhomogeneously hypoechoic; B: Doppler shows large arterial vessels within the mass; C: With Computed tomography the lesion appears pseudosolid with inhomogeneous slight enhancement; D: Magnetic resonance imaging clearly shows the cystic nature of the mass with microcystic appearance.

Solid SPNs are often misdiagnosed as chronic (focal) pancreatitis, which is important to know.



**Figure 8 Unilocular serous pancreatic neoplasia.** A: B-mode ultrasound shows a cyst in the body of the pancreas; B: Magnetic resonance imaging shows small cystic lesions in the body of the pancreas not communicating with the main pancreatic duct.

**IPMN:** Side branch or mixed type IPMN typically communicate with the pancreatic duct system and therefore can be differentiated from non-communicating SPN and MCN.

**MCN:** MCNs are also most common in females and they do not communicate with the pancreatic duct, but are usually located in the pancreatic tail<sup>[83]</sup>. The complex internal architecture of MCNs including septa and mural nodules can be best visualized using EUS and contrast enhanced EUS, but cMRI may be also helpful. In EUS-FNA, mucin and evaluation of the CEA level is important<sup>[39]</sup>. Peripherally located eggshell calcifications are a specific sign of MCN<sup>[84]</sup>. Other rare differential diagnoses include solid papillary neoplasia and lymphoepithelial cysts<sup>[39]</sup>.

In conclusion, serous pancreatic neoplasms are an important differential of cystic, mixed and solid pancreatic lesions, with a generally benign course. This large series of histologically proven cases demonstrates the typical demographic, structural, vascular and contrast enhancement features which can distinguish these lesions from more common pathologies.

## COMMENTS

### Background

Serous pancreatic cystic neoplasms are infrequent neoplasms of the pancreas. A correct diagnosis of pancreatic cystic neoplasms (SPNs) is challenging. To date, no large series describing typical and atypical ultrasound (US)- and endoscopic ultrasound (EUS)-features of SPNs have been reported.

### Research frontiers

The aim of this retrospective study was to describe typical and atypical imaging features of serous neoplasms of the pancreas using US, EUS, computed tomography and MRI.

### Innovations and breakthroughs

This multicenter international collaboration reports on imaging features in one of the largest series of 287 histologically confirmed cases of SPNs.

### Applications

Ultrasound B-mode descriptors and contrast enhanced ultrasound describing the vascular pattern and enhancement features are helpful to differentiate SPN from other neoplastic cystic lesions.

### Peer-review

Very interesting study about the serous pancreatic neoplasia.

## REFERENCES

- Piscaglia F**, Nolsøe C, Dietrich CF, Cosgrove DO, Gilja OH, Bachmann Nielsen M, Albrecht T, Barozzi L, Bertolotto M, Catalano O, Claudon M, Clevert DA, Correas JM, D'Onofrio M, Drudi FM, Eyding J, Giovannini M, Hocke M, Ignee A, Jung EM, Klausner AS, Lassau N, Leen E, Mathis G, Saftoiu A, Seidel G, Sidhu PS, ter Haar G, Timmerman D, Weskott HP. The EFSUMB Guidelines and Recommendations on the Clinical Practice of Contrast Enhanced Ultrasound (CEUS): update 2011 on non-hepatic applications. *Ultraschall Med* 2012; **33**: 33-59 [PMID: 21874631 DOI: 10.1055/s-0031-1281676]
- D'Onofrio M**, Barbi E, Dietrich CF, Kitano M, Numata K, Sofuni A, Principe F, Gallotti A, Zamboni GA, Mucelli RP. Pancreatic multicenter ultrasound study (PAMUS). *Eur J Radiol* 2012; **81**: 630-638 [PMID: 21466935 DOI: 10.1016/j.ejrad.2011.01.053]
- Beyer-Enke SA**, Hocke M, Ignee A, Braden B, Dietrich CF. Contrast enhanced transabdominal ultrasound in the characterisation of pancreatic lesions with cystic appearance. *JOP* 2010; **11**: 427-433 [PMID: 20818109]
- Dietrich CF**, Barreiros AP, Jenssen C. Zystische, neuroendokrine und andere seltene Pankreastumoren. In: Dietrich CF, editor. *Endosonographie*: Thieme Verlag, 2008: 287-331
- Khashab MA**, Shin EJ, Amateau S, Canto MI, Hruban RH, Fishman EK, Cameron JL, Edil BH, Wolfgang CL, Schulick RD, Giday S. Tumor size and location correlate with behavior of pancreatic serous cystic neoplasms. *Am J Gastroenterol* 2011; **106**: 1521-1526 [PMID: 21468008 DOI: 10.1038/ajg.2011.117]
- Bosmann FT**. World Health Organization, International Agency for Research on Cancer (2010) WHO classification of tumours of the digestive system. International Agency for Research on Cancer, Lyon
- Hruban RH**, Pitman MB. Armed Forces Institute of Pathology, American Registry of Pathology (2007) Tumours of the pancreas. Armed Forces Institute of Pathology, Washington, DC
- Jais B**, Rebours V, Malleo G, Salvia R, Fontana M, Maggino L, Bassi C, Manfredi R, Moran R, Lennon AM, Zaheer A, Wolfgang C, Hruban R, Marchegiani G, Fernández Del Castillo C, Brugge W, Ha Y, Kim MH, Oh D, Hirai I, Kimura W, Jang JY, Kim SW, Jung W, Kang H, Song SY, Kang CM, Lee WJ, Crippa S, Falconi M, Gomatos I, Neoptolemos J, Milanetto AC, Sperti C, Ricci C, Casadei R, Bissolati M, Balzano G, Frigerio I, Girelli R, Delhaye M, Bernier B, Wang H, Jang KT, Song DH, Huggett MT, Oppong KW, Pererva L, Kopchak KV, Del Chiaro M, Segersvard R, Lee LS, Conwell D, Osvaldt A, Campos V, Agüero Garcete G, Napoleon B, Matsumoto I, Shinzeki M, Bolado F, Fernandez JM, Keane MG, Pereira SP, Acuna IA, Vaquero EC, Angiolini MR, Zerbi A, Tang J, Leong RW, Faccineto A, Morana G, Petrone MC, Arcidiacono PG, Moon JH, Choi HJ, Gill RS, Pavey D, Ouasssi M, Sastre B, Spandre M, De Angelis CG, Rios-Vives MA, Concepcion-Martin M, Ikeura T, Okazaki K, Frulloni L, Messina O, Lévy P. Serous

- cystic neoplasm of the pancreas: a multinational study of 2622 patients under the auspices of the International Association of Pancreatology and European Pancreatic Club (European Study Group on Cystic Tumors of the Pancreas). *Gut* 2016; **65**: 305-312 [PMID: 26045140 DOI: 10.1136/gutjnl-2015-309638]
- 9 **Reid MD**, Choi H, Balci S, Akkas G, Adsay V. Serous cystic neoplasms of the pancreas: clinicopathologic and molecular characteristics. *Semin Diagn Pathol* 2014; **31**: 475-483 [PMID: 25441309 DOI: 10.1053/j.semdp.2014.08.009]
  - 10 **Charlesworth M**, Verbeke CS, Falk GA, Walsh M, Smith AM, Morris-Stiff G. Pancreatic lesions in von Hippel-Lindau disease? A systematic review and meta-synthesis of the literature. *J Gastrointest Surg* 2012; **16**: 1422-1428 [PMID: 22370733 DOI: 10.1007/s11605-012-1847-0]
  - 11 **Reid MD**, Choi HJ, Memis B, Krasinskas AM, Jang KT, Akkas G, Maithel SK, Sarmiento JM, Kooby DA, Basturk O, Adsay V. Serous Neoplasms of the Pancreas: A Clinicopathologic Analysis of 193 Cases and Literature Review With New Insights on Macrocytic and Solid Variants and Critical Reappraisal of So-called „Serous Cystadenocarcinoma“. *Am J Surg Pathol* 2015; **39**: 1597-1610 [PMID: 26559376 DOI: 10.1097/PAS.0000000000000559]
  - 12 **Kimura W**, Moriya T, Hirai I, Hanada K, Abe H, Yanagisawa A, Fukushima N, Ohike N, Shimizu M, Hatori T, Fujita N, Maguchi H, Shimizu Y, Yamao K, Sasaki T, Naito Y, Tanno S, Tobita K, Tanaka M. Multicenter study of serous cystic neoplasm of the Japan pancreas society. *Pancreas* 2012; **41**: 380-387 [PMID: 22415666 DOI: 10.1097/MPA.0b013e31822a27db]
  - 13 **Malleo G**, Bassi C, Rossini R, Manfredi R, Butturini G, Massignani M, Paini M, Pederzoli P, Salvia R. Growth pattern of serous cystic neoplasms of the pancreas: observational study with long-term magnetic resonance surveillance and recommendations for treatment. *Gut* 2012; **61**: 746-751 [PMID: 21940725 DOI: 10.1136/gutjnl-2011-300297]
  - 14 **El-Hayek KM**, Brown N, O'Rourke C, Falk G, Morris-Stiff G, Walsh RM. Rate of growth of pancreatic serous cystadenoma as an indication for resection. *Surgery* 2013; **154**: 794-800; discussion 800-802 [PMID: 24074417 DOI: 10.1016/j.surg.2013.07.005]
  - 15 **Pelaez-Luna MC**, Moctezuma-Velázquez C, Hernández-Calleros J, Uscanga-Domínguez LF. Serous Cystadenomas Follow a Benign and Asymptomatic Course and Do Not Present a Significant Size Change During Follow-Up. *Rev Invest Clin* 2015; **67**: 344-349 [PMID: 26950738]
  - 16 **Tseng JF**, Warshaw AL, Sahani DV, Lauwers GY, Rattner DW, Fernandez-del Castillo C. Serous cystadenoma of the pancreas: tumor growth rates and recommendations for treatment. *Ann Surg* 2005; **242**: 413-419; discussion 419-421 [PMID: 16135927]
  - 17 **Procacci C**, Biasiutti C, Carboognin G, Accordini S, Bicego E, Guarise A, Spoto E, Andreis IA, De Marco R, Megibow AJ. Characterization of cystic tumors of the pancreas: CT accuracy. *J Comput Assist Tomogr* 1999; **23**: 906-912 [PMID: 10589565]
  - 18 **Kim HJ**, Lee DH, Ko YT, Lim JW, Kim HC, Kim KW. CT of serous cystadenoma of the pancreas and mimicking masses. *AJR Am J Roentgenol* 2008; **190**: 406-412 [PMID: 18212226 DOI: 10.2214/AJR.07.2808]
  - 19 **Lee SE**, Kwon Y, Jang JY, Kim YH, Hwang DW, Kim MA, Kim SH, Kim SW. The morphological classification of a serous cystic tumor (SCT) of the pancreas and evaluation of the preoperative diagnostic accuracy of computed tomography. *Ann Surg Oncol* 2008; **15**: 2089-2095 [PMID: 18478300 DOI: 10.1245/s10434-008-9959-1]
  - 20 **Shah AA**, Sainani NI, Kambadakone AR, Shah ZK, Deshpande V, Hahn PF, Sahani DV. Predictive value of multi-detector computed tomography for accurate diagnosis of serous cystadenoma: radiologic-pathologic correlation. *World J Gastroenterol* 2009; **15**: 2739-2747 [PMID: 19522024 DOI: 10.3748/wjg.15.2739]
  - 21 **Chen F**, Liang JY, Zhao QY, Wang LY, Li J, Deng Z, Jiang TA. Differentiation of branch duct intraductal papillary mucinous neoplasms from serous cystadenomas of the pancreas using contrast-enhanced sonography. *J Ultrasound Med* 2014; **33**: 449-455 [PMID: 24567456 DOI: 10.7863/ultra.33.3.449]
  - 22 **Chu LC**, Singhi AD, Hruban RH, Fishman EK. Characterization of pancreatic serous cystadenoma on dual-phase multidetector computed tomography. *J Comput Assist Tomogr* 2014; **38**: 258-263 [PMID: 24632937 DOI: 10.1097/RCT.10.1097/RCT.0b013e3182ab1556]
  - 23 **Graziani R**, Mautone S, Vigo M, Manfredi R, Opocher G, Falconi M. Spectrum of magnetic resonance imaging findings in pancreatic and other abdominal manifestations of Von Hippel-Lindau disease in a series of 23 patients: a pictorial review. *JOP* 2014; **15**: 1-18 [PMID: 24413778 DOI: 10.6092/1590-8577/1757]
  - 24 **Manfredi R**, Ventriglia A, Mantovani W, Mehrabi S, Boninsegna E, Zamboni G, Salvia R, Pozzi Mucelli R. Mucinous cystic neoplasms and serous cystadenomas arising in the body-tail of the pancreas: MR imaging characterization. *Eur Radiol* 2015; **25**: 940-949 [PMID: 25417125 DOI: 10.1007/s00330-014-3493-2]
  - 25 **Jenssen C**, Kahl S. Management of Incidental Pancreatic Cystic Lesions. *Viszeralmedizin* 2015; **31**: 14-24 [PMID: 26288611 DOI: 10.1159/000375282]
  - 26 **Ishigami K**, Nishie A, Asayama Y, Ushijima Y, Takayama Y, Fujita N, Takahata S, Ohtsuka T, Ito T, Igarashi H, Ikari S, Metz CM, Honda H. Imaging pitfalls of pancreatic serous cystic neoplasm and its potential mimickers. *World J Radiol* 2014; **6**: 36-47 [PMID: 24765239 DOI: 10.4329/wjrv.6.13.36]
  - 27 **Choi JY**, Kim MJ, Lee JY, Lim JS, Chung JJ, Kim KW, Yoo HS. Typical and atypical manifestations of serous cystadenoma of the pancreas: imaging findings with pathologic correlation. *AJR Am J Roentgenol* 2009; **193**: 136-142 [PMID: 19542405 DOI: 10.2214/AJR.08.1309]
  - 28 **Sun HY**, Kim SH, Kim MA, Lee JY, Han JK, Choi BI. CT imaging spectrum of pancreatic serous tumors: based on new pathologic classification. *Eur J Radiol* 2010; **75**: e45-e55 [PMID: 20056368 DOI: 10.1016/j.ejrad.2009.11.017]
  - 29 **Dietrich CF**, Dong Y, Froehlich E, Hocke M. Dynamic contrast-enhanced endoscopic ultrasound: A quantification method. *Endosc Ultrasound* 2016; Epub ahead of print [PMID: 27824025]
  - 30 **Hocke M**, Ignee A, Dietrich C. Role of contrast-enhanced endoscopic ultrasound in lymph nodes. *Endosc Ultrasound* 2017; **6**: 4-11 [PMID: 28218194 DOI: 10.4103/2303-9027.190929]
  - 31 **Fusaroli P**, Saftoiu A, Dietrich CF. Contrast-enhanced endoscopic ultrasound: Why do we need it? A foreword. *Endosc Ultrasound* 2016; **5**: 349-350 [PMID: 27824026 DOI: 10.4103/2303-9027.193596]
  - 32 **Ignee A**, Atkinson NS, Schuessler G, Dietrich CF. Ultrasound contrast agents. *Endosc Ultrasound* 2016; **5**: 355-362 [PMID: 27824024 DOI: 10.4103/2303-9027.193594]
  - 33 **Adsay NV**. Cystic neoplasia of the pancreas: pathology and biology. *J Gastrointest Surg* 2008; **12**: 401-404 [PMID: 17957438 DOI: 10.1007/s11605-007-0348-z]
  - 34 **Adsay NV**, Klimstra DS, Compton CC. Cystic lesions of the pancreas. Introduction. *Semin Diagn Pathol* 2000; **17**: 1-6 [PMID: 10721802]
  - 35 **Braden B**, Jenssen C, D'Onofrio M, Hocke M, Will U, Möller K, Ignee A, Dong Y, Cui XW, Săftoiu A, Dietrich CF. B-mode and contrast-enhancement characteristics of small nonincidental neuroendocrine pancreatic tumors. *Endosc Ultrasound* 2017; **6**: 49-54 [PMID: 28218201 DOI: 10.4103/2303-9027.200213]
  - 36 **Dietrich CF**, Sahai AV, D'Onofrio M, Will U, Arcidiacono PG, Petrone MC, Hocke M, Braden B, Burmester E, Möller K, Săftoiu A, Ignee A, Cui XW, Iordache S, Potthoff A, Iglesias-Garcia J, Fusaroli P, Dong Y, Jenssen C. Differential diagnosis of small solid pancreatic lesions. *Gastrointest Endosc* 2016; **84**: 933-940 [PMID: 27155592 DOI: 10.1016/j.gie.2016.04.034]
  - 37 **Lu X**, Zhang S, Ma C, Peng C, Lv Y, Zou X. The diagnostic value of EUS in pancreatic cystic neoplasms compared with CT and MRI. *Endosc Ultrasound* 2015; **4**: 324-329 [PMID: 26643701 DOI: 10.4103/2303-9027.170425]
  - 38 **Sahani DV**, Kambadakone A, Macari M, Takahashi N, Chari S, Fernandez-del Castillo C. Diagnosis and management of cystic pancreatic lesions. *AJR Am J Roentgenol* 2013; **200**: 343-354 [PMID: 23345356 DOI: 10.2214/AJR.12.8862]



- 39 **Sahani DV**, Kadavigere R, Saokar A, Fernandez-del Castillo C, Brugge WR, Hahn PF. Cystic pancreatic lesions: a simple imaging-based classification system for guiding management. *Radiographics* 2005; **25**: 1471-1484 [PMID: 16284129 DOI: 10.1148/rg.256045161]
- 40 **Dong Y**, Wang WP, Mao F, Fan M, Ignee A, Serra C, Sparchez Z, Sporea I, Braden B, Dietrich CF. Contrast enhanced ultrasound features of hepatic cystadenoma and hepatic cystadenocarcinoma. *Scand J Gastroenterol* 2017; **52**: 365-372 [PMID: 27887203 DOI: 10.1080/00365521.2016.1259652]
- 41 **Del Chiaro M**, Verbeke C, Salvia R, Klöppel G, Werner J, McKay C, Friess H, Manfredi R, Van Cutsem E, Löhr M, Segersvärd R; European Study Group on Cystic Tumours of the Pancreas. European experts consensus statement on cystic tumours of the pancreas. *Dig Liver Dis* 2013; **45**: 703-711 [PMID: 23415799 DOI: 10.1016/j.dld.2013.01.010]
- 42 **Kishida Y**, Matsubayashi H, Okamura Y, Uesaka K, Sasaki K, Sawai H, Imai K, Ono H. A case of solid-type serous cystadenoma mimicking neuroendocrine tumor of the pancreas. *J Dig Dis* 2014; **15**: 211-215 [PMID: 24387314 DOI: 10.1111/1751-2980.12128]
- 43 **Perez-Ordóñez B**, Naseem A, Lieberman PH, Klimstra DS. Solid serous adenoma of the pancreas. The solid variant of serous cystadenoma? *Am J Surg Pathol* 1996; **20**: 1401-1405 [PMID: 8898845]
- 44 **Khurana B**, Mortelé KJ, Glickman J, Silverman SG, Ros PR. Macrocystic serous adenoma of the pancreas: radiologic-pathologic correlation. *AJR Am J Roentgenol* 2003; **181**: 119-123 [PMID: 12818841 DOI: 10.2214/ajr.181.1.1810119]
- 45 **Martínez-Noguera A**, D'Onofrio M. Ultrasonography of the pancreas. 1. Conventional imaging. *Abdom Imaging* 2007; **32**: 136-149 [PMID: 16897275 DOI: 10.1007/s00261-006-9079-y]
- 46 **Kim YH**, Saini S, Sahani D, Hahn PF, Mueller PR, Auh YH. Imaging diagnosis of cystic pancreatic lesions: pseudocyst versus nonpseudocyst. *Radiographics* 2005; **25**: 671-685 [PMID: 15888617 DOI: 10.1148/rg.253045104]
- 47 **Dietrich CF**, Ignee A, Braden B, Barreiros AP, Ott M, Hocke M. Improved differentiation of pancreatic tumors using contrast-enhanced endoscopic ultrasound. *Clin Gastroenterol Hepatol* 2008; **6**: 590-597.e1 [PMID: 18455699 DOI: 10.1016/j.cgh.2008.02.030]
- 48 **D'Onofrio M**, Zamboni G, Faccioli N, Capelli P, Pozzi Mucelli R. Ultrasonography of the pancreas. 4. Contrast-enhanced imaging. *Abdom Imaging* 2007; **32**: 171-181 [PMID: 16838218 DOI: 10.1007/s00261-006-9010-6]
- 49 **Dietrich CF**, Hocke M, Gallotti A, D'Onofrio M. Solid pancreatic tumors. In: D'Onofrio M, editor *Ultrasonography of the pancreas*. Berlin, Heidelberg, New York: Springer, 2012: 93-110
- 50 **Capelli P**, Martini PT, D'Onofrio M, Morana G, De Robertis R, Luchini C, Canestrini S, Gobbo S, Mucelli RP. Serous Neoplasms. In: D'Onofrio M, Capelli P, Pederzoli P, editors. *Imaging and Pathology of Pancreatic Neoplasms*. Milan Heidelberg New York: Springer: 277-310
- 51 **Dietrich CF**, Jenssen C. [Evidence based endoscopic ultrasound]. *Z Gastroenterol* 2011; **49**: 599-621 [PMID: 21544753 DOI: 10.1055/s-0029-1246021]
- 52 **Dietrich CF**, Hocke M, Jenssen C. [Interventional endosonography]. *Ultraschall Med* 2011; **32**: 8-22, quiz 23-quiz 25 [PMID: 21305436 DOI: 10.1055/s-0029-1246017]
- 53 **Hijioka S**, Hara K, Mizuno N, Imaoka H, Bhatia V, Yamao K. Morphological differentiation and follow-up of pancreatic cystic neoplasms using endoscopic ultrasound. *Endosc Ultrasound* 2015; **4**: 312-318 [PMID: 26643699 DOI: 10.4103/2303-9027.170423]
- 54 **Bounds BC**, Brugge WR. EUS diagnosis of cystic lesions of the pancreas. *Int J Gastrointest Cancer* 2001; **30**: 27-31 [PMID: 12489578 DOI: 10.1385/IJGC.30:1-2:027]
- 55 **Bhutani MS**. Role of endoscopic ultrasound for pancreatic cystic lesions: Past, present, and future! *Endosc Ultrasound* 2015; **4**: 273-275 [PMID: 26643692 DOI: 10.4103/2303-9027.170400]
- 56 **Seicean A**, Jinga M. Harmonic contrast-enhanced endoscopic ultrasound fine-needle aspiration: Fact or fiction? *Endosc Ultrasound* 2017; **6**: 31-36 [PMID: 28218198 DOI: 10.4103/2303-9027.196917]
- 57 **Serrani M**, Lisotti A, Caletti G, Fusaroli P. Role of contrast harmonic-endoscopic ultrasound in pancreatic cystic lesions. *Endosc Ultrasound* 2017; **6**: 25-30 [PMID: 28218197 DOI: 10.4103/2303-9027.190931]
- 58 **Yoo J**, Yan LH, Siddiqui AA. Can contrast harmonic endoscopic ultrasonography replace endoscopic ultrasonography-guided fine-needle aspiration in patients with solid pancreatic lesions? An American perspective. *Endosc Ultrasound* 2017; **6**: 1-3 [PMID: 28218193 DOI: 10.4103/2303-9027.190930]
- 59 **Ignee A**, Jenssen C, Cui XW, Schuessler G, Dietrich CF. Intracavitary contrast-enhanced ultrasound in abscess drainage-feasibility and clinical value. *Scand J Gastroenterol* 2016; **51**: 41-47 [PMID: 26166454 DOI: 10.3109/00365521.2015.1066423]
- 60 **Choi JH**, Seo DW. The Expanding Role of Contrast-Enhanced Endoscopic Ultrasound in Pancreatobiliary Disease. *Gut Liver* 2015; **9**: 707-713 [PMID: 26503571]
- 61 **Yoon WJ**, Brugge WR. The safety of endoscopic ultrasound-guided fine-needle aspiration of pancreatic cystic lesions. *Endosc Ultrasound* 2015; **4**: 289-292 [PMID: 26643695 DOI: 10.4103/2303-9027.170408]
- 62 **Alkaade S**, Chahla E, Levy M. Role of endoscopic ultrasound-guided fine-needle aspiration cytology, viscosity, and carcinoembryonic antigen in pancreatic cyst fluid. *Endosc Ultrasound* 2015; **4**: 299-303 [PMID: 26643697 DOI: 10.4103/2303-9027.170417]
- 63 **Al-Haddad M**. Role of emerging molecular markers in pancreatic cyst fluid. *Endosc Ultrasound* 2015; **4**: 276-283 [PMID: 26643693 DOI: 10.4103/2303-9027.170402]
- 64 **Belsley NA**, Pitman MB, Lauwers GY, Brugge WR, Deshpande V. Serous cystadenoma of the pancreas: limitations and pitfalls of endoscopic ultrasound-guided fine-needle aspiration biopsy. *Cancer* 2008; **114**: 102-110 [PMID: 18260088 DOI: 10.1002/cncr.23346]
- 65 **Collins BT**. Serous cystadenoma of the pancreas with endoscopic ultrasound fine needle aspiration biopsy and surgical correlation. *Acta Cytol* 2013; **57**: 241-251 [PMID: 23635954 DOI: 10.1159/000346911]
- 66 **Salomao M**, Remotti H, Allendorf JD, Poneros JM, Sethi A, Gonda TA, Saqi A. Fine-needle aspirations of pancreatic serous cystadenomas: improving diagnostic yield with cell blocks and  $\alpha$ -inhibin immunohistochemistry. *Cancer Cytopathol* 2014; **122**: 33-39 [PMID: 23939868 DOI: 10.1002/cncy.21347]
- 67 **Villa NA**, Berzosa M, Wallace MB, Raijman I. Endoscopic ultrasound-guided fine needle aspiration: The wet suction technique. *Endosc Ultrasound* 2016; **5**: 17-20 [PMID: 26879162 DOI: 10.4103/2303-9027.175877]
- 68 **Huang P**, Staerkel G, Sneige N, Gong Y. Fine-needle aspiration of pancreatic serous cystadenoma: cytologic features and diagnostic pitfalls. *Cancer* 2006; **108**: 239-249 [PMID: 16691573 DOI: 10.1002/cncr.21911]
- 69 **Yip-Schneider MT**, Wu H, Dumas RP, Hancock BA, Agaram N, Radovich M, Schmidt CM. Vascular endothelial growth factor, a novel and highly accurate pancreatic fluid biomarker for serous pancreatic cysts. *J Am Coll Surg* 2014; **218**: 608-617 [PMID: 24491241 DOI: 10.1016/j.jamcollsurg.2013.12.019]
- 70 **Cho MK**, Choi JH, Seo DW. Endoscopic ultrasound-guided ablation therapy for pancreatic cysts. *Endosc Ultrasound* 2015; **4**: 293-298 [PMID: 26643696 DOI: 10.4103/2303-9027.170414]
- 71 **Singhi AD**, Nikiforova MN, Fasanella KE, McGrath KM, Pai RK, Ohori NP, Bartholow TL, Brand RE, Chennat JS, Lu X, Papachristou GI, Slivka A, Zeh HJ, Zureikat AH, Lee KK, Tsung A, Mantha GS, Khalid A. Preoperative GNAS and KRAS testing in the diagnosis of pancreatic mucinous cysts. *Clin Cancer Res* 2014; **20**: 4381-4389 [PMID: 24938521 DOI: 10.1158/1078-0432.CCR-14-0513]
- 72 **Frampton AE**, Stebbing J, Gall TM, Silver B, Jiao LR, Krell J. Activating mutations of GNAS and KRAS in cystic fluid can help detect intraductal papillary mucinous neoplasms of the pancreas. *Expert Rev Mol Diagn* 2015; **15**: 325-328 [PMID: 25656048 DOI: 10.1080/14737175.2015.1066423]



- 10.1586/14737159.2015.1002771]
- 73 **Springer S**, Wang Y, Dal Molin M, Masica DL, Jiao Y, Kinde I, Blackford A, Raman SP, Wolfgang CL, Tomita T, Niknafs N, Douville C, Ptak J, Dobbys L, Allen PJ, Klimstra DS, Schattner MA, Schmidt CM, Yip-Schneider M, Cummings OW, Brand RE, Zeh HJ, Singhi AD, Scarpa A, Salvia R, Malleo G, Zamboni G, Falconi M, Jang JY, Kim SW, Kwon W, Hong SM, Song KB, Kim SC, Swan N, Murphy J, Geoghegan J, Brugge W, Fernandez-Del Castillo C, Mino-Kenudson M, Schulick R, Edil BH, Adsay V, Paulino J, van Hooft J, Yachida S, Nara S, Hiraoka N, Yamao K, Hijioka S, van der Merwe S, Goggins M, Canto MI, Ahuja N, Hirose K, Makary M, Weiss MJ, Cameron J, Pittman M, Eshleman JR, Diaz LA Jr, Papadopoulos N, Kinzler KW, Karchin R, Hruban RH, Vogelstein B, Lennon AM. A combination of molecular markers and clinical features improve the classification of pancreatic cysts. *Gastroenterology* 2015; **149**: 1501-1510 [PMID: 26253305 DOI: 10.1053/j.gastro.2015.07.041]
- 74 **Kadayifci A**, Atar M, Wang JL, Forcione DG, Casey BW, Pitman MB, Brugge WR. Value of adding GNAS testing to pancreatic cyst fluid KRAS and carcinoembryonic antigen analysis for the diagnosis of intraductal papillary mucinous neoplasms. *Dig Endosc* 2017; **29**: 111-117 [PMID: 27514845 DOI: 10.1111/den.12710]
- 75 **Adler DG**, Witt B, Chadwick B, Wells J, Taylor LJ, Dimaio C, Schmidt R. Pathologic evaluation of a new endoscopic ultrasound needle designed to obtain core tissue samples: A pilot study. *Endosc Ultrasound* 2016; **5**: 178-183 [PMID: 27386475 DOI: 10.4103/2303-9027.183976]
- 76 **Lewin M**, Hoeffel C, Azizi L, Lacombe C, Monnier-Cholley L, Raynal M, Arrivé L, Tubiana JM. [Imaging of incidental cystic lesions of the pancreas]. *J Radiol* 2008; **89**: 197-207 [PMID: 18354350]
- 77 **Box JC**, Douglas HO. Management of cystic neoplasms of the pancreas. *Am Surg* 2000; **66**: 495-501 [PMID: 10824753]
- 78 **Fernández-del Castillo C**, Warshaw AL. Current management of cystic neoplasms of the pancreas. *Adv Surg* 2000; **34**: 237-248 [PMID: 10997221]
- 79 **D'Onofrio M**, Gallotti A, Pozzi Mucelli R. Imaging techniques in pancreatic tumors. *Expert Rev Med Devices* 2010; **7**: 257-273 [PMID: 20214430 DOI: 10.1586/erd.09.67]
- 80 **Cohen-Scali F**, Vilgrain V, Brancatelli G, Hammel P, Vullierme MP, Sauvanet A, Menu Y. Discrimination of unilocular macrocystic serous cystadenoma from pancreatic pseudocyst and mucinous cystadenoma with CT: initial observations. *Radiology* 2003; **228**: 727-733 [PMID: 12954892 DOI: 10.1148/radiol.2283020973]
- 81 **Tanaka M**. Intraductal papillary mucinous neoplasm of the pancreas: diagnosis and treatment. *Pancreas* 2004; **28**: 282-288 [PMID: 15084972]
- 82 **Sugiyama M**, Atomi Y, Kuroda A. Two types of mucin-producing cystic tumors of the pancreas: diagnosis and treatment. *Surgery* 1997; **122**: 617-625 [PMID: 9308621]
- 83 **Warshaw AL**, Compton CC, Lewandrowski K, Cardenosa G, Mueller PR. Cystic tumors of the pancreas. New clinical, radiologic, and pathologic observations in 67 patients. *Ann Surg* 1990; **212**: 432-443; discussion 444-445 [PMID: 2171441]
- 84 **Loftus EV Jr**, Olivares-Pakzad BA, Batts KP, Adkins MC, Stephens DH, Sarr MG, DiMaggio EP. Intraductal papillary-mucinous tumors of the pancreas: clinicopathologic features, outcome, and nomenclature. Members of the Pancreas Clinic, and Pancreatic Surgeons of Mayo Clinic. *Gastroenterology* 1996; **110**: 1909-1918 [PMID: 8964418]

**P- Reviewer:** Lowenberg M, Reich K **S- Editor:** Qi Y **L- Editor:** A  
**E- Editor:** Zhang FF



Retrospective Study

# Pancreaticoduodenectomy for duodenal papilla carcinoma: A single-centre 9-year retrospective study of 112 patients with long-term follow-up

Pei-Long Lian, Yuan Chang, Xiu-Chun Xu, Zhen Zhao, Xian-Qiang Wang, Ke-Sen Xu

Pei-Long Lian, Zhen Zhao, Ke-Sen Xu, Department of Hepatobiliary Surgery, Qilu Hospital, Shandong University, Jinan 250012, Shandong Province, China

Yuan Chang, Department of Anesthesiology, Shandong Provincial Hospital Affiliated to Shandong University, Jinan 250021, Shandong Province, China

Xiu-Chun Xu, Department of Vascular Surgery, Binhai People's Hospital, Yancheng 224500, Jiangsu Province, China

Xian-Qiang Wang, Department of Hepatobiliary Surgery, the PLA General Hospital, Beijing 100853, China

**Author contributions:** Lian PL designed the research, analyzed the data, drafted and revised the paper; Wang XQ, Xu XC and Zhao Z performed the research; Chang Y searched the literature; Xu KS revised the paper, approved the final version.

**Institutional review board statement:** The study was reviewed and approved by the PLA General Hospital Institutional Review Board.

**Informed consent statement:** All study participants, or their legal guardian, provided informed written consent prior to study enrolment.

**Conflict-of-interest statement:** We declare that there are no conflicts of interest to disclose.

**Data sharing statement:** No additional data are available.

**Open-Access:** This article is an open-access article which was selected by an in-house editor and fully peer-reviewed by external reviewers. It is distributed in accordance with the Creative Commons Attribution Non Commercial (CC BY-NC 4.0) license, which permits others to distribute, remix, adapt, build upon this work non-commercially, and license their derivative works on different terms, provided the original work is properly cited and the use is non-commercial. See: <http://creativecommons.org/licenses/by-nc/4.0/>

Manuscript source: Unsolicited manuscript

Correspondence to: Ke-Sen Xu, PhD, Professor, Department of Hepatobiliary Surgery, Qilu Hospital, Shandong University, 107 Wenhua Road, Jinan 250012, Shandong Province, China. [xukesen0519@sdu.edu.cn](mailto:xukesen0519@sdu.edu.cn)

Telephone: +86-531-82169230

Fax: +86-531-82169243

Received: May 3, 2017

Peer-review started: May 4, 2017

First decision: June 1, 2017

Revised: June 13, 2017

Accepted: June 18, 2017

Article in press: June 19, 2017

Published online: August 14, 2017

## Abstract

### AIM

To retrospectively evaluate the factors that influence long-term outcomes of duodenal papilla carcinoma (DPC) after standard pancreaticoduodenectomy (SPD).

### METHODS

This is a single-centre, retrospective study including 112 DPC patients who had a SPD between 2006 and 2015. Associations between serum levels of CA19-9 and CEA and various clinical characteristics of 112 patients with DPC were evaluated by the  $\chi^2$  test and Fisher's exact test. The patients were followed-up every 3 mo in the first two years and at least every 6 mo afterwards, with a median follow-up of 60 mo (ranging from 4 mo to 168 mo). Survival analysis was conducted using the Kaplan-Meier survival and Cox proportional hazards model analysis. The difference in survival curves was evaluated with a log-rank test.

## RESULTS

In 112 patients undergoing SPD, serum levels of CA19-9 was associated with serum levels of CEA and drainage mode (the *P* values were 0.000 and 0.033, respectively); While serum levels of CEA was associated with serum levels of CA19-9 and differentiation of the tumour (the *P* values were 0.000 and 0.033, respectively). The serum levels of CA19-9 and CEA were closely correlated ( $\chi^2 = 13.277$ ,  $r = 0.344$ ,  $P = 0.000$ ). The overall 5-year survival was 50.00% for 112 patients undergoing SPD. The Kaplan-Meier survival analysis showed that increased serum levels of CA19-9, CEA, and total bilirubin were correlated with a poor prognosis, as well as a senior grade of infiltration depth, lymph node metastases, and TNM stage (the *P* values were 0.033, 0.018, 0.015, 0.000, 0.000 and 0.000, respectively). Only the senior grade of infiltration depth and TNM stage retained their significance when adjustments were made for other known prognostic factors in Cox multivariate analysis ( $RR = 2.211$ ,  $P = 0.022$  and  $RR = 2.109$ ,  $P = 0.047$ ).

## CONCLUSION

For patients with DPC, the serum levels of CA19-9 and CEA were closely correlated, and play an important role in poor survival. Increased serum levels of total bilirubin and lymph node metastases were also correlated with a poor prognosis. The senior grade of infiltration depth and TNM stage can serve as independent prognosis indexes in the evaluation of patients with DPC after SPD.

**Key words:** Duodenal papilla carcinoma; CA19-9; CEA; Survival; Pancreaticoduodenectomy

© The Author(s) 2017. Published by Baishideng Publishing Group Inc. All rights reserved.

**Core tip:** For duodenal papilla carcinoma (DPC), standard pancreaticoduodenectomy (SPD) is still the most important treatment. However, the prognosis assessment for DPC after SPD is not yet clear. So we conducted a long-term follow-up and observation with a large sample. Our study demonstrated that the serum levels of CA19-9 and CEA were closely correlated and played an important role in poor survival. Increased serum levels of total bilirubin and lymph node metastases were also correlated with a poor prognosis. The senior grade of infiltration depth and TNM stage can serve as independent prognosis indexes for patients with DPC after SPD.

Lian PL, Chang Y, Xu XC, Zhao Z, Wang XQ, Xu KS. Pancreaticoduodenectomy for duodenal papilla carcinoma: A single-centre 9-year retrospective study of 112 patients with long-term follow-up. *World J Gastroenterol* 2017; 23(30): 5579-5588 Available from: URL: <http://www.wjgnet.com/1007-9327/full/v23/i30/5579.htm> DOI: <http://dx.doi.org/10.3748/wjg.v23.i30.5579>

## INTRODUCTION

The incidence rate of primary duodenal papilla carcinoma (DPC) is low, only accounting for 0.01% of malignant tumours and accounting for 5% of gastrointestinal malignant tumours<sup>[1]</sup>. It has been reported in the literature that among malignant tumours primarily occurring in the duodenum, 60% are diagnosed as DPC<sup>[2]</sup>, and the incidence rate of DPC in periampullary carcinoma is the highest. A series of studies have demonstrated that there is a higher excision rate and better prognosis of DPC than other malignant tumours around the duodenal ampulla, and the survival rate within 5 years after the operation is in the range of 50%-60%<sup>[3]</sup>.

For DPC, Standard pancreaticoduodenectomy (SPD) is still the most important treatment mode<sup>[4-6]</sup>. Based on a large number of studies, there are still many disputes concerning the prognosis assessment for primary DPC after SPD, and there is lack of long-term follow-up and observation of a large sample.

Therefore, the main objective of this study was to review and report our own single-centre data of 112 patients with DPC at the PLA General Hospital between 2006 and 2015 to evaluate factors influencing outcome after radical SPD surgery.

## MATERIALS AND METHODS

### General data

A total of 112 patients with DPC who received SPD in the PLA General Hospital from August 2006 to November 2015 were enrolled. In this study, all patients were confirmed as DPC according to postoperative pathological examinations. There were 74 males and 38 females, with a median age of 57.95 years. The disease course was 0.13-15 years.

This study only enrolled patients who received SPD due to DPC. The following patients were not enrolled: patients who had received radiotherapy and chemotherapy before the operation; patients who received endoscopic local excision of benign tumours of the duodenum; patients who could not tolerate SPD because of body conditions; and patients with complicated malignant tumours at other sites.

All patients and/or a family member signed a written informed consent form, in which the nature of the diseases, possible therapeutic methods and postoperative potential complications were detailed. This study was approved by the ethics committee of the PLA General Hospital and was performed in accordance with the ethical standards specified in the 1964 Declaration of Helsinki and its later amendments.

### Clinical manifestations and concomitant diseases

The most common clinical manifestation was jaundice; other symptoms included body weight decreases and epigastric discomfort. In addition, there were

20 patients with cholangitis symptoms such as intermittent or acute fever. Common concomitant diseases included hypertension, heart diseases and diabetes mellitus. The medical history of other patients included 5 cases of endoscopic local excision and 4 cases of choledocholithotomy.

### Preoperative evaluation

Routine blood tests were carried out for all patients before the operation, including blood routine, hepatic and renal function, biochemical indicators, blood coagulation series and tumour markers.

There were 87 patients with increased bilirubin more than 17.1  $\mu\text{mol/L}$ , of whom there were 69 patients with increased bilirubin more than 34.2  $\mu\text{mol/L}$ . Preoperative tests of tumour markers mainly included CA19-9 and CEA. There were 39 patients with CA19-9 higher than 120 U/mL, while there were only 16 patients with CEA higher than 5 ng/mL.

Preoperative routine ultrasound and CT examinations were carried out. Intrahepatic and extrahepatic bile duct extension suggested that low-level biliary obstruction was the most common manifestation on CT. Preoperative endoscopic retrograde cholangiopancreatography (ERCP) examinations were carried out for 92 patients, during which the conditions of duodenal papilla were directly observed under an endoscope, and in 64 of them, biopsy and pathological examinations were performed before the operation, which confirmed the pathological diagnosis. In 34 patients, a biliary tract prosthesis or a drainage tube was inserted during ERCP to drain bile as an active preoperative preparation measure.

### Operation procedures

SPD was carried out for all patients. During the operation, it was found that in 2 cases, there was remote lymph node metastases, which made radical SPD impossible; therefore, they were excluded. For all pancreas stumps, anastomosis of the pancreatic duct and jejunum was carried out, and the anastomosis modes were categorized into anastomosis of the pancreatic duct and jejunal mucous membrane and invaginated pancreaticoenterostomy according to the diameter of the pancreatic duct and the size of pancreas amputation stump, with 90 cases and 22 cases, respectively. Intraoperative exploration found that in 34 cases, the diameter of the main pancreatic duct was greater than 4 mm; in 78 cases, it was smaller than 4 mm. For the intraoperative anastomosis of the pancreatic duct and jejunum, one end of a support tube was placed in the main pancreatic duct, and the other end was placed inside the jejunum or outside the abdominal wall to drain liquid. According to the position of the support tube, pancreatic duct drainage modes were divided into internal drainage and external drainage, with 85 cases and 27 cases, respectively. According to the different habits of operators, the jejunum input side to the output side

anastomosis (Braun anastomosis) was added, with the position 8 cm under the gastro-intestinal anastomotic stoma. In 54 cases, Braun anastomosis was added. All operations were performed by chief physicians with rich experience.

### Postoperative complications

For all patients, conventional postoperative treatment of the pancreas was carried out. Before being transferred back to the patients' rooms, they were observed for at least one day in the intensive care unit. After the operation, 100  $\mu\text{g}$  of octreotide was subcutaneously injected three times daily in all patients for 7 continuous days. On the second day after the operation, routine blood, liver and kidney function tests were carried out; on the third day after the operation, an abdominal Colour Doppler Ultrasound examination was carried out; and 7 d after the operation, an abdominal CT examination was carried out to observe the conditions of the abdomen. Before the end of the operation, a drainage tube was placed in the pancreaticoenteric anastomosis, cholecysto-colonic anastomosis and gastrojejunostomy anastomosis, and the amount, colour and description of the draining liquid were recorded every day.

After the operation, the pancreaticoenteric drainage tube was removed when the amylase level was less than 300 U/L (less than two times the serum amylase level) inside the drainage tube, the drainage amount was less than 50 mL each day, or the drainage duration exceeded 10 d after the operation.

According to the diagnosis criteria defined by the International Study Group on Pancreatic Fistula (ISGPF)<sup>[7]</sup>, a pancreatic fistula was defined as follows: 3 or more days after the operation, the draining liquid could be measured, and the activity of amylase was 3 times higher than that of the serum amylase activity. Pancreatic fistulas consisted of three grades (Grades A, B, and C) according to the clinical events of the patients' hospitalizations. Grade A pancreatic fistulas required no change from the normal clinical approach, did not delay discharge, and usually could be resolved through the removal of the retained operation drainage tube. Grade B pancreatic fistulas required a change of treatment strategy or adjustment of the clinical approach (for instance, fasting, total parenteral nutrition support, or the addition of antibiotics or somatostatin), delayed discharge, or needed readmission for treatment after discharge. If, according to the patients' pathogenetic conditions, invasive procedures were needed, the grade of the pancreatic fistula was upgraded to Grade C. Grade C pancreatic fistulas required a significant change of the treatment strategy or adjustment of the clinical approach; if clinical symptoms were aggravated and there were complications, such as sepsis and organ dysfunction, exploration through reoperation might be needed. Grade C pancreatic fistulas were often accompanied by complications, leading to an increased probability of



postoperative death.

A biliary fistula was diagnosed if there was persistent secretion of bilirubin-rich drainage fluid of more than 50 mL per day or if secretion continued after the 10<sup>th</sup> postoperative day<sup>[8]</sup>.

Postoperative bleeding was defined as the need for more than 2 units of red blood cells more than 2.4 h after surgery or relaparotomy for bleeding.

The nasogastric tube was removed when the drainage decreased to less than 200 mL per 24 h<sup>[8]</sup>.

Delayed gastric emptying was defined as gastric stasis requiring nasogastric intubation for 10 or more days or the inability to tolerate a regular diet on the 14<sup>th</sup> postoperative day<sup>[9]</sup>.

### Pathology

All excised specimens were examined in detail by two independent pathological experts; the contents observed included the nature of the tumours, size, infiltration depth, peripheral bile duct, nerves and pancreatic tissue infiltration, lymph node metastases, conditions of the tissue incisional margin (including common bile duct incisional margin, pancreas incisional margin, portal vein and mesenteric blood vessels incisional margin, stomach and jejunum incisional margin), tumour staging, etc. The TNM stage was done according to the UICC standard, version 7<sup>[10]</sup>.

According to the measurement of postoperative gross specimens, there were 36 cases with a diameter greater than 2 cm and 76 cases with a diameter smaller than 2 cm. In 24 patients, lymph node metastases were positive after the operation, and in 88 patients lymph node metastases were negative. The range of lymph node metastases included pancreas peripheral lymph nodes (10 cases), duodenum peripheral lymph nodes (8 cases), common bile duct peripheral lymph nodes (4 cases), and superior mesenteric lymph nodes (2 cases).

According to the infiltration depth of tumours into the duodenum wall, tumours involved the superficial muscular layer (14 cases), deep muscular layer or full-thickness (34 cases). While for tumours penetrating the intestinal wall and infiltrating the peripheral tissues, the peripheral tissues that were mainly involved included pancreas (35 cases), the bile duct (24 cases), nerves (5 cases), etc.

### Follow up

Telephone and outpatient follow-ups were performed. The patients were followed-up every 3 mo in the first two years and at least every 6 mo afterwards, with a median follow-up of 60 mo (ranging from 4 mo to 168 mo). When necessary, re-examinations by CT and MRI were carried out.

### Statistical analysis

Analysis was carried out with SPSS 16.0 statistical software. Associations between serum levels of CA19-9 and CEA and various clinical characteristics of

112 patients were evaluated by the  $\chi^2$  test and Fisher's exact test. Survival analysis was conducted using the Kaplan-Meier survival and Cox proportional hazards model analysis. The difference in survival curves was evaluated with a log-rank test. A value of  $P < 0.05$  was considered to be statistically significant.

## RESULTS

### Complications after the operation

In this study, no patients died during the operation. Forty-three patients developed one or more complications after the operation, with an incidence rate of 38.39% (43/112). The most common postoperative complications included pancreatic fistula, biliary fistula, intra-abdominal bleeding, gastric emptying disorders and peritoneal cavity infection.

Twenty-one patients developed postoperative pancreatic fistula, according to the diagnosis criteria of the ISGPF. There were 9 cases of Grade A pancreatic fistulas, 8 cases of Grade B pancreatic fistulas, and 4 cases of Grade C pancreatic fistulas. We also found that anastomosis of the pancreatic duct and jejunal mucous membrane and invaginated pancreaticoenterostomy had no influence on pancreatic fistulas. However, the incidence rate of pancreatic fistulas in patients with a pancreatic duct with a diameter greater than 4 mm was significantly lower than that in patients with a pancreatic duct with a diameter smaller than 4 mm. The incidence rate of postoperative biliary fistula was 1.78% (2/112). Seven patients developed a peritoneal cavity infection and 5 patients developed gastric emptying disorders.

After the operation, 2 patients needed reoperation, with an incidence rate of 1.78% (2/112). Of them, 4 patients received another laparotomy because of pancreatic fistulas and 2 patients underwent reoperation only because of intraabdominal bleeding. One patient experienced intraabdominal massive haemorrhage because of pancreatic fistulas, and although reoperation was performed, he still died.

### Associations between serum levels of CA19-9 and CEA and various clinical characteristics

We characterized the serum levels of CA19-9 and CEA from 112 DPC patients. For serum levels of CA19-9, 73 (65.17%) were lower than 120 U/mL, defined as negative, with 39 (34.82%) positive. For serum levels of CEA, 96 (85.71%) were lower than 5 ng/mL, defined as negative, with 16 (14.29%) positive.

As in our clinical correlation studies, serum levels of CA19-9 and CEA were compared with DPC characteristics and risk factors (Table 1). The following analysis showed that serum levels of CA19-9 was associated with serum levels of CEA and drainage mode (the  $P$  values were 0.000 and 0.033, respectively); While serum levels of CEA was associated with serum levels of CA19-9 and differentiation of the tumour (the  $P$  values

**Table 1** The serum levels of CA19-9 and CEA and clinical characteristics for 112 patients with duodenal papilla carcinoma

Characteristic	No.	Serum CA19-9		<i>P</i> value	Serum CEA		<i>P</i> value
		Negative	Positive		Negative	Positive	
Gender				0.350			0.807
Male	74	46	28		63	11	
Female	38	27	11		33	5	
Age (yr)				0.621			0.699
< 60	61	41	20		53	8	
> 60	51	32	19		43	8	
Duration (yr)				0.938			0.699
< 1	54	35	19		47	7	
> 1	58	38	20		49	9	
Serum CA19-9 (U/mL)							0.000
< 120	73				69	4	
> 120	39				27	12	
Serum CEA (ng/mL)				0.000			
< 5	96	69	27				
> 5	16	4	12				
Serum total bilirubin (μmol/L)				0.105			0.526
< 34.2	43	32	11		38	5	
> 34.2	69	41	28		58	11	
Bile pre-drainage				0.945			0.933
No	78	51	27		67	11	
Yes	34	22	12		29	5	
Tumour diameter (cm)				0.820			0.934
< 2	76	49	27		65	11	
> 2	36	24	12		31	5	
Pancreatic duct diameter (mm)				0.351			0.015
< 4	78	53	25		71	7	
> 4	34	20	14		25	9	
Drainage mode				0.033			0.928
Inside	85	60	25		73	12	
Outside	27	13	14		23	4	
End-to-end invagination				0.184			0.145
No	90	56	34		75	15	
Yes	22	17	5		21	1	
Blood loss (mL)				0.786			0.059
< 400	67	43	24		54	13	
> 400	45	30	15		42	3	
Delayed emptying				0.227			0.350
No	107	71	36		91	16	
Yes	5	2	3		5	0	
Pancreatic fistula				0.874			0.166
No	91	59	32		76	15	
Yes	21	14	7		20	1	
Differentiation				0.253			0.033
Well	40	24	16		37	3	
Moderate	38	23	15		28	10	
Poor	34	26	8		31	3	
T stage				0.946			0.062
T1	14	10	4		14	0	
T2	34	22	12		31	3	
T3	35	23	12		30	5	
T4	29	18	11		21	8	
N stage				0.078			0.301
N0	88	61	27		77	11	
N1	24	12	12		19	5	
TNM stage				0.682			0.109
I A	14	10	4		14	0	
I B	27	18	9		25	2	
II A	28	20	8		24	4	
II B	14	7	7		12	2	
III							

were 0.000 and 0.033, respectively). The serum levels of CA19-9 and CEA were closely correlated ( $\chi^2 = 13.277$ ,  $r = 0.344$ ,  $P = 0.000$ ). No evidence of a significant

association was observed between alteration of serum levels of CA19-9 or CEA and other characteristics or risk factors.

### Associations between survival and various clinical characteristics

As of August 2015, we followed up all patients after the operation, with a median follow-up of 60 mo (ranging from 4 mo to 168 mo). There was a total of 52 patients with nodiseaseprogression, and of them, 48 patients lived longer than 5 years. A total of 60 patients died of this disease, with an median survival of 24.50 mo (ranging from 4 mo to 80 mo). The overall 5-year survival was 50.00% for 112 patients undergoing SPD (Figure 1A).

The Kaplan-Meier survival analysis showed that increased serum levels of CA19-9, CEA, and total bilirubin were correlated with a poor prognosis, as well as a senior grade of infiltration depth, lymph node metastases, and TNM stage (the *P* values were 0.033, 0.018, 0.015, 0.000, 0.000 and 0.000, respectively) (Tables 2 and 3, Figure 1B-F).

Only the senior grade of infiltration depth (T3/4) and TNM stage (II B/III) retained their significance when adjustments were made for other known prognostic factors in Cox multivariate analysis (*RR* = 2.211, *P* = 0.022 and *RR* = 2.109, *P* = 0.047).

## DISCUSSION

The incidence rate of DPC is low, only accounting for 5% of gastrointestinal malignant tumours<sup>[11-13]</sup>. However, because the special position of duodenal papilla, *i.e.*, it is located at the opening of pancreatic duct, early DPC may manifest as painless progressive jaundice. SPD has always been the most important treatment mode of DPC. According to the literature, it had different 5-year survival rates and factors influencing survival<sup>[14,15]</sup>. Therefore, in this study, we carried out long-term follow-up and prognosis analysis of patients with DPC who received SPD in our centre to provide a theoretical basis for prognosis improvement of the patients.

Jaundice is the most common early clinical symptom in patients with DPC, and whether treatment for jaundice should be performed before the operation is always a topic of dispute in surgery. Some scholars think that preoperative high bilirubin may inhibit hepatocyte function and induce endotoxin dys-metabolism, thereby increasing the incidence rate of postoperative complications and influences the prognosis of patients<sup>[16,17]</sup>. However, some scholars have opposing views<sup>[18,19]</sup>. In this experiment, a poor survival was found in patients with increased bilirubin more than 34.2  $\mu\text{mol/L}$ , with a 5-year survival rate of 40.6% (*P* = 0.015). Meanwhile, 34 patients who had placement of stents or drainage tubes before the operation, live longer than the other 78 patients who did not receive treatment for jaundice, with a 5-year survival rate of 55.9% vs 47.4%, although the difference was not significantly (*P* = 0.285). Based on these data, we proposed that increased bilirubin more than 34.2  $\mu\text{mol/L}$  plays a bad role in the survival of

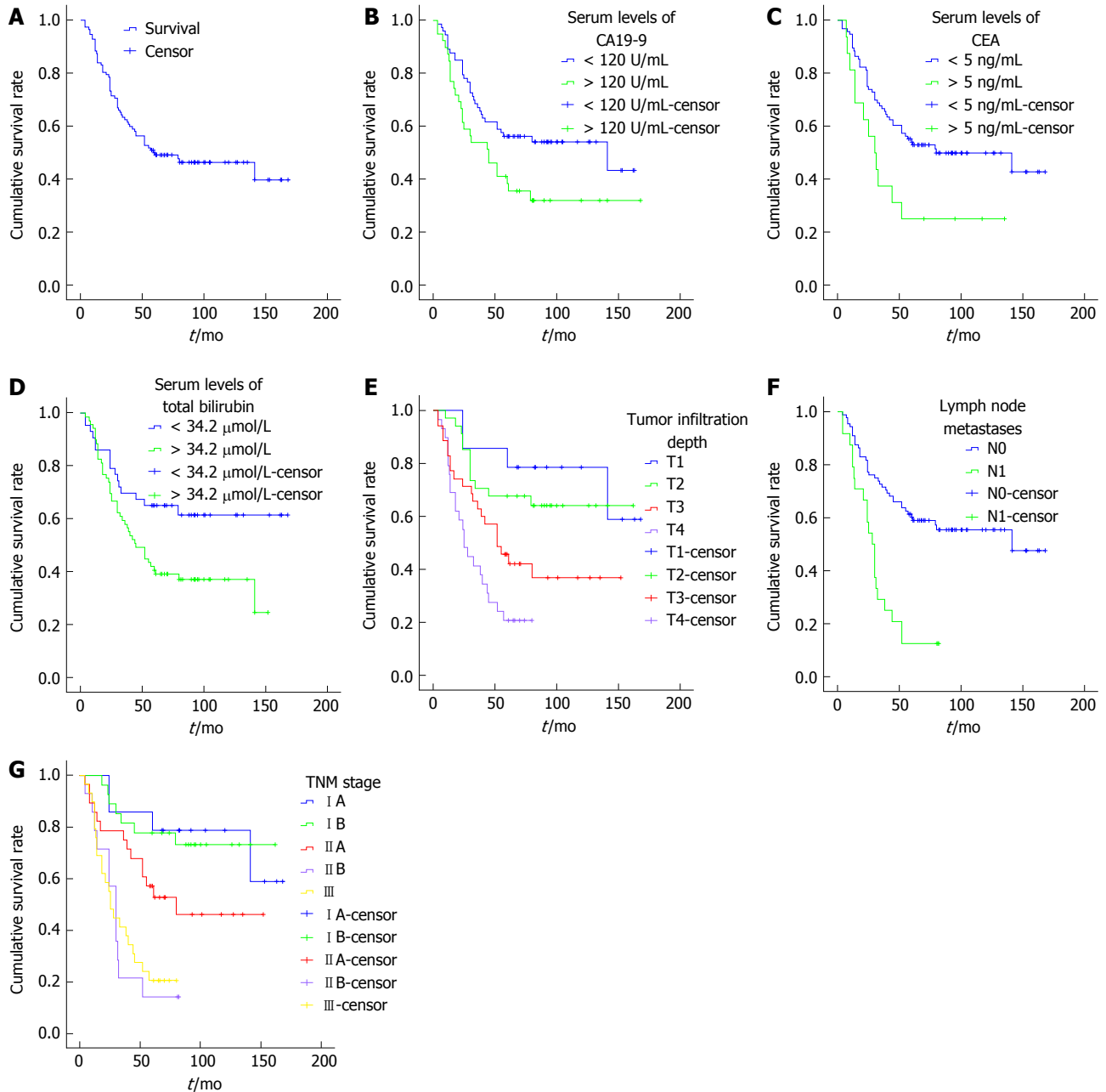
patients with DPC after SPD.

Tumour markers are mainly used for the detection of primary tumours and the differentiation of benign and malignant tumours, and they have good clinical guidance significance for the judgement of the efficacy of tumour treatment and their occurrence and prognosis of tumours. There is still a lack of specific tumour markers for DPC. In our study, serum levels of CA19-9 was associated with drainage mode (*P* = 0.033); While serum levels of CEA was associated with tumour differentiation (*P* = 0.033). Besides, the serum levels of CA19-9 and CEA were closely correlated (*r* = 0.344, *P* = 0.000). A study by Dorandeu *et al*<sup>[20]</sup> demonstrated that preoperative serum levels of CA199 and CEA were negatively related to the prognosis of patients with DPC; however, our study has opposing views. Among the 112 patients with DPC, there were 39 patients with increased serum CA19-9 and 16 patients with increased serum CEA levels. When the patients with increased levels of serum CA199 were compared with the others, the 5-year survival rates were significantly lower (38.3% vs 56.2%, *P* = 0.033). The same tendency was present in levels of serum CEA, with the 5-year survival rates of 25.0% vs 54.1% (*P* = 0.018). This indicated that the serum levels of CA19-9 and CEA are worth considering as the basis of diagnosis and prognosis for patients with DPC after SPD.

Pancreas-duodenum operations may cause great trauma, and there are many postoperative complications, of which pancreatic fistula is the most common complication<sup>[21,22]</sup>. In this study, the incidence rate of pancreatic fistula was 18.75% and was mainly Grade A and B pancreatic fistulas. However, we also found that whether there is a pancreatic fistula or not is not related with the long-term survival of patients (*P* = 0.500). In our study, we also investigated the influence of different factors on pancreatic fistulas, and our study found that anastomosis of the pancreatic duct and jejunal mucous membrane and invaginated pancreatocenterostomy had no influence on pancreatic fistulas; different pancreatic duct drainage modes and whether Braun anastomosis was added also had no influence on the occurrence of pancreatic fistulas.

When it comes to the relationship between the size of tumour and the prognosis of patients, the study by Di Giorgio *et al*<sup>[23]</sup> demonstrated that among the 64 patients who underwent SPD, the prognosis of patients with tumours with a diameter greater than 2 cm was significantly inferior to those with tumours less than 2 cm. However, the results of our study were different; there was no significant difference in prognoses between the patients with tumours with a diameter greater than 2 cm and the others, and a diameter of 2 cm is not a boundary for the difference in prognosis.

We also found that the infiltration depth of tumours is an independent factor influencing the prognosis of patients after SPD. The study by Di Giorgio *et al*<sup>[4]</sup> demonstrated that for patients who underwent SPD



**Figure 1** Kaplan-Meier plots show the association of survival and significant factors. A: The overall 5-year survival was 50.00%, with a median follow-up of 60 mo (ranging from 4 mo to 168 mo); B: Increased serum levels of CA19-9 was associated with decreased survival ( $P = 0.033$ ); C: Increased serum levels of CEA was associated with decreased survival ( $P = 0.018$ ); D: Increased serum levels of total bilirubin was associated with decreased survival ( $P = 0.015$ ); E: The senior grade of infiltration depth was associated with decreased survival ( $P = 0.000$ ), with significant difference between T1 and T3, T4 ( $P = 0.022, 0.000$ ), as well as the difference between T2 and T3, T4 ( $P = 0.036, 0.000$ ) and the difference between T3 and T4 ( $P = 0.049$ ); F: The senior grade of lymph node metastases was associated with decreased survival ( $P = 0.000$ ); G: TNM stage was associated with decreased survival ( $P = 0.000$ ), with significant difference between I A and II B, III ( $P = 0.000, 0.000$ ), as well as the difference between I B and II B, III ( $P = 0.000, 0.000$ ) and the difference between II A and II B, III ( $P = 0.006, 0.000$ ).

because of duodenal ampulla tumours, the prognosis of patients with Stage T1/2 tumours was significantly better than that of patients with Stage T3/4 tumours. Our study also demonstrated that the infiltration depth of tumours has influence on the prognosis of patients; even when adjustments were made for other known prognostic factors in Cox multivariate analysis, the senior grade of infiltration depth (T3/4) and TNM stage (II B/III) retained their significance ( $RR = 2.211, P = 0.022$  and  $RR = 2.109, P = 0.047$ ).

Whether there are lymph node metastases is an important factor influencing the prognosis of malignant tumours. The study by Klein *et al.*<sup>[24]</sup> reported that lymph node metastasis was a key factor influencing tumour recurrence and the survival of patients with ampullary carcinoma. Other studies demonstrated that the number of lymph node metastases was related to the prognosis of patients with periampullary carcinoma<sup>[25,26]</sup>. Our experiment led to the same conclusion; *i.e.*, the 5-year survival rate of patients



**Table 2** Univariate analysis comparing overall survival to prognostic factors in 112 patients with duodenal papilla carcinoma

Factors	No.	5 years survival	$\chi^2$	P value
Gender			0.561	0.454
Male	74	48.6%		
Female	38	52.4%		
Age (yr)			0.022	0.883
< 60	61	46.3%		
> 60	51	48.9%		
Duration (yr)			0.409	0.523
< 1	54	41.7%		
> 1	58	53.4%		
Serum CA19-9 (U/mL)			4.566	0.033
< 120	73	56.2%		
> 120	39	38.3%		
Serum CEA (ng/mL)			5.554	0.018
< 5	96	54.1%		
> 5	16	25.0%		
Serum total bilirubin ( $\mu$ mol/L)			5.929	0.015
< 34.2	43	65.1%		
> 34.2	69	40.6%		
Bile pre-drainage			1.144	0.285
No	78	47.4%		
Yes	34	55.9%		
Tumour diameter (cm)			0.185	0.667
< 2	76	51.3%		
> 2	36	47.2%		
Pancreatic duct diameter (mm)			0.493	0.483
< 4	78	51.2%		
> 4	34	47.1%		
Drainage mode			0.006	0.939
Inside	85	48.2%		
Outside	27	55.3%		
End-to-end invagination			0.592	0.442
No	90	48.9%		
Yes	22	54.5%		
Blood loss (mL)			0.052	0.820
< 400	67	49.2%		
> 400	45	51.1%		
Delayed emptying			0.614	0.433
No	107	50.5%		
Yes	5	40.0%		
Pancreatic fistula			0.455	0.500
No	91	47.1%		
Yes	21	57.1%		
Differentiation			3.676	0.159
Well	40	62.4%		
Moderate	38	39.5%		
Poor	34	47.1%		
Infiltration depth			22.424	0.000
T1	14	78.6%		
T2	34	67.6%		
T3	35	45.7%		
T4	29	20.7%		
Lymph metastases			21.187	0.000
N0	88	60.2%		
N1	24	12.5%		
TNM stage			35.041	0.000
I A	14	78.6%		
I B	27	77.8%		
II A	28	57.1%		
II B	14	14.3%		
III	29	20.7%		

with positive lymph node metastases was significantly lower than that of patients with negative lymph node metastases. However, lymph node metastases could not serve as an independent factor influencing the

prognosis of patients after SPD.

In conclusion, for patients with DPC, the serum levels of CA19-9 and CEA were closely correlated, and play an important role in poor survival. Increased

**Table 3** Multivariate analysis comparing overall survival to prognostic factors in 112 patients with duodenal papilla carcinoma

Factors	No.	5 years survival	Median survival (95%CI)(mo)	Relative risk (95%CI)	P value
CA19-9 (U/mL)					0.174
< 120	73	56.2%	141.0 (3.3-278.6)	1	
> 120	39	38.3%	45.0 (22.6-67.4)	1.550 (0.823-2.920)	
CEA (ng/mL)					0.528
< 5	96	54.1%	80.0 (10.4-149.5)	1	
> 5	16	25.0%	30.0 (18.2-41.8)	1.270 (0.605-2.663)	
Bilirubin (μmol/L)					0.264
< 34.2	43	65.1%		1	
> 34.2	69	40.6%	45.0 (29.9-60.1)	1.408 (0.772-2.566)	
Differentiation					0.137
Well	40	62.4%	141.0	1	
Moderate	38	39.5%	44.0 (3.09-57.1)	0.808 (0.399-1.635)	0.553
Poor	34	47.1%	52.0 (3.552-100.4)	1.636 (0.814-3.285)	0.167
Infiltration depth					0.022
T1 + T2	48	70.8%		1	
T3 + T4	64	34.4%	39.0 (26.3-51.7)	2.211 (1.119-4.367)	
lymph metastases					0.142
N0	88	60.2%	141.0	1	
N1	24	12.5%	28.0 (6.1-113.9)	1.744 (0.830-3.666)	
TNM stage					0.047
I A + I B + II A	69	69.5%		1	
II B + III	43	18.6%	28.0 (21.6-34.4)	2.109 (1.010-4.406)	

serum levels of total bilirubin and lymph node metastases were also correlated with a poor prognosis. The senior grade of infiltration depth and TNM stage can serve as independent prognosis indexes in the evaluation of patients with DPC after SPD.

## COMMENTS

### Background

For duodenal papilla carcinoma (DPC), standard pancreaticoduodenectomy (SPD) is still the most important treatment. However, the prognosis assessment for DPC after SPD is not yet clear.

### Research frontiers

Only a few researches have focused on the prognosis assessment for DPC after SPD. According to the literature, it had different 5-year survival rates and factors influencing survival.

### Innovations and breakthroughs

In this study, the authors carried out long-term follow-up and prognosis analysis of patients with DPC who received SPD in our centre to provide a theoretical basis for prognosis improvement of the patients.

### Applications

The senior grade of infiltration depth and TNM stage can serve as independent prognosis indexes in the evaluation of patients with DPC after SPD.

### Peer-review

This study is very interesting. Over all, the study was well designed, and the manuscript is well written.

## REFERENCES

- 1 DeOliveira ML, Triviño T, de Jesus Lopes Filho G. Carcinoma of the papilla of Vater: are endoscopic appearance and endoscopic biopsy discordant? *J Gastrointest Surg* 2006; **10**: 1140-1143 [PMID: 16966033 DOI: 10.1016/j.gassur.2006.05.005]
- 2 Kim MH, Lee SK, Seo DW, Won SY, Lee SS, Min YI. Tumors of the major duodenal papilla. *Gastrointest Endosc* 2001; **54**: 609-620 [PMID: 11677478 DOI: 10.1067/mge.2001.119254]
- 3 Huang W, Xiong JJ, Wan MH, Szatmary P, Bharucha S, Gomatos I, Nunes QM, Xia Q, Sutton R, Liu XB. Meta-analysis of subtotal stomach-preserving pancreaticoduodenectomy vs pylorus preserving pancreaticoduodenectomy. *World J Gastroenterol* 2015; **21**: 6361-6373 [PMID: 26034372 DOI: 10.3748/wjg.v21.i20.6361]
- 4 Di Giorgio A, Alfieri S, Rotondi F, Prete F, Di Miceli D, Ridolfini MP, Rosa F, Covino M, Doglietto GB. Pancreatoduodenectomy for tumors of Vater's ampulla: report on 94 consecutive patients. *World J Surg* 2005; **29**: 513-518 [PMID: 15776300 DOI: 10.1007/s00268-004-7498-x]
- 5 Moriya T, Kimura W, Hirai I, Mizutani M, Ma J, Kamiga M, Fuse A. Nodal involvement as an indicator of postoperative liver metastasis in carcinoma of the papilla of Vater. *J Hepatobiliary Pancreat Surg* 2006; **13**: 549-555 [PMID: 17139430 DOI: 10.1007/s00534-006-1113-5]
- 6 Winter JM, Cameron JL, Olinio K, Herman JM, de Jong MC, Hruban RH, Wolfgang CL, Eckhauser F, Edil BH, Choti MA, Schulick RD, Pawlik TM. Clinicopathologic analysis of ampullary neoplasms in 450 patients: implications for surgical strategy and long-term prognosis. *J Gastrointest Surg* 2010; **14**: 379-387 [PMID: 19911239 DOI: 10.1007/s11605-009-1080-7]
- 7 Bassi C, Dervenis C, Butturini G, Fingerhut A, Yeo C, Izbicki J, Neoptolemos J, Sarr M, Traverso W, Buchler M; International Study Group on Pancreatic Fistula Definition. Postoperative pancreatic fistula: an international study group (ISGPF) definition. *Surgery* 2005; **138**: 8-13 [PMID: 16003309 DOI: 10.1016/j.surg.2005.05.001]
- 8 Tran KT, Smeenk HG, van Eijck CH, Kazemier G, Hop WC, Greve JW, Terpstra OT, Zijlstra JA, Klinkert P, Jeekel H. Pylorus preserving pancreaticoduodenectomy versus standard Whipple procedure: a prospective, randomized, multicenter analysis of 170 patients with pancreatic and periampullary tumors. *Ann Surg* 2004; **240**: 738-745 [PMID: 15492552]
- 9 Klinkenbijnl JH, Jeekel J, Sahmoud T, van Pel R, Couvreur ML, Veenhof CH, Arnaud JP, Gonzalez DG, de Wit LT, Hennipman A, Wils J. Adjuvant radiotherapy and 5-fluorouracil after curative resection of cancer of the pancreas and periampullary region: phase III trial of the EORTC gastrointestinal tract cancer cooperative group. *Ann Surg* 1999; **230**: 776-782; discussion 782-784 [PMID: 10615932]

- 10 **Hermanek P**, Scheibe O, Spiessl B, Wagner G. [TNM classification of malignant tumors: the new 1987 edition]. *Röntgenblätter* 1987; **40**: 200 [PMID: 3616430]
- 11 **Nakase A**, Matsumoto Y, Uchida K, Honjo I. Surgical treatment of cancer of the pancreas and the periampullary region: cumulative results in 57 institutions in Japan. *Ann Surg* 1977; **185**: 52-57 [PMID: 831636]
- 12 **Yamaguchi K**, Enjoji M. Carcinoma of the ampulla of vater. A clinicopathologic study and pathologic staging of 109 cases of carcinoma and 5 cases of adenoma. *Cancer* 1987; **59**: 506-515 [PMID: 3791159]
- 13 **Gudjonsson B**. Periampullary adenocarcinoma: analysis of 5-year survivors. *Ann Surg* 1999; **230**: 736-737 [PMID: 10561100]
- 14 **Seiler CA**, Wagner M, Bachmann T, Redaelli CA, Schmied B, Uhl W, Friess H, Büchler MW. Randomized clinical trial of pylorus-preserving duodenopancreatectomy versus classical Whipple resection-long term results. *Br J Surg* 2005; **92**: 547-556 [PMID: 15800958 DOI: 10.1002/bjs.4881]
- 15 **Lin PW**, Lin YJ. Prospective randomized comparison between pylorus-preserving and standard pancreaticoduodenectomy. *Br J Surg* 1999; **86**: 603-607 [PMID: 10361177 DOI: 10.1046/j.1365-2168.1999.01074.x]
- 16 **Zhu XH**, Wu YF, Qiu YD, Jiang CP, Ding YT. Effect of early enteral combined with parenteral nutrition in patients undergoing pancreaticoduodenectomy. *World J Gastroenterol* 2013; **19**: 5889-5896 [PMID: 24124335 DOI: 10.3748/wjg.v19.i35.5889]
- 17 **Billingsley KG**, Hur K, Henderson WG, Daley J, Khuri SF, Bell RH Jr. Outcome after pancreaticoduodenectomy for periampullary cancer: an analysis from the Veterans Affairs National Surgical Quality Improvement Program. *J Gastrointest Surg* 2003; **7**: 484-491 [PMID: 12763405]
- 18 **Isla AM**, Griniatos J, Riaz A, Karvounis E, Williamson RC. Pancreaticoduodenectomy for periampullary malignancies: the effect of bile colonization on the postoperative outcome. *Langenbecks Arch Surg* 2007; **392**: 67-73 [PMID: 17089176 DOI: 10.1007/s00423-006-0102-0]
- 19 **Sewnath ME**, Birjmohun RS, Rauws EA, Huibregtse K, Obertop H, Gouma DJ. The effect of preoperative biliary drainage on postoperative complications after pancreaticoduodenectomy. *J Am Coll Surg* 2001; **192**: 726-734 [PMID: 11400966 DOI: 10.1016/S1072-7515(01)00819-5]
- 20 **Dorandeu A**, Raoul JL, Siriser F, Leclercq-Rioux N, Gosselin M, Martin ED, Ramée MP, Launois B. Carcinoma of the ampulla of Vater: prognostic factors after curative surgery: a series of 45 cases. *Gut* 1997; **40**: 350-355 [PMID: 9135524]
- 21 **Alexakis N**, Halloran C, Raraty M, Ghaneh P, Sutton R, Neoptolemos JP. Current standards of surgery for pancreatic cancer. *Br J Surg* 2004; **91**: 1410-1427 [PMID: 15499648 DOI: 10.1002/bjs.4794]
- 22 **Klaiber U**, Probst P, Knebel P, Contin P, Diener MK, Büchler MW, Hackert T. Meta-analysis of complication rates for single-loop versus dual-loop (Roux-en-Y) with isolated pancreaticojejunostomy reconstruction after pancreaticoduodenectomy. *Br J Surg* 2015; **102**: 331-340 [PMID: 25644428 DOI: 10.1002/bjs.9703]
- 23 **Di Giorgio P**, De Luca L, Calcagno G, Rivellini G, Mandato M, De Luca B. Detachable snare versus epinephrine injection in the prevention of postpolypectomy bleeding: a randomized and controlled study. *Endoscopy* 2004; **36**: 860-863 [PMID: 15452780 DOI: 10.1055/s-2004-825801]
- 24 **Klein F**, Jacob D, Bahra M, Pelzer U, Puhl G, Krannich A, Andreou A, Gül S, Guckelberger O. Prognostic factors for long-term survival in patients with ampullary carcinoma: the results of a 15-year observation period after pancreaticoduodenectomy. *HPB Surg* 2014; **2014**: 970234 [PMID: 24723741 DOI: 10.1155/2014/970234]
- 25 **Tol JA**, Brosens LA, van Dieren S, van Gulik TM, Busch OR, Besselink MG, Gouma DJ. Impact of lymph node ratio on survival in patients with pancreatic and periampullary cancer. *Br J Surg* 2015; **102**: 237-245 [PMID: 25529117 DOI: 10.1002/bjs.9709]
- 26 **Bronsart P**, Kohler I, Werner M, Makowiec F, Kuesters S, Hoepfner J, Hopt UT, Keck T, Bausch D, Wellner UF. Intestinal-type of differentiation predicts favourable overall survival: confirmatory clinicopathological analysis of 198 periampullary adenocarcinomas of pancreatic, biliary, ampullary and duodenal origin. *BMC Cancer* 2013; **13**: 428 [PMID: 24053229 DOI: 10.1186/1471-2407-13-428]

**P- Reviewer:** Araujo RLC, Lee MW **S- Editor:** Wang JL

**L- Editor:** A **E- Editor:** Zhang FF





Clinical Trials Study

## Efficacy and safety of Xiangsha Liujunzi granules for functional dyspepsia: A multi-center randomized double-blind placebo-controlled clinical study

Lin Lv, Feng-Yun Wang, Xiang-Xue Ma, Zhen-Hua Li, Sui-Ping Huang, Zhao-Hong Shi, Hai-Jie Ji, Li-Qun Bian, Bei-Hua Zhang, Ting Chen, Xiao-Lan Yin, Xu-Dong Tang

Lin Lv, Feng-Yun Wang, Xiang-Xue Ma, Zhen-Hua Li, Hai-Jie Ji, Li-Qun Bian, Bei-Hua Zhang, Ting Chen, Xiao-Lan Yin, Xu-Dong Tang, Department of Gastroenterology, Xiyuan Hospital of China Academy of Chinese Medical Sciences, Beijing 100091, China

Sui-Ping Huang, Department of Gastroenterology, Guangdong Province Traditional Chinese Medical Hospital, Guangzhou 510105, Guangdong Province, China

Zhao-Hong Shi, Department of Gastroenterology, Wuhan Integrated TCM and Western Medicine Hospital, Wuhan 430022, Hubei Province, China

**Author contributions:** Wang FY and Tang XD performed the research and drafted the manuscript; Li ZH, Huang SP and Shi ZH contributed to the development of the study protocol; Lv L contributed to the development of the study protocol and the drafting of the manuscript; Bian LQ, Zhang BH, Chen T and Yin XL recruited the participants; Ma XX and Ji HJ contributed to database management and statistical analysis; all authors approved the final version of the manuscript; Lv L took responsibility for the integrity of the work as a whole, from inception to published article.

**Supported by** the Major State Basic Research Development Program of China (973 Program), No. 2013CB531703; National Nature Science Foundation of China, No. 81503567 and No. 81673853; and the China Postdoctoral Science Foundation, No. 2015M1227 and No. 2016T90195.

**Institutional review board statement:** The study was reviewed and approved by the Ethic Committee of Xiyuan Hospital of China Academy of Chinese Medical Sciences.

**Informed consent statement:** All study participants, or their legal guardian, provided written informed consent prior to study enrollment.

**Clinical trial registration statement:** This study was registered at [www.chictr.org.cn](http://www.chictr.org.cn), and the registration identification number is ChiCTR-TRC-13003200. This study was also registered at <https://clinicaltrials.gov/>, and the registration identification number is NCT02762136.

**Conflict-of-interest statement:** The authors declare that they have no competing interests. Neither the funding agency nor any outside organization has a role in study design or manuscript preparation.

**Data sharing statement:** No additional data.

**Open-Access:** This article is an open-access article which was selected by an in-house editor and fully peer-reviewed by external reviewers. It is distributed in accordance with the Creative Commons Attribution Non Commercial (CC BY-NC 4.0) license, which permits others to distribute, remix, adapt, build upon this work non-commercially, and license their derivative works on different terms, provided the original work is properly cited and the use is non-commercial. See: <http://creativecommons.org/licenses/by-nc/4.0/>

**Manuscript source:** Unsolicited manuscript

**Correspondence to:** Xu-Dong Tang, Director, Department of Gastroenterology, Xiyuan Hospital of China Academy of Chinese Medical Sciences, No. 1, Xiyuan Caoshang, Beijing 100091, China. [txdly@sina.com](mailto:txdly@sina.com)

**Telephone:** +86-10-62835678

**Fax:** +86-10-62860397

**Received:** October 14, 2016

**Peer-review started:** October 19, 2016

**First decision:** December 2, 2016

**Revised:** May 12, 2017

**Accepted:** June 18, 2017

**Article in press:** June 19, 2017

**Published online:** August 14, 2017



## Abstract

### AIM

To assess the efficacy and safety of a Chinese herbal medicine (CHM), Xiangsha Liujunzi granules, in the treatment of patients with functional dyspepsia (FD).

### METHODS

We performed a randomized, double-blind, placebo-controlled trial with patients from three centers. Two hundred and sixteen subjects diagnosed with FD according to ROME III criteria and confirmed by upper gastrointestinal endoscopy and spleen-deficiency and Qi-stagnation syndrome were selected to receive Xiangsha Liujunzi granules or placebo for 4 wk in a 2:1 ratio by blocked randomization. The subjects also received follow-up after the 4-wk intervention. Herbal or placebo granules were dissolved in 300 mL of water. Participants in both groups were administered 130 mL (45 °C) three times a day. Participants were evaluated prior to and following 4 wk of the intervention in terms of changes in the postprandial discomfort severity scale (PDSS) score, clinical global impression (CGI) scale score, hospital anxiety and depression scale (HADS) score, traditional Chinese medicine symptoms score (SS), scores of various domains of the 36-item short form health survey (SF-36), gastric emptying (GE) and any observed adverse effects.

### RESULTS

Compared with the placebo group, patients in the CHM group showed significant improvements in the scores of PDSS, HADS, SS, SF-36 and CGI scale ( $P < 0.05$  or  $P < 0.01$ ). They also showed the amelioration in the GE rates of the proximal stomach and distal stomach ( $P < 0.05$  or  $P < 0.01$ ).

### CONCLUSION

Xiangsha Liujunzi granules offered significant symptomatic improvement in patients with FD.

**Key words:** Functional dyspepsia; Chinese herbal medicine; Xiangsha Liujunzi; Efficacy; Randomized controlled trial

© The Author(s) 2017. Published by Baishideng Publishing Group Inc. All rights reserved.

**Core tip:** Functional dyspepsia (FD) is a common clinical functional gastrointestinal disease with a very high incidence, seriously affecting the quality of life of patients. However, current chemical drugs do not achieve good curative effects. In the present study we performed a randomized, double-blind, placebo-controlled trial to assess the efficacy and safety of a Chinese herbal medicine, Xiangsha Liujunzi granules, in the treatment of patients with FD. We found that Xiangsha Liujunzi granules offered significant symptomatic improvement in patients with FD without adverse effects.

Lv L, Wang FY, Ma XX, Li ZH, Huang SP, Shi ZH, Ji HJ, Bian LQ, Zhang BH, Chen T, Yin XL, Tang XD. Efficacy and safety of Xiangsha Liujunzi granules for functional dyspepsia: A multi-center randomized double-blind placebo-controlled clinical study. *World J Gastroenterol* 2017; 23(30): 5589-5601 Available from: URL: <http://www.wjgnet.com/1007-9327/full/v23/i30/5589.htm> DOI: <http://dx.doi.org/10.3748/wjg.v23.i30.5589>

## INTRODUCTION

Functional dyspepsia (FD), one of the most frequently encountered disorders of the gastrointestinal tract, is defined as the presence of symptoms originated in the epigastrium in the absence of any systemic, organic, or metabolic disease that is likely to explain the symptoms and is characterized by symptoms of meal-induced postprandial fullness or early satiety and upper abdominal discomfort or pain<sup>[1,2]</sup>. Previous studies have reported that the prevalence of FD varies considerably among different population-based studies, with percentages ranging from 11% to 29%<sup>[3]</sup>. FD has symptoms similar to those of other conditions, including irritable bowel syndrome (IBS), peptic ulcer disease and gastroesophageal reflux. The two diagnostic categories of FD are (1) postprandial distress syndrome (PDS), which is characterized by the presence of meal-related early satiety and fullness; and (2) epigastric pain syndrome (EPS), which is characterized by the prominent symptom of epigastric pain that is generally not meal-related. However, evidence of their degree of overlap is mixed. Although its pathogenesis has not yet been fully clarified, abnormalities in gastric motor and sensory function and, more recently, low-grade duodenal inflammation have been identified<sup>[4,5]</sup>. The major pathophysiological mechanism underlying symptoms of FD is disorders of gastrointestinal motility<sup>[6]</sup>. Motility disorders lead to impaired gastric accommodation, myoelectric activity abnormalities and delayed gastric emptying (GE). Therefore, a prokinetic treatment approach is preferred in PDS. Recent evidence suggests that the subtypes of FD correlated with unhealthy dietary behaviors, especially skipping meals, eating extra meals and a preference to gas-producing food and sweet food<sup>[7]</sup>. It was recently found that the nutritional habits of FD patients are also a major factor in the production of discomfort symptoms. Carbonated drinks and fatty and spicy foods were the most common triggering food items in FD patients. Carbonated drinks and legumes were more likely to cause a symptom in PDS<sup>[8]</sup>. As the exact pathogenesis of FD has not yet been fully clarified, therapeutic drugs to relieve symptoms have thus not yet been established.

Symptomatic management of FD depends on the predominant symptoms and remains a substantial challenge. Treatment can include dietary

modifications, antiemetics, antispasmodics, prokinetics, antidepressants and analgesics, as well as proton pump inhibitors (PPIs)<sup>[9-12]</sup>. Despite the emergence of acotiamide in Japan<sup>[13]</sup>, which has given hope to some FD patients, it does not benefit more patients. Therefore, the limited effectiveness of chemical drugs and the side effects of synthetic drugs make assessments of herbal preparations an appealing prospect<sup>[14]</sup>. It is becoming increasingly difficult to ignore the role of complementary and alternative medicine in the treatment of FD. Approaches based on complementary and alternative medicine in the treatment of FD have a long history, and several modalities have been investigated with some promising results<sup>[15]</sup>. A considerable amount of literature reported that at least 44 different herbal products have been recommended alone or in combination for the treatment of dyspeptic symptoms<sup>[16]</sup>. Complementary and alternative medicine consists of traditional Persian medicine (TPM), traditional Chinese medicine (TCM) and so on. Jollab, a TPM, appeared to be more effective than the placebo in patients with FD<sup>[17]</sup>. Adjuvant supplementation of honey-based formulation of *Nigella sativa* and the association between ginger and artichoke leaf extracts can cause significant symptomatic improvement in patients with FD<sup>[18,19]</sup>. Since Liujunzi decoction was proved to be effective against FD by a randomized controlled trial for the first time, a considerable amount of literature has been published on the treatment of FD with Chinese herbal medicine (CHM)<sup>[20,21]</sup>. To date, as the good efficacy of CHM for the relief of symptoms of FD, many dyspeptic patients chose CHM. Clinically, CHM is used in combination with Western medications or alone in China. The essence of TCM is treatment based on syndrome differentiation, which is based on the different conditions of each patient. At present, the phenomenon of the same drug treatment for the same disease with the same medicine is applied. Based on TCM theory, PDS can be categorized as “stiffness and fullness”, and the most related organ is the “spleen”. A previous study has already demonstrated that the syndrome of “spleen-deficiency and Qi-stagnation” was the most common syndrome type in FD patients<sup>[22]</sup>. Based on these findings, the herbal preparation Xiangsha Liujunzi granules, a classical TCM formula, was designed and utilized in treating FD patients with “spleen-deficiency and Qi-stagnation” syndrome.

Despite ongoing clinical use, uncertainty remains regarding clinical efficacy and safety of CHM in the treatment of FD. The aim of this multicenter, double-blind, randomized placebo-controlled trial was to assess whether 4 wk of therapy with CHM was more efficacious than placebo in the relief of FD dyspeptic symptom and in improving quality of life<sup>[23]</sup>. We hoped to find strong evidence to support the use of CHM in PDS patients.

## MATERIALS AND METHODS

### Design

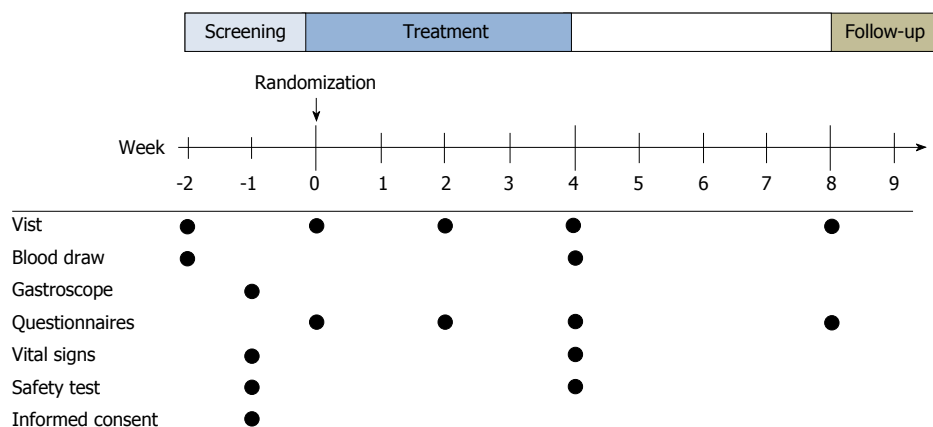
This study is a multicenter, randomized, double-blinded, placebo-controlled trial with two arms to examine the safety and efficacy of Xiangsha Liujunzi granules in the treatment of PDS patients. Participants were randomized into Xiangsha Liujunzi decoction or placebo groups in a 2:1 ratio. Since assigning an equal number of ill subjects to the ineffective placebo treatment was unethical, the 2:1 randomization plan was chosen to protect the rights of the subjects. The protocol was developed according to the Consolidated Standards of Reporting Trials statement<sup>[24]</sup>, Standard Protocol Items: Recommendations for Interventional Trials (SPIRIT) 2013<sup>[25]</sup> and SPIRIT 2013 explanation and elaboration: guidance for protocols of clinical trials<sup>[26]</sup>. The CHM group received Xiangsha Liujunzi granules, and the placebo group received a placebo. Then, all participants underwent a 4-wk treatment, followed by a 4-wk follow-up period. The study protocol was approved by the ethics committees of Xiyuan Hospital of China Academy of Chinese medical sciences, Wuhan Integrated TCM and Western Medicine Hospital, and Guangdong Province TCM Hospital, and informed consent was obtained from each participant. The study design is shown in Figure 1.

### Subjects

Subjects were recruited from outpatients of three hospitals (Xiyuan Hospital of China Academy of Chinese Medical Sciences, Guangdong Province Traditional Chinese Medical Hospital, Wuhan Integrated TCM & Western Medicine Hospital) in China, between July 2013 and July 2016. Participants were recruited through advertising media, direct calls, and health promotion events. Advertisements were put on notice boards and homepages of the hospitals and local newspapers. Patients were required to provide their medical history, receive a physical examination and laboratory safety tests, and undergo a gastroscopy. Only those who fulfilled the Rome III criteria (Table 1) and TCM Diagnostic Criteria for Distention and Fullness (Table 2) of the principle for clinical research on new drugs of TCM<sup>[27]</sup> were considered eligible subjects. The inclusion and exclusion criteria are shown in Table 3. Written informed consent was obtained from all patients prior to inclusion in the trial. Participants were free to withdraw from the study at any time.

### Randomization and blinding

The participants in the three hospitals were randomly assigned to two groups using block randomization. Random numbers based on the allocation sequence were generated using SAS (Version 9.2, Channel-leadian Pharmaceuticals R&D, Co., Ltd.; Haidian District, Beijing) by an independent statistician at the Good Clinical Practice (GCP) center of Xiyuan



**Figure 1 Study design.** There was a screening period of 2 wk before randomization. Blood draw, gastroscopy, and physical examination were performed and written informed consent were obtained from all patients in this period. Study visits were arranged at -2 wk, 0 wk, 2 wk, 4 wk and 8 wk. Some questionnaires were performed by phone during the treatment period, and this was followed by a 4-wk follow-up period.

**Table 1 Rome III diagnostic criteria for functional dyspepsia**

Functional dyspepsia	Subtype
The last 3 mo with symptom onset at least 6 mo before diagnosis, and must include: 1 One or more of: a, Bothersome postprandial fullness b, Early satiation c, Epigastric pain d, Epigastric burning AND 2 No evidence of structural disease (including at upper endoscopy) that is likely to explain the symptoms	Postprandial distress syndrome  Must include one or both of the following: 1 Bothersome postprandial fullness, occurring after ordinary sized meals, at least several times per week 2 Early satiation that prevents finishing a regular meal, at least several times per week Supportive criteria 1 Upper abdominal bloating or postprandial nausea or excessive belching can be present 2 EPS may coexist

**Table 2 Traditional Chinese medicine diagnostic criteria for stuffiness and fullness**

Spleen-deficiency and Qi-stagnation	
Primary symptoms	Abdominal distension, with obviously postprandial distress Anorexia or little appetite
Secondary symptoms	Nausea; acid reflux/heartburn; loose stools; fatigue/exhausted Fat tongue with slightly white coating Weak pulse

The diagnosis will be established when the participant conforms to all primary symptoms and any two of the secondary symptoms.

Hospital. Each randomization number was placed in a sequentially numbered opaque envelope that was sealed by the clinical research coordinator. After screening, the clinical investigator assigned the treatment according to the randomization number. Participants, clinical investigators, statisticians, and all related study staff were blinded. The blinding procedure was also verified by the authorized contract research organization. Group assignments were not revealed until the entire study was completed except in emergency situations if practical intervention was

compulsory for further management of the participant.

### Sample size

The trial was powered for superiority testing for the primary point. According to our preliminary studies, the effective rate of the Xiangsha Liujunzi decoction in treating FD was between 67% and 80%, and we estimated that the average effective rate was 70%, whereas that of the placebo for FD was approximately 45%<sup>[28]</sup>. A one-sided test yielding a 2.5% significance level was used to prove the hypothesis that Xiangsha Liujunzi granules is more effective than placebo for treating PDS. The patients were assigned to either the CHM group or the placebo group in a 2:1 ratio. The sample size was based on the superiority design as follows:

$$n_1 = \frac{[U_{\alpha}\sqrt{\pi_c(1-\pi_c)(1+c)/c} + U_{\beta}\sqrt{\pi_1(1-\pi_1) + \pi_2(1-\pi_2)/c}]^2}{(\pi_1 - \pi_2)^2}$$

$$n_2 = cn_1$$

$$n_1: \text{placebo}; n_2: \text{CHM}$$

$$\pi_c = (\pi_1 + c\pi_2)/(1+c), U_{\alpha} = 1.645, U_{\beta} = 1.985, c = 2, \pi_1 = 0.5, \pi_2 = 0.75$$

The calculation indicated that a sample size of 180 would be sufficient ( $n = 120$  in the CHM group,  $n =$

**Table 3** Inclusion and exclusion criteria

## Inclusion criteria

- 1 Age 18-70 yr, Chinese reading and writing ability
- 2 Meeting the Rome III diagnostic criteria for PDS
- 3 Having the symptom of "spleen-deficiency and Qi-stagnation", "spleen-deficiency and damp-obstruction", "spleen-Yang deficiency".
- 4 Signing the informed consent form

## Exclusion criteria

- 1 Combined with GI ulcer, erosive gastritis, atrophic gastritis, severe dysplasia of gastric mucosa or suspicious malignant lesion
- 2 Having overlap syndrome combined with gastroesophageal reflux disease or irritable bowel syndrome
- 3 Having alarm symptoms (weight loss, black or tar stool, dysphagia, *etc.*)
- 4 Having serious structural disease (disease of heart, lung, liver or kidney) or mental illness
- 5 History of surgery related with the gastrointestinal tract, except for appendectomy more than six months ago
- 6 Taking drugs which may affect the gastrointestinal tract, such as nonsteroidal anti-inflammatory drugs and aspirin
- 7 Allergy to the experimental medication
- 8 Difficulties in attending the trial (paralysis, serious mental illness, dementia, renal diseases, stroke, coronary atherosclerotic heart diseases, diabetes or mental diseases, illiteracy, *etc.*)
- 9 Pregnant or breastfeeding
- 10 Refusing to sign the informed consent form

**Table 4** Components of the Xiangsha Liujunzi granules

Scientific name	Part used	Proportion of ingredients (100%)
Astragalus mongholicus	Root	12
Codonopsis pilosula	Root	12
Rhizoma Atractylodis Macrocephalae	Rhizome	12
Poria cocos	Sclerotium	12
Fructus Aurantii	Fruit	12
Amomum villosum	Fruit	6.4
Ligusticum chuankong Hort	Sclerotium	9.6
Rhizoma corydalis	Rhizoma	9.6
Medicated Leaven	Fermentation products	12
Glycyrrhiza uralensis Fisch	Root	2.4

60 in the control group). To allow for a 20% rate of dropouts and missing data, we recruited 144 patients for the CHM group and 72 patients for the placebo group.

### Intervention

Qualified patients received a unique treatment number, which was fixed throughout the duration of the trial. The medication allocation was based on the treatment number. The composition and action of the herbal preparation of Xiangsha Liujunzi granules are summarized in Table 4. The placebo granules were made from dextrin (80%), rice (15%), bitter principle (5%) and coloring matter to ensure that the color, smell, taste and texture were similar to those of Xiangsha Liujunzi granules. Patients were informed to dissolve a sachet of granules (14 g) in 130 mL of hot water and to take the solution orally three times daily 1 h after breakfast, lunch and dinner for 4 wk. Both the herbal formula and placebo granules were manufactured by Beijing Tcmages Pharmaceutical Co., Ltd. (Shunyi District, Beijing) according to the standards of good manufacturing practice. All medications were packed identically in opaque aluminum bags with the

same labeling form except the treatment number.

### Ethical approval and registration

This trial was conducted according to the standards of the International Committee on Harmonization on GCP and the revised version of the Declaration of Helsinki. Institutional review boards at Xiyuan Hospital of China Academy of Chinese Medical Sciences, Wuhan Integrated TCM & Western Medicine Hospital, and Guangdong Province TCM Hospital approved this protocol. This trial was registered in the ChiCTR (ChiCTR-TRC-13003200, 19 April 2013) and Clinical Trials.gov (NCT02762136).

### Outcomes

**Primary outcome:** We assessed FD symptoms using the change in postprandial discomfort severity scale (PDSS) from baseline (week 0) to the treatment endpoint (week 8).

**PDSS:** Based on Rome III criteria and past clinical trials<sup>[29]</sup>, PDSS was designed to evaluate dyspeptic symptoms, including postprandial fullness, early satiety, upper abdominal pain or discomfort, and heartburn. The severity and frequency of each symptom are separately evaluated by a defined numerical score. The severity was scored as follows: 0, absent; 1, mild (awareness of symptoms but easily tolerated); 2, moderate (interference with normal activities); and 3, severe (incapacitating). The total severity score ranged from 0 to 12. The frequency scoring used the following scale: 0, absent (less than once per month); 1, rarely (less than once per week); 2, occasionally (less than three times per week); and 3, often (more than or three times per week). The total frequency score ranged from 0 to 12.

### Secondary outcomes

Changes in the clinical global impression (CGI) scale score, TCM symptom score (SS), MOS 36-Item Short-



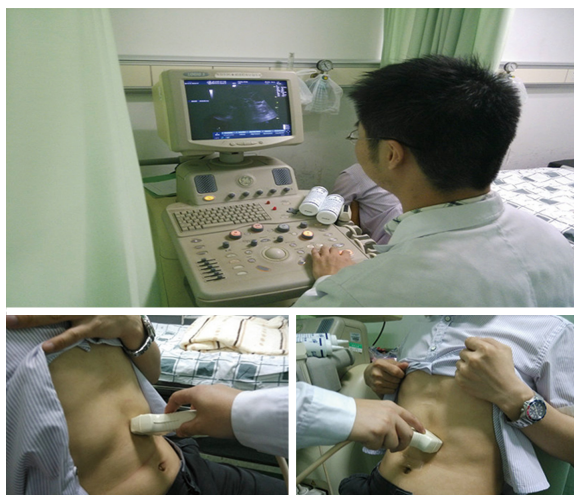

Figure 2 Gastric ultrasonography.

Form Health Survey (SF-36) score, hospital anxiety and depression scale (HADS) score, and GE were considered secondary outcomes.

**CGI scale:** The CGI scale<sup>[30]</sup> comprises two parts: CGI-severity (CGI-S) and CGI-improvement (CGI-I). The former evaluates the severity of psychopathology from 1 to 7, and the latter assesses the change from the initiation of treatment on a similar seven-point scale. In CGI-S, clinical investigators need to answer one question: "Considering your total clinical experience with this particular population, how mentally ill is the patient at this time?", which is rated on the seven-point scale: 1 = normal, not at all ill while 7 = the most extremely ill. Similarly, in CGI-I, clinical investigators need to answer another question: "Compared to the patient's condition at admission to the project, how is this patient's condition?" which is also rated on a seven-point scale: 1 = very much improved since the initiation of treatment; 4 = no change from baseline; 7 = very much worse since the initiation of treatment.

**TCM SS:** TCM SS is a scale utilized to evaluate the participant's discomfort of PDS based on TCM theory. SS contains 15 items of TCM terminology, which are used to assess the presence (yes/no) and severity of physical discomfort (0 = absent; 1 = mild; 2 = moderate; 3 = severe).

**SF-36:** SF-36, the most commonly used tool to assess quality of life that contains 36 items in eight dimensions, was used to assess the effect of experimental medication. The eight dimensions consist of general health (GH), physical functioning (PF), role physical (RP), role emotional (RE), social functioning (SF), bodily pain (BP), vitality (VT) and mental health (MH)<sup>[31]</sup>.

**HADS:** The HADS, first developed by Snaith and Zigmond in 1983, was usually used to identify cases

(possible and probable) of anxiety disorders and depression among patients in non-psychiatric hospitals<sup>[32-34]</sup>. The scale consists of 14 items, 7 related to anxiety (HADS-A) and 7 related to depression (HADS-D), each scored between 0 and 3. The authors of this scale recommended that if an individual had a score of 8, he/she should be regarded as a possible case. It was found that this threshold was optimal for HADS-A and HADS-D in both the general population and patients with somatic symptoms.

**GE:** GE was observed using gastric ultrasound<sup>[35]</sup>. Participants were asked to fast overnight before the ultrasonography. A 1120 mL esculent liquid was used as the test meal and was prepared by mixing 50 g of nutrient Cola Cao (enteral nutritional solid beverage, chocolate; Tianjin Cola Cao Food Co., LTD, Tanjin, China) and 100 g of milk powder (Nestle whole milk powder; Shuangcheng Nestle Co., Ltd, Heilongjiang, China) with 1100 mL of warm water, and the entire test meal volume was 1120 mL. This esculent liquid contained 26.5 g of protein, 29.1 g of fat and 75.5 g of carbohydrate (840 kcal). This mixed liquid meal consisted of 13% proteins, 48% carbohydrates and 39% lipids and was used at a caloric density of 0.75 kcal/mL. The liquid test meal was administered orally as tolerated at a fixed rate of 50 mL/min, and all participants were allowed to sit stationary on a chair for approximately 5 min while drinking this test meal. The subjects were scanned in a half-sitting position, sitting on an examining chair and leaning back at an angle of approximately 120°. Subjects were instructed not to move and to hold their breath at the end of expiration to permit diaphragmatic rising and restoration of the gastric configuration (Figure 2).

The proximal stomach and distal stomach volumes of each subject were scanned at six time points, which were fasting, maximum satiety, and 30 min, 60 min, 90 min, and 120 min after beginning ingestion.

GE rate was calculated as follows:  $(A_{\max} - A) / A_{\max} \times 100 (\%)$ , where  $A_{\max}$  is the volume of maximum satiety after the meal in the proximal stomach or distal stomach, and  $A$  is the volume at other time points after the meal in the proximal stomach or distal stomach.

### Safety monitoring

To assess the safety of the 4 wk treatment, routine tests of blood, urine and stool samples, as well as an electrocardiogram and blood biochemical tests (ALT, AST, BUN, Scr) were conducted before randomization and immediately after the completed treatment. During the trial, any adverse events were recorded in detail and documented using case report forms, and appropriate treatment was provided to the participant immediately if necessary.

### Statistical analysis

All statistical analyses were conducted in a blind

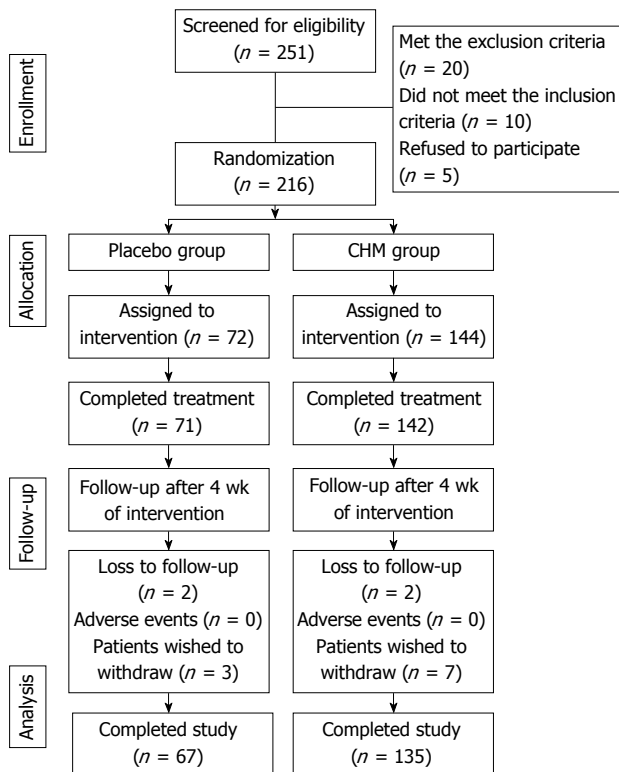


Figure 3 Flow of participants in the study.

Table 5 Subject characteristics (n = 202) n (%)

Characteristic		Placebo group (n = 67)	CHM group (n = 135)
Gender	Female	86 (63.7)	43 (64.2)
Age	mean ± SD	43.89 ± 13.32	44.33 ± 12.41
	20-29	12 (17.9)	21 (15.6)
	30-39	18 (26.9)	28 (20.7)
	40-49	8 (11.9)	31 (22.9)
	50-59	17 (25.4)	28 (20.7)
Level of education	60+	12 (17.9)	21 (15.6)
	Primary school	5 (7.5)	9 (6.7)
	Junior school	6 (8.9)	22 (16.3)
	Senior school	15 (22.4)	23 (17)
	Degree or above	41 (61.2)	81 (60)

CHM: Chinese herbal medicine.

manner by an independent statistician using SPSS (Version 19.0; SPSS Inc, Chicago, IL, United States). Significance was defined as a 2-sided *P* value of < 0.05. Demographic, clinical, and outcome variables were described using mean ± SD for continuous variables and percentages for categorical variables. First, the baseline characteristics of both groups were compared, including gender, age, and level of education. Second, the efficacy of CHM and placebo was compared, including the primary outcome and all secondary outcomes. All analyses in this study were based on the intention-to-treat principle. Missing values were recorded by the last-observation-carried-forward method, and this analysis imputes the last measured

value of the endpoint to all subsequent scheduled but missing evaluations. The baseline characteristics were compared using either  $\chi^2$  or the Student's *t*-tests. Primary and secondary outcomes are presented as the mean and SD and were analyzed using independent *t*-tests and Wilcoxon signed-rank tests. Adverse events were calculated and compared using  $\chi^2$  test.

## RESULTS

### Study population

Between July 2013 and July 2016, a total of 216 patients were recruited: 144 were randomized into the CHM group, and 72 were randomized into the placebo group. Fourteen patients withdrew from the trial due to a lack of efficacy (9 patients in the CHM group and 5 patients in the placebo group). No adverse events were reported. The physiological tests obtained after 4 wk of treatment showed no abnormal values.

### Participant flow

The flow of participants in the study is summarized in Figure 3.

### Baseline data

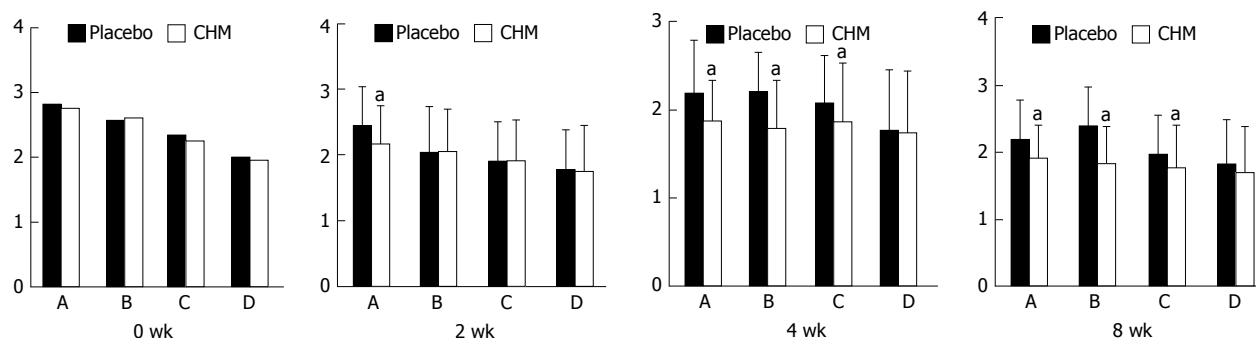
The general characteristics of the patients are shown in Table 5. No significant differences were identified between the two groups in parameters such as gender, age and level of education.

### Primary outcome

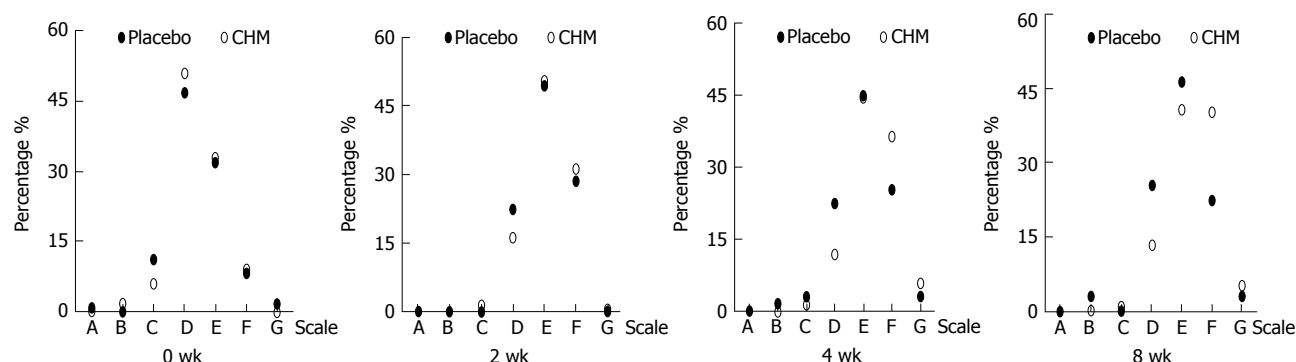
**PDSS:** At week 2, the symptom score of postprandial fullness in the CHM group was significantly better than that in the placebo group ( $t = 3.561$ ,  $P = 0.000$ ). After 4 wk of treatment, the scores of postprandial fullness, early satiety and epigastric pain of PDSS assessed by patients were significantly better in the CHM group than in the placebo group ( $t = 3.976$ ,  $P = 0.000$ ;  $t = 5.302$ ,  $P = 0.000$ ;  $t = 2.077$ ,  $P = 0.039$ ). These three symptom scores were also significantly better in the CHM group than in the placebo group during the follow-up period ( $t = 3.336$ ,  $P = 0.001$ ;  $t = 6.658$ ,  $P = 0.000$ ;  $t = 2.244$ ,  $P = 0.026$ ). The results were clinically meaningful (Figure 4).

### Secondary outcomes

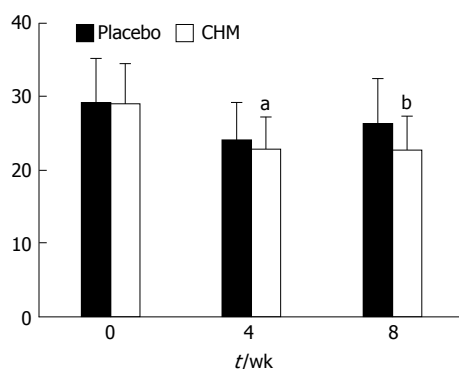
**CGI scale:** After 4 wk of treatment, the ratings of the CGI showed the following significant results for the CHM group vs placebo group: very much improved (5.9% vs 3.0%), much improved (36.3% vs 25.4%), slightly improved (44.4% vs 44.8%), and unchanged or deteriorated (11.8% vs 22.4%) ( $Z = -2.244$ ,  $P = 0.025$ ). The ratings of the CGI between the CHM group and placebo group during the follow-up period were as follows: very much improved (5.2% vs 3.0%), much improved (40.0% vs 22.4%), slightly improved (40.7% vs 46.3%), and unchanged or deteriorated (13.3% vs 25.4%) ( $Z = -2.054$ ,  $P = 0.04$ ). The results were



**Figure 4** Postprandial discomfort severity scale. A: Postprandial fullness; B: Early satiety; C: Epigastric pain; D: Epigastric burning. <sup>a</sup> $P < 0.05$  vs placebo group. CHM: Chinese herbal medicine.



**Figure 5** Clinical global impression scale. A: Very much worse since the initiation of treatment; B: Worse since the initiation of treatment; C: Slightly worse since the initiation of treatment; D: No change from baseline; E: Slightly improved since the initiation of treatment; F: Significantly improved since the initiation of treatment; G: Very much improved since the initiation of treatment. CHM: Chinese herbal medicine.



**Figure 6** Traditional Chinese medicine symptom scores. <sup>a</sup> $P < 0.05$ , <sup>b</sup> $P < 0.01$  vs placebo group. TCM: Traditional Chinese medicine; CHM: Chinese herb medicine.

clinically meaningful (Figure 5).

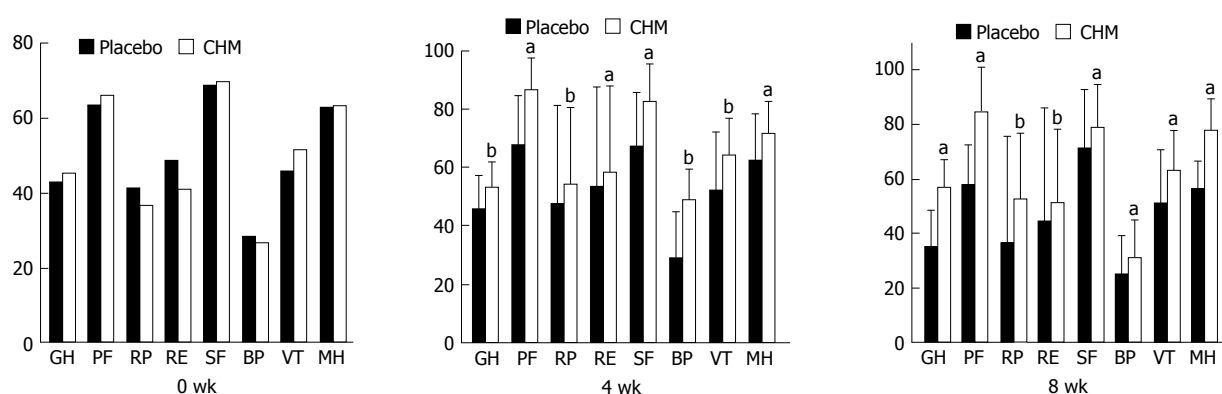
**TCM SS:** There was no significant difference between the two groups regarding SS at baseline ( $t = -0.173$ ,  $P = 0.863$ ). After 4 wk of treatment, SS in the CHM group was significantly better than that in the placebo group ( $t = -2.067$ ,  $P = 0.04$ ). The same result was also found during the follow-up period ( $t = -4.752$ ,  $P = 0.000$ ) (Figure 6).

**SF-36:** There was no significant difference between the

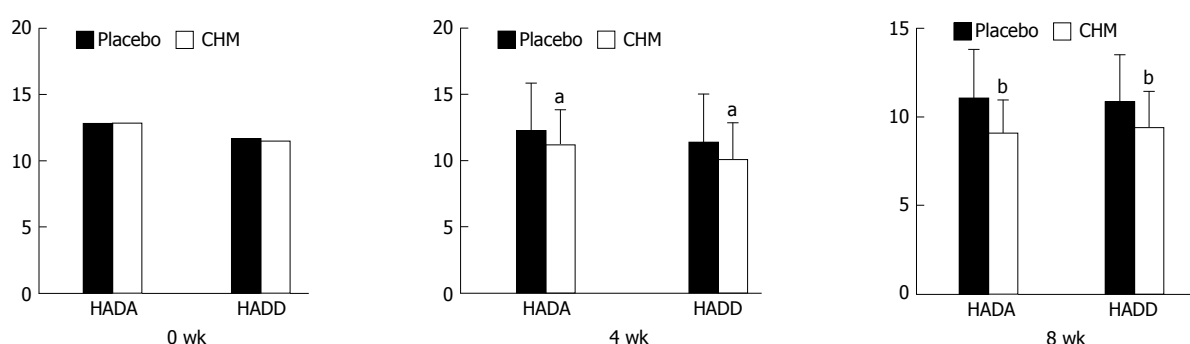
two groups regarding the eight dimensions of GH, PF, RP, RE, SF, BP, VT and MH in the SF-36 at baseline ( $t = -1.33$ ,  $P = 0.185$ ;  $t = -1.44$ ,  $P = 0.151$ ;  $t = 0.787$ ,  $P = 0.432$ ;  $t = 1.248$ ,  $P = 0.214$ ;  $t = 0.267$ ,  $P = 0.79$ ;  $t = 0.631$ ,  $P = 0.529$ ;  $t = -1.965$ ,  $P = 0.051$ ;  $t = -0.372$ ,  $P = 0.71$ ). After 4 wk of treatment, the SF-36 scores in the CHM group were significantly better than those in the placebo group ( $P < 0.05$  or  $P < 0.01$ ). The same result was also found during the follow-up period ( $P < 0.05$  or  $P < 0.01$ ) (Figure 7).

**HADS:** There was no significant difference between the two groups regarding HADA and HADD ( $t = 0.016$ ,  $P = 0.987$ ;  $t = -0.400$ ,  $P = 0.690$ ) at 0 wk. After 4 wk of treatment, the HADA and HADD scores in the CHM group were significantly better than those in the placebo group ( $t = -2.179$ ,  $P = 0.032$ ;  $t = -2.429$ ,  $P = 0.017$ ). The same result was also found during the follow-up period ( $t = -2.76$ ,  $P = 0.006$ ;  $t = -3.646$ ,  $P = 0.000$ ) (Figure 8).

**GE:** The GE rate of the proximal stomach (GERPG) in the CHM group at various time points was higher than that of the control group, and the differences were significant ( $P < 0.01$ ). Moreover, the gastric emptying rate of the distal stomach (GERDG) in the CHM group, compared with the control group, decreased at 30 min



**Figure 7** MOS 36-item short-form health survey. GH: General health; PF: Physical functioning; RP: Role physical; RE: Role emotional; SF: Social functioning; BP: bodily pain; VT: Vitality; MH: Mental health. <sup>a</sup> $P < 0.05$ , <sup>b</sup> $P < 0.01$  vs placebo group. CHM: Chinese herb medicine.



**Figure 8** Hospital anxiety and depression scale. <sup>a</sup> $P < 0.05$ , <sup>b</sup> $P < 0.01$  vs placebo group. CHM: Chinese herb medicine; HADA: Hospital anxiety and depression scale-Anxiety; HADD: Hospital anxiety and depression scale-Depression.

after the meal but increased at the other time points, and the differences were significant ( $P < 0.05$  or  $P < 0.01$ ) (Table 6).

**Adverse effects:** In the 4 wk treatment and the follow-up period, all subjects had no adverse effects.

## DISCUSSION

FD is a common gastrointestinal disease. The prevalence of FD is 20%-25% in Western countries and 8%-23% in Asia<sup>[36,37]</sup>. In China, approximately 10% of general outpatients have dyspepsia, which account for 50% of digestive internal medicine clinic services. FD involves various pathophysiological disturbances and many pathogenic factors, including impaired accommodation, delayed GE, and hypersensitivity to gastric distention. Several studies have reported that visceral hypersensitivity is the mechanism of postprandial abdominal bloating and distension. The normal abdominal accommodation is altered by an abnormal viscerosomatic response to meal ingestion<sup>[38]</sup>. Patients with PDS have the characteristics of fasting and postprandial hypersensitivity, while patients with EPS have the characteristics of a reduction in gastric compliance<sup>[39]</sup>. There are multiple drug options in clinical practice, including PPIs, prokinetic agents, anti-*Helicobacter pylori* drugs, antidepressant

drugs and mucosal protective agents. Because the pathophysiology of FD involves several physiological systems and a variety of treatment classes are available, health care providers face uncertainty in selecting therapies for patients with FD. Furthermore, these chemical drugs are not satisfactory or effective. Therefore, many patients with FD seek treatment with complementary and alternative medicine<sup>[15]</sup>. TCM, as an important component of complementary and alternative medicine, has attracted increasing attention in the world, especially in the treatment of functional gastrointestinal diseases.

Based on TCM theory, the "spleen" governs movement and transformation of food and fluid. Emotional injury, food or drink, and congenital defects are main pathogenic factors of a functional disorder of the "spleen", which can lead to the stagnation of Qi and dampness and then result in "stiffness and fullness". As spleen deficiency is the essence of these three types of syndrome, invigorating the spleen is the critical principle of treatment<sup>[40,41]</sup>. This pathogenic factor causes abnormal function of the upper abdomen, spleen and stomach, resulting in the presence of abdominal distension, appetite disorder, loose stools, and lassitude. The TCM pathogenesis of FD is spleen deficiency and Qi-stagnation. Xiangsha Liujunzi decoction is a classical formula based on invigorating the spleen and has been used by TCM



**Table 6** Gastric emptying rates of proximal and distal stomach

Time	Placebo ( <i>n</i> = 67)	CHM ( <i>n</i> = 135)	<i>t</i>	<i>P</i> value
0 wk				
GE rate of proximal stomach				
30 min	32.85 ± 19.27	30.91 ± 16.67	0.653	0.515
60 min	49.26 ± 18.67	49.46 ± 17.74	-0.066	0.947
90 min	66.37 ± 14.63	63.72 ± 17.51	0.948	0.344
120 min	76.54 ± 13.97	75.39 ± 13.91	0.487	0.627
GE rate of distal stomach				
30 min	15.68 ± 35.26	6.81 ± 37.61	1.576	0.117
60 min	32.49 ± 30.82	26.91 ± 33.36	1.124	0.263
90 min	49.26 ± 25.93	41.84 ± 33.59	1.555	0.122
120 min	61.61 ± 21.85	57.52 ± 27.02	1.053	0.294
4 wk				
GE rate of proximal stomach				
30 min	28.48 ± 13.13	36.31 ± 10.78	-4.195	0.000
60 min	47.21 ± 16.76	56.92 ± 10.27	-4.722	0.000
90 min	59.59 ± 17.71	72.92 ± 16.94	-6.919	0.000
120 min	71.47 ± 16.94	82.31 ± 7.35	-5.888	0.000
GE rate of distal stomach				
30 min	7.03 ± 35.40	-24.34 ± 34.02	5.707	0.000
60 min	26.94 ± 31.39	40.83 ± 16.37	-3.871	0.000
90 min	50.06 ± 21.97	56.90 ± 15.35	-2.406	0.017
120 min	61.89 ± 15.26	67.66 ± 13.41	-2.578	0.011

CHM: Chinese herb medicine; GE: Gastric emptying.

doctors for hundreds of years. In the past two decades, a considerable number of clinical trials have proved the efficacy and safety of this decoction in the treatment of FD<sup>[20,34,42,43]</sup>. Currently, no patient-reported outcome instrument is available for the evaluation of treatment efficacy in PDS, which makes the evaluation of treatment effects in FD difficult. To improve the evaluation criteria of this study, we chose the PDSS, CGI, SS, SF-36, and HADS. CGI instrument, an established outcome measure in psychopharmacology research, is a reliable measure of fatigue<sup>[44]</sup>. Symptoms of fatigue are often part of the clinical presentation of spleen deficiency. Mental and psychological disorders are one of the pathogenic factors for FD. Clinically, we found many FD patients with anxiety and depression symptoms. One of the “gold standard” to assess the efficacy of antidepressants and anti-anxiety medications is the Hamilton rating scale. Another scale to assess the efficacy of antidepressants and anti-anxiety medications is the CGI, which has similar effect sizes to the HAM rating scale<sup>[45]</sup>. Therefore, CGI instrument has been used in clinical practice as well as research. Zigmond and Snaith devised the HADS, which has the advantages of simplicity, fastness and ease of use, to assess anxiety and depression in a general medical population 33 years ago<sup>[46]</sup>. This scale has recently been used to assess FD patients with anxiety and depression. The remarkable placebo response is the most difficulty in clinical trials on FD patients. In order to ensure that the participants could not be able to make a distinction between placebo and active treatment, we tried our best to make the drugs in the two groups indistinguishable for the participants. The placebo granules were made from 80% dextrin, 15% rice, 5% bitter principle and coloring matter to

ensure that the color, smell, taste and texture were similar to those of Xiangsha Liujunzi granules. In this clinical study, we found that Xiangsha Liujunzi granules can relieve the postprandial fullness, early satiety, and epigastric pain symptoms in PDS patients, but the improvement in the epigastric burning sensation was not superior to that achieved by the placebo. This result may be because the inhibition of gastric acid secretion by CHM was not better than that of PPIs. The SF-36 scale was used to evaluate the improvement in quality life of patients. Our results showed the advantage of the CHM compared to placebo, with a significant improvement of 8 subscale scores of GH, PF, RP, RE, SF, BP, VT, MH on the SF-36 at 2 wk and 4 wk. These results persisted until the end of the study (8 wk). The pathophysiology of FD is diverse and its symptoms are non-specific; the pathogenesis of FD is also related to mental and psychological factors. Therefore, some antidepressants have been used to treat FD, such as mirtazapine<sup>[47]</sup>. According to our results, the HADA and HADD scores were both reduced in the CHM group compared to the placebo group at 4 wk and 8 wk, and there was a significant difference between the two groups. The CHM treatment had significant improvement in gastrointestinal-specific anxiety and depression. This study also showed that TCM symptom scores significantly improved from 2 wk to 4 wk with CHM treatment, and the result persisted to the follow-up time (8 wk). This finding shows that TCM treatment can reduce the recurrence of FD symptoms. Finally, after 4 wk of CHM treatment, the number of participants with very much improved and much improved scores on the CGI scale, compared to placebo, was significantly higher at 4 wk.

FD is one of the most common gastrointestinal

diseases, accounting for up to 5% of outpatients in gastroenterology department<sup>[48]</sup>. GE of patients with FD is usually delayed in 30%-50%<sup>[49]</sup>, including both liquid emptying<sup>[50]</sup> and solid emptying<sup>[48]</sup>. Food ingestion can directly aggravate dyspeptic symptoms of patients with FD. Data from questionnaires revealed that 75% of patients with FD had experience of aggravation of dyspeptic symptoms after ingestion of a meal. Previous studies had reported that 90% of patients with FD had aggravation of dyspeptic symptoms after ingestion of a standardized 250-kcal meal, and maximum symptom severity occurred between 45 and 90 min after meal<sup>[51]</sup>. In this study, we calculated the GERPG and GERDG at 4 time points and found that the GERDG of the CHM group at 30 min after a meal was negative. As we know, the proximal stomach functions as a reservoir, and the liquid food flows into the distal stomach and enlarges the volume of the distal stomach over time. This factor caused an illusion that the GERDG of the CHM group was decreased. Compared with those of the placebo group, the GERPG and GERDG of the CHM group were increased at 60 min, 90 min, and 120 min after the meal. The results of this study suggest that the curative effect of Xiangsha Liujunzi decoction can promote GE of patients with PDS. Furthermore, throughout the course of the experiment, participants were not found to have any adverse events.

## Conclusion

We have demonstrated the clinical efficacy of the Xiangsha Liujunzi granules to improve the symptomatic symptoms of patients with FD. In this randomized, double-blinded, placebo-controlled trial, Xiangsha Liujunzi granules was shown to be effective in the management of FD, especially in patients with postprandial fullness and bloating, early satiety, and epigastric pain. This treatment will provide a new option for clinicians in treating PDS. However, the mechanism of action for CHM to reduce gastrointestinal symptoms is still unknown, and further studies are needed to determine the precise mechanisms of action.

## COMMENTS

### Background

Functional dyspepsia (FD), one of the most common functional gastrointestinal disorders, has two diagnostic categories that are postprandial distress syndrome (PDS) and epigastric pain syndrome. Its prevalence ranges from 11% to 29%, and it seriously affects the quality of life of patients. However, current chemical drugs do not achieve good curative effect, and it is therefore necessary to find a new therapy for FD.

### Research frontiers

The major pathophysiological mechanism of PDS is gastric motility disorder, therefore, searching for a kind of effective treatment for PDS is the current research hotspot. Traditional Chinese medicine (TCM) has the advantage of treating PDS. Xiangsha Liujunzi decoction is a classical formula based on invigorating the spleen and has been used in clinical practice for hundreds of years. Gastric ultrasound is usually used to observe the gastric emptying (GE),

but its value in assessing the promoting effect of Chinese herbal medicines (CHMs) on gastric motility has not yet been studied.

## Innovations and breakthroughs

Although in the past two decades, a considerable number of clinical trials have proved the efficacy and safety of this decoction in the treatment of FD, there are still some disadvantages in assessing its efficacy. The authors use gastric ultrasound to observe proximal and distal GE rates. The advantages of the technique include being non-invasive, accurate, and reliable.

## Applications

The authors provide strong evidence to support the use of CHM in PDS patients. This treatment will provide a new option for clinicians in treating PDS in the future.

## Terminology

TCM, an independent medical system well known in China, has four ways of diagnosis that are look, listen, question and feel the pulse. It takes Yin-Yang and five elements as the theoretical basis, which holds that the human body is regarded as the unity of Qi, form and spirit. The basic principle of understanding and treating diseases for TCM is syndrome differentiation. CHMs are natural medicines that consist of plant medicine (root, stem, leaf and fruit), animal medicine (viscera, skin, bone, organ, etc.) and mineral medicine. The use of CHMs is conducted under the guidance of the theory of TCM.

## Peer-review

This paper describes a new method for treating PDS. The authors designed a multicenter, randomized, double-blinded, placebo-controlled trial with two arms to examine the safety and efficacy of Xiangsha Liujunzi granules in the treatment of PDS patients. They assessed PDS symptoms using the change in PDSS, clinical global impression scale, TCM symptom scores, MOS 36-Item Short-Form Health Survey, and hospital anxiety and depression scale. Further, they assessed proximal and distal GE rates by gastric ultrasound, which is non-invasive, accurate, and reliable. This clinical trial study provides strong evidence to support the use of CHM in PDS patients. This treatment will provide a new option for clinicians in treating PDS in the future.

## REFERENCES

- 1 Camilleri M, Stanghellini V. Current management strategies and emerging treatments for functional dyspepsia. *Nat Rev Gastroenterol Hepatol* 2013; **10**: 187-194 [PMID: 23381190 DOI: 10.1038/nrgastro.2013.11]
- 2 Tack J, Talley NJ. Functional dyspepsia--symptoms, definitions and validity of the Rome III criteria. *Nat Rev Gastroenterol Hepatol* 2013; **10**: 134-141 [PMID: 23399526 DOI: 10.1038/nrgastro.2013.14]
- 3 Petrarca L, Nenna R, Mastrogiorgio G, Florio M, Brighi M, Pontone S. Dyspepsia and celiac disease: Prevalence, diagnostic tools and therapy. *World J Methodol* 2014; **4**: 189-196 [PMID: 25332916 DOI: 10.5662/wjm.v4.i3.189]
- 4 Kindt S, Tack J. Impaired gastric accommodation and its role in dyspepsia. *Gut* 2006; **55**: 1685-1691 [PMID: 16854999 DOI: 10.1136/gut.2005.085365]
- 5 Talley NJ, Walker MM, Aro P, Ronkainen J, Storskrubb T, Hindley LA, Harmsen WS, Zinsmeister AR, Agr us L. Non-ulcer dyspepsia and duodenal eosinophilia: an adult endoscopic population-based case-control study. *Clin Gastroenterol Hepatol* 2007; **5**: 1175-1183 [PMID: 17686660 DOI: 10.1016/j.cgh.2007.05.015]
- 6 Sanger GJ, Alpers DH. Development of drugs for gastrointestinal motor disorders: translating science to clinical need. *Neurogastroenterol Motil* 2008; **20**: 177-184 [PMID: 18257767 DOI: 10.1111/j.1365-2982.2008.01084.x]
- 7 Jiang SM, Lei XG, Jia L, Xu M, Wang SB, Liu J, Song M. Unhealthy dietary behavior in refractory functional dyspepsia: a multicenter prospective investigation in China. *J Dig Dis* 2014; **15**: 654-659 [PMID: 25283636 DOI: 10.1111/1751-2980.12199]

- 8 **Göktaş Z**, Köklü S, Dikmen D, Öztürk Ö, Yılmaz B, Asıl M, Korkmaz H, Tuna Y, Kekilli M, Karamanoğlu Aksoy E, Köklü H, Demir A, Köklü G, Arslan S. Nutritional habits in functional dyspepsia and its subgroups: a comparative study. *Scand J Gastroenterol* 2016; **51**: 903-907 [PMID: 27124324 DOI: 10.3109/00365521.2016.1164238]
- 9 **van Zanten SV**, Armstrong D, Chiba N, Flook N, White RJ, Chakraborty B, Gasco A. Esomeprazole 40 mg once a day in patients with functional dyspepsia: the randomized, placebo-controlled "ENTER" trial. *Am J Gastroenterol* 2006; **101**: 2096-2106 [PMID: 16817845 DOI: 10.1111/j.1572-0241.2006.00751.x]
- 10 **Vakil N**, Laine L, Talley NJ, Zakko SF, Tack J, Chey WD, Kralstein J, Earnest DL, Ligozio G, Cohard-Radice M. Tegaserod treatment for dysmotility-like functional dyspepsia: results of two randomized, controlled trials. *Am J Gastroenterol* 2008; **103**: 1906-1919 [PMID: 18616658 DOI: 10.1111/j.1572-0241.2008.01953.x]
- 11 **Bouras EP**, Talley NJ, Camilleri M, Burton DD, Heckman MG, Crook JE, Richelson E. Effects of amitriptyline on gastric sensorimotor function and postprandial symptoms in healthy individuals: a randomized, double-blind, placebo-controlled trial. *Am J Gastroenterol* 2008; **103**: 2043-2050 [PMID: 18803000]
- 12 **Talley NJ**, Locke GR, Herrick LM, Silvernail VM, Prather CM, Lacy BE, DiBaise JK, Howden CW, Brenner DM, Bouras EP, El-Serag HB, Abraham BP, Moayyedi P, Zinsmeister AR. Functional Dyspepsia Treatment Trial (FDTT): a double-blind, randomized, placebo-controlled trial of antidepressants in functional dyspepsia, evaluating symptoms, psychopathology, pathophysiology and pharmacogenetics. *Contemp Clin Trials* 2012; **33**: 523-533 [PMID: 22343090 DOI: 10.1016/j.cct.2012.02.002]
- 13 **Altan E**, Masaoka T, Farré R, Tack J. Acotiamide, a novel gastroprokinetic for the treatment of patients with functional dyspepsia: postprandial distress syndrome. *Expert Rev Gastroenterol Hepatol* 2012; **6**: 533-544 [PMID: 23061703 DOI: 10.1586/egh.12.34]
- 14 **Saad RJ**, Chey WD. Review article: current and emerging therapies for functional dyspepsia. *Aliment Pharmacol Ther* 2006; **24**: 475-492 [PMID: 16886913 DOI: 10.1111/j.1365-2036.2006.03005.x]
- 15 **Lacy BE**, Talley NJ, Locke GR, Bouras EP, DiBaise JK, El-Serag HB, Abraham BP, Howden CW, Moayyedi P, Prather C. Review article: current treatment options and management of functional dyspepsia. *Aliment Pharmacol Ther* 2012; **36**: 3-15 [PMID: 22591037 DOI: 10.1111/j.1365-2036.2012.05128.x]
- 16 **Thompson Coon J**, Ernst E. Systematic review: herbal medicinal products for non-ulcer dyspepsia. *Aliment Pharmacol Ther* 2002; **16**: 1689-1699 [PMID: 12269960]
- 17 **Pasalar M**, Choopani R, Mosaddegh M, Kamalinejad M, Mohagheghzadeh A, Fattahi MR, Ghanizadeh A, Bagheri Lankarani K. Efficacy and safety of jollab to treat functional dyspepsia: a randomized placebo-controlled clinical trial. *Explore (NY)* 2015; **11**: 199-207 [PMID: 25777290 DOI: 10.1016/j.explore.2015.02.007]
- 18 **Mohtashami R**, Huseini HF, Heydari M, Amini M, Sadeqhi Z, Ghaznavi H, Mehrzadi S. Efficacy and safety of honey based formulation of Nigella sativa seed oil in functional dyspepsia: A double blind randomized controlled clinical trial. *J Ethnopharmacol* 2015; **175**: 147-152 [PMID: 26386381 DOI: 10.1016/j.jep.2015.09.022]
- 19 **Giaccosa A**, Guido D, Grassi M, Riva A, Morazzoni P, Bombardelli E, Perna S, Faliva MA, Rondanelli M. The Effect of Ginger (*Zingiber officinalis*) and Artichoke (*Cynara cardunculus*) Extract Supplementation on Functional Dyspepsia: A Randomised, Double-Blind, and Placebo-Controlled Clinical Trial. *Evid Based Complement Alternat Med* 2015; **2015**: 915087 [PMID: 25954317 DOI: 10.1155/2015/915087]
- 20 **Zhang S**, Zhao L, Wang H, Wang C, Huang S, Shen H, Wei W, Tao L, Zhou T. Efficacy of modified LiuJunZi decoction on functional dyspepsia of spleen-deficiency and qi-stagnation syndrome: a randomized controlled trial. *BMC Complement Altern Med* 2013; **13**: 54 [PMID: 23453018 DOI: 10.1186/1472-6882-13-54]
- 21 **Yang N**, Jiang X, Qiu X, Hu Z, Wang L, Song M. Modified chaihui shugan powder for functional dyspepsia: meta-analysis for randomized controlled trial. *Evid Based Complement Alternat Med* 2013; **2013**: 791724 [PMID: 23762161 DOI: 10.1155/2013/791724]
- 22 **Zhang SS**, Chen Z, Xu WJ, Wang HB. Study on distribution characteristic of syndrome of 565 cases of functional dyspepsia by twice differentiation of symptoms and signs based on the cold, heat, deficiency, excess. *Zhonghua Zhongyiyao Zazhi* 2008; **23**: 833-835
- 23 **Wang FY**, Zhong LLD, Kang N, Dai L, Lv L, Bian LQ, Chen T, Zhang BH, Bian ZX, Wang XG. Chinese herbal formula for postprandial distress syndrome: Study protocol of a double-blinded, randomized, placebo-controlled trial. *Eur J Integrat Med* 2016; 1-7
- 24 **Moher D**, Schulz KF, Altman DG; CONSORT Group. The CONSORT statement: revised recommendations for improving the quality of reports of parallel-group randomised trials. *Clin Oral Investig* 2003; **7**: 2-7 [PMID: 12673431]
- 25 **Chan AW**, Tetzlaff JM, Altman DG, Laupacis A, Gøtzsche PC, Krleža-Jerić K, Hróbjartsson A, Mann H, Dickersin K, Berlin JA, Doré CJ, Parulekar WR, Summerskill WS, Groves T, Schulz KF, Sox HC, Rockhold FW, Rennie D, Moher D. SPIRIT 2013 statement: defining standard protocol items for clinical trials. *Ann Intern Med* 2013; **158**: 200-207 [PMID: 23295957 DOI: 10.7326/0003-4819-158-3-201302050-00583]
- 26 **Chan AW**, Tetzlaff JM, Altman DG, Laupacis A, Gøtzsche PC, Krleža-Jerić K, Hróbjartsson A, Mann H, Dickersin K, Berlin JA, Doré CJ, Parulekar WR, Summerskill WS, Groves T, Schulz KF, Sox HC, Rockhold FW, Rennie D, Moher D. SPIRIT 2013 Statement: defining standard protocol items for clinical trials. *Rev Panam Salud Publica* 2015; **38**: 506-514 [PMID: 27440100]
- 27 **Zheng XY**. Guiding principle of clinical research on new drugs of Chinese medicine in the treatment of stiffness and fullness. In: Guiding principle of clinical research on new drugs of Chinese medicine (trial implementation). Edited by Yu XH. Beijing: Chinese Medical Science and Technology Press; 2002: 54-58
- 28 **Holtmann G**, Talley NJ, Liebrechts T, Adam B, Parow C. A placebo-controlled trial of itopride in functional dyspepsia. *N Engl J Med* 2006; **354**: 832-840 [PMID: 16495395 DOI: 10.1056/NEJMoa052639]
- 29 **Mearin F**, de Ribot X, Balboa A, Salas A, Varas MJ, Cucala M, Bartolomé R, Armengol JR, Malagelada JR. Does Helicobacter pylori infection increase gastric sensitivity in functional dyspepsia? *Gut* 1995; **37**: 47-51 [PMID: 7672680]
- 30 **Busner J**, Targum SD. The clinical global impressions scale: applying a research tool in clinical practice. *Psychiatry (Edmont)* 2007; **4**: 28-37 [PMID: 20526405]
- 31 **McHorney CA**, Ware JE Jr, Lu JF, Sherbourne CD. The MOS 36-item Short-Form Health Survey (SF-36): III. Tests of data quality, scaling assumptions, and reliability across diverse patient groups. *Med Care* 1994; **32**: 40-66 [PMID: 8277801]
- 32 **Zigmond AS**, Snaith RP. The hospital anxiety and depression scale. *Acta Psychiatr Scand* 1983; **67**: 361-370 [PMID: 6880820]
- 33 **Snaith RP**. The Hospital Anxiety And Depression Scale. *Health Qual Life Outcomes* 2003; **1**: 29 [PMID: 12914662 DOI: 10.1186/1477-7525-1-29]
- 34 **Kido T**, Nakai Y, Kase Y, Sakakibara I, Nomura M, Takeda S, Aburada M. Effects of rikkunshi-to, a traditional Japanese medicine, on the delay of gastric emptying induced by N(G)-nitro-L-arginine. *J Pharmacol Sci* 2005; **98**: 161-167 [PMID: 15937402]
- 35 **Kusunoki H**, Haruma K, Hata J, Kamada T, Ishii M, Yamashita N, Inoue K, Imamura H, Manabe N, Shiotani A. Efficacy of mosapride citrate in proximal gastric accommodation and gastrointestinal motility in healthy volunteers: a double-blind placebo-controlled ultrasonographic study. *J Gastroenterol* 2010; **45**: 1228-1234 [PMID: 20658155 DOI: 10.1007/s00535-010-0292-7]
- 36 **Oustamanolakis P**, Tack J. Dyspepsia: organic versus functional. *J Clin Gastroenterol* 2012; **46**: 175-190 [PMID: 22327302 DOI: 10.1097/MCG.0b013e318241b335]
- 37 **Ghoshal UC**, Singh R, Chang FY, Hou X, Wong BC, Kachintorn U; Functional Dyspepsia Consensus Team of the

- Asian Neurogastroenterology and Motility Association and the Asian Pacific Association of Gastroenterology. Epidemiology of uninvestigated and functional dyspepsia in Asia: facts and fiction. *J Neurogastroenterol Motil* 2011; **17**: 235-244 [PMID: 21860815 DOI: 10.5056/jnm.2011.17.3.235]
- 38 **Burri E**, Barba E, Huaman JW, Cisternas D, Accarino A, Soldevilla A, Malagelada JR, Azpiroz F. Mechanisms of postprandial abdominal bloating and distension in functional dyspepsia. *Gut* 2014; **63**: 395-400 [PMID: 23645627 DOI: 10.1136/gutjnl-2013-304574]
- 39 **Di Stefano M**, Miceli E, Tana P, Mengoli C, Bergonzi M, Pagani E, Corazza GR. Fasting and postprandial gastric sensorimotor activity in functional dyspepsia: postprandial distress vs. epigastric pain syndrome. *Am J Gastroenterol* 2014; **109**: 1631-1639 [PMID: 25199472 DOI: 10.1038/ajg.2014.231]
- 40 **Lv L**, Huang SP, Tang XD, Wang FY, Wang J, Luo SJ, Kang N. Theoretical Discussion on Treating Functional Dyspepsia From Spleen. *Zhongyiyao Zazhi* 2014; **55**: 383-385 [DOI: 10.13288/j.11-2166/r.2014.05.007]
- 41 **Du HG**, Ming L, Chen SJ, Li CD. Xiaoyao pill for treatment of functional dyspepsia in perimenopausal women with depression. *World J Gastroenterol* 2014; **20**: 16739-16744 [PMID: 25469046 DOI: 10.3748/wjg.v20.i44.16739]
- 42 **Takeda H**, Sadakane C, Hattori T, Katsurada T, Ohkawara T, Nagai K, Asaka M. Rikkunshito, an herbal medicine, suppresses cisplatin-induced anorexia in rats via 5-HT<sub>2</sub> receptor antagonism. *Gastroenterology* 2008; **134**: 2004-2013 [PMID: 18439428 DOI: 10.1053/j.gastro.2008.02.078]
- 43 **Oyachi N**, Takano K, Hasuda N, Arai H, Koshizuka K, Matsumoto M. Effects of Rikkunshi-to on infantile hypertrophic pyloric stenosis, refractory to atropine. *Pediatr Int* 2008; **50**: 581-583 [PMID: 18937758 DOI: 10.1111/j.1442-200X.2008.02682.x]
- 44 **Targum SD**, Hassman H, Pinho M, Fava M. Development of a clinical global impression scale for fatigue. *J Psychiatr Res* 2012; **46**: 370-374 [PMID: 22236834]
- 45 **Khan A**, Khan SR, Shankles EB, Polissar NL. Relative sensitivity of the Montgomery-Asberg Depression Rating Scale, the Hamilton Depression rating scale and the Clinical Global Impressions rating scale in antidepressant clinical trials[J]. *Int Clin Psychopharm* 2004; **19**: 157-160
- 46 **Zigmond AS**, Snaith RP. The Hospital Anxiety and Depression Scale. *Acta Psychiatr Scand* 1983; **67**: 361-370
- 47 **Tack J**, Ly HG, Carbone F, Vanheel H, Vanuytsel T, Holvoet L, Boeckxstaens G, Caenepeel P, Arts J, Van Oudenhove L. Efficacy of Mirtazapine in Patients With Functional Dyspepsia and Weight Loss. *Clin Gastroenterol Hepatol* 2016; **14**: 385-392.e4 [PMID: 26538208 DOI: 10.1016/j.cgh.2015.09.043]
- 48 **Knill-Jones RP**. Geographical differences in the prevalence of dyspepsia. *Scand J Gastroenterol Suppl* 1991; **182**: 17-24 [PMID: 1896825]
- 49 **Malagelada JR**. Functional dyspepsia. Insights on mechanisms and management strategies. *Gastroenterol Clin North Am* 1996; **25**: 103-112 [PMID: 8682568]
- 50 **Kellow JE**. Motility-like dyspepsia. Current concepts in pathogenesis, investigation and management. *Med J Aust* 1992; **157**: 385-388 [PMID: 1447988]
- 51 **Stanghellini V**, Tosetti C, Paternico A, Barbara G, MorselliLabate AM, Monetti N, Marengo M, Corinaldesi R. Risk indicators of delayed gastric emptying of solids in patients with functional dyspepsia. *Gastroenterology* 1996; **110**: 1036-1042 [PMID: 8612991]

**P- Reviewer:** Kim BJ, Kobayashi T **S- Editor:** Qi Y  
**L- Editor:** Wang TQ **E- Editor:** Zhang FF





## Observational Study

# Combination of acoustic radiation force impulse imaging, serological indexes and contrast-enhanced ultrasound for diagnosis of liver lesions

Xiao-Lan Sun, Hui Yao, Qiong Men, Ke-Zhu Hou, Zhen Chen, Chang-Qing Xu, Li-Wei Liang

Xiao-Lan Sun, Department of Ultrasound, Shanghai Yangpu District East Hospital, Shanghai 200433, China

Hui Yao, Department of Radiotherapy, Shanghai Yangpu District East Hospital, Shanghai 200433, China

Qiong Men, Department of Oncology, Shanghai Yangpu District East Hospital, Shanghai 200433, China

Ke-Zhu Hou, Department of Surgery, Shanghai Yangpu District East Hospital, Shanghai 200433, China

Zhen Chen, Department of Pathology, Shanghai Yangpu District East Hospital, Shanghai 200433, China

Chang-Qing Xu, Department of Radiography, Shanghai Yangpu District East Hospital, Shanghai 200433, China

Li-Wei Liang, Department of Gastroenterology, Shanghai Yangpu District East Hospital, Shanghai 200433, China

**Author contributions:** Sun XL and Liang LW designed the research; Sun XL, Yao H, Men Q, Hou KZ and Liang LW performed the research; Sun XL, Yao H, Men Q, Hou KZ, Chen Z, Xu CQ and Liang LW contributed new reagents or analytic tools; Sun XL, Hou KZ, Chen Z, Xu CQ and Liang LW analyzed the data; Sun XL and Liang LW wrote the paper.

**Supported by** Yangpu District Health and Family Planning Commission, Yangpu District Science and Technology Commission, No. YP15M18; Research Project of Shanghai Municipal Commission of Health and Family Planning, No. 201540032.

**Institutional review board statement:** This study was approved by Shanghai Yangpu District East Hospital Institutional Review Board.

**Informed consent statement:** All study participants, or their legal guardian, provided informed written consent prior to study enrollment.

**Conflict-of-interest statement:** No potential conflicts of interest

relevant to this article are reported.

**Data sharing statement:** No additional data are available.

**Open-Access:** This article is an open-access article which was selected by an in-house editor and fully peer-reviewed by external reviewers. It is distributed in accordance with the Creative Commons Attribution Non Commercial (CC BY-NC 4.0) license, which permits others to distribute, remix, adapt, build upon this work non-commercially, and license their derivative works on different terms, provided the original work is properly cited and the use is non-commercial. See: <http://creativecommons.org/licenses/by-nc/4.0/>

**Manuscript source:** Unsolicited manuscript

**Correspondence to:** Dr. Li-Wei Liang, Attending Physician, Department of Gastroenterology, Shanghai Yangpu District East Hospital, No. 999 Shiguang Road, Yangpu District, Shanghai 200433, China. [ypsdkjk@163.com](mailto:ypsdkjk@163.com)  
Telephone: +86-21-65881977

**Received:** March 27, 2017

**Peer-review started:** March 29, 2017

**First decision:** April 11, 2017

**Revised:** April 24, 2017

**Accepted:** May 9, 2017

**Article in press:** May 9, 2017

**Published online:** August 14, 2017

## Abstract

### AIM

To assess the value of combined acoustic radiation force impulse (ARFI) imaging, serological indexes and contrast-enhanced ultrasound (CEUS) in distinguishing between benign and malignant liver lesions.

### METHODS

Patients with liver lesions treated at our hospital were

included in this study. The lesions were divided into either a malignant tumor group or a benign tumor group according to pathological or radiological findings. ARFI quantitative detection, serological testing and CEUS quantitative detection were performed and compared. A comparative analysis of the measured indexes was performed between these groups. Receiver operating characteristic (ROC) curves were constructed to compare the diagnostic accuracy of ARFI imaging, serological indexes and CEUS, alone or in different combinations, in identifying benign and malignant liver lesions.

## RESULTS

A total of 112 liver lesions in 43 patients were included, of which 78 were malignant and 34 were benign. Shear wave velocity (SWV) value, serum alpha-fetoprotein (AFP) content and enhancement rate were significantly higher in the malignant tumor group than in the benign tumor group ( $2.39 \pm 1.20$  m/s *vs*  $1.50 \pm 0.49$  m/s,  $18.02 \pm 5.01$  ng/mL *vs*  $15.96 \pm 4.33$  ng/mL,  $2.14 \pm 0.21$  dB/s *vs*  $2.01 \pm 0.31$  dB/s;  $P < 0.05$ ). The ROC curve analysis revealed that the areas under the curves (AUCs) of SWV value alone, AFP content alone, enhancement rate alone, SWV value + AFP content, SWV value + enhancement rate, AFP content + enhancement rate and SWV value + AFP content + enhancement rate were 85.1%, 72.1%, 74.5%, 88.3%, 90.4%, 82.0% and 92.3%, respectively. The AUC of SWV value + AFP content + enhancement rate was higher than those of SWV value + AFP content and SWV value + enhancement rate, and significantly higher than those of any single parameter or the combination of any two of parameters.

## CONCLUSION

The combination of SWV, AFP and enhancement rate had better diagnostic performance in distinguishing between benign and malignant liver lesions than the use of any single parameter or the combination of any two of parameters. It is expected that this would provide a tool for the differential diagnosis of benign and malignant liver lesions.

**Key words:** Combined diagnosis; Liver lesions; Benign; Malignant; Differentiation

© **The Author(s) 2017.** Published by Baishideng Publishing Group Inc. All rights reserved.

**Core tip:** This study investigated the diagnostic value of combined acoustic radiation force impulse (ARFI) imaging, serological indicators and contrast-enhanced ultrasound in differentiating between benign and malignant liver lesions. The results showed that the diagnostic performance of combined ARFI, alpha-fetoprotein (AFP) and contrast-enhanced ultrasound in distinguishing between benign and malignant liver lesions was higher than the use of any single parameter or the combination of any two of parameters. It is expected that this would provide a tool for the differential diagnosis of benign and malignant liver

lesions.

Sun XL, Yao H, Men Q, Hou KZ, Chen Z, Xu CQ, Liang LW. Combination of acoustic radiation force impulse imaging, serological indexes and contrast-enhanced ultrasound for diagnosis of liver lesions. *World J Gastroenterol* 2017; 23(30): 5602-5609 Available from: URL: <http://www.wjgnet.com/1007-9327/full/v23/i30/5602.htm> DOI: <http://dx.doi.org/10.3748/wjg.v23.i30.5602>

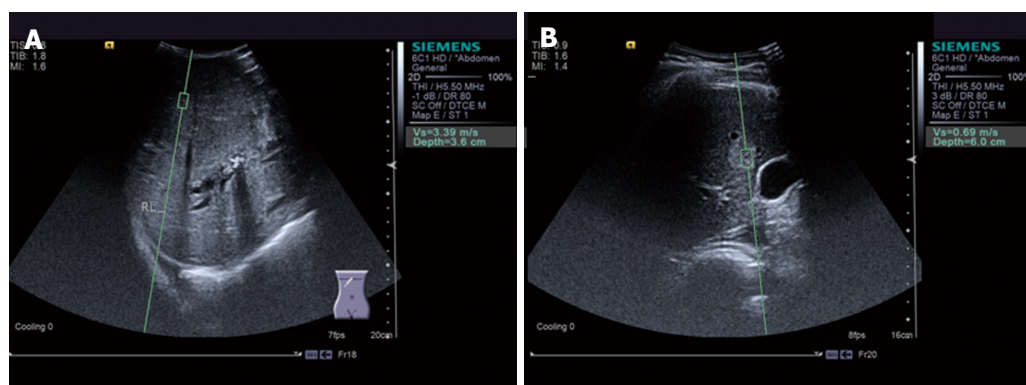
## INTRODUCTION

The gold standard for diagnosis of benign and malignant liver lesions is pathological examination. However, due to its invasive nature and the potential presence of infection, bleeding and other risks, pathological examination is only conducted in patients highly suspected of having malignant liver tumors. In addition, pathological diagnosis has many contraindications and is applicable in only a narrow range of patients. Thus, it is difficult to implement pathological diagnosis as a routine examination. For both benign and malignant liver lesions, detection of serological indicators and contrast-enhanced ultrasonography (CEUS) are routinely performed. Serological indicators alone often have a lower sensitivity and specificity than CEUS and acoustic radiation force impulse (ARFI) imaging. However, for small hepatocellular carcinoma, alpha-fetoprotein (AFP) is the most sensitive indicator<sup>[1,2]</sup>. Although CEUS is a mature examination method, its diagnostic accuracy may be affected by lesion depth, blood flow velocity and respiratory movement, which makes it not suitable for some lesions and patients<sup>[3-9]</sup>. ARFI imaging is simple and highly accepted by patients, and it can quantitatively assess the change in tissue hardness. However, it is vulnerable to biliary and intrahepatic vascular effects<sup>[10-17]</sup>. Although these three kinds of examinations have certain value in identifying benign and malignant lesions, each has its limitations. At present, the diagnostic accuracy of the combination of these three kinds of examinations in identifying benign and malignant liver lesions remains unknown, although the combined diagnosis has been widely used for other diseases. In the present study, by constructing receiver operating characteristic (ROC) curves, we compared the diagnostic accuracy of ARFI imaging, serological indexes and CEUS, alone or in different combinations, in identifying benign and malignant liver lesions, with an aim to provide a reliable tool for the differential diagnosis of benign and malignant liver lesions.

## MATERIALS AND METHODS

### Study subjects

A total of 43 patients with 112 liver lesions treated



**Figure 1** Acoustic radiation force impulse imaging of a liver tumor. A: Acoustic radiation force impulse (ARFI) detection of a malignant liver tumor [shear wave velocity (SWV) = 3.39 m/s]; B: ARFI detection of a benign liver tumor (SWV = 0.69 m/s).

at our hospital from May 2016 to February 2017 were included in this study. Among these patients, 21 were male and 22 were female. The lesion size ranged from 8 mm × 7 mm to 123 mm × 100 mm. The exclusion criteria were: (1) patients in whom shear wave velocity (SWV) values could not be acquired during ARFI imaging; (2) patients who could not tolerate the ultrasound contrast agent or critically ill patients; (3) patients with completely liquefied cystic tumors; and (4) patients with contraindications to liver puncture biopsy. The study was approved by the Ethics Committee of Shanghai Yangpu District East Hospital, and informed consent was obtained from all patients.

### Instruments and methods

**ARFI imaging:** A Siemens Acuson S3000 color Doppler ultrasound system with a 6C-1HD convex array probe (center frequency, 4.0 MHz) was used. First, a whole liver scan was performed using conventional ultrasound to observe the nature of the lesion. Then, this was switched to ARFI mode to avoid biliary ducts within the liver, blood vessels and liquid necrosis. Patients were instructed to completely hold their breath during the examination. Then, SWV measurement was initiated while keeping the probe stationary. This was repeated for 3 to 6 times at the lesion center, and repeated for 3 to 5 times at the periphery of the lesion, with average SWV value calculated.

**CEUS:** CEUS was performed with the same system for ARFI imaging in the contrast mode, with the mechanical index adjusted to the appropriate state. SonoVue suspension (2.0 mL) was administered by bolus injection *via* the elbow vein, followed by rapid injection of 5 mL of normal saline. The patient was breathing steadily throughout the procedure. After imaging, the records were exported. Then, analysis software was used to plot the time intensity curve of the lesion and obtain the initial time, peak time, initial strength, peak intensity and 180-s echo intensity of the lesion. Subsequently, peak acceleration time, intensity increment, enhancement rate, and 180-s

dissipation rate were calculated.

**Serological examination:** An automatic biochemical analyzer was used for the quantitative analysis of the following serological indicators: AFP, serum fucosidase (AFU), alanine aminotransferase (ALT), aspartate aminotransferase (AST),  $\gamma$ -glutamyltranspeptidase (GGT), and alkaline phosphatase (ALP).

### Statistical analysis

SPSS 17.0 statistical software was used for statistical analyses. Measurement data are presented as mean  $\pm$  SD. Comparison of data between groups was performed using two independent samples *t*-test. Indicators with statistically significant differences were used to construct the ROC curves to calculate the area under the curve (AUC), in order to investigate the diagnostic accuracy. Diagnostic accuracy was compared between different combinations to determine the value of combined diagnosis in identifying benign and malignant liver lesions.

## RESULTS

### Pathological results

Pathological or radiological diagnosis confirmed 78 cases of malignant tumors and 34 cases of benign tumors. Among these cases, 18 were primary liver cancer, 60 were metastatic cancer, 16 were hemangiomas, 11 were liver cysts, 5 were adenomas, and 2 were focal nodular hyperplasia.

### Comparison of SWV values between malignant and benign tumor groups

SWV values were significantly higher in the malignant tumor group ( $2.39 \pm 1.20$  m/s, a typical image is shown in Figure 1A) than in the benign tumor group ( $1.50 \pm 0.49$  m/s, a typical image is shown in Figure 1B) ( $P < 0.05$ ; Figure 2).

### Comparison of serological indicators between malignant and benign tumor groups

AFP level was significantly higher in the malignant

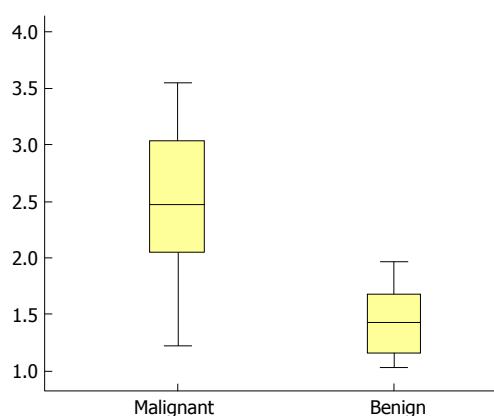
**Table 1** Comparison of serological indicators between the malignant and benign tumor groups

	AFP (ng/mL)	AFU (U/L)	ALT (U/L)	AST (U/L)	GGT (U/L)	ALP (U/L)
Malignant tumor group	18.02 ± 5.01	29.74 ± 14.22	39.01 ± 3.60	46.92 ± 12.11	62.40 ± 27.30	139.40 ± 85.90
Benign tumor group	15.96 ± 4.33	25.61 ± 13.11	37.90 ± 4.33	44.40 ± 11.60	54.90 ± 22.30	117.99 ± 57.30
<i>t</i> -value	2.081	1.446	1.705	1.409	1.409	1.328
<i>P</i> value	0.04	0.151	0.09	0.162	0.162	0.187

AFP: Alpha-fetoprotein; AFU: Serum fucosidase; ALT: Alanine aminotransferase; AST: Aspartate aminotransferase; ALP: Alkaline phosphatase; GGT: Glutamyltranspeptidase.

**Table 2** Comparison of contrast-enhanced ultrasound parameters in the malignant and benign tumor groups

	Start time (s)	Initial strength (dB)	Peak time (s)	Peak intensity (dB)	120s Echo intensity (dB)	Peak acceleration time (s)	Intensity increment (dB)	Enhancement rate (dB/s)	Extinction rate (dB/s)
Malignant tumor group	11.98 ± 2.95	8.35 ± 6.03	30.22 ± 9.65	39.27 ± 6.32	27.33 ± 17.86	17.94 ± 4.64	30.99 ± 6.67	2.24 ± 0.21	0.08 ± 0.07
Benign tumor group	13.01 ± 3.92	6.57 ± 5.66	33.33 ± 11.96	37.77 ± 7.30	32.01 ± 11.96	20.10 ± 10.32	31.22 ± 7.12	2.01 ± 0.31	0.06 ± 0.06
<i>t</i> -value	-1.532	1.463	-1.456	1.101	-1.396	-1.533	-0.164	2.589	1.449
<i>P</i> value	0.128	0.146	0.148	0.273	0.166	0.128	0.870	0.011	0.150



**Figure 2** Shear wave velocity values of the malignant and benign tumor groups. The shear wave velocity of malignant tumors was  $2.39 \pm 1.20$  m/s, while that of benign tumors was  $1.50 \pm 0.49$  m/s.

tumor group than in the benign tumor group ( $P < 0.05$ ), while the differences in AFU, ALT, AST, GGT and ALP levels were not statistically significant ( $P > 0.05$ ) (Table 1).

### Comparison of CEUS indicators between malignant and benign tumor groups

CEUS enhancement rate was significantly higher in the malignant tumor group than in the benign tumor group (a typical image is shown in Figure 3A and B) ( $P < 0.05$ ), while the differences in start time, initial strength, peak time, peak intensity, 180-second echo intensity, peak acceleration time, strength increment, and rate of regression were not statistically significant ( $P > 0.05$ ) (Table 2).

### Diagnostic accuracy of different combinations of SWV value, AFP content and enhancement rate

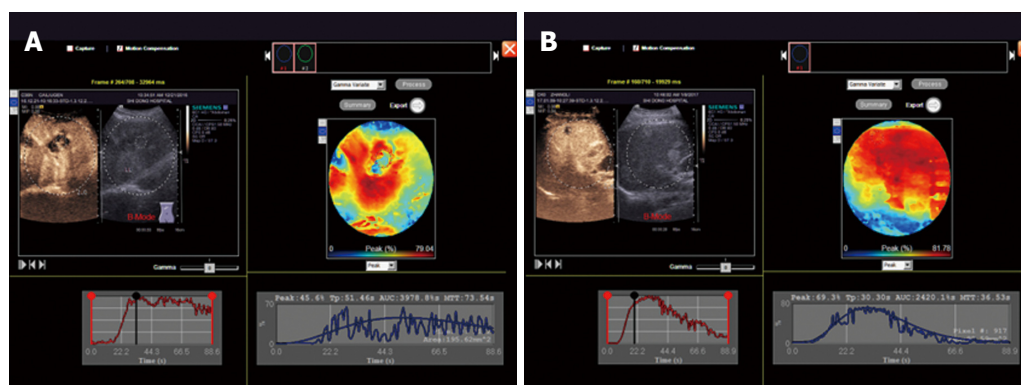
SWV value, AFP content and enhancement rate were combined in the following different ways: SWV value

+ AFP content, SWV value + enhancement rate, AFP content + enhancement rate, and SWV value + AFP content + enhancement rate. Then, the ROC curves were constructed to calculate the AUCs. The AUCs of SWV value alone, AFP content alone, enhancement rate alone, SWV value + AFP content, SWV value + enhancement rate, AFP content + enhancement rate and SWV value + AFP content + enhancement rate were 85.1%, 72.1%, 74.5%, 88.3%, 90.4%, 82.0% and 92.3%, respectively. Taking the maximum value of the Youden index, SWV = 1.60 m/s, AFP = 18.68 ng/mL, and enhancement rate = 2.21 dB/s were determined as the best cut-off values for the diagnosis of benign and malignant liver lesions (Figures 4 and 5). When the cut-off value for the regression coefficient of the SWV value, AFP content and enhancement rate was 0.8711451, it was found that 23 cases were false-negative lesions, which included 11 cases of liver metastases derived from the digestive tract and 12 cases of hepatocellular carcinoma; and there were no false-positive lesions.

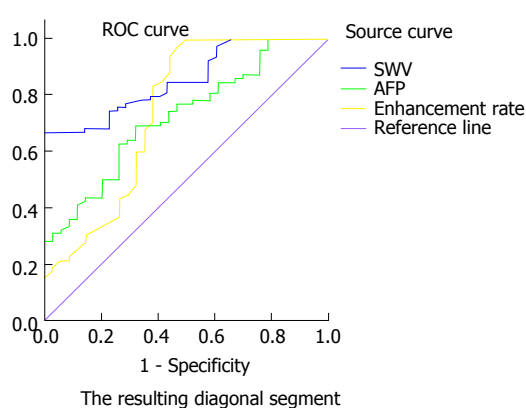
## DISCUSSION

Pathological examination is the gold standard for diagnosing liver lesions. However, patient acceptance is low due to the invasiveness of the examination. Furthermore, pathological examination cannot be routinely used for screening of benign and malignant liver lesions. Serological indicators and CEUS are commonly used noninvasive examinations in clinical practice. However, serological indicators alone have a low sensitivity and specificity, and the CEUS examination process is complex and requires some skills<sup>[18-21]</sup>. ARFI imaging is simple and can quantitatively reflect changes in tissue hardness. Studies have shown that ARFI can be used to diagnose benign and malignant





**Figure 3** Contrast-enhanced ultrasound TIC curves used to detect benign and malignant liver tumors. A: TIC curve for the detection of malignant liver tumors; B: TIC curve for the detection of benign liver tumors.

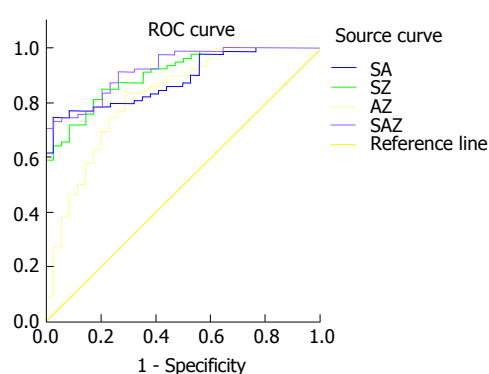


**Figure 4** Comparison of the receiver operating characteristic curves of shear wave velocity, alpha-fetoprotein and enhancement rate for the identification of benign and malignant liver tumors.

liver tumors, but it is easily affected by bile ducts and large blood vessels<sup>[22-29]</sup>. Thus, each of these three types of detection methods has its own advantages and disadvantages. Since the combined diagnosis has been widely used for other diseases at present, we hypothesized that the combination of these three kinds of examinations might have better accuracy in identifying benign and malignant liver lesions. Therefore, we constructed ROC curves to compare the diagnostic efficacy of ARFI imaging, serological indexes and CEUS, alone or in different combinations, in the present study.

#### **Comparison of ARFI, serological parameters, CEUS indicators between malignant and benign tumor groups**

Our results revealed that SWV value, AFP content and CEUS enhancement rate were significantly higher in the malignant tumor group than in the benign tumor group, suggesting that the use of these parameters is feasible for the differential diagnosis of benign and malignant liver lesions. Increased SWV value may indicate increased tumor hardness. This may be due to the richness of the liver cancer substance in tumor cells that sustains growth and promotes the invasion of capillaries, and the chaotic arrangement



**Figure 5** Comparison of the receiver operating characteristic curves of the combination of shear wave velocity value, alpha-fetoprotein content and enhancement rate for identifying benign and malignant liver tumors. SA = SWV value + AFP content; SZ = SWV value + enhancement rate; AZ = AFP content + enhancement rate; SAZ = SWV value + AFP content + enhancement rate.

of tissues that show invasive growth. Hence, activity in the surrounding tissue is limited, because the hardness of malignant liver tumors is greater than that of benign liver tumors. Elevated AFP content may be due to malignant liver cells, in which the AFP gene is re-expressed and AFP is released to blood. CEUS enhancement rate represents the rich blood supply of the tumor, because the number of microvessels per unit volume of malignant tumors is more than that of benign tumors, and the unit time into the malignant tumor contrast agent also increases. Hence, the enhancement rate is higher<sup>[3,4,30-42]</sup>. The difference in AFP and CEUS enhancement rate between benign and malignant liver tumors can be expected, and the difference in SWV value between the two groups suggests that ARFI can also be used for the analysis of benign and malignant liver lesions.

#### **Diagnostic accuracy of SWV value, AFP content and enhancement rate, alone or in different combinations, in distinguishing between malignant and benign tumors**

The results of this study showed that the AUC of SWV value was slightly higher than that of CEUS enhancement rate and significantly higher than that of

AFP content. This finding suggests that the diagnostic value of ARFI is higher than that of CEUS enhancement rate and AFP content and the diagnostic value of ARFI is higher than that of AFP. This might be because the change in the texture of liver lesions is more sensitive than that of AFP content. The diagnostic value of CEUS is less than that of ARFI, and the reason may be that CEUS reflects the hemodynamics of liver lesions, while ARFI reflects changes in tissue hardness. Tissue hardness reflects not only the vascular composition of tissue, but also the interstitial fiber composition of tissue, cell arrangement and other factors. Hence, compared to CEUS, ARFI is more comprehensive and intuitive.

The results of this study showed that the diagnostic accuracy of combined SWV value, AFP content and enhancement rate was slightly higher than that of SWV value plus AFP content and SWV value plus enhancement rate, and significantly higher than that of AFP content plus enhancement rate and any one of the three parameters. When the cut-off value for the regression coefficient of the SWV value, AFP content and enhancement rate was 0.8711451, the best diagnostic performance was achieved. With this cut-off value, the results of this study revealed that nine cases of hepatocellular carcinoma were false-negative lesions, which may have been transformed through liver cirrhosis to stage I liver cancer, in which the tumor composition was less obvious. Furthermore, SWV value and AFP content were low, which may be related to the partial necrosis in the tumor component. These led to the low SWV value, AFP content and enhancement rate regression coefficient, and then the false negative results were obtained. Meanwhile, studies have shown that the stiffness of hepatocellular carcinoma and cholangiocarcinoma is greater than that of liver metastases. Furthermore, metastatic carcinoma derived from the digestive tract has lower hardness, and AFP content is lower than the content of liver parenchyma. This led to low SWV value, AFP content and enhancement rate of regression coefficient, and then false negative results were obtained<sup>[43-51]</sup>.

The results of this study were based on data from a small sample and did not cover all types of malignant and benign liver tumors. Therefore, the results of this study should be explained with caution, especially in clinical settings. However, the clinical pathological types of liver lesions studied in this study are common and have certain representative significance. Multi-center studies with a larger sample should be performed to verify our findings.

In summary, the diagnostic performance of combined ARFI, AFP and contrast-enhanced ultrasound in distinguishing between benign and malignant liver lesions was higher than the use of any single parameter or the combination of any two of parameters. It is expected that this would provide a tool for the differential diagnosis of benign and malignant liver lesions.

## COMMENTS

### Background

The gold standard for identifying benign and malignant liver lesions is pathological diagnosis. However, due to its invasiveness, the presence of infection, bleeding and other risks, pathological examination may cause body damage. Hence, pathological examination is only suitable for patients with suspected liver malignancy. In addition, pathological diagnosis has many contraindications and is applicable in only a narrow range of patients. Thus, it is difficult to implement pathological diagnosis as a routine examination.

### Research frontiers

Serological indicators and contrast-enhanced ultrasound (CEUS) are noninvasive routine examinations for both benign and malignant liver lesions. Serological indicators alone have a low specificity and sensitivity. CEUS is a well-established examination method; however, it is relatively complex to operate and has high technical requirements, and some patients cannot tolerate the contrast agent. Acoustic radiation force impulse (ARFI) imaging is simple to operate, has high patient acceptance, and can quantitatively reflect the change in tissue hardness; however, it is easily affected by bile ducts and large blood vessels. The diagnostic value of the combined of ARFI imaging, serological indicators, and CEUS remains unclear.

### Innovations and breakthroughs

Although ARFI imaging, serological indexes and CEUS have certain value in identifying benign and malignant lesions, each has its limitations. At present, the diagnostic accuracy of the combination of these three kinds of examinations in identifying benign and malignant liver lesions remains unknown, although the combined diagnosis has been widely used for other diseases. The results of this study showed that the diagnostic performance of combined ARFI, serum alpha-fetoprotein (AFP) and contrast-enhanced ultrasound in distinguishing between benign and malignant liver lesions was higher than the use of any single parameter or the combination of any two of parameters.

### Applications

It is expected that the combination of ARFI imaging, serological indicators and CEUS would provide a tool for the differential diagnosis of benign and malignant liver lesions.

### Peer-review

The combination of acoustic radiation force impulse imaging, serological indicators, and contrast-enhanced ultrasound has high accuracy in identifying benign and malignant liver lesions. This result should be confirmed by large multi-center studies, in order to better promote its clinical use.

## REFERENCES

- 1 **Park SJ**, Jang JY, Jeong SW, Cho YK, Lee SH, Kim SG, Cha SW, Kim YS, Cho YD, Kim HS, Kim BS, Park S, Bang HI. Usefulness of AFP, AFP-L3, and PIVKA-II, and their combinations in diagnosing hepatocellular carcinoma. *Medicine* (Baltimore) 2017; **96**: e5811 [PMID: 28296720 DOI: 10.1097/md.00000000000005811]
- 2 **Best J**, Bilgi H, Heider D, Schotten C, Manka P, Bedreli S, Gorray M, Ertle J, van Grunsven LA, Dechêne A. The GALAD scoring algorithm based on AFP, AFP-L3, and DCP significantly improves detection of BCLC early stage hepatocellular carcinoma. *Z Gastroenterol* 2016; **54**: 1296-1305 [PMID: 27936479 DOI: 10.1055/s-0042-119529]
- 3 **D'Onofrio M**, Romanini L, Serra C, Magnolfi F, Bertolotto M, Quaia E, Puntel G, Colleoni A, Fiorini E, Cenci C, Santi E, Ciaravino V, Laffranchi F, Catalano O, Cantisani V, Calliada F, Derchi L. Contrast enhancement ultrasound application in focal liver lesions characterization: a retrospective study about guidelines application (SOCEUS-CEUS survey). *J Ultrasound* 2015; **19**: 99-106 [PMID: 27298641 DOI: 10.1007/s40477-015-0185-y]
- 4 **Iwamoto T**, Imai Y, Kogita S, Igura T, Sawai Y, Fukuda K, Yamaguchi Y, Matsumoto Y, Nakahara M, Morimoto O, Seki Y, Ohashi H, Fujita N, Kudo M, Takehara T. Comparison of

- Contrast-Enhanced Ultrasound and Gadolinium-Ethoxybenzyl-Diethylenetriamine Pentaacetic Acid-Enhanced MRI for the Diagnosis of Macroscopic Type of Hepatocellular Carcinoma. *Dig Dis* 2016; **34**: 679-686 [PMID: 27750237 DOI: 10.1159/000448855]
- 5 **Kondo S**, Takagi K, Nishida M, Iwai T, Kudo Y, Ogawa K, Kamiyama T, Shibuya H, Kahata K, Shimizu C. Computer-Aided Diagnosis of Focal Liver Lesions Using Contrast-Enhanced Ultrasonography with Perflubutane Microbubbles. *IEEE Trans Med Imaging* 2017; **36**: 1427-1437 [PMID: 28141517 DOI: 10.1109/TMI.2017.2659734]
  - 6 **Loria F**, Loria G, Basile S, Crea G, Frosina L, Di Carlo I. Contrast-enhanced ultrasound appearances of enhancement patterns of intrahepatic cholangiocarcinoma: correlation with pathological findings. *Updates Surg* 2014; **66**: 135-143 [PMID: 24802031 DOI: 10.1007/s13304-014-0251-6]
  - 7 **Roche V**, Pigneur F, Tselikas L, Roux M, Baranes L, Djabbari M, Costentin C, Calderaro J, Laurent A, Rahmouni A, Luciani A. Differentiation of focal nodular hyperplasia from hepatocellular adenomas with low-mechanical-index contrast-enhanced sonography (CEUS): effect of size on diagnostic confidence. *Eur Radiol* 2015; **25**: 186-195 [PMID: 25120205 DOI: 10.1007/s00330-014-3363-y]
  - 8 **Sparchez Z**, Mocan T, Radu P, Anton O, Bolog N. Contrast enhanced ultrasonography in assessing the treatment response to transarterial chemoembolization in patients with hepatocellular carcinoma. *Med Ultrason* 2016; **18**: 96-102 [PMID: 26962561 DOI: 10.11152/mu.2013.2066.181.scz]
  - 9 **Tselikas L**, Pigneur F, Roux M, Baranes L, Costentin C, Roche V, Calderaro J, Herin E, Laurent A, Zafrani E, Azoulay D, Mallat A, Rahmouni A, Luciani A. Impact of hepatobiliary phase liver MRI versus Contrast-Enhanced Ultrasound after an inconclusive extracellular gadolinium-based contrast-enhanced MRI for the diagnosis of benign hepatocellular tumors. *Abdom Radiol (NY)* 2017; **42**: 825-832 [PMID: 27704147 DOI: 10.1007/s00261-016-0921-6]
  - 10 **Bao Z**, Gu L, Liu J, Wei L, Ye Z. [Clinical value of acoustic radiation force impulse elastography in differential diagnosis of focal liver lesions]. *Zhonghua Ganzangbing Zazhi* 2016; **24**: 123-126 [PMID: 26983480]
  - 11 **Cho SH**, Lee JY, Han JK, Choi BI. Acoustic radiation force impulse elastography for the evaluation of focal solid hepatic lesions: preliminary findings. *Ultrasound Med Biol* 2010; **36**: 202-208 [PMID: 20018432 DOI: 10.1016/j.ultrasmedbio.2009.10.009]
  - 12 **Davies G**, Koenen M. Acoustic radiation force impulse elastography in distinguishing hepatic haemangiomas from metastases: preliminary observations. *Br J Radiol* 2011; **84**: 939-943 [PMID: 21385910 DOI: 10.1259/bjr/97637841]
  - 13 **Fahey BJ**, Nelson RC, Hsu SJ, Bradway DP, Dumont DM, Trahey GE. In vivo guidance and assessment of liver radio-frequency ablation with acoustic radiation force elastography. *Ultrasound Med Biol* 2008; **34**: 1590-1603 [PMID: 18471954 DOI: 10.1016/j.ultrasmedbio.2008.03.006]
  - 14 **Frulio N**, Laumonier H, Carteret T, Laurent C, Maire F, Balabaud C, Bioulac-Sage P, Trillaud H. Evaluation of liver tumors using acoustic radiation force impulse elastography and correlation with histologic data. *J Ultrasound Med* 2013; **32**: 121-130 [PMID: 23269717]
  - 15 **Gallotti A**, D'Onofrio M, Romanini L, Cantisani V, Pozzi Mucelli R. Acoustic Radiation Force Impulse (ARFI) ultrasound imaging of solid focal liver lesions. *Eur J Radiol* 2012; **81**: 451-455 [PMID: 21330078 DOI: 10.1016/j.ejrad.2010.12.071]
  - 16 **Goya C**, Hamidi C, Yavuz A, Hattapoglu S, Uslukaya O, Cetincakmak MG, Teke M, Urakci Z. The Role of Acoustic Radiation Force Impulse Elastography in the Differentiation of Infectious and Neoplastic Liver Lesions. *Ultrason Imaging* 2015; **37**: 312-322 [PMID: 25568051 DOI: 10.1177/0161734614566697]
  - 17 **Heide R**, Strobel D, Bernatik T, Goertz RS. Characterization of focal liver lesions (FLL) with acoustic radiation force impulse (ARFI) elastometry. *Ultraschall Med* 2010; **31**: 405-409 [PMID: 20652853 DOI: 10.1055/s-0029-1245565]
  - 18 **Chen L**, Chu F, Cao Y, Shao J, Wang F. Serum miR-182 and miR-331-3p as diagnostic and prognostic markers in patients with hepatocellular carcinoma. *Tumour Biol* 2015; **36**: 7439-7447 [PMID: 25903466 DOI: 10.1007/s13277-015-3430-2]
  - 19 **Chen QW**, Cheng CS, Chen H, Ning ZY, Tang SF, Zhang X, Zhu XY, Vargulick S, Shen YH, Hua YQ, Xie J, Shi WD, Gao HF, Xu LT, Feng LY, Lin JH, Chen Z, Liu LM, Ping B, Meng ZQ. Effectiveness and complications of ultrasound guided fine needle aspiration for primary liver cancer in a Chinese population with serum  $\alpha$ -fetoprotein levels  $\leq 200$  ng/ml--a study based on 4,312 patients. *PLoS One* 2014; **9**: e101536 [PMID: 25170868 DOI: 10.1371/journal.pone.0101536]
  - 20 **Cui Z**, Yu X, Guo L, Wei Y, Zheng S, Li W, Chen P, Zhu J, Peng J. Combined analysis of serum alpha-fetoprotein and MAGE-A3-specific cytotoxic T lymphocytes in peripheral blood for diagnosis of hepatocellular carcinoma. *Dis Markers* 2013; **35**: 915-923 [PMID: 24427779]
  - 21 **Song P**, Feng X, Inagaki Y, Song T, Zhang K, Wang Z, Zheng S, Ma K, Li Q, Kong D, Wu Q, Zhang T, Zhao X, Hasegawa K, Sugawara Y, Kokudo N, Tang W; Japan-China Joint Team for Medical Research and Cooperation on HCC. Clinical utility of simultaneous measurement of alpha-fetoprotein and des- $\gamma$ -carboxy prothrombin for diagnosis of patients with hepatocellular carcinoma in China: A multi-center case-controlled study of 1,153 subjects. *Biosci Trends* 2014; **8**: 266-273 [PMID: 25382443]
  - 22 **Kim JE**, Lee JY, Bae KS, Han JK, Choi BI. Acoustic radiation force impulse elastography for focal hepatic tumors: usefulness for differentiating hemangiomas from malignant tumors. *Korean J Radiol* 2013; **14**: 743-753 [PMID: 24043967 DOI: 10.3348/kjr.2013.14.5.743]
  - 23 **Kwon HJ**, Kang MJ, Cho JH, Oh JY, Nam KJ, Han SY, Lee SW. Acoustic radiation force impulse elastography for hepatocellular carcinoma-associated radiofrequency ablation. *World J Gastroenterol* 2011; **17**: 1874-1878 [PMID: 21528062 DOI: 10.3748/wjg.v17.i14.1874]
  - 24 **Mărginean CO**, Brănzaniuc K, Mărginean C, Azamfîre L, Pitea AM. Elastography, progression factor in liver ultrasound. *Rev Med Chir Soc Med Nat Iasi* 2010; **114**: 764-770 [PMID: 21235119]
  - 25 **Rizzo L**, Nunnari G, Berretta M, Cacopardo B. Acoustic Radial Force Impulse as an effective tool for a prompt and reliable diagnosis of hepatocellular carcinoma - preliminary data. *Eur Rev Med Pharmacol Sci* 2012; **16**: 1596-1598 [PMID: 23111977]
  - 26 **Shuang-Ming T**, Ping Z, Ying Q, Li-Rong C, Ping Z, Rui-Zhen L. Usefulness of acoustic radiation force impulse imaging in the differential diagnosis of benign and malignant liver lesions. *Acad Radiol* 2011; **18**: 810-815 [PMID: 21419668 DOI: 10.1016/j.acra.2011.01.026]
  - 27 **Vermehren J**, Polta A, Zimmermann O, Herrmann E, Poynard T, Hofmann WP, Bojunga J, Sarrazin C, Zeuzem S, Friedrich-Rust M. Comparison of acoustic radiation force impulse imaging with transient elastography for the detection of complications in patients with cirrhosis. *Liver Int* 2012; **32**: 852-858 [PMID: 22222050 DOI: 10.1111/j.1478-3231.2011.02736.x]
  - 28 **Ying L**, Lin X, Xie ZL, Tang FY, Hu YP, Shi KQ. Clinical utility of acoustic radiation force impulse imaging for identification of malignant liver lesions: a meta-analysis. *Eur Radiol* 2012; **22**: 2798-2805 [PMID: 22772145 DOI: 10.1007/s00330-012-2540-0]
  - 29 **Yu H**, Wilson SR. Differentiation of benign from malignant liver masses with Acoustic Radiation Force Impulse technique. *Ultrasound Q* 2011; **27**: 217-223 [PMID: 22124386 DOI: 10.1097/RUQ.0b013e318239422e]
  - 30 **Dong Y**, Wang WP, Mao F, Ji ZB, Huang BJ. Application of imaging fusion combining contrast-enhanced ultrasound and magnetic resonance imaging in detection of hepatic cellular carcinomas undetectable by conventional ultrasound. *J Gastroenterol Hepatol* 2016; **31**: 822-828 [PMID: 26480287 DOI: 10.1111/jgh.13202]
  - 31 **Dong Y**, Zhu Z, Wang WP, Mao F, Ji ZB. Ultrasound features of hepatocellular adenoma and the additional value of contrast-enhanced ultrasound. *Hepatobiliary Pancreat Dis Int* 2016; **15**: 48-54 [PMID: 26818543]

- 32 **Kong WT**, Ji ZB, Wang WP, Cai H, Huang BJ, Ding H. Evaluation of Liver Metastases Using Contrast-Enhanced Ultrasound: Enhancement Patterns and Influencing Factors. *Gut Liver* 2016; **10**: 283-287 [PMID: 26586554 DOI: 10.5009/gnl14324]
- 33 **Li R**, Tang CL, Cai P, Ma KS, Zhang XH, Ding SY, Zhang Y, Guo DY, Yan XC. Comparison of CT and contrast-enhanced ultrasound findings in hepatic angiomyolipoma with pathological correlations. *Abdom Radiol (NY)* 2016; **41**: 248-256 [PMID: 26867906 DOI: 10.1007/s00261-015-0571-0]
- 34 **Liang X**, Lin L, Cao Q, Huang R, Wang Y. Recognizing Focal Liver Lesions in CEUS With Dynamically Trained Latent Structured Models. *IEEE Trans Med Imaging* 2016; **35**: 713-727 [PMID: 26513779 DOI: 10.1109/tmi.2015.2492618]
- 35 **Liu JJ**, Li HX, Chen ZB, Yang WP, Zhao SF, Chen J, Bai T, Li H, Li LQ. Consistency analysis of contrast-enhanced ultrasound and contrast-enhanced CT in diagnosis of small hepatocellular carcinoma. *Int J Clin Exp Med* 2015; **8**: 21466-21471 [PMID: 26885093]
- 36 **Menozi G**, Maccabruni V, Marini G, Froio E, Garlassi E. Contrast-enhanced ultrasound (CEUS) appearance of hepatic myelolipoma. *J Ultrasound* 2014; **19**: 61-65 [PMID: 26941876 DOI: 10.1007/s40477-014-0137-y]
- 37 **Seitz K**, Strobel D. A Milestone: Approval of CEUS for Diagnostic Liver Imaging in Adults and Children in the USA. *Ultraschall Med* 2016; **37**: 229-232 [PMID: 27276056 DOI: 10.1055/s-0042-107411]
- 38 **Shiozawa K**, Watanabe M, Ikehara T, Matsukiyo Y, Kogame M, Shinohara M, Kikuchi Y, Shinohara M, Igarashi Y, Sumino Y. [Evaluation of Sorafenib for Hepatocellular Carcinoma with Low  $\alpha$ -Fetoprotein by Arrival Time Parametric Imaging Using Contrast-Enhanced Ultrasonography with Sonazoid]. *Gan To Kagaku Ryoho* 2016; **43**: 215-218 [PMID: 27067685]
- 39 **Sirli R**, Sporea I, Săndulescu DL, Popescu A, Dănilă M, Săftoiu A, Spârchez Z, Badea R. Contrast enhanced ultrasound for the diagnosis of liver hemangiomas - results of a Romanian multicentre study. *Med Ultrason* 2015; **17**: 444-450 [PMID: 26649337 DOI: 10.11152/mu.2013.2066.174.csu]
- 40 **Spârchez Z**, Radu P, Kacso G, Spârchez M, Zaharia T, Al Hajjar N. Prospective comparison between real time contrast enhanced and conventional ultrasound guidance in percutaneous biopsies of liver tumors. *Med Ultrason* 2015; **17**: 456-463 [PMID: 26649339 DOI: 10.11152/mu.2013.2066.174.deu]
- 41 **Sugimori K**, Numata K, Okada M, Nihonmatsu H, Takebayashi S, Maeda S, Nakano M, Tanaka K. Central vascular structures as a characteristic finding of regenerative nodules using hepatobiliary phase gadolinium ethoxybenzyl diethylenetriaminepentaacetic acid-enhanced MRI and arterial dominant phase contrast-enhanced US. *J Med Ultrason* (2001) 2017; **44**: 89-100 [PMID: 27771842 DOI: 10.1007/s10396-016-0750-9]
- 42 **Yang W**, Yan K, Wang S, Dai Y, Wu W, Yin SS, Chen MH. Differential Diagnosis of Arterial Phase Enhanced Hepatic Inflammatory Lesions and Hepatocellular Carcinomas with Contrast-enhanced Ultrasound. *Ultrasound Med Biol* 2016; **42**: 82-91 [PMID: 26456578 DOI: 10.1016/j.ultrasmedbio.2015.07.014]
- 43 **Beyer LP**, Pregler B, Wiesinger I, Stroszczynski C, Wiggermann P, Jung EM. Continuous dynamic registration of microvascularization of liver tumors with contrast-enhanced ultrasound. *Radiol Res Pract* 2014; **2014**: 347416 [PMID: 24991432 DOI: 10.1155/2014/347416]
- 44 **Corvino A**, Catalano O, Setola SV, Sandomenico F, Corvino F, Petrillo A. Contrast-enhanced ultrasound in the characterization of complex cystic focal liver lesions. *Ultrasound Med Biol* 2015; **41**: 1301-1310 [PMID: 25666723 DOI: 10.1016/j.ultrasmedbio.2014.12.667]
- 45 **Gatos I**, Tsantis S, Spiliopoulos S, Skouroliaou A, Theotokas I, Zoumpoulis P, Hazle JD, Kagadis GC. A new automated quantification algorithm for the detection and evaluation of focal liver lesions with contrast-enhanced ultrasound. *Med Phys* 2015; **42**: 3948-3959 [PMID: 26133595 DOI: 10.1118/1.4921753]
- 46 **Liu J**, Wang D, Li H, Li H, Zhou T, Zhao S, Ding Z. Clinical Value of Contrast-Enhanced Ultrasound in Diagnosis of Hyperechoic Liver Lesions. *Med Sci Monit* 2015; **21**: 2845-2850 [PMID: 26394170 DOI: 10.12659/msm.894115]
- 47 **Lyu P**, Li S, Xu H, Xu L, Lyu J, Shou J, Zhao B. [Application value of contrast-enhanced ultrasonography for assessing the high-risk population of hepatic malignant tumor]. *Zhonghua Zhongliu Zazhi* 2015; **37**: 545-548 [PMID: 26463334]
- 48 **Pschierer K**, Grothues D, Rennert J, da Silva NP, Schreyer AG, Melter M, Stroszczynski C, Jung EM. Evaluation of the diagnostic accuracy of CEUS in children with benign and malignant liver lesions and portal vein anomalies. *Clin Hemorheol Microcirc* 2015; **61**: 333-345 [PMID: 26444615 DOI: 10.3233/ch-152003]
- 49 **Sporea I**, Martie A, Bota S, Sirli R, Popescu A, Dănilă M. Characterization of focal liver lesions using contrast enhanced ultrasound as a first line method: a large monocentric experience. *J Gastrointestin Liver Dis* 2014; **23**: 57-63 [PMID: 24689098 DOI: 10.3748/wjg.v20.i13.3590]
- 50 **Tarantino L**, Ambrosino P, Di Minno MN. Contrast-enhanced ultrasound in differentiating malignant from benign portal vein thrombosis in hepatocellular carcinoma. *World J Gastroenterol* 2015; **21**: 9457-9460 [PMID: 26327753 DOI: 10.3748/wjg.v21.i32.9457]
- 51 **Kim TK**, Jang HJ. Contrast-enhanced ultrasound in the diagnosis of nodules in liver cirrhosis. *World J Gastroenterol* 2014; **20**: 3590-3596 [PMID: 24707142 DOI: 10.3748/wjg.v20.i13.3590]

**P- Reviewer:** Hoetker MS, Meropol NJ **S- Editor:** Qi Y  
**L- Editor:** Wang TQ **E- Editor:** Li D





## Prospective Study

# Incidents and adverse events of endoscopic ultrasound-guided fine-needle aspiration for pancreatic cystic lesions

Chen Du, Ning-Li Chai, En-Qiang Linghu, Hui-Kai Li, Yu-Fa Sun, Wei Xu, Xiang-Dong Wang, Ping Tang, Jing Yang

Chen Du, Ning-Li Chai, En-Qiang Linghu, Hui-Kai Li, Xiang-Dong Wang, Ping Tang, Jing Yang, Department of Gastroenterology and Hepatology, Chinese PLA General Hospital, Beijing 100853, China

Yu-Fa Sun, Wei Xu, Department of Health Care, Central Guard Bureau, Beijing 100034, China

**Author contributions:** Chai NL, Linghu EQ and Li HK designed the research; Du C, Chai NL, Linghu EQ, Li HK, Sun YF, Xu W, Wang XD, Tang P and Yang J performed the research; Du C analyzed the data; and Du C wrote the paper.

**Institutional review board statement:** The clinical trial described in this paper was reviewed and approved by the Committee of Medical Ethics of Chinese PLA General Hospital.

**Clinical trial registration statement:** The study is registered at <http://www.chictr.org.cn/showproj.aspx?proj=10604>. The registration identification number is ChiCTR-OOC-15006118.

**Informed consent statement:** All study participants, or their legal guardian, provided informed written consent prior to study enrollment.

**Conflict-of-interest statement:** There are no conflicts of interest in relation to this manuscript.

**Data sharing statement:** There are no additional data available in relation to this manuscript.

**Open-Access:** This article is an open-access article which was selected by an in-house editor and fully peer-reviewed by external reviewers. It is distributed in accordance with the Creative Commons Attribution Non Commercial (CC BY-NC 4.0) license, which permits others to distribute, remix, adapt, build upon this work non-commercially, and license their derivative works on different terms, provided the original work is properly cited and the use is non-commercial. See: <http://creativecommons.org/licenses/by-nc/4.0/>

Manuscript source: Unsolicited manuscript

**Correspondence to:** En-Qiang Linghu, MD, Department of Gastroenterology, Chinese PLA General Hospital, No. 28, Fuxing Road, Haidian District, Beijing 100853, China. [linghuenqiang@vip.sina.com](mailto:linghuenqiang@vip.sina.com)  
Telephone: +86-10-68182255-499292  
Fax: +86-10-55499292

Received: April 15, 2017

Peer-review started: April 15, 2017

First decision: June 1, 2017

Revised: June 12, 2017

Accepted: June 18, 2017

Article in press: June 19, 2017

Published online: August 14, 2017

## Abstract

### AIM

To evaluate the diagnostic value and safety mainly regarding incidents of endoscopic ultrasound-guided fine-needle aspiration (EUS-FNA) for pancreatic cystic lesions (PCLs).

### METHODS

A total of 150 consecutive patients with suspected PCLs were prospectively enrolled from April 2015 to November 2016. We finally enrolled 140 patients undergoing EUS-FNA. We compared the diagnostic accuracy of EUS-FNA and pathological diagnosis, which is regarded as the gold standard, for PCLs. Patients undergoing EUS-FNA at least 1 wk preoperatively were monitored for incidents and adverse events to evaluate its safety.

### RESULTS

There were 88 (62.9%) women and 52 (37.1%) men among 140 patients, with a mean age of 50.1 ( $\pm$  15.4) years. There were 67 cysts located in the head/

uncinate of the pancreas and 67 in the body/tail, and 6 patients had at least 1 cyst in the pancreas. There were 75 patients undergoing surgery and 55 undergoing EUS-FNA with interval at least 1 wk before other operations, with 3 patients undergoing the procedure twice. The accuracy of EUS-FNA in differentiating benign and malignant lesions was 97.3% (73/75), while the accuracy of characterizing PCL subtype was 84.0% (63/75). The incident rate was 37.9% (22/58), whereas only 1 AE was observed in 58 cases.

### CONCLUSION

EUS-FNA is effective and safe for diagnosis of PCLs, however procedure-related incidents are common. Caution should be taken in patients undergoing EUS-FNA.

**Key words:** Endoscopic ultrasound; Incident; Fine-needle aspiration; Pancreatic cystic lesion

© The Author(s) 2017. Published by Baishideng Publishing Group Inc. All rights reserved.

**Core tip:** Incidents are self-limiting and do not change therapy. Adverse events (AEs) of endoscopic ultrasound-guided fine-needle aspiration (EUS-FNA) have attracted attention, whereas incidents are almost ignored. Although incidents do not interfere with procedures and treatment, documenting them might improve procedural quality and prediction of AEs. Our study was designed to evaluate the diagnostic value and safety mainly regarding incidents of EUS-FNA. We found the accuracy of EUS-FNA in differentiating benign and malignant lesions and characterizing pancreatic cystic lesions subtype was high. The AE rate was low, however procedure-related incidents are common and should be paid attention to.

Du C, Chai NL, Linghu EQ, Li HK, Sun YF, Xu W, Wang XD, Tang P, Yang J. Incidents and adverse events of endoscopic ultrasound-guided fine-needle aspiration for pancreatic cystic lesions. *World J Gastroenterol* 2017; 23(30): 5610-5618 Available from: URL: <http://www.wjgnet.com/1007-9327/full/v23/i30/5610.htm> DOI: <http://dx.doi.org/10.3748/wjg.v23.i30.5610>

### INTRODUCTION

Pancreatic cystic lesions (PCLs) are becoming increasingly prevalent, with increased diagnosis related to the wide use of abdominal cross-sectional imaging. The incidence of asymptomatic cysts ranges from 0.7% to 24.3%<sup>[1-5]</sup>. With a broad differential diagnosis, PCLs are mainly divided into benign non-neoplastic cysts and neoplastic cysts, some of which have malignant potential or are of low malignancy. The frequency of malignancy among mucinous cystic neoplasms (MCNs) and intraductal papilla mucinous neoplasms (IPMNs) which are subtypes of neoplastic cysts, ranges from

3.9% to 81%<sup>[6]</sup>, while the 2-year survival rate of malignant PCLs is as low as 10%<sup>[7]</sup>.

Correct diagnosis and accurate classification of PCLs are important for making treatment decision. Endoscopic ultrasound (EUS) has high spatial resolution, and EUS-guided fine-needle aspiration (EUS-FNA) contributes to diagnosis by providing cystic fluid examination, cytology and biopsy<sup>[8]</sup>. EUS-FNA is the predominant method for diagnosis of PCLs<sup>[9,10]</sup>. However, compared with computed tomography (CT) and magnetic resonance imaging (MRI), EUS-FNA is an invasive operation. It is the top priority to ensure the safety of EUS-FNA.

Incidents are unplanned events that have no influence on completion of an operation and post-operative treatment, and adverse events (AEs) are defined as events that prevent completion of or change to the planned procedure<sup>[11]</sup>. Incidents are self-limiting and do not change therapy. AEs have attracted attention, whereas incidents are almost ignored. Although incidents do not interfere with procedures and treatment, documenting them might improve procedural quality and predict AEs.

There have been many studies on the safety and diagnostic accuracy of EUS-FNA for PCLs, but there have been few studies regarding the incidents related to this procedure. Our study was designed to evaluate the diagnostic value and safety mainly regarding incidents of EUS-FNA.

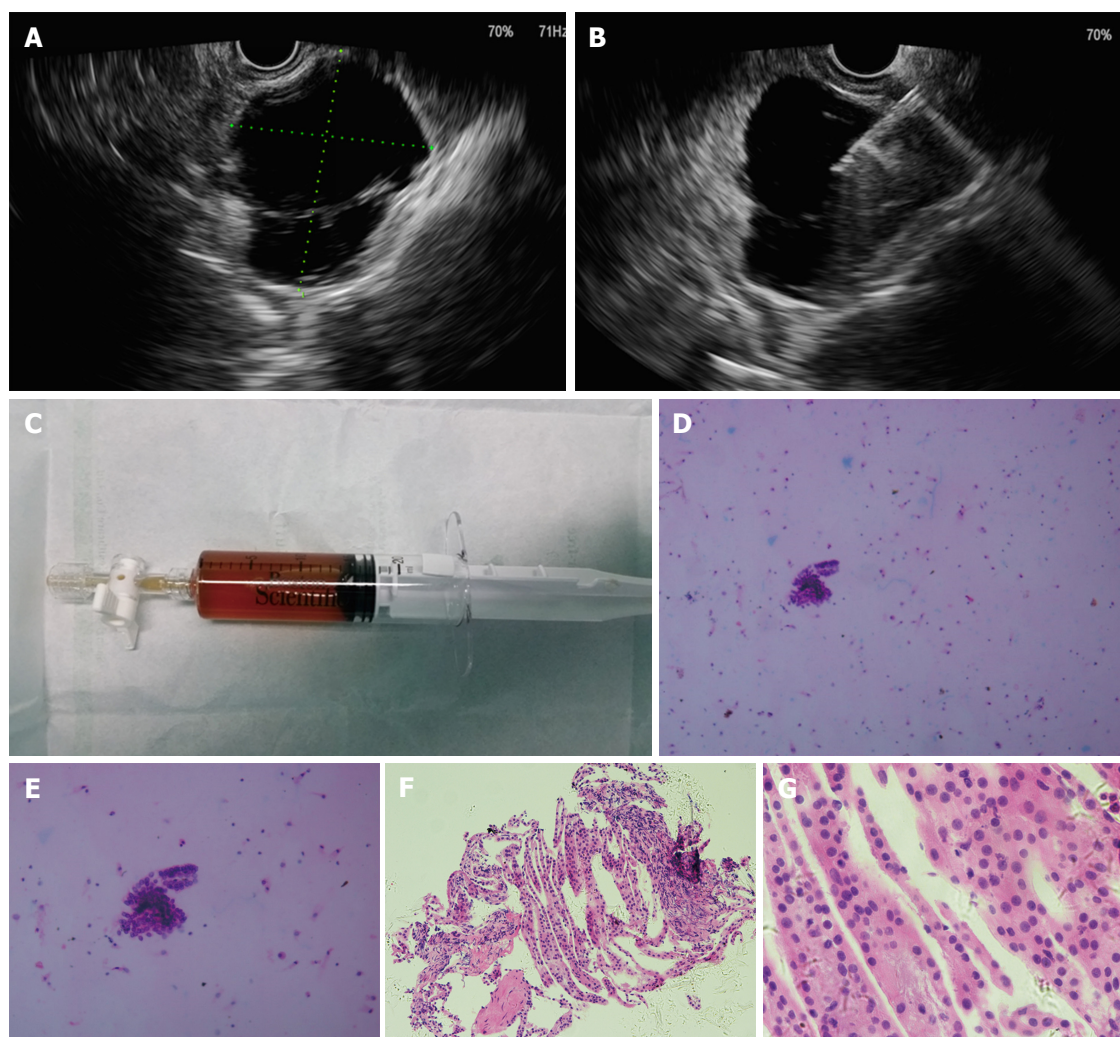
### MATERIALS AND METHODS

#### Patients

We prospectively enrolled 150 consecutive patients with suspected PCLs from April 2015 to November 2016. Excluding 10 patients who did not undergo EUS-FNA, we finally enrolled 140 patients. The indications for EUS-FNA were: (1) indeterminate PCLs in radiological imaging studies; (2) easier and safer access to the cyst; (3) age  $\geq$  18 years; and (4) signed informed consent. The following exclusion criteria were used: (1) reluctance to receive EUS-FNA or inability to sign informed consent independently; (2) high risk for operation, or pregnancy; (3) evidence of active acute pancreatitis, pancreatic necrosis or pseudocyst; and (4) coagulopathy (international normalized ratio  $>$  1.5, platelets  $<$  50000). When evaluating the diagnostic value, only the patients who underwent surgery were enrolled. When evaluating the safety of EUS-FNA, patients who did not undergo any other operation  $>$  1 wk after EUS-FNA were studied.

#### Study design

Patients with suspected PCLs by imaging examination were requested to undergo EUS examination and EUS-FNA. The EUS and EUS-FNA procedures were performed by experts with  $>$  10 years' experience. Some patients underwent other operations, like surgery,



**Figure 1** The procedures of endoscopic ultrasound-guided fine-needle aspiration. A: Endoscopic ultrasound view of the cyst, showing a 46.0 mm<sup>2</sup> × 39.0 mm<sup>2</sup> cyst in pancreatic neck; B: Puncture of the cyst with a 19-gauge needle and aspiration of the cystic fluid; C: Specimen of cystic fluid, sent for cytology and biochemical analysis; D: Histopathological image of cystic fluid cytology, diagnosed with serous cystic neoplasm (H and E, × 100); E: Histopathological image of cystic fluid cytology (H and E, × 200); F: Histopathological image of biopsy of the cystic wall of the same cyst (H and E, × 10); G: Histopathological image of biopsy of the cystic wall of the same cyst (H and E, × 40).

EUS-guided ablation and endoscopic retrograde cholangiopancreatography, after the EUS-FNA. The presumed endoscopic diagnosis was made after taking EUS and cystic fluid examination findings into consideration. The diagnostic accuracy of EUS-FNA was compared with pathological diagnosis, which is regarded as the gold standard for diagnosis of PCL.

Patients undergoing EUS-FNA ≥ 1 wk before other operations were monitored for incidents and AEs to evaluate safety; therefore, patients who underwent other operations < 1 wk after EUS-FNA were excluded when evaluating the incident and AE rates. Any symptoms and signs of abdominal pain, fever, bleeding, nausea, infection, acute pancreatitis, perforation and hyperamylasemia, were recorded. Patients were monitored on the ward for ≥ 3 d and discharged when they did not feel any discomfort. If they were hospitalized for < 7 d, we followed them up by telephone to document incidents and AEs that

might have arisen.

### Endoscopic procedures

All patients with suspected PCLs underwent EUS evaluation with a liner-array echoendoscope (Prosound F75; Aloka, Tokyo, Japan, and GF-UCT260; Olympus, Tokyo, Japan) under intravenous anesthesia. The lesions were characterized by size, location, wall thickness, number of septa, morphology of the pancreatic duct, and presence of papilla or associated mass. Transgastric or transduodenal puncture of the cyst was done using a 22-gauge or 19-gauge needle (Echotip; Cook, Limerick, Ireland) and cystic fluid was aspirated. If the cystic fluid was too viscous for aspiration, 0.9% normal saline solution was used to decrease the viscosity of the cyst. The cyst fluid was sent for cytology and biochemical analysis. Biopsy of the cystic wall through a fine needle was done if necessary. The procedures are shown in Figure 1.



**Table 1** Baseline characteristics of 140 patients suspected of pancreatic cystic lesions

Characteristic	Result <sup>1</sup>
Age, yr	50.1 ± 15.4
Sex	
Female	88 (62.9)
Male	52 (37.1)
Cyst location	
Head/uncinate	67 (47.9)
Body/tail	67 (47.8)
Multiple cysts	6 (4.3)
Pathological diagnosis	
Neoplastic cyst	70
MCN	25
SCN	27
SPN	7
IPMN	8
NEN	1
Cystadenocarcinoma	2
Non-neoplastic cyst	5
Pseudo cyst	2
True cyst	2
Cystic tuberculosis	1

<sup>1</sup>Presented as mean ± SD, *n* (%), or *n*. IPMN: Intraductal papilla mucinous neoplasm; MCN: Mucinous cystic neoplasm; SCN: Serous cystic neoplasm; SPN: Solid pancreatic neoplasms; NEN: Neuroendocrine neoplasm.

### Postoperative treatment

After EUS-FNA, patients were intravenously administered one dose of an intravenous antibiotic for 3 d and octreotide for 1 d. An intravenous proton pump inhibitor (PPI) for 1 d and an additional 3 d of an oral PPI were required. Six hours and the morning after the procedure, the patients were assessed for serum amylase and lipase levels. If these results were abnormal, rechecking was required once daily before they returned to normal. Oral intake of food was allowed 1 d after EUS-FNA if there was no severe AE.

### Definitions

Incidents were different from AEs. Incidents were defined as symptoms or signs that did not interfere with the planned treatment. AEs were defined as events that prevented completion of or change to the planned procedure. Moderate to severe abdominal pain that needed additional treatment was regarded as an AE, while mild abdominal pain was regarded as an incident. The size of PCLs was determined by their largest diameter. If EUS-FNA was performed on several cysts in one patient, the diameter was calculated as the sum of the largest diameters of these cysts. All of the patients were given a presumed diagnosis on the basis of EUS, cystic fluid analysis and cystic wall biopsy before surgery.

### Statistical analysis

All calculations were performed using SPSS version 17.0. Quantitative data, including cystic size and patients' age, were expressed by the mean or median and tested by *t*-test or nonparametric test. Enumeration data, like

diagnostic accuracy rate and incident rate, were tested using  $\chi^2$  or Fisher's exact test. A *P* value < 0.05 was considered significant.

## RESULTS

Basic characteristics are summarized in Table 1. There were 88 (62.9%) women and 52 (37.1%) men among 140 patients, with a mean age of 50.1 (± 15.4) years. There were 67 cysts located in the head/uncinate of the pancreas and 67 in the body/tail, and 6 patients had at least one cyst in the pancreas. Cystic fluid analysis was available for 89 patients and 1 patient had aspiration of two cysts. The levels of carcinoembryonic antigen, amylase, lipase and carbohydrate antigen 19-9 were 4.89 ng/mL (range: 0.20-19 636.5 ng/mL), 316.75 U/L (range: 1.2-275 020 U/L), 1713.60 U/L (range: 4.4-1 594 160 U/L) and 640.75 ng/mL (range: 1.07- > 20000 ng/mL), respectively. There were 75 patients undergoing surgery and 55 undergoing EUS-FNA with interval at least 1 wk before other operations, with 3 patients undergoing the procedure twice. Seventy pancreatic neoplastic cysts and five non-neoplastic cysts were found in pathological diagnosis. There were 25 MCNs, 27 serous cystic neoplasms, 7 solid pancreatic neoplasms, 8 IPMNs, 1 neuroendocrine neoplasm and 2 cystadenocarcinomas among the neoplastic cysts, and 2 pseudocysts, 2 true cysts and 1 case of cystic tuberculosis among the non-neoplastic cysts. There were 75 patients undergoing surgery after EUS-FNA and 58 were available for safety evaluation. The study flowchart is shown in Figure 2.

### Accuracy of EUS-FNA

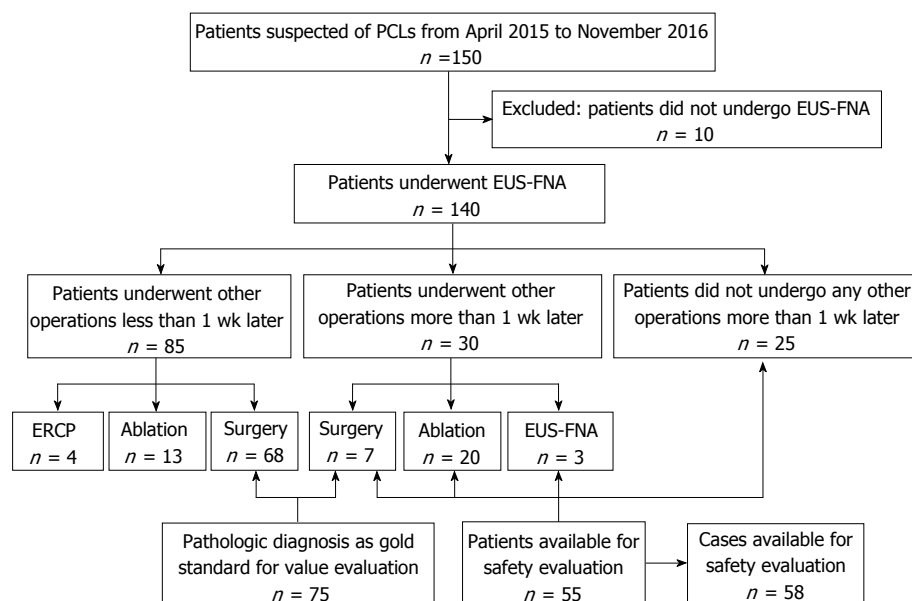
A total of 75 patients underwent surgery after EUS and pathological diagnosis was regarded as the gold standard. There were two malignant cysts by pathology and one was misdiagnosed by EUS-FNA. The sensitivity, specificity, positive predictive value, negative predictive value and accuracy of EUS-FNA in differentiating benign and malignant lesions were 98.6% (72/73), 50.0% (1/2), 98.6% (72/73), 50% (1/2) and 97.3% (73/75), respectively. When evaluating the capacity of characterizing subtype of PCLs, the accuracy of EUS-FNA was 84.0% (63/75).

### Safety of EUS-FNA

Fifty-eight patients were available for safety evaluation and monitored for ≥ 7 d. Only 1 patient with moderate abdominal pain received additional treatment with anisodamine and the pain was relieved. No other AE occurred, which resulted in an AE rate of 1.7%.

Incidents were reported in 22 patients, with a rate of 37.9% (22/58). Seven patients developed abdominal pain; nine hyperamylasemia; four both abdominal pain and hyperamylasemia; one abdominal pain, low-grade fever and hyperamylasemia simultaneously; and one low-grade fever and hyperamylasemia simultaneously (Table 2).





**Figure 2 Study flowchart.** ERCP: Endoscopic retrograde cholangiopancreatography; EUS-FNA: Endoscopic ultrasound-guided fine-needle aspiration; PCLs: Pancreatic cystic lesions.

### Comparison between incidents/AEs and non-complaints of EUS-FNA

The characteristics of the incidents/AEs and non-complaints groups are described in Table 3. We performed univariate analysis of the baseline patient and cystic characteristics to predict safety related to EUS-FNA. Among the variables, no significance was shown for age, sex, location and size of the lesions.

## DISCUSSION

PCLs are composed of true cysts, pseudocysts and cystic neoplasms. About 60% of PCLs are cystic tumors, followed by inflammation and trauma-related pseudocysts accounting for 30%<sup>[12]</sup>. PCLs have a wide range of lesions ranging from benign to malignant<sup>[13]</sup>. Although imaging modalities have made great advances, the accurate diagnosis of PCLs and differentiation of PCL subtypes remain challenging<sup>[13]</sup>. EUS and EUS-FNA contribute much to the diagnosis of PCLs because of their high resolution and the aid of cystic fluid and cytological analysis<sup>[14-18]</sup>. EUS-FNA can offer incremental diagnostic sensitivity with its ability to obtain cystic fluid and cytology from worrisome areas<sup>[19]</sup>. The American Gastroenterological Association Institute suggests that EUS-FNA should be used to examine PCLs with at least two high-risk features<sup>[20]</sup>. EUS-FNA might affect the management of 72% of incidental pancreatic cysts<sup>[21]</sup>. When referring to EUS-FNA, its diagnostic value and safety are the most important features for evaluating its feasibility.

Many studies have shown that the accuracy of EUS-FNA in diagnosis of PCLs ranged from 66.7% to 97%<sup>[22-25]</sup>. Under EUS-FNA, cystic fluid and cystic tissue can be collected for biochemical, cytological, genetic and pathological examination, which may help

to diagnose and classify PCLs<sup>[26-28]</sup>. The diagnostic yield from combined EUS-FNA imaging is better than from EUS alone<sup>[29]</sup>. EUS-FNA contributes much to differentiation between benign and malignant PCLs<sup>[30]</sup> and between mucinous and non-mucinous cystic lesions<sup>[31,32]</sup>. Cytologic diagnosis with EUS-FNA is helpful to arrive at a more definitive diagnosis<sup>[5]</sup>. EUS with or without FNA is superior to CT and MRI in accurately classifying a cyst as neoplastic<sup>[33]</sup>.

In our current study, EUS-FNA had a high sensitivity for differentiation of malignant cystic carcinoma from benign or malignant potential PCLs, but its specificity was only 50%. There were two cystic carcinomas diagnosed by EUS-FNA in our study and one was misdiagnosed. When EUS-FNA reveals malignance, we should accept its diagnosis with caution. Additional information, like age, clinical symptoms, history of present illness, blood test results and other imaging examinations, should be taken into account. However, pancreatic cancer has high malignancy with short survival time, we would rather misdiagnose than miss it. It is important to differentiate between mucinous and non-mucinous PCLs because their treatments are different.

In our research, EUS-FNA did well in classifying PCLs into different subtypes, with an accuracy of 84.0%. An earlier study suggested that diagnostic accuracy in distinguishing mucinous and non-mucinous PCLs increased up to 90% when taking cystic fluid tumor marker level, amylase level, mucin staining and cytology into consideration to make a presumed diagnosis<sup>[31]</sup>. Our result seemed lower, which may be because previous studies just made a distinction between mucinous and non-mucinous PCLs. The cystic wall puncture might increase the sensitivity of EUS-FNA<sup>[5]</sup>. A systematic review showed k-ras mutational

**Table 2 Incidents of patients after endoscopic ultrasound-guided fine-needle aspiration**

Incident	<i>n</i>
Abdominal pain	7
Hyperamylasemia	9
Abdominal pain + hyperamylasemia	4
Abdominal pain + low-grade fever + hyperamylasemia	1
Low-grade fever + hyperamylasemia	1

analysis used as an individual screening test has a poor diagnostic accuracy and the combined test of cytology and k-ras benefited the diagnostic value<sup>[34]</sup>.

When evaluating the safety of EUS-FNA, AEs have attracted a lot of attention, with AE rates ranging from 1.14% to 14%<sup>[35-39]</sup>. A large prospective multicenter study reported a complication rate of 6%<sup>[40]</sup>. In our study, the AE rate was 1.7%. A study enrolled 414 patients showed the AEs all occurred during the first day<sup>[41]</sup>. In accordance with a previous study, pancreatitis, infection, perforation, tumor seeding and clinically significant bleeding are the most common AEs of EUS-FNA<sup>[42]</sup>. The incidence of acute pancreatitis varies from 0% to 2.6% and bacteremia can be observed in  $\leq 6\%$  of EUS procedures and EUS-FNA<sup>[18,38,40,43,44]</sup>. The incidence of abdominal pain is 0%-3.6%, while fever is reported in 0%-4.1% of cases<sup>[41,43,45-47]</sup>. No protective effect was observed from periprocedural prophylactic antibiotic administration<sup>[48]</sup>. Debate remains about whether the complications of EUS-FNA for PCLs are more frequent than for pancreatic solid lesions<sup>[39,49]</sup>.

The incident rate in our study was higher than in a previous study reporting three incidents among 73 patients with PCLs and 73 with solid lesions<sup>[39]</sup>. However, the AE rate in our study was lower compared with 5.5% (4/73) in PCLs of the previous study. There are several reasons for this difference. Although the definitions of incidents and AEs are both based on an American Society for Gastrointestinal Endoscopy (ASGE) workshop, the postoperative treatment may differ. The definitions are related to planned therapy so differences in therapy will affect the discrimination between AEs and incidents. There are no clear guidelines for post-EUS-FNA treatment. Serum amylase and lipase levels were detected only when patients complained of abdominal pain in the previous study. Hyperamylasemia alone was common in our study and not necessarily accompanied by abdominal pain. Therefore, the number of incidents might have been underestimated in the previous study. Although incidents have no effect on completion of the planned procedure, paying attention to them may help optimize our treatment. For example, hyperamylasemia was reported 6 h after EUS-FNA and amylase level returned to normal the morning after the procedure. Therefore, one dose of octreotide might be enough for most patients. Noticing incidents can help operators take more care before, during and after an operation. Incidents may predict AEs, and giving attention to incidents might decrease

**Table 3 Comparison between incidents/adverse events and non-complaints of endoscopic ultrasound-guided fine-needle aspiration**

	Incidents/AEs group, <i>n</i> = 23	Non-complaints group, <i>n</i> = 35	<i>P</i> value
Age, yr	52.6 $\pm$ 19.0	52.6 $\pm$ 13.5	> 0.05 (NS)
Sex			> 0.05 (NS)
Female	12	18	
Male	11	17	
Location			> 0.05 (NS)
Head/uncinate	15	18	
Body/tail	5	15	
Multiple cysts	3	2	
Size by EUS mm	34.5 $\pm$ 20.1	41.2 $\pm$ 21.5	> 0.05 (NS)

Data are presented as mean  $\pm$  SD or *n*. AEs: Adverse events; EUS: Endoscopic ultrasound; NS: Not significant.

AEs.

To predict the incidents/AEs, we carried out univariate analysis to identify factors that might affect incidents/AEs. Incidents/AEs were similar in patients of different age and sex and with lesions of different location and size. A previous study also demonstrated that location cannot predict AEs<sup>[38]</sup>. Eloubeidi *et al.*<sup>[50]</sup> reported that the type and size of the pancreatic lesion affected AEs. We speculated that factors predicting incidents and AEs were similar. However, factors that may predict incidents deserve further investigation.

Our study prospectively revealed incidents related to EUS-FNA that may help to reduce AEs. However, there were several limitations. First, although there were 140 patients enrolled, we evaluated the accuracy of EUS-FNA in 75 patients (group 1) and safety of EUS-FNA in 55 patients (group 2). They were different groups and 17 patients among enrolled patients were neither in group 1 nor in group 2. Second, although the ASGE workshop defines incidents and AEs, there is no clear guideline for post-EUS-FNA treatment. The discrimination of incidents and AEs may vary with planned treatment. The incidents in our study may be different when changes are made to postoperative treatment. The final limitation was our small number of participants. Nearly half of the EUS-FNA procedures were done followed by surgery immediately, which made the sample for safety evaluation small.

In conclusion, EUS-FNA is effective and safe for diagnosis of PCLs, and has a high diagnostic accuracy and low AE rate. However, incidents related to EUS-FNA are common. Caution should be taken in patients undergoing EUS-FNA to prevent incidents from evolving into AEs. Incidents are similar in patients of different ages and sex and with lesions of different location and size.

## COMMENTS

### Background

Endoscopic ultrasound-guided fine-needle aspiration (EUS-FNA) is the predominant method for diagnosis of pancreatic cystic lesions (PCLs).

Compared with computed tomography and magnetic resonance imaging, EUS-FNA is an invasive operation. It is the top priority to ensure the safety of EUS-FNA.

### Research frontiers

There have been many studies on the safety and diagnostic accuracy of EUS-FNA for PCLs, but there have been few studies regarding the incidents related to this procedure. Their study was designed to evaluate the diagnostic value and safety mainly regarding incidents of EUS-FNA.

### Innovations and breakthroughs

The current study noted the incidents related to EUS-FNA, which have often been ignored. EUS-FNA is safe with low incidence of adverse events (AEs). However, incidents related to EUS-FNA are common. This study also analyzed the factors that predict safety related to EUS-FNA.

### Applications

Noticing incidents can help operators take more care before, during and after an operation. Incidents may predict AEs, and giving attention to incidents might decrease AEs.

### Terminology

Incidents were different from AEs. Incidents were defined as symptoms or signs that did not interfere with the planned treatment. AEs were defined as events that prevented completion of or change in the planned procedure.

### Peer-review

This manuscript describes an interesting investigation about the incidents and AEs of EUS-FNA for PCLs. In this study, the authors evaluated the diagnostic value and safety mainly regarding incidents of EUS-FNA for PCLs.

## REFERENCES

- Laffan TA, Horton KM, Klein AP, Berlanstein B, Siegelman SS, Kawamoto S, Johnson PT, Fishman EK, Hruban RH. Prevalence of unsuspected pancreatic cysts on MDCT. *AJR Am J Roentgenol* 2008; **191**: 802-807 [PMID: 18716113 DOI: 10.2214/AJR.07.3340]
- Spinelli KS, Fromwiller TE, Daniel RA, Kiely JM, Nakeeb A, Komorowski RA, Wilson SD, Pitt HA. Cystic pancreatic neoplasms: observe or operate. *Ann Surg* 2004; **239**: 651-657; discussion 657-659 [PMID: 15082969 DOI: 10.1097/01.sla.0000124299.57430.ce]
- Canto MI, Hruban RH, Fishman EK, Kamel IR, Schulick R, Zhang Z, Topazian M, Takahashi N, Fletcher J, Petersen G, Klein AP, Axilbund J, Griffin C, Syngal S, Saltzman JR, Morteale KJ, Lee J, Tamm E, Vikram R, Bhosale P, Margolis D, Farrell J, Goggins M; American Cancer of the Pancreas Screening (CAPS) Consortium. Frequent detection of pancreatic lesions in asymptomatic high-risk individuals. *Gastroenterology* 2012; **142**: 796-804; quiz e14-e15 [PMID: 22245846 DOI: 10.1053/j.gastro.2012.01.005]
- Yoon WJ, Brugge WR. The safety of endoscopic ultrasound-guided fine-needle aspiration of pancreatic cystic lesions. *Endosc Ultrasound* 2015; **4**: 289-292 [PMID: 26643695 DOI: 10.4103/2303-9027.170408]
- Martin AK, Zhou Z. Endoscopic ultrasound-guided fine-needle aspiration for the diagnosis of pancreatic cysts by combined cytopathology and cystic content analysis. *World J Gastrointest Endosc* 2015; **7**: 1157-1169 [PMID: 26504505 DOI: 10.4253/wjge.v7.i15.1157]
- Munigala S, Gelrud A, Agarwal B. Risk of pancreatic cancer in patients with pancreatic cyst. *Gastrointest Endosc* 2016; **84**: 81-86 [PMID: 26524643 DOI: 10.1016/j.gie.2015.10.030]
- Le Borgne J, de Calan L, Partensky C. Cystadenomas and cystadenocarcinomas of the pancreas: a multiinstitutional retrospective study of 398 cases. French Surgical Association. *Ann Surg* 1999; **230**: 152-161 [PMID: 10450728]
- Ge N, Sun S. Endoscopic ultrasound: An all in one technique vibrates virtually around the whole internal medical field. *J Transl Intern Med* 2014; **2**: 104-106 [DOI: 10.4103/2224-4018.141829]
- Bhutani MS. Role of endoscopic ultrasound for pancreatic cystic lesions: Past, present, and future! *Endosc Ultrasound* 2015; **4**: 273-275 [PMID: 26643692 DOI: 10.4103/2303-9027.170400]
- Alkaade S, Chahla E, Levy M. Role of endoscopic ultrasound-guided fine-needle aspiration cytology, viscosity, and carcinoembryonic antigen in pancreatic cyst fluid. *Endosc Ultrasound* 2015; **4**: 299-303 [PMID: 26643697 DOI: 10.4103/2303-9027.170417]
- Cotton PB, Eisen GM, Aabakken L, Baron TH, Hutter MM, Jacobson BC, Mergener K, Nemcek A Jr, Petersen BT, Petrini JL, Pike IM, Rabeneck L, Romagnuolo J, Vargo JJ. A lexicon for endoscopic adverse events: report of an ASGE workshop. *Gastrointest Endosc* 2010; **71**: 446-454 [PMID: 20189503 DOI: 10.1016/j.gie.2009.10.027]
- Yoon WJ, Brugge WR. Endoscopic ultrasound and pancreatic cystic lesions-diagnostic and therapeutic applications. *Endosc Ultrasound* 2012; **1**: 75-79 [PMID: 24949341 DOI: 10.7178/eus.02.004]
- Kosmahl M, Pauser U, Peters K, Sipos B, Lüttges J, Kremer B, Klöppel G. Cystic neoplasms of the pancreas and tumor-like lesions with cystic features: a review of 418 cases and a classification proposal. *Virchows Arch* 2004; **445**: 168-178 [PMID: 15185076 DOI: 10.1007/s00428-004-1043-z]
- Lu X, Zhang S, Ma C, Peng C, Lv Y, Zou X. The diagnostic value of EUS in pancreatic cystic neoplasms compared with CT and MRI. *Endosc Ultrasound* 2015; **4**: 324-329 [PMID: 26643701 DOI: 10.4103/2303-9027.170425]
- Wright GP, Morrow JB, Shaheen M, Goslin BJ, Baatenburg L, Chung MH. Accuracy of endoscopic ultrasound in the evaluation of cystic pancreatic neoplasms: a community hospital experience. *Pancreas* 2014; **43**: 465-469 [PMID: 24622081 DOI: 10.1097/MPA.0000000000000057]
- Gilani SM, Tashjian R, Barawi M, Al-Khafaji B. Cytologic features of solid pseudopapillary neoplasms of the pancreas: a single institutional experience based on evaluation of diagnostic utility of endoscopic ultrasound-guided fine needle aspiration (EUS-FNA). *Pathologica* 2014; **106**: 45-50 [PMID: 25291866]
- Lim LG, Lakhtakia S, Ang TL, Vu CK, Dy F, Chong VH, Khor CJ, Lim WC, Doshi BK, Varadarajulu S, Yasuda K, Wong JY, Chan YH, Nga ME, Ho KY; Asian EUS Consortium. Factors determining diagnostic yield of endoscopic ultrasound guided fine-needle aspiration for pancreatic cystic lesions: a multicentre Asian study. *Dig Dis Sci* 2013; **58**: 1751-1757 [PMID: 23314918 DOI: 10.1007/s10620-012-2528-2]
- Buscail L, Faure P, Bournet B, Selves J, Escourrou J. Interventional endoscopic ultrasound in pancreatic diseases. *Pancreatol* 2006; **6**: 7-16 [PMID: 16327280 DOI: 10.1159/000090022]
- Sahani DV, Kadavigere R, Saokar A, Fernandez-del Castillo C, Brugge WR, Hahn PF. Cystic pancreatic lesions: a simple imaging-based classification system for guiding management. *Radiographics* 2005; **25**: 1471-1484 [PMID: 16284129 DOI: 10.1148/rg.256045161]
- Vege SS, Ziring B, Jain R, Moayyedi P; Clinical Guidelines Committee; American Gastroenterology Association. American gastroenterological association institute guideline on the diagnosis and management of asymptomatic neoplastic pancreatic cysts. *Gastroenterology* 2015; **148**: 819-822; quiz e12-13 [PMID: 25805375 DOI: 10.1053/j.gastro.2015.01.015]
- Ardengh JC, Lopes CV, de Lima-Filho ER, Kemp R, Dos Santos JS. Impact of endoscopic ultrasound-guided fine-needle aspiration on incidental pancreatic cysts. A prospective study. *Scand J Gastroenterol* 2014; **49**: 114-120 [PMID: 24188361 DOI: 10.3109/00365521.2013.854830]
- de Jong K, Poley JW, van Hooft JE, Visser M, Bruno MJ, Fockens P. Endoscopic ultrasound-guided fine-needle aspiration of pancreatic cystic lesions provides inadequate material for cytology and laboratory analysis: initial results from a prospective study. *Endoscopy* 2011; **43**: 585-590 [PMID: 21611945 DOI: 10.1055/s-0030-1256440]

- 23 **Oguz D**, Özataş E, Kalkan IH, Tayfur O, Cicek B, Aydog G, Kurt M, Beyazit Y, Etik D, Nadir I, Sahin B. Accuracy of endoscopic ultrasound-guided fine needle aspiration cytology on the differentiation of malignant and benign pancreatic cystic lesions: a single-center experience. *J Dig Dis* 2013; **14**: 132-139 [PMID: 23167591 DOI: 10.1111/1751-2980.12014]
- 24 **Frossard JL**, Amouyal P, Amouyal G, Palazzo L, Amaris J, Soldan M, Giostra E, Spahr L, Hadengue A, Fabre M. Performance of endosonography-guided fine needle aspiration and biopsy in the diagnosis of pancreatic cystic lesions. *Am J Gastroenterol* 2003; **98**: 1516-1524 [PMID: 12873573 DOI: 10.1111/j.1572-0241.2003.07530.x]
- 25 **Okasha HH**, Ashry M, Imam HM, Ezzat R, Naguib M, Farag AH, Gemeie EH, Khattab HM. Role of endoscopic ultrasound-guided fine needle aspiration and ultrasound-guided fine-needle aspiration in diagnosis of cystic pancreatic lesions. *Endosc Ultrasound* 2015; **4**: 132-136 [PMID: 26020048 DOI: 10.4103/2303-9027.156742]
- 26 **Frampton AE**, Krell J, Prado MM, Gall TM, Abbassi-Ghadi N, Del Vecchio Blanco G, Funel N, Giovannetti E, Castellano L, Basyouny M, Habib NA, Kaltsidis H, Vlavianos P, Stebbing J, Jiao LR. Prospective validation of microRNA signatures for detecting pancreatic malignant transformation in endoscopic-ultrasound guided fine-needle aspiration biopsies. *Oncotarget* 2016; **7**: 28556-28569 [PMID: 27086919 DOI: 10.18632/oncotarget.8699]
- 27 **Lubezky N**, Loewenstein S, Ben-Haim M, Brazowski E, Marmor S, Pasmanik-Chor M, Oron-Karni V, Rechavi G, Klausner JM, Lahat G. MicroRNA expression signatures in intraductal papillary mucinous neoplasm of the pancreas. *Surgery* 2013; **153**: 663-672 [PMID: 23305591 DOI: 10.1016/j.surg.2012.11.016]
- 28 **Caponi S**, Funel N, Frampton AE, Mosca F, Santarpia L, Van der Velde AG, Jiao LR, De Lio N, Falcone A, Kazemier G, Meijer GA, Verheul HM, Vasile E, Peters GJ, Boggi U, Giovannetti E. The good, the bad and the ugly: a tale of miR-101, miR-21 and miR-155 in pancreatic intraductal papillary mucinous neoplasms. *Ann Oncol* 2013; **24**: 734-741 [PMID: 23139258 DOI: 10.1093/annonc/mds513]
- 29 **Mitra V**, Nayar MK, Leeds JS, Wadehra V, Haugk B, Scott J, Charnley RM, Oppong KW. Diagnostic performance of endoscopic ultrasound (EUS)/endoscopic ultrasound--fine needle aspiration (EUS-FNA) cytology in solid and cystic pancreatic neuroendocrine tumours. *J Gastrointest Liver Dis* 2015; **24**: 69-75 [PMID: 25822436 DOI: 10.15403/jgld.2014.1121.vmi]
- 30 **O'Toole D**, Palazzo L, Hammel P, Ben Yaghle L, Couvelard A, Felce-Dachez M, Fabre M, Dancour A, Aubert A, Sauvanet A, Maire F, Lévy P, Ruszniewski P. Macrocytic pancreatic cystadenoma: The role of EUS and cyst fluid analysis in distinguishing mucinous and serous lesions. *Gastrointest Endosc* 2004; **59**: 823-829 [PMID: 15173795]
- 31 **Brugge WR**, Lewandrowski K, Lee-Lewandrowski E, Centeno BA, Szyldo T, Regan S, del Castillo CF, Warshaw AL. Diagnosis of pancreatic cystic neoplasms: a report of the cooperative pancreatic cyst study. *Gastroenterology* 2004; **126**: 1330-1336 [PMID: 15131794]
- 32 **Bektas M**, Krishna SG, Ross WA, Weston B, Katz MH, Fleming JB, Lee JH, Bhutani MS. Prevalence of extra-pancreatic cysts in patients with cystic pancreatic lesions detected by endoscopic ultrasound. *Endosc Ultrasound* 2015; **4**: 219-224 [PMID: 26374580 DOI: 10.4103/2303-9027.163001]
- 33 **Khashab MA**, Kim K, Lennon AM, Shin EJ, Tignor AS, Amateau SK, Singh VK, Wolfgang CL, Hruban RH, Canto MI. Should we do EUS/FNA on patients with pancreatic cysts? The incremental diagnostic yield of EUS over CT/MRI for prediction of cystic neoplasms. *Pancreas* 2013; **42**: 717-721 [PMID: 23558241 DOI: 10.1097/MPA.0b013e3182883a91]
- 34 **Gillis A**, Cipollone I, Cousins G, Conlon K. Does EUS-FNA molecular analysis carry additional value when compared to cytology in the diagnosis of pancreatic cystic neoplasm? A systematic review. *HPB (Oxford)* 2015; **17**: 377-386 [PMID: 25428782 DOI: 10.1111/hpb.12364]
- 35 **Wiersema MJ**, Vilmann P, Giovannini M, Chang KJ, Wiersema LM. Endosonography-guided fine-needle aspiration biopsy: diagnostic accuracy and complication assessment. *Gastroenterology* 1997; **112**: 1087-1095 [PMID: 9097990]
- 36 **Barresi L**, Tarantino I, Traina M, Granata A, Curcio G, Azzopardi N, Baccarini P, Liotta R, Fornelli A, Maimone A, Jovine E, Cennamo V, Fabbri C. Endoscopic ultrasound-guided fine needle aspiration and biopsy using a 22-gauge needle with side fenestration in pancreatic cystic lesions. *Dig Liver Dis* 2014; **46**: 45-50 [PMID: 23916241 DOI: 10.1016/j.dld.2013.06.008]
- 37 **Carrara S**, Arcidiacono PG, Mezzi G, Petrone MC, Boemo C, Testoni PA. Pancreatic endoscopic ultrasound-guided fine needle aspiration: complication rate and clinical course in a single centre. *Dig Liver Dis* 2010; **42**: 520-523 [PMID: 19955025 DOI: 10.1016/j.dld.2009.10.002]
- 38 **O'Toole D**, Palazzo L, Arotçarena R, Dancour A, Aubert A, Hammel P, Amaris J, Ruszniewski P. Assessment of complications of EUS-guided fine-needle aspiration. *Gastrointest Endosc* 2001; **53**: 470-474 [PMID: 11275888 DOI: 10.1067/mge.2001.112839]
- 39 **Rodríguez-D'Jesús A**, Fernández-Esparrach G, Marra-Lopez C, Orive-Calzada A, Sendino O, Araujo IK, Rodríguez de Miguel C, Vázquez-Sequeiros E, Córdova H, Sánchez-Montes C, González-Suárez B, Ginès A. Adverse events of EUS-guided FNA of pancreatic cystic and solid lesions by using the lexicon proposed in an ASGE workshop: a prospective and comparative study. *Gastrointest Endosc* 2016; **83**: 780-784 [PMID: 26301408 DOI: 10.1016/j.gie.2015.08.035]
- 40 **Tarantino I**, Fabbri C, Di Mitri R, Pagano N, Barresi L, Mocciano F, Maimone A, Curcio G, Repici A, Traina M. Complications of endoscopic ultrasound fine needle aspiration on pancreatic cystic lesions: final results from a large prospective multicenter study. *Dig Liver Dis* 2014; **46**: 41-44 [PMID: 24054767 DOI: 10.1016/j.dld.2013.08.134]
- 41 **Al-Haddad M**, Wallace MB, Woodward TA, Gross SA, Hodgins CM, Toton RD, Raimondo M. The safety of fine-needle aspiration guided by endoscopic ultrasound: a prospective study. *Endoscopy* 2008; **40**: 204-208 [PMID: 18058615 DOI: 10.1055/s-2007-995336]
- 42 **Fujii LL**, Levy MJ. Basic techniques in endoscopic ultrasound-guided fine needle aspiration for solid lesions: Adverse events and avoiding them. *Endosc Ultrasound* 2014; **3**: 35-45 [PMID: 24949409 DOI: 10.4103/2303-9027.123006]
- 43 **Lee LS**, Saltzman JR, Bounds BC, Poneros JM, Brugge WR, Thompson CC. EUS-guided fine needle aspiration of pancreatic cysts: a retrospective analysis of complications and their predictors. *Clin Gastroenterol Hepatol* 2005; **3**: 231-236 [PMID: 15765442]
- 44 **Siddiqui AA**, Shahid H, Shah A, Khurana T, Huntington W, Ghumman SS, Loren DE, Kowalski TE, Laique S, Hayat U, Eloubeidi MA. High risk of acute pancreatitis after endoscopic ultrasound-guided fine needle aspiration of side branch intraductal papillary mucinous neoplasms. *Endosc Ultrasound* 2015; **4**: 109-114 [PMID: 26020044 DOI: 10.4103/2303-9027.156728]
- 45 **Al-Haddad M**, Gill KR, Raimondo M, Woodward TA, Krishna M, Crook JE, Skarvinko LN, Jamil LH, Hasan M, Wallace MB. Safety and efficacy of cytology brushings versus standard fine-needle aspiration in evaluating cystic pancreatic lesions: a controlled study. *Endoscopy* 2010; **42**: 127-132 [PMID: 19998218 DOI: 10.1055/s-0029-1215351]
- 46 **Hernandez LV**, Mishra G, Forsmark C, Draganov PV, Petersen JM, Hochwald SN, Vogel SB, Bhutani MS. Role of endoscopic ultrasound (EUS) and EUS-guided fine needle aspiration in the diagnosis and treatment of cystic lesions of the pancreas. *Pancreas* 2002; **25**: 222-228 [PMID: 12370531]
- 47 **Wittmann J**, Kocjan G, Sgouros SN, Deheragoda M, Pereira SP. Endoscopic ultrasound-guided tissue sampling by combined fine needle aspiration and trucut needle biopsy: a prospective study. *Cytopathology* 2006; **17**: 27-33 [PMID: 16417562 DOI: 10.1111/j.1365-2303.2006.00313.x]
- 48 **Guarner-Argente C**, Shah P, Buchner A, Ahmad NA, Kochman ML, Ginsberg GG. Use of antimicrobials for EUS-guided FNA of pancreatic cysts: a retrospective, comparative analysis. *Gastrointest*



- Endosc* 2011; **74**: 81-86 [PMID: 21704808 DOI: 10.1016/j.gie.2011.03.1244]
- 49 **Wang KX**, Ben QW, Jin ZD, Du YQ, Zou DW, Liao Z, Li ZS. Assessment of morbidity and mortality associated with EUS-guided FNA: a systematic review. *Gastrointest Endosc* 2011; **73**: 283-290 [PMID: 21295642 DOI: 10.1016/j.gie.2010.10.045]
- 50 **Eloubeidi MA**, Tamhane A, Varadarajulu S, Wilcox CM. Frequency of major complications after EUS-guided FNA of solid pancreatic masses: a prospective evaluation. *Gastrointest Endosc* 2006; **63**: 622-629 [PMID: 16564863 DOI: 10.1016/j.gie.2005.05.024]

**P- Reviewer:** Casper S, Sunanda K **S- Editor:** Wang JL

**L- Editor:** Filipodia **E- Editor:** Li D



## Systematic review of giant gastric lipomas reported since 1980 and report of two new cases in a review of 117110 esophagogastroduodenoscopies

Mitchell S Cappell, Charlton E Stevens, Mitul Amin

Mitchell S Cappell, Department of Gastroenterology and Hepatology, William Beaumont Hospital, Royal Oak, MI 48073, United States

Mitchell S Cappell, Mitul Amin, Oakland University William Beaumont School of Medicine, Royal Oak, MI 48073, United States

Charlton E Stevens, San Antonio Military Medical Center, San Antonio, TX 78219, United States

Mitul Amin, Department of Pathology, William Beaumont Hospital, Royal Oak, MI 48073, United States

**Author contributions:** Cappell MS and Stevens CE contributed equally to this work; Stevens CE wrote the initial 2 case reports and a skeleton of the results section; Cappell MS, as mentor, initiated this work, edited the 2 case reports, and wrote the bulk of the introduction, methods, results, and discussion sections; Amin M performed all the microscopic and gross pathology, and wrote the pathologic sections of the paper.

**Conflict-of-interest statement:** None for all authors. In particular, Dr. Cappell, as a consultant of the United States Food and Drug Administration (FDA) Advisory Committee for Gastrointestinal Drugs, affirms that this paper does not discuss any proprietary confidential pharmaceutical data submitted to the FDA. Dr. Cappell is also a member of the speaker's bureau for AstraZeneca and Daiichi Sankyo, co-marketers of Movantik. This work does not discuss any drug manufactured or marketed by AstraZeneca or Daiichi Sankyo.

**Data sharing statement:** Consent was not obtained but the presented data are anonymized and the risk of identification is low.

**Open-Access:** This article is an open-access article which was selected by an in-house editor and fully peer-reviewed by external reviewers. It is distributed in accordance with the Creative Commons Attribution Non Commercial (CC BY-NC 4.0) license, which permits others to distribute, remix, adapt, build upon this

work non-commercially, and license their derivative works on different terms, provided the original work is properly cited and the use is non-commercial. See: <http://creativecommons.org/licenses/by-nc/4.0/>

**Manuscript source:** Invited manuscript

**Correspondence to:** Mitchell S Cappell, MD, PhD, Chief, Department of Gastroenterology and Hepatology, William Beaumont Hospital, MOB # 602, 3535 W. Thirteen Mile Rd, Royal Oak, MI 48073, United States. [mscappell@yahoo.com](mailto:mscappell@yahoo.com)  
**Telephone:** +1-248-5511227  
**Fax:** +1-248-5517581

**Received:** April 6, 2017

**Peer-review started:** April 11, 2017

**First decision:** April 17, 2017

**Revised:** May 4, 2017

**Accepted:** June 18, 2017

**Article in press:** June 19, 2017

**Published online:** August 14, 2017

### Abstract

#### AIM

To systematically review the syndrome of giant gastric lipomas, report 2 new illustrative cases.

#### METHODS

Literature systematically reviewed using PubMed for publications since 1980 with following medical subject heading/keywords: ("giant lipoma") AND ("gastric") OR [("lipoma") and ("gastric") and ("bleeding")]. Two authors independently reviewed literature, and decided by consensus which articles to incorporate. Computerized review of pathology/endoscopy records at William Beaumont Hospitals, Royal Oak and Troy, Michigan, January 2005-December 2015, revealed

2 giant gastric lipomas among 117110 consecutive esophagogastroduodenoscopies (EGDs), which were thoroughly reviewed, including re-review of original endoscopic photographs, radiologic images, and pathologic slides.

## RESULTS

Giant gastric lipomas are extremely rare: 32 cases reported since 1980, and 2 diagnosed among 117110 consecutive EGDs. Average patient age =  $54.5 \pm 17.0$  years old (males = 22, females = 10). Maximal lipoma dimension averaged  $7.9 \text{ cm} \pm 4.1 \text{ cm}$ . Ulcerated mass occurred in 21 patients. Lipoma locations: antrum-17, body-and-antrum-4, antrum-intussuscepting-into-small-intestine-3, body-2, fundus-1, and unspecified-5. Intramural locations included submucosal-22, subserosal-2, and unspecified-8. Presentations included: acute upper gastrointestinal (UGI) bleeding-19, abdominal pain-5, nausea/vomiting-5, and asymptomatic-3. Symptoms among patients with UGI bleeding included: weakness/fatigue-6, abdominal pain-4, nausea/vomiting-4, early-satiety-3, dizziness-2, and other-1. Their hemoglobin on admission averaged  $7.5 \text{ g/dL} \pm 2.8 \text{ g/dL}$ . Patients with GI bleeding had significantly more frequently ulcers than other patients. EGD was extremely helpful diagnostically ( $n = 31$  patients), based on characteristic endoscopic findings, including yellowish hue, well-demarcated margins, smooth overlying mucosa, and endoscopic cushion, tenting, or naked-fat signs. However, endoscopic mucosal biopsies were mostly non-diagnostic (11 of 12 non-diagnostic). Twenty (95%) of 21 abdominal CTs demonstrated characteristic findings of lipomas, including: well-circumscribed, submucosal, and homogeneous mass with attenuation of fat. Endoscopic-ultrasound showed characteristic findings in 4 (80%) of 5 cases: hyperechoic, well-localized, mass in gastric-wall-layer-3. Transabdominal ultrasound and UGI series were generally less helpful. All 32 patients underwent successful therapy without major complications or mortality, including: laparotomy and full-thickness gastric wall resection of tumor using various surgical reconstructions-26; laparotomy-and-enucleation-2; laparoscopic-transgastric-resection-2; endoscopic-mucosal-resection-1, and other-1. Two new illustrative patients are reported who presented with severe UGI bleeding from giant, ulcerated, gastric lipomas.

## CONCLUSION

This systematic review may help standardize the endoscopic and radiologic evaluation and therapy of patients with this syndrome.

**Key words:** Esophagogastroduodenoscopy Lipoma; Gastric; Giant; Melena; Upper gastrointestinal bleeding; Systematic review

© The Author(s) 2017. Published by Baishideng Publishing Group Inc. All rights reserved.

**Core tip:** Systematic literature review of giant gastric lipomas revealed 32 reported cases since 1980, with 2 new cases reported among 117110 esophagogastroduodenoscopies. Two authors independently reviewed literature, and decided by consensus which articles to incorporate. Average-patient-age =  $54.5 \pm 17.0$  years (males = 68.8%). Mean-maximal-lipoma-diameter =  $7.9 \text{ cm} \pm 4.1 \text{ cm}$ . Lipoma locations: antrum-17, antrum and other gastric segments-7, other-8. Lipomas were submucosal-92%, subserosal-8%. Presentations included: acute upper gastrointestinal (UGI) bleeding-19, abdominal pain-5, nausea/vomiting-5, asymptomatic-3. Esophagogastroduodenoscopy was extremely helpful diagnostically; findings included: yellowish hue, well-demarcated margins, and smooth overlying mucosa. Endoscopic biopsies were infrequently diagnostic. Twenty of 21 abdominal CTs demonstrated characteristic lipoma findings: well-circumscribed, submucosal, and homogeneous mass with fat attenuation. Endoscopic-ultrasound showed characteristic findings in 80%. All patients underwent successful therapy without major complications/mortality, including: laparotomy-with-full-thickness-gastric-wall-resections-26; and other-6. Two newly reported patients presented with severe UGI bleeding from giant, ulcerated, gastric lipomas. This review may help standardize work-up of these patients.

Cappell MS, Stevens CE, Amin M. Systematic review of giant gastric lipomas reported since 1980 and report of two new cases in a review of 117110 esophagogastroduodenoscopies. *World J Gastroenterol* 2017; 23(30): 5619-5633 Available from: URL: <http://www.wjgnet.com/1007-9327/full/v23/i30/5619.htm> DOI: <http://dx.doi.org/10.3748/wjg.v23.i30.5619>

## INTRODUCTION

Gastric lipomas are rare, constituting < 3% of benign gastric tumors, and < 1% of all gastric tumors<sup>[1]</sup>, and giant gastric lipomas ( $\geq 4 \text{ cm}$ ) are extremely rare, with only 32 cases reported since 1980 (Table 1)<sup>[1-33]</sup>. Although small gastric lipomas are usually asymptomatic, giant gastric lipomas typically produce major symptoms from GI obstruction, tumor ulcers, or acute upper gastrointestinal (UGI) bleeding, with 19 cases of UGI bleeding reported since 1980 (Table 1). Due to its extreme rarity, all prior studies of giant gastric lipomas have comprised single case reports. This work systematically reviews the literature since 1980, and collates the case reports scattered among various and sometimes obscure journals, to semi-quantitatively describe the clinical presentation, endoscopic and radiologic findings, and therapy of the disease; and to report two new illustrative cases who presented with massive, life-threatening UGI bleeding among 117110

**Table 1 Comprehensive review of the 32 giant gastric lipomas reported since 1980**

Ref.	Age, sex, clinical presentation, PMH, signs and lab abnormalities	Diagnostic work-up	Treatment, pathology	Outcome and follow-up
Upper GI bleeding				
Current case report 1	63 y. o. M with previous medical history of hypertension and hyperlipidemia presented with melena and dyspnea on exertion for 3 d and epigastric pain, early satiety and 10-kg weight loss during the last 6 mo. BP = 144/77 mm/Hg, pulse = 87/min. Hgb = 6.2 g/dL	EGD: 13-cm-wide, submucosal, yellowish, gastric mass in antrum covered by smooth mucosa except for focal ulceration Abdominal CT: well-circumscribed, uniform 13.4 cm × 8.4 cm × 8.2 cm mass, with attenuation characteristic for fat	Laparotomy: Resected by subtotal gastrectomy extended by partial bulbar duodenectomy with Billroth II reconstruction Pathology: Homogeneous, submucosal, soft, 14.5 cm × 8.7 cm × 7.5 cm mass. Lipoma with spindle cell variant by CD34 positivity by immunohistochemistry	Did well postoperatively with no complications. Asymptomatic at 8 wk of follow-up
Current case report 2	78 y. o. F presented with melena for 3 d, associated with weakness and orthostatic dizziness. BP = 124/67 mmHg, pulse = 68/min. Rectal exam-melena. Hgb = 7.1 g/dL	Abdominal CT: submucosal, 9.5 cm × 6.0 cm × 4.5 cm, antral mass. EGD: large, focally ulcerated, antral gastric mass, exhibiting a positive cushion sign	Laparotomy: large, 9.0 cm × 6.0 cm × 4.5 cm, submucosal mass excised by distal gastrectomy. Pathology: lipoma	Patient discharged 5 d postoperatively with no further bleeding Did well postoperatively with uneventful recovery
Ramdass <i>et al</i> <sup>[1]</sup> , 2013	37 y. o. F with epigastric pain, melena, vomiting and weakness for 4 d. Pallor and epigastric tenderness. Hgb = 5.9 g/dL. Transfused 6 units packed erythrocytes	EGD: submucosal mass with 1 cm central ulcer in gastric body	Gastric body. Laparotomy: 4 cm × 3.5 cm × 3.2 cm mass at junction of body and antrum removed surgically Pathology: lipoma	Remained well at 9 mo follow-up
Almohsin <i>et al</i> <sup>[2]</sup> , 2015	61 y. o. M presented with hematemesis, melena, epigastric pain, and fatigue	EGD: Gastric mass with an ulcer. Endoscopic biopsies: benign tissue. EUS: large, hyperechoic, antral, submucosal lesion. Abdominal CT: 8.5 cm × 5 cm submucosal, well-encapsulated antral lesion with density of fat with ulcerated overlying mucosa	Laparotomy: enucleation of lesion and overlying mucosa. Pathology: lipoma	Remained well at 9 mo follow-up
Beck <i>et al</i> <sup>[3]</sup> , 1997	13 y. o. M with hematemesis, melena and abdominal pain for 2 d. Occasional nausea and vomiting for several years. Benign abdomen Hgb = 10.5 g/dL	Abdominal radiograph: polypoid mass. EGD: 8 cm × 3 cm × 4 cm soft and compressible, polypoid mass with basal ulceration on anterolateral wall of antrum. Endoscopic mucosal biopsy: normal antral tissue. Abdominal CT: smooth, uniform intraluminal mass with low attenuation in submucosal layer	Endoscopic polypectomy: Unsuccessful due to thick polyp stalk and patient pain during attempted polypectomy Surgery: Excision of polyp Pathology: lipoma	Uneventful postoperative course. Patient asymptomatic
Bijlani <i>et al</i> <sup>[4]</sup> , 1993	70 y. o. M presented with acute hematemesis. Physical examination revealed pallor. Hgb = 7.0 g/dL	EGD: Protruding mass in antrum. Could not traverse endoscope beyond mass. Endoscopic biopsies: normal UGI series: space-occupying lesion in antrum Abdominal USD: normal	Laparotomy: soft, yellowish mass in antrum stretching the serosa. Mass enucleated <i>via</i> serosal approach Pathology: lipoma	Uneventful post-operative recovery. Asymptomatic at 6 mo of follow-up N.A
Bloch <i>et al</i> <sup>[5]</sup> , 1974	55 y. o. F with 1 episode of melena Nausea, epigastric fullness, and belching for 7 mo. Physical exam reveals grapefruit-sized epigastric mass N.A	Supine abdominal radiograph: Well-demarcated, large epigastric mass UGI series: huge, sharply demarcated, mass in distal two-thirds of stomach with 2 cm × 3 cm ulcer at apex of mass	Distal two-thirds of stomach on anterior wall. Laparotomy: huge, grapefruit size submucosal lipoma arising from anterior wall with shallow central ulcer Surgical resection: not documented	Uneventful postoperative course and asymptomatic at 1 yr
Chu <i>et al</i> <sup>[6]</sup> , 1983	61 y. o. F with previous medical history of gastric ulcer and hiatal hernia diagnosed 2 yr earlier presented with melena and weakness for several days. Rectal exam: fecal occult blood. Hgb = 6.0 g/dL. Transfused 3 units of packed erythrocytes	UGI series: sliding hiatal hernia, and golf-ball-sized mass protruding from lesser curve in antrum. Mass moved in and out of pylorus EGD: well-circumscribed, submucosal, 5 cm × 3 cm-mass protruding along lesser curve in antrum. Positive cushion sign	Laparotomy: 5 cm × 4 cm × 3 cm mass in pre-pylorus. Underwent resection of mass with adjacent lesser curvature, and pyloroplasty Pathology: lipoma	Uneventful postoperative course and asymptomatic at 1 yr
Kibria <i>et al</i> <sup>[7]</sup> , 2009	44 y. o. F with hematemesis and melena for 1 d. Hgb = 8.6 g/dL	EGD: Soft, broad-based, 5 cm × 3 cm mass on greater curvature of stomach. Two ulcers on mass. Positive cushion sign. Abdominal CT: 4.5 cm × 3.0 cm gastric mass with attenuation of fat projecting into lumen. Doppler-assisted EUS: submucosal mass of mixed echogenicity	Greater curvature of stomach Surgical resection, 4.8 cm × 3.2 cm, mature adipocytes with ulceration and necrosis of overlying mucosa	Uneventful recovery. Unremarkable EGD at 6 mo of follow-up

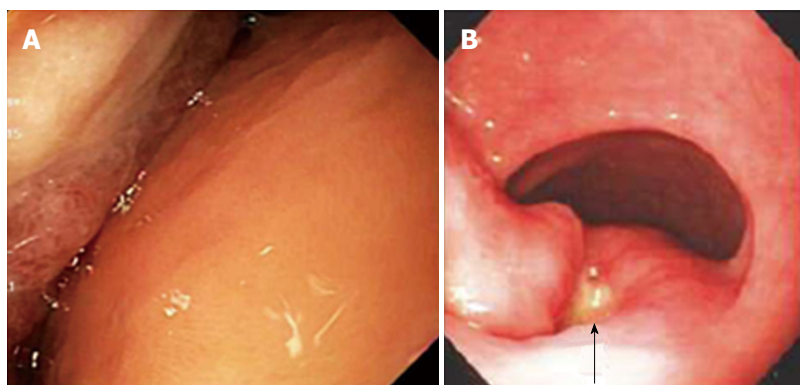


Kumar <i>et al</i> <sup>[8]</sup> , 2015	72 y. o. previously healthy M presented with presyncope associated with diaphoresis and pallor. Rectal exam revealed melena. Hgb = 9.9 g/dL	Abdominal CT: 4.3-cm-wide polypoid mass in antrum consistent with gastric lipoma. EGD: large, submucosal mass in gastric antrum with central ulcer with overlying clot. Ulcer injected with dilute epinephrine	Laparotomy: Gastrostomy with wide excision of antral lesion along anterior wall. Pathology: lipoma	Good postoperative recovery and discharged 3 d after surgery
López Cano <i>et al</i> <sup>[9]</sup> , 1991	76 y. o. M with recent NSAID use, and hypertension presented with acute melena. Hgb = 6.8 g/dL	EGD: posterior wall of antrum 3.5-cm-wide lesion with overlying smooth mucosa. Central ulceration. Endoscopic biopsy: gastritis. Abdominal ultrasound with water-filled stomach: 4-cm-wide, echogenic submucosal mass	Partial gastrectomy Pathology: lipoma	No postoperative complications
Myint <i>et al</i> <sup>[10]</sup> , 1996	54 y. o. F presented with hematemesis and melena for 1 wk. BP = 70/50 mmHg. Benign abdominal exam. Hgb = 4.0 g/dL.	EGD: 4 cm × 3 cm ulcerated submucosal mass in antrum Endoscopic biopsies: nondiagnostic. Abdominal CT: gastric mass with attenuation value of lipoma	Laparotomy: 6 cm × 6 cm mass in posterior wall of gastric antrum with central ulceration. Pathology: lipoma	Patient alive with no evident disease 6 mo after surgery
Ortiz de Solórzapo Aursua <i>et al</i> <sup>[11]</sup> , 1997	60 y. o. F. PMH: vitiligo, acute pancreatitis, duodenal ulcer presented with melena, postprandial pain, nausea, vomiting and early satiety. Pallor. Rectal exam: melena. Hgb = 12.8 g/dL	EGD: antral deformity. No active bleeding. Gastric volvulus? Abdominal USD: 5.8 cm × 3.4 cm pedunculated antral mass intussuscepting into duodenum. Abdominal CT: 4 cm × 3 cm × 3-cm-wide, well-defined, submucosal mass	Surgery; Underwent partial gastrectomy for antral mass intussuscepting into duodenum. Pathology: lipoma	Did well for 6 mo of follow-up
Paksoy <i>et al</i> <sup>[12]</sup> , 2003	71 y. o. M with acute hematemesis and melena. BP = 110/70 mmHg, Pulse = 100/min Hematocrit = 27%	EGD: 4 cm-wide mass with superficial ulcer on posterior gastric wall. Endoscopic biopsies: "benign" lesion Abdominal CT: 4 cm lesion of lipid density in inferioposterior wall of stomach	Inferioposterior wall of stomach Surgery: laparoscopic transgastric resection of 4 cm intramural lipoma Pathology: intramural lipoma	Discharged 6 d postoperatively without complications
Pérez Cabañas <i>et al</i> <sup>[13]</sup> , 1990	73 y. o. M presented with melena and hematemesis for 2 d. Recent NSAID use. PMH: hypertension. Physical exam: pallor, rectal exam-melena. Hgb = 8.6 g/dL. Transfused 5 units of packed erythrocytes	EGD: gastric mass on posterior wall and greater curve with superficial overlying ulcer, small hiatal hernia. Abdominal ultrasound: normal stomach. UGI series: large filling defect, from submucosal lesion	Surgery: Wedge resection for 5 cm × 4 cm submucosal mass Pathology: ulcerated lipoma	Did well after surgery
Priyadarshi <i>et al</i> <sup>[14]</sup> , 2015	46 y. o. M with melena for 1 yr. Palpable, soft epigastric lump. Mild epigastric tenderness Hgb = 5 mg/dL; coagulation parameters and chemistry WNL	EGD: large mass arising from posterior wall antrum with superficial ulceration. Unable to traverse pylorus due to obstruction. Abdominal CT: huge mass with lobulated surface projecting into gastric lumen with density consistent with fat. Tumor extended into pylorus and caused gastric outlet obstruction	Posterior wall of gastric antrum Laparotomy: Billroth I partial gastrectomy; 14 cm × 11 cm × 5 cm sessile broad based submucosal lipoma; path = mature adipocytes	No reported complications
Rao <i>et al</i> <sup>[15]</sup> , 2013	60 y. o. M presented with melena, fatigue and pallor. Hgb = 7.2 g/dL	EGD: large, smooth, submucosal bulge along lesser curvature of stomach. Contrast enhanced abdominal CT: Well-defined, encapsulated, submucosal mass with attenuation of fat along lesser curvature of stomach	Laparotomy: large submucosal tumor excised <i>via</i> anterior gastrotomy Pathology: 15 cm × 12 cm submucosal tumor with a focal ulcer. Microscopy demonstrates submucosal lipoma	Presently asymptomatic
Regge <i>et al</i> <sup>[16]</sup> , 1999	52 y. o. M presented with hematemesis and melena. Hgb = 5.5 g/dL	EGD: 3.5-cm-wide, round, pale-pink formation on anterior gastric antrum with oozing superficial ulcer. Hemostasis achieved with dilute epinephrine injection. Abdominal USD: 4-cm-wide hyperechoic antral lesion with distinct margins. Abdominal CT with IV contrast: 4-cm-wide, well-circumscribed, antral lesion with density of fat. Abdominal MRI: Confirmed fat-tissue signal in mass by hyperintensity on T1-weighted images and marked signal reduction on sequences performed with fat suppression	Laparotomy: Antrectomy and gastrojejunal anastomosis <i>via</i> a Roux-en-Y loop. Pathology: lipoma	N.A
Sadio <i>et al</i> <sup>[17]</sup> , 2010	44 y. o. M with medical history of hypertension, obesity, and sleep-apnea, presented with fatigue and intermittent melena for 1 mo. Physical exam revealed pallor. Hgb = 7.8 g/dL	EGD: 4-cm-wide, yellowish, submucosal mass in gastric fundus with central overlying ulceration. EUS: hyperechoic submucosal mass. Abdominal CT: homogeneous, well-circumscribed mass in fundus with density of fat	Surgery: partial gastric resection Pathology: submucosal lipoma	Did well and discharged 10 d postoperatively

Singh <i>et al</i> <sup>[18]</sup> , 1987	40 y. o. M with melena, pyrexia, chills, and weakness. BP = 100/70 mmHg, pulse = 106/min, temp = 39 °C, abdomen-soft, nontender, no palpable mass. Hgb = 4.0 g/dL	EGD: huge polypoid tumor in gastric body along greater curve. Multiple small superficial ulcers in antrum EGD biopsies: Mildly inflamed, mature adipose tissue UGI series: large gastric tumor	Gastric body along greater curve Laparotomy: smooth mass in gastric body and antrum. Multiple small ulcerations. Underwent subtotal gastrectomy and gastrojejunostomy. Pathology: 18 cm × 10 cm × 10 cm encapsulated lipoma	Discharged 2 wk postoperatively. Asymptomatic for 1 yr.
Youssef <i>et al</i> <sup>[19]</sup> , 1999	54 y. o. nonalcoholic F presented with melena and dizziness Physical exam: stable vital signs, abdominal tenderness without peritoneal signs. Hgb = 9.2 g/dL	EGD: submucosal protrusion with mucosal erosion along greater curvature in body and antrum Abdominal USD: homogeneous, hyperechoic mass in submucosa of posterior gastric wall. Abdominal CT: homogeneous, 5.1 cm × 3.7 cm lesion with density of fat in posterior gastric wall	Laparotomy: with full-thickness resection of lesion Pathology: 5.2 cm × 3.8 cm × 3.2 cm submucosal lipoma	Uneventful recovery
Abdominal pain Alberti <i>et al</i> <sup>[20]</sup> , 1999	11 y. o. F with periumbilical and RLQ abdominal pain for 3 yr. Outpatient UGI series revealed multiple filling defects in gastric antrum and body. Normal physical examination. Abdomen was soft with no palpable mass. No fecal occult blood. Normal routine blood studies. Normal iron studies	EGD: multiple, large, soft, masses protruding into gastric body and antrum with normal overlying mucosa. Gastric biopsies: normal mucosa. Abdominal USD: multiple, homogeneous, well-encapsulated, submucosal masses with attenuation characteristic of fat. Abdominal MRI: solid, hyperintense formations with signal characteristic of fat in gastric body and antrum. Percutaneous transgastric ultrasound guided biopsy: features of lipoma with mild inflammatory infiltrate	Gastric body and antrum. No treatment because became asymptomatic	"Pain progressively relieved" Follow-up MRI of abdomen: no change
Hamdane <i>et al</i> <sup>[21]</sup> , 2012	51 y. o. M with epigastric pain N.A	EGD: soft, large, ulcerated, submucosal mass in antrum Endoscopic biopsies: nonspecific inflammation of gastric mucosa. Abdominal CT: Round, well-circumscribed, low-attenuation, 9-cm-wide, gastric mass	Surgery: total gastrectomy. Pathology: 9 cm × 7.5 cm × 5 cm., mature adipocyte proliferation with variation of cell size in a fibro-myxoid background. Immunohistochemistry: positive to anti-HGMA2, but not S-100, or CD34, No MDM2 or CDK4 amplification, consistent with lipoma	Uneventful recovery. No symptoms at 1 yr follow-up
Neto <i>et al</i> <sup>[22]</sup> , 2012	63 y. o. M history of dyslipidemia, and hypertension with upper abdominal pain. Physical exam reveals a palpable, moveable upper abdominal mass Normal routine laboratory tests	Abdominal USD: large echoic mass compatible with an expansive lesion in gastric antrum. EGD: large bulging mass in posterior gastric wall with three ulcerated areas Endoscopic biopsies: necrotic mucosa Abdominal CT: well-defined, homogeneous, oval mass located within the posterior gastric wall that compressed descending duodenum and had the density of fat	Posterior gastric wall. Laparotomy with a subtotal gastrectomy and D1 lymphadenectomy with Roux-en-Y reconstruction: 12 cm × 8 cm × 6 cm, lipoma with mature, well differentiated adipocytes surrounded by a fibrous capsule with 3 ulcerative lesions of 0.5 cm, 1 cm, and 1.4 cm Antrum	Uneventful recovery with discharge 7 d postoperatively
Ramaraj <i>et al</i> <sup>[23]</sup> , 2012	52 y. o. M with dyspepsia, anorexia, and early satiety for 6 mo. Gastric ulcer 5 yr earlier. Iron deficiency anemia: Hg = 11.5 g/dL, ferritin = 5 ng/mL	Colonoscopy: within normal limits. EGD: Extrinsic indentation in distal stomach with smooth overlying mucosa. Endoscopic biopsy: normal mucosa CT abdomen: 15 cm × 14 cm fatty tumor in distal stomach	Subtotal gastrectomy: Submucosal antral lipoma with central ulceration	No postoperative complications. Asymptomatic at 4 wk of follow-up
Zak <i>et al</i> <sup>[24]</sup> , 2006	58 y. o. M with intermittent upper abdominal discomfort, early satiety, smoking, hyperlipidemia, obesity, PTSD, and depression. Has iron deficiency anemia	EGD: 10 cm × 6 cm smoothly lobulated, submucosal mass in gastric antrum along greater curvature. Chronic inflammation and intestinal metaplasia of gastric mucosa. EUS: hypoechoic submucosal mass surrounded by a hyperechoic layer in posterior wall of stomach, consistent with encapsulated lipoma. Abdominal CT: homogeneous, round, sharply-defined, encapsulated, submucosal lesion with characteristic density of fat	Gastric antrum along the greater curvature Laparotomy: resection only of the encapsulated mass Pathology: 10 cm × 6 cm lipoma	Uneventful recovery with discharge on day 7. Follow-up abdominal CT 2 mo later revealed no abnormalities
Predominantly nausea and vomiting or obstructive symptoms				

Aslan <i>et al</i> <sup>[25]</sup> , 2015	77 y. o. M with nausea and vomiting, and dyspepsia. Complete blood count and comprehensive metabolic panel: WNL	EGD: submucosal mass with normal overlying mucosa extending into antrum along lesser curve	Endoscopic submucosal resection of 9-cm-long lipoma with an intact capsule	Discharged after 3 d. Resolution of symptoms at 6 mo of follow-up. Repeat endoscopy did not reveal a mass
Lin <i>et al</i> <sup>[26]</sup> , 1992	77 y. o. F with nausea, vomiting, abdominal pain for 3 wk and 7-kg-weight-loss. Dehydrated and generalized mild abdominal tenderness. Rectal exam: fecal occult blood	UGI series: large polypoid gastric mass intussuscepting into duodenum. Abdominal USD: suspected intussusception. EGD: inadequate examination. Differential of gastric torsion <i>vs</i> intussusception	Laparotomy: large necrotic polypoid intussuscepting mass arising in stomach. Polyp resected at its base. Pathology: large polypoid lipoma	Ultimately recovered and was discharged
Mouës <i>et al</i> <sup>[27]</sup> , 2002	72 y. o. M with anorexia, early satiety, nausea, and involuntary weight loss. No overt GI bleeding. Left lung lobectomy for bronchial lung cancer 10 yr earlier. Hemoglobin = 4.7 g/dL	EGD: gastric mucosal hypertrophy extending into duodenum. Abdominal USD: hyperechoic mass in small intestine, consistent with lipoma, with likely intussusception. CT abdomen: low attenuation intraluminal tumor compatible with small intestinal lipoma	Laparotomy: large pedunculated tumor intussuscepting into jejunum. Mass reduced back into stomach. Gastrostomy revealed 10 cm × 5 cm superficially ulcerated gastric lipoma. Mass excised. Pathology: mature adipose tissue	Uneventful recovery
Nasa <i>et al</i> <sup>[28]</sup> , 2016	56 y. o. F with dyspepsia and occasional vomiting for 1 yr. Mild epigastric tenderness	EGD: smooth 5-cm-wide antral bulge with overlying normal mucosa. Positive cushion sign. Endoscopic biopsy: chronic active gastritis from <i>Helicobacter pylori</i> . EUS: homogeneous, hyperechoic, mass arising from layer 3 of gastric wall, compatible with lipoma. Abdominal CT: homogeneous, 6-cm-wide, oval mass in antropyloric region, with density of fat	Antrum and pylorus along lesser curve Laparotomy: Excision of 6 cm wide, encapsulated tumor along lesser curve of stomach	Did well and discharged. Asymptomatic at 6 mo
Treska <i>et al</i> <sup>[29]</sup> , 1998	61 y. o. M with intermittent vomiting for several days. History of gastric ulcer N.A	UGI series: spherical, smooth, 4.0 cm × 4.5 cm defect in gastric antrum. EGD: protruding, yellowish tumor in prepylorus. Two ulcers above tumor. Abdominal ultrasound: 7 cm × 6 cm × 5 cm echogenic defect in wall of gastric antrum. Abdominal CT: prepyloric intramural lipoma	Gastric antrum. Laparotomy: 7.0 cm × 6.0 cm tumor in prepylorus. Tumor resection of lipoma with performance of Billroth II	Discharge 12 d postoperatively. No GI symptoms 8 mo after surgery
Lipoma discovered incidentally in work-up for other condition				
Al Shammari <i>et al</i> <sup>[30]</sup> , 2016	41 y. o. M presented for morbid obesity with a BMI of 43.9 kg/m <sup>2</sup> and history of obstructive sleep apnea. Normal routine blood tests	Abdominal ultrasound: liver span of 18.8 cm. EGD: rounded 3 cm × 3 cm mass in antrum with normal overlying mucosa. Positive cushion sign. Abdominal CT: 3.5 cm × 3.0 cm lesion in stomach suspicious for lipoma	Antrum. Laparoscopy: Intragastic submucosal mass excised from inside stomach after gastrostomy. Sleeve gastrectomy then performed for morbid obesity. Pathology: 4 cm × 3 cm × 2 cm lipoma	Discharged 4 d postoperatively. Asymptomatic at 2 wk of follow-up
Hyun <i>et al</i> <sup>[31]</sup> , 2002	22 y. o. M who underwent abdominal CT as preoperative evaluation of retroperitoneum before orchiectomy for testicular cancer. N.A	Abdominal CT: large gastric mass with attenuation of fat projecting into gastric lumen. EGD: large, soft, sessile mass on greater curve of stomach with overlying pink mucosa. Positive cushion sign. Endoscopic biopsies: normal mucosa. EUS: Submucosal mass with less echogenicity than expected for lipoma	Surgical resection: 12 cm × 9 cm × 2.5 cm mobile mass resected. Pathology: Submucosal gastric lipoma	Doing well at 2 mo follow-up
López-Zamudio <i>et al</i> <sup>[32]</sup> , 2015	59 y. o. M who underwent abdominal CT performed during episode of acute alcoholic pancreatitis revealed probable pyloroduodenal intussusception of a tumor with attenuation suggestive of fat. Hgb = 9.3 g/dL	EGD: 8 cm long polypoid mass impeding flow near pylorus. EGD biopsy: gastritis and incomplete intestinal metaplasia. Repeat EGD: greater curve posterior wall large pedunculated polyp with central ulceration Repeat EGD biopsies: chronic gastritis, focal ulceration intestinal metaplasia and <i>Helicobacter pylori</i> infection. EUS: 5.6 cm × 4.9 cm mass in gastric antrum in muscular layer	Surgery: 5 cm × 5 cm tumor in anterior wall of gastric antrum. Underwent antroduodenectomy with gastroduodenal anastomosis and Roux-en-Y	No postoperative surgical complications. Asymptomatic at 18 mo of follow-up

PMH: Previous medical history; GI: Gastrointestinal; y.o.: Years old; M: Male; F: Female; Hgb: Hemoglobin; BP: Blood pressure; EGD: Esophagogastroduodenoscopy; CT: Computerized tomograph; EUS: Endoscopic ultrasound; UGI: Upper gastrointestinal; USD: Ultrasound; N.A: Not applicable; NSAID: Nonsteroidal anti-inflammatory drug; WNL: Within normal limits; IV: Intravenous; MRI: Magnetic resonance imaging; RLQ: Right lower quadrant; PTST: Post traumatic stress disorder; BMI: Body mass index.



**Figure 1 Findings at esophagogastroduodenoscopy in two patients with giant gastric lipomas.** A: Patient 1. Esophagogastroduodenoscopy (EGD) in a 63-year-old male who presented with melena and a hemoglobin decline to 6.2 g/dL that required transfusion of 2 units of packed erythrocytes, showing the distal body and antrum with a huge mass folded upon itself occupying most of the lumen and an 8 mm wide, nonbleeding, acute mucosal ulcer without stigmata of recent hemorrhage embedded deep in the valley (fold) between the right and left parts of the mass. The ulcer was attributed to friction from the opposing surface. The mass was 13-cm-wide, submucosal, yellowish, and covered by smooth mucosa except for focal ulceration, findings consistent with a gastric lipoma; B: Patient 2. EGD in a 78-year-old woman, who presented with melena for 3 d, orthostatic dizziness, and a hemoglobin decline to 7.1 g/dL requiring transfusion of 2 units of packed erythrocytes, revealed an acute 1-cm-wide prepyloric ulcer (arrow) with a white exudate but without stigmata of recent hemorrhage between the right and left lobes of a large, well-demarcated, submucosal, mass covered by otherwise normal, superficial mucosa. This endoscopic photograph shows only a part of the mass.

analyzed esophagogastroduodenoscopies (EGDs) at two large hospitals.

## MATERIALS AND METHODS

The literature was systematically reviewed using PubMed for articles published since 1980 with the following medical subject heading (MeSH) or keywords: ("giant lipoma") AND (gastric) OR [("lipoma") and ("gastric") and ("bleeding")]; and by reviewing the section on gastrointestinal lipomas in standard pathology textbooks or monographs. Two authors independently reviewed the literature, and decided by consensus which articles to incorporate in this review. After reviewing one case from 1974<sup>[5]</sup>, cases reported before 1980 were selectively excluded because the preoperative evaluation at the time frequently used relatively obsolete tests such as UGI series and often lacked currently mandatory tests such as EGD. Four case reports, written in Spanish<sup>[9,11,13,32]</sup>, were professionally translated into English. Case reports of large gastric adenomas which did not satisfy the minimal size criteria of giant gastric lipomas ( $\geq 4$  cm) were systematically excluded<sup>[3,34]</sup>. A video publication was excluded because clinical details were not reported<sup>[35]</sup>. A clinical series of 16 gastric lipomas were excluded because this series lumped together medium-sized and giant lipomas<sup>[36]</sup>.

Computerized review of the pathology records at William Beaumont Hospitals at Royal Oak and at Troy, Michigan from January 2005–December 2015 using the computerized system of PowerPath (Tamtron) and SOFTPath with the software terms ("lipoma" or "lipomas") AND ("gastric" or "stomach") revealed 2 cases of giant gastric lipomas. Computerized review of the EGD reports using ProVations did not reveal any

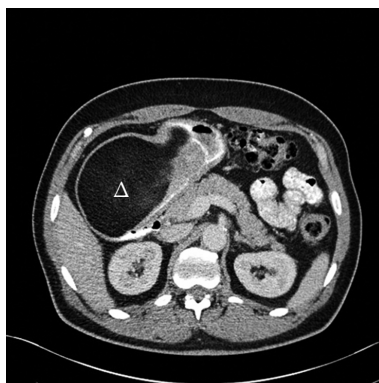
further cases. These 2 cases were thoroughly reviewed based on medical records, including re-review of the original endoscopic photographs by an expert endoscopist, radiologic images by an expert radiologist, and pathologic slides by an expert pathologist. This dual case report received exemption/approval by the IRB at William Beaumont Hospital, Royal Oak, on October 17, 2016.

## Illustrative case reports

**Case 1:** A 63-year-old, nonalcoholic, man with a medical history of hypertension treated with lisinopril, amlodipine, and nifedipine, and hyperlipidemia treated with lovastatin, presented with epigastric pain, early satiety, and involuntary 10-kg-weight-loss during the last 6 mo, and melena and dyspnea on exertion for 3 d. The vital signs were stable, with a blood pressure of 144/74 mmHg, and pulse of 87/min. The abdomen was soft, nontender, and without hepatosplenomegaly or palpable masses. Rectal examination revealed melena. The hemoglobin was 6.2 g/dL, blood urea nitrogen was 27 mg/dL, and creatinine was 1.40 mg/dL. He had 496000 platelets/mL, a normal international normalized ratio (INR), and normal partial thromboplastin time (PTT). He was transfused two units of packed erythrocytes.

EGD revealed a 13-cm-wide submucosal, yellowish, gastric mass primarily in the antrum, covered by smooth mucosa except for focal ulceration (Figure 1A), and exhibiting the pillow sign, of indentation of the mass with moderate pressure applied *via* a closed forceps<sup>[37,38]</sup>. Microscopic examination of multiple mucosal biopsies of the ulcer margin revealed superficial ulceration, granulation tissue, and no malignancy. Abdominal computerized tomography (CT) revealed a well-circumscribed, homogeneous, 13.4 cm  $\times$  8.4





**Figure 2** Abdominal computerized tomography findings in patient 1. A 63-year-old male (patient 1) presented with acute melena and hemoglobin decline to 6.2 g/dL, and esophagogastroduodenoscopy revealed a huge, submucosal mass with a smooth overlying surface and exhibiting the pillow sign characteristic of a submucosal lipoma. Illustrated abdominal computerized tomography shows an approximately 13.4 cm × 8.2 cm × 8.4 cm mostly homogeneous, hypodense mass with a characteristic attenuation of fat (-90.2 Hounsfield units) extending from proximal gastric body through entire antrum. The normal-appearing very proximal stomach is filled with oral contrast without a mass, and leads to a very narrow, compressed, distal and dorsal, gastric channel containing oral contrast that passes into the duodenum. Triangle: antral giant gastric lipoma which has the characteristic hypodense attenuation of fat.

cm × 8.2 cm mass, with attenuation characteristic of fat, arising from the gastric antrum and producing a mass effect on the proximal duodenum (Figure 2). A 7-mm-wide lesion in the body of the pancreas was also suspected to be a lipoma based on its characteristic attenuation. The patient underwent laparotomy due to the recent bleeding of the giant lipoma. It was resected *via* subtotal gastrectomy extended by partial bulbar duodenectomy due to lipoma extension into duodenal bulb, with Billroth II reconstruction. Gross pathology revealed a homogeneous, soft, submucosal mass with a cut surface exposing yellowish, greasy tissue, measuring 14.5 cm × 8.7 cm × 7.5 cm (Figure 3A), which microscopically revealed lipoma (Figure 4A). Immunohistochemical staining revealed positivity for CD34 (Figure 4B), a finding highly consistent with a spindle cell variant lipoma<sup>[39]</sup>. The patient was discharged 8 d postoperatively, and had no complications during 8 wk of follow-up.

**Case 2:** A 78-year-old, nonalcoholic, woman with a medical history of atrial fibrillation, peripheral neuropathy, hypertension, dyslipidemia, diabetes, chronic renal insufficiency, and hysterectomy for uterine fibroids, presented with melena for three days, associated with fatigue and orthostatic dizziness. Medications included warfarin, furosemide, metoprolol, diltiazem, atorvastatin, pioglitazone, amitriptyline, and glimepiride. Physical examination revealed stable vital signs, with a blood pressure of 124/67 mmHg, and pulse of 68/min. There was a heart murmur, and bilateral 3+ lower extremity edema. The abdomen was

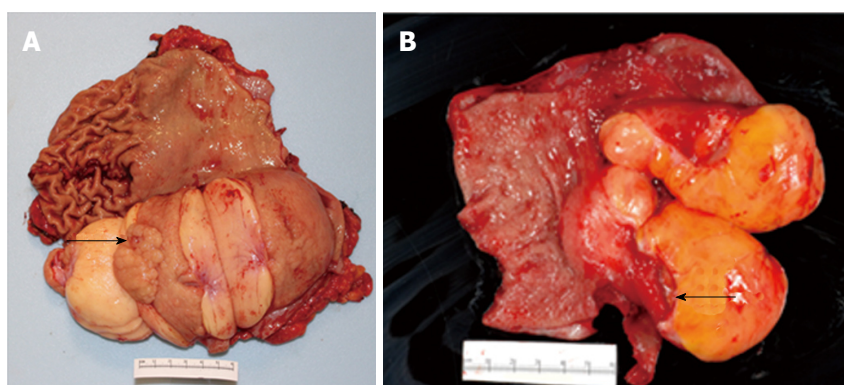
soft, and non-tender, with normoactive bowel sounds, and no organomegaly. Rectal examination revealed melena. The hemoglobin was 7.1 g/dL, INR was 4.9, platelet count was 306000/mL, and PTT was 42.5 s. The blood urea nitrogen was 44 mg/dL and creatinine was 1.8 mg/dL. An electrocardiogram revealed atrial fibrillation without acute ischemic changes.

She was transfused 2 units of packed erythrocytes and 2 units of fresh frozen plasma. Two-dimensional echocardiography revealed mild mitral valve regurgitation, moderate-to-severe right atrial dilatation, and severe tricuspid valve regurgitation. Abdominal CT revealed a submucosal, antral, gastric mass measuring 9.5 cm × 6.0 cm × 4.5 cm. EGD revealed a large, focally ulcerated, smooth, antral gastric mass, exhibiting the cushion sign (Figure 1B). Microscopic examination of multiple mucosal biopsies of the ulcer margin revealed superficial ulceration, granulation tissue, and no malignancy. The patient underwent surgery due to the recent bleeding of the giant lipoma. At laparotomy, the submucosal mass was excised by distal gastrectomy. Gross pathology of the resected mass revealed a relatively homogeneous, 9.0 cm × 6.0 cm × 4.5 cm, focally ulcerated, mass with a greasy, tan-yellow cut surface (Figure 3B), which microscopically was a lipoma (Figure 4C and D). The patient was discharged 5 d postoperatively with no further GI bleeding<sup>[37-39]</sup>.

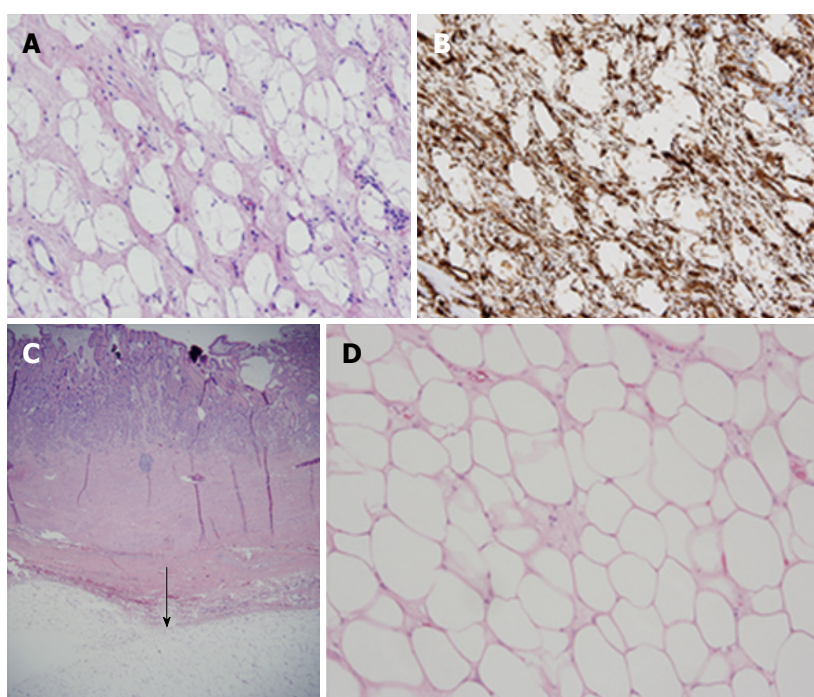
## RESULTS

Systematic literature review revealed that giant gastric lipomas are rare, with only 32 cases reported since 1980 (Table 1), and only 2 cases currently identified among 117110 EGDs performed during 11 years at William Beaumont Hospital, Royal Oak, one of the five largest hospitals in the United States, and at William Beaumont Hospital, Troy. The 32 reported patients were on average 54.5 ± 17.0 years old. Thirty were adult patients, and two were pediatric patients. Twenty-two were male, and 10 were female. Twenty-one patients had an ulcerated mass. The lipomas averaged 7.9 cm ± 4.1 cm in maximal dimension. Lipoma locations included antrum-17, body and antrum-4, antrum intussuscepting into small intestine-3, gastric body-2, fundus-1, and unspecified-5. This data confirms previous reports that giant gastric lipomas most commonly occur in the antrum<sup>[40]</sup>. Intramural locations included submucosal-22, subserosal-2, and unspecified-8. This data confirms previous reports that giant gastric lipomas are generally submucosal, but occasionally subserosal<sup>[22,36]</sup>.

Nineteen patients presented with acute UGI bleeding, including melena-11, hematemesis and melena-7, and hematemesis-1. Giant lipomas can ulcerate and bleed secondary to venous stasis<sup>[14]</sup>, friction and trauma



**Figure 3 Gross pathologic findings in gastrectomy specimens in two patients with giant gastric lipomas.** A: Patient 1. Patient 1 presented with acute melena and hemoglobin decline and had an ulcer detected at esophagogastroduodenoscopy (EGD) within a huge, lipomatous gastric mass. Gross pathologic view of the gastrectomy specimen after it is opened to expose the luminal surface shows a well-circumscribed, lobulated, 14.5 cm × 9.0 cm × 7.5 cm lipomatous mass extending from the gastric body (left) to antrum (right). A small ulcer (round depression, arrow) is present on the mucosa overlying the lipomatous mass. Normal gastric rugae are present above the mass on the upper left, but have been effaced on the upper right, likely because of chronic compression/pressure from the giant lipomatous mass located below (on the contralateral gastric wall before opening the stomach). Vertical incisions show a homogeneous yellow-tan cut surface, indicative of a lipomatous tumor; B: Patient 2. Patient 2 presented with melena for 3 d, orthostatic dizziness, and a hemoglobin decline to 7.1 g/dL requiring transfusion of 2 units of packed erythrocytes and had at EGD a large, yellowish, smooth, well-circumscribed antral mass. Gross pathologic view of distal gastrectomy specimen after it is opened to expose the luminal surface shows normal gastric antral tissue at left and a lobulated, well-circumscribed, yellow-tan, 9.0 cm × 6.0 cm × 3.5 cm lipomatous tumor at right, with a deep, clean-based, ulcer (arrow) on the mucosa overlying the mass.



**Figure 4 Histopathologic findings in gastrectomy specimens in two patients with giant gastric lipomas.** A: Patient 1-standard histochemistry. Medium power photomicrograph of a hematoxylin and eosin stain of a tissue section from the resected gastric mass in patient 1 reveals large adipocytes filled with clear, homogeneous, cytoplasm and tiny, compressed, peripheral nuclei. No lipoblasts are detected. Note the spindle-shaped stroma surrounding the adipocytes, findings consistent with spindle cell lipoma, as proven by immunohistochemistry (B); B: Patient 1-immunohistochemistry. Medium power photomicrograph of immunohistochemistry, using an antibody to CD34, reveals within tumor in patient 1 extensive staining in a spindly pattern of the stroma surrounding characteristically clear adipocytes, a characteristic staining pattern for spindle-shaped lipoma; C: Patient 2-standard histochemistry-low power. Low power photomicrograph of a hematoxylin and eosin stain of a tissue section from resected gastric mass in patient 2 reveals a well-circumscribed, submucosal layer composed of adipocytes with clear cytoplasm (arrow) and scant loose, myxoid stroma; D: Patient 2-standard histochemistry-medium power. Medium power photomicrograph of a hematoxylin and eosin stain of a tissue section from resected gastric mass in patient 2 reveals sheets of large, adipocytes filled with clear, homogeneous, cytoplasm and tiny, compressed, peripheral nuclei, with scant loose, myxoid stroma. No lipoblasts are detected. These histologic findings are characteristic of lipomas.

Table 2 Risks factors for upper gastrointestinal bleeding among 32 patients with giant gastric lipomas

Parameter	mean ± SD of parameter in patients with bleeding	mean ± SD of parameter in patients without bleeding	Patients with bleeding: <i>n</i> with parameter/ total <i>n</i> (% with parameter)	Patients without bleeding: <i>n</i> with parameter/ total <i>n</i> (% with parameter)	<i>P</i> value	OR	95%CI	Statistical test
Continuous variables								
Patient age	54.9 ± 15.5 yr	53.8 ± 19.6 yr	-	-	0.87	NA	NA	Student's <i>t</i> test
Lipoma size	7.1 cm ± 4.4 cm	9.3 cm ± 3.1 cm	-	-	0.16	NA	NA	Student's <i>t</i> test
Dichotomous variables								
Male sex	-	-	12/19 (63.2)	10/13 (76.9)	0.47	0.51	0.08-3.17	$\chi^2$ test
Ulcer overlying lipoma	-	-	16/19 (84.2)	4/13 (30.8)	0.004	12.0	1.72-101.9	Fisher's exact test

UGI: Upper gastrointestinal; *P*: Probability; NA: Not available.

of the lipoma tip against the wall contralateral to the lipoma attachment site, or, least likely, from outgrowing their blood supply. Among 19 patients presenting with acute GI bleeding, the hemoglobin on admission averaged 7.5 g/dL ± 2.8 g/dL (unavailable in 2 patients). Symptoms in the 19 patients included: weakness/fatigue-6, abdominal/epigastric pain-4, nausea and vomiting-4, epigastric fullness/early satiety-3, dizziness/presyncope-2, and belching-1. Signs included: pallor-7, epigastric tenderness-3, epigastric mass-3, tachycardia-2, and one each with diaphoresis or hypotension. Among four analyzed variables including age, sex, lipoma size, and lipoma ulceration, only lipoma ulceration was statistically significantly different (more common) in patients presenting with UGI bleeding, than in patients with other presentations (*P* = 0.004; Table 2). This difference emphasizes the importance of lipoma ulceration in the pathogenesis of bleeding.

Five patients presented predominantly with abdominal pain, without acute UGI bleeding, including 2 presenting with iron deficiency anemia. Additional symptoms in these 5 patients included early satiety-2, and anorexia-1. Five patients presented with nausea and vomiting. These patients had additional symptoms including dyspepsia/abdominal pain-3, weight loss-2, anorexia-1, and early satiety-1. Three patients had asymptomatic giant gastric lipomas incidentally detected: by EGD before bariatric surgery for morbid obesity; by abdominal CT in the evaluation of testicular cancer; and by abdominal CT for severe acute pancreatitis.

Thirty-one of the 32 patients underwent EGD (one other patient, see Methods section). EGD is standardly performed preoperatively to characterize the anatomy and show characteristic endoscopic features of lipomas. However, EGD frequently fails to obtain diagnostic tissue due to failure of superficial mucosal biopsies to reach submucosa. Among 12 patients in whom endoscopic biopsy results were reported in the present review, only 1 (8.3%) had lipoma diagnosed pathologically by endoscopic biopsies<sup>[18]</sup>. Pathologic findings in the other 11 reported biopsy specimens included chronic or nonspecific inflammation, gastritis, and normal or necrotic tissue. Repeated biopsies at the same site (well technique) may increase somewhat the diagnostic yield of endoscopic biopsies. Repeated or deep biopsies at EGD may expose yellow fat from the lipoma, a finding called the “naked fat” sign<sup>[41,42]</sup>. In the tenting sign observed at EGD the superficial mucosa retracts from the submucosal mass when it is grasped with a forceps because the submucosal lipoma has a fibrous capsule and does not infiltrate into the mucosa. Submucosal lipomas tend to be smooth except for focally ulcerated areas.

CT is currently the standard imaging modality. Lipomas are identified by having an attenuation ranging from -70 to -120 Hounsfield units, characteristic of fat density<sup>[20]</sup>. Twenty (95.2%) of 21 patients undergoing abdominal CT had CT findings highly suspicious for lipoma, and the other one had diagnostically helpful findings. CT findings consistent with a lipoma include: a well-circumscribed, submucosal, and homogeneous, mass with an attenuation characteristic of fat. Seven patients underwent upper gastrointestinal series which revealed mass size, mass location, and a smooth superficial layer, but did not show characteristic features of lipomas<sup>[4-6,13,18,26,29]</sup>. All 7 patients undergoing UGI series were reported in publications from 1998 or before, whereas only 4 of 21 patients undergoing CT were reported in publications from 1998 or before (17 CTs reported in publications from 1999-2016) (*P* < 0.00001, OR > 3.53, Fisher's exact test). This difference is consistent with replacement of UGI series by EGD and abdominal CT which provide superior characterization. In 9 (82%) of 11 cases abdominal ultrasound showed features suspicious for lipomas of a well-demarcated, submucosal, hyperechoic lesion, but the lesion was missed in 2 cases<sup>[4,9,11,16,19,20,22,26,27,29,30]</sup>. These results are consistent with abdominal ultrasound being a cheaper, but less definitive test than abdominal CT for giant gastric lipomas.



In 4 (80%) of 5 cases, endoscopic ultrasound (EUS) showed characteristic findings of a lipoma of a hyperechoic, well-localized, submucosal mass, but in one case the findings were atypical<sup>[17,24,28,31,32]</sup>. EUS is useful to identify the primary wall layer of lipomas<sup>[22,43]</sup>. The currently reported findings are consistent with EUS being an important adjunct test when abdominal CT is non-diagnostic, when a tissue diagnosis is needed preoperatively because of non-diagnostic EGD biopsies, or prior to endoscopic mucosal resection. Both patients undergoing abdominal magnetic resonance imaging (MRI) had important findings showing tumor anatomy and exhibiting signals characteristic of fat<sup>[16,20]</sup>.

Therapy was successful in all 32 patients including laparotomy with full-thickness resection of gastric wall containing tumor either *via* wedge resection, partial gastrectomy, Billroth I resection or other surgery-26; laparotomy with enucleation-2; laparoscopic transgastric resection-2; endoscopic mucosal resection-1, and successful laparotomy with polypectomy after unsuccessful, attempted endoscopic polypectomy-1. No patient suffered major postoperative or postprocedural complications. No patient died from GI bleeding from the lipoma, from the surgery, or from endoscopic therapy.

When GI bleeding or gastric obstruction are associated with a large, ulcerated gastric mass, gastric malignancy may be suspected. It is critical to preoperatively exclude liposarcomas from giant lipomas because liposarcomas require further genetic analysis of pathologic specimens, and chemotherapy after surgical resection<sup>[44]</sup>. Lipomas have well-demarcated margins on radiologic imaging due to the presence of a fibrous capsule. They are well-differentiated, devoid of lipoblasts, and grow slowly. Liposarcomas have a densitometry close to normal submucosal tissue at abdominal CT<sup>[20,45]</sup>, and are definitively diagnosed by MDM2 and CDK4 gene amplification<sup>[21,26]</sup>. Other tumors in the differential diagnosis of giant lipomas include GI stromal tumors, such as leiomyoma and fibroma; and rarely intramural tumors, such as neurilemoma, adenomyoma, Brunner's gland adenoma, and heterotopic pancreas<sup>[22]</sup>.

Treatment for lipomas is not standardized. They are often resected endoscopically when < 4-6 cm, and surgically when > 6 cm<sup>[14,22]</sup>, but endoscopy has been used to resect up to 9-cm-wide gastric lipomas<sup>[25]</sup>. Lipomas may sometimes be resected by enucleation because they are encapsulated. Resection *via* subtotal gastrectomy entails much greater morbidity from potential complications of anastomotic leakage, duodenal stump rupture, obstruction, hemorrhage, decreased acid production, delayed gastric emptying,

gastroesophageal reflux, and vitamin B12, folate, iron, or calcium deficiencies<sup>[24]</sup>.

## DISCUSSION

The current literature review demonstrates characteristic findings of giant gastric lipomas at EGD, abdominal CT, EUS, and immunohistochemistry, as summarized in Table 3<sup>[3,8,14,18,20,22,36-38,40-42,47-52]</sup>. The two currently reported cases illustrate characteristic features of giant gastric lipomas: frequently presenting with acute UGI bleeding which is often severe and life-threatening, characteristic endoscopic features, characteristic CT findings, pathologic findings indicating benignity, and excellent post-operative prognosis with rare major morbidity or mortality.

The current case reports are limited by retrospective analysis, and by only reporting 2 cases due to disease rarity. The current literature review is likewise limited first, by consisting of single case reports due to syndrome rarity; and second, by retrospectively reporting of case reports. Individually reported cases may be subject to selection bias with preferential reporting of more clinically dramatic or more successful therapeutic interventions. Third, cases from different centers reported somewhat variable clinical data, such as variable follow-up and variable imaging tests (*e.g.*, abdominal CT vs MRI). Fourth, the evaluation of lipomas has evolved over time due to development of better diagnostic tests. This effect was minimized by excluding cases reported before 1980. Fifth, imaging tests were interpreted by various radiologists and pathology specimens were interpreted by various pathologists at various hospitals in the prior case reports.

In conclusion, this systematic literature review provides a comprehensive analysis to help optimize the evaluation and management of suspected giant gastric lipomas. CT and EGD are the standard tests to evaluate suspected giant gastric lipomas. When giant gastric lipomas are identified at abdominal CT by characteristic findings of a homogeneous, well-circumscribed, submucosal mass with characteristic attenuation of fat, EGD with biopsies should be performed, but the endoscopic biopsies may be non-diagnostic. EUS with deep biopsies may be performed to obtain a definitive diagnosis if biopsies from EGD are non-diagnostic. Liposarcoma should be excluded by cytogenetic analysis when necessary. If lipoma is confirmed, endoscopic resection of only the lipoma and its fibrous capsule may be feasible for small-to-moderate sized lesions, with subtotal gastrectomy reserved for especially large lipomas.



**Table 3** Distinctive features of giant gastric lipomas

Test/technique/parameter	Distinctive characteristic	Pathophysiology	Ref.
Age	Average age = 54.5 ± 17.0 years old		Current Report
Gender ratio	Male-to-Female ratio approximately 2:1	Unknown (sexual hormones?)	Current Report
Lipoma size	Average maximal dimension = 7.9 cm × 4.1 cm		Current Report
Most common clinical presentation	19 of 32 presented with acute UGI bleeding	Postulated from ulcer at tip of lipoma caused by rubbing/trauma of tip against gastric wall contralateral to base of lipoma	Current Report
EGD	Smooth bulge covered by normal mucosa	Submucosal (or occasionally subserosal) location. No tumor invading mucosa due to benignity	Neto <i>et al</i> <sup>[22]</sup> , 2012, Thompson <i>et al</i> <sup>[36]</sup> , 2003
	Most commonly located in gastric antrum		Thompson <i>et al</i> <sup>[36]</sup> , 2003, Menon <i>et al</i> <sup>[40]</sup> , 2014
	Yellowish hue	Yellow color of adipose tissue in submucosa transmitted to mucosal surface	Menon <i>et al</i> <sup>[40]</sup> , 2014, Chen <i>et al</i> <sup>[41]</sup> , 2014
	Broad base	Rarely pedunculated	Singh <i>et al</i> <sup>[18]</sup> , 1987
	Cushion or pillow sign: easily deforms like a cushion with mild pressure applied against it by an endoscopic probe (closed biopsy forceps).	Lipoma consists of soft, compressible tissue.	De Beer <i>et al</i> <sup>[37]</sup> , 1975, Hwang <i>et al</i> <sup>[38]</sup> , 2005
	Tenting sign: Mucosa easily retracts after it is grasped and gently pulled with a forceps	Mucosa separates from submucosa when gently pulled <i>via</i> forceps because lipoma has fibrous capsule and does not infiltrate into adjacent tissue	Priyadarshi <i>et al</i> <sup>[14]</sup> , 2015
	Naked fat sign: repeated biopsies at same site reveals yellow fatty tissue	Multiple biopsies at same site (using well technique) exposes submucosal lipomatous tissue	Chen <i>et al</i> <sup>[41]</sup> , 2014, Patrick <i>et al</i> <sup>[42]</sup> , 2007
	Moderately frequent focal central ulceration of mucosa	Likely secondary to giant lipoma abutting and rubbing against contralateral gastric wall. Ischemia may also contribute to ulceration.	Kumar, <i>et al</i> <sup>[8]</sup> , 2015, Thompson <i>et al</i> <sup>[36]</sup> , 2003
Highly useful diagnostic test for lipomas	Typically strongly suggestive of diagnosis	Demonstrates anatomy of mass. Shows if ulcerated or intussuscepting mass. Characteristic findings: yellow hue, smooth overlying mucosa, relatively homogeneous, round margins. Exhibits pillow, tenting or naked fat signs.	Current Report
Endoscopic biopsies	Standard endoscopic biopsies usually reveal only normal mucosa and insensitive for pathologic diagnosis.	Standard endoscopic biopsies typically sample superficial mucosa and miss deeper submucosal lipoma.	Current Report, Neto <i>et al</i> <sup>[22]</sup> , 2012
	Techniques to increase yield of endoscopic biopsies; use jumbo forceps for endoscopic biopsies; or well technique (repeated endoscopic biopsies at same mucosal site).	Repeated biopsies at same site permits sampling of deeper (submucosal) tissue	Wang <i>et al</i> <sup>[47]</sup> , 2015
Abdominal CT	Submucosal mass	Typically submucosal, occasionally subserosal, and never mucosal.	Beck <i>et al</i> <sup>[3]</sup> , 1997
	Well-circumscribed with well-defined edges	Characteristically has a firm fibrous capsule with no invasion through capsule due to benignity	Thompson <i>et al</i> <sup>[36]</sup> , 2003
	Typically solitary	Multiple gastric lipomas are very rare	Park <i>et al</i> <sup>[48]</sup> , 1999, Skinner, <i>et al</i> <sup>[49]</sup> , 1983
	Homogeneous	Composed of homogeneous lipocytes	Park <i>et al</i> <sup>[48]</sup> , 1999, Alkhatib <i>et al</i> <sup>[50]</sup> , 2012
	Densitometry of -80 to -120 HU (Hounsfield units).	Characteristic of adipose tissue	Alberti <i>et al</i> <sup>[20]</sup> , 1999
Highly useful as diagnostic test for gastric lipomas	Demonstrates characteristic findings in about 95% of cases.	Characteristic findings: well-circumscribed, submucosal, homogeneous mass with an attenuation characteristic of fat.	Current Report
EUS	In third layer of gastric wall	Typically submucosal (rarely subserosal)	Chen <i>et al</i> <sup>[43]</sup> , 2011
	Hyperechoic (bright)		Alkhatib <i>et al</i> <sup>[50]</sup> , 2012, Eckardt <i>et al</i> <sup>[51]</sup> , 2012

EUS-guided needle biopsy or endoscopic mucosal resection	EUS guidance used to obtain diagnostic deep (submucosal) biopsies	Deep biopsies permit sampling of submucosal lipomas	Alkhatib <i>et al</i> <sup>[50]</sup> , 2012, Karaca <i>et al</i> <sup>[52]</sup> , 2010
Transcutaneous abdominal ultrasound	Not very useful for gastric lipomas.	Supplanted by abdominal CT or EUS for evaluating suspected gastric lipomas	Current Report
Upper gastrointestinal series	Mostly obsolete test	CT is a superior alternative	Current Report
Histopathology	Diagnostic features	Rounded, plump cells with abundant clear, homogeneous cytoplasm containing fat, eccentric nuclei, mature adipocytes with no lipoblasts, scant stroma, rare inflammatory cells.	Current Report
Immunohistochemistry	Reveals no MDM2 or CDK4 gene amplification.	Distinguishes lipoma from liposarcoma.	Shimada <i>et al</i> <sup>[45]</sup> , 2006, Boltze <i>et al</i> <sup>[46]</sup> , 2001
Immunohistochemistry	Lipoma stains positively for CD4	Indicates spindle-cell lipoma variant	Lau <i>et al</i> <sup>[39]</sup> , 2015

UGI: Upper gastrointestinal; EGD: Esophagogastroduodenoscopy; CT: Computerized tomography; EUS: Endoscopic ultrasound.

## COMMENTS

### Background

Gastric lipomas are rare, constituting < 1% of all gastric tumors, and giant gastric lipomas ( $\geq 4$  cm) are extremely rare, with this systematic review identifying only 32 cases reported since 1980. Although small gastric lipomas are usually asymptomatic, giant gastric lipomas typically produce major, clinically important, symptoms from GI obstruction, tumor ulcers, or upper gastrointestinal bleeding. Due to its extreme rarity, all prior studies of giant gastric lipomas have comprised single case reports. The individual case reports are scattered among numerous, and sometimes obscure, journals. This work systematically reviews the literature since 1980, to comprehensively report what is known about this disease and to inform clinicians and clinical researchers what is not known or controversial about this disease.

### Research frontiers

A systematic review is important to collate all the prior data presented as case reports to establish what is known about the clinical evaluation (tests) for this disease. This systematic review demonstrates that the standard clinical evaluation should include: (1) abdominopelvic computerized tomography (CT) to demonstrate the characteristic CT findings of a giant gastric lipoma of a well-circumscribed, submucosal, and homogeneous mass with attenuation of fat; and (2) esophagogastroduodenoscopy (EGD) to demonstrate the characteristic endoscopic findings of these lesions of yellowish hue, well-demarcated margins, smooth overlying mucosa, and endoscopic cushion, tenting, or naked fat signs.

This systematic review demonstrates that the following tests are nonstandard or generally obsolete tests: (1) upper gastrointestinal series has been superseded by EGD and should only be performed in highly unusual circumstances; and (2) traditional abdominal ultrasound has been largely superseded by abdominopelvic CT which is a better diagnostic test for this condition, and the traditional abdominal ultrasound should be performed only if the differential diagnosis is broad and not specifically directed at documenting a giant gastric lipoma.

This work systematically reviews several clinically important but controversial topics, including: (1) the role of endoscopic ultrasound: this work shows that conventional mucosal endoscopic biopsies frequently result in a non-diagnostic pathologic diagnosis because giant gastric lipomas are generally submucosal, and therefore endoscopic ultrasound with ultrasound-guided needle biopsies may be necessary if preoperative tissue diagnosis is not obtained by conventional mucosal endoscopic biopsies; and (2) the relative roles of the available therapies: endoscopic mucosal resection, laparoscopic transgastric resection, laparotomy with enucleation, laparotomy with full-thickness wedge resection, and laparotomy with partial gastrectomy and gastric reconstruction.

### Innovations and breakthroughs

While several case reports have recently been published on giant gastric

lipomas, these case reports generally incorporate limited literature reviews. The present work differs in that it provides a systematic review of the literature. The present work also reports 2 new cases of giant gastric lipomas in a review of 117110 EGDs performed during 11 years at two large teaching hospitals.

### Applications

This work provides the following highly clinically relevant conclusions: (1) standard evaluation for suspected giant gastric lipomas should include EGD to demonstrate the characteristic endoscopic findings of yellowish hue, well-demarcated margins, smooth overlying mucosa, and endoscopic cushion, tenting, or naked fat signs; (2) at EGD a submucosal mass that is a suspected lipoma should be biopsied, even though the yield of superficial endoscopic biopsies in pathologically diagnosing a gastric lipoma is relatively low. The diagnostic yield of biopsies at EGD may be increased by using jumbo forceps for the biopsies, or by repeated biopsies at the same site ("well" or biopsy-on-biopsy technique); (3) abdominopelvic CT is a standard test in the evaluation of suspected giant gastric lipomas to demonstrate the characteristic CT findings of a giant gastric lipoma of a well-circumscribed, submucosal, and homogeneous mass with characteristic attenuation of fat; (4) upper gastrointestinal (UGI) series is now generally considered an obsolete test for evaluation of suspected giant gastric lipomas and should be replaced by EGD; (5) conventional abdominal ultrasound is not the preferred test for highly suspected giant gastric lipomas, and should be replaced for this indication by abdominopelvic CT. However, abdominal ultrasound may be a very useful initial imaging test for numerous abdominal conditions in which giant gastric lipoma is in the differential diagnosis; and (6) due to scant data about this rare lesion, and absence of prospective, controlled, therapeutic trials there is no universally accepted standardization of preferred therapies for giant gastric lipomas. Reported therapies include endoscopic mucosal resection, laparoscopic transgastric resection, laparotomy with enucleation, laparotomy with full-thickness wedge resection, and laparotomy with partial gastrectomy and gastric reconstruction. All the reported therapies result in a highly favorable prognosis with no reported mortality among the 32 currently reviewed cases and rare severe morbidity because this tumor is benign, is characteristically biologically nonaggressive, and is well-encapsulated that renders it readily amenable to resection. There is recent interest on selecting less invasive techniques for lesion removal, including endoscopic mucosal resection or laparoscopic removal, as opposed to the traditional laparotomy for removal. This systematic review shows that further research is needed on the optimal therapy for giant gastric lipomas, and on individualizing the therapy according to the clinical presentation.

### Terminology

The term giant gastric lipomas refers to gastric lipomas  $\geq 4$  cm in diameter. The distinction of size  $\geq 4$  cm vs size < 4 cm is clinically important because gastric lipomas  $\geq 4$  cm generally produce major clinical symptoms from GI obstruction, tumor ulcers, or upper gastrointestinal bleeding, whereas smaller lesions are usually asymptomatic or produce minor symptoms. Furthermore, lesion size often affects the selected therapeutic modality, with lipomas < 4 cm

in diameter often removed endoscopically and lipomas  $\geq 4$  cm in diameter generally removed surgically.

### Peer-review

This is a very important review paper of the main characteristics of the giant gastric lipomas studied in one Hospital through 10 years of study and follow-up. The diagnosis is very well established and also the treatment and prognosis.

## REFERENCES

- Ramdass MJ, Mathur S, Seetahal-Maraj P, Barrow S. Gastric lipoma presenting with massive upper gastrointestinal bleeding. *Case Rep Emerg Med* 2013; **2013**: 506101 [PMID: 24363942 DOI: 10.1155/2013/506101]
- Almohsin M, Meshikhes AW. Gastric lipoma presenting with haematemesis. *BMJ Case Rep* 2015; **2015**: pii: bcr2014206884 [PMID: 25634856 DOI: 10.1136/bcr-2014-206884]
- Beck NS, Lee SK, Lee HJ, Kim HH. Gastric lipoma in a child with bleeding and intermittent vomiting. *J Pediatr Gastroenterol Nutr* 1997; **24**: 226-228 [PMID: 9106113]
- Bijlani RS, Kulkarni VM, Shahani RB, Shah HK, Dalvi A, Samsi AB. Gastric lipoma presenting as obstruction and hematemesis. *J Postgrad Med* 1993; **39**: 42-43 [PMID: 8295149]
- Bloch C, Peck HM. Case report: Giant gastric lipoma. *Mt Sinai J Med* 1974; **41**: 593-596 [PMID: 4546504]
- Chu AG, Clifton JA. Gastric lipoma presenting as peptic ulcer: case report and review of the literature. *Am J Gastroenterol* 1983; **78**: 615-618 [PMID: 6605087]
- Kibria R, Butt S, Ali SA, Akram S. An unusual case of giant gastric lipoma with hemorrhage. *J Gastrointest Cancer* 2009; **40**: 144-145 [PMID: 19936642 DOI: 10.1007/s12029-009-9095-6]
- Kumar P, Gray C. Gastric lipoma: a rare cause of gastrointestinal bleeding. *ANZ J Surg* 2015; Epub ahead of print [PMID: 25708232 DOI: 10.1111/ans.13019]
- López Cano A, Soria de la Cruz MJ, Rendon Unceta P, Moreno Gallego M, Gúezmes Domingo A, Martín Herrera L. [Gastric lipoma diagnosed using transcutaneous echography with a fluid-filled stomach]. *Rev Esp Enferm Dig* 1991; **80**: 261-263 [PMID: 1805892]
- Myint M, Atten MJ, Attar BM, Nadimpalli V. Gastric lipoma with severe hemorrhage. *Am J Gastroenterol* 1996; **91**: 811-812 [PMID: 8677963]
- Ortiz de Solórzapo Aurusa FJ, Yarritu Viilanueva C, Ruiz Adrados E, Obelar Bernal L, Acebo García M, Alvarez Rabanal R, Viguri Díaz A. [Gastroduodenal invagination and upper gastrointestinal hemorrhage secondary to gastric lipoma]. *Gastroenterol Hepatol* 1997; **20**: 303-305 [PMID: 9296846]
- Paksoy M, Böler DE, Baca B, Ertürk S, Kapan S, Bavunoglu I, Sirin F. Laparoscopic transgastric resection of a gastric lipoma presenting as acute gastrointestinal hemorrhage. *Surg Laparosc Endosc Percutan Tech* 2005; **15**: 163-165 [PMID: 15956902]
- Pérez Cabañas I, Rodríguez Garrido J, De Miguel Velasco M, Ortiz Hurtado H. [Gastric lipoma: an infrequent cause of upper digestive hemorrhage]. *Rev Esp Enferm Dig* 1990; **78**: 163-165 [PMID: 2278742]
- Priyadarshi RN, Anand U, Pandey MK, Chaudhary B, Kumar R. Giant Gastric Lipoma Presenting as Gastric Outlet Obstruction - A Case Report. *J Clin Diagn Res* 2015; **9**: PD03-PD04 [PMID: 26557564 DOI: 10.7860/JCDR/2015/14816.6595]
- Rao C, Rana SS, Lal A, Kumar M, Behera A, Dahiya D, Joshi K, Bhasin DK. Large gastric lipoma presenting with GI bleeding. *Gastrointest Endosc* 2013; **77**: 512-513 [PMID: 23410704 DOI: 10.1016/j.gie.2012.10.022]
- Regge D, Lo Bello G, Martincich L, Bianchi G, Cuomo G, Suriani R, Cavuoto F. A case of bleeding gastric lipoma: US, CT and MR findings. *Eur Radiol* 1999; **9**: 256-258 [PMID: 10101647 DOI: 10.1007/s003300050664]
- Sadio A, Peixoto P, Castanheira A, Cancela E, Ministro P, Casimiro C, Silva A. Gastric lipoma--an unusual cause of upper gastrointestinal bleeding. *Rev Esp Enferm Dig* 2010; **102**: 398-400 [PMID: 20575608]
- Singh K, Venkateshwarlu K, Malik AK, Nagi B, Yadav RV. Giant gastric lipoma presenting with fever and melena. *Indian J Gastroenterol* 1987; **6**: 181-182 [PMID: 3610264]
- Youssef PS, Wihelm LH, Schwesinger GO, Howell TD, Petermann J, Zippel RW. Gastric lipoma: A rare cause of gastrointestinal bleeding. *Saudi Med J* 1999; **20**: 891-892 [PMID: 27645018]
- Alberti D, Grazioli L, Orizio P, Matricardi L, Dughi S, Gheza L, Falchetti D, Caccia G. Asymptomatic giant gastric lipoma: What to do? *Am J Gastroenterol* 1999; **94**: 3634-3637 [PMID: 10606334 DOI: 10.1111/j.1572-0241.1999.01391.x]
- Hamdane MM, Brahim EB, Salah MB, Haouas N, Bouhafa A, Chedly-Debbiche A. Giant gastric lipoma mimicking well-differentiated liposarcoma. *Gastroenterol Hepatol Bed Bench* 2012; **5**: 60-63 [PMID: 24834200]
- Neto FA, Ferreira MC, Bertoncello LC, Neto AA, de Aveiro WC, Bento CA, Cecchino GN, Rocha MA. Gastric lipoma presenting as a giant bulging mass in an oligosymptomatic patient: a case report. *J Med Case Rep* 2012; **6**: 317 [PMID: 23006791 DOI: 10.1186/1752-1947-6-317]
- Ramaraj R, Roberts SA, Clarke G, Williams G, Thomas GA. A rare case of iron deficiency. *Eur J Gastroenterol Hepatol* 2012; **24**: 82-83 [PMID: 22008628 DOI: 10.1097/MEG.0b013e328348d642]
- Zak Y, Biagini B, Moore H, Desantis M, Ghosh BC. Submucosal resection of giant gastric lipoma. *J Surg Oncol* 2006; **94**: 63-67 [PMID: 16788947 DOI: 10.1002/jso.20551]
- Aslan F, Akpinar Z, Cekic C, Alper E. En bloc resection of a 9 cm giant gastro-duodenal lipoma by endoscopic submucosal dissection. *Dig Liver Dis* 2015; **47**: 88-89 [PMID: 25304152 DOI: 10.1016/j.dld.2014.09.005]
- Lin F, Setya V, Signor W. Gastroduodenal intussusception secondary to a gastric lipoma: a case report and review of the literature. *Am Surg* 1992; **58**: 772-774 [PMID: 1456605]
- Mouës CM, Steenvoorde P, Viersma JH, van Groningen K, de Bruïne JF. Jejunal intussusception of a gastric lipoma: a review of literature. *Dig Surg* 2002; **19**: 418-420 [PMID: 12435918]
- Nasa M, Choksey A, Phadke A, Sawant P. Gastric lipoma: an unusual cause of dyspeptic symptoms. *BMJ Case Rep* 2016; **2016**: [PMID: 27335362 DOI: 10.1136/bcr-2016-215297]
- Treska V, Pesek M, Kreuzberg B, Chudáček Z, Ludvíková M, Topolcan O. Gastric lipoma presenting as upper gastrointestinal obstruction. *J Gastroenterol* 1998; **33**: 716-719 [PMID: 9773937]
- Al Shammari JO, Al-Shadidi N, Abdulsalam AJ, Al-Daihani AE. Gastric lipoma excision during a laproscopic sleeve gastrectomy: A case report. *Int J Surg Case Rep* 2016; **24**: 128-130 [PMID: 27239791 DOI: 10.1016/j.ijscr.2016.05.040]
- Hyun CB, Coyle WJ. Giant gastric lipoma. *Gastrointest Endosc* 2002; **56**: 905 [PMID: 12447308 DOI: 10.1067/mge.2002.127159]
- López-Zamudio J, Leonher-Ruezga KL, Ramírez-González LR, Razo Jiménez G, González-Ojeda A, Fuentes-Orozco C. [Pedicled gastric lipoma. Case report]. *Cir Cir* 2015; **83**: 222-226 [PMID: 26055284 DOI: 10.1016/j.circir.2015.05.005]
- Dargan P, Sodhi P, Jain BK. Bleeding gastric lipoma: case report and review of the literature. *Trop Gastroenterol* 2003; **24**: 213-214 [PMID: 15164538]
- Johnson DC, DeGennaro VA, Pizzi WF, Nealon TF Jr. Gastric lipomas: a rare cause of massive upper gastrointestinal bleeding. *Am J Gastroenterol* 1981; **75**: 299-301 [PMID: 6973271]
- Suarez AL, Dufault DL, Mcvey MC, Shetty A, Elmunzer BJ. Stepwise endoscopic resection of a large gastric lipoma causing gastric outlet obstruction and GI bleeding. *Gastrointest Endosc* 2016; **84**: 180 [PMID: 26958739 DOI: 10.1016/j.gie.2016.02.036]
- Thompson WM, Kende AI, Levy AD. Imaging characteristics of gastric lipomas in 16 adult and pediatric patients. *AJR Am J Roentgenol* 2003; **181**: 981-985 [PMID: 14500213 DOI: 10.2214/ajr.181.4.1810981]
- De Beer RA, Shinya H. Colonic lipomas. An endoscopic analysis.

- Gastrointest Endosc* 1975; **22**: 90-91 [PMID: 1193347]
- 38 **Hwang JH**, Saunders MD, Rulyak SJ, Shaw S, Nietsch H, Kimmy MB. A prospective study comparing endoscopy and EUS in the evaluation of GI subepithelial masses. *Gastrointest Endosc* 2005; **62**: 202-208 [PMID: 16046979]
  - 39 **Lau SK**, Bishop JA, Thompson LD. Spindle cell lipoma of the tongue: a clinicopathologic study of 8 cases and review of the literature. *Head Neck Pathol* 2015; **9**: 253-259 [PMID: 25319950 DOI: 10.1007/s12105-014-0574-0]
  - 40 **Menon L**, Buscaglia JM. Endoscopic approach to subepithelial lesions. *Therap Adv Gastroenterol* 2014; **7**: 123-130 [PMID: 24790643 DOI: 10.1177/1756283X13513538]
  - 41 **Chen Y**, Andrews CN. Luminal lipoma: the “pot-of-gold” sign. *Gastrointest Endosc* 2014; **79**: 167; discussion 167 [PMID: 24112591 DOI: 10.1016/j.gie.2013.08.036]
  - 42 **Patrick A**, Epstein O. The naked fat sign. *Gastrointest Endosc* 2008; **67**: 158; commentary 159 [PMID: 17981277 DOI: 10.1016/j.gie.2007.07.030]
  - 43 **Chen HT**, Xu GQ, Wang LJ, Chen YP, Li YM. Sonographic features of duodenal lipomas in eight clinicopathologically diagnosed patients. *World J Gastroenterol* 2011; **17**: 2855-2859 [PMID: 21734794 DOI: 10.3748/wjg.v17.i23.2855]
  - 44 **Crago AM**, Dickson MA. Liposarcoma: Multimodality Management and Future Targeted Therapies. *Surg Oncol Clin N Am* 2016; **25**: 761-773 [PMID: 27591497 DOI: 10.1016/j.soc.2016.05.007]
  - 45 **Shimada S**, Ishizawa T, Ishizawa K, Matsumura T, Hasegawa T, Hirose T. The value of MDM2 and CDK4 amplification levels using real-time polymerase chain reaction for the differential diagnosis of liposarcomas and their histologic mimickers. *Hum Pathol* 2006; **37**: 1123-1129 [PMID: 16938516 DOI: 10.1016/j.humpath.2006.04.010]
  - 46 **Boltze C**, Schneider-Stock R, Jäger V, Roessner A. Distinction between lipoma and liposarcoma by MDM2 alterations: a case report of simultaneously occurring tumors and review of the literature. *Pathol Res Pract* 2001; **197**: 563-568 [PMID: 11518050 DOI: 10.1078/0344-0338-00128]
  - 47 **Wang H**, Tan Y, Zhou Y, Wang Y, Li C, Zhou J, Duan T, Zhang J, Liu D. Submucosal tunneling endoscopic resection for upper gastrointestinal submucosal tumors originating from the muscularis propria layer. *Eur J Gastroenterol Hepatol* 2015; **27**: 776-780 [PMID: 25966671 DOI: 10.1097/MEG.0000000000000394]
  - 48 **Park SH**, Han JK, Kim TK, Lee JW, Kim SH, Kim YI, Choi BI, Yeon KM, Han MC. Unusual gastric tumors: radiologic-pathologic correlation. *Radiographics* 1999; **19**: 1435-1446 [PMID: 10555667 DOI: 10.1148/radiographics.19.6.g99no051435]
  - 49 **Skinner MS**, Broadway RK, Grossman P, Seckinger D. Multiple gastric lipomas. *Dig Dis Sci* 1983; **28**: 1147-1149 [PMID: 6606546]
  - 50 **Alkhatib AA**, Faigel DO. Endoscopic ultrasonography-guided diagnosis of subepithelial tumors. *Gastrointest Endosc Clin N Am* 2012; **22**: 187-205, vii [PMID: 22632943 DOI: 10.1016/j.giec.2012.04.006]
  - 51 **Eckardt AJ**, Jenssen C. Current endoscopic ultrasound-guided approach to incidental subepithelial lesions: optimal or optional? *Ann Gastroenterol* 2015; **28**: 160-172 [PMID: 25830949]
  - 52 **Karaca C**, Turner BG, Cizginer S, Forcione D, Brugge W. Accuracy of EUS in the evaluation of small gastric subepithelial lesions. *Gastrointest Endosc* 2010; **71**: 722-727 [PMID: 20171632 DOI: 10.1016/j.gie.2009.10.019]

**P- Reviewer:** Mocellin S, Rodrigo L **S- Editor:** Ma YJ **L- Editor:** A  
**E- Editor:** Huang Y





# Acute colonic pseudo-obstruction: A systematic review of aetiology and mechanisms

Cameron I Wells, Gregory O'Grady, Ian P Bissett

Cameron I Wells, Gregory O'Grady, Ian P Bissett, Department of Surgery, University of Auckland, Auckland 1010, New Zealand

Gregory O'Grady, Ian P Bissett, Department of Surgery, Auckland District Health Board, Auckland 1010, New Zealand

**Author contributions:** All authors contributed to conception and design of the study; Wells CI acquired and analysed data; all authors contributed to interpretation of data, drafting and revising of the manuscript; all authors have given final approval of the version of the article to be published.

**Conflict-of-interest statement:** The authors have no conflicts of interest to declare.

**Data sharing statement:** No additional data are available.

**Open-Access:** This article is an open-access article which was selected by an in-house editor and fully peer-reviewed by external reviewers. It is distributed in accordance with the Creative Commons Attribution Non Commercial (CC BY-NC 4.0) license, which permits others to distribute, remix, adapt, build upon this work non-commercially, and license their derivative works on different terms, provided the original work is properly cited and the use is non-commercial. See: <http://creativecommons.org/licenses/by-nc/4.0/>

**Manuscript source:** Invited manuscript

**Correspondence to:** Dr. Ian P Bissett, Professor, Department of Surgery, University of Auckland, Private Bag 92019, Auckland Mail Centre 1142, Auckland 1010, New Zealand. [i.bissett@auckland.ac.nz](mailto:i.bissett@auckland.ac.nz)  
Telephone: +64-9-3737599-89821  
Fax: +64-9-3779656

Received: May 26, 2017

Peer-review started: May 28, 2017

First decision: June 23, 2017

Revised: June 29, 2017

Accepted: July 22, 2017

Article in press: July 24, 2017

Published online: August 14, 2017

## Abstract

### AIM

To critically review the literature addressing the definition, epidemiology, aetiology and pathophysiology of acute colonic pseudo-obstruction (ACPO).

### METHODS

A systematic search was performed to identify articles investigating the aetiology and pathophysiology of ACPO. A narrative synthesis of the evidence was undertaken.

### RESULTS

No consistent approach to the definition or reporting of ACPO has been developed, which has led to overlapping investigation with other conditions. A vast array of risk factors has been identified, supporting a multifactorial aetiology. The pathophysiological mechanisms remain unclear, but are likely related to altered autonomic regulation of colonic motility, in the setting of other predisposing factors.

### CONCLUSION

Future research should aim to establish a clear and consistent definition of ACPO, and elucidate the pathophysiological mechanisms leading to altered colonic function. An improved understanding of the aetiology of ACPO may facilitate the development of targeted strategies for its prevention and treatment.

**Key words:** Acute colonic pseudoobstruction; Acute colonic pseudo-obstruction; Colonic; Intestinal; Pseudo obstruction; Ogilvie's syndrome; Pseudo-Obstruction; Pseudo-Obstruction

© The Author(s) 2017. Published by Baishideng Publishing Group Inc. All rights reserved.

**Core tip:** Acute colonic pseudo-obstruction is associated with considerable morbidity and mortality, though the underlying pathophysiology remains poorly understood.

An abundance of risk factors and associated conditions have been identified, strongly suggesting a multifactorial origin, and likely culminating in an imbalance in autonomic nervous supply to the colon. Future areas for research are identified and may allow for the development of novel therapeutic or preventative strategies.

Wells CI, O'Grady G, Bissett IP. Acute colonic pseudo-obstruction: A systematic review of aetiology and mechanisms. *World J Gastroenterol* 2017; 23(30): 5634-5644 Available from: URL: <http://www.wjgnet.com/1007-9327/full/v23/i30/5634.htm> DOI: <http://dx.doi.org/10.3748/wjg.v23.i30.5634>

## INTRODUCTION

Acute colonic pseudo-obstruction (ACPO) is a rare condition characterised by acute colonic dilatation in the absence of mechanical obstruction. It was first described by Sir William Ogilvie in 1948, in two patients with malignant infiltration of the pre-vertebral ganglia<sup>[1]</sup>.

ACPO usually occurs in hospitalised patients with severe illness or trauma, or following general, orthopaedic, neurosurgical, gynaecological or other surgical procedures, with an estimated incidence of 100 cases per 100000 admissions and a mortality rate of 8%<sup>[2,3]</sup>. Colonic ischaemia or perforation occurs in up to 15%, and is associated with an estimated 40% mortality<sup>[4-6]</sup>. Therefore, early recognition and appropriate therapy are important determinants of prognosis<sup>[2]</sup>.

The pathophysiology underlying ACPO is poorly understood, with the prevailing hypothesis being an imbalance in colonic autonomic innervation<sup>[2,4]</sup>. Progress has been limited by a rudimentary understanding of the complex processes regulating colonic motility patterns, the lack of specific animal models for ACPO, and the poor quality of evidence arising from case reports and uncontrolled case series.

An improved understanding of the mechanisms underlying ACPO may aid the development of novel management strategies for this condition. Therefore, the aim of this systematic review was to critically review the literature addressing the definition, epidemiology, risk factors, aetiology and pathophysiology of ACPO with a view to informing knowledge gaps and identifying priority areas for future research.

## MATERIALS AND METHODS

A systematic search of the Ovid MEDLINE and Embase databases was performed from inception to 25 May 2017, using the search terms "Ogilvie's syndrome", "pseudoobstruction", and "pseudo obstruction". Google Scholar was also searched using free text entries. Identified articles were screened by title and

abstract for inclusion, with subsequent acquisition of full texts. The reference lists of included papers were manually searched, and a hand search of the scientific literature was performed to identify additional relevant publications.

Non-English articles were excluded. There were no exclusion limits by study design; both primary research and review articles were eligible. Full-text articles were evaluated for evidence addressing the definition, epidemiology, risk factors, aetiology and pathogenesis of ACPO. Clinical management has recently been reviewed in depth<sup>[7-9]</sup>, and was beyond the scope of this study, though pathophysiological hypotheses drawn from this evidence were evaluated. A narrative synthesis of the identified evidence was undertaken.

## RESULTS

### Definitions of ACPO

ACPO is characterised by acute colonic dilatation in the absence of intrinsic mechanical obstruction or extrinsic inflammatory process<sup>[10]</sup>. ACPO should be distinguished from other acute conditions, such as toxic megacolon, which may have inflammatory or infective causes, as well as chronic intestinal pseudo-obstruction (CIPO) and other causes of megacolon.

Many overlapping terms have been used in the literature to describe ACPO since its original description, reflecting the uncertainty regarding its precise aetiology (Table 1). The term "intestinal pseudo-obstruction" was first proposed by Dudley in 1958<sup>[11]</sup>, with "ACPO" not appearing for another twenty years<sup>[4]</sup>. Use of "Ogilvie's syndrome" has been discouraged due to ambiguity regarding its meaning<sup>[12]</sup>, though considerable heterogeneity in terminology still exists in recent literature<sup>[3,13,14]</sup>.

Inconsistent terminology has contributed to inconsistency in research and reporting. No standardised clinical definition or diagnostic criteria for ACPO were identified<sup>[15]</sup>, preventing reliable synthesis of data on risk factors or therapeutic strategies<sup>[7,8]</sup>. Some studies failed to distinguish ACPO from CIPO and other forms of megacolon<sup>[10,16]</sup>, despite these being distinct entities with different mechanisms and therapies<sup>[17,18]</sup>.

### Epidemiology

ACPO is uncommon, with an identified incidence of approximately 100 cases per 100000 inpatient admissions<sup>[3]</sup>. A recent US study reported a declining mortality rate associated with ACPO from 9.4% in 1998 to 6.4% in 2011, although over-diagnosis may have contributed<sup>[3]</sup>; historically mortality rates were as high as 30%<sup>[4]</sup>. Colonic perforation and ischemia occur in 10%-20%, with an associated mortality of up to 45%<sup>[2,4]</sup>. Rates of surgical and endoscopic intervention have declined in recent decades, due to an increasing focus on conservative management and pharmacological therapy with neostigmine<sup>[3]</sup>.

ACPO disproportionately affects elderly and

**Table 1** Terms found used to describe acute colonic pseudo-obstruction

Term	Ref.
Large intestine colic	[1]
Ogilvie's syndrome	[4, 153, 155-157]
Pseudo-megacolon	[158]
Adynamic ileus	[159, 160]
Paralytic ileus	[14, 142]
Functional obstruction of the intestinal tract	[161]
Idiopathic large bowel obstruction	[154]
Colonic ileus	[160, 162-164]
Intestinal pseudo-obstruction	[11, 111, 146, 165, 166]
Non-mechanical large bowel obstruction	[167]
Pseudo-obstruction of the large bowel, pseudo-obstruction of the colon	[23, 86, 140, 141, 168, 169]
Acute colonic pseudo-obstruction	[4]
Non-obstructive colonic dilatation	[170, 171]
Malignant ileus	[144]
Cecal ileus	[164]
Acute megacolon	[81, 172]

**Table 2** Prevalent medical and surgical risk factors for acute colonic pseudo-obstruction

Category	Risk factors
Surgical	Cardiac surgery, solid organ transplantation, major orthopaedic surgery, spine surgery
Cardiorespiratory	Shock, myocardial infarction, congestive heart failure, chronic obstructive pulmonary disease
Neurological	Dementia, Parkinson's disease, Alzheimer's disease, stroke, spinal cord injury
Metabolic	Electrolyte imbalance, diabetes, renal failure, hepatic failure
Medications	Opiates, anti-Parkinson agents, anticholinergics, antipsychotics, cytotoxic chemotherapy, clonidine
Obstetric/gynaecological	Caesarean section, normal vaginal delivery, instrumental delivery, preeclampsia, normal pregnancy, pelvic surgery
Infectious	Varicella-zoster virus, herpes virus, cytomegalovirus
Miscellaneous	Major burns/trauma, severe sepsis, idiopathic

comorbid patients; often those with an acute illness on a background of chronic cardiac, respiratory or neurological disease. ACPO also occurs following general, orthopaedic, neurosurgical, cardiothoracic and gynaecological procedures<sup>[19]</sup>. Vanek *et al.*<sup>[2]</sup> reported 400 cases of ACPO, with approximately 50% resulting from acute medical illness and 50% from post-surgical patients. Incidence rates have been described in spinal or orthopaedic surgery (1%-2%)<sup>[13,20]</sup>, cardiac bypass (up to 5%)<sup>[21]</sup>, and following burn injuries (0.3%)<sup>[22]</sup>. An abundance of other conditions associated with ACPO were found to have been reported in the literature, the most common of which are summarised (Table 2).

### Pathophysiology

Review of the literature revealed a vast array of risk factors for ACPO, supporting a multifactorial aetiology with several pathways leading to a common effect

on colonic motor function<sup>[23]</sup> (Figure 1). However, few published studies were found directly investigating the pathophysiological mechanisms underlying ACPO, with the majority of evidence inferred from basic physiology and other disease states such as post-operative ileus (POI). No animal models of ACPO were identified.

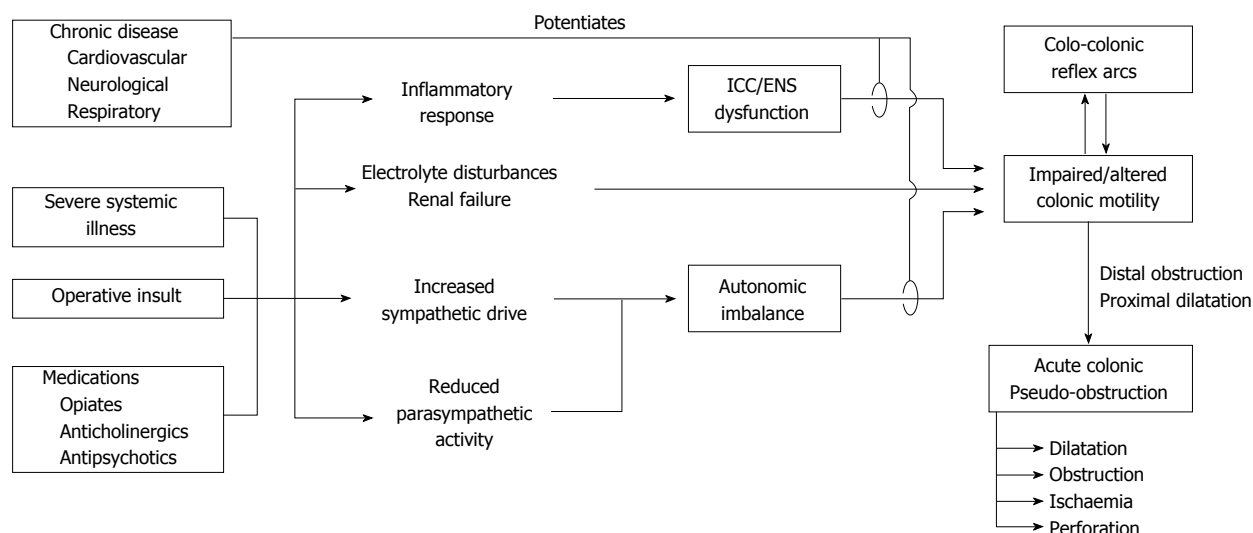
Normal colonic motor activity is regulated at several levels; (1) colonic smooth muscle; (2) pacemaker activity generated by interstitial cells of Cajal (ICC); (3) intrinsic control *via* the enteric nervous system (ENS); (4) prevertebral and spinal reflex arcs; and (5) extrinsic modulation by the autonomic nervous system and hormonal systems. Being a "functional obstruction", ACPO is presumed to result from aberrations in colonic motor activity, though physiological data specifically characterising these abnormalities was not identified.

### Autonomic imbalance

Altered extrinsic regulation of colonic function by the sympathetic and parasympathetic nervous systems is the most commonly suggested mechanism for ACPO<sup>[10,24-29]</sup>. This mechanism was first postulated by Ogilvie, who proposed a "sympathetic deprivation" of the colon<sup>[1]</sup>. Current theory favours a relative excess of sympathetic over parasympathetic tone, though it is unclear whether this is due to increased sympathetic activity, reduced parasympathetic signalling, both, or either. The prevailing hypothesis remains that ACPO is the result of reduced parasympathetic innervation to the distal colon, leading to an atonic segment and functional obstruction<sup>[2,10,27,28,30-32]</sup>; however no published physiological data was found to directly support or refute this claim<sup>[28,29]</sup>.

The colon receives sympathetic innervation from the prevertebral ganglia (proximally *via* the superior mesenteric ganglion; distally *via* the inferior mesenteric ganglion). Nerve fibres follow the respective arterial routes<sup>[33]</sup>, and the proximal colon appears to have a richer sympathetic innervation<sup>[23]</sup>. The parasympathetic supply to the mid-gut is *via* the vagus nerve while the hind-gut is innervated by sacral parasympathetic outflow (S2-4)<sup>[33]</sup>, although animal studies have demonstrated some overlap between these distributions<sup>[34]</sup>. The transition point from distended to normal colon in ACPO usually occurs near the splenic flexure<sup>[2,10,35]</sup>, where there is a transition in the innervation for both sympathetic and parasympathetic supply to the colon, supporting autonomic imbalance as a key step in pathogenesis.

Most patients with ACPO are unwell with major illness, therefore having increased systemic sympathetic drive<sup>[23,36,37]</sup>, potentially contributing to autonomic imbalance at the level of the colon. Other reported cases have involved pathology potentially disrupting the autonomic supply to the colon, such as retroperitoneal tumours or haemorrhage<sup>[38,39]</sup>. Interestingly, ACPO cannot be reproduced in humans or animals by splanchnic or pelvic nerve transection<sup>[40,41]</sup>, thus the pathogenesis appears more complex than excess or



**Figure 1** Pathophysiological factors that have been implicated in the development of acute colonic pseudo-obstruction. ICC: Interstitial cells of Cajal; ENS: Enteric nervous system.

deficiency of sympathetic or parasympathetic activity alone.

Neostigmine is an acetylcholinesterase inhibitor and parasympathomimetic commonly used in management of ACPO, further supporting autonomic imbalance as a key pathophysiological mechanism. Early studies investigated use of guanethidine, a sympatholytic, followed by neostigmine<sup>[42]</sup>. Guanethidine was later shown ineffective<sup>[43]</sup>, while neostigmine has been proven efficacious in several randomised trials<sup>[7,44-46]</sup>. Prior studies have shown that parasympathetic stimulation with neostigmine triggers colonic high amplitude propagating sequences (HAPS) in both dogs and humans<sup>[47,48]</sup>, which has been proposed as a possible mechanism for its decompressive effect in the functionally obstructed colon<sup>[49]</sup>. However, HAPS primarily arise in the proximal colon, and it is unknown what effect neostigmine has on other prominent colonic motor activity such as cyclic events, or the role of these events in ACPO<sup>[50]</sup>.

### Colonic reflex arcs

Several spinal and ganglionic reflex arcs are involved in regulating intestinal motor function. The colo-colonic inhibitory reflex refers to inhibition of proximal colonic motor activity in response to distal colonic distention<sup>[51,52]</sup>. Conversely, proximal distension also causes a reduction in basal intraluminal pressure in the distal colon<sup>[51]</sup>. Evidence from animal models suggests these reflex arcs are mediated *via* afferent mechanoreceptors synapsing with adrenergic efferent neurons in the prevertebral ganglia and spinal cord<sup>[18,51,52]</sup>.

These reflexes provide a possible mechanism to explain how disordered motility and distension of one colonic region may potentiate dilatation of other regions, contributing to ACPO<sup>[18,26,28,30]</sup>. Some authors have pointed to the therapeutic success of epidural anaesthesia and splanchnic nerve block in

case reports as evidence for this mechanism<sup>[10,53]</sup>, though it is difficult to ascertain whether this is due to disruption of the efferent limb of these reflex arcs, or simply reduction in the extrinsic sympathetic supply to the colon. Furthermore, epidural anaesthesia has been implicated as both a cause of and a therapy for ACPO<sup>[18,53,54]</sup>. The lack of high-quality evidence identified in this area makes it difficult to determine the effects of spinal or ganglionic blockade in ACPO and the precise role of the colo-colonic inhibitory reflex.

### Intrinsic colonic dysfunction

ICC are the pacemaker responsible for generating electrical slow waves, which are modulated by the ENS, resulting in the rhythmic contractile activity of the intestine<sup>[55,56]</sup>. Despite their recognised importance in the control of gastrointestinal motility, few studies were identified that specifically investigated the roles of enteric neurons or ICC in ACPO.

Permanent impairment of the ENS, ICC, and/or myopathy characterises many forms of CIPO<sup>[24,57-59]</sup>. However, the acute onset, reversibility, and different epidemiology of ACPO implies a distinct pathophysiological process from CIPO, hence these findings should not be extrapolated to the acute form of pseudo-obstruction.

Jain *et al*<sup>[57]</sup> investigated ICC using immuno-histochemistry in patients with pseudo-obstruction syndromes, showing two patients with ACPO had a normal number and distribution of ICC. However, whether ICC function is affected in ACPO remains unknown. Choi *et al*<sup>[35]</sup> reported a reduction and degeneration of enteric ganglionic cells in the resected colonic specimens of four patients with pseudo-obstruction, but it is unclear whether these patients had ACPO or CIPO, and whether these histological abnormalities represent cause or effect of the colonic



dilatation and pseudo-obstruction. Without further pathophysiological studies, the role of the ENS and ICC in the development of ACPO remains unknown.

Nitric oxide (NO) is an important inhibitory neurotransmitter released by colonic enteric neurons, and has been implicated in colonic dilatation and dysfunction in toxic megacolon<sup>[37,60,61]</sup> and colitis<sup>[62]</sup>. Several authors have speculated whether NO may also have a role in ACPO, however no physiological evidence was found to support this claim. However, polyethylene glycol (PEG), an osmotic laxative that may also reduce NO production<sup>[63,64]</sup>, has been shown to reduce relapse rates after decompression in ACPO<sup>[65]</sup>. This finding could be explained by either the laxative effects of PEG or its effect on nitrinergic signalling. A number of novel pharmacological treatments targeting NO regulation have recently been discovered, though no studies were identified that applied these therapies in patients with ACPO<sup>[66]</sup>.

### **Chronic disease and pharmacological factors**

Notably, many ACPO patients are elderly and have chronic cardiac, respiratory or neurological disease, with onset often occurring in the context of a further acute physiological insult<sup>[2,3]</sup>. Chronic stress conditioning, similar to the effects of chronic disease, potentiates excitatory and inhibitory neurotransmission<sup>[67]</sup>, potentially explaining these associations. The ENS and its extrinsic regulation are affected in several conditions commonly associated with ACPO, including diabetes mellitus<sup>[68,69]</sup>, Parkinson's<sup>[70,71]</sup> and Alzheimer's disease<sup>[70,72,73]</sup>. Furthermore, both the ENS and ICC have been shown to degenerate with age<sup>[74-76]</sup>, which may partly account for the elderly preponderance of this disorder<sup>[2,3,29,77]</sup>.

Patients with chronic conditions are also more likely to be on multiple medications affecting colonic motility<sup>[78,79]</sup>, and may therefore be predisposed to the development of ACPO. Numerous medications have been associated with ACPO, including anticholinergics, opiates, calcium channel blockers, and psychotropic drugs<sup>[80-82]</sup>. Furthermore, use of anti-motility agents is predictive of poor response to neostigmine<sup>[83]</sup>, while methylnaltrexone has been successfully used in a patient with ACPO who failed to respond to two doses of neostigmine<sup>[84]</sup>.

Many medications associated with ACPO modulate the autonomic nervous system, supporting disruption of these pathways as a key pathophysiological mechanism. Clonidine<sup>[18,85-87]</sup> and amitraz<sup>[88]</sup> are  $\alpha_2$ -adrenergic agonists that have been associated with ACPO. At the level of the colon,  $\alpha_2$ -adrenergic signalling reduces release of acetylcholine from enteric neurons, resulting in a relative imbalance of sympathetic over parasympathetic supply<sup>[89,90]</sup>, consistent with current theory regarding the pathophysiology of ACPO.

### **Obstetric causes**

The operation most commonly resulting in ACPO is

caesarean section<sup>[2,26,91-99]</sup>, but ACPO also occurs after normal and instrumental vaginal delivery<sup>[100-102]</sup>. A recent systematic review identified that preeclampsia, multiple pregnancy, and antepartum haemorrhage/placenta praevia appear to be more common in women who develop ACPO following caesarean section<sup>[103]</sup>. However, it remains unclear how these events result in acutely perturbed colonic function. Some authors have proposed that compression of parasympathetic plexuses by the gravid uterus may contribute<sup>[26,27,104]</sup>, while others have hypothesised that the uterus may fall back into the pelvis following delivery, causing a mechanical obstruction at the rectosigmoid colon<sup>[36,105]</sup>.

Pregnancy is also associated with high levels of progesterone and glucagon, both of which have been shown to diminish the tone of the large bowel<sup>[92]</sup>, and may predispose to ACPO when combined with acute physiological disturbances such as caesarean section, preeclampsia, peripartum sepsis, or haemorrhage. Resting sympathetic vasomotor outflow is increased during the third trimester, even in women with normal blood pressure<sup>[106,107]</sup>, while autonomic dysfunction and sympathetic overactivity are a feature of severe preeclampsia<sup>[108,109]</sup>. It is unknown whether sympathetic supply to the colon is also affected in these states, but this could plausibly contribute to autonomic imbalance and ACPO. Finally, prostaglandins are intimately involved in parturition<sup>[110]</sup>, and have also been suggested as a possible contributor to ACPO in obstetric patients<sup>[92]</sup> (*discussed in next section*).

### **Metabolic factors**

A disrupted "*milieu interieur*" is common in ACPO, which may precipitate or exacerbate the effects of altered autonomic function or other mechanisms. A host of metabolic factors have been shown to influence colonic motility, though few studies have investigated these specifically in ACPO. However, the isolated colonic dysfunction characterising ACPO makes it unlikely that metabolic abnormalities are the sole pathophysiological explanation.

Renal failure and electrolyte disturbances often accompany ACPO, although it has been disputed whether this is a cause or effect of the pseudo-obstruction<sup>[4,16,32,39,83,111]</sup>. Alterations in potassium and other electrolyte concentrations affect ion channel function and may alter ICC pacemaker or smooth muscle activity<sup>[112,113]</sup>. Furthermore, electrolyte imbalance has been identified as a predictor of a poor clinical response to neostigmine<sup>[83]</sup>.

Prostaglandins and cytokines are both well-established inflammatory mediators of gastrointestinal motility<sup>[114,115]</sup>. Pro-inflammatory cytokines such as TNF- $\alpha$ , IL-6, IL-8, and IL-1 $\beta$  have implicated in POI<sup>[114,115]</sup>, but have not yet been investigated in ACPO. Prostaglandins have been implicated in POI<sup>[115,116]</sup>, CIPO<sup>[117,118]</sup>, acute small intestinal dysmotility<sup>[119]</sup>, and also affect ICC function and slow wave frequency<sup>[120]</sup>. However, no studies were identified investigating the

role of prostaglandins in the development of ACPO. Cyclooxygenase-2 (COX-2) expression is increased in the distended colon of mice with experimentally-induced mechanical obstruction, and it has been suggested that this is responsible for reduced motility *via* the effects of prostaglandin E2<sup>[121]</sup>. However, caution must be taken when extrapolating these results to humans and to ACPO<sup>[122]</sup>.

### ***Viral enteroneuropathy***

ACPO has also been associated with several viral infections, most commonly herpes zoster reactivation in low thoracic or lumbar distributions<sup>[123-130]</sup>, but also disseminated varicella zoster<sup>[131-134]</sup>, acute cytomegalovirus<sup>[135]</sup>, and severe dengue<sup>[136]</sup>.

Several mechanisms have been proposed to explain these associations, all involving autonomic dysfunction. Reactivation of herpes virus in enteric ganglia may result in a sympathetic autonomic neuritis<sup>[123,124,137,138]</sup>, presumably diminishing colonic sympathetic supply. Local segmental colonic inflammation with afferent stimuli to the sacral nerve roots and blockage of colonic parasympathetic supply has also been suggested<sup>[138]</sup>, while other authors have hypothesised that viral spread from the dorsal root ganglia to the thoracolumbar or sacral lateral columns may interrupt sacral parasympathetic pathways<sup>[137]</sup>. Involvement and inflammation of the intrinsic enteric nervous system, and post-viral dysautonomia have also been suggested<sup>[136,137,139]</sup>.

### ***Other hypotheses***

Several alternate hypotheses regarding the pathophysiology of ACPO were identified. Compromised vascular supply to the colon was suggested in many early reports<sup>[11,140,141]</sup>, but now thought to represent an exacerbating complication rather than a cause. "Hinge-kinking" of the colon at the transition from retro- to intra-peritoneal structures has also been proposed<sup>[142]</sup>, however, intra-operative and radiological findings generally suggest a "gradual" transition in colonic calibre<sup>[23]</sup>. Other identified hypotheses lacking supporting evidence included the "air-fluid lock syndrome"<sup>[143-145]</sup>, and colonic distension due to aerophagy in chronic respiratory disease<sup>[146,147]</sup>.

## **DISCUSSION**

Despite considerable speculation, this comprehensive and systematic review of the literature finds that the mechanisms underpinning ACPO still remain uncertain. Limited physiological evidence from patients with ACPO was found to exist, and the lack of an animal model has required extrapolation of data from other disease states. The abundance of identified risk factors and associated conditions supports a multifactorial hypothesis, with aberrations in function at any of several levels seemingly able to lead to common or similar effects on the colon.

Overall, autonomic imbalance is the most strongly supported pathophysiological contributor, and likely plays a key role in the development of ACPO. Evidence supporting a major role for autonomic imbalance includes the observation that most patients with ACPO are systemically unwell, or have other pathology disrupting the autonomic supply to the colon. Furthermore, the transition point from distended to normal colon in ACPO usually occurs at the splenic flexure, corresponding to the change in autonomic innervation of the mid-gut and hind-gut. However, the precise aberrations in autonomic function leading to ACPO remain unclear.

ACPO is difficult to rigorously investigate due to its acute and sporadic nature and heterogeneity. The plethora of case reports identified in the literature is testament to the large number of illnesses associated with this condition. It is also clear that a categorical clinical definition of ACPO is needed to standardise research, and improve the quality of published evidence. Distinct subtypes of ACPO have recently been proposed according to gut wall thickness on cross-sectional imaging<sup>[148]</sup>, and further work should investigate the aetiology and prognostic significance of this phenomenon.

Importantly, the precise aberrations in colonic motor activity underlying ACPO have not been characterised. Despite the common assumption that the distal colon is atonic, direct physiological evidence supporting this claim could not be identified, and it remains unknown whether ACPO is fundamentally due to atony, dysmotility, or spasm in part or all of the colon, or is due to heterogeneous motility states. Furthermore, although many authors have argued that the sympathetic system decreases colonic motility and the parasympathetic increases contractility<sup>[10,18,28,30,43]</sup>, this is now recognised as overly simplistic, with further layers of modulation within the ENS, ICC and smooth muscle<sup>[27,33]</sup>. It is also important to note that the therapeutic success of neostigmine also does not specifically prove interrupted parasympathetic supply to the colon as the sole pathophysiological mechanism underlying ACPO<sup>[29]</sup>, despite this being suggested by many authors<sup>[2,42,43,149,150]</sup>. Indeed, provocation of HAPS and colonic emptying by neostigmine may be sufficient to overcome an alternative pathophysiological mechanism and result in decompression of the functionally obstructed colon.

High-resolution colonic manometry has recently been used to characterise the abnormalities underlying colonic dysmotility in the early post-operative period, demonstrating increased cyclic motor activity in the left colon, rather than atony, and an absence of HAPS<sup>[151,152]</sup>. Applying similar research methods to ACPO would be a particularly interesting research avenue, with potential to rigorously define the altered motility patterns underlying the disorder. It is interesting to note that transient "ring[s] of spasm" were noted intra-operatively in the distal colon of several of the original

descriptions of this syndrome<sup>[1,153,154]</sup>, though the pathophysiological significance of these remains unclear. Other areas for future pathophysiological investigation include the development of an animal model of ACPO, histological examination of resected specimens, and rigorous investigation of the impact of preventative or therapeutic strategies on colonic function.

This systematic review and appraisal of the literature surrounding ACPO has identified limited evidence investigating the mechanisms underlying this condition. A number of areas for further study have been identified. It is hoped that an improved understanding of the pathophysiology of ACPO will lead to the development of targeted strategies for its prevention and treatment.

## COMMENTS

### Background

Acute colonic pseudo-obstruction (ACPO) is an uncommon condition, characterised by acute colonic dilatation in the absence of a mechanical obstruction. Colonic ischaemia or perforation may occur in up to 15% of patients, and is associated with considerable morbidity and mortality.

### Research frontiers

The pathophysiology underlying ACPO is poorly understood, with a plethora of associated conditions reported in the literature. The prevailing hypothesis is an imbalance in colonic autonomic innervation, though few articles have thoroughly examined the evidence supporting this claim.

### Innovations and breakthroughs

This systematic review finds that the mechanisms underpinning ACPO still remain uncertain. Autonomic imbalance is the most strongly supported pathophysiological factor, though the precise aberrations leading to ACPO are unclear. A number of other factors may contribute to ACPO, including colonic reflex arcs, intrinsic colonic dysfunction, chronic disease, and pharmacological or metabolic disturbances.

### Applications

A number of areas for future investigation have been identified, including the use of high-resolution colonic manometry to rigorously define the altered motility patterns underlying ACPO, the development of an animal model, and histological examination of resected specimens. An improved understanding of the pathophysiology of ACPO may lead to the development of novel preventative or therapeutic strategies.

### Terminology

Pseudo-obstruction is characterised by a clinical presentation suggestive of intestinal obstruction, in the absence of a mechanically obstructing lesion. ACPO is the acute form of colonic pseudo-obstruction, while chronic intestinal pseudo-obstruction is a distinct entity with different mechanisms and therapies. "Ogilvie's syndrome" has also been used to refer to ACPO, though this term is now discouraged due to ambiguity regarding its meaning.

### Peer-review

This is a very interesting review regarding the etiology of acute colonic pseudo-obstruction. The author introduced a number of articles regarding this issue.

## REFERENCES

- Ogilvie H. Large-intestine colic due to sympathetic deprivation; a new clinical syndrome. *Br Med J* 1948; **2**: 671-673 [PMID: 18886657 DOI: 10.1136/bmj.2.4579.671]
- Vanek VW, Al-Salti M. Acute pseudo-obstruction of the colon (Ogilvie's syndrome). An analysis of 400 cases. *Dis Colon Rectum* 1986; **29**: 203-210 [PMID: 3753674 DOI: 10.1007/BF02555027]
- Ross SW, Oommen B, Wormer BA, Walters AL, Augenstein VA, Heniford BT, Sing RF, Christmas AB. Acute Colonic Pseudo-obstruction: Defining the Epidemiology, Treatment, and Adverse Outcomes of Ogilvie's Syndrome. *Am Surg* 2016; **82**: 102-111 [PMID: 26874130]
- Nanni G, Garbini A, Luchetti P, Nanni G, Ronconi P, Castagneto M. Ogilvie's syndrome (acute colonic pseudo-obstruction): review of the literature (October 1948 to March 1980) and report of four additional cases. *Dis Colon Rectum* 1982; **25**: 157-166 [PMID: 7039994 DOI: 10.1007/BF02553265]
- Delgado-Aros S, Camilleri M. Pseudo-obstruction in the critically ill. *Best Pract Res Clin Gastroenterol* 2003; **17**: 427-444 [PMID: 12763505 DOI: 10.1016/S1521-6918%2803%2900023-4]
- Saunders MD, Kimmey MB. Colonic pseudo-obstruction: the dilated colon in the ICU. *Semin Gastrointest Dis* 2003; **14**: 20-27 [PMID: 12610851]
- Valle RG, Godoy FL. Neostigmine for acute colonic pseudo-obstruction: A meta-analysis. *Ann Med Surg (Lond)* 2014; **3**: 60-64 [PMID: 25568788 DOI: 10.1016/j.amsu.2014.04.002]
- Kayani B, Spalding DR, Jiao LR, Habib NA, Zacharakis E. Does neostigmine improve time to resolution of symptoms in acute colonic pseudo-obstruction? *Int J Surg* 2012; **10**: 453-457 [PMID: 22985773 DOI: 10.1016/j.ijsu.2012.08.008]
- Elsner JL, Smith JM, Ensor CR. Intravenous neostigmine for postoperative acute colonic pseudo-obstruction. *Ann Pharmacother* 2012; **46**: 430-435 [PMID: 22388328 DOI: 10.1345/aph.1Q515]
- Pereira P, Djeudji F, Leduc P, Fanget F, Barth X. Ogilvie's syndrome-acute colonic pseudo-obstruction. *J Visc Surg* 2015; **152**: 99-105 [PMID: 25770746 DOI: 10.1016/j.jvisurg.2015.02.004]
- Dudley HA, Sinclair IS, McLaren IF, McNair TJ, Newsam JE. Intestinal pseudo-obstruction. *J R Coll Surg Edinb* 1958; **3**: 206-217 [PMID: 13514744]
- Vavilala MS, Lam AM. Neostigmine for acute colonic pseudo-obstruction. *N Engl J Med* 1999; **341**: 1622; author reply 1623 [PMID: 10577130 DOI: 10.1056/NEJM199911183412115]
- Januszewski J, Keem SK, Smith W, Beckman JM, Kanter AS, Oskuan RJ, Taylor W, Uribe JS. The Potentially Fatal Ogilvie's Syndrome in Lateral Transposas Access Surgery: A Multi-Institutional Experience with 2930 Patients. *World Neurosurg* 2017; **99**: 302-307 [PMID: 27923757 DOI: 10.1016/j.wneu.2016.11.132]
- Khan MW, Ghauri SK, Shamim S. Ogilvie's Syndrome. *J Coll Physicians Surg Pak* 2016; **26**: 989-991 [PMID: 28043313]
- Sloyer AF, Panella VS, Demas BE, Shike M, Lightdale CJ, Winawer SJ, Kurtz RC. Ogilvie's syndrome. Successful management without colonoscopy. *Dig Dis Sci* 1988; **33**: 1391-1396 [PMID: 3180976 DOI: 10.1007/BF01536993]
- Durai R. Colonic pseudo-obstruction. *Singapore Med J* 2009; **50**: 237-244 [PMID: 19352564]
- Stanghellini V. Neuro-immune interactions in the gastrointestinal tract. *Clin Auton Res* 2010; **20**: 123 [DOI: 10.1007/s10286-010-0060-z]
- Romeo DP, Solomon GD, Hover AR. Acute colonic pseudo-obstruction: a possible role for the colocolonic reflex. *J Clin Gastroenterol* 1985; **7**: 256-260 [PMID: 4020085 DOI: 10.1097/0004836-198506000-00014]
- Tenofsky PL, Beamer L, Smith RS. Ogilvie syndrome as a postoperative complication. *Arch Surg* 2000; **135**: 682-686; discussion 686-687 [PMID: 10843364 DOI: 10.1001/archsurg.135.6.682]
- Norwood MG, Lykostratis H, Garcea G, Berry DP. Acute colonic pseudo-obstruction following major orthopaedic surgery. *Colorectal Dis* 2005; **7**: 496-499 [PMID: 16108888 DOI: 10.1111/j.1463-1318.2005.00790.x]
- Simić O, Strathausen S, Hess W, Ostermeyer J. Incidence and prognosis of abdominal complications after cardiopulmonary bypass. *Cardiovasc Surg* 1999; **7**: 419-424 [PMID: 10430524 DOI: 10.1016/S0967-2109%2899%2900008-3]



- 22 **Kadesky K**, Purdue GF, Hunt JL. Acute pseudo-obstruction in critically ill patients with burns. *J Burn Care Rehabil* 1995; **16**: 132-135 [PMID: 7775506 DOI: 10.1097/00004630-199503000-00007]
- 23 **Bardsley D**. Pseudo-obstruction of the large bowel. *Br J Surg* 1974; **61**: 963-969 [PMID: 4441816 DOI: 10.1002/bjs.1800611210]
- 24 **Bernardi MP**, Warrier S, Lynch AC, Heriot AG. Acute and chronic pseudo-obstruction: a current update. *ANZ J Surg* 2015; **85**: 709-714 [PMID: 25943300 DOI: 10.1111/ans.13148]
- 25 **Chudzinski AP**, Thompson EV, Ayscue JM. Acute colonic pseudoobstruction. *Clin Colon Rectal Surg* 2015; **28**: 112-117 [PMID: 26034408 DOI: 10.1055/s-0035-1549100]
- 26 **Reeves M**, Frizelle F, Wakeman C, Parker C. Acute colonic pseudo-obstruction in pregnancy. *ANZ J Surg* 2015; **85**: 728-733 [PMID: 26044983 DOI: 10.1111/ans.13201]
- 27 **Jain A**, Vargas HD. Advances and challenges in the management of acute colonic pseudo-obstruction (ogilvie syndrome). *Clin Colon Rectal Surg* 2012; **25**: 37-45 [PMID: 23449274 DOI: 10.1055/s-0032-1301758]
- 28 **Chapple K**. Acute Colonic Pseudo-obstruction. In: Brown SR, Hartley JE, Hill J, Scott N, Williams JG. Contemporary Coloproctology: Springer, 2012: 439-449 [DOI: 10.1007/978-0-85729-889-8\_30]
- 29 **De Giorgio R**, Knowles CH. Acute colonic pseudo-obstruction. *Br J Surg* 2009; **96**: 229-239 [PMID: 19224517 DOI: 10.1002/bjs.6480]
- 30 **Saunders MD**. Acute colonic pseudo-obstruction. *Best Pract Res Clin Gastroenterol* 2007; **21**: 671-687 [PMID: 17643908 DOI: 10.1016/j.bpg.2007.03.001]
- 31 **Tack J**. Acute Colonic Pseudo-Obstruction (Ogilvie's Syndrome). *Curr Treat Options Gastroenterol* 2006; **9**: 361-368 [PMID: 16836955 DOI: 10.1007/s11938-006-0018-3]
- 32 **Saunders MD**, Kimmey MB. Systematic review: acute colonic pseudo-obstruction. *Aliment Pharmacol Ther* 2005; **22**: 917-925 [PMID: 16268965 DOI: 10.1111/j.1365-2036.2005.02668.x]
- 33 **Mathias CJ**, Bannister R. Autonomic failure: a textbook of clinical disorders of the autonomic nervous system. 5th ed. OUP Oxford, 2013
- 34 **Tong WD**, Ridolfi TJ, Kosinski L, Ludwig K, Takahashi T. Effects of autonomic nerve stimulation on colorectal motility in rats. *Neurogastroenterol Motil* 2010; **22**: 688-693 [PMID: 20067587 DOI: 10.1111/j.1365-2982.2009.01461.x]
- 35 **Choi JS**, Lim JS, Kim H, Choi JY, Kim MJ, Kim NK, Kim KW. Colonic pseudoobstruction: CT findings. *AJR Am J Roentgenol* 2008; **190**: 1521-1526 [PMID: 18492902 DOI: 10.2214/AJR.07.3159]
- 36 **Dorudi S**, Berry AR, Kettlewell MG. Acute colonic pseudo-obstruction. *Br J Surg* 1992; **79**: 99-103 [PMID: 1555081 DOI: 10.1002/bjs.1800790203]
- 37 **De Giorgio R**, Barbara G, Stanghellini V, Tonini M, Vasina V, Cola B, Corinaldesi R, Biagi G, De Ponti F. Review article: the pharmacological treatment of acute colonic pseudo-obstruction. *Aliment Pharmacol Ther* 2001; **15**: 1717-1727 [PMID: 11683685 DOI: 10.1046/j.1365-2036.2001.01088.x]
- 38 **Saunders MD**. Acute colonic pseudoobstruction. *Curr Gastroenterol Rep* 2004; **6**: 410-416 [PMID: 15341719 DOI: 10.1007/s11894-004-0059-5]
- 39 **Jetmore AB**, Timmecke AE, Gathright JB Jr, Hicks TC, Ray JE, Baker JW. Ogilvie's syndrome: colonoscopic decompression and analysis of predisposing factors. *Dis Colon Rectum* 1992; **35**: 1135-1142 [PMID: 1473414 DOI: 10.1007/BF02251964]
- 40 **Gribovskaja-Rupp I**, Takahashi T, Ridolfi T, Kosinski L, Ludwig K. Upregulation of mucosal 5-HT3 receptors is involved in restoration of colonic transit after pelvic nerve transection. *Neurogastroenterol Motil* 2012; **24**: 472-478, e218 [PMID: 22304456 DOI: 10.1111/j.1365-2982.2012.01890.x]
- 41 **Furness JB**, Callaghan BP, Rivera LR, Cho H-J. The enteric nervous system and gastrointestinal innervation: integrated local and central control. In: Lyte M, Cryan JF. Microbial Endocrinology: The Microbiota-Gut-Brain Axis in Health and Disease. Springer, 2014: 39-71 [DOI: 10.1007/978-1-4939-0897-4\_3]
- 42 **Hutchinson R**, Griffiths C. Acute colonic pseudo-obstruction: a pharmacological approach. *Ann R Coll Surg Engl* 1992; **74**: 364-367 [PMID: 1416711]
- 43 **Stephenson BM**, Morgan AR, Salaman JR, Wheeler MH. Ogilvie's syndrome: a new approach to an old problem. *Dis Colon Rectum* 1995; **38**: 424-427 [PMID: 7720453 DOI: 10.1007/BF02054234]
- 44 **Ponec RJ**, Saunders MD, Kimmey MB. Neostigmine for the treatment of acute colonic pseudo-obstruction. *N Engl J Med* 1999; **341**: 137-141 [PMID: 10403850 DOI: 10.1056/NEJM199907153410301]
- 45 **Amaro R**, Rogers AI. Neostigmine infusion: new standard of care for acute colonic pseudo-obstruction? *Am J Gastroenterol* 2000; **95**: 304-305 [PMID: 10638606]
- 46 **van der Spoel JI**, Oudemans-van Straaten HM, Stoutenbeek CP, Bosman RJ, Zandstra DF. Neostigmine resolves critical illness-related colonic ileus in intensive care patients with multiple organ failure--a prospective, double-blind, placebo-controlled trial. *Intensive Care Med* 2001; **27**: 822-827 [PMID: 11430537 DOI: 10.1007/s001340100926]
- 47 **Leelakusolvong S**, Bharucha AE, Sarr MG, Hammond PI, Brimijoin S, Phillips SF. Effect of extrinsic denervation on muscarinic neurotransmission in the canine ileocolonic region. *Neurogastroenterol Motil* 2003; **15**: 173-186 [PMID: 12680916 DOI: 10.1046/j.1365-2982.2003.00399.x]
- 48 **Law NM**, Bharucha AE, Undale AS, Zinsmeister AR. Cholinergic stimulation enhances colonic motor activity, transit, and sensation in humans. *Am J Physiol Gastrointest Liver Physiol* 2001; **281**: G1228-G1237 [PMID: 11668032]
- 49 **Bharucha AE**. High amplitude propagated contractions. *Neurogastroenterol Motil* 2012; **24**: 977-982 [PMID: 23057554 DOI: 10.1111/nmo.12019]
- 50 **Dinning PG**, Wiklendt L, Maslen L, Gibbins I, Patton V, Arkwright JW, Lubowski DZ, O'Grady G, Bampton PA, Brookes SJ, Costa M. Quantification of in vivo colonic motor patterns in healthy humans before and after a meal revealed by high-resolution fiber-optic manometry. *Neurogastroenterol Motil* 2014; **26**: 1443-1457 [PMID: 25131177 DOI: 10.1111/nmo.12408]
- 51 **Kreulen DL**, Szurszewski JH. Reflex pathways in the abdominal prevertebral ganglia: evidence for a colo-colonic inhibitory reflex. *J Physiol* 1979; **295**: 21-32 [PMID: 521925 DOI: 10.1113/jphysiol.1979.sp012952]
- 52 **Hughes SF**, Scott SM, Pilot MA, Williams NS. Adrenoceptors and colocolonic inhibitory reflex. *Dig Dis Sci* 1999; **44**: 2462-2468 [PMID: 10630498 DOI: 10.1023/A:1026682921293]
- 53 **Lee JT**, Taylor BM, Singleton BC. Epidural anesthesia for acute pseudo-obstruction of the colon (Ogilvie's syndrome). *Dis Colon Rectum* 1988; **31**: 686-691 [PMID: 3168679 DOI: 10.1007/BF02552584]
- 54 **Mashour GA**, Peterfreund RA. Spinal anesthesia and Ogilvie's syndrome. *J Clin Anesth* 2005; **17**: 122-123 [PMID: 15809128 DOI: 10.1016/j.jclinane.2004.03.015]
- 55 **Mostafa RM**, Moustafa YM, Hamdy H. Interstitial cells of Cajal, the Maestro in health and disease. *World J Gastroenterol* 2010; **16**: 3239-3248 [PMID: 20614479 DOI: 10.3748/wjg.v16.i26.3239]
- 56 **Al-Shboul OA**. The importance of interstitial cells of cajal in the gastrointestinal tract. *Saudi J Gastroenterol* 2013; **19**: 3-15 [PMID: 23319032 DOI: 10.4103/1319-3767.105909]
- 57 **Jain D**, Moussa K, Tandon M, Culpepper-Morgan J, Proctor DD. Role of interstitial cells of Cajal in motility disorders of the bowel. *Am J Gastroenterol* 2003; **98**: 618-624 [PMID: 12650797 DOI: 10.1111/j.1572-0241.2003.07295.x]
- 58 **Coulie B**, Camilleri M. Intestinal pseudo-obstruction. *Annu Rev Med* 1999; **50**: 37-55 [PMID: 10073262 DOI: 10.1146/annurev.med.50.1.37]
- 59 **Farrugia G**. Interstitial cells of Cajal in health and disease. *Neurogastroenterol Motil* 2008; **20** Suppl 1: 54-63 [PMID: 18402642 DOI: 10.1111/j.1365-2982.2008.01109.x]
- 60 **Moorelle M**, Casellas F, Guarner F, Salas A, Riveros-Moreno V, Moncada S, Malagelada JR. Induction of nitric oxide synthase in colonic smooth muscle from patients with toxic megacolon. *Gastroenterology* 1995; **109**: 1497-1502 [PMID: 7557131 DOI: 10.1016/0016-5085(95)90636-3]
- 61 **Moorelle M**, Vilaseca J, Guarner F, Salas A, Malagelada JR. Toxic



- dilatation of colon in a rat model of colitis is linked to an inducible form of nitric oxide synthase. *Am J Physiol* 1996; **270**: G425-G430 [PMID: 8638708]
- 62 **Onori L**, Aggio A, D'Alo' S, Muzi P, Cifone MG, Mellillo G, Ciccocioppo R, Taddei G, Frieri G, Latella G. Role of nitric oxide in the impairment of circular muscle contractility of distended, uninfamed mid-colon in TNBS-induced acute distal colitis in rats. *World J Gastroenterol* 2005; **11**: 5677-5684 [PMID: 16237764 DOI: 10.3748/wjg.v11.i36.5677]
  - 63 **de Winter BY**, van Nassauw L, de Man JG, de Jonge F, Bredenoord AJ, Seerden TC, Herman AG, Timmermans JP, Pelckmans PA. Role of oxidative stress in the pathogenesis of septic ileus in mice. *Neurogastroenterol Motil* 2005; **17**: 251-261 [PMID: 15787945 DOI: 10.1111/j.1365-2982.2004.00618.x]
  - 64 **Shishido SM**, de Oliveira MG. Polyethylene glycol matrix reduces the rates of photochemical and thermal release of nitric oxide from S-nitroso-N-acetylcysteine *Photochem Photobiol* 2000; **71**: 273-280 [PMID: 10732444 DOI: 10.1562/0031-8655(2000)071<0273:PGMRTR>2.0.CO;2]
  - 65 **Sgouros SN**, Vlachogiannakos J, Vassiliadis K, Bergele C, Stefanidis G, Nastos H, Avgerinos A, Mantides A. Effect of polyethylene glycol electrolyte balanced solution on patients with acute colonic pseudo obstruction after resolution of colonic dilation: a prospective, randomised, placebo controlled trial. *Gut* 2006; **55**: 638-642 [PMID: 16306137 DOI: 10.1136/gut.2005.082099]
  - 66 **Savidge TC**. Importance of NO and its related compounds in enteric nervous system regulation of gut homeostasis and disease susceptibility. *Curr Opin Pharmacol* 2014; **19**: 54-60 [PMID: 25108170 DOI: 10.1016/j.coph.2014.07.009]
  - 67 **Kimoto M**, Zeredo JL, Ota MS, Nihei Z, Toda K. Comparison of stress-induced modulation of smooth-muscle activity between ileum and colon in male rats. *Auton Neurosci* 2014; **183**: 8-11 [PMID: 24530114 DOI: 10.1016/j.autneu.2014.01.008]
  - 68 **Horváth VJ**, Putz Z, Izbéki F, Körei AE, Gerő L, Lengyel C, Kempler P, Várkonyi T. Diabetes-related dysfunction of the small intestine and the colon: focus on motility. *Curr Diab Rep* 2015; **15**: 94 [PMID: 26374571 DOI: 10.1007/s11892-015-0672-8]
  - 69 **Yarandi SS**, Srinivasan S. Diabetic gastrointestinal motility disorders and the role of enteric nervous system: current status and future directions. *Neurogastroenterol Motil* 2014; **26**: 611-624 [PMID: 24661628 DOI: 10.1111/nmo.12330]
  - 70 **Rao M**, Gershon MD. The bowel and beyond: the enteric nervous system in neurological disorders. *Nat Rev Gastroenterol Hepatol* 2016; **13**: 517-528 [PMID: 27435372 DOI: 10.1038/nrgastro.2016.107]
  - 71 **Lebouvier T**, Chaumette T, Paillusson S, Duyckaerts C, Bruley des Varannes S, Neunlist M, Derkinderen P. The second brain and Parkinson's disease. *Eur J Neurosci* 2009; **30**: 735-741 [PMID: 19712093 DOI: 10.1111/j.1460-9568.2009.06873.x]
  - 72 **Puig KL**, Lutz BM, Urquhart SA, Rebel AA, Zhou X, Manocha GD, Sens M, Tuteja AK, Foster NL, Combs CK. Overexpression of mutant amyloid- $\beta$  protein precursor and presenilin 1 modulates enteric nervous system. *J Alzheimers Dis* 2015; **44**: 1263-1278 [PMID: 25408221 DOI: 10.3233/JAD-142259]
  - 73 **Semar S**, Klotz M, Letiembre M, Van Ginneken C, Braun A, Jost V, Bischof M, Lammers WJ, Liu Y, Fassbender K, Wyss-Coray T, Kirchhoff F, Schäfer KH. Changes of the enteric nervous system in amyloid- $\beta$  protein precursor transgenic mice correlate with disease progression. *J Alzheimers Dis* 2013; **36**: 7-20 [PMID: 23531500 DOI: 10.3233/JAD-120511]
  - 74 **Camilleri M**, Cowen T, Koch TR. Enteric neurodegeneration in ageing. *Neurogastroenterol Motil* 2008; **20**: 418-429 [PMID: 18371012 DOI: 10.1111/j.1365-2982.2008.01134.x]
  - 75 **Wade PR**, Cowen T. Neurodegeneration: a key factor in the ageing gut. *Neurogastroenterol Motil* 2004; **16** Suppl 1: 19-23 [PMID: 15065999 DOI: 10.1111/j.1743-3150.2004.00469.x]
  - 76 **Gomez-Pinilla PJ**, Gibbons SJ, Sarr MG, Kendrick ML, Shen KR, Cima RR, Dozois EJ, Larson DW, Ordog T, Pozo MJ, Farrugia G. Changes in interstitial cells of cajal with age in the human stomach and colon. *Neurogastroenterol Motil* 2011; **23**: 36-44 [PMID: 20723073 DOI: 10.1111/j.1365-2982.2010.01590.x]
  - 77 **Wegener M**, Börsch G. Acute colonic pseudo-obstruction (Ogilvie's syndrome). Presentation of 14 of our own cases and analysis of 1027 cases reported in the literature. *Surg Endosc* 1987; **1**: 169-174 [PMID: 3332478 DOI: 10.1007/BF00590926]
  - 78 **Jain V**, Pitchumoni CS. Gastrointestinal side effects of prescription medications in the older adult. *J Clin Gastroenterol* 2009; **43**: 103-110 [PMID: 19142171 DOI: 10.1097/MCG.0b013e31818f9227]
  - 79 **Triantafyllou K**, Vlachogiannakos J, Ladas SD. Gastrointestinal and liver side effects of drugs in elderly patients. *Best Pract Res Clin Gastroenterol* 2010; **24**: 203-215 [PMID: 20227033 DOI: 10.1016/j.bpg.2010.02.004]
  - 80 **Catchpole BN**. Pseudo-obstruction. *Br Med J (Clin Res Ed)* 1986; **292**: 1738 [PMID: 3089378 DOI: 10.1136/bmj.292.6537.1738-c]
  - 81 **Alam HB**, Fricchione GL, Guimaraes AS, Zukerberg LR. Case records of the Massachusetts General Hospital. Case 31-2009. A 26-year-old man with abdominal distention and shock. *N Engl J Med* 2009; **361**: 1487-1496 [PMID: 19812406 DOI: 10.1056/NEJMcpc0900643]
  - 82 **Fahy BG**. Pseudoobstruction of the colon: early recognition and therapy. *J Neurosurg Anesthesiol* 1996; **8**: 133-136 [PMID: 8829560 DOI: 10.1097/00008506-199604000-00006]
  - 83 **Mehta R**, John A, Nair P, Raj VV, Mustafa CP, Suvarna D, Balakrishnan V. Factors predicting successful outcome following neostigmine therapy in acute colonic pseudo-obstruction: a prospective study. *J Gastroenterol Hepatol* 2006; **21**: 459-461 [PMID: 16509875 DOI: 10.1111/j.1440-1746.2005.03994.x]
  - 84 **Weinstock LB**, Chang AC. Methylantrexone for treatment of acute colonic pseudo-obstruction. *J Clin Gastroenterol* 2011; **45**: 883-884 [PMID: 21992933 DOI: 10.1097/MCG.0b013e31821100ab]
  - 85 **Bauer GE**, Hellestrand KJ. Letter: Pseudo-obstruction due to clonidine. *Br Med J* 1976; **1**: 769 [PMID: 1260322 DOI: 10.1136/bmj.1.6012.769-c]
  - 86 **Bear R**, Steer K. Pseudo-obstruction due to clonidine. *Br Med J* 1976; **1**: 197 [PMID: 1247772 DOI: 10.1136/bmj.1.6003.197]
  - 87 **Stieger DS**, Cantieni R, Frutiger A. Acute colonic pseudoobstruction (Ogilvie's syndrome) in two patients receiving high dose clonidine for delirium tremens. *Intensive Care Med* 1997; **23**: 780-782 [PMID: 9290993 DOI: 10.1007/s001340050409]
  - 88 **Aslan S**, Bilge F, Aydinli B, Ocak T, Uzkeser M, Erdem AF, Katirci Y. Amitraz: an unusual aetiology of Ogilvie's syndrome. *Hum Exp Toxicol* 2005; **24**: 481-483 [PMID: 16235738 DOI: 10.1191/0960327105ht550cr]
  - 89 **Doherty NS**, Hancock AA. Role of alpha-2 adrenergic receptors in the control of diarrhea and intestinal motility. *J Pharmacol Exp Ther* 1983; **225**: 269-274 [PMID: 6132991]
  - 90 **Nagao M**, Shibata C, Funayama Y, Fukushima K, Takahashi KI, Jin XL, Kudoh K, Sasaki I. Role of alpha-2 adrenoceptors in regulation of giant migrating contractions and defecation in conscious dogs. *Dig Dis Sci* 2007; **52**: 2204-2210 [PMID: 17429732 DOI: 10.1007/s10620-006-9154-9]
  - 91 **Paraskevaides EC**, Sodipo JA. Atypical Ogilvie syndrome. *Aust N Z J Obstet Gynaecol* 1988; **28**: 148-149 [PMID: 3228411 DOI: 10.1111/j.1479-828X.1988.tb01647.x]
  - 92 **Dickson MA**, McClure JH. Acute colonic pseudo-obstruction after caesarean section. *Int J Obstet Anesth* 1994; **3**: 234-236 [PMID: 15636957 DOI: 10.1016/0959-289X(94)90075-2]
  - 93 **Busch FW**, Hamdorf JM, Carroll CS Sr, Magann EF, Morrison JC. Acute colonic pseudo-obstruction following cesarean delivery. *J Miss State Med Assoc* 2004; **45**: 323-326 [PMID: 15624628]
  - 94 **Saha AK**, Newman E, Giles M, Horgan K. Ogilvie's syndrome with caecal perforation after Caesarean section: a case report. *J Med Case Rep* 2009; **3**: 6177 [PMID: 19830099 DOI: 10.4076/1752-1947-3-6177]
  - 95 **Shakir AJ**, Sajid MS, Kianifard B, Baig MK. Ogilvie's syndrome-related right colon perforation after cesarean section: a case series. *Kaohsiung J Med Sci* 2011; **27**: 234-238 [PMID: 21601169 DOI: 10.1016/j.kjms.2010.11.006]
  - 96 **Latunde-Dada AO**, Alleemudder DI, Webster DP. Ogilvie's syndrome following caesarean section. *BMJ Case Rep* 2013; **2013**: [PMID: 23784768 DOI: 10.1136/bcr-2013-010013]
  - 97 **Suraweera P**, Davis L, Gulfranz F, Lahiri S. Ogilvie's syndrome

- after caesarean section-case report and review of the literature. *BJOG* 2013; **120**: 39
- 98 **Yulia A**, Guirguis M. Ogilvie syndrome - An acute pseudo-colonic obstruction 1 week following caesarean section: A case report. *BJOG* 2012; **119**: 32-33 [DOI: 10.1111/j.1471-0528.2012.03376.x]
  - 99 **Srivastava G**, Pilkington A, Nallala D, Polson DW, Holt E. Ogilvie's syndrome: a case report. *Arch Gynecol Obstet* 2007; **276**: 555-557 [PMID: 17581761 DOI: 10.1007/s00404-007-0386-5]
  - 100 **Bhatti AB**, Khan F, Ahmed A. Acute colonic pseudo-obstruction (ACPO) after normal vaginal delivery. *J Pak Med Assoc* 2010; **60**: 138-139 [PMID: 20209705]
  - 101 **Carlidge D**, Seenath M. Acute pseudo-obstruction of the large bowel with caecal perforation following normal vaginal delivery: a case report. *J Med Case Rep* 2010; **4**: 123 [PMID: 20429893 DOI: 10.1186/1752-1947-4-123]
  - 102 **Kakarla A**, Posnett H, Jain A, Ash A. Acute pseudo-obstruction of the colon (Ogilvie's syndrome) following instrumental vaginal delivery. *Int J Clin Pract* 2006; **60**: 1303-1305 [PMID: 16981974 DOI: 10.1111/j.1742-1241.2005.00740.x]
  - 103 **Jayaram P**, Mohan M, Lindow S, Konje J. Postpartum Acute Colonic Pseudo-Obstruction (Ogilvie's Syndrome): A systematic review of case reports and case series. *Eur J Obstet Gynecol Reprod Biol* 2017; **214**: 145-149 [PMID: 28531835 DOI: 10.1016/j.ejogrb.2017.04.028]
  - 104 **Ravo B**, Pollane M, Ger R. Pseudo-obstruction of the colon following cesarean section. A review. *Dis Colon Rectum* 1983; **26**: 440-444 [PMID: 6688045 DOI: 10.1007/BF02556522]
  - 105 **Munro A**, Jones PF. Abdominal surgical emergencies in the puerperium. *Br Med J* 1975; **4**: 691-694 [PMID: 1203726 DOI: 10.1136/bmj.4.5998.691]
  - 106 **Fu Q**, Levine BD. Autonomic circulatory control during pregnancy in humans. *Semin Reprod Med* 2009; **27**: 330-337 [PMID: 19530067 DOI: 10.1055/s-0029-1225261]
  - 107 **Greenwood JP**, Stoker JB, Walker JJ, Mary DA. Sympathetic nerve discharge in normal pregnancy and pregnancy-induced hypertension. *J Hypertens* 1998; **16**: 617-624 [PMID: 9797173 DOI: 10.1097/00004872-199816050-00009]
  - 108 **Schobel HP**, Fischer T, Heuszer K, Geiger H, Schmieder RE. Preeclampsia -- a state of sympathetic overactivity. *N Engl J Med* 1996; **335**: 1480-1485 [PMID: 8890098 DOI: 10.1056/nejm199611143352002]
  - 109 **Airaksinen KE**, Kirkinen P, Takkunen JT. Autonomic nervous dysfunction in severe pre-eclampsia. *Eur J Obstet Gynecol Reprod Biol* 1985; **19**: 269-276 [PMID: 4018366 DOI: 10.1016/0028-2243(85)90040-1]
  - 110 **Chang SW**, Ohara N. Pulmonary intravascular phagocytosis in liver disease. *Clin Chest Med* 1996; **17**: 137-150 [PMID: 8665786 DOI: 10.1016/S0272-5231(05)70304-X]
  - 111 **Stephens FO**. Syndrome of Intestinal Pseudo-obstruction. *Br Med J* 1962; **1**: 1248-1238.2 [PMID: 20789407]
  - 112 **Lowman RM**. The potassium depletion states and postoperative ileus. The role of the potassium ion. *Radiology* 1971; **98**: 691-694 [PMID: 5544539 DOI: 10.1148/98.3.691]
  - 113 **Quigley EM**. Acute Intestinal Pseudo-obstruction. *Curr Treat Options Gastroenterol* 2000; **3**: 273-286 [PMID: 11096588 DOI: 10.1007/s11938-000-0041-8]
  - 114 **Akiho H**, Ihara E, Motomura Y, Nakamura K. Cytokine-induced alterations of gastrointestinal motility in gastrointestinal disorders. *World J Gastrointest Pathophysiol* 2011; **2**: 72-81 [PMID: 22013552 DOI: 10.4291/wjgp.v2.i5.72]
  - 115 **Vather R**, O'Grady G, Bissett IP, Dinning PG. Postoperative ileus: mechanisms and future directions for research. *Clin Exp Pharmacol Physiol* 2014; **41**: 358-370 [PMID: 24754527 DOI: 10.1111/1440-1681.12220]
  - 116 **Bauer AJ**, Schwarz NT, Moore BA, Türlér A, Kalff JC. Ileus in critical illness: mechanisms and management. *Curr Opin Crit Care* 2002; **8**: 152-157 [PMID: 12386517 DOI: 10.1097/00075198-200204000-00011]
  - 117 **Luderer JR**, Demers LM, Bonnem EM, Saleem A, Jeffries GH. Elevated prostaglandin e in idiopathic intestinal pseudo-obstruction. *N Engl J Med* 1976; **295**: 1179 [PMID: 980023 DOI: 10.1056/NEJM197611182952109]
  - 118 **Book LS**, Johnson DG, Jubiz W. Elevated prostaglandin E in children with chronic idiopathic intestinal pseudo-obstruction syndrome (CIIPS): Effects of prostaglandin synthetase inhibitors on gastrointestinal motility. *Clin Res* 1979; **27**: 100A
  - 119 **Chousterman M**, Petite JP, Housset E, Hornych A. Prostaglandins and acute intestinal pseudo-obstruction. *Lancet* 1977; **2**: 138-139 [PMID: 69218 DOI: 10.1016/S0140-6736(77)90147-7]
  - 120 **Xue S**, Valdez DT, Tremblay L, Collman PI, Diamant NE. Electrical slow wave activity of the cat stomach: its frequency gradient and the effect of indomethacin. *Neurogastroenterol Motil* 1995; **7**: 157-167 [PMID: 8536160 DOI: 10.1111/j.1365-2982.1995.tb00221.x]
  - 121 **Shi XZ**, Lin YM, Powell DW, Sarna SK. Pathophysiology of motility dysfunction in bowel obstruction: role of stretch-induced COX-2. *Am J Physiol Gastrointest Liver Physiol* 2011; **300**: G99-G108 [PMID: 21051526 DOI: 10.1152/ajpgi.00379.2010]
  - 122 **Lee E**, Lee J, Do YS, Myung SJ, Yu CS, Lee HK. Distribution of COX-2 and collagen accumulation in the dilated colons obtained from patients with chronic colonic pseudo-obstruction. *Gastroenterology* 2016; **1**: S537 [DOI: 10.1016/S0016-5085(16)31847-9]
  - 123 **Kesner KM**, Bar-Maor JA. Herpes zoster causing apparent low colonic obstruction. *Dis Colon Rectum* 1979; **22**: 503-504 [PMID: 583331 DOI: 10.1007/BF02586944]
  - 124 **Johnson JN**, Sells RA. Herpes zoster and paralytic ileus: a case report. *Br J Surg* 1977; **64**: 143-144 [PMID: 578122 DOI: 10.1002/bjs.1800640215]
  - 125 **Caccese WJ**, Bronzo RL, Wadler G, McKinley MJ. Ogilvie's syndrome associated with herpes zoster infection. *J Clin Gastroenterol* 1985; **7**: 309-313 [PMID: 3840187 DOI: 10.1097/00004836-198508000-00008]
  - 126 **Alpay K**, Yandt M. Herpes zoster and Ogilvie's syndrome. *Dermatology* 1994; **189**: 312 [PMID: 7949493 DOI: 10.1159/000246870]
  - 127 **Pai NB**, Murthy RS, Kumar HT, Gerst PH. Association of acute colonic pseudo-obstruction (Ogilvie's syndrome) with herpes zoster. *Am Surg* 1990; **56**: 691-694 [PMID: 2240863]
  - 128 **Jucgla A**, Badell A, Ballesta C, Arbizu T. Colonic pseudo-obstruction: a complication of herpes zoster. *Br J Dermatol* 1996; **134**: 788-790 [PMID: 8733394 DOI: 10.1111/j.1365-2133.1996.tb06993.x]
  - 129 **Rodrigues G**, Kannaiyan L, Gopasetty M, Rao S, Shenoy R. Colonic pseudo-obstruction due to herpes zoster. *Indian J Gastroenterol* 2002; **21**: 203-204 [PMID: 12416757]
  - 130 **Masood I**, Majid Z, Rind W, Zia A, Riaz H, Raza S. Herpes Zoster-Induced Ogilvie's Syndrome. *Case Rep Surg* 2015; **2015**: 563659 [PMID: 26664758 DOI: 10.1155/2015/563659]
  - 131 **Walsh TN**, Lane D. Pseudo obstruction of the colon associated with varicella-zoster infection. *Ir J Med Sci* 1982; **151**: 318-319 [PMID: 6897397 DOI: 10.1007/BF02940213]
  - 132 **Nomdedéu JF**, Nomdedéu J, Martino R, Bordes R, Portorreal R, Sureda A, Domingo-Albós A, Rutllant M, Soler J. Ogilvie's syndrome from disseminated varicella-zoster infection and infarcted celiac ganglia. *J Clin Gastroenterol* 1995; **20**: 157-159 [PMID: 7769201 DOI: 10.1097/00004836-199503000-00020]
  - 133 **Carrascosa MF**, Salcines-Caviedes JR, Román JG, Cano-Hoz M, Fernández-Ayala M, Casuso-Sáenz E, Abascal-Carrera I, Campo-Ruiz A, Martín MC, Díaz-Pérez A, González-Gutiérrez P, Aguado JM. Varicella-zoster virus (VZV) infection as a possible cause of Ogilvie's syndrome in an immunocompromised host. *J Clin Microbiol* 2014; **52**: 2718-2721 [PMID: 24808241 DOI: 10.1128/JCM.00379-14]
  - 134 **Braude MR**, Trubiano JA, Heriot A, Dickinson M, Carney D, Seymour JF, Tam CS. Disseminated visceral varicella zoster virus presenting with the constellation of colonic pseudo-obstruction, acalculous cholecystitis and syndrome of inappropriate ADH secretion. *Intern Med J* 2016; **46**: 238-239 [PMID: 26899893 DOI: 10.1111/imj.12977]
  - 135 **Shapiro AM**, Bain VG, Preiksaitis JK, Ma MM, Issa S, Kneteman NM. Ogilvie's syndrome associated with acute cytomegaloviral infection after liver transplantation. *Transpl Int* 2000; **13**: 41-45 [PMID: 10743688]
  - 136 **Anam AM**, Rabbani R. Ogilvie's syndrome in severe dengue. *Lancet* 2013; **381**: 698 [PMID: 23439104 DOI: 10.1016/

- S0140-6736(12)62031-5]
- 137 **Edelman DA**, Antaki F, Basson MD, Salwen WA, Gruber SA, Losanoff JE. Ogilvie syndrome and herpes zoster: case report and review of the literature. *J Emerg Med* 2010; **39**: 696-700 [PMID: 19327938 DOI: 10.1016/j.jemermed.2009.02.010]
  - 138 **Tribble DR**, Church P, Frame JN. Gastrointestinal visceral motor complications of dermatomal herpes zoster: report of two cases and review. *Clin Infect Dis* 1993; **17**: 431-436 [PMID: 8218686 DOI: 10.1093/clinids/17.3.431]
  - 139 **Pui JC**, Furth EE, Minda J, Montone KT. Demonstration of varicella-zoster virus infection in the muscularis propria and myenteric plexi of the colon in an HIV-positive patient with herpes zoster and small bowel pseudo-obstruction (Ogilvie's syndrome). *Am J Gastroenterol* 2001; **96**: 1627-1630 [PMID: 11374712 DOI: 10.1111/j.1572-0241.2001.03808.x]
  - 140 **Vedin A**, Wilhelmson C, Werko L. Pseudo-obstruction of the Large Bowel. *Br Med J* 1975; **2**: 105 [DOI: 10.1136/bmj.2.5963.105]
  - 141 **Addison NV**. Pseudo-obstruction of the large bowel. *J R Soc Med* 1983; **76**: 252-255 [PMID: 6687739]
  - 142 **Byrne JJ**. Unusual aspects of large bowel obstruction. *Am J Surg* 1962; **103**: 62-65 [DOI: 10.1016/0002-9610(62)90014-4]
  - 143 **Singleton AO Jr**, Wilson M. Air-fluid obstruction of the colon. *South Med J* 1967; **60**: 909-913 [PMID: 6048134 DOI: 10.1097/00007611-196709000-00001]
  - 144 **Hubbard CN**, Richardson EG. Pseudo-obstruction of the colon. A postoperative complication in orthopaedic patients. *J Bone Joint Surg Am* 1983; **65**: 226-229 [PMID: 6822584 DOI: 10.2106/00004623-198365020-00010]
  - 145 **Gammill SL**. Air-fluid lock syndrome. *Radiology* 1974; **111**: 27-30 [PMID: 4816114 DOI: 10.1148/111.1.27]
  - 146 Intestinal pseudo-obstruction. *Lancet* 1979; **1**: 535-536 [PMID: 85113]
  - 147 **Ferguson JH**, Cameron A. Intestinal pseudo-obstruction. *Br Med J* 1973; **1**: 614 [PMID: 4694418 DOI: 10.1136/bmj.1.5853.614-b]
  - 148 **Zhao C**, Xie T, Li J, Cheng M, Shi J, Gao T, Xi F, Shen J, Cao C, Yu W. Acute Colonic Pseudo-Obstruction with Feeding Intolerance in Critically Ill Patients: A Study according to Gut Wall Analysis. *Gastroenterol Res Pract* 2017; **2017**: 9574592 [PMID: 28386273 DOI: 10.1155/2017/9574592]
  - 149 **Batke M**, Cappell MS. Adynamic ileus and acute colonic pseudo-obstruction. *Med Clin North Am* 2008; **92**: 649-670, ix [PMID: 18387380 DOI: 10.1016/j.mcna.2008.01.002]
  - 150 **Stephenson BM**, Morgan AR, Wheeler MH. Parasympathomimetics in Ogilvie's syndrome. *Dis Colon Rectum* 1994; **37**: 289-290 [PMID: 8137679 DOI: 10.1007/BF02048170]
  - 151 **Lin AY**, Dinning PG, Milne T, Bissett IP, O'Grady G. The "rectosigmoid brake": review of an emerging neuromodulation target for colorectal functional disorders. *Clin Exp Pharmacol Physiol* 2017; **44**: 719-728 [PMID: 28419527 DOI: 10.1111/1440-1681.12760]
  - 152 **Vather R**, Lin A, O'Grady G, Dinning P, Rowbotham D, Bissett I. Perioperative Colonic Motility defined by High-Resolution Manometry After Intestinal Surgery. Proceedings of The American Society of Colon and Rectal Surgeons Annual Meeting; 2016 Apr 30-May 4; Los Angeles, CA, USA. Wolters Kluwer, 2016: e167
  - 153 **Macfarlane JA**, Kay SK. Ogilvie's syndrome of false colonic obstruction; is it a new clinical entity? *Br Med J* 1949; **2**: 1267-1269 [PMID: 15394635 DOI: 10.1136/bmj.2.4639.1267]
  - 154 **Rothwell-jackson RL**. Idiopathic large-bowel obstruction. *Br J Surg* 1963; **50**: 797-800 [PMID: 14068624 DOI: 10.1002/bjs.18005022606]
  - 155 **Dunlop JA**. Ogilvie's syndrome of false colonic obstruction; a case with post-mortem findings. *Br Med J* 1949; **1**: 890 [PMID: 18127686 DOI: 10.1136/bmj.1.4611.890]
  - 156 **Gerlis LM**. Ogilvie's syndrome. *Br Med J* 1949; **1**: 1137 [PMID: 18153429 DOI: 10.1136/bmj.1.4616.1137]
  - 157 **Abrahams AM**. Ogilvie's syndrome. *Br Med J* 1950; **4653**: 606 [DOI: 10.1136/bmj.1.4653.606-a]
  - 158 **Creech B**. Megacolon; a review of the literature and report of a case in the aged. *N C Med J* 1950; **11**: 241-246 [PMID: 15417023]
  - 159 **Moore CE**, Koman GM. Impending cecal perforation secondary to a crushing injury of the pelvis. *Arch Surg* 1959; **79**: 1044-1046 [PMID: 14423833 DOI: 10.1001/archsurg.1959.04320120186026]
  - 160 **Adams JT**. Adynamic ileus of the colon. An indication for cecostomy. *Arch Surg* 1974; **109**: 503-507 [PMID: 4411891 DOI: 10.1001/archsurg.1974.01360040025007]
  - 161 **Melamed M**, KUBIAN E. Relationship of the autonomic nervous system to "functional" obstruction of the intestinal tract. Report of four cases, one with perforation. *Radiology* 1963; **80**: 22-29 [PMID: 13934630 DOI: 10.1148/80.1.22]
  - 162 **Morton JH**, Schwartz SI, Gramiak R. Ileus of the colon. *Arch Surg* 1960; **81**: 425-434 [PMID: 14424467]
  - 163 **Bryk D**, Soong KY. Colonic ileus and its differential roentgen diagnosis. *Am J Roentgenol Radium Ther Nucl Med* 1967; **101**: 329-337 [PMID: 6045392 DOI: 10.2214/ajr.101.2.329]
  - 164 **Johnson CD**, Rice RP, Kelvin FM, Foster WL, Williford ME. The radiologic evaluation of gross cecal distension: emphasis on cecal ileus. *AJR Am J Roentgenol* 1985; **145**: 1211-1217 [PMID: 3877425 DOI: 10.2214/ajr.145.6.1211]
  - 165 Intestinal Pseudo-obstruction. *Br Med J* 1973; **1**: 64-65 [PMID: 20791868 DOI: 10.1136/bmj.1.5845.64]
  - 166 **Romeo DP**, Solomon GD, Hover AR. Intestinal pseudo-obstruction. *Ann Intern Med* 1983; **98**: 674 [PMID: 6846996 DOI: 10.7326/0003-4819-98-5-674\_1]
  - 167 **Gillett DJ**. Non-mechanical large-bowel obstruction. *Aust N Z J Surg* 1971; **41**: 47-50 [PMID: 5286337 DOI: 10.1111/j.1445-2197.1968.tb06256.x]
  - 168 **Soreide O**, Bjerkeset T, Fossdal JE. Pseudo-obstruction of the colon (Ogilvie's syndrome), a genuine clinical conditions? Review of the literature (1948-1975) and report of five cases. *Dis Colon Rectum* 1977; **20**: 487-491 [PMID: 902545 DOI: 10.1007/BF02586587]
  - 169 **Bachulis BL**, Smith PE. Pseudoobstruction of the colon. *Am J Surg* 1978; **136**: 66-72 [PMID: 677392 DOI: 10.1016/0002-9610(78)90202-7]
  - 170 **Strodel WE**, Nostrant TT, Eckhauser FE, Dent TL. Therapeutic and diagnostic colonoscopy in nonobstructive colonic dilatation. *Ann Surg* 1983; **197**: 416-421 [PMID: 6830348 DOI: 10.1097/00006658-198304000-00007]
  - 171 **Koneru B**, Selby R, O'Hair DP, Tzakis AG, Hakala TR, Starzl TE. Nonobstructing colonic dilatation and colon perforations following renal transplantation. *Arch Surg* 1990; **125**: 610-613 [PMID: 2331220 DOI: 10.1001/archsurg.1990.01410170056012]
  - 172 **Adeyanju MA**, Bello AO. Acute megacolon (acute colonic pseudo-obstruction)- a case report. *J Gastroenterol Hepatol Res* 2013; **2**: 485-488 [DOI: 10.6051/j.issn.2224-3992.2013.02.224]

P- Reviewer: Koda K S- Editor: Qi Y L- Editor: A  
E- Editor: Zhang FF





Published by **Baishideng Publishing Group Inc**  
7901 Stoneridge Drive, Suite 501, Pleasanton, CA 94588, USA  
Telephone: +1-925-223-8242  
Fax: +1-925-223-8243  
E-mail: [bpgoffice@wjgnet.com](mailto:bpgoffice@wjgnet.com)  
Help Desk: <http://www.f6publishing.com/helpdesk>  
<http://www.wjgnet.com>



ISSN 1007-9327

