ISSN 1007-9327 (print)
ISSN 2219-2840 (online)

World Journal of *Gastroenterology*

World J Gastroenterol 2022 April 14; 28(14): 1384-1502

Published by Baishideng Publishing Group Inc

WJG World Journal of Gastroenterology

Contents

Weekly Volume 28 Number 14 April 14, 2022

Contents

ABOUT COVER

Editorial Board Member of *World Journal of Gastroenterology*, Sung-Chul Lim, MD, PhD, Professor, Head, Department of Pathology, Chosun University Hospital, 365 Pilmun-daero, Dong-gu, Gwangju 61453, South Korea. sclim@chosun.ac.kr

AIMS AND SCOPE

The primary aim of *World Journal of Gastroenterology* (*WJG*, *World J Gastroenterol*) is to provide scholars and readers from various fields of gastroenterology and hepatology with a platform to publish high-quality basic and clinical research articles and communicate their research findings online. *WJG* mainly publishes articles reporting research results and findings obtained in the field of gastroenterology and hepatology and covering a wide range of topics including gastroenterology, hepatology, gastrointestinal endoscopy, gastrointestinal surgery, gastrointestinal oncology, and pediatric gastroenterology.

INDEXING/ABSTRACTING

The *WJG* is now indexed in Current Contents®/Clinical Medicine, Science Citation Index Expanded (also known as SciSearch®), Journal Citation Reports®, Index Medicus, MEDLINE, PubMed, PubMed Central, and Scopus. The 2021 edition of Journal Citation Report® cites the 2020 impact factor (IF) for *WJG* as 5.742; Journal Citation Indicator: 0.79; IF without journal self cites: 5.590; 5-year IF: 5.044; Ranking: 28 among 92 journals in gastroenterology and hepatology; and Quartile category: Q2. The *WJG*'s CiteScore for 2020 is 6.9 and Scopus CiteScore rank 2020: Gastroenterology is 19/136.

RESPONSIBLE EDITORS FOR THIS ISSUE

Production Editor: *Hua-Ge Yu*; **Production Department Director:** *Xu Guo*; **Editorial Office Director:** *Ze-Mao Gong*.

NAME OF JOURNAL
World Journal of Gastroenterology

ISSN
ISSN 1007-9327 (print) ISSN 2219-2840 (online)

LAUNCH DATE
October 1, 1995

FREQUENCY
Weekly

EDITORS-IN-CHIEF
Andrzej S Tarnawski

EDITORIAL BOARD MEMBERS
http://www.wjgnet.com/1007-9327/editorialboard.htm

PUBLICATION DATE
April 14, 2022

INSTRUCTIONS TO AUTHORS
https://www.wjgnet.com/bpg/gerinfo/204

GUIDELINES FOR ETHICS DOCUMENTS
https://www.wjgnet.com/bpg/GerInfo/287

GUIDELINES FOR NON-NATIVE SPEAKERS OF ENGLISH
https://www.wjgnet.com/bpg/gerinfo/240

PUBLICATION ETHICS
https://www.wjgnet.com/bpg/GerInfo/288

PUBLICATION MISCONDUCT
https://www.wjgnet.com/bpg/gerinfo/208

ARTICLE PROCESSING CHARGE
https://www.wjgnet.com/bpg/gerinfo/242

STEPS FOR SUBMITTING MANUSCRIPTS
https://www.wjgnet.com/bpg/GerInfo/239

ONLINE SUBMISSION
https://www.f6publishing.com

World Journal of Gastroenterology

Submit a Manuscript: https://www.f6publishing.com

World J Gastroenterol 2022 April 14; 28(14): 1384-1393

DOI: 10.3748/wjg.v28.i14.1384

ISSN 1007-9327 (print) ISSN 2219-2840 (online)

EDITORIAL

Hepatocellular adenoma: Where are we now?

Xi Wang, Xuchen Zhang

Specialty type: Gastroenterology and hepatology

Provenance and peer review: Invited article; Externally peer reviewed.

Peer-review model: Single blind

Peer-review report's scientific quality classification

Grade A (Excellent): A
Grade B (Very good): B
Grade C (Good): C
Grade D (Fair): 0
Grade E (Poor): 0

P-Reviewer: Kotelevets SM, Russia; Mrzljak A, Croatia; Sugimura H, Japan

Received: December 5, 2021
Peer-review started: December 5, 2021
First decision: January 8, 2022
Revised: January 9, 2022
Accepted: March 6, 2022
Article in press: March 6, 2022
Published online: April 14, 2022

Xi Wang, Xuchen Zhang, Department of Pathology, Yale University School of Medicine, New Haven, CT 06520, United States

Corresponding author: Xuchen Zhang, MD, PhD, Associate Professor, Department of Pathology, Yale University School of Medicine, 310 Cedar Street, PO Box 208023, New Haven, CT 06520, United States. xuchen.zhang@yale.edu

Abstract

Hepatocellular adenoma (HCA) is a benign hepatocellular neoplasm, commonly occurs in young women with a history of oral contraceptive use. Complications including hemorrhage and malignant transformation necessitate the need for a thorough understanding of the underlying molecular signatures in this entity. Recent molecular studies have significantly expanded our knowledge of HCAs. The well-developed phenotype-genotype classification system improves clinical management through identifying "high risk" subtype of HCAs. In this article, we attempt to provide updated information on clinical, pathologic and molecular features of each subtype of HCAs.

Key Words: Hepatocellular adenoma; Subtype; Pathology; Classification; Hepatocellular carcinoma

Core Tip: Hepatocellular adenoma (HCA) has been well recognized as a benign liver neoplasm with risks of hemorrhage and malignant transformation. Studies revealed that different HCA subtypes with specific genetic mutation and pathologic findings are associated with different clinical features. Currently HCAs are classified into at least 5 major subtypes, involving 4 different pathways driving HCA pathogenesis: Hepatocyte nuclear factor 1A, interleukin-6/the Janus kinase/signal transducer and activator of transcription, β-catenin, and Sonic hedgehog pathway.

Citation: Wang X, Zhang X. Hepatocellular adenoma: Where are we now? *World J Gastroenterol* 2022; 28(14): 1384-1393
URL: https://www.wjgnet.com/1007-9327/full/v28/i14/1384.htm
DOI: https://dx.doi.org/10.3748/wjg.v28.i14.1384

INTRODUCTION

Hepatocellular adenoma (HCA) is an uncommon benign liver neoplasm with two major complications: Hemorrhage and malignant transformation. Epidemiological data from the United States and European countries have revealed HCAs occur mainly in young to middle-aged women (median ages: 36-38 years, female/male ratio of 8:1), often with a history of long-term use of oral contraceptives (OCPs)[1,2]. Besides the well-known risk factor of exogenous estrogen exposure, other risk factors, such as androgen use, obesity, fatty liver disease, glycogen storage disease (GSD), especially GSD type 1, hepatic vascular disorders and other genetic disorders are also associated with the occurrence of HCA[2-6]. However, epidemiological data from Asia, where the use of OCPs and the incidence of obesity are lower, are unclear. Limited studies from Taiwan, China and Japan showed a male predominance in patients with HCA[7-11]. Further exploration of these epidemiological differences is needed to better understand the pathogenesis of HCA.

Historically, HCA was thought to be a single group of tumor. Recent advances in HCA clinicopathologic features and molecular biology have not only enhanced our understanding of the disease pathogenesis, but also significantly transitioned into the daily practice of pathology-morpho-molecular correlation. It is known now that HCA is a heterogenous group of liver tumors with heterogenous etiology, clinical presentation, risk of malignant transformation or hemorrhage, radiologic findings, histopathologic features, clinical management strategies and underlying molecular changes. In the current review, we will provide an overview of the current knowledge of how HCA histomorphology correlates to its underlying molecular changes, as well as discuss the controversies in some HCA variants.

HCA: MORPHO-MOLECULAR CLASSIFICATION

Currently, HCAs are classified into hepatocyte nuclear factor 1A *(HNF-1A)* inactivated HCA (H-HCA), inflammatory HCA (I-HCA), β-catenin activated HCA (b-HCA), as well as unclassified HCA (U-HCA) based on underlying molecular changes in 3 different pathways driving benign hepatocytic proliferation: HNF-1A, interleukin-6/the Janus kinase/signal transducer and activator of transcription (IL-6/JAK/STAT), and β-catenin signaling. A new subtype of Sonic hedgehog HCA (shHCA) has been recently described[2], which still needs further characterization. The different mutations in HCA identified to date are summarized in Table 1.

H-HCA

As the first identified subtype, *HNF-1A*-inactivated HCA was proposed by a French group in their pioneer work published in 2002. In an attempt to search for tumor suppressor gene in HCA, Bluteau *et al*[12] genotyped DNA from HCAs and confirmed the bi-allelic inactivation of *HNF-1A* gene in a subgroup of tumors. HNF-1A is an important transcription factor regulating hepatocytes differentiation. It is mainly expressed in pancreatic beta cells, intestine, and liver, that plays an important role in the regulation of glycolipid metabolism[13,14]. Specifically, HNF-1A positively regulates *FABP1* gene, which encodes liver fatty acid binding protein (L-FABP). As a result of *HNF-1A* inactivated mutation, expression of L-FABP is downregulated, along with diffuse steatosis due to dysregulated lipogenesis.

As expected, *HNF-1A*-inactivated HCA histomorphologically shows diffuse marked steatosis (Figure 1A). Immunohistochemical stain for L-FABP is negative (Figure 1B), indicating the functional loss of *HNF-1A* gene. Of note, some H-HCAs may not show steatosis and some other subtype HCAs such as I-HCAs can be seen with marked steatosis. Therefore, steatosis alone should not be used as a sole feature to diagnose H-HCAs. This subtype of HCA approximately composes of 30%-35% of overall HCAs and is mainly due to somatic mutation. Typical H-HCA can also be detected in magnetic resonance imaging (MRI), with diffuse and homogenous signal dropout on T1-weighted images, due to massive fat component[15]. In the clinical aspect, cases of familial liver adenomatosis (greater than 10 adenomas in the liver) have been consistently linked to the germline mutation of *HNF-1A*[16], which is also the genotype in "Maturity onset diabetes of the young, type 3 (MODY3)". Thus, detection of liver adenomatosis with H-HCA is suggested to start family screen for familial adenomatosis, MODY3 diabetes, and the *HNF-1A* germline mutation[17]. Although H-HCA is not usually associated with malignant transformation, hepatocellular carcinoma (HCC) has been reported to arise in the settings of sporadic HCAs[18] as well as those in patients with hepatic vascular disorders or MODY3[19], especially in female patients with multiple lesions without significant steatosis and presence of myxoid change, peliosis and sinusoidal dilatation[3].

I-HCA

Accumulating evidence suggests a critical role of inflammatory response in tumorigenesis, including STAT signaling pathway in the development of breast and lung cancer[20]. Similarly, a subtype of inflammatory epithelial tumors has been described in the family of HCA, involving the IL-6/JAK/STAT3 signaling pathway[21]. IL-6 belongs to the IL-6 cytokine family, which binds to the ligand-

Table 1 Morpho-molecular features of the subtypes of hepatocellular adenoma

	Key pathogenesis	Histology	Immunohistochemical stains	Clinical features
H-HCA	*HNF1A* inactivating mutation: Negative regulation of glycolipid metabolism and L-FABP	Marked steatosis	L-FABP: Negative	Associated with maturity onset diabetes of the young (MODY3) and familial hepatic adenomatosis
I-HCA	IL-6/JAK/STAT3 pathway mutations: (1) Constitutive activation of inflammatory pathway; and (2) Upregulation of acute reactants and hepatocellular proliferation	(1) Inflammatory infiltration; (2) Pseudoportal tracts; (3) Ductular reaction; and (4) Sinusoidal dilatation/peliosis	SSA and CRP: Diffuse positive	Obesity, metabolic syndrome, glycogen storage disease, high alcohol consumption, inflammatory syndrome
b-HCA	(1) *CTNNB1* gene mutation: Activation of signaling pathway and upregulation of targeted genes including GS; and (2) Level of activation depends on mutation loci (Exon 3 Non-S45: Strong activation; S45: Weak activation, and T41: Moderate activation; Exon 7/8: Weak activation)	More atypical features: Pseudoacini and mild cytologic atypia	(1) β-catenin: Aberrant nuclear expression; and (2) GS: Positive	More in men, anabolic steroids use, glycogen storage disease, high risk of malignant transformation, and high risk of bleeding (exon 7/8)
b-IHCA	Share the features of both b-HCA and I-HCA			
shHCA	*INHBE-GLI1* gene fusion: Constitutive activation of Sonic hedgehog pathway	Hemorrhage	PTGSD and ASS1	High risk of bleeding and obesity
Unclassified	Not other specified			
Uncommon subtypes	Myxoid HCA, pigmented HCA, atypical HCA, I-ICA in cirrhotic liver			

HNF1A: Hepatocyte nuclear factor 1A; L-FABP: Liver fatty acid binding protein; SSA: Serum amyloid A; CRP: C-reactive protein; CTNNB1: Catenin beta 1; GS: Glutamine synthetase; INHBE-GLI1: Inhibin beta E chain/glioma-associated oncogene 1; PTGDS: Prostaglandin D synthase; ASS1: Argininosuccinate Synthase 1; HCA: Hepatocellular adenoma; I-HCA: Inflammatory HCA; H-HCA: *HNF1A*-inactivated HCA; shHCA: Sonic hedgehog HCA; b-HCA: β-catenin mutated HCA.

specific receptor gp130 to initiate the downstream signaling. This activates downstream signaling pathways such as the Src-homology 2 domain-containing tyrosine phosphatase 2 (SHP2)-Ras-ERK, JAK1/2-STAT3, mosaic G-protein alpha-subunit (GNAS), and the phosphatidylinositol-3-kinase/Akt and the mechanistic target of rapamycin (PI3K-AKT-mTOR), and further the expression of targe genes that regulate cell survival, proliferation and angiogenesis[2,22]. Rebouissou *et al*[21] demonstrated that 60% of I-HCA harbored small in-frame deletions of *IL6ST* gene (encodes the signaling co-receptor gp130), resulting in the constitutive activation of IL-6 signaling and hepatocellular proliferation in the absence of ligand binding. The remaining I-HCAs are linked to other mutations that belong to IL-6/JAK/STAT3 family. The inflammatory response is well-observed histologically[23], characterized by inflammatory infiltration of lymphocytes, plasma cells and neutrophils, ductular reaction, and sinusoidal dilatation/peliosis (Figure 1C). Immunohistochemical stain is remarkable for diffuse overexpression of acute-phase inflammatory protein such as serum amyloid A (SAA) and C-reactive protein (CRP) (Figure 1D).

Clinically, I-HCA is frequently associated with obesity, metabolic syndrome and high alcohol consumption. Furthermore, the risk of developing HCA in patients with GSD is high. The HCAs in patients with GSD are mainly I-HCAs (52%), followed by b-HCAs (28%) and U-HCAs (20%), but never H-HCAs[5]. A few I-HCA cases had also been reported to induce systemic AA amyloidosis[24]. Typical I-HCA also has unique MRI features, with hyperintensity on T2-weighted images due to sinusoidal dilatation[15]. This subtype approximately composes of 35%-45% of overall HCAs, and about 10% also have β-catenin activation. While the mutation alone is not associated with malignant transformation, it is important to remember that I-HCA can co-exist with β-catenin mutation, the latter of which can transform into HCC[2].

b-HCA

Aberrant Wnt/β-catenin signaling has been identified underlying pathogenesis of many diseases including the well-known familial adenomatous polyposis[25]. In the liver, it also plays an essential role in regulating various cellular events including differentiation, proliferation, survival and others. Not surprisingly, β-catenin (cadherin-associated protein) beta 1 (*CTNNB1*) gene mutations have been reported in around 20%-40% of HCC cases. Chen *et al*[26] detected interstitial deletions in the *CTNNB1* gene in HCAs, indicating the dysregulation of Wnt/β-catenin as a possible preneoplastic pathway for hepatocellular proliferation. Exome sequencing study[27] further subclassified into two types: Exon 3

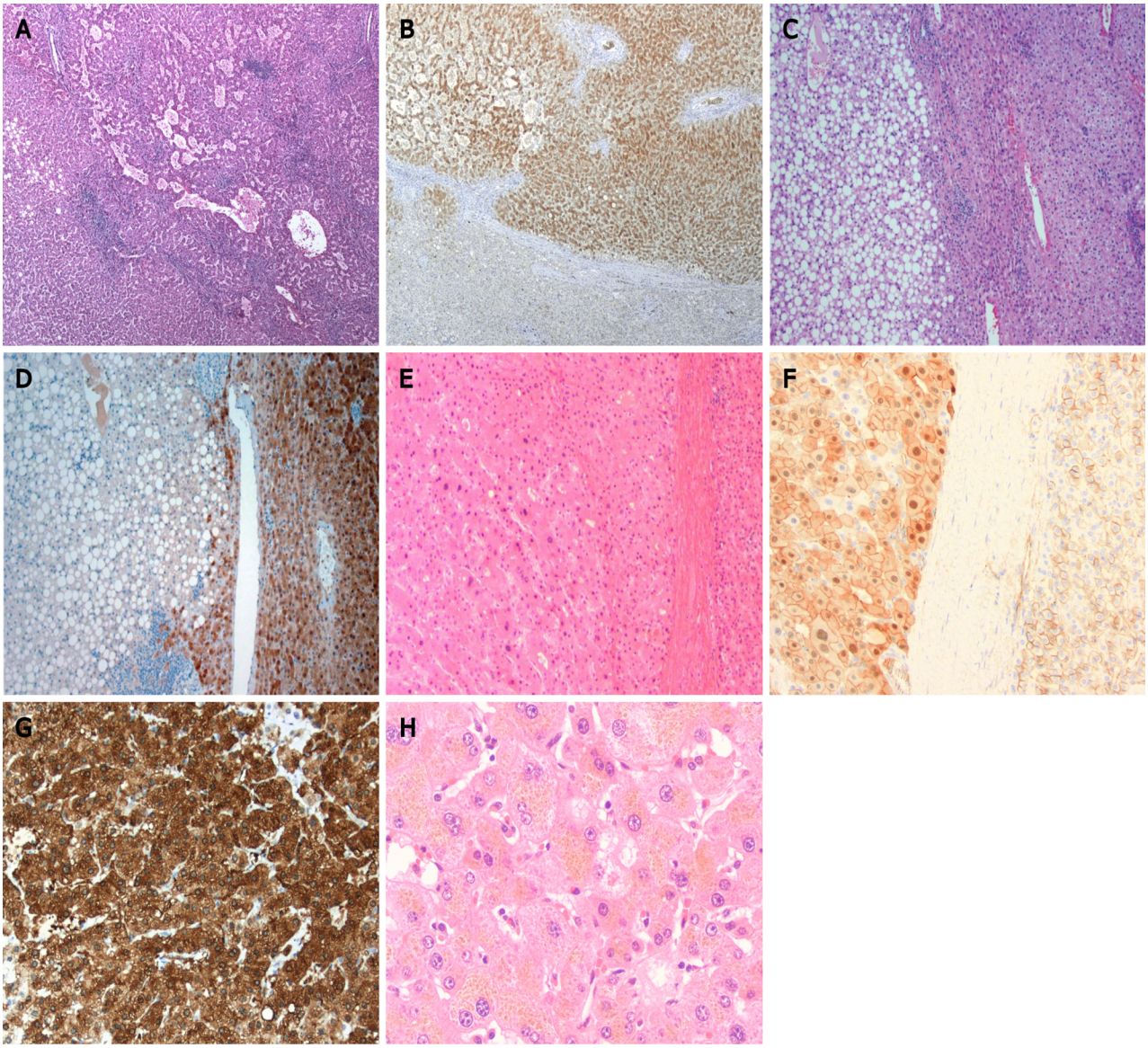

DOI: 10.3748/wjg.v28.i14.1384

Figure 1 Histologic features of hepatocellular adenoma. A: Hepatocyte nuclear factor 1A (HNF-1A) inactivated hepatocellular adenoma showing marked steatosis (Hematoxylin-eosin stain, original magnification 200 ×); B: HNF-1A inactivated hepatocellular adenoma showing loss expression of liver fatty acid binding protein in tumor component (Immunohistochemical stain, original magnification 200 ×); C: Inflammatory hepatocellular adenoma showing marked sinusoidal dilatation and pseudoportal tract with inflammatory infiltrate and ductular reaction (Hematoxylin-eosin stain, original magnification 200 ×); D: Inflammatory hepatocellular adenoma showing strong and diffuse expression of C-reactive protein in tumor component (Immunohistochemical stain, original magnification 200 ×); E: β-catenin activated hepatocellular adenoma showing mild cytologic atypia and pseudoacini (Hematoxylin-eosin stain, original magnification 200 ×); F: β-catenin activated hepatocellular adenoma showing nuclear expression of β-catenin in tumor component (Immunohistochemical stain, original magnification 400 ×); G: β-catenin activated hepatocellular adenoma showing strong and diffuse expression of glutamine synthetase in tumor component (Immunohistochemical stain, original magnification 200 ×); H: Pigmented hepatocellular adenoma showing marked cytoplasmic lipofuscin (Hematoxylin-eosin stain, original magnification 400 ×).

and exon 7/8 with distinct canonical and non-canonical mutations respectively. In the canonical pathway, inactive β-catenin is attached with E-cadherin at cell membrane to maintain cell-cell adhesion. Cytoplasmic β-catenin is sequestered by a "destruction protein complex", then phosphorylated, and further recognized by E3 ubiquitin, eventually degraded in the cytoplasm by proteasomes. The overall net effect is low β-catenin levels within the cells. In the activate states or upon WNT binding, the phosphorylation activity is inhibited and the disheveled protein complex becomes disintegrated. As a result, β-catenin accumulates in the cytoplasm and translocates into the nucleus to regulate downstream target gene expression, such as a glutamate-ammonia ligase, which codes for glutamine synthase (GS) and leucine-rich-repeat containing G protein-coupled receptor-5 (LGR5). Thus, the overall net effect is abnormally high expression level of β-catenin within the nucleus and cytoplasm[28]. HCAs with β-catenin mutation are divided into two groups based on the mutation loci in the *CTNNB1* coding for β-catenin: β-catenin exon 3 mutated HCA and β-catenin exon 7/8 mutated HCA[29].

b-HCA exon 3: Approximately 10%-15% of HCAs harbored canonical mutations in *CTNNB1* gene exon 3. The level of β-catenin pathway activation further depends on the specific mutations: Large in-frame deletions, D32-S37 deletions and T41 exon 3 mutations are associated with high level, whereas S45 exon 3 mutations are associated with low level of activation[29]. Comparing with other HCA subtypes, this subtype HCA has more atypical features including mild cytologic atypia, cholestasis, and/or pseudoacinar formation (Figure 1E), which sometimes can be difficult to distinguish from well differentiated HCC. Of note, no specific histologic features can be reliably used to predict a diagnosis of b-HCA. Immunohistochemical stains for β-catenin shows aberrant nuclear and cytoplasmic expression (Figure 1F). While the interpretation of β-catenin expression can be challenging, a better surrogate marker, GS, is also widely used. A recent study has revealed that diffuse homogenous GS staining pattern was strongly associated with exon 3 non-S45 mutation (Figure 1G). Whereas, a diffuse heterogenous GS staining pattern with strong positivity at the tumor periphery indicated exon 3 S45 mutation [30].

Clinically, β-catenin exon 3 mutated HCA is more frequent in men than other subtypes and is more often associated with androgen exposure. In addition, this subtype especially with large in-frame deletions is associated with a high risk of malignant transformation. It is hypothesized that *CTNNB1* exon 3 mutation is the earliest genetic alteration, while additional mutations such as telomere reverse transcriptase (TERT) promoter mutation is involved in the final step of transition from HCA to HCC [27].

b-HCA exon 7/8: A smaller subset of HCAs (5%-10%) harbor non-canonical mutations of *CTNNB1* gene in exon 7 and 8, which is exclusive to mutations in exon 3. In comparison with exon 3 mutations, mutations in exon 7 and 8 result in a weak activation of β-catenin. A focal patchy GS staining pattern in the tumor with strong positivity at the tumor periphery by immunohistochemistry can indicate exon 7/8 mutation[30]. This subtype is associated with a low risk of malignant transformation. A recent study demonstrated that b-HCA exon 7/8 is significantly associated with tumor hemorrhage[31].

β-catenin activated I-HCA

While β-catenin mutations are nearly exclusive to *HNF-1A* mutations, they can be associated with altered JAK/STAT pathway and demonstrate inflammatory features. If the I-HCA shows beta-catenin activation, then a diagnosis of I-HCA with beta-catenin activation can be rendered [β-catenin activated I-HCA (b-IHCA)], which shares the histopathologic features of both b-HCA and I-HCA, and carries malignant transformation potential similarly. It is thus important to continue workup for β-catenin inactivation when a diagnosis of I-HCA is made.

shHCA

ShHCA is a recently recognized subtype of HCA with sonic hedgehog pathway activation[2]. This subtype represents approximately 4% of overall HCAs and was previously classified as unclassified HCA due to the lack of mutations in typical HCA genes. Genetic studies demonstrated that this type of HCA is caused by inhibin beta E subunit (*INHBE*) gene and *GLI1* gene fusion (INHBE-GLI1). The Hedgehog pathway is a complex signal transduction pathway including 4 main components: The ligand Hedgehog, the receptor Patched, the signal transducer Smoothened and the effector transcription factor, Gli[32]. It is not only crucial for embryogenesis of liver, but also plays a role in liver regeneration. Evidence has shown that the Hedgehog pathway is dormant in healthy adult liver, while significantly activated after liver injury. INHBE is a growth factor belonging to the transforming growth factor-beta family. It is highly expressed in the liver and regulates hepatocellular growth and differentiation. As a result, the INHBE-GLI1 fusion leads to uncontrolled activation of sonic hedgehog pathway due to overexpression of transcription factor GLI1.

Clinically, shHCAs are more frequently seen in women and are associated with higher body mass index and/or OCP use. While there are no specific histopathologic features in this HCA subtype, it seems that prostaglandin D synthase and argininosuccinate synthase 1 (ASS1), particularly ASS1 positivity by immunohistochemistry is a hallmark of shHCA[2,33]. Although ASS1 may be expressed in other HCA subtypes with hemorrhage and thought to be a marker of hemorrhage[34], a recent study showed ASS1 expression did not correlate with HCA hemorrhagic complications[35]. Interestingly, higher risk of hemorrhage has been consistently observed both histologically and clinically in shHCA[2, 31]. This serious complication warrants a thorough understanding of pathogenesis of shHCA for better diagnosis and clinical management.

Unclassified HCA

Even though extensive studies have been conducted to explore molecular features of HCAs, approximately 5%-10% remain unclassified. These HCAs lack distinct histopathologic features and any specific molecular abnormality[2].

UNUSUAL SUBTYPES AND CONTROVERSIES

In addition, uncommon HCA subtypes have been well documented, which do not fit well into the current classification.

Pigmented HCA

Pigmented HCAs are a heterogenous group of HCAs with different genetic mutations, which contain pigment deposition of lipofuscin (Figure 1H) as confirmed by electron microscopy[36]. Although H-HCA is the commonest subtype, other subtypes such as b-HCA, I-HCA, b-IHCA, and unclassified HCA also can be seen in pigmented HCAs[36-38]. Pigmented HCAs often show histologic atypia with higher risk malignant transformation. Besides the heavy deposition of lipofuscin in tumor cells, lipofuscin pigment deposition is commonly seen in hepatocytes of the background livers[36]. Although unclear, the underlying biology may be related to dysregulation of autophagy resulting in lipofuscin accumulation, which could contribute to carcinogenesis including the liver[39,40].

Myxoid HCA

Myxoid HCAs are characterized by the deposition of myxoid materials between the hepatic cords within the tumor[41-44]. In addition to loss of L-FABP expression and/or *HNF-1A* mutation as documented in all myxoid HCAs, a recent study identified recurrent mutations in genes within the protein kinase A (PKA) pathway or in genes that regulate the PKA pathway, such as GNAS, CDKN1B (p27) and RNF123, in myxoid HCAs[44]. Myxoid HCAs are often seen in individuals with older age and carry a high risk of malignant transformation[3,44]. It is still controversial whether this is a rare variant of H-HCA with additional mutations or a distinct subtype of HCAs.

Atypical/borderline HCA/hepatocellular neoplasm of uncertain malignant potential

HCA, as described above, has potential of malignant transformation that sometimes can be challenging to distinguish from well-differentiated HCC, especially in biopsy specimens. Various terms, such as atypical HCA, borderline HCA, atypical hepatocellular neoplasm, well-differentiated hepatocellular neoplasm with atypical or borderline features, and hepatocellular neoplasm of uncertain malignant potential (HUMP) have been used for hepatocellular neoplasms that demonstrate features atypical for HCA but insufficient for an unequivocal diagnosis of HCC. So far there are no widely accepted criteria in diagnosing this entity, however, these clinical (male, females > 50 years or < 15 years) and pathologic (focal cytological atypia, small cell change, pseudoacini, focal reticulin network loss, presence of β-catenin activation or *CTNNB1* mutations) features have been consistently used when an atypical/borderline HCA (A-HCA)/HUMP is diagnosed[45-47]. A recent study showed that greater than 60% HCAs would be re-classified as A-HCAs/HUMPs using the above suggested criteria. Furthermore, in this study A-HCA/HUMP does not seem to correlate in patients with or without synchronous or metachronous HCC[45]. The high rate of HCAs placed in the category of A-HCA/HUMP, particularly in resected tumors may cause confusion to clinicians in managing those tumors. Molecular study of *TERT* promoter mutations, a marker of HCC, may be useful to distinguish A-HCA/HUMP from well-differentiated HCC and predict the risk of malignant transformation. Studies have demonstrated that *TERT* promoter mutations have been identified in 17% of A-HCAs/HUMPs compared with 50%–60% of HCC[48]. Further study to refine the widely accepted criteria of diagnosing A-HCA/HUMP and to predict its malignant behavior by combining the clinical, pathological and molecular features is warranted.

I-HCA in cirrhotic livers

HCAs typically arise in the livers without significant fibrosis. The background liver can be histologically normal or have steatosis or steatohepatitis or other genetic and vascular disorders that have been recognized as risk factors for developing HCAs. Thus, a solid mass arising in a cirrhotic liver is generally not considered as HCA. However, rare HCAs with SAA positivity or harboring activating mutations in *IL6ST* or *STAT3* same as I-HCAs have been described in metabolic syndrome and/or alcoholic cirrhosis[49,50]. Of note, some cirrhotic nodules and HCCs can be positive for CRP and SAA, the two important I-HCA markers. Furthermore, activation of IL-6/gp130/STAT3-dependent pathway is involved in the development of liver fibrosis[51]. Therefore, classifying those SAA-positive cirrhotic nodules with *IL6ST* or *STAT3* mutations as I-HCAs is thought to be premature[52]. Additional data are warranted to confirm whether HCA can arise in a background liver with cirrhosis.

MANAGEMENT

Guidelines from both the American College of Gastroenterology[53] and the European Association for Study of the Liver[54] recommend a surgical resection when HCAs are > 5 cm, since they have a higher potential for hemorrhage and malignant transformation. The adoption of a genotype-phenotype classi-

fication is increasingly relevant to clinical decision-making given growing evidence that the risk of complications is likely dependent on HCA subtype and gender. Currently, the treatment of HCA is based on HCA subtype and gender[17,54,55]. Briefly, surgery is recommended for all men with HCAs since they carry a high risk of malignant transformation. For women, after the initial 6 mo lifestyle management including the discontinuation of OCPs and control of body weight, the management of HCAs is based on the size and HCA subtypes. For tumors persistently > 5 cm, or increasing in size after lifestyle change, irrespective of their subtypes, resection or curative treatment is indicated. For tumors < 5 cm of the H-HCA subtype, or those that are either inflammatory or β-catenin negative on biopsy, conservative management is recommended. Of note, surgical resection is recommended for b-HCAs, b-IHCAs and A-HCAs/HUMPs, irrespective of size. Of note, HCAs arising in patients with underlying liver diseases, such as GSD and hepatic vascular disorders seem to have a higher risk of malignant transformation, that should also be considered when manage these HCAs.

CONCLUSION

Recent molecular studies have significantly expanded our knowledge of HCAs. The newly developed phenotype-genotype classification system not only fulfils our curiosity academically, but more importantly, helps improving clinical management through identifying the "high risk" subtype of HCAs. However, further studies are needed, including how to incorporate the uncommon HCA subtypes into the classification system, how to effectively guide the HCA management by using the classification system and identifying the underlying molecular changes of the unclassified HCAs.

FOOTNOTES

Author contributions: Wang X reviewed the literature and drafted the manuscript; Zhang X provided overall intellectual input, reviewed the literature, acquired the histological images, and edited the final version of the manuscript; all authors approved the final version to be published.

Conflict-of-interest statement: The authors have no conflicts of interest to disclose.

Country/Territory of origin: United States

ORCID number: Xi Wang 0000-0001-8916-5132; Xuchen Zhang 0000-0002-1484-4672.

S-Editor: Fan JR
L-Editor: A
P-Editor: Fan JR

REFERENCES

1 **Margolskee E**, Bao F, de Gonzalez AK, Moreira RK, Lagana S, Sireci AN, Sepulveda AR, Remotti H, Lefkowitch JH, Salomao M. Hepatocellular adenoma classification: a comparative evaluation of immunohistochemistry and targeted mutational analysis. *Diagn Pathol* 2016; **11**: 27 [PMID: 26961851 DOI: 10.1186/s13000-016-0475-5]

2 **Nault JC**, Couchy G, Balabaud C, Morcrette G, Caruso S, Blanc JF, Bacq Y, Calderaro J, Paradis V, Ramos J, Scoazec JY, Gnemmi V, Sturm N, Guettier C, Fabre M, Savier E, Chiche L, Labrune P, Selves J, Wendum D, Pilati C, Laurent A, De Muret A, Le Bail B, Rebouissou S, Imbeaud S; GENTHEP Investigators, Bioulac-Sage P, Letouzé E, Zucman-Rossi J. Molecular Classification of Hepatocellular Adenoma Associates With Risk Factors, Bleeding, and Malignant Transformation. *Gastroenterology* 2017; **152**: 880-894.e6 [PMID: 27939373 DOI: 10.1053/j.gastro.2016.11.042]

3 **Putra J**, Ferrell LD, Gouw ASH, Paradis V, Rishi A, Sempoux C, Balabaud C, Thung SN, Bioulac-Sage P. Malignant transformation of liver fatty acid binding protein-deficient hepatocellular adenomas: histopathologic spectrum of a rare phenomenon. *Mod Pathol* 2020; **33**: 665-675 [PMID: 31570768 DOI: 10.1038/s41379-019-0374-x]

4 **Cheng L**, Jain D, Kakar S, Torbenson MS, Wu TT, Yeh MM. Hepatocellular neoplasms arising in genetic metabolic disorders: steatosis is common in both the tumor and background liver. *Hum Pathol* 2021; **108**: 93-99 [PMID: 33245984 DOI: 10.1016/j.humpath.2020.11.012]

5 **Calderaro J**, Labrune P, Morcrette G, Rebouissou S, Franco D, Prévot S, Quaglia A, Bedossa P, Libbrecht L, Terracciano L, Smit GP, Bioulac-Sage P, Zucman-Rossi J. Molecular characterization of hepatocellular adenomas developed in patients

with glycogen storage disease type I. *J Hepatol* 2013; **58**: 350-357 [PMID: 23046672 DOI: 10.1016/j.jhep.2012.09.030]

6 **Sakellariou S**, Al-Hussaini H, Scalori A, Samyn M, Heaton N, Portmann B, Tobal K, Quaglia A. Hepatocellular adenoma in glycogen storage disorder type I: a clinicopathological and molecular study. *Histopathology* 2012; **60**: E58-E65 [PMID: 22372484 DOI: 10.1111/j.1365-2559.2011.04153.x]

7 **Huang WC**, Liau JY, Jeng YM, Liu KL, Lin CN, Song HL, Tsai JH. Hepatocellular adenoma in Taiwan: Distinct ensemble of male predominance, overweight/obesity, and inflammatory subtype. *J Gastroenterol Hepatol* 2020; **35**: 680-688 [PMID: 31698521 DOI: 10.1111/jgh.14903]

8 **Wang H**, Yang C, Rao S, Ji Y, Han J, Sheng R, Zeng M. MR imaging of hepatocellular adenomas on genotype-phenotype classification: A report from China. *Eur J Radiol* 2018; **100**: 135-141 [PMID: 29496071 DOI: 10.1016/j.ejrad.2018.01.023]

9 **Sasaki M**, Yoneda N, Kitamura S, Sato Y, Nakanuma Y. Characterization of hepatocellular adenoma based on the phenotypic classification: The Kanazawa experience. *Hepatol Res* 2011; **41**: 982-988 [PMID: 21883740 DOI: 10.1111/j.1872-034X.2011.00851.x]

10 **Fukusato T**, Soejima Y, Kondo F, Inoue M, Watanabe M, Takahashi Y, Aso T, Uozaki H, Sano K, Sanada Y, Niki T. Preserved or enhanced OATP1B3 expression in hepatocellular adenoma subtypes with nuclear accumulation of β-catenin. *Hepatol Res* 2015; **45**: E32-E42 [PMID: 25418671 DOI: 10.1111/hepr.12453]

11 **Izu A**, Sugitani M, Kinukawa N, Matsumura H, Ogawa M, Moriyama M, Yamazaki S, Takayama T, Hano H, Yao T, Kanda H, Suzuki K, Hayashi S, Ariizumi S, Yamamoto M, Morishita Y, Matsumoto K, Nakamura N, Nakano M. Hepatocellular adenoma, approximately half and predominantly inflammatory subtype, in 38 Japanese patients with several differences in age, gender, and clinical background factors from Western populations. *Hepatol Res* 2021; **51**: 336-342 [PMID: 33381872 DOI: 10.1111/hepr.13613]

12 **Bluteau O**, Jeannot E, Bioulac-Sage P, Marqués JM, Blanc JF, Bui H, Beaudoin JC, Franco D, Balabaud C, Laurent-Puig P, Zucman-Rossi J. Bi-allelic inactivation of TCF1 in hepatic adenomas. *Nat Genet* 2002; **32**: 312-315 [PMID: 12355088 DOI: 10.1038/ng1001]

13 **Cereghini S**, Yaniv M, Cortese R. Hepatocyte dedifferentiation and extinction is accompanied by a block in the synthesis of mRNA coding for the transcription factor HNF1/LFB1. *EMBO J* 1990; **9**: 2257-2263 [PMID: 2357969]

14 **Yamagata K**, Oda N, Kaisaki PJ, Menzel S, Furuta H, Vaxillaire M, Southam L, Cox RD, Lathrop GM, Boriraj VV, Chen X, Cox NJ, Oda Y, Yano H, Le Beau MM, Yamada S, Nishigori H, Takeda J, Fajans SS, Hattersley AT, Iwasaki N, Hansen T, Pedersen O, Polonsky KS, Bell GI. Mutations in the hepatocyte nuclear factor-1alpha gene in maturity-onset diabetes of the young (MODY3). *Nature* 1996; **384**: 455-458 [PMID: 8945470 DOI: 10.1038/384455a0]

15 **Shanbhogue A**, Shah SN, Zaheer A, Prasad SR, Takahashi N, Vikram R. Hepatocellular adenomas: current update on genetics, taxonomy, and management. *J Comput Assist Tomogr* 2011; **35**: 159-166 [PMID: 21412084 DOI: 10.1097/RCT.0b013e31820bad61]

16 **Bacq Y**, Jacquemin E, Balabaud C, Jeannot E, Scotto B, Branchereau S, Laurent C, Bourlier P, Pariente D, de Muret A, Fabre M, Bioulac-Sage P, Zucman-Rossi J. Familial liver adenomatosis associated with hepatocyte nuclear factor 1alpha inactivation. *Gastroenterology* 2003; **125**: 1470-1475 [PMID: 14598263 DOI: 10.1016/j.gastro.2003.07.012]

17 **Védie AL**, Sutter O, Ziol M, Nault JC. Molecular classification of hepatocellular adenomas: impact on clinical practice. *Hepat Oncol* 2018; **5**: HEP04 [PMID: 30302195 DOI: 10.2217/hep-2017-0023]

18 **Hechtman JF**, Abou-Alfa GK, Stadler ZK, Mandelker DL, Roehrl MHA, Zehir A, Vakiani E, Middha S, Klimstra DS, Shia J. Somatic HNF1A mutations in the malignant transformation of hepatocellular adenomas: a retrospective analysis of data from MSK-IMPACT and TCGA. *Hum Pathol* 2019; **83**: 1-6 [PMID: 30121369 DOI: 10.1016/j.humpath.2018.08.004]

19 **Stueck AE**, Qu Z, Huang MA, Campreciós G, Ferrell LD, Thung SN. Hepatocellular Carcinoma Arising in an HNF-1α-Mutated Adenoma in a 23-Year-Old Woman with Maturity-Onset Diabetes of the Young: A Case Report. *Semin Liver Dis* 2015; **35**: 444-449 [PMID: 26676820 DOI: 10.1055/s-0035-1567827]

20 **Grivennikov S**, Karin M. Autocrine IL-6 signaling: a key event in tumorigenesis? *Cancer Cell* 2008; **13**: 7-9 [PMID: 18167335 DOI: 10.1016/j.ccr.2007.12.020]

21 **Rebouissou S**, Amessou M, Couchy G, Poussin K, Imbeaud S, Pilati C, Izard T, Balabaud C, Bioulac-Sage P, Zucman-Rossi J. Frequent in-frame somatic deletions activate gp130 in inflammatory hepatocellular tumours. *Nature* 2009; **457**: 200-204 [PMID: 19020503 DOI: 10.1038/nature07475]

22 **Rosell R**, Bertran-Alamillo J, Molina MA, Taron M. IL-6/gp130/STAT3 signaling axis in cancer and the presence of in-frame gp130 somatic deletions in inflammatory hepatocellular tumors. *Future Oncol* 2009; **5**: 305-308 [PMID: 19374537 DOI: 10.2217/fon.09.3]

23 **Fievet P**, Sevestre H, Boudjelal M, Noel LH, Kemeny F, Franco D, Delamarre J, Capron JP. Systemic AA amyloidosis induced by liver cell adenoma. *Gut* 1990; **31**: 361-363 [PMID: 2157638 DOI: 10.1136/gut.31.3.361]

24 **Calderaro J**, Letouzé E, Bayard Q, Boulai A, Renault V, Deleuze JF, Bestard O, Franco D, Zafrani ES, Nault JC, Moutschen M, Zucman-Rossi J. Systemic AA Amyloidosis Caused by Inflammatory Hepatocellular Adenoma. *N Engl J Med* 2018; **379**: 1178-1180 [PMID: 30231230 DOI: 10.1056/NEJMc1805673]

25 **Clevers H**, Nusse R. Wnt/β-catenin signaling and disease. *Cell* 2012; **149**: 1192-1205 [PMID: 22682243 DOI: 10.1016/j.cell.2012.05.012]

26 **Chen YW**, Jeng YM, Yeh SH, Chen PJ. P53 gene and Wnt signaling in benign neoplasms: beta-catenin mutations in hepatic adenoma but not in focal nodular hyperplasia. *Hepatology* 2002; **36**: 927-935 [PMID: 12297840 DOI: 10.1053/jhep.2002.36126]

27 **Pilati C**, Letouzé E, Nault JC, Imbeaud S, Boulai A, Calderaro J, Poussin K, Franconi A, Couchy G, Morcrette G, Mallet M, Taouji S, Balabaud C, Terris B, Canal F, Paradis V, Scoazec JY, de Muret A, Guettier C, Bioulac-Sage P, Chevet E, Calvo F, Zucman-Rossi J. Genomic profiling of hepatocellular adenomas reveals recurrent FRK-activating mutations and the mechanisms of malignant transformation. *Cancer Cell* 2014; **25**: 428-441 [PMID: 24735922 DOI: 10.1016/j.ccr.2014.03.005]

28 **Jiang Y**, Han QJ, Zhang J. Hepatocellular carcinoma: Mechanisms of progression and immunotherapy. *World J Gastroenterol* 2019; **25**: 3151-3167 [PMID: 31333308 DOI: 10.3748/wjg.v25.i25.3151]

29 **Rebouissou S**, Franconi A, Calderaro J, Letouzé E, Imbeaud S, Pilati C, Nault JC, Couchy G, Laurent A, Balabaud C,

Bioulac-Sage P, Zucman-Rossi J. Genotype-phenotype correlation of CTNNB1 mutations reveals different ß-catenin activity associated with liver tumor progression. *Hepatology* 2016; **64**: 2047-2061 [PMID: 27177928 DOI: 10.1002/hep.28638]

30 **Sempoux C**, Gouw ASH, Dunet V, Paradis V, Balabaud C, Bioulac-Sage P. Predictive Patterns of Glutamine Synthetase Immunohistochemical Staining in CTNNB1-mutated Hepatocellular Adenomas. *Am J Surg Pathol* 2021; **45**: 477-487 [PMID: 33560657 DOI: 10.1097/PAS.0000000000001675]

31 **Julien C**, Le-Bail B, Ouazzani Touhami K, Frulio N, Blanc JF, Adam JP, Laurent C, Balabaud C, Bioulac-Sage P, Chiche L. Hepatocellular Adenoma Risk Factors of Hemorrhage: Size Is Not the Only Concern! *Ann Surg* 2021; **274**: 843-850 [PMID: 34334644 DOI: 10.1097/SLA.0000000000005108]

32 **Machado MV**, Diehl AM. Hedgehog signalling in liver pathophysiology. *J Hepatol* 2018; **68**: 550-562 [PMID: 29107151 DOI: 10.1016/j.jhep.2017.10.017]

33 **Sala M**, Gonzales D, Leste-Lasserre T, Dugot-Senant N, Paradis V, Di Tommaso S, Dupuy JW, Pitard V, Dourthe C, Sciarra A, Sempoux C, Ferrell LD, Clouston AD, Miller G, Yeh MM, Thung S, Gouw ASH, Quaglia A, Han J, Huan J, Fan C, Crawford J, Nakanuma Y, Harada K, le Bail B, Castain C, Frulio N, Trillaud H, Possenti L, Blanc JF, Chiche L, Laurent C, Balabaud C, Bioulac-Sage P, Raymond AA, Saltel F. ASS1 Overexpression: A Hallmark of Sonic Hedgehog Hepatocellular Adenomas; Recommendations for Clinical Practice. *Hepatol Commun* 2020; **4**: 809-824 [PMID: 32490318 DOI: 10.1002/hep4.1514]

34 **Henriet E**, Abou Hammoud A, Dupuy JW, Dartigues B, Ezzoukry Z, Dugot-Senant N, Leste-Lasserre T, Pallares-Lupon N, Nikolski M, Le Bail B, Blanc JF, Balabaud C, Bioulac-Sage P, Raymond AA, Saltel F. Argininosuccinate synthase 1 (ASS1): A marker of unclassified hepatocellular adenoma and high bleeding risk. *Hepatology* 2017; **66**: 2016-2028 [PMID: 28646562 DOI: 10.1002/hep.29336]

35 **Lehrke HD**, Van Treeck BJ, Allende D, Denham LJ, Gonzalez RS, Moreira RK, Mounajjed T, Naini BV, Smoot RL, Zreik RT, Jenkins S, Graham RP. Does Argininosuccinate Synthase 1 (ASS1) Immunohistochemistry Predict an Increased Risk of Hemorrhage for Hepatocellular Adenomas? *Appl Immunohistochem Mol Morphol* 2020; **28**: 464-470 [PMID: 31135443 DOI: 10.1097/PAI.0000000000000774]

36 **Mounajjed T**, Yasir S, Aleff PA, Torbenson MS. Pigmented hepatocellular adenomas have a high risk of atypia and malignancy. *Mod Pathol* 2015; **28**: 1265-1274 [PMID: 26205181 DOI: 10.1038/modpathol.2015.83]

37 **Souza LN**, de Martino RB, Thompson R, Strautnieks S, Heaton ND, Quaglia A. Pigmented well-differentiated hepatocellular neoplasm with beta-catenin mutation. *Hepatobiliary Pancreat Dis Int* 2015; **14**: 660-664 [PMID: 26663015 DOI: 10.1016/s1499-3872(15)60381-2]

38 **Hoshino K**, Harimoto N, Muranushi R, Hagiwara K, Yamanaka T, Ishii N, Tsukagoshi M, Igarashi T, Watanabe A, Kubo N, Araki K, Tomomasa R, Nobusawa S, Aishima S, Nakashima O, Shirabe K. Unclassified hepatocellular adenoma with histological brown pigment deposition and serum PIVKA-II level elevation: a case report. *Surg Case Rep* 2020; **6**: 94 [PMID: 32382834 DOI: 10.1186/s40792-020-00853-6]

39 **Liu L**, Liao JZ, He XX, Li PY. The role of autophagy in hepatocellular carcinoma: friend or foe. *Oncotarget* 2017; **8**: 57707-57722 [PMID: 28915706 DOI: 10.18632/oncotarget.17202]

40 **Marsman DS**, Goldsworthy TL, Popp JA. Contrasting hepatocytic peroxisome proliferation, lipofuscin accumulation and cell turnover for the hepatocarcinogens Wy-14,643 and clofibric acid. *Carcinogenesis* 1992; **13**: 1011-1017 [PMID: 1600604 DOI: 10.1093/carcin/13.6.1011]

41 **Salaria SN**, Graham RP, Aishima S, Mounajjed T, Yeh MM, Torbenson MS. Primary hepatic tumors with myxoid change: morphologically unique hepatic adenomas and hepatocellular carcinomas. *Am J Surg Pathol* 2015; **39**: 318-324 [PMID: 25602798 DOI: 10.1097/PAS.0000000000000382]

42 **Young JT**, Kurup AN, Graham RP, Torbenson MS, Venkatesh SK. Myxoid hepatocellular neoplasms: imaging appearance of a unique mucinous tumor variant. *Abdom Radiol (NY)* 2016; **41**: 2115-2122 [PMID: 27334021 DOI: 10.1007/s00261-016-0812-x]

43 **De Vos N**, Van der Meulen J, Van Der Linden M, Claes K, Candaele AS, Vanlander A, Troisi RI, Van Vlierberghe H, Smeets P, Van Dorpe J, Hoorens A. Myxoid hepatocellular adenoma, a rare variant of hepatocellular adenoma with distinct imaging features: A case report with immunohistochemical and molecular analysis and literature review. *Clin Res Hepatol Gastroenterol* 2021; **45**: 101478 [PMID: 32620388 DOI: 10.1016/j.clinre.2020.06.004]

44 **Rowan DJ**, Yasir S, Chen ZE, Mounajjed T, Erdogan Damgard S, Cummins L, Zhang L, Whitcomb E, Falck V, Simon SM, Singhi AD, Torbenson MS. Morphologic and Molecular Findings in Myxoid Hepatic Adenomas. *Am J Surg Pathol* 2021; **45**: 1098-1107 [PMID: 34232602 DOI: 10.1097/PAS.0000000000001711]

45 **Larson BK**, Guindi M. Applying criteria for hepatocellular neoplasm of uncertain malignant potential reclassifies more than half of hepatocellular adenomas. *Ann Diagn Pathol* 2021; **55**: 151833 [PMID: 34597957 DOI: 10.1016/j.anndiagpath.2021.151833]

46 **Choi WT**, Kakar S. Atypical Hepatocellular Neoplasms: Review of Clinical, Morphologic, Immunohistochemical, Molecular, and Cytogenetic Features. *Adv Anat Pathol* 2018; **25**: 254-262 [PMID: 29649004 DOI: 10.1097/PAP.0000000000000189]

47 **Bedossa P**, Burt AD, Brunt EM, Callea F, Clouston AD, Dienes HP, Goodman ZD, Gouw AS, Hubscher SG, Roberts EA, Roskams T, Terracciano L, Tiniakos DG, Torbenson MS, Wanless IR. Well-differentiated hepatocellular neoplasm of uncertain malignant potential: proposal for a new diagnostic category. *Hum Pathol* 2014; **45**: 658-660 [PMID: 24529331 DOI: 10.1016/j.humpath.2013.09.020]

48 **Cancer Genome Atlas Research Network**. Comprehensive and Integrative Genomic Characterization of Hepatocellular Carcinoma. *Cell* 2017; **169**: 1327-1341.e23 [PMID: 28622513 DOI: 10.1016/j.cell.2017.05.046]

49 **Calderaro J**, Nault JC, Balabaud C, Couchy G, Saint-Paul MC, Azoulay D, Mehdaoui D, Luciani A, Zafrani ES, Bioulac-Sage P, Zucman-Rossi J. Inflammatory hepatocellular adenomas developed in the setting of chronic liver disease and cirrhosis. *Mod Pathol* 2016; **29**: 43-50 [PMID: 26516697 DOI: 10.1038/modpathol.2015.119]

50 **Sasaki M**, Yoneda N, Sawai Y, Imai Y, Kondo F, Fukusato T, Yoshikawa S, Kobayashi S, Sato Y, Matsui O, Nakanuma Y. Clinicopathological characteristics of serum amyloid A-positive hepatocellular neoplasms/nodules arising in alcoholic

cirrhosis. *Histopathology* 2015; **66**: 836-845 [PMID: 25318388 DOI: 10.1111/his.12588]

51 **Xiang DM**, Sun W, Ning BF, Zhou TF, Li XF, Zhong W, Cheng Z, Xia MY, Wang X, Deng X, Wang W, Li HY, Cui XL, Li SC, Wu B, Xie WF, Wang HY, Ding J. The HLF/IL-6/STAT3 feedforward circuit drives hepatic stellate cell activation to promote liver fibrosis. *Gut* 2018; **67**: 1704-1715 [PMID: 28754776 DOI: 10.1136/gutjnl-2016-313392]

52 **Torbenson M**. Hepatic Adenomas: Classification, Controversies, and Consensus. *Surg Pathol Clin* 2018; **11**: 351-366 [PMID: 29751879 DOI: 10.1016/j.path.2018.02.007]

53 **Marrero JA**, Ahn J, Rajender Reddy K; Americal College of Gastroenterology. ACG clinical guideline: the diagnosis and management of focal liver lesions. *Am J Gastroenterol* 2014; **109**: 1328-47; quiz 1348 [PMID: 25135008 DOI: 10.1038/ajg.2014.213]

54 **European Association for the Study of the Liver (EASL)**. EASL Clinical Practice Guidelines on the management of benign liver tumours. *J Hepatol* 2016; **65**: 386-398 [PMID: 27085809 DOI: 10.1016/j.jhep.2016.04.001]

55 **Klompenhouwer AJ**, de Man RA, Dioguardi Burgio M, Vilgrain V, Zucman-Rossi J, Ijzermans JNM. New insights in the management of Hepatocellular Adenoma. *Liver Int* 2020; **40**: 1529-1537 [PMID: 32464711 DOI: 10.1111/liv.14547]

World Journal of Gastroenterology

Submit a Manuscript: https://www.f6publishing.com

World J Gastroenterol 2022 April 14; 28(14): 1394-1404

DOI: 10.3748/wjg.v28.i14.1394

ISSN 1007-9327 (print) ISSN 2219-2840 (online)

OPINION REVIEW

Endoluminal vacuum-assisted therapy to treat rectal anastomotic leakage: A critical analysis

Andrea Vignali, Paola De Nardi

Specialty type: Gastroenterology and hepatology

Provenance and peer review: Invited article; Externally peer reviewed.

Peer-review model: Single blind

Peer-review report's scientific quality classification

Grade A (Excellent): 0
Grade B (Very good): 0
Grade C (Good): C
Grade D (Fair): 0
Grade E (Poor): 0

P-Reviewer: Bencurik V, Czech Republic

Received: May 10, 2021
Peer-review started: May 10, 2021
First decision: June 23, 2021
Revised: July 7, 2021
Accepted: March 4, 2022
Article in press: March 4, 2022
Published online: April 14, 2022

Andrea Vignali, Paola De Nardi, Department of Gastrointestinal Surgery, IRCCS San Raffaele Scientific Institute, Milano 20132, Italy

Andrea Vignali, Department of Surgery, Vita-Salute University, Milano 20132, Italy

Corresponding author: Paola De Nardi, FASCRS, MD, Staff Physician, Surgeon, Department of Gastrointestinal Surgery, IRCCS San Raffaele Scientific Institute, *via* Olgettina 60, Milano 20132, Italy. denardi.paola@hsr.it

Abstract

Endoluminal vacuum-assisted therapy (EVT) has been introduced recently to treat colorectal anastomotic leaks in clinically stable non-peritonitic patients. Its application has been mainly reserved to low colorectal and colo-anal anastomoses. The main advantage of this new procedure is to ensure continuous drainage of the abscess cavity, to promote and to accelerate the formation of granulation tissue resulting in a reduction of the abscess cavity. The reported results are promising allowing a higher preservation of the anastomosis when compared to conventional treatments that include trans-anastomotic tube placement, percutaneous drainage, endoscopic clipping of the anastomotic defect or stent placement. Nevertheless, despite this procedure is gaining acceptance among the surgical community, indications, inclusion criteria and definitions of success are not yet standardized and extremely heterogeneous, making it difficult to reach definitive conclusions and to ascertain which are the real benefits of this new procedure. Moreover, long-term and functional results are poorly reported. The present review is focused on critically analyzing the theoretical benefits and risks of the procedure, short- and long-term functional results and future direction in the application of EVT.

Key Words: Anastomotic leakage; Rectal surgery; Endoluminal vacuum therapy; Endosponge; Complications

Core Tip: Endoluminal vacuum therapy for the treatment of rectal anastomotic leakage, in clinically stable patients, has been reported to be promising, in term of high rate of anastomotic salvage and length of hospital stay. Nevertheless, inclusion criteria, definition of success and complications, are heterogeneous. Moreover, long-term anorectal function is poorly reported. This opinion review aims at clarify, through a critical analysis, all the raised points to stimulate the surgical community to a more standardized approach and algorithm of treatment, and to further study the long-term consequences of this technique.

Citation: Vignali A, De Nardi P. Endoluminal vacuum-assisted therapy to treat rectal anastomotic leakage: A critical analysis. *World J Gastroenterol* 2022; 28(14): 1394-1404
URL: https://www.wjgnet.com/1007-9327/full/v28/i14/1394.htm
DOI: https://dx.doi.org/10.3748/wjg.v28.i14.1394

INTRODUCTION

Anastomotic leak (AL) still represents the most dreaded complication following colorectal resection due to its consequences that could severely affect functional and oncological outcome[1,2]. The gravity of the phenomenon is amplified when rectal cancer only is considered, with reported leakage rate ranging from 3% to 19%[3] and a mortality rate varying from to 1.7% to 16.4%[4]. The choice of the treatment is strictly influenced by the patient general condition and by the dimension of the anastomotic defect[5]. In 2007, the international rectal cancer study group, which includes expert colorectal surgeons and interventional radiologists from several regions in the world, proposed a standardized algorithm for treating ALs. Treatment options varies according to the location of the anastomosis, dimension of the abscess, and patient's clinical conditions[6]. In patients in whom a diffuse peritonitis has occurred, a laparotomy and takedown of the anastomosis is the suggested surgical treatment. More conservative treatments including the salvage of the anastomosis could be an option in patients who remain clinically stable or in presence of a small defect. Different options have been reported including trans-anastomotic tube drainage, percutaneous drainage of the peri-anastomotic abscess in association with fecal diversion, if not fashioned at primary operation, placement of stent or endoscopic clipping of the defect [4,6]. Nevertheless, in presence of a large defect, even in a clinically stable patient, the healing process is extremely long, resulting in a delay of diverting stoma and devastating future function of the neorectum, in particular when an extra-peritoneal anastomosis is taken into consideration. In the early 2000s, an endoluminal vacuum-assisted therapy (EVT) was introduced to treat presacral anastomotic abscesses in stable, non-peritonitic patients[7]. The principle is based on the application of topic negative pressure in order to drain, to clean, to induce the collapse of the cavity, and to prevent the development of chronic sinus. Several case reports papers, reviews, and meta-analyses[7-20] have been published so far with promising results. Nevertheless, the majority of papers are heterogeneous both in term of success rate definition, salvage and long-term results, paucity of comparative studies and thus definitive conclusions are not warranted at present time. In particular, the majority of the studies were focused on success rate, healing time and stoma closure rates, while only few papers dealt with long-term anastomotic function and complications that play a pivotal role when the issue of the efficacy of a novel treatment is taken into consideration. In this narrative review, we aim to critically appraise the literature with regard to the results of the EVT in term of success rate and complications and to evaluate the long-term functional results of this novel treatment.

EVT DEVICE DESCRIPTION

The endoscopic vacuum device consists of an open-cell polyurethane sponge measuring 7 cm × 3 cm, which can be cut down until minimum size, depending on the size of the cavity. The sponge dressing is placed into the abscess cavity using a specially developed introducer system. The end of the evacuation probe is connected to a vacuum wound drainage system *via* a variable drain connector (Figure 1).

In the majority of available studies the evacuation probe was connected to a low vacuum suction bottle (Redyrob® Trans Plus bottle with variable vacuum) (Figure 2), creating a constant negative vacuum pressure of 125-150 mmHg[20]. Higher values were reported by Arezzo *et al*[15] who connected the tube to a vacuum system producing continuum negative pressure up to 700 mmHg when in hospital, and a portable system producing continuum negative pressure up to 200 mmHg when discharged.

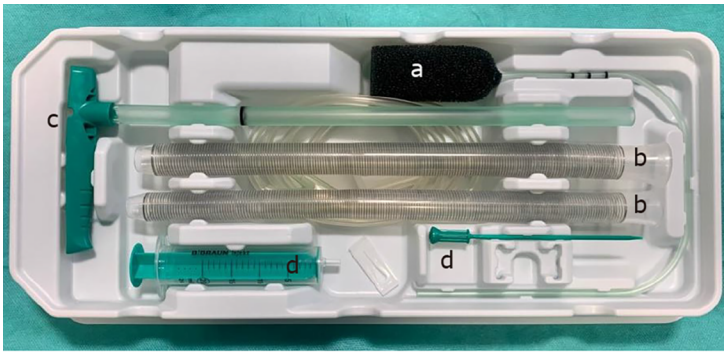

DOI: 10.3748/wjg.v28.i14.1394

Figure 1 Endo-SPONGE® kit including open-pore sponge drain (a), two silicon overtubes (b), the sponge pusher (c), and the irrigation set (d).

DOI: 10.3748/wjg.v28.i14.1394

Figure 2 Redyrob® Trans Plus vacuum bottle: this device is meant to be used connected to the Endo-SPONGE drain.

INCLUSION CRITERIA

The main indication to the use of EVT was represented by the presence of an extraperitoneal leak confirmed by flexible endoscopy ± computed tomography scan (CT) and on clinical and/or laboratory deterioration and drain secretion. Only patients in stable condition with no sign or only localized peritonitis were included. In the majority of patients, a leak following colorectal resection for cancer was considered. Table 1 reports the inclusion criteria of the available studies. The table shows up the lack of standardization in the inclusion criteria, some including both benign and malignant, some purely malignant or pure benign disease, to the different anastomotic heights, surgical approach, including both PME and TME, or in the different indications to EVT therapy, including Hartmann "stump insufficiency" or rectal perforation, as well as leaks following a proctectomy with a J-pouch ileoanal anastomosis. These data lead us to extreme caution in their interpretation, in the effort to make a critical analysis of the reported results. Moreover, a strong clinical heterogeneity has been reported with respect to initial cavity size ranging from 4.9 cm to 10 cm among the reported series[8-22]. Limitations to inclusion with respect to the initial cavity dimension have been reported only in one study[23].

Recently, it has been reported on the intraoperative use of indocyanine green (ICG) fluorescence from the luminal side *via* a trans-anal approach which enables to evaluate the whole circumference of anastomosis in the proximal and distal intestines[24]. Results showed that in patients in whom the vessels were not depicted by the ICG, a higher incidence of AL was observed. This finding is of relevance and it will be probably useful in selecting patients who will beneficiate of EVT *vs* patients in whom a more aggressive operative strategy is recommended. Possible future applications of this technique combined with endoscopy, will be the evaluation in patients with suspected leak, in order to confirm the presence of a leak and to evaluate local perfusion over the entire circumference of anastomosis in real time.

Table 1 Inclusion criteria among different studies

Ref.	# Patients	Anastomosis location	Inclusion criteria	Type of disease (*n*)	Neoadjuvant therapy (%)
Weidenhagen *et al* [7], 2008	29	Lower rectum; Middle rectum	Local peritonitis (20); General peritonitis (9)	Cancer of the rectum (22); Rectosigmoid cancer (3); Benign disease (4)	9 (40.9)
von Bernstorff *et al* [27], 2009	26	Lower rectum; Ileorectal	Local peritonitis	Cancer of the rectum + rectosigmoid	14 (54)
Riss *et al*[30], 2010	20	Lower rectum; Middle rectum	Not reported	Cancer of the rectum	6 (30)
van Koperen *et al* [8], 2009	16	Lower rectum; Ileo-anal	Not reported	Cancer (13); Ulcerative colitis (3)	9 (56)
Nerup *et al*[25], 2013	13	Lower rectum	Local peritonitis	Cancer	6 (46.1)
Mees *et al*[23], 2008	5	Lower rectum	Local peritonitis Abscess (> 3 cm × 3 cm, or < 10 cm × 10 cm)	Cancer of the rectum	No
Arezzo *et al*[15], 2015	14	Lower rectum	Local peritonitis	Cancer of the rectum (7); Other (1)	7 (50)
Strangio *et al*[11], 2015	25	Lower rectum (19); Middle rectum (5); Ileoanal (1)	Local peritonitis Anastomotic leak less than 270	Rectal cancer (18); Endometriosis (1); Left sided colon cancer (4); Diverticulitis (1); Ulcerative colitis (1)	18 (84)
Mussetto *et al*[31], 2017	11	Lower rectum(8); Middle (3)	Local peritonitis	Rectal cancer	5 (45)
Keskin *et al*[13], 2015	15	3 (20)	Local peritonitis	Rectal cancer (12); Other (3)	NR
Milito *et al*[16], 2017	14	Lower rectum	Local peritonitis	Cancer of the rectum	14 (100)
Srinivasamurthy *et al*[14], 2013	8	Lower rectum; Ileoanal	Not reported	Ulcerative colitis (1); Cancer of the rectum (8)	8 (100)
Abdalla *et al*[24], 2020	47	Middle (5); Lower (42)	Local peritonitis + asymptomatic leak	Cancer of the rectum (44); Other (3)	27 (57.4)
Kühn *et al*[28], 2021	281	Lower rectum; Ileoanal; Middle rectum	Local peritonitis extraperitoneal anastomotic leak; Rectal defect	Sigmoid or rectal cancer 183 (65); Other malignancies 50 (18); Diverticular disease 17 (6); Inflammatory bowel disease 12 (4); Perforation 8 (3); Benign/malignant diseases 11 (4)	84 (30)

EVT THERAPY RESULTS

EVT has been identified as a successful method in order to treat AL in clinically stable and non-peritonitic patients with reported figures ranging from 60% to 100% and a rate of diverting stoma closure ranging between 31% to 100%, as emerged by recently published systematic reviews on this issue[20,21]. The rate of success was significantly influenced by early therapy start (within 6 wk from onset) with summarized odds ratio of 3.48 as reported by Mahendran *et al*[18] in their review paper including 266 patients from 16 studies. Nevertheless, data extracted from the same paper underlined that an additional treatment was needed in 12.8% of patients, due to the persistence of the abscess cavity, including fibrin glue application, sutures under general anesthesia, clips placing over the scope or a combination of different techniques. Treatment duration, in current literature, varies between 11 and 244 d. Data are encouraging and promising showing that approximatively 67% of the patients had their anastomosis saved with no need of abdominal surgery[9]. Moreover, in selected cases, the EVT treatment could be performed without the need of a diverting stoma[7]. These percentages favorably compares with results reported by Kühn *et al*[21] in the largest comparative study recently published including 21 patients treated with EVT *vs* 41 historical controls treated with conventional management. The authors reported a significant higher preservation of the intestinal continuity in the EVT *vs* conventional group (86.7% *vs* 37.5%; P = 0.001) and shorter duration of hospital stay. Similarly, Nagell and Holte[22], who compared 4 patients treated with EVT with 10 historical controls, reported favorable results in healing time and length of stay in the EVT group when compared to conventional treatment. Mees *et al*[23] also reported a significantly shorter time for closure and reduced length of stay in the EVT group.

DEFINTION OF SUCCESS

Another point of discussion is represented by a lack of a standardization in the definition of success of the EVT treatment. In particular, data from the two large series (CLEAN study and GRECCAR study) including 39 and 47 patients respectively, defined the success rate as the absence of extravasation of contrast during abdominal CT or the presence of an intact anastomosis on endoscopy[17,25]. Other authors identified the cavity size, associated or not with the presence of granulating healthy tissue, to define the success rate, with figures ranging from 0.5 cm to 3 cm with no consensus among authors[7,9,26-28]. Kühn *et al*[28], in the largest monocentric series recently published, including both AL and rectal stump leak, defined success as granulating closure of the cavity, more than 90% clean and granulating tissue, decreasing wound secretion, reduction of fibrinous tissue, and no interventional or surgical procedure required in the further course.

FACTORS INFLUENCING SUCCESS

Different variables could potentially influence the success rate such as neoadjuvant therapy, presence of diverting stoma during the treatment, and length of follow-up[7-24]. von Bernstorff *et al*[27] first evaluated the effect of radiotherapy on the healing process following EVT therapy. The aforementioned author, and others later, reported a longer duration of therapy, more endoscopies, more sponge exchanges, and longer time to close the abscess cavity in patients who underwent neo-adjuvant treatment[7,15,27,29]. In contrast, others did not find any correlation of neo-adjuvant treatment on healing time and success rate[26,30]. A definitive answer to this topic has come from a subgroup analysis on the radiotherapy subject including eight studies, extrapolated from a meta-analysis, which reported a negative effect of radiotherapy on healing and success rate with a odds ratio of 0.56[20]. Similarly, Shalaby *et al*[9] in a cumulative analysis, encompassing more than 300 patients, identified preoperative radiotherapy (P = 0.018), development of complications (P = 0.002), male sex (P = 0.014) and absence of diverting stoma before treatment, as predictive factors for failure. This latter point deserves some consideration since, intuitively, the presence of a stoma plays a main role in the healing process, nevertheless, to the best of our knowledge, there is no paper or meta-analysis specifically addressing its role and future subgroup analyses will be advisable. In particular, to further clarify this issue, a detailed report of the stoma formation differentiating patients receiving a stoma at primary operation or after the leak was diagnosed will be mandatory, which actually is not fully available from the reported studies as recently stressed by Sharp *et al*[19] in their meta-analysis. Despite stoma reversal was considered by the majority of authors as a marker of success, concern has been expressed by some authors due to the complexity of this variable and to the fact that its closure could be influenced by different factors such as severe co-morbidity, insufficiency of the anal sphincter, chronic pre-sacral sinus, or local recurrence and malignancy[18,20].

Finally, with respect to the duration of follow-up, the latter is of pivotal importance since, as emerged by the multicenter study of Riss *et al*[30], more than 25% of the patients developed a recurrent abscess after a median follow-up of 17 mo. However, data extrapolated from the three recent meta-analyses published in the international literature, show that some of the included studies do not comprise follow-up data, or reported figures ranging within 1 and 4 mo, while less than 50% of the studies report a follow-up time longer than 12 mo, ranging between 14 and 41[18-20].

COMPLICATIONS

The overall EVT-related complication rate among the published series ranges from to 0% to 34.5%, with a mean of 11.1% (96 per cent confidence interval 6.0 to 16.2) as recently reported by Shalaby *et al*[9]. However not all the available studies report on this variable. The complication issue has been recently analyzed and discussed in two systematic reviews on EVT for rectal anastomotic leakage, including 295 and 335 patients respectively[20,21]. According to the review of Nagell and Holte[22], the most common complication is represented by pelvic abscess accounting for 11.5% of cases. Shalaby *et al*[9] reached similar conclusions in another review paper. The majority of abscesses were managed with a conservative treatment or *via* repeated EVT with success rate of 71%-75%, while in case of failure Hartmann's or Miles operation were performed (Table 2). From a more accurate analysis it emerged that in 1% of cases, the abscess occurred early and it should be considered as a treatment failures, while in 10% they were recurrent and thus they should be considered as a relapse after a primary healing has occurred [20]. According to these findings, could we still consider them as a complication or it would be more appropriate to classify them as a treatment failure? The same question spontaneously arises for the fistula issue. According to data extracted from studies reporting complications, overall 13 cases of fistulas were reported, of which 7 in a single series (Table 3). The majority of them were managed with Hartmann's procedure. Of note, the high incidence of fistulas recently reported by Kühn *et al*[28] in their series including 281 patients. In the aforementioned paper, all the fistulas were recto-vaginal in their

Table 2 Reported complications and treatment among studies reporting complications

Ref.	# Patients	Overall complications *n* (%)	Type of complication	Treatment	Ileostomy closure %
Weidenhagen *et al* [7], 2008	29	10 (34.5)	10 anastomotic stenosis; 2 fistulas	Bougienage/balloon dilatation (*n* = 10); Hartmann procedure for persistent fistula (*n* = 1)	88
von Bernstorff *et al* [27], 2009	26	2 (7.7)	2 intra-abdominal fistulas	Hartmann procedures (*n* = 2)	NR
Riss *et al*[30], 2010	23	6 (23)	1 stenosis; 5 recurrent abscess	Dilatation for stenosis (*n* = 1); Hartmann's procedure (*n* = 3); CT-guided drainage (*n* = 1); No further action (*n* = 1)	76.5
van Koperen *et al* [8], 2009	16	4 (25)	2 abscesses; 1 bleeding; 1 severe pain; 1 anastomotic stenosis	Hartmann procedure for recurrent abscess (*n* = 2); 1 stopped treatment for pain; 1 dilatation for stenosis	55.6
Nerup *et al*[25], 2013	13	1 (7.7)	1 anastomotic stenosis	Permanent colostomy (*n* = 1)	91
Mees *et al*[23], 2008	5	1 (20)	1 anastomotic stenosis	Dilatation (*n* = 1)	20
Arezzo *et al*[15], 2015	14	1 (14)	1 peritonitis; 2 poor compliance	Fibrin glue injection	NR
Strangio *et al*[11], 2015	25	3 (12)	2 fistulas (1 ureteric, 1 ileal); 1 recurrent abscess	Surgery (*n* = 3)	84.6
Mussetto *et al*[31], 2017	11	2 (18)	2 anastomotic stricture	1 endoscopic dilatation; 1 stent placement	91
Keskin *et al*[13], 2015	15	3 (20)	2 pelvic sepsis; 1 bleeding	Treatment discontinued	71
Milito *et al*[16], 2017	14	5 (36)	Moderate pain	None	NR
Srinivasamurthy *et al*[14], 2013	8	1 (12)	Iatrogenic injury during sponge placement	End stoma	64
Abdalla *et al*[24], 2020	47	4 (8.5)	1 intractable pelvic pain; 3 anastomotic stenosis	Treatment discontinued (pain); Endoscopic dilatation	NR
Kühn *et al*[28], 2021	281	27 (10)	10 anastomotic stenosis; 7 rectovaginal fistulas; 4 bleeding	Endoscopic dilatation (*n* = 10); Surgery (*n* = 7); Endoscopic haemostasis (*n* = 3); Surgery for intractable beelding (*n* = 1)	62

NR: Not reported.

nature, occurred in the early phase of EVT treatment, and the majority of the patients had initial surgery involving partial resection of the vagina or the uterus, suggesting that EVT might have either prompted or revealed a vaginal leak. In other series, fistulas were classified as abdominal, colovescical, ileal or ureteric, thus suggesting a progression of the leakage process and thus a failure of the treatment more than a complication[7,11,28].

Other complications of endoscopic vacuum treatment include anastomotic stenosis, with an estimated incidence of 4.4% in the cumulative analysis by Popivanov *et al*[20]. Widenhagen reported the occurrence of anastomotic stenosis in 33% of patients in a retrospective analysis of 29 cases. Stenoses were managed with bougienage or balloon dilatation[7]. In the series of Mussetto *et al*[31], including 11 patients, anastomotic stenosis accounted for 16%, while figures ranging from 6% to 11% were reported by others[26,32,33]. Nevertheless, the real incidence of the phenomenon is difficult to establish due to the limited follow-up period in a large percentage of the published studies. Moreover, anastomotic stenosis can also normally occur because of chronic inflammation related to the anastomotic leakage itself not as a direct consequence of EVT treatment, and thus considering purely as an EVT complication is questionable. Under this view, a comparative study with adequate follow-up period with patients who had received conventional treatment should be advisable to reach definitive conclusions.

The occurrence of moderate pain was a common complication in the series by Milito *et al*[16], accounting for 36% (5/14 patients), while intractable pain leading to a discontinuation of the EVT treatment been reported in two cases only[8,16,25]. The phenomenon is rare, 2%, for moderate pain and 0.4% for severe pain as emerged by data derived from the systematic review of Popivanov *et al*[20]. Other reported complications were bleeding from the cavity, which generally occurs in the act of changing the sponge. In the majority of cases, an endoscopic management has been successful, with only one case requiring conventional surgery. Migration of the sponge into the abdominal cavity has been also reported with an estimated overall incidence of 1%[20].

Table 3 Assessment of ano-rectal function after treatment of anastomotic leak with endoluminal vacuum-assisted therapy

Ref.	# Patients	# Patients with functional assessment	Follow-up time	Instrument to evaluate ano-rectal function	Results
Borstlap *et al*[17], 2018	30	15	6, 9, 12 mo	LARS score; COREFO	81% major LARS; 13% minor LARS
Huisman *et al*[36], 2019	20	13	2.6 (0.8-3.5) yr	LARS score	77% major LARS; 23% minor LARS
Katz *et al*[42], 2018	6	4	Not reported	None	Reasonable function
Srinivasamurthy *et al*[14], 2013	8	6	41 (10-45) mo	None	Good or reasonable function
Abdalla *et al*[24], 2020	47	17	14.8 ± 8.9 mo	LARS score	47.1% major LARS; 52.9% no or minor LARS
Rottoli *et al*[12], 2018	8 (pouch)	7	11.6 (6-18) mo	None	No feces or gas incontinence; BM: Daytime: 5 (3-8); Nighttime: 1.7 (1-4)
Weréen *et al*[43], 2020	14	6	5.9 (0.53-13) yr	LARS score	67% major LARS

LARS: Low anterior resection syndrome score; COREFO: Colorectal functional outcome; BM: Bowel movements.

CHRONIC SINUS AND ABSCESS RECURRENCE

One of the long-term sequelae of anastomotic failure is the development of chronic sinus. The true incidence is unknown, however, a large multicenter retrospective study on 1063 patients, reporting an incidence of 6.4% of anastomotic leakage after colorectal anastomosis or restorative proctocolectomy, 36% of whom developed a chronic sinus[34]. The occurrence of chronic sinus involves multiple interventions and a high risk of permanent stoma[35]. A proportion of chronic sinuses may heal spontaneously over time, nevertheless when sinus eventually resolves, it is associated with poor functional outcome[36]. The occurrence of chronic sinuses after AL treatment with EVT is poorly studied. Borstlap *et al*[17] reported a 34% rate after a 6 mo follow-up. Comparing patients who underwent early treatment (before 3 wk) *vs* late treatment (after 3 wk), they observed a higher rate (47%) in the latter group *vs* 21% in the former. Accordingly, the diverting ileostomy could be reversed in 60% of the patients in the late group as compared to 73% in the early group[37]. The authors argued that a late starting could lead to excessive fibrosis of the bowel thus hampering fistula closure.

Time for beginning EVT treatment was evaluated as prognostic factors by other authors with conflicting results. Huisman *et al*[36] reported that 3/20 patients (15%) experienced a chronic sinus, after a median follow-up of 10 mo, and all three received a permanent stoma because of the sinus. They grouped the patients according to start of EVT, before or after 20 d from surgery, but no significant difference between the early and late treatment groups were found.

Another important issue is recurrent leak after the anastomosis is healed. Riss *et al*[30] studied 20 patients treated by rectal resection for rectal cancer and by successful endoscopic EVT of AL (17 patients) or insufficiency of the rectal stump after Hartmann's procedure (3 patients). The patients received annual routine visits and colonoscopy. Five patients (25%) developed a recurrent pelvic abscess, three of them underwent surgery (Hartmann's procedure) and one to CT guided drainage; the treatment for the last patient was still under discussion at the time of publication. Interestingly, the authors did not identify any demographic, therapeutic, or temporal related significant factors that could predict the occurrence of late leak recurrence. The authors concluded that a surveillance of at least 2 years would be recommended for early identification and treatment of this problem. Actually, treatment of chronic sinus is challenging, since its presence precludes the closure of the ileostomy or dictates other surgical treatments such as Hartmann's procedure with closure of the ileostomy, and creation of a permanent colostomy, in the majority of the patients[7,28]. Jagielski *et al*[37] reported a different experience. They treated two patients, with recurrent abscess and anastomotic fistula, once more with EVT. The treatment duration was 15 d with four endosponge changes; they obtained fistula healing without need of major surgery. The authors also underlined that the endoscopic treatment could be interrupted as far as the cavity reached 30 mm with granulation tissue on the wall, without waiting for complete healing; this approach allowed faster endoluminal treatment with no impact on recovery.

In conclusion, despite endoscopic vacuum-assisted treatment allows successful treatment of AL, persistent sinus or recurrent fistula and abscess may occur. A constant follow-up is advisable for early diagnosis and care. Therapy often entails surgical treatment; however, a conservative treatment might also be attempted in selected cases.

FUNCTIONAL RESULTS

After restorative anterior rectal resection, bowel function could be impaired, which adversely affects quality of life. Low anterior resection syndrome (LARS), including incontinence, urgency, diarrhea, frequency and clustering of bowel motions, is being increasingly recognized[38]. The scores are categorized into three groups: 1- no LARS (0-20 points), 2- minor LARS (21-30 points) or 3- major LARS (31-42 points). Although an altered function could be present, in patients with rectal cancer, before any treatment, radiotherapy and surgery represent detrimental factors since they can affect both internal and external anal sphincter function as well as rectal compliance and sensory thresholds[39]. Recently a patient-reported outcome measure on bowel related quality of life showed that 85% of patients had some degree of impairment up to 5 years after surgery. Moreover the degree of quality of life impairment increased as the LARS and Wexner fecal incontinence scores increased, indicating that severity of quality of life impairment reflects severity of bowel dysfunction[40]. Bowel function can improve up to 18 mo after surgery or stoma reversal, however, after that time, further recovery is unlikely. A recent systematic review on 11 studies on rectal cancer patients who underwent low anterior rectal resection and completed a LARS score, with a mean or median follow-up of at least 18 mo, found a prevalence of major LARS of 41%, ranging between 18% to 56%. Radiotherapy and tumor height were the most significant factors for LARS development; AL, diverting ileostomy, and having a stoma for prolonged period, were also associated with increased risk of developing major LARS[41].

Articles on the EVT treatment of rectal AL mainly focus on leak resolution and preservation/restoration of the intestinal continuity. Very few assess long-term functional results, and the majority of them did not employ validated score systems or systematic search of the functional outcomes. Two small series observed "reasonable function", both in 5 patients who underwent stoma closure, after a mean follow-up of 28 and 41 mo respectively[14,42]. However, no score was used to grade bowel function. In another study, of the seven patients who had the ileostomy reversed, none reported incontinence to feces or gas after 11.6 mean follow-up, though it is not described if these symptoms were systematically explored[12].

Intestinal function was evaluated with the LARS questionnaires by few authors. Abdalla *et al*[24] studied 17 patients (out of 26 who had successful EVT treatment) after 14 mo on average following stoma reversal or AL healing, and reported 47.1% with major LARS.

The more complete assessment of postoperative function and related quality of life was performed by Borstlap *et al*[17]. The authors evaluated the LARS score, the colorectal functional outcome (COREFO) scale, the short form 36 (SF-36), the gastrointestinal quality of life index (GIQLI) questionnaire and the EQ-5D-5L at fixed time points. Eighty-one per cent of the patients experienced major LARS, 13% minor-LARS and only 6% did not report any functional problem. Analysis of the COREFO showed that function did not improve from 6 mo to 12 mo postoperatively. On the other hand improvement of the EQ-5D-5 L, GIQLI and SF-36 scores was noted during follow-up.

Only one study compared functional outcome in patients with AL treated with EVT with a group of patients without AL, after rectal resection[37]. A worse LARS score was found in the EVT group (37, range 23-42 points) with respect to the control group (30, range 4-41) points (P = 0.009), with 77% of patients reporting major LARS in the EVT group as compared with 48% in the control group. This study supports the impairment of long-term anorectal function caused by anastomotic dehiscence, possibly due to fibrosis and reduced rectal compliance. However, the question whether EVT treatment could improve functional results in patients with AL remain unanswered.

CONCLUSION

Our narrative review shows, with all the limitations related to the nature of the available studies from international literature, that EVT represents, in clinically stable non-peritonitic patients, a valid alternative to conservative approach (diverting stoma, drain) with relatively low percentage of complications, higher rate of stoma closure, and shorter length of hospital stay. Some questions currently remain unanswered, in particular with respect to quality of life and functional results following EVT treatment. Moreover, it seems to us extremely difficult to identify patients who will beneficiate most of these new treatment, due to strong heterogeneous inclusion criteria, different materials and treatment algorithms.

Objectively a randomized trial would be advisable to assess the real efficacy of a new therapy, nevertheless due to ethical considerations and to the “fragile” status of these patients, may prove difficult to perform. A possible alternative could be represented by a well-designed multicenter control study with standardized inclusion criteria, standardized definition of success, and adequate follow-up period and control group. These latter two points, in our opinion, are of pivotal importance in order to give a definitive answer on the diverting stoma closure issue, which identification as a marker of success, due to its complexity, should be re-considered.

FOOTNOTES

Author contributions: Vignali A conceived the idea for the manuscript; Vignali A and De Nardi P reviewed the literature and drafted the manuscript.

Conflict-of-interest statement: The authors declare no conflict of interests.

Country/Territory of origin: Italy

ORCID number: Andrea Vignali 0000-0002-7887-4088; Paola De Nardi 0000-0002-9337-6765.

S-Editor: Gao CC
L-Editor: A
P-Editor: Gao CC

REFERENCES

1 **Mirnezami A**, Mirnezami R, Chandrakumaran K, Sasapu K, Sagar P, Finan P. Increased local recurrence and reduced survival from colorectal cancer following anastomotic leak: systematic review and meta-analysis. *Ann Surg* 2011; **253**: 890-899 [PMID: 21394013 DOI: 10.1097/SLA.0b013e3182128929]

2 **Branagan G**, Finnis D; Wessex Colorectal Cancer Audit Working Group. Prognosis after anastomotic leakage in colorectal surgery. *Dis Colon Rectum* 2005; **48**: 1021-1026 [PMID: 15789125 DOI: 10.1007/s10350-004-0869-4]

3 **Rullier E**, Laurent C, Garrelon JL, Michel P, Saric J, Parneix M. Risk factors for anastomotic leakage after resection of rectal cancer. *Br J Surg* 1998; **85**: 355-358 [PMID: 9529492 DOI: 10.1046/j.1365-2168.1998.00615.x]

4 **Blumetti J**, Chaudhry V, Cintron JR, Park JJ, Marecik S, Harrison JL, Prasad LM, Abcarian H. Management of anastomotic leak: lessons learned from a large colon and rectal surgery training program. *World J Surg* 2014; **38**: 985-991 [PMID: 24305917 DOI: 10.1007/s00268-013-2340-y]

5 **Bakker IS**, Grossmann I, Henneman D, Havenga K, Wiggers T. Risk factors for anastomotic leakage and leak-related mortality after colonic cancer surgery in a nationwide audit. *Br J Surg* 2014; **101**: 424-32; discussion 432 [PMID: 24536013 DOI: 10.1002/bjs.9395]

6 **Phitayakorn R**, Delaney CP, Reynolds HL, Champagne BJ, Heriot AG, Neary P, Senagore AJ; International Anastomotic Leak Study Group. Standardized algorithms for management of anastomotic leaks and related abdominal and pelvic abscesses after colorectal surgery. *World J Surg* 2008; **32**: 1147-1156 [PMID: 18283511 DOI: 10.1007/s00268-008-9468-1]

7 **Weidenhagen R**, Gruetzner KU, Wiecken T, Spelsberg F, Jauch KW. Endoscopic vacuum-assisted closure of anastomotic leakage following anterior resection of the rectum: a new method. *Surg Endosc* 2008; **22**: 1818-1825 [PMID: 18095024 DOI: 10.1007/s00464-007-9706-x]

8 **van Koperen PJ**, van Berge Henegouwen MI, Rosman C, Bakker CM, Heres P, Slors JF, Bemelman WA. The Dutch multicenter experience of the endo-sponge treatment for anastomotic leakage after colorectal surgery. *Surg Endosc* 2009; **23**: 1379-1383 [PMID: 19037698 DOI: 10.1007/s00464-008-0186-4]

9 **Shalaby M**, Emile S, Elfeki H, Sakr A, Wexner SD, Sileri P. Systematic review of endoluminal vacuum-assisted therapy as salvage treatment for rectal anastomotic leakage. *BJS Open* 2019; **3**: 153-160 [PMID: 30957061 DOI: 10.1002/bjs5.50124]

10 **Kuehn F**, Janisch F, Schwandner F, Alsfasser G, Schiffmann L, Gock M, Klar E. Endoscopic Vacuum Therapy in Colorectal Surgery. *J Gastrointest Surg* 2016; **20**: 328-334 [PMID: 26597270 DOI: 10.1007/s11605-015-3017-7]

11 **Strangio G**, Zullo A, Ferrara EC, Anderloni A, Carlino A, Jovani M, Ciscato C, Hassan C, Repici A. Endo-sponge therapy for management of anastomotic leakages after colorectal surgery: A case series and review of literature. *Dig Liver Dis* 2015; **47**: 465-469 [PMID: 25769505 DOI: 10.1016/j.dld.2015.02.007]

12 **Rottoli M**, Di Simone MP, Vallicelli C, Vittori L, Liguori G, Boschi L, Poggioli G. Endoluminal vacuum-assisted therapy as treatment for anastomotic leak after ileal pouch-anal anastomosis: a pilot study. *Tech Coloproctol* 2018; **22**: 223-229 [PMID: 29502228 DOI: 10.1007/s10151-018-1762-9]

13 **Keskin M**, Bayram O, Bulut T, Balik E. Effectiveness of Endoluminal Vacuum-assisted Closure Therapy (Endosponge) for the Treatment of Pelvic Anastomotic Leakage After Colorectal Surgery. *Surg Laparosc Endosc Percutan Tech* 2015; **25**: 505-508 [PMID: 26551234 DOI: 10.1097/SLE.0000000000000216]

14 **Srinivasamurthy D**, Wood C, Slater R, Garner J. An initial experience using transanal vacuum therapy in pelvic anastomotic leakage. *Tech Coloproctol* 2013; **17**: 275-281 [PMID: 23111399 DOI: 10.1007/s10151-012-0911-9]

15 **Arezzo A**, Verra M, Passera R, Bullano A, Rapetti L, Morino M. Long-term efficacy of endoscopic vacuum therapy for the treatment of colorectal anastomotic leaks. *Dig Liver Dis* 2015; **47**: 342-345 [PMID: 25563812 DOI: 10.1016/j.dld.2014.12.003]

16 **Milito G**, Lisi G, Venditti D, Campanelli M, Aronadio E, Grande S, Cabry F, Grande M. Endoluminal Vacuum Therapy as Treatment for Anastomotic Colorectal Leakage. *Surg Technol Int* 2017; **30**: 125-130 [PMID: 28072899]

17 **Borstlap WAA**, Musters GD, Stassen LPS, van Westreenen HL, Hess D, van Dieren S, Festen S, van der Zaag EJ, Tanis PJ, Bemelman WA. Vacuum-assisted early transanal closure of leaking low colorectal anastomoses: the CLEAN study. *Surg Endosc* 2018; **32**: 315-327 [PMID: 28664443 DOI: 10.1007/s00464-017-5679-6]

18 **Mahendran B**, Rossi B, Coleman M, Smolarek S. The use of Endo-SPONGE® in rectal anastomotic leaks: a systematic review. *Tech Coloproctol* 2020; **24**: 685-694 [PMID: 32377984 DOI: 10.1007/s10151-020-02200-1]

19 **Sharp G**, Steffens D, Koh CE. Evidence of negative pressure therapy for anastomotic leak: a systematic review. *ANZ J Surg* 2021; **91**: 537-545 [PMID: 33480168 DOI: 10.1111/ans.16581]

20 **Popivanov GI**, Mutafchiyski VM, Cirocchi R, Chipeva SD, Vasilev VV, Kjossev KT, Tabakov MS. Endoluminal negative pressure therapy in colorectal anastomotic leaks. *Colorectal Dis* 2020; **22**: 243-253 [PMID: 31274227 DOI: 10.1111/codi.14754]

21 **Kühn F**, Janisch F, Schwandner F, Gock M, Wedermann N, Witte M, Klar E, Schiffmann L. Comparison Between Endoscopic Vacuum Therapy and Conventional Treatment for Leakage After Rectal Resection. *World J Surg* 2020; **44**: 1277-1282 [PMID: 31965274 DOI: 10.1007/s00268-019-05349-5]

22 **Nagell CF**, Holte K. Treatment of anastomotic leakage after rectal resection with transrectal vacuum-assisted drainage (VAC). A method for rapid control of pelvic sepsis and healing. *Int J Colorectal Dis* 2006; **21**: 657-660 [PMID: 16447032 DOI: 10.1007/s00384-005-0083-4]

23 **Mees ST**, Palmes D, Mennigen R, Senninger N, Haier J, Bruewer M. Endo-vacuum assisted closure treatment for rectal anastomotic insufficiency. *Dis Colon Rectum* 2008; **51**: 404-410 [PMID: 18197452 DOI: 10.1007/s10350-007-9141-z]

24 **Abdalla S**, Cotte E, Epin A, Karoui M, Lefevre JH, Berger A, Marchal F, Denost Q, Penna C, Benoist S, Brouquet A; on behalf the French GRECCAR group. Short-term and Long-term Outcome of Endoluminal Vacuum Therapy for Colorectal or Coloanal Anastomotic Leakage: Results of a Nationwide Multicenter Cohort Study From the French GRECCAR Group. *Dis Colon Rectum* 2020; **63**: 371-380 [PMID: 31842165 DOI: 10.1097/DCR.0000000000001560]

25 **Nerup N**, Johansen JL, Alkhefagie GA, Maina P, Jensen KH. Promising results after endoscopic vacuum treatment of anastomotic leakage following resection of rectal cancer with ileostomy. *Dan Med J* 2013; **60**: A4604 [PMID: 23651714]

26 **Glitsch A**, von Bernstorff W, Seltrecht U, Partecke I, Paul H, Heidecke CD. Endoscopic transanal vacuum-assisted rectal drainage (ETVARD): an optimized therapy for major leaks from extraperitoneal rectal anastomoses. *Endoscopy* 2008; **40**: 192-199 [PMID: 18189215 DOI: 10.1055/s-2007-995384]

27 **von Bernstorff W**, Glitsch A, Schreiber A, Partecke LI, Heidecke CD. ETVARD (endoscopic transanal vacuum-assisted rectal drainage) leads to complete but delayed closure of extraperitoneal rectal anastomotic leakage cavities following neoadjuvant radiochemotherapy. *Int J Colorectal Dis* 2009; **24**: 819-825 [PMID: 19241081 DOI: 10.1007/s00384-009-0673-7]

28 **Kühn F**, Wirth U, Zimmermann J, Beger N, Hasenhütl SM, Drefs M, Heiliger C, Burian M, Werner J, Schiergens TS. Endoscopic vacuum therapy for in- and outpatient treatment of colorectal defects. *Surg Endosc* 2021; **35**: 6687-6695 [PMID: 33259019 DOI: 10.1007/s00464-020-08172-5]

29 **Verlaan T**, Bartels SA, van Berge Henegouwen MI, Tanis PJ, Fockens P, Bemelman WA. Early, minimally invasive closure of anastomotic leaks: a new concept. *Colorectal Dis* 2011; **13** Suppl 7: 18-22 [PMID: 22098512 DOI: 10.1111/j.1463-1318.2011.02775.x]

30 **Riss S**, Stift A, Kienbacher C, Dauser B, Haunold I, Kriwanek S, Radlsboek W, Bergmann M. Recurrent abscess after primary successful endo-sponge treatment of anastomotic leakage following rectal surgery. *World J Gastroenterol* 2010; **16**: 4570-4574 [PMID: 20857528 DOI: 10.3748/wjg.v16.i36.4570]

31 **Mussetto A**, Arena R, Buzzi A, Fuccio L, Dari S, Brancaccio ML, Triossi O. Long-term efficacy of vacuum-assisted therapy (Endo-SPONGE®) in large anastomotic leakages following anterior rectal resection. *Ann Gastroenterol* 2017; **30**: 649-653 [PMID: 29118559 DOI: 10.20524/aog.2017.0194]

32 **van Koperen PJ**, van der Zaag ES, Omloo JM, Slors JF, Bemelman WA. The persisting presacral sinus after anastomotic leakage following anterior resection or restorative proctocolectomy. *Colorectal Dis* 2011; **13**: 26-29 [PMID: 20649900 DOI: 10.1111/j.1463-1318.2010.02377.x]

33 **Sloothaak DA**, Buskens CJ, Bemelman WA, Tanis PJ. Treatment of chronic presacral sinus after low anterior resection. *Colorectal Dis* 2013; **15**: 727-732 [PMID: 23216939 DOI: 10.1111/codi.12094]

34 **Borstlap WAA**, Westerduin E, Aukema TS, Bemelman WA, Tanis PJ; Dutch Snapshot Research Group. Anastomotic Leakage and Chronic Presacral Sinus Formation After Low Anterior Resection: Results From a Large Cross-sectional Study. *Ann Surg* 2017; **266**: 870-877 [PMID: 28746154 DOI: 10.1097/SLA.0000000000002429]

35 **Sturiale A**, Martellucci J, Zurli L, Vaccaro C, Brusciano L, Limongelli P, Docimo L, Valeri A. Long-term functional follow-up after anterior rectal resection for cancer. *Int J Colorectal Dis* 2017; **32**: 83-88 [PMID: 27695976 DOI: 10.1007/s00384-016-2659-6]

36 **Huisman JF**, van Westreenen HL, van der Wouden EJ, Vasen HFA, de Graaf EJR, Doornebosch PG, Tang TJ, Schot I, Brohet RM, de Vos Tot Nederveen Cappel WH, Vermaas M. Effectiveness of endosponge therapy for the management of presacral abscesses following rectal surgery. *Tech Coloproctol* 2019; **23**: 551-557 [PMID: 31338710 DOI: 10.1007/s10151-019-02007-9]

37 **Jagielski M**, Piątkowski J, Jarczyk G, Jackowski M. Transrectal endoscopic drainage with vacuum-assisted therapy in patients with anastomotic leaks following rectal cancer resection. *Surg Endosc* 2022; **36**: 959-967 [PMID: 33650007 DOI: 10.1007/s00464-021-08359-4]

38 **Emmertsen KJ**, Laurberg S. Low anterior resection syndrome score: development and validation of a symptom-based scoring system for bowel dysfunction after low anterior resection for rectal cancer. *Ann Surg* 2012; **255**: 922-928 [PMID: 22504191 DOI: 10.1097/SLA.0b013e31824f1c21]

39 **De Nardi P**, Testoni SG, Corsetti M, Andreoletti H, Giollo P, Passaretti S, Testoni PA. Manometric evaluation of anorectal function in patients treated with neoadjuvant chemoradiotherapy and total mesorectal excision for rectal cancer. *Dig Liver Dis* 2017; **49**: 91-97 [PMID: 27720700 DOI: 10.1016/j.dld.2016.09.005]

40 **Croese AD**, Lonie JM, Trollope AF, Vangaveti VN, Ho YH. A meta-analysis of the prevalence of Low Anterior Resection Syndrome and systematic review of risk factors. *Int J Surg* 2018; **56**: 234-241 [PMID: 29936195 DOI:

10.1016/j.ijsu.2018.06.031]

41 **Emmertsen KJ**, Laurberg S; Rectal Cancer Function Study Group. Impact of bowel dysfunction on quality of life after sphincter-preserving resection for rectal cancer. *Br J Surg* 2013; **100**: 1377-1387 [PMID: 23939851 DOI: 10.1002/bjs.9223]

42 **Katz E**, White I, Shpitz B, Ghinea R, Avital S. Different approaches for Endo-SPONGE® insertion to treat rectal anastomotic leaks. *Tech Coloproctol* 2018; **22**: 231-233 [PMID: 29480425 DOI: 10.1007/s10151-018-1764-7]

43 **Weréen A**, Dahlberg M, Heinius G, Pieniowski E, Saraste D, Eklöv K, Nygren J, Pekkari K, Everhov ÅH. Long-Term Results after Anastomotic Leakage following Rectal Cancer Surgery: A Comparison of Treatment with Endo-Sponge and Transanal Irrigation. *Dig Surg* 2020; **37**: 456-462 [PMID: 32829324 DOI: 10.1159/000508935]

World Journal of Gastroenterology

Submit a Manuscript: https://www.f6publishing.com

World J Gastroenterol 2022 April 14; 28(14): 1405-1429

DOI: 10.3748/wjg.v28.i14.1405

ISSN 1007-9327 (print) ISSN 2219-2840 (online)

REVIEW

Viral hepatitis: Past, present, and future

Matthew August Odenwald, Sonali Paul

Specialty type: Gastroenterology and hepatology

Provenance and peer review: Invited article; Externally peer reviewed.

Peer-review model: Single blind

Peer-review report's scientific quality classification

Grade A (Excellent): A
Grade B (Very good): B
Grade C (Good): 0
Grade D (Fair): 0
Grade E (Poor): 0

P-Reviewer: Cao HC, China; Wang CR, Taiwan

Received: June 27, 2021
Peer-review started: June 27, 2021
First decision: July 14, 2021
Revised: March 4, 2022
Article in press: March 4, 2022
Published online: April 14, 2022

Matthew August Odenwald, Sonali Paul, Department of Medicine, Section of Gastroenterology, Hepatology, and Nutrition, Center for Liver Diseases, University of Chicago, Chicago, IL 60637, United States

Corresponding author: Sonali Paul, MD, MS, Assistant Professor, Department of Medicine, Section of Gastroenterology, Hepatology, and Nutrition, Center for Liver Diseases, University of Chicago, 5841 S. Maryland Ave. Rm J-517, MC7120, Chicago, IL 60637, United States. spaul@medicine.bsd.uchicago.edu

Abstract

Each hepatitis virus—Hepatitis A, B, C, D, E, and G—poses a distinct scenario to the patient and clinician alike. Since the discovery of each virus, extensive knowledge regarding epidemiology, virologic properties, and the natural clinical and immunologic history of acute and chronic infections has been generated. Basic discoveries about host immunologic responses to acute and chronic viral infections, combined with virologic data, has led to vaccines to prevent Hepatitis A, B, and E and highly efficacious antivirals for Hepatitis B and C. These therapeutic breakthroughs are transforming the fields of hepatology, transplant medicine in general, and public and global health. Most notably, there is even an ambitious global effort to eliminate chronic viral hepatitis within the next decade. While attainable, there are many barriers to this goal that are being actively investigated in basic and clinical labs on the local, national, and international scales. Herein, we discuss pertinent clinical information and recent organizational guidelines for each of the individual hepatitis viruses while also synthesizing this information with the latest research to focus on exciting future directions for each virus.

Key Words: Viral Hepatitis; Hepatitis A; Hepatitis B; Hepatitis C; Hepatitis D; Hepatitis E; Hepatitis G

Core Tip: Viral hepatitis encompasses a wide array of clinical diseases—from asymptomatic and self-limited to chronic liver disease to acute liver failure. Extensive historical research has resulted in vaccines to prevent Hepatitis A, B, and E and highly efficacious antivirals for Hepatitis B and C, and these therapeutic breakthroughs are transforming the fields of hepatology, transplant medicine in general, and public and global health. While these breakthroughs are highly promising, there are many barriers to eventually elimination of chronic viral hepatitis. These barriers are being actively investigated, and we discuss ongoing research in the historical context of viral hepatitis research.

Citation: Odenwald MA, Paul S. Viral hepatitis: Past, present, and future. *World J Gastroenterol* 2022; 28(14): 1405-1429
URL: https://www.wjgnet.com/1007-9327/full/v28/i14/1405.htm
DOI: https://dx.doi.org/10.3748/wjg.v28.i14.1405

INTRODUCTION

In this review of viral hepatitis infections, we discuss the pertinent clinical information and recent organizational guidelines for each of the individual hepatitis viruses while also synthesizing this information with the latest research to focus on exciting future directions for each virus.

HEPATITIS A

Hepatitis A

The Hepatitis A Virus (HAV) is a single stranded, non-enveloped ribonucleic acid (RNA) molecule. HAV is a member of the Picornaviridae family and the *Hepatovirus* genus that is transmitted primarily through a fecal-oral route *via* person-to-person contact or ingestion of contaminated food or water[1,2]. Globally, serologic evidence of prior infection is quite high, but prevalence has high geographic and demographic variability[3]. Acute HAV infection characteristically causes a self-limited illness. However, cases of fulminant liver failure have been reported with advanced age being the greatest risk factor for symptomatic disease[4]. Treatment is primarily preventative with vaccination prior to possible exposures, and both vaccination and HAV immunoglobulin to confer both active and passive immunity after exposure[5].

Epidemiology

An estimated 1.4 million cases of hepatitis A occur globally each year[6]. Estimates of disease prevalence vary regionally and are highly dependent on socioeconomic status and access to clean water. In developing countries with poor sanitation, there is nearly 100% seropositivity for HAV immunoglobulin G (IgG). In these countries, it is presumed that most children are infected at very early ages, when minimal symptoms develop and therefore clinical presentation of HAV infection is very rare[3]. In wealthy nations, including the United States, HAV IgG seropositivity rates are much lower[7]. Seropositivity increased with age and was lower among United States-born residents compared to immigrants [8]. Since the introduction of the HAV vaccine in 1996, new cases of HAV have declined by over 90% in the United States despite relatively low rates of HAV vaccination[9]. International travel to endemic areas or person-to-person contact with an infected person are the main risk factors for HAV.

Natural History of Infection and Clinical Course

The primary route of HAV infection is the fecal-oral route from contaminated food and water. This is evidenced by detection of HAV RNA in stool during the incubation period and for up to 4-5 mo after the onset of symptoms[10]. In small children, the infection is largely asymptomatic with fewer than 10% of children < 6 years old developing jaundice with HAV infection, and the only evidence of infection is serologic presence of anti-HAV antibodies. In older children and adults, HAV infection follows a characteristic pattern[5]. Infection is followed by an average 28-d incubation period where the virus actively replicates in hepatocytes. HAV itself is not thought to be directly hepatotoxic as there is no laboratory or clinical evidence of liver damage during the incubation period, and HAV can be propagated *in vitro* without any evidence of cytopathology[11]. After the incubation period, however, there is immune-mediated damage to the hepatocytes that results in non-specific symptoms of fever, malaise, fatigue, and loss of appetite followed by jaundice in approximately 70% of patients[12]. The majority of patients (approximately 60%) have a full recovery within 2 mo. Of the patients who do not fully recover within 2 mo, some develop prolonged cholestasis and others have relapsing disease with 2 or more bouts within a 6-10 wk period driven primarily by viral shedding within the stool and

reinfection. The overwhelming majority (nearly 100%) of these patients fully recover within 6 mo of disease onset, and there is no increase in mortality with any of these disease presentations[9].

Fulminant HAV is associated with low HAV RNA titers and high bilirubin levels, likely related to a robust host immune response reducing HAV viral load and resulting in significant hepatocyte damage [4]. Acute liver failure occurs in less than 1% of cases of HAV infection[4]. It is more common among patients with advance age (> 75 years old), underlying liver disease, or chronic kidney disease. The incidence of fulminant HAV in the United States has decreased dramatically from 1990 to 2005[13]. Data from the United States Acute Liver Failure Study Group (ALFSG) showed that the proportion of ALFSG cases due to HAV was low (29 of 925 patients, 3.1%), and of these patients, 55% recovered, 31% received transplant, and 14% died[13]. In 2006, the ALFSG study group designed a prognostic model based on clinical features at presentation [alanine transaminase (ALT) < 2600 IU/L, creatinine > 2.0 mg/dL, intubation, and vasopressors] that predict the likelihood of death and need for transplant with high accuracy[13]. Subsequently, a refined scoring system was derived from a cohort of 294 Korean patients with fulminant hepatitis A to predict the likelihood of death or need for liver transplant[14]. This scoring system takes multiple objective values (age, international normalized ratio, bilirubin, ammonia, creatinine, and hemoglobin) at the time of HAV-associated ALF into account, and compared to the ALFSG study group, this new model better predicted the likelihood of death or need for transplantation in both the Korean discovery cohort and international validation cohorts[14]. These scoring systems are useful in determining the level of care that a patient with acute HAV infection should receive. Nevertheless, there is an unusually high rate of recovery for HAV-related acute liver failure, and given this, auxiliary transplantation and artificial liver devices have been proposed as therapeutic bridges to native liver recovery and regeneration[15]. However, these are not commonly used in clinical practice.

Prevention, Diagnosis, and Treatment

There are currently 4 inactivated HAV vaccines available, all with similar efficacy and side effect profiles. However, widespread vaccination programs are not currently universal[16]. In fact, the World Health Organization (WHO) recommends that large-scale efforts should not be undertaken in highly endemic areas where nearly 100% of children contract HAV early in life and are asymptomatic[16]. On the other hand, in regions with lower rates of disease and higher acute infection rates later in life (when it is more likely to be symptomatic and result in increased healthcare costs) the WHO recommends either targeted vaccination of high-risk groups (in very low prevalence areas) or universal vaccination programs (in intermediate endemic areas)[16]. Given recent outbreaks and increases in the number of cases reported in the United States each year, the United States Centers for Disease Control (CDC) now recommends vaccination of all children > 1 year old in addition to the traditional at-risk groups[17].

Clinically, HAV infection is indistinguishable from other forms of acute viral hepatitis and diagnosis relies on serologies. An acute infection is defined by the presence of anti-HAV-immunoglobulin M (IgM) antibodies, which are present within a couple of weeks of exposure and at the onset of symptoms. Anti-HAV-IgG antibodies are also present at the onset of symptoms. While the anti-HAV-IgM titer decreases over time and is generally undetectable after 1 year of exposure, the IgG antibody is present for life and confers lifelong immunity. HAV RNA can be found in various bodily secretions and excretions, which can determine infectivity but levels are not currently used clinically.

Treatment for HAV is largely supportive with spontaneous recovery in the overwhelming majority of patients. While there is no anti-viral treatment for HAV, some studies have investigated post-exposure prophylaxis with both active immunity with HAV vaccination and conferring passive immunity through HAV immunoglobulin infusions. The most comprehensive study came in 2007 when Victor *et al* [18] performed a randomized control trial comparing HAV vaccination to HAV immunoglobulin in 1090 household contacts aged (2 to 40) of HAV patients. Both groups had low rates of hepatitis A, and the study's noninferiority criteria were met[18]. As such, the United States CDC recommends either HAV vaccine or HAV immunoglobulin for post-exposure prophylaxis within 2 wk of exposure[19]; however, the HAV vaccine does have an advantage over immunoglobulin, including active immunity and longer duration of action.

In summary, while effective HAV vaccines are available, the available data support the current practice of targeted vaccination in areas where patients who are more prone to more severe symptoms from HAV are more likely to be exposed rather than vaccinating all individuals in endemic areas. For those who are exposed, it will be interesting to see if further improvements can be made to already good predictive models to determine the clinical trajectory of patients with acute, fulminant HAV to determine whether liver transplant will be needed. Finally, we will be eagerly watching for further data on currently investigational liver support devices, which hold promise to provide supportive care through fulminant HAV and obviate the need for liver transplantation.

HEPATITIS B

Hepatitis B infection is caused by the Hepatitis B Virus (HBV), a deoxyribonucleic acid (DNA) virus belonging to the Hepadnaviridae family and the Orthohepadnavirus genus[20]. It is transmitted *via*

exposure to infected blood or bodily fluids, most commonly from intravenous drug use, sexual contact, or vertical transmission from mother to child[20]. The burden of HBV is declining in the developed world due to vaccination[21], but HBV prevalence is still quite high in endemic areas primarily due to vertical transmission between mother and child and early life exposures[22]. The age of HBV infection is the principal factor determining the course of disease; the overwhelming majority of perinatally infected patients develop chronic hepatitis B whereas the majority of adults who are infected readily clear the virus[23]. Antiviral medications can stop viral replication and subsequent liver damage. While no available treatments can clear HBV infection, there are exciting investigational agents that may provide therapeutic benefit in the future[24]. Moreover, there is a broad global health effort to eliminate HBV *via* a combination of aggressive vaccination, diagnostic, and treatment programs[25].

Epidemiology

In 2006, it was estimated that 2 billion people had been infected with HBV and that 360 million people were living with chronic hepatitis B worldwide. There is geographic variation in hepatitis B prevalence. Endemic regions like Southeast Asia, Sub-Saharan Africa, and parts of South America have prevalence rates greater than 8% compared to 2% in non-endemic areas, including the majority of North America [26]. Routes of transmission differ between endemic and non-endemic areas and determine the course of HBV infection. In endemic areas, vertical transmission between mother and child and horizontal transmission among young children are the most common routes of HBV infection, but in non-endemic areas, intravenous drug use and sexual transmission in adults are the predominant modes of infection [27]. Exposure to HBV within the first six months of life confers a nearly 90% risk of developing a chronic infection due to immunologic tolerance, which decreases to approximately 50% risk if exposed before the age of 6[27]. Acutely infected adults with intact immune systems, however, spontaneously clear HBV infection in a remarkable 95% of cases. Taken together, these data indicate that the majority of chronic HBV in the world is within endemic areas. In line with this, recent studies have shown that more than 90% of cases of chronic HBV in the United States are in immigrants from endemic areas[28]. While the incidence of acute HBV is declining in the United States due to vaccination, blood product screening, and perinatal screening, the incidence of chronic HBV is increasing due to changing immigration patterns and increasing immigration from endemic areas[28]. A recent meta-analysis assessed the prevalence of hepatitis B surface antigen (HBsAg) in hemodialysis patients in the Middle East found a 4.4% positivity rate, which is decreasing over time[29].

Natural History of Infection and Clinical Course

Hepatitis B is a small DNA virus with 10 known genotypes. The enveloped hepatitis B virus is recognized *via* the HBsAg and enters the cell *via* receptor-mediated endocytosis[20]. Upon entry into the cell, HBV is uncoated and undergoes repair of the single-stranded DNA to either integrate into the host genome or form covalently closed circular DNA (cccDNA), both of which serve as templates for transcription and translation[20]. The cccDNA persists in hepatocytes even after other signs of declining virus activity, including HBsAg loss, and is the main cause of HBV persistence despite antiviral treatment. The 3.2kb genome has 4 open reading frames that encode for the (1) Core gene (important for viral packaging and production of e-antigen (eAg); (2) surface gene (encodes surface proteins); (3) X-gene (which maintains expression of cccDNA); and (4) polymerase gene (encodes multiple proteins important for DNA replication, including a reverse transcriptase and polymerase)[24]. Once transcribed from cccDNA, immature RNA molecules are packaged into nucleocapsids that can either be recycled to the nucleus or further packaged and trafficked to budding sites in a HBsAg-dependent manner.

HBV is not directly cytotoxic but instead the clinical course of HBV is determined by the intensity of the immune response[30,31]. Acute HBV infection is a subclinical illness in approximately 2/3 of the cases while the other 1/3 develop symptomatic hepatitis and 1% develop acute liver failure with survival rates of only 20%. Regardless of the initial clinical manifestation, with an intact immune system, the majority of HBV is rapidly cleared, and understanding the modes of natural clearance are important for developing new treatment strategies.

The innate immune system is classically thought of as the initial line of defense against pathogens: It uses non-specific defenses including proinflammatory cytokines, interferons, and natural killer (NK) cells to keep the virus under reasonable control[31]. The adaptive immune system is fine-tuned to more specifically fight the pathogen. In hepatitis B, however, the line between these two arms of the immune system are blurred. In acute HBV infection, the innate immune system has a relatively weak release of the prototypical cytokines and weak induction of interferon and interferon-stimulated genes[32]. In fact, HBV has been shown to actively suppress interferon release and inhibit with interferon functions[33]. In one study of 21 patients with acute HBV infection, these patients had an increase in the anti-inflammatory cytokine interleukin (IL)-10 while there was no change in interferon levels from baseline[34]. Increases in IL-10 were accompanied by a decrease in NK cell activation and attenuated HBV-specific $CD4^+$ and $CD8^+$ T-cell responses[34]. Moreover, there is a decrease in NK cell function in clearing the initial infection. However, non-traditional roles for NK cells, including regulating the adaptive T-cell response, and the non-classical NK T-cells (NKT cells) can clear HBV without the help of $CD4^+$ or $CD8^+$ T-cells. These defects in the innate immune response to HBV infection are likely the culprit for the relatively low rate of symptomatic hepatitis in the acute phase and have led to HBV being considered a

"stealth virus"[35].

Adaptive immunity plays a crucial role in clearance of acute HBV infection. Classically, CD8$^+$ T-cells selectively eliminate virus-infected cells by recognizing short viral epitopes on infected cells, and HBV-specific CD8$^+$ T-cells are an integral component of natural HBV control[31]. This was suggested by a study of 23 patients with acute, self-limited HBV[36]. Interestingly, the highest frequency of HBV-specific CD8$^+$ T-cells correlated with the clinically acute phase of infection[36]. Causation was more convincingly demonstrated with an experimental chimpanzee model with selective depletion of either CD4$^+$ T-cells or CD8$^+$ T-cells prior to acute HBV infection[37]. Chimpanzees with depletion of CD8$^+$ T-cells had delayed viral clearance, and viral clearance did not occur until the reappearance of CD8$^+$ T-cells[37]. Repopulation of CD8$^+$ T-cells and viral clearance also coincided with interferon expression. Depletion of CD4$^+$ T-cells did not have any appreciable effect on viral clearance compared to controls [37].

Patients who are unable to mount this initial immune response fail to clear the virus and progress to chronic HBV. Immunologic hallmarks of chronic hepatitis B infection include numerical and functional deficiency of HBV-specific CD8$^+$ T-cells as well as decreased B-cell function[38-40]. Given their crucial role in clearing acute HBV infection, augmenting the number and function of CD8$^+$ T-cells is of great interest in therapeutic development.

Chronic hepatitis B has four distinct phases: the immune tolerant phase, immune active phase, inactive carrier phase, and reactivation. In the immune tolerant phase, there are high HBV viral loads without lab evidence of liver inflammation. Immune active phase is evidenced by lower viral loads with elevated transaminases. If untreated, patients in the immune active phase have a very high chance (approximately 20%) of progressing to chronic liver disease with cirrhosis and hepatocellular carcinoma (HCC) in approximately 25%-30% of patients with the presence of active viral replication and necroinflammatory liver disease being predictors of disease progression. In the absence of antiviral therapy, patients with HBsAg-positive cirrhosis have an 84% 5-year survival when compensated but a bleak 14% 5-year survival rate after the initial decompensation event[41]. While current antivirals can help improve liver histology, decrease hepatic decompensation, and improve long-term survival, achieving a functional cure (*i.e.*, HBsAg loss) is an uncommon event with unknown predictive factors[42,43]. In the inactive carrier state, patients have normalization of transaminases, undetectable HBV virus levels, and in some patients, fibrosis improvement[44]. However, these patients can reactivate either due to loss of immune control whether spontaneously or induced by immunosuppressive therapies[45]. Despite available treatments, the burden of chronic HBV is still very high and is estimated to account for 700000 deaths each year from decompensated cirrhosis and HCC[46].

Prevention, Diagnosis, and Treatment

As discussed above, vertical and horizontal transmission in childhood are responsible for the majority of chronic HBV infections. HBV can be prevented with administration of an effective HBV vaccine, which has been available since the 1980s. This was demonstrated with mass childhood vaccination programs in the endemic area of Taiwan that started in 1984[47]. Seroprevalence of HBV was tested 10 years after the introduction of mass vaccination programs and showed marked declines in the childhood presence of HBsAg (from 9.8% to 1.3%) and rising rates of immunity as marked by hepatitis B surface antibody (HBsAb) (from 23% to 79%)[47]. Importantly, a subsequent study showed that universal childhood HBV vaccination was also linked to reduced incidence of childhood HCC and HCC-associated mortality[48]. A similar aggressive vaccination program for Native Alaskans was conducted in newborns and young-children and was linked to elimination of acute, symptomatic HBV infections and HCC[49]. Additionally, despite a growing population, the number of children identified with HBsAg fell from 697 to 2 after initiation of this vaccination program[49]. The effect of vaccination has also been studied in infants at highest risk of vertical transmission—those born to HBeAg positive, HBsAg carrier mothers[50]. In combination with hepatitis B immunoglobulin (HBIG), neonatal vaccination for HBV was extremely efficacious. Persistent HBsAg was found in only 6% of the infants receiving both vaccination and HBIG compared to 88% of those receiving placebo[50]. With this marked efficacy in mind, the World Health Organization has recommended universal birth dose vaccination against HBV. However, despite the demonstrated efficacy more than 35 years ago, this has still not occurred in the majority of endemic countries. Expanding HBV vaccination is therefore the focus of many ongoing global health efforts to eliminate HBV[25].

Available antiviral medications against HBV are interferon-based regimens or nucleotide/nucleoside reverse transcriptase inhibitors (NRTIs), including entecavir, tenofovir, lamivudine, adefovir, and telbivudine[42]. Interferon-based therapies have both immune stimulating and antiviral effects and have higher potency than NRTIs; however, it is used much less frequently because of its adverse effects. The first generation NRTIs (lamivudine, adefovir, and telbivudine) suffered from low-barriers to viral resistance and have been replaced by second generation NRTIs (entecavir and tenofovir) in clinical practice[42]. When used alone, NRTIs can achieve HBV DNA negativity in 70%-85% of patients and e-antigen seroconversion in 20%-25% of patients after 1 year of treatment with even further benefit after 3 years[51]. However, even patients with seroconversion have high rates of HBV relapse upon withdrawal of medication (approximately 30% by 5 years), which has led to prolonged therapy even after e-antigen seroconversion to decrease the risk of reactivation[52]. While many patients are treated

with lifelong NRTIs with minimal side effects, even the simplest treatment algorithms require physician visits, lab draws, and HCC screening every 6 mo. This is costly and inconvenient, which can lead to non-adherence to care for a variety of reasons, especially in many resource-limited endemic countries. Indeed, worldwide, many patients that guidelines would suggest to be on NRTI therapy do not actually receive treatment[25]. Multiple approaches to remove this barrier to receiving care are being investigated and include determining if and when therapy can safely be withdrawn and combining NRTI therapy with other therapies to improve durable, off-treatment responses. In retrospective analyses of patients who have discontinued NRTI, it appears safe to stop therapy if patients do not have HBeAg, have very low levels of HBsAg, and have minimal fibrosis. However, flares can still occur and HCC screening is still required, and therefore close follow up is still warranted, suggesting that this approach may not be feasible on a global scale[53]. NRTI withdrawal appears to be more feasible in non-cirrhotic, HBeAg negative patients with low HBV DNA titers if NRTI is combined with interferon therapy; however, this too was done in a highly regimented clinical trial setting with relatively short-term follow up[54]. At the moment, this approach is only experimental, and real-world experience with longer term data to determine HBV relapse rates and HCC occurrence has yet to be seen.

In sum, the most promising method for prevention of primary HBV infections is early, universal vaccination, and we are hopeful that aggressive vaccination campaigns already underway will substantially reduce the burden of HBV in the coming decades. Fortunately, highly active antivirals are capable of controlling the virus and reducing the burden of advanced liver disease from HBV; however, there remains no cure for HBV. In the next section, we discuss many exciting experimental approaches aimed at curing HBV *via* multiple different mechanisms.

Future Therapies Under Investigation

The high rate of HBV relapse after NRTI withdrawal reflects the persistence of cccDNA and integrated HBV DNA. Multiple drugs in development target components of the HBV lifecycle as well as the immune response to HBV infection. Future approaches to achieving a cure for hepatitis B will likely exploit all three pathways. That is, (1) Use of existing potent antivirals in combination with; (2) novel, direct acting antivirals; and (3) immunomodulators that enhance clearance of cells that harbor HBV DNA[24]. Novel direct-acting antiviral therapies under investigation include gene editing and suppression *via* clustered regularly interspaced short palindromic repeats (CRISPR-CAS-9) technology and gene suppression *via* silencing RNA (siRNA) and antisense oligonucleotides (ASOs)[24].

The CRISPR approach has been used with guide RNAs designed to target cccDNA components (core, polymerase, or X open reading frames)[55]. This study demonstrated the ability of CRISPR technology to directly cleave cccDNA and significantly reduce both HBV RNA titers and HBsAg concentrations *in vitro* with both transient transfection and sustained expression. In a mouse model of HBV infection, simultaneous delivery of HBV and guide RNA was also shown to result in decreased HBV viral titers and HBsAg levels[55]. Given that both integrated HBV DNA and cccDNA can contribute to HBV persistence, another group successfully used CRISPR to excise a full-length integrated DNA fragment while simultaneously disrupting cccDNA in a cell line that stably expressed HBV DNA[56]. All measures of HBV chronicity were undetectable for 12 mo after this therapy[56]. While this is promising, CRISPR-Cas9 targets the integrated DNA by inducing double stranded DNA breaks within the host genome, which has the potential to have detrimental off-target effects including host genome rearrangement. More targeted approaches with CRISPR-Cas-9 "nickases" to mediate only single strand nicks and base-editing to introduce mutations have also been employed[57]. A more targeted approach with CRISPR-Cas9-mediated base-editing to introduce mutations has also been attempted *in vitro*. The introduction of either missense or nonsense mutations resulted in inactivation of both integrated and cccDNA with associated reductions in HBV viral titers, HBsAg, and reductions in both surface and polymerase proteins[57]. Moreover, CRISPR-Cas-9-mediated knockout of HBsAg in an HCC cell line reduced proliferation *in vitro* and the ability of these cells to form tumors in mice, suggesting therapeutic potential for HBV-associated HCC as well[58]. Together, these data suggest that CRISPR-Cas9 technology has the potential to promote a true HBV cure.

Alternative approaches that directly target the hepatitis B virus include targeting the RNA products of both cccDNA and integrated HBV transcription *via* specific siRNA or ASOs. Both siRNA and ASOs are short RNA sequences that are complementary to the viral mRNA and therefore generate double stranded RNA that is targeted for degradation *via* dicer or RNase-H, respectively[59]. With multiple siRNA or ASOs administered in each dose, this approach has the potential to target multiple mRNA products simultaneously[59].

One siRNA molecule, ARC-520, is designed to target the open reading frame of HBV X but overlaps with all cccDNA transcripts and therefore has the potential to target all cccDNA transcripts for degradation. ARC-520 was shown to be safe in healthy volunteers[60], and in a phase II study, ARC-520 resulted in significant reduction in HBsAg production in patients that were NRTI-naïve or had HBeAg [61]. The difference in response to RNA interference (RNAi) between HBeAg+ and HBeAg- patients was investigated using chimpanzees and determined to be due to the presence of integrated DNA in addition to cccDNA[61]. In follow up studies of ARC-520 activity against chronic HBV in NRTI-experienced patients, four monthly doses of the siRNA resulted in dose-dependent reduction in HBsAg concentrations regardless of HBeAg status. The reductions were only modest (approximately 0.4 log

reduction from baseline), possibly resulting from the presence of integrated DNA that is not targeted by this particular siRNA[62]. Additional siRNAs are currently under development and preliminary data from one siRNA that uses a N-Acetylgalactosamine ligand to target the siRNA to the liver suggests improved HBsAg reduction (approximately 1.75 log reduction) with dosing every 4 wk[63].

The potential of ASO in treating chronic HBV was recently demonstrated in preclinical *in vitro* and *in vivo* mouse models[64]. A target second-generation ASO that was complementary to reference sequences in HBV genotypes A-H was identified as an effective ASO using *in vitro* models. This ASO reduced HBV DNA expression, replication, viremia, and HBsAg and HBeAg production in multiple HBV genotypes[64]. Importantly, the ASO used had no interference with the anti-viral activity of NRTIs when given simultaneously, suggesting that combination with existing therapy is feasible[64]. An HBV-targeted ASO was recently shown to be safe in escalating doses in healthy human subjects[65], and subsequently shown to have excellent antiviral activity in patients with chronic hepatitis B with reduction in HBsAg regardless of concurrent therapy after 29 d[66]. In addition to the longer-term follow up that is underway, it will be important to determine if there can be a further decline in measures of HBV infection if combined with additional ASOs or if sequence variations between individuals can be accounted for with use of multiple ASOs simultaneously[67]. Moreover, further modifications to ASOs are currently in development to improve delivery to hepatocytes[67].

Immunomodulation aims to rectify the relative functional and numerical deficiency of $CD8^+$ T-cells that is present in patients with chronic hepatitis B infections. This can be achieved either by augmenting the function of existing $CD8^+$ T-cells, creating a new source of $CD8^+$ T-cells, or immune mobilization[24,31,68,69]. One hallmark of $CD8^+$ T-cells in chronic HBV is overexpression of inhibitory molecules, among them programmed cell death protein-1 (PD-1). This has led to the hypothesis that PD-1 inhibition may increase recruitment of T-cells to help clear chronic hepatitis B. Efficacy of a single dose of the PD-1 inhibitor nivolumab was tested in patients who already had viral suppression and were HBeAg negative and demonstrated a modest further reduction in HBsAg production at 12 wk (average reduction was 0.3 log reduction) with only 1 patient achieving loss of HBsAg production in the study period[70]. While these data demonstrate some additive benefit of immunotherapy with currently available antivirals, it is notable that this study specifically excluded patients with advanced fibrosis leaving open the possibility that patients with cirrhosis may not be ideal candidates for this approach. Moreover, given extremely low number of HBV-specific $CD8^+$ T-cells in chronic hepatitis B, it is unlikely that recruitment of autologous T-cells alone will provide a durable cure.

This realization has led to efforts to generate new functional pools of effector T-cells by engineering large numbers of HBV-specific T-cells using chimeric antigen receptor (CAR) and T-cell receptor (TCR) technology. This approach has been successfully employed in mouse models of chronic HBV. One group isolated $CD8^+$ T-cells from mice and engineered them to express CAR that bind to HBV envelope proteins prior to transferring them into HBV transgenic mice[71]. These adoptively transferred HBV-specific T-cells engrafted, expanded, honed to the liver, reduced HBV replication, and caused only transient liver damage[71]. Similar success was achieved in HBV-infected humanized mice using human T-cells that were engineered to express an HBV-specific T-cell receptor[72]. Further, simultaneous treatment with the TCR-engineered cells and the HBV entry inhibitor myrcludex led to long-term control of HBV infection with limited liver injury[72].

A third approach has recently been described and acts as a hybrid between the above described methods of recruitment autologous T-cells and engineering larger pools of T-cells[69]. This approach uses immune-mobilizing monoclonal T-cell receptors against the virus (immTAV), which are soluble bispecific proteins that bind to both the TCR, which specifically recognizes the HBV viral peptide-human leukocyte antigen complex, and to CD3, which recognizes non-specific T-cells. Using an HBV envelope protein-specific immTAV, one group demonstrated that this approach can redirect polyclonal T-cells to destroy hepatocytes that are either infected with HBV or have integrated HBV DNA[69].

Despite the success of these immunotherapy approaches in cell culture and animal models, these have not yet been translated into human trials. Investigators are likely to proceed with caution given that these cytotoxic T-cells are targeting infected tissue within an essential organ and any exaggerated or off-target effect has the potential to induce irreparable liver damage and prove fatal. One possible way to minimize this chance is to minimize the portion of hepatocytes harboring HBV infection with existing antivirals. It is therefore likely that this approach will be most useful after existing or novel antiviral medications deplete significant portions of HBV DNA. Enhancing $CD8^+$ T-cell function will therefore result in destruction of the few remaining infected hepatocytes to allow for a cure.

HEPATITIS C

Hepatitis C infection is caused by the Hepatitis C virus (HCV), a single stranded RNA virus. HCV is a member of the Flaviviridae family and *Hepacivirus* genus that is transmitted primarily through direct bloodstream inoculation[73,74]. HCV successfully evades the immune system to cause a chronic hepatitis in the majority of cases, which often leads to advanced fibrosis and cirrhosis if untreated[73]. While there are no effective vaccines for HCV prevention, with the advent of direct-acting antivirals

(DAA) for the treatment of HCV, HCV can be easily cured in the overwhelming majority of cases. This has now led to ambitious global efforts to eliminate HCV[75]. Additionally, DAAs have led to the exciting possibility of transplanting organs from HCV-positive donors, which has the potential to greatly expand the organ donor pool and increase the availability of scarce resources.

Epidemiology

HCV is estimated to effect approximately 3% of the population worldwide, which translates into nearly 200 million cases worldwide. There is a wide geographic variation in disease prevalence with rates of approximately 1.5% in the United States to nearly 15% in Egypt and up to 50% in certain age groups in Egypt[74,76,77]. The unusually high rate of HCV positivity in Egypt has been traced to campaigns to administer parenteral anti-schistosomiasis treatment with inadequate needle sterilization in the 1950-1980s and subsequent spread with blood transfusions and medical and dental procedures[78]. More recently, a large effort to screen and treat Egyptians for HCV was undertaken and successfully screened 49.6 million people for HCV and showed a lower seroprevalence than previous estimates after large treatment efforts, now at 4.61%[79]. Remarkably, after DAA treatment 98.8% of patients with a known treatment outcome had achieved sustained viral response, suggesting an even lower disease prevalence in Egypt now[79].

The estimates of prevalence in the United States are based on the National Health and Nutrition Examination Survey (NHANES) database, which surveys a representative sample of 5000 adults annually; however, it is notable that this survey does not include homeless or incarcerated individuals, where HCV prevalence is estimated to be significantly higher, with weighted prevalence of 23.1% in the incarcerated population and 32.1% in the homeless[80]. The estimates in the United States are therefore likely to underestimate the true disease burden with one study calculating that NHANES underestimates the number of HCV infections in the US by approximately 1 million[80]. Moreover, in recent years, the opioid epidemic has led to increasing rates of HCV cases and a shifting demographic, now with rates of infection rising fastest in young people while rates in the baby boomer generation fall due to screening efforts and treatment[81].

Hepatitis C transmission occurs with parenteral exposures, most commonly from intravenous drug use and contaminated blood transfusions with a notable exception in Egypt, as discussed above. A case control series from 1997 surveyed both 2316 HCV-positive and 2316 HCV-negative blood donors from the United States for lifestyle and socioeconomic factors to elucidate possible mechanisms of HCV exposure and transmission and to assist with finding populations that may benefit from closer screening [82]. They found that the strongest risk factors for HCV-positive individuals were intravenous (IV) drug use (OR 49.6), blood transfusion, (OR 10.9), and sex with an IV drug user (OR 6.3)[82]. Since 1992, the United States has enacted universal HCV screening of donated blood, which has dramatically reduced the risk of HCV transmission *via* blood transfusions[83]. HCV can survive on an unsterilized needle for many days depending on the temperature and inoculum[84]. There are an estimated 11-21 million IV drug users worldwide[85], with rates rising in many countries, most notably with the opioid epidemic in the United States[81]. This has already led to rates of HCV infection rising sharply since 2010[86] and is likely to continue to do so until the opioid epidemic is under better control.

Natural History of Infection and Clinical Course

Nearly all cases of acute hepatitis C are asymptomatic, and fulminant hepatitis C has been reported only in case reports[87]. The lack of symptoms in early infections has precluded identification of patients for large studies to fully characterize this phase of the disease. Studies of transfusion-associated infections have been able to identify some patients with acute, transfusion-related HCV infections[88]. These studies have identified that HCV RNA rises rapidly after infection followed by a rise in ALT in 1-3 mo, indicating hepatocyte damage. The latent period (defined as the period prior to ALT elevations) is inversely proportional to the donor HCV viral load and is shorter in patients with clinically overt disease[88]. Importantly, these studies have helped identify host factors that assist with HCV clearance and those that make hosts susceptible to developing chronic disease. More recently, the factors that mediate this rapid immune response are being used in the hopes of developing a hepatitis C vaccine.

One such study analyzed women who were infected with HCV when prophylactically treated with Rh_o (D) immunoglobulin and found that spontaneous viral clearance is strongly associated with genetic polymorphisms near the interleukin 28B (*IL28B*) gene, which encodes interferon (IFN)-λ-3[89]. Moreover, women who did not have the favorable *IL28B* polymorphism had increased chance of viral clearance if they developed jaundice in the acute phase of infection[89]. This finding has been confirmed in additional studies, and one study followed 632 patients with acute HCV and found that 25% of patients cleared acute HCV with clearance being more likely if patients were female, had the favorable *IL28B* genotype (C/C), or were infected with HCV genotype 1[90]. This large study suggests that HCV becomes a chronic infection in approximately 75% of acutely infected individuals, which is in line with widely quoted estimates of 50%-85% chronicity rates[90].

Chronic HCV is also largely asymptomatic prior to the development of advanced fibrosis, and cirrhosis is estimated to occur in 16% of patients within 20 years of HCV infection[91]. Factors that contribute to chronic HCV progressing to cirrhosis include advanced age, concurrent HBV, ongoing alcohol use, immunocompromised states, and risk factors for non-alcoholic steatosis including obesity

and insulin resistance[92]. Once a patient has cirrhosis, they are at higher risk for hepatic decompensation and the development of HCC. While HCV-associated HCC can develop in non-cirrhotic livers[93], the risk is much higher in patients with cirrhosis and additional risk is conferred by many of the factors associated with progression to cirrhosis in the first place, including age, alcohol use, and male sex[92].

Diagnosis and Treatment

As briefly discussed above, Hepatitis C is almost universally a chronic, asymptomatic disease until it ultimately causes advanced fibrosis and cirrhosis, when it has symptoms that overlap with a variety of advanced liver diseases. As such, diagnosis relies entirely on serologies. Given the frequency of HCV in the general population, the asymptomatic nature of early HCV, and the ease of treatment (discussed more below), it is recommended that all adults in the United States be screened for HCV at least once and that high-risk individuals be screened more frequently[94]. In most patients, diagnostic testing consists of a hepatitis C antibody test with a reflex to HCV RNA viral load if the antibody test is positive. Alternatively, in high-risk patients, some physicians may choose to send an HCV RNA level regardless of antibody result. If any test yields a positive result, further characterization of liver function—including a fibrosis assessment—will help direct further treatment and screening procedures.

The introduction of direct acting antivirals (DAA) has revolutionized the care of patients with HCV [95-98]. With pan-genotypic treatments now available, insurance coverage, falling costs of available agents, and widely available algorithms for simplifying treatment of patients with HCV (*e.g.*, https://www.hcvguidelines.org), treatment of HCV is readily available to the majority of patients in developed countries such as the United States. Treatment goals have therefore shifted towards reaching as many patients as possible and have led to the aggressive goals of eliminating HCV globally[25,75]. As briefly discussed above, an impressive voluntary global health effort in Egypt was able to screen 49.6 million citizens, which identified over 1 million untreated HCV RNA patients and led to successful treatment in 98.8% of patients with long-term follow up[79]. Remarkably, the cost of identifying and curing each case of Hepatitis C was $130.62 in contrast to the cost of chronic medical care and disability in patients with untreated HCV, which is estimated to be in excess of $100000 per patient[79]. This study highlights the feasibility of large-scale screening and treatment efforts in resource-limited settings. With the recent changes to the United States Preventative Services Task Force recommendations to expand screening from all adults born between 1945 and 1965 to all adults between age 18 to 79[94], it will be interesting to see if similar massive-scale screening and treatment can be successfully completed in the United States.

Despite this impressive effort, several factors remain barriers to global elimination of HCV[25]. Notably, in the Egyptian effort, 20.6% of the population did not participate in voluntary screening with men and young people (< 25 years old) having the lowest participation rates[79]. While these efforts will likely be successful in patients without ongoing risk factors for HCV infection, IV drug users who are at particularly high risk for HCV infection are among the patients least likely to seek out regular medical care and to adhere to a course of antiviral therapy. With this in mind, multiple studies in the United States have experimented with modified treatment protocols to decrease the burden of treatment and improve access to care. For example, the MINMON study (Clinical Trial Number: NCT03512210) aims to test whether a minimal monitoring approach is safe and effective when using the pan-genotypic agent sofosbuvir/velpatasvir in treatment-naïve HCV patients. To do this, they require no pretreatment genotyping, provided patients all of the necessary medication up front, and do not schedule any clinic or lab visits while patients were undergoing treatment but did remotely contact patients at 4 and 22 wk. Promising results for this study were presented at the American Association for the Study of Liver Diseases Liver Meeting in 2020 and showed that sustained virologic response (SVR) was near 95%[99]. If adopted on a broader scale, this approach has the potential to further simplify HCV treatment and remove some of the treatment burden. Additional studies have attempted to identify the most effective way to treat patients who inject drugs in the multi-center HERO study[100]. In this study, patients are randomly assigned to receive HCV treatment in one of two ways: (1) Directly observed treatment where patients take medication in front of a staff member; or (2) With the help of patient navigators who attempt to help patients overcome barriers to taking medication. Final results are forthcoming but will hopefully help provide guidance for HCV treatment in this difficult to treat population.

Prevention Efforts

Expansion of HCV prevention strategies are also vital to elimination efforts. Given HCV is most commonly transmitted from unsafe injection practices, especially among injection drug users, programs to increase safe injections are critically important to efforts to prevent HCV transmission and are gaining acceptance[101].

As with other hepatitis viruses, primary prevention of HCV with vaccination would be extremely beneficial. Moreover, reinfection is a significant risk for patients who have successfully completed DAA therapy but continue to have risk factors for HCV infection. Development of an effective HCV vaccine has proven difficult due to the extreme genetic diversity of HCV—7 known genotypes with over 80 known subtypes—and an error-prone viral polymerase that confers HCV with rapid mutability[102]. Hope for a vaccine comes from the observation that approximately 25% of acutely infected individuals

spontaneously clear HCV[103]; however, re-infection can occur despite the appearance of broadly neutralizing antibodies in patients who clear their initial HCV infection. Nevertheless, a study that followed 22 active IV drug users who had previously cleared HCV demonstrated that upon reinfection with HCV, virus clearance occurs 83% of the time[104]. Moreover, reinfection is characterized by reduced maximal viral titers, shorter duration of viremia, and augmented T-cell responses[104]. Benefit of humoral immunity in preventing HCV infection has been demonstrated in chimpanzees treated with immunoglobulin derived from a human patient in the acute phase of post-transfusion hepatitis C infection[105]. In this case, human immunoglobulin directed against the hypervariable region 1 of the envelope 2 protein prevented infection with homologous HCV strains[105]. In another study, HCV neutralizing antibodies derived from a patient infected with HCV genotype 1a protected chimpanzees from infection with genotype 1a and 6a but failed to protect them from infection with HCV genotypes 4a or 5a[106]. Pools of broadly neutralizing antibodies can prevent infections with multiple HCV genotypes in humanized mice[107,108], and together with the extreme genetic variability of HCV, this suggests that in order for a vaccine to be widely effective, it should be able to induce generation of broadly neutralizing HCV antibodies. Multiple experimental vaccines have used this approach; however, to date, the majority of recipients of these vaccines—either chimpanzee or human—have failed to produce sufficient titers of broadly neutralizing antibodies in most subjects[102,109]. Nevertheless, new culture strategies may enable use of whole inactivated HCV rather than only envelope protein epitopes to allow for additional vaccine epitopes and promote generation of more broadly neutralizing antibodies.

At the moment, prevention of HCV infection is dependent upon behavioral risk reduction (*e.g.*, clean needle programs), which is unfortunately being overpowered by a surge of new cases with the ongoing opioid epidemic in the United States. While a vaccine would be ideal, there are various obstacles to overcome, as detailed above. Fortunately, widespread screening and treatment programs are underway on a global scale, and we are hopeful that these will achieve the goal of elimination of chronic hepatitis.

Hepatitis C and Organ Transplantation

DAAs have also made it possible to transplant solid organs from hepatitis C positive donors, which has the potential to greatly expand the donor pool, shorten time on the waitlist, and improve mortality in patients in need of organ transplantation[110]. Solid organ transplantation can transmit HCV to the organ recipient and was a major concern in the pre-DAA era. This was demonstrated by a retrospective review of all cadaveric donors to the New England Organ Bank between 1986 and 1990, and of 716 organ donors, 1.8% (13) were determined to be HCV positive[111]. Of these 13 HCV positive donors, their organs—19 kidneys, 6 hearts, and 4 livers—were transplanted into 29 different recipients, and 14 of the recipients (48%) developed HCV, which caused chronic liver disease in the majority of infected patients[111]. This study raised serious concerns about whether HCV-positive organs should be offered for transplant given the lack of effective treatment for HCV at the time of the study. Subsequent studies from the pre-DAA era showed that transplant patients tend to have worse outcomes if they receive HCV positive organs. HCV-positive liver transplant recipients have decreased patient and graft survival, primarily attributed to HCV recurrence after transplantation[112]. Additionally, in immunosuppressed patients, including recipients of both liver transplants and other solid organs, HCV positivity is associated with exceptionally high HCV replication and the development of fibrosing cholestatic hepatitis C, an aggressive presentation of HCV that has a high risk of liver failure and mortality[113]. For heart transplant patients who receive hearts from HCV-positive donors, there is significantly increased mortality at 1, 5, and 10 years that may be attributable to both the development of liver disease and accelerated and more severe coronary artery vasculopathy[114,115]. In kidney transplant recipients, HCV, whether from the donor organ or already present in the recipient, is associated with both increased mortality and graft failure[116,117].

Prior to the introduction of highly effective treatment for HCV, these findings understandably led to reservations about using organs from HCV-positive donors and historically resulted in discarding high-quality organs from HCV-positive donors at much higher rates. Compared to high-quality HCV-negative livers, high-quality HCV-positive livers were 3 times more likely to be discarded from 2005 to 2010, a rate which has decreased after DAAs but is still approximately 1.7 times more likely[118]. Similarly, high-quality kidneys from HCV-positive donors were 2.6 times more likely to be discarded between 1995 and 2009, and a more recent analysis (from 2005-2014) concluded that only 37% of kidneys from HCV-positive donors were transplanted (*i.e.* 63% were discarded) despite most being of good quality and many available recipients[119,120]. Hearts from HCV-positive donors are also significantly less likely to be used. In 2015, hearts from HCV-naïve donors were used approximately 30% of the time compared to 0.7% and 1.4% for hearts from HCV-viremic and non-viremic HCV-Ab positive donors, respectively[121].

If attitudes towards transplanting solid organs from HCV-positive patients do not change, there is likely to be an even greater mismatch between available high-quality donor organs and patients on transplant waitlists, as the opioid epidemic is resulting in an alarming rise in overdose deaths[122]. A recent National Registry Study characterized organ donations form deceased donors who died of drug overdose (ODD, overdose death donor) between 2000 and 2017 found that ODDs have risen significantly in that time from 1.1% of donors in 2000 to 13.4% of donors in 2017[122]. Compared to non-

ODDs, ODDs were more likely to be young, white, have little comorbidity, and have HCV infection (18.3% were HCV-positive)[122]. Despite the higher rates of HCV positivity, the authors found similar 5-year patient and graft survival rates between non-ODDs and ODDs[122].

Along with the organ shortage and rise in availability of high-quality organs from HCV-positive donors, the success of DAAs in curing HCV has led to several clinical trials to determine the outcomes of transplanting organs from HCV-positive donors. In general, these trials have been an overwhelming success. Two separate studies of 10 HCV-mismatched kidney transplant recipients (Donor positive, recipient negative) showed 100% success rate of achieving SVR in recipients[123,124]. Moreover, this mismatched strategy reduced wait times, and recipients had excellent graft function at 6 mo post-transplant[124]. Similar results have been shown in both mismatched heart and lung transplant patients. An early study performed HCV-mismatched heart transplants on 13 patients, and 9 of the 13 developed HCV viremia shortly after transplant. Eight of these patients completed DAA treatment and demonstrated SVR (the 9th patient died of a pulmonary embolus)[125]. Another study enrolled 44 patients awaiting heart or lung transplant and performed 36 HCV-mismatched lung transplants and 9 heart transplants regardless of HCV genotype[126]. Ninety-five percent of patients had detectable HCV RNA immediately after transplant, and 100% achieved SVR with the pan-genotypic DAA sofosbuvir–velpatasvir[126]. Importantly, at 6 mo, the patients continued to have excellent graft function and no detectable HCV RNA[126].

Finally, a larger, more recent study that performed 80 HCV-mismatched heart transplants and followed patients for 1 year showed comparable 1-year survival and similarly, low rates of allograft rejection between patients who received HCV-positive organs and those who received HCV-negative organs[127]. However, there was significantly more primary graft dysfunction and a trend towards increased early coronary allograft vasculopathy in patients who received organs from HCV-positive donors, although this was not statistically significant[127]. A large retrospective registry study of patients who underwent a single organ liver transplant from 2008 through 218 demonstrated similar 2-year graft survival rates (approximately 88%) among all combinations of donor-recipient HCV RNA status[128]. Importantly, graft survival from HCV-positive donors has improved in the DAA era, with 3-year graft survival now approximately 88% regardless of recipient HCV status[128]. Moreover, this study demonstrated a trend towards increasing use of organs from HCV-positive donors for HCV-negative recipients from 7 in 2008 to 107 in 2018, highlighting increased acceptance of this novel strategy of expanding the pool of available organs[128].

Together, these data are extremely promising in demonstrating early, post-transplant HCV cure and similar graft and recipient survival in short- and mid-term follow-up. They also provide justification for the use of organs from HCV-positive donors, regardless of recipient HCV status. This strategy is gaining popularity: The Scientific Registry Transplant Recipients indicates increasing numbers of mismatched transplants, and there are now similar utilization rates of available HCV-positive and HCV-negative donor hearts[128]. Nevertheless, there still exists some skepticism of this strategy, as a recent survey of 99 transplant nephrology providers demonstrated that fewer than half support offering HCV-positive kidneys as part of routine care outside of a research setting[129]. These attitudes will likely shift to usher in more widespread use of this practice if long-term outcomes are as promising as the available clinical trial results.

HEPATITIS D

Hepatitis D infection is caused by the Hepatitis D virus (HDV), a single stranded, enveloped RNA molecule. HDV is the smallest virus known to infect humans, and it is often classified as a subvirus given that the HDV lifecycle is entirely dependent on HBV[130,131]. Transmission occurs through similar means as HBV and can occur either at the same time as an HBV infection (*i.e.*, coinfection) or in patients with chronic HBV infections (*i.e.*, superinfection). This relationship to HBV infection timing determines the natural history of HDV infection, with superinfection more often leading to a rapid clinical deterioration with progressive hepatitis, cirrhosis and development of complications of cirrhosis, including HCC. Current treatment strategies for HDV are centered around prevention and the management of HBV, as HDV is entirely dependent on the HBV lifecycle; however, directed therapies against HDV are under investigation[132].

Epidemiology

There are multiple estimates of HDV prevalence, as high as 13% of all HBV carriers; however, a recent meta-analysis estimated that approximately 4.5% of HBsAg-positive people are coinfected with HDV, which corresponds to approximately 12 million HDV infections worldwide[133]. HDV is present worldwide with geographic variation that does not align with HBV prevalence. There is a very high prevalence of HDV in Mongolia (36.9% of patients with HBsAg) and in central African countries (with estimates of > 10% prevalence in the HBsAg-positive population). Despite high rates of HBV infection, there are very low rates of HDV co-infection in other Asian countries, including China[133]. Regardless of geography, the populations at highest risk for HDV include people who inject drugs and those with

human immunodeficiency virus (HIV) or HCV[133]. HDV is even more prevalent in patients with HBV-associated cirrhosis and HCC, highlighting the pathogenic importance of HDV.

Natural History of Infection and Clinical Course

The primary modes of transmission for HDV are similar to those for HBV with the highest infection rates in people who inject drugs. HDV is a 1.7kb single stranded RNA molecule that encodes for the hepatitis D antigen (HDAg)[134]. Depending on RNA processing, the HDAg has one of two forms—the short form (HDAg-S) or long form (HDAg-L)—each with distinct functional roles. HDAg-S activates further HDV RNA synthesis, while HDAg-L inhibits HDV RNA synthesis and promotes HDV assembly with HBsAg to allow for packaging and transport[134]. It has been proposed that HDV mediates liver toxicity *via* both direct hepatotoxicity and indirect immune-mediated hepatocellular damage, although immune-mediated damage is the current prevailing theory.

Evidence suggesting direct hepatotoxicity is based on (1) Histopathology with limited immune infiltrate in acute HDV infection[135]; (2) ultrastructural analysis of hepatocytes infected with HBV and with HDV that showed a strong correlation between the appearance of cytoplasmic structures and hepatocellular damage as assessed by ALT levels[136]; and (3) *in vitro* cell culture data in which HDAg expression is associated with cell death in the absence of immune cells[137]. However, the conclusion that HDV causes direct cytotoxicity has been questioned. Transgenic mice with hepatocyte-specific expression of both HDAg-S and HDAg-L demonstrated no direct cytotoxic effect regardless of the level of HBsAg coexpression[138]. This finding was mirrored with histologic assessment of HBsAg carriers with chronic HDV infection, which demonstrated that HDAg expression was low during acute hepatitis and increased with the development of chronic disease[139]. However, these studies do not test the possibility of other stages of the HDV lifecycle causing direct cytotoxicity and some have suggested that HDV viral replication itself leads to cytotoxicity. More convincing evidence is present for HDV infection causing immune-mediated hepatotoxicity. Nevertheless, long-term follow up of 76 patients who underwent liver transplant for HDV-related cirrhosis showed that either HDV RNA (serum) or liver HDAg were present in 88% of patients within the first year[140]. However, these patients did not develop hepatitis unless active HBV infection recurs, suggesting that HDV is not hepatotoxic when expressed alone but instead requires HBV expression[140].

Regardless of the mode of hepatotoxicity, HDV has different clinical courses that depend on the timing of HDV infection in relationship to HBV-mediated liver disease. For coinfection, HBV and HDV are acquired simultaneously, whereas a superinfection occurs when HDV is acquired in a patient with an established HBV infection. Coinfection is most common in patients who use IV drugs. Since HDV is dependent on HBV and HBV infection is cleared in the majority of cases acquired in adulthood, HDV acquired in this manner also spontaneously clears. When the coinfection does not clear, some evidence suggests that HDV may cause a more intense hepatitis[141]. This was suggested by the high seroprevalence of HDV in patients with fulminant hepatitis B (52% in 1 study), but in this same study of fulminant hepatitis B, HDV coinfection correlated with better survival than with those infected with HBV alone (57.8% survival in coinfection vs. 16.7% survival with HBV alone)[141].

HDV superinfection occurs when a patient with a preexisting liver disease from chronic HBV infection contracts HDV. This is often accompanied by very high levels of HDV RNA expression with a subsequent severe hepatitis and decompensation of preexisting liver disease, as the HDV replication is protected by high levels of HBsAg[142]. Despite HDV inhibition of HBV replication, HBV infection is already established and allows development of chronic HDV infection in the majority of cases. Chronic HDV infection often leads to hepatitis with rapidly developing cirrhosis and increased risk of decompensation and HCC[143]. The increased risk of HCC in patients chronically infected with HDV is evidenced by multiple long-term cohort studies. A 28-year study of 299 patients with HDV infection with a median follow up of 233 mo demonstrated that active HDV replication portends an increased risk of cirrhosis and HCC with annual rates of 4% and 2.8%, respectively[144]. Moreover, this study also reported that HDV replication was an independent predictor of mortality in these patients[144]. Another cohort demonstrated that HCC developed in 42% of patients with chronic HDV within 12 years of diagnosis[131].

Prevention, Diagnosis, and Treatment

As discussed above, HDV infection and replication is entirely dependent upon HBV infection, and therefore HDV prevention efforts are largely centered around HBV prevention with vaccination programs. HBV vaccination programs have therefore led to a significant reduction in HDV infections in developed countries[145]. The impressive ongoing global efforts to eliminate chronic viral hepatitis—including HBV—should also significantly reduce the burden of HDV.

The only currently available treatment for HDV is interferon, which may exert its effect on HDV either *via* direct inhibition of HDV or inhibition of HBV[146]. Despite initial control of HDV viral load and improved histology during the treatment phases, multiple trials have shown exceptionally high rates of HDV relapse after completing interferon therapy[147]. The largest of these studies randomly assigned 42 patients with chronic HDV to receive either placebo or 3 million or 9 million units of interferon-alpha-2a[147]. This study demonstrated a dose-dependent response with regards to ALT levels, HDV RNA levels, and histology scores[147]. While the decreases in ALT levels were maintained

for 4 years of follow up, even patients treated with high dose interferon demonstrated relapses in HDV replication during post-treatment follow up[147]. Nevertheless, when these patients were followed for an additional 2-14 years, this group discovered that patients who received high dose interferon therapy had a dramatic long-term survival benefit[148]. Further, non-randomized, studies assessed the response of chronic HDV to peginterferon-alpha-2b[149,150]. These studies demonstrated variable responses to peginterferon-alpha-2b with a 57% sustained response in one study and only 17% sustained response in the other study with sustained response defined as undetectable HDV-RNA 6-mo post-treatment[149,150]. Those most likely to have a sustained response are likely to also have early reductions in HDV-RNA levels[149,150]. Conversely, no patients with cirrhosis demonstrated a sustained response[149].

Given the dependence of HDV on HBV, it is logical that therapies directed against HBV may also treat HDV. However, HDV replication is independent of HBV replication and only requires HBsAg. Therefore, any therapeutic benefit of HBV therapy on HDV infection is an indirect result of decreasing HBsAg production, which is not significantly reduced by nucleos(t)ide analogs. Unfortunately, trials of nucleos(t)ide analogs have not proven any sustained benefit in chronic hepatitis D despite excellent suppression of HBV DNA[151]. While there have been reports of Tenofovir resulting in HDV virus suppression in patients with either HBV-HDV co-infection or triple infection with HIV, HBV, and HDV [152,153], but it is questioned whether this results in a sustained benefit if tenofovir is withdrawn. Moreover, when combined with peginterferon alpha-2a in a placebo-controlled randomized control trial, tenofovir had no additional benefit with respect to HDV RNA level[154]. Similarly, the nucleoside analog adefovir also had no benefit on HDV levels when used alone and had no added benefit to interferon therapy[155]. Taken together, these data highlight the need for more directed HDV therapies. Directed treatments against HDV are currently under investigation and included inhibitors of cell entry, prenylation inhibitors, and subviral particle release inhibitors[132,146]. However, none of these are currently approved for use outside of clinical trials.

HEPATITIS E

Hepatitis E infection is caused by the Hepatitis E virus (HEV), a single stranded, quasi-enveloped RNA molecule in the Hepeviridae family[156]. There are 8 known genotypes, with genotypes 1-4 being the most studied[157]. Transmission occurs either *via* fecal-oral route (genotypes 1 and 2) or zoonotic transmission with ingestion of raw or undercooked meat (genotypes 3 and 4). HEV typically causes an acute, self-limited hepatitis that is particularly severe in pregnant women; however, cases of chronic hepatitis E have been reported in immunocompromised hosts. Prevention is centered around improving hygiene and vaccination, although a vaccine is available for use only in China[158]. Currently, treatment of acute HEV is supportive, and chronic HEV is treated with a multipronged approach with decreasing the underlying immunosuppression and occasionally ribavirin.

Epidemiology

There are two distinct, genotype-dependent epidemiologic patterns of Hepatitis E. Hepatitis E virus genotypes 1 and 2 are only known to infect humans and are highly endemic in developing countries throughout the world[157]. In these regions, HEV genotypes 1 and 2 result in large outbreaks in areas of poor sanitation, primarily in developing countries and related to drinking water contaminated with feces[159]. This was demonstrated by a naïve volunteer who developed a hepatitis-like illness after ingesting pooled feces extracts from patients with non-A, non-B hepatitis, which led to the discovery of hepatitis E[160]. Genotypes 1 and 2 are estimated to cause at least 20 million acute infections that result in approximately 3.4 million symptomatic cases, 70000 deaths, and 3000 stillbirths each year[161].

In addition to humans, HEV genotypes 3 and 4 are known to infect multiple species including swine, deer, and rabbits and are more commonly reported in the developed world (Europe, North America, Australia, and Japan)[156]. HEV genotypes 3 and 4 account for very few (less than 1%) of the cases of viral hepatitis in the developed world, and transmission is thought to be from consumption of undercooked meat, primarily pork. This is evidenced by the exceptionally high rate of HEV infection in both wild and domesticated pigs in multiple European countries[162,163]. A study of the Swedish swine population also sequenced partial genomes of HEV strains from humans, pigs, and wild boars and found a high degree of relatedness, suggesting zoonotic transmission[163]. The ability of swine HEV genotype 3 to cross species was confirmed with inoculation of rhesus monkeys and chimpanzees[164]; however, pigs have varying degrees of susceptibility to experimental infection with HEV from humans [165,166]. Nevertheless, HEV has been detected in multiple stages of consumer pork product processing across Europe[167-169], but HEV is inactivated by adequate food preparation, as pigs cannot be inoculated with HEV-infected pureed pig livers subjected to heating to 71 °C for 20 min or longer[170].

While very few cases of HEV are reported in the developed world each year, this likely owes to undertesting and the self-limited nature of the disease. Screening blood donations in Western Europe has shown HEV RNA in 0.02%-0.14% of all screened blood products. In England, one study that screened 225000 blood donations found that 79 donors (0.04%) were infected with HEV RNA[171]. These infected donors generated in 129 blood components and resulted in an estimated 42% infectivity

Table 1 Overview of epidemiology, symptoms, natural history and clinical management of viral hepatitis infections

Virus	Estimated number of infections worldwide	Mode of transmission	Typical clinical signs/symptoms	Natural history	Diagnosis	Treatment	Prevention
Hepatitis A	1.4 million annually	Fecal-oral route	Many asymptomatic. Most with non-specific symptoms of fatigue, nausea, vomiting, anorexia, jaundice	Asymptomatic, self-limited illness, prolonged cholestasis, relapsing, fulminant hepatitis (very rare)	Hepatitis A IgM	Supportive care, post-exposure vaccination and HAV immuno-globulin	Sanitation efforts, vaccination
Hepatitis B	257million chronic HBV infections (WHO 2017 Global Hepatitis Report)	Vertical transmission (common for chonic HBV); IVDU, blood product transfusions, sexual contact (common for acute HBV)	Acute: non-specific symptoms (fatigue, nausea, vomiting, anorexia, jaundice); chronic: often asymptomatic, can progress to cirrhosis and HCC	Infection at birth: chronic HBV infection (immune tolerance, immune clearance, inactive carrier, reactivation). Eventual progression to cirrhosis and HCC; infection in adulthood: > 95% clearance	Past infection-HBsAg negative, HBsAb positive, HBcAb positive, HBeAb +/-; current infection-HBsAg positive, HBsAb negative, HBcAb positive, HBeAb +/-	Nucleot(s)ide reverse transcriptase inhibitors (entecavir, tenofovir); interferon	HBV vaccine (universal vaccination recommended at birth); HBIG in select cases
Hepatitis C	71 million (WHO 2017 Global Hepatitis Report)	Direct blood stream inoculation (IVDU, unregulated tattoos/piercings, blood transfusion and organ transplants)	Typically asymptomatic until cirrhosis develops	Spontaneous clearance: 10%-25%; chronic Infection: 75%-90%, can progress to cirrhosis and HCC	HCV antibody, HCV RNA viral load	Direct acting antivirals	Widespread screening efforts
Hepatitis D	12 million cases annually, 4.5% of HBV-infected individuals	Similar to Hepatitis B (IVDU, blood product transfusions, sexual contact)	Non-specific symptoms of fatigue, nausea, vomiting, anorexia, jaundice	Simultaneous coinfection of HDV and HBV: rare fulminant hepatitis, usually complete recovery; superinfection on chronic HBV: accellerated progression of chronic HBV	HDV IgM (acute), HDV IgG (chronic)	Hepatitis B treatment	Hepatitis B vaccination
Hepatitis E	20 million acute infections (The Global Burden of Hepatitis E Virus Genotypes 1 and 2 in 2005)	Genotypes 1 and 2: Fecal-oral route; genotypes 3 and 4: Zoonotic, contam-inated meat	Commonly asymptomatic; prodromal flu-like symptoms, nausea, vomiting, anorexia, fatigue followed by jaundice	Acute self-limited in majority of cases, severe in pregnant women; chronic hepatitis in immunocompromised hosts	HEV IgM (acute), HEV IgG (chronic)	Chronic infection: decrease immunosup-pression, ribavirin	Genotypes 1 and 2: Sanitation efforts, vaccine available in China
Hepatitis G	4.8% worldwide	Direct blood stream inoculation (IVDU, unregulated tattoos/piercings, blood transfusion and organ transplants)	Not well-described, likely asymptomatic	Not well-described. Unlikely to cause clinically significant hepatitis in humans.	Hepatitis G RNA; not currently used clinically	None	None

HAV: Hepatitis A virus; HBV: Hepatitis B virus; HCV: Hepatitis C virus; HDV: Hepatitis D virus; HEV: Hepatitis E virus; HGV: Hepatitis G virus; WHO: World Health Organization; IVDU: Intravenous drug use; HCC: Hepatocellular carcinoma; HBIG Hepatitis B immunoglobulin; HBsAb: Hepatitis B surface antibody; HBsAg: Hepatitis B surface antigen; IgG: Immunoglobulin G; IgM: Immunoglobulin M.

rate (18 of 43 followed up), which has led some to call for universal screening of blood donations for HEV[171,172]. Seropositivity in the developed world ranges from 6% in the United States to 39.1% in Southern France, although assays for HEV IgG have reportedly wide ranges of sensitivity[156]. A 2017 systematic review that analyzed the prevalence of HEV in Iran found an overall positivity rate of 9.7%

with varying rates between cities (1.1% in Tehran *vs* 46.1% in Ahvaz)[173]. Finally, a recent systematic review and meta-analysis of 56 studies on the seroprevalence of HEV in patients on maintenance hemodialysis (HD) found that the pooled seroprevalence of HEV was 11.13% between 2016 and 2020, which had increased from 6.6% from 1994 to 2000[174]. Moreover, the length of time on HD was associated with higher seroprevalence as those on HD for more than 60 mo had a significantly higher chance of being seropositive (27.69% more than 60 mo *vs* 15.78% less than 60 mo)[174].

Natural History of Infection and Clinical Course

Hepatitis E enters into the hepatocyte in 1 of 2 distinct mechanisms depending on whether the virus is enveloped or not, and upon entry, the virus is uncoated, transcribed and translated into 3 different proteins that facilitate viral replication, repackaging, sorting and release into both the blood stream and bile[156]. Upon HEV release into the bile, the envelope is degraded by bile acids and detergents prior to being released into the intestinal lumen and excreted with stool. The unenveloped version of the virus released into the feces has a much more efficient mechanism of hepatocyte entry and helps explain the most common form of HEV transmission. HEV is not thought to be directly cytotoxic. Instead, HEV causes hepatotoxicity *via* immune mediated mechanisms as patients with acute hepatitis E infection show both $CD4^+$ and $CD8^+$ T-cell responses[175].

HEV infection is most commonly asymptomatic as evidenced by the high seroprevalence of anti-HEV IgG and lack of recollection of acute symptoms[176]. When symptomatic, HEV has a 2-10 d incubation period followed by non-specific prodromal symptoms of fatigue, nausea, vomiting, and anorexia, similar to other acute hepatitis infections. Ultimately, HEV causes an acute, self-limited hepatitis characterized by jaundice and marked AST and ALT elevations. These symptoms typically self-resolve within 1 mo, although some cases of prolonged cholestasis (up to 6 mo) and even cases of fulminant hepatic failure with resultant death have been reported[177].

Pregnant women are particularly prone to severe hepatitis E infections that can result in fulminant hepatic failure in approximately 20% of infected patients with an associated high mortality rate and high rate of fetus and neonatal complications, including spontaneous abortions, stillbirths, and neonatal deaths. Infections within the third trimester are the most problematic and are thought to be so detrimental because of an altered immune system and hormonal changes[178].

All reported cases of chronic hepatitis E infection have been linked to genotype 3 and have been reported in immunocompromised patients including those with HIV[179], undergoing chemotherapy [180], or solid organ transplant recipients[181]. This has been linked to the development of cirrhosis and HCC. However, the limited number of cases reported precludes detailed assessment of risk of these complications of chronic HEV infection.

Prevention, Diagnosis, and Treatment

Given that the primary mode of transmission for the most common HEV variants (genotypes 1 and 2) is through contaminated water, the main mode of prevention is through increased sanitation efforts to provide citizens of the developing world with clean drinking water. A vaccine to protect against HEV is now approved for human use in China but not elsewhere; however, this is likely to benefit those infected in the rest of the world[158]. Efforts to bring clean drinking water to all parts of the world should reduce the burden of HEV, and we are hopeful that the vaccine for HEV may be approved outside of China for further HEV prevention.

There is currently no direct acting antiviral to treat HEV. In immunocompromised patients, the mainstay of treatment is to reduce immunosuppression if possible[181,182]. This results in a sustained viral response (*i.e.*, no detectable HEV RNA) in approximately 30% of patients. In patients where decreasing immunosuppression is either not possible or does not result in SVR, ribavirin is currently the main therapeutic option[183]. Unfortunately, ribavirin is a category X drug, meaning that is should not be given to pregnant women. Some cases of ribavirin exposure do occur during pregnancy, which is the subject of study in the ribavirin pregnancy registry[184]. Interim analysis has failed to show a direct link between ribavirin and teratogenicity, but full results of the study are forthcoming and for the moment, ribavirin remains a category X drug[184]. Additional therapies, including pegylated interferon and sofosbuvir have been evaluated only in limited clinical settings[185,186].

HEPATITIS G

What is now regarded as the hepatitis G virus (HGV) was initially described in 1966 and named the GB virus (GBV) after the surgeon G. Barker, who fell ill with hepatitis. Subsequent studies isolated genetically similar agents, named GBV-A, GBV-B, and GBV-C, and GBV-C was genetically similar to a separate isolate already named HGV[187].

Hepatitis G virus is a less well-described entity with a global distribution but varying reports of HGV prevalence in the general population. A systematic review evaluated studies reporting the prevalence of HGV in healthy voluntary blood donors and found 649 infections in 13610 voluntary blood donors (4.8% positivity rate) [188]. The studies included in the review reported HGV positivity rates ranging

from 0.5% prevalence in a Japanese study to 18.9% in a South African study[188]. Currently, HGV is not widely tested for clinically, so the true incidence is not well-known.

The natural history of HGV is not well-characterized, and it is questioned whether HGV causes a clinically significant liver disease. While HGV has been detected in many different clinical scenarios, including acute presumed viral hepatitis, cirrhosis of unknown cause, and HCC, the clinical relevance is still questioned given the high co-infection rate with other causes of viral hepatitis, including HCV and that HGV co-infection does not exacerbate the course of HCV[189]. Moreover, greater than 75% of patients who are positive for HGV have normal liver function tests[190]. This group also reported that among HGV-positive individuals with elevated liver function tests, aminotransferase elevations are negligible and that there is no correlation between HGV viral load and aminotransferase elevations in patients on chronic dialysis[190]. In another study, 0 of 16 HGV-positive patients on chronic hemodialysis had elevated aminotransferase levels despite prolonged viral persistence[191].

Additionally, individuals who undergo liver transplantation are often incidentally HGV-positive, and both HGV-positive and HGV-negative liver recipients have similar outcomes (including 40-mo survival), suggesting that HGV positivity does not affect engraftment or graft function[192]. Additional studies have suggested that the liver is not the site of viral replication as the liver-to-serum ratio of HGV RNA is less than 1, which is consistent with blood contamination of liver tissue[193]. Finally, despite initial reports of HGV-associated fulminant liver failure, it is now thought that these patients were positive for HGV RNA due to blood product administration during the hospitalization rather than HGV being present at the time of admission[194]. Experimental models also argue against HGV causing a clinically significant disease as studies in chimpanzees demonstrate that HGV can reach high levels of viremia in chimpanzees without causing a concurrent rise in liver enzymes[195]. Taken together, these data provide evidence that HGV does not cause clinically significant liver disease. As such, HGV is not a common test ordered on the clinical wards.

CONCLUSION

As a group, viral hepatitis represents an ongoing global health concern (Table 1). Acute viral hepatitis infections—HAV and HEV—tend to be self-limited infections with little-to-no long-lasting effect, and both vaccines and improved sanitation conditions will decrease the burden of disease over time. Moreover, ever-improving understanding of the risk factors for acute liver failure from acute hepatitis and experimental supportive care options will aid in further reducing the impact of acute viral hepatitis. Chronic viral hepatitis infections—HBV and HCV—on the other hand, often result in cirrhosis and death if left untreated. While vaccination for HBV is highly effective in reducing transmission, and treatments for HBV are effective in reducing HBV viral load and progression of liver disease, an effective cure for HBV remains elusive. Conversely, an effective vaccine for HCV has not been achieved, but highly effective treatments cure HCV in nearly 100% of cases and are now revolutionizing the fields of transplant medicine. Despite unique barriers, there are ongoing global efforts to eliminate chronic viral hepatitis, and given substantial progress, we are hopeful that this ambitious goal will be realized.

FOOTNOTES

Author contributions: Odenwald MA and Paul S both contributed equally to this work. Both wrote and revised this review article, and both authors approve of the final manuscript.

Conflict-of-interest statement: The authors have no conflicts of interest to declare.

Country/Territory of origin: United States

ORCID number: Matthew August Odenwald 0000-0003-1740-6472; Sonali Paul 0000-0002-0136-5496.

S-Editor: Chang KL
L-Editor: A
P-Editor: Chang KL

REFERENCES

1 **Coulepis AG**, Locarnini SA, Westaway EG, Tannock GA, Gust ID. Biophysical and biochemical characterization of hepatitis A virus. *Intervirology* 1982; **18**: 107-127 [PMID: 6292126 DOI: 10.1159/000149314]

2 **Coulepis AG**, Anderson BN, Gust ID. Hepatitis A. *Adv Virus Res* 1987; **32**: 129-169 [PMID: 3039812 DOI: 10.1016/s0065-3527(08)60476-5]

3 **Jacobsen KH**, Wiersma ST. Hepatitis A virus seroprevalence by age and world region, 1990 and 2005. *Vaccine* 2010; **28**: 6653-6657 [PMID: 20723630 DOI: 10.1016/j.vaccine.2010.08.037]

4 **Rezende G**, Roque-Afonso AM, Samuel D, Gigou M, Nicand E, Ferre V, Dussaix E, Bismuth H, Féray C. Viral and clinical factors associated with the fulminant course of hepatitis A infection. *Hepatology* 2003; **38**: 613-618 [PMID: 12939587 DOI: 10.1053/jhep.2003.50366]

5 **Cuthbert JA**. Hepatitis A: old and new. *Clin Microbiol Rev* 2001; **14**: 38-58 [PMID: 11148002 DOI: 10.1128/cmr.14.1.38-58.2001]

6 **The World Health Organization**. Immunization, Vaccines and Biologicals: Hepatitis A. Available from: https://www.who.int/immunization/diseases/hepatitisA/en/

7 **Klevens RM**, Kruszon-Moran D, Wasley A, Gallagher K, McQuillan GM, Kuhnert W, Teshale EH, Drobeniuc J, Bell BP. Seroprevalence of hepatitis A virus antibodies in the U.S.: results from the National Health and Nutrition Examination Survey. *Public Health Rep* 2011; **126**: 522-532 [PMID: 21800746 DOI: 10.1177/003335491112600408]

8 **Bell BP**, Kruszon-Moran D, Shapiro CN, Lambert SB, McQuillan GM, Margolis HS. Hepatitis A virus infection in the United States: serologic results from the Third National Health and Nutrition Examination Survey. *Vaccine* 2005; **23**: 5798-5806 [PMID: 16307834 DOI: 10.1016/j.vaccine.2005.03.060]

9 **Centers for Disease Control and Prevention**. Hepatitis A. Available from: https://www.cdc.gov/vaccines/pubs/pinkbook/hepa.html

10 **Rosenblum LS**, Villarino ME, Nainan OV, Melish ME, Hadler SC, Pinsky PP, Jarvis WR, Ott CE, Margolis HS. Hepatitis A outbreak in a neonatal intensive care unit: risk factors for transmission and evidence of prolonged viral excretion among preterm infants. *J Infect Dis* 1991; **164**: 476-482 [PMID: 1651359 DOI: 10.1093/infdis/164.3.476]

11 **Provost PJ**, Hilleman MR. Propagation of human hepatitis A virus in cell culture in vitro. *Proc Soc Exp Biol Med* 1979; **160**: 213-221 [PMID: 217023 DOI: 10.3181/00379727-160-40422]

12 **Phan C**, Hollinger FB. Hepatitis A: Natural history, immunopathogenesis, and outcome. *Clin Liver Dis (Hoboken)* 2013; **2**: 231-234 [PMID: 30992869 DOI: 10.1002/cld.253]

13 **Taylor RM**, Davern T, Munoz S, Han SH, McGuire B, Larson AM, Hynan L, Lee WM, Fontana RJ; US Acute Liver Failure Study Group. Fulminant hepatitis A virus infection in the United States: Incidence, prognosis, and outcomes. *Hepatology* 2006; **44**: 1589-1597 [PMID: 17133489 DOI: 10.1002/hep.21439]

14 **Kim JD**, Cho EJ, Ahn C, Park SK, Choi JY, Lee HC, Kim DY, Choi MS, Wang HJ, Kim IH, Yeon JE, Seo YS, Tak WY, Kim MY, Lee HJ, Kim YS, Jun DW, Sohn JH, Kwon SY, Park SH, Heo J, Jeong SH, Lee JH, Nakayama N, Mochida S, Ido A, Tsubouchi H, Takikawa H, Shalimar, Acharya SK, Bernal W, O'Grady J, Kim YJ. A Model to Predict 1-Month Risk of Transplant or Death in Hepatitis A-Related Acute Liver Failure. *Hepatology* 2019; **70**: 621-629 [PMID: 30194739 DOI: 10.1002/hep.30262]

15 **Rela M**, Kaliamoorthy I, Reddy MS. Current status of auxiliary partial orthotopic liver transplantation for acute liver failure. *Liver Transpl* 2016; **22**: 1265-1274 [PMID: 27357489 DOI: 10.1002/lt.24509]

16 WHO position paper on hepatitis A vaccines - June 2012. *Wkly Epidemiol Rec* 2012; **87**: 261-76 [PMID: 22905367]

17 **Desai AN**, Kim AY. Management of Hepatitis A in 2020-2021. *JAMA* 2020; **324**: 383-384 [PMID: 32628251 DOI: 10.1001/jama.2020.4017]

18 **Victor JC**, Monto AS, Surdina TY, Suleimenova SZ, Vaughan G, Nainan OV, Favorov MO, Margolis HS, Bell BP. Hepatitis A vaccine versus immune globulin for postexposure prophylaxis. *N Engl J Med* 2007; **357**: 1685-1694 [PMID: 17947390 DOI: 10.1056/nejmoa070546]

19 **Nelson NP**, Link-Gelles R, Hofmeister MG, Romero JR, Moore KL, Ward JW, Schillie SF. Update: Recommendations of the Advisory Committee on Immunization Practices for Use of Hepatitis A Vaccine for Postexposure Prophylaxis and for Preexposure Prophylaxis for International Travel. *MMWR Morb Mortal Wkly Rep* 2018; **67**: 1216-1220 [PMID: 30383742 DOI: 10.15585/mmwr.mm6743a5]

20 **Ganem D**, Prince AM. Hepatitis B virus infection--natural history and clinical consequences. *N Engl J Med* 2004; **350**: 1118-1129 [PMID: 15014185 DOI: 10.1056/nejmra031087]

21 **Kruszon-Moran D**, Paulose-Ram R, Martin C, Barker L, and McQuillan, G. Prevalence and trends in hepatitis B virus infection in the United States, 2015-2018. *NCHS Data Brief* 2020; **361**: 1-8

22 **Jefferies M**, Rauff B, Rashid H, Lam T, Rafiq S. Update on global epidemiology of viral hepatitis and preventive strategies. *World J Clin Cases* 2018; **6**: 589-599 [PMID: 30430114 DOI: 10.12998/wjcc.v6.i13.589]

23 **McMahon BJ**, Alward WL, Hall DB, Heyward WL, Bender TR, Francis DP, Maynard JE. Acute hepatitis B virus infection: relation of age to the clinical expression of disease and subsequent development of the carrier state. *J Infect Dis* 1985; **151**: 599-603 [PMID: 3973412 DOI: 10.1093/infdis/151.4.599]

24 **Fanning GC**, Zoulim F, Hou J, Bertoletti A. Therapeutic strategies for hepatitis B virus infection: towards a cure. *Nat Rev Drug Discov* 2019; **18**: 827-844 [PMID: 31455905 DOI: 10.1038/s41573-019-0037-0]

25 **Thomas DL**. Global Elimination of Chronic Hepatitis. *N Engl J Med* 2019; **380**: 2041-2050 [PMID: 31116920 DOI: 10.1056/NEJMra1810477]

26 **Shepard CW**, Simard EP, Finelli L, Fiore AE, Bell BP. Hepatitis B virus infection: epidemiology and vaccination. *Epidemiol Rev* 2006; **28**: 112-125 [PMID: 16754644 DOI: 10.1093/epirev/mxj009]

27 **Schweitzer A**, Horn J, Mikolajczyk RT, Krause G, Ott JJ. Estimations of worldwide prevalence of chronic hepatitis B virus infection: a systematic review of data published between 1965 and 2013. *Lancet* 2015; **386**: 1546-1555 [PMID: 26231459 DOI: 10.1016/S0140-6736(15)61412-X]

28 **Mitchell T**, Armstrong GL, Hu DJ, Wasley A, Painter JA. The increasing burden of imported chronic hepatitis B--United States, 1974-2008. *PLoS One* 2011; **6**: e27717 [PMID: 22163270 DOI: 10.1371/journal.pone.0027717]

29 **Tavakoli A**, Moghoofei M, Mostafaei S, Ghaffari H, Alavian SHM& SM, Alavian SM. Prevalence of hepatitis B surface antigen among hemodialysis patients from Middle Eastern countries: a systematic review and meta-analysis. *Future Virology* 2017; 12 [DOI: 10.2217/fvl-2017-0035]

30 **Oh IS**, Park SH. Immune-mediated Liver Injury in Hepatitis B Virus Infection. *Immune Netw* 2015; **15**: 191-198 [PMID: 26330805 DOI: 10.4110/in.2015.15.4.191]

31 **Tan A**, Koh S, Bertoletti A. Immune Response in Hepatitis B Virus Infection. *Cold Spring Harb Perspect Med* 2015; **5**: a021428 [PMID: 26134480 DOI: 10.1101/cshperspect.a021428]

32 **Wieland S**, Thimme R, Purcell RH, Chisari FV. Genomic analysis of the host response to hepatitis B virus infection. *Proc Natl Acad Sci U S A* 2004; **101**: 6669-6674 [PMID: 15100412 DOI: 10.1073/pnas.0401771101]

33 **Tan G**, Song H, Xu F, Cheng G. When Hepatitis B Virus Meets Interferons. *Front Microbiol* 2018; **9**: 1611 [PMID: 30072974 DOI: 10.3389/fmicb.2018.01611]

34 **Dunn C**, Peppa D, Khanna P, Nebbia G, Jones M, Brendish N, Lascar RM, Brown D, Gilson RJ, Tedder RJ, Dusheiko GM, Jacobs M, Klenerman P, Maini MK. Temporal analysis of early immune responses in patients with acute hepatitis B virus infection. *Gastroenterology* 2009; **137**: 1289-1300 [PMID: 19591831 DOI: 10.1053/j.gastro.2009.06.054]

35 **Wieland SF**, Chisari FV. Stealth and cunning: hepatitis B and hepatitis C viruses. *J Virol* 2005; **79**: 9369-9380 [PMID: 16014900 DOI: 10.1128/jvi.79.15.9369-9380.2005]

36 **Maini MK**, Boni C, Ogg GS, King AS, Reignat S, Lee CK, Larrubia JR, Webster GJ, McMichael AJ, Ferrari C, Williams R, Vergani D, Bertoletti A. Direct ex vivo analysis of hepatitis B virus-specific CD8(+) T cells associated with the control of infection. *Gastroenterology* 1999; **117**: 1386-1396 [PMID: 10579980 DOI: 10.1016/s0016-5085(99)70289-1]

37 **Thimme R**, Wieland S, Steiger C, Ghrayeb J, Reimann KA, Purcell RH, Chisari FV. CD8(+) T cells mediate viral clearance and disease pathogenesis during acute hepatitis B virus infection. *J Virol* 2003; **77**: 68-76 [PMID: 12477811 DOI: 10.1128/jvi.77.1.68-76.2003]

38 **Burton AR**, Pallett LJ, McCoy LE, Suveizdyte K, Amin OE, Swadling L, Alberts E, Davidson BR, Kennedy PT, Gill US, Mauri C, Blair PA, Pelletier N, Maini MK. Circulating and intrahepatic antiviral B cells are defective in hepatitis B. *J Clin Invest* 2018; **128**: 4588-4603 [PMID: 30091725 DOI: 10.1172/JCI121960]

39 **Heim K**, Neumann-Haefelin C, Thimme R, Hofmann M. Heterogeneity of HBV-Specific $CD8^+$ T-Cell Failure: Implications for Immunotherapy. *Front Immunol* 2019; **10**: 2240 [PMID: 31620140 DOI: 10.3389/fimmu.2019.02240]

40 **Boni C**, Fisicaro P, Valdatta C, Amadei B, Di Vincenzo P, Giuberti T, Laccabue D, Zerbini A, Cavalli A, Missale G, Bertoletti A, Ferrari C. Characterization of hepatitis B virus (HBV)-specific T-cell dysfunction in chronic HBV infection. *J Virol* 2007; **81**: 4215-4225 [PMID: 17287266 DOI: 10.1128/jvi.02844-06]

41 **de Jongh FE**, Janssen HL, de Man RA, Hop WC, Schalm SW, van Blankenstein M. Survival and prognostic indicators in hepatitis B surface antigen-positive cirrhosis of the liver. *Gastroenterology* 1992; **103**: 1630-1635 [PMID: 1426884 DOI: 10.1016/0016-5085(92)91188-a]

42 **Terrault NA**, Lok ASF, McMahon BJ, Chang KM, Hwang JP, Jonas MM, Brown RS Jr, Bzowej NH, Wong JB. Update on prevention, diagnosis, and treatment of chronic hepatitis B: AASLD 2018 hepatitis B guidance. *Hepatology* 2018; **67**: 1560-1599 [PMID: 29405329 DOI: 10.1002/hep.29800]

43 **Lok AS**, Zoulim F, Dusheiko G, Chan HLY, Buti M, Ghany MG, Gaggar A, Yang JC, Wu G, Flaherty JF, Subramanian GM, Locarnini S, Marcellin P. Durability of Hepatitis B Surface Antigen Loss With Nucleotide Analogue and Peginterferon Therapy in Patients With Chronic Hepatitis B. *Hepatol Commun* 2020; **4**: 8-20 [PMID: 31909352 DOI: 10.1002/hep4.1436]

44 **Perrillo RP**, Brunt EM. Hepatic histologic and immunohistochemical changes in chronic hepatitis B after prolonged clearance of hepatitis B e antigen and hepatitis B surface antigen. *Ann Intern Med* 1991; **115**: 113-115 [PMID: 2058858 DOI: 10.7326/0003-4819-115-2-113]

45 **Loomba R**, Liang TJ. Hepatitis B Reactivation Associated With Immune Suppressive and Biological Modifier Therapies: Current Concepts, Management Strategies, and Future Directions. *Gastroenterology* 2017; **152**: 1297-1309 [PMID: 28219691 DOI: 10.1053/j.gastro.2017.02.009]

46 **The World Health Organization**. Global Hepatitis Report, 2017. [cited 27 June 2021]. Available from: https://www.who.int/publications/i/item/global-hepatitis-report-2017

47 **Chen HL**, Chang MH, Ni YH, Hsu HY, Lee PI, Lee CY, Chen DS. Seroepidemiology of hepatitis B virus infection in children: Ten years of mass vaccination in Taiwan. *JAMA* 1996; **276**: 906-908 [PMID: 8782640 DOI: 10.1001/jama.1996.03540110060032]

48 **Chang MH**, Chen CJ, Lai MS, Hsu HM, Wu TC, Kong MS, Liang DC, Shau WY, Chen DS. Universal hepatitis B vaccination in Taiwan and the incidence of hepatocellular carcinoma in children. Taiwan Childhood Hepatoma Study Group. *N Engl J Med* 1997; **336**: 1855-1859 [PMID: 9197213 DOI: 10.1056/nejm199706263362602]

49 **McMahon BJ**, Bulkow LR, Singleton RJ, Williams J, Snowball M, Homan C, Parkinson AJ. Elimination of hepatocellular carcinoma and acute hepatitis B in children 25 years after a hepatitis B newborn and catch-up immunization program. *Hepatology* 2011; **54**: 801-807 [PMID: 21618565 DOI: 10.1002/hep.24442]

50 **Beasley RP**, Hwang LY, Lee GC, Lan CC, Roan CH, Huang FY, Chen CL. Prevention of perinatally transmitted hepatitis B virus infections with hepatitis B immune globulin and hepatitis B vaccine. *Lancet* 1983; **2**: 1099-1102 [PMID: 6138642 DOI: 10.1016/s0140-6736(83)90624-4]

51 **Yuen MF**, Seto WK, Fung J, Wong DK, Yuen JC, Lai CL. Three years of continuous entecavir therapy in treatment-naïve chronic hepatitis B patients: VIRAL suppression, viral resistance, and clinical safety. *Am J Gastroenterol* 2011; **106**: 1264-1271 [PMID: 21364549 DOI: 10.1038/ajg.2011.45]

52 **Lee HW**, Lee HJ, Hwang JS, Sohn JH, Jang JY, Han KJ, Park JY, Kim DY, Ahn SH, Paik YH, Lee CK, Lee KS, Chon CY, Han KH. Lamivudine maintenance beyond one year after HBeAg seroconversion is a major factor for sustained virologic response in HBeAg-positive chronic hepatitis B. *Hepatology* 2010; **51**: 415-421 [PMID: 19902424 DOI: 10.1002/hep.23323]

53 **Azhari H**, Frolkis A, Shaheen AA, Israelson H, Pinto J, Congly SE, Borman MA, Aspinall A, Stinton LM, Swain, Burak MG. Real World Single Center Experience On The Efficacy Of Stopping Long Term Nucleos (T) Ide Analog Therapy In Patients With Chronic Hepatitis B. *The Liver Meeting Digital Experience* 2020

54 **Terrault N**, Lok AS, Wahed A, Wong DK, Khalili M, Fried MW, Lau D, Ghany MG, Sterling RK, Bisceglie D, Perrillo AM. Randomized trila of 190 weeks of tenmfovir with or without peginterferon alfa for the first 24 weeks followed by protocolozed adults with chronic hepatitis B. *The Liver Meeting Digital Experience* 2020

55 **Ramanan V**, Shlomai A, Cox DB, Schwartz RE, Michailidis E, Bhatta A, Scott DA, Zhang F, Rice CM, Bhatia SN. CRISPR/Cas9 cleavage of viral DNA efficiently suppresses hepatitis B virus. *Sci Rep* 2015; **5**: 10833 [PMID: 26035283 DOI: 10.1038/srep10833]

56 **Li H**, Sheng C, Wang S, Yang L, Liang Y, Huang Y, Liu H, Li P, Yang C, Yang X, Jia L, Xie J, Wang L, Hao R, Du X, Xu D, Zhou J, Li M, Sun Y, Tong Y, Li Q, Qiu S, Song H. Removal of Integrated Hepatitis B Virus DNA Using CRISPR-Cas9. *Front Cell Infect Microbiol* 2017; **7**: 91 [PMID: 28382278 DOI: 10.3389/fcimb.2017.00091]

57 **Yang YC**, Chen YH, Kao JH, Ching C, Liu IJ, Wang CC, Tsai CH, Wu FY, Liu CJ, Chen PJ, Chen DS, Yang HC. Permanent Inactivation of HBV Genomes by CRISPR/Cas9-Mediated Non-cleavage Base Editing. *Mol Ther Nucleic Acids* 2020; **20**: 480-490 [PMID: 32278307 DOI: 10.1016/j.omtn.2020.03.005]

58 **Song J**, Zhang X, Ge Q, Yuan C, Chu L, Liang HF, Liao Z, Liu Q, Zhang Z, Zhang B. CRISPR/Cas9-mediated knockout of HBsAg inhibits proliferation and tumorigenicity of HBV-positive hepatocellular carcinoma cells. *J Cell Biochem* 2018; **119**: 8419-8431 [PMID: 29904948 DOI: 10.1002/jcb.27050]

59 **Roberts TC**, Langer R, Wood MJA. Advances in oligonucleotide drug delivery. *Nat Rev Drug Discov* 2020; **19**: 673-694 [PMID: 32782413 DOI: 10.1038/s41573-020-0075-7]

60 **Schluep T**, Lickliter J, Hamilton J, Lewis DL, Lai CL, Lau JY, Locarnini SA, Gish RG, Given BD. Safety, Tolerability, and Pharmacokinetics of ARC-520 Injection, an RNA Interference-Based Therapeutic for the Treatment of Chronic Hepatitis B Virus Infection, in Healthy Volunteers. *Clin Pharmacol Drug Dev* 2017; **6**: 350-362 [PMID: 27739230 DOI: 10.1002/cpdd.318]

61 **Wooddell CI**, Yuen MF, Chan HL, Gish RG, Locarnini SA, Chavez D, Ferrari C, Given BD, Hamilton J, Kanner SB, Lai CL, Lau JYN, Schluep T, Xu Z, Lanford RE, Lewis DL. RNAi-based treatment of chronically infected patients and chimpanzees reveals that integrated hepatitis B virus DNA is a source of HBsAg. *Sci Transl Med* 2017; **9** [PMID: 28954926 DOI: 10.1126/scitranslmed.aan0241]

62 **Yuen MF**, Schiefke I, Yoon JH, Ahn SH, Heo J, Kim JH, Lik Yuen Chan H, Yoon KT, Klinker H, Manns M, Petersen J, Schluep T, Hamilton J, Given BD, Ferrari C, Lai CL, Locarnini SA, Gish RG. RNA Interference Therapy With ARC-520 Results in Prolonged Hepatitis B Surface Antigen Response in Patients With Chronic Hepatitis B Infection. *Hepatology* 2020; **72**: 19-31 [PMID: 31654573 DOI: 10.1002/hep.31008]

63 **Yuen**, M. F., Berliba, E., Kim, Y.J., Holmes, J.A., Lim, Y.S., Strasser, S.I., Schwabe, C., Jucov, A., Lee, A.C., Thi, Harasym EP and, T. SAFETY AND PHARMACODYNAMICS OF THE GALNAC-siRNA AB-729 IN SUBJECTS WITH CHRONIC HEPATITIS B INFECTION. *The Liver Meeting Digital Experience* 2020

64 **Billioud G**, Kruse RL, Carrillo M, Whitten-Bauer C, Gao D, Kim A, Chen L, McCaleb ML, Crosby JR, Hamatake R, Hong Z, Garaigorta U, Swayze E, Bissig KD, Wieland S. In vivo reduction of hepatitis B virus antigenemia and viremia by antisense oligonucleotides. *J Hepatol* 2016; **64**: 781-789 [PMID: 26658683 DOI: 10.1016/j.jhep.2015.11.032]

65 **Han K**, Cremer J, Elston R, Oliver S, Baptiste-Brown S, Chen S, Gardiner D, Davies M, Saunders J, Hamatake R, Losos J, Leivers M, Hood S, van der Berg F, Paff M, Ritter JM, Theodore D. A Randomized, Double-Blind, Placebo-Controlled, First-Time-in-Human Study to Assess the Safety, Tolerability, and Pharmacokinetics of Single and Multiple Ascending Doses of GSK3389404 in Healthy Subjects. *Clin Pharmacol Drug Dev* 2019; **8**: 790-801 [PMID: 30861337 DOI: 10.1002/cpdd.670]

66 **Yuen M-F**, Heo J, Jang JW, Yoon J-H, Kweon YO, Park S-J, Bennett CF, Kwoh TJ. AS067 Hepatitis B virus (HBV) surface antigen (HBsAg) inhibition with isis 505358 in chronic hepatitis B (CHB) patients on stable nucleos (t)ide analogue (NA) regimen and in NA-naive CHB patients: phase 2a, randomized, double-blind, placebo-controlled study. *J Hepatol* 2020; **73**: S49-S50 [DOI: 10.1016/s0168-8278(20)30646-2]

67 **Hong J**, Tan H, Lin T-I, Kang H, Nie Y, Bhattacharya A, Pandey R, Blatt LM, Symons JA, Beigelman and LN. COMBINATION OF ANTISENSE OLIGONUCLEOTIDES (ASOS) ALG-020572 AND ALG-020576 AGAINST HEPATITIS B VIRUS (HBV) IMPROVES ACTIVITY AND CAN BE COMBINED WITH OTHER ANTI-HBV AGENTS. *The Liver Meeting Digital Experience* 2020

68 **Bertoletti A**. ImmTAV, a New Immunotherapy Targeting the Source of HBV Infection. *Hepatology* 2020; **72**: 1514-1517 [PMID: 32865247 DOI: 10.1002/hep.31527]

69 **Fergusson JR**, Wallace Z, Connolly MM, Woon AP, Suckling RJ, Hine DW, Barber C, Bunjobpol W, Choi BS, Crespillo S, Dembek M, Dieckmann N, Donoso J, Godinho LF, Grant T, Howe D, McCully ML, Perot C, Sarkar A, Seifert FU, Singh PK, Stegmann KA, Turner B, Verma A, Walker A, Leonard S, Maini MK, Wiederhold K, Dorrell L, Simmons R, Knox A. Immune-Mobilizing Monoclonal T Cell Receptors Mediate Specific and Rapid Elimination of Hepatitis B-Infected Cells. *Hepatology* 2020; **72**: 1528-1540 [PMID: 32770836 DOI: 10.1002/hep.31503]

70 **Gane E**, Verdon DJ, Brooks AE, Gaggar A, Nguyen AH, Subramanian GM, Schwabe C, Dunbar PR. Anti-PD-1 blockade with nivolumab with and without therapeutic vaccination for virally suppressed chronic hepatitis B: A pilot study. *J Hepatol* 2019; **71**: 900-907 [PMID: 31306680 DOI: 10.1016/j.jhep.2019.06.028]

71 **Krebs K**, Böttinger N, Huang LR, Chmielewski M, Arzberger S, Gasteiger G, Jäger C, Schmitt E, Bohne F, Aichler M, Uckert W, Abken H, Heikenwalder M, Knolle P, Protzer U. T cells expressing a chimeric antigen receptor that binds hepatitis B virus envelope proteins control virus replication in mice. *Gastroenterology* 2013; **145**: 456-465 [PMID: 23639914 DOI: 10.1053/j.gastro.2013.04.047]

72 **Wisskirchen K**, Kah J, Malo A, Asen T, Volz T, Allweiss L, Wettengel JM, Lütgehetmann M, Urban S, Bauer T, Dandri M, Protzer U. T cell receptor grafting allows virological control of Hepatitis B virus infection. *J Clin Invest* 2019; **129**: 2932-2945 [PMID: 31039136 DOI: 10.1172/JCI120228]

73 **Rosen HR**. Clinical practice. Chronic hepatitis C infection. *N Engl J Med* 2011; **364**: 2429-2438 [PMID: 21696309 DOI:

10.1056/NEJMcp1006613]
74 **Armstrong GL**, Wasley A, Simard EP, McQuillan GM, Kuhnert WL, Alter MJ. The prevalence of hepatitis C virus infection in the United States, 1999 through 2002. *Ann Intern Med* 2006; **144**: 705-714 [PMID: 16702586 DOI: 10.7326/0003-4819-144-10-200605160-00004]
75 **The World Health Organization**. Global health sector strategy on viral hepatitis 2016-2021. Towards ending viral hepatitis. 2016. [cited 27 June 2021]. Available from: https://www.who.int/publications/i/item/WHO-HIV-2016.06
76 **Guerra J**, Garenne M, Mohamed MK, Fontanet A. HCV burden of infection in Egypt: results from a nationwide survey. *J Viral Hepat* 2012; **19**: 560-567 [PMID: 22762140 DOI: 10.1111/j.1365-2893.2011.01576.x]
77 **Hofmeister MG**, Rosenthal EM, Barker LK, Rosenberg ES, Barranco MA, Hall EW, Edlin BR, Mermin J, Ward JW, Ryerson AB. Estimating Prevalence of Hepatitis C Virus Infection in the United States, 2013-2016. *Hepatology* 2019; **69**: 1020-1031 [PMID: 30398671 DOI: 10.1002/hep.30297]
78 **Frank C**, Mohamed MK, Strickland GT, Lavanchy D, Arthur RR, Magder LS, El Khoby T, Abdel-Wahab Y, Aly Ohn ES, Anwar W, Sallam I. The role of parenteral antischistosomal therapy in the spread of hepatitis C virus in Egypt. *Lancet* 2000; **355**: 887-891 [PMID: 10752705 DOI: 10.1016/s0140-6736(99)06527-7]
79 **Waked I**, Esmat G, Elsharkawy A, El-Serafy M, Abdel-Razek W, Ghalab R, Elshishiney G, Salah A, Abdel Megid S, Kabil K, El-Sayed MH, Dabbous H, El Shazly Y, Abo Sliman M, Abou Hashem K, Abdel Gawad S, El Nahas N, El Sobky A, El Sonbaty S, El Tabakh H, Emad E, Gemeah H, Hashem A, Hassany M, Hefnawy N, Hemida AN, Khadary A, Labib K, Mahmoud F, Mamoun S, Marei T, Mekky S, Meshref A, Othman A, Ragab O, Ramadan E, Rehan A, Saad T, Saeed R, Sharshar M, Shawky H, Shawky M, Shehata W, Soror H, Taha M, Talha M, Tealaab A, Zein M, Hashish A, Cordie A, Omar Y, Kamal E, Ammar I, AbdAlla M, El Akel W, Doss W, Zaid H. Screening and Treatment Program to Eliminate Hepatitis C in Egypt. *N Engl J Med* 2020; **382**: 1166-1174 [PMID: 32187475 DOI: 10.1056/NEJMsr1912628]
80 **Edlin BR**, Eckhardt BJ, Shu MA, Holmberg SD, Swan T. Toward a more accurate estimate of the prevalence of hepatitis C in the United States. *Hepatology* 2015; **62**: 1353-1363 [PMID: 26171595 DOI: 10.1002/hep.27978]
81 **Zibbell JE**, Iqbal K, Patel RC, Suryaprasad A, Sanders KJ, Moore-Moravian L, Serrecchia J, Blankenship S, Ward JW, Holtzman D; Centers for Disease Control and Prevention (CDC). Increases in hepatitis C virus infection related to injection drug use among persons aged ≤30 years - Kentucky, Tennessee, Virginia, and West Virginia, 2006-2012. *MMWR Morb Mortal Wkly Rep* 2015; **64**: 453-458 [PMID: 25950251]
82 **Murphy EL**, Bryzman SM, Glynn SA, Ameti DI, Thomson RA, Williams AE, Nass CC, Ownby HE, Schreiber GB, Kong F, Neal KR, Nemo GJ. Risk factors for hepatitis C virus infection in United States blood donors. NHLBI Retrovirus Epidemiology Donor Study (REDS). *Hepatology* 2000; **31**: 756-762 [PMID: 10706569 DOI: 10.1002/hep.510310329]
83 **Stramer SL**, Glynn SA, Kleinman SH, Strong DM, Caglioti S, Wright DJ, Dodd RY, Busch MP; National Heart, Lung, and Blood Institute Nucleic Acid Test Study Group. Detection of HIV-1 and HCV infections among antibody-negative blood donors by nucleic acid-amplification testing. *N Engl J Med* 2004; **351**: 760-768 [PMID: 15317889 DOI: 10.1056/nejmoa040085]
84 **Paintsil E**, He H, Peters C, Lindenbach BD, Heimer R. Survival of hepatitis C virus in syringes: implication for transmission among injection drug users. *J Infect Dis* 2010; **202**: 984-990 [PMID: 20726768 DOI: 10.1086/656212]
85 **Mathers BM**, Degenhardt L, Phillips B, Wiessing L, Hickman M, Strathdee SA, Wodak A, Panda S, Tyndall M, Toufik A, Mattick RP; 2007 Reference Group to the UN on HIV and Injecting Drug Use. Global epidemiology of injecting drug use and HIV among people who inject drugs: a systematic review. *Lancet* 2008; **372**: 1733-1745 [PMID: 18817968 DOI: 10.1016/S0140-6736(08)61311-2]
86 **Suryaprasad AG**, White JZ, Xu F, Eichler BA, Hamilton J, Patel A, Hamdounia SB, Church DR, Barton K, Fisher C, Macomber K, Stanley M, Guilfoyle SM, Sweet K, Liu S, Iqbal K, Tohme R, Sharapov U, Kupronis BA, Ward JW, Holmberg SD. Emerging epidemic of hepatitis C virus infections among young nonurban persons who inject drugs in the United States, 2006-2012. *Clin Infect Dis* 2014; **59**: 1411-1419 [PMID: 25114031 DOI: 10.1093/cid/ciu643]
87 **Farci P**, Alter HJ, Shimoda A, Govindarajan S, Cheung LC, Melpolder JC, Sacher RA, Shih JW, Purcell RH. Hepatitis C virus-associated fulminant hepatic failure. *N Engl J Med* 1996; **335**: 631-634 [PMID: 8687517 DOI: 10.1056/nejm199608293350904]
88 **Mosley JW**, Operskalski EA, Tobler LH, Andrews WW, Phelps B, Dockter J, Giachetti C, Busch MP. Viral and host factors in early hepatitis C virus infection. *Hepatology* 2005; **42**: 86-92 [PMID: 15954090 DOI: 10.1002/hep.20742]
89 **Tillmann HL**, Thompson AJ, Patel K, Wiese M, Tenckhoff H, Nischalke HD, Lokhnygina Y, Kullig U, Göbel U, Capka E, Wiegand J, Schiefke I, Güthoff W, Grüngreiff K, König I, Spengler U, McCarthy J, Shianna KV, Goldstein DB, McHutchison JG, Timm J, Nattermann J; German Anti-D Study Group. A polymorphism near IL28B is associated with spontaneous clearance of acute hepatitis C virus and jaundice. *Gastroenterology* 2010; **139**: 1586-1592, 1592.e1 [PMID: 20637200 DOI: 10.1053/j.gastro.2010.07.005]
90 **Grebely J**, Page K, Sacks-Davis R, van der Loeff MS, Rice TM, Bruneau J, Morris MD, Hajarizadeh B, Amin J, Cox AL, Kim AY, McGovern BH, Schinkel J, George J, Shoukry NH, Lauer GM, Maher L, Lloyd AR, Hellard M, Dore GJ, Prins M; InC3 Study Group. The effects of female sex, viral genotype, and IL28B genotype on spontaneous clearance of acute hepatitis C virus infection. *Hepatology* 2014; **59**: 109-120 [PMID: 23908124 DOI: 10.1002/hep.26639]
91 **Thein HH**, Yi Q, Dore GJ, Krahn MD. Estimation of stage-specific fibrosis progression rates in chronic hepatitis C virus infection: a meta-analysis and meta-regression. *Hepatology* 2008; **48**: 418-431 [PMID: 18563841 DOI: 10.1002/hep.22375]
92 **Hajarizadeh B**, Grebely J, Dore GJ. Epidemiology and natural history of HCV infection. *Nat Rev Gastroenterol Hepatol* 2013; **10**: 553-562 [PMID: 23817321 DOI: 10.1038/nrgastro.2013.107]
93 **Desai A**, Sandhu S, Lai JP, Sandhu DS. Hepatocellular carcinoma in non-cirrhotic liver: A comprehensive review. *World J Hepatol* 2019; **11**: 1-18 [PMID: 30705715 DOI: 10.4254/wjh.v11.i1.1]
94 **US Preventive Services Task Force**; Owens DK, Davidson KW, Krist AH, Barry MJ, Cabana M, Caughey AB, Donahue K, Doubeni CA, Epling JW Jr, Kubik M, Ogedegbe G, Pbert L, Silverstein M, Simon MA, Tseng CW, Wong JB. Screening for Hepatitis C Virus Infection in Adolescents and Adults: US Preventive Services Task Force Recommendation Statement. *JAMA* 2020; **323**: 970-975 [PMID: 32119076 DOI: 10.1001/jama.2020.1123]

95 **Sulkowski MS**, Gardiner DF, Rodriguez-Torres M, Reddy KR, Hassanein T, Jacobson I, Lawitz E, Lok AS, Hinestrosa F, Thuluvath PJ, Schwartz H, Nelson DR, Everson GT, Eley T, Wind-Rotolo M, Huang SP, Gao M, Hernandez D, McPhee F, Sherman D, Hindes R, Symonds W, Pasquinelli C, Grasela DM; AI444040 Study Group. Daclatasvir plus sofosbuvir for previously treated or untreated chronic HCV infection. *N Engl J Med* 2014; **370**: 211-221 [PMID: 24428467 DOI: 10.1056/NEJMoa1306218]

96 **Kowdley KV**, Gordon SC, Reddy KR, Rossaro L, Bernstein DE, Lawitz E, Shiffman ML, Schiff E, Ghalib R, Ryan M, Rustgi V, Chojkier M, Herring R, Di Bisceglie AM, Pockros PJ, Subramanian GM, An D, Svarovskaia E, Hyland RH, Pang PS, Symonds WT, McHutchison JG, Muir AJ, Pound D, Fried MW; ION-3 Investigators. Ledipasvir and sofosbuvir for 8 or 12 weeks for chronic HCV without cirrhosis. *N Engl J Med* 2014; **370**: 1879-1888 [PMID: 24720702 DOI: 10.1056/NEJMoa1402355]

97 **Afdhal N**, Zeuzem S, Kwo P, Chojkier M, Gitlin N, Puoti M, Romero-Gomez M, Zarski JP, Agarwal K, Buggisch P, Foster GR, Bräu N, Buti M, Jacobson IM, Subramanian GM, Ding X, Mo H, Yang JC, Pang PS, Symonds WT, McHutchison JG, Muir AJ, Mangia A, Marcellin P; ION-1 Investigators. Ledipasvir and sofosbuvir for untreated HCV genotype 1 infection. *N Engl J Med* 2014; **370**: 1889-1898 [PMID: 24725239 DOI: 10.1056/NEJMoa1402454]

98 **Lawitz E**, Mangia A, Wyles D, Rodriguez-Torres M, Hassanein T, Gordon SC, Schultz M, Davis MN, Kayali Z, Reddy KR, Jacobson IM, Kowdley KV, Nyberg L, Subramanian GM, Hyland RH, Arterburn S, Jiang D, McNally J, Brainard D, Symonds WT, McHutchison JG, Sheikh AM, Younossi Z, Gane EJ. Sofosbuvir for previously untreated chronic hepatitis C infection. *N Engl J Med* 2013; **368**: 1878-1887 [PMID: 23607594 DOI: 10.1056/NEJMoa1214853]

99 **Solomon SS**, Wagner-Cardoso S, Smeaton L, Sowah LA, Wimbish C, Robbins G, Brates I, Scello C, Son A, Avihingsanon A, Linas B, Anthony D, Nunes EP, Kliemann DA, Supparatpinyo K, Kityo C, Tebas P, Bennet JA, Santana-Bagur J, Benson CA, Van Schalkwyk M, Cheinquer N, Naggie S, Wyles D, Sulkowski M. A minimal monitoring approach for the treatment of hepatitis C virus infection (ACTG A5360 [MINMON]): a phase 4, open-label, single-arm trial. *The Lancet Gastroenterology & Hepatology* 2022 [DOI: 10.1016/s2468-1253(21)00397-6]

100 **Litwin AH**, Jost J, Wagner K, Heo M, Karasz A, Feinberg J, Kim AY, Lum PJ, Mehta SH, Taylor LE, Tsui JI, Pericot-Valverde I, Page K; HERO Study Group. Rationale and design of a randomized pragmatic trial of patient-centered models of hepatitis C treatment for people who inject drugs: The HERO study. *Contemp Clin Trials* 2019; **87**: 105859 [PMID: 31669450 DOI: 10.1016/j.cct.2019.105859]

101 **Pépin J**, Abou Chakra CN, Pépin E, Nault V, Valiquette L. Evolution of the global burden of viral infections from unsafe medical injections, 2000-2010. *PLoS One* 2014; **9**: e99677 [PMID: 24911341 DOI: 10.1371/journal.pone.0099677]

102 **Bailey JR**, Barnes E, Cox AL. Approaches, Progress, and Challenges to Hepatitis C Vaccine Development. *Gastroenterology* 2019; **156**: 418-430 [PMID: 30268785 DOI: 10.1053/j.gastro.2018.08.060]

103 **Micallef JM**, Kaldor JM, Dore GJ. Spontaneous viral clearance following acute hepatitis C infection: a systematic review of longitudinal studies. *J Viral Hepat* 2006; **13**: 34-41 [PMID: 16364080 DOI: 10.1111/j.1365-2893.2005.00651.x]

104 **Osburn WO**, Fisher BE, Dowd KA, Urban G, Liu L, Ray SC, Thomas DL, Cox AL. Spontaneous control of primary hepatitis C virus infection and immunity against persistent reinfection. *Gastroenterology* 2010; **138**: 315-324 [PMID: 19782080 DOI: 10.1053/j.gastro.2009.09.017]

105 **Farci P**, Shimoda A, Wong D, Cabezon T, De Gioannis D, Strazzera A, Shimizu Y, Shapiro M, Alter HJ, Purcell RH. Prevention of hepatitis C virus infection in chimpanzees by hyperimmune serum against the hypervariable region 1 of the envelope 2 protein. *Proc Natl Acad Sci U S A* 1996; **93**: 15394-15399 [PMID: 8986822 DOI: 10.1073/pnas.93.26.15394]

106 **Bukh J**, Engle RE, Faulk K, Wang RY, Farci P, Alter HJ, Purcell RH. Immunoglobulin with High-Titer In Vitro Cross-Neutralizing Hepatitis C Virus Antibodies Passively Protects Chimpanzees from Homologous, but Not Heterologous, Challenge. *J Virol* 2015; **89**: 9128-9132 [PMID: 26085160 DOI: 10.1128/JVI.01194-15]

107 **de Jong YP**, Dorner M, Mommersteeg MC, Xiao JW, Balazs AB, Robbins JB, Winer BY, Gerges S, Vega K, Labitt RN, Donovan BM, Giang E, Krishnan A, Chiriboga L, Charlton MR, Burton DR, Baltimore D, Law M, Rice CM, Ploss A. Broadly neutralizing antibodies abrogate established hepatitis C virus infection. *Sci Transl Med* 2014; **6**: 254ra129 [PMID: 25232181 DOI: 10.1126/scitranslmed.3009512]

108 **Law M**, Maruyama T, Lewis J, Giang E, Tarr AW, Stamataki Z, Gastaminza P, Chisari FV, Jones IM, Fox RI, Ball JK, McKeating JA, Kneteman NM, Burton DR. Broadly neutralizing antibodies protect against hepatitis C virus quasispecies challenge. *Nat Med* 2008; **14**: 25-27 [PMID: 18064037 DOI: 10.1038/nm1698]

109 **Law JL**, Chen C, Wong J, Hockman D, Santer DM, Frey SE, Belshe RB, Wakita T, Bukh J, Jones CT, Rice CM, Abrignani S, Tyrrell DL, Houghton M. A hepatitis C virus (HCV) vaccine comprising envelope glycoproteins gpE1/gpE2 derived from a single isolate elicits broad cross-genotype neutralizing antibodies in humans. *PLoS One* 2013; **8**: e59776 [PMID: 23527266 DOI: 10.1371/journal.pone.0059776]

110 **Werbel WA**, Durand CM. Pro: Use of Hepatitis C Virus-Positive Donors Should Be Considered Standard of Care. *Clin Liver Dis (Hoboken)* 2018; **12**: 100-104 [PMID: 30988922 DOI: 10.1002/cld.743]

111 **Pereira BJ**, Milford EL, Kirkman RL, Levey AS. Transmission of hepatitis C virus by organ transplantation. *N Engl J Med* 1991; **325**: 454-460 [PMID: 1649402 DOI: 10.1056/nejm199108153250702]

112 **Forman LM**, Lewis JD, Berlin JA, Feldman HI, Lucey MR. The association between hepatitis C infection and survival after orthotopic liver transplantation. *Gastroenterology* 2002; **122**: 889-896 [PMID: 11910340 DOI: 10.1053/gast.2002.32418]

113 **Verna EC**, Abdelmessih R, Salomao MA, Lefkowitch J, Moreira RK, Brown RS Jr. Cholestatic hepatitis C following liver transplantation: an outcome-based histological definition, clinical predictors, and prognosis. *Liver Transpl* 2013; **19**: 78-88 [PMID: 23081888 DOI: 10.1002/lt.23559]

114 **Gasink LB**, Blumberg EA, Localio AR, Desai SS, Israni AK, Lautenbach E. Hepatitis C virus seropositivity in organ donors and survival in heart transplant recipients. *JAMA* 2006; **296**: 1843-1850 [PMID: 17047214 DOI: 10.1001/jama.296.15.1843]

115 **Haji SA**, Starling RC, Avery RK, Mawhorter S, Tuzcu EM, Schoenhagen P, Cook DJ, Ratliff NB, McCarthy PM, Young JB, Yamani MH. Donor hepatitis-C seropositivity is an independent risk factor for the development of accelerated coronary vasculopathy and predicts outcome after cardiac transplantation. *J Heart Lung Transplant* 2004; **23**: 277-283

[PMID: 15019636 DOI: 10.1016/s1053-2498(03)00148-7]
116 **Heo NY**, Mannalithara A, Kim D, Udompap P, Tan JC, Kim WR. Long-term Patient and Graft Survival of Kidney Transplant Recipients With Hepatitis C Virus Infection in the United States. *Transplantation* 2018; **102**: 454-460 [PMID: 28976413 DOI: 10.1097/TP.0000000000001953]
117 **Cohen JB**, Eddinger KC, Shelton B, Locke JE, Forde KA, Sawinski D. Effect of kidney donor hepatitis C virus serostatus on renal transplant recipient and allograft outcomes. *Clin Kidney J* 2017; **10**: 564-572 [PMID: 28852496 DOI: 10.1093/ckj/sfx048]
118 **Bowring MG**, Kucirka LM, Massie AB, Luo X, Cameron A, Sulkowski M, Rakestraw K, Gurakar A, Kuo I, Segev DL, Durand CM. Changes in Utilization and Discard of Hepatitis C-Infected Donor Livers in the Recent Era. *Am J Transplant* 2017; **17**: 519-527 [PMID: 27456927 DOI: 10.1111/ajt.13976]
119 **Kucirka LM**, Singer AL, Ros RL, Montgomery RA, Dagher NN, Segev DL. Underutilization of hepatitis C-positive kidneys for hepatitis C-positive recipients. *Am J Transplant* 2010; **10**: 1238-1246 [PMID: 20353475 DOI: 10.1111/j.1600-6143.2010.03091.x]
120 **Reese PP**, Abt PL, Blumberg EA, Goldberg DS. Transplanting Hepatitis C-Positive Kidneys. *N Engl J Med* 2015; **373**: 303-305 [PMID: 26200976 DOI: 10.1056/NEJMp1505074]
121 **Madan S**, Patel SR, Rahgozar K, Saeed O, Murthy S, Vukelic S, Sims DB, Shin JJ, Goldstein DJ, Jorde UP. Utilization rates and clinical outcomes of hepatitis C positive donor hearts in the contemporary era. *J Heart Lung Transplant* 2019; **38**: 907-917 [PMID: 31495408 DOI: 10.1016/j.healun.2019.06.023]
122 **Durand CM**, Bowring MG, Thomas AG, Kucirka LM, Massie AB, Cameron A, Desai NM, Sulkowski M, Segev DL. The Drug Overdose Epidemic and Deceased-Donor Transplantation in the United States: A National Registry Study. *Ann Intern Med* 2018; **168**: 702-711 [PMID: 29710288 DOI: 10.7326/M17-2451]
123 **Durand CM**, Bowring MG, Brown DM, Chattergoon MA, Massaccesi G, Bair N, Wesson R, Reyad A, Naqvi FF, Ostrander D, Sugarman J, Segev DL, Sulkowski M, Desai NM. Direct-Acting Antiviral Prophylaxis in Kidney Transplantation From Hepatitis C Virus-Infected Donors to Noninfected Recipients: An Open-Label Nonrandomized Trial. *Ann Intern Med* 2018; **168**: 533-540 [PMID: 29507971 DOI: 10.7326/M17-2871]
124 **Goldberg DS**, Abt PL, Blumberg EA, Van Deerlin VM, Levine M, Reddy KR, Bloom RD, Nazarian SM, Sawinski D, Porrett P, Naji A, Hasz R, Suplee L, Trofe-Clark J, Sicilia A, McCauley M, Farooqi M, Gentile C, Smith J, Reese PP. Trial of Transplantation of HCV-Infected Kidneys into Uninfected Recipients. *N Engl J Med* 2017; **376**: 2394-2395 [PMID: 28459186 DOI: 10.1056/NEJMc1705221]
125 **Schlendorf KH**, Zalawadiya S, Shah AS, Wigger M, Chung CY, Smith S, Danter M, Choi CW, Keebler ME, Brinkley DM, Sacks SB, Ooi H, Perri R, Awad JA, Lewis S, Hayes R, O'Dell H, Darragh C, Carver A, Edmonds C, Ruzevich-Scholl S, Lindenfeld J. Early outcomes using hepatitis C-positive donors for cardiac transplantation in the era of effective direct-acting anti-viral therapies. *J Heart Lung Transplant* 2018; **37**: 763-769 [PMID: 29530322 DOI: 10.1016/j.healun.2018.01.1293]
126 **Woolley AE**, Singh SK, Goldberg HJ, Mallidi HR, Givertz MM, Mehra MR, Coppolino A, Kusztos AE, Johnson ME, Chen K, Haddad EA, Fanikos J, Harrington DP, Camp PC, Baden LR; DONATE HCV Trial Team. Heart and Lung Transplants from HCV-Infected Donors to Uninfected Recipients. *N Engl J Med* 2019; **380**: 1606-1617 [PMID: 30946553 DOI: 10.1056/NEJMoa1812406]
127 **Schlendorf KH**, Zalawadiya S, Shah AS, Perri R, Wigger M, Brinkley DM, Danter MR, Menachem JN, Punnoose LR, Balsara K, Sacks SB, Ooi H, Awad JA, Sandhaus E, Schwartz C, O'Dell H, Carver AB, Edmonds CL, Ruzevich-Scholl S, Lindenfeld J. Expanding Heart Transplant in the Era of Direct-Acting Antiviral Therapy for Hepatitis C. *JAMA Cardiol* 2020; **5**: 167-174 [PMID: 31851352 DOI: 10.1001/jamacardio.2019.4748]
128 **Cotter TG**, Paul S, Sandıkçı B, Couri T, Bodzin AS, Little EC, Sundaram V, Charlton M. Increasing Utilization and Excellent Initial Outcomes Following Liver Transplant of Hepatitis C Virus (HCV)-Viremic Donors Into HCV-Negative Recipients: Outcomes Following Liver Transplant of HCV-Viremic Donors. *Hepatology* 2019; **69**: 2381-2395 [PMID: 30706517 DOI: 10.1002/hep.30540]
129 **Couri T**, Katz J, Stoeckle K, Nugooru A, Yeh H, Chung R, Paul S. Provider Attitudes toward the Use of Hepatitis C Virus-Positive Organs in Kidney Transplantation. *Am J Nephrol* 2019; **50**: 168-176 [PMID: 31390615 DOI: 10.1159/000502049]
130 **Rizzetto M**, Canese MG, Aricò S, Crivelli O, Trepo C, Bonino F, Verme G. Immunofluorescence detection of new antigen-antibody system (delta/anti-delta) associated to hepatitis B virus in liver and in serum of HBsAg carriers. *Gut* 1977; **18**: 997-1003 [PMID: 75123 DOI: 10.1136/gut.18.12.997]
131 **Hadziyannis SJ**. Review: hepatitis delta. *J Gastroenterol Hepatol* 1997; **12**: 289-298 [PMID: 9195369 DOI: 10.1111/j.1440-1746.1997.tb00424.x]
132 **Farci P**, Anna Niro G. Current and Future Management of Chronic Hepatitis D. *Gastroenterol Hepatol (N Y)* 2018; **14**: 342-351 [PMID: 30166948]
133 **Stockdale AJ**, Kreuels B, Henrion MYR, Giorgi E, Kyomuhangi I, de Martel C, Hutin Y, Geretti AM. The global prevalence of hepatitis D virus infection: Systematic review and meta-analysis. *J Hepatol* 2020; **73**: 523-532 [PMID: 32335166 DOI: 10.1016/j.jhep.2020.04.008]
134 **Lai MM**. The molecular biology of hepatitis delta virus. *Annu Rev Biochem* 1995; **64**: 259-286 [PMID: 7574482 DOI: 10.1146/annurev.bi.64.070195.001355]
135 **Popper H**, Thung SN, Gerber MA, Hadler SC, de Monzon M, Ponzetto A, Anzola E, Rivera D, Mondolfi A, Bracho A. Histologic studies of severe delta agent infection in Venezuelan Indians. *Hepatology* 1983; **3**: 906-912 [PMID: 6629319 DOI: 10.1002/hep.1840030603]
136 **Kamimura T**, Ponzetto A, Bonino F, Feinstone SM, Gerin JL, Purcell RH. Cytoplasmic tubular structures in liver of HBsAg carrier chimpanzees infected with delta agent and comparison with cytoplasmic structures in non-A, non-B hepatitis. *Hepatology* 1983; **3**: 631-637 [PMID: 6413349 DOI: 10.1002/hep.1840030502]
137 **Cole SM**, Gowans EJ, Macnaughton TB, Hall PD, Burrell CJ. Direct evidence for cytotoxicity associated with expression of hepatitis delta virus antigen. *Hepatology* 1991; **13**: 845-851 [PMID: 1709411 DOI: 10.1002/hep.1840130508]

138 **Guilhot S**, Huang SN, Xia YP, La Monica N, Lai MM, Chisari FV. Expression of the hepatitis delta virus large and small antigens in transgenic mice. *J Virol* 1994; **68**: 1052-1058 [PMID: 8289334 DOI: 10.1128/jvi.68.2.1052-1058.1994]

139 **Verme G**, Amoroso P, Lettieri G, Pierri P, David E, Sessa F, Rizzi R, Bonino F, Recchia S, Rizzetto M. A histological study of hepatitis delta virus liver disease. *Hepatology* 1986; **6**: 1303-1307 [PMID: 3793008 DOI: 10.1002/hep.1840060613]

140 **Samuel D**, Zignego A, Reynes M, Ferry C, Arulnaden JL, David M-F, Gigou M, Bismuth A, Mathieu D, Gentilini P, Benhamou J, Brechot C, Bismuth H. Long-term clinical and virological outcome after liver transplantation for cirrhosis caused by chronic delta hepatitis. *Hepatology* 1995; **21**: 333-339 [DOI: 10.1016/0270-9139(95)90089-6]

141 **Tassopoulos NC**, Koutelou MG, Macagno S, Zorbas P, Rizzetto M. Diagnostic significance of IgM antibody to hepatitis delta virus in fulminant hepatitis B. *J Med Virol* 1990; **30**: 174-177 [PMID: 2341833 DOI: 10.1002/jmv.1890300305]

142 **Abbas Z**, Afzal R. Life cycle and pathogenesis of hepatitis D virus: A review. *World J Hepatol* 2013; **5**: 666-675 [PMID: 24409335 DOI: 10.4254/wjh.v5.i12.666]

143 **Fattovich G**, Giustina G, Christensen E, Pantalena M, Zagni I, Realdi G, Schalm SW. Influence of hepatitis delta virus infection on morbidity and mortality in compensated cirrhosis type B. The European Concerted Action on Viral Hepatitis (Eurohep). *Gut* 2000; **46**: 420-426 [PMID: 10673308 DOI: 10.1136/gut.46.3.420]

144 **Romeo R**, Del Ninno E, Rumi M, Russo A, Sangiovanni A, de Franchis R, Ronchi G, Colombo M. A 28-year study of the course of hepatitis Delta infection: a risk factor for cirrhosis and hepatocellular carcinoma. *Gastroenterology* 2009; **136**: 1629-1638 [PMID: 19208358 DOI: 10.1053/j.gastro.2009.01.052]

145 **Rizzetto M**. Hepatitis D Virus: Introduction and Epidemiology. *Cold Spring Harb Perspect Med* 2015; **5**: a021576 [PMID: 26134842 DOI: 10.1101/cshperspect.a021576]

146 **Asselah T**, Loureiro D, Tout I, Castelnau C, Boyer N, Marcellin P, Mansouri A. Future treatments for hepatitis delta virus infection. *Liver Int* 2020; **40** Suppl 1: 54-60 [PMID: 32077603 DOI: 10.1111/liv.14356]

147 **Farci P**, Mandas A, Coiana A, Lai ME, Desmet V, Van Eyken P, Gibo Y, Caruso L, Scaccabarozzi S, Criscuolo D. Treatment of chronic hepatitis D with interferon alfa-2a. *N Engl J Med* 1994; **330**: 88-94 [PMID: 8259188 DOI: 10.1056/nejm199401133300202]

148 **Farci P**, Roskams T, Chessa L, Peddis G, Mazzoleni AP, Scioscia R, Serra G, Lai ME, Loy M, Caruso L, Desmet V, Purcell RH, Balestrieri A. Long-term benefit of interferon alpha therapy of chronic hepatitis D: regression of advanced hepatic fibrosis. *Gastroenterology* 2004; **126**: 1740-1749 [PMID: 15188169 DOI: 10.1053/j.gastro.2004.03.017]

149 **Erhardt A**, Gerlich W, Starke C, Wend U, Donner A, Sagir A, Heintges T, Häussinger D. Treatment of chronic hepatitis delta with pegylated interferon-alpha2b. *Liver Int* 2006; **26**: 805-810 [PMID: 16911462 DOI: 10.1111/j.1478-3231.2006.01279.x]

150 **Castelnau C**, Le Gal F, Ripault MP, Gordien E, Martinot-Peignoux M, Boyer N, Pham BN, Maylin S, Bedossa P, Dény P, Marcellin P, Gault E. Efficacy of peginterferon alpha-2b in chronic hepatitis delta: relevance of quantitative RT-PCR for follow-up. *Hepatology* 2006; **44**: 728-735 [PMID: 16941695 DOI: 10.1002/hep.21325]

151 **Kabaçam G**, Onder FO, Yakut M, Seven G, Karatayli SC, Karatayli E, Savas B, Idilman R, Bozdayi AM, Yurdaydin C. Entecavir treatment of chronic hepatitis D. *Clin Infect Dis* 2012; **55**: 645-650 [PMID: 22573857 DOI: 10.1093/cid/cis459]

152 **James G**, Sidhu P, Raza M. First report of successful clearance of hepatitis B and D coinfection with tenofovir monotherapy. *Hepatology* 2015; **62**: 317-318 [PMID: 25234819 DOI: 10.1002/hep.27446]

153 **Soriano V**, Vispo E, Sierra-Enguita R, Mendoza Cd, Fernández-Montero JV, Labarga P, Barreiro P. Efficacy of prolonged tenofovir therapy on hepatitis delta in HIV-infected patients. *AIDS* 2014; **28**: 2389-2394 [PMID: 25111082 DOI: 10.1097/QAD.0000000000000417]

154 **Wedemeyer H**, Yurdaydin C, Hardtke S, Caruntu FA, Curescu MG, Yalcin K, Akarca US, Gürel S, Zeuzem S, Erhardt A, Lüth S, Papatheodoridis GV, Keskin O, Port K, Radu M, Celen MK, Idilman R, Weber K, Stift J, Wittkop U, Heidrich B, Mederacke I, von der Leyen H, Dienes HP, Cornberg M, Koch A, Manns MP; HIDIT-II study team. Peginterferon alfa-2a plus tenofovir disoproxil fumarate for hepatitis D (HIDIT-II): a randomised, placebo controlled, phase 2 trial. *Lancet Infect Dis* 2019; **19**: 275-286 [PMID: 30833068 DOI: 10.1016/S1473-3099(18)30663-7]

155 **Wedemeyer H**, Yurdaydın C, Dalekos GN, Erhardt A, Çakaloğlu Y, Değertekin H, Gürel S, Zeuzem S, Zachou K, Bozkaya H, Koch A, Bock T, Dienes HP, Manns MP; HIDIT Study Group. Peginterferon plus adefovir versus either drug alone for hepatitis delta. *N Engl J Med* 2011; **364**: 322-331 [PMID: 21268724 DOI: 10.1056/NEJMoa0912696]

156 **Nimgaonkar I**, Ding Q, Schwartz RE, Ploss A. Hepatitis E virus: advances and challenges. *Nat Rev Gastroenterol Hepatol* 2018; **15**: 96-110 [PMID: 29162935 DOI: 10.1038/nrgastro.2017.150]

157 **Meng XJ**. Expanding Host Range and Cross-Species Infection of Hepatitis E Virus. *PLoS Pathog* 2016; **12**: e1005695 [PMID: 27490119 DOI: 10.1371/journal.ppat.1005695]

158 **Zhang J**, Zhang XF, Huang SJ, Wu T, Hu YM, Wang ZZ, Wang H, Jiang HM, Wang YJ, Yan Q, Guo M, Liu XH, Li JX, Yang CL, Tang Q, Jiang RJ, Pan HR, Li YM, Shih JW, Ng MH, Zhu FC, Xia NS. Long-term efficacy of a hepatitis E vaccine. *N Engl J Med* 2015; **372**: 914-922 [PMID: 25738667 DOI: 10.1056/NEJMoa1406011]

159 **The World Health Organization**. Waterborne Outbreaks of Hepatitis E: Recognition, Investigation, and Control. 2014. Available from: https://apps.who.int/iris/bitstream/handle/10665/129448/9789241507608_eng.pdf;jsessionid=71621FB7964A3D06CF9019A4157D9963?sequence=1

160 **Balayan MS**, Andjaparidze AG, Savinskaya SS, Ketiladze ES, Braginsky DM, Savinov AP, Poleschuk VF. Evidence for a virus in non-A, non-B hepatitis transmitted *via* the fecal-oral route. *Intervirology* 1983; **20**: 23-31 [PMID: 6409836 DOI: 10.1159/000149370]

161 **Rein DB**, Stevens GA, Theaker J, Wittenborn JS, Wiersma ST. The global burden of hepatitis E virus genotypes 1 and 2 in 2005. *Hepatology* 2012; **55**: 988-997 [PMID: 22121109 DOI: 10.1002/hep.25505]

162 **Jiménez de Oya N**, de Blas I, Blázquez AB, Martín-Acebes MA, Halaihel N, Gironés O, Saiz JC, Escribano-Romero E. Widespread distribution of hepatitis E virus in Spanish pig herds. *BMC Res Notes* 2011; **4**: 412 [PMID: 21999141 DOI: 10.1186/1756-0500-4-412]

163 **Widén F**, Sundqvist L, Matyi-Toth A, Metreveli G, Belák S, Hallgren G, Norder H. Molecular epidemiology of hepatitis E virus in humans, pigs and wild boars in Sweden. *Epidemiol Infect* 2011; **139**: 361-371 [PMID: 20546635 DOI:

10.1017/S0950268810001342]
164 **Meng XJ**, Halbur PG, Shapiro MS, Govindarajan S, Bruna JD, Mushahwar IK, Purcell RH, Emerson SU. Genetic and experimental evidence for cross-species infection by swine hepatitis E virus. *J Virol* 1998; **72**: 9714-9721 [PMID: 9811705 DOI: 10.1128/jvi.72.12.9714-9721.1998]
165 **Meng XJ**, Halbur PG, Haynes JS, Tsareva TS, Bruna JD, Royer RL, Purcell RH, Emerson SU. Experimental infection of pigs with the newly identified swine hepatitis E virus (swine HEV), but not with human strains of HEV. *Arch Virol* 1998; **143**: 1405-1415 [PMID: 9722883 DOI: 10.1007/s007050050384]
166 **Balayan MS**, Usmanov RK, Zamyatina NA, Djumalieva DI, Karas FR. Brief report: experimental hepatitis E infection in domestic pigs. *J Med Virol* 1990; **32**: 58-59 [PMID: 2122999 DOI: 10.1002/jmv.1890320110]
167 **Berto A**, Grierson S, Hakze-van der Honing R, Martelli F, Johne R, Reetz J, Ulrich RG, Pavio N, Van der Poel WH, Banks M. Hepatitis E virus in pork liver sausage, France. *Emerg Infect Dis* 2013; **19**: 264-266 [PMID: 23347828 DOI: 10.3201/eid1902.121255]
168 **Di Bartolo I**, Diez-Valcarce M, Vasickova P, Kralik P, Hernandez M, Angeloni G, Ostanello F, Bouwknegt M, Rodríguez-Lázaro D, Pavlik I, Ruggeri FM. Hepatitis E virus in pork production chain in Czech Republic, Italy, and Spain, 2010. *Emerg Infect Dis* 2012; **18**: 1282-1289 [PMID: 22840221 DOI: 10.3201/eid1808.111783]
169 **Berto A**, Martelli F, Grierson S, Banks M. Hepatitis E virus in pork food chain, United Kingdom, 2009-2010. *Emerg Infect Dis* 2012; **18**: 1358-1360 [PMID: 22840183 DOI: 10.3201/eid1808.111647]
170 **Barnaud E**, Rogée S, Garry P, Rose N, Pavio N. Thermal inactivation of infectious hepatitis E virus in experimentally contaminated food. *Appl Environ Microbiol* 2012; **78**: 5153-5159 [PMID: 22610436 DOI: 10.1128/AEM.00436-12]
171 **Hewitt PE**, Ijaz S, Brailsford SR, Brett R, Dicks S, Haywood B, Kennedy IT, Kitchen A, Patel P, Poh J, Russell K, Tettmar KI, Tossell J, Ushiro-Lumb I, Tedder RS. Hepatitis E virus in blood components: a prevalence and transmission study in southeast England. *Lancet* 2014; **384**: 1766-1773 [PMID: 25078306 DOI: 10.1016/S0140-6736(14)61034-5]
172 **Pawlotsky JM**. Hepatitis E screening for blood donations: an urgent need? *Lancet* 2014; **384**: 1729-1730 [PMID: 25078305 DOI: 10.1016/S0140-6736(14)61187-9]
173 **Hadifar S**, Sedighi M, Mostafaei S, Miri A, Amiri H, Abiri R, Babaei F, Kabir K, Moghoofei M. Prevalence of hepatitis E infection in the general population of Iran: a systematic review and meta-analysis. *Future Virology* 2017; 12 [DOI: 10.2217/fvl-2016-0112]
174 **Tavakoli A**, Alavian SM, Moghoofei M, Mostafaei S, Abbasi S, Farahmand M. Seroepidemiology of hepatitis E virus infection in patients undergoing maintenance hemodialysis: Systematic review and meta-analysis. *Ther Apher Dial* 2021; **25**: 4-15 [PMID: 32348032 DOI: 10.1111/1744-9987.13507]
175 **Suneetha PV**, Pischke S, Schlaphoff V, Grabowski J, Fytili P, Gronert A, Bremer B, Markova A, Jaroszewicz J, Bara C, Manns MP, Cornberg M, Wedemeyer H. Hepatitis E virus (HEV)-specific T-cell responses are associated with control of HEV infection. *Hepatology* 2012; **55**: 695-708 [PMID: 22006345 DOI: 10.1002/hep.24738]
176 **Pischke S**, Behrendt P, Bock CT, Jilg W, Manns MP, Wedemeyer H. Hepatitis E in Germany--an under-reported infectious disease. *Dtsch Arztebl Int* 2014; **111**: 577-583 [PMID: 25249359 DOI: 10.3238/arztebl.2014.0577]
177 **Aggarwal R**, Naik S. Epidemiology of hepatitis E: current status. *J Gastroenterol Hepatol* 2009; **24**: 1484-1493 [PMID: 19686410 DOI: 10.1111/j.1440-1746.2009.05933.x]
178 **Pérez-Gracia MT**, Suay-García B, Mateos-Lindemann ML. Hepatitis E and pregnancy: current state. *Rev Med Virol* 2017; **27**: e1929 [PMID: 28318080 DOI: 10.1002/rmv.1929]
179 **Neukam K**, Barreiro P, Macías J, Avellón A, Cifuentes C, Martín-Carbonero L, Echevarría JM, Vargas J, Soriano V, Pineda JA. Chronic hepatitis E in HIV patients: rapid progression to cirrhosis and response to oral ribavirin. *Clin Infect Dis* 2013; **57**: 465-468 [PMID: 23575198 DOI: 10.1093/cid/cit224]
180 **Tavitian S**, Péron JM, Huynh A, Mansuy JM, Ysebaert L, Huguet F, Vinel JP, Attal M, Izopet J, Récher C. Hepatitis E virus excretion can be prolonged in patients with hematological malignancies. *J Clin Virol* 2010; **49**: 141-144 [PMID: 20678959 DOI: 10.1016/j.jcv.2010.06.016]
181 **Kamar N**, Selves J, Mansuy JM, Ouezzani L, Péron JM, Guitard J, Cointault O, Esposito L, Abravanel F, Danjoux M, Durand D, Vinel JP, Izopet J, Rostaing L. Hepatitis E virus and chronic hepatitis in organ-transplant recipients. *N Engl J Med* 2008; **358**: 811-817 [PMID: 18287603 DOI: 10.1056/NEJMoa0706992]
182 **Kamar N**, Abravanel F, Selves J, Garrouste C, Esposito L, Lavayssière L, Cointault O, Ribes D, Cardeau I, Nogier MB, Mansuy JM, Muscari F, Peron JM, Izopet J, Rostaing L. Influence of immunosuppressive therapy on the natural history of genotype 3 hepatitis-E virus infection after organ transplantation. *Transplantation* 2010; **89**: 353-360 [PMID: 20145528 DOI: 10.1097/TP.0b013e3181c4096c]
183 **Kamar N**, Izopet J, Tripon S, Bismuth M, Hillaire S, Dumortier J, Radenne S, Coilly A, Garrigue V, D'Alteroche L, Buchler M, Couzi L, Lebray P, Dharancy S, Minello A, Hourmant M, Roque-Afonso AM, Abravanel F, Pol S, Rostaing L, Mallet V. Ribavirin for chronic hepatitis E virus infection in transplant recipients. *N Engl J Med* 2014; **370**: 1111-1120 [PMID: 24645943 DOI: 10.1056/NEJMoa1215246]
184 **Sinclair SM**, Jones JK, Miller RK, Greene MF, Kwo PY, Maddrey WC. The Ribavirin Pregnancy Registry: An Interim Analysis of Potential Teratogenicity at the Mid-Point of Enrollment. *Drug Saf* 2017; **40**: 1205-1218 [PMID: 28689333 DOI: 10.1007/s40264-017-0566-6]
185 **van der Valk M**, Zaaijer HL, Kater AP, Schinkel J. Sofosbuvir shows antiviral activity in a patient with chronic hepatitis E virus infection. *J Hepatol* 2017; **66**: 242-243 [PMID: 27702641 DOI: 10.1016/j.jhep.2016.09.014]
186 **Haagsma EB**, Riezebos-Brilman A, van den Berg AP, Porte RJ, Niesters HG. Treatment of chronic hepatitis E in liver transplant recipients with pegylated interferon alpha-2b. *Liver Transpl* 2010; **16**: 474-477 [PMID: 20373458 DOI: 10.1002/lt.22014]
187 **Reshetnyak VI**, Karlovich TI, Ilchenko LU. Hepatitis G virus. *World J Gastroenterol* 2008; **14**: 4725-4734 [PMID: 18720531 DOI: 10.3748/wjg.14.4725]
188 Wiwanitkit V. Hepatitis G virus RNA positivity among the voluntary blood donors: a summary. *Ann Hepatol* 2005; **4**: 43-46 [DOI: 10.1016/S1665-2681(19)32084-8]
189 **Alter HJ**, Nakatsuji Y, Melpolder J, Wages J, Wesley R, Shih JW-K, Kim JP. The Incidence of Transfusion-Associated

Hepatitis G Virus Infection and Its Relation to Liver Disease. *New England Journal of Medicine* 1997; **336**: 747-754 [DOI: 10.1056/nejm199703133361102]

190 **Alter HJ**. The cloning and clinical implications of HGV and HGBV-C. *N Engl J Med* 1996; **334**: 1536-1537 [PMID: 8618611 DOI: 10.1056/nejm199606063342310]

191 **Masuko K**, Mitsui T, Iwano K, Yamazaki C, Okuda K, Meguro T, Murayama N, Inoue T, Tsuda F, Okamoto H, Miyakawa Y, Mayumi M. Infection with hepatitis GB virus C in patients on maintenance hemodialysis. *N Engl J Med* 1996; **334**: 1485-1490 [PMID: 8618602 DOI: 10.1056/nejm199606063342301]

192 **Fried MW**, Khudyakov YE, Smallwood GA, Cong M, Nichols B, Diaz E, Siefert P, Gutekunst K, Gordon RD, Boyer TD, Fields HA. Hepatitis G virus co-infection in liver transplantation recipients with chronic hepatitis C and nonviral chronic liver disease. *Hepatology* 1997; **25**: 1271-1275 [PMID: 9141451 DOI: 10.1002/hep.510250536]

193 **Pessoa MG**, Terrault NA, Detmer J, Kolberg J, Collins M, Hassoba HM, Wright TL. Quantitation of hepatitis G and C viruses in the liver: evidence that hepatitis G virus is not hepatotropic. *Hepatology* 1998; **27**: 877-880 [PMID: 9500722 DOI: 10.1002/hep.510270335]

194 **Kanda T**, Yokosuka O, Ehata T, Maru Y, Imazeki F, Saisho H, Shiratori Y, Omata M. Detection of GBV-C RNA in patients with non-A-E fulminant hepatitis by reverse-transcription polymerase chain reaction. *Hepatology* 1997; **25**: 1261-1265 [PMID: 9141449 DOI: 10.1002/hep.510250534]

195 **Bukh J**, Kim JP, Govindarajan S, Apgar CL, Foung SK, Wages J Jr, Yun AJ, Shapiro M, Emerson SU, Purcell RH. Experimental infection of chimpanzees with hepatitis G virus and genetic analysis of the virus. *J Infect Dis* 1998; **177**: 855-862 [PMID: 9534956 DOI: 10.1086/515255]

World Journal of Gastroenterology

Submit a Manuscript: https://www.f6publishing.com

World J Gastroenterol 2022 April 14; 28(14): 1430-1443

DOI: 10.3748/wjg.v28.i14.1430

ISSN 1007-9327 (print) ISSN 2219-2840 (online)

REVIEW

Osteosarcopenia in autoimmune cholestatic liver diseases: Causes, management, and challenges

Nicola Pugliese, Ivan Arcari, Alessio Aghemo, Andrea G Lania, Ana Lleo, Gherardo Mazziotti

Specialty type: Gastroenterology and hepatology

Provenance and peer review: Invited article; Externally peer reviewed.

Peer-review model: Single blind

Peer-review report's scientific quality classification

Grade A (Excellent): 0
Grade B (Very good): B, B
Grade C (Good): 0
Grade D (Fair): 0
Grade E (Poor): 0

P-Reviewer: Filipec Kanizaj T, Croatia; Reshetnyak VI, Russia

Received: September 9, 2021
Peer-review started: September 9, 2021
First decision: November 21, 2021
Revised: December 5, 2021
Accepted: March 7, 2022
Article in press: March 7, 2022
Published online: April 14, 2022

Nicola Pugliese, Ivan Arcari, Alessio Aghemo, Andrea G Lania, Ana Lleo, Gherardo Mazziotti, Department of Biomedical Sciences, Humanitas University, Pieve Emanuele 20090, Milan, Italy

Nicola Pugliese, Ivan Arcari, Alessio Aghemo, Ana Lleo, Division of Internal Medicine and Hepatology, Department of Gastroenterology, IRCCS Humanitas Research Hospital, Rozzano 20089, MI, Italy

Andrea G Lania, Gherardo Mazziotti, Department of Endocrinology, Diabetology and Medical Andrology Unit, IRCCS Humanitas Research Hospital, Rozzano 20089, MI, Italy

Corresponding author: Ana Lleo, MD, PhD, Professor, Department of Biomedical Sciences, Humanitas University, Via Rita Levi Montalcini 4, Pieve Emanuele 20090, Milan, Italy. ana.lleo@humanitas.it

Abstract

Primary biliary cholangitis and primary sclerosing cholangitis (PSC) are the most common cholestatic liver diseases (CLD) in adults and are both characterized by an immune pathogenesis. While primary biliary cholangitis is a model autoimmune disease, with over 90% of patients presenting very specific autoantibodies against mitochondrial antigens, PSC is considered an immune mediated disease. Osteoporosis is the most common bone disease in CLD, resulting in frequent fractures and leading to significant morbidity. Further, sarcopenia is emerging as a frequent complication of chronic liver diseases with a significant prognostic impact and severe implications on the quality of life of patients. The mechanisms underlying osteoporosis and sarcopenia in CLD are still largely unknown and the association between these clinical conditions remains to be dissected. Although timely diagnosis, prevention, and management of osteosarcopenia are crucial to limit the consequences, there are no specific guidelines for management of osteoporosis and sarcopenia in patients with CLD. International guidelines recommend screening for bone disease at the time of diagnosis of CLD. However, the optimal monitoring strategies and treatments have not been defined yet and vary among centers. We herein aim to comprehensively outline the pathogenic mechanisms and clinical implications of osteosarcopenia in CLD, and to summarize expert recommendations for appropriate diagnostic and therapeutic approaches.

Key Words: Cholestatic liver diseases; Primary biliary cholangitis; Primary sclerosing

cholangitis; Osteoporosis; Sarcopenia

Core Tip: Cholestatic liver diseases (CLD) in adults are characterized by an immune pathogenesis. Osteoporosis is the most common bone disease in CLD, resulting in frequent fractures and leading to significant morbidity. Sarcopenia is emerging as a frequent complication with a significant prognostic impact and severe implications on the quality of life of patients. The lack of useful preventive measures and efficacious treatment strategies remains one of the largest challenges in the management of patients with CLD.

Citation: Pugliese N, Arcari I, Aghemo A, Lania AG, Lleo A, Mazziotti G. Osteosarcopenia in autoimmune cholestatic liver diseases: Causes, management, and challenges. *World J Gastroenterol* 2022; 28(14): 1430-1443
URL: https://www.wjgnet.com/1007-9327/full/v28/i14/1430.htm
DOI: https://dx.doi.org/10.3748/wjg.v28.i14.1430

INTRODUCTION

Cholestatic liver diseases (CLD) are characterized by progressive inflammation, damage, and destruction of bile ducts that lead to liver damage and, eventually, liver cirrhosis and systemic alterations. Accumulation of bile acids within liver cells cause detergent-induced damage of cellular membranes, which ultimately determines the development of apoptosis, inflammation, necrosis, fibrosis, and carcinogenesis[1,2]. Primary biliary cholangitis (PBC) and primary sclerosing cholangitis (PSC) are the most common CLD in adults. Although PBC is considered a classic autoimmune disease with nearly 95% of patients presenting very specific autoantibodies against mitochondrial antigens, PSC is recognized as an immune-mediated disease, with immunogenetic features and a strong association with inflammatory bowel disease (IBD). Both PBC and PSC are associated with a vast group of extrahepatic manifestations, including, but not limited to, fatigue, low bone mass, and other autoimmune diseases such as IBD, systemic sclerosis, and Sjogren syndrome[2,3].

Bone disease, including osteopenia and osteoporosis, is a common complication of CLD. Osteoporosis is characterized by a decreased bone density that leads to an increased risk of fractures. It increases morbidity and mortality in patients, and it is four times more common in patients with PBC compared to gender and age-matched controls. Moreover, sarcopenia and skeletal frailty have recently emerged as frequent complications of CLD, leading to severe morbidity, worse clinical outcome of disease, and lower quality of life of patients. The burden of osteosarcopenia in patients with CLD remains significant and therefore prevention is essential. In recent years, there have been advances in elucidating the risk factors and pathogenetic mechanisms underlying osteoporosis and sarcopenia in CLD but, unfortunately, validated diagnostic and therapeutic guidelines are not yet available. This review focuses on the pathogenic mechanisms and clinical implications of osteosarcopenia in CLD and summarizes expert recommendations for appropriate diagnostic and therapeutic approaches.

OSTEOPENIA AND OSTEOPOROSIS

The World Health Organization (WHO) defines osteoporosis as a skeletal disorder characterized by compromised bone strength predisposing to an increased risk of fracture. In clinical practice, this condition is diagnosed using dual X-ray absorptiometry (DXA) for measurement of bone mineral density (BMD) at the lumbar spine, femoral neck, and total hip. In individuals older than 50 years of age and post-menopausal women, skeletal demineralization is graded based on comparisons of patient's BMD with the average for young adults, after adjusting for race and gender. A T-score less than or equal to −2.5 standard deviations (SD) at the hip or spine is defined as osteoporosis, whereas osteopenia is defined as a T-score between −1 and −2.5 SD. These densitometric definitions cannot be applicable for younger subjects in whom the Z-score (*i.e.*, the number of SD from age-matched controls) of 2.0 or lower is used to define a BMD "below the expected range for age"[4]. Although low BMD is consistently correlated with an increased fracture risk in the general population, fragility fractures may develop even in the context of normal BMD especially in subjects with secondary osteoporosis, in whom bone quality is affected more than bone quantity[5]. In these cases, evaluation of trabecular and cortical bone microstructure by high-resolution peripheral computed tomography can provide more reliable information on risk of fractures[6]. In the United States and Europe, the estimated number of

osteoporosis-related hip fractures is about 0.3 and 1.7 million *per* year, respectively. More relevant is the impact of vertebral fractures (VFs) that have been consistently reported as an earlier and frequent complication of osteoporosis in the general population potentially associated with decreased survival and impaired quality of life[7-9].

Osteomalacia, defined by a reduction in bone mineralization with a preserved bone mass, was once thought to play a primary role in increasing fracture risk in patients with CLD[10], but more recent studies have proven that it is rarely associated with liver diseases, as it has been only reported in patients with advanced PBC and severe intestinal malabsorption associated with limited exposure to sunlight[11]. However, skeletal fragility can be associated with a worse outcome in patients with liver disease, as it entails an increased risk of fractures and consequently an overall increased disability prevalence and reduced quality of life[12].

Although osteoporosis is associated with liver diseases including cirrhosis, it is most prevalent in cholestatic disorders[13]. Most of the studies that try to understand the relationship between the bone and liver have focused on PBC, though the pathophysiological mechanisms likely overlap in the case of end-stage liver disease from other etiologies. These mechanisms are numerous and not fully elucidated (Figure 1). The predominant process determining the reduction in bone mass appears to be a reduction in bone formation[11,13], although it seems that in some cases an increase in bone resorption is also involved, such as in post-menopausal women and patients with hypogonadism[14-16]. Bone formation, mediated by osteoblasts, and bone resorption, dependent on osteoclasts, are the two opposite processes that influence bone mass: When resorption exceeds formation, bone mass inevitably decreases and this negative balance leads to bone loss and osteoporosis. Osteoblast dysfunction may be directly linked to elevated serum levels of bile acids and bilirubin[17]. Some *in vitro* studies showed that lithocholic acid (LCA), a monohydroxylated secondary bile acid, can negatively influence osteoblasts' activity, both directly and indirectly through the ligation to vitamin D receptor (VDR) and the successive modification of expression of VDR-mediated genes, such as receptor activator for nuclear factor kappa B (NF-kB) ligand (RANKL) and bone gamma-carboxyglutamate protein, which serve as a regulator of osteoclast and osteoblast maturation, respectively[18]. Curiously, it appears that albumin, when added to cultures of osteoblasts exposed to LCA, can reduce the toxic effects of the molecule on the osteoblasts. It could be hypothesized that the amount of circulating albumin is one of the critical factors linked to the harmful effects on bone of circulating bile acids[11], but data regarding this association are still lacking. Osteoblast dysfunction can also depend on the reduced circulating levels of osteoblast stimulating factors such as insulin-like growth factor 1 (IGF1) secondary to the lack of hepatic synthesis seen in advanced chronic liver disease (ACLD) and reduced absorption[19,20], respectively. IGF1 acts directly on bone to promote longitudinal growth during the development phase and maintain adequate levels of bone mass once peak bone mass is reached[21]. Liver diseases impair the somatotropic axis and associate with liver growth hormone (GH) resistance; the consequent reductions in serum IGF1 can contribute to impair osteoblast function and cause skeletal fragility in individuals with CLD[21,22]. In this context, the role of paracrine and autocrine actions of locally produced IGF1 in the skeleton under control of parathyroid hormone (PTH) is unknown and in need of future studies[21].

In patients with PBC, low liver tissue and serum levels of RANKL and high levels of osteoprotegerin (OPG) have been previously reported[23-25]. This is at first glance unexpected, since OPG has a bone preserving function while RANKL activates osteoclastogenesis and tends to increase bone loss. However, RANKL can be interpreted both as a marker of bone resorption and as a marker of osteoblasts activity: Low RANKL would therefore indicate low osteoblast activity and a reduced bone turnover, which inevitably leads to increased bone fragility and risk of fractures[26]. High OPG levels on the other hand could indicate the homeostatic response attempting to prevent bone loss. Finally, the importance of osteoblast dysfunction has been proved by a series of studies that evaluated bone histomorphometry in patients with advanced CLD undergoing orthotopic liver transplant (OLT). In these studies, osteoblast numbers and bone formation rates appear to be decreased when compared to controls[27,28]. This data correlates with the low levels of osteocalcin, a non-collagenous marker of bone formation, seen in patients with cholestasis[29]: Two different studies observed that osteocalcin levels were decreased in up to 74% of PBC patients[30,31]. However, a previous study has revealed that increased bone resorption and turnover showed by bone histomorphometry are early characteristics of PBC-related bone disease[32]. More studies are needed to evaluate the variation of bone formation and bone resorption markers and to link them to cholestasis. An exemplary study on PBC patients showed no significant decrease in the levels of bone-specific alkaline phosphatase, a bone formation marker, but up to 95% of patients showed above-normal values; also, no significant variation was observed in the urine levels of type I collagen-cross-linked N-telopeptide, a marker of bone resorption[33]. Although it seems reasonable to think that a defect in the secretion of bile acids leads to reduced intestinal absorption of vitamin D, thus leading to hypocalcemia and secondary hyperparathyroidism, data in this regard are conflicting and not conclusive. Old studies have found decreased calcium absorption and serum vitamin D levels in PBC patients[34], but others have found normal vitamin D, calcium, and PTH levels even among osteoporotic patients with PBC[27,35]. It also appears that vitamin D supplementation in patients with cholestasis and malabsorption is unable to significantly improve BMD[36,37], although some old studies proved otherwise[34].

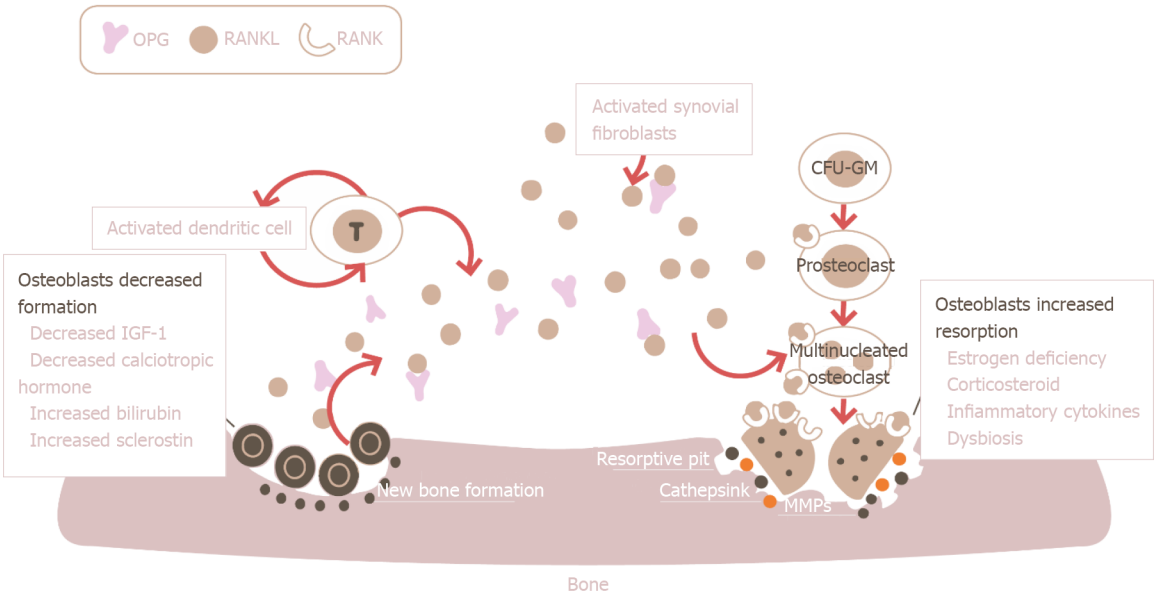

DOI: 10.3748/wjg.v28.i14.1430

Figure 1 Possible pathophysiological mechanisms of development of osteoporosis in cholestatic diseases. The figure describes the role of multiple factors linked to cholestatic diseases in the development of osteoporosis. Emphasis is placed on the difference between factors that cause osteoblasts dysfunction and factors that cause increased osteoclasts activity. OPG: Osteoprotegerin; RANK: Receptor activator for nuclear factor kappa B; RANKL: Receptor activator for nuclear factor kappa B ligand; IGF-1: Insulin-like growth factor 1; CFU-GM: Granulocyte-macrophage-colony forming unit; MMPs: Matrix Metalloproteinases.

Since the main risk factors for the development of osteoporosis in OLT patients are pre-transplant bone mass state and pre-transplant fragility fractures, it is not surprising that cirrhotic patients who undergo liver transplant for PBC and PSC are at an extremely high risk of developing osteoporosis and suffering pathological fractures. Osteoporosis is a primary co-morbidity in post-transplant patients and is becoming more and more relevant, as their longtime survival has significantly increased in the last few years. In these patients, there is a rapid bone loss within the first 3 to 6 mo after transplantation and a frequency of fragility fractures of about 21%, most of which happen in the first period after transplant [38]. A study reported that the severity of bone loss was more frequently seen in patients of younger age with PSC, higher pretransplant BMD, no IBD, shorter duration of disease, current smoking, and ongoing cholestasis at 4 mo since OLT[39]. An important contributing cause of rapid bone loss in the immediate postoperative period of these patients is probably the use of high doses of corticosteroids and other immunosuppressive agents, such as tacrolimus and cyclospirn A, as well as immobilization during hospitalization after OLT[40]. After the first 3 to 6 postoperative months, bone gain occurs during the first 2 years with favoring factors for improvement of lower baseline and/or 4-mo BMD, premenopausal status for females, lesser glucocorticoids, no ongoing cholestasis, and higher levels of vitamin D and parathyroid function[39].

SARCOPENIA

Sarcopenia, a progressive and generalized loss of skeletal muscle mass, strength, and function, is the other side of the coin of the metabolic abnormality in patients with liver disease[41]. It can be assessed in numerous ways, such as by bioelectrical impedance analysis or DXA, but the recommended method is by measuring anthropometric parameters, such as skeletal muscle area (SMA) and the Skeletal Muscle Index (SMI), by computed tomography and magnetic resonance imaging[42,43]. SMI is the metric recommended by the International Consensus panel on cachexia. It is the result of SMA (cm^2) depicted on a single image slice [usually at the level of the third lumbar vertebra (L3)], adjusted by the height of the patient (m^2) (this is often referred to as L3SMI method). This measurement can be easily compared to specific cut-off values based on healthy European young adults[44]. Importantly, sarcopenia is significantly associated with mortality and reduced quality of life in patients with liver cirrhosis[45,46].

Although recent data demonstrate that sarcopenia can be identified in up to 70% of cirrhotic patients [47], no data are available on the prevalence of sarcopenia in non-advanced cholestatic diseases. An outstanding study has recently been published analyzing the relationship between PBC, bone diseases, and sarcopenia[48]. Saeki *et al*[48] demonstrated that the association between osteoporosis and sarcopenia was stronger than the association among osteoporosis, female gender, and menopause in PBC patients, and *vice versa* osteoporosis and VFs were important risk factors for sarcopenia,

independently of sex and menopause[48]. The increasing evidence of the existing association between bone mass and muscle loss, defined all together as osteosarcopenia, is of incredible relevance in liver diseases, given that it impacts the prognosis and health-related quality of life. The association of the two conditions is particularly hazardous, since it causes both ease of falling (due to sarcopenia) and bone vulnerability (due to osteoporosis)[49]. More data are, however, needed to fully comprehend the real impact of sarcopenia on non-advanced CLD. At the moment, the only considerations that can be made are based on studies on cirrhotic patients, in which, however, it appears that the main mechanism is linked to hyperammonemia, a phenomenon not present in the early stages of cholestatic diseases[50]. The role of cholestasis in sarcopenia in cirrhotic patients is only hinted at and remains anecdotal. Protein synthesis, protein breakdown, and muscle regenerative capacity mediated by satellite cells are the main processes that influence skeletal muscle mass: When their balance is disrupted, there is a loss in lean mass leading to sarcopenia. Skeletal muscle expression and serum levels of myostatin, a member of the TGFβ superfamily, are increased in patients with ACLD[51,52] and this hormone increases autophagy and proteolysis and prevents protein synthesis by inhibiting the mTORC1 pathway. Serum ammonia has been recognized as a stimulus in the synthesis of myostatin, by acting *via* a NF-kB mediated mechanism[53-55]. Hyperammonemia also impairs the formation of α-ketoglutarate (αKG), a molecule involved in the cycle of tricarboxylic acids (TCA)[53]. This results in several potential consequences including lower flux of the TCA cycle, impaired mitochondrial function, and decreased ATP synthesis. Since protein synthesis is an energy intense process, low ATP concentrations may also cause reduced protein synthesis. Similarly to hyperammonemia, hypoglycemia and low glucose levels in skeletal muscle cells are linked to the lack of glycogenolysis secondary to the reduction of hepatic glycogen stores, and can lead to the consumption of muscle amino acids for the production of energy[56]. Although hyperammonemia does not manifest itself in non-advanced CLD, the mechanisms leading to sarcopenia may be in some way analogous. Liver damage caused by the underlying pathology, malabsorption, and increased energy demands may lead to an energy deficit that would push the skeletal muscles to use amino acids as an alternative source of energy, in a similar way to how it occurs in case of hypoglycemia due to reduced hepatic glycogen reserve[57].

PREVALENCE AND DETERMINANTS OF OSTEOSARCOPENIA IN CLD

PBC

PBC is a chronic inflammatory autoimmune cholestatic liver disease which, if left untreated, could culminate in end-stage biliary cirrhosis[58]. It is the most studied condition as regards metabolic bone disease, both for the high prevalence of osteoporosis in PBC patients and for the possibility of directly studying the pathophysiological mechanisms underlying the interaction between cholestasis and reduction in bone mass.

Osteoporosis is a common complication of PBC, with the most recent studies reporting a prevalence ranging from 20% to 45%, four-fold higher than that in the general population[59,60], with the highest prevalence in patients with cirrhosis on the liver transplant list[39]. Accordingly, the incidence and prevalence of fractures are also increased in PBC patients, ranging from 0% to 14% over a 2-year period and from 9% to 22%, respectively[61]. In a prospective study, Guañabens *et al*[62] observed a prevalence of vertebral, non-vertebral, and overall fractures of 11.2%, 12.2%, and 20.8%, respectively (Table 1). In that study, more than 20% of fractures occurred without a densitometric diagnosis of osteoporosis consistent with the pathophysiological concept that alteration of osteoblastogenesis and bone formation in CLD may induce impairment of bone quality more than bone quantity as in other forms of secondary osteoporosis. In addition to the common risk factors associated with skeletal fragility, such as age and post-menopausal state, additional independent risk factors have been identified in patients with PBC. The most prominent risk factor for developing osteoporosis is the stage of the disease. A study based on histologic staging observed that patients with more advanced histologic stages (such as stage 3 or 4) had more than a 5-fold increased risk of developing osteoporosis than patients with an earlier stage of the disease and the rate of bone loss over time was significantly greater in the former as compared with the latter[63]. A more recent study observed that liver stiffness measured by FibroScan was directly related with the reduction of both cortical and trabecular bone parameters in the tibia and distal radius[64]. The stage of disease appears to have an effect far stronger than the post-menopausal state in PBC patients [65]. Other less important risk factors that seem to have been identified include female gender, the necessity of transplant and, to some extent, genetic predisposition[58,66]. Indeed, some studies identified some gene loci that positively correlate with osteoporosis[67-69]. Although vitamin D does not seem to play an important role in determining skeletal fragility in CLD, polymorphisms of VDR have been associated with osteoporosis in individuals with PBC. One study in women affected by PBC concluded that VDR genotype is an independent genetic predictor of osteoporosis[67]. In addition, a polymorphism of the gene encoding collagen type I alpha1 (COLIA1), Sp1, is associated with reduced baseline BMD in patients with PBC[69]. Lastly, some polymorphisms of a tight junction membrane gene, the claudin-14 (CLDN-14), suspected to be involved in the pathogenesis of CLD, has been proved to be associated with low BMD in PBC patients[70].

Table 1 Prevalence of osteoporosis and fractures according to the severity and stage of primary biliary cholangitis

Ref.	N of patients	Age (yr) mean	Female (%)	Diagnosis	Osteoporosis (%)	Vertebral fractures (%)	Peripheral fractures (%)	Overall fractures (%)	Cirrhosis (%)
Guañabens *et al* [114]	38	51	100	DPA	45	13	NR	13	94
Parés *et al*[68]	61	54	100	DXA	21	10	10	13	26
Guañabens *et al* [65]	142	54	100	DXA	31	14	11	14	26
Guichelaar *et al* [39]	156	53	86	DXA	44	22	NR	22	100
Guañabens *et al* [62]	185	56	100	DXA	32	11	12	21	23
Solaymani-Dodaran *et al* [115]	930	NR	88	NR	NR	NR	7.4	14.7	31

NR: Not reported; DXA: Dual-energy X-ray absorptiometry; DPA: Dual-photon absorptiometry.

Another important independent risk factor is low body mass index (BMI). Beyond the direct association of reduced muscle mass and low bone mass, it seems that in PBC patients, preponderant hormonal mechanisms associated with BMI come into play: Leptin, an adipocyte derived hormone, seems to indirectly regulate bone metabolism since it increases osteoblast proliferation and bone matrix synthesis, resulting in increased bone formation, and inhibits RANKL production, decreasing bone resorption. Szalay *et al*[71] observed decreased leptin levels in PBC patients and also demonstrated a positive correlation between leptin, BMI, and BMD[71].

Although sarcopenia is a fascinating new topic in hepatology and has been recently studied in ACLD patients, very few data are available on its relationship with PBC in non-cirrhotic patients. The only article available in the literature at the time of writing this review has been previously cited and dates back to May 2020[48]. Saeki *et al*[48] reported the prevalence of sarcopenia, diagnosed according to the Japan Society of Hepatology guidelines[48,72], between PBC patients: 23.1% for all patients and 25% for female patients, greater than in other non-cirrhotic liver conditions, where the prevalence was reported to be approximately 15%[73,74]. These findings suggest that patients with PBC are more susceptible to sarcopenia, compared to those with other chronic liver diseases. This study also proved that sarcopenia is strongly correlated with osteoporosis and increased fracture risk (especially VFs) and *vice versa*, proving that osteosarcopenia as a unified clinical entity is an important complication of PBC, occurring in up to 15.4% of patients, requiring careful monitoring in all patients, especially post-menopausal women, who represent the majority of PBC patients. The clinical relevance of osteosarcopenia has been proven in studies focused on geriatric patients, in which the osteosarcopenic group had greater impairment of physical performance and balance than the non-osteosarcopenic and sarcopenia/osteoporosis alone groups. Consequently, osteosarcopenia conferred an increased rate of falls and fractures and a consequent higher mortality rate[75-77]. Despite the clinical relevance, recommendations on follow-up and treatment cannot yet be made, as these aspects are still in the early stages of definition [78].

PSC

PSC is a chronic, cholestatic liver disease characterized by immune-mediated inflammation and fibrosis of both intrahepatic and extrahepatic bile ducts, leading to the formation of multifocal bile duct strictures and to the development of biliary cirrhosis[79]. Although it is a clinical entity of considerable interest, both for its hepatological implications and for the set of clinical conditions with which it is associated, there are still very few studies that focus on the link between PSC and bone disease, and almost none that investigate a possible relationship of PSC with sarcopenia.

As with other chronic liver diseases, the prevalence of osteoporosis in PSC is higher than that of the general population, accounting for 15%–30% of patients with PSC[80,81]. General risk factors include female gender, age, and low BMI. Studies are still needed to evaluate if duration of the disease is a risk factor and, curiously, osteoporosis does not appear to be related to the severity of the underlying PSC [27]. Although previous studies reported a possible association between osteoporosis and the stage of disease[82,83], more recent studies observed otherwise and failed to prove a significance correlation between osteoporosis and the severity of liver disease. It is possible that this difference is based on population cohorts analyzed, since in previous studies the patients were less heterogeneous and predominantly post-menopausal women[84]. Moreover, the close association between PSC and IBD [85], the consequent malabsorption, and the possible use of steroid therapy at high doses for long

periods of time can certainly influence bone metabolism and represent an important risk factor for the development of osteoporosis. In addition, patients with IBD presents themselves with a lower bone mass at the diagnosis[86], likely due to the systemic inflammatory state of IBD.

No conclusive data are yet available regarding the possible relationship between PSC and sarcopenia but, considering the cholestasis-associated malabsorption, which may be worsened by the eventual concomitant IBD related to PSC, and the increased prevalence of sarcopenia in patients with other liver diseases including PBC, it is reasonable to assume that these patients also have an increased prevalence of sarcopenia compared to the general population that should be investigated at the time of diagnosis and during the follow-up. Interestingly, Shteyer *et al*[87] failed to prove a significant difference between pediatric patients with PSC and the control group; also, children and young adults with concomitant PSC and IBD appeared to have lesser degree of sarcopenia in comparison to patients with PSC alone [87]. Although interesting, larger studies are required to confirm these curious findings.

MANAGEMENT OF OSTEOSARCOPENIA IN CLD

Osteoporosis

Management of osteoporosis in cholestatic diseases cannot be evidence-based and no guidelines have been developed for diagnosis and treatment of osteoporosis in this specific clinical setting. However, based on our personal experience and the few studies so far published on the topic, some recommendations could be provided (Table 2). DXA measurement of BMD should be performed at the initial diagnosis of PBC to identify subjects with low BMD at higher risk of fractures.

The optimal timing of monitoring PBC patients is yet to be defined, but in clinical practice bone densitometry with DXA should be performed, depending on the presence of risk factors for osteoporosis and fractures, in 1 to 3 years if initial results are normal. A more stringent follow-up is indicated in the presence of altered BMD or risk factors such as severe cholestasis, menopause before the age of 45 years old, family history of osteoporosis or fragility fractures, BMI less than 19 kg/m^2, tobacco use, heavy alcohol abuse, and glucocorticoid use greater than 3 mo and or > 5 mg daily. In patients who are already on osteoporosis treatment, DXA should be performed annually to assess treatment response. In addition to imaging, routine monitoring of vitamin D, calcium, phosphorus, and PTH should be performed every 1 to 2 years based on the current risk of developing bone disease[58,61].

Over the last decade, several algorithms (*e.g.*, FRAX) have been proposed to improve the value of DXA results in predicting fracture risk[88] but their use in secondary osteoporosis in general and in CLD in particular has not been validated. Noteworthy, the traditional risk factors of osteoporosis and fractures included in the algorithm FRAX seem to have a role also in influencing the occurrence of fragility fractures in subjects with CLD.

The new generation DXA machines can also provide information on bone quality. For instance, the trabecular bone score (TBS) is a texture parameter obtained directly from DXA images through the evaluation of the average pixel gray-scale variation. A low TBS value correlates with a weaker microarchitecture with reduced and scarcely interconnected trabeculae, resulting in lower bone strength and mechanical resistance[89]. Measuring this parameter, the clinicians may have another reliable information on risk of fractures even in individuals with either normal or only slightly decreased BMD [90].

As in other forms of secondary osteoporosis, the search of VFs is indicated in all subjects at diagnosis of CLD since they may occur even in the context of normal BMD. In more than 55% of the cases, VFs occur without specific clinical symptoms and the radiological and morphometric approach has emerged as the method of choice for evaluating the true prevalence and incidence of these fractures in the clinical practice. VFs are identified by marking the vertebral body with six points to describe the vertebral shape and heights. According to the quantitative morphometric approach, VFs are defined mild, moderate, and severe based on a height ratio decrease of 20%-25%, 25%-40%, and more than 40%, respectively[91]. VFs are routinely assessed by examining lateral projection images of conventional spine X-ray radiographs, although other approaches using DXA and the low-dose biplane X-ray imaging system (EOS imaging, Paris, France) have been proposed as alternative tools to limit radiation exposure in clinical practice[92,93]. The current guidelines indicate that finding of non-traumatic VFs, regardless of underlying disease and BMD values, is sufficient to establish the diagnosis of osteoporosis and to consider pharmacologic treatment as secondary prophylaxis[94].

Bone active agents used to treat osteoporosis are classified as anti-resorptive and anabolic drug[95]. Bisphosphonates inhibit bone resorption and are the most prescribed drugs for the treatment of osteoporosis. Denosumab is a human monoclonal antibody (IgG2 immunoglobulin isotype) binding RANKL with high affinity and specificity and inducing a reversible inhibition of osteoclastogenesis and bone resorption. Teriparatide is the 1-34 active fragment of PTH with stimulating effects on osteoblastogenesis and bone formation when intermittently administered once daily. Teriparatide is currently the only anabolic drug approved for treatment of osteoporosis at high risk of fractures and for glucocorticoid-induced osteoporosis.

Table 2 General expert recommendations for management of osteosarcopenia in patients with cholestatic liver diseases

Risk for osteoporosis should be considered in all patients with cholestatic liver diseases	
DXA should be considered to assess BMD at presentation and at follow-up where indicated	T-score > -1.5 - > repeat in 2-3 yr Osteopenia, T-score ≤ -1.5 but > -2.5, or presence of risk factors - > repeat in 1-2 yr Osteoporosis, T score ≤ -2.5, or pathological fractures with normal BMD - > repeat in one year
VFs should be investigated at presentation with lateral spine X-rays radiograph in all patients with cholestatic liver diseases	
Alcohol and smoking cessation in addition to increasing aerobic exercise and practicing routine weight-bearing exercises are highly recommended in all patients with cholestatic liver diseases	
Consider including supplements of 25-(OH)-vitamin D (800 IU daily) and calcium (1000–1500 mg daily) in patients with cholestatic liver disease and osteopenia or osteoporosis	
Consider utilizing bisphosphonates in patients with osteoporosis and patients with VFs, regardless of underlying disease and BMD values	
For patients with PBC, denosumab might have a beneficial role both for osteoporosis treatment and for PBC but data are scarce, and recommendation cannot be made yet	
Consider evaluating sarcopenia by cross-sectional imaging when strong clinical suspicion is present in all patients with cholestatic liver diseases	
Consider exercise programs and adequate nutritional and caloric intake in all patients with sarcopenia and cholestatic liver diseases	

DXA: Dual-energy X-ray absorptiometry; BMD: Bone mineral density; VFs: Vertebral fractures; PBC: Primary biliary cholangitis.

Data on the efficacy and safety of bone-active drugs in CLD are scant and their use in this clinical setting can be guided by evidence extrapolated from the literature on the treatment of postmenopausal osteoporosis[96]. A comprehensive Cochrane systematic review published in 2011 concluded that there are no conclusive data showing the benefits of bisphosphonate use on BMD, mortality, or reduced fracture risk in this specific clinical context[97]. There is only one randomized clinical trial that compares newer generation bisphosphonates (in this case alendronate) to placebo in PBC[98]: It proved that after 1 year, there was a significant improvement in lumbar spine BMD in patients treated with bisphosphonates (10.4% *vs* –0.12% in patients in the placebo arm, $P < 0.005$) but failed to prove a significant reduction in fractures (0% *vs* 7.1% in patients in the placebo arm, $P = 0.3$)[98]. Particular attention must be given to patients with ACLD with a high risk of oesophageal varices since esophagitis and oesophageal ulcers are side-effects of oral bisphosphonates. In these patients, parenteral bisphosphonates can be proposed[99,100].

Preliminary data on denosumab in patients with PBC indicate that lumbar spine T-score significantly improved after 1 and 3 years of treatment, along with levels of markers of bone formation, despite that the prevalent mechanism determining osteoporosis is osteoblast dysfunction[101,102]. As the studies are extremely small, no recommendations can be made yet, but certainly the use of denosumab in these patients is promising. Importantly, recent evidence strengthens a critical role of RANK/RANKL signaling in autoimmunity besides bone density, with the immune and skeletal systems being closely interconnected. It has been demonstrated that cholangiocytes from PBC patients express high levels of RANK; most importantly, the immune infiltrates within the portal areas around bile ducts in PBC are highly RANKL positive and the hepatic level of RANKL was associated with disease severity[25]. Lleo *et al*[25] hypothesized that damaged cholangiocytes in PBC, which show high levels of RANK, determine the recruitment of RANKL positive cells and consequently portal tract infiltrates. Taken all together, a number of recent and old evidence point out that denosumab might have a beneficial role in PBC therapy, besides osteoporosis, but data are scarce and more studies are needed to make recommendation[25].

No data are available on the efficacy and safety of teriparatide and PTH-analogues but, whereas the main pathogenetic mechanism that determines the development of osteoporosis in patients with PBC is reduced osteoblasts activity, osteoanabolic agents could play a crucial role in the treatment of the condition in this setting.

Inactivity, alcohol consumption, tobacco use, and reduced dietary calcium intake can all lead to reduced bone density. For this reason, alcohol and smoking cessation in addition to increasing aerobic exercise and practicing routine weight-bearing exercises is highly recommended. Dietary supplementation of calcium (1000-1500 mg daily) and vitamin D [800 international units (IU) daily] is also recommended in patients who are at particularly high risk of developing osteoporosis, especially in patients with ACLD[58,103]. Patients receiving cholestyramine should be monitored closely since its

administration may reduce intestinal absorption of vitamin D[104,105]. Although this is standard clinical practice, data on the effect of calcium and vitamin D supplementation are controversial: As previously stated, some studies prove a significant improvement in BMD[34] while other studies failed to do so[36,37].

It is important to assess the presence of osteoporosis by DXA at the moment of diagnosis of PSC, as well as considering supplementation with calcium and vitamin D in all patients, though this has no clear benefit based on the literature[106,107]. No protocols exist on how to handle the specific follow-up and treatment of these patients, so WHO or ISCD guidelines for the management of osteoporosis are usually used[4] and the recommended diagnostic-therapeutic approach is the same as in PBC, even if the two diseases differ both in pathogenesis and in the phenotype of the population affected.

Sarcopenia

The diagnosis of sarcopenia should be made by cross-sectional imaging when strong clinical suspicion is present. Treatment can be derived by studies based on ACLD, but even in this setting clear guidelines are not currently available, both because the studies existing so far showed great heterogeneity and were based on a small number of patients, thus limiting the possibility of defining specific and reliable guidelines for the pathology, and no treatment had proven to be particularly effective[57]. Exercise programs finalized on avoiding natural deterioration of muscle mass[108,109] and nutritional supplementation with BCAA[110-112] are no established treatment and the data on these approaches are controversial. It should also be noted that physical activity may be difficult as one of the salient clinical features of this disease is chronic asthenia and fatigue. Considering the molecular mechanisms that lead to sarcopenia, improving protein synthesis and reducing autophagy with molecules like myostatin antagonists, direct mTORC1 activators, antioxidants, and mitochondrial protective agents could have the potential to benefit skeletal muscle protein turnover but have not been adequately evaluated[113]. More studies are needed to define the correct timing of follow-up.

CONCLUSION

Osteosarcopenia is a common complication of CLD that strongly influences quality of life and leads to severe morbidity. Indeed, cholestasis is directly associated with both bone and lean mass loss and the prevalence of bone damage is demonstrated to be higher in CLD than in the general population. Risk factors and etiopathogenesis of osteoporosis in PBC have been widely investigated; however, evaluation of the efficacy of osteoporosis drugs and preventive measures remain poorly known and data on PSC are scarce. On the other hand, studies on risk factors, etiologic mechanisms, and management of sarcopenia in CLD are lacking.

It is widely accepted that preventing the reduction of bone density is important to decrease the risk of fractures and improve morbidity and mortality. Further, PSC and PBC mostly affect young patients, and therefore prevention and screening are widely recommended. However, the timing is not yet defined, and no clinical guidelines are available for management of osteosarcopenia in CLD. Unfortunately, the overall quality of evidence is low and data on the treatment of CLD-related osteosarcopenia are inadequate.

Table 2 provides a proposed algorithm for the management of osteosarcopenia in CLD. Not pharmacological measures, including alcohol and smoking cessation, and aerobic and weight-bearing exercises, are highly recommended in all patients. The primary medical intervention for the treatment of osteoporosis in CLD is bisphosphonates in association with calcium and vitamin D supplements, though a benefit in terms of fracture reduction has never been shown. The use of further therapies for osteoporosis in CLD are based on the postmenopausal osteoporosis literature and new studies are desperately needed to define the best therapeutic approach to osteosarcopenia in a group of patients with high prevalence.

FOOTNOTES

Author contributions: Pugliese N, Arcari I, Lleo A, and Mazziotti G made substantial contributions to conception and design of the study, acquisition, analysis, and interpretation of the data, drafting the article, making critical revisions related to important intellectual content of the manuscript, and final approval of the version of the article to be published; Aghemo A and Lania AG made substantial contributions to conception and design of the study, making critical revisions related to important intellectual content of the manuscript, and final approval of the version of the article to be published.

Conflict-of-interest statement: AA has served as a speaker, consultant, and advisory board member for Gilead, MSD, Abbvie, Mylan, Intercept, and Alfasigma and has received research funding from Gilead and Abbvie. AL reports receiving consulting fees from Intercept Pharma, AlfaSigma, AbbVie, Gilead, and MSD and travel expenses from Intercept Pharma, AlfaSigma, and AbbVie. GM received consultant fees from Eli Lilly, Ipsen, and Novartis and

lecture fees from Abiogen and Amgen.

Country/Territory of origin: Italy

ORCID number: Nicola Pugliese 0000-0001-6466-1412; Ivan Arcari 0000-0002-3601-1612; Alessio Aghemo 0000-0003-0941-3226; Andrea G Lania 0000-0002-5380-2141; Ana Lleo 0000-0002-0561-7902; Gherardo Mazziotti 0000-0001-5458-701X.

Corresponding Author's Membership in Professional Societies: American Association for the Study of Liver Diseases; European Association for the Study of the Liver (EASL).

S-Editor: Fan JR
L-Editor: Wang TQ
P-Editor: Fan JR

REFERENCES

1 **Maillette de Buy Wenniger L**, Beuers U. Bile salts and cholestasis. *Dig Liver Dis* 2010; **42**: 409-418 [PMID: 20434968 DOI: 10.1016/j.dld.2010.03.015]
2 **de Vries E**, Beuers U. Management of cholestatic disease in 2017. *Liver Int* 2017; **37** Suppl 1: 123-129 [PMID: 28052628 DOI: 10.1111/liv.13306]
3 **Assis DN**. Chronic Complications of Cholestasis: Evaluation and Management. *Clin Liver Dis* 2018; **22**: 533-544 [PMID: 30259851 DOI: 10.1016/j.cld.2018.03.014]
4 **Lorentzon M**, Cummings SR. Osteoporosis: the evolution of a diagnosis. *J Intern Med* 2015; **277**: 650-661 [PMID: 25832448 DOI: 10.1111/joim.12369]
5 **Mirza F**, Canalis E. Management of endocrine disease: Secondary osteoporosis: pathophysiology and management. *Eur J Endocrinol* 2015; **173**: R131-R151 [PMID: 25971649 DOI: 10.1530/EJE-15-0118]
6 **Samelson EJ**, Broe KE, Xu H, Yang L, Boyd S, Biver E, Szulc P, Adachi J, Amin S, Atkinson E, Berger C, Burt L, Chapurlat R, Chevalley T, Ferrari S, Goltzman D, Hanley DA, Hannan MT, Khosla S, Liu CT, Lorentzon M, Mellstrom D, Merle B, Nethander M, Rizzoli R, Sornay-Rendu E, Van Rietbergen B, Sundh D, Wong AKO, Ohlsson C, Demissie S, Kiel DP, Bouxsein ML. Cortical and trabecular bone microarchitecture as an independent predictor of incident fracture risk in older women and men in the Bone Microarchitecture International Consortium (BoMIC): a prospective study. *Lancet Diabetes Endocrinol* 2019; **7**: 34-43 [PMID: 30503163 DOI: 10.1016/S2213-8587(18)30308-5]
7 **Jackson RD**, Mysiw WJ. Insights into the epidemiology of postmenopausal osteoporosis: the Women's Health Initiative. *Semin Reprod Med* 2014; **32**: 454-462 [PMID: 25321423 DOI: 10.1055/s-0034-1384629]
8 **Adachi JD**, Loannidis G, Berger C, Joseph L, Papaioannou A, Pickard L, Papadimitropoulos EA, Hopman W, Poliquin S, Prior JC, Hanley DA, Olszynski WP, Anastassiades T, Brown JP, Murray T, Jackson SA, Tenenhouse A; Canadian Multicentre Osteoporosis Study (CaMos) Research Group. The influence of osteoporotic fractures on health-related quality of life in community-dwelling men and women across Canada. *Osteoporos Int* 2001; **12**: 903-908 [PMID: 11804016 DOI: 10.1007/s001980170017]
9 **Miller PD**. Management of severe osteoporosis. *Expert Opin Pharmacother* 2016; **17**: 473-488 [PMID: 26605922 DOI: 10.1517/14656566.2016.1124856]
10 **Compston JE**, Horton LW, Thompson RP. Treatment of osteomalacia associated with primary biliary cirrhosis with parenteral vitamin D2 or oral 25-hydroxyvitamin D3. *Gut* 1979; **20**: 133-136 [PMID: 311747 DOI: 10.1136/gut.20.2.133]
11 **Guañabens N**, Parés A. Liver and bone. *Arch Biochem Biophys* 2010; **503**: 84-94 [PMID: 20537977 DOI: 10.1016/j.abb.2010.05.030]
12 **Raszeja-Wyszomirska J**, Miazgowski T. Osteoporosis in primary biliary cirrhosis of the liver. *Prz Gastroenterol* 2014; **9**: 82-87 [PMID: 25061487 DOI: 10.5114/pg.2014.42502]
13 **Danford CJ**, Trivedi HD, Bonder A. Bone Health in Patients With Liver Diseases. *J Clin Densitom* 2020; **23**: 212-222 [PMID: 30744928 DOI: 10.1016/j.jocd.2019.01.004]
14 **Guañabens N**, Parés A, Mariñoso L, Brancós MA, Piera C, Serrano S, Rivera F, Rodés J. Factors influencing the development of metabolic bone disease in primary biliary cirrhosis. *Am J Gastroenterol* 1990; **85**: 1356-1362 [PMID: 2220729]
15 **Ensrud KE**, Crandall CJ. Osteoporosis. *Ann Intern Med* 2017; **167**: ITC17-ITC32 [PMID: 28761958 DOI: 10.7326/AITC201708010]
16 **Marchioni Beery RM**, Vaziri H, Forouhar F. Primary Biliary Cirrhosis and Primary Sclerosing Cholangitis: a Review Featuring a Women's Health Perspective. *J Clin Transl Hepatol* 2014; **2**: 266-284 [PMID: 26357630 DOI: 10.14218/JCTH.2014.00024]
17 **Ruiz-Gaspà S**, Martinez-Ferrer A, Guañabens N, Dubreuil M, Peris P, Enjuanes A, Martinez de Osaba MJ, Alvarez L, Monegal A, Combalia A, Parés A. Effects of bilirubin and sera from jaundiced patients on osteoblasts: contribution to the development of osteoporosis in liver diseases. *Hepatology* 2011; **54**: 2104-2113 [PMID: 21837749 DOI:

10.1002/hep.24605]
18 **Ruiz-Gaspà S**, Guañabens N, Enjuanes A, Peris P, Martinez-Ferrer A, de Osaba MJ, Gonzalez B, Alvarez L, Monegal A, Combalia A, Parés A. Lithocholic acid downregulates vitamin D effects in human osteoblasts. *Eur J Clin Invest* 2010; **40**: 25-34 [PMID: 20055894 DOI: 10.1111/j.1365-2362.2009.02230.x]
19 **de la Garza RG**, Morales-Garza LA, Martin-Estal I, Castilla-Cortazar I. Insulin-Like Growth Factor-1 Deficiency and Cirrhosis Establishment. *J Clin Med Res* 2017; **9**: 233-247 [PMID: 28270882 DOI: 10.14740/jocmr2761w]
20 **Koshihara Y**, Hoshi K, Okawara R, Ishibashi H, Yamamoto S. Vitamin K stimulates osteoblastogenesis and inhibits osteoclastogenesis in human bone marrow cell culture. *J Endocrinol* 2003; **176**: 339-348 [PMID: 12630919 DOI: 10.1677/joe.0.1760339]
21 **Mazziotti G**, Frara S, Giustina A. Pituitary Diseases and Bone. *Endocr Rev* 2018; **39**: 440-488 [PMID: 29684108 DOI: 10.1210/er.2018-00005]
22 **Liu Z**, Han T, Werner H, Rosen CJ, Schaffler MB, Yakar S. Reduced Serum IGF-1 Associated With Hepatic Osteodystrophy Is a Main Determinant of Low Cortical but Not Trabecular Bone Mass. *J Bone Miner Res* 2018; **33**: 123-136 [PMID: 28902430 DOI: 10.1002/jbmr.3290]
23 **Kartsogiannis V**, Zhou H, Horwood NJ, Thomas RJ, Hards DK, Quinn JM, Niforas P, Ng KW, Martin TJ, Gillespie MT. Localization of RANKL (receptor activator of NF kappa B ligand) mRNA and protein in skeletal and extraskeletal tissues. *Bone* 1999; **25**: 525-534 [PMID: 10574572 DOI: 10.1016/s8756-3282(99)00214-8]
24 **Szalay F**, Hegedus D, Lakatos PL, Tornai I, Bajnok E, Dunkel K, Lakatos P. High serum osteoprotegerin and low RANKL in primary biliary cirrhosis. *J Hepatol* 2003; **38**: 395-400 [PMID: 12663228 DOI: 10.1016/s0168-8278(02)00435-x]
25 **Lleo A**, Bian Z, Zhang H, Miao Q, Yang F, Peng Y, Chen X, Tang R, Wang Q, Qiu D, Fang J, Sobacchi C, Villa A, Di Tommaso L, Roncalli M, Gershwin ME, Ma X, Invernizzi P. Quantitation of the Rank-Rankl Axis in Primary Biliary Cholangitis. *PLoS One* 2016; **11**: e0159612 [PMID: 27631617 DOI: 10.1371/journal.pone.0159612]
26 **Schett G**, Kiechl S, Redlich K, Oberhollenzer F, Weger S, Egger G, Mayr A, Jocher J, Xu Q, Pietschmann P, Teitelbaum S, Smolen J, Willeit J. Soluble RANKL and risk of nontraumatic fracture. *JAMA* 2004; **291**: 1108-1113 [PMID: 14996780 DOI: 10.1001/jama.291.9.1108]
27 **Guichelaar MM**, Malinchoc M, Sibonga J, Clarke BL, Hay JE. Bone metabolism in advanced cholestatic liver disease: analysis by bone histomorphometry. *Hepatology* 2002; **36**: 895-903 [PMID: 12297836 DOI: 10.1053/jhep.2002.36357]
28 **Guichelaar MM**, Malinchoc M, Sibonga J, Clarke BL, Hay JE. Immunosuppressive and postoperative effects of orthotopic liver transplantation on bone metabolism. *Liver Transpl* 2004; **10**: 638-647 [PMID: 15108255 DOI: 10.1002/Lt.20160]
29 **Klein GL**, Soriano H, Shulman RJ, Levy M, Jones G, Langman CB. Hepatic osteodystrophy in chronic cholestasis: evidence for a multifactorial etiology. *Pediatr Transplant* 2002; **6**: 136-140 [PMID: 12000470 DOI: 10.1034/j.1399-3046.2002.01060.x]
30 **Pietschmann P**, Resch H, Müller C, Woloszczuk W, Willvonseder R. Decreased serum osteocalcin levels in patients with liver cirrhosis. *Bone Miner* 1990; **8**: 103-108 [PMID: 2306557 DOI: 10.1016/0169-6009(90)90113-t]
31 **Bagur A**, Mautalen C, Findor J, Sorda J, Somoza J. Risk factors for the development of vertebral and total skeleton osteoporosis in patients with primary biliary cirrhosis. *Calcif Tissue Int* 1998; **63**: 385-390 [PMID: 9799822 DOI: 10.1007/s002239900545]
32 **Cuthbert JA**, Pak CY, Zerwekh JE, Glass KD, Combes B. Bone disease in primary biliary cirrhosis: increased bone resorption and turnover in the absence of osteoporosis or osteomalacia. *Hepatology* 1984; **4**: 1-8 [PMID: 6693061 DOI: 10.1002/hep.1840040101]
33 **Seki A**, Ikeda F, Miyatake H, Takaguchi K, Hayashi S, Osawa T, Fujioka SI, Tanaka R, Ando M, Seki H, Iwasaki Y, Yamamoto K, Okada H. Risk of secondary osteoporosis due to lobular cholestasis in non-cirrhotic primary biliary cholangitis. *J Gastroenterol Hepatol* 2017; **32**: 1611-1616 [PMID: 28114749 DOI: 10.1111/jgh.13746]
34 **Kehayoglou AK**, Holdsworth CD, Agnew JE, Whelton MJ, Sherlock S. Bone disease and calcium absorption in primary biliary cirrhosis with special reference to vitamin-D therapy. *Lancet* 1968; **1**: 715-718 [PMID: 4170960 DOI: 10.1016/s0140-6736(68)92164-8]
35 **Kawelke N**, Bentmann A, Hackl N, Hager HD, Feick P, Geursen A, Singer MV, Nakchbandi IA. Isoform of fibronectin mediates bone loss in patients with primary biliary cirrhosis by suppressing bone formation. *J Bone Miner Res* 2008; **23**: 1278-1286 [PMID: 18348696 DOI: 10.1359/jbmr.080313]
36 **Crippin JS**, Jorgensen RA, Dickson ER, Lindor KD. Hepatic osteodystrophy in primary biliary cirrhosis: effects of medical treatment. *Am J Gastroenterol* 1994; **89**: 47-50 [PMID: 8273797]
37 **Herlong HF**, Recker RR, Maddrey WC. Bone disease in primary biliary cirrhosis: histologic features and response to 25-hydroxyvitamin D. *Gastroenterology* 1982; **83**: 103-108 [PMID: 6978827]
38 **Guichelaar MM**, Schmoll J, Malinchoc M, Hay JE. Fractures and avascular necrosis before and after orthotopic liver transplantation: long-term follow-up and predictive factors. *Hepatology* 2007; **46**: 1198-1207 [PMID: 17654700 DOI: 10.1002/hep.21805]
39 **Guichelaar MM**, Kendall R, Malinchoc M, Hay JE. Bone mineral density before and after OLT: long-term follow-up and predictive factors. *Liver Transpl* 2006; **12**: 1390-1402 [PMID: 16933236 DOI: 10.1002/Lt.20874]
40 **Bjøro K**, Brandsæter B, Wiencke K, Bjøro T, Godang K, Bollerslev J, Schrumpf E. Secondary Osteoporosis in Liver Transplant Recipients: a Longitudinal Study in Patients With and Without Cholestatic Liver Disease. *Scand J Gastroenterol* 2003; **38**: 320-327 [PMID: 28248598 DOI: 10.1080/00365520310000681a]
41 **Ebadi M**, Bhanji RA, Mazurak VC, Montano-Loza AJ. Sarcopenia in cirrhosis: from pathogenesis to interventions. *J Gastroenterol* 2019; **54**: 845-859 [PMID: 31392488 DOI: 10.1007/s00535-019-01605-6]
42 **Reiss J**, Iglseder B, Kreutzer M, Weilbuchner I, Treschnitzer W, Kässmann H, Pirich C, Reiter R. Case finding for sarcopenia in geriatric inpatients: performance of bioimpedance analysis in comparison to dual X-ray absorptiometry. *BMC Geriatr* 2016; **16**: 52 [PMID: 26928275 DOI: 10.1186/s12877-016-0228-z]
43 **Beaudart C**, McCloskey E, Bruyère O, Cesari M, Rolland Y, Rizzoli R, Araujo de Carvalho I, Amuthavalli Thiyagarajan

J, Bautmans I, Bertière MC, Brandi ML, Al-Daghri NM, Burlet N, Cavalier E, Cerreta F, Cherubini A, Fielding R, Gielen E, Landi F, Petermans J, Reginster JY, Visser M, Kanis J, Cooper C. Sarcopenia in daily practice: assessment and management. *BMC Geriatr* 2016; **16**: 170 [PMID: 27716195 DOI: 10.1186/s12877-016-0349-4]

44 **Fearon K**, Strasser F, Anker SD, Bosaeus I, Bruera E, Fainsinger RL, Jatoi A, Loprinzi C, MacDonald N, Mantovani G, Davis M, Muscaritoli M, Ottery F, Radbruch L, Ravasco P, Walsh D, Wilcock A, Kaasa S, Baracos VE. Definition and classification of cancer cachexia: an international consensus. *Lancet Oncol* 2011; **12**: 489-495 [PMID: 21296615 DOI: 10.1016/S1470-2045(10)70218-7]

45 **Kim SE**, Kim DJ. Sarcopenia as a prognostic indicator of liver cirrhosis. *J Cachexia Sarcopenia Muscle* 2022; **13**: 8-10 [PMID: 34812591 DOI: 10.1002/jcsm.12869]

46 **Lanza E**, Masetti C, Messana G, Muglia R, Pugliese N, Ceriani R, Lleo de Nalda A, Rimassa L, Torzilli G, Poretti D, D'Antuono F, Politi LS, Pedicini V, Aghemo A; Humanitas HCC Multidisciplinary Group. Sarcopenia as a predictor of survival in patients undergoing bland transarterial embolization for unresectable hepatocellular carcinoma. *PLoS One* 2020; **15**: e0232371 [PMID: 32555707 DOI: 10.1371/journal.pone.0232371]

47 **Cruz-Jentoft AJ**, Bahat G, Bauer J, Boirie Y, Bruyère O, Cederholm T, Cooper C, Landi F, Rolland Y, Sayer AA, Schneider SM, Sieber CC, Topinkova E, Vandewoude M, Visser M, Zamboni M; Writing Group for the European Working Group on Sarcopenia in Older People 2 (EWGSOP2), and the Extended Group for EWGSOP2. Sarcopenia: revised European consensus on definition and diagnosis. *Age Ageing* 2019; **48**: 601 [PMID: 31081853 DOI: 10.1093/ageing/afz046]

48 **Saeki C**, Oikawa T, Kanai T, Nakano M, Torisu Y, Sasaki N, Abo M, Saruta M, Tsubota A. Relationship between osteoporosis, sarcopenia, vertebral fracture, and osteosarcopenia in patients with primary biliary cholangitis. *Eur J Gastroenterol Hepatol* 2021; **33**: 731-737 [PMID: 32558699 DOI: 10.1097/MEG.0000000000001791]

49 **Hirschfeld HP**, Kinsella R, Duque G. Osteosarcopenia: where bone, muscle, and fat collide. *Osteoporos Int* 2017; **28**: 2781-2790 [PMID: 28733716 DOI: 10.1007/s00198-017-4151-8]

50 **Bunney PE**, Zink AN, Holm AA, Billington CJ, Kotz CM. Orexin activation counteracts decreases in nonexercise activity thermogenesis (NEAT) caused by high-fat diet. *Physiol Behav* 2017; **176**: 139-148 [PMID: 28363838 DOI: 10.1016/j.physbeh.2017.03.040]

51 **Tandon P**, Ney M, Irwin I, Ma MM, Gramlich L, Bain VG, Esfandiari N, Baracos V, Montano-Loza AJ, Myers RP. Severe muscle depletion in patients on the liver transplant wait list: its prevalence and independent prognostic value. *Liver Transpl* 2012; **18**: 1209-1216 [PMID: 22740290 DOI: 10.1002/lt.23495]

52 **García PS**, Cabbabe A, Kambadur R, Nicholas G, Csete M. Brief-reports: elevated myostatin levels in patients with liver disease: a potential contributor to skeletal muscle wasting. *Anesth Analg* 2010; **111**: 707-709 [PMID: 20686014 DOI: 10.1213/ANE.0b013e3181eac1c9]

53 **Qiu J**, Thapaliya S, Runkana A, Yang Y, Tsien C, Mohan ML, Narayanan A, Eghtesad B, Mozdziak PE, McDonald C, Stark GR, Welle S, Naga Prasad SV, Dasarathy S. Hyperammonemia in cirrhosis induces transcriptional regulation of myostatin by an NF-κB-mediated mechanism. *Proc Natl Acad Sci U S A* 2013; **110**: 18162-18167 [PMID: 24145431 DOI: 10.1073/pnas.1317049110]

54 **McFarlane C**, Plummer E, Thomas M, Hennebry A, Ashby M, Ling N, Smith H, Sharma M, Kambadur R. Myostatin induces cachexia by activating the ubiquitin proteolytic system through an NF-kappaB-independent, FoxO1-dependent mechanism. *J Cell Physiol* 2006; **209**: 501-514 [PMID: 16883577 DOI: 10.1002/jcp.20757]

55 **Wing SS**, Lecker SH, Jagoe RT. Proteolysis in illness-associated skeletal muscle atrophy: from pathways to networks. *Crit Rev Clin Lab Sci* 2011; **48**: 49-70 [PMID: 21699435 DOI: 10.3109/10408363.2011.586171]

56 **Kim G**, Kang SH, Kim MY, Baik SK. Prognostic value of sarcopenia in patients with liver cirrhosis: A systematic review and meta-analysis. *PLoS One* 2017; **12**: e0186990 [PMID: 29065187 DOI: 10.1371/journal.pone.0186990]

57 **Pugliese N**, Lanza E, Aghemo A. Sarcopenia in chronic liver disease: easy to diagnose but hard to treat. *Liver Int* 2020; **40**: 2627-2629 [PMID: 33415841 DOI: 10.1111/liv.14690]

58 **European Association for the Study of the Liver**. EASL Clinical Practice Guidelines: The diagnosis and management of patients with primary biliary cholangitis. *J Hepatol* 2017; **67**: 145-172 [PMID: 28427765 DOI: 10.1016/j.jhep.2017.03.022]

59 **Danford CJ**, Trivedi HD, Papamichael K, Tapper EB, Bonder A. Osteoporosis in primary biliary cholangitis. *World J Gastroenterol* 2018; **24**: 3513-3520 [PMID: 30131657 DOI: 10.3748/wjg.v24.i31.3513]

60 **Glass LM**, Su GL. Metabolic Bone Disease in Primary Biliary Cirrhosis. *Gastroenterol Clin North Am* 2016; **45**: 333-343 [PMID: 27261902 DOI: 10.1016/j.gtc.2016.02.009]

61 **Trivedi HD**, Danford CJ, Goyes D, Bonder A. Osteoporosis in Primary Biliary Cholangitis: Prevalence, Impact and Management Challenges. *Clin Exp Gastroenterol* 2020; **13**: 17-24 [PMID: 32021374 DOI: 10.2147/CEG.S204638]

62 **Guañabens N**, Cerdá D, Monegal A, Pons F, Caballería L, Peris P, Parés A. Low bone mass and severity of cholestasis affect fracture risk in patients with primary biliary cirrhosis. *Gastroenterology* 2010; **138**: 2348-2356 [PMID: 20178794 DOI: 10.1053/j.gastro.2010.02.016]

63 **Menon KV**, Angulo P, Weston S, Dickson ER, Lindor KD. Bone disease in primary biliary cirrhosis: independent indicators and rate of progression. *J Hepatol* 2001; **35**: 316-323 [PMID: 11592591 DOI: 10.1016/s0168-8278(01)00144-1]

64 **Schmidt T**, Schmidt C, Schmidt FN, Butscheidt S, Mussawy H, Hubert J, Hawellek T, Oehler N, Barvencik F, Lohse AW, Schinke T, Schramm C, Amling M, Rolvien T. Disease Duration and Stage Influence Bone Microstructure in Patients With Primary Biliary Cholangitis. *J Bone Miner Res* 2018; **33**: 1011-1019 [PMID: 29470841 DOI: 10.1002/jbmr.3410]

65 **Guañabens N**, Parés A, Ros I, Caballería L, Pons F, Vidal S, Monegal A, Peris P, Rodés J. Severity of cholestasis and advanced histological stage but not menopausal status are the major risk factors for osteoporosis in primary biliary cirrhosis. *J Hepatol* 2005; **42**: 573-577 [PMID: 15763344 DOI: 10.1016/j.jhep.2004.11.035]

66 **Parés A**, Guañabens N. Primary biliary cholangitis and bone disease. *Best Pract Res Clin Gastroenterol* 2018; **34-35**: 63-70 [PMID: 30343712 DOI: 10.1016/j.bpg.2018.06.005]

67 **Springer JE**, Cole DE, Rubin LA, Cauch-Dudek K, Harewood L, Evrovski J, Peltekova VD, Heathcote EJ. Vitamin D-

receptor genotypes as independent genetic predictors of decreased bone mineral density in primary biliary cirrhosis. *Gastroenterology* 2000; **118**: 145-151 [PMID: 10611163 DOI: 10.1016/s0016-5085(00)70423-9]

68 **Parés A**, Guañabens N, Rodés J. Gene polymorphisms as predictors of decreased bone mineral density and osteoporosis in primary biliary cirrhosis. *Eur J Gastroenterol Hepatol* 2005; **17**: 311-315 [PMID: 15716655 DOI: 10.1097/00042737-200503000-00009]

69 **Lakatos PL**, Bajnok E, Tornai I, Folhoffer A, Horvath A, Lakatos P, Habior A, Szalay F. Insulin-like growth factor I gene microsatellite repeat, collagen type Ialpha1 gene Sp1 polymorphism, and bone disease in primary biliary cirrhosis. *Eur J Gastroenterol Hepatol* 2004; **16**: 753-759 [PMID: 15256976 DOI: 10.1097/01.meg.0000108364.41221.d0]

70 **Tang R**, Wei Y, Li Z, Chen H, Miao Q, Bian Z, Zhang H, Wang Q, Wang Z, Lian M, Yang F, Jiang X, Yang Y, Li E, Seldin MF, Gershwin ME, Liao W, Shi Y, Ma X. A Common Variant in CLDN14 is Associated with Primary Biliary Cirrhosis and Bone Mineral Density. *Sci Rep* 2016; **6**: 19877 [PMID: 26842849 DOI: 10.1038/srep19877]

71 **Szalay F**, Folhoffer A, Horváth A, Csak T, Speer G, Nagy Z, Lakatos P, Horváth C, Habior A, Tornai I, Lakatos PL. Serum leptin, soluble leptin receptor, free leptin index and bone mineral density in patients with primary biliary cirrhosis. *Eur J Gastroenterol Hepatol* 2005; **17**: 923-928 [PMID: 16093869 DOI: 10.1097/00042737-200509000-00007]

72 **Nishikawa H**, Shiraki M, Hiramatsu A, Moriya K, Hino K, Nishiguchi S. Japan Society of Hepatology guidelines for sarcopenia in liver disease (1st edition): Recommendation from the working group for creation of sarcopenia assessment criteria. *Hepatol Res* 2016; **46**: 951-963 [PMID: 27481650 DOI: 10.1111/hepr.12774]

73 **Hayashi M**, Abe K, Fujita M, Okai K, Takahashi A, Ohira H. Association between sarcopenia and osteoporosis in chronic liver disease. *Hepatol Res* 2018; **48**: 893-904 [PMID: 29734510 DOI: 10.1111/hepr.13192]

74 **Nishikawa H**, Enomoto H, Yoh K, Iwata Y, Sakai Y, Kishino K, Ikeda N, Takashima T, Aizawa N, Takata R, Hasegawa K, Ishii N, Yuri Y, Nishimura T, Iijima H, Nishiguchi S. Serum Zinc Concentration and Sarcopenia: A Close Linkage in Chronic Liver Diseases. *J Clin Med* 2019; **8** [PMID: 30862022 DOI: 10.3390/jcm8030336]

75 **Sepúlveda-Loyola W**, Phu S, Bani Hassan E, Brennan-Olsen SL, Zanker J, Vogrin S, Conzade R, Kirk B, Al Saedi A, Probst V, Duque G. The Joint Occurrence of Osteoporosis and Sarcopenia (Osteosarcopenia): Definitions and Characteristics. *J Am Med Dir Assoc* 2020; **21**: 220-225 [PMID: 31669290 DOI: 10.1016/j.jamda.2019.09.005]

76 **Reiss J**, Iglseder B, Alzner R, Mayr-Pirker B, Pirich C, Kässmann H, Kreutzer M, Dovjak P, Reiter R. Sarcopenia and osteoporosis are interrelated in geriatric inpatients. *Z Gerontol Geriatr* 2019; **52**: 688-693 [PMID: 31049683 DOI: 10.1007/s00391-019-01553-z]

77 **Drey M**, Sieber CC, Bertsch T, Bauer JM, Schmidmaier R; FiAT intervention group. Osteosarcopenia is more than sarcopenia and osteopenia alone. *Aging Clin Exp Res* 2016; **28**: 895-899 [PMID: 26563287 DOI: 10.1007/s40520-015-0494-1]

78 **European Association for the Study of the Liver**. EASL Clinical Practice Guidelines on nutrition in chronic liver disease. *J Hepatol* 2019; **70**: 172-193 [PMID: 30144956 DOI: 10.1016/j.jhep.2018.06.024]

79 **Fricker ZP**, Lichtenstein DR. Primary Sclerosing Cholangitis: A Concise Review of Diagnosis and Management. *Dig Dis Sci* 2019; **64**: 632-642 [PMID: 30725292 DOI: 10.1007/s10620-019-05484-y]

80 **Raszeja-Wyszomirska J**, Kucharski R, Zygmunt M, Safranow K, Miazgowski T. The impact of fragility fractures on health-related quality of life in patients with primary sclerosing cholangitis. *Hepat Mon* 2015; **15**: e25539 [PMID: 25972904 DOI: 10.5812/hepatmon.25539]

81 **Williamson KD**, Chapman RW. Primary sclerosing cholangitis. *Dig Dis* 2014; **32**: 438-445 [PMID: 24969292 DOI: 10.1159/000358150]

82 **Angulo P**, Therneau TM, Jorgensen A, DeSotel CK, Egan KS, Dickson ER, Hay JE, Lindor KD. Bone disease in patients with primary sclerosing cholangitis: prevalence, severity and prediction of progression. *J Hepatol* 1998; **29**: 729-735 [PMID: 9833910 DOI: 10.1016/s0168-8278(98)80253-5]

83 **Hay JE**, Lindor KD, Wiesner RH, Dickson ER, Krom RA, LaRusso NF. The metabolic bone disease of primary sclerosing cholangitis. *Hepatology* 1991; **14**: 257-261 [PMID: 1860683]

84 **Campbell MS**, Lichtenstein GR, Rhim AD, Pazianas M, Faust T. Severity of liver disease does not predict osteopenia or low bone mineral density in primary sclerosing cholangitis. *Liver Int* 2005; **25**: 311-316 [PMID: 15780055 DOI: 10.1111/j.1478-3231.2005.01075.x]

85 **Annese V**. A Review of Extraintestinal Manifestations and Complications of Inflammatory Bowel Disease. *Saudi J Med Med Sci* 2019; **7**: 66-73 [PMID: 31080385 DOI: 10.4103/sjmms.sjmms_81_18]

86 **Targownik LE**, Bernstein CN, Leslie WD. Inflammatory bowel disease and the risk of osteoporosis and fracture. *Maturitas* 2013; **76**: 315-319 [PMID: 24139749 DOI: 10.1016/j.maturitas.2013.09.009]

87 **Shteyer E**, Cytter-Kuint R, L Winberg L. P401 Sarcopenia in children and young adults with primary sclerosing cholangitis and IBD. *J Crohns and Colitis* 2020; **14**: S371-S372

88 **Marques A**, Ferreira RJ, Santos E, Loza E, Carmona L, da Silva JA. The accuracy of osteoporotic fracture risk prediction tools: a systematic review and meta-analysis. *Ann Rheum Dis* 2015; **74**: 1958-1967 [PMID: 26248637 DOI: 10.1136/annrheumdis-2015-207907]

89 **Ulivieri FM**, Silva BC, Sardanelli F, Hans D, Bilezikian JP, Caudarella R. Utility of the trabecular bone score (TBS) in secondary osteoporosis. *Endocrine* 2014; **47**: 435-448 [PMID: 24853880 DOI: 10.1007/s12020-014-0280-4]

90 **McCloskey EV**, Odén A, Harvey NC, Leslie WD, Hans D, Johansson H, Barkmann R, Boutroy S, Brown J, Chapurlat R, Elders PJM, Fujita Y, Glüer CC, Goltzman D, Iki M, Karlsson M, Kindmark A, Kotowicz M, Kurumatani N, Kwok T, Lamy O, Leung J, Lippuner K, Ljunggren Ö, Lorentzon M, Mellström D, Merlijn T, Oei L, Ohlsson C, Pasco JA, Rivadeneira F, Rosengren B, Sornay-Rendu E, Szulc P, Tamaki J, Kanis JA. A Meta-Analysis of Trabecular Bone Score in Fracture Risk Prediction and Its Relationship to FRAX. *J Bone Miner Res* 2016; **31**: 940-948 [PMID: 26498132 DOI: 10.1002/jbmr.2734]

91 **Chesnut C**, Majumdar S, Gardner J, Shields A, Newitt DC, Erickson E, Glott M, Kriegman A, Mindeholm L. Assessment of bone quality, quantity, and turnover with multiple methodologies at multiple skeletal sites. *Adv Exp Med Biol* 2001; **496**: 95-97 [PMID: 11783630 DOI: 10.1007/978-1-4615-0651-5_10]

92 **Griffith JF**, Genant HK. New advances in imaging osteoporosis and its complications. *Endocrine* 2012; **42**: 39-51

[PMID: 22618377 DOI: 10.1007/s12020-012-9691-2]
93 **Nuti R**, Brandi ML, Checchia G, Di Munno O, Dominguez L, Falaschi P, Fiore CE, Iolascon G, Maggi S, Michieli R, Migliaccio S, Minisola S, Rossini M, Sessa G, Tarantino U, Toselli A, Isaia GC. Guidelines for the management of osteoporosis and fragility fractures. *Intern Emerg Med* 2019; **14**: 85-102 [PMID: 29948835 DOI: 10.1007/s11739-018-1874-2]
94 **Kanis JA**, McCloskey EV, Johansson H, Cooper C, Rizzoli R, Reginster JY; Scientific Advisory Board of the European Society for Clinical and Economic Aspects of Osteoporosis and Osteoarthritis (ESCEO) and the Committee of Scientific Advisors of the International Osteoporosis Foundation (IOF). European guidance for the diagnosis and management of osteoporosis in postmenopausal women. *Osteoporos Int* 2013; **24**: 23-57 [PMID: 23079689 DOI: 10.1007/s00198-012-2074-y]
95 **Mazziotti G**, Bilezikian J, Canalis E, Cocchi D, Giustina A. New understanding and treatments for osteoporosis. *Endocrine* 2012; **41**: 58-69 [PMID: 22180055 DOI: 10.1007/s12020-011-9570-2]
96 **Danford CJ**, Ezaz G, Trivedi HD, Tapper EB, Bonder A. The Pharmacologic Management of Osteoporosis in Primary Biliary Cholangitis: A Systematic Review and Meta-Analysis. *J Clin Densitom* 2020; **23**: 223-236 [PMID: 31146965 DOI: 10.1016/j.jocd.2019.05.003]
97 **Rudic JS**, Giljaca V, Krstic MN, Bjelakovic G, Gluud C. Bisphosphonates for osteoporosis in primary biliary cirrhosis. *Cochrane Database Syst Rev* 2011; CD009144 [PMID: 22161446 DOI: 10.1002/14651858.CD009144.pub2]
98 **Zein CO**, Jorgensen RA, Clarke B, Wenger DE, Keach JC, Angulo P, Lindor KD. Alendronate improves bone mineral density in primary biliary cirrhosis: a randomized placebo-controlled trial. *Hepatology* 2005; **42**: 762-771 [PMID: 16175618 DOI: 10.1002/hep.20866]
99 **Treeprasertsuk S**, Silveira MG, Petz JL, Lindor KD. Parenteral bisphosphonates for osteoporosis in patients with primary biliary cirrhosis. *Am J Ther* 2011; **18**: 375-381 [PMID: 20460985 DOI: 10.1097/MJT.0b013e3181d7e1d3]
100 **Lima TB**, Santos LAA, Nunes HRC, Silva GF, Caramori CA, Qi X, Romeiro FG. Safety and efficacy of risedronate for patients with esophageal varices and liver cirrhosis: a non-randomized clinical trial. *Sci Rep* 2019; **9**: 18958 [PMID: 31831865 DOI: 10.1038/s41598-019-55603-y]
101 **Sugiyama T**. Letter to the Editor: Bone Health and Denosumab Treatment in Autoimmune Liver Diseases: A Possible Involvement of Physical Activity. *Hepatology* 2020; **71**: 1131-1132 [PMID: 31630426 DOI: 10.1002/hep.31001]
102 **Arase Y**, Tsuruya K, Hirose S, Ogiwara N, Yokota M, Anzai K, Deguchi R, Shiraishi K, Shirai T, Kagawa T. Efficacy and Safety of 3-Year Denosumab Therapy for Osteoporosis in Patients With Autoimmune Liver Diseases. *Hepatology* 2020; **71**: 757-759 [PMID: 31429969 DOI: 10.1002/hep.30904]
103 **Bjelakovic G**, Nikolova D, Bjelakovic M, Gluud C. Vitamin D supplementation for chronic liver diseases in adults. *Cochrane Database Syst Rev* 2017; **11**: CD011564 [PMID: 29099543 DOI: 10.1002/14651858.CD011564.pub2]
104 **Danielsson A**, Lorentzon R, Larsson SE. Normal hepatic vitamin-D metabolism in icteric primary biliary cirrhosis associated with pronounced vitamin-D deficiency symptoms. *Hepatogastroenterology* 1982; **29**: 6-8 [PMID: 7095738]
105 **Knodel LC**, Talbert RL. Adverse effects of hypolipidaemic drugs. *Med Toxicol* 1987; **2**: 10-32 [PMID: 3547004 DOI: 10.1007/BF03259858]
106 **Lundqvist K**, Broomé U. Differences in colonic disease activity in patients with ulcerative colitis with and without primary sclerosing cholangitis: a case control study. *Dis Colon Rectum* 1997; **40**: 451-456 [PMID: 9106695 DOI: 10.1007/BF02258391]
107 **Lima CA**, Lyra AC, Mendes CMC, Lopes MB, Coqueiro FG, Rocha R, Santana GO. Bone mineral density and inflammatory bowel disease severity. *Braz J Med Biol Res* 2017; **50**: e6374 [PMID: 29069227 DOI: 10.1590/1414-431X20176374]
108 **Zenith L**, Meena N, Ramadi A, Yavari M, Harvey A, Carbonneau M, Ma M, Abraldes JG, Paterson I, Haykowsky MJ, Tandon P. Eight weeks of exercise training increases aerobic capacity and muscle mass and reduces fatigue in patients with cirrhosis. *Clin Gastroenterol Hepatol* 2014; **12**: 1920-6.e2 [PMID: 24768811 DOI: 10.1016/j.cgh.2014.04.016]
109 **Román E**, García-Galcerán C, Torrades T, Herrera S, Marín A, Doñate M, Alvarado-Tapias E, Malouf J, Nácher L, Serra-Grima R, Guarner C, Cordoba J, Soriano G. Effects of an Exercise Programme on Functional Capacity, Body Composition and Risk of Falls in Patients with Cirrhosis: A Randomized Clinical Trial. *PLoS One* 2016; **11**: e0151652 [PMID: 27011355 DOI: 10.1371/journal.pone.0151652]
110 **Park JG**, Tak WY, Park SY, Kweon YO, Chung WJ, Jang BK, Bae SH, Lee HJ, Jang JY, Suk KT, Oh MJ, Heo J, Woo HY, Jang SY, Lee YR, Lee JS, Kim DY, Kim SH, Suh JI, Kim IH, Kang MK, Lee WK. Effects of Branched-Chain Amino Acid (BCAA) Supplementation on the Progression of Advanced Liver Disease: A Korean Nationwide, Multicenter, Prospective, Observational, Cohort Study. *Nutrients* 2020; **12** [PMID: 32429077 DOI: 10.3390/nu12051429]
111 **Kitajima Y**, Takahashi H, Akiyama T, Murayama K, Iwane S, Kuwashiro T, Tanaka K, Kawazoe S, Ono N, Eguchi T, Anzai K, Eguchi Y. Supplementation with branched-chain amino acids ameliorates hypoalbuminemia, prevents sarcopenia, and reduces fat accumulation in the skeletal muscles of patients with liver cirrhosis. *J Gastroenterol* 2018; **53**: 427-437 [PMID: 28741271 DOI: 10.1007/s00535-017-1370-x]
112 **Ooi PH**, Gilmour SM, Yap J, Mager DR. Effects of branched chain amino acid supplementation on patient care outcomes in adults and children with liver cirrhosis: A systematic review. *Clin Nutr ESPEN* 2018; **28**: 41-51 [PMID: 30390892 DOI: 10.1016/j.clnesp.2018.07.012]
113 **Ponziani FR**, Gasbarrini A. Sarcopenia in Patients with Advanced Liver Disease. *Curr Protein Pept Sci* 2018; **19**: 681-691 [PMID: 28462693 DOI: 10.2174/1389203718666170428121647]
114 **Guañabens N**, Parés A, Navasa M, Martínez de Osaba MJ, Hernández ME, Muñoz J, Rodés J. Cyclosporin A increases the biochemical markers of bone remodeling in primary biliary cirrhosis. *J Hepatol* 1994; **21**: 24-28 [PMID: 7963418 DOI: 10.1016/s0168-8278(94)80132-0]
115 **Solaymani-Dodaran M**, Card TR, Aithal GP, West J. Fracture risk in people with primary biliary cirrhosis: a population-based cohort study. *Gastroenterology* 2006; **131**: 1752-1757 [PMID: 17087953 DOI: 10.1053/j.gastro.2006.09.012]

World Journal of Gastroenterology

Submit a Manuscript: https://www.f6publishing.com

World J Gastroenterol 2022 April 14; 28(14): 1444-1454

DOI: 10.3748/wjg.v28.i14.1444

ISSN 1007-9327 (print) ISSN 2219-2840 (online)

ORIGINAL ARTICLE

Basic Study

Syngeneic implantation of mouse hepatic progenitor cell-derived three-dimensional liver tissue with dense collagen fibrils

Miho Tamai, Eijiro Adachi, Masaya Kawase, Yoh-ichi Tagawa

Specialty type: Gastroenterology and hepatology

Provenance and peer review: Invited article; Externally peer reviewed.

Peer-review model: Single blind

Peer-review report's scientific quality classification

Grade A (Excellent): 0
Grade B (Very good): B
Grade C (Good): C
Grade D (Fair): 0
Grade E (Poor): 0

P-Reviewer: Gao W

Received: February 27, 2021
Peer-review started: February 27, 2021
First decision: March 28, 2021
Revised: April 10, 2021
Accepted: September 2, 2021
Article in press: September 2, 2021
Published online: April 14, 2022

Miho Tamai, Yoh-ichi Tagawa, School of Life Science and Technology, Tokyo Institute of Technology, Yokohama-shi 226-8501, Japan

Miho Tamai, Faculty of Dental Medicine, Hokkaido University, Sapporo 060-8586, Japan

Eijiro Adachi, Department of Molecular Morphology, Kitasato University, Yokohama-shi 319-3526, Japan

Eijiro Adachi, Long-Term Care Health Facility Yasuragi, Ibaraki Zip or Postal Code, Japan

Masaya Kawase, Nagahama Institute of Bio-Science and Technology, Shiga 526-0829, Japan

Corresponding author: Yoh-ichi Tagawa, DSc, Associate Professor, School of Life Science and Technology, Tokyo Institute of Technology, 4259 B51, Nagatsuta-cho, Midori-ku, Yokohama-shi 226-8501, Japan. ytagawa@bio.titech.ac.jp

Abstract

BACKGROUND

Liver transplantation is a therapy for irreversible liver failure; however, at present, donor organs are in short supply. Cell transplantation therapy for liver failure is still at the developmental stage and is critically limited by a shortage of human primary hepatocytes.

AIM

To investigate the possibility that hepatic progenitor cells (HPCs) prepared from the portal branch-ligated hepatic lobe may be used in regenerative medicine, we attempted to enable the implantation of extracellular matrices containing organoids consisting of HPC-derived hepatocytes and non-parenchymal cells.

METHODS

In vitro liver organoid tissue has been generated by accumulating collagen fibrils, fibroblasts, and HPCs on a mesh of polylactic acid fabric using a bioreactor; this was subsequently implanted into syngeneic wild-type mice.

RESULTS

The *in vitro* liver organoid tissues generated transplantable tissues in the condensed collagen fibril matrix and were obtained from the mouse through partial hepatectomy.

CONCLUSION
Liver organoid tissue was produced from expanded HPCs using an originally designed bioreactor system. This tissue was comparable to liver lobules, and with fibroblasts embedded in the network collagen fibrils of this artificial tissue, it is useful for reconstructing the hepatic interstitial structure.

Key Words: Liver; Three-dimensional tissue culture; Hepatic progenitor cells; Angiogenesis; Biomimetic extracellular matrix

Core Tip: Liver transplantation is a therapeutic procedure used to recover liver function in patients with irreversible liver failure; however, there is presently a shortage of transplant organs available. Hepatic stem and progenitor cells are expected to allow regenerative medicine to produce a cell source as an alternative to whole organs. The portal branch-ligated, hepatic lobe-derived HPCs multiplied in a bioreactor chamber to form liver organoid tissues comparable to liver lobules. These organoid tissues were implanted into syngeneic mice. This portal branch-ligated-derived HPC line has the potential to proliferate, mature, and form implantable hepatic tissue.

Citation: Tamai M, Adachi E, Kawase M, Tagawa YI. Syngeneic implantation of mouse hepatic progenitor cell-derived three-dimensional liver tissue with dense collagen fibrils. *World J Gastroenterol* 2022; 28(14): 1444-1454
URL: https://www.wjgnet.com/1007-9327/full/v28/i14/1444.htm
DOI: https://dx.doi.org/10.3748/wjg.v28.i14.1444

INTRODUCTION

Liver transplantation is a therapy for irreversible liver failure; however, donor organs are currently in short supply[1,2]. Cell transplantation therapy for liver failure is still at the developmental stage and has a critical problem in terms of a shortage of human primary hepatocytes[3]. Human embryonic stem/induced pluripotent stem (ES/iPS) cell-derived hepatocytes are thought to be an alternative to human primary hepatocytes, but ES/iPS cells are difficult to differentiate into mature hepatocytes in culture[4,5]. ES/iPS cell-derived immature hepatocytes successfully developed into mature liver tissue in animals after implantation[6,7]. However, this process requires a great deal of time, effort, and expense in order to obtain a sufficient number of ES/iPS cell-derived hepatocytes in culture to achieve the amount needed for them to continue to proliferate. There have been several reports of rat HPCs, such as small hepatocytes[8] and Lgr5+ rat and mouse liver stem cells[9,10], becoming established in culture. These hepatic stem/progenitor cells have the ability to proliferate and differentiate into hepatocytes and cholangiocytes[11,12]. Recently, we also succeeded in establishing HPC lines prepared from the portal branch-ligated hepatic lobe in mice (PBL-HPCs)[13]. These cells could differentiate into mature hepatocytes in the presence of oncostatin M, or to cholangiocytes in EHS gel.

Besides dissociated hepatocyte implantation, regenerative medicine is also expected to enable the implantation of extracellular matrices containing aggregate, or organoids consisting of hepatocytes and non-parenchymal cells[14-16]. *In vitro* liver organoid tissue has previously been generated by accumulating collagen fibrils, human fibroblast cell line (HFO cell), and human hepatocarcinoma cell line (Hep G2) on a mesh of polylactic acid (PLA) fabric using a bioreactor[14]. Also, instead of HFO and Hep G2, mouse embryonic fibroblasts and primary hepatocytes were used for this *in vitro* liver organoid tissue. These *in vitro* liver organoid tissues generated transplantable liver organoid tissues in the right portal vein branch-ligated *nu/nu* mouse with a condensed collagen fibril matrix[14]. The fibroblasts are embedded in the network collagen fibrils of this artificial tissue, and it is therefore useful for reconstructing the hepatic interstitial structure.

In this study, the PBL-HPCs were expanded and formed liver organoid tissue, which was comparable to liver lobules using an originally designed bioreactor system, and was also implanted into its syngeneic wild-type mouse.

MATERIALS AND METHODS

Animals

Pregnant BALB/cA mice at 13.5 d post-coitus (CLEA Japan, Tokyo, Japan) were used for embryonic fibroblast isolation. Six-week-old female and male BALB/cA Jcl and BALB/cA Jcl-nu/nu 3 mice (CLEA Japan, Tokyo, Japan) were used as transplant recipients. The animal protocol was approved by the Animal Experimentation Committee of the Tokyo Institute of Technology.

Cells and cultures

The PBL-HPCs were established in a previous study with portal vein ligated methods[13]. The cells were cultured in Williams' E medium (GIBCO Laboratories, Grand Island, NY, United States) supplemented with 5% fetal bovine serum, 10 mmol/L nicotinamide (Sigma-Aldrich, St. Louis, MO, United States), 0.1 μmol/L dexamethasone (Sigma-Aldrich), 1×Insulin-Transferrin-Sodium Selenite Supplement (Roche Diagnostics, Mannheim, Germany), and 20 ng/mL Recombinant Mouse Epidermal Growth Factor (R&D Systems, Minneapolis, MN, United States) in 5% CO_2 at 37°C. These cells were passaged by treatment with 0.05% trypsin (Invitrogen) and 20 μmol/L ethylenediaminetetraacetic acid (EDTA; NACALAI TESQUE, Kyoto, Japan).

Preparation of murine embryonic fibroblasts

A pregnant female BALB/c mouse at 13.5 dpc (days post-coitus) was sacrificed by cervical dislocation, and embryos were removed. The limbs of the embryos were minced and treated with 0.25% trypsin (Invitrogen, Tokyo, Japan) + 1 mmol/L EDTA (about 2 mL per embryo) and incubated with gentle stirring at 37 °C for 10-15 min. The cells were subsequently cultured in DMEM containing 10% (v/v) FBS.

Generation of three-dimensional liver tissue culture model

As shown in Figure 1, the three-dimensional (3-D) liver tissue culture model was generated by accumulating collagen fibrils, primary murine embryonic fibroblasts, and PBL-HPCs using a closed-loop system with a bioreactor chamber (diameter 17 mm; thickness 20 mm) developed by our group as previously reported[14,17]. Briefly, primary embryonic fibroblasts (1.0×10^5 cells/mL) in 10% FBS and 7.5 mg/mL type I collagen prepared from calfskin (Koken Collagen, Tokyo, Japan) in Williams' E medium flowed through the closed-loop system at a predetermined flow rate (1-5 mL/min) for 6 h. Subsequently, the same medium was circulated through the closed-loop system, and PBL-HPCs (5.0×10^6 cells/mL) were injected using a syringe into the system upstream of the bioreactor chamber for 2 h. Finally, a suspension of fibroblasts (1.0×10^5 cells/mL) was circulated for 6 h.

Morphological analyses

The 3-D liver tissue culture models were fixed with Zamboni's fixative for light microscopy. The samples were dehydrated with an ethanol series and embedded in paraffin. The sections were stained with hematoxylin and eosin or AZAN and examined with a light microscope.

Hepatic function assay in liver tissue culture model

Urea production in the medium was quantified using a urea assay kit (Bioassay Systems, Hayward, CA, United States) 24 h after the addition of 2 mmol/L NH_4Cl. Albumin production was quantified in the medium using an albumin EIA (Albuwell M) mouse kit (Exocell, Philadelphia, PA, United States).

The metabolites of testosterone in the medium were quantified by HPLC analysis[18]. The 3-D liver tissue culture models were incubated with fresh medium containing 0.25 mmol/L testosterone and the medium was collected at 24 h. After sample treatment, HPLC analysis was performed using LC-10ADVP (Shimadzu, Kyoto, Japan) with Cadenza columns (Cadenza CD-C18) (Imtakt, Kyoto, Japan) and SPD-10A VP (Shimadzu, Kyoto, Japan).

Transplantation of liver tissue culture model

Under isoflurane anesthesia, mice were subjected to an upper-abdominal incision, followed by exposure and ligation of the left portal vein branch and subsequent hepatectomy of the left and middle lobes (70%). The 3-D liver tissue culture model was transplanted into the subcutaneous layer of a mouse. Two weeks later, the 3-D liver tissue culture model was removed for histological analysis of the vascular network.

Statistical analysis

Results of multiple experiments were reported as the mean ± SE. Statistical comparisons were made using a Tukey-Kramer method and a Welch *t*-test using the IBM SPSS Statistic 27.

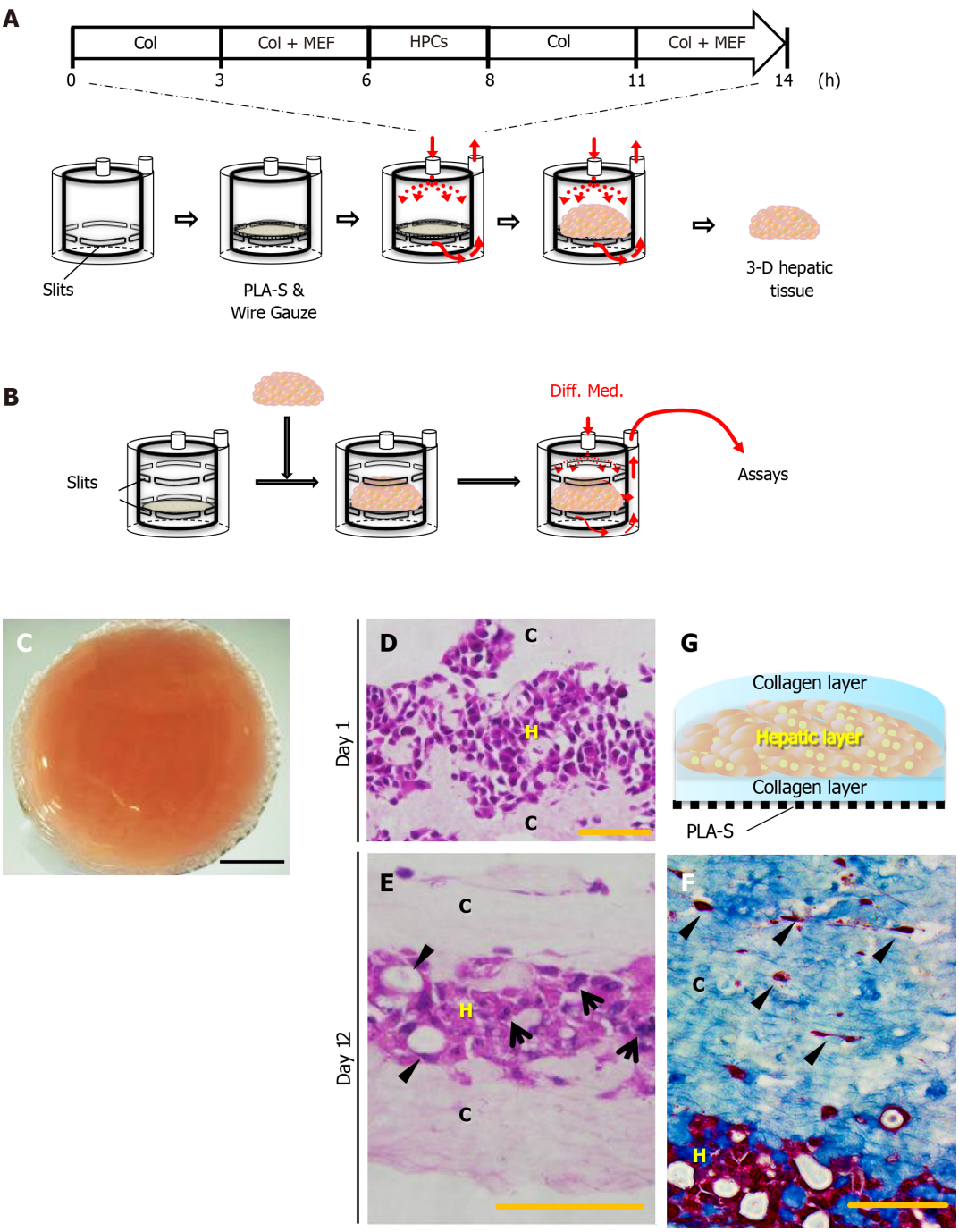

Figure 1 Reconstruction of the three-dimensional liver tissue culture model using hepatic progenitor cells. A and B: A schematic illustration showing reconstruction of the liver tissue culture model using a bioreactor; preparation steps (A), and culture steps (B); C: Micrographs of a reconstructed three-dimensional (3-D) liver tissue culture model with dense collagen fibrils; D and E: Histological analyses: hematoxylin-eosin staining of a section of the 3-D liver tissue culture model on day 1 (D) and day 12 (E). Arrows indicate binuclear populations, like hepatocytes. Arrowheads indicate a bile duct–like structure; F: Histological analyses: AZAN staining of a section of the 3-D liver tissue culture model on day 12. Arrowheads indicate fibroblasts at condensed collagen fibril matrices. Bar corresponds to (C) 5 mm, (D) 50 μm, and (E) and (F) 100 μm. Col: Collagen; HPCs: Portal branch-ligated-hepatic progenitor cells; PLA-S: Polylactic acid sheet; C: Collagen layer; H: Hepatic layer.

RESULTS

Preparation of 3-D hepatic progenitor cell-derived 3-D liver tissue culture model

Type I collagen solution was circulated through a sheet of PLA into a reverse radial flow-type bioreactor, followed by the suspension of 5.0 × 10^6 cells of mouse embryonic fibroblasts (MEFs). In the next step, the suspension of 1.0 × 10^7 PBL-HPCs was circulated without oncostatin M. After these steps, the type I collagen solution was circulated again followed by the suspension of 5.0 × 10^6 MEFs. Finally a 3-D aggregate was prepared (Figure 1A). The surface of this 3-D aggregate which included PBL-HPCs, primary fibroblasts, and type I collagen was glossy and measured 17 mm in diameter and 1.5 mm in

height. This glossy aggregate consisted of a layer of PBL-HPCs, sandwiched between two layers of collagen fibrils with MEFs, and was constructed on a sheet of PLA as shown in Figure 1G. Cross-sectional profiles of the 3-D liver tissue culture models were stained with hematoxylin-eosin and AZAN as shown in Figure 1D-F. The collagen layers were composed of densely packed collagen fibrils running parallel to the plane of the PLA sheet. A layer of PBL-HPCs 200-300 μm thick (Figure 1D), and two layers of collagen fibrils populated with embryonic fibroblasts, approximately 400 μm thick, were observed in the 3-D liver tissue culture model. To culture the 3-D liver tissue model, the cylinder inside the bioreactor was changed from construction to culture (Figure 1B). The 3-D liver tissue culture model was cultured using a differentiation medium containing 20 ng/mL oncostatin M in the bioreactor for 12 d. After this, PBL-HPCs differentiated into mature hepatocyte-like cells, in binuclear populations, and with a bile duct-like structure (Figure 1E). Collagen layers were maintained by the collagen fibers and fibroblasts on day 12.

Expression of liver-related genes in hepatic progenitor cell-derived 3-D liver tissue culture model

The expression of liver-specific genes was determined in the 3-D liver tissue culture model. To investigate whether the 3-D liver tissue culture models were able to show hepatic lineage differentiation (*i.e.*, to mature into hepatocytes and bile duct cells), the cells were cultured in the presence of oncostatin M. By day 12 of the culture in the hepatic lineage differentiation medium, quantitative real-time polymerase chain reaction analysis revealed that the cells expressed hepatocyte differentiation markers including: Afp (α-fetoprotein); Albumin; Tat (tyrosine aminotransferase); Tdo (tryptophan 2,3-dioxygenase); Cps1 (carbamoyl-phosphate synthetase 1); Cyp1a2 (Cytochrome P450, family 1, sub-family a2); Cyp2e1 (Cytochrome P450, family 2, sub-family e1); and Abcc2 [ATP-binding cassette, sub-family C (CFTR/MRP), member 2] (Figure 2A-H). On the other hand, the gene expression of *Bsep* (bile salt export pump) and *ABCB11* (ATP-binding cassette, sub-family B member 11) decreased in the 3-D liver tissue culture model (Figure 2I). The expression of *CK19*, a representative marker for HPCs, was confirmed in the PBL-HPCs. The gene expression of *CK19* decreased in the 3-D liver tissue culture models (Figure 2J). In addition, PBL-HPCs expressed the *CD44* gene, a progenitor cell marker, which decreased in the 3-D liver tissue culture models (Figure 2K). After that, *CD44* expression increased in the 3-D liver tissue culture models on day 12 of culture (Figure 2K).

The 3-D liver tissue culture model exhibits expression of multiple liver-specific functions

The expression of several liver-specific functions, such as the production of urea and albumin, and drug metabolism, were analyzed in the 3-D liver tissue culture models. Urea production was examined in cultured 3-D liver tissue culture models in a hepatic lineage differentiation medium containing 2 mmol/L NH_4^+. The level of urea production in the 3-D liver tissue culture model gradually increased and was significantly higher on days 6 and 12 than in the 2-D culture (Figure 3A). The amount of albumin released from the 3-D liver tissue culture model into the medium was measured in each medium on day 1, day 6, and day 12 by enzyme-linked immunosorbent assay. As seen in Figure 3B, the albumin level increased gradually from day 1 to day 12. These results suggest that the 3-D liver tissue culture model with PBL-HPCs had differentiated.

To quantify P450 activities, the hydroxylated pattern of testosterone by cultured 3-D liver tissue culture models in a hepatic lineage differentiation medium, containing 250 μmol/L testosterone, was examined using high-performance liquid chromatography. The concentration of each hydroxylated testosterone (6β-OHT, 7α-OHT, 16α-OHT, and 16β-OHT, respectively, corresponding to oxidation by Cyp3a, Cyp2a4/5 and 2d9, Cyp2d9 and 2b, and Cyp2c29 and 2e) was quantified. The concentrations of hydroxylated testosterones, such as 6β-OHT, 7α-OHT, 16α-OHT, and 16β-OHT, in the media of the 3-D liver tissue culture models after 12 days culture were measured. As compared with the hydroxylation levels of 6b-OHT, 7a-OHT, and 16a-OHT in the 2-D culture, the hydroxylation levels were significantly increased in the 3-D liver tissue models (Figure 3C).

The 3-D liver tissue was engrafted in the partially hepatectomized mouse

The 3-D liver tissue culture model of PBL-HPCs was syngeneically transplanted into the subcutaneous layer of a BALB/cA mouse which had received a 70% partial hepatectomy as shown in Figure 4A. The graft could be observed in the subcutaneous layer two weeks after transplantation. Microvascular networks were seen throughout this engrafted tissue. As shown in Figure 4B and C, the hematoxylin-eosin staining of this specimen in the graft area showed that collagen remained rich in the graft, fibroblasts existed in the collagen area, and vessel-like tube formation was observed. To investigate whether the cells in these areas were hepatocytes, an immunohistochemical examination using staining with anti-albumin antibodies was carried out (Figure 4D). This confirmed that the PBL-HPCs were accepted as albumin-positive cells after transplantation. These results indicate that the 3-D liver tissue culture model was successfully grafted with angiogenesis in the partially hepatectomized mouse.

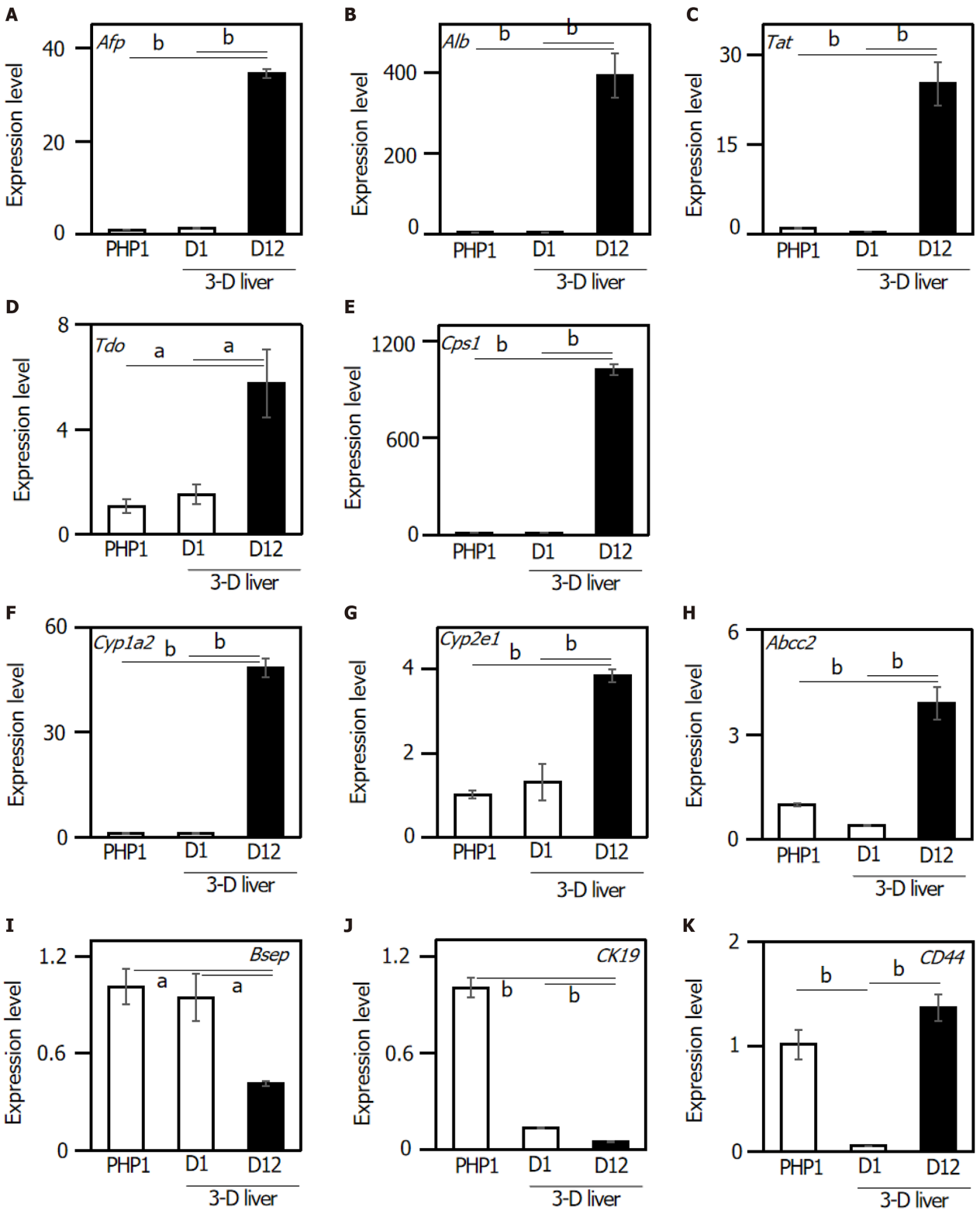

Figure 2 Relative gene expression levels in the three-dimensional liver tissue culture model cultured in a bioreactor on day 1 and day 12. Relative gene expression levels were analyzed in the three-dimensional liver tissue culture model. A: *Afp*; B: *Albumin*; C: *Tat*; D: *Tdo*; E: *Cps1*; F: *Cyp1a2*; G: *Cyp2e1* ; H: *Abcc2*; I: *Bsep*; J: *CK19*; K: *CD44*. *Hprt* was used as an internal control. Statistical comparisons were made using the Tukey-Kramer method. Data are shown as means ± SE, $n = 3$, $^aP < 0.05$ and $^bP < 0.01$. Afp: Alpha-fetoprotein; Tat: Tyrosine aminotransferase; Tdo: Tryptophan 2,3-dioxygenase; Cps1: Carbamoyl-phosphate synthetase 1; Cyp1a2: Cytochrome P450, family 1, sub-family a2; Cyp2e1: Cytochrome P450, family 2, sub-family e1; Abcc2: ATP-binding cassette, sub-family C (CFTR/MRP), member 2; Bsep: Bile salt export pump; ABCB11: ATP-binding cassette, sub-family B member 11; CK19: Cytokeratin 19; CD44: Hyaluronic Acid Binding Protein.

DISCUSSION

It is crucial to develop a technology that enables transplantable engineered tissues to be functionally

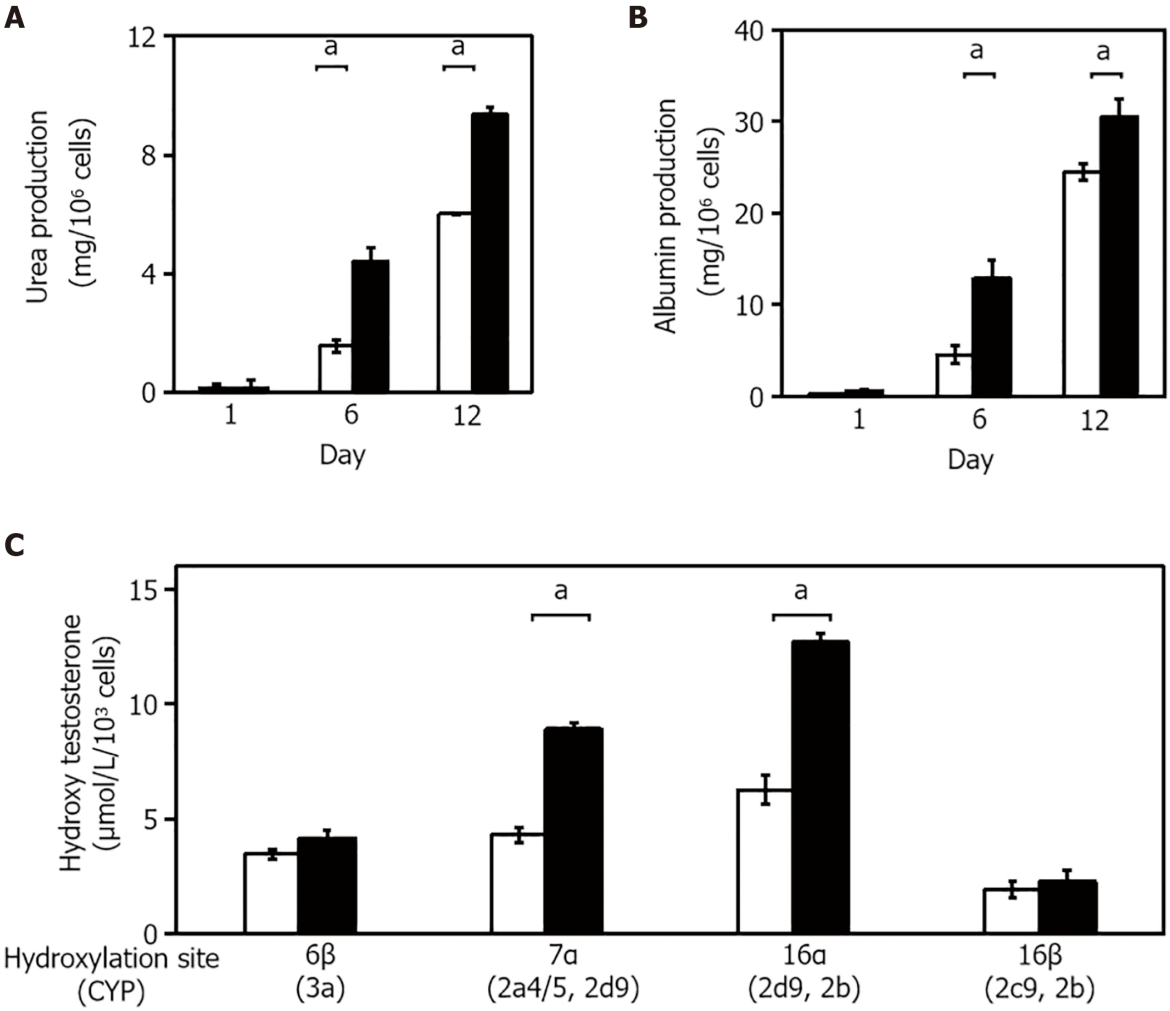

Figure 3 Validation of hepatic functions in the three-dimensional liver tissue culture model. A and B: Urea (A) and albumin (B) production levels in the culture medium in each culture condition; C: Hydroxylation activity of testosterone in the three-dimensional (3-D) liver tissue culture model. The amount of each hydroxylated testosterone in culture medium. Culture medium was changed every 2 d over the course of the measurement period. 2-D culture (open columns) and 3-D culture (closed columns) system. Statistical comparisons were made using the Welch *t*-test. Data are shown as means ± SE, $n = 3$, $^{a}P < 0.01$.

engrafted and long-lasting, in order to maximize the therapeutic effects of this procedure[19-21]. There are reports of transplanted hepatocytes at several different extrahepatic sites such as the small intestine [22,23]. Tissue engineering has been a promising procedure for providing transplantable tissues mimicking liver *ex vivo*[24,25]. The attachment of hepatocytes to extracellular matrix scaffolds can help in their engraftment in extrahepatic sites[26,27]. It is important to provide scaffold materials for hepatocytes to enable significantly greater hepatocyte survival in heterotypic transplantation[28]. The liver is encased mainly with collagen fibrils. By fabricating graded structures specific for target tissues and organs, one can obtain suitable scaffolds for tissue regeneration[29]. Taking into account the architecture of the liver, we have generated a 3-D liver tissue culture model of HPCs with a collagen fibril matrix using a bioreactor. Furthermore, defining and validating new sources is mandatory for ensuring functional hepatic cell supply[30]. Hepatic stem/progenitor cells have many advantages compared to adult hepatocytes as they are bipotent cells, so they can differentiate into hepatocytes and cholangiocytes[20]. Moreover, they have high proliferation ability.

In this study, HPCs — PBL-HPCs — were used in an original procedure to generate a 3-D liver tissue culture model. The histological structure of this model resembled that of the liver, with respect to its capillary network and surrounding cell clusters. As PBL-HPCs have the potential to reproduce themselves, it is easy to prepare the necessary numbers of cells (1×10^7 cells order). The PBL-HPC-derived 3-D liver tissue culture model reconstructed in a bioreactor produced cells that differentiated into hepatic-like cells, binuclear populations, and bile duct–like structures (Figure 1F). These cells expressed hepatocyte differentiation markers (Figure 2) after 12 days of culture. The PBL-HPCs differentiated not only into hepatic cells but also bile duct-like cells in a reconstituted collagen fibril matrix. In the 3-D liver tissue culture model derived from PBL-HPCs, the levels of urea and albumin production were gradually enhanced and were significantly higher than those cultured in dishes on days 6 and 12 (Figure 3A and B). Cyp3a, 2a4/5, 2d9, and 2b activities were significantly increased in the 3-D liver

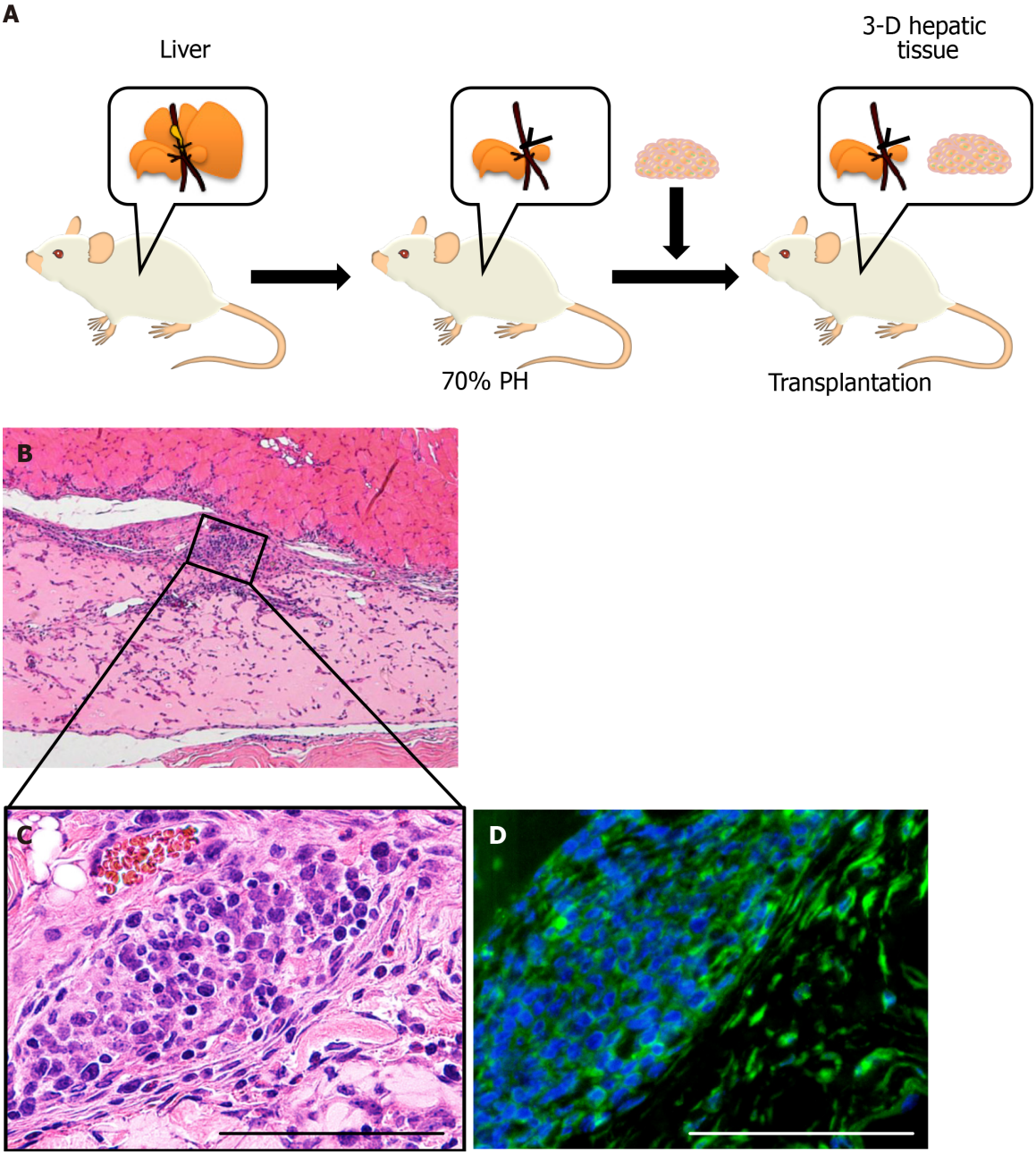

Figure 4 Transplanted three-dimensional liver tissue culture models in partially hepatectomized model mice. A: A schematic illustration showing the transplantation of the three-dimensional (3-D) liver tissue culture model; B: Histological analyses and hematoxylin-eosin staining of the section for the 3-D liver tissue culture model after transplantation; C: Higher magnification of the inscribed area in (B). The vascularization was observable at condensed collagen fibril matrices. Arrowheads indicate new blood vessels; D: Immunohistochemical analysis of the 3-D liver tissue culture model of albumin-positive hepatic cells after being transplanted using anti-albumin (green) antibodies. Bar corresponds to 100 μm.

tissue culture models (Figure 3C). These results suggest that the PBL-HPCs differentiated to mature hepatocytes in the 3-D liver tissue culture model.

Since PBL-HPCs differentiated into cells expressing hepatic functions in a 3-D liver tissue culture model, further investigation was carried out to determine whether PBL-HPCs also maintained their acquired functions after transplantation. Following implantation of the PBL-HPC-derived 3-D liver tissue culture model into mice, the 3-D liver tissue culture model was grafted, and vessel-like tube formation was observed (Figure 4B and C).

Also, the 3-D liver tissue culture model was grafted in the healthy mouse which did not undergo partial hepatectomy, and vascularization was observed (Supplementary Figure 1A and B). On the other hand, the Matrigel-embedded PBL-HPCs were transplanted into male healthy mice or nu/nu mice, and vascularization was not observed (Supplementary Figure 1C-F). PBL-HPCs differentiated into albumin positive cells (Figure 4D). This haptic tissue consisted of fibroblasts and HPCs which can be differentiated into only hepatocytes and bile duct cells, not immune cells. As some blood vessels were observed after implantation, lymphocytes and monocytes may have been circulating. However, we did not detect

Kupffer cells in the grafts. The 3-D liver tissue culture model was investigated for efficiency of transplantation in extrahepatic sites. These findings demonstrated that a reconstituted collagen fibril matrix can provide an extracellular microenvironment to promote the maturation of progenitor cells into hepatic cells. A local vascular network would allow nutrient and gas transport to the graft. These findings could make a significant contribution to the problem of liver graft shortage.

CONCLUSION

In conclusion, a 3-D liver tissue culture model was developed using HPCs. The advantage of our system is that it consists of proliferative HPCs. The 3-D liver tissue culture models can be generated in an originally designed bioreactor within 24 h. By mimicking the structure of the natural liver, our system was effective in constructing a functional liver tissue model.

ARTICLE HIGHLIGHTS

Research background

Liver transplantation is a therapeutic procedure to recover liver function in patients with irreversible liver failure; however, there is currently a shortage of available transplant organs, which limits the availability of this treatment.

Research motivation

Portal branch-ligated (PBL) HPCs are expected to allow regenerative medicine to produce a cell source to provide an alternate source for transplantation.

Research objectives

We aimed to development a liver model using HPCs.

Research methods

Hepatic stem/progenitor cells have the ability to multiply *ex vivo* and differentiate into hepatocytes and cholangiocytes. We have previously established HPC lines derived from the hepatic tissues of mice after ligation of venous drainage. In this study, the PBL hepatic lobe-derived HPCs multiplied in a bioreactor chamber to form liver organoid tissues comparable to liver lobules. These organoid tissues were implanted into syngeneic wild-type mice.

Research results

In the three-dimensional (3-D) liver tissue culture model, PBL-HPCs differentiated into mature hepatocyte-like cells, in binuclear populations, and with a bile duct–like structure. Quantitative real-time polymerase chain reaction analysis revealed that the cells expressed hepatocyte differentiation markers. In the 3-D liver tissue culture model derived from PBL-HPCs, the levels of urea and albumin production and activities of Cytochrome P450 enzymes were gradually enhanced.

Research conclusions

By mimicking the structure of the natural liver, our system was effective for the construction of a functional liver tissue model.

Research perspectives

This PBL-derived HPC line has the potential to proliferate, mature, and form implantable hepatic tissue.

ACKNOWLEDGEMENTS

The authors would like to acknowledge Sakai H and Miyagawa S (Department of Surgery, Shinshu University School of Medicine) for skillful technical assistance.

FOOTNOTES

Author contributions: Tagawa YI designed the study; Tamai M conducted all experiments; Kawase M performed statistical processing; Adachi E and Tagawa YI supervised the project; Tamai M and Tagawa YI wrote the manuscript; all authors read and approved the manuscript.

Supported by Grants-in-Aid for Scientific Research (A), No. 25242040 (to Tagawa YI); Grants-in-Aid for Challenging Exploratory Research, No. 20K21520 (to Tagawa YI); Grants-in-Aid for Early Career Scientists from the Japan Society for the Promotion of Science (JSPS), No. 19K20655 (to Tamai M); Grant-in-Aid for Scientific Research on Innovative Areas from the Ministry of Education, Culture, Sports, Science and Technology of Japan (MEXT), No. 231190003 (to Tagawa YI); Japan Agency for Medical Research and Development (AMED), No. 20fk0310102 (to Tagawa YI); and Building of Consortia for the Development of Human Resources in Science and Technology, Ministry of Education, Culture, Sports, Science and Technology, Japan (to Tamai M).

Institutional animal care and use committee statement: All animal experiments conformed to the internationally accepted principles for the care and use of laboratory animals. All animal experiments were conducted in accordance with policies of the Animal Experimentation Committee of the Tokyo Institute of Technology Guide for the Care and Use of Laboratory Animals. Specific protocols used in this study were approved by the Animal Experimentation Committee of the Tokyo Institute of Technology (approved protocols are D2015009, D2012019 and 2009024-5).

Conflict-of-interest statement: The authors declare no conflict of interest relevant to this manuscript.

Data sharing statement: No additional data are available.

ARRIVE guidelines statement: The authors have read the ARRIVE Guidelines, and the manuscript was prepared and revised according to the ARRIVE Guidelines.

Country/Territory of origin: Japan

ORCID number: Miho Tamai 0000-0001-8016-9663; Eijiro Adachi 0000-0002-0520-5211; Masaya Kawase 0000-0003-4003-4013; Yoh-ichi Tagawa 0000-0002-7673-6781.

S-Editor: Gao CC
L-Editor: Webster JR
P-Editor: Guo X

REFERENCES

1 **Dwyer BJ**, Macmillan MT, Brennan PN, Forbes SJ. Cell therapy for advanced liver diseases: Repair or rebuild. *J Hepatol* 2021; **74**: 185-199 [PMID: 32976865 DOI: 10.1016/j.jhep.2020.09.014]
2 **Sasaki K**, Akagi T, Asaoka T, Eguchi H, Fukuda Y, Iwagami Y, Yamada D, Noda T, Wada H, Gotoh K, Kawamoto K, Doki Y, Mori M, Akashi M. Construction of three-dimensional vascularized functional human liver tissue using a layer-by-layer cell coating technique. *Biomaterials* 2017; **133**: 263-274 [PMID: 28448819 DOI: 10.1016/j.biomaterials.2017.02.034]
3 **Iansante V**, Chandrashekran A, Dhawan A. Cell-based liver therapies: past, present and future. *Philos Trans R Soc Lond B Biol Sci* 2018; **373** [PMID: 29786563 DOI: 10.1098/rstb.2017.0229]
4 **Tricot T**, De Boeck J, Verfaillie C. Alternative Cell Sources for Liver Parenchyma Repopulation: Where Do We Stand? *Cells* 2020; **9** [PMID: 32121068 DOI: 10.3390/cells9030566]
5 **Inoue T**, Iwazaki N, Araki T, Hitotsumachi H. Human-Induced Pluripotent Stem Cell-Derived Hepatocytes and their Culturing Methods to Maintain Liver Functions for Pharmacokinetics and Safety Evaluation of Pharmaceuticals. *Curr Pharm Biotechnol* 2020; **21**: 773-779 [PMID: 32003687 DOI: 10.2174/1389201021666200131123524]
6 **Duan Y**, Catana A, Meng Y, Yamamoto N, He S, Gupta S, Gambhir SS, Zern MA. Differentiation and enrichment of hepatocyte-like cells from human embryonic stem cells *in vitro* and in vivo. *Stem Cells* 2007; **25**: 3058-3068 [PMID: 17885076 DOI: 10.1634/stemcells.2007-0291]
7 **Liu H**, Kim Y, Sharkis S, Marchionni L, Jang YY. In vivo liver regeneration potential of human induced pluripotent stem cells from diverse origins. *Sci Transl Med* 2011; **3**: 82ra39 [PMID: 21562231 DOI: 10.1126/scitranslmed.3002376]
8 **Mitaka T**, Mizuguchi T, Sato F, Mochizuki C, Mochizuki Y. Growth and maturation of small hepatocytes. *J Gastroenterol Hepatol* 1998; **13** Suppl: S70-S77 [PMID: 9792037]
9 **Prior N**, Hindley CJ, Rost F, Meléndez E, Lau WWY, Göttgens B, Rulands S, Simons BD, Huch M. Lgr5^{+} stem and progenitor cells reside at the apex of a heterogeneous embryonic hepatoblast pool. *Development* 2019; **146** [PMID: 31142540 DOI: 10.1242/dev.174557]
10 **Kuijk EW**, Rasmussen S, Blokzijl F, Huch M, Gehart H, Toonen P, Begthel H, Clevers H, Geurts AM, Cuppen E. Generation and characterization of rat liver stem cell lines and their engraftment in a rat model of liver failure. *Sci Rep* 2016; **6**: 22154 [PMID: 26915950 DOI: 10.1038/srep22154]
11 **Fausto N**. Liver regeneration and repair: hepatocytes, progenitor cells, and stem cells. *Hepatology* 2004; **39**: 1477-1487

[PMID: 15185286 DOI: 10.1002/hep.20214]
12 **Miyajima A**, Tanaka M, Itoh T. Stem/progenitor cells in liver development, homeostasis, regeneration, and reprogramming. *Cell Stem Cell* 2014; **14**: 561-574 [PMID: 24792114 DOI: 10.1016/j.stem.2014.04.010]
13 **Sakai H**, Tagawa Y, Tamai M, Motoyama H, Ogawa S, Soeda J, Nakata T, Miyagawa S. Isolation and characterization of portal branch ligation-stimulated Hmga2-positive bipotent hepatic progenitor cells. *Biochem Biophys Res Commun* 2010; **403**: 298-304 [PMID: 21075076 DOI: 10.1016/j.bbrc.2010.11.021]
14 **Tamai M**, Adachi E, Tagawa Y. Characterization of a liver organoid tissue composed of hepatocytes and fibroblasts in dense collagen fibrils. *Tissue Eng Part A* 2013; **19**: 2527-2535 [PMID: 23815236 DOI: 10.1089/ten.TEA.2012.0704]
15 **Soto-Gutierrez A**, Navarro-Alvarez N, Yagi H, Nahmias Y, Yarmush ML, Kobayashi N. Engineering of an hepatic organoid to develop liver assist devices. *Cell Transplant* 2010; **19**: 815-822 [PMID: 20573303 DOI: 10.3727/096368910X508933]
16 **Hosoya S**, Watanabe M, Ueno M, Adachi E. Hepatoblastoma-derived cells (HepG2) used to restore polarized hepatocyte morphology by culturing them in 3D collagen gels. *Kitasato Med J* 2014; **44**: 139-147
17 **Iwashiro H**, Hosoya S, Hirai K, Mima T, Ohashi S, Aihara T, Ito S, Ohara S, Adachi E. Characterization of dense artificial connective tissues generated in a newly designed bioreactor. *Connect Tissue Res* 2011; **52**: 340-352 [PMID: 21117908 DOI: 10.3109/03008207.2010.531801]
18 **Tsutsui M**, Ogawa S, Inada Y, Tomioka E, Kamiyoshi A, Tanaka S, Kishida T, Nishiyama M, Murakami M, Kuroda J, Hashikura Y, Miyagawa S, Satoh F, Shibata N, Tagawa Y. Characterization of cytochrome P450 expression in murine embryonic stem cell-derived hepatic tissue system. *Drug Metab Dispos* 2006; **34**: 696-701 [PMID: 16415121 DOI: 10.1124/dmd.105.007674]
19 **Tatsumi K**, Okano T. Hepatocyte Transplantation: Cell Sheet Technology for Liver Cell Transplantation. *Curr Transplant Rep* 2017; **4**: 184-192 [PMID: 28932649 DOI: 10.1007/s40472-017-0156-7]
20 **Heydari Z**, Najimi M, Mirzaei H, Shpichka A, Ruoss M, Farzaneh Z, Montazeri L, Piryaei A, Timashev P, Gramignoli R, Nussler A, Baharvand H, Vosough M. Tissue Engineering in Liver Regenerative Medicine: Insights into Novel Translational Technologies. *Cells* 2020; **9** [PMID: 32012725 DOI: 10.3390/cells9020304]
21 **Rana D**, Zreiqat H, Benkirane-Jessel N, Ramakrishna S, Ramalingam M. Development of decellularized scaffolds for stem cell-driven tissue engineering. *J Tissue Eng Regen Med* 2017; **11**: 942-965 [PMID: 26119160 DOI: 10.1002/term.2061]
22 **Kita S**, Yasuchika K, Ishii T, Katayama H, Yoshitoshi EY, Ogiso S, Kawai T, Yasuda K, Fukumitsu K, Mizumoto M, Uemoto S. The Protective Effect of Transplanting Liver Cells Into the Mesentery on the Rescue of Acute Liver Failure After Massive Hepatectomy. *Cell Transplant* 2016; **25**: 1547-1559 [PMID: 26883767 DOI: 10.3727/096368916X690999]
23 **Iwasaki J**, Hata T, Uemoto S, Fujimoto Y, Kanazawa H, Teratani T, Hishikawa S, Kobayashi E. Portocaval shunt for hepatocyte package: challenging application of small intestinal graft in animal models. *Organogenesis* 2013; **9**: 273-279 [PMID: 23974217 DOI: 10.4161/org.25968]
24 **Langer R**, Vacanti JP. Tissue engineering. *Science* 1993; **260**: 920-926 [PMID: 8493529 DOI: 10.1126/science.8493529]
25 **Han F**, Wang J, Ding L, Hu Y, Li W, Yuan Z, Guo Q, Zhu C, Yu L, Wang H, Zhao Z, Jia L, Li J, Yu Y, Zhang W, Chu G, Chen S, Li B. Tissue Engineering and Regenerative Medicine: Achievements, Future, and Sustainability in Asia. *Front Bioeng Biotechnol* 2020; **8**: 83 [PMID: 32266221 DOI: 10.3389/fbioe.2020.00083]
26 **Forbes SJ**, Gupta S, Dhawan A. Cell therapy for liver disease: From liver transplantation to cell factory. *J Hepatol* 2015; **62**: S157-S169 [PMID: 25920085 DOI: 10.1016/j.jhep.2015.02.040]
27 **Kaur S**, Tripathi DM, Venugopal JR, Ramakrishna S. Advances in biomaterials for hepatic tissue engineering. *Curr Opin Biomed Eng* 2020; **13**: 190-196 [DOI: 10.1016/j.cobme.2020.05.005]
28 **Nicolas CT**, Hickey RD, Chen HS, Mao SA, Lopera Higuita M, Wang Y, Nyberg SL. Concise Review: Liver Regenerative Medicine: From Hepatocyte Transplantation to Bioartificial Livers and Bioengineered Grafts. *Stem Cells* 2017; **35**: 42-50 [PMID: 27641427 DOI: 10.1002/stem.2500]
29 **Salvatore L**, Gallo N, Natali ML, Terzi A, Sannino A, Madaghiele M. Mimicking the Hierarchical Organization of Natural Collagen: Toward the Development of Ideal Scaffolding Material for Tissue Regeneration. *Front Bioeng Biotechnol* 2021; **9**: 644595 [PMID: 33987173 DOI: 10.3389/fbioe.2021.644595]
30 **Messina A**, Luce E, Hussein M, Dubart-Kupperschmitt A. Pluripotent-Stem-Cell-Derived Hepatic Cells: Hepatocytes and Organoids for Liver Therapy and Regeneration. *Cells* 2020; **9** [PMID: 32059501 DOI: 10.3390/cells9020420]

World Journal of Gastroenterology

Submit a Manuscript: https://www.f6publishing.com

World J Gastroenterol 2022 April 14; 28(14): 1455-1478

DOI: 10.3748/wjg.v28.i14.1455

ISSN 1007-9327 (print) ISSN 2219-2840 (online)

ORIGINAL ARTICLE

Retrospective Cohort Study

Clinical classification of symptomatic heterotopic pancreas of the stomach and duodenum: A case series and systematic literature review

Michael T LeCompte, Brandon Mason, Keenan J Robbins, Motoyo Yano, Deyali Chatterjee, Ryan C Fields, Steven M Strasberg, William G Hawkins

Specialty type: Gastroenterology and hepatology

Provenance and peer review: Unsolicited article; Externally peer reviewed.

Peer-review model: Single blind

Peer-review report's scientific quality classification

Grade A (Excellent): 0
Grade B (Very good): B, B, B
Grade C (Good): C, C
Grade D (Fair): D
Grade E (Poor): 0

P-Reviewer: Fujino Y, Japan; Mikulic D, Croatia; Wang J, China; Wu YH, , China; Yang CW, China

Received: June 8, 2021
Peer-review started: June 8, 2021
First decision: June 27, 2021
Revised: July 11, 2021
Accepted: March 4, 2022
Article in press: March 4, 2022
Published online: April 14, 2022

Michael T LeCompte, Department of Surgical Oncology, University of North Carolina, Raleigh, NC 27608, United States

Brandon Mason, Department of Radiology, Stillwater Medical Center, Stillwater, OK 74074, United States

Keenan J Robbins, Department of General Surgery, Washington University St. Louis, St. Louis, MO 63110-8109, United States

Motoyo Yano, Department of Radiology, Mayo Clinic, Phoenix, AZ 8505, United States

Deyali Chatterjee, Department of Pathology and Immunology, MD Anderson Cancer Center, Houston, TX 77030, United States

Ryan C Fields, Department of Surgical Oncology, Washington University School of Medicine, St. Louis, MO 63110-8109, United States

Steven M Strasberg, William G Hawkins, Section of Hepatobiliary-Pancreatic and GI Surgery, Washington University St. Louis, St. Louis, MO 63110, United States

Corresponding author: Michael T LeCompte, MD, Assistant Professor, Department of Surgical Oncology, University of North Carolina, 2800 Blue Ridge Rd. Suite 300, Raleigh, NC 27608, United States. mtleco01@gmail.com

Abstract

BACKGROUND

Heterotopic pancreas (HP) is an aberrant anatomic malformation that occurs most commonly in the upper gastrointestinal tract. While the majority of heterotopic pancreatic lesions are asymptomatic, many manifest severe clinical symptoms which require surgical or endoscopic intervention. Understanding of the clinical manifestations and symptoms of HP is limited due to the lack of large volume studies in the literature. The purpose of this study is to review symptomatic cases at a single center and compare these to a systematic review of the literature in order to characterize common clinical manifestations and treatment of this disease.

AIM
To classify the common clinical manifestations of heterotopic pancreas.

METHODS
A retrospective review was conducted of pathologic samples containing heterotopic pancreas from 2000-2018. Review was limited to HP of the upper gastrointestinal tract due to the frequency of presentation in this location. Symptomatic patients were identified from review of the medical records and clinical symptoms were tabulated. These were compared to a systematic review of the literature utilizing PubMed and Embase searches for papers pertaining to heterotopic pancreas. Publications describing symptomatic presentation of HP were selected for review. Information including demographics, symptoms, presentation and treatment were compiled and analyzed.

RESULTS
Twenty-nine patient were identified with HP at a single center, with six of these identified has having clinical symptoms. Clinical manifestations included, gastrointestinal bleeding, gastric ulceration with/without perforation, pancreatitis, and gastric outlet obstruction. Systemic review of the literature yielded 232 publications detailing symptomatic cases with only 20 studies describing ten or more patients. Single and multi-patient studies were combined to form a cohort of 934 symptomatic patients. The majority of patients presented with abdominal pain (67%) combined with one of the following clinical categories: (1) Dyspepsia, (n = 445, 48%); (2) Pancreatitis (n = 260, 28%); (3) Gastrointestinal bleeding (n = 80, 9%); and (4) Gastric outlet obstruction (n = 80, 9%). The majority of cases (n = 832, 90%) underwent surgical or endoscopic resection with 85% reporting resolution or improvement in their symptoms.

CONCLUSION
Heterotopic pancreas can cause significant clinical symptoms in the upper gastrointestinal tract. Better understanding and classification of this disease may result in more accurate identification and treatment of this malformation.

Key Words: Heterotopic pancreas; Ectopic pancreas; Aberrant pancreas; Pancreatic rest; Groove pancreatitis

Core Tip: This is a retrospective study that compares a single institution's experience with that of a systematic literature review to evaluate the common clinical symptoms and presentation of heterotopic pancreas. To date, there have been numerous small volume studies in the literature reporting heterotopic pancreas. However, these studies predominantly report asymptomatic or incidental cases and there are few studies characterizing the symptomatic presentation of this disease. The goal of this study is to classify symptomatic cases of heterotopic pancreas to better identify the presentation and management of this disease.

Citation: LeCompte MT, Mason B, Robbins KJ, Yano M, Chatterjee D, Fields RC, Strasberg SM, Hawkins WG. Clinical classification of symptomatic heterotopic pancreas of the stomach and duodenum: A case series and systematic literature review. *World J Gastroenterol* 2022; 28(14): 1455-1478
URL: https://www.wjgnet.com/1007-9327/full/v28/i14/1455.htm
DOI: https://dx.doi.org/10.3748/wjg.v28.i14.1455

INTRODUCTION

Heterotopic pancreas (HP) is an uncommon embryologic abnormality, defined as aberrant pancreatic tissue separated anatomically from the main body and blood supply of the pancreas. This tissue can be located throughout the gastrointestinal tract with a reported frequency of 1/500 in surgical specimens [1]. Most of these lesions are asymptomatic and are identified incidentally on pathologic specimens or at autopsy. However, some of these anatomic anomalies can manifest clinical symptoms. When this occurs, the clinical presentation can often be severe, requiring surgical intervention[2].

Knowledge of the clinical features of this disease process and the appropriate treatment is limited. While reports of clinically relevant cases are present in the literature dating back to 1727, the majority of the available literature consists of case reports, with few studies containing more than a handful of patients[3]. Thus, little is known about the "typical" clinical manifestations of HP due to small volume

studies. Classification of this aberrancy is further limited by the diversity of possible symptoms which are often dictated by the anatomic location, size and functionality of ectopic lesion. While HP is most commonly located in the foregut, it has been identified in tissues including the small bowel, colon, gallbladder, spleen, esophagus and mediastinum[4]. This leads to further complexity in appropriate diagnosis and treatment of HP as it is often mimics other disease processes.

To address the deficit in description and classification of symptomatic HP we evaluated our center's experience with symptomatic HP cases and compared it to a systematic review of the available literature. The scope of this study focuses on describing and characterizing the common clinical manifestations for HP within the stomach and duodenum as these locations represent the majority of cases. Cases identified in this study were compared with the results of a review of the available reported cases to identify the common symptoms, presentation, and treatment options for this disease process.

MATERIALS AND METHODS

A review of pathology specimens from 2000-2018 was conducted at a single academic institution. Approval was obtained from the institutional review board (#210811062). Specimens with pathologic confirmation of heterotopic pancreatic tissue were identified. Lesions found in the upper gastrointestinal tract were selected in adult patients over 18 for final review. Electronic medical records were analyzed and factors associated with the clinical presentation, symptoms, diagnosis and treatment were identified in each of the cases. Based upon the clinical history and presentation, patients were classified as symptomatic or asymptomatic. Symptomatic patients were defined as those who presented with upper gastrointestinal complaints which could be attributed to the identified pathology and ultimately resolved with treatment or removal of the ectopic tissue. Asymptomatic patients were classified as patients in whom the presence of heterotopic pancreas was identified in the workup or treatment of symptoms related to other clinically established pathology, or were found incidentally in a surgical pathologic specimen. Symptomatic patients were analyzed and categorized based upon their clinical features, presentation and treatment.

The cohort of patients with symptomatic manifestations from our institution was then compared that of published cases in the literature. A literature review of heterotopic pancreas using Embase and PubMED databases was conducted. The terms "heterotopic pancreas", "ectopic pancreas", and "aberrant pancreas" were searched. Publications printed in the English language were selected. Inclusion criteria were limited to publications reporting symptomatic cases of pathologically confirmed heterotopic pancreas located in stomach or duodenum. Publications which reported symptomatic and asymptomatic cases were excluded if they lacked characterization and description of clinical symptoms. Patients from the included publications were combined into a single cohort and categorized based on the presenting clinical symptoms, available demographic information and treatment. This sample was then compared with a series of patients identified at our institution for similarities. Descriptive statistics were employed to tabulate and report the results.

RESULTS

Institutional results

Twenty-nine pathology specimens were identified with pancreatic heterotopia in the upper gastrointestinal tract during the study period of January 2000 to December 2018. Of these, fourteen patients were female (48%). Six patients (20%) were identified as having symptoms related to an HP lesion. The remaining patients were identified as asymptomatic with incidentally noted lesions on pathology or discovered on endoscopy (Table 1). Five of the symptomatic patients underwent surgical treatment of their disease process and one declined surgery in favor of medical management.

Of the symptomatic patients, two (7%) presented with elevated lipase and evidence of pancreatitis within the heterotopic lesion, two patients presented with gastrointestinal bleeding or anemia, one patient (3.4%) presented with perforated gastric ulceration related to a heterotopic lesion, and one patient presented with gastric outlet obstruction from a HP lesion located at the pylorus. The six case presentations are briefly summarized below.

Case 1: 28-year-old male who presented as an outpatient with a history of mid-epigastric abdominal pain, nausea and daily vomiting for approximately 3 mo. He reported associated anorexia and a weight loss of approximately 40 Lbs. On exam he was noted to be cachectic with a BMI of 17 with moderate abdominal tenderness to palpation in the upper abdomen. Workup demonstrated an elevated lipase of 123 and an amylase of 141. Computed tomography revealed a 3.4cm hyper-enhancing mass near the pylorus on CT imaging. This was associated with a complex fluid collection within the wall of the stomach and evidence of inflammatory stranding, gastric thickening and edema. Endoscopy revealed a mass within the wall of the gastric antrum. Endoscopic ultrasound and biopsy demonstrated pancreatic acini. The patient was subsequently taken to the operating room for antrectomy and billroth II

Table 1 Pathologic specimens identified with heterotopic pancreas; specimens are divided into symptomatic classification

Clinical features	*n*	Percent
Total patients	29	100%
Symptomatic HP	6	20.0%
Pancreatitis	2	7.0%
Bleeding/anemia	2	7.0%
Peptic ulceration	1	3.4%
Gastric outlet obstruction	1	3.4%
Asymptomatic HP	23	80.0%
Incidental finding on pathology	5	17.2%
Noted on Endoscopy	17	58.6%
Identified at time of surgery	1	3.4%

HP: Heterotopic pancreas.

reconstruction. His pathology demonstrated heterotopic pancreatic tissue, 3.5 cm in size within the gastric antrum (Figure 1). In addition, there was an associated 4.3 cm pseudocyst within the gastric wall with surrounding inflammation. The patient was seen in follow up clinic one month later and was noted to be eating well with an increase in his weight of 14 Lbs since discharge.

Case 2: 37-year-old male who presented with a chief complaint of melena, epigastric abdominal pain, anorexia and weight loss of approximately 20 Lbs. An esophagogastroduodenoscopy was performed which demonstrated a 2 cm submucosal mass with overlying ulcerated mucosa. An endoscopic ultrasound and FNA were obtained. Results demonstrated atypical cells. Radiographic imaging was obtained, however computed tomography scan was unable to identify or localize the mass. Surgical resection was offered, and the patient underwent a laparoscopic assisted gastric wedge resection. Pathology from the specimen was identified as a 2.5 cm × 2.0 cm mass consistent with multilobulated pancreatic tissue located between the gastric mucosa and muscularis propria with evidence of inflammation and ulcerated mucosa. The patient recovered without complication and with resolution of his anemia.

Case 3: 42-year-old male presented with acute abdominal pain and the presence of free air on upright abdominal film. He was noted to be tachycardic and with evidence of peritonitis on exam. A computed tomography scan confirmed the presence of free air and intraperitoneal fluid in the abdomen. His past medical history was notable only for a history of gastroesophageal reflux and indigestion that was refractory to years of proton pump inhibitor therapy. He was taken to the operating room for exploration where a large ulcer was identified upon opening the lesser sac in the posterior wall of the stomach approximately 6cm from the pylorus. A distal gastrectomy and reconstruction with a billroth II gastrojejunostomy was performed.

Pathology from the resected specimen demonstrated a transmural gastric perforation with evidence of associated pancreatic tissue within the gastric wall and along the edge of the ulcerated mucosa. The patient tolerated the procedure well and remained symptom free.

Case 4: 43-year-old male presented to the emergency department with chronic symptoms of non-bloody, non-billious vomiting and intolerance of oral intake. A detailed history revealed that the patient had suffered from intermittent vomiting and progressive oral intolerance over the prior 6 mo. A computed tomography scan was obtained which demonstrated a grossly distended stomach and a hyperenhancing mass as the level of the pylorus and first portion of the duodenum with an associated gastric outlet obstruction.

He was taken to surgery where an abnormal mass was palpated near the level of the pylorus. A distal gastrectomy was performed with a billroth II reconstruction. Final pathology demonstrated heterotopic pancreas at the level of the pylorus.

Case 5: 52-year-old female presented with anemia underwent upper endoscopy, which showed a submucosal mass along the lesser curve of the stomach near the incisura. EUS was performed, where a submucosal mas was identified with ulceration concerning for a gastrointestinal stromal tumor. Fine needle aspiration was non-diagnostic. She proceeded to surgery where a laparoscopic wedge resection was performed. Her pathology showed a 1.5 cm × 1.1 cm × 1.0 cm mass of pancreatic tissue. On post-operative follow up she was noted to have resolution of her anemia.

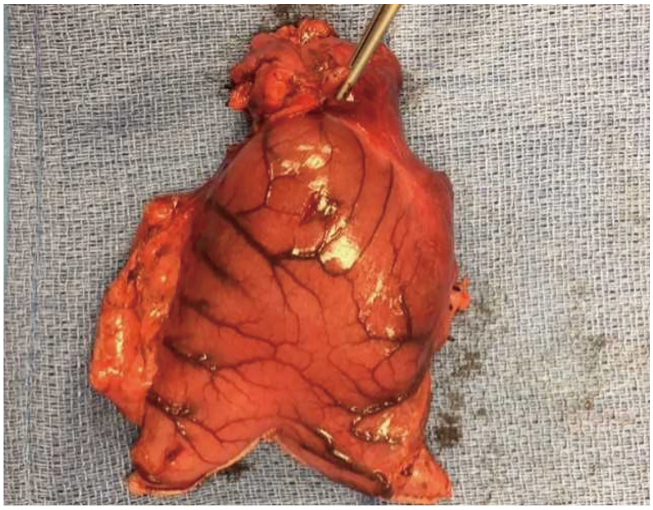

DOI: 10.3748/wjg.v28.i14.1455

Figure 1 Image demonstrating the gastric antrum with an intramural mass identified within the wall of the stomach.

Case 6: 29-year-old male presented with abdominal pain and anorexia over the course of on year with a weight loss of 75 Lbs. Imaging with computed tomography showed 2.6 cm × 1.6 cm mass along the lesser curve of stomach and the patient was noted to have mild elevation in his amylase and lipase. Upper endoscopy with endoscopic ultrasound demonstrated a 2.3 cm subepithelial lesion along the lesser curve with surrounding gastritis. Biopsy demonstrated chronic gastritis and benign pancreatic tissue. The patient was placed on proton pump inhibitors and carafate with improvement in his symptoms. He was referred for surgical evaluation but declined intervention as his symptoms had improved with medical therapy.

Results of literature analysis

A systematic review of the literature was conducted to identify published cases of HP lesions. The initial search resulted in 1220 unique publications. Of these, 232 publications described cases of symptomatic lesions and met the inclusion criteria. The majority of these publications (n = 182) were single patient case studies. There were only 20 studies identified which contained more than 10 symptomatic patients in their series. The majority of the larger studies contained cases of both symptomatic and asymptomatic disease with few publications dedicated to describing symptomatic cases. In total, these studies included 1762 patients of which 934 patients were reported to have symptomatic lesions in the stomach or duodenum and comprised the total cohort of this evaluation. Demographic information was provided for 864 patients (94%) of which the mean age at symptom presentation was 43 years old and 564 were male (61%). In total, there were 556 patients with gastric lesions (59%) and 378 with duodenal lesions (41%).

A summary of the clinical cases of HP was performed by individual publication and were tabulated for review in Table 2. The majority of patients presented with epigastric abdominal pain (n = 620, 67%). In addition to pain, the remaining symptoms were noted to fall within one of 4 predominant diagnostic categories: (1) Dyspepsia, which included symptoms of epigastric pain, eructation, nausea or bloating with meals (n = 445, 48%); (2) Pancreatitis within the ectopic lesion (n = 260, 28%); (3) Gastrointestinal bleeding (n = 80, 9%); and (4) Gastric outlet obstruction (n = 80, 9%). There were also 37 patients who presented with jaundice and biliary obstruction due to periampullary lesions (4%), and 3 patients with perforated ulcers. The remaining patients presented with various symptoms which included fever, diarrhea, abscess, carcinoid syndrome and dysphagia but were in single cases or small numbers. The majority of patients who presented with pancreatitis were found to have radiographic evidence of pseudocyst formation or cystic degeneration of an ectopic lesion (n = 251, 97%). These lesions were commonly located within the wall of the stomach or duodenum or were characterized as "groove pancreatitis" with ectopic pancreatic tissue located between the medial duodenal wall and the head of the pancreas. Of the patients with clinical and radiographic evidence of pancreatitis, only 50 cases (19%) reported elevations in biochemical markers such as serum amylase or lipase to correlate with the clinical or radiographic evidence of pancreatitis. One hundred forty-five cases (56%) were reported to be associated with alcohol consumption as the inciting etiology.

The majority of cases (n = 832, 90%) underwent surgical or endoscopic management of their heterotopic pancreatic lesion, while 92 were observed or managed medically. Surgical therapy ranged from radical gastrectomy or pancreaticoduodenectomy to local excision or endoscopic resection. Available data on the therapies provided are listed in Table 3. Data on the effect of treatment on symptom control was available for 645 patients. Of the cases which reported post-intervention follow

Table 2 Summary of systematic literature review listed by publication, number of symptomatic cases, demographics and clinical symptoms

Ref.	Year	Total patients	Symptomatic patients	Mean age	Gastric lesions	Duodenal lesions	Location other than foregut	Abdominal Pain	Dyspepsia	Gastrointestinal Bleeding	Pancreatitis	Gastric outlet obstruction	Perforation	Nausea	Jaundice
Noh *et al*[5]	2019	5	5	32	5			5			5				
Zhou *et al*[6]	2019	93	78	39.75	78			38	41					4	
Betzler *et al*[7]	2017	67	11	53		11		8			7				
Jun *et al*[8]	2017	165	79	45.2	46	18	15	64	64					64	
Zhang *et al*[9]	2016	184	26	49	25	1		26	26						1
Liao *et al*[10]	2014	2	2	36	2				2						
Chou *et al*[11]	2014	13	13	40.8	13			6	7						
Endo *et al*[12]	2014	2	2	74	1	1		1		1					
Liu *et al*[13]	2013	9	9	48.3	9			6	9			1			
Zhong *et al*[14]	2013	60	30	39	30			16	24	6					
Shah *et al*[15]	2011	30	4	53	1	1	2	1			1	1			
Park *et al*[16]	2011	26	9	34	9			4	9						
Wei *et al*[17]	2011	11	11	52	3	8		6	8	3				2	
Ryu *et al*[18]	2010	8	4	36	4				4						
Yuan *et al*[19]	2009	2	2	61		1	1	1	1						
Khashab *et al* [20]	2009	2	2	32	2				1	1					
Casetti *et al*[21]	2009	58	58	44.7		58		46	1		58				
Jovanovic *et al* [22]	2008	13	13	41.5		13		10			6	1		7	4
Chen, H *et al* [23]	2008	39	15	46	12	1	2	9	9	5					
Chen, S *et al* [24]	2008	20	13	39	12	1		9	4						
Rebours *et al* [25]	2007	105	105	46		105		91		5	105			30	13
Tison *et al*[26]	2007	9	9	49.6		9		8			9	9			1

Ormarsson *et al* [4]	2006	30	11	49.2	11			5	5					1		
Pessaux *et al* [27]	2006	12	12	42.4		12		11		1		12		8		
Ayantunde *et al*[28]	2006	3	3	55	3			1	1				2	2		
Chatelain *et al* [29]	2005	2	2	40.5		2		2				2	2			
Zinkiewicz *et al* [30]	2003	12	7	34	6	1		7	7							
Shi *et al*[31]	2002	7	7	41	1	4	2		2	1			1			3
Huang *et al*[32]	2002	2	2	46	2								2			
Otani *et al*[33]	2000	34	2	43	2			1	1							
Hsia *et al*[34]	1999	17	10	47.5	8	2			8	2						
Fekete *et al*[35]	1996	6	6	40	1	5		6		1		6				
Flejou *et al*[36]	1993	10	10	41	1	9		7		1		10				2
Claudon *et al* [37]	1988	2	2	41	2			2	2							
Pang *et al*[38]	1988	32	14	44	3	4	7	6	5	2				1		1
Lai *et al*[39]	1986	37	9	50	6	3		7	7	1			1			
Mollitt *et al*[40]	1984	9	6	6.8	6			3	3				3			
Armstrong *et al* [41]	1981	34	13	51	5	5	3		11	2						
Thoeni *et al*[42]	1980	9	6	43	6			1	1	1		1	1			
Yamagiwa *et al* [43]	1977	64	26	45.2	23	3		17	15	4				8		
Dolan *et al*[44]	1974	212	73	60	43	25	5	52	46	7				1		
Eklof *et al*[45]	1973	4	4	7	3	1		3	2					1		
Nebel *et al*[46]	1973	3	3	28	1	2		3	3							
McGarity *et al* [47]	1971	2	2	33	2				2				1	2		
Abrahams *et al* [48]	1966	9	9	49.8	5	4			9	6						

Tonkin *et al*[49]	1962	4	4	44	2	2		3	4			1				
Dirks *et al*[50]	1961	3	3	44.6	0	3		3	2	1						
Martinez *et al* [51]	1958	51	28	43.1	21		7	16	19	2		3				
Waugh *et al*[52]	1946	5	5	34.8	5			3	3	2						
De Castro Barboso *et al*[1]	1947	41	17	43	10	7		10	11	4						
Single case studies (*n* = 182)[3,53-233]		182	182	39.1	126	56		96	66	21	38	51	3	57	12	
Total		1761	978	43	556	378	44	620	445	80	260	80	3	188	37	

up, five hundred forty-nine patients demonstrated symptom resolution with treatment (85%), 63 were reported to have symptom improvement (9.7%) and 33 reported no improvement (5.1%). Based on the level of detail reported in the literature, there was no delineation of whether patients who did not improve were treated medically or *via* surgical or endoscopic intervention. Likewise, there was no study providing a direct comparison of treatment outcomes between medical versus surgical therapies nor was there a study comparing outcomes between different interventional therapies.

DISCUSSION

Heterotopic pancreas is a congenital anomaly, often identified incidentally in asymptomatic patients, yet it has the ability to illicit significant clinical symptoms in some cases. These lesions can arise in tissues throughout the body including stomach, small bowel, gallbladder, esophagus and mediastinum, leading to a wide range of manifestations[234]. Characterization of symptomatic lesions is difficult due to the relative infrequency of this diagnosis and the variability in presentation. This often leads to misidentification and suboptimal management in many cases. Large volume studies characterizing the common presentation of HP are lacking and the aim of this study was to provide a conglomerate population to classify the typical clinical presentation within the foregut and aid in classification. With improved understanding and recognition of this disease process, clinicians can render more appropriate treatment decisions that may save patients morbidity from radical resection.

The clinical manifestations of HP are dictated in large part by two factors, the location and the functionality of the lesion. The anatomic location is often predetermined early in life by embryologic development. The exact mechanism by which this abnormality forms is not well understood however, it is believed to be related to a disruption in the normal embryologic migration of the pancreas. Formation of dorsal and ventral pancreatic buds results from endodermal outpouchings of the duodenum[235]. Aberrant separation of these tissues from the visceral endoderm may be responsible for retained pancreatic tissue within the developing gastrointestinal tract and subsequent migration as the embryo develops[235]. However, this theory does not fully account for the development of HP in all cases as this

Table 3 Treatment of heterotopic pancreas; listing of surgical or endoscopic procedures performed for patients with symptomatic heterotopic pancreas by procedure

Procedure	*n*	Percent (%)
Distal gastrectomy	84	10.50
Billroth I reconstruction	14	1.70
Billroth II reconstruction	64	8.00
Roux-en-Y reconstruction	6	0.75
Gastric wedge resection	81	10.00
Subtotal gastrectomy	18	2.25
Total gastrectomy	5	0.63
Gastrotomy and local excision	42	5.30
Partial gastrectomy NOS	215	27.00
Pancreaticoduodenectomy	168	21.00
Trans-duodenal excision	19	2.40
Partial duodenectomy	7	0.90
Ampullectomy	2	0.25
Endoscopic submucosal excision	158	19.77
Total procedures	799	100.00

anomaly has also been reported to be found in tissues outside the gastrointestinal tract including the gallbladder, fallopian tube, umbilicus, mediastinum, omentum, mesentery and spleen[9,39]. An alternative explanation in these cases is the "metaplasia" theory in which totipotent endodermal tissues develop into pancreatic tissue during embryologic development and can present in various tissues throughout the body[235].

However, the majority of these lesions are located within the upper gastrointestinal tract with surgical and autopsy data reporting a frequency within the stomach of 25-52%, 27-36% in the duodenum and 15%-17% in the jejunum[9,44,235]. HP symptoms often mimic common upper gastrointestinal pathology and are difficult to identify. The location within the foregut often dictates symptom manifestation with peripyloric lesions more likely to lead to gastric outlet obstruction while periampullary lesions may cause biliary obstruction[17,80,164,236,237].

In addition to the anatomic location, the histologic location within the layers of the visceral wall may also have an effect on symptom presentation. HP occurs most frequently between the submucosa and lamina propria but can be found within all layers of the visceral wall[238]. Submucosal lesions may be more likely to cause ulceration with local gastritis or duodenitis while transmural lesions which involve all layers of the bowel wall can lead to chronic inflammation, and ultimately stricture or perforation[77].

While location may often explain symptom presentation it does not fully account for why some lesions are symptomatic while others found in similar locations are not. The remaining factor can be potentially explained by the functionality of the lesion, and the ability to perform the normal exocrine and endocrine functions of the pancreas. Histopathologic evaluation by Heinrich in 1909 demonstrated differences in the composition of these lesions which were later revised by Fuentes in 1973[239,240]. These classification systems categorized HP lesions based on the presence of all the cellular components of functional pancreas tissue (Type I in both categories) versus presence of ducts, acinar tissue or islet cells alone (Fuentes classification types II, III and IV respectively)[240] (Figure 2). The presence or absence of histologic elements may affect the functionality of the lesion and contribute to its ability (or inability) to produce symptoms. It has been proposed that lesions with functional exocrine potential can produce local chemical irritation of surrounding tissues while those without appropriate ductal drainage may lead to pancreatitis and pseudocyst formation within the lesion[4,60].

The clinical nature of HP may therefore have variable patterns of presentation which are highly dependent on both the location and the functional ability of the lesion. Since the majority of identified cases are located within the upper gastrointestinal tract, the scope of this study was restricted to identifying and characterizing symptoms within these locations. The combined experience from our center and the analysis of the published literature demonstrated that the majority of clinically significant cases can be categorized within 4 main groups. These categories are significant as they are common presentations of other pathology within the upper GI tract and can lead to difficulty in diagnosing and treating this pathology.

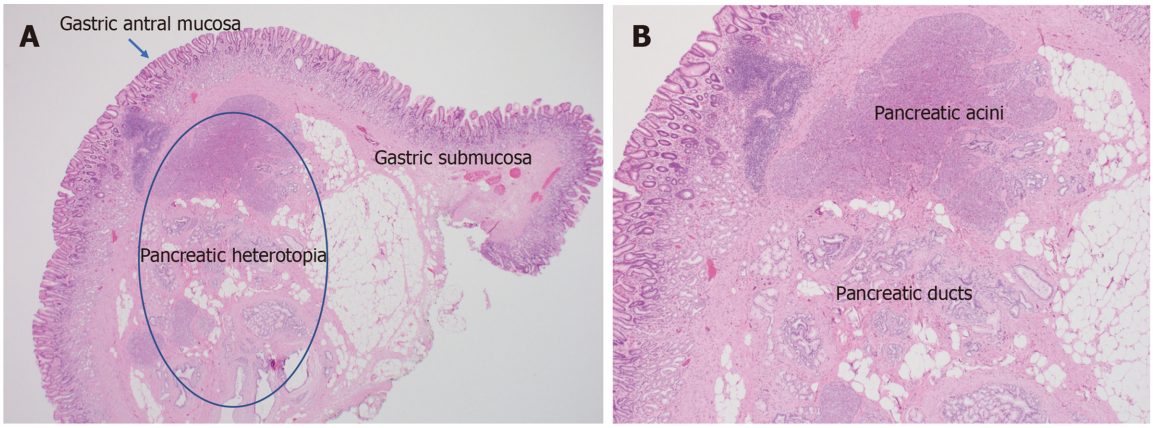

DOI: 10.3748/wjg.v28.i14.1455

Figure 2 Histopathologic images. A: Histologic appearance of heterotopic pancreas in the stomach; B: High power view of heterotopic pancreas demonstrating pancreatic acinar and ductal architecture.

Dyspepsia

The majority of cases identified in this series reported symptoms consistent with epigastric abdominal pain, bloating, belching and nausea which are typically associated with eating. This category consisted predominantly of patients with gastric lesions. The manifestation of symptoms has been thought to be related to local chemical irritation of the gastric mucosa by products of the exocrine pancreas[87]. This acts as an inciting factor that then may lead to inflammatory mucositis and subsequent gastritis or duodenitis, with or without ulceration. As many of these patients present with identical symptoms to those with peptic ulcer disease (PUD) (and indeed, are often misdiagnosed as such), many authors argue that ulceration is the inciting factor and etiology of the majority of symptoms associated with HP [2,44]. In the series of 34 patients reported by Armstrong *et al*[41] the extent of mucosal involvement on pathology was correlated with symptoms suggesting a causal relationship. In the series published by Lai *et al*[39] comparing the histology of symptomatic and asymptomatic patients, 49% of symptomatic patients had mucosal ulcers while asymptomatic patients in their series lacked objective evidence of ulceration or gastritis.

Mucosal ulceration in some cases may progress to visceral perforation. This is thought to be the result of normal evolution of inflammation seen in peptic ulcer disease, with ulceration of the protective mucosal barrier, caused by heterotopic pancreas, acting as the initial catalyst. Perforation may also be related the degree of penetration within the gastric wall of the ectopic lesion. Extension of the HP lesions through the serosa can be seen in up to 4% of histologically examined specimens[84]. Lesions which penetrate deeper through the layers of the gastric wall can lead to transmural inflammation, necrosis and perforation of the stomach wall. This theory is supported by the histologic findings reported by Martinez *et al*[51] demonstrating inflammation and fibrosis extending through multiple layers of the gastric wall on tissue histology depending on the histologic depth of the lesion. Overall, this is a rare complication of HP, with only three identified publications describing visceral perforation related to HP[77,121,241]. We report the fourth known case above in Case 3 where the transmural gastric ulceration was clearly associated with HP. It is possible that additional cases exist but remain undocumented as they may have been treated with omental patching without resection or biopsy. Still, this remains an uncommon symptomatic presentation of HP compared to local mucosal ulceration.

While there are clear associations for mucosal ulceration with the symptomatic presentations of HP it does not account for all cases. Multiple series including that of Dolan *et al*[44] report on patients with symptoms of dyspepsia who did not exhibit evidence of ulceration or gastritis. This is also supported by reports such as that by Ormarsson *et al*[4] and Barbosa *et al*[242] which demonstrate resolution of symptoms in patients undergoing resection of HP with and without the presence of ulceration. In these patients, the etiology of abdominal pain and/or dyspepsia is not fully clear. It has been proposed that exocrine secretions into the stomach may affect the pH composition of the gastric lumen leading to alterations in the digestive process, gas formation and bloating, although confirmation of this *via* testing of gastric pH in the setting of HP has not been conducted to our knowledge[47]. In addition, it is hard to conceive that these lesions, unless the reach a large size, are able to secrete enough volume to significantly alter the pH composition of gastric juices.

The majority of patients with HP and dyspeptic symptoms are initially misdiagnosed and managed with medical therapy designed for reduction of acid secretion. It is unclear whether traditional treatments for gastritis and PUD is beneficial in these patients. If the inciting physiology is chemical irritation from pancreatic secretions, then traditionally prescribed therapies to reduce acid secretion would be unlikely to help alleviate symptoms. In patients who develop mucosal ulceration there may be some plausible benefit that acid reduction may prevent ulcer progression once breakdown of the

mucosal barrier has already occurred. However, it is not clear whether this can promote adequate ulcer resolution in the setting of HP or prevent future recurrent ulceration since acid secretion is not believed to be the causative factor for inflammation or ulceration in this setting[41]. There were few symptomatic patients in the reviewed studies who were managed with observation or medical therapy and long term follow up was lacking. The single patient treated with medical therapy at our institution (Case 6), demonstrated symptomatic improvement and to date, has not returned with recurrent symptoms over six years of observation. However, an adequate evaluation of medical management compared to surgical or endoscopic resection is lacking and further study is needed to evaluate the optimal treatment modality.

Heterotopic pancreatitis

Manifestations of acute and chronic pancreatitis in HP tissues were the second most common presentation in our review. Clinical symptoms may include abdominal pain, nausea, vomiting, anorexia and weight loss[85,163]. Similar to orthotopic pancreatitis, the most common causes can be related to alcohol, medications, smoking, autoimmune disease or inadequate ductal drainage[243]. According to the histologic classification system proposed by Heinrich and Fuentes, heterotopic pancreas types I-III contain functional pancreatic acini and ductal components. Impaired drainage and outflow obstruction of these ducts may lead to pancreatitis and pseudocyst formation[241]. Cystic formation within the visceral wall of the stomach or duodenum was demonstrated radiographically in the majority of patients with pancreatitis in our series. This was often associated with radiographic signs of stranding, edema and inflammation. This pathophysiology is commonly seen in "groove pancreatitis" where ectopic pancreatic tissue between the duodenal wall and pancreas lack appropriate enteric drainage leading to inflamation and cystic degeneration[244,245].

Diagnosis of heterotopic pancreatitis is made through a combination of clinical presentation, radiographic imaging and biochemical evaluation[243,245]. Serum labs may yield mild elevations of amylase and lipase however, these levels are usually only modestly elevated, even in the setting of severe inflammation due to the relatively small volume of pancreatic tissue within the heterotopic lesion [235]. Leakage of enzyme-rich pancreatic fluid can cause pancreatic pseudocyst formation within the gastric wall producing symptoms of early satiety and gastric outlet obstruction[60]. This finding results in the appearance of a cystic structure within the wall of the stomach or bowel and is often mistaken for a duplication cyst or mucinous neoplasm[208].

Conservative treatment may be successful in mild cases of this disease process. Investigation of the inciting etiology should be performed with cessation of alcohol or smoking when applicable. However, in patients with repeated episodes of abdominal pain, oral intolerance and vomiting (as in Case 1 above), surgical intervention may be required. When accurately diagnosed, drainage of the pseudocyst and local excision is typically adequate. However, in patients with recurrent groove pancreatitis or cystic degeneration of the duodenal wall, more radical surgical intervention is often required. Groove pancreatitis may require pancreaticoduodenectomy in order to resolve recurrent flairs of pancreatitis and avoid complications such as duodenal stricturing and necrosis of the pancreatic head. The largest series of patients with groove pancreatitis and cystic degeneration of the duodenal wall was published by Rebours *et al*[25] and included 105 patients. In this series, 18% resolved with observation, 43% resolved with medical therapy, of which half of these required nutritional support and 39% required surgical intervention. The majority of patients underwent a pancreaticoduodenectomy (N=`17) with the remainder undergoing endoscopic cyst fenestration, biliary bypass or gastric bypass for symptom management[25].

Gastrointestinal bleeding

Gastrointestinal bleeding is a rare but potentially serious presentation of HP. Bleeding may manifest as chronic melena as in the two patients in our series (Case 2 and 5). However, there are also reports of massive gastrointestinal hemorrhage associated with large volume transfusion and hemodynamic instability[86,191]. Martinez *et al*[51] reported a rate of bleeding of 7% in gastric lesions which was supported by the experience of Pang *et al*[38] who also reported a bleeding rate of 7% in symptomatic patients. The largest series of HP published by Dolan *et al*[44] from the Mayo Clinic evaluated 212 cases of HP of which 40 were discovered due to clinical symptoms. Of these, 7 patients (17.5%), presented with anemia and or evidence of gastrointestinal bleeding. Overall, the rate of patients presenting with gastrointestinal bleeding in pooled analysis of the literature was 9%.

The etiology of bleeding in patients with heterotopic pancreas is believed to be related to ulceration of the gastric mucosa overlying the aberrant lesion. As described previously, chemical irritation and inflammation can lead to disruption of the mucosal barrier while pancreatic enzymes, such as elastase, may cause thinning and erosion into the walls of underlying vasculature. Ulceration as the source of gastrointestinal bleeding is supported by the series put forth by Pang and colleagues which reported ulcerated mucosa in pathologic specimens from patients with evidence of bleeding[38,86]. However, this does not account for all reported cases of bleeding related to HP as there are several cases of documented bleeding and anemia in which the mucosa overlying the resected lesion was found to be intact[246]. One proposed explanation for this is through the concept of hemorrhagic "suffusion". This idea, originally proposed by Madinaveita and Loma, and later described by Hudock and colleagues

speculates that chronic inflammation from heterotopic lesions leads to edema and congestion in the gastric submucosa[191,247]. Congestion of the fragile vasculature in the submucosa may lead to bleeding and diapedesis into the gastric lumen.

Definitive management of major bleeding caused by heterotopic pancreatic lesions is primarily through resection. There is no clear role for medical management in gastric bleeding related to HP. Even among those patients with bleeding related to gastric ulceration, traditional medical management for gastric ulceration is of questionable utility as the presumed etiology of mucosal ulceration is not related to acid secretion. However, there may be an argument that medical therapy may reduce the potential of gastric secretions to propagate ulceration in the setting of an already disrupted mucosal barrier from HP. In the setting of acute gastrointestinal bleeding, endoscopic therapies can be utilized to control hemorrhage but ultimately, resection of the offending lesion should be considered. There have been reports of endoscopic submucosal dissection and resection of HP in patients with melena and chronic anemia[14,18]. However, surgical resection remains the preferred management of a bleeding mass in most cases. This may be achieved with localized partial gastrectomy or duodenectomy in the setting of small lesions and more extensive resection and reconstructions can often be avoided.

Gastric outlet obstruction

Gastric outlet obstruction is the source of symptomatic presentation in 9% of patients based on our review. The most common location for lesions arising in the stomach is the distal antrum, accounting for 85-96% of cases[94]. Given the proximity to the pylorus, growth of these lesions may lead to obstruction of the pyloric channel. While complete gastric outlet obstruction is possible, the more common scenario is partial or intermittent obstruction from a ball-valve occlusion or protrusion of the mass into the pylorus[51]. Symptoms associated with this process include abdominal pain, nausea, intermittent vomiting, bloating and anorexia[81,162]. Gastric outlet obstruction is a common presentation in infants and pediatric patients where smaller lesions can easily occlude the pyloric channel[32,247]. Nevertheless, obstruction is also seen in adults where ectopic lesions grow to a size that can lead to mechanical obstruction as seen in Case 4[41]. Lesions that are small and otherwise asymptomatic for decades, may also become acutely symptomatic in setting of inflammation and edema[60,92]. Likewise, the development of cysts and fluid collections within the wall of the stomach may grow to a size that can impede gastric emptying[163]. Some have also proposed that HP lesions may cause functional obstruction due to pyloric spasm[28].

Definitive management involves gastric decompression with a nasogastric tube and surgical correction of the obstruction. Surgical resection in these scenarios will typically require a more extensive resection than local excision or wedge resection as lesions causing obstruction are typically large (> 2 cm) and located at or near the pylorus or duodenum. Distal gastrectomy with a Billroth I, Billroth II or Roux-en-Y reconstruction are the most common operations performed for gastric lesions causing obstruction while partial duodenectomy or pancreaticoduodenectomy may be required in the obstructing lesion in the duodenum. If the lesion is small with a large cystic component causing obstruction and the pathology of the lesion is definitively known prior to surgery, a less extensive resection can be accomplished with preservation of the pylorus[95]. In the case series published by Ayantunde *et al*[28], two out of three cases of gastric outlet obstruction underwent distal gastrectomy while one underwent an anterior gastrotomy and local resection of the submucosal lesion. The majority of studies reviewed in the literature however, reported more extensive surgical resection and reconstruction procedures[14,58,64,244].

Evaluation and treatment

Regardless of the presenting symptoms, accurate diagnosis of HP can alter management and affect surgical decision making. Appropriate imaging and diagnostic studies must be ordered and evaluated carefully if suspicion for HP is high. Lesions of sufficient size can be identified with computed tomography, MRI, and fluoroscopy. When found within the stomach, HP tissue is typically seen along the greater curvature within 6 cm of the pylorus[238]. On CT, uncomplicated HP tissue will present as a soft tissue mass within the wall of the stomach, exhibiting similar enhancement and attenuation characteristics to that of normal pancreatic tissue[17] (Figure 3). However, the attenuation can be variable depending upon the dominant cellular type in the HP tissue, as there are pathologically different structures of heterotopic tissue described and characterized Heinrich's classification system[95,248]. Due to the variable enhancement of the HP tissue, it can sometimes be difficult to differentiate it from a gastrointestinal stromal tumor (GIST) or other common submucosal lesions[163]. In the setting of elevated pancreatic enzymes, sequelae of acute inflammation can be identified surrounding the ectopic tissue (Figure 4). On MRI the imaging of HP tissue will follow the signal intensity and enhancement characteristics of the native pancreas on all sequences. The HP tissue will demonstrate high signal intensity similar to that of the native pancreas on non-contrast T1 weighted imaging and demonstrate avid enhancement on post contrast images[234] (Figure 5). Barium fluoroscopy may also demonstrate a characteristic rounded filling defect with central indentation[241] (Figure 6).

Further diagnostic workup may require biochemical evaluation of serum amylase, lipase or, in some cases, tumor markers and/or endoscopic investigation[249]. EGD will typically demonstrate the presence of a submucosal mass which may be associated with a central umbilication and or ulceration.

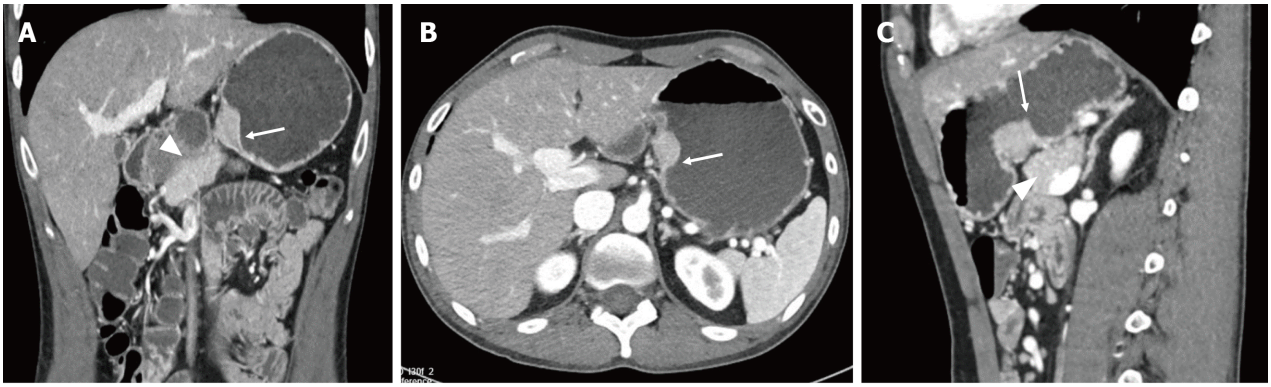

DOI: 10.3748/wjg.v28.i14.1455 **Copyright** © The Author(s) 2022.

Figure 3 Coronal (A), axial (B), and (C) sagittal images of the abdomen and pelvis following the administration of IV contrast demonstrates enhancing heterotopic pancreatic tissue within the wall of the stomach along the lesser curvature (white arrows). The heterotopic pancreatic tissue is intramural in location and demonstrates similar attenuation characteristics of the adjacent pancreatic tissue seen on the coronal and sagittal images (white arrowhead).

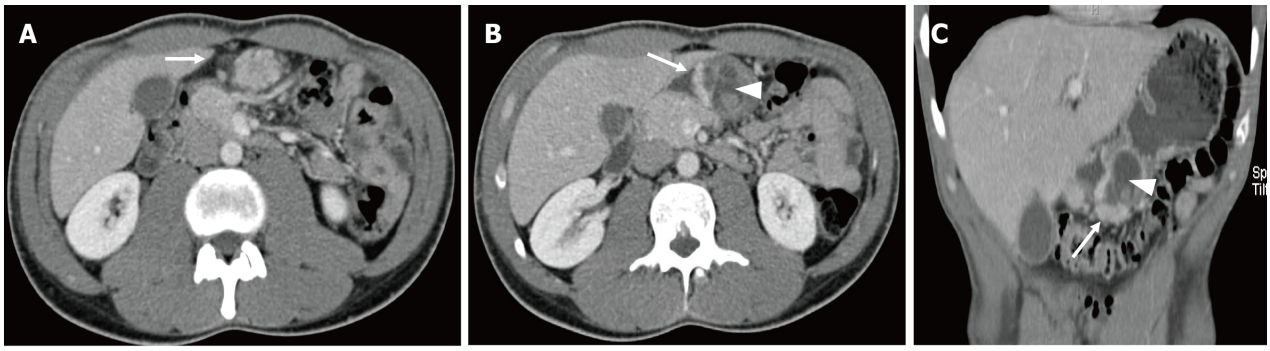

DOI: 10.3748/wjg.v28.i14.1455 **Copyright** © The Author(s) 2022.

Figure 4 Computed tomography images. A: Axial image demonstrating heterotopic pancreatic tissue within the stomach (white arrow). B: Axial image demonstrating heterotopic pancreas (white arrow) with associated psudocyst (white arrowhead). C: Coronal reformatted image demonstrating heterotopic pancreas tissue (white arrow) with associated pseudocyst (arrowhead) causing gastric outlet obstruction.

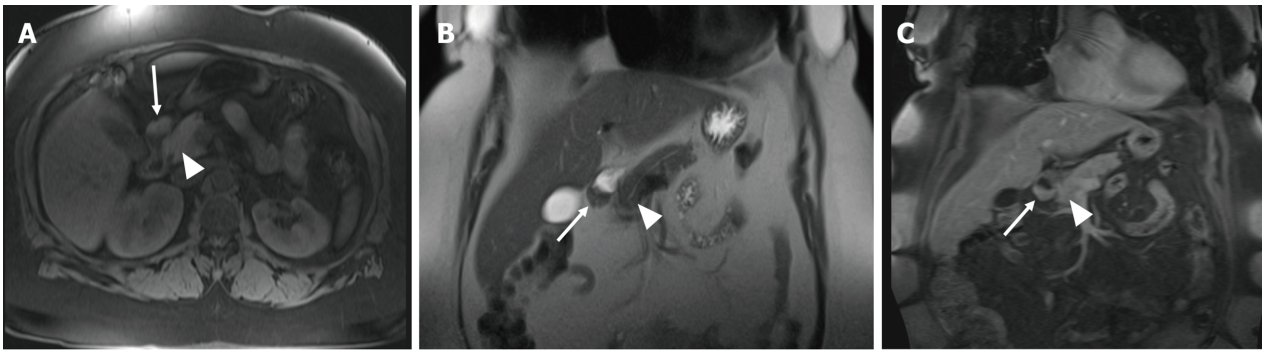

DOI: 10.3748/wjg.v28.i14.1455 **Copyright** © The Author(s) 2022.

Figure 5 Non-contrast axial T1 weighted (A), coronal T2 weighted (B), and coronal postcontrast T1 weighted (C) images show a lesion within the first portion of the duodenum (white arrow) demonstrating T1 pre-contrast hyperintense signal similar to that of the adjacent pancreas (white arrowhead). This tissue shows similar imaging characteristics of the adjacent pancreatic tissue on the T2 coronal and T1 coronal post contrast images.

At centers with expertise in endoscopic ultrasound, this modality may be helpful in determining the size, location and depth of penetration within the visceral wall. Final determination is achieved by tissue biopsy. This can often be difficult in the setting of ulceration, cystic degeneration and in lesions that are located within the outer wall of the viscera and EUS will may help facilitate accurate targeting and biopsy.

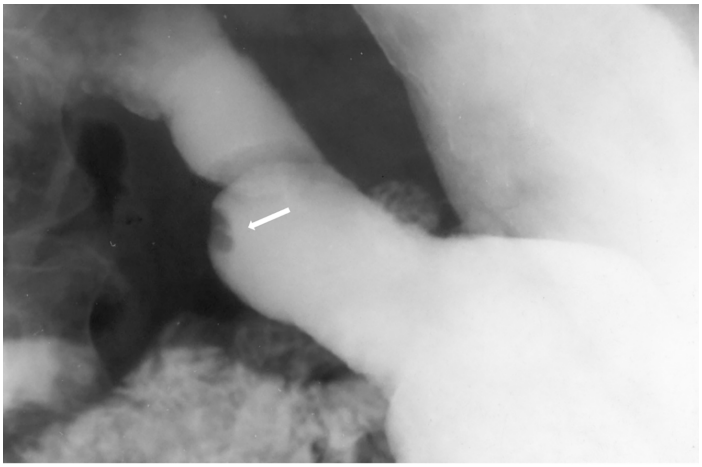

DOI: 10.3748/wjg.v28.i14.1455

Figure 6 Single spot image of the stomach on a barium fluoroscopic study demonstrates an intraluminal filling defect within the stomach with a central indentation (arrow) consistent with pancreatic heterotopia.

Accurate identification of HP in the diagnostic workup is an important factor in determining appropriate management. Unfortunately, many patients are misdiagnosed or assumed to have alternative pathology at the time of surgery. The range of clinical and radiographic findings makes proper pre-operative identification difficult, especially in the context of a relatively rare anatomic anomaly. Most lesions are mistakenly identified as malignant or premalignant pathology. This often affects the surgical decision making and may lead to a more extensive resection than would otherwise be required. This is evident in studies such as the one performed by Zhang *et al*[9] which reported that over 54% of patients with HP were misdiagnosed preoperatively. Many of the lesions were presumed to represent malignancy and underwent extensive resections. In our series, 18 patients underwent subtotal gastrectomy, 78 underwent distal gastrectomy and reconstruction and 168 underwent a pancreaticoduodenectomy. As the majority of HP lesions are benign and do not involve the entire visceral wall, many are amenable to local or endoscopic resection. Overall, we identified 158 cases of local endoscopic resection in our series. The largest series was published by Zhou *et al*[6] who reported endoscopic submucosal dissection in 78 symptomatic patients with good results. In this series, the majority of patients had lesions located in the submucosa or lamina propria and were less than 1cm in size. Likewise, the series published by Zhong *et al*[14] included 30 patients of which 90% were under 2cm in size. Thus, an endoscopic approach is a reasonable intervention in pathologically confirmed HP, < 2 cm in size in the submucosa.

Limitations

There are several limitations to this study. First, the relatively rare presentation of the disease process makes it difficult to identify a sufficiently large patient population to analyze and draw conclusions from. For this reason, we combined our single institution experience with that of a cohort derived from a literature review in order to evaluate a meaningful number of symptomatic cases. This type of analysis can be subject to inconsistency due to the differences in reporting, and classification of symptomatic cases in the literature. Likewise, a cohort derived from retrospective review of the literature may lead to selection bias as only those cases which are clearly symptomatic or associated with a higher level of severity are reported, potentially neglecting less symptomatic or milder cases. However, given the paucity of data and characterization of this abnormality, the reporting of the known literature and experience of HP in a conglomerate population may be important in the understanding and management of patients and to help guide future analysis and treatment decisions.

CONCLUSION

Heterotopic pancreatic tissue is a relatively rare anatomic anomaly that is found within the stomach and gastrointestinal tract. While numerous case reports of this pathology exist within the literature, there are few large volume studies that describe and characterize the clinical significance of this disease process. Review of a single institutional series and the available literature identified four categories of symptomatic features that occur within the upper gastrointestinal system. Many of these lesions are misdiagnosed and undergo invasive surgical resection. Better understanding of the clinical presentation and diagnosis of these lesions may lead to improved treatment and reduction of unnecessary surgical resection.

ARTICLE HIGHLIGHTS

Research background

Heterotopic pancreas (HP) is a rare embryologic anomaly that occurs when aberrant pancreatic tissue develops independently from the main body of the main body of the pancreas. This can occur throughout the body and develop in various tissues however, this most commonly occurs in the stomach and duodenum. While the majority of these lesions are asymptomatic, many have the potential to cause harmful clinical manifestations.

Research motivation

Symptomatic heterotopic pancreas is difficult to identify and often mimics common upper gastrointestinal pathology making diagnosis and treatment challenging. Symptomatic cases of HP often require surgical or endoscopic management however, the optimal treatment strategy is poorly understood at this time and patients often undergo radical resection.

Research objectives

The purpose of this study was to review the cases of symptomatic HP at a single, high volume academic institution and compare these with a cohort of patients derived from a systematic review of symptomatic cases in the English literature. This combined cohort was used to classify the common presentation and clinical symptoms for HP and identify the various treatment options.

Research methods

A retrospective review was conducted of pathologic specimens containing heterotopic pancreas at a single, high volume, academic medical center. Symptomatic cases were identified and analyzed for details related to presentation, symptoms and treatment. A systematic review was then conducted utilizing Embase and PubMed databases for publications in English which pertained to heterotopic pancreas. Publications which included symptomatic cases of HP were included for final literature analysis and results were tabulated into a final cohort for review.

Research results

Institutional review: Twenty-nine cases of HP were identified at a single institution, of which, six presented with symptoms (20%). Two patients (7%) presented with elevated lipase and evidence of pancreatitis within the heterotopic lesion, two patients presented with gastrointestinal bleeding or anemia, one patient (3.4%) presented with perforated gastric ulceration related to a heterotopic lesion, and one patient presented with gastric outlet obstruction from a HP lesion located at the pylorus.

Systematic review: Literature review resulted in identification of 1220 unique publications related to HP of which 232 publications met inclusion criteria and were reviewed. The final cohort of patients was 934 patients. Analysis of symptomatic cases revealed that the majority of cases could be classified into the following: (1) Dyspepsia, which included symptoms of epigastric pain, eructation, nausea or bloating with meals (n = 445, 48%); (2) Pancreatitis within the ectopic lesion (n = 260, 28%); (3) Gastrointestinal bleeding (n = 80, 9%); and (4) Gastric outlet obstruction (n = 80, 9%). 37 patients presented with jaundice and biliary obstruction due to periampullary lesions (4%), and 3 patients presented with perforated ulcers. The majority of patients underwent surgical or endoscopic resection (n = 832, 90%) and 85% of reported cases indicated symptom resolution. However, most patients underwent some form of formal anatomic resection (n = 490, 61%) most commonly related to improper diagnosis preoperatively and few benefited from local surgical or endoscopic resection.

Research conclusions

Heterotopic pancreas is a rare condition but has the ability to manifest severe clinical symptoms. These most commonly arise in the stomach and duodenum and can be classified within for main categories. Improved recognition and diagnosis of this disease process may help guide treatment recommendations and improve outcomes for patients.

Research perspectives

Prospective evaluation of medical and interventional therapies is needed to determine the most appropriate treatment for the different manifestations for heterotopic pancreas.

FOOTNOTES

Author contributions: LeCompte M designed the study and performed the research, reviewed the manuscripts and wrote the paper; Mason B and Yano M reviewed the radiographic images and contributed content to the manuscript regarding radiographic identification; Chatterjee D collected and reviewed pathologic specimens; Robbins K assisted

in reviewing medical records and collecting data; Hawkins G, Strasberg S, and Fields R participated in designing the study and contributed to the analysis and editing of the manuscript.

Institutional review board statement: This study was reviewed and approved by the institutional review board of Washington University of St. Louis. IRB number [#210811062].

Informed consent statement: Based on the study protocol and design, informed consent was determined to not be required and was therefore not obtained for this study. Patient information was collected and reviewed based on the parameters laid out by the IRB at our institution and was deidentified for analysis and reporting. The remainder of the study population was constructed based on a cohort of patients obtained through systematic review of the literature and was therefore based on patient information which had already been published and presented in the literature. For further questions or concerns please feel free to contact the corresponding author.

Conflict-of-interest statement: The authors of this study have no related conflicts of interest to disclose.

Data sharing statement: Technical data and information were provided by the corresponding author, Michael LeCompte who can be reached at michael_lecompte@med.unc.edu. Data from research subjects was anonymized and excluded any patient identifiers. Given the retrospective nature of this study, informed consent was deemed not necessary by the IRB. Additional data was collected and reviewed from datasets collected and published in the literature.

STROBE statement: The authors have read and revised the manuscript based on the STROBE guidelines.

Country/Territory of origin: United States

ORCID number: Michael T LeCompte 0000-0001-8853-2957; Brandon Mason 0000-0003-2102-1233; Keenan J Robbins 0000-0001-6950-175X; Motoyo Yano 0000-002-4837-1906; Deyali Chatterjee 0000-002-3322-1163; Ryan C Fields 0000-0001-6176-8943; Steven M Strasberg 0000-0003-0777-2698; William G Hawkins 0000-0001-7087-3585.

Corresponding Author's Membership in Professional Societies: American Hepatopancreatobiliary Association; Society of Ameican Gastrointestinal and Endoscopic Surgeons; and American College of Surgeons.

S-Editor: Gong ZM
L-Editor: A
P-Editor: Gong ZM

REFERENCES

1 **De Castro Barboso J**, Waugh JM. Heterotopic pancreatic tissue, clinically significant, in the gastric wall of a boy six years of age. *Proc Staff Meet Mayo Clin* 1947; **22**: 25-30 [PMID: 20290034]
2 **Eisenberger CF**, Gocht A, Knoefel WT, Busch CB, Peiper M, Kutup A, Yekebas EF, Hosch SB, Lambrecht W, Izbicki JR. Heterotopic pancreas--clinical presentation and pathology with review of the literature. *Hepatogastroenterology* 2004; **51**: 854-858 [PMID: 15143933]
3 **Guimarães M**, Rodrigues P, Gonçalves G, Nora M, Monteiro MP. Heterotopic pancreas in excluded stomach diagnosed after gastric bypass surgery. *BMC Surg* 2013; **13**: 56 [PMID: 24267291 DOI: 10.1186/1471-2482-13-56]
4 **Ormarsson OT**, Gudmundsdottir I, Mårvik R. Diagnosis and treatment of gastric heterotopic pancreas. *World J Surg* 2006; **30**: 1682-1689 [PMID: 16902740 DOI: 10.1007/s00268-005-0669-6]
5 **Noh JH**, Kim DH, Kim SW, Park YS, Na HK, Ahn JY, Jung KW, Lee JH, Choi KD, Song HJ, Lee GH, Jung HY. Endoscopic submucosal dissection as alternative to surgery for complicated gastric heterotopic pancreas. *World J Clin Cases* 2020; **8**: 4708-4718 [PMID: 33195638 DOI: 10.1016/j.gie.2019.03.1288]
6 **Zhou Y**, Zhou S, Shi Y, Zheng S, Liu B. Endoscopic submucosal dissection for gastric ectopic pancreas: a single-center experience. *World J Surg Oncol* 2019; **17**: 69 [PMID: 30992068 DOI: 10.1186/s12957-019-1612-x]
7 **Betzler A**, Mees ST, Pump J, Schölch S, Zimmermann C, Aust DE, Weitz J, Welsch T, Distler M. Clinical impact of duodenal pancreatic heterotopia - Is there a need for surgical treatment? *BMC Surg* 2017; **17**: 53 [PMID: 28482873 DOI: 10.1186/s12893-017-0250-x]
8 **Jun SY**, Son D, Kim MJ, Kim SJ, An S, Park YS, Park SR, Choi KD, Jung HY, Kim SC, Yook JH, Kim BS, Hong SM. Heterotopic Pancreas of the Gastrointestinal Tract and Associated Precursor and Cancerous Lesions: Systematic Pathologic Studies of 165 Cases. *Am J Surg Pathol* 2017; **41**: 833-848 [PMID: 28368927 DOI: 10.1097/PAS.0000000000000850]
9 **Zhang Y**, Sun X, Gold JS, Sun Q, Lv Y, Li Q, Huang Q. Heterotopic pancreas: a clinicopathological study of 184 cases

from a single high-volume medical center in China. *Hum Pathol* 2016; **55**: 135-142 [PMID: 27195908 DOI: 10.1016/j.humpath.2016.05.004]

10 **Liao X**, Zhan W, Cai LJ, Hu X, Gao Q, Jiao J, Liu J, Yang Q. The giant lower esophageal diverticulum within a heterotopic pancreas. *Int J Clin Exp Med* 2016; **9**: 5213-5217

11 **Chou JW**, Cheng KS, Ting CF, Feng CL, Lin YT, Huang WH. Endosonographic features of histologically proven gastric ectopic pancreas. *Gastroenterol Res Pract* 2014; **2014**: 160601 [PMID: 25371670 DOI: 10.1155/2014/160601]

12 **Endo S**, Saito R, Ochi D, Yamada T, Hirose M, Hiroshima Y, Yamamoto Y, Ueno T, Hasegawa N, Moriwaki T, Narasaka T, Kaneko T, Fukuda K, Suzuki H, Mizokami Y, Hyodo I. Effectiveness of an endoscopic biopsy procedure using EUS-FNA and EMR-C for diagnosing adenocarcinoma arising from ectopic pancreas: two case reports and a literature review. *Intern Med* 2014; **53**: 1055-1062 [PMID: 24827484 DOI: 10.2169/internalmedicine.53.1420]

13 **Liu X**, Wang G, Ge N, Wang S, Guo J, Liu W, Sun S. Endoscopic removal of symptomatic gastric heterotopic pancreas: a report of nine cases. *Surg Innov* 2013; **20**: NP40-NP46 [PMID: 24019308 DOI: 10.1177/1553350613499453]

14 **Zhong YS**, Shi Q, Yao LQ, Zhou PH, Xu MD, Wang P. Endoscopic mucosal resection/endoscopic submucosal dissection for gastric heterotopic pancreas. *Turk J Gastroenterol* 2013; **24**: 322-329 [PMID: 24254263 DOI: 10.4318/tjg.2013.0516]

15 **Shah H**, Singh M, Heller SJ, Tokar JL, Haluszka O. Heterotopic pancreas: Five-year experience at single academic institution. *Gastrointest Endosc* 2011; **73**: AB227 [DOI: 10.1016/j.gie.2011.03.359]

16 **Park SH**, Kim GH, Park DY, Shin NR, Cheong JH, Moon JY, Lee BE, Song GA, Seo HI, Jeon TY. Endosonographic findings of gastric ectopic pancreas: a single center experience. *J Gastroenterol Hepatol* 2011; **26**: 1441-1446 [PMID: 21557771 DOI: 10.1111/j.1440-1746.2011.06764.x]

17 **Wei R**, Wang QB, Chen QH, Liu JS, Zhang B. Upper gastrointestinal tract heterotopic pancreas: findings from CT and endoscopic imaging with histopathologic correlation. *Clin Imaging* 2011; **35**: 353-359 [PMID: 21872124 DOI: 10.1016/j.clinimag.2010.10.001]

18 **Ryu DY**, Kim GH, Park DY, Lee BE, Cheong JH, Kim DU, Woo HY, Heo J, Song GA. Endoscopic removal of gastric ectopic pancreas: an initial experience with endoscopic submucosal dissection. *World J Gastroenterol* 2010; **16**: 4589-4593 [PMID: 20857531 DOI: 10.3748/wjg.v16.i36.4589]

19 **Yuan Z**, Chen J, Zheng Q, Huang XY, Yang Z, Tang J. Heterotopic pancreas in the gastrointestinal tract. *World J Gastroenterol* 2009; **15**: 3701-3703 [PMID: 19653355 DOI: 10.3748/wjg.15.3701]

20 **Khashab MA**, Cummings OW, DeWitt JM. Ligation-assisted endoscopic mucosal resection of gastric heterotopic pancreas. *World J Gastroenterol* 2009; **15**: 2805-2808 [PMID: 19522034 DOI: 10.3748/wjg.15.2805]

21 **Casetti L**, Bassi C, Salvia R, Butturini G, Graziani R, Falconi M, Frulloni L, Crippa S, Zamboni G, Pederzoli P. "Paraduodenal" pancreatitis: results of surgery on 58 consecutives patients from a single institution. *World J Surg* 2009; **33**: 2664-2669 [PMID: 19809849 DOI: 10.1007/s00268-009-0238-5]

22 **Jovanovic I**, Alempijevic T, Lukic S, Knezevic S, Popovic D, Dugalic V, Micev M, Krstic M. Cystic dystrophy in heterotopic pancreas of the duodenal wall. *Dig Surg* 2008; **25**: 262-268 [PMID: 18663311 DOI: 10.1159/000148133]

23 **Chen HL**, Chang WH, Shih SC, Bair MJ, Lin SC. Changing pattern of ectopic pancreas: 22 years of experience in a medical center. *J Formos Med Assoc* 2008; **107**: 932-936 [PMID: 19129053 DOI: 10.1016/S0929-6646(09)60016-4]

24 **Chen SH**, Huang WH, Feng CL, Chou JW, Hsu CH, Peng CY, Yang MD. Clinical analysis of ectopic pancreas with endoscopic ultrasonography: an experience in a medical center. *J Gastrointest Surg* 2008; **12**: 877-881 [PMID: 18246404 DOI: 10.1007/s11605-008-0476-0]

25 **Rebours V**, Lévy P, Vullierme MP, Couvelard A, O'Toole D, Aubert A, Palazzo L, Sauvanet A, Hammel P, Maire F, Ponsot P, Ruszniewski P. Clinical and morphological features of duodenal cystic dystrophy in heterotopic pancreas. *Am J Gastroenterol* 2007; **102**: 871-879 [PMID: 17324133 DOI: 10.1111/j.1572-0241.2007.01091.x]

26 **Tison C**, Regenet N, Meurette G, Mirallié E, Cassagnau E, Frampas E, Le Borgne J. Cystic dystrophy of the duodenal wall developing in heterotopic pancreas: report of 9 cases. *Pancreas* 2007; **34**: 152-156 [PMID: 17198198 DOI: 10.1097/01.mpa.0000246669.61246.08]

27 **Pessaux P**, Lada P, Etienne S, Tuech JJ, Lermite E, Brehant O, Triau S, Arnaud JP. Duodenopancreatectomy for cystic dystrophy in heterotopic pancreas of the duodenal wall. *Gastroenterol Clin Biol* 2006; **30**: 24-28 [PMID: 16514378 DOI: 10.1016/s0399-8320(06)73073-1]

28 **Ayantunde AA**, Pinder E, Heath DI. Symptomatic pyloric pancreatic heterotopia: report of three cases and review of the literature. *Med Sci Monit* 2006; **12**: CS49-CS52 [PMID: 16733487]

29 **Chatelain D**, Vibert E, Yzet T, Geslin G, Bartoli E, Manaouil D, Delcenserie R, Brevet M, Dupas JL, Regimbeau JM. Groove pancreatitis and pancreatic heterotopia in the minor duodenal papilla. *Pancreas* 2005; **30**: e92-e95 [PMID: 15841034 DOI: 10.1097/01.mpa.0000161885.79373.1d]

30 **Zinkiewicz K**, Juśkiewicz W, Zgodziński W, Szumiło J, Cwik G, Furtak J, Maciejewski R, Wallner G. Ectopic pancreas: endoscopic, ultrasound and radiological features. *Folia Morphol (Warsz)* 2003; **62**: 205-209 [PMID: 14507048]

31 **Shi HQ**, Zhang QY, Teng HL, Chen JC. Heterotopic pancreas: report of 7 patients. *Hepatobiliary Pancreat Dis Int* 2002; **1**: 299-301 [PMID: 14612289]

32 **Huang YC**, Chen HM, Jan YY, Huang TL, Chen MF. Ectopic pancreas with gastric outlet obstruction: report of two cases and literature review. *Chang Gung Med J* 2002; **25**: 485-490 [PMID: 12350037]

33 **Otani Y**, Ohgami M, Igarashi N, Kimata M, Kubota T, Kumai K, Kitajima M, Mukai M. Laparoscopic wedge resection of gastric submucosal tumors. *Surg Laparosc Endosc Percutan Tech* 2000; **10**: 19-23 [PMID: 10872521]

34 **Hsia CY**, Wu CW, Lui WY. Heterotopic pancreas: a difficult diagnosis. *J Clin Gastroenterol* 1999; **28**: 144-147 [PMID: 10078823 DOI: 10.1097/00004836-199903000-00012]

35 **Fékété F**, Noun R, Sauvanet A, Fléjou JF, Bernades P, Belghiti J. Pseudotumor developing in heterotopic pancreas. *World J Surg* 1996; **20**: 295-298 [PMID: 8661834 DOI: 10.1007/s002689900047]

36 **Fléjou JF**, Potet F, Molas G, Bernades P, Amouyal P, Fékété F. Cystic dystrophy of the gastric and duodenal wall developing in heterotopic pancreas: an unrecognised entity. *Gut* 1993; **34**: 343-347 [PMID: 8097180 DOI: 10.1136/gut.34.3.343]

37 **Claudon M**, Verain AL, Bigard MA, Boissel P, Poisson P, Floquet J, Regent D. Cyst formation in gastric heterotopic

pancreas: report of two cases. *Radiology* 1988; **169**: 659-660 [PMID: 3055030 DOI: 10.1148/radiology.169.3.3055030]
38 **Pang LC**. Pancreatic heterotopia: a reappraisal and clinicopathologic analysis of 32 cases. *South Med J* 1988; **81**: 1264-1275 [PMID: 3051429]
39 **Lai EC**, Tompkins RK. Heterotopic pancreas. Review of a 26 year experience. *Am J Surg* 1986; **151**: 697-700 [PMID: 3717502 DOI: 10.1016/0002-9610(86)90045-0]
40 **Mollitt DL**, Golladay ES. Symptomatic gastroduodenal pancreatic rest in children. *J Pediatr Surg* 1984; **19**: 449-450 [PMID: 6481592 DOI: 10.1016/s0022-3468(84)80273-0]
41 **Armstrong CP**, King PM, Dixon JM, Macleod IB. The clinical significance of heterotopic pancreas in the gastrointestinal tract. *Br J Surg* 1981; **68**: 384-387 [PMID: 7237066 DOI: 10.1002/bjs.1800680606]
42 **Thoeni RF**, Gedgaudas RK. Ectopic pancreas: usual and unusual features. *Gastrointest Radiol* 1980; **5**: 37-42 [PMID: 6965644 DOI: 10.1007/BF01888597]
43 **Yamagiwa H**, Ishihara A, Sekoguchi T, Matsuzaki O. Heterotopic pancreas in surgically resected stomach. *Gastroenterol Jpn* 1977; **12**: 380-386 [PMID: 598670 DOI: 10.1007/BF02774535]
44 **Dolan RV**, ReMine WH, Dockerty MB. The fate of heterotopic pancreatic tissue. A study of 212 cases. *Arch Surg* 1974; **109**: 762-765 [PMID: 4420439 DOI: 10.1001/archsurg.1974.01360060032010]
45 **Eklöf O**, Lassrich A, Stanley P, Chrispin AR. Ectopic pancreas. *Pediatr Radiol* 1973; **1**: 24-27 [PMID: 4768239 DOI: 10.1007/BF00972820]
46 **Nebel OT**, Farrell RL, Kirchner JP, Macionus RF. Aberrant pancreas--an endoscopic diagnosis. *Am J Gastroenterol* 1973; **60**: 295-300 [PMID: 4745169]
47 **McGarity WC**, Perry CW 3rd. Complications of gastric heterotopic pancreas: two case reports. *Am Surg* 1971; **37**: 77-79 [PMID: 5099967]
48 **Abrahams JI**. Heterotopic pancreas simulating peptic ulceration. *Arch Surg* 1966; **93**: 589-592 [PMID: 5296930 DOI: 10.1001/archsurg.1966.01330040053009]
49 **Tonkin RD**, Field TE, Wykes PR. Pancreatic heterotopia as a cause of dyspepsia. *Gut* 1962; **3**: 135-139 [PMID: 13921861 DOI: 10.1136/gut.3.2.135]
50 **Dirks KR**, Field TE. Heterotopic pancreas causing symptoms. *J R Army Med Corps* 1961; **107**: 173-175 [PMID: 13723056]
51 **Martinez NS**, Morlock CG, Dockerty MB, Waugh JM, Weber HM. Heterotopic pancreatic tissue involving the stomach. *Ann Surg* 1958; **147**: 1-12 [PMID: 13498612 DOI: 10.1097/00000658-195801000-00001]
52 **Waugh TR**, Harding EW. Heterotopic pancreatic tissue in the region of the pyloric orifice; a radiological and pathological analysis of five cases of clinically suspected peptic ulcer in which only pancreatic rests were found. *Gastroenterology* 1946; **6**: 417-435 [PMID: 20985714]
53 **Barbu ST**, Valeanu D, Muresan A, Munteanu D, Casoinic F. Cystic Dystrophy of the Duodenal Wall in Heterotopic Pancreas with Groove Pancreatitis: A Diagnostic and Therapeutic Challenge. *Chirurgia (Bucur)* 2018; **113**: 418-423 [PMID: 29981674 DOI: 10.21614/chirurgia.113.3.418]
54 **Jin HB**, Lu L, Yang JF, Lou QF, Yang J, Shen HZ, Tang XW, Zhang XF. Interventional endoscopic ultrasound for a symptomatic pseudocyst secondary to gastric heterotopic pancreas. *World J Gastroenterol* 2017; **23**: 6365-6370 [PMID: 28974904 DOI: 10.3748/wjg.v23.i34.6365]
55 **Desai GS**, Phadke A, Kulkarni D. Cystic Dystrophy of the Duodenum Due to Heterotopic Pancreas - A Case Report and Review of Literature. *J Clin Diagn Res* 2016; **10**: PD11-PD13 [PMID: 27790515 DOI: 10.7860/JCDR/2016/20798.8498]
56 **Subasinghe D**, Sivaganesh S, Perera N, Samarasekera DN. Gastric fundal heterotopic pancreas mimicking a gastrointestinal stromal tumour (GIST): a case report and a brief review. *BMC Res Notes* 2016; **9**: 185 [PMID: 27005685 DOI: 10.1186/s13104-016-1995-5]
57 **Baisakh MR**, Mohapatra N, Baisakh P, Sahoo S, Kar M. Heterotopic pancreas in the stomach masquerading neoplasm. *J Clin Diagn Res* 2014; **8**: FL01-FL02 [PMID: 25653961 DOI: 10.7860/JCDR/2014/9142.5243]
58 **Rodriguez AA**, Berquist W, Bingham D. Gastric outlet obstruction caused by heterotopic pancreas in an adolescent. *Dig Dis Sci* 2015; **60**: 835-837 [PMID: 25107445 DOI: 10.1007/s10620-014-3314-0]
59 **Eskandari A**, Choi E. Gastric heterotopic pancreas complicated by pancreatitis and pseudocyst formation: A rare complication of an uncommon lesion. *Am J Gastroenterol* 2014; **109**: S454 [DOI: 10.1038/ajg.2014.279]
60 **Bryan DS**, Waxman I, Matthews JB. Gastric obstruction due to intramural pseudocyst associated with heterotopic pancreas. *J Gastrointest Surg* 2014; **18**: 1225-1226 [PMID: 24668368 DOI: 10.1007/s11605-014-2511-7]
61 **Şişman G**, Erzin Y, Tuncer M, Şentürk H. Endoscopic treatment of heterotopic pancreas localized in the duodenum. *Turk J Gastroenterol* 2014; **25**: 216-217 [PMID: 25003686 DOI: 10.5152/tjg.2014.3415]
62 **Aly AM**, Saied T. Cystic dystrophy of the duodenal wall in heterotopic pancreas: A case report. *Egypt J Radiol Nucl Med* 2014; **45**: 295-298 [DOI: 10.1016/j.ejrnm.2014.01.009]
63 **Décarie PO**, Paye F, Arrivé L. Cystic dystrophy of the gastroduodenal wall in heterotopic pancreas. *Clin Res Hepatol Gastroenterol* 2013; **37**: 551-552 [PMID: 23664762 DOI: 10.1016/j.clinre.2013.03.009]
64 **Hasan MK**, Hawes R, Varadarajulu S. Gastric heterotopic pancreas abscess leading to gastric outlet obstruction. *Gastrointest Endosc* 2013; **78**: 550-551 [PMID: 23948200 DOI: 10.1016/j.gie.2013.03.1327]
65 **Carbonero-Celis MJ**, Romero-Moriña H, Northrop-Sharp B, Umbría-Jiménez S, Argüelles-Martín F, Asensio-García J. Upper digestive tract hemorrhage in a child with heterotopic pancreas in a gastric diverticulum. *Rev Esp Enferm Dig* 2013; **105**: 54-55 [PMID: 23548014 DOI: 10.4321/S1130-01082013000100012]
66 **Deprez FC**, Pauls C, Coulier B. Heterotopic pancreas revealed by post-traumatic pancreatitis. *JBR-BTR* 2012; **95**: 83-86 [PMID: 22764662 DOI: 10.5334/jbr-btr.100]
67 **Trifan A**, Târcoveanu E, Danciu M, Huţanaşu C, Cojocariu C, Stanciu C. Gastric heterotopic pancreas: an unusual case and review of the literature. *J Gastrointestin Liver Dis* 2012; **21**: 209-212 [PMID: 22720312]
68 **Kinoshita H**, Yamaguchi S, Shimizu A, Sakata Y, Arii K, Mori K, Nasu T. Adenocarcinoma arising from heterotopic pancreas in the duodenum. *Int Surg* 2012; **97**: 351-355 [PMID: 23294078 DOI: 10.9738/cc148.1]

69 **Lhewa T**, Zhang Z, Rozelle C, Terry A. Gastric antral diverticulum with heterotopic pancreas in a teenage patient. *J Pediatr Gastroenterol Nutr* 2011; **53**: 471 [PMID: 22020538 DOI: 10.1097/MPG.0b013e31821b0cd3]

70 **Karaca G**, Taş A, Pekceci R, Özer H, Köklü S. Unusual Cause of Severe Nausea and Vomiting in an Elderly Man: Heterotopic Pancreas. International Journal of Gerontology 2011; 5: 133-134 [DOI: 10.1016/j.ijge.2011.04.007]

71 **Reggoug S**, Errabih I, Ouazzani L, Benzzoubeir N, Krami H, Raiss M, Hrora A, Ahallat M, Ouazzani H. Heterotopic pancreas: an unusual cause of epigastric pain. *Gastroenterol Clin Biol* 2010; **34**: 726-727 [PMID: 20970937 DOI: 10.1016/j.gcb.2010.09.005]

72 **Patel N**, Berzin T. Intraductal papillary mucinous neoplasm arising in a heterotopic pancreas: a case report. *Am J Gastroenterol* 2010; **105**: 2513-2514 [PMID: 21048696 DOI: 10.1038/ajg.2010.298]

73 **Gokhale UA**, Nanda A, Pillai R, Al-Layla D. Heterotopic pancreas in the stomach: a case report and a brief review of the literature. *JOP* 2010; **11**: 255-257 [PMID: 20442522]

74 **Payeras G**, Castellón C, De Jaime J, Barranco R, Calvache A, Castro P. Heterotopic pancreas: a difficult diagnosis. *Endoscopy* 2010; **42** Suppl 2: E121 [PMID: 20306404 DOI: 10.1055/s-0029-1243988]

75 **Inoue Y**, Hayashi M, Arisaka Y, Higuchi K, Egashira Y, Tanigawa N. Adenocarcinoma arising in a heterotopic pancreas (Heinrich type III): a case report. *J Med Case Rep* 2010; **4**: 39 [PMID: 20205891 DOI: 10.1186/1752-1947-4-39]

76 **Yoshida N**, Nakayama H, Hemmi A, Suzuki T, Takayama T. Duodenal stenosis caused by cystic dystrophy in heterotopic pancreas: report of a case. *Surg Today* 2009; **39**: 803-806 [PMID: 19779779 DOI: 10.1007/s00595-009-3939-3]

77 **Gurocak B**, Gokturk HS, Kayacetin S, Bakdik S. A rare case of heterotopic pancreas in the stomach which caused closed perforation. *Neth J Med* 2009; **67**: 285-287 [PMID: 19687523]

78 **Galloro G**, Napolitano V, Magno L, Diamantis G, Nardone G, Bruno M, Mollica C, Persico G. Diagnosis and therapeutic management of cystic dystrophy of the duodenal wall in heterotopic pancreas. A case report and revision of the literature. *JOP* 2008; **9**: 725-732 [PMID: 18981555]

79 **Rimal D**, Thapa SR, Munasinghe N, Chitre VV. Symptomatic gastric heterotopic pancreas: clinical presentation and review of the literature. *Int J Surg* 2008; **6**: e52-e54 [PMID: 17400528 DOI: 10.1016/j.ijsu.2007.02.002]

80 **Jiang LX**, Xu J, Wang XW, Zhou FR, Gao W, Yu GH, Lv ZC, Zheng HT. Gastric outlet obstruction caused by heterotopic pancreas: A case report and a quick review. *World J Gastroenterol* 2008; **14**: 6757-6759 [PMID: 19034986 DOI: 10.3748/wjg.14.6757]

81 **Margolin DJ**. Endoscopy-assisted laparoscopic resection of gastric heterotopic pancreas. *Am Surg* 2008; **74**: 829-831 [PMID: 18807671]

82 **Lopez-Pelaez MS**, Hoyos FB, Isidro MG, Unzurrunzaga EA, Lopez Ede V, Collazo YQ. Cystic dystrophy of heterotopic pancreas in stomach: radiologic and pathologic correlation. *Abdom Imaging* 2008; **33**: 391-394 [PMID: 17632748 DOI: 10.1007/s00261-007-9275-4]

83 **Stefanescu C**, Vullierme MP, Couvelard A, Bretagnol F, Amouyal P, Maire F, Rebours V, Hammel P, Ruszniewski P, Lévy P. Cystic dystrophy in gastric heterotopic pancreas complicated by intracystic hemorrhage and fistulisation in the stomach - a pediatric case. *Gastroenterol Clin Biol* 2008; **32**: 645-648 [PMID: 18547764 DOI: 10.1016/j.gcb.2008.02.032]

84 **Christodoulidis G**, Zacharoulis D, Barbanis S, Katsogridakis E, Hatzitheofilou K. Heterotopic pancreas in the stomach: a case report and literature review. *World J Gastroenterol* 2007; **13**: 6098-6100 [PMID: 18023108 DOI: 10.3748/wjg.13.6098]

85 **Wilde GE**, Gakhal M, Sartip KA, Corso MJ, Butt WG. Pancreatitis in initially occult gastric heterotopic pancreas. *Clin Imaging* 2007; **31**: 356-359 [PMID: 17825747 DOI: 10.1016/j.clinimag.2007.05.007]

86 **Wall I**, Shah T, Tangorra M, Li JJ, Tenner S. Giant heterotopic pancreas presenting with massive upper gastrointestinal bleeding. *Dig Dis Sci* 2007; **52**: 956-959 [PMID: 17342389 DOI: 10.1007/s10620-006-9481-x]

87 **Biswas A**, Husain EA, Feakins RM, Abraham AT. Heterotopic pancreas mimicking cholangiocarcinoma. Case report and literature review. *JOP* 2007; **8**: 28-34 [PMID: 17228130]

88 **Kobayashi S**, Okayama Y, Hayashi K, Sano H, Shiraki S, Goto K, Ohara H, Joh T. Heterotopic pancreas in the stomach which caused obstructive stenosis in the duodenum. *Intern Med* 2006; **45**: 1137-1141 [PMID: 17106157 DOI: 10.2169/internalmedicine.45.1814]

89 **Emerson L**, Layfield LJ, Rohr LR, Dayton MT. Adenocarcinoma arising in association with gastric heterotopic pancreas: A case report and review of the literature. *J Surg Oncol* 2004; **87**: 53-57 [PMID: 15221920 DOI: 10.1002/jso.20087]

90 **Tolentino LF**, Lee H, Maung T, Stabile BE, Li K, French SW. Islet cell tumor arising from a heterotopic pancreas in the duodenal wall with ulceration. *Exp Mol Pathol* 2004; **76**: 51-56 [PMID: 14738869 DOI: 10.1016/j.yexmp.2003.08.005]

91 **Ormarsson OT**, Haugen SE, Juul I. Gastric outlet obstruction caused by heterotopic pancreas. *Eur J Pediatr Surg* 2003; **13**: 410-413 [PMID: 14743331 DOI: 10.1055/s-2003-44733]

92 **Ikematsu Y**, Nishiwaki Y, Kida H, Iwaoka Y, Nagashima S, Ozawa T, Hasegawa S, Okawada T, Waki S. Gastric outlet obstruction caused by a heterotopic pancreas in a pregnant woman: report of a case. *Surg Today* 2003; **33**: 952-955 [PMID: 14669092 DOI: 10.1007/s00595-003-2614-3]

93 **Griffin AC**, Brost BC, Staren ED. Symptomatic heterotopic pancreas following seat belt injury. *Injury* 2003; **34**: 944-945 [PMID: 14636742 DOI: 10.1016/S0020-1383(02)00044-X]

94 **Haj M**, Shiller M, Loberant N, Cohen I, Kerner H. Obstructing gastric heterotopic pancreas: case report and literature review. *Clin Imaging* 2002; **26**: 267-269 [PMID: 12140158]

95 **Hazzan D**, Peer G, Shiloni E. Symptomatic heterotopic pancreas of stomach. *Isr Med Assoc J* 2002; **4**: 388-389 [PMID: 12040835]

96 **Halkic N**, Nordback P. Soft-tissue images. Malignant degeneration of heterotopic pancreas. *Can J Surg* 2001; **44**: 407 [PMID: 11764870]

97 **Shaib YH**, Rabaa E, Feddersen RM, Jamal MM, Qaseem T. Gastric outlet obstruction secondary to heterotopic pancreas in the antrum: case report and review. *Gastrointest Endosc* 2001; **54**: 527-530 [PMID: 11577327 DOI: 10.1067/mge.2001.116461]

98 **Chetty R**, Weinreb I. Gastric neuroendocrine carcinoma arising from heterotopic pancreatic tissue. *J Clin Pathol* 2004; **57**: 314-317 [PMID: 14990608 DOI: 10.1136/jcp.2003.013557]

99 **Bethel CA**, Luquette MH, Besner GE. Cystic degeneration of heterotopic pancreas. *Pediatr Surg Int* 1998; **13**: 428-430 [PMID: 9639636 DOI: 10.1007/s003830050358]

100 **Lucena JF**, Alvarez OA, Gross GW. Endoscopic resection of heterotopic pancreas of the minor duodenal papilla: case report and review of the literature. *Gastrointest Endosc* 1997; **46**: 69-72 [PMID: 9260710 DOI: 10.1016/s0016-5107(97)70214-1]

101 **Mönig SP**, Selzner M, Raab M, Eidt S. Heterotopic pancreas. A difficult diagnosis. *Dig Dis Sci* 1996; **41**: 1238-1240 [PMID: 8654158 DOI: 10.1007/bf02088243]

102 **Allison JW**, Johnson JF 3rd, Barr LL, Warner BW, Stevenson RJ. Induction of gastroduodenal prolapse by antral heterotopic pancreas. *Pediatr Radiol* 1995; **25**: 50-51 [PMID: 7761164 DOI: 10.1007/BF02020846]

103 **Ueno S**, Ishida H, Hayashi A, Kamagata S, Morikawa M. Heterotopic pancreas as a rare cause of gastrointestinal hemorrhage in the newborn: report of a case. *Surg Today* 1993; **23**: 269-272 [PMID: 8467181 DOI: 10.1007/BF00309240]

104 **Jeng KS**, Yang KC, Kuo SH. Malignant degeneration of heterotopic pancreas. *Gastrointest Endosc* 1991; **37**: 196-198 [PMID: 2032610 DOI: 10.1016/s0016-5107(91)70687-1]

105 **Farrar WB**, Scott M, O'Dwyer PJ. Heterotopic pancreas. *Ir J Med Sci* 1990; **159**: 19-20 [PMID: 2318605 DOI: 10.1007/BF02937209].]

106 **Burke GW**, Binder SC, Barron AM, Dratch PL, Umlas J. Heterotopic pancreas: gastric outlet obstruction secondary to pancreatitis and pancreatic pseudocyst. *Am J Gastroenterol* 1989; **84**: 52-55 [PMID: 2912031]

107 **Laughlin EH**, Keown ME, Jackson JE. Heterotopic pancreas obstructing the ampulla of Vater. *Arch Surg* 1983; **118**: 979-980 [PMID: 6870529 DOI: 10.1001/archsurg.1983.01390080081020]

108 **O'Reilly DJ**, Craig RM, Lorenzo G, Yokoo H. Heterotopic pancreas mimicking carcinoma of the head of the pancreas: a rare cause of obstructive jaundice. *J Clin Gastroenterol* 1983; **5**: 165-168 [PMID: 6853990 DOI: 10.1097/00004836-198304000-00014]

109 **Goldfarb WB**, Bennett D, Monafo W. Carcinoma in heterotopic gastric pancreas. *Ann Surg* 1963; **158**: 56-58 [PMID: 14042636 DOI: 10.1097/00000658-196307000-00011]

110 **Laird EG**. Heterotopic pancreas of the duodenum diagnosed pre-operatively. *Del Med J* 1963; **35**: 149-151 [PMID: 13928132]

111 **Alastal Y**, Khalil B, Singh S, Almadani SB. Ectopic Pancreas in the Gastric Antrum Wall Complicated by Ectopic Pancreatitis and Persistent Gastric Abscess. *ACG Case Rep J* 2018; **5**: e34 [PMID: 29774224 DOI: 10.14309/crj.2018.34]

112 **Štor Z**, Hanžel J. Gastric ectopic pancreas mimicking a gastrointestinal stromal tumour: A case report. *Int J Surg Case Rep* 2018; **53**: 348-350 [PMID: 30472628 DOI: 10.1016/j.ijscr.2018.11.014]

113 **Ning X**, Liang B, Liu Q, Chen X, Xu M. Gastric inflammatory myofibroblastic tumor identified as ectopic pancreas and treated by endoscopic submucosal dissection. *Gastrointest Endosc* 2017; **86**: 921-922 [PMID: 28587772 DOI: 0.1016/j.gie.2017.05.037].]

114 **Parra V**, Acero F, Alvarez E, Aponte DM, Sabbagh LC. A case of mucinous cystic neoplasm from a gastric ectopic pancreas. *Gastrointest Endosc* 2017; **85**: 1096-1097 [PMID: 27329092 DOI: 10.1016/j.gie.2016.06.010]

115 **Passos ID**, Chatzoulis G, Milias K, Tzoi E, Christoforakis C, Spyridopoulos P. Gastric duplication cyst (gdc) associated with ectopic pancreas: Case report and review of the literature. *Int J Surg Case Rep* 2017; **31**: 109-113 [PMID: 28131064 DOI: 10.1016/j.ijscr.2017.01.033]

116 **Fujii S**, Tanaka H, Ono K, Onizawa Y, Miyazono Y, Sakamoto N, Gotoh C, Urita Y, Shinkai T, Takayasu H, Sumazaki R, Masumoto K. Gastric outlet obstruction caused by an ectopic pancreas in a neonate: A case report. Journal of Pediatric Surgery Case Reports 2015; 3(12): 573-576 [DOI: 10.1016/j.epsc.2015.10.019]

117 **Gong EJ**, Kim DH, Cho CJ, Lee SS, Jung HY, Yoo SH. Endoscopic submucosal dissection of ectopic pancreas with pancreatitis and pseudocyst formation. *Gastrointest Endosc* 2015; **82**: 1126 [PMID: 26215649 DOI: 10.1016/j.gie.2015.06.029]

118 **Lee SL**, Ku YM, Lee HH, Cho YS. Gastric ectopic pancreas complicated by formation of a pseudocyst. *Clin Res Hepatol Gastroenterol* 2014; **38**: 389-391 [PMID: 24726272 DOI: 10.1016/j.clinre.2014.02.011]

119 **Kalaitzakis E**, Elebro J, Johansson J. Gastric ectopic pancreas: not always an innocent bystander. *JOP* 2013; **14**: 684-685 [PMID: 24216564 DOI: 10.6092/1590-8577/1991]

120 **Kishiki T**, Abe N, Sugiyama M, Tokutsu T, Matsuoka H, Yanagida O, Masaki T, Mori T. Inflammatory mass formation caused by gastric ectopic pancreas: report of a case. *Surg Today* 2013; **43**: 1448-1451 [PMID: 22948664 DOI: 10.1007/s00595-012-0317-3]

121 **O'Malley RB**, Maturen KE, Al-Hawary MM, Mathur AK. Case of the season: ectopic pancreas. *Semin Roentgenol* 2013; **48**: 188-191 [PMID: 23796369 DOI: 10.1053/j.ro.2013.03.011]

122 **Fukino N**, Oida T, Mimatsu K, Kida K, Kawasaki A, Kuboi Y, Kano H. Diffuse Peritonitis due to Perforated Gastric Ectopic Pancreas. *Case Rep Gastroenterol* 2012; **6**: 689-694 [PMID: 23185151 DOI: 10.1159/000345382]

123 **Lee YT**, Lin H, Guo JC, Yan SL, Hou HJ, Lai YS, Liu YH, Wu HS, Hwang MH. Laparoscopy-assisted billroth I gastrectomy for ectopic pancreas in the prepyloric region. *Case Rep Gastroenterol* 2012; **6**: 712-719 [PMID: 23185154 DOI: 10.1159/000345388]

124 **Uğur Kantar F**, Akarsu M, Atılla K, Sağol O, Soytürk M, Akpinar H. Ectopic pancreas presenting with intractable diarrhea: case report. *Turk J Gastroenterol* 2011; **22**: 426-429 [PMID: 21948576]

125 **Goto S**, Okazaki T, Koga H, Miyano G, Arakawa A, Yao T, Lane GJ, Yamataka A. Ectopic pancreas presenting as a submucosal gastric tumor: case report and literature review. *Pediatr Surg Int* 2011; **27**: 107-109 [PMID: 20862586 DOI: 10.1007/s00383-010-2717-z]

126 **Sharma DK**, Agarwal S, Saran RK, Agarwal AK. Pseudocyst of ectopic pancreas of the duodenal wall masquerading as malignant cystic tumor of pancreas. *Saudi J Gastroenterol* 2009; **15**: 271-273 [PMID: 19794276 DOI: 10.4103/1319-3767.56101]

127 **Surov A**, Hainz M, Hinz L, Holzhausen HJ, Finke R, Spielmann RP, Kunze C. Case report: ectopic pancreas with pseudocyst and pseudoaneurysm formation. *Clin Radiol* 2009; **64**: 734-737 [PMID: 19520218 DOI:

10.1016/j.crad.2009.01.013]
128 **Kim KJ**. Endoscopic resection of ectopic pancreas in the minor papilla. *Endoscopy* 2009; **41** Suppl 2: E12 [PMID: 19180425 DOI: 10.1055/s-0028-1103467]
129 **Hsu SD**, Wu HS, Kuo CL, Lee YT. Robotic-assisted laparoscopic resection of ectopic pancreas in the posterior wall of gastric high body: case report and review of the literature. *World J Gastroenterol* 2005; **11**: 7694-7696 [PMID: 16437703 DOI: 10.3748/wjg.v11.i48.7694]
130 **Mizuno Y**, Sumi Y, Nachi S, Ito Y, Marui T, Saji S, Matsutomo H. Acinar cell carcinoma arising from an ectopic pancreas. *Surg Today* 2007; **37**: 704-707 [PMID: 17643220 DOI: 10.1007/s00595-006-3384-5].]
131 **Ogata M**, Chihara N, Matsunobu T, Koizumi M, Yoshino M, Shioya T, Watanabe M, Tokunaga A, Tajiri T, Matsumoto K. Case of intra-abdominal endocrine tumor possibly arising from an ectopic pancreas. *J Nippon Med Sch* 2007; **74**: 168-172 [PMID: 17507794 DOI: 10.1272/jnms.74.168]
132 **Phillips J**, Katz A, Zopolsky P. Intraductal papillary mucinous neoplasm in an ectopic pancreas located in the gastric wall. *Gastrointest Endosc* 2006; **64**: 814-5; discussion 815 [PMID: 17055883 DOI: 10.1016/j.gie.2006.05.017]
133 **Chou SJ**, Chou YW, Jan HC, Chen VT, Chen TH. Ectopic pancreas in the ampulla of vater with obstructive jaundice. A case report and review of literature. *Dig Surg* 2006; **23**: 262-264 [PMID: 17035700 DOI: 10.1159/000096158]
134 **Ertem D**, Tutar E, Cam S, Ugras M, Pehlivanoglu E. Severe gastric outlet obstruction in a child with ectopic pancreas: is there a role for Helicobacter pylori? *J Pediatr Gastroenterol Nutr* 2006; **43**: 385-387 [PMID: 16954964 DOI: 10.1097/01.mpg.0000221895.51748.44]
135 **Hsu SD**, Chan DC, Hsieh HF, Chen TW, Yu JC, Chou SJ. Ectopic pancreas presenting as ampulla of Vater tumor. *Am J Surg* 2008; **195**: 498-500 [PMID: 18304504 DOI: 10.1016/j.amjsurg.2007.01.043]
136 **Tanemura A**, Yano T, Tamaki H, Sanda T, Ohashi N, Ishihara A, Fukutome K, Shiraki K. Ectopic pancreas in the minor duodenal papilla presenting as upper-GI bleeding. *Gastrointest Endosc* 2005; **62**: 324-326 [PMID: 16047011 DOI: 10.1016/S0016-5107(05)01571-3]
137 **De Vogelaere K**, Buydens P, Reynaert H, Vanhoey M, Delvaux G. Laparoscopic wedge resection for gastric ectopic pancreas. *Surg Laparosc Endosc Percutan Tech* 2005; **15**: 166-168 [PMID: 15956903 DOI: 10.1097/01.sle.0000166991.05099.b4]
138 **Mulholland KC**, Wallace WD, Epanomeritakis E, Hall SR. Pseudocyst formation in gastric ectopic pancreas. *JOP* 2004; **5**: 498-501 [PMID: 15536290]
139 **Sharma SB**, Gupta V. Ectopic pancreas as a cause of gastric outlet obstruction in an infant. *Indian J Gastroenterol* 2004; **23**: 219 [PMID: 15627663]
140 **Fragoso AC**, Correia-Pinto J, Carvalho JL, Dias JA, Troncoso MP, Estevão-Costa J. Ectopic pancreas and foveolar hyperplasia in a newborn: a unifying etiopathogenesis for gastric outlet obstruction. *J Pediatr Gastroenterol Nutr* 2004; **39**: 92-94 [PMID: 15187788 DOI: 10.1097/00005176-200407000-00018]
141 **Verma R**, Abraham DT, Joseph P, Nayak S, Agarwal S. Ectopic pancreas mimicking superior mesenteric artery syndrome. *Indian J Gastroenterol* 2003; **22**: 105-106 [PMID: 12839387]
142 **Jeong HY**, Yang HW, Seo SW, Seong JK, Na BK, Lee BS, Song GS, Park HS, Lee HY. Adenocarcinoma arising from an ectopic pancreas in the stomach. *Endoscopy* 2002; **34**: 1014-1017 [PMID: 12471549 DOI: 10.1055/s-2002-35836]
143 **Paolucci P**, Brasesco OE, Rosin D, Saber AA, Avital S, Berho M, Rosenthal RJ. Laparoscopic resection of ectopic pancreas in the gastric antrum: case report and literature review. *J Laparoendosc Adv Surg Tech A* 2002; **12**: 139-141 [PMID: 12019576 DOI: 10.1089/10926420252939691]
144 **Ozcan C**, Celik A, Güçlü C, Balik E. A rare cause of gastric outlet obstruction in the newborn: Pyloric ectopic pancreas. *J Pediatr Surg* 2002; **37**: 119-120 [PMID: 11782002 DOI: 10.1053/jpsu.2002.29443]
145 **Chen CH**, Yang CC, Yeh YH, Chou DA, Kuo CL. Ectopic pancreas located in the major duodenal papilla: case report and review. *Gastrointest Endosc* 2001; **53**: 121-123 [PMID: 11154509 DOI: 10.1067/mge.2001.111396]
146 **Hayes-Jordan A**, Idowu O, Cohen R. Ectopic pancreas as the cause of gastric outlet obstruction in a newborn. *Pediatr Radiol* 1998; **28**: 868-870 [PMID: 9799321 DOI: 10.1007/s002470050485]
147 **Kawashima H**, Iwanaka T, Matsumoto M, Takayasu H, Aihara T, Kishimoto H, Imaizumi S. Pyloric stenosis caused by noncystic duodenal duplication and ectopic pancreas in a neonate. *J Pediatr Gastroenterol Nutr* 1998; **27**: 228-229 [PMID: 9702660 DOI: 10.1097/00005176-199808000-00020]
148 **Blais C**, Massé S. Preoperative ultrasound diagnosis of a gastric duplication cyst with ectopic pancreas in a child. *J Pediatr Surg* 1995; **30**: 1384-1386 [PMID: 8523255 DOI: 10.1016/0022-3468(95)90516-2]
149 **Laurent T**, Fournier D, Doenz F, Karaaslan T, Wassmer FA. Complex lesion of the gastric wall: an unusual presentation of ectopic pancreas. *J Clin Ultrasound* 1995; **23**: 438-441 [PMID: 7560159 DOI: 10.1002/jcu.1870230709]
150 **Dawson KP**. Ectopic pancreas and cystic fibrosis. *Aust N Z J Med* 1988; **18**: 788-789 [PMID: 3242466 DOI: 10.1111/j.1445-5994.1988.tb00181.x]
151 **Chung JP**, Lee SI, Kim KW, Chi HS, Jeong HJ, Moon YM, Kang JK, Park IS. Duodenal ectopic pancreas complicated by chronic pancreatitis and pseudocyst formation--a case report. *J Korean Med Sci* 1994; **9**: 351-356 [PMID: 7848585 DOI: 10.3346/jkms.1994.9.4.351]
152 **Lucaya J**, Ochoa JB. Ectopic pancreas in the stomach. *J Pediatr Surg* 1976; **11**: 101-102 [PMID: 1245980 DOI: 10.1016/0022-3468(76)90181-0]
153 **Clark RE**, Teplick SK. Ectopic pancreas causing massive upper gastrointestinal hemorrhage. Report of a case diagnosed arteriographically. *Gastroenterology* 1975; **69**: 1331-1333 [PMID: 1081460]
154 **Weiss GN**, Marek FH. Surgical intervention for ectopic pancreas in the pylorus. *J La State Med Soc* 1953; **105**: 389-393 [PMID: 13096961]
155 **Munroe CA**, Ross E, Bolinger B. Don't Mess With the Pancreas (Wherever It May Be): Acute Pancreatic Rest"itis" Presenting as a Submucosal Mass With Gastric Outlet Obstruction. *Gastroenterology* 2018; **155**: e1-e2 [PMID: 29409828 DOI: 10.1053/j.gastro.2017.12.034]
156 **Polavarapu AD**, Philipose J, Daoud M, Zheng X, Opitz L, Andrawes S. Low grade pre-malignant lesion of pancreatic rest in stomach, surveillance a dilemma. *Am J Gastroenterol* 2017; **112**: S1425-S1426

157 **Masoodi I**, Al-Lehibi A, Almohaimeed K, Hussain S. Pancreatic Rest - An Unusual Cause of Dyspepsia: A Case Report with Literature Review. *Saudi J Med Med Sci* 2016; **4**: 225-228 [PMID: 30787736 DOI: 10.4103/1658-631X.188261]

158 **Peng JS**, Ritter K, Hamadeh F, Seifarth FG. Asymmetric Hypertrophic Pyloric Stenosis with Concurrent Pancreatic Rest Presenting as Gastric Outlet Obstruction. *J Pediatr* 2016; **174**: 273-273.e1 [PMID: 27179550 DOI: 10.1016/j.jpeds.2016.03.079]

159 Pancreatic/Biliary. *Am J Gastroenterol* 2014; **109** Suppl 2: S59-S101 [PMID: 25289908 DOI: 10.1038/ajg.2014.275]

160 **Faigel DO**, Gopal D, Weeks DA, Corless C. Cap-assisted endoscopic submucosal resection of a pancreatic rest. *Gastrointest Endosc* 2001; **54**: 782-784 [PMID: 11726863 DOI: 10.1067/mge.2001.116620]

161 **Wan Abdul Rahman WF**, Che Jalil NA, Samsudin H, Hi Merican SR, Lam AK. Duodenal Mass from Heterotopic Pancreas: A Unique Cause of Septic Shock. *Ann Acad Med Singap* 2016; **45**: 421-423 [PMID: 27748790]

162 **Matsumoto T**, Tanaka N, Nagai M, Koike D, Sakuraoka Y, Kubota K. A case of gastric heterotopic pancreatitis resected by laparoscopic surgery. *Int Surg* 2015; **100**: 678-682 [PMID: 25875550 DOI: 10.9738/intsurg-d-14-00182.1]

163 **Sarsenov D**, Tırnaksız MB, Doğrul AB, Tanas Ö, Gedikoglu G, Abbasoğlu O. Heterotopic pancreatic pseudocyst radiologically mimicking gastrointestinal stromal tumor. *Int Surg* 2015; **100**: 486-489 [PMID: 25785332 DOI: 10.9738/intsurg-d-13-00242.1]

164 **Filip R**, Walczak E, Huk J, Radzki RP, Bieńko M. Heterotopic pancreatic tissue in the gastric cardia: a case report and literature review. *World J Gastroenterol* 2014; **20**: 16779-16781 [PMID: 25469051 DOI: 10.3748/wjg.v20.i44.16779]

165 **Kalkan İH**, Öztaş E, Beyazit Y, Suvak B, Yildiz H, Ibiş M. An unusual case of double heterotopic pancreatic tissues in the same localization. *JOP* 2012; **13**: 243-244 [PMID: 22406612]

166 **Karpińska MS**, Nienartowicz M, Markowska-Woyciechowska A, Budrewicz-Czapska K. Heterotopic pancreas in the stomach (type II according to Heinrich) - literature review and case report. *Pol Przegl Chir* 2011; **83**: 171-174 [PMID: 22166320 DOI: 10.2478/v10035-011-0026-4]

167 **Almashat S**, Sepehr A. Obstructive and inflammatory gastric heterotopic pancreatic tissue. *Arch Iran Med* 2011; **14**: 357-358 [PMID: 21888463]

168 **Beleta E**, Peghin M, Guarner L. Cystic dystrophy of the pancreas in patient with only one previous cyst. *Rev Esp Enferm Dig* 2011; **103**: 95-97 [PMID: 21366373 DOI: 10.4321/s1130-01082011000200010]

169 **Sinha A**, Saluja SS, Gamanagatti S. Gastric duplication cyst with macroscopic serosal heterotopic pancreas. *JOP* 2010; **11**: 470-473 [PMID: 20818119]

170 **Agale SV**, Agale VG, Zode RR, Grover S, Joshi S. Heterotopic pancreas involving stomach and duodenum. *J Assoc Physicians India* 2009; **57**: 653-654 [PMID: 20214004]

171 **Zheng LD**, Tong QS, Tang ST, Du ZY, Ruan QL. Duodenal heterotopic pancreas in a child. *World J Pediatr* 2009; **5**: 146-148 [PMID: 19718539 DOI: 10.1007/s12519-009-0029-y]

172 **Jarry J Jr**, Rault A, Sa Cuhna A, Collet D, Masson B. Acute recurrent pancreatitis by heterotopic fundic mucosa at the ampulla of vater. *Pancreas* 2009; **38**: 351-353 [PMID: 19307936 DOI: 10.1097/MPA.0b013e3181888feb]

173 **Sukumar N**, Teoh CM. Heterotopic pancreas in the stomach. *Med J Malaysia* 2004; **59**: 541-543 [PMID: 15779591]

174 **Rubbia-Brandt L**, Huber O, Hadengue A, Frossard JL. An unusual case of gastric heterotopic pancreas. *JOP* 2004; **5**: 484-487 [PMID: 15536286]

175 **Jovanovic I**, Knezevic S, Micev M, Krstic M. EUS mini probes in diagnosis of cystic dystrophy of duodenal wall in heterotopic pancreas: a case report. *World J Gastroenterol* 2004; **10**: 2609-2612 [PMID: 15300920 DOI: 10.3748/wjg.v10.i17.2609]

176 **Obermaier R**, Walch A, Kurtz C, von Dobschuetz E, Adam U, Neeff H, Benz S, Hopt UT. Heterotopic pancreatitis with obstruction of the major duodenal papill--a rare trigger of obstructive orthotopic pancreatitis. *Pancreatology* 2004; **4**: 244-248 [PMID: 15148443 DOI: 10.1159/000078435]

177 **Hammock L**, Jorda M. Gastric endocrine pancreatic heterotopia. *Arch Pathol Lab Med* 2002; **126**: 464-467 [PMID: 11900574 DOI: 10.1043/0003-9985(2002)126<0464:geph>2.0.co;2]

178 **Chetty R**, Salahshor S, Bapat B, Berk T, Croitoru M, Gallinger S. Intraductal papillary mucinous neoplasm of the pancreas in a patient with attenuated familial adenomatous polyposis. *J Clin Pathol* 2005; **58**: 97-101 [PMID: 15623495 DOI: 10.1136/jcp.2004.020925]

179 **Indinnimeo M**, Cicchini C, Stazi A, Ghini C, Laghi A, Memeo L, Iannaccone R, Teneriello FL, Mingazzini PL. Duodenal pancreatic heterotopy diagnosed by magnetic resonance cholangiopancreatography: report of a case. *Surg Today* 2001; **31**: 928-931 [PMID: 11759893 DOI: 10.1007/s005950170038]

180 **Osanai M**, Miyokawa N, Tamaki T, Yonekawa M, Kawamura A, Sawada N. Adenocarcinoma arising in gastric heterotopic pancreas: clinicopathological and immunohistochemical study with genetic analysis of a case. *Pathol Int* 2001; **51**: 549-554 [PMID: 11472568 DOI: 10.1046/j.1440-1827.2001.01240.x]

181 **Hackett TR**, Memon MA, Fitzgibbons RJ Jr, Mixter CG. Laparoscopic resection of heterotopic gastric pancreatic tissue. *J Laparoendosc Adv Surg Tech A* 1997; **7**: 307-312 [PMID: 9453876 DOI: 10.1089/lap.1997.7.307]

182 **Steyaert H**, Voigt JJ, Brouet P, Vaysse P. Uncommon complication of gastric duplication in a three-year-old child. *Eur J Pediatr Surg* 1997; **7**: 243-244 [PMID: 9297524 DOI: 10.1055/s-2008-1071104]

183 **Nopajaroonsri C**. Mucus retention in heterotopic pancreas of the gastric antrum. A lesion mimicking mucinous carcinoma. *Am J Surg Pathol* 1994; **18**: 953-957 [PMID: 8067516 DOI: 10.1097/00000478-199409000-00011]

184 **Kesieme EB**, Dongo AE, Osime CO, Olomu SC, Awe OO, Eze GI, Eluehike SU. Gastric duplication: a rare cause of massive lower gastrointestinal haemorrhage, chest wall mass, and enterocutaneous fistula. *Case Rep Gastrointest Med* 2012; **2012**: 250890 [PMID: 22970394 DOI: 10.1155/2012/250890]

185 **Teixeira CR**, Haruma K, Shimamoto T, Tsuda T, Okamoto S, Sumii K, Kajiyama G. Heterotopic pancreas diagnosed by endoscopic ultrasonography and endoscopic injection of ethanol to make a histologic diagnosis. *J Clin Gastroenterol* 1992; **15**: 52-54 [PMID: 1500662 DOI: 10.1097/00004836-199207000-00012]

186 **Visentin M**, Vaysse P, Guitard J, Fedacou F, Juskiewenski S. Pyloric obstruction with complicated pancreatic heterotopia. *Eur J Pediatr Surg* 1991; **1**: 247-248 [PMID: 1931849 DOI: 10.1055/s-2008-1042500]

187 **Lim PH**, Chng HC, Ho JM. Transendoscopic removal of heterotopic pancreatic tissue in the stomach--a case report. *Singapore Med J* 1987; **28**: 366-368 [PMID: 3423809]

188 **Rohrmann CA Jr**, Delaney JH Jr, Protell RL. Heterotopic pancreas diagnosed by cannulation and duct study. *AJR Am J Roentgenol* 1977; **128**: 1044-1045 [PMID: 414539 DOI: 10.2214/ajr.128.6.1044]

189 **Barrocas A**, Fontenelle LJ, Williams MJ. Gastric heterotopic pancreas: a case report and review of literature. *Am Surg* 1973; **39**: 361-365 [PMID: 4735939]

190 **McCorriston JR**. Heterotopic pancreatic tissue in wall of duodenum associated with bleeding duodenal ulcer. *Can J Surg* 1958; **1**: 153-156 [PMID: 13489582]

191 **Hudock JJ**, Wanner H, Reilly CJ. Acute massive gastro-intestinal hemorrhage associated with pancreatic heterotopic tissue of the stomach. *Ann Surg* 1956; **143**: 121-125 [PMID: 13275909 DOI: 10.1097/00000658-195601000-00017]

192 **Foote EL**. Heterotopic pancreas in stomach; case report. *J Maine Med Assoc* 1955; **46**: 277-279 [PMID: 13263789]

193 **Wagner M**. Clinical significance of heterotopic pancreas in wall of stomach; report of a case and review of the literature. *AMA Arch Surg* 1952; **64**: 840-846 [PMID: 14923108 DOI: 10.1001/archsurg.1952.01260010860016]

194 **Stich MH**. Heterotopic pancreatic tissue in the duodenum. *N Y State J Med* 1952; **52**: 1057 [PMID: 14929367]

195 **Busard JM**, Walters W. HETEROTOPIC PANCREATIC TISSUE: Report of a Case Presenting Symptoms of Ulcer and Review of the Recent Literature. *Arch Surg* 1950; **60**: 674-682 [DOI: 10.1001/archsurg.1950.01250010695003]

196 **Kim SB**, Oh MJ, Lee SH. Gastric subepithelial lesion complicated with abscess: Case report and literature review. *World J Gastroenterol* 2015; **21**: 6398-6403 [PMID: 26034377 DOI: 10.3748/wjg.v21.i20.6398]

197 **Carvalho R**, Freire P, Portela F, Gomes D, Andrade P, Bento A, Batista H, Cipriano MA, Sofia C. Ectopic pancreas as a rare cause of obstructive jaundice. *Rev Esp Enferm Dig* 2014; **106**: 557-558 [PMID: 25544417]

198 **Lemaire J**, Delaunoit T, Molle G. Adenocarcinoma arising in gastric heterotopic pancreas. Case report and review of the literature. *Acta Chir Belg* 2014; **114**: 79-81 [PMID: 24720145]

199 **Verdin V**, Putzeys V, Delbecque K, Demarche M. Pancreatic ectopia: a case report. *Acta Chir Belg* 2013; **113**: 449-451 [PMID: 24494474]

200 **Ginori A**, Vassallo L, Butorano MA, Bettarini F, Di Mare G, Marrelli D. Pancreatic adenocarcinoma in duodenal ectopic pancreas: a case report and review of the literature. *Pathologica* 2013; **105**: 56-58 [PMID: 23946982]

201 **Rao RN**, Kamlesh Y, Pallav G, Singla N. Ectopic pancreas presenting as periampullary tumor with obstructive jaundice and pruritus is a rare diagnostic and therapeutic dilemma. A case report. *JOP* 2011; **12**: 607-609 [PMID: 22072252]

202 **Bini R**, Voghera P, Tapparo A, Nunziata R, Demarchi A, Capocefalo M, Leli R. Malignant transformation of ectopic pancreatic cells in the duodenal wall. *World J Gastroenterol* 2010; **16**: 1293-1295 [PMID: 20222176 DOI: 10.3748/wjg.v16.i10.1293]

203 **Yi SY**. Ectopic pancreas in duodenal bulb. *Clin Gastroenterol Hepatol* 2010; **8**: e30 [PMID: 19835995 DOI: 10.1016/j.cgh.2009.10.005]

204 **Filippou DK**, Vezakis A, Filippou G, Condilis N, Rizos S, Skandalakis P. A rare case of ectopic pancreas in the ampulla of Vater presented with obstructive jaundice. *Ann Ital Chir* 2006; **77**: 517-519 [PMID: 17343237]

205 **Wagle PK**, Shetty GS, Sampat M, Patel K. Ectopic pancreatic tissue mimicking ampullary tumor. *Indian J Gastroenterol* 2005; **24**: 265-266 [PMID: 16424630]

206 **Sloots CE**, de Brauw LM, Bot FJ, Greve JW. False-positive cytology in diagnostic laparoscopy due to ectopic pancreas. *Dig Surg* 1999; **16**: 434-436 [PMID: 10567808 DOI: 10.1159/000018762]

207 **Kaneda M**, Yano T, Yamamoto T, Suzuki T, Fujimori K, Itoh H, Mizumoto R. Ectopic pancreas in the stomach presenting as an inflammatory abdominal mass. *Am J Gastroenterol* 1989; **84**: 663-666 [PMID: 2729238]

208 **Jain AS**, Patel AM, Jain SR, Thakkar A. Accessory pancreatic lobe with gastric duplication cyst: diagnostic challenges of a rare congenital anomaly. *BMJ Case Rep* 2015; **2015** [PMID: 25766439 DOI: 10.1136/bcr-2014-207751]

209 **Kumagai H**, Yokoyama K, Shimamura W, Miura Y, Yamagata T. Endoscopic ultrasonography appearance of pancreatic rest. *Pediatr Int* 2014; **56**: 654 [PMID: 25252062 DOI: 10.1111/ped.12364]

210 **Deshpande VP**, Raghunath BV, Sarin YK, Sinha S. Heterotopic pancreas causing duodenal obstruction in a patient previously treated for choledochal cyst. *J Indian Assoc Pediatr Surg* 2012; **17**: 40-42 [PMID: 22279366 DOI: 10.4103/0971-9261.91088]

211 **Shah A**, Gordon AR, Ginsberg GG, Furth EE, Levine MS. Case report: ectopic pancreatic rest in the proximal stomach mimicking gastric neoplasms. *Clin Radiol* 2007; **62**: 600-602 [PMID: 17467399 DOI: 10.1016/j.crad.2007.01.001]

212 **Friedland S**, Yu A, Rouse RV, Wong D, Nino-Murcia M, Soetikno RM. Gastric pancreatic rest leading to pyogenic liver abscess. *Gastrointest Endosc* 2002; **56**: 438-440 [PMID: 12196792 DOI: 10.1016/s0016-5107(02)70058-8]

213 **Shalaby M**, Kochman ML, Lichtenstein GR. Heterotopic pancreas presenting as dysphagia. *Am J Gastroenterol* 2002; **97**: 1046-1049 [PMID: 12003387 DOI: 10.1016/S0002-9270(02)03983-7]

214 **De Roche K**, Gilbert M. Heterotopic pancreas presenting as hematemesis. *Am J Gastroenterol* 2016; **111**: S1123 [DOI: 10.1038/ajg.2016.375]

215 **Sharma A**, Mohapatra S, Lim KJ, Chaubal A. Broder A. Gastric Outlet Obstruction Caused by a Triple Lesion: Eosinophilic Gastroenteritis, Brunner's Gland Hyperplasia, and Pancreatic Heterotopia in Unison. *J Surg* 2017; **5**: 43-46 [DOI: 10.11648/j.js.20170503.12]

216 **Pakala T**, Wu G. An Unusual Location for Pancreatic Heterotopia: The Gastroesophageal Junction. *Am J Gastroenterol* 2016; **111**: S802 [DOI: 10.14309/00000434-201610001-01686]

217 **Bashir S**, Borum M. Co-existent heterotopic pancreas and brunner gland hyperplasia causing gastric outlet obstruction and mimicking a pancreatic head tumor. *Am J Gastroenterol* 2012; **107**: S380 [DOI: 10.1038/ajg.2012.273]

218 **Matsushita M**, Hajiro K, Takakuwa H. Acute pancreatitis occurring in gastric aberrant pancreas accompanied by paralytic ileus. *Am J Gastroenterol* 1997; **92**: 2121-2122 [PMID: 9362210]

219 **Tanemura H**, Uno S, Suzuki M, Miyauchi Y, Shimokawa K, Saji S, Ohashi H, Sakata K. Heterotopic gastric mucosa accompanied by aberrant pancreas in the duodenum. *Am J Gastroenterol* 1987; **82**: 685-688 [PMID: 3605031]

220 **Waku T**, Uetsuka H, Watanabe N, Mori T, Shiiki S, Nakai H, Orita Y, Harafuji I. A Case of Mucin-Producing Duodenal

Carcinoma Arising from the Aberrant Pancreas. *Jap J Gastroenterol Surg* 1996; **29**: 2289-2293 [DOI: 10.5833/jjgs.29.2289]

221 **Nam JY**, Lee SI, Chung JP, Choi SH, Lee DY, Choi JP, Lee JI, Lee SJ, Lee KS, Kang JK, Kim KW, Lim BJ, Park CI. [A case of duodenal adenocarcinoma arising from the heterotopic pancreas]. *Korean J Gastroenterol* 2003; **42**: 164-167 [PMID: 14532722]

222 **Matsuki M**, Gouda Y, Ando T, Matsuoka H, Morita T, Uchida N, Kuriyama S. Adenocarcinoma arising from aberrant pancreas in the stomach. *J Gastroenterol* 2005; **40**: 652-656 [PMID: 16007401 DOI: 10.1007/s00535-004-1601-9]

223 **Stock C**, Keutgen XM, Pisapia D, Crawford C, Zarnegar R. Heterotopic pancreatic neoplasm presenting as an obstructing mass at the fourth portion of the duodenum. *JOP* 2011; **12**: 241-243 [PMID: 21546699]

224 **Okamoto H**, Kawaoi A, Ogawara T, Fujii H. Invasive ductal carcinoma arising from an ectopic pancreas in the gastric wall: a long-term survival case. *Case Rep Oncol* 2012; **5**: 69-73 [PMID: 22611364 DOI: 10.1159/000335870]

225 **Mehra R**, Pujahari AK, Jaiswal SS. Duodenal heterotopic pancreatic tissue: a case report and literature review. *Gastroenterol Rep (Oxf)* 2015; **3**: 262-265 [PMID: 25064173 DOI: 10.1093/gastro/gou049]

226 **Priyathersini N**, Sundaram S, Senger JL, Rajendiran S, Balamurugan TD, Kanthan R. Malignant Transformation in Gastric Pancreatic Heterotopia A Case Report and Review of the Literature. *JOP* 2017; **18**: 73-77

227 **Fujii M**, Kawamoto H, Nagahara T, Tsutsumi K, Kato H, Shinoura S, Seno S, Okada H, Yamamoto K. A case of gastric aberrant pancreas diagnosed with EUS-guided FNA. *Gastrointest Endosc* 2011; **74**: 407-409 [PMID: 21561616 DOI: 10.1016/j.gie.2011.03.1124].]

228 **Tanaka T**, Omote R, Okazaki N, Yanai H, Yoshino T. Gastric neuroendocrine tumor arising from heterotopic pancreas. *Clin J Gastroenterol* 2018; **11**: 34-37 [PMID: 29218566 DOI: 10.1007/s12328-017-0795-3].]

229 **Li Y**, Zhou Y, Gu W, Nie Y. Obstructive Jaundice Caused by Heterotopic Pancreas. *Am J Gastroenterol* 2017; **112**: 1777 [PMID: 29215624 DOI: 10.1038/ajg.2017.356]

230 **Sahni S**, Mbachu JC, Stallwood C. Can we rest on just a rest? *Am J Gastroenterol* 2017; **112**: S1380

231 **Shiwani MH**. Laparoscopic excision of heterotopic pancreas of stomach. *J Coll Physicians Surg Pak* 2010; **20**: 620-621 [PMID: 20810058]

232 **Plier M**, Durez P, Komuta M, Raptis A. Severe panniculitis and polyarthritis caused by acinar cell carcinoma arising from an ectopic pancreas. *BMJ Case Rep* 2017; **2017**: bcr2017222241 [PMID: 29167188 DOI: 10.1136/bcr-2017-222241].]

233 **Boyaci C**, Pasaoglu E, Okcu O, Dursun N. Gastric heterotopic pancreas with low grade dysplasia of the ducts. *Pathol Int* 2016; **66**: 645-647 [PMID: 27699925 DOI: 10.1111/pin.12465].]

234 **Rezvani M**, Menias C, Sandrasegaran K, Olpin JD, Elsayes KM, Shaaban AM. Heterotopic Pancreas: Histopathologic Features, Imaging Findings, and Complications. *Radiographics* 2017; **37**: 484-499 [PMID: 28287935 DOI: 10.1148/rg.2017160091]

235 **Jennings RE**, Berry AA, Strutt JP, Gerrard DT, Hanley NA. Human pancreas development. *Development* 2015; **142**: 3126-3137 [PMID: 26395141 DOI: 10.1242/dev.120063]

236 **Papageorge M**, Waghray A, Chen L, Yoo J. Pedunculated small bowel lipoma with heterotopic pancreas causing intussusception. *Clin Case Rep* 2018; **6**: 1885-1886 [PMID: 30214784 DOI: 10.1002/ccr3.1710]

237 **Molinari M**, Ong A, Farolan MJ, Helton WS, Espat NJ. Pancreatic heterotopia and other uncommon causes of non-malignant biliary obstruction. *Surg Oncol* 2000; **9**: 135-142 [PMID: 11356342]

238 **Kim JY**, Lee JM, Kim KW, Park HS, Choi JY, Kim SH, Kim MA, Lee JY, Han JK, Choi BI. Ectopic pancreas: CT findings with emphasis on differentiation from small gastrointestinal stromal tumor and leiomyoma. *Radiology* 2009; **252**: 92-100 [PMID: 19561251 DOI: 10.1148/radiol.2521081441]

239 von Heinrich H. Ein Beitrag zur Histologie des sogen. akzessorischen Pankreas. Virchows Archiv für pathologische Anatomie und Physiologie und für klinische Medizin 1909; 198(3): 392-401 [DOI: 10.1007/BF02085327]

240 **Gaspar Fuentes A**, Campos Tarrech JM, Fernández Burgui JL, Castells Tejón E, Ruíz Rossello J, Gómez Pérez J, Armengol Miró J. [Pancreatic ectopias]. *Rev Esp Enferm Apar Dig* 1973; **39**: 255-268 [PMID: 4699117]

241 **Mandal S**, Mandal AK. Heterotopic pancreas presenting as a tumour nodule along with perforation and peritonitis is rare: report of two cases. *ANZ J Surg* 2008; **78**: 725 [PMID: 18796045 DOI: 10.1111/j.1445-2197.2008.04634.x]

242 **De Castro Barbosa JJ**, Dockerty MB, Waugh JM. Pancreatic heterotopia; review of the literature and report of 41 authenticated surgical cases, of which 25 were clinically significant. *Surg Gynecol Obstet* 1946; **82**: 527-542 [PMID: 21024692]

243 **Elwir S**, Glessing B, Amin K, Jensen E, Mallery S. Pancreatitis of ectopic pancreatic tissue: a rare cause of gastric outlet obstruction. *Gastroenterol Rep (Oxf)* 2017; **5**: 237-240 [PMID: 26224685 DOI: 10.1093/gastro/gov037]

244 **Jani B**, Rzouq F, Saligram S, Nawabi A, Nicola M, Dennis K, Ernst C, Abbaszadeh A, Bonino J, Olyaee M. Groove Pancreatitis: A Rare form of Chronic Pancreatitis. *N Am J Med Sci* 2015; **7**: 529-532 [PMID: 26713302 DOI: 10.4103/1947-2714.170624]

245 **Raman SP**, Salaria SN, Hruban RH, Fishman EK. Groove pancreatitis: spectrum of imaging findings and radiology-pathology correlation. *AJR Am J Roentgenol* 2013; **201**: W29-W39 [PMID: 23789694 DOI: 10.2214/ajr.12.9956]

246 **Razi MD**. Ectopic pancreatic tissue of esophagus with massive upper gastrointestinal bleeding. *Arch Surg* 1966; **92**: 101-104 [PMID: 5322190 DOI: 10.1001/archsurg.1966.01320190103024]

247 **Madinaveitia JM**, Madinaveitia M, Loma V. [Aberrant pancreas]. *Rev Esp Enferm Apar Dig Nutr* 1951; **10**: 31-42 [PMID: 14844971]

248 **Sathyanarayana SA**, Deutsch GB, Bajaj J, Friedman B, Bansal R, Molmenti E, Nicastro JM, Coppa GF. Ectopic pancreas: a diagnostic dilemma. *Int J Angiol* 2012; **21**: 177-180 [PMID: 23997566 DOI: 10.1055/s-0032-1325119]

249 **Chou JW**, Chang KP, Wu YH. A Rare Cause of Elevated Serum CA19-9. *Gastroenterology* 2021; **160**: 31-32 [PMID: 32828817 DOI: 10.1053/j.gastro.2020.08.031]

World Journal of Gastroenterology

Submit a Manuscript: https://www.f6publishing.com

World J Gastroenterol 2022 April 14; 28(14): 1479-1493

DOI: 10.3748/wjg.v28.i14.1479

ISSN 1007-9327 (print) ISSN 2219-2840 (online)

ORIGINAL ARTICLE

Retrospective Study

Radiomics signature: A potential biomarker for β-arrestin1 phosphorylation prediction in hepatocellular carcinoma

Feng Che, Qing Xu, Qian Li, Zi-Xing Huang, Cai-Wei Yang, Li Ye Wang, Yi Wei, Yu-Jun Shi, Bin Song

Specialty type: Gastroenterology and hepatology

Provenance and peer review: Invited article; Externally peer reviewed.

Peer-review model: Single blind

Peer-review report's scientific quality classification

Grade A (Excellent): A
Grade B (Very good): 0
Grade C (Good): C
Grade D (Fair): 0
Grade E (Poor): 0

P-Reviewer: Costa G, Italy; Gumbs A, France

Received: November 9, 2021
Peer-review started: November 9, 2021
First decision: January 9, 2022
Revised: January 22, 2022
Accepted: March 6, 2022
Article in press: March 6, 2022
Published online: April 14, 2022

Feng Che, Qian Li, Zi-Xing Huang, Cai-Wei Yang, Yi Wei, Bin Song, Department of Radiology, West China Hospital, Sichuan University, Chengdu 610041, Sichuan Province, China

Qing Xu, Yu-Jun Shi, Institute of Clinical Pathology, West China Hospital, Sichuan University, Chengdu 610041, Sichuan Province, China

Li Ye Wang, Department of Research and Development, Shanghai United Imaging Intelligence Co., Ltd, Shanghai 200232, China

Corresponding author: Bin Song, MD, Chief Doctor, Doctor, Professor, Department of Radiology, West China Hospital, Sichuan University, No 37, Guoxue Alley, Wuhou District, Chengdu 610041, Sichuan Province, China. songlab_radiology@163.com

Abstract

BACKGROUND

The phosphorylation status of β-arrestin1 influences its function as a signal strongly related to sorafenib resistance. This retrospective study aimed to develop and validate radiomics-based models for predicting β-arrestin1 phosphorylation in hepatocellular carcinoma (HCC) using whole-lesion radiomics and visual imaging features on preoperative contrast-enhanced computed tomography (CT) images.

AIM

To develop and validate radiomics-based models for predicting β-arrestin1 phosphorylation in HCC using radiomics with contrast-enhanced CT.

METHODS

Ninety-nine HCC patients (training cohort: n = 69; validation cohort: n = 30) receiving systemic sorafenib treatment after surgery were enrolled in this retrospective study. Three-dimensional whole-lesion regions of interest were manually delineated along the tumor margins on portal venous CT images. Radiomics features were generated and selected to build a radiomics score using logistic regression analysis. Imaging features were evaluated by two radiologists independently. All these features were combined to establish clinico-radiological (CR) and clinico-radiological-radiomics (CRR) models by using multivariable logistic regression analysis. The diagnostic performance and clinical usefulness of the models were measured by receiver operating characteristic and decision curves, and the area under the curve (AUC) was determined. Their association

with prognosis was evaluated using the Kaplan-Meier method.

RESULTS

Four radiomics features were selected to construct the radiomics score. In the multivariate analysis, alanine aminotransferase level, tumor size and tumor margin on portal venous phase images were found to be significant independent factors for predicting β-arrestin1 phosphorylation-positive HCC and were included in the CR model. The CRR model integrating the radiomics score with clinico-radiological risk factors showed better discriminative performance (AUC = 0.898, 95%CI, 0.820 to 0.977) than the CR model (AUC = 0.794, 95%CI, 0.686 to 0.901; P = 0.011), with increased clinical usefulness confirmed in both the training and validation cohorts using decision curve analysis. The risk of β-arrestin1 phosphorylation predicted by the CRR model was significantly associated with overall survival in the training and validation cohorts (log-rank test, $P < 0.05$).

CONCLUSION

The radiomics signature is a reliable tool for evaluating β-arrestin1 phosphorylation which has prognostic significance for HCC patients, providing the potential to better identify patients who would benefit from sorafenib treatment.

Key Words: Hepatocellular carcinoma; Sorafenib resistance; β-Arrestin1 phosphorylation; Radiomics; Computed tomography; Overall survival

Core Tip: The aim of this study was to develop and validate radiomics-based models for predicting β-arrestin1 phosphorylation in hepatocellular carcinoma (HCC). A total of 99 HCC patients (training cohort: n = 69; validation cohort: n = 30) were included, and the final clinico-radiological-radiomics model integrating the radiomics scores and clinico-radiological risk factors showed satisfactory discriminative performance (AUC = 0.898, 95%CI, 0.820 to 0.977). The preoperative prediction model can be used as a noninvasive and effective tool to help predict the outcome of HCC patients treated with sorafenib and identify patients who would benefit most from sorafenib treatment.

Citation: Che F, Xu Q, Li Q, Huang ZX, Yang CW, Wang LY, Wei Y, Shi YJ, Song B. Radiomics signature: A potential biomarker for β-arrestin1 phosphorylation prediction in hepatocellular carcinoma. *World J Gastroenterol* 2022; 28(14): 1479-1493

URL: https://www.wjgnet.com/1007-9327/full/v28/i14/1479.htm

DOI: https://dx.doi.org/10.3748/wjg.v28.i14.1479

INTRODUCTION

Hepatocellular carcinoma (HCC) was the sixth most common cancer and the third leading cause of cancer-related death worldwide in 2020[1]. Liver resection and transplantation are considered potentially curative methods for early-stage patients with well-preserved liver function. For advanced-stage HCC, systemic therapies such as multikinase inhibitors and immune checkpoint inhibitors, represented by sorafenib, have shown the potential to confer a survival advantage of 2-3 mo[2,3]. However, patients undergoing sorafenib treatment have a high resistance rate, which is still the greatest challenge and leads to a discouraging prognosis[3]. Hence, identifying patients who are more likely to benefit from sorafenib treatment and discovering related biomarkers associated with sorafenib treatment response are urgently needed.

β-Arrestins, including β-arrestin1 and β-arrestin2, are important regulators of seven-transmembrane domain G-protein-coupled receptors. They can block subsequent G protein activation and result in receptor desensitization by phosphorylation/dephosphorylation of β-arrestin1 at a carboxyl-terminal serine, Ser-412[4,5]. The development of sorafenib resistance includes primary and secondary resistance, and the phosphorylation of ERK has been widely accepted to play an important role in both[6-8]. Activation of AKT and epithelial-mesenchymal transition (EMT) also participates in acquired resistance and the signaling pathways mentioned above have strong relationships with β-arrestin1[9-11]. Wu *et al* revealed that β-arrestin1 enhances hepatocellular carcinogenesis by inflammation-mediated Akt signaling[12] and promotes HCC invasion and metastasis through p-ERK1/2 to mediate EMT[13]. The phosphorylation status of β-arrestin1 influences its function in activating downstream receptors such as

ERK1/2, forming a negative feedback loop[14]. All these signals are highly related to sorafenib resistance[9,15], which indicates that the expression of phosphorylated β-arrestin1 (p-β-arrestin1) may correlate with sorafenib resistance in HCC patients. Thus, the preoperative prediction of β-arrestin1 phosphorylation may help identify patients who could benefit from sorafenib treatment.

Radiomics is a newly emerging computational medical imaging method that allows for the quantitative analysis and translation of medical images[16,17]. Additionally, radiomics studies can provide insights into the depth and comprehensive characterization of tumor heterogeneity, with the underlying hypothesis that radiomics can better characterize tumor heterogeneity[18-20]. Preliminary studies have suggested that radiomics features can be useful for tumor lesion detection[18,21] and are potentially predictive of the microenvironment and molecular status of tumors[16,22,23]. Xu *et al*[24] extracted radiomics signatures from contrast-enhanced computed tomography (CECT) images to build a risk model that showed good performance in microvascular invasion stratification and could well predict the clinical outcomes of HCC patients. To the best of our knowledge, the value of radiomics based on CECT images in predicting β-arrestin1 phosphorylation in HCC has not yet been reported.

The purpose of this study was therefore to develop and validate a radiomics-based model combining visual imaging and clinical features for the preoperative noninvasive prediction of β-arrestin1 phosphorylation and to further investigate its association with prognostic outcomes in HCC patients.

MATERIALS AND METHODS

Patients

This retrospective study was approved by the Institutional Review Board of West China Hospital and the requirement for informed consent was waived. Patients who had histologically proven HCC and received systemic treatment with sorafenib after surgery between January 2013 and April 2017 were retrospectively reviewed and consecutively recorded. The inclusion criteria were as follows: (1) Age ≥18 years; (2) Pathologically confirmed HCC; (3) Interval between CECT imaging and surgery less than four weeks; (4) Treatment naive [*i.e.*, no hepatectomy, transcatheter arterial chemoembolization (TACE) or radiofrequency ablation (RFA) before CECT]; and (5) Administration of 400 mg sorafenib twice a day after surgery with up to two dose reductions allowed (from 400 mg once daily to 400 mg every 2 d) for drug-related adverse events. The exclusion criteria were as follows: (1) Incomplete or poor-quality CT images; (2) Interrupted sorafenib treatment for longer than 48 h between the initiation of sorafenib and the first follow-up time point; and (3) Death or loss to follow-up. Among the 146 eligible patients, 47 patients were excluded because CECT imaging was performed more than 4 wk before surgery (n = 13), the CT images were incomplete or of poor quality (n = 11), sorafenib treatment was interrupted for longer than 48 h between the initiation of sorafenib and the first follow-up time point (n = 8), or the patient was lost to follow-up (n = 15). Therefore, 99 patients were ultimately enrolled in this study. In addition, the investigated laboratory data within 7 days of the CT examination and clinical conditions were recorded, as shown in Figure 1.

In this study, consecutive patients who underwent surgery between January 2013 and March 2016 comprised the training cohort and were used to construct the nomograms, and patients who underwent surgery from April 2016 to April 2017 comprised the validation cohort.

Imaging techniques

CT imaging was performed by using multidetector CT scanners (Revolution, GE Healthcare, Milwaukee, United States; SOMATOM definition, Siemens Healthcare, Erlangen, Germany). Precontrast images were first obtained before contrast agent (iodine concentration, 300-370 mg/mL; volume, 1.5-2.0 mL/kg of body weight; contrast type, iopromide injection, Bayer Pharma AG) injection. Then, the arterial phase and portal venous phase were obtained with the following parameters: tube voltage, 100-120 kVp; tube current, 450 mA; slice thickness, 0.625 mm; pitch, 0.992:1; rotation speed: 0.5 s/rot; and ASIR-V: 30%. The arterial phase and portal venous phase were obtained at 25 s and 60 s after contrast injection.

Imaging evaluation

Three abdominal radiologists who were blinded to the histopathological results, clinical data, and survival outcomes reviewed all the CT images. The following imaging features were assessed by these readers: (1) Tumor margin, defined as a non-smooth margin with budding portion protruding into the liver parenchyma or infiltrative appearance at the tumor periphery, otherwise as smooth margin; (2) Tumor size, defined as the maximum diameter, measured on arterial phase transverse images or portal venous phase images; (3) Pseudocapsule, defined as a complete capsule with a uniform border around most or all of the tumor, unequivocally thicker or more conspicuous than the fibrotic tissue around background nodules, otherwise as incomplete integrity or not applicable; (4) Multifocality; (5) Arterial phase hyperenhancement; (6) Portal venous/delay phase hypoenhancement; (7) Radiologic evidence of necrosis; (8) Radiologic evidence of cirrhosis; and (9) Portal vein tumor thrombosis invasion. All examinations were performed using a workstation and recorded on a picture archiving and

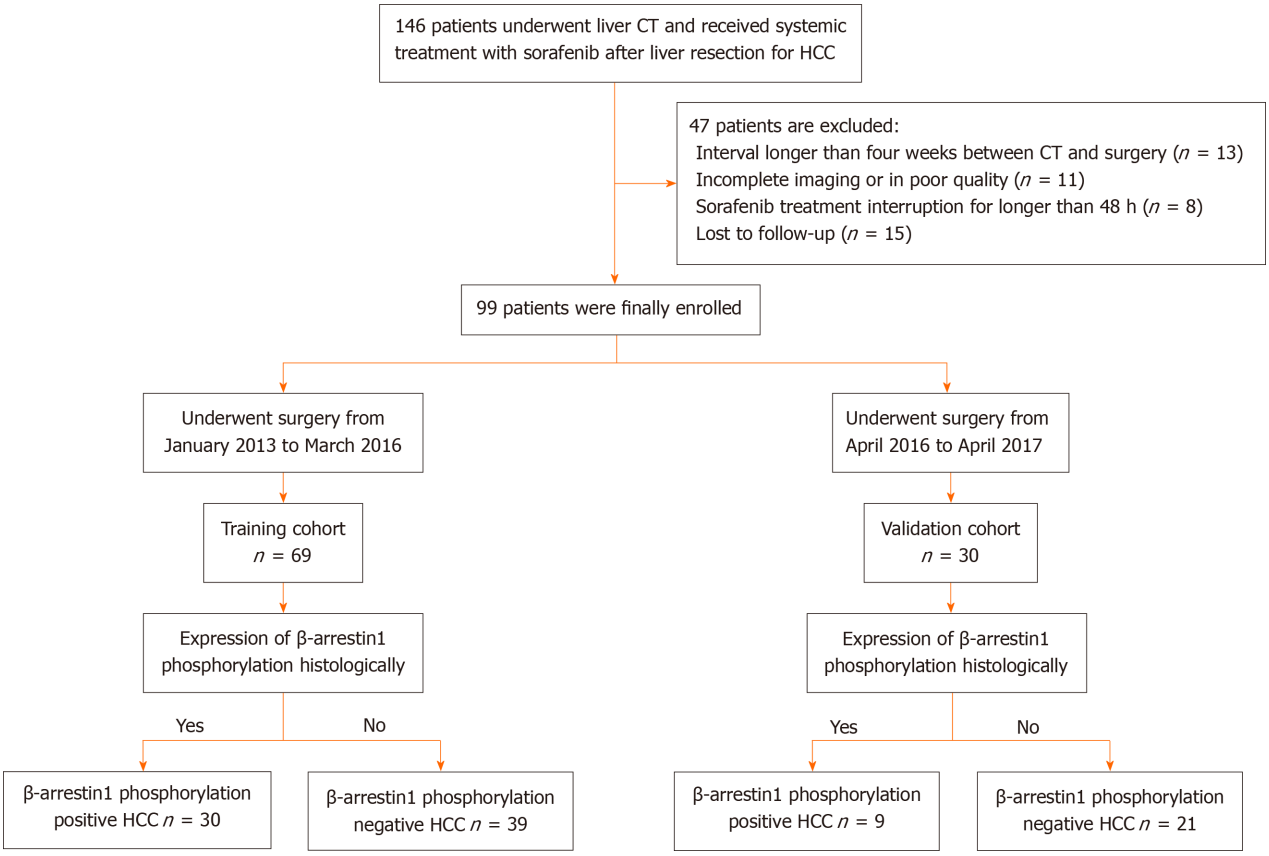

Figure 1 Patient recruitment process.

communication system.

Immunohistochemistry

Surgically resected specimens embedded in paraffin were cut into 4 μm-thick sections dewaxed, hydrated, and subjected to antigen retrieval. Subsequently, the tissue slides were incubated with primary antibodies using rabbit anti-human p-β-arrestin1 polyclonal antibody (Abcam Biotechnology, ab247229; diluted, 1:200) at 4 °C overnight, followed by incubation with secondary antibodies (cat # K5007; Dako). Staining was performed with 3,3′-diaminobenzidine (DAB) and counterstained with hematoxylin. Two senior pathologists who were blinded to all radiological and clinical results independently selected five nonoverlapping and discontinuous regions to calculate the mean for statistical analysis. Variations in the results within a range of 5% were reassessed, and a consensus decision was made. With the threshold value of 5% (p-β-arrestin1 tumor cells/total tumor cells), cases with expression higher than 5% were considered p-β-arrestin1 positive.

Follow-up surveillance after surgical resection

The patients were consistently followed-up after liver resection at intervals of 3 to 6 mo based on α-fetoprotein and imaging examinations, including ultrasound, CT or magnetic resonance imaging (MRI), and the time of disease-specific progression (local recurrence or distant organ metastasis) and time of death were recorded. These survival data were collected by one radiologist using electronic medical records and follow-up imaging studies until June 30, 2020. Overall survival (OS) was measured as the interval from the date of surgery to the date of death from a disease-related cause or the latest follow-up. For patients who were alive at the latest follow-up, the data were censored.

Radiomics workflow

Regions of interest (ROIs) were manually delineated around the outline of the tumor slice by slice using ITK-SNAP software (version 3.6.0) and excluded necrosis and calcification in the tumors. Radiomics features were generated from the images using in-house scientific research 3D analysis software (Analysis Kit, version V3.0.0. R, GE healthcare). Two classes of feature extraction methods were extracted as follows: the original feature class and 14 filter classes (boxmean, additiveGaussiannoise, binomialblurimage, curvatureflow, boxsigmaimage, log, wavelet, normalize, laplaciansharpening, discreteGaussian, mean, specklenoise, recursiveGaussian and shotnoise). A total of 2600 features were extracted from the tumors. Two radiologists (readers 1 and 2) performed ROI segmentation in a blinded

manner to assess interobserver reliability. Reader 1 repeated the feature extraction twice during a 1-wk period to evaluate intraobserver reliability. The interobserver reliability and intraobserver reliability were assessed by obtaining the intraclass correlation coefficient (ICC). Features with ICC values > 0.75 were selected for subsequent investigation. The feature selection process comprised the following three steps in the training group: variance analysis, Spearman correlation, and Lasso regression analysis. The radiomics score of each patient was calculated using this determined multivariable logistic regression model.

Prediction models of β-arrestin1 phosphorylation

For CT radiographic and clinical factors, predictors with $P < 0.05$ in the univariate logistic analysis ($P < 0.05$) were included. Multivariate logistic analysis, which was used to identify significant predictors based on a backward stepwise selection process with the Akaike information criterion, was employed to develop a clinical-radiological (CR) model. In addition, a clinical-radiological-radiomics (CRR) model was constructed by multivariate logistic regression analysis, tests of the association with radiomics scores, clinical factor evaluations and CT imaging findings based on a backward stepwise selection process with the Akaike information criterion.

Statistical analysis

Categorical variables are summarized as frequencies and proportions, while continuous variables are expressed as the means and standard deviations or medians and interquartile ranges (IQRs). The differences in characteristics between groups were evaluated using Student's *t* test (normal distribution) and the Mann-Whitney *U* test (skewed distribution) for continuous variables and the chi-squared test or Fisher's exact test for categorical variables. OS curves were drawn by using the Kaplan-Meier method, and the difference in OS between groups was compared using the log-rank test. Inter-observer agreement was applied to assess the reliability of imaging analysis using the Kappa test; 0-0.2 represents slight, 0.21-0.40: fair, 0.41-0.60: moderate, 0.61-0.80: substantial, 0.81-1: excellent.

The discriminative performance of the prediction models was quantified by the area under the curve (AUC) of receiver operator characteristic (ROC) curves. Differences in the ROC curves were compared by using the DeLong test. Calibration curves were generated to assess the calibration of the prediction model with the Hosmer-Lemeshow test. The probabilities of net benefits were quantified by decision curve analysis to evaluate the clinical application value of the prediction models.

The statistical analyses were implemented using *R* statistical software (version 3.4.2, http://www.R-project.org) and SPSS software (version 22.0, IBM), and two-sided *P* values < 0.05 were considered significant.

RESULTS

Patient characteristics

Of the 99 patients [male/female: 88/11; mean age, 51.53 ± 12.62 years, range 21 to 78 years) included in the study (training (n = 69) and validation (n = 30)], p-β-arrestin1 was identified in 39 (39.4%) patients. The 3-year survival rates of p-β-arrestin1-positive and p-β-arrestin1-negative HCC patients were 38.5% and 31.7%, respectively. The Kaplan-Meier method showed that p-β-arrestin1-positive patients lived longer than p-β-arrestin1-negative patients ($P < 0.05$ with the log-rank test). The clinical, pathological, and imaging characteristics of patients in the training and validation cohorts are summarized in Table 1.

Development of the radiomics score

Variance analysis using *t* test identified 15 radiomics features, assessed by Spearman rank correlation, and 4 features (boxsigmaimage_glrlm_RunLengthNonUniformity, wavelet_firstorder_wavelet-HLL-Skewness, wavelet_glcm_wavelet-HLH-Correlation, and wavelet_ngtdm_wavelet-LHL-Busyness) were chosen for logistic regression analysis ($P > 0.05$). Variables with $P < 0.1$ in the univariable logistic regression analysis were included in the multivariable regression model with backward stepwise selection using the Akaike information criterion. The radiomics score was calculated with the following formula: radiomics score = -0.3527 + 0.4748 × boxsigmaimage_glrlm_RunLengthNonUniformity + 0.7046 × wavelet_firstorder_wavelet-HLL-Skewness-0.5697 × wavelet_glcm_wavelet-HLH-Correlation + 0.6471 × wavelet_ngtdm_wavelet-LHL-Busyness.

Development of the predictive models

In total, 2 clinical characteristics [alanine aminotransferase (ALT) and aspartate aminotransferase (AST) levels], 2 imaging features (tumor size and tumor margin on portal venous phase images) and the radiomics score were identified by univariate analysis (all $P < 0.1$). In the multivariable logistic regression analysis, radiomics score [odds ratio (OR), 3.412; 95%CI: 1.562-7.453, $P = 0.002$], ALT level (OR, 0.159; 95%CI: 0.038-0.673, $P < 0.012$), tumor size (OR, 0.243; 95%CI: 0.059-1.003, $P = 0.05$) and tumor margin (OR, 0.170; 95%CI: 0.044-0.664, $P = 0.011$) significantly predicted β-arrestin1 phosphorylation

Table 1 Baseline characteristics of the patients in the training and validation cohorts

Variables	Training cohort (*n* = 69)	Validation cohort (*n* = 30)	*P* value
Age, mean ± SD, yr	51.00 ± 13.019	52.73 ± 11.776	0.269
Gender			0.751
Male	61 (88.4)	26 (86.7)	
ALT (IU/L)			0.375
< 40	44 (63.8)	16 (53.5)	
AST (IU/L)			0.829
< 35	32 (46.4)	13 (43.4)	
ALB (g/L)			0.612
< 40	15 (21.7)	8 (26.7)	
GGT (μ/L)			0.817
< 45	24 (34.8)	9 (30.0)	
TBIL (μmol/L)			0.828
< 17.1	39 (56.5)	16 (53.3)	
PLT (× 10^9/L)			0.791
< 100	14 (20.3)	7 (23.3)	
PT(s)			0.596
< 9.6 or > 12.8	16 (23.2)	5 (16.7)	
AFP (ng/mL)			0.279
< 400	34 (49.3)	11 (36.7)	
CEA (ng/mL)			0.798
< 3.4	53 (76.8)	24 (80.0)	
HBsAg			0.270
Positive	61 (88.4)	29 (96.7)	
MVI			0.827
Absent	36 (52.2)	17 (56.7)	
Present	33 (47.8)	13 (43.3)	
Differentiation			0.661
Highly	37 (53.6)	18 (60.0)	
Middle-Low	32 (46.4)	12 (40.0)	
BCLC			0.254
0-A	9 (13.0)	8 (26.7)	
B	28 (40.6)	10 (33.3)	
C	32 (46.4)	12 (40.0)	
Child-Pugh Score			0.770
< 3	57 (82.6)	26 (86.7)	
Morphologic CT features			
Tumour size			0.499
< 5 cm	24 (34.8)	13 (43.3)	
Multifocality			0.351
1	49 (71.0)	18 (60.0)	
≥ 2	20 (29.0)	12 (40.0)	

Tumour margin			0.661
Smooth	32 (46.4)	12 (40.0)	
Non-smooth	37 (53.6)	18 (60.0)	
Pseudo–capsule			0.824
Well-defined	27 (39.1)	13 (43.3)	
Ill-defined	42 (60.9)	17 (56.7)	
AP hyperenhancement			0.448
No	5 (7.2)	4 (13.3)	
Yes	64 (92.8)	26 (86.7)	
PVP hypoenhancement			0.430
No	4 (5.8)	3 (10.0)	
Yes	65 (94.2)	27 (90.0)	
Radiologic evidence of necrosis			0.822
Absent	25 (36.2)	12 (40.0)	
Present	44 (63.8)	18 (60.0)	
Radiologic evidence of cirrhosis			0.654
Absent	45 (65.2)	18 (60.0)	
Present	24 (34.8)	12 (40.0)	
Portal vein tumor thrombosis invasion			0.186
Absent	43 (62.3)	14 (46.7)	
Present	26 (37.7)	16 (53.3)	

Note: Unless otherwise indicated, data are the number of patients, and data in parentheses are percentages. AFP: Alpha-fetoprotein; CEA: Carcinoembryonic antigen; HBsAg: Hepatitis B surface antigen; ALT: Alanine aminotransferase; AST: Aspartate aminotransferase; TBIL: Total bilirubin; ALB: Albumin; PT: Prothrombin time; PLT: Platelet count; GGT: γ-glutamyl transpeptidase; MVI: Microvascular invasion; BCLC: Barcelona Clinic Liver Cancer; SD: Standard deviation; AP: Arterial phase; PVP: Portal venous phase.

(Table 2). Thus, the CR and CRR models were constructed by using the above aggressive features and the nomograms of the above multiparametric models are shown in Figure 2A and B. Excellent interobserver agreement was observed for the imaging feature evaluation, with Kappa values of 0.890 for tumor size and 0.789 for smooth tumor margin (Figure 3).

Predictive performance of the models

In the training cohort, the AUCs of the radiomics score, CR model and CRR model were 0.754 (95%CI: 0.640-0.868), 0.794 (95%CI: 0.686-0.901) and 0.898 (95%CI: 0.820-0.977), respectively. The CRR model had a significantly higher AUC than the radiomics score (P = 0.007) and the CR model (P = 0.011). In the validation cohort, the AUCs of the radiomics score, CR model and CRR model were 0.704 (95%CI: 0.454-0.953), 0.646 (95%CI: 0.411-0.880) and 0.735 (95%CI: 0.505-0.966), respectively. The diagnostic performance of the radiomics score and two models is shown in Table 3 and Figure 2C and D. The calibration curve of all the models showed excellent agreement between the predictions and observations in both the training and validation cohorts (all P > 0.05) (Figure 2E and F). The decision curve showed that the CRR model had the largest overall net benefit compared with the treat-all-patients as p-β-arrestin1 positive and treat-none patients as p-β-arrestin1 negative across the full range of reasonable threshold probabilities (Figure 4).

Risk stratification with p-β-arrestin1 predicted by the CRR model

According to the risk of β-arrestin1 phosphorylation predicted by the CRR model, patients with p-β-arrestin1 positivity lived longer than those with p-β-arrestin1 negativity using the log-rank test (P < 0.05) in both the training and validation cohorts (Figure 5).

Table 2 Univariate and multivariate regression analyses of the p-β-arrestin1-positive and p-β-arrestin1-negative groups in the training cohort

Variables	Univariable analysis		Multivariable analysis	
	OR (95%CI)	*P* value	OR (95%CI)	*P* value
ALT	0.237 (0.043-1.292)	0.096[a]	0.159 (0.038-0.673)	0.012[a]
AST	0.497 (0.100-2.471)	0.393	-	-
Tumor size	0.245 (0.059-1.019)	0.053[a]	0.243 (0.059-1.003)	0.050[a]
Tumor margin	0.180 (0.046-0.706)	0.014[a]	0.170 (0.044-0.664)	0.011[a]
Radiomics	3.473 (1.574-7.663)	0.002[a]	3.412 (1.562-7.453)	0.002[a]

[a]*P* value < 0.1.
ALT: Alanine aminotransferase; AST: Aspartate aminotransferase; CI: Confidence interval; OR: Odds ratio.

Table 3 Diagnostic performance of the three models for predicting β-arrestin1 phosphorylation-positive hepatocellular carcinoma

	Training group				Validation cohort			
	AUC (95%CI)	SPE	SEN	*P* value	AUC (95%CI)	SPE	SEN	*P* value
RS	0.754 (0.640-0.868)	53.8	86.7	0.007[1]	0.704 (0.454-0.953)	47.6	77.8	0.791[1]
CR	0.794 (0.686-0.901)	87.2	66.7	0.631[2]	0.646 (0.411-0.880)	81.0	33.3	0.713[2]
CRR	0.898 (0.820-0.977)	87.2	86.7	0.011[3]	0.735 (0.505-0.966)	71.4	66.7	0.147[3]

[1]AUCs of the radiomics score and clinico-radiological-radiomics model were compared.
[2]AUCs of the radiomics score and clinico-radiological model were compared.
[3]AUCs of the clinico-radiological model and clinico-radiological-radiomics model were compared.
RS: Radiomics score; CR: Clinico-radiological; CRR: Clinico-radiological-radiomics; SEN: Sensitivity; SPE: Specificity; AUC: Area under the curve; CI: Confidence interval.

DISCUSSION

In this retrospective study, a CT image-based model incorporating qualitative imaging features, clinical characteristics and quantitative radiomics features for predicting β-arrestin1 phosphorylation in HCC was generated. In addition, in patients treated with sorafenib, we found that p-β-arrestin1-positive HCC patients predicted by the CRR model were associated with better prognosis. The CRR model may serve as a noninvasive and effective tool to predict HCC patients β-arrestin1 phosphorylation status and help select patients who are suitable for sorafenib treatment.

For predicting β-arrestin1 phosphorylation in HCC patients, radiomics features provided increased power (AUC = 0.754) and were indicated to be independent predictors for p-β-arrestin1 in the final CRR model (P = 0.005). Utilizing the radiomics method, the proposed CRR model yielded an improved diagnostic performance in the training cohort (AUC from 0.794 to 0.898) and validation cohort (AUC from 0.646 to 0.735), indicating that the combined radiomics approach may have greater value in preoperative β-arrestin1 phosphorylation prediction than clinico-radiological features. The reason why the CRR model achieved the best predictive performance can be explained by the fact that the final model includes both qualitative and quantitative imaging features to provide a comprehensive overview of the correlations of radiomics features with HCC pathological status and genomics characteristics[25]. The radiomics signature includes shape, intensity, and texture information, which can reflect the complexity of the properties of the target tissue. Previous studies have shown that imaging features, including texture features, are informative of the gene expression profiles of HCC lesions, which parallels the diversity of molecular activities[26]. Hectors *et al* found that MRI radiomics features are highly associated with HCC immuno-oncological characteristics and can serve as noninvasive predictors of its status[27]. A predictive nomogram incorporating a radiomics signature and other clinico-radiological factors showed a significantly improved diagnostic performance in cytokeratin19 stratification of HCC[28]. However, to our knowledge, no other studies have investigated the possible value of quantitative analysis integrating clinical factors in predicting β-arrestin1 phosphorylation in HCC. Developed in the training cohort and applied to the validation cohort, the radiomics score based on CECT images combined with clinico-radiological factors could correctly identify the β-arrestin1 phosphorylation status of more than 86.7% of the patients in the training cohort and was well validated

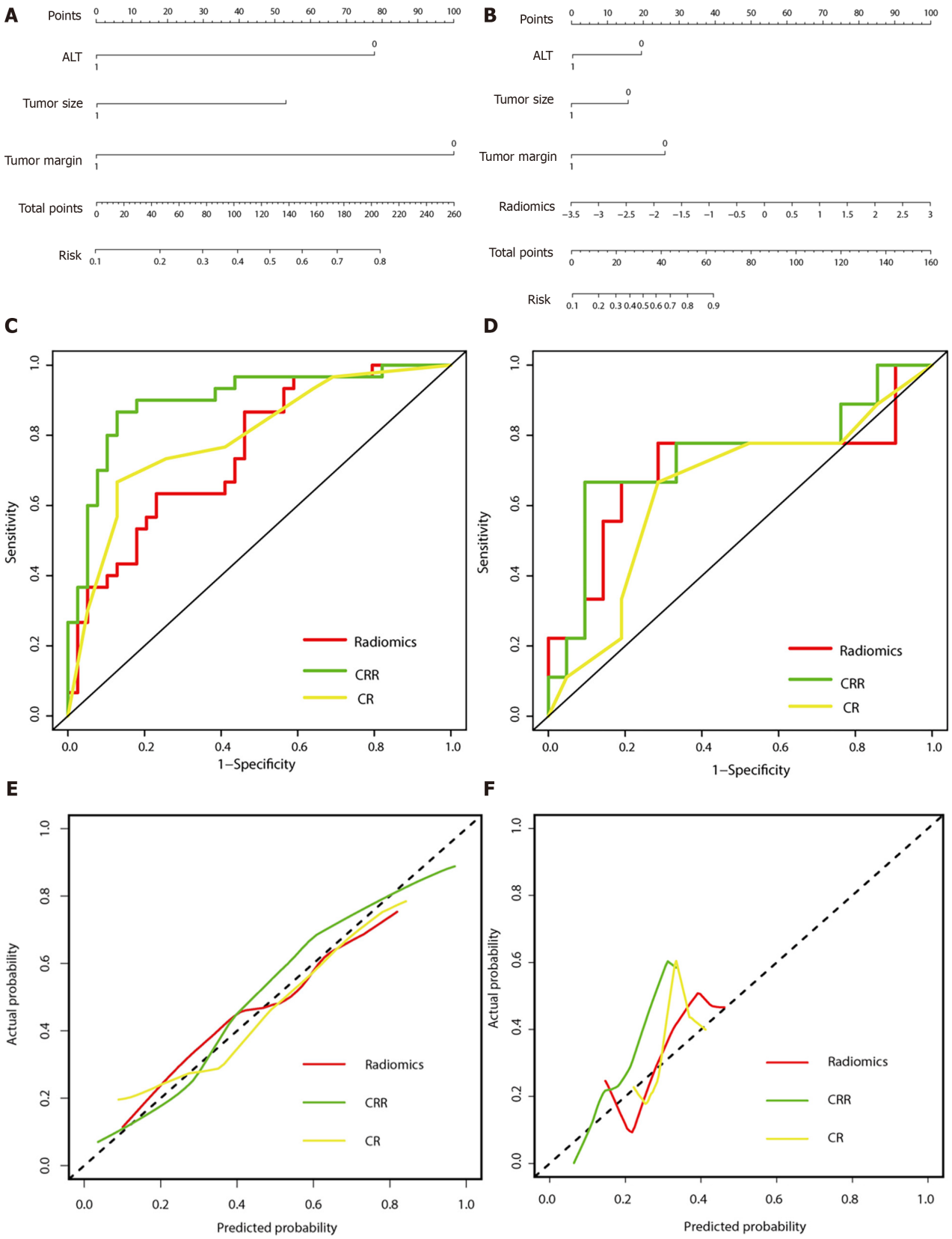

Figure 2 Performance of the three models. A: The developed clinico-radiological (CR) nomogram; B: The developed clinico-radiological-radiomics (CRR) nomogram. Predictor points are found on the uppermost point scale that corresponds to each variable. On the bottom scale, the points for all variables are added and translated into a β-arrestin1 phosphorylation positivity probability. C: Comparison of receiver operating characteristic (ROC) curves of the radiomics model, CR model and CRR model in the training cohort; D: Comparison of receiver operating characteristic (ROC) curves of the radiomics model, CR model and CRR model in the validation cohort. E: Calibration curves of the three models in the training cohort; F: Calibration curves of the three models in the validation cohort. The actual high expression of p-β-arrestin1 is represented on the y-axis, and the predicted probability is represented on the x-axis. The closer fit of the solid line to the ideal black dotted line indicates a better calibration.

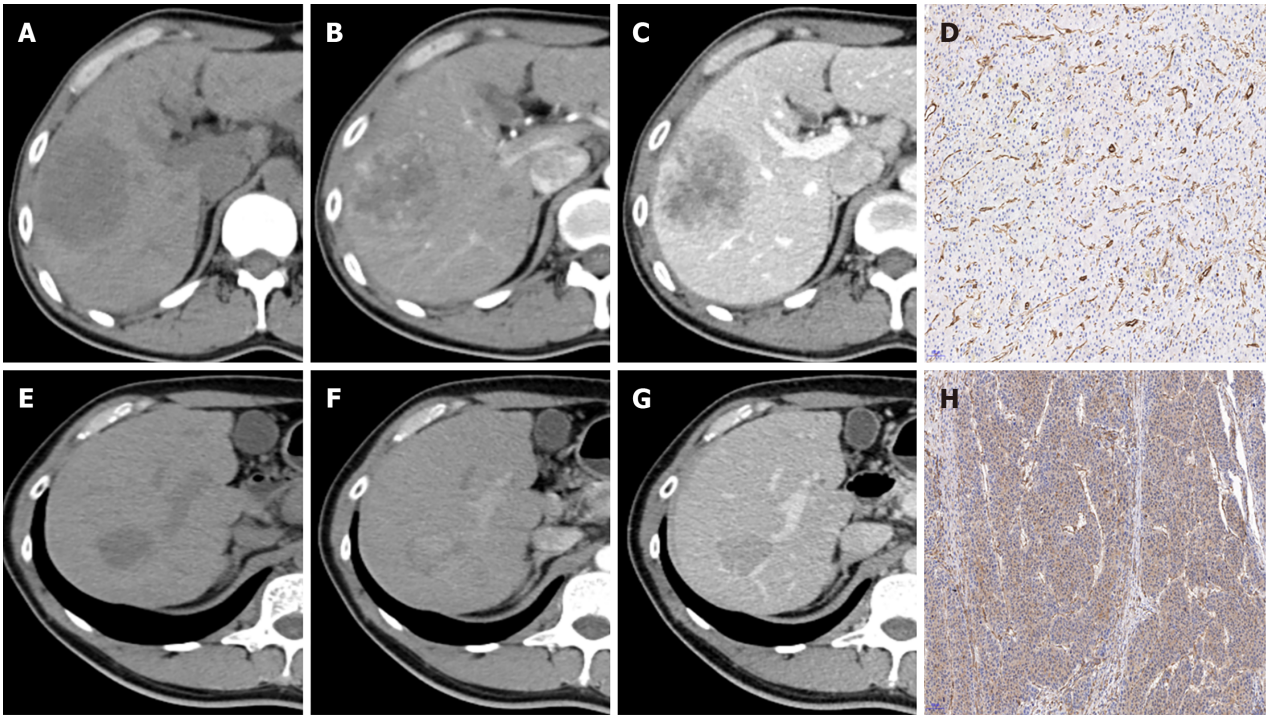

Figure 3 Representative images of contrast-enhanced computed tomography and β-Arrestin1 phosphorylation (magnification, × 100). A: CT images of a 45-year-old man with a 6.3-cm hepatocellular carcinoma (HCC) in the right liver lobe in the plain phase; B: The tumor shows heterogeneous hyperenhancement in the arterial phase; C: The tumor shows washout at the portal venous phase with intratumor necrosis, an ill-defined capsule and a non-smooth tumor margin. D: Immunohistochemical staining shows a β-arrestin1 phosphorylation-negative status at 100× magnification.

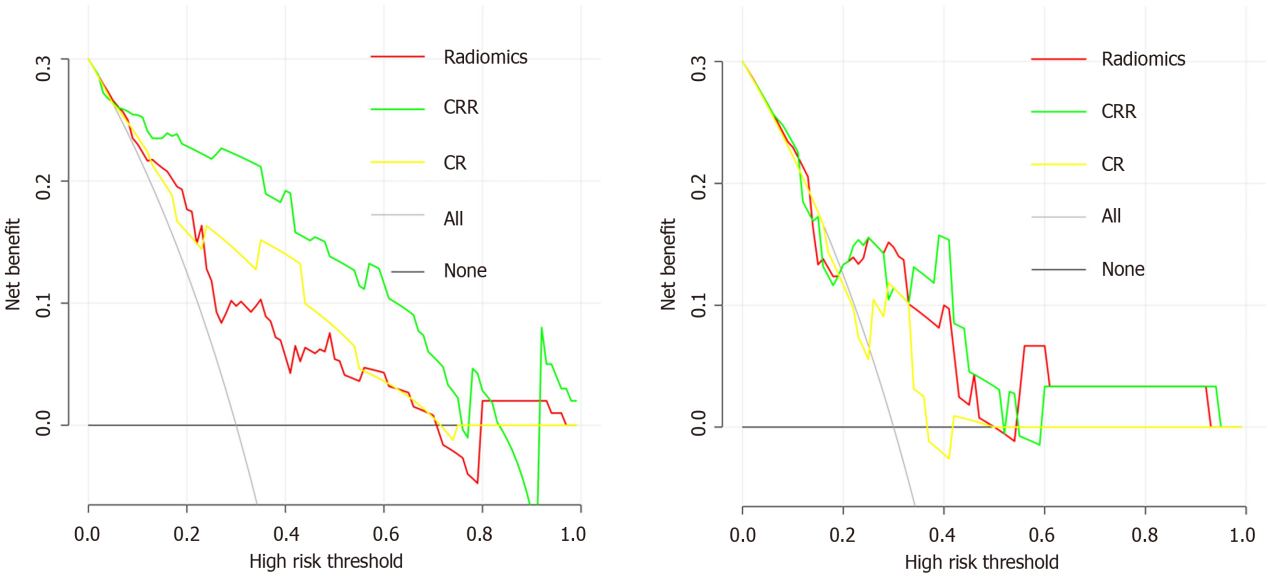

Figure 4 Decision curve analysis for each model. A: Decision curve analysis in the training cohort; B: Decision curve analysis in the validation cohort. The y-axis measures the net benefit, and the x-axis is the threshold probability. The gray line represents the hypothesis that all patients are β-arrestin1 phosphorylation-positive. The black line represents the hypothesis that all patients are β-arrestin1 phosphorylation-negative. Among the three models, the clinico-radiological-radiomics (CRR) model provided the highest net benefit compared with the radiomics and clinico-radiological (CR) models.

to serve as a quantitative multiple-feature parameter for the β-arrestin1 phosphorylation-based risk stratification of HCC patients. Our study investigates the predictive aspects of computational-assisted models for the preoperative prediction of β-arrestin1 phosphorylation status, which currently can now only be attained by invasive biopsy or surgery. This computational method can guide clinical management by identifying patients for targeted therapy, as most patients recommended for systematic treatment according to the Barcelona Clinic Liver Cancer algorithm are not candidates for surgery due to their poor condition[29].

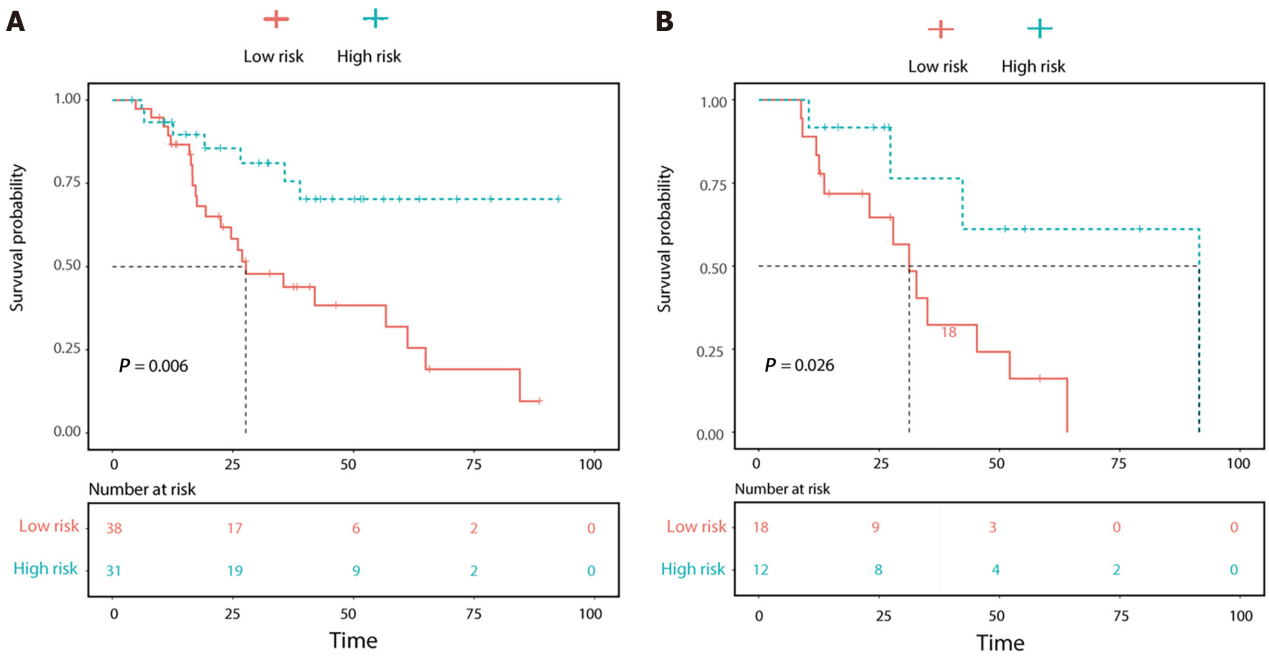

Figure 5 Overall survival (OS) curve analysis. A: The OS curve estimates by clinic-radiological-radiomics model in patients with β-Arrestin1 phosphorylation positive and β-Arrestin1 phosphorylation negative in the training cohort; B: The OS curve estimates by clinic-radiological-radiomics model in patients with β-Arrestin1 phosphorylation positive and β-Arrestin1 phosphorylation negative in the validation cohort.

The clinicopathologic features of preoperative serum ALT levels were significantly different in the p-β-arrestin1-positive and p-β-arrestin1-negative groups in this study. In line with the findings of previous studies, serum ALT is an important hepatic inflammation marker that is correlated with liver function. Hepatitis infection can simultaneously induce serum ALT increases and β-arrestin1 upregulation, and higher serum ALT levels are a feature commonly associated with this subtype of HCC[12]. In clinical practice, serum ALT levels can be easily obtained and incorporated into a radiomics model for individualized risk estimation. A larger tumor size and nonsmooth tumor margins were also shown to be associated with p-β-arrestin1 expression. This finding is in accordance with previous studies showing that β-arrestin1 can promote hepatocellular proliferation *via* the Akt pathway, and HCCs with higher p-β-arrestin1 levels are more likely to have an infiltrative growth pattern[13]. Serum AST levels were associated with p-β-arrestin1 in the univariate analysis but not the multivariate models, probably because of a lack of statistical power due to the insufficient number of patients.

We also found that patients who were p-β-arrestin1-positive lived longer than those who were p-β-arrestin1-negative. Previous studies have revealed that high expression of β-arrestin1 contributes to tumor survival, proliferation, angiogenesis, invasion and metastasis and is associated with the prognosis of epithelial ovarian cancer, prostate cancer and lung cancer[30-34]. Although the correlation of β-arrestin1 with HCC prognosis has not been investigated, β-arrestin1 has been shown to be positively related to HCC carcinogenesis and metastasis[12,13]. Evidence has shown that the sorafenib response is impaired in HCC with dysregulated phosphorylated ERK (p-ERK) and AKT (p-AKT) activation and that suppression of ERK1/2 increases sorafenib sensitivity in several HCC cell lines[35-37], while β-arrestin1 can activate PI3K/Akt signaling by Akt phosphorylation and trigger ERK1/2 phosphorylation-mediated EMT in HCC. Moreover, hyperactive PI3K/AKT signaling has been reported to be one of the primary causes of EMT in HCC resistance to sorafenib[35,36,38]. These studies indicate that PI3K/AKT signaling and p-ERK1/2-mediated EMT signal hyperactivity may function in β-arrestin1-induced HCC resistance to sorafenib and further influence the prognosis of HCC patients treated with sorafenib, which was consistent with a series of studies recently showing that β-arrestin1 expression had some correlation with resistance to therapy in several types of cancers, such as breast[39] ovarian[40,41] and non-small-cell lung cancer[42]. Increased phosphorylation of β-arrestin1 Leads to decreased levels of dephosphorylated β-arrestin1, which influences its function in the activation of downstream factors, such as p-ERK and p-AKT. Therefore, the phosphorylation status of β-arrestin1 has a critical role in HCC sorafenib resistance. Predicting p-β-arrestin1 can help to identify patients who are sensitive to this treatment and prevent unnecessary side effects.

There were some limitations in our study. First, this was a retrospective longitudinal cohort study and selection bias may exist due to the strict inclusion criteria. Although we performed internal validation, additional external validation is needed to facilitate the wider use of this predictive model. Second, our study was performed at a single institution, and the CT scanner in this study was not fixed in their protocol. However, this could be a strength in terms of the generalizability of the findings by reflecting actual clinical practice. Third, p-β-arrestin1 positivity was defined as a cutoff of 5% for tumor

cells to avoid false-positive results. The association between our predictive model and the graded degree of p-β-arrestin1 immunopositivity should be further assessed.

CONCLUSION

In conclusion, CECT-based radiomics combining clinico-radiological factors achieved desirable results in the prediction of β-arrestin1 phosphorylation in HCC which showed prognostic value in patients treated with sorafenib. This finding suggests that CT radiomics may provide promising and noninvasive biomarkers for the evaluation of p-β-arrestin1 expression and may help identify the subset of HCC patients who are more sensitive to sorafenib treatment, thus potentially guiding personalized treatment strategies.

ARTICLE HIGHLIGHTS

Research background

Sorafenib is regarded as a first-line systematic treatment option for patients with advanced hepatocellular carcinoma (HCC), but its efficacy is largely influenced by raising resistance. The phosphorylation status of β-arrestin1 influences its function as a signal strongly related to sorafenib resistance.

Research motivation

Identifying patients who are more likely to benefit from sorafenib treatment and discovering related biomarkers associated with sorafenib treatment response can guide personal management.

Research objectives

The purpose of this study was to develop and validate radiomics-based models for predicting β-arrestin1 phosphorylation in HCC with contrast-enhanced computed tomography (CT).

Research methods

We included ninety-nine HCC patients (training cohort: n = 69; validation cohort: n = 30) who received systemic sorafenib treatment after surgery. Radiomics features were generated and selected to build a radiomics score and then combined with clinical and imaging features to establish clinico-radiological (CR) and clinico-radiological-radiomics (CRR) models. The performance and clinical usefulness of the models were measured by receiver operating characteristic and decision curves. Their association with prognosis was also evaluated using the Kaplan-Meier method.

Research results

Our study found that the ALT level, tumor size and tumor margin were significant independent factors for predicting β-arrestin1 phosphorylation. The CRR model showed better discriminative performance than the radiomic score or the CR model. The β-arrestin1 phosphorylation status predicted by the CRR model was shown to be significantly associated with overall survival.

Research conclusions

The radiomics signature is a reliable tool for evaluating β-arrestin1 phosphorylation, and may help to better identify patients who would benefit from sorafenib treatment.

Research perspectives

The results of this study suggests that CT-based radiomics may provide promising and noninvasive biomarkers for the evaluation of β-arrestin1 phosphorylation and may help to identify the subset of HCC patients who are more sensitive to sorafenib treatment, thus potentially guiding personalized treatment strategies.

FOOTNOTES

Author contributions: Che F, Xu Q, Shi YJ and Song B designed the research; Che F, Li Q and Xu Q conducted literature search and analysis; Yang CW, Huang ZX, Wang LY and Wei Y provided material support; Song B provided funding for the article; Che F and Xu Q wrote the paper; Che F and Xu Q contributed equally to this work.

Supported by the Science and Technology Support Program of Sichuan Province, No. 2021YFS0144 and No. 2021YFS0021; China Postdoctoral Science Foundation, No. 2021M692289; and National Natural Science Foundation of

China, No. 81971571.

Institutional review board statement: This study was approved by the Ethics Committee of West China Hospital.

Informed consent statement: Patients were not required to give informed consent to the study because this retrospective study used anonymous clinical data that were obtained after each patient agreed to treatment by written consent.

Conflict-of-interest statement: We have no financial relationships to disclose.

Data sharing statement: No additional data are available.

Country/Territory of origin: China

ORCID number: Feng Che 0000-0002-8008-2696; Qing Xu 0000-0001-9438-5535; Qian Li 0000-0001-8330-7654; Zi-Xing Huang 0000-0001-7967-5948; Cai-Wei Yang 0000-0003-3335-3948; Li-Ye Wang 0000-0002-5535-4514; Yi Wei 0000-0003-3993-9747; Yu-Jun Shi 0000-0003-0494-6023; Bin Song 0000-0002-7269-2101.

S-Editor: Wu YXJ
L-Editor: A
P-Editor: Yu HG

REFERENCES

1 **Sung H**, Ferlay J, Siegel RL, Laversanne M, Soerjomataram I, Jemal A, Bray F. Global Cancer Statistics 2020: GLOBOCAN Estimates of Incidence and Mortality Worldwide for 36 Cancers in 185 Countries. *CA Cancer J Clin* 2021; **71**: 209-249 [PMID: 33538338 DOI: 10.3322/caac.21660]

2 **Llovet JM**, Ricci S, Mazzaferro V, Hilgard P, Gane E, Blanc JF, de Oliveira AC, Santoro A, Raoul JL, Forner A, Schwartz M, Porta C, Zeuzem S, Bolondi L, Greten TF, Galle PR, Seitz JF, Borbath I, Häussinger D, Giannaris T, Shan M, Moscovici M, Voliotis D, Bruix J; SHARP Investigators Study Group. Sorafenib in advanced hepatocellular carcinoma. *N Engl J Med* 2008; **359**: 378-390 [PMID: 18650514 DOI: 10.1056/NEJMoa0708857]

3 **Cheng AL**, Kang YK, Chen Z, Tsao CJ, Qin S, Kim JS, Luo R, Feng J, Ye S, Yang TS, Xu J, Sun Y, Liang H, Liu J, Wang J, Tak WY, Pan H, Burock K, Zou J, Voliotis D, Guan Z. Efficacy and safety of sorafenib in patients in the Asia-Pacific region with advanced hepatocellular carcinoma: a phase III randomised, double-blind, placebo-controlled trial. *Lancet Oncol* 2009; **10**: 25-34 [PMID: 19095497 DOI: 10.1016/S1470-2045(08)70285-7]

4 **Lin FT**, Krueger KM, Kendall HE, Daaka Y, Fredericks ZL, Pitcher JA, Lefkowitz RJ. Clathrin-mediated endocytosis of the beta-adrenergic receptor is regulated by phosphorylation/dephosphorylation of beta-arrestin1. *J Biol Chem* 1997; **272**: 31051-31057 [PMID: 9388255 DOI: 10.1074/jbc.272.49.31051]

5 **Whalen EJ**, Rajagopal S, Lefkowitz RJ. Therapeutic potential of β-arrestin- and G protein-biased agonists. *Trends Mol Med* 2011; **17**: 126-139 [DOI: 10.1016/j.molmed.2010.11.004]

6 **Ezzoukhry Z**, Louandre C, Trécherel E, Godin C, Chauffert B, Dupont S, Diouf M, Barbare JC, Mazière JC, Galmiche A. EGFR activation is a potential determinant of primary resistance of hepatocellular carcinoma cells to sorafenib. *Int J Cancer* 2012; **131**: 2961-2969 [PMID: 22514082 DOI: 10.1002/ijc.27604]

7 **Ma Y**, Xu R, Liu X, Zhang Y, Song L, Cai S, Zhou S, Xie Y, Li A, Cao W, Tang X. LY3214996 relieves acquired resistance to sorafenib in hepatocellular carcinoma cells. *Int J Med Sci* 2021; **18**: 1456-1464 [PMID: 33628103 DOI: 10.7150/ijms.51256]

8 **Negri FV**, Dal Bello B, Porta C, Campanini N, Rossi S, Tinelli C, Poggi G, Missale G, Fanello S, Salvagni S, Ardizzoni A, Maria SE. Expression of pERK and VEGFR-2 in advanced hepatocellular carcinoma and resistance to sorafenib treatment. *Liver Int* 2015; **35**: 2001-2008 [PMID: 25559745 DOI: 10.1111/liv.12778]

9 **Mendoza MC**, Er EE, Blenis J. The Ras-ERK and PI3K-mTOR pathways: cross-talk and compensation. *Trends Biochem Sci* 2011; **36**: 320-328 [PMID: 21531565 DOI: 10.1016/j.tibs.2011.03.006]

10 **Zhang PF**, Li KS, Shen YH, Gao PT, Dong ZR, Cai JB, Zhang C, Huang XY, Tian MX, Hu ZQ, Gao DM, Fan J, Ke AW, Shi GM. Galectin-1 induces hepatocellular carcinoma EMT and sorafenib resistance by activating FAK/PI3K/AKT signaling. *Cell Death Dis* 2016; **7**: e2201 [PMID: 27100895 DOI: 10.1038/cddis.2015.324]

11 **Chen HA**, Kuo TC, Tseng CF, Ma JT, Yang ST, Yen CJ, Yang CY, Sung SY, Su JL. Angiopoietin-like protein 1 antagonizes MET receptor activity to repress sorafenib resistance and cancer stemness in hepatocellular carcinoma. *Hepatology* 2016; **64**: 1637-1651 [PMID: 27530187 DOI: 10.1002/hep.28773]

12 **Yang Y**, Guo Y, Tan S, Ke B, Tao J, Liu H, Jiang J, Chen J, Chen G, Wu B. β-Arrestin1 enhances hepatocellular carcinogenesis through inflammation-mediated Akt signalling. *Nat Commun* 2015; **6**: 7369 [PMID: 26077142 DOI: 10.1038/ncomms8369]

13 **Xu X**, Lei Y, Zhou H, Guo Y, Liu H, Jiang J, Yang Y, Wu B. β-Arrestin1 is involved in hepatocellular carcinoma metastasis *via* extracellular signal-regulated kinase-mediated epithelial-mesenchymal transition. *J Gastroenterol Hepatol* 2020; **35**: 2229-2240 [PMID: 32445259 DOI: 10.1111/jgh.15115]

14 **Lin FT**, Miller WE, Luttrell LM, Lefkowitz RJ. Feedback regulation of beta-arrestin1 function by extracellular signal-regulated kinases. *J Biol Chem* 1999; **274**: 15971-15974 [PMID: 10347142 DOI: 10.1074/jbc.274.23.15971]

15 **Cohen JV**, Sullivan RJ. Developments in the Space of New MAPK Pathway Inhibitors for BRAF-Mutant Melanoma. *Clin Cancer Res* 2019; **25**: 5735-5742 [PMID: 30992297 DOI: 10.1158/1078-0432.CCR-18-0836]

16 **Sun R**, Limkin EJ, Vakalopoulou M, Dercle L, Champiat S, Han SR, Verlingue L, Brandao D, Lancia A, Ammari S, Hollebecque A, Scoazec JY, Marabelle A, Massard C, Soria JC, Robert C, Paragios N, Deutsch E, Ferté C. A radiomics approach to assess tumour-infiltrating CD8 cells and response to anti-PD-1 or anti-PD-L1 immunotherapy: an imaging biomarker, retrospective multicohort study. *Lancet Oncol* 2018; **19**: 1180-1191 [PMID: 30120041 DOI: 10.1016/S1470-2045(18)30413-3]

17 **Huang YQ**, Liang CH, He L, Tian J, Liang CS, Chen X, Ma ZL, Liu ZY. Development and Validation of a Radiomics Nomogram for Preoperative Prediction of Lymph Node Metastasis in Colorectal Cancer. *J Clin Oncol* 2016; **34**: 2157-2164 [PMID: 27138577 DOI: 10.1200/JCO.2015.65.9128]

18 **Aerts HJ**, Velazquez ER, Leijenaar RT, Parmar C, Grossmann P, Carvalho S, Bussink J, Monshouwer R, Haibe-Kains B, Rietveld D, Hoebers F, Rietbergen MM, Leemans CR, Dekker A, Quackenbush J, Gillies RJ, Lambin P. Decoding tumour phenotype by noninvasive imaging using a quantitative radiomics approach. *Nat Commun* 2014; **5**: 4006 [PMID: 24892406 DOI: 10.1038/ncomms5006]

19 **Kickingereder P**, Götz M, Muschelli J, Wick A, Neuberger U, Shinohara RT, Sill M, Nowosielski M, Schlemmer HP, Radbruch A, Wick W, Bendszus M, Maier-Hein KH, Bonekamp D. Large-scale Radiomic Profiling of Recurrent Glioblastoma Identifies an Imaging Predictor for Stratifying Anti-Angiogenic Treatment Response. *Clin Cancer Res* 2016; **22**: 5765-5771 [PMID: 27803067 DOI: 10.1158/1078-0432.CCR-16-0702]

20 **Gillies RJ**, Kinahan PE, Hricak H. Radiomics: Images Are More than Pictures, They Are Data. *Radiology* 2016; **278**: 563-577 [PMID: 26579733 DOI: 10.1148/radiol.2015151169]

21 **Ma X**, Wei J, Gu D, Zhu Y, Feng B, Liang M, Wang S, Zhao X, Tian J. Preoperative radiomics nomogram for microvascular invasion prediction in hepatocellular carcinoma using contrast-enhanced CT. *Eur Radiol* 2019; **29**: 3595-3605 [PMID: 30770969 DOI: 10.1007/s00330-018-5985-y]

22 **Ye Z**, Jiang H, Chen J, Liu X, Wei Y, Xia C, Duan T, Cao L, Zhang Z, Song B. Texture analysis on gadoxetic acid enhanced-MRI for predicting Ki-67 status in hepatocellular carcinoma: A prospective study. *Chin J Cancer Res* 2019; **31**: 806-817 [PMID: 31814684 DOI: 10.21147/j.issn.1000-9604.2019.05.10]

23 **Tang C**, Hobbs B, Amer A, Li X, Behrens C, Canales JR, Cuentas EP, Villalobos P, Fried D, Chang JY, Hong DS, Welsh JW, Sepesi B, Court L, Wistuba II, Koay EJ. Development of an Immune-Pathology Informed Radiomics Model for Non-Small Cell Lung Cancer. *Sci Rep* 2018; **8**: 1922 [PMID: 29386574 DOI: 10.1038/s41598-018-20471-5]

24 **Xu X**, Zhang HL, Liu QP, Sun SW, Zhang J, Zhu FP, Yang G, Yan X, Zhang YD, Liu XS. Radiomic analysis of contrast-enhanced CT predicts microvascular invasion and outcome in hepatocellular carcinoma. *J Hepatol* 2019; **70**: 1133-1144 [PMID: 30876945 DOI: 10.1016/j.jhep.2019.02.023]

25 **Lambin P**, Rios-Velazquez E, Leijenaar R, Carvalho S, van Stiphout RG, Granton P, Zegers CM, Gillies R, Boellard R, Dekker A, Aerts HJ. Radiomics: extracting more information from medical images using advanced feature analysis. *Eur J Cancer* 2012; **48**: 441-446 [PMID: 22257792 DOI: 10.1016/j.ejca.2011.11.036]

26 **Segal E**, Sirlin CB, Ooi C, Adler AS, Gollub J, Chen X, Chan BK, Matcuk GR, Barry CT, Chang HY, Kuo MD. Decoding global gene expression programs in liver cancer by noninvasive imaging. *Nat Biotechnol* 2007; **25**: 675-680 [PMID: 17515910 DOI: 10.1038/nbt1306]

27 **Hectors SJ**, Lewis S, Besa C, King MJ, Said D, Putra J, Ward S, Higashi T, Thung S, Yao S, Laface I, Schwartz M, Gnjatic S, Merad M, Hoshida Y, Taouli B. MRI radiomics features predict immuno-oncological characteristics of hepatocellular carcinoma. *Eur Radiol* 2020; **30**: 3759-3769 [PMID: 32086577 DOI: 10.1007/s00330-020-06675-2]

28 **Wang W**, Gu D, Wei J, Ding Y, Yang L, Zhu K, Luo R, Rao SX, Tian J, Zeng M. A radiomics-based biomarker for cytokeratin 19 status of hepatocellular carcinoma with gadoxetic acid-enhanced MRI. *Eur Radiol* 2020; **30**: 3004-3014 [PMID: 32002645 DOI: 10.1007/s00330-019-06585-y]

29 **Forner A**, Llovet JM, Bruix J. Hepatocellular carcinoma. *Lancet* 2012; **379**: 1245-1255 [PMID: 22353262 DOI: 10.1016/S0140-6736(11)61347-0]

30 **Shenoy SK**, Han S, Zhao YL, Hara MR, Oliver T, Cao Y, Dewhirst MW. β-arrestin1 mediates metastatic growth of breast cancer cells by facilitating HIF-1-dependent VEGF expression. *Oncogene* 2012; **31**: 282-292 [PMID: 21685944 DOI: 10.1038/onc.2011.238]

31 **Zecchini V**, Madhu B, Russell R, Pértega-Gomes N, Warren A, Gaude E, Borlido J, Stark R, Ireland-Zecchini H, Rao R, Scott H, Boren J, Massie C, Asim M, Brindle K, Griffiths J, Frezza C, Neal DE, Mills IG. Nuclear ARRB1 induces pseudohypoxia and cellular metabolism reprogramming in prostate cancer. *EMBO J* 2014; **33**: 1365-1382 [PMID: 24837709 DOI: 10.15252/embj.201386874]

32 **Dasgupta P**, Rizwani W, Pillai S, Davis R, Banerjee S, Hug K, Lloyd M, Coppola D, Haura E, Chellappan SP. ARRB1-mediated regulation of E2F target genes in nicotine-induced growth of lung tumors. *J Natl Cancer Inst* 2011; **103**: 317-333 [PMID: 21212384 DOI: 10.1093/jnci/djq541]

33 **Wang LG**, Su BH, Du JJ. Expression of β-arrestin 1 in gastric cardiac adenocarcinoma and its relation with progression. *Asian Pac J Cancer Prev* 2012; **13**: 5671-5675 [PMID: 23317236 DOI: 10.7314/apjcp.2012.13.11.5671]

34 **Cianfrocca R**, Tocci P, Rosanò L, Caprara V, Sestito R, Di Castro V, Bagnato A. Nuclear β-arrestin1 is a critical cofactor of hypoxia-inducible factor-1α signaling in endothelin-1-induced ovarian tumor progression. *Oncotarget* 2016; **7**: 17790-17804 [PMID: 26909598 DOI: 10.18632/oncotarget.7461]

35 **Huang XY**, Ke AW, Shi GM, Zhang X, Zhang C, Shi YH, Wang XY, Ding ZB, Xiao YS, Yan J, Qiu SJ, Fan J, Zhou J. α B-crystallin complexes with 14-3-3ζ to induce epithelial-mesenchymal transition and resistance to sorafenib in hepatocellular carcinoma. *Hepatology* 2013; **57**: 2235-2247 [PMID: 23316005 DOI: 10.1002/hep.26255]

36 **Zhai B**, Sun XY. Mechanisms of resistance to sorafenib and the corresponding strategies in hepatocellular carcinoma. *World J Hepatol* 2013; **5**: 345-352 [PMID: 23898367 DOI: 10.4254/wjh.v5.i7.345]

37 **Wang C**, Jin H, Gao D, Lieftink C, Evers B, Jin G, Xue Z, Wang L, Beijersbergen RL, Qin W, Bernards R. Phospho-ERK is a biomarker of response to a synthetic lethal drug combination of sorafenib and MEK inhibition in liver cancer. *J Hepatol* 2018; **69**: 1057-1065 [PMID: 30030148 DOI: 10.1016/j.jhep.2018.07.004]

38 **van Malenstein H**, Dekervel J, Verslype C, Van Cutsem E, Windmolders P, Nevens F, van Pelt J. Long-term exposure to sorafenib of liver cancer cells induces resistance with epithelial-to-mesenchymal transition, increased invasion and risk of rebound growth. *Cancer Lett* 2013; **329**: 74-83 [PMID: 23111106 DOI: 10.1016/j.canlet.2012.10.021]

39 **Lundgren K**, Tobin NP, Lehn S, Stål O, Rydén L, Jirström K, Landberg G. Stromal expression of β-arrestin-1 predicts clinical outcome and tamoxifen response in breast cancer. *J Mol Diagn* 2011; **13**: 340-351 [PMID: 21497294 DOI: 10.1016/j.jmoldx.2011.01.009]

40 **Rosanò L**, Cianfrocca R, Tocci P, Spinella F, Di Castro V, Caprara V, Semprucci E, Ferrandina G, Natali PG, Bagnato A. Endothelin A receptor/β-arrestin signaling to the Wnt pathway renders ovarian cancer cells resistant to chemotherapy. *Cancer Res* 2014; **74**: 7453-7464. [PMID: 25377471 DOI: 10.1158/0008-5472.CAN-13-3133]

41 **Sestito R**, Cianfrocca R, Rosanò L, Tocci P, Di Castro V, Caprara V, Bagnato A. Macitentan blocks endothelin-1 receptor activation required for chemoresistant ovarian cancer cell plasticity and metastasis. *Life Sci* 2016; **159**: 43-48 [PMID: 26776834 DOI: 10.1016/j.lfs.2016.01.009]

42 **Jiang Y**, Zhuo X, Fu X, Wu Y, Mao C. Targeting PAR2 Overcomes Gefitinib Resistance in Non-Small-Cell Lung Cancer Cells Through Inhibition of EGFR Transactivation. *Front Pharmacol* 2021; **12**: 625289 [PMID: 33967759 DOI: 10.3389/fphar.2021.625289]

World Journal of Gastroenterology

Submit a Manuscript: https://www.f6publishing.com

World J Gastroenterol 2022 April 14; 28(14): 1494-1498

DOI: 10.3748/wjg.v28.i14.1494

ISSN 1007-9327 (print) ISSN 2219-2840 (online)

LETTER TO THE EDITOR

Comment on review article: Chronic hepatitis C virus infection cascade of care in pediatric patients

Nouhoum Bouare, Mamadou Keita, Jean Delwaide

Specialty type: Gastroenterology and hepatology

Provenance and peer review: Invited article; Externally peer reviewed.

Peer-review model: Single blind

Peer-review report's scientific quality classification

Grade A (Excellent): 0
Grade B (Very good): 0
Grade C (Good): C
Grade D (Fair): D, D, D
Grade E (Poor): 0

P-Reviewer: Mukhopadhyay A, India; Papadopoulos K, Thailand; Singh SP, United States

Received: September 13, 2021
Peer-review started: September 13, 2021
First decision: September 29, 2021
Revised: October 20, 2021
Accepted: March 7, 2022
Article in press: March 7, 2022
Published online: April 14, 2022

Nouhoum Bouare, Biomedical Sciences, National Institute of Public Health, Bamako 1771, Mali

Mamadou Keita, Department of Prevention, Medical and Psychosocial Management, CSLS-HIV-TB-H, Bamako E 595, Mali

Jean Delwaide, Department of Gastroenterology and Hepatology, CHULiege, Liege 4000, Belgium

Corresponding author: Nouhoum Bouare, DSc, PhD, Research Scientist, Biomedical Sciences, National Institute of Public Health, Hippodrome 235, Bamako 1771, Mali. nouhoumsamakoro@yahoo.fr

Abstract

An enhanced cascade of care should include a younger population, helping to achieve the goal of the World Health Organization with a focus on elimination in the pediatric population. Furthermore, enhanced screening and awareness efforts and continued education of health care providers will improve the outcomes of chronic hepatitis C virus (HCV) infection in the pediatric population. The present work discusses and comments on the topic "cascade of care in HCV chronic pediatric patients".

Key Words: Cascade of care; Hepatitis C virus; Chronic patients; Pediatric population; Disease management; Commentary

Core Tip: Worldwide disparities exist regarding the chronic hepatitis C virus (HCV) infection cascade of care, and it is most evident between high-income countries and areas with scarce resources. An integrative strategy encompassing efficient pediatric HCV diagnosis and treatment as well as prevention is needed. Addressing health care disparities by insightfully applying successful outcomes from high-income countries in certain disadvantaged regions with poor cascade of care may help to achieve the elimination goal of HCV set by the World Health Organization.

Citation: Bouare N, Keita M, Delwaide J. Comment on review article: Chronic hepatitis C virus infection cascade of care in pediatric patients. *World J Gastroenterol* 2022; 28(14): 1494-1498
URL: https://www.wjgnet.com/1007-9327/full/v28/i14/1494.htm
DOI: https://dx.doi.org/10.3748/wjg.v28.i14.1494

TO THE EDITOR

To eliminate viral hepatitis worldwide by 2030, the World Health Organization (WHO) focused on strategic objectives to reach a decrease of the disease incidence and mortality by 90% and 65%, respectively[1,2]. The cascade of care (CoC) originates from HIV management aimed in some an extent to achieve sustained virological response[2]. It addresses the diagnosis, treatment and possible cure of hepatitis C virus (HCV)[1,2]. HCV chronic infection is reported as affecting 71 million persons globally, and many of them are unaware of their infectious status[3]. The global HCV and hepatitis B virus populations remain largely underdiagnosed and undertreated[4]. For worldwide heterogeneity, reliable HCV prevalence estimates (adjusted to age and geographic area) are needed. These country-specific estimates can highly improve the intervention by accelerating HCV elimination[1].

Rogers and Balistreri[1] reported a number of field epidemiological and/or clinical factors impacting disease evolution. The perinatal route is mainly responsible for the HCV infection propagation in the pediatric population. This route is reported as favorable to genotype 1a that is even associated with decreased clearance, persistent viremia and the risk of liver damages such as end-stage liver disease in treatment-naïve children. High grade fibrosis or cirrhosis patients are still at high risk to develop hepatocellular carcinoma even if achieving sustained virological response. Histological studies are still needed to support direct acting antiviral (DAA) treatment efficacy. The authors noticed the need of fibrosis control in children regarding the constant risk of portal hypertension and hepatocellular carcinoma occurrence. Moreover, poor social act and health-related quality of life were described in adolescent HCV patients[1]. Delaying treatment until 18 years of age favors lifetime risk of avoidable late liver complications. Hence early treatment is economic and lifesaving[1].

However, HCV CoC reports, similar to that of Rogers and Balistreri[1], mostly emanate from high-income countries[2]. Extending an HCV CoC strategy to low- and middle-income countries (LMIC) must initially and insightfully focus on disease awareness and education to disseminate the desired global health goal. Moreover, addressing the differences between a CoC applicable in high-income countries and another adjusted for low-income areas is central to achieving the ultimate HCV elimination goal.

Regarding HCV therapy, DAAs highly impact CoC. However, in 2016 the treatment was less accessible for the patients. As for CoC, updated estimates are needed to assess the impact of newly implemented approaches aimed to promote hepatitis C elimination[5]. Furthermore, improving the linkage to care is lifesaving given the precipitous dropouts occurring in HCV CoC[6]. Rogers and Balistreri[1] reported innovative intervention approaches to promote HCV management through an academic mentorship program. This program intended to build a model that could improve the health of underserved communities in the Appalachian region. It has even reinforced the competences of primary health care providers to treat patients on site, thus reducing the need for travel to seek a DAA therapy specialist. The advent of telemedicine has also had a positive impact on HCV treatment. Extension for community health care outcomes through videoconferencing technology may be useful for HCV treatment in underserved communities[1].

This educative, extensive and informative model, combined with efficient and reliable HCV diagnostic and treatment efforts among pediatric patients along with preventive tools, should thoroughly address the hepatitis C elimination goal worldwide. The simultaneous screening of three viral infections (HIV, HCV and hepatitis B virus) using a multiplex immunochromatographic rapid diagnosis test [HCV/hepatitis B surface antigen/HIV Combo RDT Cassette (ITHD-C43), Biotest Biotech Inc, Hangzhou, China] in childbearing aged women may reinforce the prevention against these diseases [7]. This multiplex test may be useful in sub-Saharan Africa because it improves the "cascade of screening" and linkage to care with reduced cost[7].

The electronic medical record-based screening programs are also recommended for low-income areas since it was determined to be an effective method to manage patients for HIV and HCV in the Appalachian region[8]. Among the primary preventive means, we can enumerate campaigns for behavioral changes in high-risk groups, such as persons who inject drugs, and surveillance of pregnant women and diabetic and non-hepatic cancer patients.

However, high treatment costs and small numbers of trained providers are the primary reasons for slow HCV comprehensive elimination in low-income areas[9]. Successful efforts toward HCV elimination among persons who inject drugs contrast with the relative lack of attention to scarce resource settings where the hopes and potential for elimination are less clear, such as in many LMICs [10]. In addition, pretherapeutic tests and treatment access are still challenging in developing countries [11]. CoC is a major challenge in regard to the prison setting. Post release interventions that integrate

HCV care are highly effective. The treatment observance can be highly improved by a close collaboration between community and prison health care programs. Investigations are still needed to determine predictors of linkage to HCV care after release[12].

To overcome these barriers mentioned above, an efficient model for HCV CoC should be simple, targeted, pluralistic, scalable, integrated, patient-centered and affordable[13]. Efforts should focus on linkage to care to capitalize on DAA treatment advances and increase patient access to Medicaid assurance[14]. Regular follow-up of patients greatly increases HCV therapy effectiveness. Modelling studies show that a perfect follow-up would be cost-effective. Multilevel interventions along the cascade should be prioritized rather than single level[15]. Interventions that promote chronic hepatitis B/C elimination can be summarized as follow: Prioritize management of patients at multiple levels of the health care setting; define the required supports enabling to notice unassessed patients; expand disease management skill in a variety of settings; and promote harm reduction services[16].

Moreover, if major price reduction achieved by the HIV/AIDS community can be applied to HCV, a similar success story could emerge[17]. Domestic program and funding are continually implemented in many middle-income areas to support large scale DAA treatment, intended to achieve the WHO HCV elimination objective. However, investments required to achieve the WHO related elimination targets are insufficient given the feeble contribution from domestic financing sources and weakness of international funding for HCV programs. In fact, Unitaid partnership is starting with some countries to simplify and decentralize HCV CoC for a large scale feasibility. This donor is even encouraging coordination among other partners working in the field to support the Global Hepatitis Program for better response[18]. Models of service delivery are being piloted and implemented throughout the Western Pacific Region, which will support "learning by doing," in the delivery of hepatitis testing, care and treatment tailored to countries' unique health contexts[19].

Malaysia launched universal coverage of free testing and treatment for HCV in March 2018, with rapid expansion of services to decentralize testing and treatment in primary care clinics in 2019. In Vietnam, pilot programs are in progress to assess the feasibility of decentralizing HCV testing using point-of-care diagnostics to screen in different settings. In China, the entry of DAAs into the market changed conversations on the possibility of eliminating HCV and improving large-scale access to treatment. Many high-income countries in the Asian region universally covered hepatitis testing, care and treatment through government financing and health insurance.

However, challenges remain regarding vulnerable populations, including persons who inject drugs, incarcerated populations, migrants and indigenous people. These challenges involve increasing testing access and connection to care after diagnosis, improving public awareness of hepatitis B and C, training health care providers, particularly at the primary care level and addressing stigma and discrimination.

Medicines (DAAs) have revolutionized treatment for HCV, and they are becoming available in many LMICs, even if the cost can barely be borne by patients in a large majority of these countries. The market for generics has developed quickly but is volatile due to fluctuations in demand combined with inconsistent and insufficient financing. In the Asian region, affordability has improved as generic medicines have become more widely available. In countries where medicine prices remain high, access is limited by rationing and cost containment. On the other hand, where cheaper generics are available, financing and affordability by those most affected by HCV can still be a major barrier to access.

Out-of-pocket expenses vary widely across the Asian region and are still a significant barrier to access. There are significant differences in how countries control the prices of medicines, ranging from free pricing to single-payer, controlled pricing arrangements. Countries with single-payer systems achieved significant price controls for the new DAAs by using their monopoly purchasing power. For example, the Australian Department of Health negotiated a 5-year volume-based price deal based on treating 62000 people for AUS$ 1 billion. Over 38000 people were treated in the 1st year. This innovative approach removed price as a barrier to treatment. In New Zealand, the advantage of the Pharmaceutical Management Agency helps to secure favorable prices for medicines in negotiations with suppliers. Similar purchasing strategies could be used in other countries where medicines are financed by the government. Greater sharing of information on prices and negotiation strategies across the region is important to improve access to expensive medicines.

Another option for accessing affordable hepatitis medicine has been to take advantage of a commercial agreement related to intellectual property rights *a fortiori* in LMICs[19]. As far as HCV CoC is concerned, interesting and successful decentralized public health programs and government support have been tested in Africa (Rwanda, for instance) and Asia[20]. Moreover, Rwanda and Egypt have incredibly developed their national HCV programs in line with the WHO elimination targets, as reported by Shah *et al*[21]. However, to reach the above targets, the sub-Saharan African region must still overcome several barriers. Important investments and political engagement are needed to overcome these challenges[21]. From the period of 2014-2020, Egypt undertook a vast campaign of HCV screening and treatment in line with the disease elimination purpose. In fact, more than 50 million residents were screened for chronic HCV (4 million were treated). The key successful elements were as follow: Reliable epidemiological surveillance; robust public health system; inclusive care open to all social sectors; increased health care spending; and innovative research and use of new technologies of communication. Egypt is suggested to be the first country to eliminate HCV out of its territory. This expertise can be useful for other LMICs with high HCV burdens[22].

As far as the WHO HCV elimination goal is concerned, Mali has included viral hepatitis in the category of priority diseases through the promulgation of Law No. 2019-021 of July 3, 2019, which creates the sectorial unit to fight HIV/AIDS, tuberculosis and viral hepatitis and takes these diseases into account in the 10-year social health development plan 2014-2023. In this country, despite the political will that has been shown, there are still difficulties such as low level of knowledge of health workers on viral hepatitis, insufficient human resources, infrastructure and reagents for the management of viral hepatitis and financial and geographic (for the patients who reside outside Bamako) inaccessibility to antivirals[23]. The care centers for HCV patients, mainly made up of hepatogastroenterology, infectious diseases and internal medicine departments, are concentrated in Bamako (the capital of Mali). DAA medicines such as sofosbuvir in combination with ledipasvir or velpatasvir, which are not provided in management centers, are sold at a high price in private pharmacies. These drugs are not covered by governmental compulsory health insurance. Other factors limiting access to treatment are the high costs of pretreatment investigations (170000 XOF by patient for HCV)[23].

The next key steps to strengthen interventions include: Sustaining efforts to reach major cost reduction of HCV management (for instance promotion of both generic DAAs and diagnosis tests) in all countries at a level comparable to HIV pricing; recording potential generic drug manufacturers at the country level; improving domestic and donor funding; reinforcing of monitoring and evaluation system by using digital tools to tract patients and manage stock; integrating programs such as HIV and sexually transmitted diseases, harm reducing service, primary health care and reproductive health; decentralizing and task delegation service; and further community engagement. Furthermore, early management of disease is important because it is cheaper to treat HCV early than treat complications *a fortiori* in LMICs where resources are scarce[20].

Pediatric patients with liver fibrosis evidence must be regularly monitored given the constant risk of portal hypertension and hepatocellular carcinoma occurrence. Early treatment can save money and lives. Furthermore, the actions taken to improve access to health care in certain disadvantaged regions of high-income countries, as seen in the Appalachian region, can be usefully employed in low-income countries.

ACKNOWLEDGEMENTS

We warmly thank the Department of Hepatogastroenterology of CHULiege for its generous contribution to the fee for editing the language of our manuscript.

FOOTNOTES

Author contributions: Bouare N and Delwaide J contributed by designing, drafting and reviewing the manuscript; Keita M contributed by reviewing the manuscript; All authors reviewed, read and approved the final version of the manuscript.

Conflict-of-interest statement: The authors declare no conflicts of interest.

Country/Territory of origin: Mali

ORCID number: Nouhoum Bouare 0000-0002-8362-6740; Mamadou Keita 0000-0001-5572-8996; Jean Delwaide 0000-0001-7894-8123.

S-Editor: Fan JR
L-Editor: Filipodia
P-Editor: Fan JR

REFERENCES

1 **Rogers ME**, Balistreri WF. Cascade of care for children and adolescents with chronic hepatitis C. *World J Gastroenterol* 2021; **27**: 1117-1131 [PMID: 33828389 DOI: 10.3748/wjg.v27.i12.1117]

2 **Web Annex C**. Estimates of the coverage of diagnosis. [cited 10 August 2021]. Available from: https://apps.who.int›iris›bitstream›handle

3 **Basyte-Bacevice V**, Kupcinskas J. Evolution and Revolution of Hepatitis C Management: From Non-A, Non-B Hepatitis Toward Global Elimination. *Dig Dis* 2020; 1-6 [PMID: 31905358 DOI: 10.1159/000505434]

4 **Global Cascade of Care for HBV and HCV**. On behalf of the Polaris Observatory Collaborators June 16, 2018. [cited 10 August 2021]. Available from: https://cdafound.org/content/hepsummit/Razavi

5 **Brouard C**, Pillonel J, Boussac M, de Lédinghen V, Rachas A, Silvain C, Lydié N, Chevaliez S, Pioche C, Durand J, Lot F, Delarocque-Astagneau E. French hepatitis C care cascade: substantial impact of direct-acting antivirals, but the road to elimination is still long. *BMC Infect Dis* 2020; **20**: 759 [PMID: 33059617 DOI: 10.1186/s12879-020-05478-6]

6 **Balakrishnan M**, Kanwal F. The HCV Treatment Cascade: Race Is a Factor to Consider. *J Gen Intern Med* 2019; **34**: 1949-1951 [PMID: 31342332 DOI: 10.1007/s11606-019-04962-3]

7 **Mboumba Bouassa RS**, Nodjikouambaye ZA, Sadjoli D, Moussa AM, Adawaye C, Koyalta D, Bélec L. Usefulness of Simultaneous Screening for HIV- and Hepatitis C-Specific Antibodies and Hepatitis B Surface Antigen by Capillary-Based Multiplex Immunochromatographic Rapid Test to Strengthen Prevention Strategies and Linkage to Care in Childbearing-Aged Women Living in Resource-Limited Settings. *Open Forum Infect Dis* 2018; **5**: ofy069 [PMID: 29766018 DOI: 10.1093/ofid/ofy069]

8 **Burrell CN**, Sharon MJ, Davis SM, Wojcik EM, Martin IBK. Implementation of a Collaborative HIV and Hepatitis C Screening Program in Appalachian Urgent Care Settings. *West J Emerg Med* 2018; **19**: 1057-1064 [PMID: 30429942 DOI: 10.5811/westjem.2018.9.39512]

9 **Maier MM**, Ross DB, Chartier M, Belperio PS, Backus LI. Cascade of Care for Hepatitis C Virus Infection Within the US Veterans Health Administration. *Am J Public Health* 2016; **106**: 353-358 [PMID: 26562129 DOI: 10.2105/AJPH.2015.302927]

10 **Grebely J**, Hajarizadeh B, Lazarus JV, Bruneau J, Treloar C; International Network on Hepatitis in Substance Users. Elimination of hepatitis C virus infection among people who use drugs: Ensuring equitable access to prevention, treatment, and care for all. *Int J Drug Policy* 2019; **72**: 1-10 [PMID: 31345644 DOI: 10.1016/j.drugpo.2019.07.016]

11 **Mayor S**. BMJ Awards: nominations open with seven new categories for 2019. *BMJ* 2018; **363**: k4434 [PMID: 30341063 DOI: 10.1136/bmj.k4434]

12 **Hariri S**, Sharafi H, Sheikh M, Merat S, Hashemi F, Azimian F, Tamadoni B, Ramazani R, Gouya MM, Abbasi B, Tashakorian M, Alasvand R, Alavian SM, Poustchi H, Malekzadeh R. Continuum of hepatitis C care cascade in prison and following release in the direct-acting antivirals era. *Harm Reduct J* 2020; **17**: 80 [PMID: 33081794 DOI: 10.1186/s12954-020-00431-x]

13 **Lazarus JV**, Pericàs JM, Picchio C, Cernosa J, Hoekstra M, Luhmann N, Maticic M, Read P, Robinson EM, Dillon JF. We know DAAs work, so now what? *J Intern Med* 2019; **286**: 503-525 [PMID: 31472002 DOI: 10.1111/joim.12972]

14 **Zuckerman A**, Douglas A, Nwosu S, Choi L, Chastain C. Increasing success and evolving barriers in the hepatitis C cascade of care during the direct acting antiviral era. *PLoS One* 2018; **13**: e0199174 [PMID: 29912944 DOI: 10.1371/journal.pone.0199174]

15 **Linas BP**, Barter DM, Leff JA, Assoumou SA, Salomon JA, Weinstein MC, Kim AY, Schackman BR. The hepatitis C cascade of care: identifying priorities to improve clinical outcomes. *PLoS One* 2014; **9**: e97317 [PMID: 24842841 DOI: 10.1371/journal.pone.0097317]

16 **CATIE News, 2019**. Progress made in the hepatitis C virus cascade of care but more work lies ahead in B.C. [cited 10 August 2021]. Available from: https://www.catie.ca/en/catienews?page=3

17 **Suthar AB**, Harries AD. A public health approach to hepatitis C control in low- and middle-income countries. *PLoS Med* 2015; **12**: e1001795 [PMID: 25757228 DOI: 10.1371/journal.pmed.1001795]

18 **Unitaid Innovation in Global Health**. Impact story: Paving the way to hepatitis C elimination. [cited 10 August 2021]. Available from: https://unitaid.org/assets/Impact-story-paving-the-way-to-hepatitis-c-elimination.pdf

19 **WHO**. Implementation progress of the regional action plan for viral hepatitis in the Western Pacific 2016-2020. Priority Area 5: An accessible and effective treatment cascade. [cited 10 August 2021]. Available from: https://www.who.int›hepatitis›pri

20 **Boeke CE**, Adesigbin C, Agwuocha C, Anartati A, Aung HT, Aung KS, Grover GS, Ngo D, Okamoto E, Ngwije A, Nsanzimana S, Sindhwani S, Singh G, Sun LP, Kinh NV, Waworuntu W, McClure C. Initial success from a public health approach to hepatitis C testing, treatment and cure in seven countries: the road to elimination. *BMJ Glob Health* 2020; **5** [PMID: 33328200 DOI: 10.1136/bmjgh-2020-003767]

21 **Shah R**, Agyei-Nkansah A, Alikah F, Asamoah-Akuoko L, Bagou YCO, Dhiblawe A, Ehichioya D, Finch PJ, Katsidzira L, Kodjoh N, Kpossou RA, Lakoh S, Makuza JD, Marowa L, Ndububa DA, Mbendi CN, Nyirenda M, Ocama P, Opio CK, Seremba E, Shindano TA, Thomson EC; Hepatitis C Virus sub-Saharan Africa Network. Hepatitis C virus in sub-Saharan Africa: a long road to elimination. *Lancet Gastroenterol Hepatol* 2021; **6**: 693-694 [PMID: 34391525 DOI: 10.1016/S2468-1253(21)00224-7]

22 **Hassanin A**, Kamel S, Waked I, Fort M. Egypt's Ambitious Strategy to Eliminate Hepatitis C Virus: A Case Study. *Glob Health Sci Pract* 2021; **9**: 187-200 [PMID: 33795369 DOI: 10.9745/GHSP-D-20-00234]

23 **Mali MSAS/CSLS-TBH/OMS**. Analyse de situation des hépatites virales au Mali VF Avril 2020. [cited 10 August 2021]. Ministère de la santé_Cellule sectorielle de lutte contre le VIH/SIDA, La tuberculose et les hepatites virales

World Journal of Gastroenterology

Submit a Manuscript: https://www.f6publishing.com

World J Gastroenterol 2022 April 14; 28(14): 1499-1502

DOI: 10.3748/wjg.v28.i14.1499

ISSN 1007-9327 (print) ISSN 2219-2840 (online)

LETTER TO THE EDITOR

Comments on "Effect of type 2 diabetes mellitus in the prognosis of acute-on-chronic liver failure patients in China"

Wei Wang, Chen-Chen Pan, Wen-Ying Zhao, Jin-Yu Sheng, Qi-Qi Wu, Si-Si Chen

Specialty type: Gastroenterology and hepatology

Provenance and peer review: Unsolicited article; Externally peer reviewed.

Peer-review model: Single blind

Peer-review report's scientific quality classification

Grade A (Excellent): 0
Grade B (Very good): 0
Grade C (Good): 0
Grade D (Fair): D
Grade E (Poor): E

P-Reviewer: Javed N, Pakistan; Saha S, India

Received: October 20, 2021
Peer-review started: October 20, 2021
First decision: December 27, 2021
Revised: January 13, 2022
Accepted: March 16, 2022
Article in press: March 16, 2022
Published online: April 14, 2022

Wei Wang, Department of Interventional Oncology, Taizhou Municipal Hospital, Taizhou 318000, Zhejiang Province, China

Chen-Chen Pan, Wen-Ying Zhao, Jin-Yu Sheng, Qi-Qi Wu, School of Medicine Taizhou University, Taizhou 318000, Zhejiang Province, China

Si-Si Chen, Department of Obstetrics and Gynecology, Taizhou Women and Children's Hospital of Wenzhou Medical University, Taizhou 318000, Zhejiang Province, China

Corresponding author: Si-Si Chen, MD, Occupational Physician, Department of Obstetrics and Gynecology, Taizhou Women and Children's Hospital of Wenzhou Medical University, No. 188 Qianjin Village, Jiajia Street, Jiaojiang District, Taizhou 318000, Zhejiang Province, China. chensisiobstetrics@126.com

Abstract

A study addressing the influence of type 2 diabetes on the prognosis of acute-on-chronic liver failure patients was reviewed. Some statistical deficiencies were found in the reviewed article, and the sample size was too small to support the study. In addition, age should have been considered as one of the prognostic factors.

Key Words: Type 2 diabetes mellitus; Liver failure; Complication; Prognosis; Age

Core Tip: This is a comment on a study of the influence of type 2 diabetes on the prognosis of patients with acute-on-chronic liver failure. We believe that the conclusion of this study can provide more significant data.

Citation: Wang W, Pan CC, Zhao WY, Sheng JY, Wu QQ, Chen SS. Comments on "Effect of type 2 diabetes mellitus in the prognosis of acute-on-chronic liver failure patients in China". *World J Gastroenterol* 2022; 28(14): 1499-1502
URL: https://www.wjgnet.com/1007-9327/full/v28/i14/1499.htm
DOI: https://dx.doi.org/10.3748/wjg.v28.i14.1499

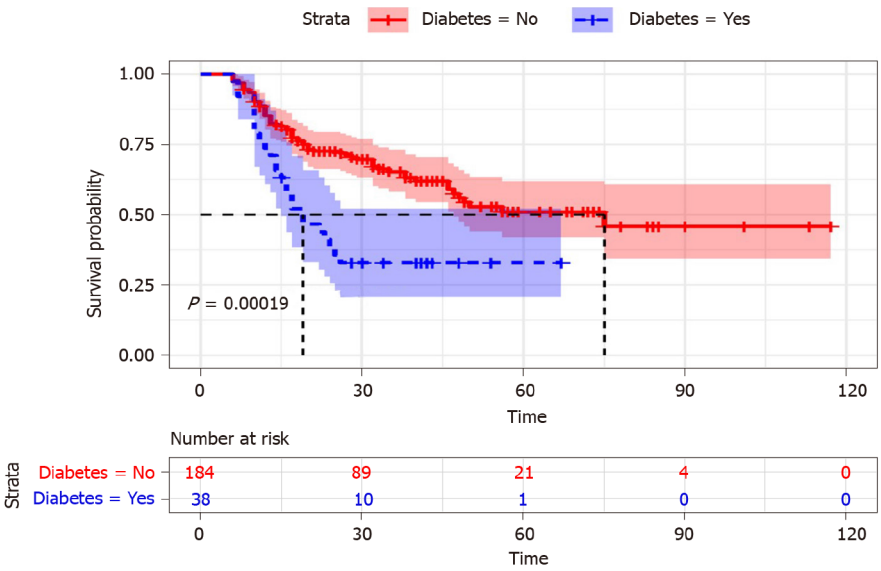

Figure 1 Cumulative survival time in acute-on-chronic liver failure patients with diabetic mellitus and non-diabetic mellitus[1]. Citation: Lai RM, Chen TB, Hu YH, Wu G, Zheng Q. Effect of type 2 diabetic mellitus in the prognosis of acute-on-chronic liver failure patients in China. *World J Gastroenterol* 2021; 27: 3372-3385. Copyright© The Authors 2020. Published by Baishideng Publishing Group Inc.

TO THE EDITOR

We were pleased to read the high-level article published by Lai *et al*[1]. The results of their study showed a significant relationship between the prognosis of diabetes mellitus (DM) and acute-on-chronic liver failure (ACLF) patients. ACLF patients with DM have higher in-hospital mortality and infection rates than patients without DM. This is an important study that has made a significant contribution to the study of prognostic indicators for ACLF patients. However, there are still questionable issues in this study that we would like to discuss with the authors.

First, the Materials and Methods section needs to be more detailed and refined. The author should list the number of diabetic patients included and the number of people after grouping. The author should state the time for follow-up of the patients and redefine the concept of follow-up. If the author regards the discharge time as the end of the follow-up event, it may cause data loss. Therefore, another reference could be added for loss to follow-up. We notice that they performed multivariate analysis on parameters with $P < 0.1$ in univariate analysis, which is not convincing. A P value less than 0.05 would make the results more convincing. In addition, a sample of 200 for a study period of 7 years is small; the author should calculate the population size and analyze the sample size.

There are problems in the statistical analyses. Statistical analyses should be described in detail. In the table in the Results section, the author should provide more accurate statistical values, such as Student's t-values or χ^2 values. Table 1 shows that there are statistical differences in age between the DM group and non-DM group. Therefore, the author should describe the frequency and distribution of age in more detail and discuss the possible impact of age as a potential risk factor on the disease. For example, the author could divide the patients into different levels in the DM and non-DM groups according to age and statistically analyze the impact of different ages in each level on the mortality and infection rate of related diseases. According to the criteria of the World Health Organization in 2012[1,2], a younger age was defined as less than 45 years, and an older age was defined as greater or equal to 45 years. Therefore, the author could divide the original two groups into four groups. In Figure 1 (Figure in the manuscript "Effect of type 2 diabetes mellitus in the prognosis of acute-on-chronic liver failure patients in China"[1]), the author should indicate the time unit. We do not know how long the patients lived. In addition, we also noticed that the author did not indicate the corresponding P value when stating some conclusions.

In the paper, the author repeatedly proposed that DM could predict ACLF. This is a confusing statement. The study only proves that DM has a certain influence on ACLF. To further predict ACLF through DM, a survival model would need to be established. The author should provide more detailed data, such as median follow-up and survival times, to build up the survival model.

In the Discussion section, the author explained that albumin (ALB) has nothing to do with the prognosis of liver failure in this study and believed that exogenous injection of ALB interfered with the experimental results. Inferring from this, we believe that the author neglected interference caused by the patients' medications on the experimental results during treatment. ALB constitutes about half of serum proteins. ALB is involved in scavenging free radicals, maintaining colloidal osmotic pressure and protecting neuronal cells and is closely related to nutritional level[3] and systemic inflammatory

Table 1 Demographic characteristics and clinical features of the patients between diabetic mellitus and non-diabetic mellitus[1]

	DM (yes) (*n* = 38)	DM (no) (*n* = 184)	*P* value
Age (yr)	56.32 ± 14.23	49.16 ± 12.84	0.002
Gender, *n* (%)			0.309
Male	28 (73.68)	149 (80.98)	
Female	10 (26.32)	35 (19.02)	
Cause of disease, *n* (%)			0.201
Hepatitis B virus	26 (68.42)	139 (75.54)	
Hepatitis B virus + other	5 (13.16)	20 (10.87)	
Alcohol	2 (5.26)	15 (8.15)	
Others	5 (13.16)	10 (5.44)	
WBC (10^9/L)	6.17 ± 4.03	7.35 ± 3.58	0.07
RBC (10^{12}/L)	3.68 ± 0.87	3.94 ± 0.84	0.084
Hb (g/L)	117.21 ± 24.71	121.95 ± 23.13	0.257
PLT (10^9/L)	100.34 ± 42.20	118.79 ± 59.09	0.069
PT (s)	23.01 ± 5.38	24.45 ± 6.95	0.229
INR	1.97 ± 0.45	2.10 ± 0.59	0.229
ALT (U/L)	396.08 ± 448.56	560.36 ± 693.06	0.163
AST (U/L)	365.95 ± 391.18	419.99 ± 513.42	0.541
γ-GGT (U/L)	174.16 ± 305.61	137.57 ± 127.33	0.231
TBIL (μmol/L)	320.71 ± 141.31	309.56 ± 134.00	0.664
ALB (g/L)	29.25 ± 4.51	30.73 ± 4.03	0.045
Scr (μmol/L)	56.37 ± 22.00	63.45 ± 27.28	0.134
BUN (mmol/L)	3.94 ± 2.65	4.25 ± 2.98	0.56
TCHO (mmol/L)	2.67 ± 0.81	2.65 ± 1.05	0.919
TG (mmol/L)	1.45 ± 0.67	1.26 ± 0.70	0.124
Na^+ (mmol/L)	136.98 ± 3.97	136.86 ± 4.43	0.878
K^+ (mmol/L)	3.90 ± 0.46	4.08 ± 0.58	0.072
AMON (μmol/L)	3.90 ± 0.46	4.08 ± 0.58	0.332
AFP (ng/mL)	64.40 ± 40.39	128.19 ± 192.02	0.784
BMI (kg/m^2)	24.99 ± 3.32	22.78 ± 3.03	< 0.001
FBG (mmol/L)	5.34 ± 1.87	3.83 ± 1.07	< 0.001
Scoring systems			
CTP	10.79 ± 1.49	10.40 ± 1.35	0.115
MELD	19.38 ± 4.52	20.74 ± 5.06	0.128
MELD-Na	20.89 ± 5.00	22.27 ± 6.84	0.239
Death, *n* (%)	25 (65.79)	69 (37.5)	0.001

γ-GGT: Gamma-glutamyl transpeptidase; AFP: Alpha fetal protein; ALB: Albumin; ALT: Alanine aminotransferase; AMON: Ammonia; AST: Aspartate aminotransferase; BMI: Body mass index; BUN: Blood urea nitrogen; CTP: Child-Turcotte-Pugh; DM: Diabetic mellitus; FBG: Fasting blood-glucose; Hb: Hemoglobin; INR: International normalized ratio; K+: Kalium; MELD: Model for End-Stage Liver Disease; MELD-Na: Model for End-Stage Liver Disease with serum sodium; Na+: Natrium ion; PLT: Platelet count; PT: Prothrombin time; Scr: Serum creatinine; TBIL: Total bilirubin; TCHO: Total cholesterol; TG: Triglyceride; RBC: Red blood cell; WBC: White blood cell. Citation: **Lai RM**, Chen TB, Hu YH, Wu G, Zheng Q. Effect of type 2 diabetic mellitus in the prognosis of acute-on-chronic liver failure patients in China. *World J Gastroenterol* 2021; **27**: 3372-3385. Copyright© The Authors 2020. Published by Baishideng Publishing Group Inc.

response[4]. The author should describe in detail in the Methods section the type, dosage and method of drug injection during the treatment process. Actually, well-established indications for the use of human ALB in patients with cirrhosis pertain to conditions that are characterized by an acute deterioration of effective hypovolemia[5], such as renal dysfunction secondary to spontaneous bacterial peritonitis and hepatorenal syndrome, as shown by the international guidelines on the management of decompensated cirrhosis[6]. The current established indications for ALB use in patients with cirrhosis, such as preventing renal dysfunction induced by systolic blood pressure, suggest that patients should receive 1.5 g/kg body weight at diagnosis +1 g/kg body weight at day 3[7].

All in all, this is a high-level article in the field of diabetes and liver cirrhosis. Although there are some statistical deficiencies in the article, the author may be able to expand the sample and establish a multicenter prospective cohort study. For example, age factors could be considered for related diseases to evaluate the impact of DM on the prognosis in ACLF patients.

FOOTNOTES

Author contributions: Wang W and Chen SS contributed equally to this work; Wang W, Chen SS, Pan CC, Zhao WY, Sheng JY and Wu QQ designed the research study; Wang W, Chen SS, Pan CC and Zhao WY performed the research; Wang W and Chen SS contributed to new reagents and analytic tools; Wang W, Pan CC and Zhao WY analyzed the data and wrote the manuscript; All authors have read and approve the final manuscript.

Conflict-of-interest statement: Each author has reviewed the statement by the Baishideng Publishing Group on conflict of interest, and every author stated that there is no conflict of interest.

Country/Territory of origin: China

ORCID number: Wei Wang 0000-0001-5630-3287; Chen-Chen Pan 0000-0001-8234-6870; Wen-Ying Zhao 0000-0002-8190-2561; Jin-Yu Sheng 0000-0002-6132-4637; Qi-Qi Wu 0000-0002-4997-1022; Si-Si Chen 0000-0003-0125-8022.

S-Editor: Fan JR
L-Editor: Filipodia
P-Editor: Fan JR

REFERENCES

1 **Lai RM**, Chen TB, Hu YH, Wu G, Zheng Q. Effect of type 2 diabetic mellitus in the prognosis of acute-on-chronic liver failure patients in China. *World J Gastroenterol* 2021; **27**: 3372-3385 [PMID: 34163118 DOI: 10.3748/wjg.v27.i23.3372]
2 **D'Angio RG**. Is there a role for albumin administration in nutrition support? *Ann Pharmacother* 1994; **28**: 478-482 [PMID: 8038474 DOI: 10.1177/106002809402800411]
3 **Zaccherini G**, Bernardi M. The role and indications of albumin in advanced liver disease. *Acta Gastroenterol Belg* 2019; **82**: 301-308 [PMID: 31314192]
4 **Garcia-Martinez R**, Caraceni P, Bernardi M, Gines P, Arroyo V, Jalan R. Albumin: pathophysiologic basis of its role in the treatment of cirrhosis and its complications. *Hepatology* 2013; **58**: 1836-1846 [PMID: 23423799 DOI: 10.1002/hep.26338]
5 **European Association for the Study of the Liver**. EASL Clinical Practice Guidelines for the management of patients with decompensated cirrhosis. *J Hepatol* 2018; **69**: 406-460 [PMID: 29653741 DOI: 10.1016/j.jhep.2018.03.024]
6 **Margarson MP**, Soni N. Serum albumin: touchstone or totem? *Anaesthesia* 1998; **53**: 789-803 [PMID: 9797524 DOI: 10.1046/j.1365-2044.1998.00438.x]
7 World Health Day 2012 focuses on ageing and health. *East Mediterr Health J* 2012; **18**: 303 [PMID: 22768689]

Published by **Baishideng Publishing Group Inc**
7041 Koll Center Parkway, Suite 160, Pleasanton, CA 94566, USA
Telephone: +1-925-3991568
E-mail: bpgoffice@wjgnet.com
Help Desk: https://www.f6publishing.com/helpdesk
https://www.wjgnet.com