ISSN 1007-9327
CN 14-1219/R

World Journal of Gastroenterology®

Indexed and Abstracted in:

Current Contents®/Clinical Medicine, Science Citation Index Expanded (also known as SciSearch®) and Journal Citation Reports/Science Edition, *Index Medicus*, MEDLINE and PubMed, Chemical Abstracts, EMBASE/Excerpta Medica, Abstracts Journals, *Nature Clinical Practice Gastroenterology and Hepatology*, CAB Abstracts and Global Health.
ISI JCR 2003-2000 IF: 3.318, 2.532, 1.445 and 0.993.

Volume 14 Number 32
August 28, 2008
World J Gastroenterol
2008 August 28; 14(32): 4977-5104

Online Submissions
wjg.wjgnet.com
www.wjgnet.com
Printed on Acid-free Paper
世界胃肠病学杂志

A Weekly Journal of Gastroenterology and Hepatology

World Journal of Gastroenterology®

Editorial Board

2007-2009

Published by The WJG Press and Baishideng
Room 903, Ocean International Center, Building D
No. 62 Dongsihuan Zhonglu, Chaoyang District, Beijing 100025, China
Fax: +86-10-8538-1893 E-mail: wjg@wjgnet.com http://www.wjgnet.com

The World Journal of Gastroenterology Editorial Board consists of 1208 members, representing a team of worldwide experts in gastroenterology and hepatology. They are from 60 countries, including Albania (1), Argentina (4), Australia (39), Austria (10), Belarus (1), Belgium (15), Brazil (2), Bulgaria (1), Canada (28), Chile (1), China (60), Croatia (2), Cuba (1), Czech (2), Denmark (7), Egypt (4), Estonia (1), Finland (4), France (44), Germany (108), Greece (9), Hungary (2), Iceland (1), India (12), Iran (3), Ireland (4), Israel (8), Italy (96), Japan (176), Lebanon (3), Lithuania (1), Macedonia (1), Malaysia (3), Mexico (6), Monaco (1), Morocco (1), The Netherlands (26), New Zealand (1), Nigeria (1), Norway (3), Pakistan (2), Peru (1), Poland (6), Portugal (1), Russia (3), Saudi Arabia (2), Serbia (1), Singapore (4), Slovakia (2), Slovenia (1), South Africa (2), South Korea (14), Spain (38), Sweden (15), Switzerland (13), Turkey (8), United Arab Emirates (1), United Kingdom (83), United States (316) and Uruguay (2).

HONORARY EDITORS-IN-CHIEF

Montgomery Bissell, *San Francisco*
James L Boyer, *New Haven*
Chao-Long Chen, *Kaohsiung*
Ke-Ji Chen, *Beijing*
Li-Fang Chou, *Taipei*
Jacques V Dam, *Stanford*
Martin H Floch, *New Haven*
Guadalupe Garcia-Tsao, *New Haven*
Zhi-Qiang Huang, *Beijing*
Shinn-Jang Hwang, *Taipei*
Ira M Jacobson, *New York*
Derek Jewell, *Oxford*
Emmet B Keeffe, *Palo Alto*
Min-Liang Kuo, *Taipei*
Nicholas F LaRusso, *Rochester*
Jie-Shou Li, *Nanjing*
Geng-Tao Liu, *Beijing*
Lein-Ray Mo, *Tainan*
Bo-Rong Pan, *Xi'an*
Fa-Zu Qiu, *Wuhan*
Eamonn M Quigley, *Cork*
David S Rampton, *London*
Rafiq A Sheikh, *Sacramento*
Rudi Schmid, *Kentfield*[1]
Nicholas J Talley, *Rochester*
Sun-Lung Tsai, *Young-Kang City*
Guido NJ Tytgat, *Amsterdam*
Hsiu-Po Wang, *Taipei*
Jaw-Ching Wu, *Taipei*
Meng-Chao Wu, *Shanghai*
Ming-Shiang Wu, *Taipei*
Jia-Yu Xu, *Shanghai*
Ta-Sen Yeh, *Taoyuan*
Ming-Lung Yu, *Kaohsiung*

PRESIDENT AND EDITOR-IN-CHIEF

Lian-Sheng Ma, *Beijing*

STRATEGY ASSOCIATE EDITORS-IN-CHIEF

Peter Draganov, *Florida*
Ronnie Fass, *Tucson*
Hugh J Freeman, *Vancouver*
John P Geibel, *New Haven*
Maria Concepción Gutiérrez-Ruiz, *México*
Kazuhiro Hanazaki, *Kochi*
Akio Inui, *Kagoshima*
Kalpesh Jani, *Vadodara*
Sanaa M Kamal, *Cairo*
Ioannis E Koutroubakis, *Heraklion*
Jose JG Marin, *Salamanca*
Javier S Martin, *Punta del Este*
Natalia A Osna, *Omaha*
Jose Sahel, *Marseille*
Ned Snyder, *Galveston*
Nathan Subramaniam, *Brisbane*
Wei Tang, *Tokyo*
Alan BR Thomson, *Edmonton*
Paul Joseph Thuluvath, *Baltimore*
James F Trotter, *Denver*
Shingo Tsuji, *Osaka*
Harry HX Xia, *Hanover*
Yoshio Yamaoka, *Houston*
Jesue K Yamamoto-Furusho, *México*

ASSOCIATE EDITORS-IN-CHIEF

Gianfranco D Alpini, *Temple*
Bruno Annibale, *Roma*
Roger W Chapman, *Oxford*
Chi-Hin Cho, *Hong Kong*
Alexander L Gerbes, *Munich*
Shou-Dong Lee, *Taipei*
Walter E Longo, *New Haven*
You-Yong Lu, *Beijing*
Masao Omata, *Tokyo*

BIOSTATISTICAL EDITOR

Liang-Ping Hu, *Beijing*

MEMBERS OF THE EDITORIAL BOARD

Albania

Bashkim Resuli, *Tirana*

Argentina

Julio H Carri, *Córdoba*
Carlos J Pirola, *Buenos Aires*
Silvia Sookoian, *Buenos Aires*
Adriana M Torres, *Rosario*

Australia

Leon Anton Adams, *Nedlands*
Minoti V Apte, *Liverpool*
Richard B Banati, *Lidcombe*
Michael R Beard, *Adelaide*
Patrick Bertolino, *Sydney*

Andrew V Biankin, *Sydney*
Filip Braet, *Sydney*
Andrew D Clouston, *Sydney*
Graham Cooksley, *Queensland*
Darrell HG Crawford, *Brisbane*
Adrian G Cummins, *Woodville South*
Guy D Eslick, *Sydney*
Michael A Fink, *Melbourne*
Robert JL Fraser, *Daw Park*
Peter Raymond Gibson, *Victoria*
Jacob George, *Westmead*
Mark D Gorrell, *Sydney*
Yik-Hong Ho, *Townsville*
Gerald J Holtmann, *Adelaide*
Michael Horowitz, *Adelaide*
John E Kellow, *Sydney*
Rupert Leong, *Concord*
Geoffrey W McCaughan, *Sydney*
Finlay A Macrae, *Victoria*
Daniel Markovich, *Brisbane*
Phillip S Oates, *Perth*
Jacqui Richmond, *Victoria*
Stephen M Riordan, *Sydney*
Ian C Roberts-Thomson, *Adelaide*
Devanshi Seth, *Camperdown*
Arthur Shulkes, *Melbourne*
Ross C Smith, *Sydney*
Kevin J Spring, *Brisbane*
Huy A Tran, *New South Wales*
Debbie Trinder, *Fremantle*
Martin J Veysey, *Gosford*
Daniel L Worthley, *Bedford*

Austria

Peter Ferenci, *Vienna*
Valentin Fuhrmann, *Vienna*
Alfred Gangl, *Vienna*
Christoph Gasche, *Vienna*
Kurt Lenz, *Linz*
Markus Peck-Radosavljevic, *Vienna*
Rudolf E Stauber, *Auenbruggerplatz*
Herbert Tilg, *Innsbruck*
Michael Trauner, *Graz*
Harald Vogelsang, *Vienna*
Guenter Weiss, *Innsbruck*

Belarus

Yury K Marakhouski, *Minsk*

Belgium

Rudi Beyaert, *Gent*
Bart Rik De Geest, *Leuven*
Inge I Depoortere, *Leuven*
Olivier Detry, *Liège*
Benedicte Y De Winter, *Antwerp*
Karel Geboes, *Leuven*
Thierry Gustot, *Brussels*
Yves J Horsmans, *Brussels*
Geert G Leroux-Roels, *Ghent*
Louis Libbrecht, *Leuven*
Etienne M Sokal, *Brussels*
Marc Peeters, *De Pintelaan*
Gert A Van Assche, *Leuven*
Yvan Vandenplas, *Brussels*
Eddie Wisse, *Keerbergen*

Brazil

Heitor Rosa, *Goiania*
Ana Cristina Simões e Silva, *Belo Horizonte*

Bulgaria

Zahariy Krastev, *Sofia*

Canada

Fernando Alvarez, *Québec*
David Armstrong, *Ontario*
Jeffrey P Baker, *Toronto*
Olivier Barbier, *Québec*
Nancy Baxter, *Toronto*
Matthew Bjerknes, *Toronto*
Frank J Burczynski, *Manitoba*
Michael F Byrne, *Vancouver*
Wang-Xue Chen, *Ottawa*
Chantal Guillemette, *Québec*
Samuel S Lee, *Calgary*
Gary A Levy, *Toronto*
Andrew L Mason, *Alberta*
John K Marshall, *Ontario*
Donna-Marie McCafferty, *Calgary*
Thomas I Michalak, *St. John's*
Gerald Y Minuk, *Manitoba*
Paul Moayyedi, *Hamilton*
Kostas Pantopoulos, *Québec*
William G Paterson, *Kingston*
Eldon Shaffer, *Calgary*
Morris Sherman, *Toronto*
Martin Storr, *Calgary*
Elena F Verdu, *Ontario*
John L Wallace, *Calgary*
Eric M Yoshida, *Vancouver*

Chile

Silvana Zanlungo, *Santiago*

China

Henry LY Chan, *Hongkong*
Xiao-Ping Chen, *Wuhan*
Zong-Jie Cui, *Beijing*
Da-Jun Deng, *Beijing*
Er-Dan Dong, *Beijing*
Sheung-Tat Fan, *Hong Kong*
Jin Gu, *Beijing*
Xin-Yuan Guan, *Pokfulam*
De-Wu Han, *Taiyuan*
Ming-Liang He, *Hong Kong*
Wayne HC Hu, *Hong Kong*
Chee-Kin Hui, *Hong Kong*
Ching-Lung Lai, *Hong Kong*
Kam Chuen Lai, *Hong Kong*
James YW Lau, *Hong Kong*
Yuk-Tong Lee, *Hong Kong*
Suet-Yi Leung, *Hong Kong*
Wai-Keung Leung, *Hong Kong*
John M Luk, *Pokfulam*
Chung-Mau Lo, *Hong Kong*
Jing-Yun Ma, *Beijing*
Ronnie Tung Ping Poon, *Hong Kong*
Lun-Xiu Qin, *Shanghai*
Yu-Gang Song, *Guangzhou*
Qin Su, *Beijing*
Wai-Man Wong, *Hong Kong*
Hong Xiao, *Shanghai*
Dong-Liang Yang, *Wuhan*
Winnie Yeo, *Hong Kong*
Yuan Yuan, *Shenyang*
Man-Fung Yuen, *Hong Kong*
Jian-Zhong Zhang, *Beijing*
Xin-Xin Zhang, *Shanghai*
Bo-Jian Zheng, *Hong Kong*
Shu Zheng, *Hangzhou*

Croatia

Tamara Cacev, *Zagreb*
Marko Duvnjak, *Zagreb*

Cuba

Damian C Rodriguez, *Havana*

Czech

Milan Jirsa, *Praha*
Pavel Trunečka, *Prague*

Denmark

Peter Bytzer, *Copenhagen*
Asbjørn M Drewes, *Aalborg*
Hans Gregersen, *Aalborg*
Jens H Henriksen, *Hvidovre*
Claus P Hovendal, *Odense*
Fin S Larsen, *Copenhagen*
Søren Møller, *Hvidovre*

Egypt

Abdel-Rahman El-Zayadi, *Giza*
Amr M Helmy, *Cairo*
Ayman Yosry, *Cairo*

Estonia

Riina Salupere, *Tartu*

Finland

Irma E Jarvela, *Helsinki*
Katri M Kaukinen, *Tampere*
Minna Nyström, *Helsinki*
Pentti Sipponen, *Espoo*

France

Bettaieb Ali, *Dijon*
Corlu Anne, *Rennes*
Denis Ardid, *Clermont-Ferrand*
Charles P Balabaud, *Bordeaux*
Soumeya Bekri, *Rouen*
Jacques Belghiti, *Clichy*
Jacques Bernuau, *Clichy Cedex*
Pierre Brissot, *Rennes*
Patrice P Cacoub, *Paris*
Franck Carbonnel, *Besancon*
Laurent Castera, *Pessac*
Bruno Clément, *Rennes*
Benoit Coffin, *Colombes*
Jacques Cosnes, *Paris*
Thomas Decaens, *Cedex*

Francoise L Fabiani, *Angers*
Gérard Feldmann, *Paris*
Jean Fioramonti, *Toulouse*
Jean-Noël Freund, *Strasbourg*
Jean-Paul Galmiche, *Nantes*
Catherine Guettier, *Villejuif*
Chantal Housset, *Paris*
Juan L Iovanna, *Marseille*
Rene Lambert, *Lyon*
Patrick Marcellin, *Paris*
Philippe Mathurin, *Lille*
Tamara Matysiak–Budnik, *Paris*
Francis Mégraud, *Bordeaux*
Richard Moreau, *Clichy*
Thierry Piche, *Nice*
Raoul Poupon, *Paris*
Jean Rosenbaum, *Bordeaux*
Dominique Marie Roulot, *Bobigny*
Thierry Poynard, *Paris*
Jean-Philippe Salier, *Rouen*
Didier Samuel, *Villejuif*
Jean-Yves Scoazec, *Lyon*
Khalid A Tazi, *Clichy*
Emmanuel Tiret, *Paris*
Baumert F Thomas, *Strasbourg*
Marie-Catherine Vozenin-brotons, *Villejuif*
Jean-Pierre H Zarski, *Grenoble*
Jessica Zucman-Rossi, *Paris*

Germany

Hans-Dieter Allescher, *G-Partenkirchen*
Martin Anlauf, *Kiel*
Rudolf Arnold, *Marburg*
Max G Bachem, *Ulm*
Thomas F Baumert, *Freiburg*
Daniel C Baumgart, *Berlin*
Hubert Blum, *Freiburg*
Thomas Bock, *Tuebingen*
Katja Breitkopf, *Mannheim*
Dunja Bruder, *Braunschweig*
Markus W Büchler, *Heidelberg*
Christa Buechler, *Regensburg*
Reinhard Buettner, *Bonn*
Elke Cario, *Essen*
Uta Dahmen, *Essen*
Christoph F Dietrich, *Bad Mergentheim*
Arno J Dormann, *Koeln*
Rainer J Duchmann, *Berlin*
Volker F Eckardt, *Wiesbaden*
Paul Enck, *Tuebingen*
Fred Fändrich, *Kiel*
Ulrich R Fölsch, *Kiel*
Helmut Friess, *Heidelberg*
Peter R Galle, *Mainz*
Nikolaus Gassler, *Aachen*
Andreas Geier, *Aachen*
Markus Gerhard, *Munich*
Wolfram H Gerlich, *Giessen*
Dieter Glebe, *Giessen*
Burkhard Göke, *Munich*
Florian Graepler, *Tuebingen*
Axel M Gressner, *Aachen*
Veit Gülberg, *Munich*
Rainer Haas, *Munich*
Eckhart G Hahn, *Erlangen*
Stephan Hellmig, *Kiel*
Martin Hennenberg, *Bonn*
Johannes Herkel, *Hamburg*
Klaus R Herrlinger, *Stuttgart*
Eva Herrmann, *Homburg/Saar*
Eberhard Hildt, *Berlin*
Joerg C Hoffmann, *Berlin*
Ferdinand Hofstaedter, *Regensburg*
Werner Hohenberger, *Erlangen*
Jörg C Kalff, *Bonn*
Ralf Jakobs, *Ludwigshafen*
Jutta Keller, *Hamburg*
Andrej Khandoga, *Munich*
Sibylle Koletzko, *München*
Stefan Kubicka, *Hannover*
Joachim Labenz, *Siegen*
Frank Lammert, *Bonn*
Thomas Langmann, *Regensburg*
Christian Liedtke, *Aachen*
Matthias Löhr, *Mannheim*
Christian Maaser, *Muenster*
Ahmed Madisch, *Dresden*
Peter Malfertheiner, *Magdeburg*
Michael P Manns, *Hannover*
Helmut Messmann, *Augsburg*
Stephan Miehlke, *Dresden*
Sabine Mihm, *Göttingen*
Silvio Nadalin, *Essen*
Markus F Neurath, *Mainz*
Johann Ockenga, *Berlin*
Florian Obermeier, *Regensburg*
Gustav Paumgartner, *Munich*
Ulrich KS Peitz, *Magdeburg*
Markus Reiser, *Bochum*
Emil C Reisinger, *Rostock*
Steffen Rickes, *Magdeburg*
Tilman Sauerbruch, *Bonn*
Dieter Saur, *Munich*
Hans Scherubl, *Berlin*
Joerg Schirra, *Munich*
Roland M Schmid, *München*
Volker Schmitz, *Bonn*
Andreas G Schreyer, *Regensburg*
Tobias Schroeder, *Essen*
Henning Schulze-Bergkamen, *Mainz*
Hans Seifert, *Oldenburg*
Norbert Senninger, *Muenster*
Manfred V Singer, *Mannheim*
Gisela Sparmann, *Rostock*
Christian J Steib, *München*
Jurgen M Stein, *Frankfurt*
Ulrike S Stein, *Berlin*
Manfred Stolte, *Bayreuth*
Christian P Strassburg, *Hannover*
Wolfgang R Stremmel, *Heidelberg*
Harald F Teutsch, *Ulm*
Robert Thimme, *Freiburg*
Hans L Tillmann, *Leipzig*
Tung-Yu Tsui, *Regensburg*
Axel Ulsenheimer, *Munich*
Patrick Veit-Haibach, *Essen*
Claudia Veltkamp, *Heidelberg*
Siegfried Wagner, *Deggendorf*
Henning Walczak, *Heidelberg*
Heiner Wedemeyer, *Hannover*
Fritz von Weizsacker, *Berlin*
Jens Werner, *Heidelberg*
Bertram Wiedenmann, *Berlin*
Reiner Wiest, *Regensburg*
Stefan Wirth, *Wuppertal*
Stefan JP Zeuzem, *Homburg*

Greece

Alexandra A Alexopoulou, *Athens*
George N Dalekos, *Larissa*
Christos Dervenis, *Athens*
Melanie Maria Deutsch, *Athens*
Tsianos Epameinondas, *Ioannina*
Elias A Kouroumalis, *Heraklion*
George Papatheodoridis, *Athens*
Spiros Sgouros, *Athens*

Hungary

Peter L Lakatos, *Budapest*
Zsuzsa Szondy, *Debrecen*

Iceland

Hallgrimur Gudjonsson, *Reykjavik*

India

Philip Abraham, *Mumbai*
Rakesh Aggarwal, *Lucknow*
Kunissery A Balasubramanian, *Vellore*
Deepak Kumar Bhasin, *Chandigarh*
Sujit K Bhattacharya, *Kolkata*
Yogesh K Chawla, *Chandigarh*
Radha K Dhiman, *Chandigarh*
Sri Prakash Misra, *Allahabad*
Ramesh Roop Rai, *Jaipur*
Nageshwar D Reddy, *Hyderabad*
Rakesh Kumar Tandon, *New Delhi*

Iran

Seyed-Moayed Alavian, *Tehran*
Reza Malekzadeh, *Tehran*
Seyed A Taghavi, *Shiraz*

Ireland

Billy Bourke, *Dublin*
Ronan A Cahill, *Cork*
Anthony P Moran, *Galway*

Israel

Simon Bar-Meir, *Hashomer*
Abraham R Eliakim, *Haifa*
Zvi Fireman, *Hadera*
Yaron Ilan, *Jerusalem*
Avidan U Neumann, *Ramat-Gan*
Yaron Niv, *Pardesia*
Ran Oren, *Tel Aviv*
Ami D Sperber, *Beer-Sheva*

Italy

Giovanni Addolorato, *Roma*
Luigi E Adinolfi, *Naples*
Domenico Alvaro, *Rome*
Mario Angelico, *Rome*
Vito Annese, *San Giovanni Rotond*
Filippo Ansaldi, *Genoa*
Adolfo F Attili, *Roma*
Giovanni Barbara, *Bologna*
Claudio Bassi, *Verona*
Gabrio Bassotti, *Perugia*
Pier M Battezzati, *Milan*
Stefano Bellentani, *Carpi*
Antonio Benedetti, *Ancona*
Mauro Bernardi, *Bologna*
Livia Biancone, *Rome*
Luigi Bonavina, *Milano*
Flavia Bortolotti, *Padova*
Giuseppe Brisinda, *Rome*
Elisabetta Buscarini, *Crema*
Giovanni Cammarota, *Roma*

Antonino Cavallari, *Bologna*
Giuseppe Chiarioni, *Valeggio*
Michele Cicala, *Rome*
Massimo Colombo, *Milan*
Amedeo Columbano, *Cagliari*
Massimo Conio, *Sanremo*
Dario Conte, *Milano*
Gino R Corazza, *Pavia*
Francesco Costa, *Pisa*
Antonio Craxi, *Palermo*
Silvio Danese, *Milan*
Roberto de Franchis, *Milano*
Roberto De Giorgio, *Bologna*
Maria Stella De Mitri, *Bologna*
Giovanni D De Palma, *Naples*
Fabio Farinati, *Padua*
Giammarco Fava, *Ancona*
Francesco Feo, *Sassari*
Fiorucci Stefano, *Perugia*
Andrea Galli, *Firenze*
Valeria Ghisett, *Turin*
Gianluigi Giannelli, *Bari*
Edoardo G Giannini, *Genoa*
Paolo Gionchetti, *Bologna*
Fabio Grizzi, *Milan*
Salvatore Gruttadauria, *Palermo*
Mario Guslandi, *Milano*
Pietro Invernizzi, *Milan*
Ezio Laconi, *Cagliari*
Giacomo Laffi, *Firenze*
Giovanni Maconi, *Milan*
Lucia Malaguarnera, *Catania*
Emanuele D Mangoni, *Napoli*
Paolo Manzoni, *Torino*
Giulio Marchesini, *Bologna*
Fabio Marra, *Florence*
Marco Marzioni, *Ancona*
Giuseppe Mazzella, *Bologna*
Mario U Mondelli, *Pavia*
Giuseppe Montalto, *Palermo*
Giovanni Monteleone, *Rome*
Giovanni Musso, *Torino*
Gerardo Nardone, *Napoli*
Valerio Nobili, *Rome*
Fabio Pace, *Milano*
Luisi Pagliaro, *Palermo*
Francesco Pallone, *Rome*
Fabrizio R Parente, *Milan*
Maurizio Parola, *Torino*
Francesco Perri, *San Giovanni Rotondo*
Raffaele Pezzilli, *Bologna*
Alberto Pilotto, *San Giovanni Rotondo*
Alberto Piperno, *Monza*
Mario Pirisi, *Novara*
Anna C Piscaglia, *Roma*
Paolo Del Poggio, *Treviglio*
Gabriele B Porro, *Milano*
Piero Portincasa, *Bari*
Cosimo Prantera, *Roma*
Bernardino Rampone, *Siena*
Oliviero Riggio, *Rome*
Claudio Romano, *Messina*
Marco Romano, *Napoli*
Gerardo Rosati, *Potenza*
Mario Del Tacca, *Pisa*
Gloria Taliani, *Rome*
Pier A Testoni, *Milan*
Enrico Roda, *Bologna*
Domenico Sansonno, *Bari*
Vincenzo Savarino, *Genova*
Vincenzo Stanghellini, *Bologna*
Giovanni Tarantino, *Naples*
Roberto Testa, *Genoa*
Dino Vaira, *Bologna*
Anna Linda Zignego, *Florence*

Japan

Kyoichi Adachi, *Izumo*
Yasushi Adachi, *Sapporo*
Taiji Akamatsu, *Matsumoto*
Sk Md Fazle Akbar, *Ehime*
Takafumi Ando, *Nagoya*
Akira Andoh, *Otsu*
Taku Aoki, *Tokyo*
Masahiro Arai, *Tokyo*
Tetsuo Arakawa, *Osaka*
Yasuji Arase, *Tokyo*
Masahiro Asaka, *Sapporo*
Hitoshi Asakura, *Tokyo*
Takeshi Azuma, *Fukui*
Yoichi Chida, *Fukuoka*
Takahiro Fujimori, *Tochigi*
Jiro Fujimoto, *Hyogo*
Kazuma Fujimoto, *Saga*
Mitsuhiro Fujishiro, *Tokyo*
Yoshihide Fujiyama, *Otsu*
Hiroyuki Fukui, *Tochigi*
Hiroyuki Hanai, *Hamamatsu*
Naohiko Harada, *Fukuoka*
Makoto Hashizume, *Fukuoka*
Tetsuo Hayakawa, *Nagoya*
Toru Hiyama, *Higashihiroshima*
Kazuhide Higuchi, *Osaka*
Keisuke Hino, *Ube*
Keiji Hirata, *Kitakyushu*
Yuji Iimuro, *Nishinomiya*
Kenji Ikeda, *Tokyo*
Toru Ikegami, *Fukuoka*
Kenichi Ikejima, *Bunkyo-ku*
Fumio Imazeki, *Chiba*
Yutaka Inagaki, *Kanagawa*
Yasuhiro Inokuchi, *Yokohama*
Haruhiro Inoue, *Yokohama*
Masayasu Inoue, *Osaka*
Hiromi Ishibashi, *Nagasaki*
Shunji Ishihara, *Izumo*
Toru Ishikawa, *Niigata*
Kei Ito, *Sendai*
Masayoshi Ito, *Tokyo*
Hiroaki Itoh, *Akita*
Ryuichi Iwakiri, *Saga*
Yoshiaki Iwasaki, *Okayama*
Terumi Kamisawa, *Tokyo*
Hiroshi Kaneko, *Aichi-Gun*
Shuichi Kaneko, *Kanazawa*
Takashi Kanematsu, *Nagasaki*
Mitsuo Katano, *Fukuoka*
Junji Kato, *Sapporo*
Mototsugu Kato, *Sapporo*
Shinzo Kato, *Tokyo*
Norifumi Kawada, *Osaka*
Sunao Kawano, *Osaka*
Mitsuhiro Kida, *Kanagawa*
Yoshikazu Kinoshita, *Izumo*
Tsuneo Kitamura, *Chiba*
Seigo Kitano, *Oita*
Kazuhiko Koike, *Tokyo*
Norihiro Kokudo, *Tokyo*
Satoshi Kondo, *Sapporo*
Shoji Kubo, *Osaka*
Shigeki Kuriyama, *Kagawa*[2]
Katsunori Iijima, *Sendai*
Masato Kusunoki, *Tsu Mie*
Shin Maeda, *Tokyo*
Shigeru Marubashi, *Suita*
Masatoshi Makuuchi, *Tokyo*
Osamu Matsui, *Kanazawa*
Yasuhiro Matsumura, *Chiba*
Yasushi Matsuzaki, *Tsukuba*
Kiyoshi Migita, *Omura*
Kenji Miki, *Tokyo*
Tetsuya Mine, *Kanagawa*
Hiroto Miwa, *Hyogo*
Masashi Mizokami, *Nagoya*
Yoshiaki Mizuguchi, *Tokyo*
Motowo Mizuno, *Hiroshima*
Morito Monden, *Suita*
Hisataka S Moriwaki, *Gifu*
Yasuaki Motomura, *Iizuka*
Yoshiharu Motoo, *Kanazawa*
Naofumi Mukaida, *Kanazawa*
Kazunari Murakami, *Oita*
Kunihiko Murase, *Tusima*
Hiroaki Nagano, *Suita*
Masahito Nagaki, *Gifu*
Masaki Nagaya, *Kawasaki*
Yujl Naito, *Kyoto*
Atsushi Nakajima, *Yokohama*
Hisato Nakajima, *Tokyo*
Hiroki Nakamura, *Yamaguchi*
Shotaro Nakamura, *Fukuoka*
Mikio Nishioka, *Niihama*
Shuji Nomoto, *Nagoya*
Susumu Ohmada, *Maebashi*
Hirohide Ohnishi, *Akita*
Masayuki Ohta, *Oita*
Tetsuo Ohta, *Kanazawa*
Kazuichi Okazaki, *Osaka*
Katsuhisa Omagari, *Nagasaki*
Saburo Onishi, *Nankoku*
Morikazu Onji, *Ehime*
Satoshi Osawa, *Hamamatsu*
Masanobu Oshima, *Kanazawa*
Hiromitsu Saisho, *Chiba*
Hidetsugu Saito, *Tokyo*
Yutaka Saito, *Tokyo*
Isao Sakaida, *Yamaguchi*
Michiie Sakamoto, *Tokyo*
Yasushi Sano, *Chiba*
Hiroki Sasaki, *Tokyo*
Iwao Sasaki, *Sendai*
Motoko Sasaki, *Kanazawa*
Chifumi Sato, *Tokyo*
Shuichi Seki, *Osaka*
Hiroshi Shimada, *Yokohama*
Mitsuo Shimada, *Tokushima*
Tomohiko Shimatan, *Hiroshima*
Hiroaki Shimizu, *Chiba*
Ichiro Shimizu, *Tokushima*
Yukihiro Shimizu, *Kyoto*
Shinji Shimoda, *Fukuoka*
Tooru Shimosegawa, *Sendai*
Tadashi Shimoyama, *Hirosaki*
Ken Shirabe, *Iizuka City*
Yoshio Shirai, *Niigata*
Katsuya Shiraki, *Mie*
Yasushi Shiratori, *Okayama*
Masayuki Sho, *Nara*
Yasuhiko Sugawara, *Tokyo*
Hidekazu Suzuki, *Tokyo*
Minoru Tada, *Tokyo*
Tadatoshi Takayama, *Tokyo*
Tadashi Takeda, *Osaka*
Koji Takeuchi, *Kyoto*
Kiichi Tamada, *Tochigi*
Akira Tanaka, *Kyoto*
Eiji Tanaka, *Matsumoto*
Noriaki Tanaka, *Okayama*
Shinji Tanaka, *Hiroshima*
Hideki Taniguchi, *Yokohama*
Kyuichi Tanikawa, *Kurume*
Akira Terano, *Shimotsugagun*
Hitoshi Togash, *Yamagata*
Shinji Togo, *Yokohama*
Kazunari Tominaga, *Osaka*
Takuji Torimura, *Fukuoka*

Minoru Toyota, *Sapporo*
Akihito Tsubota, *Chiba*
Takato Ueno, *Kurume*
Naomi Uemura, *Tokyo*
Shinichi Wada, *Tochigi*
Hiroyuki Watanabe, *Kanazawa*
Toshio Watanabe, *Osaka*
Yuji Watanabe, *Ehime*
Toshiaki Watanabe, *Tokyo*
Chun-Yang Wen, *Nagasaki*
Satoshi Yamagiwa, *Niigata*
Koji Yamaguchi, *Fukuoka*
Takayuki Yamamoto, *Yokkaichi*
Takashi Yao, *Fukuoka*
Masashi Yoneda, *Tochigi*
Hiroshi Yoshida, *Tokyo*
Masashi Yoshida, *Tokyo*
Norimasa Yoshida, *Kyoto*
Hitoshi Yoshiji, *Nara*
Kentaro Yoshika, *Toyoake*
Yasunobu Yoshikai, *Fukuoka*
Masahide Yoshikawa, *Kashihara*
Katsutoshi Yoshizato, *Higashihiroshima*

Lebanon
Bassam N Abboud, *Beirut*
Ala I Sharara, *Beirut*
Joseph D Boujaoude, *Beirut*

Lithuania
Limas Kupcinskas, *Kaunas*

Macedonia
Vladimir C Serafimoski, *Skopje*

Malaysia
Andrew Seng Boon Chua, *Ipoh*
Khean-Lee Goh, Kuala *Lumpur*
Jayaram Menon, *Sabah*

Mexico
Diego Garcia-Compean, *Monterrey*
Eduardo R Marin-Lopez, *Jesús García*
Nahum Méndez-Sánchez, *Mexico*
Saúl Villa-Treviño, *México*

Monaco
Patrick Rampal, *Monaco*

Morocco
Abdellah Essaid, *Rabat*

The Netherlands
Ulrich Beuers, *Amsterdam*
Gerd Bouma, *Amsterdam*
Lee Bouwman, *Leiden*
J Bart A Crusius, *Amsterdam*
NKH de Boer, *Amsterdam*
Koert P de Jong, *Groningen*
Henrike Hamer, *Maastricht*
Frank Hoentjen, *Haarlem*
Janine K Kruit, *Groningen*
Ernst J Kuipers, *Rotterdam*
CBHW Lamers, *Leiden*
Ton Lisman, *Utrecht*
Yi Liu, *Amsterdam*
Jeroen Maljaars, *Maastricht*
Servaas Morré, *Amsterdam*
Chris JJ Mulder, *Amsterdam*
Michael Müller, *Wageningen*
Amado S Peña, *Amsterdam*
Robert J Porte, *Groningen*
Ingrid B Renes, *Rotterdam*
Andreas Smout, *Utrecht*
Paul E Sijens, *Groningen*
Reinhold W Stockbrugger, *Maastricht*
Luc JW van der Laan, *Rotterdam*
Karel van Erpecum, *Utrecht*
Gerard P VanBerge-Henegouwen,*Utrecht*

New Zealand
Ian D Wallace, *Auckland*

Nigeria
Samuel B Olaleye, *Ibadan*

Norway
Trond Berg, *Oslo*
Tom H Karlsen, *Oslo*
Helge L Waldum, *Trondheim*

Pakistan
Muhammad S Khokhar, *Lahore*
Syed MW Jafri, *Karachi*

Peru
Hector H Garcia, *Lima*

Poland
Tomasz Brzozowski, *Cracow*
Robert Flisiak, *Bialystok*
Hanna Gregorek, *Warsaw*
Dariusz M Lebensztejn, *Bialystok*
Wojciech G Polak, *Wroclaw*
Marek Hartleb, *Katowice*

Portugal
Miguel C De Moura, *Lisbon*

Russia
Vladimir T Ivashkin, *Moscow*
Leonid Lazebnik, *Moscow*
Vasiliy I Reshetnyak, *Moscow*

Saudi Arabia
Ibrahim A Al Mofleh, *Riyadh*
Ahmed Helmy, *Riyadh*

Serbia
Dusan M Jovanovic, *Sremska Kamenica*

Singapore
Bow Ho, *Singapore*
Khek-Yu Ho, *Singapore*
Fock Kwong Ming, *Singapore*
Francis Seow-Choen, *Singapore*

Slovakia
Silvia Pastorekova, *Bratislava*
Anton Vavrecka, *Bratislava*

Slovenia
Sasa Markovic, *Ljubljana*

South Africa
Rosemar Joyce Burnett, *Pretoria*
Michael C Kew, *Parktown*

South Korea
Byung Ihn Choi, *Seoul*
Ho Soon Choi, *Seoul*
Marie Yeo, *Suwon*
Sun Pyo Hong, *Gyeonggi-do*
Jae J Kim, *Seoul*
Jin-Hong Kim, *Suwon*
Myung-Hwan Kim, *Seoul*
Chang Hong Lee, *Seoul*
Jong Kyun Lee, *Seoul*
Eun-Yi Moon, *Seoul*
Jae-Gahb Park, *Seoul*
Dong Wan Seo, *Seoul*
Dong Jin Suh, *Seoul*
Byung Chul Yoo, *Seoul*

Spain
Juan G Abraldes, *Barcelona*
Agustin Albillos, *Madrid*
Raul J Andrade, *Málaga*
Luis Aparisi, *Valencia*
Fernando Azpiroz, *Barcelona*
Ramon Bataller, *Barcelona*
Josep M Bordas, *Barcelona*
Xavier Calvet, *Sabadell*
Jordi Camps, *Catalunya*
Andres Cardenas, *Barcelona*
Vicente Carreño, *Madrid*
Jose Castellote, *Barcelona*
Antoni Castells, *Barcelona*
Vicente Felipo, *Valencia*
Juan C Garcia-Pagán, *Barcelona*
Jaime B Genover, *Barcelona*
Javier P Gisbert, *Madrid*
Jaime Guardia, *Barcelona*
Isabel Fabregat, *Barcelona*
Mercedes Fernandez, *Barcelona*
Angel Lanas, *Zaragoza*
Juan-Ramón Larrubia, *Guadalajara*
Laura Lladóa, *Barcelona*
María IT López, *Jaén*
Juan R Malagelada, *Barcelona*
José M Mato, *Derio*
Juan F Medina, *Pamplona*
Miguel A Muñoz-Navas, *Pamplona*
Julian Panes, *Barcelona*
Miguel M Perez, *Valencia*
Miguel Perez-Mateo, *Alicante*

Josep M Pique, *Barcelona*
Jesús M Prieto, *Pamplona*
Sabino Riestra, *Pola De Siero*
Luis Rodrigo, *Oviedo*
Manuel Romero-Gómez, *Sevilla*
Joan Roselló-Catafau, *Barcelona*

Sweden

Einar S Björnsson, *Gothenburg*
Curt Einarsson, *Huddinge*
Per M Hellström, *Stockholm*
Ulf Hindorf, *Lund*
Elisabeth Hultgren-Hörnquist, *Örebro*
Anders E Lehmann, *Mölndal*
Hanns-Ulrich Marschall, *Stockholm*
Lars C Olbe, *Molndal*
Lars A Pahlman, *Uppsala*
Matti Sallberg, *Stockholm*
Magnus Simrén, *Göteborg*
Xiao-Feng Sun, *Linköping*
Ervin Tóth, *Malmö*
Weimin Ye, *Stockholm*
Christer S von Holstein, *Lund*

Switzerland

Chrish Beglinger, *Basel*
Pierre A Clavien, *Zurich*
Jean-Francois Dufour, *Bern*
Franco Fortunato, *Zürich*
Jean L Frossard, *Geneva*
Gerd A Kullak-Ublick, *Zurich*
Pierre Michetti, *Lausanne*
Francesco Negro, *Genève*
Bruno Stieger, *Zurich*
Radu Tutuian, *Zurich*
Stephan R Vavricka, *Zurich*
Gerhard Rogler, *Zurich*
Arthur Zimmermann, *Berne*

Turkey

Yusuf Bayraktar, *Ankara*
Figen Gurakan, *Ankara*
Aydin Karabacakoglu, *Konya*
Serdar Karakose, *Konya*
Hizir Kurtel, *Istanbul*
Osman C Ozdogan, *Istanbul*
Özlem Yilmaz, *Izmir*
Cihan Yurdaydin, *Ankara*

United Arab Emirates

Sherif M Karam, *Al-Ain*

United Kingdom

David H Adams, *Birmingham*
Simon Afford, *Birmingham*
Navneet K Ahluwalia, *Stockport*
Ahmed Alzaraa, *Manchester*
Lesley A Anderson, *Belfast*
Charalambos G Antoniades, *London*
Anthony TR Axon, *Leeds*
Qasim Aziz, *Manchester*
Nicholas M Barnes, *Birmingham*
Jim D Bell, *London*
Mairi Brittan, *London*
Alastair D Burt, *Newcastle*
Simon S Campbell, *Manchester*
Simon R Carding, *Leeds*
Paul J Ciclitira, *London*
Eithne Costello, *Liverpool*
Tatjana Crnogorac-Jurcevic, *London*
Harry Dalton, *Truro*
Amar P Dhillon, *London*
William Dickey, *Londonderry*
James E East, *London*
Emad M El-Omar, *Aberdeen*
Ahmed M Elsharkawy, *Newcastle Upon Tyne*
Annette Fristscher-Ravens, *London*
Elizabeth Furrie, *Dundee*
Daniel R Gaya, *Edinburgh*
Subrata Ghosh, *London*
William Greenhalf, *Liverpool*
Indra N Guha, *Southampton*
Peter C Hayes, *Edinburgh*
Gwo-Tzer Ho, *Edinburgh*
Anthony R Hobson, *Salford*
Lesley A Houghton, *Manchester*
Stefan G Hübscher, *Birmingham*
Robin Hughes, *London*
Pali Hungin, *Stockton*
David P Hurlstone, *Sheffield*
Rajiv Jalan, *London*
Janusz AZ Jankowski, *Oxford*
Brian T Johnston, *Belfast*
David EJ Jones, *Newcastle*
Roger Jones, *London*
Michael A Kamm, *Harrow*
Peter Karayiannis, *London*
Laurens Kruidenier, *Harlow*
Patricia F Lalor, *Birmingham*
Chee Hooi Lim, *Midlands*
Hong-Xiang Liu, *Cambridge*
Yun Ma, *London*
Kenneth E L McColl, *Glasgow*
Stuart AC McDonald, *London*
Dermot P Mcgovern, *Oxford*
Giorgina Mieli-Vergani, *London*
Nikolai V Naoumov, *London*
John P Neoptolemos, *Liverpool*
James Neuberger, *Birmingham*
Philip Noel Newsome, *Birmingham*
Mark S Pearce, *Newcastle Upon Tyne*
Stephen P Pereira, *London*
D Mark Pritchard, *Liverpool*
Sakhawat Rahman, *London*
Stephen E Roberts, *Swansea*
Marco Senzolo, *Padova*
Soraya Shirazi-Beechey, *Liverpool*
Robert Sutton, *Liverpool*
Simon D Taylor-Robinson, *London*
Paris P Tekkis, *London*
Ulrich Thalheimer, *London*
David G Thompson, *Salford*
Nick P Thompson, *Newcastle*
David Tosh, *Bath*
Frank I Tovey, *London*
Chris Tselepis, *Birmingham*
Diego Vergani, *London*
Geoffrey Warhurst, *Salford*
Alastair John Watson, *Liverpool*
Peter J Whorwell, *Manchester*
Roger Williams, *London*
Karen L Wright, *Bath*
Min Zhao, *Foresterhill*

United States

Manal F Abdelmalek, *Durham*
Gary A Abrams, *Birmingham*
Maria T Abreu, *New York*
Reid B Adams, *Virginia*
Golo Ahlenstiel, *Bethesda*
BS Anand, *Houston*
Frank A Anania, *Atlanta*
M Ananthanarayanan, *New York*
Gavin E Arteel, *Louisville*
Jasmohan S Bajaj, *Milwaukee*
Subhas Banerjee, *Palo Alto*
Peter A Banks, *Boston*
Jamie S Barkin, *Miami Beach*
Kim E Barrett, *San Diego*
Marc D Basson, *Detroit*
Anthony J Bauer, *Pittsburgh*
Wallace F Berman, *Durham*
Timothy R Billiar, *Pittsburgh*
Edmund J Bini, *New York*
David G Binion, *Milwaukee*
Jennifer D Black, *Buffalo*
Herbert L Bonkovsky, *Charlotte*
Carla W Brady, *Durham*
Andrea D Branch, *New York*
Robert S Bresalier, *Houston*
Alan L Buchman, *Chicago*
Ronald W Busuttil, *Los Angeles*
Alan Cahill, *Philadelphia*
John M Carethers, *San Diego*
David L Carr-Locke, *Boston*
Maurice A Cerulli, *New York*
Ravi S Chari, *Nashville*
Jiande Chen, *Galveston*
Xian-Ming Chen, *Omaha*
Xin Chen, *San Francisco*
Ramsey Chi-man Cheung, *Palo Alto*
William D Chey, *Ann Arbor*
John Y Chiang, *Rootstown*
Parimal Chowdhury, *Arkansas*
Raymond T Chung, *Boston*
James M Church, *Cleveland*
Ram Chuttani, *Boston*
Mark G Clemens, *Charlotte*
Ana J Coito, *Los Angeles*
Vincent Coghlan, *Beaverton*
David Cronin II, *New Haven*
John Cuppoletti, *Cincinnati*
Mark J Czaja, *New York*
Peter V Danenberg, *Los Angeles*
Kiron M Das, New *Brunswick*
Conor P Delaney, *Cleveland*
Jose L del Pozo, *Rochester*
Sharon DeMorrow, *Temple*
Deborah L Diamond, *Seattle*
Douglas A Drossman, *Chapel Hill*
Katerina Dvorak, *Tucson*
Bijan Eghtesad, *Cleveland*
Hala El-Zimaity, *Houston*
Michelle Embree-Ku, *Providence*
Sukru Emre, New *Haven*
Douglas G Farmer, *Los Angeles*
Alessio Fasano, *Baltimore*
Mark A Feitelson, *Philadelphia*
Ariel E Feldstein, *Cleveland*
Alessandro Fichera, *Chicago*
Robert L Fine, *New York*
Magali Fontaine, *Stanford*
Chris E Forsmark, *Gainesville*
Glenn T Furuta, *Aurora*
Chandrashekhar R Gandhi, *Pittsburgh*
Susan L Gearhart, *Baltimore*
Xupeng Ge, *Boston*
Xin Geng, *New Brunswick*
M Eric Gershwin, *Suite*
Jean-Francois Geschwind, *Baltimore*
Ignacio Gil-Bazo, *New York*
Shannon S Glaser, *Temple*
Ajay Goel, *Dallas*
Richard M Green, *Chicago*
Julia B Greer, *Pittsburgh*

James H Grendell, *New York*
David R Gretch, *Seattle*
Stefano Guandalini, *Chicago*
Anna S Gukovskaya, *Los Angeles*
Sanjeev Gupta, *Bronx*
David J Hackam, *Pittsburgh*
Stephen B Hanauer, *Chicago*
Gavin Harewood, *Rochester*
Margaret M Heitkemper, *Washington*
Alan W Hemming, *Gainesville*
Samuel B Ho, *San Diego*
Peter R Holt, *New York*
Colin W Howden, *Chicago*
Hongjin Huang, *Alameda*
Jamal A Ibdah, *Columbia*
Atif Iqbal, *Omaha*
Hajime Isomoto, *Rochester*
Hartmut Jaeschke, *Tucson*
Dennis M Jensen, *Los Angeles*
Cheng Ji, *Los Angeles*
Leonard R Johnson, *Memphis*
Michael P Jones, *Chicago*
Peter J Kahrilas, *Chicago*
Anthony N Kalloo, *Baltimore*
Marshall M Kaplan, *Boston*
Neil Kaplowitz, *Los Angeles*
Serhan Karvar, *Los Angeles*
Rashmi Kaul, *Tulsa*
Jonathan D Kaunitz, *Los Angeles*
Ali Keshavarzian, *Chicago*
Miran Kim, *Providence*
Joseph B Kirsner, *Chicago*
Leonidas G Koniaris, *Miami*
Burton I Korelitz, *New York*
Robert J Korst, *New York*
Richard A Kozarek, *Seattle*
Alyssa M Krasinskas, *Pittsburgh*
Michael Kremer, *Chapel Hill*
Shiu-Ming Kuo, *Buffalo*
Paul Y Kwo, *Indianapolis*
Daryl Tan Yeung Lau, *Galvesto*
Stephen J Lanspa, *Omaha*
Joel E Lavine, *San Diego*
Bret Lashner, *Cleveland*
Dirk J van Leeuwen, *Lebanon*
Glen A Lehman, *Indianapolis*
Alex B Lentsch, *Cincinnati*
Andreas Leodolter, *La Jolla*
Gene LeSage, *Houston*
Josh Levitsky, *Chicago*
Cynthia Levy, *Gainesville*
Ming Li, *New Orleans*
Zhiping Li, *Baltimore*
Zhe-Xiong Lian, *Davis*
Lenard M Lichtenberger, *Houston*
Gary R Lichtenstein, *Philadelphia*
Otto Schiueh-Tzang Lin, *Seattle*
Martin Lipkin, *New York*
Chen Liu, *Gainesville*
Edward V Loftus, *Rocheste*
Robin G Lorenz, *Birmingham*
Michael R Lucey, *Madison*
James D Luketich, *Pittsburgh*
Guangbin Luo, *Cheveland*
Henry T Lynch, *Omaha*
Patrick M Lynch, *Houston*
John S Macdonald, *New York*
Bruce V MacFadyen, *Augusta*
Willis C Maddrey, *Dallas*
Ashok Malani, *Los Angeles*
Mercedes Susan Mandell, *Aurora*
Peter J Mannon, *Bethesda*
Charles M Mansbach, *Tennessee*
John F Di Mari, *Texas*
John M Mariadason, *Bronx*
Jorge A Marrero, *Ann Arbor*
Paul Martin, *New York*
Paulo Ney Aguiar Martins, *Boston*
Wendy M Mars, *Pittsburgh*
Laura E Matarese, *Pittsburgh*
Richard W McCallum, *Kansas*
Beth A McCormick, *Charlestown*
Lynne V McFarland, *Washington*
Kevin McGrath, *Pittsburgh*
Harihara Mehendale, *Monroe*
Ali Mencin, *New York*
Fanyin Meng, *Ohio*
Stephan Menne, *New York*
Didier Merlin, *Atlanta*
Howard Mertz, *Nashville*
George W Meyer, *Sacramento*
George Michalopoulos, *Pittsburgh*
James M Millis, *Chicago*
Fabrizio Michelassi, *New York*
Albert D Min, *New York*
Pramod K Mistry, *New Haven*
Emiko Mizoguchi, *Boston*
Smruti R Mohanty, *Chicago*
Satdarshan S Monga, *Pittsburgh*
Timothy H Moran, *Baltimore*
Peter L Moses, *Burlington*
Steven F Moss, *Providence*
Andrew J Muir, *Durham*
Milton G Mutchnick, *Detroit*
Masaki Nagaya, *Boston*
Victor Navarro, *Philadelphia*
Laura E Nagy, *Cleveland*
Hiroshi Nakagawa, *Philadelphia*
Douglas B Nelson, *Minneapolis*
Justin H Nguyen, *Florida*
Patrick G Northup, *Charlottesville*
Christopher O'Brien, *Miami*
Robert D Odze, *Boston*
Brant K Oelschlager, *Washington*
Curtis T Okamoto, *Los Angeles*
Stephen JD O'Keefe, *Pittsburgh*
Dimitry Oleynikov, *Omaha*
Stephen J Pandol, *Los Angeles*
Georgios Papachristou, *Pittsburgh*
Pankaj J Pasricha, *Galveston*
Zhiheng Pei, *New York*
Michael A Pezzone, *Pittsburgh*
CS Pitchumoni, *New Brunswiuc*
Paul J Pockros, *La Jolla*
Jay Pravda, *Gainesville*
Massimo Raimondo, *Jacksonville*
GS Raju, *Galveston*
Raymund R Razonable, *Minnesota*
Murray B Resnick, *Providence*
Adrian Reuben, *Charleston*
Douglas K Rex, *Indianapolis*
Victor E Reyes, *Galveston*
Basil Rigas, *New York*
Yehuda Ringel, *Chapel Hill*
Richard A Rippe, *Chapel Hill*
Maribel Rodriguez-Torres, *Santurce*
Marcos Rojkind, *Washington*
Philip Rosenthal, *San Francisco*
Barry Rosser, *Jacksonville Florida*
Hemant K Roy, *Evanston*
Sammy Saab, *Los Angeles*
Shawn D Safford, *Norfolk*
Dushyant V Sahani, *Boston*
Bruce E Sands, *Boston*
James M Scheiman, *Ann Arbor*
Eugene R Schiff, *Miami*
Nicholas J Shaheen, *Chapel Hill*
Vanessa M Shami, *Charlottesville*
Prateek Sharma, *Kansas City*
Harvey L Sharp, *Minneapolis*
Stuart Sherman, *Indianapolis*
Shivendra Shukla, *Columbia*
Alphonse E Sirica, *Virginia*
Shanthi V Sitaraman, *Atlanta*
Stuart J Spechler, *Dallas*
Shanthi Srinivasan, *Atlanta*
Michael Steer, *Boston*
Peter D Stevens, *New York*
Charmaine A Stewart, *Rochester*
Christian D Stone, *Saint Louis*
Gary D Stoner, *Columbus*
R Todd Stravitz, *Richmond*
Liping Su, *Chicago*
Christina Surawicz, *Seattle*
Robert W Summers, *Iowa City*
Wing-Kin Syn, *Durham*
Gyongyi Szabo, *Worcester*
Yvette Taché, *Los Angeles*
Seng-Lai Tan, *Seattle*
Andrzej S Tarnawski, *Orange*
K-M Tchou-Wong, *New York*
Jonathan P Terdiman, *San Francisco*
Neil D Theise, *New York*
Christopher C Thompson, *Boston*
Swan N Thung, *New York*
Michael Torbenson, *Baltimore*
Natalie J Torok, *Sacramento*
RA Travagli, *Baton Rouge*
George Triadafilopoulos, *Stanford*
Chung-Jyi Tsai, *Lexington*
Janet Elizabeth Tuttle-Newhall, *Durham*
Andrew Ukleja, *Florida*
Michael F Vaezi, *Nashville*
Hugo E Vargas, *Scottsdale*
Arnold Wald, *Wisconsin*
Scott A Waldman, *Philadelphia*
Jian-Ying Wang, *Baltimore*
Timothy C Wang, *New York*
Irving Waxman, *Chicago*
Steven A Weinman, *Galveston*
Steven D Wexner, *Weston*
Keith T Wilson, *Baltimore*
Jacqueline L Wolf, *Boston*
Jackie Wood, *Ohio*
George Y Wu, *Farmington*
Jian Wu, *Sacramento*
Samuel Wyllie, *Houston*
Wen Xie, *Pittsburgh*
Vijay Yajnik, *Boston*
Vincent W Yang, *Atlanta*
Francis Y Yao, *San Francisco*
Hal F Yee, *San Francisco*
Xiao-Ming Yin, *Pittsburgh*
Min You, *Tampa*
Zobair M Younossi, *Virginia*
Liqing Yu, *Winston-Salem*
David Yule, *Rochester*
Ruben Zamora, *Pittsburgh*
Michael E Zenilman, *New York*
Zhi Zhong, *Chapel Hill*
Michael A Zimmerman, *Colorado*
Stephen D Zucker, *Cincinnati*

Uruguay

Henry Cohen, *Montevideo*

[1]Passed away on October 20, 2007
[2]Passed away on June 11, 2007

World Journal of Gastroenterology®

National Journal Award 2005

Weekly Established in October 1995

Volume 14 Number 32
August 28, 2008

百世登 Baishideng™©

Contents

EDITORIAL

4977 Update and actual trends on bacterial infections following liver transplantation
del Pozo JL

4984 Calcium signaling and T-type calcium channels in cancer cell cycling
Taylor JT, Zeng XB, Pottle JE, Lee K, Wang AR, Yi SG, Scruggs JAS, Sikka SS, Li M

4992 Diagnostic criteria for autoimmune pancreatitis in Japan
Kamisawa T, Okazaki K, Kawa S

REVIEW

4995 Giant duodenal ulcers
Newton EB, Versland MR, Sepe TE

GASTRIC CANCER

5000 Mechanism and pathobiologic implications of CHFR promoter methylation in gastric carcinoma
Gao YJ, Xin Y, Zhang JJ, Zhou J

LIVER CANCER

5008 Positional and expressive alteration of prohibitin during the induced differentiation of human hepatocarcinoma SMMC-7721 cells
Xu DH, Tang J, Li QF, Shi SL, Chen XF, Liang Y

RAPID COMMUNICATION

5015 Significance of scintigraphy for the localization of obscure gastrointestinal bleedings
Brünnler T, Klebl F, Mundorff S, Eilles C, Reng M, von Korn H, Schölmerich J, Langgartner J, Grüne S

5020 Probiotic effects on intestinal fermentation patterns in patients with irritable bowel syndrome
Barrett JS, Canale KEK, Gearry RB, Irving PM, Gibson PR

5025 Hepatocytes isolated from neoplastic liver-immunomagnetic purging as a new source for transplantation
Gunasegaram A, Akhter J, Yao P, Johnson LA, Riodan SM, Morris DL

5032 Differentiation of malignant and benign proximal bile duct strictures: The diagnostic dilemma
Kloek JJ, van Delden OM, Erdogan D, ten Kate FJ, Rauws EA, Busch OR, Gouma DJ, van Gulik TM

5039 Accuracy of *Helicobacter pylori* serology in two peptic ulcer populations and in healthy controls
Lindsetmo RO, Johnsen R, Eide TJ, Gutteberg T, Husum HH, Revhaug A

5046 Endoscopic findings in patients with upper gastrointestinal bleeding clinically classified into three risk groups prior to endoscopy
Tammaro L, Di Paolo MC, Zullo A, Hassan C, Morini S, Caliendo S, Pallotta L

5051 Colonoscopy evaluation after short-term anti-tuberculosis treatment in nonspecific ulcers on the ileocecal area
Park YS, Jun DW, Kim SH, Lee HH, Jo YJ, Song MH, Kim NI, Lee JS

5059 Cellular DNA repair cofactors affecting hepatitis B virus infection and replication
Zhao F, Hou NB, Song T, He X, Zheng ZR, Ma QJ, Li L, Zhang YH, Zhong H

5066 Treatment of polycystic liver disease with resection-fenestration and a new classification
Li TJ, Zhang HB, Lu JH, Zhao J, Yang N, Yang GS

5073 Treatment of upper gastrointestinal fistula and leakage with personal stage nutrition support
Wang Q, Liu ZS, Qian Q, Sun Q, Pan DY, He YM

5078 Polymorphisms of alcohol dehydrogenase 2 and aldehyde dehydrogenase 2 and colorectal cancer risk in Chinese males
Gao CM, Takezaki T, Wu JZ, Zhang XM, Cao HX, Ding JH, Liu YT, Li SP, Cao J, Matsuo K, Hamajima N, Tajima K

5084 Ivor Lewis subtotal esophagectomy with two-field lymphadenectomy for squamous cell carcinoma of the lower thoracic esophagus
Wu J, Chai Y, Zhou XM, Chen QX, Yan FL

5090 *Lactobacilli* inhibit interleukin-8 production induced by *Helicobacter pylori* lipopolysaccharide-activated Toll-like receptor 4
Zhou C, Ma FZ, Deng XJ, Yuan H, Ma HS

CASE REPORT

5096 Large solitary ovarian metastasis from colorectal cancer diagnosed by endoscopic ultrasound
Moparty B, Gomez G, Bhutani MS

World Journal of Gastroenterology
Volume 14 **Number** 32 **August** 28, 2008

Contents

5098 Serious drug-induced liver disease secondary to ezetimibe
Castellote J, Ariza J, Rota R, Girbau A, Xiol X

ACKNOWLEDGMENTS **5100** Acknowledgments to Reviewers of *World Journal of Gastroenterology*

APPENDIX **5101** Meetings

5102 Instructions to authors

FLYLEAF I-VII Editorial Board

INSIDE BACK COVER Online Submissions

INSIDE FRONT COVER Online Submissions

RESPONSIBLE EDITORS FOR THIS ISSUE
Assistant Editor: *Hui Li* **Review Editor:** *Lin Tian* **Electronic Page Editor:** *Yin-Ping Lin*
Editor-in-Charge: *Jian-Xia Cheng* **Copy Editor:** *Gianfranco D Alpini, Professor*
Associate Senior Editor: *Jian-Xia Cheng* **Layout Editor:** *Lian-Sheng Ma*

NAME OF JOURNAL
World Journal of Gastroenterology

RESPONSIBLE INSTITUTION
Department of Science and Technology of Shanxi Province

SPONSOR
Taiyuan Research and Treatment Center for Digestive Diseases, 77 Shuangta Xijie, Taiyuan 030001, Shanxi Province, China

EDITING
Editorial Board of *World Journal of Gastroenterology,* Room 903, Ocean International Center, Building D, No. 62 Dongsihuan Zhonglu, Chaoyang District, Beijing 100025, China
Telephone: +86-10-59080039
Fax: +86-10-85381893
E-mail: wjg@wjgnet.com
http://www.wjgnet.com

PUBLISHING
The WJG Press and Beijing Baishideng BioMed Scientific Co., Ltd., Room 903, Ocean International Center, Building D, No. 62 Dongsihuan Zhonglu, Chaoyang District, Beijing 100025, China
Telephone: +86-10-59080039
Fax: +86-10-85381893
E-mail: wjg@wjgnet.com
http://www.wjgnet.com

PRINTING
Beijing Kexin Printing House

OVERSEAS DISTRIBUTOR
Beijing Bureau for Distribution of Newspapers and Journals
(Code No. 82-261)
China International Book Trading Corporation PO Box 399, Beijing, China (Code No. M4481)

PUBLICATION DATE
August 28, 2008

EDITOR-IN-CHIEF
Lian-Sheng Ma, *Beijing*

SUBSCRIPTION
RMB 50 Yuan for each issue, RMB 2400 Yuan for one year

CSSN
ISSN 1007-9327
CN 14-1219/R

HONORARY EDITORS-IN-CHIEF
Montgomery Bissell, *San Francisco*
James L Boyer, *New Haven*
Chao-Long Chen, *Kaohsiung*
Ke-Ji Chen, *Beijing*
Li-Fang Chou, *Taipei*
Jacques V Dam, *Stanford*
Martin H Floch, *New Haven*
Guadalupe Garcia-Tsao, *New Haven*
Zhi-Qiang Huang, *Beijing*
Shinn-Jang Hwang, *Taipei*
Ira M Jacobson, *New York*
Derek Jewell, *Oxford*
Emmet B Keeffe, *Palo Alto*
Min-Liang Kuo, *Taipei*
Nicholas F LaRusso, *Rochester*
Jie-Shou Li, *Nanjing*
Geng-Tao Liu, *Beijing*
Lein-Ray Mo, *Tainan*
Bo-Rong Pan, *Xi'an*
Fa-Zu Qiu, *Wuhan*
Eamonn M Quigley, *Cork*
David S Rampton, *London*
Rafiq A Sheikh, *Sacramento*
Rudi Schmid, *Kentfield*[†]
Nicholas J Talley, *Rochester*
Sun-Lung Tsai, *Young-Kang City*
Guido NJ Tytgat, *Amsterdam*
Hsiu-Po Wang, *Taipei*
Jaw-Ching Wu, *Taipei*
Meng-Chao Wu, *Shanghai*
Ming-Shiang Wu, *Taipei*
Jia-Yu Xu, *Shanghai*
Ta-Sen Yeh, *Taoyuan*
Ming-Lung Yu, *Kaohsiung*

STRATEGY ASSOCIATE EDITORS-IN-CHIEF
Peter Draganov, *Florida*
Ronnie Fass, *Tucson*
Hugh J Freeman, *Vancouver*
John P Geibel, *New Haven*
Maria C Gutiérrez-Ruiz, *México*
Kazuhiro Hanazaki, *Kochi*
Akio Inui, *Kagoshima*
Kalpesh Jani, *Vadodara*
Sanaa M Kamal, *Cairo*
Ioannis E Koutroubakis, *Heraklion*
Jose JG Marin, *Salamanca*
Javier S Martin, *Punta del Este*
Natalia A Osna, *Omaha*
Jose Sahel, *Marseille*
Ned Snyder, *Galveston*
Nathan Subramaniam, *Brisbane*
Wei Tang, *Tokyo*
Alan BR Thomson, *Edmonton*
Paul Joseph Thuluvath, *Baltimore*
James F Trotter, *Denver*
Shingo Tsuji, *Osaka*
Harry HX Xia, *Hanover*
Yoshio Yamaoka, *Houston*
Jesue K Yamamoto-Furusho, *México*

ASSOCIATE EDITORS-IN-CHIEF
Gianfranco D Alpini, *Temple*
Bruno Annibale, *Roma*
Roger William Chapman, *Oxford*
Chi-Hin Cho, *Hong Kong*
Alexander L Gerbes, *Munich*
Shou-Dong Lee, *Taipei*
Walter Edwin Longo, *New Haven*
You-Yong Lu, *Beijing*
Masao Omata, *Tokyo*

EDITORIAL OFFICE
Director: Jian-Xia Cheng, *Beijing*
Deputy Director: Jian-Zhong Zhang, *Beijing*

LANGUAGE EDITORS
Director: Jing-Yun Ma, *Beijing*
Deputy Director: Xian-Lin Wang, *Beijing*

MEMBERS
Gianfranco D Alpini, *Temple*
BS Anand, *Houston*
Manoj Kumar, *Nepal*
Patricia F Lalor, *Birmingham*
Ming Li, *New Orleans*
Margaret Lutze, *Chicago*
Sabine Mihm, *Göttingen*
Francesco Negro, *Genève*
Bernardino Rampone, *Siena*
Richard A Rippe, *Chapel Hill*
Stephen E Roberts, *Swansea*

COPY EDITORS
Gianfranco D Alpini, *Temple*
Sujit Kumar Bhattacharya, *Kolkata*
Filip Braet, *Sydney*
Kirsteen N Browning, *Baton Rouge*
Radha K Dhiman, *Chandigarh*
John Frank Di Mari, *Texas*
Shannon S Glaser, *Temple*
Eberhard Hildt, *Berlin*
Patricia F Lalor, *Birmingham*
Ming Li, *New Orleans*
Margaret Lutze, *Chicago*
MI Torrs, *Jaén*
Sri Prakash Misra, *Allahabad*
Giovanni Monteleone, *Rome*
Giovanni Musso, *Torino*
Valerio Nobili, *Rome*
Osman Cavit Ozdogan, *Istanbul*
Francesco Perri, *San Giovanni Rotondo*
Thierry Piche, *Nice*
Bernardino Rampone, *Siena*
Richard A Rippe, *Chapel Hill*
Ross C Smith, *Sydney*
Daniel Lindsay Worthley, *Bedford*
George Y Wu, *Farmington*
Jian Wu, *Sacramento*

COPYRIGHT
© 2008 Published by The WJG Press. All rights reserved; no part of this publication may be reproduced, stored in a retrieval system, or transmitted in any form or by any means, electronic, mechanical, photocopying, recording, or otherwise without the prior permission of *WJG*. Authors are required to grant *WJG* an exclusive licence to publish.

SPECIAL STATEMENT
All articles published in this journal represent the viewpoints of the authors except where indicated otherwise.

INSTRUCTIONS TO AUTHORS
Full instructions are available online at http://www.wjgnet.com/wjg/help/instructions.jsp. If you do not have web access please contact the editorial office.

ONLINE SUBMISSION
http://wjg.wjgnet.com

Online Submissions: wjg.wjgnet.com
wjg@wjgnet.com
doi:10.3748/wjg.14.4977

World J Gastroenterol 2008 August 28; 14(32): 4977-4983
World Journal of Gastroenterology ISSN 1007-9327
© 2008 The WJG Press. All rights reserved.

EDITORIAL

Update and actual trends on bacterial infections following liver transplantation

Jose Luis del Pozo

Jose Luis del Pozo, Division of Infectious Diseases, Department of Medicine, Mayo Clinic Rochester, Rochester MN 55905, United States
Author contributions: del Pozo JL contributed all to this paper.
Correspondence to: Dr. Jose Luis del Pozo, MD, PhD, Division of Infectious Diseases, Department of Medicine, Mayo Clinic, 200 First St. SW, Rochester MN 55905, United States. delpozo.jose@mayo.edu
Telephone: +1-507-2840965 Fax: +1-507-2840966
Received: April 29, 2008 Revised: August 12, 2008
Accepted: August 19, 2008
Published online: August 28, 2008

Abstract

Recent advances in effective antimicrobial prophylactic strategies have led to a decline in the incidence of opportunistic infections in liver transplant recipients. However, morbidity and mortality due to infectious diseases remain as major problems. Bacterial infections occurring early after transplant are mainly related to the technical aspects of the procedure. By contrast, after the first postoperative days and beyond, the nature and variety of infectious complications change. Opportunistic bacterial infections are uncommon after 6 mo in patients receiving stable and reduced maintenance doses of immunosuppression with good graft function and little is documented about these cases in the literature. Transplant recipients may be more susceptible to some pathogens, such as the *Nocardia* species, *Legionella* species, *Listeria monocytogenes*, *Mycoplasma* species, *Salmonella* species or *Rhodococcus equi.* Respiratory infections due to capsulated bacteria, such as *Streptococcus pneumoniae* and *Haemophilus influenza*, can be life-threatening if not promptly treated in this population. These late bacterial infections may be very difficult to recognize and treat in this population. In this article, we review what has been described in the literature with regards to late bacterial infections following liver transplantation.

© 2008 The WJG Press. All rights reserved.

Key words: Liver transplant; Bacterial infections; *Nocardia* species; *Listeria* species; *Legionella* species; *Mycoplasma* species; *Bartonella* species

Peer reviewer: Paulo Ney Aguiar Martins, MD, PhD, Department of Surgery, Massachusetts General Hospital, Harvard Medical School, Transplantation Biology Center, MGH East, 13th Street, Bldg 149-9019, Boston MA 02129, United States

del Pozo JL. Update and actual trends on bacterial infections following liver transplantation. *World J Gastroenterol* 2008; 14(32): 4977-4983 Available from: URL: http://www.wjgnet.com/1007-9327/14/4977.asp DOI: http://dx.doi.org/10.3748/wjg.14.4977

INTRODUCTION

Since the first report in 1963, liver transplantation has become an established treatment for properly selected patients with end-stage liver disease, primary and some secondary hepatic malignancies and some rare metabolic liver-based disorders. During the past decade, survival rates after liver transplantation have steadily improved, with one-year survival exceeding 90% and approaching 70% at 8 years[1]. Increasingly, potent immunosuppressive agent use has dramatically reduced the incidence of rejection in the transplanted population, while increasing patient susceptibility to opportunistic infections and cancer[2]. However, recent advances in effective antimicrobial prophylactic strategies have led to a decline in the incidence of opportunistic infections in liver transplant recipients. Nevertheless, morbidity and mortality due to infectious complications remain as major problems in this selected population.

Infection and rejection remain major causes of morbidity after a liver transplant, accounting for up to 85% of deaths in some studies[3]. Infections were the most common cause of death after liver transplantation, and were present in 64% of a total of 321 cases in a study[4]. Two-thirds of all infections occurred during the first 100 d post transplantation in this study. Overall, the infections were bacterial in 48% of the cases, fungal in 22%, and viral in 12%[4]. The ratio of infectious to non-infectious causes of death did not change significantly during the 15-year study period, and the relative percentages of bacterial, fungal, and viral infections showed relatively little discrepancy on a year-to-year basis in this study[4]. In one other study, 83% of a liver transplant population had 1 or more episodes of infection and 67% had severe infections[5]. 70% of severe infections occurred within the first 2 mo after transplantation. The most frequent severe

infections occurred were abdominal abscesses, bacterial pneumonia, invasive candidiasis, *Pneumocystis jiroveci* pneumonia, and symptomatic cytomegalovirus infection[5]. In a 10-year Swiss single-centre study[6], 80% of patients developed an infection following transplantation. Almost half of these were bacterial with an infection rate that peaked during the first month following transplantion. The temporal relation between graft rejection and the occurrence of infection showed that the incidences of both viral and bacterial infections were increased by immunosuppressive supplementation. The overall incidence of bacterial infections was much higher during the first month following transplantation than after 1 mo in this study; 188.2 *vs* 5.8 episodes per 1000 patient-days[6].

Patterns of opportunistic bacterial infections after transplantation have been altered by routine antimicrobial prophylaxis for *Pneumocystis jirovecii* (trimethoprim-sulfamethoxazole prophylaxis for as little as 3 mo or for as long as a lifetime), and by infections due to organisms with antimicrobial resistance. Infections occur in a generally predictable pattern after solid-organ transplantation and most can be grouped into three major periods: the early period posttransplant (up to 6 wk), an intermediate period (1 to 6 mo); and a late period (more than 6 mo)[2].

Infections occurring immediately post-transplantation are similar to those seen in post-operative immunocompetent hosts. Bacterial infections predominate; they usually have a nosocomial source, such as central vascular access sites, external drainage catheters or are related to foreign bodies, necrotic tissue, or prolonged endobronchial intubation. Abdominal abscesses and peritonitis, intrahepatic abscesses (often associated with hepatic artery thrombosis), cholangitis, wound infections, nosocomial pneumonias (in patients who require prolonged ventilation) are common during this time frame. Patients may become infected with nosocomial, antimicrobial-resistant bacteria, including methicillin-resistant *Staphylococcus aureus*, vancomycin-resistant *Enterococcus faecalis*, *Clostridium difficile*, and antimicrobial-resistant gram-negative bacteria.

During the intermediate period, the nature of common infections changes and patients are most at risk for the development of opportunistic infections due to the cumulative effect of relatively high-dose immunosuppression, although residual problems from the perioperative period can persist. Viral pathogens and allograft rejection are responsible for the majority of febrile episodes that occur during the period from 1 to 6 mo after transplantation[2].

Opportunistic infections are uncommon after 6 mo in patients receiving stable and reduced maintenance doses of immunosuppression with good graft function, and little is documented about them in the literature. Potential etiologies of infection in these patients are diverse, including common, community-acquired bacterial infections seen in the general population, and uncommon opportunistic infections of clinical significance only in immunocompromised hosts. Respiratory infections due to capsulated pathogens, such as *Streptococcus pneumoniae* and *Haemophilus influenza*, can be life-threatening if not promptly treated in this population. In addition, transplant recipients may be more susceptible to certain bacterial pathogens, such as the *Nocardia* species, *Legionella* species, *Listeria monocytogenes*, *Mycoplasma* species, *Salmonella* species *Bartonella* species, or *Rhodococcus equi*. These late bacterial infections may be very difficult to recognize and treat in this population. Little information is available on the opportunistic late bacterial infections in liver transplant recipients. This review will focus on the risk, recognition and management of specific late bacterial infections, which are anticipated to occur more than 6 mo after liver transplantation.

SPECIAL INFECTION CHARACTERISTICS OF THE LIVER TRANSPLANT PATIENT

In general, it is more difficult to recognize infection in transplant recipients than it is in patients with normal immune function. Inflammatory responses associated with infection may be impaired by immunosuppressive therapy, and signs and symptoms of infection may often be diminished. Furthermore, noninfectious causes of fever, such as allograft rejection, may develop in these patients. Because of the immunosuppressed state of this population, they are susceptible to a broad range of opportunistic infections, which frequently present with multi-organ system involvement and progress rapidly. In addition, altered anatomy following transplant surgery may alter the physical signs of infection.

Cytomegalovirus infection can be documented in more than half of patient populations after organ transplantation[7]; with viral replication persisting long term. It is known that cytomegalovirus can affect the capacity of the host to mount a defense against complicating infections. Cytomegalovirus infection was associated with a 2.45-fold higher incidence of major infections between day 30 and 180 after orthotopic liver transplantation in a study, with most of these infections caused by gram-positive cocci[8].

Serologic testing is not generally useful for diagnosis since seroconversion is often delayed in these patients (antigen-based tests or nucleic acid-based molecular assays are recommended for diagnosing in this population). In the same way, tissue biopsies with histopathology and microbiology are often needed to make an early and specific microbiologic diagnosis.

The choice of antimicrobial regimens is often more complex than in other patients due to increased antimicrobial resistance, urgency of therapy and the high frequency of drug related toxicities and interactions with immunosuppressant drugs.

SPECIFIC LATE BACTERIAL INFECTIONS

Listeria monocytogenes infection in the liver transplant patient

Listeriosis is a clinical condition occurring with an annual

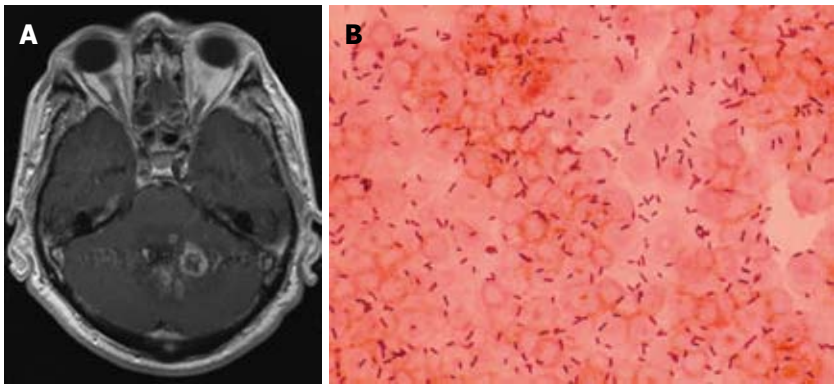

Figure 1 **A**: Gadolinium enhanced brain MRI demonstrating multiple ring-enhancing lesions, compatible with abscesses, located in the cerebellum; **B**: Gram stain of the spinal fluid of the same patient showing gram-positive rods. *Listeria monocytogenes* was isolated in spinal fluid culture.

incidence of 4.4/million individuals in the US and an associated mortality of approximately 20%[9]. *Listeria monocytogenes* has long been known as a pathogen of immunocompromised hosts (Figure 1). However, *Listeria* infections have only rarely been reported following orthotopic liver transplantation. The low incidence may be due, in part, to the prophylactic use of trimethoprim-sulfamethoxazole for *Pneumocystis jiroveci* pneumonia for up to 1 year following liver transplantation. Listeriosis occurs rarely after this 1 year period, so that further use of prophylactic antibiotics against this infection seems unjustified according to some authors[10]. The route of infection is usually through the intestinal tract following ingestion of contaminated food products, as well as from mother to child either transplacentally or during childbirth. The importance of dietary and other environmental exposures cannot be underestimated[11]. Most reported cases of listeriosis occurred months to years following liver transplantation, but it may also occur in the early postoperative period[12]. Its principal manifestations include bacteremia[10,13] and meningitis[14,15], although endocarditis[16], peritonitis[17], hepatitis[18,19], epididymitis or orchitis[20] have been reported. *Listeria* meningitis can be associated with profound changes in mental status or focal neurologic signs from involvement of the brain stem (rhombencephalitis) or even presence of a brain abscess[15]. Clinically, bacteremia is almost always present and is usually instrumental in getting the diagnosis. Treatment with antibiotics including ampicillin or trimethoprim-sulfamethoxazole with or without an aminoglycoside has proven successful in the majority of the cases.

Five cases of listeriosis following liver transplantation have been reported[14], four within 3 wk and one within 4 mo following transplantation. Rettally *et al*[10] reported a case of a patient presenting with *L. monocytogenes* bacteremia at 32 mo following orthotopic liver transplantation. The patient was successfully treated with 3 wk of intravenous treatment with ampicillin and vancomycin. In the case reported by Avery *et al*[16], the patient was receiving trimethoprim-sulfamethoxazole prophylaxis for *P. jiroveci* pneumonia until 7 mo post-transplant, at which time aerosolized pentamidine was substituted because of the concern about possible drug hepatotoxicity. Three months later, the patient was diagnosed with a tricuspid valve *L. monocytogenes* endocarditis. The patient was successfully treated with a total of 6 wk of ampicillin followed by penicillin therapy, with gentamicin administered for the first 4 wk of this course. Doses of her immunosuppressive medications were decreased. Bourgeois *et al*[18] reported the case of a liver transplant recipient who was diagnosed with *L. monocytogenes* acute hepatitis 8 mo after grafting. The patient made a full clinical recovery after therapy with ampicillin and gentamicin intravenously for 4 wk.

Legionella species infection in the liver transplant patient

Legionella species account for approximately 5% of cases of pneumonia in the general US population. Although more than 30 species have been described in the *Legionellae* family, 70% to 90% of infections are caused by *L. pneumophila*, particularly serogroups 1 and 6, followed by *L. micdadei*[21]. Aquatic habitats are considered the environmental reservoir for community and nosocomial acquired pneumonia[22]. Susceptible hosts include the elderly, cigarette smokers, individuals receiving immunosuppressive therapy, and organ transplant recipients[23]. Although community acquisition occurs, nosocomial *L. pneumonia* is more commonly reported in transplant patients (Figure 2). In solid organ recipients, infection often occurs early in the post-transplantation period or coincidentally with corticosteroid therapy for allograft rejection[22]. The radiographic findings of *L. pneumonia* in immunosuppressed patients can vary and include unilateral or bilateral dense, patchy, or nodular pulmonary infiltrates that can progress to cavitation.

The first case of infection with *Legionella* species in a liver transplant recipient was reported by Tokunaga *et al*[24] in 1992. *L. pneumophila*, serogroup 1, was identified by direct immunofluorescence in the lung and liver graft from a 2-mo-old infant who underwent orthotopic liver transplantation because of fulminant hepatic failure secondary to neonatal hepatitis. The patient died of respiratory failure due to this infection 22 d after transplantation despite treatment with erythromycin. Singh *et al*[25] described 3 adult liver transplant patients with evidence for Legionellosis acquired within 2 mo of surgical transplantation, including one case of *L. bozemanii* pneumonia, one case of *L. pneumophila* pericarditis, and one case of *L. pneumophila* pneumonia. In addition, the third case also had *L. micdadei* isolated from

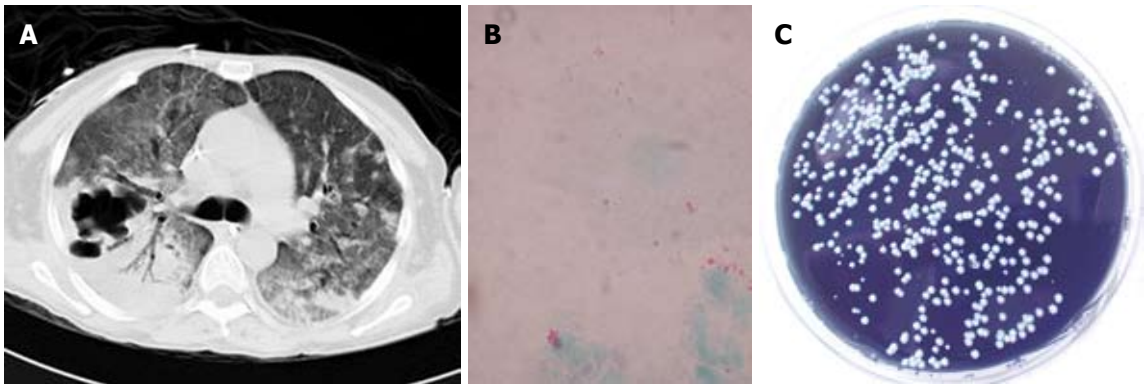

Figure 2 **A**: Chest CT scan showing multilobar pneumonic consolidation with cavitary lesions; **B**: Gimenez stain of a bronchoalveolar lavage specimen of the same patient showing small red coccobacilli; **C**: *Legionella pneumophila* was cultured on selective buffered charcoal yeast extract agar.

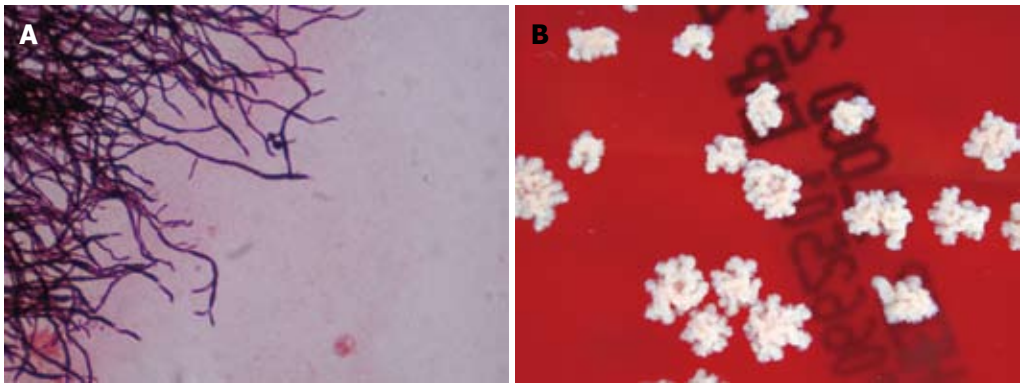

Figure 3 **A**: Gram stained smear of a subcutaneous lesion aspirate demonstrating branching and beaded filamentous appearance gram-positive rods; **B**: *Nocardia asteroides* was isolated in culture.

pleural fluid. All three cases responded to a combination of erythromycin and ciprofloxacin. A *L. pneumonia* nosocomial outbreak after liver transplantation has been described[26]. Patients presented with fever, nonspecific constitutional symptoms, and either unilateral or bilateral infiltrates developing 3 wk to 12 wk after transplantation. Treatment with either erythromycin (four cases) or ciprofloxacin (one case) was successful in three of five patients. A hospital-acquired pneumonia due to *L. parisiensis* was reported by Presti *et al*[27] in 1997. The diagnosis was made on the basis of clinical and radiological signs of pneumopathy in a liver transplant patient and was confirmed by microbiological data. The patient was successfully treated with erythromycin for 3 wk, allowing resolution of the pneumonia. Ernst *et al*[28] reported a liver transplant recipient with community acquired *L. micdadei* pneumonia 8 years after transplantation. The patient was successfully treated with a 3-wk course of ciprofloxacin. According to the authors, the predisposition in this case might in part be attributed to the need for a course of heightened immunosuppressive agents to treat an episode of acute organ rejection. Fraser *et al*[29] reported a liver transplant recipient who presented with cavitary pneumonia caused by *L. pneumophila* 7 years after transplantation. The patient required surgical resection and a 21-d course of therapy with levofloxacin for diagnosis and cure.

Legionella pneumonia is a rare complication of orthotopic liver transplantation in adults, and it remains a significant cause of morbidity and mortality in the susceptible host. Definitive diagnosis of *Legionella* pneumonia can be particularly elusive. As the urinary *Legionella* antigen is negative when other species or serogroups different than *L. pneumophila* serogroup 1 are implicated, examination of respiratory secretions in combination with immunofluorescent staining or specialized culture is required to establish the diagnosis. Erythromycin, rifampin, trimethoprim-sulfamethoxazole, doxycycline, clindamycin, and quinolones, alone or in combination, for 3 wk are effective treatments. Due to the risk of undesirable drug interaction of erythromycin with tacrolimus or cyclosporine, fluoroquinolone agents such as levofloxacin or ciprofloxacin may be the preferred treatment for legionellosis in transplant recipients.

Nocardia species infection in the liver transplant patient

Nocardia species are ubiquitous environmental saprophytes, living in soil, organic matter and water[30]. There are at least 12 species with *N. asteroides* complex (*N. asteroides* sensu strictu, *N. farcinica* and *N. nova*), with *N. brasiliensis*, *N. otitidiscaviarum* and *N. transvaliensis*[30] being the most important ones. *Nocardia* species are Gram-positive, variably acid-fast, actinomycetes with branching rods (Figure 3). The frequency of nocardial

infections in solid organ transplant recipients varies between 0.7% and 3% and has mostly been reported in heart, kidney and liver transplant recipients, and less frequently in lung transplantation[31]. In a recent study involving 1840 liver transplant recipients, only 2 (0.1%) had a Nocardia infection and only 1 of them had a disseminated infection consisting of bacteremia[31]. Disseminated nocardiosis is more frequent in cellular immunocompromised patients, and it is often a potentially life-threatening infection. It is endogenous (i.e., secondary to bloodstream spread) from a primary pulmonary infection[30]. However, it may result very rarely from a primary nonpulmonary (e.g. cutaneous, gastrointestinal) infection. The brain is the most frequent nonpulmonary site involved in disseminated nocardiosis[32]. A *N. farcinica disseminated (subcutaneous and neural)* infection has been described in a liver transplant recipient[33]. The patient presented in postoperative mo 3 with fever and pain in the lower leg. Ten days after admission, the patient developed neurological symptoms and 3 brain abscesses were detected in an MRI.

A case of *N. asteroides* osteomyelitis of the tibia accompanied by brain abscesses in a liver transplant recipient was recently described[34]. The majority of bone cases are presumed to be due to direct extension from local soft tissue infection. Imaging of the brain should be performed in all cases of nocardiosis affecting a liver transplant recipient, since central nervous system involvement may be present even in the absence of neurological findings. Pulmonary involvement should also be excluded.

An optimal therapeutic approach has not been well established, especially in the disseminated forms. It is debated whether invasive resection or aspiration of the CNS lesions are necessary[2,35,36]. Some authors recommend an early biopsy of the lesions to achieve specific identification, even in cases where an extra-cranial focus of infection is found[37]. However, there are some reports that suggest that brain surgery is not always needed[35,36]. Sulfonamides are the drugs of choice for treatment of nocardiosis; however, there are an increasing number of reports of resistance to these agents[38]. The length of therapy in the treatment of nocardial infections in the transplant patient is debated. Some authors suggest extending it for 9 mo to 12 mo if there is CNS involvement[37]. The clinical use of other drugs should be supported by susceptibility testing. Linezolid is an oxazolidinone with activity against all of the clinically relevant species of Nocardia[39], which has been shown to be an effective alternative for the treatment of nocardiosis, especially for the CNS forms[34]. Lewis *et al* described a case in which minocycline was used for 12 mo with a good response. Doxycycline and minocycline[34,40] may be attractive options as rescue therapy in those patients in which other treatments failed.

Rhodococcus equi infection in the liver transplant patient

Rhodococcus equi is an intracellular gram-positive, aerobic, nonmotile, non-spore-forming bacillus that is an increasingly important opportunistic respiratory pathogen in immunocompromised hosts. Impairment of cell-mediated immunity is the most important risk factor for infection with *R. equi* in humans[41]. Several cases have been described in patients with immunosuppression due to either human immunodeficiency infection, therapy for neoplastic disorders, or kidney and heart transplantation. 15 patients with a *R. equi* infection following solid-organ transplantation have been described in the literature[42-45]. In all patients, rhodococcal infection presented late after transplantation (median, 4 years). *R. equi* resides in the soil and humans acquire the infection through the respiratory tract. Exposure to farm animals was reported in only two cases; in four cases contact with contaminated soil or manure was considered a likely infectious source. Thirteen of 15 patients had pulmonary and/or pleural involvement. Soft-tissue infections were common in this population. Most patients received erythromycin and/or ciprofloxacin in combination therapy, which was generally associated with a successful outcome. Recurrent disease was observed after initial treatment with imipenem and tobramycin and in patients receiving monotherapy.

Sabater *et al*[43] reported the first case of *R. equi* infection in a liver transplant recipient. The patient was diagnosed with two subcutaneous abscesses on his left arm and an asymptomatic necrotizing bilateral pneumonia 28 mo following transplantation. The patient had been intensively immunosuppressed and working with calf manure. He was successfully treated with a combination of erythromycin, ciprofloxacin, and rifampicin. A case of vertebral osteomyelitis due to *R. equi* in a liver transplant recipient 7 mo after transplantation was reported by Fischer *et al*[42]. The patient was initially diagnosed with a recurrent pneumonia and a pleura-based lung abscess and subsequently developed osteomyelitis of the lower thoracic spine. Drainage of the paraspinal abscess and removal of the infected bone was performed while he was being treated with erythromycin and imipenem. Postoperatively, the patient received intravenous imipenem, vancomycin, and erythromycin for 14 d and then oral clarithromycin and rifabutin. Schilz *et al*[44] reported a case of a liver transplant patient with a pulmonary nodule caused by *R. equi* that followed a benign clinical course and resolved spontaneously.

Although solid-organ transplant recipients are rarely affected, *R. equi* must be included in the differential diagnosis of recurrent pneumonia or lung abscess in liver transplant recipients. Metastatic spread of infection is common, and diagnosis of pulmonary rhodococcal infection should prompt a search for additional involvement of extra-pulmonary sites. Monotherapy must be considered insufficient for transplant patients and surgery may be helpful in some cases.

Other late bacterial infections in the liver transplant patient

Bartonella henselae, the etiologic agent of cat-scratch

disease, may cause a spectrum of illness in both immunocompetent and immunocompromised hosts. Disseminated infections caused by *Bartonella* species have been reported infrequently in solid organ transplant recipients. Humar *et al*[46] reported a case of a liver transplant recipient who presented 4 years later with fever of unknown origin, and was found to have a granulomatous hepatitis of the transplant allograft with a *Bartonella* species. Diagnosis was performed by serology (immunofluorescent antibody test). The patient completed a successful 4 wk course of azithromycin.

Apalsch *et al*[47] described a case of a disseminated cat-scratch disease in a 12-year-old liver transplant recipient with fever and lymphadenopathy. Granulomatous inflammation was shown in liver and lymph node biopsy specimens.

Because this organism may be difficult to grow in culture, serological and molecular tests are important for diagnosis. Antimicrobial therapy can result in prompt resolution of illness and usually consists of a macrolide or tetracycline derivative. However, the optimal antibiotic and duration of therapy for disseminated disease in immunocompromised patients is unknown.

Three cases of *Mycoplasma hominis* infections have been reported in the literature. Jacobs *et al*[48] reported the case of a recipient of liver transplantation with a postsurgical infection and Vogel *et al*[49] reported two patients with extragenital infections.

Clostridium difficile remains a significant complication in liver transplant recipients. In this patient population, *C. difficile* diarrhea may be more difficult to diagnose and may have a more complicated clinical course than in non-immunocompromised patients. Although the prevalence of *C. difficile* infection is usually the highest during the early post-transplant period, when immunosuppression is the highest, Albright *et al*[50] described 3 cases of late onset *C. difficile* infection (2, 3 and 5 years after transplantation). Nevertheless, the prognosis is good in most cases with timely diagnosis and treatment.

CONCLUSION

In summary, late opportunistic bacterial infections following liver transplantation are rare. Trimethoprim-sulfamethoxazole taken daily or three times weekly in patients without an allergy to sulfonamides for the first 4 to 12 mo posttransplant primarily reduce the risk of *P. jiroveci* pneumonia and probably also helps to prevent infections with *L. monocytogenes*, *N. asteroides*, or *Toxoplasma gondii*. Early detection and treatment of these late bacterial infections is the key to obtaining a better prognosis in liver transplant patients.

REFERENCES

1 **Roberts MS**, Angus DC, Bryce CL, Valenta Z, Weissfeld L. Survival after liver transplantation in the United States: a disease-specific analysis of the UNOS database. *Liver Transpl* 2004; **10**: 886-897

2 **Fishman JA**. Infection in solid-organ transplant recipients. *N Engl J Med* 2007; **357**: 2601-2614

3 **Barkholt L**, Ericzon BG, Tollemar J, Malmborg AS, Ehrnst A, Wilczek H, Andersson J. Infections in human liver recipients: different patterns early and late after transplantation. *Transpl Int* 1993; **6**: 77-84

4 **Torbenson M**, Wang J, Nichols L, Jain A, Fung J, Nalesnik MA. Causes of death in autopsied liver transplantation patients. *Mod Pathol* 1998; **11**: 37-46

5 **Kusne S**, Dummer JS, Singh N, Iwatsuki S, Makowka L, Esquivel C, Tzakis AG, Starzl TE, Ho M. Infections after liver transplantation. An analysis of 101 consecutive cases. *Medicine* (Baltimore) 1988; **67**: 132-143

6 **Garbino J**, Romand JA, Pittet D, Giostra E, Mentha G, Suter P. Infection and rejection in liver transplant patients: a 10-year Swiss single-centre experience. *Swiss Med Wkly* 2005; **135**: 587-593

7 **Rubin RH**. Prevention of infection in the liver transplant recipient. *Liver Transpl Surg* 1996; **2**: 89-98

8 **van den Berg AP**, Klompmaker IJ, Haagsma EB, Peeters PM, Meerman L, Verwer R, The TH, Slooff MJ. Evidence for an increased rate of bacterial infections in liver transplant patients with cytomegalovirus infection. *Clin Transplant* 1996; **10**: 224-231

9 **Tappero JW**, Schuchat A, Deaver KA, Mascola L, Wenger JD. Reduction in the incidence of human listeriosis in the United States. Effectiveness of prevention efforts? The Listeriosis Study Group. *JAMA* 1995; **273**: 1118-1122

10 **Rettally CA**, Speeg KV. Infection with Listeria monocytogenes following orthotopic liver transplantation: case report and review of the literature. *Transplant Proc* 2003; **35**: 1485-1487

11 **Fishman JA**, Rubin RH. Infection in organ-transplant recipients. *N Engl J Med* 1998; **338**: 1741-1751

12 **Limaye AP**, Perkins JD, Kowdley KV. Listeria infection after liver transplantation: report of a case and review of the literature. *Am J Gastroenterol* 1998; **93**: 1942-1944

13 **Lorber B**. Listeriosis. *Clin Infect Dis* 1997; **24**: 1-9; quiz 10-11

14 **Mizuno S**, Zendejas IR, Reed AI, Kim RD, Howard RJ, Hemming AW, Schain DC, Soldevila-Pico C, Firpi RJ, Fujita S. Listeria monocytogenes following orthotopic liver transplantation: central nervous system involvement and review of the literature. *World J Gastroenterol* 2007; **13**: 4391-4393

15 **Paya CV**, Hermans PE. Bacterial infections after liver transplantation. *Eur J Clin Microbiol Infect Dis* 1989; **8**: 499-504

16 **Avery RK**, Barnes DS, Teran JC, Wiedemann HP, Hall G, Wacker T, Guth KJ, Frost JB, Mayes JT. Listeria monocytogenes tricuspid valve endocarditis with septic pulmonary emboli in a liver transplant recipient. *Transpl Infect Dis* 1999; **1**: 284-287

17 **Chapoutot C**, Perney P, Pageaux GP, Lefebvre A, Souche B, Blanc F. [Spontaneous Listeria monocytogenes peritoneal infection complicating hepatic transplantation] *Gastroenterol Clin Biol* 1996; **20**: 700-702

18 **Bourgeois N**, Jacobs F, Tavares ML, Rickaert F, Deprez C, Liesnard C, Moonens F, Van de Stadt J, Gelin M, Adler M. Listeria monocytogenes hepatitis in a liver transplant recipient: a case report and review of the literature. *J Hepatol* 1993; **18**: 284-289

19 **Vargas V**, Aleman C, de Torres I, Castells L, Gavalda J, Margarit C, Esteban R, Guardia J. Listeria monocytogenes-associated acute hepatitis in a liver transplant recipient. *Liver* 1998; **18**: 213-215

20 **von Schnakenburg C**, Hinrichs B, Fuchs J, Kardorff R. Post-transplant epididymitis and orchitis following Listeria monocytogenes septicaemia. *Pediatr Transplant* 2000; **4**: 156-158

21 **Nguyen MH**, Stout JE, Yu VL. Legionellosis. *Infect Dis Clin North Am* 1991; **5**: 561-584

22 **Winston DJ**, Seu P, Busuttil RW. Legionella pneumonia in liver transplant recipients. *Transplantation* 1998; **66**: 410

23 **Jensen WA**, Rose RM, Hammer SM, Jenkins RL, Bothe A

Jr, Benotti PN, Dzik WH, Costello P, Khettry U, Trey C. Pulmonary complications of orthotopic liver transplantation. *Transplantation* 1986; **42**: 484-490
24 **Tokunaga Y**, Concepcion W, Berquist WE, Cox KL, Wiviott LD, Garcia-Kennedy R, Itasaka H, Nakazato P, Esquivel CO. Graft involvement by Legionella in a liver transplant recipient. *Arch Surg* 1992; **127**: 475-477
25 **Singh N**, Muder RR, Yu VL, Gayowski T. Legionella infection in liver transplant recipients: implications for management. *Transplantation* 1993; **56**: 1549-1551
26 **Ampel NM**, Wing EJ. Legionella infection in transplant patients. *Semin Respir Infect* 1990; **5**: 30-37
27 **Lo Presti F**, Riffard S, Vandenesch F, Reyrolle M, Ronco E, Ichai P, Etienne J. The first clinical isolate of Legionella parisiensis, from a liver transplant patient with pneumonia. *J Clin Microbiol* 1997; **35**: 1706-1709
28 **Ernst A**, Gordon FD, Hayek J, Silvestri RC, Koziel H. Lung abcess complicating Legionella micdadei pneumonia in an adult liver transplant recipient: case report and review. *Transplantation* 1998; **65**: 130-134
29 **Fraser TG**, Zembower TR, Lynch P, Fryer J, Salvalaggio PR, Yeldandi AV, Stosor V. Cavitary Legionella pneumonia in a liver transplant recipient. *Transpl Infect Dis* 2004; **6**: 77-80
30 **Lerner PI**. Nocardiosis. *Clin Infect Dis* 1996; **22**: 891-903; quiz 904-905
31 **Peleg AY**, Husain S, Qureshi ZA, Silveira FP, Sarumi M, Shutt KA, Kwak EJ, Paterson DL. Risk factors, clinical characteristics, and outcome of Nocardia infection in organ transplant recipients: a matched case-control study. *Clin Infect Dis* 2007; **44**: 1307-1314
32 **McNeil MM**, Brown JM, Magruder CH, Shearlock KT, Saul RA, Allred DP, Ajello L. Disseminated Nocardia transvalensis infection: an unusual opportunistic pathogen in severely immunocompromised patients. *J Infect Dis* 1992; **165**: 175-178
33 **Shin N**, Sugawara Y, Tsukada K, Tamura S, Akamatsu N, Okugawa S, Koike K, Kikuchi K, Makuuchi M. Successful treatment of disseminated Nocardia farcinica infection in a living-donor liver transplantation recipient. *Transpl Infect Dis* 2006; **8**: 222-225
34 **del Pozo JL**, Herrero JI, Manubens A, Garcia-Quetglas E, Yuste JR, Alfonso M, Leiva J, Quiroga J, Azanza JR. Disseminated Nocardia asteroides infection presenting as an atraumatic leg fracture in a liver transplant recipient. *Liver Transpl* 2008; **14**: 257-258
35 **Fihman V**, Bercot B, Mateo J, Losser MR, Raskine L, Riahi J, Loirat P, Pors MJ. First successful treatment of Nocardia farcinica brain abscess with moxifloxacin. *J Infect* 2006; **52**: e99-e102
36 **Vigano SM**, Edefonti A, Ferraresso M, Ranzi ML, Grossi P, Righini A, Rusconi R, Santambrogio L, Ghio L. Successful medical treatment of multiple brain abscesses due to Nocardia farcinica in a paediatric renal transplant recipient. *Pediatr Nephrol* 2005; **20**: 1186-1188
37 **Fleetwood IG**, Embil JM, Ross IB. Nocardia asteroides cerebral abscess in immunocompetent hosts: report of three cases and review of surgical recommendations. *Surg Neurol* 2000; **53**: 605-610
38 **Khan Z**, Al-Sayer H, Chugh TD, Chandy R, Provost F, Boiron P. Antimicrobial susceptibility profile of soil isolates of Nocardia asteroides from Kuwait. *Clin Microbiol Infect* 2000; **6**: 94-98
39 **Brown-Elliott BA**, Ward SC, Crist CJ, Mann LB, Wilson RW, Wallace RJ Jr. In vitro activities of linezolid against multiple Nocardia species. *Antimicrob Agents Chemother* 2001; **45**: 1295-1297
40 **Lewis KE**, Ebden P, Wooster SL, Rees J, Harrison GA. Multi-system Infection with Nocardia farcinica-therapy with linezolid and minocycline. *J Infect* 2003; **46**: 199-202
41 **Prescott JF**. Rhodococcus equi: an animal and human pathogen. *Clin Microbiol Rev* 1991; **4**: 20-34
42 **Fischer L**, Sterneck M, Albrecht H, Krupski G, Polywka S, Rogiers X, Broelsch CE. Vertebral osteomyelitis due to Rhodococcus equi in a liver transplant recipient. *Clin Infect Dis* 1998; **26**: 749-752
43 **Sabater L**, Andreu H, Garcia-Valdecasas JC, Moreno A, Vila J, Rimola A, Grande L, Navasa M, Visa J, Rodes J. Rhodococcus equi infection after liver transplantation. *Transplantation* 1996; **61**: 980-982
44 **Schilz RJ**, Kavuru MS, Hall G, Winkelman E. Spontaneous resolution of rhodococcal pulmonary infection in a liver transplant recipient. *South Med J* 1997; **90**: 851-854
45 **Scott MA**, Graham BS, Verrall R, Dixon R, Schaffner W, Tham KT. Rhodococcus equi--an increasingly recognized opportunistic pathogen. Report of 12 cases and review of 65 cases in the literature. *Am J Clin Pathol* 1995; **103**: 649-655
46 **Humar A**, Salit I. Disseminated Bartonella infection with granulomatous hepatitis in a liver transplant recipient. *Liver Transpl Surg* 1999; **5**: 249-251
47 **Apalsch AM**, Nour B, Jaffe R. Systemic cat-scratch disease in a pediatric liver transplant recipient and review of the literature. *Pediatr Infect Dis J* 1993; **12**: 769-774
48 **Jacobs F**, Van de Stadt J, Gelin M, Nonhoff C, Gay F, Adler M, Thys JP. Mycoplasma hominis infection of perihepatic hematomas in a liver transplant recipient. *Surgery* 1992; **111**: 98-100
49 **Vogel U**, Luneberg E, Kuse ER, Neulinger AL, Frosch M. Extragenital Mycoplasma hominis infection in two liver transplant recipients. *Clin Infect Dis* 1997; **24**: 512-513
50 **Albright JB**, Bonatti H, Mendez J, Kramer D, Stauffer J, Hinder R, Michel JA, Dickson RC, Hughes C, Nguyen J, Chua H, Hellinger W. Early and late onset Clostridium difficile-associated colitis following liver transplantation. *Transpl Int* 2007; **20**: 856-866

S- Editor Li DL **L- Editor** Lutze M **E- Editor** Lin YP

Online Submissions: wjg.wjgnet.com
wjg@wjgnet.com
doi:10.3748/wjg.14.4984

World J Gastroenterol 2008 August 28; 14(32): 4984-4991
World Journal of Gastroenterology ISSN 1007-9327
© 2008 The WJG Press. All rights reserved.

EDITORIAL

Calcium signaling and T-type calcium channels in cancer cell cycling

James T Taylor, Xiang-Bin Zeng, Jonathan E Pottle, Kevin Lee, Alun R Wang, Stephenie G Yi, Jennifer A S Scruggs, Suresh S Sikka, Ming Li

James T Taylor, Stephenie G Yi, Jennifer A S Scruggs, Department of Pharmacology, Tulane University Health Sciences Center, New Orleans LA 70112, United States
Xiang-Bin Zeng, Suresh S Sikka, Department of Urology, Tulane University Health Sciences Center, New Orleans LA 70112, United States
Jonathan E Pottle, Kevin Lee, Ming Li, Department of Physiology, Tulane University Health Sciences Center, New Orleans LA 70112, United States
Alun R Wang, Department of Pathology, Tulane University Health Sciences Center, New Orleans LA 70112, United States
Author contributions: Taylor JT and Li M wrote the paper; Zeng XB, Lee K, Yi SG, Scruggs JAS and Sikka SS searched the literature; Pottle JE and Wang AR critically evaluated and edited the manuscript.
Correspondence to: Ming Li, PhD, Associate Professor, Department of Physiology, Tulane University Health Sciences Center, New Orleans LA 70112, United States. mli@tulane.edu
Telephone: +1-504-9888207
Received: February 27, 2008 Revised: May 1, 2008
Accepted: May 8, 2008
Published online: August 28, 2008

Abstract

Regulation of intracellular calcium is an important signaling mechanism for cell proliferation in both normal and cancerous cells. In normal epithelial cells, free calcium concentration is essential for cells to enter and accomplish the S phase and the M phase of the cell cycle. In contrast, cancerous cells can pass these phases of the cell cycle with much lower cytoplasmic free calcium concentrations, indicating an alternative mechanism has developed for fulfilling the intracellular calcium requirement for an increased rate of DNA synthesis and mitosis of fast replicating cancerous cells. The detailed mechanism underlying the altered calcium loading pathway remains unclear; however, there is a growing body of evidence that suggests the T-type Ca^{2+} channel is abnormally expressed in cancerous cells and that blockade of these channels may reduce cell proliferation in addition to inducing apoptosis. Recent studies also show that the expression of T-type Ca^{2+} channels in breast cancer cells is proliferation state dependent, i.e. the channels are expressed at higher levels during the fast-replication period, and once the cells are in a non-proliferation state, expression of this channel is minimal. Therefore, selectively blocking calcium entry into cancerous cells may be a valuable approach for preventing tumor growth. Since T-type Ca^{2+} channels are not expressed in epithelial cells, selective T-type Ca^{2+} channel blockers may be useful in the treatment of certain types of cancers.

© 2008 The WJG Press. All rights reserved.

Key words: T-type calcium channels; Cancer; Cell cycle; Calcium

Peer reviewers: Anna S Gukovskaya, Professor, VA Greater Los Angeles Health Care System, University of California, Los Angeles, 11301 Wilshire Blvd, Los Angeles 91301, United States; Zong-Jie Cui, PhD, Professor, Institute of Cell Biology, Beijing Normal University, 19 Xinjiekou Waidajie, Beijing 100875, China

Taylor JT, Zeng XB, Pottle JE, Lee K, Wang AR, Yi SG, Scruggs JAS, Sikka SS, Li M. Calcium signaling and T-type calcium channels in cancer cell cycling. *World J Gastroenterol* 2008; 14(32): 4984-4991 Available from: URL: http://www.wjgnet.com/1007-9327/14/4984.asp DOI: http://dx.doi.org/10.3748/wjg.14.4984

INTRODUCTION

Calcium is an essential signal transduction element involved in the regulation of many eukaryotic cellular functions including cell cycle progression[1]. Control of intracellular Ca^{2+} ($[Ca^{2+}]_i$) is crucial for the orderly progression of the cell cycle and plays a vital role in the regulation of cell proliferation and growth[2]; however, excessive calcium or loss of control in calcium signaling can lead to cell death[3]. Therefore, careful control of calcium signaling is required for cell survival. Upon stimulation, the intracellular calcium concentration can increase dramatically, often reaching micromolar amounts. This increase in cytoplasmic calcium can occur *via* release from intracellular stores or influx through a variety of plasma membrane ion channels. Voltage-gated and ligand-gated Ca^{2+} channels in the plasma membrane, along with ryanodine receptors (RynR) and inositol triphosphate receptors (InsP3R) at the intracellular calcium stores, provide fluxes of Ca^{2+} to the cytoplasm.

The driving force for calcium entry is the result of an electrochemical gradient between the extracellular concentration (1.3×10^{-3}-2×10^{-3} mol/L) of calcium and the intracellular concentration (< 10^{-8} mol/L).

In general, non-excitable tissues, including the epithelium, do not express voltage gated Ca^{2+} channels. This is partly because the ranges of membrane potential changes in these cells are too small to activate these channels. However, recent studies show that T-type Ca^{2+} channels are expressed in cancerous cells, although their functional role has only begun to be investigated. Furthermore, there is a growing body of evidence suggesting that tumor cell proliferation can be halted by the use of ion channel blockers. T-type calcium channels are a class of calcium permeable low voltage activated (LVA) ion channels which open after small depolarizations of the membrane. Molecular biology has revealed the existence of three different T-type calcium channel subunits, the α_{1G}, α_{1H} and α_{1I}. The α_1 designation refers to the channels primary ion conducting protein, which consists of four domains each containing six transmembrane segments. There are other auxiliary calcium channel subunits; however, the LVA alpha1 subunits can function as stand alone complexes. The unique low voltage dependent activation/inactivation and slow deactivation of T-type Ca^{2+} channels indicate that these channels may play a physiological role in carrying depolarizing current at low membrane potentials. Therefore, these channels may play a direct role in regulating $[Ca^{2+}]_i$, especially in non-excitable tissues, including some cancerous cells. At low voltages, T-type Ca^{2+} channels are known to mediate a phenomenon known as "window current"[4-6]. The term "window" refers to the voltage overlap between the activation and steady state inactivation at low or resting membrane potentials. As a result, there is a sustained inward calcium current carried by a small portion of channels that are not completely inactivated. Window current allows T-type Ca^{2+} channels to regulate Ca^{2+} homeostasis under non-stimulated or resting membrane conditions[7]. The most direct evidence of T-type Ca^{2+} channel mediated Ca^{2+} window current is from a study conducted in HEK-293 cells expressing the T-type isoform α_{1G}[8], which demonstrated window current peaked at -48 mV. Membrane potentials around this voltage can occur in un-stimulated non-excitable cells.

CALCIUM SIGNALING AND CELL CYCLING

As shown in Figure 1, the cell cycle is divided into four stages: G1, S, G2 and M. DNA replication occurs in the S phase and mitosis occurs in the M phase. Cells must pass through a restriction point between the G1 and S phases before continuing proliferation; otherwise, they exit the cell cycle to G0 and differentiate or terminate. Another checkpoint in the cell cycle is between phases G2 and M. For cells to pass through these various points, one of the most prominent messengers is Ca^{2+}, as demonstrated by the induction of mitotic events by injection of exogenous Ca^{2+} in a fertilized egg model[9]. Steinhardt *et al*[10] observed transient increases in cytosolic Ca^{2+} during late G1, prior to the initiation of the S phase and during G2 before entry into the M phase that were dependent upon external physiological Ca^{2+} concentration. In the transition from G1 to S phase, cells require external Ca^{2+} in addition to functional calcium channels in order to directly or indirectly trigger a myriad of critical downstream enzymes such as thymidine kinase, thymidylate synthase, ribonucleotide reductase and DNA polymerase and begin DNA replication. In the transition from G2 to M phase, Ca^{2+} flashes activate enzymes that are critical for microtubule rearrangement and microfilament contraction. In order to confirm the significant role that Ca^{2+} plays in the cell cycle, researchers have blocked the progression of the cell cycle *via* injection of Ca^{2+} chelators into the same fertilized eggs[11]. The influence of Ca^{2+} channels on cell growth is clearly demonstrated in pharmacological studies using Ca^{2+} channel antagonists. In a study by Zeitler *et al*[12], various Ca^{2+} channel blockers, including verapamil, nifedipine, diltiazem and isradipine, caused G0/G1 cell-cycle arrest in growth factor induced human umbilical arterial endothelial cells (HUAEC) during proliferation. The Ca^{2+} signal has also been linked to activation of immediate early genes (e.g. *c-fos*) that are responsible for inducing resting cells in G0 to re-enter the cell cycle, an attribute most frequently up-regulated in rapidly proliferating cells[10].

At the end of the cycle, cells can undergo suicide through a process known as apoptosis or active cell death, which is a genetic program specifically designed to shape organs during development and adjust cell population levels to appropriate values. The key players of apoptosis are a killer Ca^{2+} surge and the nuclear membrane Ca^{2+} activated endonuclease, which terminates the cell by cutting chromatin into fragments (Figure 1). Underlying mechanisms for Ca^{2+} mediated effects in cell proliferation may involve a wide variety of other intracellular signal transduction pathways such as G-proteins, protein kinase C (PKC), calmodulin, m-calpain, MAP kinase, phospholipase A2 and others[13,14]. Although the details of each pathway is beyond the scope of this discussion, there are several notable mechanisms that act to amplify $[Ca^{2+}]_i$ for activation of gene transcription or cell migration. One mechanism is the hydrolysis of inositol lipids by the enzyme phospholipase C, the activation of which is itself dependent on an initial rise in $[Ca^{2+}]_i$, producing diacylglycerol (DAG) and InsP3. Resulting from the activation of G protein-linked or tyrosine-kinase linked receptors[15], InsP3 thus causes a form of Ca^{2+} dependent Ca^{2+} release from intracellular stores. Described as "calcium puffs", which propagate into a local or global Ca^{2+} signal, this Ca^{2+} release is important for converting the cytoplasm into an excitable medium that can support repetitive Ca^{2+} oscillations[16]. The resulting amplification of $[Ca^{2+}]_i$ contributes to the signal for mitosis and DNA synthesis.

In addition to InsP3, sensory proteins also play

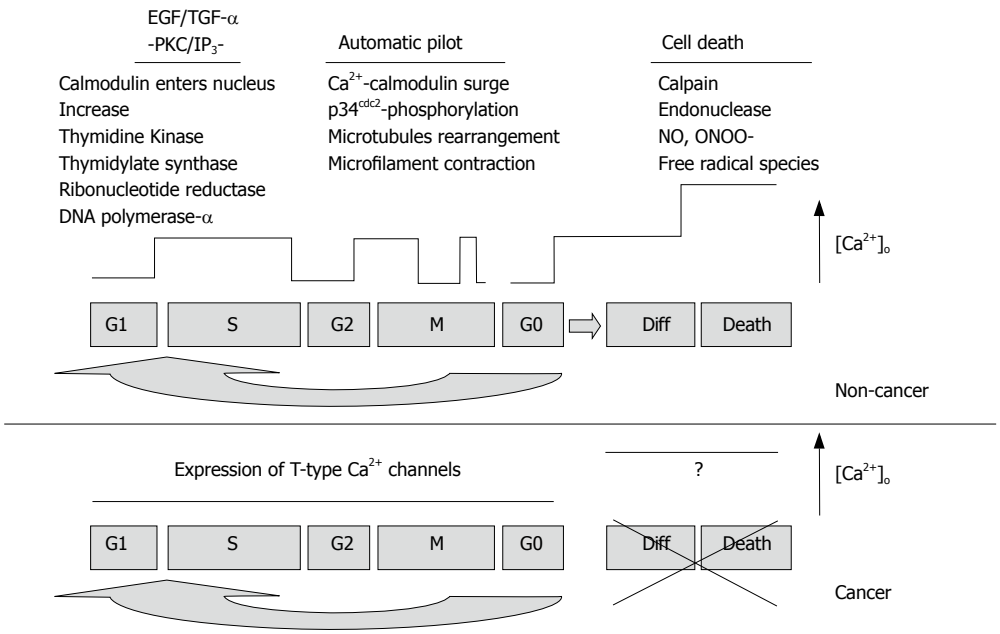

Figure 1 Ca^{2+} signaling pathways differ between cancerous and non-cancerous cells (adapted from [23]).

a role in maintaining the calcium signaling system. Calmodulin is a Ca^{2+} binding protein that acts as a Ca^{2+} sensor in the cell cycle. High expression of calmodulin has been observed during the S phase and mitosis, while inhibition of its activity by administration of calmodulin monoclonal antibodies is shown to block DNA synthesis[17]. Another sensory mechanism occurs through an extracellular calcium ion concentration sensing receptor (CaR) and calbindin, a high affinity Ca^{2+}-binding regulatory protein belonging to the same family as calmodulin. Parkash *et al* observed that CaR plays a role in sensing and responding to changes in extracellular Ca^{2+} ($[Ca^{2+}]_o$). Upon activation by increased $[Ca^{2+}]_o$, CaR interacts with phospholipase C (PLC) *via* G proteins to produce DAG and InsP3[18]. The subsequent increase in $[Ca^{2+}]_i$ is regulated by calbindin, which was previously found to bind to L-type HVA Ca^{2+} channels in pancreatic islets-cells[19]. It has also been shown that calbindin/CaR co-localization occurs in the estrogen receptor positive breast cancer cell line MCF-7[20]. Activated CaR also increases parathyroid hormone related protein (PTHrP), which appears to exacerbate cell metastasis in MCF-7 cells[21]. A study by Lewalle *et al*[22] shows that an increase in $[Ca^{2+}]_i$ mediates tumor cell transendothelial migration *in vitro*. By associating the upregulation of these mechanisms in cancerous cells, increases in $[Ca^{2+}]_i$ are shown to provide an important and pronounced signal for cell growth.

Calcium signaling in cancerous cells, however, uses an altered pathway during cell cycling[23]. Whitfield has shown that colon carcinomas undergoing carcinogenesis, which have lost their tumor-suppressing genes, have dramatically altered calcium signal mechanisms, and have ignored normal calcium-dependent restrictions by overproducing calcium-binding signal proteins (Figure 1)[18]. Attempts to terminate the mutant cells with Ca^{2+} signal surges are futile, as the cells are no longer responsive to Ca^{2+} signals: instead, they produce and respond to their own renegade growth factors. Ca^{2+} and the signaling enzymes that are directly activated by Ca^{2+} or by Ca^{2+}-binding proteins play crucial roles in most cell signals and programs and must be understood and implemented in any future differentiation therapies. Since cancerous cells express T-type Ca^{2+} channels, it is possible that these channels provide an altered Ca^{2+} influx pathway in responding to the increasing demand of Ca^{2+} during rapid cell proliferation.

T-TYPE CALCIUM CHANNELS IN CANCEROUS CELL PROLIFERATION

T-type Ca^{2+} channels and non-cancerous cell cycling

The function of regulating Ca^{2+} homeostasis may allow T-type Ca^{2+} channels to play an important role in controlling cell proliferation and differentiation in many tissues. In primary cultured rat aortic smooth muscle cells, a T-type Ca^{2+} current was found to be present in cells during the G1 and S phases but decreased or absent in all other phases of the cell cycle[24-26]. It was shown that cultured smooth muscle cells exhibited an increased T-type Ca^{2+} current during stages of proliferation and this current decreased as the cells became confluent or when they came into contact with one another[27]. T-type Ca^{2+} currents are also present in freshly dissociated or 1-2 d cultured neonatal rat ventricular myocytes when they are still able to proliferate, but are not observed in cells cultured greater than 3 d[28]. Likewise, older tissues under pathological conditions, such as cardiomyopathic hamster heart[29], hypertrophied adult feline left ventricular myocytes[30], and rat neointimal formation after vascular injury[31] have increased T-type Ca^{2+} current activity. These studies suggest that T-type calcium

Table 1 Cancerous cells that expresses T-type Ca^{2+} channels

Cell type	Cell line	T-type isoform	Reference
Breast carcinoma	MCF-7, MDA-435	α_{1G}, α_{1H}	[33-36]
	MDA-231, MDA-361 MB-468, MB-474, BT-20, CAMA1, SKBR-3	α_{1G}	[34-36]
Neuroblastoma	SK-N-SH,	α_{1G}	[34,37-40]
	NG 108-15, SK-N-MC		
	N1E-115	α_{1G}, α_{1H}	[37]
Retinoblastoma	Y-79, WERI-Rb1	α_{1G}, α_{1H}, α_{1I}	[41,42]
Glioma	Primary (biopsy)	α_{1G}	[36]
	U87-MG	α_{1G}, α_{1H}	[37]
Prostate carcinoma	TSU-PRL, DUPRO	α_{1G}	[35,43]
	LNCaP	α_{1H}	[1,34,35]
	PC-3, DU-145	α_{1G}, α_{1H}	[34,35]
Esophageal carcinoma	TE1, TE10, TE12, KYSE150, KYSE180, KYSE450	α_{1H}	[44]
	SKGT4, TE3, TE7, KYSE70	α_{1G}, α_{1H}	[44]
	COLO-680N, SEG1, TE8, TE11, KYSE30, KYSE410, KYSE510	α_{1G}, α_{1H}, α_{1I}	[44]
Fibrosarcoma	HT1080	α_{1G}	[45]
Colorectal carcinoma	Caco2, DLD-1, Lovo, SW837	α_{1G}	[35]
Pheochromocytoma	MPC 9/3L	α_{1G}	[46]
	PC-12	α_{1H}	[47]
Adenocarcinoma	H295R	α_{1H}	[48]
Insulinoma	INS-1	α_{1G}	[49]



Figure 2 T-type Ca^{2+} channel expression in human malignant breast cancer tissue.

Table 2 Q-RT-PCR detected T-type Ca^{2+} channels expression in non-confluent cultures of breast cancer cell lines

Cell types	T-channels	Non-confluent Δct	Confluent Δct
MDA-MB-231	α_{1H}	14.28 ± 0.16	NA, ct > 40
MDA-MB-231	α_{1G}	9.45 ± 0.87	NA, ct > 40
MCF-7	α_{1H}	13.43 ± 0.24	NA, ct > 40
MCF-7	α_{1G}	7.32 ± 0.3	NA, ct > 40

NA: Not applicable.

channels may play a vital role in regulating proliferation under specialized conditions.

T-type Ca^{2+} channels are broadly expressed in tumor cells

If these channels do participate in proliferation under abnormal conditions, cells must first maintain control of the expression of α_{1G} T-type Ca^{2+} channel messenger RNA in order to prevent functional expression of the protein. Otherwise, loss of this control may lead to aberrant cell growth and tumor progression. A recent study revealed the presence of T-type calcium channel mRNA expressed in breast tumor tissue that was removed from human biopsies (Figure 2)[32]. In this case, the tumor was later diagnosed as malignant and estrogen receptor positive by pathological examination. Expression of these channels in tumor cells has been reported broadly, as shown in Table 1[1,33-49]. For example, MCF-7 cells, a cell line derived from a human breast adenocarcinoma that has been shown to express α_{1G} and α_{1H} T-type Ca^{2+} channel mRNA and current transiently (Table 2)[33]. T-type Ca^{2+} channels have also been suggested as a potential therapeutic target for intracranial tumor and prostate cancer. Mibefradil was found to inhibit human astrocytoma (U87-MG) and neuroblastoma (N1E-115) proliferation and that over-expression of T-type Ca^{2+} channel protein doubled the proliferation rate while antisense treatment reduced the proliferation rate of these cells[37]. Human prostate cancer epithelial cells (LNCap) have also been shown to express increased T-type Ca^{2+} channel (α_{1H}) current and mRNA. Similarly, increased T-type Ca^{2+} channel protein doubled proliferation while antisense treatment reduced the proliferation rate of these cells[1,43]. It was also shown that these channels were found to regulate intracellular calcium in LNCap cells. Another study examined the role of T-type Ca^{2+} channels in esophageal carcinoma cell proliferation; these data suggested that T-type Ca^{2+} channels may have a functional role in proliferation that can be reduced by inhibition of T-type Ca^{2+} channels[44]. Given the role that T-type calcium channels play in cell cycle progression and the relatively recent findings that show the functional expression of these channels in many different cancerous cell types, researchers have now been given the opportunity to investigate the potential of an entirely new target in the fight against cancer. Developing new compounds that target these proteins may hold the key to controlling certain types of cancer.

EFFECT OF T-TYPE Ca^{2+} CHANNEL BLOCKERS ON BREAST CANCER CELL PROLIFERATION

The function of T-type Ca^{2+} channels with regards to

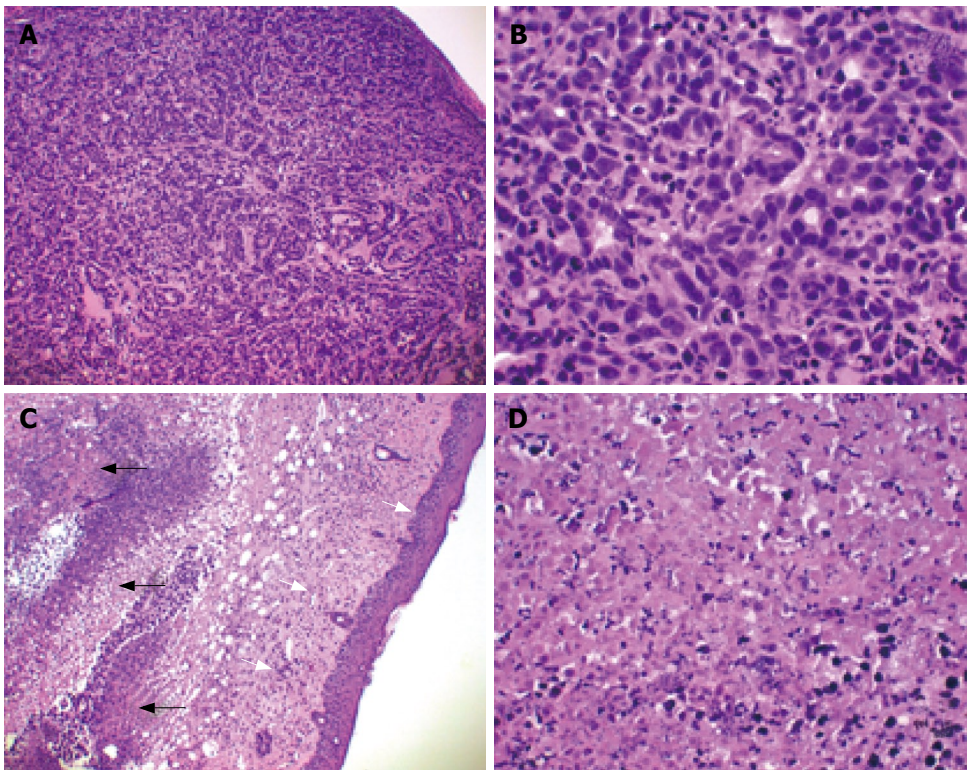

Figure 3 Mibefradil destroys tumor cells implanted in a nude mouse. HE stain was applied to show the nuclei and cytoplasm of the cells (**A** and **C**, x 100; **B** and **D**, x 400).

tumor cell proliferation was also reviewed[50,51]. One study found the T-type Ca^{2+} channel to be particularly effective in controlling oscillations in intracellular Ca^{2+} as the result of the channels unique activation/inactivation properties. It was concluded that new selective antagonists may become helpful as a therapeutic approach against tumors in which proliferation depends on T-type Ca^{2+} channel expression[51]. A study performed in knockout animals found that selective inhibition of T-type Ca^{2+} channels may have impact upon the treatment of cancer[52].

Studies have shown an inhibition in breast cancer proliferation by the channel blockers pimozide, thioridazine[53] and mibefradil[42]. The endogenous cannabinoid anandamide has also been shown to block T-type Ca^{2+} channels[54], in addition to inhibition of breast cancer cell proliferation[55], an effect that may be due to blockage of T-type Ca^{2+} channels.

The anti-cancer effect of a T-type Ca^{2+} channel antagonists on tumor cells *in vivo* has been investigated[32]. MCF-7 cells were implanted into nude mice, athymic nude BSLB/c, and then either mibefradil (0.5 mg/100 μL) or saline (0.5 mg/100 μL) was injected locally at the tumor sites (s.c) twice a week. After 30 d of the treatment, mice were sacrificed and the tumors were removed for histochemistry examination.

As shown in Figure 3A and B, in the saline injected tissue the proliferation of the malignant tumor cells formed nodules in subcutis. The tumor cells were malignant as indicated by hyperchromatic nuclei with enlarged nuclei, irregular nuclear membrane, prominent nucleoli, and many mitotic features. No signs of degeneration and necrosis were detected. In contrast, the mibefradil injected tissue showed large areas of tumor degeneration and necrosis (Figure 3C and D). The tumor necrosis was accompanied by prominent edema. Furthermore, as shown in Figure 3C, mibefradil more potently destroyed breast cancer cells (indicated by the black arrows) than non-cancerous cells at adjacent areas (indicated by the white arrows), including fibroblasts, endothelial cells and keratinocytes. These results indicate that a local injection of mibefradil induces necrosis of human breast carcinoma cells implanted into subcutaneous adipose tissue in mice.

More recently, the antiproliferative effect of the T-type calcium channel inhibitor NNC 55-0396[56] has been examined in cell lines derived from breast epithelial tissue, MCF-7, MDA-MB-231(ER-α), and an adriamycin resistant cell line ADR. All three of these cell types express α_{1G} and α_{1H} Ca^{2+} channel mRNA and their proliferation was suppressed by NNC 55-0396, with IC_{50} of about 1-2 μmol/L[32,33]. The specificity of NNC 55-0396 antagonism on cancerous cell proliferation was investigated in a prostate epithelial cell line (RWPE-1) that does not express T-type Ca^{2+} channels[32]. As shown in Figure 4, NNC 55-0396 exhibited neither dose-dependent (up to 20 μmol/L Figure 4A) nor time-dependent (up to 60 h, Figure 4B) inhibitory effects on RWPE-1 cell growth, suggesting that the anti-proliferation effect of NNC 55-0396 most likely resulted from blocking T-type Ca^{2+} channels of breast cancer cells. It also suggested that the general toxicity of NNC 55-0396 is minimal at the concentration that induces suppression of proliferation. T-type Ca^{2+} channel antisense treatment in these cells reduced the proliferation rate by 45% and antisense had no effect on proliferation on tumor cells not expressing T-type Ca^{2+} channels.

The role of T-type Ca^{2+} channels in cancerous cell proliferation has also been examined with specific siRNA

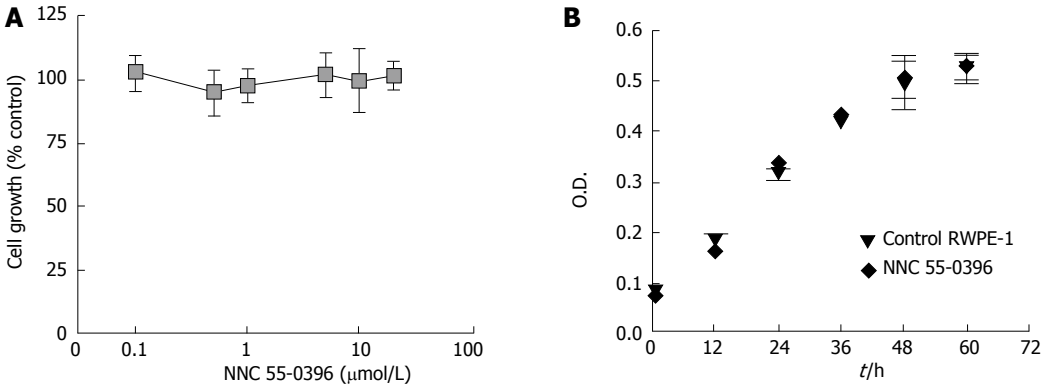

Figure 4 Effect of NNC 55-0396 on RWPE-1 cell proliferation (Error bars represent SE; *n* = 3).

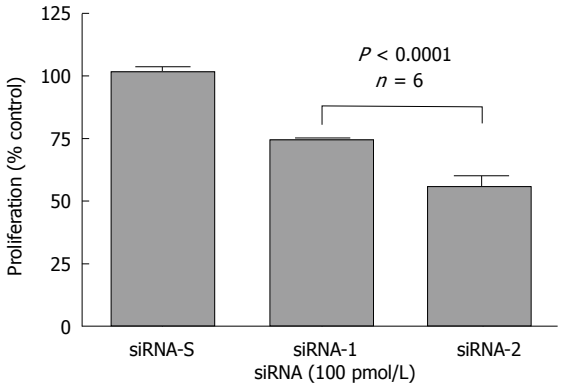

Figure 5 Effect of siRNAs on MCF-7 cell proliferation.

antagonism[33]. Specifically, MCF-7 cells were treated with siRNA targeting both α_{1G} and α_{1H} ($\alpha_{1G/H}$). The cells were treated with scrambled (siRNA-S, 100 pmol/L), $\alpha_{1G/H}$-1 (siRNA-1) or $\alpha_{1G/H}$-2 (siRNA-2) for 48 h and subjected to MTT assay. The effects of siRNAs on cell proliferation were shown as percent (%) of vehicle control. As shown in Figure 5, scrambled siRNA was not significantly different than the control. However, both siRNA-1 and siRNA-2 treated cells had significantly lower proliferation rates compared to the scrambled and vehicle control siRNAs. These results strongly support the role of T-type Ca^{2+} channels in breast cancer cell proliferation and indicate that the effect of NNC 55-0396 on the breast cancer cell proliferation is due to the blockade of these channels.

CONCERNS

Since T-type Ca^{2+} channels are normally expressed in the brain, heart and endocrine tissues of the human body, the potential side-effects of T-type Ca^{2+} channel blockers to these systems are of concern for therapeutic applications. Although T-type Ca^{2+} channel blockers have been used clinically for the treatment of neurological disorders (e.g. ethosuximide for absence seizures), the adverse effects of these drugs on the cardiovascular and central nervous systems are still unclear. Specifically, it is important to determine the possible arrhythmic and sedative effects of these drugs.

Human blood cells do not express T-type Ca^{2+} channels; therefore, it is advantageous to apply T-type Ca^{2+} channel blockers in the hemopoietic system, since current chemotherapeutic drugs have displayed severe side effects on this system. If we can locally deliver T-type Ca^{2+} channel blocker into the hemopoietic system, the compound should be very selective in eliminating the breast cancer cells in the blood stream. Thus, T-type Ca^{2+} channel blockers can be potential anti-metastasis drugs for adjuvant therapy of breast cancer.

PERSPECTIVES

The function of T-type Ca^{2+} channels may not be restricted to cancerous cell proliferation. These channels may also play roles in cancerous cell colonization, invasion, secretion and angiogenesis. The growing number of proliferating cells need to attract blood vessels (angiogenesis) in order to receive nutrients, O_2, *etc.* to sustain themselves. The transformed cells are able to enter the blood stream and survive there, and colonize (metastasize) other tissues. Invasive growth or cell migration is a highly regulated process in which the migrating cells must secrete matrix proteases that disrupt the extracellular matrix (ECM) and permit easier transit through the surrounding environment. In addition, they must also profoundly reshape their structure, which involves massive cytoskeletal rearrangement. Precise regulation of intracellular calcium concentration is crucial for all of these processes. It is very possible that T-type Ca^{2+} channels also play significant roles in these processes[45].

An expansion of the list of ion channels implicated in cancer development is expected, and the tools needed to investigate this issue are more readily available. As is the case with other protein families, it will be probably difficult to ascribe tumor development to the malfunction of a single ion channel. Rather, defects in T-type Ca^{2+} channels probably contribute to the neoplastic phenotype through complex interactions with other ion channels, most of which have not been properly identified. For instance, regulation of K^+ channels can affect the membrane potential, which in turn regulates the window currents mediated by T-type Ca^{2+} channels. However, since in many cases there are already known pharmacological modulators (blockers

and activators) of ion channels, identification of a single defective ion channel in a particular cancer could provide a ready-to-go therapeutic approach.

REFERENCES

1 **Mariot P**, Vanoverberghe K, Lalevee N, Rossier MF, Prevarskaya N. Overexpression of an alpha 1H (Cav3.2) T-type calcium channel during neuroendocrine differentiation of human prostate cancer cells. *J Biol Chem* 2002; **277**: 10824-10833

2 **Ciapa B**, Pesando D, Wilding M, Whitaker M. Cell-cycle calcium transients driven by cyclic changes in inositol trisphosphate levels. *Nature* 1994; **368**: 875-878

3 **Choi DW**. Ionic dependence of glutamate neurotoxicity. *J Neurosci* 1987; **7**: 369-379

4 **Cohen CJ**, McCarthy RT, Barrett PQ, Rasmussen H. Ca channels in adrenal glomerulosa cells: K+ and angiotensin II increase T-type Ca channel current. *Proc Natl Acad Sci USA* 1988; **85**: 2412-2416

5 **Tsien RW**, Clozel J-P, Nargeot J. Low-voltage-activated T-type Ca2+ channels. Chester: Adis International Ltd, 1998: 1-394

6 **Crunelli V**, Toth TI, Cope DW, Blethyn K, Hughes SW. The 'window' T-type calcium current in brain dynamics of different behavioural states. *J Physiol* 2005; **562**: 121-129

7 **Bean BP**, McDonough SI. Two for T. *Neuron* 1998; **20**: 825-828

8 **Chemin J**, Monteil A, Briquaire C, Richard S, Perez-Reyes E, Nargeot J, Lory P. Overexpression of T-type calcium channels in HEK-293 cells increases intracellular calcium without affecting cellular proliferation. *FEBS Lett* 2000; **478**: 166-172

9 **Trump BF**, Berezesky IK. Calcium-mediated cell injury and cell death. *FASEB J* 1995; **9**: 219-228

10 **Steinhardt RA**, Alderton J. Intracellular free calcium rise triggers nuclear envelope breakdown in the sea urchin embryo. *Nature* 1988; **332**: 364-366

11 **Zucker RS**, Steinhardt RA. Prevention of the cortical reaction in fertilized sea urchin eggs by injection of calcium-chelating ligands. *Biochim Biophys Acta* 1978; **541**: 459-466

12 **Zeitler H**, Ko Y, Glodny B, Totzke G, Appenheimer M, Sachinidis A, Vetter H. Cell-cycle arrest in G0/G1 phase of growth factor-induced endothelial cell proliferation by various calcium channel blockers. *Cancer Detect Prev* 1997; **21**: 332-339

13 **Ariyoshi H**, Okahara K, Sakon M, Kambayashi J, Kawashima S, Kawasaki T, Monden M. Possible involvement of m-calpain in vascular smooth muscle cell proliferation. *Arterioscler Thromb Vasc Biol* 1998; **18**: 493-498

14 **Akagi K**, Nagao T, Urushidani T. Correlation between Ca(2+) oscillation and cell proliferation via CCK(B)/gastrin receptor. *Biochim Biophys Acta* 1999; **1452**: 243-253

15 **Berridge MJ**. Inositol trisphosphate and calcium signalling. *Nature* 1993; **361**: 315-325

16 **Lechleiter JD**, Clapham DE. Molecular mechanisms of intracellular calcium excitability in X. laevis oocytes. *Cell* 1992; **69**: 283-294

17 **Reddy GP**, Reed WC, Sheehan E, Sacks DB. Calmodulin-specific monoclonal antibodies inhibit DNA replication in mammalian cells. *Biochemistry* 1992; **31**: 10426-10430

18 **Kifor O**, Diaz R, Butters R, Brown EM. The Ca2+-sensing receptor (CaR) activates phospholipases C, A2, and D in bovine parathyroid and CaR-transfected, human embryonic kidney (HEK293) cells. *J Bone Miner Res* 1997; **12**: 715-725

19 **Parkash J**, Chaudhry MA, Amer AS, Christakos S, Rhoten WB. Intracellular calcium ion response to glucose in beta-cells of calbindin-D28k nullmutant mice and in betaHC13 cells overexpressing calbindin-D28k. *Endocrine* 2002; **18**: 221-229

20 **Parkash J**, Chaudhry MA, Rhoten WB. Calbindin-D28k and calcium sensing receptor cooperate in MCF-7 human breast cancer cells. *Int J Oncol* 2004; **24**: 1111-1119

21 **Sanders JL**, Chattopadhyay N, Kifor O, Yamaguchi T, Butters RR, Brown EM. Extracellular calcium-sensing receptor expression and its potential role in regulating parathyroid hormone-related peptide secretion in human breast cancer cell lines. *Endocrinology* 2000; **141**: 4357-4364

22 **Lewalle JM**, Cataldo D, Bajou K, Lambert CA, Foidart JM. Endothelial cell intracellular Ca2+ concentration is increased upon breast tumor cell contact and mediates tumor cell transendothelial migration. *Clin Exp Metastasis* 1998; **16**: 21-29

23 **Whitfield JF**. Calcium signals and cancer. *Crit Rev Oncog* 1992; **3**: 55-90

24 **Kuga T**, Kobayashi S, Hirakawa Y, Kanaide H, Takeshita A. Cell cycle--dependent expression of L- and T-type Ca2+ currents in rat aortic smooth muscle cells in primary culture. *Circ Res* 1996; **79**: 14-19

25 **Guo W**, Kamiya K, Kodama I, Toyama J. Cell cycle-related changes in the voltage-gated Ca2+ currents in cultured newborn rat ventricular myocytes. *J Mol Cell Cardiol* 1998; **30**: 1095-1103

26 **Li M**, Zhang M, Huang L, Zhou J, Zhuang H, Taylor JT, Keyser BM, Whitehurst RM Jr. T-type Ca2+ channels are involved in high glucose-induced rat neonatal cardiomyocyte proliferation. *Pediatr Res* 2005; **57**: 550-556

27 **Richard S**, Neveu D, Carnac G, Bodin P, Travo P, Nargeot J. Differential expression of voltage-gated Ca(2+)-currents in cultivated aortic myocytes. *Biochim Biophys Acta* 1992; **1160**: 95-104

28 **Gomez JP**, Potreau D, Branka JE, Raymond G. Developmental changes in Ca2+ currents from newborn rat cardiomyocytes in primary culture. *Pflugers Arch* 1994; **428**: 241-249

29 **Bkaily G**, Sculptoreanu A, Jacques D, Jasmin G. Increases of T-type Ca2+ current in heart cells of the cardiomyopathic hamster. *Mol Cell Biochem* 1997; **176**: 199-204

30 **Nuss HB**, Houser SR. T-type Ca2+ current is expressed in hypertrophied adult feline left ventricular myocytes. *Circ Res* 1993; **73**: 777-782

31 **Schmitt R**, Clozel JP, Iberg N, Buhler FR. Mibefradil prevents neointima formation after vascular injury in rats. Possible role of the blockade of the T-type voltage-operated calcium channel. *Arterioscler Thromb Vasc Biol* 1995; **15**: 1161-1165

32 **Taylor JT**, Rider B, Huang L, Keyser B, Agrawal K, Li M. A selective T-type calcium channel antagonist inhibits breast cancer cell growth (abstract). *FASEB* 2004; A996

33 **Taylor JT**, Huang L, Pottle JE, Liu K, Yang Y, Zeng X, Keyser BM, Agrawal KC, Hansen JB, Li M. Selective blockade of T-type Ca(2+) channels suppresses human breast cancer cell proliferation. *Cancer Lett* 2008; **267**: 116-124

34 **Gray LS**, Perez-Reyes E, Gomora JC, Haverstick DM, Shattock M, McLatchie L, Harper J, Brooks G, Heady T, Macdonald TL. The role of voltage gated T-type Ca2+ channel isoforms in mediating "capacitative" Ca2+ entry in cancer cells. *Cell Calcium* 2004; **36**: 489-497

35 **Toyota M**, Ho C, Ohe-Toyota M, Baylin SB, Issa JP. Inactivation of CACNA1G, a T-type calcium channel gene, by aberrant methylation of its 5' CpG island in human tumors. *Cancer Res* 1999; **59**: 4535-4541

36 **Latour I**, Louw DF, Beedle AM, Hamid J, Sutherland GR, Zamponi GW. Expression of T-type calcium channel splice variants in human glioma. *Glia* 2004; **48**: 112-119

37 **Panner A**, Cribbs LL, Zainelli GM, Origitano TC, Singh S, Wurster RD. Variation of T-type calcium channel protein expression affects cell division of cultured tumor cells. *Cell Calcium* 2005; **37**: 105-119

38 **Leuranguer V**, Bourinet E, Lory P, Nargeot J. Antisense depletion of beta-subunits fails to affect T-type calcium channels properties in a neuroblastoma cell line. *Neuropharmacology* 1998; **37**: 701-708

39 **Wyatt CN**, Page KM, Berrow NS, Brice NL, Dolphin AC. The effect of overexpression of auxiliary Ca2+ channel subunits on native Ca2+ channel currents in undifferentiated mammalian NG108-15 cells. *J Physiol* 1998; **510** (Pt 2): 347-360
40 **Assandri R**, Egger M, Gassmann M, Niggli E, Bauer C, Forster I, Gorlach A. Erythropoietin modulates intracellular calcium in a human neuroblastoma cell line. *J Physiol* 1999; **516** (Pt 2): 343-352
41 **Hirooka K**, Bertolesi GE, Kelly ME, Denovan-Wright EM, Sun X, Hamid J, Zamponi GW, Juhasz AE, Haynes LW, Barnes S. T-Type calcium channel alpha1G and alpha1H subunits in human retinoblastoma cells and their loss after differentiation. *J Neurophysiol* 2002; **88**: 196-205
42 **Bertolesi GE**, Shi C, Elbaum L, Jollimore C, Rozenberg G, Barnes S, Kelly ME. The Ca(2+) channel antagonists mibefradil and pimozide inhibit cell growth via different cytotoxic mechanisms. *Mol Pharmacol* 2002; **62**: 210-219
43 **Wang YQ**, Brooks G, Zhu CB, Yuan WZ, Li YQ, Wu XS. [Functional analysis of the human T-type calcium channel alpha 1H subunit gene in cellular proliferation] Y*ichuan Xuebao* 2002; **29**: 659-665
44 **Lu F**, Chen H, Zhou C, Liu S, Guo M, Chen P, Zhuang H, Xie D, Wu S. T-type Ca2+ channel expression in human esophageal carcinomas: a functional role in proliferation. *Cell Calcium* 2008; **43**: 49-58
45 **Huang JB**, Kindzelskii AL, Clark AJ, Petty HR. Identification of channels promoting calcium spikes and waves in HT1080 tumor cells: their apparent roles in cell motility and invasion. *Cancer Res* 2004; **64**: 2482-2489
46 **Harkins AB**, Cahill AL, Powers JF, Tischler AS, Fox AP. Expression of recombinant calcium channels support secretion in a mouse pheochromocytoma cell line. *J Neurophysiol* 2003; **90**: 2325-2333
47 **Del Toro R**, Levitsky KL, Lopez-Barneo J, Chiara MD. Induction of T-type calcium channel gene expression by chronic hypoxia. *J Biol Chem* 2003; **278**: 22316-22324
48 **Lesouhaitier O**, Chiappe A, Rossier MF. Aldosterone increases T-type calcium currents in human adrenocarcinoma (H295R) cells by inducing channel expression. *Endocrinology* 2001; **142**: 4320-4330
49 **Zhuang H**, Bhattacharjee A, Hu F, Zhang M, Goswami T, Wang L, Wu S, Berggren PO, Li M. Cloning of a T-type Ca2+ channel isoform in insulin-secreting cells. *Diabetes* 2000; **49**: 59-64
50 **Lee JY**, Park SJ, Park SJ, Lee MJ, Rhim H, Seo SH, Kim KS. Growth inhibition of human cancer cells in vitro by T-type calcium channel blockers. *Bioorg Med Chem Lett* 2006; **16**: 5014-5017
51 **Panner A**, Wurster RD. T-type calcium channels and tumor proliferation. *Cell Calcium* 2006; **40**: 253-259
52 **Lory P**, Chemin J. Towards the discovery of novel T-type calcium channel blockers. *Expert Opin Ther Targets* 2007; **11**: 717-722
53 **Strobl JS**, Kirkwood KL, Lantz TK, Lewine MA, Peterson VA, Worley JF 3rd. Inhibition of human breast cancer cell proliferation in tissue culture by the neuroleptic agents pimozide and thioridazine. *Cancer Res* 1990; **50**: 5399-5405
54 **Chemin J**, Monteil A, Perez-Reyes E, Nargeot J, Lory P. Direct inhibition of T-type calcium channels by the endogenous cannabinoid anandamide. *EMBO J* 2001; **20**: 7033-7040
55 **De Petrocellis L**, Melck D, Palmisano A, Bisogno T, Laezza C, Bifulco M, Di Marzo V. The endogenous cannabinoid anandamide inhibits human breast cancer cell proliferation. *Proc Natl Acad Sci USA* 1998; **95**: 8375-8380
56 **Li M**, Hansen JB, Huang L, Keyser BM, Taylor JT. Towards selective antagonists of T-type calcium channels: design, characterization and potential applications of NNC 55-0396. *Cardiovasc Drug Rev* 2005; **23**: 173-196

S- Editor Zhong XY **L- Editor** Roberts SE **E- Editor** Yin DH

Online Submissions: wjg.wjgnet.com
wjg@wjgnet.com
doi:10.3748/wjg.14.4992

World J Gastroenterol 2008 August 28; 14(32): 4992-4994
World Journal of Gastroenterology ISSN 1007-9327
© 2008 The WJG Press. All rights reserved.

EDITORIAL

Diagnostic criteria for autoimmune pancreatitis in Japan

Terumi Kamisawa, Kazuichi Okazaki, Shigeyuki Kawa

Terumi Kamisawa, Department of Internal Medicine, Tokyo Metropolitan Komagome Hospital, Tokyo 113-8677, Japan
Kazuichi Okazaki, Third Department of Internal Medicine, Kansai Medical University, Osaka 573-1191, Japan
Shigeyuki Kawa, Center for Health, Safety and Environmental Management, Shinshu University, Matsumoto, 390-8621 Japan
Author contributions: Kamisawa T, Okazaki K and Kawa S contributed equally to this work; Kamisawa T wrote the paper.
Supported by Research for Intractable Disease of the Pancreas, Ministry of Health, Labor and Welfare of Japan
Correspondence to: Terumi Kamisawa, MD, PhD, Department of Internal Medicine, Tokyo Metropolitan Komagome Hospital, 3-18-22 Honkomagome, Bunkyo-ku, Tokyo 113-8677, Japan. kamisawa@cick.jp
Telephone: +81-3-38232101 Fax: +81-3-38241552
Received: March 31, 2008 Revised: May 7, 2008
Accepted: May 14, 2008
Published online: August 28, 2008

Abstract

Autoimmune pancreatitis (AIP) is a particular type of pancreatitis of presumed autoimmune etiology. Currently, AIP should be diagnosed based on combination of clinical, serological, morphological, and histopathological features. When diagnosing AIP, it is most important to differentiate it from pancreatic cancer. Diagnostic criteria for AIP, proposed by the Japan Pancreas Society in 2002 first in the world, were revised in 2006. The criteria are based on the minimum consensus of AIP and aim to avoid misdiagnosing pancreatic cancer as far as possible, but not for screening AIP. The criteria consist of the following radiological, serological, and histopathological items: (1) radiological imaging showing narrowing of the main pancreatic duct and enlargement of the pancreas, which are characteristic of the disease; (2) laboratory data showing abnormally elevated levels of serum γ-globulin, IgG or IgG4, or the presence of autoantibodies; (3) histopathological examination of the pancreas demonstrating marked fibrosis and prominent infiltration of lymphocytes and plasma cells, which is called lymphoplasmacytic sclerosing pancreatitis (LPSP). For a diagnosis of AIP, criterion 1 must be present, together with criterion 2 and/or criterion 3. However, it is necessary to exclude malignant diseases such as pancreatic or biliary cancer.

© 2008 The WJG Press. All rights reserved.

Key words: Autoimmune pancreatitis; Diagnostic criteria; IgG4; Lymphoplasmacytic sclerosing pancreatitis

Peer reviewers: Yoshiharu Motoo, MD, PhD, FACP, FACG, Professor and Chairman, Department of Medical Oncology, Kanazawa Medical University, 1-1 Daigaku, Uchinada, Ishikawa 920-0293, Japan; Dr. Karel van Erpecum, Department of Gastroenterology and Hepatology, University Hospital Utrecht, PO Box 855003508 GA, Utrecht, The Netherlands

Kamisawa T, Okazaki K, Kawa S. Diagnostic criteria for autoimmune pancreatitis in Japan. *World J Gastroenterol* 2008; 14(32): 4992-4994 Available from: URL: http://www.wjgnet.com/1007-9327/14/4992.asp DOI: http://dx.doi.org/10.3748/wjg.14.4992

INTRODUCTION

Autoimmune pancreatitis (AIP) is a particular type of pancreatitis that is thought to have an autoimmune etiology[1]. Since Yoshida *et al*[2] proposed AIP as a diagnostic entity in 1995, many cases of AIP have been reported in Japan. As there is currently no diagnostic serological marker for AIP, AIP should be diagnosed on the basis of presence of a combination of abnormalities unique to AIP. In 2002, the Japan Pancreas Society established the "Diagnostic Criteria for Autoimmune Pancreatitis"[3] consisting of the following 3 items: (1) radiological imaging showing diffuse enlargement of the pancreas and diffuse irregular narrowing of the main pancreatic duct (more than one-third of the entire pancreas); (2) laboratory data demonstrating abnormally elevated levels of serum gamma globulin or IgG, or the presence of autoantibodies; and (3) histological examination of the pancreas showing lymphoplasmacytic infiltration and fibrosis. With accumulation of AIP cases, the concept of AIP has changed slightly, and the AIP criteria 2002 are becoming inadequate. Therefore, they were revised in 2006 by the Research Committee of Intractable Diseases of the Pancreas supported by the Japanese Ministry of Health, Labor and Welfare and the Japan Pancreas Society[4]. In 2006, two new sets of diagnostic criteria for AIP were proposed, in Korea[5] and USA, respectively[6]. Currently, there are several diagnostic criteria for AIP in the world. We describe the clinical diagnostic criteria for AIP in Japan.

CLINICAL DIAGNOSTIC CRITERIA FOR AUTOIMMUNE PANCREATITIS 2006

The diagnostic criteria for AIP in Japan are based on the minimum consensus of AIP and aim to avoid

misdiagnosing pancreatic cancer as far as possible, but not for screening AIP. Therefore, the criteria emphasize the importance of imaging studies. In the 2002 criteria[3], extent limitation on main pancreatic duct involvement (more than one-third the length of the entire pancreas) was required to diagnose only typical AIP cases and to avoid the possible inclusion of pancreatic cancer. However, with the accumulation of more AIP cases, it has become clear that, in several cases that are strongly suspected of having AIP, the degree of narrowing of the main pancreatic duct is less than one-third of the entire pancreas[5-7]. Furthermore, serum IgG4 levels are rather significantly and specifically elevated in AIP patients[8]. Thus, the 2006 criteria[4] delete the requirement that "more than one-third of the entire pancreas" is involved, allowing segmental AIP cases to be diagnosed. Furthermore, the 2006 criteria[4] include elevation of the serum IgG4 level as a diagnostic factor. Finally, the 2006 criteria[4] stress the need to exclude malignant diseases such as pancreatic or biliary cancer, before making the diagnosis of AIP (Table 1).

Table 1 Clinical diagnostic criteria for autoimmune pancreatitis 2006[4]

Clinical diagnostic criteria
1 Diffuse or segmental narrowing of the main pancreatic duct with irregular wall and diffuse or localized enlargement of the pancreas by imaging studies, such as abdominal ultrasonography (US), computed tomography (CT) and magnetic resonance imaging (MRI)
2 High serum γ-globulin, IgG or IgG4, or the presence of autoantibodies, such as antinuclear antibodies and rheumatoid factor
3 Marked inter-lobular fibrosis and prominent infiltration of lymphocytes and plasma cells in the peri-ductal area, occasionally with lymphoid follicles in the pancreas

For diagnosis, criterion 1 must be present, together with criterion 2 and/or criterion 3. Diagnosis of autoimmune pancreatitis is established when criterion 1, together with criterion 2 and/or criterion 3, are fulfilled. However, it is necessary to exclude malignant diseases such as pancreatic or biliary cancers.

The preface of the criteria is described below[4]. It is suspected that the pathogenesis of autoimmune pancreatitis (AIP) involves autoimmune mechanisms. Currently, the main cases observed for characteristic findings of AIP are the diffuse enlargement of the pancreas and the narrowing of the pancreatic duct, which are associated with the findings that are suggestive of the involvement of autoimmune mechanisms such as increased levels of γ-globulin and IgG, the presence of autoantibodies, and the effective response to steroid therapy. In some cases, AIP shows extra-pancreatic manifestations such as sclerosing cholangitis, sclerosing sialadenitis, and retroperitoneal fibrosis, suggesting that AIP is a systemic disease. In Western countries, AIP is occasionally observed in association with ulcerative colitis and formation of tumors, suggesting that it is somewhat contrary to the definition and concept of the disease adopted in Japan.

Patients with AIP often show discomfort in the epigastrium, obstructive jaundice due to bile duct stricture, and diabetes mellitus. AIP is more common in middle-aged and elderly males. Although long-term prognosis of the disease is not clear, pancreatic stone formation has been found in some cases. When diagnosing AIP, it is important to differentiate it from neoplastic lesions such as pancreatic or biliary cancer, and to avoid facile therapeutic diagnosis by steroidal administration. The present criteria, therefore, are based on the minimum consensus of AIP to avoid mis-diagnosing pancreas or biliary cancer as far as possible, but not for screening AIP.

Furthermore, description note of the criteria is reported as below[4]: (Ⅰ) Imaging studies: (1) Diffuse or localized swelling of the pancreas. Abdominal ultrasonography (US), computed tomography (CT), and/or magnetic resonance imaging (MRI) show diffused or localized swelling of the pancreas. (A) The US feature of pancreatic swelling is usually hypoechoic, sometimes with scattered echogenic spots. (B) Contrast-enhanced CT generally shows delayed enhancement similar to normal pancreas with a sausage-like enlargement, and/or a capsular-like low density rim. (C) MRI shows diffuse or localized enlargement of the pancreas with a lower density in T1-weighed image and a higher density in T2-weighed image compared with each of the liver images. (2) Narrowing of the pancreatic duct. The main pancreatic duct shows diffuse or localized narrowing. (A) Unlike obstruction or stricture, narrowing of the pancreatic duct extends over a larger range where the duct is narrowed with irregular walls. In typical cases, more than one-third of the entire pancreatic duct is narrowed. Even in cases where the narrowing is segmental and extends to less than one-third, the upper stream of the main pancreatic duct rarely shows notable dilatation. (B) When the pancreatic images do show typical findings but laboratory data do not, there is a possibility of AIP. However, without histopathological examinations, it is difficult to distinguish AIP from pancreatic cancer. (C) To obtain the images of pancreatic duct, it is necessary to use endoscopic retrograde the cholangiopancreatography (ERCP), and additionally the direct images taken during the operation or on specimens. Currently, the diagnosis is difficult to depend on magnetic resonance cholangiopancreatography (MRCP). (3) The pancreatic image findings described above may be observed retrospectively at the time of diagnosis. (Ⅱ) Laboratory data: (1) In many cases, patients with AIP show increased levels of serum γ-globulin, IgG or IgG4. High serum IgG4, however, is not specific to AIP, since it is also observed in other disorders such as atopic dermatitis, pemphigus, or asthma. Currently, the significance of high serum IgG4 in the pathogenesis and the pathophysiology of AIP are unclear. (2) Although increased levels of serum γ-globulin (≥ 2.0 g/dL), IgG (≥ 1800 mg/dL), and IgG4 (≥ 135 mg/dL) may be used as criteria for the diagnosis of AIP, further studies are necessary. Health insurance in Japan does not cover the cost of measuring serum IgG4 levels in AIP patients. (3) Autoantibodies, such as antinuclear antibody and rheumatoid factor, are often detected in patients with AIP. (Ⅲ) Pathohistological findings of the pancreas: (1) Fibrotic changes associated with prominent infiltration of lymphocytes and plasma cells, occasionally with lymphoid follicles, are observed. In many cases, infiltration of IgG4-positive plasma cells is observed. (2) Lymphocytic infiltration is prominent

in the peri-ductal area, together with inter-lobular fibrosis, occasionally including intra-lobular fibrosis. (3) Inflammatory cell infiltration involving the ducts results in diffuse narrowing of the pancreatic duct with atrophy of acini. (4) Obliterative phlebitis is often observed. (5) Although fine needle biopsy under ultrasonic endoscope (EUS-FNA) is useful in differentiating AIP from malignant tumors, diagnosis may be difficult if the specimen is too small. (Ⅳ) Endocrine and exocrine function of the pancreas: Some patients with AIP show decline of exocrine pancreatic function and diabetes mellitus. In some cases, steroid therapy improves endocrine and exocrine pancreatic dysfunction.

AIP may be associated with sclerosing cholangitis and sialadenitis, or retroperitoneal fibrosis. Most of AIP patients with sclerosing sialadenitis are negative for both anti-SSA and anti-SSB antibodies, suggesting that AIP is different from Sjogren's syndrome. Sclerosing cholangitis-like lesions accompanying AIP and primary sclerosing cholangitis (PSC) respond differently to steroid therapy and follow different prognoses, suggesting that they are not the same disorder. Further studies are necessary to clarify the role of autoimmune mechanisms in AIP.

In the diagnostic criteria in Korea[5] and the United States (Mayo Clinic)[6], "response to steroid" is included as one of the diagnostic items. When response to steroid therapy is added to the criteria, the diagnostic sensitivity is increased. Since relief of narrowing of the pancreatic duct can be seen as early as 2 wk after steroid therapy in AIP cases, it dose not occur in pancreatic cancer cases. The Korean investigators advocate a short trial of steroid therapy to differentiate AIP from pancreatic cancer in cases that do not fulfill the Japanese criteria[5]. We also agree that a trial of steroid therapy can be used to assist in making the diagnosis when it is used appropriately. However, since general physicians who are not pancreatologists use the criteria, it is possible that the facile use of steroid trials will delay pancreatic cancer surgery, which could lead to cancer progression in some cases. Therefore, "response to steroid" is excluded in the diagnostic criteria in Japan[4,9,10].

AIP with neutrophilic infiltration in the epithelium of the pancreatic duct (idiopathic duct-centric chronic pancreatitis: IDCP, or granulocyte epithelial lesion: GEL) has been reported by American[11] and Italian[12] pathologists. These patients showing different clinicopathological features from AIP are defined in Japan as follows: no prediction for elderly males, frequent association with inflammatory bowel disease, and weaker association with other sclerosing diseases. Histopathological finding of AIP in Japan is lymphoplasmacytic sclerosing pancreatitis (LPSP), and the above Western AIP cases have not been confirmed in Japan owing to the limited number of studies.

AIP patients usually have various extrapancreatic lesions such as sclerosing cholangitis and sialadenitis, and retroperitoneal fibrosis[13]. The histopathological findings of these extrapancreatic lesions are uniformly fibrosis with marked infiltration of IgG4-positive plasma cells and lymphocytes, which are similar to those in the pancreas[14,15]. Therefore, the recent concept of AIP suggests that AIP is a pancreatic lesion of IgG4-related systemic disease[1,15,16]. In the future, criteria for AIP might develop into criteria for IgG4-related systemic disease.

REFERENCES

1 **Kamisawa T**, Okamoto A. Autoimmune pancreatitis: proposal of IgG4-related sclerosing disease. *J Gastroenterol* 2006; **41**: 613-625

2 **Yoshida K**, Toki F, Takeuchi T, Watanabe S, Shiratori K, Hayashi N. Chronic pancreatitis caused by an autoimmune abnormality. Proposal of the concept of autoimmune pancreatitis. *Dig Dis Sci* 1995; **40**: 1561-1568

3 **Members of the Criteria Committee for Autoimmune Pancreatitis of the Japan Pancreas Society**. Diagnostic criteria for autoimmune pancreatitis by the Japan Pancreas Society (in Japanese). *J Jpn Pan Soc* 2002; **17**: 585-587

4 **Okazaki K**, Kawa S, Kamisawa T, Naruse S, Tanaka S, Nishimori I, Ohara H, Ito T, Kiriyama S, Inui K, Shimosegawa T, Koizumi M, Suda K, Shiratori K, Yamaguchi K, Yamaguchi T, Sugiyama M, Otsuki M. Clinical diagnostic criteria of autoimmune pancreatitis: revised proposal. *J Gastroenterol* 2006; **41**: 626-631

5 **Kim KP**, Kim MH, Kim JC, Lee SS, Seo DW, Lee SK. Diagnostic criteria for autoimmune chronic pancreatitis revisited. *World J Gastroenterol* 2006; **12**: 2487-2496

6 **Chari ST**, Smyrk TC, Levy MJ, Topazian MD, Takahashi N, Zhang L, Clain JE, Pearson RK, Petersen BT, Vege SS, Farnell MB. Diagnosis of autoimmune pancreatitis: the Mayo Clinic experience. *Clin Gastroenterol Hepatol* 2006; **4**: 1010-1016; quiz 934

7 **Kamisawa T**, Tu Y, Egawa N, Nakajima H, Tsuruta K, Okamoto A. Involvement of pancreatic and bile ducts in autoimmune pancreatitis. *World J Gastroenterol* 2006; **12**: 612-614

8 **Hamano H**, Kawa S, Horiuchi A, Unno H, Furuya N, Akamatsu T, Fukushima M, Nikaido T, Nakayama K, Usuda N, Kiyosawa K. High serum IgG4 concentrations in patients with sclerosing pancreatitis. *N Engl J Med* 2001; **344**: 732-738

9 **Okazaki K**, Uchida K, Matsushita M, Takaoka M. How to diagnose autoimmune pancreatitis by the revised Japanese clinical criteria. *J Gastroenterol* 2007; **42** Suppl 18: 32-38

10 **Kamisawa T**. Diagnostic criteria for autoimmune pancreatitis. *J Clin Gastroenterol* 2008; **42**: 404-407

11 **Notohara K**, Burgart LJ, Yadav D, Chari S, Smyrk TC. Idiopathic chronic pancreatitis with periductal lymphoplasmacytic infiltration: clinicopathologic features of 35 cases. *Am J Surg Pathol* 2003; **27**: 1119-1127

12 **Zamboni G**, Luttges J, Capelli P, Frulloni L, Cavallini G, Pederzoli P, Leins A, Longnecker D, Kloppel G. Histopathological features of diagnostic and clinical relevance in autoimmune pancreatitis: a study on 53 resection specimens and 9 biopsy specimens. *Virchows Arch* 2004; **445**: 552-563

13 **Kamisawa T**, Egawa N, Nakajima H, Tsuruta K, Okamoto A. Extrapancreatic lesions in autoimmune pancreatitis. *J Clin Gastroenterol* 2005; **39**: 904-907

14 **Kamisawa T**, Funata N, Hayashi Y, Tsuruta K, Okamoto A, Amemiya K, Egawa N, Nakajima H. Close relationship between autoimmune pancreatitis and multifocal fibrosclerosis. *Gut* 2003; **52**: 683-687

15 **Kamisawa T**, Funata N, Hayashi Y, Eishi Y, Koike M, Tsuruta K, Okamoto A, Egawa N, Nakajima H. A new clinicopathological entity of IgG4-related autoimmune disease. *J Gastroenterol* 2003; **38**: 982-984

16 **Kamisawa T**, Nakajima H, Egawa N, Funata N, Tsuruta K, Okamoto A. IgG4-related sclerosing disease incorporating sclerosing pancreatitis, cholangitis, sialadenitis and retroperitoneal fibrosis with lymphadenopathy. *Pancreatology* 2006; **6**: 132-137

S- Editor Zhong XY **L- Editor** Wang XL **E- Editor** Lin YP

Online Submissions: wjg.wjgnet.com
wjg@wjgnet.com
doi:10.3748/wjg.14.4995

World J Gastroenterol 2008 August 28; 14(32): 4995-4999
World Journal of Gastroenterology ISSN 1007-9327
© 2008 The WJG Press. All rights reserved.

REVIEW

Giant duodenal ulcers

Eric Benjamin Newton, Mark R Versland, Thomas E Sepe

Eric Benjamin Newton, Mark R Versland, Department of Medicine, Division of Gastroenterology-Hepatology, University of Connecticut Health Center, Farmington CT 06030-1845, United States
Thomas E Sepe, Warren Alpert School of Medicine, Brown University, Providence, Rhode Island 02903, United States
Author contributions: Newton EB wrote the paper; Sepe TE generated the concept for the paper, revised and edited the paper; Versland MR revised and edited the paper.
Correspondence to: Eric Benjamin Newton, Department of Medicine, Division of Gastroenterology-Hepatology, University of Connecticut Health Center, 263 Farmington Ave., Farmington CT 06030-1845, United States. enewton@uchc.edu
Telephone: +1-860-679-3158 Fax: +1-860-679-3159
Received: February 15, 2008 Revised: August 10, 2008
Accepted: August 17, 2008
Published online: August 28, 2008

Abstract

Giant duodenal ulcers (GDUs) are a subset of duodenal ulcers that have historically resulted in greater morbidity than usual duodenal ulcers. Until recently, few cases had been successfully treated with medical therapy. However, the widespread use of endoscopy, the introduction of H-2 receptor blockers and proton pump inhibitors, and the improvement in surgical techniques all have revolutionized the diagnosis, treatment and outcome of this condition. Nevertheless, GDUs are still associated with high rates of morbidity, mortality and complications. Thus, surgical evaluation of a patient with a GDU should remain an integral part of patient care. These giant variants, while usually benign, can frequently harbor malignancy. A careful review of the literature highlights the important differences when comparing GDUs to classical peptic ulcers and why they must be thought of differently than their more common counterpart.

© 2008 The WJG Press. All rights reserved.

Key words: Giant duodenal ulcer; *Helicobacter pylori*; Nonsteroidal anti-inflammatory drugs; Malignancy; Endoscopy

Peer reviewer: Vasiliy I Reshetnyak, MD, PhD, Professor, Scientist Secretary of the Scientific Research Institute of General Reanimatology, 25-2, Petrovka str., Moscow 107031, Russia

Newton EB, Versland MR, Sepe TE. Giant duodenal ulcers. *World J Gastroenterol* 2008; 14(32): 4995-4999 Available from: URL: http://www.wjgnet.com/1007-9327/14/4995.asp DOI: http://dx.doi.org/10.3748/wjg.14.4995

INTRODUCTION

The history of giant duodenal ulcers (GDUs) dates back to 1931 when Brdiczka first described these exceptionally large ulcers[1]. Initially, GDUs were notable for being difficult to diagnose with barium roentgenogram[2,3] and their high morbidity and mortality[4-6]. Prompt and correct diagnosis was often delayed, and for decades the only curative intervention was invasive, surgical procedures fraught with technical difficulties. Until the early 1980's, few cases were ever described within medical literature in which patients with GDUs were successfully treated with medical therapy. Since the late 1970's and early 80's, technological and pharmacological advancements have markedly changed the manner in which physicians diagnose, treat and manage patients with GDUs. The widespread use of endoscopy, the introduction of H-2 receptor blockers and proton pump inhibitors, and the improvement in surgical techniques have all contributed to this evolution. Despite this, we suggest that GDUs remain an under recognized entity, and are often assumed to be identical to standard sized ulcers. A careful review of the literature highlights the important differences when comparing GDUs to classical peptic ulcers and why they must be thought of differently than their more common counterpart.

HISTORY AND DEFINITION

Brdiczka is credited with being the first to describe GDUs and their radiographic appearance[1]. Most early case reports and small series emphasized the common problem of missed diagnosis on barium studies[7-10]. This was due to the fact that the ulcer crater was so large it would often be mistaken for a normal or slightly deformed duodenal cap. Kirsh and Brendel best illustrated this in their 1968 publication[4]. They examined 42 cases of GDU and found that only 24 were correctly diagnosed with a barium meal. They also established criteria for the diagnosis of GDUs. Their criteria included: an ulcerative crater greater than 2 cm, performance of the roentgen examination before surgical or pathological demonstration of ulcer, proof

that the lesion was benign and confirmation at surgery or post-mortem examination. Over the years, with the advent and technologic advancements of endoscopic evaluation, the criteria have unofficially evolved. Today, endoscopy has essentially replaced barium contrast studies for visualization of the upper gastrointestinal tract and there is little difficulty with the diagnosis of these lesions. GDUs are generally now defined simply as a benign, full thickness ulcer at least 2 cm in diameter, and usually involving a large portion of the duodenal bulb[11].

EPIDEMIOLOGY

Peptic ulcer disease remains a common medical problem worldwide, with the lifetime prevalence ranging from approximately 11% to 20% for men, and 8% to 11% for women[12]. Given this substantial lifetime prevalence, there are major economic loses and health care expenditures due to this problem. GDUs comprise approximately 1%-2% of all duodenal ulcers[13] and 5% of peptic ulcers requiring surgical intervention[14]. In most epidemiologic studies, the male to female ratio of standard sized ulcer disease is 2.3 to 1[15], and the ratio in those with GDUs is approximately 3 to 1[11].

The etiology of standard sized and GDUs has been associated with two major contributing causes: recent usage of nonsteroidal anti-inflammatory drugs (NSAIDs), and *Helicobacter pylori* (*H pylori*) infection. Worldwide, infection with *H pylori* continues to be widespread despite decreasing prevalence in select countries such as the United States. In addition, NSAID use has remained high, and the point prevalence of standard sized duodenal ulcers can reach 19% in chronic NSAID users[16]. Given these statistics, the clinician's awareness and familiarity with GDUs will be necessary, as patients will assuredly continue to develop these dangerous variants of peptic ulcer disease.

PATHOPHYSIOLOGY

As stated above, GDUs have been most commonly associated with recent NSAID use and *H pylori* infection. The mechanism by which each of these factors causes duodenal ulcers is markedly different. Simply stated, *H pylori* infection has been shown to lead to a dysregulation of acid secretion, and an antral predominant gastritis. This leads to a high duodenal acid load and promotes gastric metaplasia within the duodenal bulb. This in turn favors *H pylori* colonization in the duodenum within these islands of gastric metaplasia. Through multiple different mechanisms, the bacteria cause inflammation within the duodenum, which is exacerbated by the increased acid load, and ultimately leads to the formation of an ulcer[17]. Meanwhile, NSAIDs lead to ulcer formation primarily through the inhibition of prostaglandins and direct mucosal injury[17].

The true incidence of *H pylori* in standard sized duodenal ulcer formation is not known, but recent data suggests that it exceeds 85%[18,19]. However, two recent studies suggest that the percentage of GDUs caused by *H pylori* is less than when compared to standard sized ulcers, and that NSAID use may play a more prominent role[20,21]. In 1999, Fischer *et al* reviewed 28 cases of GDU. In their study, only 39% of patients tested were found to have *H pylori* infection. In addition, Colleen *et al*[20] evaluated 184 patients with duodenal ulcers, and compared patients with standard sized ulcers to those with GDUs. They found that 53% of patients with GDUs had used daily NSAIDs in the month prior to presentation versus only 8% in the standard sized duodenal ulcer group. This same study also evaluated the basal acid output of patients with GDUs as compared to those with standard size ulcers; however, no significant difference existed[20].

This collection of data suggests that daily NSAID use plays a more prominent role in the formation of GDUs than in standard sized duodenal ulcers. And while *H pylori* infection likely plays a role in the formation of GDUs, it is not as prevalent as it is with the formation of standard size duodenal ulcers.

Unfortunately, little data exists to explain the pathophysiologic differences that lead certain patients to develop these giant variants. Plausible explanations include genetic predisposition, dietary or environmental factors, microbial influence, variations in immunologic response or any combination of these factors[22,23]. Clearly, investigation and research are necessary to help provide further insight into these heretofore unexplained mechanisms.

CLINICAL FEATURES

The presenting symptoms of most patients reflect the anatomical changes and the histopathology of the disease process. The most common of these symptoms is abdominal pain. Most patients describe the pain as involving the epigastric region, and some experience involvement of the right hypochondrium and/or radiation into the back. This requires the physician to include biliary and pancreatic pathology in their differential diagnosis. The pain of these ulcers has been described as more persistent than classically described with smaller duodenal ulcers. In addition, patients with GDUs are not provided relief from food or alkali[6,24].

The majority of GDUs will present with hemorrhage[6,25]. This may manifest with melena, hematochezia, hematemesis, or any combination of the above. Anemia typically occurs in the setting of the bleeding ulcers. Surgical and endoscopic evaluation has often revealed the gastroduodenal artery within the ulcer bed. The size of the ulcer and the surrounding inflammation may cause gastric outlet obstruction. This often causes nausea and vomiting. Obstruction may be evident endoscopically by the presence of a large volume of gastric contents.

Additionally, the inflammatory mass can produce significant constitutional symptoms such as weight loss, cachexia, malnutrition and chronic abdominal pain. This constellation of symptoms can often mislead the clinician to suspect malignancy as the most likely

diagnosis.

Other important historical features are the personal history of ulcer disease and the recent use of NSAIDs. Some case series note that over 40% of patients will have a prior history of a peptic ulcer[11]. In 1994, Colleen *et al*[20] revealed that patients with daily NSAID use greater than 1 mo prior to presentation had a markedly increased risk of forming GDUs.

It is well known that there is a high rate of complications with GDUs, and these complications directly lead to the high morbidity and mortality associated with this entity[5,6,25]. Common complications encountered with GDUs include bleeding and, on occasion, massive hemorrhage. One study showed that a GDU with adherent clot or a visible vessel on index EGD is a marker of an ulcer that is more likely to require surgical intervention[21]. Another feared complication is perforation. In previous case series, the perforation rate has varied between 0% and 7%[20,21,25,26]. Other complications include obstruction of the affected portion of the duodenum or proximal pylorus due to the massive inflammatory response, fistula formation, adhesions to or erosions into surrounding organs, and stricture formation in the biliary tree, pancreatic duct or the small bowel itself. These inflammatory changes are also one of the reasons that make a surgical approach fraught with technical difficulties[11,25,26].

DIAGNOSIS

As discussed above, the difficulty in diagnosis of GDUs has been one of the hallmarks of this disease entity since first described. Making the radiographic diagnosis by barium meal has been difficult[2,3]. The size of the ulcer often causes replacement of the duodenal bulb. As a result, GDUs may be altogether missed or misinterpreted as a deformed bulb, diverticulum or pseudodiverticulum during a barium study. The radiographic criteria to make the diagnosis of GDU were summarized by Klamer and Mahr in 1978[25]. Despite increased awareness of these criteria by clinicians, the successful diagnosis based solely on upper GI series remained unacceptably low. As a result, the entity of GDUs was likely under-diagnosed and frequently missed[4].

The advent and widespread use of endoscopy has markedly improved clinician's ability to detect GDUs with greater accuracy[27]. Jaszewski *et al* highlighted this in 1983. In their series, seven cases of GDU were initially evaluated by upper GI barium meal. EGD then followed. GDUs were successfully diagnosed with roentgenography in only three of the seven cases. However, endoscopy confirmed the presence in all seven cases. This highlighted the importance of endoscopy in patients with symptoms suggestive of giant or regular duodenal ulcers. Subsequent case series have since used only endoscopy with measurements as diagnostic criteria[13,21]. Indeed, barium studies are now used far less frequently, typically when endoscopy is contraindicated or incapable of passing through a stricture. As a result, many clinicians may now encounter a GDU during an endoscopy without the expectation of finding one, and may be inclined to misdiagnose a GDU as a simple peptic ulcer. Please see Figure 1 for an example of a GDU appearance during endoscopy.

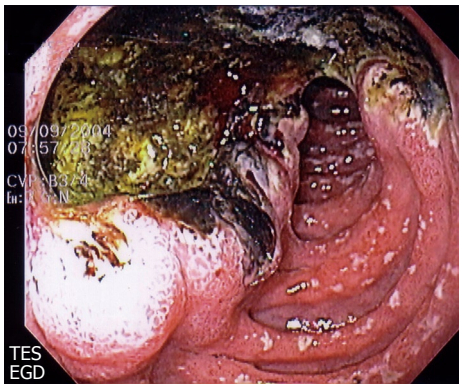

Figure 1 Endoscopic photograph of a Giant Duodenal Ulcer in a patient taking NSAIDs. The ulcer involves the proximal second portion of the duodenum. The ulcer seen is larger than 2 cm, and involves over fifty percent of the mucosal circumference.

The other obvious benefit of endoscopy is the ability to biopsy. This allows the clinician to exclude a neoplastic source as the cause of ulcer formation. While routine biopsy of standard sized duodenal ulcers is generally not recommended, this practice is worthwhile in the setting of GDUs, particularly those with nodularity at the edge. These giant variants, while usually benign, can frequently harbor malignancy. This was supported by a recent review of 52 cases of duodenal ulcers larger than 2 cm which were biopsied by Rathi *et al*. They found a malignancy rate of approximately 19% (primary duodenal carcinoma in 15%, lymphoma and tuberculosis in 2% each)[13]. Thus, we recommend multiple biopsies from the ulcer edges in all cases of GDUs.

DIFFERENTIAL DIAGNOSIS

Prior to endoscopy, the differential diagnosis of benign GDUs had to include entities that mimicked its appearance on upper GI series. This included carcinoma of the duodenum, lymphosarcoma, duodenal diverticulum, pseudodiverticulum, regional enteritis, MALT lymphoma and tuberculosis. However, with the widespread use of endoscopy as detailed above, the differential diagnosis is somewhat narrowed. Frequently, the endoscopist cannot differentiate a benign giant ulcer from a malignant one macroscopically. As described above, patients may present with insidious symptoms such as weight loss, anorexia, and malnutrition raising concern for a malignant etiology. Therefore, again, biopsy and histopathologic examination is a necessity. Gastrinoma must also be included in the differential diagnosis, particularly in patients with evidence of acid hypersecretion, multiple ulcers extending beyond the second portion of the duodenum, diarrhea or a personal or family history of multiple endocrine neoplasia type 1 (MEN1).

TREATMENT

Prior to the introduction of H2 receptor blockers in the late 1970's, GDUs were managed primarily with surgery. This was reflected in the literature, as before 1982, there were very few cases published detailing successful medical management of GDUs[10-12]. Lumsden was able to document one patient who was a long-term (> 6 mo), asymptomatic survivor of a GDU after medical treatment only[6].

Initially, the mortality rate associated with surgical management of GDUs was extremely high, reaching greater than 40% in early case series[24,25]. Those patients who had prompt and accurate pre-operative diagnosis had the lowest mortality. The inflammatory qualities of GDUs that make them distinct in size and nature from standard ulcers also make them more difficult to approach surgically[11]. Classically, the surgical technique most commonly recommended is truncal vagotomy and subtotal gastrectomy[21]. However, technical variations of the surgical approach have been debated. For example, management of the duodenal stump has been controversial[11,28].

In subsequent decades, the mortality rate has fallen markedly due to numerous factors including improved radiographic technique, the advent of endoscopy and improved surgical and anesthetic techniques[11,21]. Most recently, since the 1970s, the advent of new acid suppression medication, the discovery of *H pylori* and its role in ulcer formation, and the importance of eradication therapy has led to the possibility of successful medical management of GDUs[21,27,29].

In 1983, Jaszewski *et al*[27] reviewed 14 consecutive cases of GDUs between 1980 and 1982. Nine patients qualified for a trial of extended conservative medical treatment with close follow up. They were treated with cimetidine 1200 mg daily and antacids every 2 h while awake. Eight of the nine patients were successfully treated with the medical regimen and were asymptomatic for a mean of 14.9 mo. One patient failed medical treatment and had a perforation on day 23. This study suggested that medical treatment of uncomplicated GDUs could be accomplished with medical management, close observation and follow up with the assistance of endoscopic monitoring. In a Letter to the Editor responding to this article, Porro *et al* retrospectively reviewed 23 cases of GDUs, nine of which were eligible for similar treatment with cimetidine. Their letter agreed that H2 receptor blockers could be used as short-term medical treatment of GDUs[30].

Both of these reviews were performed before the release of proton pump inhibitors. In 1999, Fischer *et al*[21] published a prospective study of 28 patients with GDUs. One patient met criteria for immediate surgical referral, and the remaining 27 were placed on omeprazole 40 mg by mouth daily. Of these 27 patients, 7 required secondary surgical treatment for GDU complications or failure of medical therapy (4 emergent operations for re-bleeding, 3 elective operations for gastric outlet obstruction). Of these twenty remaining patients, fifteen of them had complete documented healing on endoscopy. Of the eight patients requiring surgery, seven had a visible vessel or adherent clot on index EGD. Lastly, only 39% of patients had evidence of *H pylori* infection, and these patients were less likely to require surgery than those who were *H pylori* negative. The authors concluded that omeprazole appears to be a safe first-line treatment in stable patients, and should decrease the eventual need for operative intervention.

Several studies have confirmed the superiority of proton pump inhibitors (PPIs) versus H2 receptor blockers in the treatment of standard sized gastric and duodenal ulcers[31-34]. Thus, attempts at medical treatment of GDUs should consist of proton pump inhibitors.

Despite the marked improvement delivered by the administration of proton pump inhibitors, GDUs are still associated with high rates of morbidity, mortality and complications. Thus, surgical evaluation of a patient with a GDU should remain an integral part of patient care. Indeed, there are indications for emergent and elective surgical intervention. The most common emergent indications include uncontrolled hemorrhage and perforation whereas unresolving obstruction, intractable or recurrent bleeding, and fistula formation are some of the elective indications[14]. Based on the data above, PPIs should be administered as a medical adjunct to the operation.

Lastly, discontinuation of NSAIDs and antimicrobial treatment of *H pylori* infection are recommended in the presence of these risk factors. Eradication of *H pylori* has been well documented to improve healing of peptic ulcers[29,35].

CONCLUSION

Historically, the two hallmark features of GDU disease were the difficulties in prompt diagnosis and the failures of medical management. A review of the literature suggests the changing nature of both of these features. The advent and widespread use of endoscopy has made a prompt diagnosis of GDU more accurate and easy to obtain. Once a diagnosis has been made, initiation of therapy can begin. Uncontrolled hemorrhage, perforation and unstable patients still should be cared for with immediate surgical evaluation and management. Recent data examining the use of H2-receptor blockers and proton pump inhibitors suggest that stable patients may be safely treated initially with medication, close observation and repeat endoscopic evaluation[21,27,30]. In addition, endoscopic biopsies allow a clinician to test for malignant etiologies of giant ulcers, which may be more common than suspected[13]. For this reason, we recommend that biopsies should be performed on all duodenal ulcers > 2 cm in diameter, particularly those with nodular appearing edges.

Due to evolving endoscopic and medical therapies, the management of GDUs has changed. What was once a disease that was difficult to diagnose, and managed solely with surgical intervention has become one easily diagnosed and potentially treated medically. It is of utmost importance that physicians recognize GDUs as

being different than their standard sized counterparts, and that we continue to further our understanding of this entity.

REFERENCES

1 **Brdiczka JG**. Das Grosse ulcus duodeni in rontgenbild. *Fortschr Geb Rontgenstr* 1931; **44**: 177-181
2 **Freedman E**, Goehring HD. Diagnostic errors in ulcerative lesions of the stomach and duodenum. *Am J Roentgenol Radium Ther* 1940; **44**: 48-58
3 **Elkin WP**. Diagnostic problems in cases of large or giant duodenal ulcer. *Radiology* 1941; **37**: 748-750
4 **Kirsh IE**, Brendel T. The importance of giant duodenal ulcer. *Radiology* 1968; **91**: 14-19
5 **Carmichael JL**, Tidwell OK. Giant duodenal ulcer: a case report and brief review of the literature. *Ala J Med Sci* 1970; **7**: 385-387
6 **Lumsden K**, MacLarnon JC, Dawson J. Giant duodenal ulcer. *Gut* 1970; **11**: 592-599
7 **Evashwick G**. Giant benign duodenal ulcer; report of a case. *Ann Surg* 1951; **133**: 417-420
8 **Bullock WK**, Snyder EN. Benign giant duodenal ulcer. *Gastroenterology* 1952; **20**: 330-336
9 **Stainton RM**, Growdon JH. Benign giant duodenal ulcer. *Am Surg* 1957; **23**: 1081-1096
10 **Pinck RL**, Held BT. Giant ulcers or walled-off perforations of the duodenum. *N Engl J Med* 1961; **264**: 541-543
11 **Nussbaum MS**, Schusterman MA. Management of giant duodenal ulcer. *Am J Surg* 1985; **149**: 357-361
12 **Kurata JH**, Nogawa AN, Abbey DE, Petersen F. A prospective study of risk for peptic ulcer disease in Seventh-Day Adventists. *Gastroenterology* 1992; **102**: 902-909
13 **Rathi P**, Parikh S, Kalro RH. Giant duodenal ulcer: a new look at a variant of a common illness. *Indian J Gastroenterol* 1996; **15**: 33-34
14 **Gustavsson S**, Kelly KA, Hench VS, Melton LJ 3rd. Giant gastric and duodenal ulcers: a population-based study with a comparison to nongiant ulcers. *World J Surg* 1987; **11**: 333-338
15 **Watanabe Y**, Kurata JH, Kawamoto K, Kawai K. Epidemiological study of peptic ulcer disease among Japanese and Koreans in Japan. *J Clin Gastroenterol* 1992; **15**: 68-74
16 **Loeb DS**, Talley NJ, Ahlquist DA, Carpenter HA, Zinsmeister AR. Long-term nonsteroidal anti-inflammatory drug use and gastroduodenal injury: the role of Helicobacter pylori. *Gastroenterology* 1992; **102**: 1899-1905
17 **Shiotani A**, Graham DY. Pathogenesis and therapy of gastric and duodenal ulcer disease. *Med Clin North Am* 2002; **86**: 1447-1466, viii
18 **Ciociola AA**, McSorley DJ, Turner K, Sykes D, Palmer JB. Helicobacter pylori infection rates in duodenal ulcer patients in the United States may be lower than previously estimated. *Am J Gastroenterol* 1999; **94**: 1834-1840
19 **Bytzer P**, Teglbjaerg PS. Helicobacter pylori-negative duodenal ulcers: prevalence, clinical characteristics, and prognosis--results from a randomized trial with 2-year follow-up. *Am J Gastroenterol* 2001; **96**: 1409-1416
20 **Collen MJ**, Santoro MJ, Chen YK. Giant duodenal ulcer. Evaluation of basal acid output, nonsteroidal antiinflammatory drug use, and ulcer complications. *Dig Dis Sci* 1994; **39**: 1113-1116
21 **Fischer DR**, Nussbaum MS, Pritts TA, Gilinsky NH, Weesner RE, Martin SP, Giannella RA. Use of omeprazole in the management of giant duodenal ulcer: results of a prospective study. *Surgery* 1999; **126**: 643-648; discussion 648-649
22 **Arkkila PE**, Kokkola A, Seppala K, Sipponen P. Size of the peptic ulcer in Helicobacter pylori-positive patients: association with the clinical and histological characteristics. *Scand J Gastroenterol* 2007; **42**: 695-701
23 **Karpouza A**, Samouilidou E, Karagiannis S, Kostopoulou V, Sotiropoulou M, Roma E, Petraki K, Michopoulos S. Patients with duodenal ulcer have lower levels of serum cholesterol compared to other dyspeptic patients independently of Helicobacter pylori status. *Scand J Gastroenterol* 2008; **43**: 922-928
24 **Mistilis SP**, Wiot JF, Nedelman SH. Giant duodenal ulcer. *Ann Intern Med* 1963; **59**: 155-164
25 **Klamer TW**, Mahr MM. Giant duodenal ulcer: a dangerous variant of a common illness. *Am J Surg* 1978; **135**: 760-762
26 **Morrow CE**, Mulholland MW, Dunn DH, Schwartz ML, Sutherland DE, Goodale RL, Humphrey E, Najarian JS. Giant duodenal ulcer. *Am J Surg* 1982; **144**: 330-331
27 **Jaszewski R**, Crane SA, Cid AA. Giant duodenal ulcers. Successful healing with medical therapy. *Dig Dis Sci* 1983; **28**: 486-489
28 **Wu X**, Zen D, Xu S, Zhang L, Wang P. A modified surgical technique for the emergent treatment of giant ulcers concomitant with hemorrhage in the posterior wall of the duodenal bulb. *Am J Surg* 2002; **184**: 41-44
29 **Arkkila PE**, Seppala K, Kosunen TU, Sipponen P, Makinen J, Rautelin H, Farkkila M. Helicobacter pylori eradication as the sole treatment for gastric and duodenal ulcers. *Eur J Gastroenterol Hepatol* 2005; **17**: 93-101
30 **Bianchi Porro G**, Lazzaroni M, Petrillo M. Giant duodenal ulcers. *Dig Dis Sci* 1984; **29**: 781
31 **Walan A**, Bader JP, Classen M, Lamers CB, Piper DW, Rutgersson K, Eriksson S. Effect of omeprazole and ranitidine on ulcer healing and relapse rates in patients with benign gastric ulcer. *N Engl J Med* 1989; **320**: 69-75
32 **Bader JP**, Delchier JC. Clinical efficacy of pantoprazole compared with ranitidine. *Aliment Pharmacol Ther* 1994; **8** Suppl 1: 47-52
33 **Yeomans ND**, Tulassay Z, Juhasz L, Racz I, Howard JM, van Rensburg CJ, Swannell AJ, Hawkey CJ. A comparison of omeprazole with ranitidine for ulcers associated with nonsteroidal antiinflammatory drugs. Acid Suppression Trial: Ranitidine versus Omeprazole for NSAID-associated Ulcer Treatment (ASTRONAUT) Study Group. *N Engl J Med* 1998; **338**: 719-726
34 **Agrawal NM**, Campbell DR, Safdi MA, Lukasik NL, Huang B, Haber MM. Superiority of lansoprazole vs ranitidine in healing nonsteroidal anti-inflammatory drug-associated gastric ulcers: results of a double-blind, randomized, multicenter study. NSAID-Associated Gastric Ulcer Study Group. *Arch Intern Med* 2000; **160**: 1455-1461
35 **Arkkila PE**, Seppala K, Kosunen TU, Haapiainen R, Kivilaakso E, Sipponen P, Makinen J, Nuutinen H, Rautelin H, Farkkila MA. Eradication of Helicobacter pylori improves the healing rate and reduces the relapse rate of nonbleeding ulcers in patients with bleeding peptic ulcer. *Am J Gastroenterol* 2003; **98**: 2149-2156

S- Editor Li DL **L- Editor** Li M **E- Editor** Lin YP

Online Submissions: wjg.wjgnet.com
wjg@wjgnet.com
doi:10.3748/wjg.14.5000

World J Gastroenterol 2008 August 28; 14(32): 5000-5007
World Journal of Gastroenterology ISSN 1007-9327
© 2008 The WJG Press. All rights reserved.

GASTRIC CANCER

Mechanism and pathobiologic implications of CHFR promoter methylation in gastric carcinoma

Yu-Jia Gao, Yan Xin, Jian-Jun Zhang, Jin Zhou

Yu-jia Gao, Yan Xin, The Fourth Laboratory of Cancer Institute & Department of Tumor Pathology of General Surgery Institute, The First Affiliated Hospital of China Medical University, Shengyang 110001, Liaoning Province, China
Jian-Jun Zhang, Jin Zhou, Department of Surgery and Internal Medicine, Liaoning Tumor Hospital, Shengyang 110042, Liaoning Province, China
Author contributions: Gao YJ, Xin Y contributed equally to this work; Gao YJ and Xin Y designed and performed the research; Gao YJ and Xin Y were responsible for data management and analysis; Zhang JJ and Zhou J assisted with the data collection and provided specimens; Gao YJ wrote the manuscript.
Supported by The National Natural Science Foundation of China, No. 30371607, the Special Scientific Research Foundation for Distinguished Researchers, Education Department of Liaoning Province, No. 2006R53
Correspondence to: Yan Xin, The Fourth Laboratory of Cancer Institute & Department of Tumor Pathology of General Surgery Institute, The First Affiliated Hospital of China Medical University, Shengyang 110001, Liaoning Province, China. yxin@mail.cmu.edu.cn
Telephone: +86-24-83282351 Fax: +86-24-83282351
Received: June 4, 2008 Revised: August 11, 2008
Accepted: August 18, 2008
Published online: August 28, 2008

Abstract

AIM: To investigate the aberrant methylation of CHFR promoter in human gastric cancer (GC) and its impact on the expression of *CHFR* mRNA and protein, as well as its correlation with clinical and histological features of human GC.

METHODS: Methylation-specific polymerase chain reaction (MSPCR) was used to detect the methylation status of CHFR promoter in 20 primary GC samples and paired normal gastric mucosa. The *CHFR* mRNA and protein expressions were investigated both by RT-PCR and by Western blotting. The CHFR protein expression in 69 GC samples was immunohistochemically examined.

RESULTS: The DNA methylation of the *CHFR* gene was found in 9 of the 20 GC samples (45%) and the down-regulation of *CHFR* mRNA and protein was significantly associated with the methylation status of the *CHFR* gene (P = 0.006). In 20 samples of corresponding non-neoplastic mucosa, no DNA methylation of the CHFR gene was detected. The *CHFR* gene methylation in poorly differentiated GC samples was significantly higher than that in well-differentiated GC samples (P = 0.014). Moreover, the negative CHFR protein expression rate in paraffin-embedded GC samples was 55.07% (38/69), the positive rate in poorly differentiated GC samples was 36.73% (18/49), which was significantly lower than 65.00% (13/20) in well-differentiated GC samples (χ^2 = 4.586, P = 0.032).

CONCLUSION: Aberrant methylation of the *CHFR* gene may be involved in the carcinogenesis and development of GC, and is the predominant cause of down-regulation or loss of *CHFR* mRNA or protein expression. As aberrant methylation of CHFR promoter is correlated with tumor differentiation, it may help to predict the prognosis of GC and *CHFR* may become a novel target of gene therapy for GC in the future.

© 2008 The WJG Press. All rights reserved.

Key words: *CHFR* gene; Gastric carcinoma; DNA methylation

Peer reviewer: Dr. Richard A Rippe, Department of Medicine, The University of North Carolina at Chapel Hill, Chapel Hill, NC 27599-7038, United States

Gao YJ, Xin Y, Zhang JJ, Zhou J. Mechanism and pathobiologic implications of CHFR promoter methylation in gastric carcinoma. *World J Gastroenterol* 2008; 14(32): 5000-5007 Available from: URL: http://www.wjgnet.com/1007-9327/14/5000.asp DOI: http://dx.doi.org/10.3748/wjg.14.5000

INTRODUCTION

Gastric cancer (GC) is one of the most common malignancies worldwide[1]. As other malignant tumors, gastric carcinogenesis is a pathological process involving multiple genes and steps. The relevant genes are mainly oncogenes, tumor suppressor genes, and DNA mismatch repair genes. Tumor suppressor genes may lose their functions by gene mutation, loss of heterozygosity and methylation of promoters. Methylation is an epigenetic modification whereby the gene activity is controlled by adding methyl groups (CH3) to specific cytosines of the DNA. This control mechanism is important during mammalian embryonic development, and has received increasing attention in

carcinogenesis research[2]. Aberrant DNA methylation can change the chromosomal structure and DNA stability, cause abnormalities of gene expression, and affect proliferation and differentiation of tumors[3]. Hypermethylation in the promoter region, as a key factor for carcinogenesis, causes silencing of suppressor genes[4,5]. *CHFR* (checkpoint with FHA and RING finger) is a mitotic checkpoint gene that is localized at chromosome 12q24.33. *CHFR* encodes a protein with FHA and RING finger domains that governs transition from prophase to metaphase in the mitotic checkpoint pathway. In cellular response to mitotic stress by microtubule inhibitors, *CHFR* activation delays chromosome condensation during prophase and increases the cells' ability to survive the stress[6]. *CHFR* prevents errors in chromosome segregation that can lead to neoplasia. Recently, some studies showed that *CHFR* is an important tumor suppressor gene and its encoding product is a ubiquity ligase of Plk1[7-10]. Plk1 regulates both Wee1 kinase and Cdc25C phosphatase, which in turn control the Cdc2 kinase activity at the G2 to M transition. The *CHFR* gene can ubiquitinate and degenerate the Plk1, which prevents cells from entering prophase and metaphase. *CHFR* is ubiquitously expressed in normal human tissues while loss of *CHFR* expression has been observed in human tumors, in which it fails to prevent proliferation of abnormal cells from G2 to M phase, and abnormal differentiation and proliferation of cells occurs[11]. Moreover, CHFR protein, comprised of fork head- associated FHA and RING-finger (RF) domain, is frequently down-regulated in human colon cancer and GC (up to 50%). Loss of *CHFR* mRNA expression is a consequence of promoter methylation, suggesting that it plays a tumor suppressor role in gastrointestinal carcinogenesis. The checkpoint function of the FHA domain of *CHFR* is a core component of anti-proliferating properties against gastrointestinal carcinogenesis[12]. GC is the second most common cause of cancer-related death in Asia. Although surgery is the standard treatment for this disease, early detection and treatment are the only way to reduce its mortality[13].

This study was performed to assess the methylation of CHFR promoter in Chinese GC tissue samples, its impact on gene expression, and its correlation with the clinical and pathobiological characteristics of GC.

MATERIALS AND METHODS

Tissue samples and DNA extraction

We studied GC samples and adjacent normal mucosa from 20 patients who underwent surgical resections at the Department of Surgery of Liaoning Tumor Hospital (Shengyang, China) from March to September 2007. None of these patients received chemotherapy or radiotherapy before surgery. Informed consent for use of the samples was obtained from each patient before surgery. All tissue samples were confirmed by histopathology. The samples were placed in liquid nitrogen immediately and then stored at -80℃ until analysis. For immunohistochemical analysis, we used archival formalin-fixed, paraffin-embedded tissues from 69 GC patients and paired normal gastric mucosa, which were obtained from the First Affiliated Hospital of China Medical University during December 2003 to May 2004. Age and sex of the patients, tumor size, differentiation degree, Borrman type, depth of tumor invasion and status of lymph node metastasis were obtained from the histopathological reports of these patients. We attributed highly or moderately differentiated adenocarcinoma to "well differentiated", and attributed adenocarcinoma, mucinous carcinoma and signet cell carcinoma to "poorly differentiated". High molecular weight genomic DNA was extracted using the TIANamp genomic blood/cell/tissue genomic DNA kit (TIANGEN Biotech, Beijing), according to the manufacturer's instructions.

Bisulfite modification and methylation-specific poly merase chain reaction (MSPCR)

Sodium bisulfite treatment of DNA converted all unmethylated cytosines to uracils, but the level of methylated cytosines was unaffected. Briefly, 2 μg aliquots of genomic DNA was denatured by adding 6 μL freshly prepared 3 mol/L NaOH and incubating the solution at 37℃ for 10 min. For complete denaturation, the samples were incubated at 95℃ for 1 min and subsequently cooled on ice. Bisulphate solution was prepared by dissolving 8.1 g sodium bisulphate in 16 mL H_2O, adding 30 μL 10 mmol/L hydrochinone solution and adjusting the pH to 5.0 with 520 μL 3 mol/L NaOH. Bisulphate solution (0.5 mL) was mixed with the denatured DNA, overlaid with mineral oil, and incubated at 50℃ for 17.5 h in a water bath in the dark. DNA was recovered using the Wizard DNA clean-up system (Promega, Madison, WI, USA) and eluted in 100 μL H_2O. Following this, 11 μL 3 mol/L NaOH was added and the sample was incubated for 15 min at 37℃. The solution was then neutralized by adding 110 μL 16 mol/L NH_4OAC (pH 7.0). DNA was ethanol-precipitated, washed with 70% ethanol, dried and resuspended in 50 μL distilled H_2O. Bisulphate-treated DNA, as a template for MSPCR, was used in each of the PCR assays. Amplification was carried out in a 25 μL reaction volume containing 2 μL 1 × PCR buffer, 2.0 mmol/L $MgCl_2$, 2.5 mmol/L dNTPs, 50 mg/mL DMSO, 10 μmol/L each primer, 50 ng DNA template, 2 U hot start Taq polymerase (Finzymes OY, Finland). After heating at 95℃ for 5 min, PCR was performed in a thermal cycler for 40 cycles of denaturation at 95℃ for 45 s, annealing at 51℃ (CHFR-UMS) or at 55℃ (CHFR-MS) for 45 s and extension at 72℃ for 45 s. Distilled water without DNA was used as a negative control. The PCR products were separated on 3.0% agarose gels. The following primer sets were used: CHFR M forward (5'-TTTT AATATAATATGGCGTCGATC-3'), a CHFR M reverse (5'-AACGACAACTAAAACGAAACCG-3') for methylated CHFR sequences, which could amplify a 141-base pair product. CHFR U forward (5'-GTTT

TAATATAATATGGTGTTGATT-3') and CHFR U reverse (5'-AAAACAACAACTAAAACAAA CCA-3') for unmethylated CHFR sequences, which could amplify a 144-base pair product as described previously[14].

Reverse transcription-PCR (RT-PCR)

Expression of the *CHFR* gene was analyzed by RT-PCR. Total RNA was extracted with TRIzol reagent (Invitrogen, Carlsbad, CA, USA) according to the manufacturer's instructions. First-strand cDNA was generated using a first strand cDNA synthesis kit (Qiagen, German), then amplified by a primer set that is specific for the *CHFR* gene. The primer sequences are CHFR S (sense):5'-TAAAGGAAGTGGTCCCTCTGTG-3' and CHFR AS (anti-sense): 5'-GGTTTGGGCATTTCTA CGC-3', which resulted in a DNA product of 205 bp. The PCR amplification consisted of 1 cycle at 95℃ for 5 min, 35 cycles at 95℃ for 30 s, at 58℃ for 45 s, and at 72℃ for 1 min, and 1 cycle at 72℃ for 6 min. The expression of β-actin was used as a control to confirm the success of RT-PCR using the following primer pair: 5'-AGTTGCGTTACACCC TTTCTTG-3' (forward) and 5'-TCACCTTCACCGTTCCAGTTT-3' (reverse). The PCR products were separated by 2% agarose gel electrophoresis, stained with ethidium bromide, and visualized under UV light. Electrophoresis strips were analyzed by BANDSCAND 5.0 software and the optical density ratio of target mRNA to β-actin served as an index for statistical analysis. If the relative optical density value of *CHFR* mRNA expression was decreased more than 50% compared with paired normal gastric mucosa, it was defined as down-regulation of expression. No expression was regarded as loss of mRNA expression.

Western blotting

Tumor and control tissue samples were homogenized for extract preparations in an ice-cold mild lysis buffer containing 10 mL/L nonidet P-40, 0.15 mol/L NaCl, 0.01 mol/L sodium phosphate (pH 7.2), 2 mmol/L EDTA, 50mmol/L sodium fluoride, 0.2 mmol/L sodium vanadate, and 1 μg/mL aprotinin. The tissue homogenates were centrifuged at 20 000 r/min for 15 min and supernatants were collected. Protein density was determined by Coomassie brilliant blue, and then 12% SDS polyacrylamide gel electrophoresis was performed. Separated proteins were then transferred onto nitrocellulose membranes, which were blocked in 50 g/L nonfat milk in TBST (TBS buffer containing 1 g/L Tween 20) for 2 h at room temperature, incubated in primary antibodies specific for mouse CHFR (1:400 dilution) for 2 h, washed and probed with horseradish peroxidase-conjugated secondary antibody for 1 h at room temperature. Immunoreactive bands were visualized by enhanced chemiluminescence (Santa Cruz Biotechnology, Santa Cruz, CA, USA). The specific bands were quantified by BANDSCAN 5.0 software and the optical density ratio of target protein to β-tubulin served as an index for statistical analysis. If the relative optical density value of CHFR protein expression was decreased more than 50% compared with paired normal gastric mucosa, it was defined as down-regulation of expression. No expression was regarded as loss of protein expression.

Immunohistochemical staining

Tissue chips of GC, precancerous lesions and normal gastric mucosa were immunohistochemically stained by the Envision method. Immuno-bridge kits, mouse anti-human CHFR monoclonal antibody (diluted at 1:75) were bought from Abnova Company. All steps were accomplished in accordance with the instructions. PBS (0.01 mol/L, pH7.4) was used instead of specific antibodies for negative control. Immunohistochemical staining was graded as positive if the staining signals of CHFR protein were yellow brown granules and located in cytoplasm. For each sample, two representative high power fields were examined. The average positive rate was assessed by the percent of positive cells in the totally counted 100 cells from two representative high power fields. Positive cells ≤ 20% of the totally counted cells were defined as negative while positive cells > 20% of the totally counted cells as positive.

Statistical analysis

The data were processed by SPSS 13.0 statistical software. Quantitative data were expressed as mean ± SD. Data were analyzed by Fisher's exact test and chi square test, independent sample t-test and Spearman rank related test. $P < 0.05$ was considered statistically significant.

RESULTS

Aberrant methylation of CHFR gene in GC tissue samples

The representative results of MSPCR for the *CHFR* gene promoter in GC samples are shown in Figure 1 and Table 1. DNA methylation of the *CHFR* gene was detected in 9 (45%) of the 20 GC samples. By contrast, no methylation was detected in the corresponding normal gastric mucosa from these same patients. The difference in GC tissue and normal gastric mucosa samples was significant ($P < 0.001$). A significant difference was observed in the tumor samples ($P = 0.014$), indicating that poorly differentiated GC is more frequently methylated than well-differentiated GC. However, aberrant methylation of the *CHFR* gene in human GC was not significantly correlated with other clinicopathological factors such as gender, age, tumor size, Borrman type, depth of tumor invasion, and status of lymph node metastasis.

Aberrant expression of CHFR mRNA in GC tissue samples

As shown in Table 2, *CHFR* mRNA expression was down-regulated in GC tissue samples (0.2186 ± 0.2113) compared with normal gastric mucosa (0.7020 ± 0.2163) and the difference was significant ($t = 7.148$, $P < 0.0001$).

Table 1 Clinicopathological features of CHFR promoter methylation in GC

Variable	*n*	Methylated	Unmethylated	Methylated rate (%)	*P* value
Total	20	9	11		
Age (yr)					
≤ 50	6	3	3	50.00	1.000
> 50	14	6	8	42.86	
Gender					
Female	12	5	7	41.67	1.000
Male	8	4	4	50.00	
Gastric cancer					
Tumor size (cm)					
< 5.0	9	5	4	55.56	0.653
≥ 5.0	11	4	7	36.36	
Borrman type					
Ⅰ + Ⅱ	10	4	6	40.00	1.000
Ⅲ + Ⅳ	10	5	5	50.00	
Differentiation degree					
Well	6	0	6	0.00	0.014
Poorly	14	9	5	64.29	
Invasive depth					
Within Muscle layer	5	2	3	40.00	1.000
Penetratingmuscle layer	15	7	8	46.67	
Lymph node metastasis					
Positive	12	6	6	50.00	0.670
Negative	8	3	5	37.50	

Table 2 Clinicopathological features of *CHFR* mRNA and protein expression in GC

Variable	*n*	Relative expression density of *CHFR* mRNA	*t*	*P*	Relative expression density of CHFR protein	*t*	*P*
Age (yr)			1.189	0.176		0.965	0.347
≤ 50	6	0.1400 ± 0.1572			0.3300 ± 0.3809		
> 50	14	0.2800 ± 0.2187			0.2064 ± 0.1989		
Gender			0.608	0.551		0.648	0.525
Female	12	0.1942 ± 0.2179			0.2125 ± 0.2618		
Male	8	0.2537 ± 0.2094			0.2913 ± 0.2734		
Gastric cancer							
Tumor size (cm)			0.872	0.395		1.346	0.195
< 5.0	9	0.1722 ± 0.1780			0.3289 ± 0.3360		
≥ 5.0	11	0.2555 ± 0.2364			0.1736 ± 0.1678		
Borrman type			0.797	0.436		0.208	0.838
Ⅰ + Ⅱ	10	0.2560 ± 0.2312			0.2310 ± 0.2772		
Ⅲ + Ⅳ	10	0.1800 ± 0.1934			0.2560 ± 0.2602		
Differentiation degree			3.276	0.004		5.162	0.001
Well	6	0.4106 ± 0.1574			0.5447 ± 0.2573		
poorly	14	0.1364 ± 1.1772			0.1143 ± 0.1224		
Invasive depth			0.296	0.907		1.243	0.230
Within muscle layer	5	0.2480 ± 0.1620			0.3678 ± 0.3346		
Penetrating muscle layer	15	0.2147 ± 0.2320			0.2020 ± 0.2320		
Lymph node metastasis			1.892	0.075		1.318	0.204
Positive	12	0.1500 ± 0.1839			0.1817 ± 0.2353		
Negative	8	0.3200 ± 0.2190			0.3363 ± 0.2879		

Among them, *CHFR* mRNA expression in 14 poorly differentiated GC tissue samples (0.1364 ± 1.772) was significantly lower than that (0.4106 ± 0.1574) in 6 well-differentiated GC samples (t = 3.276, P = 0.004). The representative RT-PCR results for the *CHFR* mRNA expression in GC samples are shown in Figure 2.

CHFR protein expression levels in GC tissue samples

Western blotting analysis showed that the down-regulation and loss rate of the CHFR gene-coded protein was 70.00% (14/20) in GC tissue samples. The difference in relative optical density value between GC tissue and normal gastric mucosa samples was significant (0.2435 ± 0.2620 *vs* 0.5955 ± 0.2196, t = 4.605, P < 0.0001). The level of CHFR protein expression in poorly differentiated GC tissue samples was significantly lower than that in well-differentiated GC tissue samples (t = 5.162, P = 0.001). The CHFR protein expression level was correlated with the other clinicopathological features of GC tissue samples and paired normal gastric mucosa samples (Table 2). The representative Western blotting results for the CHFR protein expression in GC samples

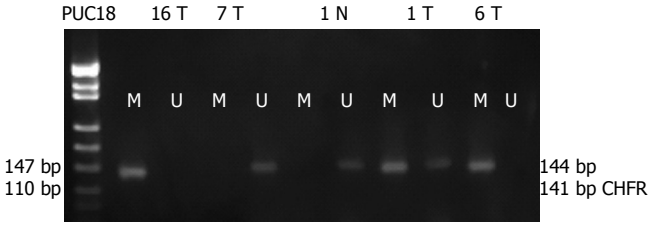

Figure 1 Representative results of MSPCR in human GC tissue samples. Lanes U and M: Products derived from unmethylated and methylated alleles, respectively. Methylation of the *CHFR* gene was detected in 16 and 6 poorly-differentiated adenocarcinoma tissue samples and 1 mucinous adenocarcinoma tissue sample, while unmethylation of the *CHFR* gene was detected in 7 well-differentiated adenocarcinoma tissue samples. PUC18: Marker; N: Normal gastric mucosa corresponding to tumors; T: Gastric cancer.

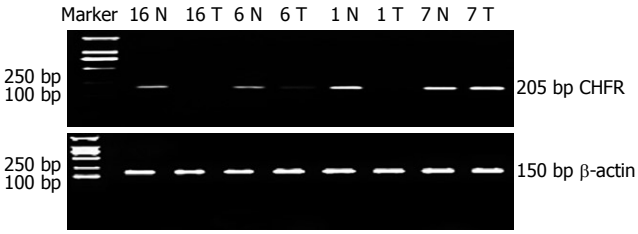

Figure 2 Representative results of RT-PCR in human GC tissue samples. β-actin was used as an internal control. *CHFR* mRNA expression level in 16 and 6 poorly differentiated adenocarcinoma tissue samples and 1 mucinous adenocarcinoma tissue sample was significantly lower than that in paired normal gastric mucosa samples from the same patients, while no difference was found in 7 well-differentiated adenocarcinoma tissue samples. Marker, D2000: Marker; N: Normal gastric mucosa corresponding to tumors; T: Gastric cancer.

are shown in Figure 3.

In addition, the CHFR protein expression in 69 GC tissue samples was analyzed by immunohistochemical staining of paraffin-embedded sections. Negative staining was observed in 55.07% of GC tissue samples (38/69). Positive staining was observed in 36.73% of poorly differentiated GC tissue samples (18/49), which was significantly lower than 65.00% (13/20) of well-differentiated GC tissue samples (χ^2 = 4.586, P = 0.032). However, the CHFR protein expression in human GC tissue samples was not correlated to the other clinicopathological factors such as gender, age, tumor size, Borrman type, depth of tumor invasion and status of lymph node metastasis. The example of immunohistochemical staining is shown in Figure 4.

Correlation of aberrant CHFR methylation with mRNA and protein expression level

The level of *CHFR* mRNA and protein expression in 9 GC tissue samples with CHFR methylation was down-regulated or lost. The level of mRNA and protein expression was down-regulated only in 5 of the 11 GC tissue samples with an unmethylated *CHFR* gene. The *CHFR* mRNA and protein expression was inversely correlated with promoter methylation (r = 0.592, P = 0.006).

DISCUSSION

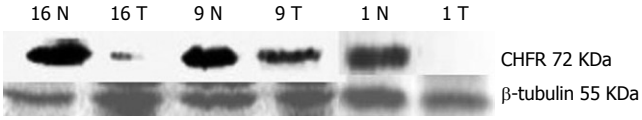

Figure 3 Representative results of Western blot in human GC tissue samples. β-tubulin was used as an internal control. CHFR protein expression level in GS tissue samples was significantly lower than that in paired normal gastric mucosa samples. Aberrant methylation of CHFR and down-regulation or loss of *CHFR* mRNA expression were detected in 16 poorly differentiated adenocarcinoma tissue samples and 1 mucinous adenocarcinoma tissue sample, while positive protein expression of CHFR was detected in 9 moderately-differentiated adenocarcinoma tissue samples without CHFR methylation. N: Normal gastric mucosa corresponding to tumors; T: Gastric cancer.

It is well known that both carcinogenesis and tumor progression evolve from genetic and epigenetic alterations of several genes[15]. Epigenetic alteration refers to the heritable phenotypic alteration in the absence of DNA sequence changes, and DNA methylation is one of the extensively studied epigenetic alterations[16]. In human beings and other mammals, CpG island methylation is an important physiological mechanism. The inactivated X-chromosome in female silenced alleles of imprinted genes or inserted viral genes and repeat elements are inactivated through promoter methylation[17]. Aberrant CpG methylation is common in cancer development and may play an important role in the carcinogenic process[18-25]. Methylation changes occurring in cancer include global hypomethylation in genomic DNA and gene-specific promoter hypermethylation. Whereas global hypomethylation increases mutation rates and chromosomal instability, promoter hypermethylation usually results in transcriptional gene inactivation. Thus, promoter hypermethylation, by silencing anti-cell-proliferation genes, anti-apoptosis genes, anti-angiogenesis genes, DNA repair genes, and anti-metastasis genes, plays an important role in carcinogenesis[26,27]. Recent evidence indicates that epigenetic changes might "addict" cancer cells to altered signal-transduction pathways during the early stages of tumor development. Dependence on these pathways for cell proliferation or survival allows them to acquire genetic mutations in the same pathways, providing the cells with selective advantages that promote tumor progression[28]. Processes that regulate gene transcription are directly under the influence of genome organization. DNA methylation of CpGs constitutes an epigenetic mark generally correlated with transcriptionally silent condensed chromatin. Replication of methylation patterns by DNA methyltransferases maintains genome stability through cell division. Periodic, strand-specific methylation and demethylation occur during transcriptional cycling of the *pS2/TFF1* gene promoter activated by estrogens. DNA methyltransferases exhibit dual actions during these cycles and are involved in CpG methylation and active demethylation of 5mCpGs through deamination. Inhibition of this process precludes demethylation of the *pS2* gene promoter and its subsequent transcriptional activation. Cyclical changes in the methylation status of

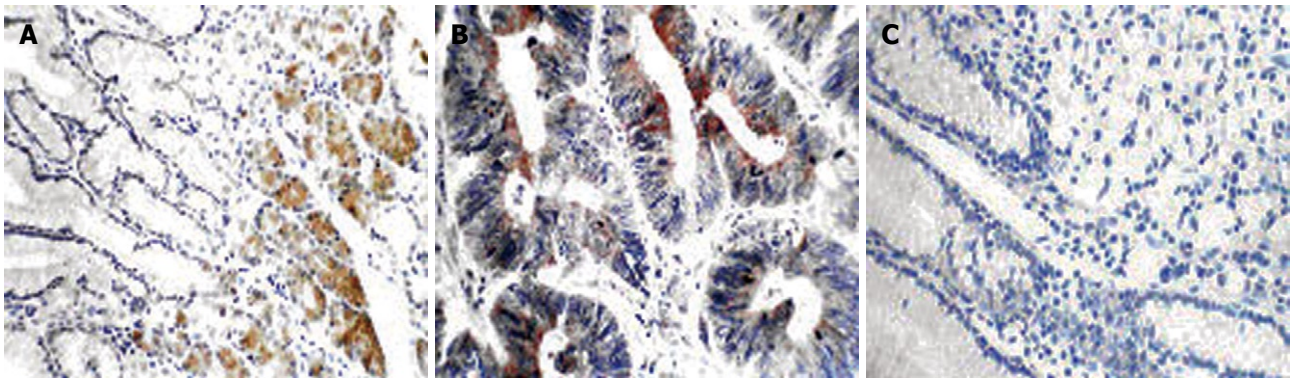

Figure 4 Immunohistochemical staining for CHFR protein expression in GC tissue samples and normal gastric mucosa samples. Positive expression of CHFR in normal gastric mucosa tissue samples (**A**), in well-differentiated adenocarcinoma tissue samples (**B**), and in signet-ring cell carcinoma tissue samples (**C**).

promoter CpGs may thus represent a critical event in transcriptional achievement[29].

However, aberrant methylation of CpGs is not a random event, but an event with gene-specific or tissue-specific differentiation. According to quantitative DNA methylation patterns at 4600 *Not* I sites and more than 150 differentially methylated regions in several C57BL/6J mouse tissue samples, comparative analysis between mice and human beings suggests that some, but not all, tissue-specific differentially methylated regions are conserved. A deeper understanding of cell-type-specific differences in DNA methylation might lead to a better illustration of the mechanisms behind tissue-specific differentiation in mammals[16].

As a tumor suppresser gene, aberrant methylation of CHFR promoter region associated with gene silencing has been reported in several primary tumors as followings[30-35].

The aberrant hypermethylation rate of CHFR was 12.3% (2/14) in cervical adenocarcinoma samples[30]. Thirty-six percent of patient samples showed a low or negative CHFR protein expression or staining. In addition, lack of CHFR detection was associated with increased tumor size and weakly correlated with estrogen receptor-negative tumors, suggesting that decreased CHFR expression results in the acquisition of many phenotypes associated with malignant progression, including accelerated growth rates, higher mitotic index, enhanced invasiveness, increased motility, greater aneuploidy, and amplified colony formation in soft agar, further supporting the role of *CHFR* as a tumor suppressor in breast cancer[31]. An aberrant methylation of the *CHFR* gene was detected in 25 out of 98 (26%) primary colorectal cancers and no methylation was detected in the corresponding normal tissue specimens[32]. In 46 patients with GC, 24 (52%) had aberrant CHFR methylation. By contrast, aberrant methylation was detected in only 2 samples (4%) of normal gastric mucosa and CHFR methylation status did not correlate with gender, sex, and clinicopathological features, such as tumor size, histological type, and stage. In cell lines, aberrant CHFR methylation correlated with the loss of mRNA expression, and treatment with the methyltransferase inhibitor 5-aza-dC induced re-expression of the gene, indicating that loss of CHFR expression due to aberrant methylation may be a cancer-specific event, which frequently occurs in primary GC[33]. CHFR staining was lost in 33% (57/174) of GC tissue samples, and there was a significant difference between staining in diffuse and intestinal histology. Loss of CHFR expression was found more commonly in the diffuse-type GC (P = 0.001), but no correlation was observed with age, location or tumor stage[34]. The aberrant methylation rate of CHFR was 41.1% (23/56) in GC samples. The mean age of patients with CHFR methylation was significantly higher than that of patients without CHFR methylation (P = 0.040). However, no significant correlation was observed with the other clinicopathologic factors[35].

In this study, the methylation rate of *CHFR* genes in GC tissue samples was significantly higher than that in paired normal gastric mucosa, suggesting that aberrant methylation of *CHFR* gene may be involved in carcinogenesis and development of GC. In addition, a significant difference was observed in GC (P = 0.014), indicating that poorly differentiated GC is more frequently methylated than well-differentiated GC and that aberrant methylation of the *CHFR* gene may participate in histological differentiation of GC and is associated with tumor malignant behavior. Its exact mechanism needs to be further studied. However, aberrant methylation of the *CHFR* gene in human GC was not significantly correlated with other clinicopathological factors such as gender, age, tumor size, Borrman type, depth of tumor invasion and status of lymph node metastasis. Moreover, the *CHFR* mRNA or protein expression level in 9 GC tissue samples with CHFR methylation was down-regulated or lost, while the level of the mRNA or protein expression was down-regulated only in 5 of 11 GC tissue samples with an unmethylated *CHFR* gene. These findings show that aberrant methylation of CHFR promoter in GC tissue samples is the main cause of down-regulation or loss of its mRNA or coded protein expression. On the other hand, CHFR staining was lost in 55.07% (38/69) of GC tissue samples, and there was a significant difference between staining in poorly differentiated and well-differentiated GC tissue samples. Because such a loss

was found more commonly in GC tissue samples, CHFR probably acts as a tumor suppressor in development of GC.

In conclusion, aberrant methylation of the *CHFR* gene is a frequent event in human GC and the principle mechanism underlying gene silencing, down-regulation or loss of CHFR. Since aberrant methylation of *CHFR* gene is closely correlated with tumor pathobiological behavior, the detection of the *CHFR* gene may be helpful in predicting the prognosis of GC and *CHFR* may become a novel target of gene therapy for GC in the future.

ACKNOWLEDGMENTS

The authors would like to thank Dr. Xi-Ming Yuan from Linköping University (Sweden) for his helpful suggestions and careful revision of the manuscript in English.

COMMENTS

Background

CHFR is a novel tumor suppressor gene and its encoding product is a ubiquitous ligase of Plk1. In cellular response to mitotic stress induced by microtubule inhibitors, CHFR activation delays chromosome condensation during prophase and increases the cells' ability to survive the stress. CHFR prevents errors in chromosome segregation that can lead to neoplasia. CHFR is ubiquitously expressed in normal human tissues while loss of CHFR expression due to aberrant methylation has been observed in human tumors, suggesting that it may be involved in carcinogenesis and development of gastric cancer. To date, few studies have addressed whether aberrant methylation of CHFR promoter is a common event in gastric cancer (GC).

Research frontiers

The pathogenesis of GC is poorly understood. DNA methylation is an epigenetic modification. This control mechanism has received increasing attention in carcinogenesis research. As a tumor suppresser gene, aberrant methylation of CHFR promoter associated with gene silencing has been reported in several primary tumors including lung, esophageal, colorectal and hepatocellular cancers. In this study, we found that aberrant methylation of CHFR promoter played an important role in gastric carcinogenesis.

Innovations and breakthroughs

Our study showed that aberrant methylation of CHFR promoter was a frequent event in Chinese GC tissue samples and the principle mechanism underlying gene silencing, down-regulation or loss of CHFR. Aberrant methylation of CHFR promoter was closely correlated with tumor pathobiological behavior. Results of the present study may further our understanding of the molecular mechanism of DNA methylation, which is an epigenetic modification.

Applications

The data obtained from this study demonstrate that aberrant methylation of *CHFR* gene is a frequent event in human GC and the principle mechanism underlying gene silencing, down-regulation or loss of CHFR, suggesting that CHFR probably acts as a tumor suppressor in development of GC. Moreover, aberrant methylation of the *CHFR* gene was found to be closely correlated with tumor malignant behavior, indicating that detection of the *CHFR* gene may be helpful in predicting the prognosis of GC and CHFR may become a novel target of gene therapy for GC in the future.

Peer review

In this study, the authors showed that methylation of CHFR promoter was significantly increased in GC tissue samples and was higher in poorly differentiated GC tissue samples than in well-differentiated GC tissue samples. Protein expression was found to be inversely correlated with promoter methylation. These findings suggest that aberrant mathyltion of the *CHFR* gene may be involved in the development of gastric carcinoma. This paper is original and informative.

REFERENCES

1 **Jemal A**, Siegel R, Ward E, Hao Y, Xu J, Murray T, Thun MJ. Cancer statistics, 2008. *CA Cancer J Clin* 2008; **58**: 71-96

2 **Auerkari EI**. Methylation of tumor suppressor genes p16(INK4a), p27(Kip1) and E-cadherin in carcinogenesis. *Oral Oncol* 2006; **42**: 5-13

3 **Turek-Plewa J**, Jagodzinski PP. The role of mammalian DNA methyltransferases in the regulation of gene expression. *Cell Mol Biol Lett* 2005; **10**: 631-647

4 **Chiang JW**, Karlan BY, Cass L, Baldwin RL. BRCA1 promoter methylation predicts adverse ovarian cancer prognosis. *Gynecol Oncol* 2006; **101**: 403-410

5 **Tamura G**. Alterations of tumor suppressor and tumor-related genes in the development and progression of gastric cancer. *World J Gastroenterol* 2006; **12**: 192-198

6 **Scolnick DM**, Halazonetis TD. Chfr defines a mitotic stress checkpoint that delays entry into metaphase. *Nature* 2000; **406**: 430-435

7 **Derks S**, Postma C, Carvalho B, van den Bosch SM, Moerkerk PT, Herman JG, Weijenberg MP, de Bruine AP, Meijer GA, van Engeland M. Integrated analysis of chromosomal, microsatellite and epigenetic instability in colorectal cancer identifies specific associations between promoter methylation of pivotal tumour suppressor and DNA repair genes and specific chromosomal alterations. *Carcinogenesis* 2008; **29**: 434-439

8 **Chen K**, Sawhney R, Khan M, Benninger MS, Hou Z, Sethi S, Stephen JK, Worsham MJ. Methylation of multiple genes as diagnostic and therapeutic markers in primary head and neck squamous cell carcinoma. *Arch Otolaryngol Head Neck Surg* 2007; **133**: 1131-1138

9 **Henken FE**, Wilting SM, Overmeer RM, van Rietschoten JG, Nygren AO, Errami A, Schouten JP, Meijer CJ, Snijders PJ, Steenbergen RD. Sequential gene promoter methylation during HPV-induced cervical carcinogenesis. *Br J Cancer* 2007; **97**: 1457-1464

10 **Kim BH**, Cho NY, Choi M, Lee S, Jang JJ, Kang GH. Methylation profiles of multiple CpG island loci in extrahepatic cholangiocarcinoma versus those of intrahepatic cholangiocarcinomas. *Arch Pathol Lab Med* 2007; **131**: 923-930

11 **Kang D**, Chen J, Wong J, Fang G. The checkpoint protein Chfr is a ligase that ubiquitinates Plk1 and inhibits Cdc2 at the G2 to M transition. *J Cell Biol* 2002; **156**: 249-259

12 **Fukuda T**, Kondo Y, Nakagama H. The anti-proliferative effects of the CHFR depend on the forkhead associated domain, but not E3 ligase activity mediated by ring finger domain. *PLoS ONE* 2008; **3**: e1776

13 **Leung WK**, Wu MS, Kakugawa Y, Kim JJ, Yeoh KG, Goh KL, Wu KC, Wu DC, Sollano J, Kachintorn U, Gotoda T, Lin JT, You WC, Ng EK, Sung JJ. Screening for gastric cancer in Asia: current evidence and practice. *Lancet Oncol* 2008; **9**: 279-287

14 **Morioka Y**, Hibi K, Sakai M, Koike M, Fujiwara M, Kodera Y, Ito K, Nakao A. Aberrant methylation of the CHFR gene in digestive tract cancer. *Anticancer Res* 2006; **26**: 1791-1795

15 **Yanagawa N**, Tamura G, Oizumi H, Kanauchi N, Endoh M, Sadahiro M, Motoyama T. Promoter hypermethylation of RASSF1A and RUNX3 genes as an independent prognostic prediction marker in surgically resected non-small cell lung cancers. *Lung Cancer* 2007; **58**: 131-138

16 **Nagase H**, Ghosh S. Epigenetics: differential DNA methylation in mammalian somatic tissues. *FEBS J* 2008; **275**: 1617-1623

17 **Tischoff I**, Tannapfe A. DNA methylation in hepatocellular carcinoma. *World J Gastroenterol* 2008; **14**: 1741-1748

18 **Izutsu N**, Maesawa C, Shibazaki M, Oikawa H, Shoji T, Sugiyama T, Masuda T. Epigenetic modification is involved in aberrant expression of class III beta-tubulin, TUBB3, in

ovarian cancer cells. *Int J Oncol* 2008; **32**: 1227-1235
19 **Shiah SG**, Chang LC, Tai KY, Lee GH, Wu CW, Shieh YS. The involvement of promoter methylation and DNA methyltransferase-1 in the regulation of EpCAM expression in oral squamous cell carcinoma. *Oral Oncol* 2009; **45**: e1-e8
20 **Abbaszadegan MR**, Moaven O, Sima HR, Ghafarzadegan K, A'rabi A, Forghani MN, Raziee HR, Mashhadinejad A, Jafarzadeh M, Esmaili-Shandiz E, Dadkhah E. p16 promoter hypermethylation: a useful serum marker for early detection of gastric cancer. *World J Gastroenterol* 2008; **14**: 2055-2060
21 **Harder J**, Opitz OG, Brabender J, Olschewski M, Blum HE, Nomoto S, Usadel H. Quantitative promoter methylation analysis of hepatocellular carcinoma, cirrhotic and normal liver. *Int J Cancer* 2008; **122**: 2800-2804
22 **Feng Q**, Hawes SE, Stern JE, Wiens L, Lu H, Dong ZM, Jordan CD, Kiviat NB, Vesselle H. DNA methylation in tumor and matched normal tissues from non-small cell lung cancer patients. *Cancer Epidemiol Biomarkers Prev* 2008; **17**: 645-654
23 **Shaw RJ**, Hall GL, Lowe D, Liloglou T, Field JK, Sloan P, Risk JM. The role of pyrosequencing in head and neck cancer epigenetics: correlation of quantitative methylation data with gene expression. *Arch Otolaryngol Head Neck Surg* 2008; **134**: 251-256
24 **Kim MS**, Lebron C, Nagpal JK, Chae YK, Chang X, Huang Y, Chuang T, Yamashita K, Trink B, Ratovitski EA, Califano JA, Sidransky D. Methylation of the DFNA5 increases risk of lymph node metastasis in human breast cancer. *Biochem Biophys Res Commun* 2008; **370**: 38-43
25 **Kawasaki T**, Ohnishi M, Nosho K, Suemoto Y, Kirkner GJ, Meyerhardt JA, Fuchs CS, Ogino S. CpG island methylator phenotype-low (CIMP-low) colorectal cancer shows not only few methylated CIMP-high-specific CpG islands, but also low-level methylation at individual loci. *Mod Pathol* 2008; **21**: 245-255
26 **Sato F**, Meltzer SJ. CpG island hypermethylation in progression of esophageal and gastric cancer. *Cancer* 2006; **106**: 483-493
27 **Esteller M**. Epigenetics in cancer. *N Engl J Med* 2008; **358**: 1148-1159
28 **Baylin SB**, Ohm JE. Epigenetic gene silencing in cancer - a mechanism for early oncogenic pathway addiction? *Nat Rev Cancer* 2006; **6**: 107-116
29 **Metivier R**, Gallais R, Tiffoche C, Le Peron C, Jurkowska RZ, Carmouche RP, Ibberson D, Barath P, Demay F, Reid G, Benes V, Jeltsch A, Gannon F, Salbert G. Cyclical DNA methylation of a transcriptionally active promoter. *Nature* 2008; **452**: 45-50
30 **Banno K**, Yanokura M, Kawaguchi M, Kuwabara Y, Akiyoshi J, Kobayashi Y, Iwata T, Hirasawa A, Fujii T, Susumu N, Tsukazaki K, Aoki D. Epigenetic inactivation of the CHFR gene in cervical cancer contributes to sensitivity to taxanes. *Int J Oncol* 2007; **31**: 713-720
31 **Privette LM**, Gonzalez ME, Ding L, Kleer CG, Petty EM. Altered expression of the early mitotic checkpoint protein, CHFR, in breast cancers: implications for tumor suppression. *Cancer Res* 2007; **67**: 6064-6074
32 **Morioka Y**, Hibi K, Sakai M, Koike M, Fujiwara M, Kodera Y, Ito K, Nakao A. Aberrant methylation of the CHFR gene is frequently detected in non-invasive colorectal cancer. *Anticancer Res* 2006; **26**: 4267-4270
33 **Koga Y**, Kitajima Y, Miyoshi A, Sato K, Sato S, Miyazaki K. The significance of aberrant CHFR methylation for clinical response to microtubule inhibitors in gastric cancer. *J Gastroenterol* 2006; **41**: 133-139
34 **Milne AN**, Sitarz R, Carvalho R, Polak MM, Ligtenberg M, Pauwels P, Offerhaus GJ, Weterman MA. Molecular analysis of primary gastric cancer, corresponding xenografts, and 2 novel gastric carcinoma cell lines reveals novel alterations in gastric carcinogenesis. *Hum Pathol* 2007; **38**: 903-913
35 **Mitsuno M**, Kitajima Y, Ide T, Ohtaka K, Tanaka M, Satoh S, Miyazaki K. Aberrant methylation of p16 predicts candidates for 5-fluorouracil-based adjuvant therapy in gastric cancer patients. *J Gastroenterol* 2007; **42**: 866-873

S- Editor Zhong XY **L- Editor** Wang XL **E- Editor** Lin YP

Online Submissions: wjg.wjgnet.com
wjg@wjgnet.com
doi:10.3748/wjg.14.5008

World J Gastroenterol 2008 August 28; 14(32): 5008-5014
World Journal of Gastroenterology ISSN 1007-9327
© 2008 The WJG Press. All rights reserved.

LIVER CANCER

Positional and expressive alteration of prohibitin during the induced differentiation of human hepatocarcinoma SMMC-7721 cells

Dong-Hui Xu, Jian Tang, Qi-Fu Li, Song-Lin Shi, Xiang-Feng Chen, Ying Liang

Dong-Hui Xu, Department of Hepatic Biliary Pancreatic Vascular Surgery, 1st Hospital of Xiamen, Fujian Medical University, Xiamen 361003, Fujian Province, China
Jian Tang, Qi-Fu Li, Song-Lin Shi, Xiang-Feng Chen, Ying Liang, The Key Laboratory of Chinese Ministry of Education for Cell Biology and Tumor Cell Engineering, School of Life Sciences, Xiamen University, Xiamen 361005, Fujian Province, China
Author contributions: Li QF designed research; Xu DH, Tang J, Shi SL, Chen XF and Liang Y performed research; Xu DH, Tang J and Li QF analyzed data; Tang J, Shi SL and Li QF wrote and revised the paper.
Supported by The National Natural Science Foundation of China, No. 30470877; Chinese Postdoctoral Science Foundation, No. 20070420754; and the Natural Science Foundation of Fujian Province of China, No. 2008J0302
Correspondence to: Dr. Qi-Fu Li, Laboratory of Cell Biology, School of Life Sciences, Xiamen University, Xiamen 361005, Fujian Province, China. chifulee@xmu.edu.cn
Telephone: +86-592-2185363 Fax: +86-592-2181015
Received: May 8, 2008 Revised: July 26, 2008
Accepted: August 2, 2008
Published online: August 28, 2008

Abstract

AIM: To explore the existence and distribution of prohibitin (PHB) in nuclear matrix and its co-localization with products of some related genes during the differentiation of human hepatocarcinoma SMMC-7721 cells.

METHODS: The nuclear matrix of the SMMC-7721 cells cultured with or without 5×10^{-3} mmol/L hexamethylene bisacetamide (HMBA) was selectively extracted. Western blot was used to analyze the expression of PHB in nuclear matrix; immunofluorescence microscope observation was used to analyze the distribution of PHB in cell. LCSM was used to observe the co-localization of PHB with products of oncogenes and tumor suppressor genes.

RESULTS: Western blot analysis showed that PHB existed in the composition of nuclear matrix proteins and was down-regulated by HMBA treatment. Immunofluorescence observation revealed that PHB existed in the nuclear matrix, and its distribution regions and expression levels were altered after HMBA treatment. Laser scanning confocal microscopy revealed the co-localization between PHB and the products of oncogenes or tumor repression genes including *c-fos*, *c-myc*, *p53* and *Rb* and its alteration of distributive area in the cells treated by HMBA.

CONCLUSION: These data confirm that PHB is a nuclear matrix protein, which is located in the nuclear matrix, and the distribution and expression of PHB and its relation with associated genes may play significant roles during the differentiation of SMMC-7721 cells.

© 2008 The WJG Press. All rights reserved.

Key words: Prohibitin; Nuclear matrix; SMMC-7721 cells; Hexamethylamine; Bisacetamide; Cell differentiation

Peer reviewer: Devanshi Seth, PhD, Drug Health Services & Centenary Institute, Royal Prince Alfred Hospital, Missenden Road, Camperdown NSW 2050, Australia

Xu DH, Tang J, Li QF, Shi SL, Chen XF, Liang Y. Positional and expressive alteration of prohibitin during the induced differentiation of human hepatocarcinoma SMMC-7721 cells. *World J Gastroenterol* 2008; 14(32): 5008-5014 Available from: URL: http://www.wjgnet.com/1007-9327/14/5008.asp DOI: http://dx.doi.org/10.3748/wjg.14.5008

INTRODUCTION

Prohibitin (PHB) is a tumor suppressor protein that is expressed in a variety of cell lines. It is not only localized to the inner membrane of mitochondria, where it acts as a chaperone protein, but is also present in the nucleus where it negatively regulates transcription. PHB plays important roles in the regulation of cell growth, proliferation, differentiation, aging and apoptosis. It is also involved in the genesis of tumor and some degenerative diseases[1-3]. In cell differentiation, some studies have found that the expression level of PHB was very low in rapidly proliferating cells, whereas it was much higher in cells undergoing differentiation. This indicates that PHB may promote cell differentiation and suppress cell proliferation[4]. Heretofore, over-expression of PHB has been found in various tumor cells. This seems to be conflictive with its tumor suppressive function. So far, the mechanism of its subcellular localization, nuclear transportation and regulation of cell proliferation and differentiation are

not well understood. Our previous studies revealed that PHB existed in nuclear matrix extractions of human adenocarcinoma MGc80-3 cells, and its expression level was altered during the differentiation induced by hexamethylene bisacetamide (HMBA)[5]. Furthermore, in the differentiation of human osteosarcoma MG-63 cells, we observed similar results[6]. This implies that PHB might be a common differentially expressed nuclear matrix protein in some tumor cells. In this study, we further studied the existence, localization, expression alteration of PHB in the nuclear matrix and the relationship between PHB and related products of oncogenes during the differentiation of human hepatocarcinoma SMMC-7721 cells induced by HMBA. This study provides scientific evidence for the function of PHB during cell differentiation and understanding of the mechanism of development of cancer and its reversion.

MATERIALS AND METHODS

Materials

Human hepatocarcinoma SMMC-7721 cells were obtained from China Center for Type Culture Collection (Wuhan University). RPMI-1640 was from Gibco Co., newborn calf serum was from Hangzhou Sijiqing Biological Engineering Materials Co., Ltd. HMBA was from Sigma Co. The antibodies used are listed in Table 1.

Table 1 Antibodies used in the study

Antibodies	Source	Antibodies	Source
Mouse anti-human PHB	NeoMarkers Co.	Goat anti-mouse IgG/HRP	Boster Co.
Goat anti-rabbit IgG-FITC	KPL Co.	Goat anti-rabbit IgG/HRP	Boster Co.
Goat anti-mouse IgG-TRITC	KPL Co.	Rabbit anti-p53	Boster Co.
Rabbit anti-human β-actin	Boster Co.	Rabbit anti-pRb	Boster Co.
Rabbit anti-c-Fos	Boster Co.	Rabbit anti-c-Myc	Boster Co.

Cell culture and inducement

Human hepatocarcinoma SMMC-7721 cells were cultured at 37℃ in RPMI-1640 medium (pH 7.2) supplemented with 15% newborn calf serum, 100 U/mL penicillin, 100 U/mL streptomycin and 50 μg/mL kanamycin. Cells were passaged in log phase. Twenty-four hours after passaging the cells the experimental group was treated with culture media containing 5 mmol/L HMBA. Fresh culture media was added to the cells every 48-72 h. Cells were harvested at subconfluency.

Cell selective extraction and sample preparation for light microscope

The cells were selectively extracted as described in our previous article[7]. The nuclear matrix-intermediate filament (NM-IF) samples on the cover slip strips after the selective extraction were prefixed in 2% glutaraldehyde at 4℃ for 30 min, and rinsed in phosphate-buffered saline (PBS), pH 7.4. The samples were then stained with 0.2% Coomassie brilliant blue for 20 min, washed in distilled water, air dried, clarified by xylene, enveloped in the resin, and observed using an Olympus BH-2 microscope.

Purification of nuclear matrix proteins

Nuclear matrix proteins of SMMC-7721 cells were purified by using a routine method with a few improvements[8]. The SMMC-7721 cells were washed with PBS and extracted with cytoskeleton buffer (CSK100) (10 mmol/L PIPES pH 6.8, 300 mmol/L sucrose, 100 mmol/L NaCl, 4 mmol/L $CaCl_2$, 1.0 mmol/L PMSF, 0.5% Triton X-100) at 0℃ for 10 min, and subjected to centrifugation for 5 min at 400 *g*. The pellet was washed twice with CSK50 (10 mmol/L PIPES pH 6.8, 300 mmol/L sucrose, 50 mmol/L NaCl, 4 mmol/L $CaCl_2$, 1.0 mmol/L PMSF, 0.5% Triton X-100) and digested for 30 min at 25℃ in the same buffer containing 300 U/mL DNase I. One mole per liter ammonium sulfate was added dropwise to a final concentration of 0.25 mmol/L. After incubation for 15 min, the nuclear matrix proteins were pelleted by centrifugation at 1000 r/min for 5 min, and washed once with the CSK50 buffer, then stored at -80℃.

Western blot of PHB

The nuclear matrix proteins were separated by SDS-PAGE and then transferred onto PVDF membranes. Nonspecific reactivity was blocked by incubation at room temperature for 1.5 h in 5% BSA buffer. The membrane was then incubated with PHB (1:2000) primary antibody at room temperature for 2 h. After washing, a horseradish peroxidase tagged secondary antibody was used to detect the primary antibody. Reactive protein was detected by the enhanced chemiluminescence (ECL) detection system (Pierce). As a negative control, the primary antibody was replaced by 5% BSA buffer. β-actin was also detected as an internal control.

Sample preparation for fluorescence microscopy

The NM-IF samples on the cover slip were prefixed in 4% paraformaldehyde at 4℃ for 10 min, rinsed in the TPBS (contain 0.5% Triton X-100) twice, 5 min each, blocked by 5% BSA at room temperature for 1 h, incubated with mouse anti-PHB monoclonal antibody (1:300) at room temperature for 30 min, and 4℃ overnight, then washed 3 times with TPBS. Then, the cells were incubated with goat anti-mouse secondary antibody labeled with fluorescence dye TRITC, washed with water and dried by airing. Afterwards, 90% glycerol/PBS was applied and the cells observed using fluorescence microscopy. The entire process after incubation with secondary antibody was performed in the dark. The primary antibody was replaced by 5% BSA buffer as a negative control.

Sample preparation for LSCM

Cells on the cover slips were rinsed in PBS, submerged in TBS (including 0.5% Triton X-100) for 30 min. After being washed with PBS, the cells were fixed in 4% paraformaldehyde for 10 min, blocked with 5%

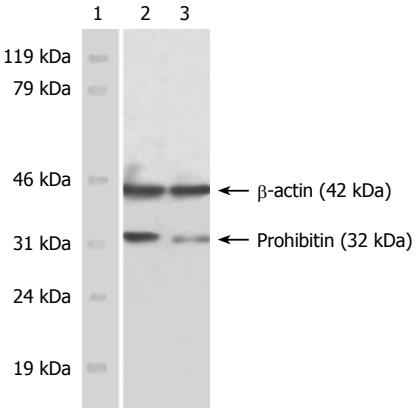

Figure 1 Western blot of PHB in nuclear matrix of SMMC-7721 cell. Lane 1: Marker; Lane 2: SMMC-7721 cells; Lane 3: HMBA-treated cells.

BSA at room temperature for 1 h, and then incubated with dual primary antibodies at room temperature for 30 min and then 4℃ overnight. The dual primary antibody sets comprised of PHB (1:1000)/c-Fos (1:200), PHB (1:1000)/c-Myc (1:200), PHB (1:1000)/p53 (1:200), PHB (1:1000)/pRb (1:200). After being washed with TTBS, the cells were incubated with different secondary antibody sets (goat anti rabbit or goat anti mouse) which were labeled with FITC and TRITC, respectively, at room temperature for 30 min and then 4℃ overnight, washed with TPBS, enveloped with 90% glycerol/PBS after drying and then observed under LSCM (TCS- SP2 MP).

RESULTS

Detection of PHB in nuclear matrix by Western blot

Western blot results showed the dominant PHB band located at 32 kDa (PHB) and β-actin positioned at 42 kDa. The immunobead of PHB in the nuclear matrix of SMMC-7721 cells was obviously fuscous, while it was light and thin in HMBA-treated cells. The expression level of hnRNP A2/B1 was significantly decreased. The expression level of β-actin, which was referred to as endogenous control, had no obvious changes (Figure 1).

Localization and expression of PHB in the NM-IF system of SMMC-7721 cells

Light microscopy observation revealed that the intermediate filaments in SMMC-7721 cells were sparse and arranged irregularly. In HMBA-treated MG-63 cells, the whole framework became more outspread, and the NM-IF system showed characteristics of uniform distribution. The intermediate filaments, which were uniformly stained, spread from the region around the nucleus to the cellular edge and formed a well-distributed and regular network throughout the cytoplasmic region. The nuclear matrix filaments were abundant and evenly distributed (Figure 2A and B).

The observation of immunofluorescence revealed the localization and expression of PHB. PHB was labeled with TRITC (red). The results showed PHB existed in the whole cell, but was weak in nuclei where it was scattered as little particles. It was relatively strong in regions near the nuclear membrane. The distribution of PHB was uniform in the cytoplasmic region (Figure 2C). After treatment with HMBA, the distribution and expression of PHB in the NM-IF system was significantly altered. The holistic intensity of the fluorescence in nuclear matrix and nuclear lamina region dropped dramatically, while the fluorescence in the cytoplasmic region of HMBA-treated cells strengthened. It displayed a tendency of transferring from NM to lamina and cytoplasm of PHB (Figure 2D).

Co-localization study of PHB with products of several predominant oncogenes and tumor suppressor genes

The localization of PHB and the opposite proteins including c-Fos, c-Myc, p53 and pRb were observed by LSCM. PHB was labeled with TRITC (red), other proteins were labeled with FITC (green). The co-localization fluorescence was yellow or orange when two different colors of fluorescence overlapped (Figure 3).

In SMMC-7721 cells, PHB mainly distributed in the nucleus, nuclear membrane, cytoplasm and the edge region of cells. In karyoplasm, the fluorescence was relatively weak and scattered unevenly. In SMMC-7721 cells treated with HMBA, PHB expression became decreased or even disappeared in the nuclear regions and was enhanced and scattered broadly in the cytoplasm.

Co-localization of PHB with c-Fos in SMMC-7721 cells

In SMMC-7721 cells, c-Fos was distributed mainly in the nucleolus region. The yellow overlapped fluorescence indicated co-localization between PHB and c-Fos existed mainly in the nucleolus region. In SMMC-7721 cells treated with HMBA, the holistic intensity of PHB and c-Fos fluorescence all weakened. The overlapped fluorescence indicated that the co-localization between PHB and c-Fos in the nucleolus weakened, but the co-localized fluorescence in karyotheca and cytoplasm was enhanced. It seemed that the co-localized region of both proteins transferred from the nucleolus region to karyotheca and cytoplasm (Figure 3A-F).

Co-localization of PHB with c-Myc in SMMC-7721 cells

In SMMC-7721 cells, the highly-expressed c-Myc distributed mainly in the nucleolus and its peripheral regions. The overlapped fluorescence indicated they were co-localized in karyoplasms and karyotheca. In SMMC-7721 cells induced by HMBA, c-Myc dispersed in the whole cell, and its expression decreased. The overlapped fluorescence of PHB and c-Myc showed that the co-localization of two proteins strengthened in the karyotheca region, and clustered co-localization fluorescence could be seen in some special places. It indicated the tendency of transportation from karyoplasm to the nearby nuclear membrane (Figure 3G-L).

Co-localization of PHB with p53 in SMMC-7721 cells

Due to the short half-life of wild-p53 in tumor cells (6 min), the p53 detected in this article was mostly its mutant counterpart namely mtp53. In SMMC-7721 cells, the highly-expressed mtp53 concentrated mainly

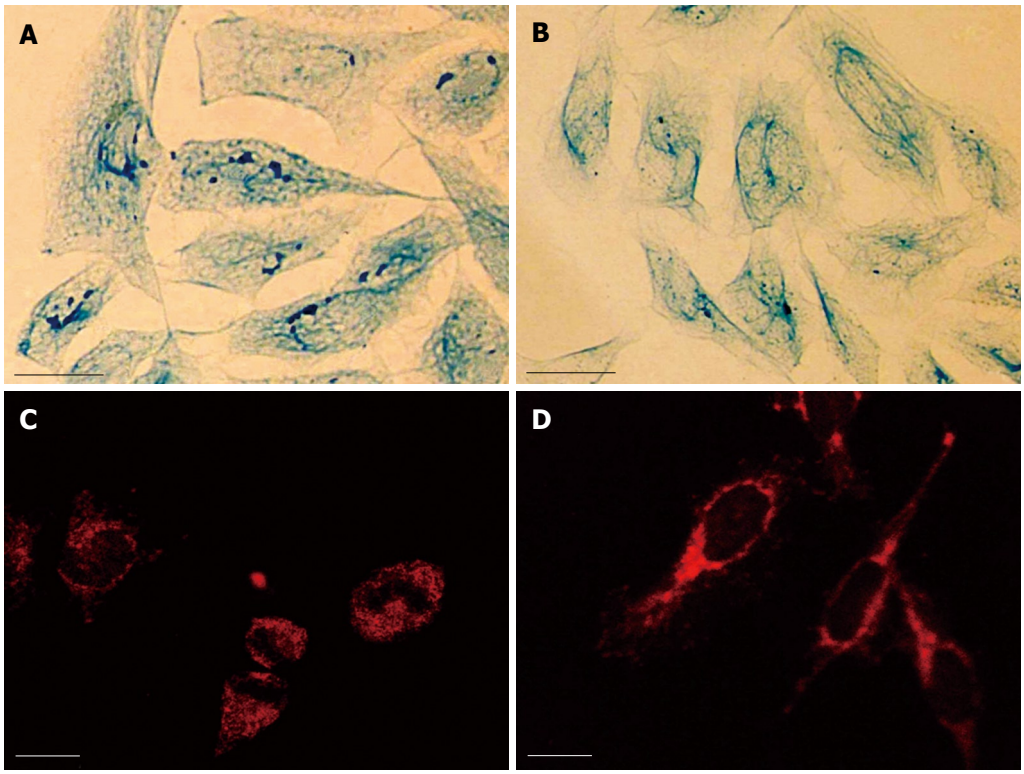

Figure 2 **A**: LM observation of NM-IF system in SMMC-7721 cells, coomassie brilliant blue staining, bar = 10 μm; **B**: LM observation of NM-IF system in SMMC-7721 cells after HMBA treatment, Coomassie brilliant blue staining, bar = 10 μm; **C**: Immunofluorescence staining of PHB in the NMIF system of SMMC-7721 cells, bar = 10 μm; **D**: Immunofluorescence staining of PHB in the nuclear matrix-intermediate filament system of SMMC-7721 cells after HMBA treatment, bar = 10 μm.

in the nucleolus and evenly distributed in other regions of the nucleus. The overlapped fluorescence indicated the co-localization distributed mainly in the region of karyoplasm and cytoplasm. In SMMC-7721 cells induced by HMBA, mtP53 decreased and its distribution was much more dispersive than that of untreated cells. The overlapped fluorescence showed the co-localization region of two proteins existed in the cytoplasm and lamina regions, and the co-localization fluorescence weakened remarkably after treatment (Figure 3M-R).

Co-localization of PHB with pRb in SMMC-7721 cells

In SMMC-7721 cells, Rb expression in the nucleolus was stronger than in other regions where it was relatively weak and distributed evenly. The overlapped fluorescence indicated they were co-localized in most regions of the nuclear membrane and cytoplasm. After treatment with HMBA, Rb increased remarkably and localized mainly at the nuclear membrane and nucleus regions after HMBA treatment. The overlapped fluorescence indicated the co-localization region of two proteins existed mainly in the nuclear membrane. It also showed their co-localization had a tendency of transferring from the cytoplasm to the nuclear membrane during the differentiation of SMMC-7721 cells (Figure 3S-X).

DISCUSSION

Changes of the expression and localization of PHB in the nuclear matrix

PHB is an important tumor suppressor protein. It not only mediates signaling of cell proliferation by acting as a membrane receptor, but is also involved in the maintenance of stability and function of mitochondria. Previous studies have shown that PHB was mainly present in the mitochondria, and could be found in other subcellular organelles rarely[9,10]. So far, the localization of PHB in the nuclear matrix has not been reported. In this study, Western blot analysis confirmed that PHB was one of the components of the nuclear matrix and its expression in the nuclear matrix was down-regulated remarkably after treatment with HMBA. Immunofluorescence microscopy revealed that PHB was distributed mainly in the regions of the nuclear membrane and cytoplasm of SMMC-7721 cells. These results indicate that PHB exists not only in the cytoplasm, but also in the nuclear matrix of SMMC-7721 cells. Therefore, our laboratory, for the first time, has discovered the subcellular location of PHB in the nuclear matrix and showed it was a nuclear matrix protein.

PHB has great relevance to the development of cancer. Recent studies have shown that expression of PHB was abnormal in a variety of tumor cell lines[11-14]. In this study, using Western blot analysis, we found PHB is expressed highly in the nuclear matrix of SMMC-7721 cells, but in cells treated with HMBA, its expression was down-regulated. Immunofluorescent microscopy showed that the distribution of PHB in the nuclear matrix of SMMC-7721 cells was altered after HMBA treatment. PHB was mainly distributed in the karyoplasms and cytoplasm region, while in the HMBA-treated cells, PHB localized to the nuclear membrane and cytoplasm. PHB might have undergone translocation from nucleus to cytoplasm. Over expression of PHB has been reported in many kinds of tumor cells[15,16]. Our previous studies on the nuclear matrix proteins

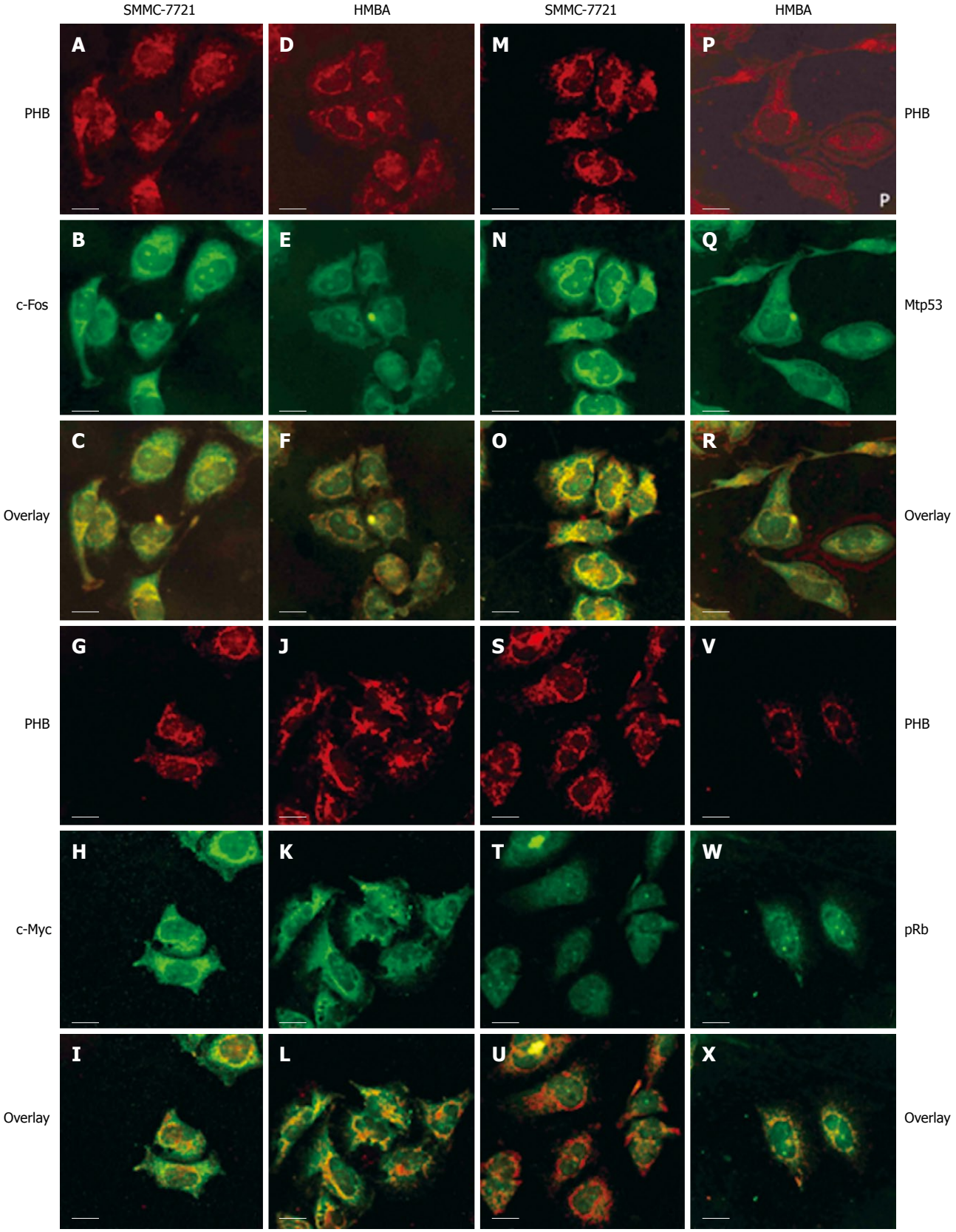

Figure 3 LSCM observation of the co-localization of PHB, bar = 10 μm. **A-F**: With c-Fos in SMMC-7721 cells; **G-L**: With c-Myc in SMMC-7721 cells; **M-R**: With mtp53 in SMMC-7721 cells; **S-X**: With pRb in SMMC-7721 cells.

of human adenocarcinoma MGc80-3 and human osteosarcoma MG-63 cells showed that PHB existed as a component of the nuclear matrix, and expression of PHB was down-regulated during differentiation. Therefore, our results further affirmed the alterations of PHB expression, and confirmed the involvement of

PHB in the regulation of tumor cell proliferation and differentiation.

Co-localization of PHB with products of related genes and its alteration during differentiation of SMMC-7721 cells

The regulation of PHB in cell proliferation, senescence, apoptosis and differentiation involves complicated molecular mechanisms, including interaction between PHB and associated regulators in signaling and cell cycle, the subcellular localization of PHB in the cell, the phosphorylation level of PHB, and the connection between PHB and related oncogenes[17-19]. In this study, the results of laser scanning confocal microscopy revealed that there was a co-localizational relationship between PHB and the products of *c-fos*, *c-myc*, *p53* and *Rb* genes in SMMC-7721 cells, and the co-localization areas changed after HMBA treatment.

c-fos and *c-myc* are oncogenes whose expressions are up-regulated frequently in hepatocellular carcinomas (HCC). Our research indicated PHB colocalized with c-Fos, c-Myc in the nuclear region of SMMC-7721 cells. When SMMC-7721 cells were induced into differentiation, the co-localization relationship of PHB with c-Fos and c-Myc strengthened in the regions of lamina and karyotheca, but weakened in the karyoplasms. Other studies showed that PHB was a downstream target gene of *c-myc* and *c-myc* could bind to the promoter region of the *PHB* gene[20]. This indicated the close relation between PHB and c-Myc. The direct interaction of PHB and c-Fos has not yet been reported. Our research showed the co-localization between PHB and c-Myc, c-Fos in the region of the nucleus, and its alteration in SMMC-7721 cells after treatment with HMBA. It suggested that PHB might interact directly with the products of *c-myc* and *c-fos* genes. Our study discovered that PHB and p53 were co-localized at the nuclear membrane and karyoplasms region. The co-localization fluorescence transferred from nucleus to cytoplasm after HMBA treatment. This suggested that PHB might have direct connection with p53. Recently, some studies showed that PHB and p53 could cooperate with each other and participated in regulating downstream gene expression. Some studies found co-localization between PHB, p53 and E2F1 in the nucleus of breast cancer cells, and demonstrated PHB could activate transcription mediated by p53 and enhance binding of p53 with the promoter. It is also reported that p53-PHB complex translocated from nucleus to cytoplasm after stimulation by the signal of apoptosis[21-23]. Our results were consistent with former studies. It implies that PHB can directly interact with p53 and participate in the regulation of transcription mediated by p53. The co-transferring of p53 and PHB may be one of the mechanisms that mediate regulation of cell proliferation and differentiation. The studies about Rb and PHB showed that PHB could cooperate with products of Rb, a dominant tumor suppressor gene which regulates transcriptional activity of E2F. PHB could also form a triad with Rb and E2F in the nucleus, suppress activity of E2F, and thereby inhibit cell proliferation[24,25]. The results of this study revealed that the co-localizational fluorescence in the region of the nuclear lamina was enhanced after HMBA treatment. It is obvious that the alteration is correlative with the state of proliferation and differentiation of SMMC-7721 cells. Nuclear lamina is the active site of DNA replication and transcription. Because of these, the alteration of PHB transferring and its enhanced combination with Rb in the lamina might repress the activity of E2F which promotes transcription of its downstream genes.

Taken together, these findings suggest that the subcellular localization and altered expression of PHB may have a potential role in the differentiation and phenotype reversion of SMMC-7721 cells by cooperating with products of oncogenes or tumor suppressor genes. Further investigation of the function of PHB in the nuclear matrix will help to clarify the mechanism of cell differentiation, cell cancer development and its reversion.

COMMENTS

Background

Previous studies showed that prohibitin (PHB) played important roles in the regulation of cell growth, proliferation, differentiation and tumorigenesis. However, the existence and expression of PHB in the nuclear matrix of tumor cells have not been well illustrated, and the functions of PHB in the induced differentiation of human hepatocarcinoma SMMC-7721 cells have also not been investigated in detail.

Research frontiers

To identify differentially expressed nuclear matrix proteins and analyze their function in cancer cell differentiation is one of the most interesting hotspots in current studies of nuclear matrix.

Innovations and breakthroughs

The authors revealed for the first time that PHB was a nuclear matrix protein in SMMC-7721 cells, and the distribution/expression of PHB and its relation with associated genes played a significant roles during the differentiation of SMMC-7721 cells.

Applications

PHB can be used as a potential target in both diagnosis and treatment of tumors.

Terminology

Nuclear matrix is the residual protein structure that remains after the nuclei are depleted of the nuclear membranes, histones, soluble nuclear proteins and nucleic acids. The structures that remain in matrix preparations are the nuclear lamina, the residual nucleolus and the fibrillogranular network.

Peer review

The study is about the expression and distribution of proteins. Scientific content is interesting as several protein complexes are involved in cellular processes and identification of a role for PHB in carcinogenesis by association with other oncogenes is intriguing.

REFERENCES

1 **Mishra S**, Murphy LC, Nyomba BL, Murphy LJ. Prohibitin: a potential target for new therapeutics. *Trends Mol Med* 2005; **11**: 192-197

2 **Dell'Orco RT**, McClung JK, Jupe ER, Liu XT. Prohibitin and the senescent phenotype. *Exp Gerontol* 1996; **31**: 245-252

3 **McClung JK**, Jupe ER, Liu XT, Dell'Orco RT. Prohibitin: potential role in senescence, development, and tumor suppression. *Exp Gerontol* 1995; **30**: 99-124

4 **Dixit VD**, Sridaran R, Edmonsond MA, Taub D, Thompson WE. Gonadotropin-releasing hormone attenuates pregnancy-associated thymic involution and modulates

the expression of antiproliferative gene product prohibitin. *Endocrinology* 2003; **144**: 1496-1505

5 **Zhao CH**, Li QF. Altered profiles of nuclear matrix proteins during the differentiation of human gastric mucous adenocarcinoma MGc80-3 cells. *World J Gastroenterol* 2005; **11**: 4628-4633

6 **Li QF**, Zhao CH, Tang J, Liu QR, Shi SL. [Localization of prohibitin in nuclear matrix and its expressive alteration during the differentiation of human osteosarcoma MG-63 cells induced by HMBA] *Fenzi Xibao Shengwu Xuebao* 2008; **41**: 1-10

7 **Li QF**. Effect of retinoic acid on the changes of nuclear matrix in termediate filament system in gastric carcinoma cells. *World J Gastroenterol* 1999; **5**: 417-420

8 **Michishita E**, Kurahashi T, Suzuki T, Fukuda M, Fujii M, Hirano H, Ayusawa D. Changes in nuclear matrix proteins during the senescence-like phenomenon induced by 5-chlorodeoxyuridine in HeLa cells. *Exp Gerontol* 2002; **37**: 885-890

9 **Artal-Sanz M**, Tsang WY, Willems EM, Grivell LA, Lemire BD, van der Spek H, Nijtmans LG. The mitochondrial prohibitin complex is essential for embryonic viability and germline function in Caenorhabditis elegans. *J Biol Chem* 2003; **278**: 32091-32099

10 **Nijtmans LG**, Artal SM, Grivell LA, Coates PJ. The mitochondrial PHB complex: roles in mitochondrial respiratory complex assembly, ageing and degenerative disease. *Cell Mol Life Sci* 2002; **59**: 143-155

11 **Jang JS**, Cho HY, Lee YJ, Ha WS, Kim HW. The differential proteome profile of stomach cancer: identification of the biomarker candidates. *Oncol Res* 2004; **14**: 491-499

12 **Hussain-Hakimjee EA**, Peng X, Mehta RR, Mehta RG. Growth inhibition of carcinogen-transformed MCF-12F breast epithelial cells and hormone-sensitive BT-474 breast cancer cells by 1alpha-hydroxyvitamin D5. *Carcinogenesis* 2006; **27**: 551-559

13 **Tsai HW**, Chow NH, Lin CP, Chan SH, Chou CY, Ho CL. The significance of prohibitin and c-Met/hepatocyte growth factor receptor in the progression of cervical adenocarcinoma. *Hum Pathol* 2006; **37**: 198-204

14 **Qi Y**, Chiu JF, Wang L, Kwong DL, He QY. Comparative proteomic analysis of esophageal squamous cell carcinoma. *Proteomics* 2005; **5**: 2960-2971

15 **Campbell IG**, Allen J, Eccles DM. Prohibitin 3' untranslated region polymorphism and breast cancer risk. *Cancer Epidemiol Biomarkers Prev* 2003; **12**: 1273-1274

16 **Manjeshwar S**, Branam DE, Lerner MR, Brackett DJ, Jupe ER. Tumor suppression by the prohibitin gene 3' untranslated region RNA in human breast cancer. *Cancer Res* 2003; **63**: 5251-5256

17 **Tatsuta T**, Model K, Langer T. Formation of membrane-bound ring complexes by prohibitins in mitochondria. *Mol Biol Cell* 2005; **16**: 248-259

18 **Wang S**, Nath N, Adlam M, Chellappan S. Prohibitin, a potential tumor suppressor, interacts with RB and regulates E2F function. *Oncogene* 1999; **18**: 3501-3510

19 **Coates PJ**, Nenutil R, McGregor A, Picksley SM, Crouch DH, Hall PA, Wright EG. Mammalian prohibitin proteins respond to mitochondrial stress and decrease during cellular senescence. *Exp Cell Res* 2001; **265**: 262-273

20 **Menssen A**, Hermeking H. Characterization of the c-MYC-regulated transcriptome by SAGE: identification and analysis of c-MYC target genes. *Proc Natl Acad Sci USA* 2002; **99**: 6274-6279

21 **Fusaro G**, Dasgupta P, Rastogi S, Joshi B, Chellappan S. Prohibitin induces the transcriptional activity of p53 and is exported from the nucleus upon apoptotic signaling. *J Biol Chem* 2003; **278**: 47853-47861

22 **Rastogi S**, Joshi B, Fusaro G, Chellappan S. Camptothecin induces nuclear export of prohibitin preferentially in transformed cells through a CRM-1-dependent mechanism. *J Biol Chem* 2006; **281**: 2951-2959

23 **Joshi B**, Rastogi S, Morris M, Carastro LM, DeCook C, Seto E, Chellappan SP. Differential regulation of human YY1 and caspase 7 promoters by prohibitin through E2F1 and p53 binding sites. *Biochem J* 2007; **401**: 155-166

24 **Wang S**, Fusaro G, Padmanabhan J, Chellappan SP. Prohibitin co-localizes with Rb in the nucleus and recruits N-CoR and HDAC1 for transcriptional repression. *Oncogene* 2002; **21**: 8388-8396

25 **Wang S**, Nath N, Fusaro G, Chellappan S. Rb and prohibitin target distinct regions of E2F1 for repression and respond to different upstream signals. *Mol Cell Biol* 1999; **19**: 7447-7460

S- Editor Li DL **L- Editor** Rippe RA **E- Editor** Ma WH

Online Submissions: wjg.wjgnet.com
wjg@wjgnet.com
doi:10.3748/wjg.14.5015

World J Gastroenterol 2008 August 28; 14(32): 5015-5019
World Journal of Gastroenterology ISSN 1007-9327
© 2008 The WJG Press. All rights reserved.

RAPID COMMUNICATION

Significance of scintigraphy for the localization of obscure gastrointestinal bleedings

Tanja Brünnler, Frank Klebl, Sascha Mundorff, Christoph Eilles, Michael Reng, Hans von Korn, Jürgen Schölmerich, Julia Langgartner, Stefan Grüne

Tanja Brünnler, Frank Klebl, Jürgen Schölmerich, Julia Langgartner, Department of Internal Medicine I, University of Regensburg, Regensburg D-93042, Germany
Hans von Korn, Stefan Grüne, Department of Internal Medicine II, Hospital Hetzelstift, Neustadt D-67434, Germany
Sascha Mundorff, Department of Surgery, Hospital Neumarkt, Neumarkt D-92318, Germany
Christoph Eilles, Department of Nuclear Medicine, University of Regensburg, Regensburg D-93042, Germany
Michael Reng, Department of Internal Medicine Hospital Bogen, Bogen 94327, Germany
Author contributions: Klebl F, Mundorff S, Eilles C, Reng M, von Korn H, Schölmerich J, and Grüne S designed the study; Klebl F, Mundorff S, Eilles C, Reng M, von Korn H, Schölmerich J, Langgartner J, and Grüne S performed the study; Brünnler T, Mundorff S, Schölmerich J, Langgartner J, and Grüne S analyzed the data; Brünnler T and Langgartner J wrote the paper.
Correspondence to: Tanja Brünnler, MD, Klinik und Poliklinik fuer Innere Medizin I, Klinikum der Universität Regensburg, Regensburg D-93042,
Germany. tanja.bruennler@klinik.uni-r.de
Telephone: +49-941-9447010 Fax: +49-941-9447107
Received: April 5, 2008 Revised: July 13, 2008
Accepted: July 20, 2008
Published online: August 28, 2008

Abstract

AIM: To determine the role of scintigraphy in patients with gastrointestinal (GI) bleeding of unknown localization.
METHODS: We performed retrospective analyses on 92 patients receiving scintigraphies from 1993 to 2000 in the University of Regensburg hospital, which were done for localization of GI bleeding as a diagnostic step after an unsuccessful endoscopy. In addition to the scintigraphies, further diagnostic steps such as endoscopy, angiography or operations were performed. In some of the scintigraphies with negative results, a provocation test for bleeding with heparinisation was carried out.
RESULTS: 73% of all scintigraphies showed a positive result. In 4.5% of the positive results, the source was located in the stomach, in 37% the source was the small bowel, in 25% the source was the right colon, in 4.5% the source was the left colon, and in 20% no clear localization was possible. Only 4% of all scintigraphies were false positive. A reliable positive scintigraphy was independent of the age of the examined patient. A provocation test for bleeding with heparin resulted in an additional 46% of positive scintigraphies with a reliable localization in primary negative scintigraphies.
CONCLUSION: Our results show that scintigraphy and scintigraphy with heparin provocation tests are reliable procedures. They enable a reliable localization in about half of the obscure GI-bleeding cases. Scintigraphy is superior to angiography in locating a bleeding. It is shown that even in the age of video capsule endoscopy and double-balloon enteroscopy, scintigraphy provides a reliable and directed localization of GI bleeding and offers carefully targeted guidance for other procedures.

© 2008 The WJG Press. All rights reserved.

Key words: Gastrointestinal bleeding; Scintigraphy; Localization; Angiography

Peer reviewer: Phillip S Oates, PhD, Department of Physiology, School of Biomedical and Chemical Sciences, the University of Western Australia, Perth, Western Australia 6009, Australia

Brünnler T, Klebl F, Mundorff S, Eilles C, Reng M, von Korn H, Schölmerich J, Langgartner J, Grüne S. Significance of scintigraphy for the localization of obscure gastrointestinal bleedings. *World J Gastroenterol* 2008; 14(32): 5015-5019 Available from: URL: http://www.wjgnet.com/1007-9327/14/5015.asp DOI: http://dx.doi.org/10.3748/wjg.14.5015

INTRODUCTION

Gastrointestinal (GI) bleeding is a common GI disorder that requires an exact localization to guarantee adequate treatment. The clinical presentation ranges from asymptomatic or mild symptoms to a life threatening situation with mortality rates of up to 10%-14%[1-3]. Most deaths are associated with comorbidities and often occur in elderly patients[1,2]. Moreover the incidence of GI bleeding increases with age[3].

GI bleeding is usually categorized by its localization as an upper GI bleeding (originating proximal to the Ligament of Treitz) or a lower GI bleeding (localized distal to the Ligament of Treitz), or must be classified as

obscure bleeding if not defined[4]. Dependent on local and on other factors, such as hemodynamic instability or age, different diagnostic steps, including endoscopic, radiological, or nuclear medical methods, must be performed. An example for such a diagnostic algorithm was published by Lee and Laberge 2004[5].

Radionucleotide imaging is one diagnostic possibility for the detection of GI bleeding. Its sensitivity as well as its specificity for bleeding localization seems to be high, with results of 93% to 95% at a rate of 0.04 mL/min for red blood cell (RBC) scans[6]. Its accuracy rises up from 41% to 97% when the results are verified by endoscopy, angiography or surgery[7]. This method offers advantages in being non-invasive, not requiring special preparations for the patient, and detecting both arterial and venous bleeding sites, whereas angiography only detects arterial bleedings. Moreover it offers the capability of imaging over a prolonged period of time. But, as a disadvantage, localization of bleeding sites is often not precise.

In our study we retrospectively evaluated the results of 92 patients requiring scintigraphy with ^{99m}Technetium (^{99m}Tc) labelled red blood cells with special focus on elderly patients, patients with scintigraphy after a provocation test with heparin, and comparison of the results with angiography.

MATERIALS AND METHODS

Patient recruitment and review of data

This is a retrospective study performed at a university hospital. By searching the internal medicine databases, 92 patients were identified with the diagnosis GI bleeding of unknown localization who underwent scintigraphy with ^{99m}Tc-marked red blood cells as a diagnostic procedure. If a patient required a second hospital stay, it was considered as a new case. Demographic (age, sex) and clinical data (length of hospital stay, underlying diseases if related to bleeding) as well as diagnostic and therapeutic approaches performed were collected by reviewing patient flow charts. Thereby we assessed the time of scintigraphy in relation to the time of first bleeding symptoms. Duration of not more than 7 d was classified as acute bleeding; a bleeding persisting for more than 7 d was classified as chronic bleeding. For laboratory values, we assessed the red blood cell count, and if patients required blood products we evaluated the number of red blood cell units and classified the patients as having received one unit, two units, three or more units.

For negative scintigraphies, a provocation test for bleeding with heparinisation was carried out. Comparative diagnostic or therapeutic procedures following scintigraphy, such as gastroscopy, colonoscopy, angiography, laparoscopy, and computed tomography (CT) scan, were assessed.

Nuclear medicine procedures

For scintigraphy with ^{99m}Tc labeled red blood cells, a kit from Nycomed Amersham Sorin Italia, containing 24 mg DTPA, 3.6 mg $SnCl_2$ H_2O, 22 mg Sodium-acetate and 9 mg Sodium-chloride, was used. The intravenous ^{22m}Tc pertechnetate activity was 1000 MBq. Imaging procedures were performed dynamically during the first hour (one picture every second during the influx period, then one picture per minute until 1 h) with a static image after exactly 1 h. If further images were needed they were performed up to 29 h after the initial application. For imaging procedures, a Siemens Company camera was used as well as an Icon Processing Work Station for reconstructions.

Statistical analysis

Statistical analyses were performed with SPSS 12.0 statistical software (SPSS inc., Chicago, IL) and Microsoft Excel. Values are shown as total numbers, average or median with range, or as percentages where necessary. Kind support for statistical analyses was given by Metronomia Clinical Research GmbH (Munich, Germany).

RESULTS

Patient population

From our database, we identified 92 patients with GI bleeding who received scintigraphy as a diagnostic procedure and for whom complete data could be collected. Table 1 shows demographic characteristics, underlying diseases, fractions of acute and chronic bleeding, use of red blood cell units and the need of heparin induced provocation as a further diagnostic step for all 92 patients.

Characteristics of scintigraphy

The details of performed scintigraphy in relation to a positive or negative result are shown in Table 2. In 25 patients (27%), there was no evidence of GI bleeding and no further examination or treatment was necessary in 19 patients. In 67 patients (73%), a positive result was found. Verification of the location was performed with further diagnostic procedures, such as gastroscopy, colonoscopy, angiography, computed tomography, and laparoscopy. 23 results were definitively correct and 7 were definitively false. A positive scintigraphy result was not confirmed by further diagnostic procedures in 37 patients (Figure 1).

Concerning reliable positive scintigraphies, no significant difference between age-groups was found (Figure 2).

Scintigraphy after provocation with heparin

A provocation test with heparin was performed in 13 patients. Five of these patients had previously received a scintigraphy without heparinisation, which was negative in 2 patients, slightly positive in 2 patients, and positive without localization in one patient. The other 8 patients received a heparin-provocated scintigraphy initially in our hospital because they had a negative scintigraphy outside the university hospital. Six (46%) patients had a positive result with localization of the bleeding, 3 (23%)

Table 1 Patients characteristics

	Characteristics (n = 92)	
	Average	Range (%)
Age	60	17-88
Male	52	56.5
Gastrointestinal bleeding without underlying disease	47	51.1
Gastrointestinal bleeding with underlying disease	45	48.9
Gastro-intestinal malignancy	11	11.9
Diverticulosis	5	5.4
Acute leukemia	6	6.5
Chronic renal insufficiency	3	3.3
Angiodysplasia	3	3.3
Chronic inflammatory bowel disease	4	4.4
Hepatic cirrhosis	3	3.3
Others	10	11.9
Acute gastro-intestinal bleeding	55	59.8
Chronic gastro-intestinal bleeding	37	40.2
Use of red blood cell concentrates		
⩽ 1	70	76.1
2	17	18.5
⩾ 3	5	5.4
Provocation test with heparin	13	14.1
Positive	9	9.8
Negative	4	4.4
Intestinoscopies during surgery	8	8.7
With a definite bleeding localization	2	2.2
Without a definite bleeding localization	6	6.5
Mortality	9	10.9

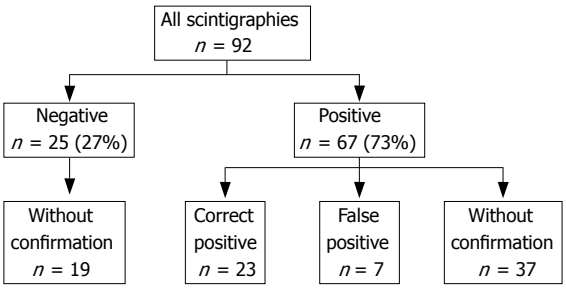

Figure 1 Scintigraphy results.

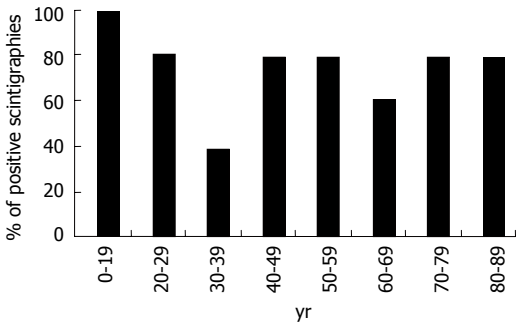

Figure 2 Reliable positive scintigraphies by age.

Table 2 Details of performed scintigraphy

	Negative scintigraphy result	Positive scintigraphy result
Total (n = 92)	n = 25 (27.2%)	n = 67 (72.8%)
Total time of scintigraphy (h)	18 (0.75-25)	19 (1-48)
Radioactivity (MBq)	903 (312-1360)	975 (486-1300)
Gastrointestinal bleeding without underlying disease	11 (44%)	36 (54%)
Gastrointestinal bleeding with underlying disease	14 (56%)	31 (46%)
Acute bleeding	17 (68%)	38 (57%)
Chronic bleeding	8 (32%)	29 (43%)
Surgery required	3 (3.3%)	22 (23.9%)
Laboratory values		
Hemoglobin (mg/dL)	10.1 (6.9-15.5)	8.6 (3.2-15.6)
Platelet count (/dL)	241 (18-643)	268 (40-665)
PTT (s)	36.5 (24.2-6.9)	33.5 (21.2-64.7)
Quick (%)	89 (51-100)	89 (39-100)
Use of red blood cell concentrates		
⩽ 1	20	50
2	5	12
⩾ 3	0	5

patients showed a positive result without localization, and 4 (31%) patients showed a negative result.

Comparison in patients receiving angiography

An angiogram was performed in 33 of our 92 patients. 6 patients were negative in both tests. Retrospectively, 1 of these 6 patients showed a false negative result in both of the examinations. Twenty two patients had a negative angiogram, however, 9 of these patients showed a positive scintigraphy result (correct localization in 8 patients and unclear localization in 1 patient). Thirteen patients showed a false positive scintigraphy result. Five patients showed a positive angiogram with positive scintigrams. The localization was correct in 2 patients, unclear in 2 patients and in 1 patient correct in the angiogram but false positive in the scintigram (Figure 3).

Relevance of performed scintigraphy

Our results showed a sensitivity of 79% (23/29) for the presence of bleeding with scintigraphy, and a specificity of 30% (19/63). The negative predictive value was 76% (19/25), the positive predictive value 77%, including the patients with a positive scintigraphy result without confirmation 34% (23/67).

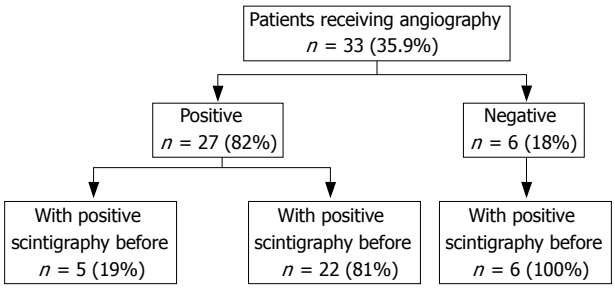

Figure 3 Angiography.

Outcome

Nine of 92 patients died. Death occurred due to underlying diseases, which was hemato-oncologic malignancy in 6 patients, sepsis by vasculitis and gangrenous leg in one patient, sepsis and cirrhosis of the liver in one patient, and terminal heart insufficiency due to ischemic cardiomyopathy in one patient.

No death was correlated to the performed scintigraphy, and there were no procedure-associated complications documented. In the subpopulation of patients receiving heparinisation, no patient died. Scintigraphy itself, even with heparin-induced provocation, seems to be a safe procedure.

DISCUSSION

Scintigraphy with ^{99m}Tc labelled red blood cells is a possible tool in the diagnosis of GI bleeding[8-13]. The reported success rates for identifying correct locations of bleeding range from 19% to 96% according to the literature[14-19].

Different reasons may explain the wide range of sensitivities, specifies or accuracies of localizations. In some studies, results were not confirmed by further diagnostic procedures or were confirmed by diagnostic tests, such as barium contrast studies or simple clinical observation, which are not very effective procedures regarding localization of GI bleeding. Therefore, confirmation of scintigraphy results differs in the reported studies making comparisons of results difficult.

In previous studies, focus was on positive results rather than negative results, however, mortality and morbidity due to diagnostic and therapeutic procedures can be controlled by a cautious and well planned surgical approach. It has been shown in this context that a negative result is predictive of a good outcome, and may help in diagnostic risk stratification by avoiding unnecessary emergency care[20]. This fact may also be reflected in our population with 3 out of 25 patients dying in the subpopulation of patients with negative scintigraphy results but with no death correlated with the GI bleeding.

For imaging procedures, we used scintigraphy with ^{99m}Tc-labelled red blood cells. Imaging protocols have recently been well described[21-23]. Active bleeding rates greater than 0.3 mL/min can be detected[24] and also some evidence exists that bleeding rates lower than 0.1 mL/min can be detected[25]. In contrast to the erythrocyte labelled method, there is also the possibility of using ^{99m}Tc-labelled sulfur colloid scintigraphy. This method, first described in 1977[26], is also a successful tool for identification of bleeding sites, but may be problematic in the detection of bleeding in the stomach, proximal duodenum, or colonic flexures, due to intense radiotracer activity within the liver and the spleen. It has been shown that there is no practical advantage in the use of ^{99m}Technetium labelled red blood cell scintigraphy over ^{99m}Tc-labeled sulfur colloid scintigraphy[27].

Our study has some limitations. One limitation is the study was retrospective within a single centre. Moreover, the patient cohort was mixed in terms of existing underlying diseases.

Our study shows that scintigraphies, as well as scintigraphies with heparin provocation tests, are safe procedures. They enable a reliable localization in about half of the GI bleeding cases. Scintigraphy is, in our setting, superior to angiography and there is evidence that it seems to be a helpful procedure especially for older patients who are restricted concerning invasive procedures. To our knowledge, no literature exists specifically for older patients receiving blood pool scintigraphy.

Even in the era of video capsule endoscopy and double-ballon enteroscopy, we showed that scintigraphy is a safe and helpful diagnostic tool, which allows for safe detection of GI bleeding sites and therefore carefully targeted use of further procedures.

COMMENTS

Background

In 30%-35% of all gastrointestinal (GI) bleedings no clear localization of the bleeding site through endoscopy is possible. For further diagnostic steps scintigraphy is a safe method to detect the possible localizations of a so far unknown bleeding.

Research frontiers

Blood pool scintigraphy is an established method in the diagnostic of the obscure GI bleeding. Our data show that it is a safe procedure being non-invasive with low-examination-related risks. Further prospective evaluation and correlation with further diagnostic tests as i.e. capsule endoscopy and double-balloon enteroscopy scintigraphy is needed.

Innovations and breakthroughs

It is shown that even in the time of video capsule endoscopy and double-balloon enteroscopy blood pool scintigraphy enables a reliable and directed localization of a GI bleeding and a carefully targeted use of further diagnostic procedures.

Applications

These findings may help to optimize the diagnostic approach in patients with an obscure GI bleeding.

Peer review

The study was a retrospective analysis of 92 patients for patients with unknown intestinal bleeds further leading to unsuccessful endoscopy. The significance of scintigraphy is under evaluation and this paper helps to bring focus on this issue particularly as there is presently a limited ability to detect GI bleeding.

REFERENCES

1 **Longstreth GF**. Epidemiology and outcome of patients hospitalized with acute lower gastrointestinal hemorrhage: a population-based study. *Am J Gastroenterol* 1997; **92**: 419-424
2 **Longstreth GF**. Epidemiology of hospitalization for acute upper gastrointestinal hemorrhage: a population-based study. *Am J Gastroenterol* 1995; **90**: 206-210
3 **Palmer K**. Management of haematemesis and melaena.

Postgrad Med J 2004; **80**: 399-404
4 **Zuckerman GR**, Prakash C, Askin MP, Lewis BS. AGA technical review on the evaluation and management of occult and obscure gastrointestinal bleeding. *Gastroenterology* 2000; **118**: 201-221
5 **Lee EW**, Laberge JM. Differential diagnosis of gastrointestinal bleeding. *Tech Vasc Interv Radiol* 2004; **7**: 112-122
6 **Zuckier LS**. Acute gastrointestinal bleeding. *Semin Nucl Med* 2003; **33**: 297-311
7 **Zuckerman GR**, Prakash C. Acute lower intestinal bleeding: part I: clinical presentation and diagnosis. *Gastrointest Endosc* 1998; **48**: 606-617
8 **Bearn P**, Persad R, Wilson N, Flanagan J, Williams T. 99mTechnetium-labelled red blood cell scintigraphy as an alternative to angiography in the investigation of gastrointestinal bleeding: clinical experience in a district general hospital. *Ann R Coll Surg Engl* 1992; **74**: 192-199
9 **Dusold R**, Burke K, Carpentier W, Dyck WP. The accuracy of technetium-99m-labeled red cell scintigraphy in localizing gastrointestinal bleeding. *Am J Gastroenterol* 1994; **89**: 345-348
10 **Emslie JT**, Zarnegar K, Siegel ME, Beart RW Jr. Technetium-99m-labeled red blood cell scans in the investigation of gastrointestinal bleeding. *Dis Colon Rectum* 1996; **39**: 750-754
11 **Garofalo TE**, Abdu RA. Accuracy and efficacy of nuclear scintigraphy for the detection of gastrointestinal bleeding. *Arch Surg* 1997; **132**: 196-199
12 **Hunter JM**, Pezim ME. Limited value of technetium 99m-labeled red cell scintigraphy in localization of lower gastrointestinal bleeding. *Am J Surg* 1990; **159**: 504-506
13 **Leitman IM**, Paull DE, Shires GT 3rd. Evaluation and management of massive lower gastrointestinal hemorrhage. *Ann Surg* 1989; **209**: 175-180
14 **Nicholson ML**, Neoptolemos JP, Sharp JF, Watkin EM, Fossard DP. Localization of lower gastrointestinal bleeding using in vivo technetium-99m-labelled red blood cell scintigraphy. *Br J Surg* 1989; **76**: 358-361
15 **O'Neill BB**, Gosnell JE, Lull RJ, Schecter WP, Koch J, Halvorsen RA, Harris HW. Cinematic nuclear scintigraphy reliably directs surgical intervention for patients with gastrointestinal bleeding. *Arch Surg* 2000; **135**: 1076-1081; discussion 1081-1082
16 **Orecchia PM**, Hensley EK, McDonald PT, Lull RJ. Localization of lower gastrointestinal hemorrhage. Experience with red blood cells labeled in vitro with technetium Tc 99m. *Arch Surg* 1985; **120**: 621-624
17 **Rantis PC Jr**, Harford FJ, Wagner RH, Henkin RE. Technetium-labelled red blood cell scintigraphy: is it useful in acute lower gastrointestinal bleeding? *Int J Colorectal Dis* 1995; **10**: 210-215
18 **Suzman MS**, Talmor M, Jennis R, Binkert B, Barie PS. Accurate localization and surgical management of active lower gastrointestinal hemorrhage with technetium-labeled erythrocyte scintigraphy. *Ann Surg* 1996; **224**: 29-36
19 **Van Geelen JA**, De Graaf EM, Bronsveld W, Boer RO. Clinical value of labeled red blood cell scintigraphy in patients with difficult to diagnose gastrointestinal bleeding. *Clin Nucl Med* 1994; **19**: 949-952
20 **Zettinig G**, Staudenherz A, Leitha T. The importance of delayed images in gastrointestinal bleeding scintigraphy. *Nucl Med Commun* 2002; **23**: 803-808
21 **Maurer AH**. Gastrointestinal bleeding and cine-scintigraphy. *Semin Nucl Med* 1996; **26**: 43-50
22 **McKusick KA**, Froelich J, Callahan RJ, Winzelberg GG, Strauss HW. 99mTc red blood cells for detection of gastrointestinal bleeding: experience with 80 patients. *AJR Am J Roentgenol* 1981; **137**: 1113-1118
23 **Winzelberg GG**, Froelich JW, McKusick KA, Strauss HW. Scintigraphic detection of gastrointestinal bleeding: a review of current methods. *Am J Gastroenterol* 1983; **78**: 324-327
24 **Winzelberg GG**, McKusick KA, Strauss HW, Waltman AC, Greenfield AJ. Evaluation of gastrointestinal bleeding by red blood cells labeled in vivo with technetium-99m. *J Nucl Med* 1979; **20**: 1080-1086
25 **Thorne DA**, Datz FL, Remley K, Christian PE. Bleeding rates necessary for detecting acute gastrointestinal bleeding with technetium-99m-labeled red blood cells in an experimental model. *J Nucl Med* 1987; **28**: 514-520
26 **Alavi A**, Dann RW, Baum S, Biery DN. Scintigraphic detection of acute gastrointestinal bleeding. *Radiology* 1977; **124**: 753-756
27 **Ponzo F**, Zhuang H, Liu FM, Lacorte LB, Moussavian B, Wang S, Alavi A. Tc-99m sulfur colloid and Tc-99m tagged red blood cell methods are comparable for detecting lower gastrointestinal bleeding in clinical practice. *Clin Nucl Med* 2002; **27**: 405-409

S- Editor Li DL **L- Editor** Lutze M **E- Editor** Yin DH

Online Submissions: wjg.wjgnet.com
wjg@wjgnet.com
doi:10.3748/wjg.14.5020

World J Gastroenterol 2008 August 28; 14(32): 5020-5024
World Journal of Gastroenterology ISSN 1007-9327
© 2008 The WJG Press. All rights reserved.

RAPID COMMUNICATION

Probiotic effects on intestinal fermentation patterns in patients with irritable bowel syndrome

Jacqueline S Barrett, Kim EK Canale, Richard B Gearry, Peter M Irving, Peter R Gibson

Jacqueline S Barrett, Kim EK Canale, Richard B Gearry, Peter M Irving, Peter R Gibson, Monash University, Department of Medicine, and Department of Gastroenterology, Box Hill Hospital, Box Hill, Victoria 3128, Australia
Author contributions: Gibson PR designed the research; Barrett JS, Canale KEK, Gearry RB and Irving PM performed the research; Barrett JS analysed data; Barrett JS and Gibson PR wrote the paper.
Supported by Yakult Ltd, Melbourne Australia
Correspondence to: Peter R Gibson, Professor, Monash University, Department of Medicine, and Department of Gastroenterology, Box Hill Hospital, Box Hill, Victoria 3128, Australia. peter.gibson@med.monash.edu.au
Telephone: +61-3-98950349 Fax: +61-3-98950332
Received: April 2, 2008 Revised: August 12, 2008
Accepted: August 19, 2008
Published online: August 28, 2008

© 2008 The WJG Press. All rights reserved.

Key words: Probiotics; Small intestinal bacterial overgrowth; Breath hydrogen testing; Functional gut symptoms

Peer reviewer: Christina Surawicz, MD, Christina Surawicz, Harborview Medical Center, 325 9th Ave, #359773, Seattle WA 98104, United States

Barrett JS, Canale KEK, Gearry RB, Irving PM, Gibson PR. Probiotic effects on intestinal fermentation patterns in patients with irritable bowel syndrome. *World J Gastroenterol* 2008; 14(32): 5020-5024 Available from: URL: http://www.wjgnet.com/1007-9327/14/5020.asp DOI: http://dx.doi.org/10.3748/wjg.14.5020

Abstract

AIM: To determine whether *Lactobacillus casei* strain Shirota (Yakult®) can alter small intestinal bacterial overgrowth (SIBO), as tested by the lactulose breath test, and whether this is associated with changes in symptoms in irritable bowel syndrome (IBS).

METHODS: 18 patients with IBS (Rome Ⅱ criteria), who showed an early rise in breath hydrogen with lactulose (ERBHAL), consumed 65 mL of Yakult® daily for 6 wk. Lactulose breath test was repeated at the end of the treatment period. Symptoms were recorded daily using a 10 cm visual analogue scale.

RESULTS: 14 patients completed the study, 9 (64%) had reversal of ERBHAL, with the median time of first rise in breath hydrogen increasing from 45 to 75 min (P = 0.03). There was no significant improvement in the symptom score with probiotic therapy, except for wind (P = 0.04). Patients commencing with at least moderate symptoms and who no longer had ERBHAL at the end of treatment, showed improvement in the overall symptoms scores [median final score 5.3 (IQR 3.9-5.9), 55% reduction; n = 6] to a greater extent than those who had had persisting ERBHAL [final score 6.9 (5.0-7.0), 12% reduction; n = 5; P = 0.18].

CONCLUSION: Yakult® is effective in altering fermentation patterns in the small bowel, consistent with reducing SIBO. The loss of ERBHAL was associated with reduced symptoms. The true interpretation of these findings awaits a randomised, controlled trial.

INTRODUCTION

Irritable bowel syndrome (IBS) is the most common gastrointestinal disorder, thought to affect approximately 15% of the population[1]. Differences in gut microflora are evident between IBS sufferers and controls, with the former demonstrating significantly lower concentrations of bifidobacteria and lactobacilli, and higher concentrations of *Streptococcus*, *E. coli* and *Clostridia*[2,3]. Small intestinal bacterial overgrowth (SIBO) occurs in up to 78% patients with IBS, and may be directly related to the genesis of IBS symptoms[4,5]. The mechanism by which symptoms are generated from SIBO is most probably through fermentation, with rapid production of hydrogen, methane and carbon dioxide. This results in distention of the small intestine, leading to discomfort, sensation of bloating and secondary disturbances in motility.

SIBO is difficult to assess, but can be detected indirectly through the use of lactulose breath hydrogen or ^{14}C-xylose breath tests. In the case of the lactulose hydrogen breath test, a rise in breath hydrogen is expected approximately 90 min after the solution is consumed. An early rise in breath hydrogen after lactulose (ERBHAL) leads to one of two conclusions: either bacterial fermentation is occurring in the small intestine due to bacterial overgrowth, or there is rapid small intestinal transit[6].

The role of SIBO in the genesis of IBS symptoms has been reviewed recently[7]. Several clinical trials have played

a key role in examining this association, in which antibiotic use has not only normalized lactulose breath hydrogen tests but has also led to an improvement in the symptoms of IBS[5,8-10]. It has also been suggested that malabsorption of fructose and lactose may result from SIBO, which, when corrected with antibiotics (as demonstrated by normalisation of the lactulose breath test), is associated with improved absorption of these sugars[5,8].

Apart from antibiotics, other potential therapies have been suggested for the treatment of SIBO. Dietary restriction of fermentable carbohydrates is promising, as shown by the use of elemental diets[11]. However, an elemental diet is not a practical solution. Secondly, prokinetic agents, such as tegaserod, may play a role in promoting clearance of the lumen[12]. Finally, probiotics may influence bacterial populations in the small intestinal biofilm, manifesting as reduction in the total count or as a change in the activity, such that symptoms are not induced. It has been well documented that probiotics modify fermentation in the large intestine by increasing the absolute count of probiotic-type bacteria and reducing the *Streptococcus* counts[13]. It has also been shown that some probiotic strains improve symptoms of bloating, wind and pain in IBS patients[14,15]. However, the impact of probiotics specifically on SIBO in IBS patients has not been formally investigated.

The primary aim of the present study was to address the hypothesis that probiotics reverse SIBO, as defined by the breath hydrogen criteria. The secondary aim was to determine whether changes in the symptoms were associated with changes in breath test patterns. To examine this, an open label, pilot study was performed to assess the effect of *L. casei* strain Shirota (Yakult®) on ERBHAL in patients with IBS and ERBHAL.

MATERIALS AND METHODS

Patients

Patients referred for breath testing, who were found to have ERBHAL and fulfilled Rome Ⅱ criteria for IBS, were invited to participate in the study. Patients were excluded if they were currently taking IBS medication, had previous specific dietary therapy, had taken probiotics for greater than 2 wk within the previous six months, or antibiotics in the previous 2 mo, were ingesting aspirin, non-steroidal anti-inflammatory drugs or alcohol in excess of 20 g/d, or had any clinically significant co-morbidity. Eighteen patients were recruited. The mean age (range) was 44 (20-70) years; five subjects were male. All patients fulfilled Rome Ⅱ criteria for IBS, with 8 (44%) being constipation-predominant, 4 (22%) diarrhoea-predominant, and 6 (33%) having alternating bowel habits.

Experimental protocol

Patients undertook a 1 to 2 wk run in period during which they completed a daily symptom diary. Daily recordings were made regarding symptom severity and, at the end of each week, the patients rated their symptoms overall, including the following specific symptoms-abdominal pain/discomfort, bloating, satisfaction with stool consistency, passage of wind, tiredness, and nausea-using a 10 cm visual analogue scale (VAS). The symptoms were classified as "mild" if VAS was < 3 cm, "moderate" 3 to < 7 cm and "severe" ⩾ 7 cm. The patients were then started on probiotic therapy, comprising of 65 mL (one bottle, 6.5 billion bacteria, 1 g lactose per dose) of *L. casei* strain Shirota in a solution containing sucrose, skim milk powder and dextrose (Yakult®, Yakult Ltd, Melbourne Australia), which was taken each morning prior to breakfast, for 6 wk. The same symptom diary and weekly questionnaire was completed throughout the treatment period. The patients were reviewed after 3 and 6 wk of treatment. During the last week of the study, the lactulose breath test was repeated.

Patients whose symptoms worsened significantly, terminated the study early and, if possible, the lactulose breath hydrogen test was performed prior to the cessation of the probiotic therapy. The symptom scores were considered valid if the patient had completed at least 3 wk of treatment.

Breath hydrogen test

Prior to the breath hydrogen test, dietary restriction (minimising intake of fibre and poorly absorbed short-chain carbohydrates) was advised for 24 h and the subjects fasted overnight. The patients consumed 15 g lactulose, made up to a 100 mL solution with water. Breath hydrogen samples were collected at baseline and every 15 min for at least 2 h.

ERBHAL was defined as a rise of breath hydrogen of 10 ppm or greater above the baseline breath hydrogen on two consecutive 15-min samples before 90 min, following the ingestion of lactulose. The time of the first rise in breath hydrogen of 10 ppm or more was recorded.

Statistical analysis

Data were expressed as mean and standard error of the mean (SEM), or median and interquartile range (IQR) according to the distribution of the findings. Changes in the end-points were compared using a Wilcoxon matched pairs test. Univariate regression analyses were performed and Pearson's correlation coefficients were calculated. All statistical tests were performed using Microsoft Office® Excel 2003 and GraphPad Prism (version 3.00 for Windows, GraphPad Software, San Diego California USA). $P \leqslant 0.05$ was considered statistically significant.

RESULTS

Patient baseline symptom characteristics

On the self-rated scales, the overall symptom severity varied across the patients, with three patients experiencing very mild symptoms, 11 moderate symptoms and two severe symptoms. However, all patients, rated at least one specific abdominal symptom as ⩾ 3 cm, with the passage of wind and dissatisfaction with stool consistency being

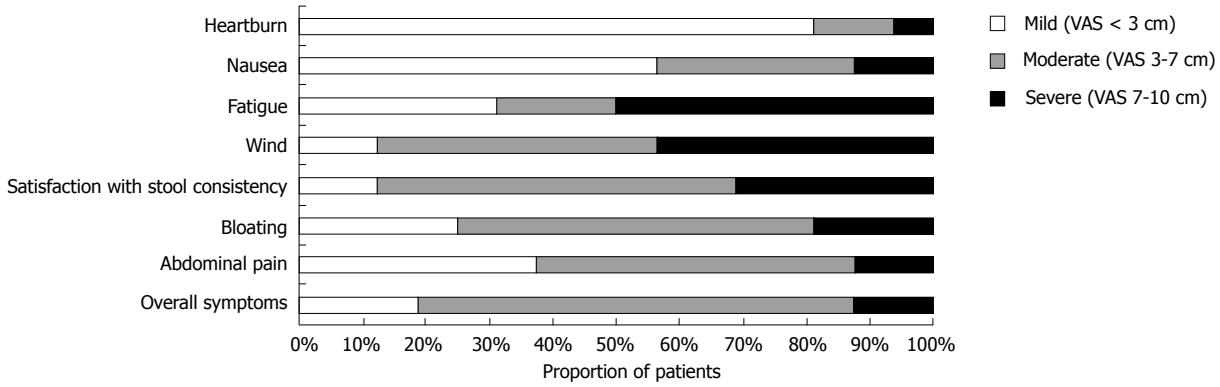

Figure 1 Individual and overall symptom scores at baseline, based on the visual analogue scale (VAS).

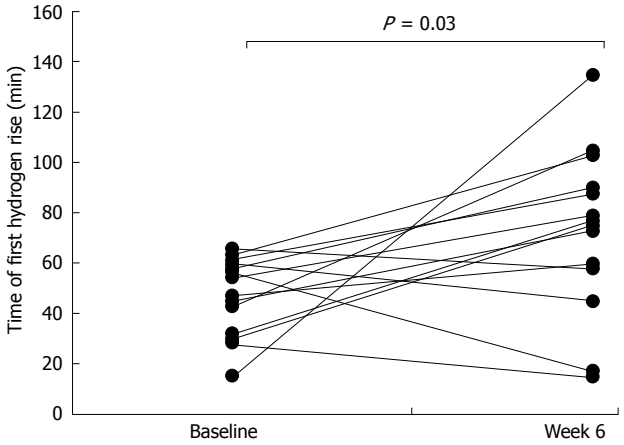

Figure 2 The time of the first rise at or above 10 ppm in breath hydrogen after lactulose during the baseline period, and during treatment with *L. casei* strain Shirota. The time during the treatment period was significantly later compared to at baseline (P = 0.03, Wilcoxon matched pairs test).

the most frequently reported symptoms. The proportion of patients with mild, moderate or severe baseline symptoms is shown in Figure 1.

Adherence to protocol and treatment

Two patients terminated the study after taking Yakult® for < 2 wk due to intolerable symptoms (increasing nausea). They were excluded from the analysis as per protocol. An additional patient terminated after 3 wk, also because of increasing nausea but did not agree for a repeat hydrogen breath test. One patient commenced antibiotics for an unrelated illness after taking Yakult® for 3 wk and was withdrawn from the study due to the confounding influence of antibiotic therapy. Thus, breath test assessment was performed as per protocol in 14 patients and the effect of probiotics on symptoms was evaluable in 16 patients.

Adherence to the study treatment was > 95% in all the participants, as judged by the returned open and unused probiotic bottles.

Effect of Yakult® on end-points

Prior to treatment, the median time after ingestion of lactulose when breath hydrogen deviated by ⩾ 10 ppm from the baseline was 45 min (IQR 30-60) (Figure 2). During probiotic therapy, the median time for the first breath hydrogen rise increased to 75 min (IQR 60-90) (P = 0.03) with 9 patients (64%) no longer demonstrating an ERBHAL, according to the entry criterion (Figure 2).

There was no significant difference in the VAS score for the overall abdominal symptoms from baseline (mean ± SEM, 4.8 ± 0.56 cm) to the final week of treatment (4.2 ± 0.68 cm) (P = 0.33). The effect of probiotic treatment was examined for each individual symptom. Only the VAS score for the passage of wind improved significantly with Yakult® (6.1 ± 0.5 cm to 4.4 ± 0.56 cm; P = 0.04), while none of the symptoms worsened significantly. There was no association of change in the symptoms with the subtype of IBS (data not shown).

Relationship between final ERBHAL status and change in symptoms

Patients were divided into two groups: those who no longer had ERBHAL at the end of 6 wk's therapy ("no-ERBHAL" group; n = 9), and those with continuing ERBHAL ("ERBHAL" group; n = 5). The change in VAS for the overall symptoms in the two groups is shown in Figure 3. Seven of the 9 patients in the no-ERBHAL group had moderate overall symptoms prior to treatment; 5 improved by at least 2 cm on the VAS, compared with none of 5 patients in the ERBHAL group (P = 0.06; Fisher's exact test). The change in the overall symptom score in patients with at least moderate symptoms prior to treatment was greater in those who no longer had ERBHAL [median final score 5.3 (IQR 3.9-5.9), 55% reduction; n = 6] compared to patients with continuing ERBHAL [final score 6.9 (5.0-7.0), 12% reduction; n = 5; P = 0.18; Mann Whitney t-test].

DISCUSSION

This is the first study on the effect of a probiotic agent in patients with IBS and ERBHAL. The findings show that Yakult®-induced change in the fermentation pattern resulted in 64% patients no longer fulfilling the definition of ERBHAL at the end of the treatment period. While such a change may represent regression towards the mean due to the repetition of the breath test[16], it more likely reflects a physiological change. This could conceivably be due to slower oro-caecal transit,

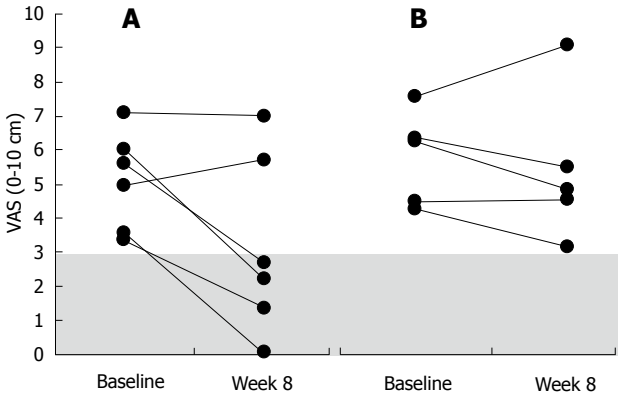

Figure 3 The overall abdominal symptom score at baseline in patients with more than minimal symptoms (VAS < 3 cm), compared with scores at week 6 of treatment, with and without ERBHAL at the conclusion of the treatment. **A**: Without ERBHAL; **B**: With continuing ERBHAL. Shading indicates the minimal symptom score category. These changes were statistically not significant.

however, there are no reports of *L. casei* altering gastric emptying or small intestinal transit time. Alternatively, the effect may represent a more distal intestinal shift in the initial fermentation of lactulose. Formal radionuclide transit tests could address this issue in future studies, but the findings that ERBHAL represents SIBO in the majority of patients has been observed previously, along with the findings of reduction in functional gut symptoms, with the use of antibiotics and elemental diet[5,8,9,11].

The criteria used for the diagnosis of SIBO by the lactulose breath test have varied with different investigators. Much of the earlier work used bacterial cultures of the proximal small bowel as the gold standard[6,17]. However, such methodology is not helpful in detecting an increase in bacterial biofilm, if it occurs in the distal small bowel. The presence of findings such as a double peak in hydrogen production after lactulose, or high basal breath hydrogen are not well validated in patients with IBS, and are no longer considered appropriate diagnostic features. Glucose breath hydrogen test is useful for the detection of proximal bacterial overgrowth, but since glucose is readily absorbed in the proximal small intestine, SIBO occurring more distally is not detected[18]. The most consistent and accepted measure is the time of the first significant rise (usually $\geqslant$ 10 ppm) in breath hydrogen after lactulose, which therefore was applied in the present study.

No consistent effect of treatment with Yakult® was observed on abdominal symptoms or fatigue; some patients worsened whereas others improved. Three patients terminated the study early because of increasing nausea. All three complained of nausea at baseline and only one had previously been tested for lactose intolerance (that person was not lactose intolerant). However, regardless of whether these patients were lactose intolerant, it is unlikely that the small amount of lactose in 1 bottle of Yakult® (1 g) was the cause of these symptoms, given that up to 7 g of lactose in one sitting is well tolerated even in true lactose intolerant patients[19].

The loss of ERBHAL resulted in improvement in the overall abdominal symptom VAS score by at least 2 cm in 71% of the patients with moderate to severe baseline symptoms compared to 0% who maintained the early rise. However, one patient who lost ERBHAL developed more severe symptoms compared to the baseline findings. It cannot be expected that all patients will improve with the correction of ERBHAL, since only 35% improved symptomatically when ERBHAL was corrected with the use of antibiotics[9]. Previous studies on IBS have identified a particular ability of probiotics to improve bloating and wind[20-22]. While bloating did not improve with Yakult®, a significant improvement was seen in the passage of wind. A pathogenic link between the passage of wind, bacterial overgrowth and fermentation can be postulated. The present study was not designed to specifically address the effect on symptoms. However, our findings raise the possibility that symptomatic benefit can be obtained when ERBHAL is corrected with the use of Yakult®.

In conclusion, the hypothesis that treatment with Yakult® alters the fermentation pattern, exhibited by hydrogen breath testing after lactulose was supported in this uncontrolled, proof-of-concept study. A small dose of *L. casei* strain Shirota led to a statistically significant shift in the time of early rise of breath hydrogen after lactulose, suggesting a reduction in SIBO. Furthermore, the overall abdominal symptoms tended to improve when ERBHAL was corrected. Our findings suggest that probiotics may have a beneficial effect, but further work is required to determine the dose effects and clinical relevance with well powered, double blind, placebo-controlled trials including the measurement of transit time to support the interpretation of ERBHAL.

ACKNOWLEDGMENTS

JSB was in receipt of the Sir Robert Menzies Memorial Research Scholarship in Allied Health Sciences; RBG was supported by Pharmatel Fresenius Kabi IBD Fellowship and the New Zealand Society of Gastroenterology-Ferring Pharmaceuticals Fellowship; PMI was supported by a Fellowship from Nycomed.

COMMENTS

Background

Small intestinal bacterial overgrowth (SIBO) is a common feature of irritable bowel syndrome (IBS) and may be directly related to the genesis of IBS symptoms. An early rise in breath hydrogen after lactulose (ERBHAL) may indicate SIBO. The use of antibiotics and elemental diets has been shown to be effective in treating SIBO, but the efficacy of probiotics is untested.

Research frontiers

This was a pilot study designed to determine the effect of *Lactobacillus casei* strain Shirota (Yakult®) on the intestinal fermentation pattern in IBS, using the lactulose breath test. The results indicate that Yakult alters the fermentation pattern suggesting a reduction in SIBO. ERBHAL may also indicate rapid transit and therefore, in order to confirm the effect of Yakult on SIBO, future studies should include monitoring of transit time in addition to a placebo control group.

Innovations and breakthroughs

The most promising treatments to date for SIBO are antibiotics and elemental diets, the side effects and practicalities of which make them undesirable

options. This is the first study evaluating the effect of a probiotic on SIBO. The shift of the time of the first rise of hydrogen following lactulose indicating SIBO was no longer present at the end of 6 wk of treatment. These results offer a promising alternative treatment for SIBO in IBS. A placebo controlled trial is required to confirm these findings.

Applications

The results indicate that Yakult® may be an effective treatment for SIBO in IBS. Our findings have important implications in the treatment of IBS if these results are supported by a placebo controlled trial.

Peer review

The shift in fermentation patterns and the trend towards improvement of symptoms indicates the need for further work to examine the dose effects and clinical relevance with well powered, double blind, placebo controlled trials including the measurement of transit time to support the interpretation of ERBHAL. This is a well written paper with a nice literature review.

REFERENCES

1 **Markowitz MA**, Jhingran P, Asgharian A, Harris WA, Brod M, Wentz AL, Gordon SH, Carter E. IBS Prevalence: Results from a community based patient registry based on the Rome II criteria. *Am J Gastroenterol* 2000; **95**: 2634

2 **Balsari A**, Ceccarelli A, Dubini F, Fesce E, Poli G. The fecal microbial population in the irritable bowel syndrome. *Microbiologica* 1982; **5**: 185-194

3 **Kassinen A**, Krogius-Kurikka L, Makivuokko H, Rinttila T, Paulin L, Corander J, Malinen E, Apajalahti J, Palva A. The fecal microbiota of irritable bowel syndrome patients differs significantly from that of healthy subjects. *Gastroenterology* 2007; **133**: 24-33

4 **Lin HC**. Small intestinal bacterial overgrowth: a framework for understanding irritable bowel syndrome. *JAMA* 2004; **292**: 852-858

5 **Pimentel M**, Chow EJ, Lin HC. Eradication of small intestinal bacterial overgrowth reduces symptoms of irritable bowel syndrome. *Am J Gastroenterol* 2000; **95**: 3503-3506

6 **Riordan SM**, McIver CJ, Walker BM, Duncombe VM, Bolin TD, Thomas MC. The lactulose breath hydrogen test and small intestinal bacterial overgrowth. *Am J Gastroenterol* 1996; **91**: 1795-1803

7 **Vanner S**. The Small Intestinal Bacterial Overgrowth-Irritable Bowel Syndrome Hypothesis: Implications for Treatment. *Gut* 2008; **57**: 1315-1321

8 **Nucera G**, Gabrielli M, Lupascu A, Lauritano EC, Santoliquido A, Cremonini F, Cammarota G, Tondi P, Pola P, Gasbarrini G, Gasbarrini A. Abnormal breath tests to lactose, fructose and sorbitol in irritable bowel syndrome may be explained by small intestinal bacterial overgrowth. *Aliment Pharmacol Ther* 2005; **21**: 1391-1395

9 **Pimentel M**, Chow EJ, Lin HC. Normalization of lactulose breath testing correlates with symptom improvement in irritable bowel syndrome. a double-blind, randomized, placebo-controlled study. *Am J Gastroenterol* 2003; **98**: 412-419

10 **Dear KL**, Elia M, Hunter JO. Do interventions which reduce colonic bacterial fermentation improve symptoms of irritable bowel syndrome? *Dig Dis Sci* 2005; **50**: 758-766

11 **Pimentel M**, Constantino T, Kong Y, Bajwa M, Rezaei A, Park S. A 14-day elemental diet is highly effective in normalizing the lactulose breath test. *Dig Dis Sci* 2004; **49**: 73-77

12 **Camilleri M**. Treating irritable bowel syndrome: overview, perspective and future therapies. *Br J Pharmacol* 2004; **141**: 1237-1248

13 **Hunter JO**, Lee AJ, King TS, Barratt MEJ, Linggood MA, Blades JA. Enterococcus faecium strain PR88: An effective probiotic. *Gut* 1996; **38**: A62

14 **Gawronska A**, Dziechciarz P, Horvath A, Szajewska H. A randomized double-blind placebo-controlled trial of Lactobacillus GG for abdominal pain disorders in children. *Aliment Pharmacol Ther* 2007; **25**: 177-184

15 **Guyonnet D**, Chassany O, Ducrotte P, Picard C, Mouret M, Mercier CH, Matuchansky C. Effect of a fermented milk containing Bifidobacterium animalis DN-173 010 on the health-related quality of life and symptoms in irritable bowel syndrome in adults in primary care: a multicentre, randomized, double-blind, controlled trial. *Aliment Pharmacol Ther* 2007; **26**: 475-486

16 **Davis CE**. The effect of regression to the mean in epidemiologic and clinical studies. *Am J Epidemiol* 1976; **104**: 493-498

17 **Corazza GR**, Menozzi MG, Strocchi A, Rasciti L, Vaira D, Lecchini R, Avanzini P, Chezzi C, Gasbarrini G. The diagnosis of small bowel bacterial overgrowth. Reliability of jejunal culture and inadequacy of breath hydrogen testing. *Gastroenterology* 1990; **98**: 302-309

18 **Simren M**, Stotzer PO. Use and abuse of hydrogen breath tests. *Gut* 2006; **55**: 297-303

19 **Vesa TH**, Korpela RA, Sahi T. Tolerance to small amounts of lactose in lactose maldigesters. *Am J Clin Nutr* 1996; **64**: 197-201

20 **Kim HJ**, Vazquez Roque MI, Camilleri M, Stephens D, Burton DD, Baxter K, Thomforde G, Zinsmeister AR. A randomized controlled trial of a probiotic combination VSL# 3 and placebo in irritable bowel syndrome with bloating. *Neurogastroenterol Motil* 2005; **17**: 687-696

21 **Whorwell PJ**, Altringer L, Morel J, Bond Y, Charbonneau D, O'Mahony L, Kiely B, Shanahan F, Quigley EM. Efficacy of an encapsulated probiotic Bifidobacterium infantis 35624 in women with irritable bowel syndrome. *Am J Gastroenterol* 2006; **101**: 1581-1590

22 **Kim HJ**, Camilleri M, McKinzie S, Lempke MB, Burton DD, Thomforde GM, Zinsmeister AR. A randomized controlled trial of a probiotic, VSL#3, on gut transit and symptoms in diarrhoea-predominant irritable bowel syndrome. *Aliment Pharmacol Ther* 2003; **17**: 895-904

S- Editor Li DL **L- Editor** Anand BS **E- Editor** Lin YP

Online Submissions: wjg.wjgnet.com
wjg@wjgnet.com
doi:10.3748/wjg.14.5025

World J Gastroenterol 2008 August 28; 14(32): 5025-5031
World Journal of Gastroenterology ISSN 1007-9327
© 2008 The WJG Press. All rights reserved.

RAPID COMMUNICATION

Hepatocytes isolated from neoplastic liver-immunomagnetic purging as a new source for transplantation

Aravin Gunasegaram, Javed Akhter, Peng Yao, Loreena A Johnson, Stephen M Riodan, David L Morris

Aravin Gunasegaram, Javed Akhter, Peng Yao, Loreena A Johnson, David L Morris, University of New South Wales, Department of Surgery, St George Hospital, Sydney 2044, Australia
Stephen M Riodan, Gastrointestinal and Liver Unit, Prince of Wales Hospital, University of New South Wales, Sydney 2044, Australia
Author contributions: Gunasegaram A, Akhter J and Johnson LA contributed equally to this work; Akhter J and Morris DL designed research; Gunasegaram A, Akhter J and Johnson LA performed research; Gunasegaram A and Akhter J analysed data; Gunasegaram A, Akhter J, Yao P, Johnson LA and Riodan SM wrote the paper.
Correspondence to: David L Morris, Professor, Level 3 Pitney Building, St George Hospital, Kogarah 2217, New South Wales, Australia. david.morris@unsw.edu.au
Telephone: +61-2-93502070 Fax: +61-2-93503997
Received: February 1, 2008 Revised: August 8, 2008
Accepted: August 15, 2008
Published online: August 28, 2008

Abstract

AIM: To investigate whether hepatocytes isolated from macroscopically normal liver during hepatic resection for neoplasia could provide a novel source of healthy hepatocytes, including the development of reliable protocols for malignant cells removal from the hepatocyte preparation.
METHODS: Hepatocytes were procured from resected liver of 18 patients with liver tumors using optimised digestion and cell-enrichment protocols. Suspensions of various known quantities of the HT-29 tumor cell line and patient hepatocytes were treated or not with Ep-CAM-antibody-coated immunomagnetic beads in order to investigate the efficacy of tumor-purging by immunomagnetic depletion, using a semi-quantitative RT-PCR method developed to detect tumor cells. Immunomagnetic bead-treated or bead-untreated tumor cell-hepatocyte suspensions were transplanted intra-peritoneally in Balb/C nude mice to assess the rates of tumor development.
RESULTS: Mean viable hepatocyte yield was 9.3 x 10^6 cells per gram of digested liver with mean viability of 70.5%. Immunomagnetic depletion removed tumor cells to below the RT-PCR detection-threshold of 1 tumor cell in 10^6 hepatocytes, representing a maximum tumor purging efficacy of greater than 400000-fold. Transplanted, immunomagnetic bead-purged tumor cell-hepatocyte suspensions did not form peritoneal tumors in Balb/C nude mice. Co-transplantation of hepatocytes with tumor cells did not increase tumorigenesis of the tumor cells.
CONCLUSION: Immunomagnetic depletion appears to be an effective method of purging contaminating tumor cells to below threshold for likely tumorigenesis. Along with improved techniques for isolation of large numbers of viable hepatocytes, normal liver resected for neoplasia has potential as another clinically useful source of hepatocytes for transplantation.

© 2008 The WJG Press. All rights reserved.

Key words: Hepatocyte transplantation; Immunomagnetic purging; Isolation of hepatocytes

Peer reviewer: Ana J Coito, Associate Professor, Department of Surgery, The Dumont UCLA Transplant Center, 77-120 CHS BOX 90095-7054, Los Angeles 90095, United States

Gunasegaram A, Akhter J, Yao P, Johnson LA, Riodan SM, Morris DL. Hepatocytes isolated from neoplastic liver-immunomagnetic purging as a new source for transplantation. *World J Gastroenterol* 2008; 14(32): 5025-5031 Available from: URL: http://www.wjgnet.com/1007-9327/14/5025.asp DOI: http://dx.doi.org/10.3748/wjg.14.5025

INTRODUCTION

While advances in supportive medical care have improved survival, liver failure in its most severe form continues to carry a high mortality rate unless orthotopic liver transplantation (OLT) is performed. Nonetheless, there is a limit to the number of patients that can be treated in this way. The rapidity with which the clinical syndrome often progresses and a worldwide shortage of donor organs are significant limiting factors and many patients listed for OLT die or develop contraindications to transplantation before a donor liver becomes available. Further, the presence of co-morbidities in a substantial number of patients often precludes listing for OLT altogether. Consequently, there is considerable ongoing interest in the provision of other means of liver support, including extracorporeal artificial or bioartificial devices and hepatocyte transplantation (HT).

The feasibility of HT as a therapeutic tool has been demonstrated in studies performed in animals with liver-

based metabolic defects such as analbuminaemic and Gunn rats, hypercholesterolaemic rabbits and dogs with impaired purine metabolism[1-3]. Experience with HT in experimental animals with liver failure due to chemically-induced hepatic necrosis, surgical models of hepatic ischaemia or resection has also been favourable, with evidence of improved survival even when small numbers of cells (0.5% to 3% of normal hepatocyte mass) are used[4-7].

Transplantation of human hepatocytes has, to date, been performed in only a small number of paediatric and adult patients with liver failure[8-11]. Instances of mostly short-term improvement in encephalopathy and some metabolic parameters have been recorded both in OLT and non-OLT candidates. Potential advantages of HT over OLT include its minimal invasiveness, ease of treatment, substantially lower cost and the possibility of on-demand use following the establishment of a cell bank. Limited availability of primary human hepatocytes for transplantation however, represents a major limitation. Currently, the standard approach is to isolate hepatocytes from livers rejected for liver transplantation due to excessive steatosis, cirrhosis and prolonged ischemia. However, availability of hepatocytes from this source is in increasingly short supply and concerns with the functional capability of such cells have been raised[12].

Our group recently reported the feasibility of harvesting tumor-free hepatocytes from macroscopically normal liver unavoidably removed during hepatic resection for malignancy[13]. Here we report further improvements in our hepatocyte isolation and tumor-purging techniques, resulting in the harvest of sufficiently large numbers of viable hepatocytes from resected liver specimens to offer the prospect of effective clinical support and a high degree of tumor-purging efficacy. Furthermore, we demonstrate the safety of transplantation of hepatocytes harvested in this way, in terms of lack of complicating tumor development in an athymic mouse model.

MATERIALS AND METHODS

Hepatocyte isolation and cryopreservation

The human isolation study was approved by the South East Sydney Area Health Service Ethics Committee (approval No. 01/123). Hepatocytes were harvested from liver resection specimens of consenting patients undergoing partial hepatectomy for neoplasia. Patients with hepatocellular carcinoma were excluded. Patient demographic and disease details are outlined (Table 1). The bulk of specimens (61%) arose from livers with colorectal metastases.

Following resection, the specimen was transferred to a sterile table where the diseased portion of the liver was dissected with a 1cm margin, leaving the remaining macroscopically normal liver for hepatocyte harvest. The tissue was placed immediately into a sterile cooling solution (< 4℃) and 2-4 of the largest vessels were cannulated. Warm ischemic time, defined as clamping time of hepatic inflow and/or outflow during resection plus specimen processing time before being cooled, was recorded. Cannulae ranging from 0.95 mm to 2 mm diameter were suture-ligated around the respective vessels and capped with one-way valved bungs to prevent backflow. Histoacryl® (Braun, Germany) was used to seal most of the remaining liver surface, in addition to the cannula entry points. This was done to prevent leakage of perfusate and to maximize perfusion of the microcirculation during isolation, having been previously shown to increase hepatocyte yield and viability[14,15]. The specimen was then flushed with 500-1000 mL of heparinized (5000 units per litre) Custodiol® histidine-tryptophan-ketoglutarate (HTK) solution (Kohler Chemie, Germany)[16] to prevent obstruction of the hepatic microcirculation by thrombus and facilitate organ preservation. The specimen was then transported under sterile conditions to the laboratory where it was re-warmed and digested by a modified version of Seglen's original 2-step technique[17]. Cold ischemic time, defined as time that the specimen had been on ice prior to re-warming, was recorded. Pre-warmed (37℃) buffers were perfused in the following order: (1) Wash buffer-HBSS without Ca^{2+}/Mg^{2} (Gibco, Auckland, New Zealand) + 208.1 mg/L EDTA (Sigma, St Louis, MO, USA) + ascorbic acid 50 mg/L (Sigma, St Louis, MO, USA) + bovine serum albumin (BSA) (Sigma, St Louis, MO, USA) 0.5% w/v-10 min perfusion and then discarded. (2) EDTA washout-HBSS + BSA 0.5% w/v; 5 min perfusion and then discarded. (3) Digestion buffer-HBSS + 0.05% w/v Collagenase P (Roche, Germany) + 0.5% w/v BSA-re-circulated for 20-30 min.

Perfusion was carried out manually due to the varying size of the specimens (range, 55-690 g) at 20-40 mL/min per cannula depending on the weight of the specimen and cannula size. Digestion buffer was perfused until the specimen was soft and friable. A cell suspension was obtained by gentle mechanical dissociation of the digested specimen in 500 mL of ice-cold suspension buffer DMEM (Gibco, Auckland, New Zealand) + 10% (v/v) FCS (Gibco, Auckland, New Zealand) +

Table 1 Patient demographic, clinical and operative details

Parameters	*n*
Age (yr; mean ± SD, range)	59 ± 11 (33-78)
Male	10
Female	8
Primary tumor	
Colorectal cancer	12
Benign liver lesions	2
Renal carcinomas	1
Prostate carcinoma	1
Cholangiocarcinoma	1
Pseudopapillary pancreas tumor	1
Operation	
Right hemi-hepatectomy	7
Left hemi-hepatectomy	4
Extended right hemi-hepatectomy	2
Right lateral sectorectomy	2
Extended left hemi-hepatectomy	1
Left lateral sectorectomy	1
Non-anatomic resection	1

1% antibiotic-antimycotic Penicillin 10 000 units/mL + streptomycin 25μg/mL + amphotericin B as Fungizone® (Gibco, Auckland, New Zealand) and sequentially filtered through three sterile stainless steel filters of decreasing pore size (425 μm, 150 μm and 75 μm) (Endecotts, UK). The raw fraction was pelleted by centrifugation at 50 *g* for 3 min at 4℃ and washed three times in the suspension buffer. Cells were counted in quadruplicate and viability assessed by Trypan blue exclusion, using a hemocytometer (Neubauer, Germany). Cells were cryopreserved in suspension medium containing 10% DMSO in 5-mL tubes by freezing to -80℃ in 1℃ decrements per minute and then transferred to liquid nitrogen after 24 h.

Hepatocyte spiking & purging

In vitro and *in vivo* studies were performed using suspensions of isolated human hepatocytes spiked with various numbers of HT-29 human colorectal cell-line tumor cells and then treated or not with immunomagnetic beads (CELLection® Epithelial Enrich; Dynal AS, Oslo, Norway), in the method described by Kielhorn *et al*[18] and Flatmark *et al*[19]. Specifically, we used 4.5 μm magnetic beads coated with mouse IgG1 Ber-EP4 antibody against Ep-CAM, an antigen highly expressed on colorectal cancer (CRC) cells (including HT-29 tumor cells), but not on mature hepatocytes[20].

In vitro hepatocyte and HT-29 cell-line preparation

Cryopreserved human hepatocytes were thawed in a 37℃ water bath, diluted in suspension medium, pelleted by centrifuging at 50 *g* for 3 min at 4℃ and re-suspended in suspension medium. Density gradient centrifugation was performed to purify the thawed hepatocytes. The suspension was then mixed with a Percoll® (Amersham Biosciences, Uppsala, Sweden) density gradient (25% final concentration) medium and centrifuged at 75 *g* for 5 min at 4℃ to separate viable from dead hepatocytes. Pellets were re-suspended in PBS with 0.1% BSA and placed on ice. Cells were counted in quadruplicate, using a hemocytometer (Neubauer, Germany), and their viability assessed by Trypan blue exclusion. HT-29 cells grown in 75 cm^2 culture flasks (Greiner Bio-One, Germany) in 95% O_2 and 5% CO_2 at 37℃ were trypsinised, washed in PBS (Invitrogen, Auckland, New Zealand), pelleted by centrifugation at 75 *g* for 5 min, re-suspended in PBS and counted as above.

Determination of RT-PCR sensitivity for tumor cell detection

One, 10, 50, 100, 1000, 5000 or 10 000 HT-29 cells were added to suspensions of 1 million human hepatocytes to establish the lower limit of detection of tumor cells by RT-PCR. Suspensions of 1 million HT-29 cells alone and 1 million hepatocytes alone served as positive and negative controls respectively.

Total RNA was extracted using TRIzol® reagent (15596026, Invitrogen) as per the manufacturer's instructions. Following DNase I treatment (18068-015, Invitrogen), the total RNA concentration and quantity was assessed by spectrophotometry at 260 nm and the RNA stored at -80℃.

RT-PCR

cDNA was synthesized from total RNA using One-Step SuperScript Ⅲ® system (12574-026, Invitrogen) with target specific primers as per the manufacturer's instructions. EpCAM primers were as published by Sakaguchi *et al*[21] with actin housekeeping primers as follows; antisense 5'-GGAGCAATGATCTTGATCTT-3'; sense 5'-CTTCCTGGGCATGGAGTCCT-3'. The RT-PCR program was as follows; cycle one, 56℃, 30 min, 94℃ for 3 min, followed by 40 cycles of 30 s at 94℃ , 30 s at 60℃, 30 s at 72℃, with a final extension for 10 min at 72℃. The cDNA products were visualized on a 1% agarose gel, and sequenced to confirm product identity.

Immunomagnetic bead treatment of spiked hepatocytes

Five mL suspensions of 1×10^6 hepatocytes spiked with 1000, 10 000 and 50 000 HT-29 cells per mL were prepared in duplicate. Immunomagnetic beads (CELLection® Epithelial Enrich; Dynal AS; 4×10^8 beads/mL), were washed in PBS + 0.1% (w/v) BSA, and added to half the tubes in the ratio of 20 beads to 1 HT-29 cell. The remaining preparations constituted controls and contained no immunomagnetic beads. All tubes were placed in a rotator (15 r/min) at 4℃ for 30 min, to allow maximal tumor cell-bead contact and capture. Treated tubes were placed in the magnetic particle concentrator provided by the manufacturer for 2 min, the supernatant transferred to new tubes and the process repeated. One mL from each sample was collected after treatment for RT-PCR analysis to assess the efficacy of immunomagnetic bead-mediated tumor-purging.

In vivo study

Male Balb/C athymic nude mice (Animal Resource Centre, Perth, WA, Australia) were housed and fed under specific pathogen-free conditions according to study protocols approved by the Animal Care & Ethics Committee of UNSW (approval No. 02/103). The athymic mouse was chosen due to its minimal cellular immunity, so as to minimize risk of rejection of human hepatocytes and facilitate tumor engraftment. The main aims were to study (a) the tumor load required for tumorigenesis following intraperitoneal transplantation, (b) the effect of co-transplantation of human hepatocytes on tumorigenesis and (c) the effect of our immunomagnetic purging protocol on tumorigenesis. The experimental protocol is described below in Table 2.

Hepatocytes and HT-29 cells were prepared as per the *in vitro* arm, separately and in combination to produce suspensions containing the cell numbers required per mL PBS (cf Table 2). Two hundred μL samples, containing 20% of the cell number in each 1 mL inoculation, were collected for negative control,

Table 2 Mice & cell transplantation details

Treatment groups	Mouse group	IP injection	No. of mice
Negative control (Hepatocyte only)	1	5 x 10^6 hepatocytes	3
Positive control 1 (HT-29 only)	2	5000 HT-29 cells	3
	3	100 000 HT-29 cells	3
	4	500 000 HT-29 cells	3
	5	2 million HT-29 cells	3
Positive control 2 (Hepatocytes + HT-29)	6	5 million hepatocytes + 5000 HT-29	3
	7	5 million hepatocytes + 100 000 HT-29	3
	8	5 million hepatocytes + 500 000 HT-29	3
	9	5 million hepatocytes + 2 million HT-29	3
Bead (Hepatocyte + HT-29)	10	5 million hepatocytes + 5000 HT-29	3
	11	5 million hepatocytes + 100 000 HT-29	3
	12	5 million hepatocytes + 500 000 HT-29	3
	13	5 million hepatocytes + 2 million HT-29	3

Table 3 Tumor growth

Treatment groups	IP injection	Mouse with tumour	Percentage expression (%)
Negative control (Hepatocyte only)	5 x 10^6 hepatocytes	0/3	0
Positive control 1 (HT-29 only)	5000 HT-29 cells	0/3	0
	100 000 HT-29 cells	1/3[1]	0[1]
	500 000 HT-29 cells	*2/3*	*67*
	2 million HT-29 cells	*3/3*	*100*
Positive control 2 (Hepatocytes + HT-29)	5 million hepatocytes + 5000 HT-29	0/3	0
	5 million hepatocytes + 100 000 HT-29	0/3	0
	5 million hepatocytes + 500 000 HT-29	*3/3*	*100*
	5 million hepatocytes + 2 million HT-29	*2/3*	*67*
Bead (Hepatocyte + HT-29)	5 million hepatocytes + 5000 HT-29	0/3	0
	5 million hepatocytes + 100 000 HT-29	0/3	0
	5 million hepatocytes + 500 000 HT-29	0/3	0
	5 million hepatocytes + 2 million HT-29	0/3	0

[1]Injection-site tumor in skin only; In italics: Groups in which tumor was found; In standard form: Tumor-free.

positive control and immunomagnetic bead groups, before and after purging for RT-PCR analysis.

Mice were monitored for 28 d post-transplantation after which they were sacrificed with a lethal 6 mg dose of pentobarbital sodium. The abdomen, pelvis and thorax were examined visually for the presence of tumor.

RESULTS

Isolation of hepatocytes

The total viable hepatocyte yield averaged at 9.3 × 10^8 cells per isolation (range 2.0 × 10-36.3 × 10^8; mean ± SD viable hepatocyte yield 9.33 × 10^6 ± 6.0 × 10^6 cells/g digested liver tissue), with the five most recent isolations each yielding over 1.0 × 10^9 cells. The mean viability of freshly isolated hepatocytes was 70.5% ± 8.1%. Mean warm ischemic time was 31 ± 19 min (range, 25-60 min); mean cold ischemic time was 1.5 ± 0.6 h (range, 0.5-16 h).

Tumorigenesis of transplanted hepatocyte and tumor cell suspensions

RT-PCR analysis demonstrated clear single bands at the 515 bp position, indicating Ep-CAM detection, in representative samples of all hepatocyte/HT-29 cell suspensions transplanted into mice belonging to Positive Control 2 and pre-treatment Bead groups. No detectable bands were seen in the samples transplanted into the Negative Control and post-treatment Bead groups (gel images not shown), indicating in the latter case the removal of Ep-CAM positive cells (including HT-29 cells) to below the detection limit of 1 tumor cell in 1 million hepatocytes (Figure 1) and thus, a maximum tumor purging efficacy of immunomagnetic bead treatment of at least 400 000 fold (Figure 2).

In the control groups, all mice injected with 100 000 HT-29 cells and below showed no tumor, except for one animal inoculated with 100 000 HT-29 cells only. The mouse developed a small (0.1 g) skin nodule at the injection site and had no evidence of intra-abdominal tumor on detailed examination. This is probably due to an inadvertent subcutaneous rather than intraperitoneal injection of cells, and could thus be excluded on the basis of technical error. All except two mice inoculated with at least 500 000 HT-29 cells (83%) developed tumor. There was no significant difference in tumor expression between mice injected with or without hepatocytes (Tables 2 and 3). These results would suggest that the minimum tumor load required for engraftment and growth was between 100 000 and 500 000.

There was a complete absence of tumor development in any mouse injected with HT-29 cell-spiked hepatocyte

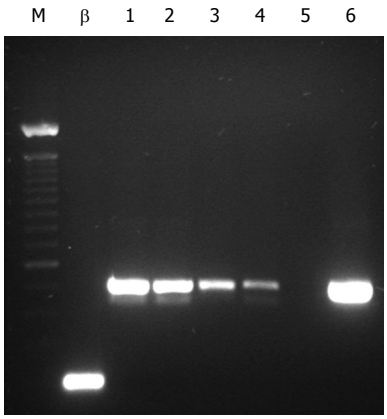

Figure 1 Detection sensitivity. RT-PCR detection of HT-29 cells in 1 x 10^6 hepatocytes. Lane M: 100 bp ladder (100 bp to 1 kb); Lane β: β-actin; Lane 1: 100 HT-29 cells; Lane 2: 10 HT-29 cells; Lane 3: 5 HT-29 cells; Lane 4: 1 HT-29 cell; Lane 5: Hepatocytes only; Lane 6: HT29 only.

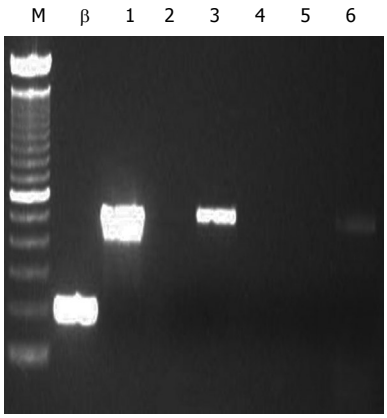

Figure 2 Tumor-purging efficacy. RT-PCR detection of EpCAM RNA in HT-29-cell-spiked hepatocytes (1 x 10^6) with and without treatment with Ber-EP4-coated immunomagnetic beads. Lane M: 100 bp ladder (100 bp to 1 kb); Lane β: β-actin; Lane 1: 50 000 HT-29 cells; Lane 2: 50 000 HT-29 cells treated with immunomagnetic beads; Lane 3: 10 000 HT-29 cells; Lane 4: 10 000 HT-29 cells treated with immunomagnetic beads; Lane 5: 10 HT-29 cells treated with immunomagnetic beads; Lane 6: 10 HT-29 cells only.

suspensions treated with immunomagnetic beads. All mice survived until day 28 without any significant weight loss/gain or signs of malaise or distress. Where intraperitoneal tumors occurred, these were seen only intra-abdominally, expressed as distinct, scirrhous, white nodules adherent to the parietal or visceral peritoneum, without evidence of metastasis.

DISCUSSION

Our results show that clinically relevant numbers of hepatocytes can be recovered from macroscopically normal liver unavoidably removed during hepatic resection for neoplasia. Further, when isolated and subjected to an immunomagnetic cell separation technique, the resulting hepatocytes can be safely transplanted intra-peritoneally in athymic mice without increased risk of development of tumor. Only patients requiring anatomical resection were included in this study. Our technique may be less useful in the case of patients undergoing small, non-anatomical resection; in this situation the viable hepatocyte yield would be less.

Our mean viable yield of 9.33×10^6/g is a significant improvement from our preliminary study[13] and marginally exceeds that reported by Richert *et al*[22]. To achieve this, the original isolation protocol was altered to include sealing of cannula points and cut surfaces prior to perfusion and ensure a cold ischemic time of less than 5 h; both of these changes have been independently identified to positively influence viable yield[22,23].

The number of hepatocytes transplanted in clinical experiences to date has ranged between 2×10^8 to 4×10^9 cells[24]. Given a mean viable yield of 9.3×10^8 cells per isolation, our technique offers the possibility of one hepatocyte transplant for every hepatocyte isolation. In the order of 80-100 liver resections are performed annually in our unit, of which approximately half will be suitable for hepatocyte isolation. Thus, a minimum of forty hepatocyte transplants could potentially be performed annually.

A comparison of viable hepatocytes yield from resection specimens versus cells obtained from explanted organs rejected for OLT shows that the resected specimens have a consistently higher viable yield[22]. Further, recovery from cryopreservation of hepatocytes derived from normal resected liver is significantly higher compared to that of cells obtained from organs rejected for liver transplantation[25], thus improving the potential quality and quantity of bankable cells for use on-demand. Such factors, combined with the opportunity to utilize a hitherto untapped hepatocyte source, further enhance the potential application of hepatocyte transplantation as a clinically relevant treatment modality.

An important concern regarding the use of hepatocytes isolated from liver resections performed for malignancy has been the possibility of co-transplanting contaminating tumor cells. Although immunomagnetic cell separation has been widely utilized to enhance detection of tumor cells in different body compartments, purging has been mainly limited to *ex vivo* removal of tumor cells from autologous stem cell transplants[18,19,26,27]. To our knowledge, our centre is the first to propose immunomagnetic purging of any residual, contaminating tumor cells from isolated hepatocyte suspensions.

The Ep-CAM cell-surface antigen is consistently present on both HT-29 colorectal cancer cells and most colorectal metastases[28], the pathology in the majority of our liver resection specimens in this study. The antigen is not expressed by mature hepatocytes[20] making differential separation of Ep-CAM-expressing tumor cells by immunomagnetic beads (coated with Ber-EP4) possible. Various other carcinomas, including all the types from our patient cohort, also express Ep-CAM[29]. As Ep-CAM has been shown consistently to be absent in hepatocellular carcinoma, patients with such tumors, along with other Ep-CAM-negative lesions, were excluded from our study to avoid undetectable tumor contamination. Whilst hepatocytes were harvested only from patients whose tumors expressed Ep-CAM in this

study, the targeting of additional molecular markers such as CK-20 and CEA enhanced detection of any potential tumour cells without an Ep-CAM phenotype[30,31]. Additional surface antigens are currently being studied to potentially increase the tumor-purging efficacy by multiplying the number of target molecules per cell.

In our study, immunomagnetic purging was shown to remove tumor cells by a factor greater than 400 000. This compares favorably with similar large-scale experiments involving breast cancer cells in blood stem cell harvests[32]. It also represents a substantial improvement on our preliminary experience[13], attributable to optimization of the sample purging treatment and bead to cell ratio employed. The development of an RT-PCR detection assay, in addition to standard immunohistochemical methods, has enabled a more efficient and sensitive detection of tumor contamination (1 tumor cell per 1 million hepatocytes) enabling confidence that in a typical human hepatocyte transplant of 1 billion cells, a maximum tumor load of no more than 1000 cells could be present in the preparation. This is significantly below the 100 000-500 000 cell threshold for tumor engraftment and growth demonstrated in our athymic mouse model in this study. Further, no additional growth potential was conferred to tumor cells by the co-transplantation of hepatocytes, an important observation that indicates that the presence of hepatocytes does not magnify the risk of tumor cell engraftment.

We have demonstrated that with the use of an optimized cell-isolation protocol, liver resection specimens obtained from patients undergoing resection for neoplasia can offer sufficient viable hepatocytes to potentially provide clinically-relevant liver support. We have further shown both *in vitro* and in a suitable *in vivo* animal model that immunomagnetic purging can confer safety from the potential of tumor contamination of hepatocyte suspensions. We therefore propose that liver resection specimens, by a simple purging step, may provide a safe, alternative hepatocyte source for clinical transplantation.

COMMENTS

Background

With a world wide shortage of liver donor organs, adjunct treatment regimes to support patients to orthotopic liver transplantation (OLT) or to replace when OLT is contra-indicated are becoming increasingly important. Hepatocyte transplantation is one such, however, a major limitation to its clinical application is the availability of primary human hepatocytes. Hepatocytes isolated from macroscopically normal liver removed during hepatic resection for neoplasia could provide an additional source of hepatocytes, given the development of strategies to detect and remove residual malignant cells.

Research frontiers

The liver margins of neoplasia patients, an increasingly common procedure, are normally discarded. The aim was to discover whether clinically relevant numbers of healthy hepatocytes could be recovered from these waste pieces and used for transplantation, thereby adding another source to the traditional sources of hepatocytes.

Innovations and breakthroughs

It was found that clinically relevant numbers of hepatocytes can be recovered from macroscopically normal liver removed during neoplasia hepatic resection. A protocol based on current immunomagnetic bead technology was developed to capture and remove cancerous cells from hepatocytes in concert with a novel RT-PCR assay for detection of the tumour cells.

Applications

An additional source of hepatocytes for transplantation boosts both ongoing research into the efficacy of hepatocyte transplantation and clinically, increases the number of treatable patients. Additionally, hepatocytes prepared correctly can be stored until required, divided amongst multiple patients, or combined with hepatocytes from other donors, increasing further the number of patients that can be treated.

Peer review

The authors evaluated the efficacy of Ep-CAM-antibody-coated magnetic beads in tumor cell removal from hepatocyte suspensions. This is an interesting work that normal liver resected for neoplasia may be potential as another clinically useful source of hepatocytes for transplantation.

REFERENCES

1 **Eguchi S**, Rozga J, Lebow LT, Chen SC, Wang CC, Rosenthal R, Fogli L, Hewitt WR, Middleton Y, Demetriou AA. Treatment of hypercholesterolemia in the Watanabe rabbit using allogeneic hepatocellular transplantation under a regeneration stimulus. *Transplantation* 1996; **62**: 588-593

2 **Moscioni AD**, Rozga J, Chen S, Naim A, Scott HS, Demetriou AA. Long-term correction of albumin levels in the Nagase analbuminemic rat: repopulation of the liver by transplanted normal hepatocytes under a regeneration response. *Cell Transplant* 1996; **5**: 499-503

3 **Kocken JM**, Borel Rinkes IH, Bijma AM, de Roos WK, Bouwman E, Terpstra OT, Sinaasappel M. Correction of an inborn error of metabolism by intraportal hepatocyte transplantation in a dog model. *Transplantation* 1996; **62**: 358-364

4 **Vogels BA**, Maas MA, Bosma A, Chamuleau RA. Significant improvement of survival by intrasplenic hepatocyte transplantation in totally hepatectomized rats. *Cell Transplant* 1996; **5**: 369-378

5 **Sutherland DE**, Numata M, Matas AJ, Simmons RL, Najarian JS. Hepatocellular transplantation in acute liver failure. *Surgery* 1977; **82**: 124-132

6 **Sommer BG**, Sutherland DE, Matas AJ, Simmons RL, Najarian JS. Hepatocellular transplantation for treatment of D-galactosamine-induced acute liver failure in rats. *Transplant Proc* 1979; **11**: 578-584

7 **Eguchi S**, Lilja H, Hewitt WR, Middleton Y, Demetriou AA, Rozga J. Loss and recovery of liver regeneration in rats with fulminant hepatic failure. *J Surg Res* 1997; **72**: 112-122

8 **Bilir BM**, Guinette D, Karrer F, Kumpe DA, Krysl J, Stephens J, McGavran L, Ostrowska A, Durham J. Hepatocyte transplantation in acute liver failure. *Liver Transpl* 2000; **6**: 32-40

9 **Habibullah CM**, Syed IH, Qamar A, Taher-Uz Z. Human fetal hepatocyte transplantation in patients with fulminant hepatic failure. *Transplantation* 1994; **58**: 951-952

10 **Strom SC**, Fisher RA, Thompson MT, Sanyal AJ, Cole PE, Ham JM, Posner MP. Hepatocyte transplantation as a bridge to orthotopic liver transplantation in terminal liver failure. *Transplantation* 1997; **63**: 559-569

11 **Strom SC**, Chowdhury JR, Fox IJ. Hepatocyte transplantation for the treatment of human disease. *Semin Liver Dis* 1999; **19**: 39-48

12 **Baccarani U**, Sanna A, Cariani A, Sainz-Barriga M, Adani GL, Zambito AM, Piccolo G, Risaliti A, Nanni-Costa A, Ridolfi L, Scalamogna M, Bresadola F, Donini A. Isolation of human hepatocytes from livers rejected for liver transplantation on a national basis: results of a 2-year experience. *Liver Transpl* 2003; **9**: 506-512

13 **Haghighi KS**, Woon WW, Akhter J, Marr PJ, Bolton E, Riordan S, Morris DL. A new source of hepatocytes for transplantation. *Transplant Proc* 2004; **36**: 2466-2468

14 **Mitry RR**, Hughes RD, Aw MM, Terry C, Mieli-Vergani G, Girlanda R, Muiesan P, Rela M, Heaton ND, Dhawan

A. Human hepatocyte isolation and relationship of cell viability to early graft function. *Cell Transplant* 2003; **12**: 69-74

15 **Alexandre E**, Cahn M, Abadie-Viollon C, Meyer N, Heyd B, Mantion G, Cinqualbre J, David P, Jaeck D, Richert L. Influence of pre-, intra- and post-operative parameters of donor liver on the outcome of isolated human hepatocytes. *Cell Tissue Bank* 2002; **3**: 223-233

16 **Ringe B**, Braun F, Moritz M, Zeldin G, Soriano H, Meyers W. Safety and efficacy of living donor liver preservation with HTK solution. *Transplant Proc* 2005; **37**: 316-319

17 **Seglen PO**. Preparation of rat liver cells. I. Effect of Ca 2+ on enzymatic dispersion of isolated, perfused liver. *Exp Cell Res* 1972; **74**: 450-454

18 **Kielhorn E**, Schofield K, Rimm DL. Use of magnetic enrichment for detection of carcinoma cells in fluid specimens. *Cancer* 2002; **94**: 205-211

19 **Flatmark K**, Bjornland K, Johannessen HO, Hegstad E, Rosales R, Harklau L, Solhaug JH, Faye RS, Soreide O, Fodstad O. Immunomagnetic detection of micrometastatic cells in bone marrow of colorectal cancer patients. *Clin Cancer Res* 2002; **8**: 444-449

20 **de Boer CJ**, van Krieken JH, Janssen-van Rhijn CM, Litvinov SV. Expression of Ep-CAM in normal, regenerating, metaplastic, and neoplastic liver. *J Pathol* 1999; **188**: 201-206

21 **Sakaguchi M**, Virmani AK, Ashfaq R, Rogers TE, Rathi A, Liu Y, Kodagoda D, Cunningham HT, Gazdar AF. Development of a sensitive, specific reverse transcriptase polymerase chain reaction-based assay for epithelial tumour cells in effusions. *Br J Cancer* 1999; **79**: 416-422

22 **Richert L**, Alexandre E, Lloyd T, Orr S, Viollon-Abadie C, Patel R, Kingston S, Berry D, Dennison A, Heyd B, Mantion G, Jaeck D. Tissue collection, transport and isolation procedures required to optimize human hepatocyte isolation from waste liver surgical resections. A multilaboratory study. *Liver Int* 2004; **24**: 371-378

23 **LeCluyse EL**, Alexandre E, Hamilton GA, Viollon-Abadie C, Coon DJ, Jolley S, Richert L. Isolation and culture of primary human hepatocytes. *Methods Mol Biol* 2005; **290**: 207-229

24 **Fox IJ**, Chowdhury JR. Hepatocyte transplantation. *Am J Transplant* 2004; **4** Suppl 6: 7-13

25 **Terry C**, Mitry RR, Lehec SC, Muiesan P, Rela M, Heaton ND, Hughes RD, Dhawan A. The effects of cryopreservation on human hepatocytes obtained from different sources of liver tissue. *Cell Transplant* 2005; **14**: 585-594

26 **Zborowski M**, Chalmers JJ. Magnetic cell sorting. *Methods Mol Biol* 2005; **295**: 291-300

27 **Pedrazzoli P**, Lanza A, Battaglia M, Da Prada GA, Zambelli A, Perotti C, Ponchio L, Salvaneschi L, Robustelli della Cuna G. Negative immunomagnetic purging of peripheral blood stem cell harvests from breast carcinoma patients reduces tumor cell contamination while not affecting hematopoietic recovery. *Cancer* 2000; **88**: 2758-2765

28 **Shetye J**, Frodin JE, Christensson B, Grant C, Jacobsson B, Sundelius S, Sylven M, Biberfeld P, Mellstedt H. Immunohistochemical monitoring of metastatic colorectal carcinoma in patients treated with monoclonal antibodies (MAb 17-1A). *Cancer Immunol Immunother* 1988; **27**: 154-162

29 **Balzar M**, Winter MJ, de Boer CJ, Litvinov SV. The biology of the 17-1A antigen (Ep-CAM). *J Mol Med* 1999; **77**: 699-712

30 **Chausovsky G**, Luchansky M, Figer A, Shapira J, Gottfried M, Novis B, Bogelman G, Zemer R, Zimlichman S, Klein A. Expression of cytokeratin 20 in the blood of patients with disseminated carcinoma of the pancreas, colon, stomach, and lung. *Cancer* 1999; **86**: 2398-2405

31 **Martin-Henao GA**, Picon M, Limon A, Carmona M, Amill B, Azqueta C, Lopez R, Gonzalez-Barca E, Granena A, Brunet S, Garcia J. Immunomagnetic bone marrow (BM) and peripheral blood progenitor cell (PBPC) purging in follicular lymphoma (FL). *Bone Marrow Transplant* 1999; **23**: 579-587

32 **Tyer CL**, Vredenburgh JJ, Heimer M, Peters WP, Bast RC Jr. Breast cancer cells are effectively purged from peripheral blood progenitor cells with an immunomagnetic technique. *Clin Cancer Res* 1996; **2**: 81-86

S- Editor Zhong XY **L- Editor** Li M **E- Editor** Lin YP

Online Submissions: wjg.wjgnet.com
wjg@wjgnet.com
doi:10.3748/wjg.14.5032

World J Gastroenterol 2008 August 28; 14(32): 5032-5038
World Journal of Gastroenterology ISSN 1007-9327
© 2008 The WJG Press. All rights reserved.

RAPID COMMUNICATION

Differentiation of malignant and benign proximal bile duct strictures: The diagnostic dilemma

Jaap Jacob Kloek, Otto Marinus van Delden, Deha Erdogan, Fibo Jan ten Kate, Erik Anthoni Rauws, Olivier Robert Busch, Dirk Joan Gouma, Thomas Mathijs van Gulik

Jaap Jacob Kloek, Deha Erdogan, Olivier Robert Busch, Dirk Joan Gouma, Thomas Mathijs van Gulik, Department of Surgery, Academic Medical Center, University of Amsterdam, Amsterdam 1100 DE, Netherlands
Otto Marinus van Delden, Department of Radiology, Academic Medical Center, University of Amsterdam, Amsterdam 1100 DE, Netherlands
Fibo Jan ten Kate, Department of Pathology, Academic Medical Center, University of Amsterdam, Amsterdam 1100 DE, Netherlands
Erik Anthoni Rauws, Department of Gastroenterology, Academic Medical Centre, University of Amsterdam, Amsterdam 1100 DE, Netherlands
Author contributions: Kloek JJ, van Delden OM, Erdogan D, Rauws EA, ten Kate FJ, Busch OR, Gouma DJ and van Gulik TM designed the research; Kloek JJ, van Delden OM, ten Kate FJ, Rauws EA, Busch OR, Gouma DJ performed research; Kloek JJ, van Delden OM and Erdogan D, and van Gulik TM analyzed the data; and Kloek JJ, van Delden OM, Erdogan D, and van Gulik TM wrote the paper.
Correspondence to: Thomas Mathijs van Gulik, MD, Department of Surgery, Academic Medical Center, University of Amsterdam, Amsterdam 1100 DE, Netherlands. t.m.vangulik@amc.uva.nl
Telephone: +31-20-5665572 Fax: +31-20-6976621
Received: May 20, 2008 Revised: June 30, 2008
Accepted: July 6, 2008
Published online: August 28, 2008

Abstract

AIM: To identify the criteria for the differentiation of hilar cholangiocarcinoma (HCCA) from benign strictures.
METHODS: A total of 68 patients underwent resection of lesions suspicious for HCCA between 1998 and 2006. The results of laboratory investigations, imaging studies and brush cytology were collected. These findings were analyzed to obtain the final diagnosis.
RESULTS: Histological examination of the resected specimens confirmed HCCA in 58 patients (85%, group Ⅰ) whereas 10 patients (15%, group Ⅱ) were diagnosed to have benign strictures. The most common presenting symptom was obstructive jaundice in 77% patients (79% group Ⅰ *vs* 60% group Ⅱ, P = 0.23). Laboratory findings showed greater elevation of transaminase levels in group Ⅰ compared to group Ⅱ. The various imaging modalities showed vascular involvement exclusively in the malignant group (36%, $P < 0.05$). Brush cytology was positive for malignant cells in only 50% patients in group Ⅰ whereas none in group Ⅱ showed malignant cells.
CONCLUSION: Despite improvements in imaging techniques, 10 patients (15%) with a presumptive diagnosis of HCCA were ultimately found to have benign strictures. Except for vascular involvement which was associated significantly with malignancy, there were no conclusive features of malignancy on regular imaging modalities. This uncertainty should be taken into account when patients with a suspicious lesion at the liver hilum are considered for resection.

© 2008 The WJG Press. All rights reserved.

Key words: Biliary stricture; Hilar cholangiocarcinoma; Benign; Radiological; Vascular involvement

Peer reviewer: Georgios Papachristou, MD, Assistant Professor of Medicine, Division of Gastroenterology, UPMC Presbyterian, 200 Lothrop Street, Pittsburgh PA 15213, United States

Kloek JJ, van Delden OM, Erdogan D, ten Kate FJ, Rauws EA, Busch OR, Gouma DJ, van Gulik TM. Differentiation of malignant and benign proximal bile duct strictures: The diagnostic dilemma. *World J Gastroenterol* 2008; 14(32): 5032-5038 Available from: URL: http://www.wjgnet.com/1007-9327/14/5032.asp DOI: http://dx.doi.org/10.3748/wjg.14.5032

INTRODUCTION

Hilar resection en bloc with liver resection is the only curative treatment option for patients with carcinoma at the hepatic duct confluence. Although mortality rates associated with partial hepatectomy have decreased markedly in the past decades, postoperative morbidity is considerable and can exceed 50 percent[1-4]. Undertaking partial hepatectomy for hilar cholangiocarcinoma (HCCA) becomes even more a subject of discussion when histopathology of the resected specimen shows benign disease. A variety of benign lesions at the liver hilum can mimic malignancy. In particular, inflammatory lesions may present with the same clinical and radiological features as a malignant tumor.

In the past decade, imaging techniques have improved and the diagnostic work-up of patients suspected of HCCA usually comprised of ultra-sonography (US), contrast enhanced multi-slice computed tomography (CT) and magnetic resonance cholangiography (MRC). In experienced hands, colour Doppler US is very useful in assessing proximal biliary extension of the tumor and vascular invasion, but has limited value in distinguishing HCCA from inflammatory lesions[5]. Contrast enhanced CT and MR imaging (MRI) provide important information regarding resectability and vascular involvement[6-8]. Furthermore, these cross-sectional imaging modalities are accurate in detecting a tumor mass and signs of lymphadenopathy, although both features may also be present in benign diseases. Cholangiography in combination with brush cytology has a low sensitivity, and although the specificity is higher, it is not 100% since longstanding stenting of the biliary duct may give rise to false positive cytology results[9]. Overall, an extensive work-up with multiple imaging techniques may improve the differentiation between malignant and benign proximal bile duct strictures.

Several studies have noted that approximately 14% to 25% of patients resected for presumed HCCA prove to have a benign lesion at histopathology[10-14]. A recent study attempted to identify potential criteria for distinguishing patients with HCCA from those with an alternative diagnosis[15]. However, the non-HCCA patients in this series comprised of benign and malignant diseases (for instance gallbladder cancer), which makes any conclusions difficult to interpret. In a previous series of 132 patients who had undergone surgical treatment for suspicious HCCA at our center from 1983 to 1998, 15% (20/132) of the patients had benign lesions[16]. In the present study, which covers a more recent period during which improved imaging techniques were used, the rate of mis-diagnosed benign lesions was re-examined and the diagnostic features of benign and malignant lesions was compared. The aim of the study was to identify criteria that can differentiate HCCA from benign proximal bile duct strictures.

MATERIALS AND METHODS

Between January 1998 and December 2006, a total of 143 patients underwent a diagnostic laparoscopy for staging of HCCA, and 13 patients underwent laparotomy without diagnostic laparoscopy. Unresectable disease was found in 36 patients undergoing laparoscopy, and in the majority of these cases the diagnosis was confirmed by histology (Figure 1). Another 52 patients were found to have unresectable disease during subsequent laparotomy which was confirmed by histology. Finally, 68 consecutive patients underwent resection and are the subject of the present study (Figure 1). These patients had hilar resection with complete lymphadenectomy of the hepato-duodenal ligament usually en bloc with (extended) hemi-hepatectomy including resection of the caudate lobe and left or right portal vein[17]. Although in the majority of the patients included in the study,

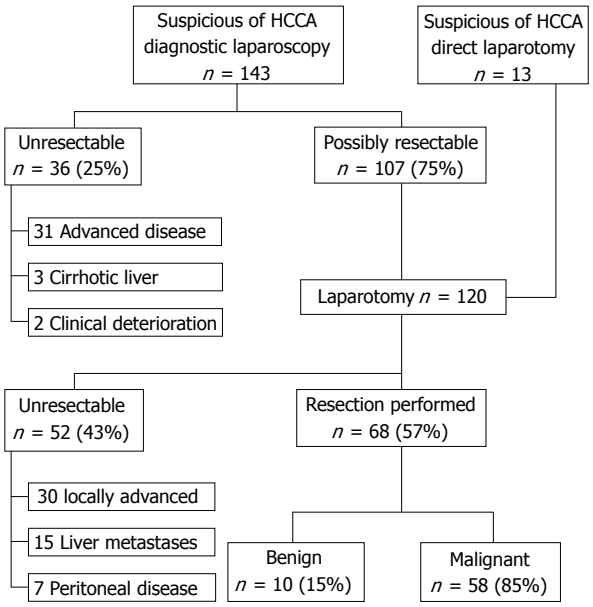

Figure 1 Flow chart of patients eligible for resection of hilaire cholangiocarcinoma (HCCA) with final histopathological outcome in the period from January 1998 to December 2006.

the initial diagnostic evaluation was performed at the referring hospital, imaging studies such as US, CT and MRC were usually repeated in our center. The medical data of patients obtained from these hospitals and from our center included demographic features, relevant medical history, presenting symptoms, laboratory investigations, results of imaging studies (including cholangiography, CT, MRC, duplex US), radiological and endoscopic interventions including placement of a stent, brush cytology and intra-operative findings.

The results of biliary brush cytology obtained during antegrade percutaneous transhepatic cholangiography (PTC) or endoscopic retrograde cholangiopancre aticography (ERCP) were categorized as follows: highly suspicious for adenocarcinoma, atypical cells/ inconclusive, and no malignant cells. Data from imaging studies were collected for staging purposes. The data recorded from these studies included: the presence of a mass lesion, proximal extent of the tumor within the biliary tree according to the Bismuth-Corlette classification system, vascular involvement (hepatic artery, portal vein), liver lobe atrophy, and lymphadenopathy. Ultrasonography, CT and MRI were used to detect a mass lesion, to determine the size of the lesion and the level of the biliary obstruction. Findings on PTC and/or ERCP showing an irregular and eccentric stenosis and/or a blunt end rather than a smooth tapering narrowing of the duct were considered more suggestive of a malignant lesion. Vascular invasion on colour Doppler US was defined as an increase in flow compatible with stenosis or absence of flow compatible with occlusion. Furthermore, on contrast enhanced CT, presence of vascular stenosis or occlusion of the portal vein and encasement of the artery were indicative of vascular involvement.

The final histological diagnosis was correlated with

the preoperative clinical and laboratory findings as well as with the radiological data in an effort to identify criteria which may be useful for the differentiation of HCCA (group Ⅰ, 58 patients) from benign proximal bile duct stricture (group Ⅱ, 10 patients). The resected specimens of the benign lesions were re-assessed by a single pathologist, specialized in hepatobiliary pathology (FJ. tK.). The results obtained are expressed as the mean (SEM). The differences between categorical variables were evaluated by chi-square analysis, while Student's *t* test was used for all comparisons among continuous variables. A two-tailed *P* value less than 0.05 was considered to indicate significant differences. All statistics were carried out using the SPSS Base 12.0 for Windows Statistical Package for Social Sciences (SPSS®, Chicago, IL).

RESULTS

The demographic features, presenting symptoms, and preoperative laboratory findings are shown in Table 1. The mean age and male-female gender ratio were equal in the two study groups. Although 9 patients (groups combined) had a prior cholecystectomy, none of the patients had a complicated procedure with bile duct stricture. In the group with benign lesions, one patient had history of alcohol abuse and related chronic pancreatitis, and another patient had history of inflammatory bowel disease (ulcerative colitis). In the malignant group, one patient had history of alcohol abuse and one patient had Crohn's colitis with primary sclerosing cholangitis (PSC).

There were no statistically significant differences between the two groups with respect to the clinical presentation. Jaundice was present in 79% of the patients in group Ⅰ and 60% of group Ⅱ. Abdominal pain, usually located in the right upper abdomen or in the epigastric region was mostly vague and nonpersistent. Weight loss was observed in both groups with a median loss of 6.4 kg in group Ⅰ (range 2-16) and 7.3 kg (range 2-10) in group Ⅱ. No differences were observed in the results of the laboratory tests, except for serum transaminase levels which showed higher levels in group Ⅰ compared to group Ⅱ ($P < 0.05$, Table 1). Assessment of tumor markers, including carcinoembryonic antigen (CEA) and carbohydrate antigen 19-9 (CA 19-9) was not performed routinely.

The majority of patients underwent imaging studies, and interventions such as ERCP, PTC and diagnostic laparoscopy (Table 2). The mean number of imaging procedures was 3.3 per patient in both groups. CT scan was performed most frequently, with an overall rate of 96%. Sixty patients (88%) underwent colour Doppler US, while MRI was performed in 21 patients (31%). Cholangiography (either ERCP or PTC) was performed in 63 patients (93%). Forty-seven patients underwent ERCP and 15 patients underwent PTC with at least one bile duct stent or drainage tube inserted. Five patients underwent both ERCP and PTC to achieve biliary decompression. Examination of brush cytology, shown in Table 2, showed malignant cells in 50% of patients in group Ⅰ, whereas none in group Ⅱ showed malignant cells ($P < 0.05$). Furthermore, brush cytology in 9 patients in the malignant group proved false negative. Atypical cells were found in 6 and 2 patients in group Ⅰ and Ⅱ, respectively.

The findings obtained with the imaging studies are shown in Table 3. A mass lesion at the hepatic duct confluence was seen in 56 patients (97%) in group Ⅰ and 8 patients (80%) in group Ⅱ. The presence and size of a mass could not distinguish between benign or malignant disease. The extent of bile duct involvement classified according to the Bismuth-Corlette system was similar in the two groups. Vascular involvement was

Table 1 Demographic features, presenting symptoms and laboratory findings in patients resected for presumed HCCA

	Malignant (*n* = 58)	Benign (*n* = 10)	*P*
Demographics			
Gender male/female	35/23	3/7	0.09
Mean age (range)	62 (30-80)	61 (40-71)	0.62
Prior history of cholecystectomy	6 (10%)	3 (30%)	0.12
Presenting symptoms			
Jaundice	46 (79%)	6 (60%)	0.23
Abdominal pain	27 (47%)	6 (60%)	0.51
Weight loss	34 (59%)	4 (40%)	0.32
Fever	2 (3%)	2 (20%)	0.10
Preoperative laboratory findings			
Bilirubin (μmol/L)	144 (± 15)	107 (± 35)	0.36
AP (U/L)	430 (± 61)	371 (± 64)	0.73
AST (U/L)	119 (± 12)	58 (± 15)	0.02
ALT (U/L)	190 (± 21)	88 (± 22)	0.03
GGT (U/L)	675 (± 89)	405 (± 114)	0.32
LDH (U/L)	313 (± 20)	277 (± 30)	0.42
PT (Prolonged-Normal)	3-33 (8%)	1-6 (14%)	0.62

HCCA: Hilar cholangiocarcinoma; AST: Aspartate aminotransferase; ALT: Alanine aminotransferase; GGT: Gamma glutamyl transpeptidase; LDH: Lactate dehydrogenase; PT: Prothrombin time; AP: Alkaline phosphatase.

Table 2 Imaging studies and interventions in patients resected for presumed HCCA

	Malignant (*n* = 58)	Benign (*n* = 10)	*P*
No. of imaging studies			
ERCP	51 (88%)	9 (90%)	
PTC	13 (22%)	3 (30%)	
US + colour Doppler	52 (90%)	8 (80%)	
CT	56 (97%)	9 (90%)	
MRC	17 (29%)	4 (40%)	
Mean No. of procedures per patient	3.3	3.3	
Stent placement procedure			
ERCP	40	7	
PTC	12	3	
ERCP and PTC	4	1	
Biliary brushing			
No. of brushings performed	30/58 (52%)	6/10 (60%)	0.74
Highly suspicious	15/30 (50%)	0/6 (0%)	0.03
No malignant cells	9/30 (30%)	4/6 (67%)	0.16
Atypical cells, inconclusive	6/30 (20%)	2/6 (33%)	0.60
Diagnostic laparoscopy			
No. of laparoscopies performed	53 (91%)	8 (80%)	
Intra-operative US performed	15	1	

Table 3 Results of imaging studies and intra-operative findings in patients resected for presumed HCCA

	Malignant (n = 58)	Benign (n = 10)	P
Findings on preoperative imaging			
Presence of mass	56 (97%)	8 (80%)	0.10
Mean size (range, cm)	2.5 (0.7-7.0)	2.6 (1.0-3.7)	0.62
Bismuth classification			
Type Ⅰ, Ⅱ	14	3	0.70
Type Ⅲa/b, IV	39	6	
Intrahepatic	5	1	
Vascular involvement[1]	21 (36%)	0 (0%)	0.03
Portal vein	19	0	
Hepatic artery	6	0	
Lobar atrophy	10 (17%)	1 (10%)	1.00
Lymph nodes (> 1 cm)	12 (21%)	1 (10%)	0.67
Intra-operative findings			
FS performed[2]	57/58 (99%)	10/10 (100%)	
FS positive for malignancy	20/57 (35%)	0/10 (0%)	0.03
Suspicious[3]-Not suspicious	51-7	5-5	
Type of resection			
Local bile duct resection	17 (29%)	3 (30%)	
Concomitant partial hepatectomy	41 (71%)	7 (70%)	

FS: Frozen section. [1]Non cumulative, patients with simultaneously portal v. and hepatic a. involvement; [2]FS from suspicious lesions, lymph nodes and/or resection margins; [3]A positive FS and/or palpable mass.

observed only in patients with malignant disease (P < 0.05), although lobar atrophy was not more frequent in the malignant group. Lobar atrophy was present in one patient in the benign group, probably caused by segmental biliary obstruction. Moreover, the presence of enlarged lymph nodes (> 1 cm, short axis diameter) could not differentiate the two groups. After taking into consideration the clinical presentation, laboratory findings, imaging studies, prior interventions and brush cytology, all 68 patients were diagnosed to have a lesion suspicious of HCCA.

During surgical exploration, frozen sections were obtained of suspicious lymph nodes, tissue suspicious of tumor infiltrating the vessel walls, and the resection margins to ensure radical resection in all patients except one (Table 3). The frozen section examination confirmed malignancy in 35% of the patients in group Ⅰ, and no false positive results were obtained in group Ⅱ (P < 0.05). A palpable, suspicious hilar tumor was found in 5 patients (50%) in the benign group and in 51 patients (88%) in the malignant group. Eventually, 70% of all patients underwent hilar resection, in combination with partial liver resection; the prevalence of local bile duct excision was equally divided between the two groups. Histological analysis of the resected specimens showed a benign bile duct stricture in 10 patients, diagnosed as chronic fibrosing lesion, erosive inflammation, sclerosing cholangitis or autoimmune cholangitis (IgG4-related) (Table 4). In the remaining 58 resection specimens, histology confirmed HCCA.

DISCUSSION

Cholangiocarcinoma and benign, inflammatory lesions of the biliary tract may have a similar clinical presentation. Differentiating the two conditions is complex because on the one hand, HCCA is frequently associated with secondary inflammatory changes, and on the other hand, conditions such as PSC predispose to malignancy of the bile ducts (with a reported prevalence of 30%)[18]. A combination of different imaging modalities is usually employed in the diagnosis of hilar bile duct lesions[8]. However, to date, no single investigation has been found to reliably differentiate HCCA from benign proximal bile duct strictures.

In the present study, the rate of patients (15%) with benign lesions misdiagnosed as malignancy was similar to the rate (15%) observed in a previous study performed at our center a decade earlier (1983-1997)[16]. Despite considerable improvements in imaging techniques (contrast enhanced multi-slice CT and MRC), and an increase in the number of imaging procedures (a mean of 3 modalities in comparison to 2 in the previous study), patients still required unnecessary extensive resections, for achieving adequate biliary drainage. Case series from other groups worldwide, have noted comparable rates of benign lesions in resections performed for presumed HCCA (Table 5). Our observations confirm the findings of these studies and emphasize the difficulty in differentiating benign from malignant lesions at the liver hilum, despite use of state-of-the-art imaging modalities.

Clinical features alone cannot differentiate HCCA from benign proximal bile duct strictures. With regard to laboratory tests, plasma transaminase values were significantly elevated in the malignant group compared to patients with benign hilar lesions. Although raised transaminase values may occur in patients with benign proximal bile duct strictures (usually in conjunction with cholangitis), our results show that this is an uncommon finding. Other laboratory tests failed to identify patients with a malignancy. The diagnostic value of tumor markers such as CA 19-9 and CEA in biliary cancer has been extensively studied. One study showed 100% sensitivity using a combination of CA 19-9 and CEA[19], but these results could not be confirmed by other workers[9,10]. Another, potentially useful test is serum IgG4. Recently, IgG4-related lymphoplasmacytic sclerosing disease was observed in patients with strictures of the pancreatic duct mimicking carcinoma[20]. In a study from our center, it was shown that IgG4-related sclerosing disease also occurs in patients with benign proximal bile duct strictures[21]. In the present series, two of the ten patients with benign proximal bile duct strictures showed infiltration by IgG4-plasma cells with histological features suggestive of an autoimmune disorder. Serum levels of IgG4 have potential to differentiate benign disease from HCCA, although the diagnostic value of this marker and the role of immunomodulatory drugs requires further investigation[22].

The findings obtained with the different imaging studies revealed that only one feature, i.e. vascular involvement, was significantly different between the

Table 4 Patients with benign proximal bile duct strictures: Preoperative, intra-operative and histological findings

Number of patient	Age/Gender	Medical history	Bismuth classification	Brush cytology	Intra-operative findings	Treatment	Final histological diagnosis
1	40/F	LC	Intrahepatic	Atypical cells	Suspicious	Hemihepatectomy le	Fibrosing cholangitis
2	54/F	-	Type Ⅲa	No malignancy	Suspicious	Hemihepatectomy ri[1]	Sclerosing cholangitis
3	56/M	IBD	Type Ⅲb	-	Not suspicious	Hemihepatectomy le[1,2]	Sclerosing cholangitis
4	60/F	-	Type Ⅱ	No malignancy	Not suspicious	Local resection	Fibrosing cholangitis
5	63/F	LC	Type Ⅱ	Atypical cells	Suspicious	Local resection	Erosive inflammation
6	65/F	-	Type Ⅲa	-	Not suspicious	Hemihepatectomy ri	Autoimmune-like cholangitis
7	68/F	LC	Type Ⅲa	-	Suspicious	Hemihepatectomy ri	Fibrosing cholangitis
8	69/F	-	Type Ⅲb	-	Not suspicious	Hemihepatectomy le	Sclerosing cholangitis
9	70/M	-	Type Ⅱ	No malignancy	Not suspicious	Local resection	Erosive inflammation
10	71/M	CP	Type Ⅲa	No malignancy	Suspicious	Hemihepatectomy ri[1]	Autoimmune-like cholangitis

CP: Chronic pancreatitis; LC: Laparoscopic cholecystectomy; IBD: Inflammatory bowel disease. [1]Partial liver resection + local resection; [2]Partial liver resection was performed because of atrophic liver lobes.

Table 5 Incidence of benign lesions in patients resected for presumed HCCA: Review of literature

Source, yr[1]	Period of inclusion	Number of patients[2]	Number of benign lesions (%)
Hadjis *et al* 1985[34]	1979-1983	104[3]	8 (8)
Wetter *et al* 1991[35]	1985-1990	59[4]	8 (14)
Verbeek *et al* 1992[36]	1984-1990	82	11 (13)
Nakayama *et al* 1999[10]	1990-1997	99	14 (15)
Gerhards *et al* 2001[16]	1983-1997	132	20 (15)
Knoefel *et al* 2003[12]	1996-1999	33	6 (18)
Khalili *et al* 2003[13]	2000-2001	20	4 (20)
Koea *et al* 2004[37]	1998-2002	49	12 (24)
Corvera *et al* 2005[38]	1992-2003	275[3]	22 (8)
Are *et al* 2006[15]	1997-2001	59	9 (15)
Uhlmann *et al* 2006[39]	1998-2004	49	7 (14)
Present study	1998-2006	68	10 (15)

[1]Listed chronologically; [2]Indicates only patients undergoing resection; [3]Patients evaluated of suspected hilar cholangiocarcinoma (not all resected); [4]Patients resected for papillary tumours were excluded (n = 5).

benign and malignant groups. Even a mass lesion was not able to differentiate between the two groups. Furthermore, in contrast to the report by Are and co-workers[15], we did not find any difference between the benign and malignant groups with respect to either the level of obstruction or the extent of lesion. Moreover, there was no difference in rate of liver lobe atrophy. Portal vein occlusion of one side of the liver typically gives rise to ipsilateral lobar atrophy and compensatory hypertrophy of the contralateral lobe. However, it is possible to develop lobar atrophy without portal vein occlusion. In benign disease, lobar atrophy can develop secondary to longstanding cholestasis. In a series of 162 patients with intrahepatic cholelithiasis, lobe atrophy was observed in 7% of the patients[23]. Overall, the finding of lobar atrophy is uncommon with benign disease and should be considered as a manifestation of vascular involvement and therefore of malignancy. Occlusion of the portal vein obviously suggests malignancy, however two cases have been reported of a benign inflammatory pseudotumor mimicking HCCA with vascular involvement[24,25]. Therefore, although uncommon, even vascular involvement may be seen in benign lesions at the liver hilum.

Brush cytology of a biliary stricture is often undertaken during ERCP or PTC. Unfortunately, the diagnostic yield is poor with sensitivity rates around 50%[9,26]. Moreover, the specificity is not 100% since longstanding stenting of the biliary duct induces chronic inflammation, which makes it difficult to differentiate benign from malignant cells, resulting in false positive results[9]. The present study showed similar rates which is consistent with previous studies. Fluorescence in situ hybridization (FISH) has been increasingly used to facilitate the identification of neoplastic cells in cytologic specimens[27]. In one study, 20% of patients with cholangiocarcinoma missed by conventional cytology were identified by FISH without affecting the specificity[28]. Several studies have evaluated the diagnostic yield of endoscopic US fine needle aspiration in patients with biliary strictures[29-32]. In one of the studies, the sensitivity and specificity of biopsy were 89% and 100%, respectively[30]. Moreover, the planned surgical approach was changed in 27 of 44 patients. Therefore, biopsy from either the mass or the surrounding malignant-appearing lymph nodes appears to have a higher sensitivity than ERCP or PTC with brush cytology. More recently, techniques such as intraductal ultrasound (IDUS) and cholangioscopy have been used to obtain direct biopsy specimens. IDUS with biopsy increased the accuracy of ERCP from 58%-60% to 83%-90% in distinguishing benign and malignant strictures[33]. These diagnostic modalities appear very promising in differentiating benign and malignant biliary lesions, although they are highly expert-dependent and are still not widely available.

In one-half of the patients diagnosed to have a benign lesion at the liver hilum, the intra-operative findings were consistent with a malignant tumor (i.e. positive frozen section diagnosis and/or evident palpable mass). Furthermore, 7 patients in the malignant group were not found to have a suspicious lesion during laparotomy. Thus, even at surgery it is difficult to determine the nature of a hilar lesion, and resection is the only way to rule out malignancy.

In conclusion, despite improvements in the quality and increase in the number of imaging studies, 10

out of 68 (15%) patients with presumed HCCA, were misdiagnosed. Vascular involvement showed a significant association with malignant lesions. However, there was no feature on imaging studies or laboratory tests that reliably distinguished HCCA from benign proximal bile duct lesions. Therefore, differentiation of benign from malignant lesions at the liver hilum remains difficult and this should be taken into account when considering resection in patients with suspicious hilar lesions.

COMMENTS

Background

The main etiology of proximal bile duct stricture is hilar cholangiocarcinoma (HCCA). However, the differentiation of benign and malignant strictures is difficult which has obvious important consequences for management. Extensive work-up including multi-slice computed tomography and magnetic resonance cholangiography may help improve the diagnostic dilemma.

Research frontiers

The differentiation of benign and malignant lesions at the liver hilum remains a diagnostic dilemma despite improvements in the quality and increase in the number of imaging techniques. Novel diagnostic and imaging techniques are discussed, although none have shown a high rate of accuracy. The most promising diagnostic modality appears to be intraductal ultrasound in combination with cholangioscopic biopsy.

Innovations and breakthroughs

The authors observed that vascular involvement had a significant association with malignant lesions. No other feature on imaging studies or laboratory tests was able to reliably distinguish HCCA from benign proximal bile duct lesions.

Applications

Vascular involvement emerged as the most important diagnostic feature.

Terminology

Vascular invasion on colour Doppler ultrasonography was defined as an increase in the portal and/or hepatic arterial flow compatible with stenosis, or absence of flow compatible with occlusion. Furthermore, on contrast enhanced computed tomography a vascular stenosis or occlusion was considered as vascular involvement.

Peer review

This is a retrospective study of 68 patients with suspicion of cholangiocarcinoma. Fifteen percent of patients were found to have benign strictures after resection. The authors concluded that despite the use of sophisticated diagnostic tests and imaging studies, differentiation of malignant from benign hilar lesions remains a dilemma.

REFERENCES

1 **Jarnagin WR**, Fong Y, DeMatteo RP, Gonen M, Burke EC, Bodniewicz BS J, Youssef BA M, Klimstra D, Blumgart LH. Staging, resectability, and outcome in 225 patients with hilar cholangiocarcinoma. *Ann Surg* 2001; **234**: 507-517; discussion 517-519

2 **Witzigmann H**, Berr F, Ringel U, Caca K, Uhlmann D, Schoppmeyer K, Tannapfel A, Wittekind C, Mossner J, Hauss J, Wiedmann M. Surgical and palliative management and outcome in 184 patients with hilar cholangiocarcinoma: palliative photodynamic therapy plus stenting is comparable to r1/r2 resection. *Ann Surg* 2006; **244**: 230-239

3 **Dinant S**, Gerhards MF, Rauws EA, Busch OR, Gouma DJ, van Gulik TM. Improved outcome of resection of hilar cholangiocarcinoma (Klatskin tumor). *Ann Surg Oncol* 2006; **13**: 872-880

4 **Seyama Y**, Kubota K, Sano K, Noie T, Takayama T, Kosuge T, Makuuchi M. Long-term outcome of extended hemihepatectomy for hilar bile duct cancer with no mortality and high survival rate. *Ann Surg* 2003; **238**: 73-83

5 **Looser C**, Stain SC, Baer HU, Triller J, Blumgart LH. Staging of hilar cholangiocarcinoma by ultrasound and duplex sonography: a comparison with angiography and operative findings. *Br J Radiol* 1992; **65**: 871-877

6 **Masselli G**, Gualdi G. Hilar cholangiocarcinoma: MRI/MRCP in staging and treatment planning. *Abdom Imaging* 2008; **33**: 444-451

7 **Park MS**, Kim TK, Kim KW, Park SW, Lee JK, Kim JS, Lee JH, Kim KA, Kim AY, Kim PN, Lee MG, Ha HK. Differentiation of extrahepatic bile duct cholangiocarcinoma from benign stricture: findings at MRCP versus ERCP. *Radiology* 2004; **233**: 234-240

8 **Domagk D**, Wessling J, Conrad B, Fischbach R, Schleicher C, Bocker W, Senninger N, Heinecke A, Heindel W, Domschke W, Kucharzik T. Which imaging modalities should be used for biliary strictures of unknown aetiology? *Gut* 2007; **56**: 1032

9 **Khan SA**, Davidson BR, Goldin R, Pereira SP, Rosenberg WM, Taylor-Robinson SD, Thillainayagam AV,Thomas HC,Thursz MR,Wasan H. Guidelines for the diagnosis and treatment of cholangiocarcinoma: consensus document. *Gut* 2002; **51** Suppl 6: VI1-VI9

10 **Nakayama A**, Imamura H, Shimada R, Miyagawa S, Makuuchi M, Kawasaki S. Proximal bile duct stricture disguised as malignant neoplasm. *Surgery* 1999; **125**: 514-521

11 **Singh SS**, Sharma R, Pal S, Sahni P, Kanti CT. Differentiation between benign and malignant hilar obstructions using laboratory and radiological investigations: A prospective study. *HPB* (Oxford) 2007; **9**: 373-382

12 **Knoefel WT**, Prenzel KL, Peiper M, Hosch SB, Gundlach M, Eisenberger CF, Strate T, Scheunemann P, Rogiers X, Izbicki JR. Klatskin tumors and Klatskin mimicking lesions of the biliary tree. *Eur J Surg Oncol* 2003; **29**: 658-661

13 **Khalili K**, Metser U, Wilson SR. Hilar biliary obstruction: preliminary results with Levovist-enhanced sonography. *AJR Am J Roentgenol* 2003; **180**: 687-693

14 **Binkley CE**, Eckhauser FE, Colletti LM. Unusual causes of benign biliary strictures with cholangiographic features of cholangiocarcinoma. *J Gastrointest Surg* 2002; **6**: 676-681

15 **Are C**, Gonen M, D'Angelica M, DeMatteo RP, Fong Y, Blumgart LH, Jarnagin WR. Differential diagnosis of proximal biliary obstruction. *Surgery* 2006; **140**: 756-763

16 **Gerhards MF**, Vos P, van Gulik TM, Rauws EA, Bosma A, Gouma DJ. Incidence of benign lesions in patients resected for suspicious hilar obstruction. *Br J Surg* 2001; **88**: 48-51

17 **Van Gulik TM**, Dinant S, Busch OR, Rauws EA, Obertop H, Gouma DJ. Original article: New surgical approaches to the Klatskin tumour. *Aliment Pharmacol Ther* 2007; **26** Suppl 2: 127-132

18 **Lazaridis KN**, Gores GJ. Cholangiocarcinoma. *Gastroenterology* 2005; **128**: 1655-1667

19 **Siqueira E**, Schoen RE, Silverman W, Martin J, Rabinovitz M, Weissfeld JL, Abu-Elmaagd K, Madariaga JR, Slivka A. Detecting cholangiocarcinoma in patients with primary sclerosing cholangitis. *Gastrointest Endosc* 2002; **56**: 40-47

20 **Hamano H**, Kawa S, Horiuchi A, Unno H, Furuya N, Akamatsu T, Fukushima M, Nikaido T, Nakayama K, Usuda N, Kiyosawa K. High serum IgG4 concentrations in patients with sclerosing pancreatitis. *N Engl J Med* 2001; **344**: 732-738

21 **Erdogan D**, Kloek JJ, ten Kate FJ, Rauws EA, Busch OR, Gouma DJ, van Gulik TM. Immunoglobulin G4-related sclerosing cholangitis in patients resected for presumed malignant bile duct strictures. *Br J Surg* 2008; **95**: 727-734

22 **Ghazale A**, Chari ST, Zhang L, Smyrk TC, Takahashi N, Levy MJ, Topazian MD, Clain JE, Pearson RK, Petersen BT, Vege SS, Lindor K, Farnell MB. Immunoglobulin G4-associated cholangitis: clinical profile and response to therapy. *Gastroenterology* 2008; **134**: 706-715

23 **Chen HH**, Zhang WH, Wang SS, Caruana JA. Twenty-two year experience with the diagnosis and treatment of intrahepatic calculi. *Surg Gynecol Obstet* 1984; **159**: 519-524

24 **Kai K**, Matsuyama S, Ohtsuka T, Kitahara K, Mori D, Miyazaki K. Multiple inflammatory pseudotumor of the liver, mimicking cholangiocarcinoma with tumor embolus

in the hepatic vein: report of a case. *Surg Today* 2007; **37**: 530-533
25. **Broughan TA**, Fischer WL, Tuthill RJ. Vascular invasion by hepatic inflammatory pseudotumor. A clinicopathologic study. *Cancer* 1993; **71**: 2934-2940
26 **Joyce AM**, Kochman ML. Update on biliary endoscopy. *Curr Opin Gastroenterol* 2005; **21**: 354-358
27 **Halling KC**, Kipp BR. Fluorescence in situ hybridization in diagnostic cytology. *Hum Pathol* 2007; **38**: 1137-1144
28 **Moreno Luna LE**, Kipp B, Halling KC, Sebo TJ, Kremers WK, Roberts LR, Barr Fritcher EG, Levy MJ, Gores GJ. Advanced cytologic techniques for the detection of malignant pancreatobiliary strictures. *Gastroenterology* 2006; **131**: 1064-1072
29 **Eloubeidi MA**, Chen VK, Jhala NC, Eltoum IE, Jhala D, Chhieng DC, Syed SA, Vickers SM, Mel Wilcox C. Endoscopic ultrasound-guided fine needle aspiration biopsy of suspected cholangiocarcinoma. *Clin Gastroenterol Hepatol* 2004; **2**: 209-213
30 **Fritscher-Ravens A**, Broering DC, Knoefel WT, Rogiers X, Swain P, Thonke F, Bobrowski C, Topalidis T, Soehendra N. EUS-guided fine-needle aspiration of suspected hilar cholangiocarcinoma in potentially operable patients with negative brush cytology. *Am J Gastroenterol* 2004; **99**: 45-51
31 **DeWitt J**, Misra VL, Leblanc JK, McHenry L, Sherman S. EUS-guided FNA of proximal biliary strictures after negative ERCP brush cytology results. *Gastrointest Endosc* 2006; **64**: 325-333
32 **Gleeson FC**, Rajan E, Levy MJ, Clain JE, Topazian MD, Harewood GC, Papachristou GI, Takahashi N, Rosen CB, Gores GJ. EUS-guided FNA of regional lymph nodes in patients with unresectable hilar cholangiocarcinoma. *Gastrointest Endosc* 2008; **67**: 438-443
33 **Stavropoulos S**, Larghi A, Verna E, Battezzati P, Stevens P. Intraductal ultrasound for the evaluation of patients with biliary strictures and no abdominal mass on computed tomography. *Endoscopy* 2005; **37**: 715-721
34 **Hadjis NS**, Collier NA, Blumgart LH. Malignant masquerade at the hilum of the liver. *Br J Surg* 1985; **72**: 659-661
35 **Wetter LA**, Ring EJ, Pellegrini CA, Way LW. Differential diagnosis of sclerosing cholangiocarcinomas of the common hepatic duct (Klatskin tumors). *Am J Surg* 1991; **161**: 57-62; discussion 62-63
36 **Verbeek PC**, van Leeuwen DJ, de Wit LT, Reeders JW, Smits NJ, Bosma A, Huibregtse K, van der Heyde MN. Benign fibrosing disease at the hepatic confluence mimicking Klatskin tumors. *Surgery* 1992; **112**: 866-871
37 **Koea J**, Holden A, Chau K, McCall J. Differential diagnosis of stenosing lesions at the hepatic hilus. *World J Surg* 2004; **28**: 466-470
38 **Corvera CU**, Blumgart LH, Darvishian F, Klimstra DS, DeMatteo R, Fong Y, D'Angelica M, Jarnagin WR. Clinical and pathologic features of proximal biliary strictures masquerading as hilar cholangiocarcinoma. *J Am Coll Surg* 2005; **201**: 862-869
39 **Uhlmann D**, Wiedmann M, Schmidt F, Kluge R, Tannapfel A, Berr F, Hauss J, Witzigmann H. Management and outcome in patients with Klatskin-mimicking lesions of the biliary tree. *J Gastrointest Surg* 2006; **10**: 1144-1150

S- Editor Li DL **L- Editor** Anand BS **E- Editor** Lin YP

Online Submissions: wjg.wjgnet.com
wjg@wjgnet.com
doi:10.3748/wjg.14.5039

World J Gastroenterol 2008 August 28; 14(32): 5039-5045
World Journal of Gastroenterology ISSN 1007-9327
© 2008 The WJG Press. All rights reserved.

RAPID COMMUNICATION

Accuracy of *Helicobacter pylori* serology in two peptic ulcer populations and in healthy controls

Rolv-Ole Lindsetmo, Roar Johnsen, Tor Jac Eide, Tore Gutteberg, Hanne Haukland Husum, Arthur Revhaug

Rolv-Ole Lindsetmo, Department of Gastrointestinal Surgery, University Hospital of North Norway and Institute of Clinical Medicine, Tromsø University, Tromsø N-9036, Norway
Roar Johnsen, Institute of Public Health and General Practice, Norwegian University of Science and Technology, Trondheim N-7006, Norway
Tor Jac Eide, Department of Pathology, National Hospital, Oslo N-0027, Norway
Tore Gutteberg, Hanne Haukland Husum, Department of Microbiology, University Hospital of North Norway, Tromsø N-9036, Norway
Arthur Revhaug, Department of Gastrointestinal Surgery, University Hospital of North Norway and Institute of Clinical Medicine, Tromsø University, Tromsø N-9036, Norway
Author contributions: All authors have made substantial contributions to interpretation of data, participated in drafting of the article and revised it critically for important intellectual content and have given final approval of the manuscript to be submitted and published; Lindsetmo RO, Johnsen R and Revhaug A made the conception and design; Lindsetmo RO, Eide TJ, Gutteberg T and Husum HH acquired the data; Lindsetmo RO wrote the paper.
Correspondence to: Rolv-Ole Lindsetmo, MD, PhD, MPH, Department of Gastrointestinal Surgery, University Hospital of North Norway, and Institute of Clinical Medicine, Tromsø University, Tromsø N-9036, Norway. rolv.ole.lindsetmo@unn.no
Telephone: +47-77-626000 Fax: +47-77-626605
Received: March 10, 2008 Revised: August 13, 2008
Accepted: August 20, 2008
Published online: August 28, 2008

Abstract

AIM: To estimate the test characteristics of *Helicobacter pylori* (*H pylori*) serology and of C14-urea breath test (C14-UBT) in two different peptic ulcer populations and in community controls. Second, the aim was to explore the association between the level of *H pylori* IgG antibodies and severity of inflammation as to active peptic ulceration in the same populations.
METHODS: Vagotomized (n = 83), medically treated peptic ulcer patients (n = 73) and one reference group of community controls (n = 88) were gastroscoped. *H pylori* status was determined by histology, bacterial growth, C14-UBT and serology. Based on the updated Sydney System, cumulative scores from biopsies from the prepyloruos, incisura angularis, corpus and fundus were calculated.
RESULTS: The prevalence of *H pylori* infection varied from 70% to 79%. The C14-UBT had high accuracy compared to the serology test. The sensitivity of the serology test was good, but the specificity was low (41%-71%). The association between *H pylori* IgG antibodies and scores of gastric mucosal inflammation and current or previous peptic ulcer were weak.
CONCLUSION: The accuracy of C14-UBT to diagnose *H pylori* infection was good, and the clinical utility of a negative *H pylori* serology test was substantial, while the gain in clinical information of a positive test was meagre. Positive *H pylori* titres could not distinguish between subjects with or those without active peptic ulceration.

© 2008 The WJG Press. All rights reserved.

Key words: C14-urea breath test; Gastric inflammation; *Helicobacter pylori* serology; Peptic ulcers; Test characteristics

Peer reviewer: Amado S Peña, Professor, Department of Pathology, Immunogenetics, VU University Medical Centre, De Boelelaan 1117, PO Box 7057, Amsterdam 1007 MB, Netherlands

Lindsetmo RO, Johnsen R, Eide TJ, Gutteberg T, Husum HH, Revhaug A. Accuracy of *Helicobacter pylori* serology in two peptic ulcer populations and in healthy controls. *World J Gastroenterol* 2008; 14(32): 5039-5045 Available from: URL: http://www.wjgnet.com/1007-9327/14/5039.asp DOI: http://dx.doi.org/10.3748/wjg.14.5039

INTRODUCTION

Serology and C14-urea breath test (C14-UBT) are the most commonly used non-invasive tests of *Helicobacter pylori* (*H pylori*) infection[1-3]. Knowledge about the diagnostic validity of particular serological tests is mandatory for inferring its test results[4]. In the diagnostics of *H pylori* infection, most commercially available serological tests are reported to have both a high sensitivity and a high specificity[5]. The diagnostic characteristics of the tests depend also on the prevalence of *H pylori* infection in the population tested[5-7]. Higher prevalence's would imply higher sensitivity and lower specificity[5-7]. There are reports suggesting that there is an association between the level of *H pylori* IgG antibodies and the severity of inflammation of the gastric mucosa and also

between antibody level and a current peptic ulcer[8-10]. If so, the level, not only positively or not, of *H pylori* IgG antibody tests might be of clinical importance.

The aim of this study was to estimate the test characteristics of *H pylori* serology compared to the urea breath test (C14-UBT) in two different peptic ulcer populations and in a randomly selected group of community controls without known peptic ulcer disease. Second, the aim was to explore the association between the level of *H pylori* IgG antibodies and severity of inflammation as to active peptic ulceration in the same populations.

MATERIALS AND METHODS

Based upon a questionnaire survey[11], three groups of subjects were invited to participate in an upper endoscopic investigation: one group of vagotomized peptic ulcer patients; one group of medically treated peptic ulcer patients and one reference group of community controls without known peptic ulcer disease.

Vagotomized peptic ulcer patients

The medical records of all patients operated with a vagotomy for peptic ulcer disease from 1967 to 1990 at Tromsø University Hospital were reviewed, totally 1 038 records. Seven hundred and twenty one were alive and received a postal questionnaire with 105 different questions on abdominal and dyspeptic complaints, medications, use of health services, health, life style, diet and social conditions. Two hundred and eighty two answered that they were interested in a gastroscopic examination if offered. By binominal distribution 106 of these 282 vagotomized patients were randomly selected and invited into the study. Sixteen patients were excluded because they had undergone gastric resections in addition to the vagotomy operation and seven due to interrupted endoscopic examination according to the patient's wishes. Accordingly, 83 patients in these groups completed the investigation protocol. Fifty nine had been electively vagotomized, whereas 24 had been vagotomized on emergency indications.

Medically treated, non-operated, peptic ulcer patients

Two hundred and thirty one medically treated patients with radiographically (barium meal) or endoscopically verified peptic ulcer disease diagnosed in the period 1979 to 1986 received the same questionnaire as the vagotomized patients. One hundred and five were interested in an endoscopic examination if offered. All of these were invited. Seventy four finally accepted the invitation; one patient failed to swallow the endoscope. Accordingly, 73 patients fulfilled the investigation protocol.

Community controls

For comparison a group of community controls was included. Seven hundred and sixty two inhabitants of the local municipality were randomly selected from the National Population Registry. They were all without known peptic ulcer disease and were invited to participate in the same questionnaire survey as the peptic ulcer patients to serve as a community reference group in the comparison of abdominal and dyspeptic complaints. They were group-matched with the vagotomized patients regarding sex distribution and mean age. Two hundred and twenty five persons responded positively to the offered endoscopic examination. By binominal distribution, 105 subjects were randomly selected and invited to the endoscopic study. Ninety six finally accepted the invitation of which 7 were excluded due to interrupted endoscopic examination according to the patient's wishes, and one because of previous gastric surgery. Accordingly, 88 community subjects completed the investigation protocol.

The Regional Ethical Committee for Medical Sciences and the Norwegian Social Science Data Services approved the study design and the data security. There was no financial gain or hints of health benefits associated with participation in the study.

After an overnight fast, all subjects were pre-medicated with a topical anaesthetic spray (lidocaine hydrochloride, 10 mg/dose, Astra, Sweden). No additional sedation was used. The same endoscopist (ROL) examined all patients, and he was unaware of the subjects' peptic ulcer history, any previous treatment or current dyspeptic or abdominal complaints. All endoscopies were recorded by a Sony Hi-8 video-recorder using a Pentax gastroscope EG 2901.

None of the participants in the study received long term or continuous medical acid suppressive treatment prior to the endoscopic examination or any known treatment against *H pylori* infection.

Detection of H pylori

The culture, PCR and the serology tests were performed in the laboratories at the Department of Microbiology, Tromsø University Hospital (accredited according to the ISO 45001 standard).

Histology

The biopsy specimens for histological detection of *H pylori* infection was taken from the greater curvature of the duodenal bulb, from the greater curvature in the prepyloric antrum 2-3 cm from the pyloric channel, from the angulus (incisura angularis) of the lesser curvature, from the corpus of the greater curvature 10 cm from the cardia, and from the fundic top. Separate biopsy specimens were taken from all lesions. All biopsies were fixed in neutral-buffered 4% formaldehyde. Hematoxilin-eosin stains of paraffin-embedded biopsies were used for histological evaluation[12]. Histology was considered positive if *H pylori* like organisms were found in any of the four gastric biopsy sites, and negative if *H pylori* like organisms were not found in any of the biopsies. All histological specimens were evaluated by the same experienced pathologist (TJE) who was blinded for the subjects' medical history and other *H pylori* test results. The histological evaluations were performed according to the updated Sydney System recommendation[13].

Table 1 Sensitivity, specificity and likelihood ratio of positive test (LR+) of C14-UBT and IgG and IgA antibodies against *H pylori* at cut-off values 300 and 500 in vagotomized (vag) or medically (med) treated peptic ulcer patients (med) and in community controls (con)

	Sensitivity (95% CI)			Specificity (95% CI)			LR+ (95% CI)		
	vag	med	con	vag	med	con	vag	med	con
Method of detection									
C14-UBT	94 (85-99)	92 (81-98)	96 (87-100)	85 (62-97)	80 (56-94)	90 (73-98)	6.3 (2.4-31.5)	4.6 (1.7-17.6)	9.3 (3.0-46.6)
Serology IgG300	95 (86-99)	98 (90-100)	93 (83-98)	41 (21-64)	50 (28-72)	68 (49-83)	1.6 (0.9-3.2)	2.0 (1.0-4.2)	2.9 (1.5-6.4)
Serology IgG500	87 (76-94)	90 (79-97)	83 (70-91)	55 (32-76)	50 (28-72)	71 (52-86)	1.9 (1.0-4.2)	1.8 (0.9-3.9)	2.8 (1.4-6.6)
Serology IgG/IgA[1]	95 (86-99)	98 (90-100)	93 (83-98)	32 (14-55)	50 (28-72)	58 (39-76)	1.4 (0.8-2.7)	2.0 (1.0-4.2)	2.2 (1.2-4.4)

H pylori infection detected by a positive histology and/or by a positive culture was defined as reference standard. [1]Serology IgG/IgA: IgG ⩾ 300 and/or IgA ⩾ 500.

Gastric inflammation score

Semi-quantitative descriptions of the updated Sydney System were transformed to exact numbers from 1-4 (1 = no/none/no *H pylori*, 2 = slight/mild/*H pylori* in 1-3 pits, 3 = moderate/*H pylori* in more than 3 pits, but not all, 4 = severe/*H pylori* in all pits). The score from the 4 local biopsy sites were added up and the total scores were grouped in order to describe the histologically evaluated gastric inflammation of the total gastric mucosa. The same semi-quantitative terms were used for the chronic gastritis score. A score of 4 denotes no chronic gastritis/no *H pylori*, 5-8 denotes mild chronic gastritis/few *H pylori*, 9-12 denotes moderate chronic gastritis/some *H pylori*, 13-16 denotes severe chronic gastritis/much *H pylori*. The inflammatory activity was described as 1 = no inflammatory activity, 2 = slight/moderate inflammatory activity, 3 = severe inflammatory activity. In the scoring of the inflammatory activity 4 denotes no inflammatory activity, 5-6 slight inflammatory activity, 7-8 moderate inflammatory activity, 9-12 severe inflammatory activity.

H pylori culture growth

Two biopsies taken from the angulus of the lesser curvature were placed in a transport medium (Portagerm pylori, bioMèrieux, Lyon, France) and immediately transported to the Department of Microbiology for culture and detection of the *H pylori* DNA by PCR. Culture was preformed using selective (Oxoid SR 147E supplement) and nonselective columbia agar (Oxoid CM 331) with 7% lysed horse blood at 37℃. The plates were incubated under a microaerobic atmosphere (5% = 2, 7% CO_2, 8% H_2, 80% N_2) for at least 7 d. The culture was classified as positive when oxidase-, catalase- and urease positive colonies showed typical *H pylori* morphology on Gram staining.

C14 urea breath test

Fifty milliliters of tap water with 2.5 μCi carbon-14 labelled urea was given orally to the overnight fasted patient. Double breath samples were taken immediately before and at 10, 20 and 30 min after the ingestion of the urea solution and analysed for $^{14}CO_2$ in a Beta-counter as a measure of *H pylori* urease activity in the stomach. *H pylori* negative patients do not expire ^{14}C labelled CO_2. A ^{14}C urea breath test was positive when the accumulated $^{14}CO_2$ in the breath samples adjusted for the patients' bodyweight and the background radiation was more than 1.5% of the ingested ^{14}C dose[14].

Enzyme-linked immunoabsorbent assay (ELISA) detection of IgG and IgA H pylori antibodies

ELISA was used for detection of serum IgG and IgA antibodies according to the specifications of the manufacturer (Pyloriset EIA-G®, Orion Diagnostica, Finland). A titre ⩾ 300 was interpreted as a positive IgG serology result.

Reference standard

As reference tests were chosen the combination of histologically detected presence of *H pylori*-like organisms in any of the four biopsy sites[15] augmented by *H pylori* culture growth. A patient was considered as *H pylori* positive when having a positive test for *H pylori* by histological examination and/or by culture. The biopsies from the gastric mucosa were taken according to recommended biopsy sites and procedures[16].

Statistical analysis

The microcomputer software Confidence Interval analysis[17] estimated 95% confidence intervals for the various proportions and Epiinfo 6[18] was used to analyze dichotomous variables by the Mantel-Haenszel χ^2-test with Yates correction.

RESULTS

The prevalence of *H pylori* positive individuals among the vagotomized peptic ulcer patients was 79% (95% CI: 69-88), 75% (95% CI: 63-85) among the medically treated peptic ulcer patients, and 70% (95% CI: 59-80) among the community controls.

Anti *H pylori* IgG at a cut-off value 300 had comparable properties to C14-UBT in detecting the true positive patients in all three groups with sensitivities around 95% (Table 1). When increasing the cut-off value to 500, the sensitivities decreased 8%-10% in all three groups. The combination of anti *H pylori* IgG at a cut-off value 300 and anti *H pylori* IgA at a cut-off value 500 did not improve the sensitivity or specificity of the test in any of

Table 2 ***H pylori*** **status by histology and inflammatory activity in the gastric angulus (anginflam) in different combinations with culture growth, related to level of IgG antibodies against** ***H pylori*** **in each category**

	n	Range	Mean (95% CI)	Median
IgG when histologyHP neg and growth neg	66	100-12800	700 (290-1120)	200
IgG when histologyHP pos and growth neg	9	100-18000	4960 (530-9390)	4000
IgG when histologyHP pos and growth pos	143	100-20000	3480 (2740-4220)	1600
IgG when histologyHP neg and growth pos	12	200-7000	2660 (1270-4050)	2250
IgG when anginflam neg and growth neg	60	100-18000	690 (90-1290)	200
IgG when anginflam pos and growth neg	8	300-9000	3830 (1420-6240)	3750
IgG when anginflam pos and growth pos	126	100-20000	3500 (2700-4300)	1650
IgG when anginflam neg and growth pos	19	100-13000	2840 (960-4720)	1200

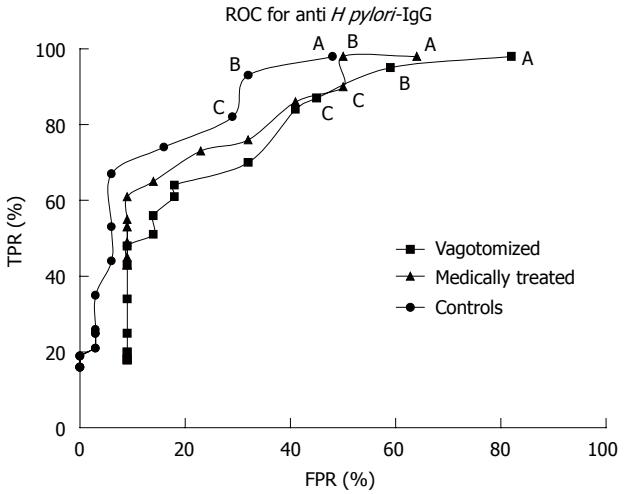

Figure 1 Receiver operating characteristic (ROC) curve for different cut-off values for *H pylori* IgG antibodies in vagotomized or medically treated peptic ulcer patients and in community controls. Cut-off values were 200, 300, 500, 600 and at intervals of 300 for IgG values above 600 to 4800. TRP = True positive rate (sensitivity), FPR = False positive rate (1-specificity). A: Cut-off 200; B: Cut-off 300; C: Cut-off 500.

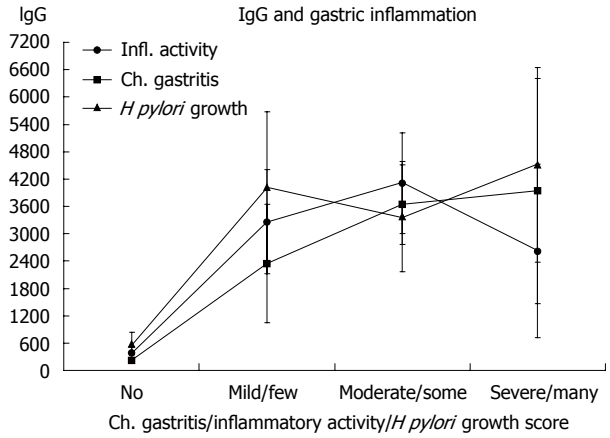

Figure 2 Grade of inflammatory activity (no, mild, moderate, severe), grade of chronic gastritis (no, mild, moderate, severe) and semiquantitative numbers of *H pylori* (no, few = *H pylori* like organisms in 1-3 pits, some = *H pylori* like organisms in more than 3 pits but not all, many = *H pylori* like organisms in all pits) detected in gastric biopsies from 4 different biopsy sites (prepylorus, angulus, corpus and fundus) related to the mean value with 95% confidence intervals of IgG antibodies against *H pylori* in each category.

the groups. The specificity of anti *H pylori* IgG and IgA were between 32%-50% among the peptic ulcer patients and 58%-71% among the controls, and far lower than C14-UBT with a specificity ranging from 80%-90% in all three groups.

When combining the sensitivity and specificity expressed by the ROC (receiver operating characteristic) curve for anti *H pylori* IgG curves for each group, the area under the curve was largest in the control group (Figure 1).

Incomplete or missing biopsies for *H pylori* detection by both histology and culture growth occurred in 14 cases (n = 230, histology HP and growth, Table 2), whereas 215 biopsies were finally included to evaluate inflammation in the angulus. Two of these had missing culture growth biopsies (n = 213, anginflam and growth, Table 2).

Anti *H pylori* IgG had a median value of 200 when the reference standard (no *H pylori* like bacteria in any of the four biopsy sites and negative culture growth) was negative. Signs of *H pylori* either by histology or by bacterial growth, or by inflammation in the angulus were associated to elevate anti *H pylori* IgG levels (Table 2). This association was dichotomous and independent of severity of active inflammation or quantitative histological evaluation of *H pylori* (Figure 2).

Increasing levels of *H pylori* IgG antibodies were associated with increasing frequency of subjects with active peptic ulcer (Figure 3). With levels of *H pylori* IgG antibodies above 1000, there was an increase in PU prevalence (P = 0.03). Still, 80% of the subjects did not have PU.

DISCUSSION

The prevalence of *H pylori* in the peptic ulcer patients was 75%-79%. This is somewhat lower than expected in peptic ulcer populations[19,20]. Among the vagotomized or medically treated patients are subjects with gastric ulcers that have a lower *H pylori* prevalence than duodenal ulcer patients have[19]. In addition, false negative *H pylori* tests or previous antibiotic treatment of other indications than *H pylori* infections might also decrease the prevalence of *H pylori* infection.

In populations with high prevalence of *H pylori* infection the test characteristics of C14-UBT are very good. While the sensitivity of the serology test is excellent too,

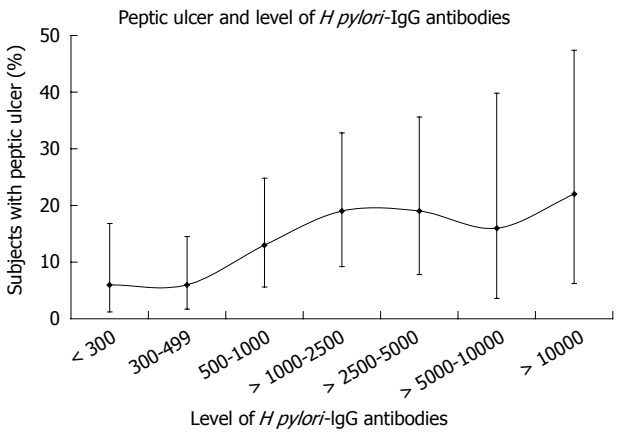

Figure 3 Subjects with peptic ulcer related to level of *H pylori* IgG antibodies. Frequencies are shown with 95% CI.

the specificity is low. The validity varies with the prevalence of *H pylori* infection, illustrating the effects of spectrum bias[21]. The test characteristics are, at best, in the control group with the lowest prevalence of *H pylori* infection. Increasing the threshold of a positive test from 300 to 500 or higher did not improve the validity of the test.

The relative low specificity of the anti *H pylori* IgG and/or IgA test indicates a high antibody titre despite no actual presence of *H pylori* in the gastric mucosa. Previous *H pylori* infection or cross-reacting antibodies from closely related bacteria might explain a positive serology test despite no actual *H pylori* infection.

Likelihood ratio is a more clinically relevant method of reporting accuracy than only specificity and sensitivity of a test. The probability of having a disease after a positive or negative test can be calculated and reveals more understandable information in the clinical setting and could also be applied to the clinical problem of dyspepsia management[22].

By comparing the true positive rate to the false positive rate, information about the probability of whether a positive test result is likely to be from a truly *H pylori* positive subject, compared to a similar result to be from a truly *H pylori* negative subject, can be obtained (positive likelihood ratio)[15]. By this method C14-UBT was about three times better than Hp serology. 13C-UBT is in full concordance with 14C-UBT and should be preferred because of its lack of radioactivity.

The low specificity reduces the clinical utility of a positive test rest result. When, among medically treated peptic ulcer group, applying the test results of a sensitivity of 98%, a specificity of 50%, and a pre-test probability of 75%, the post-test probability of a positive test barely increases to 85%, while the post-test probability of a negative test enlarges from 25% to 90%.

In 21 subjects, there were discrepancies between the results of histological identification of *H pylori* and growth of the bacteria. As culture growth is highly specific[2], and since none of the 12 subjects with negative histology and positive culture is a false positive, the sensitivity of the histology could not be 100%[16]. If there is a misclassification of the reference standard applied in this study, the direction is towards an overrating of *H pylori* positive subjects. Consequently, the test characteristics, mainly the sensitivities of serology could be somewhat underestimated.

Others have published sensitivity of 100% and specificity of 79% using the same serology Elisa-kit[23]. However, the population was on average about 10 years younger than in this study and the *H pylori* prevalence was 82%. The prevalence of *H pylori* is equivalent to our vagotomy group. While the sensitivity is comparable, the populations differ regarding the specificity of the test. The two populations could differ regarding number of case-mix, or people in North Norway might have more infections that could cross-react with *H pylori* serology kits.

An objection to this presentation is the lack of validation of the constructed cumulative scores of inflammatory activity, chronic gastritis and *H pylori* density, based on the histological Sydney System scores at the four different biopsy sites. The chronic gastritis and the subsequent atrophic changes in *H pylori* infected subjects are commonly described as antrum pre-dominant, corpus-predominant or both (pangastritis)[24]. However, the objective of this study was to detect any association between the global measurement of *H pylori* serology and the general inflammatory status of the gastric mucosa. Depending on the severity grading, according to the updated Sydney System, the antral predominant chronic gastritis would thus have a relatively high cumulative score, as the condition would be detected in the biopsies from both the pre-pylorous and from the incisura angularis. In addition to the corpus biopsy, the corpus-predominant chronic gastritis should also be reflected in the cumulative scoring system in the transition zone (incisura angularis) as much as the antrum-predominant chronic gastritis. Pangastritis would be reflected by even higher scores by summation from all four biopsy sites.

The percentage of subjects with peptic ulcers was not significantly different at various levels of *H pylori* IgG antibodies above the recommended cut-off titre value of 300. The same tests could neither differentiate between previous peptic ulcer patients and community controls, nor in the severity score of gastric inflammation measured by inflammatory activity, chronic gastritis or histologically evaluated bacterial growth.

In this study, *H pylori* IgG antibodies could not be used to differentiate between previous peptic ulcer patients and healthy community controls, nor between patients with or those without active peptic ulcers.

No association was found between the level of positive IgG titres and the cumulative scores of inflammatory activity and *H pylori* density, according to the updated Sydney System, from the four different biopsy sites in the gastric mucosa. In the clinical setting, this means that the level of positive *H pylori* titres give no diagnostic information about the degree of inflammation in the gastric mucosa, nor cannot distinguish between subjects with or those without active peptic ulceration, nor between previous peptic ulcer patients and community controls. Others have also reported that *H pylori* serology is a poor marker of peptic ulcer disease[25-28].

When using *H pylori* serology tests a negative result is of clinical importance at the recommended cut-off value of IgG titre 300, due to the high sensitivity of the test. A negative serology test result is also reported to almost rule out pre-malignant conditions in the gastric mucosa in screening situations[29]. A low specificity, however, reduces the clinical utility of a positive test result. Independent of previous peptic ulcer status among the tested subjects, *H pylori* serology and C14-UBT showed comparable sensitivity.

We could not find any association between gastric mucosal morphology and serology, in contrast to what is published by others[30]. However, in that study, a combination of serology tests were used, and a more dichotomous approach to the presence of *H pylori* infection and its morphological consequences were applied.

Uncritical use of *H pylori* serology will represent a considerable overestimation of *H pylori* prevalence in the population tested. *H pylori* serology is, on the other hand, very reliable to exclude *H pylori* infection and thereby useful in screening purposes.

ACKNOWLEDGMENTS

The authors want to thank the staff in the Department for Clinical Investigation for their excellent service to the patients and their valuable contribution in the administration of the study. We also want to thank the Department of Microbiology and Department of Pathology for expedited and high quality service of all the biopsy specimens.

COMMENTS

Background

Serology and C14-urea breath test (C14-UBT) are the most commonly used non-invasive tests of *Helicobacter pylori* (*H pylori*) infection. Knowledge about the diagnostic validity of particular serological tests is mandatory for inferring its test results. In the diagnostics of *H pylori* infection, most commercially available serological tests are reported to have both a high sensitivity and a high specificity. The diagnostic characteristics of the tests depend also on the prevalence of *H pylori* infection in the population tested. Higher prevalences would imply higher sensitivity and lower specificity.

Research frontiers

Application of test characteristics to illustrate limited value of a commonly used blood test (*H pylori* serology) for detection of *H pylori* gastric infection or peptic ulcer. However, a negative test result rule out *H pylori* infection with high certainty.

Applications

General practice and gastroenterological specialist practice.

Terminology

Sensitivity means a test ability to correctly identify a true positive subject with a positive test result (frequency of positive test or true positive rate). Specificity means a test ability to correctly identify a true negative subject with a negative test result (frequency of negative test or true negative rate).

Peer review

This retrospective study has estimated the test characteristics of *H pylori* serology and of C14-UBT in 83 vagotomized patients, 73 medically treated peptic ulcer patients and 88 gastroscoped community controls in Norway. It is helpful to know the prevalence of the infection in the area of study.

REFERENCES

1 **Basset C**, Holton J, Ricci C, Gatta L, Tampieri A, Perna F, Miglioli M, Vaira D. Review article: diagnosis and treatment of Helicobacter: a 2002 updated review. *Aliment Pharmacol Ther* 2003; **17** Suppl 2: 89-97

2 **de Boer WA**. Diagnosis of Helicobacter pylori infection. Review of diagnostic techniques and recommendations for their use in different clinical settings. *Scand J Gastroenterol Suppl* 1997; **223**: 35-42

3 **Malfertheiner P**, Megraud F, O'Morain C, Bazzoli F, El-Omar E, Graham D, Hunt R, Rokkas T, Vakil N, Kuipers EJ. Current concepts in the management of Helicobacter pylori infection: the Maastricht III Consensus Report. *Gut* 2007; **56**: 772-781

4 **Hirschl AM**, Makristathis A. Methods to detect Helicobacter pylori: from culture to molecular biology. *Helicobacter* 2007; **12** Suppl 2: 6-11

5 **Roberts AP**, Childs SM, Rubin G, de Wit NJ. Tests for Helicobacter pylori infection: a critical appraisal from primary care. *Fam Pract* 2000; **17** Suppl 2: S12-S20

6 **Richardson WS**, Wilson MC, Keitz SA, Wyer PC. Tips for teachers of evidence-based medicine: making sense of diagnostic test results using likelihood ratios. *J Gen Intern Med* 2008; **23**: 87-92

7 **Nurgalieva ZZ**, Graham DY. Pearls and pitfalls of assessing Helicobacter pylori status. *Dig Liver Dis* 2003; **35**: 375-377

8 **Yamamoto I**, Fukuda Y, Mizuta T, Fukada M, Nishigami T, Shimoyama T. Serum anti-Helicobacter pylori antibodies and gastritis. *J Clin Gastroenterol* 1995; **21** Suppl 1: S164-S168

9 **Nakata H**, Itoh H, Yokoya Y, Kawai J, Nishioka S, Miyamoto K, Kitamoto N, Miyamoto H, Tanaka T. Serum antibody against Helicobacter pylori assayed by a new capture ELISA. *J Gastroenterol* 1995; **30**: 295-300

10 **Kreuning J**, Lindeman J, Biemond I, Lamers CB. Relation between IgG and IgA antibody titres against Helicobacter pylori in serum and severity of gastritis in asymptomatic subjects. *J Clin Pathol* 1994; **47**: 227-231

11 **Lindsetmo RO**, Johnsen R, Revhaug A. Abdominal and dyspeptic symptoms in patients with peptic ulcer treated medically or surgically. *Br J Surg* 1998; **85**: 845-849

12 **Cutler AF**. Diagnostic tests for Helicobacter pylori infection. *Gastroenterologist* 1997; **5**: 202-212

13 **Stolte M**, Meining A. The updated Sydney system: classification and grading of gastritis as the basis of diagnosis and treatment. *Can J Gastroenterol* 2001; **15**: 591-598

14 **Berstad K**, Wilhelmsen I, Berstad A. Biometric evaluation of gastric urease activity in man. *Scand J Gastroenterol* 1992; **27**: 977-983

15 **Feldman RA**, Evans SJ. Accuracy of diagnostic methods used for epidemiological studies of Helicobacter pylori. *Aliment Pharmacol Ther* 1995; **9** Suppl 2: 21-31

16 **Genta RM**, Graham DY. Comparison of biopsy sites for the histopathologic diagnosis of Helicobacter pylori: a topographic study of H. pylori density and distribution. *Gastrointest Endosc* 1994; **40**: 342-345

17 **Gardner MJ**, Gardner SB, Winter PD. Confidence intervals analysis. BMJ publishing group, London: BMJ Publishing Group, 1998

18 **Dean AG**, Dean FA, Burton AH, Dicker RC. Epi Info, Version 6: A word processing, database and statistics system for epidemiology on microcomputers. USD, Stone Mountain, Georgia, 1999

19 **Marshall BJ**. Helicobacter pylori. *Am J Gastroenterol* 1994; **89**: S116-S128

20 **Bernersen B**, Johnsen R, Bostad L, Straume B, Sommer AI, Burhol PG. Is Helicobacter pylori the cause of dyspepsia? *BMJ* 1992; **304**: 1276-1279

21 **Lachs MS**, Nachamkin I, Edelstein PH, Goldman J, Feinstein AR, Schwartz JS. Spectrum bias in the evaluation of diagnostic tests: lessons from the rapid dipstick test for urinary tract infection. *Ann Intern Med* 1992; **117**: 135-140

22 **Moayyedi P**, Axon AT. The usefulness of the likelihood ratio in the diagnosis of dyspepsia and gastroesophageal reflux disease. *Am J Gastroenterol* 1999; **94**: 3122-3125

23 **van de Wouw BA**, de Boer WA, Jansz AR, Roymans RT,

Staals AP. Comparison of three commercially available enzyme-linked immunosorbent assays and biopsy-dependent diagnosis for detecting Helicobacter pylori infection. *J Clin Microbiol* 1996; **34**: 94-97

24 **Sipponen P**, Kekki M, Seppala K, Siurala M. The relationships between chronic gastritis and gastric acid secretion. *Aliment Pharmacol Ther* 1996; **10** Suppl 1: 103-118

25 **Xia HH**, Kalantar JS, Mitchell HM, Talley NJ. Can helicobacter pylori serology still be applied as a surrogate marker to identify peptic ulcer disease in dyspepsia? *Aliment Pharmacol Ther* 2000; **14**: 615-624

26 **Quartero AO**, Numans ME, de Melker RA, de Wit NJ. In-practice evaluation of whole-blood Helicobacter pylori test: its usefulness in detecting peptic ulcer disease. *Br J Gen Pract* 2000; **50**: 13-16

27 **Zuniga-Noriega JR**, Bosques-Padilla FJ, Perez-Perez GI, Tijerina-Menchaca R, Flores-Gutierrez JP, Maldonado Garza HJ, Garza-Gonzalez E. Diagnostic utility of invasive tests and serology for the diagnosis of Helicobacter pylori infection in different clinical presentations. *Arch Med Res* 2006; **37**: 123-128

28 **Weijnen CF**, Numans ME, de Wit NJ, Smout AJ, Moons KG, Verheij TJ, Hoes AW. Testing for Helicobacter pylori in dyspeptic patients suspected of peptic ulcer disease in primary care: cross sectional study. *BMJ* 2001; **323**: 71-75

29 **Storskrubb T**, Aro P, Ronkainen J, Vieth M, Stolte M, Wreiber K, Engstrand L, Nyhlin H, Bolling-Sternevald E, Talley NJ, Agreus L. A negative Helicobacter pylori serology test is more reliable for exclusion of premalignant gastric conditions than a negative test for current H. pylori infection: a report on histology and H. pylori detection in the general adult population. *Scand J Gastroenterol* 2005; **40**: 302-311

30 **Mardh E**, Mardh S, Mardh B, Borch K. Diagnosis of gastritis by means of a combination of serological analyses. *Clin Chim Acta* 2002; **320**: 17-27

S- Editor Li DL **L- Editor** Rippe RA **E- Editor** Ma WH

Online Submissions: wjg.wjgnet.com
wjg@wjgnet.com
doi:10.3748/wjg.14.5046

World J Gastroenterol 2008 August 28; 14(32): 5046-5050
World Journal of Gastroenterology ISSN 1007-9327
© 2008 The WJG Press. All rights reserved.

RAPID COMMUNICATION

Endoscopic findings in patients with upper gastrointestinal bleeding clinically classified into three risk groups prior to endoscopy

Leonardo Tammaro, Maria Carla Di Paolo, Angelo Zullo, Cesare Hassan, Sergio Morini, Sebastiano Caliendo, Lorella Pallotta

Leonardo Tammaro, Maria Carla Di Paolo, Sebastiano Caliendo, Lorella Pallotta, Gastroenterology and Digestive Endoscopy Ⅱ, "San Giovanni Addolorata" Hospital, Rome 00184, Italy
Angelo Zullo, Cesare Hassan, Sergio Morini, Gastroenterology and Digestive Endoscopy, "Nuovo Regina Margherita" Hospital, Rome 00153, Italy
Author contributions: Tammaro L and Di Paolo MC designed the research; Tammaro L, Di Paolo MC, Caliendo S and Pallotta L performed research; Zullo A and Hassan C analyzed data and wrote the paper; Morini S contributed with constructive criticisms.
Correspondence to: Dr. Angelo Zullo, Gastroenterologia ed Endoscopia Digestiva, Ospedale Nuovo Regina Margherita, Via E. Morosini, 300, Roma 00153, Italy. zullo66@yahoo.it
Telephone: +39-06-58446533 Fax: +39-06-58446608
Received: May 28, 2008 Revised: July 28, 2008
Accepted: August 4, 2008
Published online: August 28, 2008

Abstract

AIM: To investigate in a prospective study whether a simplified clinical score prior to endoscopy in upper gastrointestinal bleeding (UGIB) patients was able to predict endoscopic findings at urgent endoscopy.
METHODS: All consecutive UGIB patients referred to a single endoscopic center during a 16 mo period were enrolled. Before endoscopy patients were stratified according to a simple clinical score (T-score), including T1 (high-risk), T2 (intermediate-risk) and T3 (low-risk). Endoscopy was performed in all cases within 2 h, and high-risk stigmata were considered for further analysis.
RESULTS: Out of the 436 patients included into the study, 126 (29%) resulted to be T1, 135 (31%) T2, and 175 (40%) T3. Overall, stigmata of recent haemorrhage (SRH) were detected in 118 cases (27%). SRH occurred more frequently in T1 patients than in T2/T3 cases (85% *vs* 3.2%; χ^2 = 304.5309, P < 0.001). Older age (t = 3.311; P < 0.01) and presence of comorbidities (χ^2 = 14.7458; P < 0.01) were more frequently detected in T1 than in T2/T3 patients.
CONCLUSION: Our simplified clinical score appeared to be associated with the detection of endoscopic findings which may deserve urgent endoscopy. A further, randomised study is needed to assess its accuracy in safely scheduling endoscopy in UGIB patients.

© 2008 The WJG Press. All rights reserved.

Key words: Upper gastrointestinal bleeding; Urgent endoscopy; Timing score; Endoscopic treatment; Oesophageal varices; Peptic ulcer

Peer reviewer: Dr. Philip Abraham, Professor, Consultant Gastroenterologist & Hepatologist, P. D. Hinduja National Hospital & Medical Research Centre, Veer Savarkar Marg, Mahim, Mumbai 400016, India

Tammaro L, Di Paolo MC, Zullo A, Hassan C, Morini S, Caliendo S, Pallotta L. Endoscopic findings in patients with upper gastrointestinal bleeding clinically classified into three risk groups prior to endoscopy. *World J Gastroenterol* 2008; 14(32): 5046-5050 Available from: URL: http://www.wjgnet.com/1007-9327/14/5046.asp DOI: http://dx.doi.org/10.3748/wjg.14.5046

INTRODUCTION

Acute upper gastrointestinal bleeding (UGIB) is a very common condition, with an estimated incidence as high as 40-150 cases per 100 000 annually[1-3]. Undeniably, UGIB is a dramatic event resulting in a high mortality rate, ranging from 0.9% to 26.5%[1-4]. Moreover, it leads to 50-150 hospitalizations per 100 000 adults each year[5]. Upper gastrointestinal endoscopy plays a pivotal role in the diagnosis and therapy of these patients, reducing mortality, rebleeding, requirement for transfusion, hospital stay and health care costs[6-9]. Endoscopic haemostasis has been shown to be effective in most of the causes of UGIB, such as peptic ulcer, gastro-oesophageal varices and Mallory-Weiss lesions[8,10,11]. For this reason, urgent endoscopy is routinely provided by several hospitals both in Europe and United States. Moreover, the absence of stigmata of recent haemorrhage (SRH), such as an adherent clot or an arterial bleeding, may prompt an early discharge of the patients, resulting in substantial healthcare savings[12]. Furthermore, several scoring systems, based on clinical-

endoscopic features, have been extrapolated in order to predict the risk of rebleeding and mortality[13-17]. Specifically, haemoglobin level, hemodynamic instability, and the presence of comorbidities have been shown to be clinical variables associated with a poorer outcome. Regarding timing of urgent endoscopy, it is widely accepted that it should be performed within 24 h from the admission[18]. However, within this period of time, it is still unclear whether it should be performed either very early-i.e. within 2 h- or in a more delayed interval, such as after 6, 12 or 24 h. In particular, some retrospective series did not show a clear advantage for early versus delayed urgent endoscopy[19-22]. However, in clinical practice, the endoscopist may be expected to be called by the emergency department immediately after the hospital admission of the bleeding patient, making it his responsibility to proceed towards an immediate procedure or delaying it up to 12 or 24 h. Legal aspects are clearly entailed in this decisional process, so that, in the absence of clear data, endoscopists may be expected to rush in the endoscopic units, even in low-risk cases. This may be particularly troublesome in large hospitals in which the specialist may be repeatedly called during the night or on non-working days. Moreover, due to lack of clinical evidence, administrative parameters have been shown to be important predictors of the timing to endoscopy in UGIB, dangerously exposing similar patients to different outcomes according to the referral hospital. Therefore, optimal timing for urgent endoscopy in UGIB patients has not been yet established. The aim of this prospective study was to evaluate whether a simplified clinical score prior to endoscopy in UGIB patients was able to predict either active bleeding or SRH that may require an urgent (< 2 h) endoscopy.

MATERIALS AND METHODS

All consecutive patients referred to a single Endoscopic Unit because of an episode of UGIB during a 16 mo period were enrolled. The Endoscopic Unit belongs to a large hospital in which the physicians are urged to contact the gastroenterologist on call when patients present with an UGIB. For the purpose of the study, urgent endoscopy was always performed within 2 h from the referral. Before the procedure, patients were stratified by the endoscopists according to 4 easily assessable clinical variables, already validated in the UGIB setting: (1) general conditions (poor, intermediate, good), (2) pulse (< 90 beats/min, 90-110 beats/min, > 110 beats/min), (3) systolic blood pressure (< 90 mmHg, 90-110 mmHg, > 110 mmHg), and haemoglobin level (⩽ 8 g/dL, 9-10 g/dL, > 10 g/dL)[13-15]. General conditions were intended as a measure of the risk of an impending shock or the presence of symptomatic comorbidities (cardiovascular, hepatic, nephropathic, diabetes, malignancy). In detail, "poor condition" included patients with impending shock or with ⩾ 3 comorbities, "good condition" included patients with no debilitation and without postural hypotension and ⩽ 1 comorbidity, and "intermediate condition" those patients with conditions in the middle. As shown in Table 1, a numerical score was created for each of these parameters, the sum of all the parameters resulting in the total score (T-score) for each patient who was thereafter classified according to arbitrarily defined T-score cut-off in 3 categories. In detail, a sum ⩽ 6 corresponds to T1 (high-risk) , a sum of 7-9 to T2 (intermediate-risk), and a cumulative value ⩾ 10 to T3 (low-risk). Further clinical information were collected for data analysis. Validity of such a classification was tested according to the presence of SRH at endoscopy. In detail, SRH was defined as an adherent clot, a bleeding (oozing or spurting) or nonbleeding visible vessel[23], or gastro-oesophageal varices with active or recent signs of bleeding, such as a fibrin clot. All patients gave their informed consent prior endoscopic examination.

Table 1 Numerical values for each parameter of the clinical index adopted in the study

Clinical parameter	Score		
	1	2	3
General conditions	Poor	Intermediate	Good
Pulse (beats/min)	> 110	90-110	< 90
Systolic blood pressure (mmHg)	< 90	90-110	> 110
Haemoglobin levels (g/dL)	⩽ 8	9-10	> 10

The T-score is the sum of the corresponding values for the 4 parameters. In detail, a sum ⩽ 6 corresponds to T1 (high-risk), 7-9 to T2 (intermediate-risk), and a cumulative value ⩾ 10 to T3 (low-risk).

Statistical analysis

Data analysis was performed by using Chi-square and Student's *t*-test as appropriate, and $P < 0.05$ was considered statistically significant.

RESULTS

Overall, 436 patients (270 males, 166 females; Mean age: 65 ± 13 years) were included in the study. Regarding the setting, 126 (29%) patients were already hospitalized before the UGIB, whilst the remaining 310 (71%) had been admitted by the emergency department because of the UGIB. Major comorbidities were present in 157 patients (36%). In detail, a cardiac disease was present in 78 (18%) patients, a hepatic disease in 61 (14%) cases, a clotting impairment in 9 (2%) cases, whilst renal or neurological comorbidities were detected in the remaining 9 (2%) cases. The mean time between the request to the endoscopic unit and the performance of the urgent endoscopy was 1.6 ± 0.47 h. No death occurred before or during the endoscopic procedure itself. The main endoscopic findings are provided in Table 2. In detail, SRH were detected in 118 cases (27%), prompting an immediate endoscopic haemostasis in 105 (89%) of these cases. When classifying patients according to T-score, 126 (29%) resulted to be T1, 135 (31%) T2, and 175 (40%) T3. A SRH was detected at endoscopy in 107 (85%) T1-cases. In detail, an active bleeding (oozing or spurting) was reported in 34 (32%) T1-patients, a nonbleeding visible vessel/adherent clot was described

Table 2 Endoscopic findings and SRH detected in the study population

	Number of patients (%)
Endoscopic finding	436 cases
Duodenal ulcer	144 (33)
Gastric ulcer	74 (17)
Gastro-oesophageal varices	52 (12)
Erosive esophagitis	44 (10)
Malignancy	35 (8)
Erosive gastritis/duodenitis	80 (18)
Mallory-Weiss syndrome	7 (2)
SRH	118 cases
Active bleeding	37 (31)
Nonbleeding visible vessel	16 (14)
Adherent clot	40 (34)
Gastro-oesophageal varices with active or recent signs of bleeding	25 (21)

in 50 (47%) cases, and gastro-oesophageal varices with active or recent signs of bleeding in 24 (22%) patients. As far as T2-patients are concerned, only in 7 (5%) cases a SRH was detected, being an active bleeding in 2 cases, a nonbleeding visible vessel/adherent clot in 4 cases, and gastro-oesophageal varices in 1. Regarding the 175 patients classified as T3, a SRH was found at endoscopy only in 3 (2%) cases, being a nonbleeding visible vessel/adherent clot in 2 patients and an oozing bleeding in 1 case. When comparing the rate of SRH in T1 patients (85%) with that identified in T2 (5%) and/or T3 (2%), a significant difference emerged ($P < 0.001$). Comparison of further demographic and clinical variables is provided in Table 3. As shown, patients classified as T1 were older (69 *vs* 63 and 64 years; $t = 3.311$ and 3.443, respectively; $P < 0.01$) and more frequently had comorbidities (49% *vs* 20% and 31%; $\chi^2 = 14.7458$ and 13.4355, respectively; $P < 0.01$) than T2 and T3 patient groups.

DISCUSSION

UGIB incidence may be expected to increase as the proportion of elderly people in the population rises, because of the higher prevalence of gastroduodenal diseases in this subgroup of people[24], particularly those NSAID associated[1,25]. Indeed, NSAIDs are widely used in clinical practice and they are the most relevant cause of UGIB[1,2,26], and recent data suggested that even selective COX-2 inhibitors are not risk free[27]. Undeniably, UGIB has a relevant economic impact[28]. Therefore, optimizing an urgent endoscopy setting is of a paramount importance. Indeed, upper endoscopy plays a pivotal role in UGIB diagnosis and treatment[29]. However, although it is widely accepted that urgent endoscopy should be performed within 24 h, the best timing is still unclear[18]. In the present study, we evaluated whether a simplified clinical score prior to endoscopy in UGIB patients was able to predict either active bleeding or SRH that may require an urgent (< 2 h) endoscopy. Our data found that within 24 h, different timing of urgent endoscopy for UGIB may

Table 3 Demographical and clinical characteristics of the UGIB patients according to T-score classes

Variable	T1 (n = 126)	T2 (n = 135)	T3 (n = 175)	P
Mean age ± SD (yr)	69 ± 13	63 ± 16	64 ± 12	< 0.01[1]
Male sex (%)	66	62	60	NS
Comorbidities (%)	49	20	31	< 0.01[1]
Systolic blood pressure (mmHg)	85 ± 15	106 ± 22	139 ± 37	< 0.01[2]
Hemoglobin level (g/dL)	7.2 ± 1.3	9.7 ± 2.3	13.8 ± 3	< 0.01[2]

[1]T1 *vs* T2 or T3; [2]T1 *vs* T2 or T3 and T2 *vs* T3.

be proposed. In particular, urgent endoscopy may provide a therapeutic resource for most of the patients in severe clinical conditions (T1 score), whilst it does not appear to be necessary in those patients with more favourable conditions (T2/T3 score). Although there was no evidence of a better clinical outcome-i.e. rebleeding and mortality-after a very early endoscopy in some retrospective series[19-22], our study shows that endoscopic therapy is necessary in most of the clinically severe cases. Since an effective endoscopic haemostasis has been associated with a better outcome for both variceal and non-variceal UGIB[8,9], it may be conservatively advised to perform a very early endoscopy, at least in patients in more severe conditions. Moreover, endoscopy may be also useful to stratify these compromised patients, since endoscopic SRH have been shown to predict the UGIB-associated morbidity and mortality[13]. On the other hand, our prospective study clearly shows that urgent endoscopy is useless in the vast majority of those patients in intermediate or good clinical conditions, which account for more than two thirds of all UGIB patients, since only a very few of them really gain some benefit from the endoscopic procedure. Due to the relatively stable clinical conditions, it is foreseeable that even in those few patients with SHR, a delay in the urgent endoscopy to 12 h, sufficient to postpone the endoscopy procedure from the night to the immediate following day endoscopic routine list, would have not changed the overall outcome. Our study suggests that the use of a simple clinical score may predict endoscopic SRH in UGIB patients. In particular, to our knowledge, this is the first time that a simple clinical score has been associated with endoscopic findings at urgent endoscopy in a prospective series. This points out that clinical parameters are not only useful in selecting those who may need an urgent endoscopy from those who may not, but also in selecting, among those who need it, those who need a very early procedure. On the other hand, upper endoscopy in T2/T3 score patients may be delayed until the next routine endoscopic list, in which a more suitable setting, i.e. either a more skilled endoscopist or a prolonged pre-endoscopic proton pump inhibitor therapy may result in a better outcome[29,30]. Importantly, no death occurred before endoscopy and in the endoscopic setting, supporting the safety of a very early endoscopy even in severe patients, although previous series described

higher cardiovascular complications as compared to more delayed procedures[21]. Although urgent endoscopy is usually defined as a within 24 h-procedure[18], legal aspects may be raised against the on-call physician who prefers a delayed approach, when severe complications or even mortality associated to the UGIB episode occur before endoscopy. For this reason, endoscopists generally prefer to anticipate more than to delay an emergency procedure. We feel that our study allows an immediate and user-friendly clinical stratification, allowing less severe patients to be postponed until the next morning. Some limitations are entailed in the present study. In particular, we did not assess the rebleeding rate and the associated mortality in the post-endoscopic period. Nevertheless, SRH's have been shown to be intimately related with these outcomes, and may therefore be regarded as valid intermediate surrogates. However, further studies specifically addressing these end-points, namely rebleeding rate and associated mortality, are needed before proposing the use of such a pre-endoscopic score in clinical practice. In particular, we cannot exclude that even severe UGIB episodes may be only of marginal clinical interest in patients affected by severe comorbidities, such as renal failure. Moreover, it would be important to further validate in future studies our score with others already available in the literature. Secondly, we did not apply different timings (very early *versus* delayed) in T2/T3 patients. However, after these findings, we feel clinically meaningful to plan a further study in which different timings will be tailored according to clinical conditions. Thirdly, we may not exclude that if the urgent endoscopy had been performed later than 2 h, but still within 24 h, the rate of SRH would have been different. However, it is unlikely that such a wide difference between T1, on one side, and T2 and T3, on the other, would have been significantly affected. Fourthly, we applied our score also to oesophageal variceal bleeding. However, as soon as these patients are correctly diagnosed with the underlying liver disease, they should have a prompt endoscopy, irrespective of the severity of the bleeding.

In conclusion, our study shows that timing of urgent endoscopy following an episode of UGIB could be differentiated according to a simple score purely reflecting the clinical conditions of the patients. This would allow most of the patients with SRH to be effectively treated, whilst delaying most of the purely diagnostic procedures in low risk clinical patients. A future, randomized study is required to validate this clinical score.

COMMENTS

Background

Acute upper gastrointestinal bleeding (UGIB) is a very common condition, with an incidence of 40-150 cases per 100 000, resulting in high hospitalization and mortality rates. Upper gastrointestinal endoscopy plays a major role in the diagnosis and therapy of these patients, reducing mortality, rebleeding, requirement for transfusion, hospital stay and health care costs. It is widely accepted that urgent endoscopy for UGIB should be performed within 24 h from the admission. However, within this period of time, it is still unclear whether it should be performed either very early, i.e. within 2 h, or in a more delayed interval, such as after 6, 12 or 24 h. Therefore, optimal timing for urgent endoscopy in UGIB patients has not been yet established.

Research frontiers

A simple clinical score prior to endoscopy, purely based on general conditions, pulse and haemoglobin level, was strongly associated with the detection of active bleeding or stigmata of recent hemorrhage. When classifying 436 patients according to this score (T-score), active bleeding or signs of recent hemorrhage was detected in 85% of T1 (most severe) patients and only in 5% and 2% of those T2/T3 (less severe), respectively.

Innovations and breakthroughs

This study shows that timing of urgent endoscopy following an episode of UGIB may be differentiated according to a simple score purely reflecting the clinical conditions of the patients. This would allow most of the high-risk patients to be effectively treated, whilst delaying most of the purely diagnostic procedures in low risk clinical patients. A future, randomized study is required to validate this clinical score.

Peer review

This is an interesting study that attempts to stratify the urgency for upper GI endoscopy in a patient presenting with acute bleeding. The choice of the "clinical" parameters and the cut-off values chosen are empiric.

REFERENCES

1 **Ibanez L**, Vidal X, Vendrell L, Moretti U, Laporte JR. Upper gastrointestinal bleeding associated with antiplatelet drugs. *Aliment Pharmacol Ther* 2006; **23**: 235-242

2 **Lanas A**, Perez-Aisa MA, Feu F, Ponce J, Saperas E, Santolaria S, Rodrigo L, Balanzo J, Bajador E, Almela P, Navarro JM, Carballo F, Castro M, Quintero E. A nationwide study of mortality associated with hospital admission due to severe gastrointestinal events and those associated with nonsteroidal antiinflammatory drug use. *Am J Gastroenterol* 2005; **100**: 1685-1693

3 **Palmer K**. Acute upper gastrointestinal haemorrhage. *Br Med Bull* 2007; **83**: 307-324

4 **Sandel MH**, Kolkman JJ, Kuipers EJ, Cuesta MA, Meuwissen SG. Nonvariceal upper gastrointestinal bleeding: differences in outcome for patients admitted to internal medicine and gastroenterological services. *Am J Gastroenterol* 2000; **95**: 2357-2362

5 **Wolfe MM**, Lichtenstein DR, Singh G. Gastrointestinal toxicity of nonsteroidal antiinflammatory drugs. *N Engl J Med* 1999; **340**: 1888-1899

6 **Church NI**, Dallal HJ, Masson J, Mowat NA, Johnston DA, Radin E, Turner M, Fullarton G, Prescott RJ, Palmer KR. Validity of the Rockall scoring system after endoscopic therapy for bleeding peptic ulcer: a prospective cohort study. *Gastrointest Endosc* 2006; **63**: 606-612

7 **Zappa M**, Visioli CB, Ciatto S, Grazzini G, Rubeca T, Bonanomi AG, Confortini M, Paci E, Castiglione G. Gastric cancer after positive screening faecal occult blood testing and negative assessment. *Dig Liver Dis* 2007; **39**: 321-326

8 **Manner H**, May A, Faerber M, Rabenstein T, Ell C. Safety and efficacy of a new high power argon plasma coagulation system (hp-APC) in lesions of the upper gastrointestinal tract. *Dig Liver Dis* 2006; **38**: 471-478

9 **Thomopoulos K**, Theocharis G, Mimidis K, Lampropoulou-Karatza Ch, Alexandridis E, Nikolopoulou V. Improved survival of patients presenting with acute variceal bleeding. Prognostic indicators of short- and long-term mortality. *Dig Liver Dis* 2006; **38**: 899-904

10 **Barkun A**, Sabbah S, Enns R, Armstrong D, Gregor J, Fedorak RN, Rahme E, Toubouti Y, Martel M, Chiba N, Fallone CA. The Canadian Registry on Nonvariceal Upper Gastrointestinal Bleeding and Endoscopy (RUGBE): Endoscopic hemostasis and proton pump inhibition are associated with improved outcomes in a real-life setting. *Am J Gastroenterol* 2004; **99**: 1238-1246

11 **Sacks HS**, Chalmers TC, Blum AL, Berrier J, Pagano D.

Endoscopic hemostasis. An effective therapy for bleeding peptic ulcers. *JAMA* 1990; **264**: 494-499
12 **Lee JG**, Turnipseed S, Romano PS, Vigil H, Azari R, Melnikoff N, Hsu R, Kirk D, Sokolove P, Leung JW. Endoscopy-based triage significantly reduces hospitalization rates and costs of treating upper GI bleeding: a randomized controlled trial. *Gastrointest Endosc* 1999; **50**: 755-761
13 **Rockall TA**, Logan RF, Devlin HB, Northfield TC. Risk assessment after acute upper gastrointestinal haemorrhage. *Gut* 1996; **38**: 316-321
14 **Blatchford O**, Murray WR, Blatchford M. A risk score to predict need for treatment for upper-gastrointestinal haemorrhage. *Lancet* 2000; **356**: 1318-1321
15 **Camellini L**, Merighi A, Pagnini C, Azzolini F, Guazzetti S, Scarcelli A, Manenti F, Rigo GP. Comparison of three different risk scoring systems in non-variceal upper gastrointestinal bleeding. *Dig Liver Dis* 2004; **36**: 271-277
16 **Bessa X**, O'Callaghan E, Balleste B, Nieto M, Seoane A, Panades A, Vazquez DJ, Andreu M, Bory F. Applicability of the Rockall score in patients undergoing endoscopic therapy for upper gastrointestinal bleeding. *Dig Liver Dis* 2006; **38**: 12-17
17 **Rockall TA**. Risk scoring in acute upper gastrointestinal haemorrhage. *Dig Liver Dis* 2006; **38**: 10-11
18 **Barkun A**, Bardou M, Marshall JK. Consensus recommendations for managing patients with nonvariceal upper gastrointestinal bleeding. *Ann Intern Med* 2003; **139**: 843-857
19 **Lin HJ**, Wang K, Perng CL, Chua RT, Lee FY, Lee CH, Lee SD. Early or delayed endoscopy for patients with peptic ulcer bleeding. A prospective randomized study. *J Clin Gastroenterol* 1996; **22**: 267-271
20 **Yen D**, Hu SC, Chen LS, Liu K, Kao WF, Tsai J, Chern CH, Lee CH. Arterial oxygen desaturation during emergent nonsedated upper gastrointestinal endoscopy in the emergency department. *Am J Emerg Med* 1997; **15**: 644-647
21 **Lee CT**, Huang SP, Cheng TY, Chiang TH, Tai CM, Su WC, Huang CH, Lin JT, Wang HP. Factors associated with myocardial infarction after emergency endoscopy for upper gastrointestinal bleeding in high-risk patients: a prospective observational study. *Am J Emerg Med* 2007; **25**: 49-52
22 **Tai CM**, Huang SP, Wang HP, Lee TC, Chang CY, Tu CH, Lee CT, Chiang TH, Lin JT, Wu MS. High-risk ED patients with nonvariceal upper gastrointestinal hemorrhage undergoing emergency or urgent endoscopy: a retrospective analysis. *Am J Emerg Med* 2007; **25**: 273-278
23 **Forrest JA**, Finlayson ND, Shearman DJ. Endoscopy in gastrointestinal bleeding. *Lancet* 1974; **2**: 394-397
24 **Pilotto A**. Aging and the gastrointestinal tract. *Ital J Gastroenterol Hepatol* 1999; **31**: 137-153
25 **Zullo A**, Hassan C, Campo SM, Morini S. Bleeding peptic ulcer in the elderly: risk factors and prevention strategies. *Drugs Aging* 2007; **24**: 815-828
26 **Chan FK**, Graham DY. Review article: prevention of non-steroidal anti-inflammatory drug gastrointestinal complications--review and recommendations based on risk assessment. *Aliment Pharmacol Ther* 2004; **19**: 1051-1061
27 **Lanas A**, Garcia-Rodriguez LA, Arroyo MT, Gomollon F, Feu F, Gonzalez-Perez A, Zapata E, Bastida G, Rodrigo L, Santolaria S, Guell M, de Argila CM, Quintero E, Borda F, Pique JM. Risk of upper gastrointestinal ulcer bleeding associated with selective cyclo-oxygenase-2 inhibitors, traditional non-aspirin non-steroidal anti-inflammatory drugs, aspirin and combinations. *Gut* 2006; **55**: 1731-1738
28 **Marshall JK**, Collins SM, Gafni A. Prediction of resource utilization and case cost for acute nonvariceal upper gastrointestinal hemorrhage at a Canadian community hospital. *Am J Gastroenterol* 1999; **94**: 1841-1846
29 **Parente F**, Anderloni A, Bargiggia S, Imbesi V, Trabucchi E, Baratti C, Gallus S, Bianchi Porro G. Outcome of non-variceal acute upper gastrointestinal bleeding in relation to the time of endoscopy and the experience of the endoscopist: a two-year survey. *World J Gastroenterol* 2005; **11**: 7122-7130
30 **Keyvani L**, Murthy S, Leeson S, Targownik LE. Pre-endoscopic proton pump inhibitor therapy reduces recurrent adverse gastrointestinal outcomes in patients with acute non-variceal upper gastrointestinal bleeding. *Aliment Pharmacol Ther* 2006; **24**: 1247-1255

S- Editor Li DL **L- Editor** Li M **E- Editor** Yin DH

Online Submissions: wjg.wjgnet.com
wjg@wjgnet.com
doi:10.3748/wjg.14.5051

World J Gastroenterol 2008 August 28; 14(32): 5051-5058
World Journal of Gastroenterology ISSN 1007-9327
© 2008 The WJG Press. All rights reserved.

RAPID COMMUNICATION

Colonoscopy evaluation after short-term anti-tuberculosis treatment in nonspecific ulcers on the ileocecal area

Young Sook Park, Dae Won Jun, Seong Hwan Kim, Han Hyo Lee, Yun Ju Jo, Moon Hee Song, Nam In Kim, Jun Seok Lee

Young Sook Park, Dae Won Jun, Seong Hwan Kim, Han Hyo Lee, Yun Ju Jo, Moon Hee Song, Nam In Kim, Jun Seok Lee, Department of Internal Medicine, Eulji University School of Medicine, Eulji Medical Center, Seoul 139-711, South Korea
Author contributions: Park YS, Kim SH, Lee HH, Jo YJ, and Song MH designed and performed research; Park YS, Jun DW, Kim NI, and Lee JS analyzed data; and Park YS wrote the paper.
Correspondence to: Young Sook Park, MD, PhD, Director of Internal Medicine and Gastroenterology, Department of Internal Medicine, Eulji University School of Medicine, Eulji Medical Center, 280-1, Hagye 1 dong, Nowon-Gu, Seoul 139-711, South Korea. pys1109@eulji.ac.kr
Telephone: +82-2-9708207 Fax: +82-2-9708621
Received: March 23, 2008 Revised: August 6, 2008
Accepted: August 15, 2008
Published online: August 28, 2008

Abstract

AIM: To evaluate the efficacy of colonoscopy follow-up after short-term anti-tuberculosis treatment in patients with nonspecific ulcers on ileocecal areas being suspicious of tuberculous colitis.
METHODS: We prospectively analyzed the colonoscopic findings before and after short term anti-tuberculosis treatment in 18 patients with nonspecific ulcers on the ileocecal area and compared them with 7 patients of confirmed tuberculous colitis by acid-fast bacilli or caseating granuloma on colonic biopsy.
RESULTS: Mean duration for short-term follow-up was 107.3 d with combined chemotherapy containing isoniazid, rifampicin, ethambutol and pyrazinamide. Seven patients with tuberculous colitis showed complete healing of active ulcers after short-term medication. After short-term anti-tuberculosis treatment, follow-up colonoscopy findings divided 18 patients with nonspecific ulcers into two groups by ulcer state. One is the "suspicious tuberculous colitis group" showing healing of ulcers and erosions and another is the "suspicious inflammatory bowel disease group" showing active ulcers with or without aggravation of the lesion. Finally, all 9 of the "suspicious tuberculous colitis group" were diagnosed as tuberculous colitis showing no recurrence of ulcers after termination of 9 mo of anti-tuberculosis medication. Patients of the "suspicious inflammatory bowel disease group" were finally diagnosed as Crohn's disease or nonspecific colonic ulcers during long-term follow up.
CONCLUSION: Follow-up colonoscopy shows a healing stage ulcer or scarring change without an active ulcer with just 2 mo to 3 mo of medication in patients with tuberculous colitis. Colonoscopy follow-up after short term anti-tuberculosis trial in patients with nonspecific ulcers on the ileocecal area is valuable in making early differential diagnosis of tuberculous colitis.

© 2008 The WJG Press. All rights reserved.

Key words: Colonoscopy; Short-term; Anti-tuberculosis medication; Tuberculous colitis; Ileocecal ulcer

Peer reviewer: Otto Schiueh-Tzang Lin, MD, C3-Gas, Gastroenterology Section, Virginia Mason Medical Center, 1100 Ninth Avenue, Seattle, WA 98101, United States

Park YS, Jun DW, Kim SH, Lee HH, Jo YJ, Song MH, Kim NI, Lee JS. Colonoscopy evaluation after short-term anti-tuberculosis treatment in nonspecific ulcers on the ileocecal area. *World J Gastroenterol* 2008; 14(32): 5051-5058 Available from: URL: http://www.wjgnet.com/1007-9327/14/5051.asp DOI: http://dx.doi.org/10.3748/wjg.14.5051

INTRODUCTION

Worldwide incidence of abdominal tuberculosis has been steadily increasing for the past 20 years[1-4], and 2%-3% of reported patients with abdominal tuberculosis have isolated colonic involvement[5]. Particularly in Asia, pulmonary and extrapulmonary tuberculosis have been rare until now. Although both the incidence and prevalence rates of inflammatory bowel disease (IBD) are still relatively low compared to Europe and North America, they are increasing rapidly in many Asian countries, including Korea[6].

Difficult colonoscopic differentiation between tuberculous colitis and Crohn's colitis is caused when both entities can present themselves with mucosal ulcerations and nodularity, aphthous ulcers, edematous mucosal folds, strictures, pseudopolyps and luminal narrowing on the ileocecal area[7].

Although caseating granulomas and acid-fast bacilli

make it easy to differentiate the disease entity, many nonspecific ulcers on the ileocecal area in patients with chronic diarrhea and right lower quadrant pain do not provide confirmative diagnosis between tuberculous colitis and other inflammatory bowel diseases.

Therapeutic trial of anti-tuberculosis treatment has been accepted in the case of high clinical suspicion of tuberculosis, which should be continued if there is a good clinical response[8]. Sometimes clinical response is not correlated with disease itself. Generally 9 mo to 12 mo of anti-tuberculous medication is necessary for tuberculous colitis. In patients with IBD, disease will be more aggravated during that long-term therapeutic trial. The clinician needs a diagnostic tool confirming tuberculous colitis as early as possible. The precise colonoscopic features after 2 mo to 3 mo of short-term medication in patients with either tuberculous colitis or suspicious tuberculous colitis have not been documented. Thus, we prospectively evaluated the colonoscopic findings after short-term anti-tuberculosis treatment both in patients with nonspecific ulcers on the ileocecal area and in patients with confirmed tuberculous colitis.

MATERIALS AND METHODS

Patients

This prospective case-control study was conducted at the Medical Center of Eulji University, from March 2002 to October 2004. Eighteen patients (6 males and 12 females) with chronic diarrhea or right lower abdominal discomfort and showing nonspecific ulcers on the ileocecal area on initial colonoscopy were enrolled. The definition of nonspecific ulcer in this study is colonic ulcer with chronic active inflammation without caseating granuloma on biopsy. As a control, we evaluated colonoscopic features of 7 patients with tuberculous colitis who had either acid-fast bacilli or caseating granuloma on colonic biopsy combined with active pulmonary tuberculosis.

Patients with less than 3 wk of symptoms combined with perianal lesion or skipped lesion on either the left side of the colon or proximal small bowel were excluded. Stool exam and culture studies were performed to exclude any parasites and bacterial infection. The anti-tuberculosis medication trial proceeded after full and informed consent was granted by each patient.

Methods

One expert colonoscopist, with more than 10 years experience, performed the colonoscopies throughout this study. Colonoscopy was performed with videocolonoscopes (CF240L, Olympus, Japan) after 4 L polyethylene glycol preparation. The whole colon from rectum to cecal base and terminal ileum was photographed for comparison. Chest X-ray and small bowel double-contrast barium study were performed before medication for evaluation of small bowel lesion and pulmonary lesion. During anti-tuberculous medication, liver function test results, clinical symptoms and follow-up chest X-ray were regularly evaluated.

To determine the patient's susceptibility to drug, we regularly evaluated the tolerance, upper GI symptoms and allergic symptoms relating to medication on outpatient care. "Very good" meant "no complaints during medication; no side effects", "good" meant "some complaints after taking medication", "poor" meant "difficulty in taking medication" due to GI trouble or side effects.

The regimen for tuberculosis was combined chemotherapy containing isoniazid, rifampicin, ethambutol and pyrazinamide.

Study design

The follow-up colonoscopy was performed after 2-3 mo of anti-tuberculosis medication on all enrolled patients by the aforementioned colonoscopist, and some of the features evaluated were ulcer shape, number and location. Compared with colonoscopic features of patients with tuberculous colitis, we subdivided the patients with nonspecific ulcers into either a "suspicious tuberculous colitis group" or "suspicious inflammatory bowel disease (IBD) group". If there were healing of active ulcers similar to tuberculous colitis on follow-up colonoscopy findings, the patients were classified as "suspicious tuberculous colitis group", and if there were still active ulcers or extension of the lesion, classified as "suspicious IBD group". Finally, we confirmed tuberculous colitis by complete resolution of the whole lesion and clinical symptoms after 10 mo of anti-tuberculosis treatment in the "suspicious tuberculous colitis group". For the "suspicious IBD group", we stopped anti-tuberculosis treatment after a short-term trial and reevaluated.

The human subject committee of our hospital approved this study.

Statistical analysis

Kruskal-Wallis tests (three groups) were used for intergroup comparison of continuous variables, whereas Fisher exact tests were used to compare the categorical variables. Continuous variables are summarized as median ± SD, whereas categorical variables are summarized as counts or percentages. Statistical analysis was performed with SPSS 11.0 software.

RESULTS

Clinical findings

All enrolled patients were performed follow-up colonoscopy after short-term anti-tuberculosis treatment. The mean duration of the trial was 107.3 (62-120) d.

Clinical features for enrolled patients are summarized in Table 1. The median age of patients in the "suspicious IBD group" was younger than patients in the "tuberculous colitis group" or "suspicious tuberculous colitis group". Active lesion or old pulmonary lesion on chest X-ray was significant in helping the diagnosis of tuberculous colitis ($P < 0.001$). On laboratory findings, there are no specific differences between groups.

Table 1 Clinical characteristics

Group	Tbc colitis (*n* = 7)	Nonspecific ulcers (*n* = 18)		P^1
		Suspicious tbc colitis (*n* = 9)	Suspicious IBD (*n* = 9)	
M/F	4/3	2/7	4/5	NS
Median age (yr)	40.1	44.1	28.1	0.03
Chest X-ray (%)				
Active pulmonary tbc	5 (71.4)	3 (33.3)	0 (0)	
Old pulmonary tbc	0 (0)	2 (22.2)	0 (0)	< 0.001
Normal	2 (28.6)	4 (44.4)	9 (100)	
Lab finding (%)				
ESR rise	7 (100)	8 (88.9)	9 (100)	NS
pANCA (+/-)	Not check	Not check	1/8 (11.1/88.9)	
Small bowel lesion (%)				
No lesion	4 (57.1)	4 (44.4)	3 (33.3)	
Jejunum	0 (0)	0 (0)	0 (0)	
Prox. ileum	0 (0)	0 (0)	1 (11.1)	NS
Terminal ileum	3 (42.9)	5 (55.5)	6 (66.7)	
Anal & rectal lesion (%)	0 (0)	0 (0)	0 (0)	

NS: Not significant. [1]Significant at $P < 0.05$ by Fisher's exact test and Kruskall-Wallis test.

Table 2 Colonoscopy features before anti-tuberculosis medication trial

Group	Tbc colitis (*n* = 7)	Nonspecific ulcers (*n* = 18)		P^1
		Suspicious tbc colitis (*n* = 9)	Suspicious IBD (*n* = 9)	
Location of lesion (%)				
Terminal ileum	3 (42.9)	5 (55.6)	6 (66.7)	NS
IC valve	5 (71.4)	8 (88.9)	7 (77.8)	NS
Cecum	2 (28.6)	2 (22.2)	5 (55.6)	NS
Prox. Ascending colon	6 (85.7)	6 (66.7)	6 (66.7)	NS
Shape of lesion				
Geographic ulcer	3 (42.9)	2 (22.2)	2 (22.2)	NS
Irregular ulcer	1 (14.3)	3 (33.3)	5 (55.6)	NS
Aphthous ulcer	0 (0)	2 (22.2)	6 (66.7)	0.01
Transverse ulcer	3 (42.6)	2 (22.2)	2 (22.2)	NS
Stenosis	2 (28.6)	1 (11.1)	2 (22.2)	NS
Pathology (%)				
Granuloma	2 (28.6)	3 (28.0)	4 (44.4)	NS
Caseating granuloma	4 (57.1)	0 (0)	0 (0)	0.01
Acid fast bacilli+	3 (21.7)	0 (0)	0 (0)	0.01
Non-specific inflammation	0 (0)	6 (66.7)	5 (55.6)	0.02

NS: Not significant. [1]Significant at $P < 0.05$ by Fisher's exact test.

Serologic results of patients with nonspecific ulcers are not so helpful in diagnosis. On small bowel study, there are no significant differences between groups. All of the enrolled patients had no ano-rectal symptoms or any other Upper GI tract lesion.

Colonoscopy findings

Initial Colonoscopy findings before anti-tuberculosis medication are summarized in Table 2. Ulcers were located at the ileocecal valve, cecum, proximal ascending colon and terminal ileum in both groups. There were no rectal and perianal lesion in enrolled patients initially. Ulcers showed geographic, irregular shape and sometimes-transverse array. Significantly, aphthous ulcers were common in the "suspicious IBD group" ($P = 0.01$). About 30% of patients in each group showed non-caseating granuloma on biopsy. Acid-fast bacilli were noted in only 3 patients of tuberculous colitis even though this is definite evidence of tuberculosis infection.

Table 3 Follow-up colonoscopy results and feasibility to anti-tuberculosis

Group	Tbc colitis (*n* = 7)	Nonspecific ulcers (*n* = 18)		P^1
		Suspicious tbc colitis (*n* = 9)	Suspicious IBD (*n* = 9)	
Active ulcer	0/7	0/9	9/9	< 0.001
Improvement of stenosis	2/2	0/1	0/2	NS
No. of inflammatory polyps	Increase	Increase	Increase	NS
Extent of lesion	Decrease	Decrease	Increase	0.01
Feasibility to drug (%)				0.01
Very good	5 (71.4)	4 (44.4)	0 (0)	
Good	2 (28.6)	5 (55.6)	5 (55.6)	
Poor	0 (0)	0 (0)	4 (44.4)	

NS: Not significant. [1]Significant at $P < 0.05$ by Fisher's exact test.

The follow-up colonoscopy features are summarized in Table 3. After short-term anti-tuberculosis medication, there are only scarring and inflammatory polyps remained in patients with tuberculous colitis (Figure 1).

Nine of 18 patients with nonspecific ulcers also showed dramatic response after short-term trial similar to patients with tuberculous colitis presenting no active ulcer or erosions, irrespective of initial lesion (Figure 2, $P < 0.001$). We regarded them as the "suspicious tuberculous colitis group" and maintained anti-tuberculosis treatment for 10 mo.

The extent of lesion and stenosis in "tuberculous colitis" and "suspicious" groups were also improved, except in one patient of the "suspicious tuberculous colitis group" who underwent ileocecectomy due to obstruction during short-term anti-tuberculosis treatment.

Another 9 patients of nonspecific ulcers who showed active ulcers remaining and sometimes more aggravated after trial ($P < 0.001$) were regarded as the "suspicious IBD group".

Some patients of the "suspicious IBD group" showed an expansion of the extent of involved colon with aggravation of stenosis (Figures 3 and 4).

Feasibility of anti-tuberculosis treatment

Most of the patients in the "suspicious tuberculous colitis group" showed good tolerance of anti-tuberculosis treatment during the trial, some of the patients in the "suspicious IBD group" showed poor tolerance of anti-tuberculosis treatment ($P = 0.01$, Table 3). But more than half of the "suspicious IBD group" also showed good toleration and mild symptomatic improvement in spite of aggravating colonoscopic findings.

Clinical outcome

The 9 patients of the "suspicious tuberculous colitis

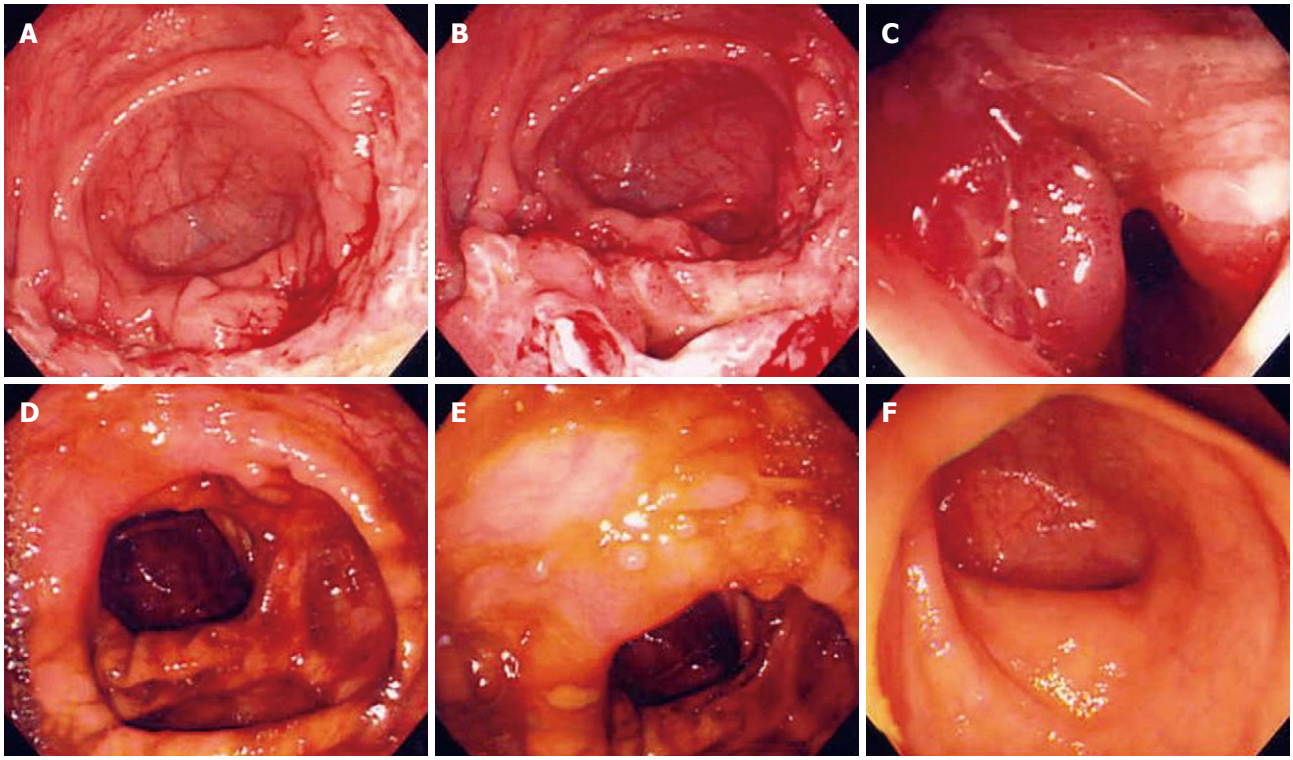

Figure 1 Colonoscopy findings before (**A-C**) and after (**D-F**) anti-tuberculosis medication in a 30-year-old male patient with tuberculous colitis on the ileocecal valve which shows acid-fast bacilli on biopsy. After medication, scar and inflammatory polyps were noted.

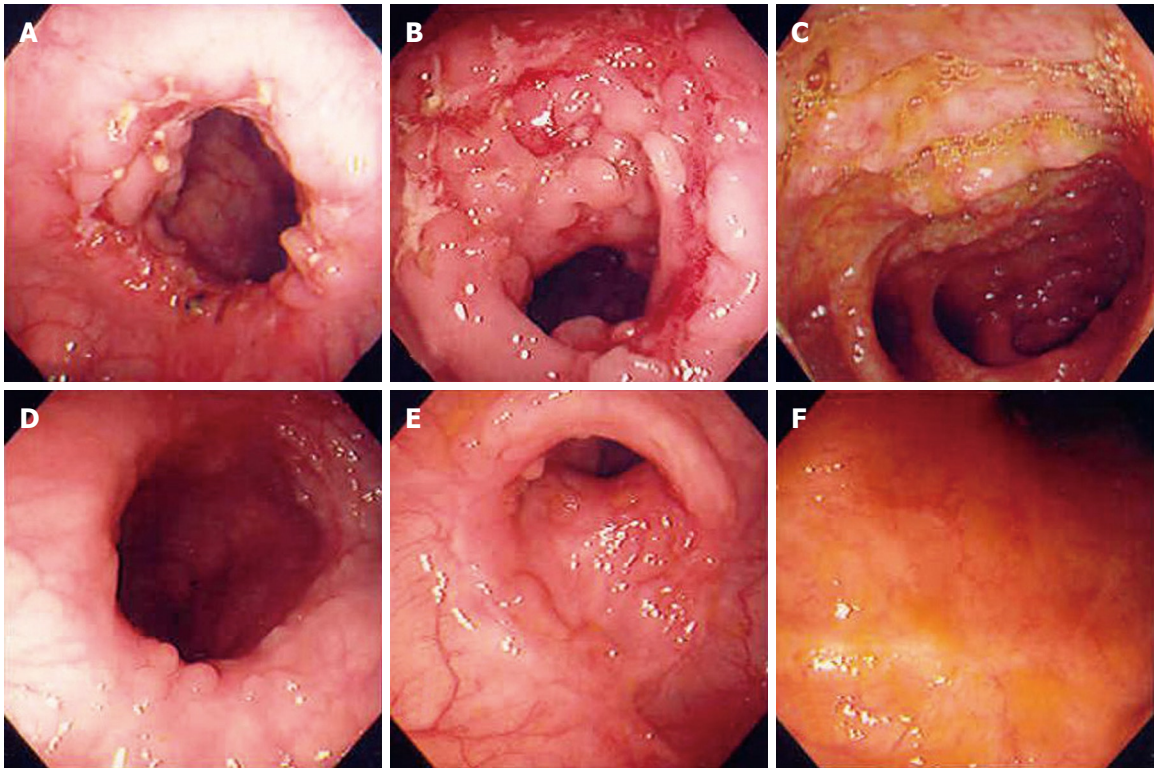

Figure 2 Colonoscopy findings before (**A-C**) and after (**D-F**) anti-tuberculosis treatment in a 37-year-old female patient. It showed transverse arrayed geographic ulcers on ileocecal valve with granuloma on biopsy and presented nodularity on terminal ileum. After medication, only healing stage ulcers were left. We classified this case as "suspicious tuberculous colitis group".

group" showed weight gain and general improvement in well being along with complete resolution of the whole lesion and GI symptoms after 10-mo of anti-tuberculosis treatment. They were therefore finally confirmed as tuberculous colitis.

The 9 patients in the "suspicious IBD group" who had

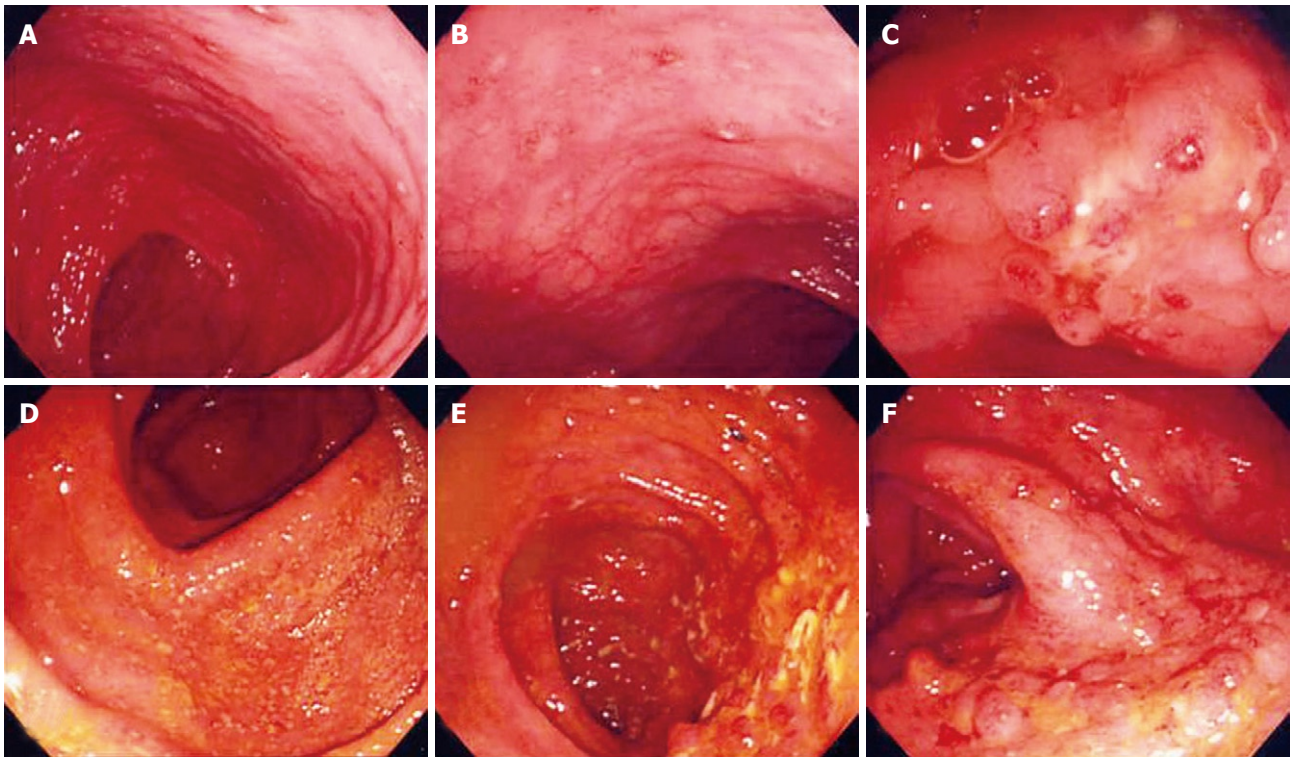

Figure 3 Colonoscopy findings before (**A-C**) and after (**D-F**) anti-tuberculosis treatment in a 23-year-old male patient with aphthous ulcers on the proximal ascending colon. After medication it shows aggravating active ulcers and extension of the lesion. We classified this case as the "suspicious IBD group".

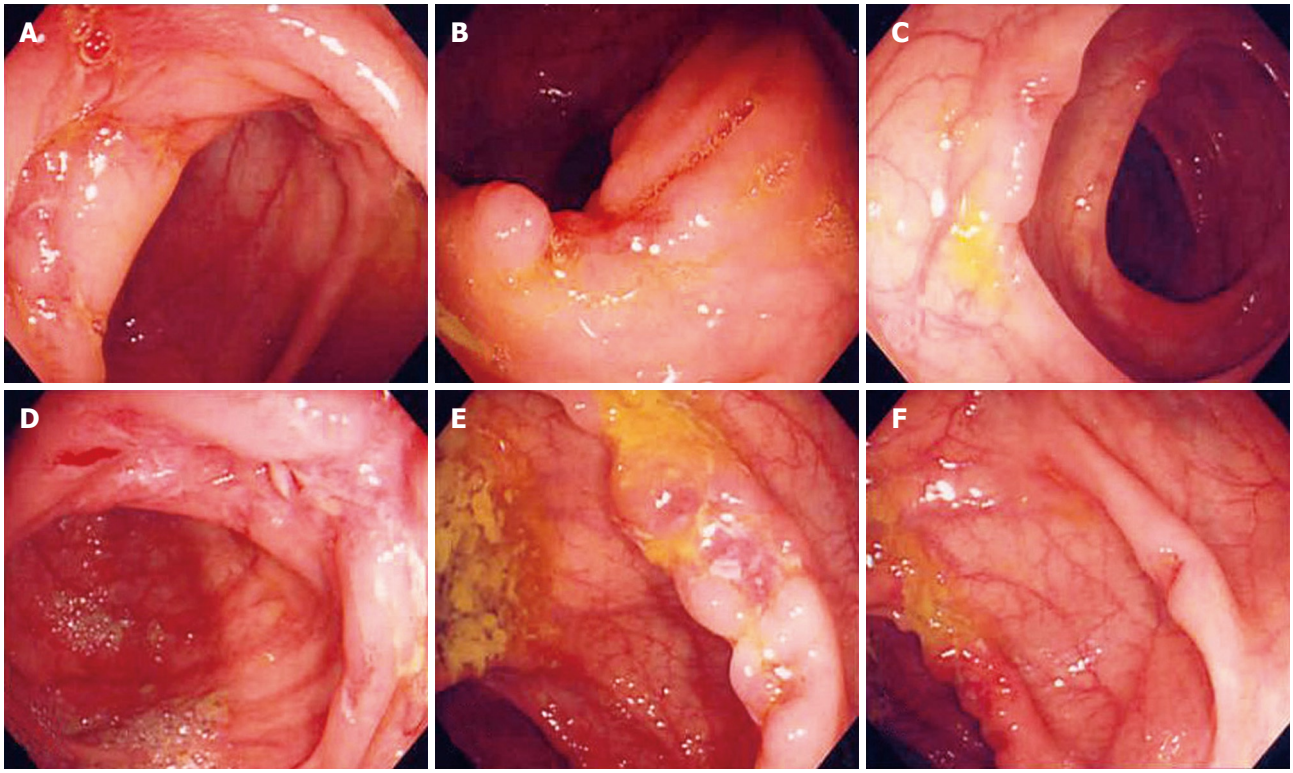

Figure 4 Colonoscopy findings before (**A-C**) and after (**D-F**) anti-tuberculosis medication in a 39-year-old female patient with irregular ulcers on the Ileocecal valve and proximal AC. After medication, it showed active ulcers and extension. We classified this case as "suspicious IBD group" and performed mesalazine trial. The patient showed no response to all the medical trials, so we confirmed this case as the "nonspecific colonic ulcers" by surgery.

active ulcers on follow-up colonoscopy were reevaluated; a second biopsy was performed and withdrawn from the anti-tuberculosis treatment trial. They were switched to mesalazine and/or corticosteroid for inflammatory bowel disease. The new medication was well-tolerated and showed slow clinical improvement by 8 of the "suspicious

Table 4 Final diagnosis of the patients of "suspicious inflammatory bowel disease group"

Patient	Response	Other manifestation during follow-up	Final Dx
#1 F/32	Response to mesalazine		CD
#2 F/15	Response to steroid	perianal abscess after 2 years	CD
#3 F/20	Response to mesalazine		CD
#4 F/39	No response to mesalazine, active ulcer and symptoms	hemicolectomy	Non-specific ulcers
#5 M/24	Response to mesalazine		CD
#6 M/42	Response to steroid		CD
#7 M/16	Response to mesalazine	Ileocecectomy due to ileal perforation after 2 years	CD
#8 F/27	Response to mesalazine	perianal fistula after 2 years	CD
#9 M/26	Response to steroid	perianal abscess after 1 year	CD

IBD group". However, 1 patient of the "suspicious IBD group" complained of sustained symptoms and weight loss and his 3rd colonoscopy showed more aggravation of lesions, chronic inflammation was found on repeated biopsy. After a 6-mo trial of mesalazine which did not show improvement, it was decided to perform a right hemicolectomy for confirmative diagnosis and treatment (Figure 4). The surgical specimen showed diffuse chronic ulcers on the ileocecal valve and ascending colon with neither granuloma nor any other malignant cells. After operation, the patient was observed for 2 years without further GI problems. During the 2 years of follow-up, 8 patients of the "suspicious IBD group" were improved in diarrhea, abdominal pain and colonic lesion, but 3 patients developed anal problems, and 1 patient underwent an operation due to ileal perforation. Finally 8 patients of the "suspicious IBD group" were diagnosed as Crohn's disease, one patient as nonspecific simple colonic ulcers after a right hemicolectomy (Table 4).

DISCUSSION

The Asian Pacific region was previously designated as a low incidence area of IBD, but this could be due to lack of solid population-based studies, low diagnostic awareness, and high incidence of intestinal infections. Current literature and recent information leave no doubt that a true increase of IBD is occurring throughout this region[9]. By contrast, the incidence of tuberculosis is rising, both in the United States of America as well as in the United Kingdom[3,10,11]. Following the resurgence of tuberculosis, two series of patients with abdominal tuberculosis were recently published in the United States[12,13].

Thus, each side of the world is having to face the task of differentiating between the two diseases, Crohn's disease and tuberculous colitis, which are similar in both clinical features and colonoscopy findings. In spite of similar clinical findings, the ultimate natural history of the two diseases is different. Appropriate anti-tuberculosis treatment leads in most cases of tuberculous ileocolitis to complete cure, whereas Crohn's disease is a progressive relapsing illness unaffected by anti-tuberculosis treatment.

In tuberculous colitis, the cecum, Ileocecal valve and terminal ileum are commonly affected sites[14-17], and are also the most common sites of Crohn's disease. In all areas of the world where Tuberculosis is endemic high-risk patients in developed countries need differentiation of the two diseases as early as possible.

Typical colonoscopy features described in patients with tuberculous colitis are transverse or linear ulcers, nodules, a deformed ileocecal valve and cecum, presence of inflammatory polyps, and multiple fibrous bands arranged in a haphazard fashion[14-16,18]. By contrast, typical Crohn's disease shows segmental longitudinal ulcers with a cobble stone appearance, stricture, perianal lesion and pseudo polyps[19]. In clinical practice, however, nonspecific ulcers on ileocecal valve and cecum without typical features are often seen.

Biopsy during colonoscopy helps in the diagnosis of nonspecific ulcers in the ileocecal area. Caseating granulomas and/or acid-fast bacilli are present only in a small proportion of patients with tuberculous colitis[20]. Granulomas, with or without caseation, are usually seen in less than 50% of patients with tuberculous colitis[3,15,16], while clusters of epithelioid cells without well formed granulomas have been reported to occur in 20%-30% of the biopsies obtained[15,16]. Our study shows non-caseating granuloma is not significant to the differential diagnosis of tuberculous colitis from Crohn's colitis.

Acid-fast bacilli have been reported in 50%-100% of specimens from patients with tuberculous colitis[21-24], but there are several reports where acid-fast bacilli could not be detected on histological examination of the biopsy material[14-16,18,25]. Acid-fast bacilli were seen in only 3 specimens (21.7%) in our cases. Thus, in a considerable number of tuberculous colitis the biopsies have features of chronic inflammation but no granulomas, caseation or clusters of epithelioid cells[15,16]. Culture of the biopsy material may increase the diagnostic yield[3]. However, disappointing results with 0% detection of acid-fast bacilli have also been reported[16]. Polymerase chain action analyses of biopsy specimens obtained endoscopically has been shown to be more sensitive than culture and acid-fast stains in diagnosing tuberculous colitis[26]. Other studies have suggested that an enzyme-linked immunosorbent assay using mycobacterial saline-extracted antigen may increase the yield of correct diagnosis of colonic tuberculosis[27]. The symptoms of tuberculous colitis such as chronic diarrhea, RLQ discomfort, and malaise are non-specific. But chest radiographs showing evidence of

active or healed pulmonary infection may be a clue to diagnosis[15,16,28], in our cases, 70% of tuberculous colitis and 33% of suspicious tuberculous colitis cases showed active pulmonary tuberculosis and old scar in 22% of suspicious cases. By contrast, none of the patients of the "suspicious IBD group" showed abnormal chest radiographs ($P < 0.001$).

In clinical practice, therefore, nonspecific ulcers on the ileocecal valve and cecum without any other clue for specific diagnosis are often seen. Efforts to exclude other infection including amoeboma, Yersinia infection, GI histoplasmosis, and periappendiceal abscess must be considered[3]. If the clinical and colonoscopy features are suggestive of tuberculous colitis and multiple target biopsies do not show evidence of any other disease, then a therapeutic trial of anti-tuberculosis treatment can safely be given to these patients[29]. Clinical response to the anti-tuberculosis treatment is usually dramatic and less than 1-year treatment is sufficient for patients with tuberculous colitis compared to life long treatment for inflammatory bowel disease.

The recommended regimen for pulmonary tuberculosis is combined chemotherapy containing isoniazid, rifampicin, ethambutol and pyrazinamide during 9 mo[30]. But the exact duration of anti-tuberculosis treatment for tuberculous colitis is not yet established due to difficulties in bacteriological diagnosis and the assessment of response to therapy. As a result, extra-pulmonary tuberculosis has been treated for 12 mo to 24 mo on the basis of warnings of disease recurrence without supportive data. Recent study has shown tuberculosis enterocolitis can be treated with 9 mo of chemotherapy without disease recurrence[29]. Our study showed that 10 mo of 4 regimens of chemotherapy were adequate for patients with tuberculous colitis combined with or without pulmonary tuberculosis.

How long a period will be adequate for an empirical trial of undetermined patients? Generally, 2 mo to 3 mo are accepted as adequate for trials based on clinical response. However, the colonoscopy findings are not reported after a 2-mo to 3-mo trial. As our study shows, active ulcers and erosions are completely healed after 2 mo to 3 mo of medication and only leave scarring and inflammatory polyps in all patients with tuberculous colitis and suspicious tuberculous colitis. That means a 2-mo to 3-mo trial of anti-tuberculosis treatment and colonoscopy follow-up are very useful for differential diagnosis of tuberculous colitis with other inflammatory bowel diseases. It is an exciting result that some patients with suspicious tuberculous colitis, who showed no active ulcer and significant resolution on follow-up colonoscopy without any other specific clue for tuberculosis, were also confirmed as tuberculous colitis after 10-mo medication. Likewise, every patient of the "suspicious IBD group" who showed no response to a short-term trial was ultimately confirmed as Crohn's disease or non-specific ulcer. This study also showed that, in patients with suspicious inflammatory bowel disease, a 2-mo to 3-mo trial was sufficient to exclude tuberculous colitis and adequate medication for inflammatory bowel disease could be started based on the trial.

Clinical response of symptoms and tolerance to anti-tuberculosis treatment was also important during the trial. In our study, most patients of the "suspicious tuberculous colitis group" tolerated medication well. About 45% of patients in the "suspicious IBD group" showed poor tolerance. But half also showed good tolerance to anti-tuberculosis treatment and mild clinical response during the trial too. Thus, during the anti-tuberculosis treatment trial, the physician's concern for a patient's tolerance to drug and clinical improvement is helpful but not definitive to decide maintaining anti-tuberculous treatment. We conclude that in cases of a therapeutic trial on nonspecific ulcers of the ileocecal area, 2 mo to 3 mo of anti-tuberculous medication and colonoscopy follow-up are valuable for making early confirmative diagnosis.

COMMENTS

Background

Differentiation between tuberculous colitis and Crohn's colitis can be difficult due to nonspecific GI symptoms and similar colonoscopic findings. In Asia, pulmonary and extrapulmonary tuberculosis are not rare until now. Also, the incidence and prevalence rates of inflammatory bowel disease (IBD) are increasing rapidly in many Asian countries, including Korea.

Research frontiers

There are efforts to differentiate two disease entities through colonoscopic findings. But some of them still could not be confirmed by initial colonoscopic findings. Short-term trial of anti-tuberculosis treatment is necessary before confirmative diagnosis of Crohn's colitis in the endemic area of tuberculosis.

Innovations and breakthroughs

The precise colonoscopic features after short-term medication in patients with either tuberculous colitis or suspicious tuberculous colitis have not been documented. This study was performed prospectively and showed that active ulcers and erosions were completely healed after 2-mo to 3-mo of medication and only leave scarring and inflammatory polyps in all patients with tuberculous colitis and suspicious tuberculous colitis. This study showed that, in patients with suspicious inflammatory bowel disease, a 2-mo to 3-mo trial and colonoscopic evaluation would be sufficient to exclude tuberculous colitis and adequate medication for inflammatory bowel disease to be started.

Applications

We conclude that in cases of therapeutic trial on nonspecific ulcers on the ileocecal area, especially the endemic area of tuberculosis, 2 mo to 3 mo of anti-tuberculous medication and colonoscopy follow-up are valuable for making early confirmative diagnosis. Duration of the therapeutic trial will be shortened after further clinical trial.

Peer review

This study provides colonoscopic features after short term anti-tuberculosis medication in patients with tuberculosis colitis and other chronic inflammatory bowel disease.

REFERENCES

1 **Guth AA**, Kim U. The reappearance of abdominal tuberculosis. *Surg Gynecol Obstet* 1991; **172**: 432-436

2 **Watson JM**, Gill ON. HIV infection and tuberculosis. *BMJ* 1990; **300**: 63-65

3 **Marshall JB**. Tuberculosis of the gastrointestinal tract and peritoneum. *Am J Gastroenterol* 1993; **88**: 989-999

4 **Snider DE Jr**, Roper WL. The new tuberculosis. *N Engl J Med* 1992; **326**: 703-705

5 **Palmer KR**, Patil DH, Basran GS, Riordan JF, Silk DB. Abdominal tuberculosis in urban Britain--a common disease. *Gut* 1985; **26**: 1296-1305

6 **Loftus EV Jr**. Clinical epidemiology of inflammatory bowel disease: Incidence, prevalence, and environmental influences. *Gastroenterology* 2004; **126**: 1504-1517
7 **Ferentzi CV**, Sieck JO, Ali MA. Colonoscopic diagnosis and medical treatment of ten patients with colonic tuberculosis. *Endoscopy* 1988; **20**: 62-65
8 **Misra SP**, Misra V, Dwivedi M, Gupta SC. Colonic tuberculosis: clinical features, endoscopic appearance and management. *J Gastroenterol Hepatol* 1999; **14**: 723-729
9 **Ouyang Q**, Tandon R, Goh KL, Ooi CJ, Ogata H, Fiocchi C. The emergence of inflammatory bowel disease in the Asian Pacific region. *Curr Opin Gastroenterol* 2005; **21**: 408-413
10 **OPCS**. Registrar General's Weekly Return for England and Wales. London: HMSO, 1994
11 **Hayward AC**, Watson JM. Tuberculosis in England and Wales 1982-1993: notifications exceeded predictions. *Commun Dis Rep CDR Rev* 1995; **5**: R29-R33
12 **Guth AA**, Kim U. The reappearance of abdominal tuberculosis. *Surg Gynecol Obstet* 1991; **172**: 432-436
13 **Rosengart TK**, Coppa GF. Abdominal mycobacterial infections in immunocompromised patients. *Am J Surg* 1990; **159**: 125-131
14 **Bhargava DK**, Tandon HD, Chawla TC, Shriniwas, Tandon BN, Kapur BM. Diagnosis of ileocecal and colonic tuberculosis by colonoscopy. *Gastrointest Endosc* 1985; **31**: 68-70
15 **Shah S**, Thomas V, Mathan M, Chacko A, Chandy G, Ramakrishna BS, Rolston DD. Colonoscopic study of 50 patients with colonic tuberculosis. *Gut* 1992; **33**: 347-351
16 **Singh V**, Kumar P, Kamal J, Prakash V, Vaiphei K, Singh K. Clinicocolonoscopic profile of colonic tuberculosis. *Am J Gastroenterol* 1996; **91**: 565-568
17 **Chen WS**, Leu SY, Hsu H, Lin JK, Lin TC. Trend of large bowel tuberculosis and the relation with pulmonary tuberculosis. *Dis Colon Rectum* 1992; **35**: 189-192
18 **Aoki G**, Nagasako K, Nakae Y, Suzuki H, Endo M, Takemoto T. The fiber colonoscopy diagnosis of tuberculous colitis. *Endoscopy* 1975; **7**: 113-121
19 **D'Haens G**, Rutgeerts P. Endoscopic evaluation. In: Prantera C, Korelitz B, eds. Crohn's disease. 1st ed. New York: Marcel Dekker, Inc., 1996: 113-123
20 **Pulimood AB**, Ramakrishna BS, Kurian G, Peter S, Patra S, Mathan VI, Mathan MM. Endoscopic mucosal biopsies are useful in distinguishing granulomatous colitis due to Crohn's disease from tuberculosis. *Gut* 1999; **45**: 537-541
21 **Pettengell KE**, Pirie D, Simjee AE. Colonoscopic features of early intestinal tuberculosis. Report of 11 cases. S *Afr Med J* 1991; **79**: 279-280
22 **Howell JS**, Knapton PT. Ileocecal tuberculosis. *Gut* 1964; **5**: 524-529
23 **Wig KL**, Chitkara NL, Gupta SP, Kishore K, Manchanda RL. Ileocecal tuberculosis with particular reference to isolation of Mycobacterium tuberculosis. With a note on its relation to regional ileitis (Crohn's disease). *Am Rev Respir Dis* 1961; **84**: 169-178
24 **Sakai Y**. Colonoscopic diagnosis of the intestinal tuberculosis. *Mater Med Pol* 1979; **11**: 275-278
25 **Radhakrishnan S**, Al Nakib B, Shaikh H, Menon NK. The value of colonoscopy in schistosomal, tuberculous, and amebic colitis. Two-year experience. *Dis Colon Rectum* 1986; **29**: 891-895
26 **Anand BS**, Schneider FE, El-Zaatari FA, Shawar RM, Clarridge JE, Graham DY. Diagnosis of intestinal tuberculosis by polymerase chain reaction on endoscopic biopsy specimens. *Am J Gastroenterol* 1994; **89**: 2248-2249
27 **Bhargava DK**, Dasarathy S, Shriniwas MD, Kushwaha AK, Duphare H, Kapur BM. Evaluation of enzyme-linked immunosorbent assay using mycobacterial saline-extracted antigen for the serodiagnosis of abdominal tuberculosis. *Am J Gastroenterol* 1992; **87**: 105-108
28 **al Karawi MA**, Mohamed AE, Yasawy MI, Graham DY, Shariq S, Ahmed AM, al Jumah A, Ghandour Z. Protean manifestation of gastrointestinal tuberculosis: report on 130 patients. *J Clin Gastroenterol* 1995; **20**: 225-232
29 **Horvath KD**, Whelan RL. Intestinal tuberculosis: return of an old disease. *Am J Gastroenterol* 1998; **93**: 692-696
30 **Kim SG**, Kim JS, Jung HC, Song IS. Is a 9-month treatment sufficient in tuberculous enterocolitis? A prospective, randomized, single-centre study. *Aliment Pharmacol Ther* 2003; **18**: 85-91

S- Editor Zhong XY **L- Editor** Alpini GD **E- Editor** Lin YP

Online Submissions: wjg.wjgnet.com
wjg@wjgnet.com
doi:10.3748/wjg.14.5059

World J Gastroenterol 2008 August 28; 14(32): 5059-5065
World Journal of Gastroenterology ISSN 1007-9327
© 2008 The WJG Press. All rights reserved.

RAPID COMMUNICATION

Cellular DNA repair cofactors affecting hepatitis B virus infection and replication

Fan Zhao, Ning-Bo Hou, Ting Song, Xiang He, Zi-Rui Zheng, Qing-Jun Ma, Li Li, Yan-Hong Zhang, Hui Zhong

Fan Zhao, Ning-Bo Hou, Ting Song, Xiang He, Zi-Rui Zheng, Qing-Jun Ma, Li Li, Yan-Hong Zhang, Hui Zhong, Beijing Institute of Biotechnology, Room 841, East District Building, No. 27 Taiping Road, Haidian District, Beijing 100850, China
Author contributions: Zhao F and Hou NB contributed equally to this work; Ma QJ, Li L, Zhang YH and Zhong H designed the research; Zhao F, Hou NB, Song T, He X and Zheng ZR performed the research; Zhong H wrote the paper.
Supported by National Natural Science Foundation of China, No. 30772605, 30700413
Correspondence to: Hui Zhong, PhD, Beijing Institute of Biotechnology, Room 841, East District Building, No. 27 Taiping Road, Haidian District, Beijing 100850, China. towall@yahoo.com
Telephone: +86-010-66931809 Fax: +86-010-88272563
Received: April 15, 2008 Revised: July 14, 2008
Accepted: July 21, 2008
Published online: August 28, 2008

Abstract

AIM: To investigate whether hepatitis B virus (HBV) infection activates DNA damage response and DNA repair cofactors inhibit HBV infection and replication.
METHODS: Human hepatocyte cell line HL7702 was studied. Immunoblotting was performed to test the expression of ataxia telangiectasia-mutated (ATM)-Rad3-related protein (ATR), p21 and the level of phosphorylation of Chk1, p53, H2AX, ATM in HBV-infected or non-infected-cells. Special short RNAi oligos was transfected to induce transient ATR knockdown in HL7702. ATR-ATM chemical inhibitors caffeine (CF) and theophylline (TP), or Chk1 inhibitor 7-hydroxystaurosporine (UCN01) was studied to determine whether they suppress cellular DNA damage response and MG132 inhibits proteasome.
RESULTS: The ATR checkpoint pathway, responding to single-strand breaks in DNA, was activated in response to HBV infection. ATR knockdown cells decreased the HBV DNA yields, implying that HBV infection and replication could activate and exploit the activated DNA damage response. CF/TP or UCN01 reduced the HBV DNA yield by 70% and 80%, respectively. HBV abrogated the ATR-dependent DNA damage signaling pathway by degrading p21, and introduction of the p21 protein before HBV infection reduced the HBV DNA yield. Consistent with this result, p21 accumulation after MG132 treatment also sharply decreased the HBV DNA yield.
CONCLUSION: HBV infection can be treated with therapeutic approaches targeting host cell proteins by inhibiting a cellular gene required for HBV replication or by restoring a response abrogated by HBV, thus providing a potential approach to the prevention and treatment of HBV infection.

© 2008 The WJG Press. All rights reserved.

Key words: Hepatitis B virus; DNA damage response; Hepatitis B virus infection; Caffeine; RNAi

Peer reviewer: Dr. Carla Brady, Duke University Medical Center, DUMC Box 3913, Durham 27705, United States

Zhao F, Hou NB, Song T, He X, Zheng ZR, Ma QJ, Li L, Zhang YH, Zhong H. Cellular DNA repair cofactors affecting hepatitis B virus infection and replication. *World J Gastroenterol* 2008; 14(32): 5059-5065 Available from: URL: http://www.wjgnet.com/1007-9327/14/5059.asp DOI: http://dx.doi.org/10.3748/wjg.14.5059

INTRODUCTION

Eukaryotic cells employ multiple strategies of checkpoint signaling and DNA repair mechanisms to monitor and repair damaged DNA. There are two branches in the checkpoint response pathway: ataxia telangiectasia-mutated (ATM) branch and ATM-Rad3-related (ATR) branch[1,2]. Many viruses are now known to interact with DNA damage sensing and repair machinery. These viruses have evolved tactics to eliminate, circumvent, or exploit various aspects of the DNA damage response to the host cells. Strategies include activation of repair proteins or targeting of specific cellular factors for degradation or mislocalization[3-6]. It is necessary to examine the DNA damage pathway activated by viral replication for generation of antiviral drugs. In human immunodeficiency virus (HIV), it has been clearly determined that prevention of viral integration inhibits viral replication and promotes cellular apoptosis. The ATM-specific inhibitor ku55933 can inhibit HIV replication in primary T cells[7].

Although a safe and efficient vaccine is available at present, chronic hepatitis B virus (HBV) infection

remains a major health problem worldwide. Interferon treatment is effective in only approximately one-third of the patients and produces considerable side effects. Long-term treatment with the second-generation of nucleoside analogue lamivudine (lam) efficiently inhibits HBV replication with frequent viral polymerase mutations. We found that HBV infection could trigger ATR-dependent DNA damage response, resulting in increased ATR and Chk1 phosphorylation levels. However, ATR checkpoint signaling is blocked downstream of the p53-dependent pathway to evade apoptosis by degrading p21. We designed a strategy to select new drug targets that inhibit a cellular gene required for HBV replication or restore a response stalled by HBV in the ATR DNA damage pathway.

The ATM and ATR kinases are targets of a known inhibitor, caffeine (CF), of DNA damage response. CF has shown to inhibit the activity of these kinases *in vitro* and the response to cellular DNA damage controlled by ATM and ATR. Theophylline (TP) is a product of CF metabolism *in vivo* and has been clinically used in treatment of asthma. It has also been demonstrated that TP exhibits CF-like effects on DNA damage response[8].

Originally developed as a protein kinase C (PKC) inhibitor, 7-hydroxystaurosporine (UCN-01) has been subsequently shown to inhibit several other cell survival/cell cycle regulatory proteins, including Chk1 and 3-phosphoinositide-dependent protein kinase-1 (PDK1)/protein kinase B (Akt). By inhibiting Chk1, UCN-01 blocks the proteasome degradation of the cdc25C phosphatase, resulting in dephosphorylation (activation) of $p34^{cdc2}$. In this way, UCN-01 functions as a checkpoint abrogator that potentiates the lethal effects of several DNA-damaging agents, including ara-C18 and camptothecin[9,10].

Proteasome, a multicatalytic enzyme complex, controls the regulation (by means of degradation) of many proteins involved in cell cycle arrest and apoptosis. The proteasome inhibitor MG132 can restore wild-type (WT) p53 levels reduced by E6 and sensitize HPV-positive cervical cancer cell lines to apoptotic stimuli such as rhTRAIL. It was also reported that MG13 could inhibit HSV replication by preventing HSV-1-induced NF-κB activation[11,12].

In this paper, we report that HBV infection activates and exploits DNA damage response to replication stress. We investigated whether inhibition of DNA damage response by CF, TP and UCN01 or restoration of p21 expression by p21 transfection or proteasome inhibition leads to suppression of HBV replication. We set up a chronic HBV infection model by culturing HL7702 liver cells with HBV-positive serum without washing off input virus as conventional. HBV DNA titers inside the infected cells represent the final viral amount including the infected DNA not degraded and the newly synthesized HBV DNA. In this way, we could study the efficacy of DNA damage response inhibitors on HBV infection and replication. In addition, since DNA damage response is an acute response occurring quickly after virus infection, we assume that early intervention of the DNA damage pathway would function more efficiently, and thus can be used in clinical practice as a HBV infection therapy during its early infectious stage or fulminant HBV infection.

MATERIALS AND METHODS

Chemicals

CF, TP, UCN01 and MG132 were obtained from Sigma (St. Louis, MO). The stock concentration was 100 mmol/L. CF and UCN01 were dissolved in water, whereas TP was dissolved in 0.1 mol/L NaOH, and MG132 was dissolved in DMSO.

Cell cultures, HBV strains, and infections

The human hepatocyte cell line HL7702, isolated from a HBV sera-negative individual, was obtained from Shanghai Biochemistry Institute. HL7702 cells were cultured in RPMI-1640 with 10% heat-inactivated fetal bovine serum (FBS). Serum samples from HBV carriers obtained for infection test were analyzed. The number of serum HBV viral particles was 7×10^9 copies/mL, as quantified by FQ-PCR. The sera were stored at -80℃ until use.

HBV infection was monitored by culturing 10^5 HL7702 cells in a 6-cm plate in 3 mL RPMI-1640 containing 10^6 HBV virus particles. Infected cells were simultaneously treated with different types of drugs (CF, TP and UCN01) at various concentrations. The cells were washed thoroughly 8 times to remove excessive viral inputs and drugs before harvesting. Serum from healthy individuals was used as a negative control. All procedures were performed under level P2 biosafety conditions to minimize the possibility of cross-contamination.

RNA interference

siRNA duplex composed of 21-bp sense and antisense oligonucleotides of ATR was synthesized by Beijing AuGCT Biotechnology Co. Ltd (China). The sequence of siRNA oligos used in this study was (only the sense strand is shown) siATR: 5'-AACCUCCGUGAUGUUGCUUG ATT-3'. HL7702 cells were transfected with 50 nmol/L siRNA using lipofectamine 2000 (Promega Corp., Madison, WI, USA) according to the manufacturer's protocol. At 24 h after transfection, cells were subjected to HBV infection and then the HBV DNA load was tested at indicated time points post-infection.

Detection of HBV DNA by FQ-PCR

For FQ-PCR analyses, virus DNA was extracted from the culture medium using an alkaline lysis method. Briefly, HBV DNA was measured using a FQ-PCR diagnostic kit from Da-An Gene Corporation. FQ-PCR was performed using a Lightcycler™ Roche FQ-PCR system with the following amplification cycle: an initial denaturation at 93℃ for 2 min, followed by 40 cycles of annealing at 93℃ for 5 s, at 57℃ for 45 s, and a final extension at 37℃ for 10 s.

Immunoblotting assay

Cell extracts were lysed in ice-cold Tris buffer (50 mmol/L, pH 7.5) containing 5 mmol/L EDTA, 300 mmol/L NaCl, 0.1% Igepal, 0.5 mmol/L NaF, 0.5 mmol/L Na_3VO_4, 0.5 mmol/L PMSF, and antiprotease mixture (Roche Molecular Biochemicals) for 30 min and centrifuged at 13000 × *g* for 10 min. The supernatant protein concentration was determined with the Bradford procedure (BioRad). The proteins were resolved on a 7%-15% SDS-PAGE gel and transferred onto nitrocellulose membranes. Blots were blocked in TBST containing 5% nonfat dried milk and incubated with the primary antibodies. Antibodies against p21, ATR (Santa Cruz) and tubulin (Sigma) were incubated at room temperature for 1 h, while antibodies against ATM phosphoserine 1981 (ATMp), Chk1 phosphoserine 345 (Chk1p), and p53 phosphoserine 15 (p53p) (cell signaling) were incubated at 4℃ overnight. Secondary antibodies were from Jackson Laboratories. Horseradish peroxidase-based detection was performed using a chemiluminescence reagent (Amersham Biosciences), according to the manufacturer's instructions.

RESULTS

HBV infection induced an ATR-dependent cellular DNA damage response

To identify whether a cellular DNA damage response was induced upon HBV infection, we set up a HBV infection and replication model by culturing normal HL7702 liver cells with HBV-positive serum[13]. A monolayer (10^5) of the human HL7702 liver cells in 6-cm plates was infected with 10^6 HBV-DNA copies/mL serum at 37℃ in an atmosphere containing 50 mL/L CO_2. HBV infection induced an increase in the steady state levels of the ATR protein and in the phosphorylation levels of its downstream substrates Chk1 and p53 (Figure 1A). Chk1 phosphorylation at Ser-345 was evidently increased at the start of infection with a further increase from 6 to 48 h. p53 phosphorylation at Ser-15 was elevated beginning at 24 hpi and increased considerably at 48 hpi.

In contrast to ATR and its target, the phosphorylated form of ATM at Ser-1981 did not effectively increase upon infection. Furthermore, the phosphorylation of its downstream substrate Chk2 at Thr-68 began to decrease from 3 hpi (data not shown). p53 transcriptional target $p21^{cip1/waf1}$, a cyclin-dependent kinase inhibitory protein, decreased substantially with time after infection, suggesting that p53-dependent downstream signaling can be blocked during HBV infection despite the appearance of phosphorylated p53. Taken together, these results indicate that HBV infection elicited activation of the ATR DNA damage checkpoint pathway that responds to replication stress rather than the ATM DNA damage checkpoint pathway.

HBV infection and replication exploited activated DNA damage response

To investigate the effect of the activated DNA damage response on HBV infection and replication, HBV infection was performed in ATR knockdown cells. ATR knockdown was conducted with short RNAi oligos transfection using lipofectamine 2000. RNAi technique diminished total ATR protein from 24 h to 72 h after RNA oligos transfection (Figure 1B). Based on this, HBV-positive serum was added to ATR knockdown cells 24 h after the transfection, cells were then harvested for HBV DNA titer assay at 9, 24 and 48 h, respectively, after infection. HBV DNA load in ATR knockdown

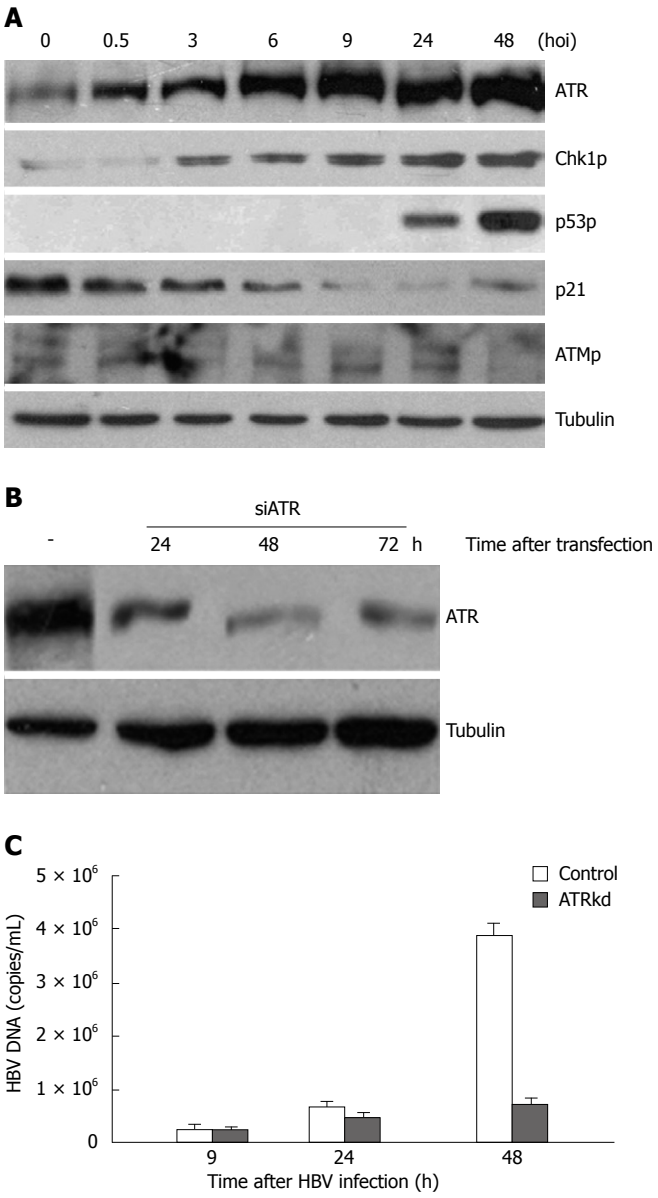

Figure 1 An ATR-dependent cellular checkpoint response activated by HBV infection. **A**: 10^5 human HL7702 monolayer liver cells in a 6 cm plate were infected with 10^6 virus particles from HBV-positive patients at 37℃ in an atmosphere containing 50 mL/L CO_2. Normal serum from healthy individuals was used as non-infected control. Prior to cell harvesting, the cells were washed 8 times thoroughly to remove the excessive viral input. Whole cell lysates were prepared at various time points of infection (hours of infection, hoi) and subjected to immunoblotting assay using antibodies to the indicated proteins. Alpha-tubulin was used as the equal loading control; **B**: Specialized siRNA for ATR was transfected in HL7702 cells using lipofectamine 2000. At the indicated time points, cells were collected for Western blotting testing the ATR level; **C**: HBV-positive serum was added to ATR knockdown cells 24 h after transfection, cells were then harvested for FQ-PCR to test HBV DNA titers at the indicated time points post-infection.

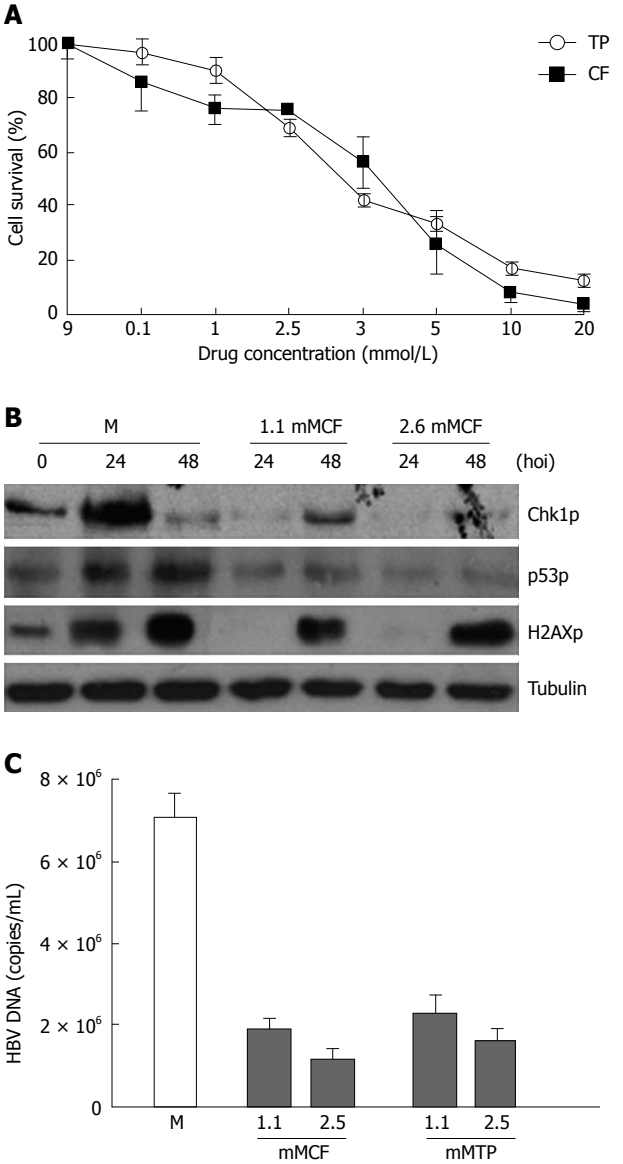

Figure 2 HBV infection and replication suppressed by CF and TP. **A**: Cells were treated with CF or TP at different concentrations for 48 h, and survived cells were counted with trypan blue staining; **B**: Results of whole cell lysis, Western blotting of infected cells (M) or addition of CF-treated cells (1.1 mol/L CF, 2.5 mmol/L CF) and antibodies at the indicated time points; **C**: FQ-PCR analysis of HBV DNA from the infected cells (M) or addition of both HBV and CF (mMCF) or TP (mMTP).

cells was reduced to about 20% of control (Figure 1C), indicating that HBV replication is dependent on the presence of ATR protein.

ATM-ATR kinase inhibitor suppressed HBV infection and replication

To evaluate the influence of the ATR and ATM kinase inhibitor CF and its methylxanthines on HBV replication, the infected cells were simultaneously treated with different types of drugs (CF and TP) at various concentrations. Trypan blue staining was performed and viable cells were counted at different time points after drug addition. The percentage of cells survived was determined by the ratio of the number of treated cells divided by the number of untreated cells. The DNA

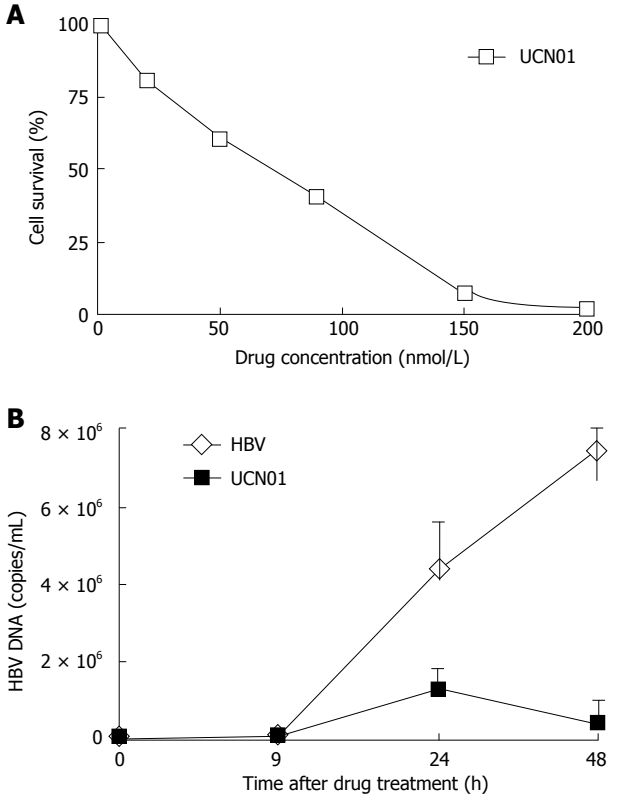

Figure 3 HBV infection and replication suppressed by CF and TP. **A**: HL7702 cells were treated with the indicated concentrations of UCN01, and survived cells were counted 48 h post-treatment with trypan blue staining; **B**: FQ-PCR analysis of HBV DNA from the infected cells (HBV) or addition of both HBV and UCN01 (UCN01) at the indicated time points.

extracted from the infected cells was subjected to FQ-PCR analysis, and the degree of amplification of the viral genome over the time course of infection was determined. We observed a 70% decrease in HBV DNA yields in cells treated with 1.1 mmol/L CF at 48 h during HBV infection (Figure 2C). However, such a dose did not affect cell proliferation (Figure 2A) but abrogated the phosphorylation of target proteins with ATR kinase activity such as Chk1 at Ser-345, H2AX at Ser-139, and p53 at Ser-15 (Figure 2B).

Chk1 inhibitor suppressed HBV infection and replication

Chk1 phosphorylation was greatly increased during HBV infection. We therefore investigated whether Chk1 inhibitors would have an effect on HBV replication. Infected cells were simultaneously treated with various concentrations of UCN01. The percentage of survived cells was calculated as described above. The DNA extracted from infected cells was subjected to FQ-PCR analysis. We observed a 90% decrease in HBV DNA yields in cells treated with 50 nmol/L UCN01 (Figure 3B), which did not significantly affect the cell survival was not significantly affected in 48 h (Figure 3A).

p21 introduction suppressed HBV infection and replication

In contrast to increased levels of sustained ATR and Chk1 (ATR substrate) phosphorylation during HBV

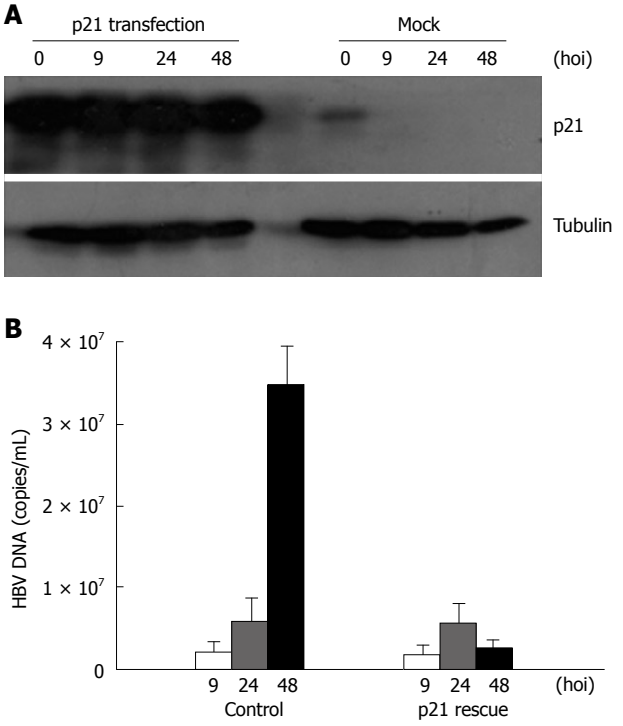

Figure 4 HBV infection and replication suppressed by introduction of p21. **A**: Result of whole cell lysis, Western blotting of p21- transfected cells and control cells (Mock) at the indicated time points; **B**: FQ-PCR analysis of HBV DNA from the infected cells (control) or both HBV and p21- transfected cells (p21 rescue) at the indicated time points.

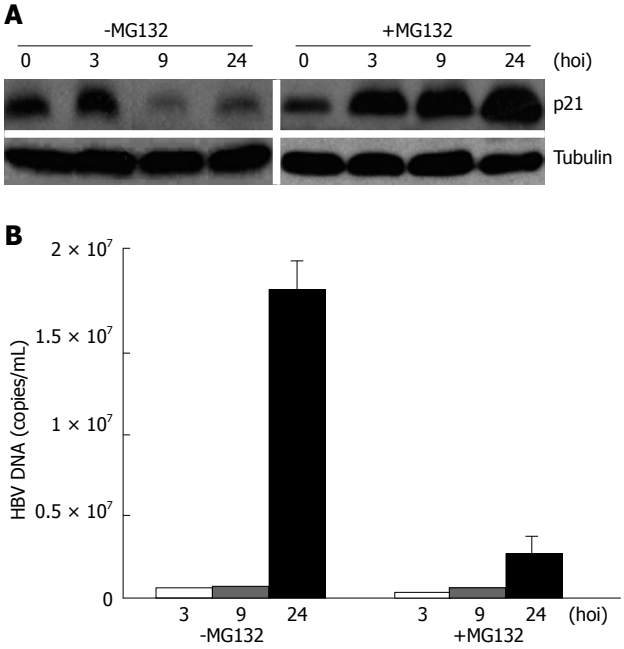

Figure 5 HBV replication inhibited by MG132. **A**: Result of whole cell lysis, Western blotting of MG132- treated cells (+MG132) and control cells (-MG132) at the indicated time points; **B**: FQ-PCR analysis of HBV DNA from the infected cells (-MG132) or both HBV and MG132-treated cells (+MG132) at the indicated time points.

infection, HBV abrogated p53-dependent cell cycle checkpoint signaling by degrading p21 (Figure 1A). We thus introduced p21 into host cells to investigate its effect on HBV replication. WT p21 cDNA was transfected into HL7702 cells, which were infected with HBV-positive serum 24 h later, harvested at 9, 24 and 48 h respectively after HBV infection, and subjected to FQ-PCR and immunoblotting. p21 expression decreased with time after infection, and myc-tagged p21 expression was higher in the transfected host cells than in the mock-transfected cells (Figure 4A). We then investigated the effects of p21 transfection on HBV infection and replication. Figure 4B showed that the yield of HBV DNA in the p21-transfected cells was only approximately 8% of that in the cells infected only with HBV, indicating that recovery of p21 destroyed by HBV infection has a detrimental effect on replication of the virus.

MG132 inhibited HBV replication

Previous studies have established that HIV-1 infection can be enhanced by treatment of infected cells with proteasome chemical inhibitors[7,8]. It is likely that such inhibitors protect the viral core from degradation in target cells. We have proved that introduction of p21 into infected cells leads to decreased HBV replication. Therefore, we tested whether the proteasome inhibitor MG132 would have an effect on HBV replication in the presence of p21 accumulation. To determine p21 levels and the effect of proteasome inhibitors on cell susceptibility to HBV infection, we pretreated cultures of HL7702 cells with MG132 (10 μM) for 2 h and then monitored HBV infection. HBV-infected cells were harvested at 0, 9, 24, 48 h after extensive washes 8 times with PBS, and then subjected to immunoblotting and FQ-PCR. The level of p21 expression decreased with time after infection, the addition of MG132 resulted in a substantial increase in the p21 expression levels (Figure 5A). To investigate whether treatment with MG132 can also effectively inhibit virus replication, we analyzed the effect of MG132 on HBV replication. The yield of HBV in the presence of proteasome inhibitors was only approximately 10% of that in control cells 48 h after HBV infection (Figure 5B), indicating that proteasome inhibitors can reduce HBV replication by up-regulating p21.

DISCUSSION

Several viruses, including DNA virus herpes simplex virus (HSV)[14,15], Kaposi's sarcoma-associated herpesvirus[16], human cytomegalovirus (HCMV)[17] Epstein-Barr virus (EBV)[18], papillomavirus[19,20], simian virus 40 (SV40)[21] and retrovirus HIV[22-24], trigger cellular signaling cascades that are characteristic of a DNA damage response. Infection and replication of HBV have been achieved in human hepatoma cell lines and primary fetal human hepatocytes using transfected HBV genomes or HBV serum. In this study, HL7702 cells were inoculated with HBV serum consistently (10^6 particles per 10^5 cells), mimicking the HBV infection process. Serum from healthy individuals was used as the non-infected control. By using FQ-PCR and southern blotting, we demonstrated that human hepatocytes

could maintain HBV infection *in vitro* and support the replication of HBV DNA (data not shown), suggesting that HBV infection activates the DNA damage response to replication stress accompanying increased ATR and Chk1 (ATR substrate) phosphorylation. Furthermore, HBV abrogated the checkpoint signaling by degrading p21. The results of this study show that the ATM and ATR inhibitor CF and its methylxanthine TP, the Chk1 inhibitor UCN01, the proteasome inhibitor MG132 and p21 up-regulation could suppress HBV replication. These findings suggest that some DNA damage responsive proteins are implicated in modulating HBV infections and therefore can be used in treatment of drug-resistant viral strains. In addition, targeting cellular proteins with a low mutation rate may not lead to the rapid emergence of HBV strains that are resistant to inhibitors of these proteins.

The effect of CF is mediated by inhibiting its cellular target, the ATR kinase involved in retroviral integration. The precise role of ATR in HBV replication is unclear. The integration of HBV DNA into chromosomes has been reported[13]. Interestingly, treatment with TP has an inhibitory effect on HBV replication even at a concentration as low as 0.1 mmol/L, which is too low to impact ATM/ATR kinase activity. Therefore, the antioxidant function of TP or CF may have a great inhibitory effect on HBV infection process, and further experiments should be done on this issue.

Chk1 is activated following HBV infection and the Chk1 inhibitor UCN01 can inhibit HBV replication. however, the precise mechanism underlying this inhibition remains to be determined. The resultant S-G2 phase-like cellular condition appears to favor replication of viral DNA.

In cervical carcinogenesis, the p53 suppressor pathway is disrupted by HPV E6-mediated proteasome degradation. MG132 could restore WT p53 levels and thus may sensitize papillomavirus (PV) positive human cervical cancer cells to apoptosis[11,25]. Several studies have recently demonstrated that proteasome is a suitable neoplastic target with a clinical potential[26-28]. We report here that MG132 can be used to suppress HBV replication by up-regulating p21. As a latency virus, HBV abrogates the checkpoint signaling controlled by ATR to prevent triggering of apoptotic signals. The mechanism underlying the regulation of apoptosis by HBV is *via* both p53-dependent pathways. The p53-dependent cell cycle checkpoint pathway involves p21-mediated inactivation of cdk2/cyclinE. HBV abrogates p53-dependent checkpoint activation by degrading p21. Our results demonstrate that MG132 could up-regulate p21 and thus suppress HBV replication, possibly due to the partial recovery of the p53-dependent checkpoint signaling pathway.

In summary, CF and its related methylxanthines can suppress replication of HIV as previously reported[8]. However, since DNA damage response is acute, DNA repair cofactors against HBV infection and replication should be used in early stage HBV infection. Further studies are necessary to determine the mechanism by which DNA damage response inhibitors down-regulate HBV infection and replication.

COMMENTS

Background

Eukaryotic cells employ multiple strategies of checkpoint signaling and DNA repair mechanisms to monitor and repair damaged DNA. There are two branches in the checkpoint response pathway: ataxia telangiectasia-mutated (ATM) branch and ATM-Rad3-related (ATR) branch. Many viruses are now known to interact with DNA damage and repair machinery. These viruses have evolved tactics to eliminate, circumvent, or exploit various aspects of DNA damage response to the host cells. Strategies include activation of repair proteins or targeting of specific cellular factors for degradation or mislocalization.

Research frontiers

In human immunodeficiency virus (HIV), prevention of viral integration inhibits viral replication and promotes cellular apoptosis. Thus, the ATM-specific inhibitor ku55933 can inhibit HIV replication in primary T cells.

Innovations and breakthroughs

In this paper, we first report that (hepatic B virus) HBV infection activates and exploits DNA damage response to replication stress. We investigated whether the inhibition of DNA damage response by CF, TP and UCN01 or the restoration of p21 expression by p21 transfection or proteasome inhibition would lead to suppression of HBV replication. We set up a chronic HBV infection model by culturing HL7702 liver cells with HBV-positive serum without washing off input virus as conventional. HBV DNA titers inside the infected cells represent the final viral amount including the infected DNA not degraded and the newly synthesized HBV DNA. In this way, we can study the efficacy of DNA damage response inhibitors on HBV infection and replication.

Applications

Since DNA damage response is an acute response occurring quickly after virus infection, we assume that early intervention of the DNA damage pathway would function more efficiently and thus can be used in clinical practice as a HBV infection therapy during its early infectious stage or fulminant HBV infection.

Peer review

This is an interesting article that reports data on the effect of DNA repair cofactors on HBV replication and infection. The study is well designed. The data or findings are reliable.

REFERENCES

1 **Shiloh Y**. ATM and related protein kinases: safeguarding genome integrity. *Nat Rev Cancer* 2003; **3**: 155-168

2 **Helt CE**, Cliby WA, Keng PC, Bambara RA, O'Reilly MA. Ataxia telangiectasia mutated (ATM) and ATM and Rad3-related protein exhibit selective target specificities in response to different forms of DNA damage. *J Biol Chem* 2005; **280**: 1186-1192

3 **Weitzman MD**, Carson CT, Schwartz RA, Lilley CE. Interactions of viruses with the cellular DNA repair machinery. *DNA Repair* (Amst) 2004; **3**: 1165-1173

4 **Everett RD**. Interactions between DNA viruses, ND10 and the DNA damage response. *Cell Microbiol* 2006; **8**: 365-374

5 **Lilley CE**, Schwartz RA, Weitzman MD. Using or abusing: viruses and the cellular DNA damage response. *Trends Microbiol* 2007; **15**: 119-126

6 **Lilley CE**, Carson CT, Muotri AR, Gage FH, Weitzman MD. DNA repair proteins affect the lifecycle of herpes simplex virus 1. *Proc Natl Acad Sci USA* 2005; **102**: 5844-5849

7 **Lau A**, Swinbank KM, Ahmed PS, Taylor DL, Jackson SP, Smith GC, O'Connor MJ. Suppression of HIV-1 infection by a small molecule inhibitor of the ATM kinase. *Nat Cell Biol* 2005; **7**: 493-500

8 **Nunnari G**, Argyris E, Fang J, Mehlman KE, Pomerantz RJ, Daniel R. Inhibition of HIV-1 replication by caffeine and caffeine-related methylxanthines. *Virology* 2005; **335**: 177-184

9 **Xiao Z**, Xue J, Semizarov D, Sowin TJ, Rosenberg SH, Zhang H. Novel indication for cancer therapy: Chk1 inhibition

sensitizes tumor cells to antimitotics. *Int J Cancer* 2005; **115**: 528-538

10 **Liu Q**, Guntuku S, Cui XS, Matsuoka S, Cortez D, Tamai K, Luo G, Carattini-Rivera S, DeMayo F, Bradley A, Donehower LA, Elledge SJ. Chk1 is an essential kinase that is regulated by Atr and required for the G(2)/M DNA damage checkpoint. *Genes Dev* 2000; **14**: 1448-1459

11 **Hougardy BM**, Maduro JH, van der Zee AG, de Groot DJ, van den Heuvel FA, de Vries EG, de Jong S. Proteasome inhibitor MG132 sensitizes HPV-positive human cervical cancer cells to rhTRAIL-induced apoptosis. *Int J Cancer* 2006; **118**: 1892-900

12 **Qi M**, Aiken C. Selective restriction of Nef-defective human immunodeficiency virus type 1 by a proteasome-dependent mechanism. *J Virol* 2007; **81**: 1534-1536

13 **Lin M**, Chen Q, Yang LY, Li WY, Cao XB, Wu JR, Peng YP, Chen MR. Hepatitis B virus infection and replication in primarily cultured human fetal hepatocytes. *World J Gastroenterol* 2007; **13**: 1027-1031

14 **Wilkinson DE**, Weller SK. Herpes simplex virus type I disrupts the ATR-dependent DNA-damage response during lytic infection. *J Cell Sci* 2006; **119**: 2695-2703

15 **Liang X**, Pickering MT, Cho NH, Chang H, Volkert MR, Kowalik TF, Jung JU. Deregulation of DNA damage signal transduction by herpesvirus latency-associated M2. *J Virol* 2006; **80**: 5862-5874

16 **Shin YC**, Nakamura H, Liang X, Feng P, Chang H, Kowalik TF, Jung JU. Inhibition of the ATM/p53 signal transduction pathway by Kaposi's sarcoma-associated herpesvirus interferon regulatory factor 1. *J Virol* 2006; **80**: 2257-2266

17 **Gaspar M**, Shenk T. Human cytomegalovirus inhibits a DNA damage response by mislocalizing checkpoint proteins. *Proc Natl Acad Sci USA* 2006; **103**: 2821-2826

18 **Kudoh A**, Fujita M, Zhang L, Shirata N, Daikoku T, Sugaya Y, Isomura H, Nishiyama Y, Tsurumi T. Epstein-Barr virus lytic replication elicits ATM checkpoint signal transduction while providing an S-phase-like cellular environment. *J Biol Chem* 2005; **280**: 8156-8163

19 **Kumar A**, Zhao Y, Meng G, Zeng M, Srinivasan S, Delmolino LM, Gao Q, Dimri G, Weber GF, Wazer DE, Band H, Band V. Human papillomavirus oncoprotein E6 inactivates the transcriptional coactivator human ADA3. *Mol Cell Biol* 2002; **22**: 5801-5812

20 **Horner SM**, DeFilippis RA, Manuelidis L, DiMaio D. Repression of the human papillomavirus E6 gene initiates p53-dependent, telomerase-independent senescence and apoptosis in HeLa cervical carcinoma cells. *J Virol* 2004; **78**: 4063-4073

21 **Shi Y**, Dodson GE, Shaikh S, Rundell K, Tibbetts RS. Ataxia-telangiectasia-mutated (ATM) is a T-antigen kinase that controls SV40 viral replication in vivo. *J Biol Chem* 2005; **280**: 40195-40200

22 **Zimmerman ES**, Sherman MP, Blackett JL, Neidleman JA, Kreis C, Mundt P, Williams SA, Warmerdam M, Kahn J, Hecht FM, Grant RM, de Noronha CM, Weyrich AS, Greene WC, Planelles V. Human immunodeficiency virus type 1 Vpr induces DNA replication stress in vitro and in vivo. *J Virol* 2006; **80**: 10407-10418

23 **Daniel R**, Kao G, Taganov K, Greger JG, Favorova O, Merkel G, Yen TJ, Katz RA, Skalka AM. Evidence that the retroviral DNA integration process triggers an ATR-dependent DNA damage response. *Proc Natl Acad Sci USA* 2003; **100**: 4778-4783

24 **Roshal M**, Kim B, Zhu Y, Nghiem P, Planelles V. Activation of the ATR-mediated DNA damage response by the HIV-1 viral protein R. *J Biol Chem* 2003; **278**: 25879-25886

25 **Aguilar-Lemarroy A**, Gariglio P, Whitaker NJ, Eichhorst ST, zur Hausen H, Krammer PH, Rosl F. Restoration of p53 expression sensitizes human papillomavirus type 16 immortalized human keratinocytes to CD95-mediated apoptosis. *Oncogene* 2002; **21**: 165-175

26 **Poulaki V**, Mitsiades CS, Kotoula V, Negri J, McMillin D, Miller JW, Mitsiades N. The proteasome inhibitor bortezomib induces apoptosis in human retinoblastoma cell lines in vitro. *Invest Ophthalmol Vis Sci* 2007; **48**: 4706-4719

27 **Spano JP**, Bay JO, Blay JY, Rixe O. Proteasome inhibition: a new approach for the treatment of malignancies. *Bull Cancer* 2005; **92**: E61-E66, 945-952

28 **Kuhn DJ**, Chen Q, Voorhees PM, Strader JS, Shenk KD, Sun CM, Demo SD, Bennett MK, van Leeuwen FW, Chanan-Khan AA, Orlowski RZ. Potent activity of carfilzomib, a novel, irreversible inhibitor of the ubiquitin-proteasome pathway, against preclinical models of multiple myeloma. *Blood* 2007; **110**: 3281-3290

S- Editor Zhong XY **L- Editor** Wang XL **E- Editor** Lin YP

Online Submissions: wjg.wjgnet.com
wjg@wjgnet.com
doi:10.3748/wjg.14.5066

World J Gastroenterol 2008 August 28; 14(32): 5066-5072
World Journal of Gastroenterology ISSN 1007-9327
© 2008 The WJG Press. All rights reserved.

RAPID COMMUNICATION

Treatment of polycystic liver disease with resection-fenestration and a new classification

Tuan-Jie Li, Hai-Bin Zhang, Jun-Hua Lu, Jun Zhao, Ning Yang, Guang-Shun Yang

Tuan-Jie Li, Hai-Bin Zhang, Jun-Hua Lu, Jun Zhao, Ning Yang, Guang-Shun Yang, Eastern Hepatobiliary Hospital, Second Military Medical University, Shanghai 200438, China
Author contributions: Li TJ and Zhang HB contributed equally to this work; Yang GS and Lu JH designed the study; Zhao J and Yang N performed the study; Li TJ and Zhang HB wrote the paper.
Correspondence to: Dr. Guang-Shun Yang, Eastern Hepatobiliary Hospital, Second Military Medical University, Shanghai 200438, China. gs_yang00@yahoo.com
Telephone: +86-21-25070789 Fax: +86-21-25070789
Received: April 15, 2008 Revised: June 30, 2008
Accepted: July 7, 2008
Published online: August 28, 2008

Key words: Autosomal dominant polycyst liver disease; Autosomal dominant polycyst kidney disease; Fenestration

Peer reviewer: James Neuberger, Professor, Liver Unit, Queen Elizabeth Hospital, Birmingham B15 2TH, United Kingdom

Li TJ, Zhang HB, Lu JH, Zhao J, Yang N, Yang GS. Treatment of polycystic liver disease with resection-fenestration and a new classification. *World J Gastroenterol* 2008; 14(32): 5066-5072 Available from: URL: http://www.wjgnet.com/1007-9327/14/5066.asp DOI: http://dx.doi.org/10.3748/wjg.14.5066

Abstract

AIM: To evaluate outcomes in patients with autosomal dominant polycyst liver disease (APLD) treated by combined hepatic resection and fenestration. A new classification was recommended to presume postoperative complications and long outcome of patients.

METHODS: Twenty-one patients with APLD were treated by a combined hepatic resection and fenestration technique. All patients were reviewed retrospectively, and clinical symptoms, performance status and morbidity were recorded. A new classification of APLD is recommended here.

RESULTS: All patients were discharged when free of symptoms. The mean follow-up time was 55.7 mo and three patients had a recurrence of symptoms at 81, 68 and 43 mo after operation, respectively. The overall morbidity rate was 76.2%. Two patients with Type B-Ⅱ and Type B-Ⅰ developed biliary leakage. Four patients had severe ascites, including three with Type B-Ⅲ and one with Type B-Ⅱ. Nine patients had pleural effusion, including one with Type A-Ⅰ; one with Type B-Ⅰ; five with Type B-Ⅱ; one with Type A-Ⅲ and one with Type B-Ⅲ. Three patients with Type B had recurrence of symptoms, while none with Type A had severe complications.

CONCLUSION: Combined hepatic resection and fenestration is an acceptable procedure for treatment of APLD. According to our classification, postoperative complications and long outcome can be predicted before surgery.

© 2008 The WJG Press. All rights reserved.

INTRODUCTION

Autosomal dominant polycyst liver disease (APLD) is a genetic heterogeneous disorder characterized by progressive development of multiple fluid-filled, biliary epithelial liver cysts[1-5], and is frequently associated with autosomal dominant polycystic kidney disease[5-7]. Most cases of APLD are asymptomatic and do not require surgical treatment. However, a number of patients with highly symptomatic cystic hepatomegaly or with a complicated presentation would benefit from surgical decompression of the hepatomegaly[8]. Currently, there is controversy over what is the most appropriate therapeutic approach for APLD. Transient improvement with non-surgical treatment such as sclerosing agents has been reported[9,10]. Surgical therapies include laparoscopic fenestration[11-14], open fenestration[15-18], liver resection and fenestration[19-22], and liver transplantation[23-26]. In 1997, Giot *et al*[1] recommended a stratification scheme for the most appropriate surgical approach. In the present study, we evaluated outcomes in patients with APLD treated by combined hepatic resection and fenestration, and provided a new classification to presume the postoperative complications and long-term outcome of patients with APLD.

MATERIALS AND METHODS

Between May 1995 and May 2007, 21 patients with APLD-associated severe symptoms were referred to Eastern Hepatobiliary Surgery Hospital of the Second Military Medical University in Shanghai. They were

treated by a medical team headed by Dr. Yang *et al*, using the combined hepatic resection and fenestration technique. The patients included 19 women and two men ranging in age from 34 years to 63 years with a mean of 44.7 (median, 43) years. Of the 21 patients, 12 patients (57.1%) had a familial history of polycyst liver disease (PLD), and 17 patients (81.1%) had associated autosomal dominant polycystic kidney disease. The mean time lap between the diagnosis of APLD and surgery was 65.3 mo (median, 60; range, 1-240 mo). The mean duration of symptoms was 30.6 mo (median, 24; range, 1-168 mo). Specific symptoms included massive abdominal distention (20/21, 95.2%), early satiety (11/21, 52.4%), chronic abdominal pain (9/21, 42.9%), hypertension (8/21, 38.1%), ascites (5/21, 23.8%), supine dyspnea (3/21,14.3%), elevated temperature related to superinfected cysts (2/21, 9.5%), regurgitation (2/21, 9.5%) and pleural effusion (2/21, 9.5%). Abdominal examination revealed hepatomegaly in all patients. Eleven patients had received treatment previously, including percutaneous cyst aspiration with alcohol sclerotherapy in eight patients, laparotomic fenestration in two patients, and laparoscopic fenestration in one patient. Liver function tests were essentially normal, except for mild elevation of serum alkaline phosphatase in two patients, glutamyltranspeptidase in five patients, hypoalbuminemia and hyperbilirubinemia in four patients. All patients underwent an abdominal computed tomography (CT) scan in order to delineate cyst distribution, assess portal vein patency, and provide baseline measurement for follow-up comparison in each patient. Since some of the patients in our series were not appropriate for Giot classification[1], a new classification of APLD patients that is different from Giot classification was recommended. This new classification involved a preoperative evaluation of the number of deep cysts in the liver parenchyma that could not be treated during operation. Based on the preoperative evaluation, APLD patients were classified into two types: Type A, with a small number of cysts that could not be treated and left in the deep site of the liver parenchyma (usually $\leqslant$ 15),and Type B, with a large number of such cysts (usually $\geqslant$ 15). For each type, according to the location of cysts diffused in the liver, they were further classified into three grades: Grade I included patients with diffused cysts occupying less than one lobe of the liver; Grade Ⅲ was a severe form of APLD with liver parenchyma involving fewer than 3 segments; and Grade Ⅱ was the grade between Grade I and Ⅲ, where liver parenchyma was limited in the right lobe or left lobe of the liver, or involving 3-4 segments, but not limited in one lobe of the liver (Figure 1).

Preoperative preparations of each patient included: electrocardiography (ECG), gastroscopy and pulmonary function, major medical contraindications for surgical resection were identified, and specific hepatic factors were evaluated. In 13 patients, prothrombin time (PT) was prolonged (within 3 s above the normal reference). Venous catheterization was also important with these patients. The abdomen was explored through a bilateral subcoastal incision. The hepatoduodenal ligament was explored to provide access to vascular clamping areas and to identify major vascular and biliary structures. The liver was mobilized by the division of hepatic peritoneal attachments, which was facilitated by sequential fenestration of accessible cysts according to the Lin technique[15]. Liver segments spared of cystic involvement were identified to define limits of resection. No anatomic segmental or lobar planes were removed even if cysts distorted the normal anatomy. Liver segments spared of cystic involvement were identified prior to parenchymal transaction to define limits of resection. Significant islands of functional liver parenchyma were preserved when possible. Two to five segments were resected during operation. After resection of the major cyst segments, extensive fenestration of the residual cysts in the parenchyma was addressed by excision of the cyst walls. Using cautery, the transection plane was developed further by division and excision of the inter-cystic septa[27]. Vascular and biliary radicals that coursed through the cyst septa were lighted as indicated. Finally, cyst cavities exposed to the peritoneum were fulgurated by argon beam coagulation (Bard Electromedical Systems, USA) in 15 patients in an attempt to ablate secretory epithelium and reduce postoperative peritoneal fluid losses[28]. The portal vein, hepatic vein and small bile duct were identified and carefully protected in order to avoid hemorrhage and bile leakage. Cholecystectomy was performed in seven patients. The hepatic resection beds were drained by two large closed suction drains. Eighteen patients were monitored in the intensive care unit. Both colloid and crystalloid fluids were used for volume replacement to compensate for expected postoperative fluid losses and excessive peritoneal drainage. Fluid maintenance and hemodynamic balance were aided by central venous pressure. Postoperative blood gas analysis was examined in all patients. All patients were followed-up through either telephone calls or at clinical visits. Special data included CT scan and current hepatic and renal function test. SPSS 10.0 was used for statistical analysis.

RESULTS

No patient died during the operation. All 21 patients were discharged from the hospital free of the preoperative symptoms. The mean postoperative hospital stay was 15.5 d (median, 13; range, 6-60 d). The mean operation time was 247.6 min (median, 225 min; range, 150-435 min). Component transfusion was given intraoperatively and during hospitalization in 16 patients. The median transfusion of packed red blood cells was 4.5 units (range, 1-20 units). The median transfusion of blood plasma was 1400 mL (range, 200-4600 mL). Fifteen patients had ascites. The mean duration of drainage was 8.29 d (median, 5 d; range, 2-57 d). Needle aspiration was attempted to prevent ascites from infection. Seven patients received continuous needle aspiration to relieve ascites, with a

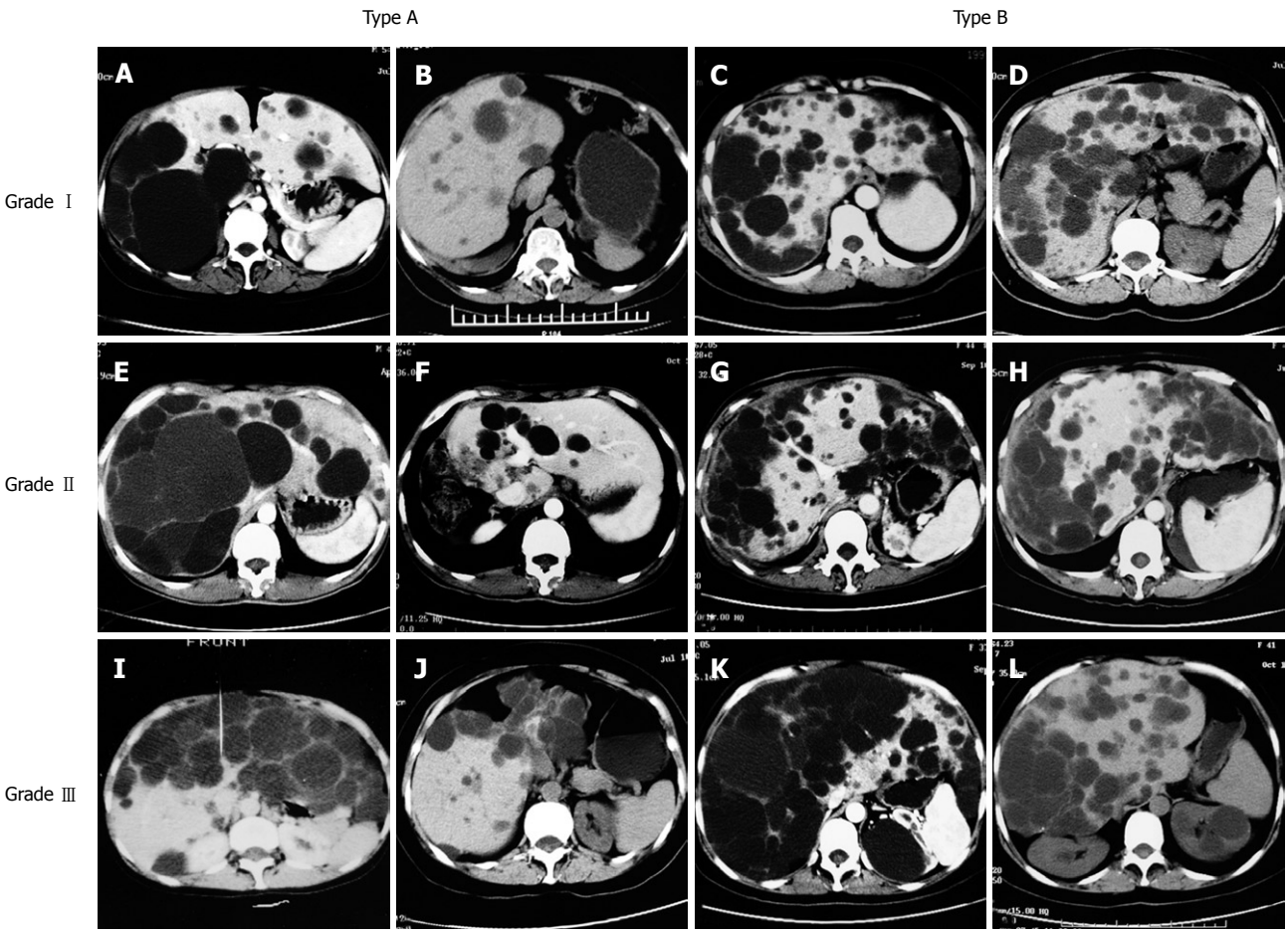

Figure 1 CT examinations of our classification of APLD. **A** and **B**: Type A-Ⅰ, preoperative and postoperative CT examinations; **C** and **D**: Type B-Ⅰ, preoperative and postoperative CT examinations; **E** and **F**: Type A-Ⅱ, preoperative and postoperative CT examinations; **G** and **H**: Type B-Ⅱ, preoperative and postoperative CT examinations; **I** and **J**: Type A-Ⅲ, preoperative and postoperative CT examinations; **K** and **L**: Type B-Ⅲ, preoperative and postoperative CT examinations.

mean duration of 7.54 d (median, 4 d; range, 3-24 d). Eight patients were successfully managed with diuretics and drainage was achieved within one week. Nine patients had pleural effusion, of which 6 patients needed thoracentesis due to chest distress. Bile leakage occurred in two patients. Postoperative hemorrhage occurred in one patient. The overall morbidity rate was 76.2%. There was a morbidity rate of 38.1% for complications that required special treatment. These included severe ascites, bile leakage, hemorrhage, and pleural effusion. The mean follow-up duration was 60.7 mo (median, 59; range, 10-155 mo). Two patients died of renal failure due to polycystic kidney disease at 137 and 85 mo after operation. Three patients had recurrence of the symptoms at 81, 68 and 43 mo after operation with a recurrence rate of (3/21) 14.3%. Total bilirubin was slightly elevated in two patients. The symptoms (occasional abdominal swelling and abdominal pain) of three patients were not severe, therefore they received outpatient treatment.

Follow-up CT data were available in 19 patients, and lost in the remaining two patients who died. Six patients were classified as Type A, including three with Grade Ⅰ, one with Grade Ⅱ and two with Grade Ⅲ. Thirteen patients were classified as Type B APLD, including one with Grade Ⅰ, eight with Grade Ⅱ and four with Grade Ⅲ. The mean age, mode of presentation, duration of symptoms, mean operation time, intra-operative component transfusion and hospital stay were not significantly different between the two types.

Of the six patients with Type A in our series, three had mild ascites and one had pleural effusion after operation. None of the patients with Type A had severe complications. In patients with Type B in our series, one with Grade Ⅱ who received laparoscopic treatment 4 years earlier had massive hemorrhage after operation. Biliary complications occurred in two patients, including one with Grade Ⅱ and one with Grade Ⅲ. Severe ascites occurred in three patients with Grade Ⅲ and one patient with Grade Ⅱ. Eight patients had pleural effusion, including one with Grade Ⅰ, six with Grade Ⅱ, and one with Grade Ⅲ. Eleven patients had mild ascites, including two with Grade Ⅰ, seven with Grade Ⅱ, and two with Grade Ⅲ. Symptoms reoccurred in three patients with Type B, including one with Grade Ⅰ, and two patients with Grade Ⅱ. The follow-up ranged from 12 mo to 155 mo with a mean of 61.2 mo for Type A patients, and from 10 mo to 141 mo with a mean of 58.2 mo for Type B patients. There was no significant difference in follow-up duration between the two types. Postoperative complications and symptom recurrence based on our APLD classification are presented in Table 1.

Table 1 Postoperative complications and symptom recurrence based on our APLD classification

Classification		*n*	Severe ascites	Pleural effusion	Bile leakage	Mild ascites	Hemorrhage	Recurrence
Type A	Ⅰ	3	-	1	-	1	-	-
	Ⅱ	1	-	-	-	1	-	-
	Ⅲ	2	-	-	-	1	-	-
Type B	Ⅰ	1	-	-	-	1	-	1
	Ⅱ	8	1	6	1	6	1	2
	Ⅲ	4	3	1	1	1	-	-
Total		19	4	8	2	11	1	3

Table 2 Review of the literature: mortality, morbidity and outcome of patients with APLD treated by combined hepatic resection and cystic fenestration

Authors[ref]	Number of patients	Mortality (%)	Morbidity (%)	Mean follow-up (mo)	Rate of symptom recurrence (%)	Re-operation (%)
Turnage[18]	3	2 (67)	2 (67)	9.6	33	0
Vauthey[19]	5	0	5 (100)	14	0	0
Henne-Bruns[35]	8	0	3 (38)	15	50	0
Que[20]	31	1 (3)	18 (58)	28	3	0
Soravia[36]	10	1 (10)	2 (20)	68	33	11
Koperna[11]	5	0	NR	NR	0	0
Ours	21	0	16 (76)	60.7	14	0

NR: No report.

DISCUSSION

APLD is a rare disorder usually associated with autosomal dominant kidney disease[7,29]. An increasing prevalence is associated with age and female sex[30]. Symptoms usually arise from liver enlargement and compression of adjacent organs. Most symptomatic patients complained of an increasing abdominal girth and chronic abdominal dull pain. Liver enlargement may cause early satiety, respiration compromise, and physical disability. Complications such as portal hypertension, pleural effusion, esophageal varices, obstructive jaundice, hepatic failure and malignant degeneration are rare[31-33]. In patients with APLD, the optimal treatment is still under dispute. Percutaneous aspiration with alcohol sclerotherapy seems valuable for solitary cysts but not for patients with APLD because cyst collapse may not be sufficient[9,10]. In 1968, Lin *et al*[15] reported the use of a more extensive cyst fenestration procedure in three patients in whom successively deeper cysts were unroofed and drained through more superficial ones, resulting in a long-term favorable outcome. Kabbej *et al*[13] reported in a recent study that 13 patients with APLD underwent laparoscopic fenestration, with a symptom recurrence rate of 72% during a mean follow-up of 26 mo. In patients with the majority of cysts in segments Ⅵ, Ⅶ, Ⅷ, and in patients with deeply seated cysts that are difficult to visualize and fenestrate with laparoscopy, the postoperative recurrence rate is usually high due to inadequate fenestration of all cysts[12,14,34]. Armitage *et al*[27] described a patient with APLD who was treated by partial hepatic resection and cyst fenestration in 1984. This procedure allowed for excision of most prominent cysts with minimal resection of the liver tissue, and the liver parenchyma was preserved as much as possible. Other reports have shown the feasibility of such an approach[11,18-20,35,36](Table 2).

We have already reported seven patients with APLD who were treated by hepatic resection and cyst fenestration during a follow-up of 20.4 mo[22]. All patients were relieved of the symptoms after operation. Mild symptoms recurred in three patients, and symptoms were relieved after treatment in the ambulatory clinic at 6-mo intervals. The long-term benefit of combined hepatic resection and fenestration depends on whether there is a progressive increase in size of deep residual untreated liver cysts rather than new cyst development[1]. Our experience with the treatment of Type B patients also supports this conclusion. Current data of the natural history of autosomal dominant polycyst kidney disease (APKD) and APLD suggest that progression of cystic disease is slow, affording the possibility of prolonged benefit. Our experience with combined hepatic resection and fenestration shows that some patients with massive polycystic liver benefit markedly from this procedure. No patients with polycystic kidney disease had kidney failure during operation. Two patients in our series died of renal failure during the follow-up period due to polycystic kidney disease. Whether this operation technique affects renal function is still unknown.

According to our classification of APLD patients with Type A seemed less likely to have severe complications after operation. None in Type A had severe ascites or bile leakage in our studies. Patients in every grade with Type A, had more cysts to be resected than cysts to be fenestrated during operation. In addition, their cysts in the liver parenchyma were relatively superficial, and could be treated easily. After fenestration there was little difference in cyst epithelium areas exposed to the abdominal cavity in each grade of patients with Type

A, so their ascites and pleural effusion occurrence rates were seemly no different after operation. Some Type A patients had small bile leakage or hemorrhage during the operation, but these were found easily during operation. In different grades, operative technical difficulties to repair these leakages and hemorrhages were different. Patients in Grade Ⅲ had large numbers of cysts to be resected or fenestrated, and vascular and biliary radicals coursing through the cyst septa were more difficult to recognize than those of patients in Grade Ⅱ or Grade Ⅰ. Operative risk factors increased with increasing grades. Vascular and biliary radicals should be recognized and protected during operation to avoid injury, especially for patients in Grade Ⅲ.

In Type B patients, a proportion of cysts needed resection, but most cysts in the liver parenchyma could not be resected in order to preserve liver parenchyma as much as possible. Therefore, Type B patients had more cysts requiring fenestration, and cyst epithelium areas that were exposed to the abdominal cavity were also larger. Since cystic epithelium functions in secretion[37], severe ascites occur more in Type B. Severe ascites was found in four patients in Type B, including three with Grade Ⅲ and one with Grade Ⅱ. Patients with Grade Ⅲ had more cysts to be fenestrated than patients with Grade Ⅱ, and patients with Grade Ⅱ more than patients with Grade Ⅰ during operation. Patients with Grade Ⅲ also had larger cyst epithelium areas exposed to the abdominal cavity than Grade Ⅱ, and patients with Grade Ⅱ more than patients with Grade Ⅰ after operation. We presume that patients with Grade Ⅲ are more likely to develop asctes than patients with Grade Ⅱ, and patients with Grade Ⅱ are more likely to develop asctes than patients with Grade Ⅰ. Bile leakage occurred in two patients in our series with Type B, including one with Grade Ⅲ and one with Grade Ⅱ. Patients with Type B had more cysts in the deep liver parenchyma. We attempted to fenestrate the cysts when possible, though it was dangerous to fenestrate deep interseptal cysts without sufficient exposure. Two risk factors may contribute to biliary complications. One is the possible injury to small biliary radicals on the surface of the cyst lining, when the cyst lining was fulgurated by argon beam coagulation to ablate secretory epithelium The other is that biliary ducts distorted in polycystic liver anatomy are usually difficult to identify, and likely to be injured within cystic septa during a fenestration procedure especially of deep cysts[1]. These two patients with peritoneal closed suction drainage had spontaneous resolution 27 d and 56 d after operation as identified by subsequent radiologic examination. Therefore we recommend a clearly routine examination on the wound surface to avoid missing the biliary ducts and veins which are possibly injured by the end of the operation.

Our classification of APLD applied the postoperative course which was uncomplicated in six patients with Type A, including three patients with mild ascites and one patient with pleural effusion. No patient in Type A had symptom recurrence in the follow-up period. In Type B, two patients had bile leakage, four had severe ascites, seven had pleural effusion, and three had symptom recurrence. Type A APLD patients may have good immediate and long-term outcomes, so we recommend a combined hepatic resection and fenestration. Symptom recurrence was related to a progressive increase in size of deep residual untreated liver cysts. Patients in Grade Ⅰ and in Grade Ⅱ with Type B had more cysts in deep sites within the liver parenchyma, which could not be treated during operation, therefore those patients had a high rate of symptom recurrence. Cysts in Grade Ⅲ patients can be resected or fenestrated effectively during operation, leading to less symptom recurrence. So we recommend a new classification to predict the postoperative complications and long-term outcome of patients with APLD. This classification still needs to be validated in the future.

We had two patients who received laparotomic fenestration and one patient received laparoscopic fenestration previously. They had symptom reoccurrence 99, 67 and 53 mo after operation, and received combined liver resection and fenestration. They are living well asymptomatically. But in these patients, more intense intra-abdominal adhesions posed technical difficulties[28]. Their complications were severe after operation, including one that had abdominal hemorrhage, and one that had severe ascites and bile leakage. The patient who underwent laparoscopic fenestration previously had an abdominal hemorrhage in the right lobe, due to tight adhesion of the cyst wall with the diaphragm, where a small artery was not ligated after stripping. Hemorrhage occurred when blood pressure was returned to normal after operation. For these patients, combined fenestration with resection still can be considered as the choice of treatment, but their operation should be performed by experienced surgical teams due to their severe postoperative complications. Liver transplantation as a treatment for APLD may be another good way to treat APLD, but it has a limited role due to the shortage of liver donors and severe postoperative complications. Two large studies reported by Lang *et al*[24] and Pirenne *et al*[25] reported the outcomes of liver transplantation in 17 and 16 patients respectively. The former reported 5 deaths (29%) and the latter reported 2 deaths (12.5%). The mortality they reported is higher than that in patients who received combined fenestration procedures. Patients with APLD who receive liver transplantation are placed on immune suppression therapy, and therefore do not have a "normal immune system." Immune suppressants have many side effects on patients with liver transplantation, and after operation they still need much attention to sustain the state of immune suppression to avoid graft rejection. Starzl and his colleagues described the "syndrome of lethal exhaustion" as the major indication to consider when offering transplantation to these patients[38]. We fully agree that liver transplantation should be used for patients with cachexia, weight loss, portal hypertension, refractory ascites, liver insufficiency or associated with severe kidney disease[24,25,39,40]. Liver resection and fenestration of the remnant liver are more effective than

fenestration and less invasive than liver transplantation, combined liver resection and fenestration should be considered as the choice for treatment for APLD.

COMMENTS

Background

Autosomal dominant polycyst liver disease (APLD) is a rare disorder usually associated with autosomal dominant kidney disease with an increasing prevalence associated with age and female sex. Symptoms usually arise from liver enlargement and compression of adjacent organs. Surgical therapies include laparoscopic fenestration, open fenestration, liver resection and fenestration, and liver transplantation, what is the optimal treatment is still under dispute.

Research frontiers

The study analyzed and summarized the author's clinical experiences in recent 12 years in the treatment of APLD and in an attempt to propose some practicable guidelines, and suggested a new classification to presume postoperative complications and long outcome of each patient.

Innovations and breakthroughs

Combined hepatic resection-fenestration is a good choice for the treatment of highly symptomatic adult polycystic liver disease. According to the author's classification, postoperative complications and long outcome of each patient can be predicted before surgery.

Applications

The study provides some practicable guidelines for the treatment of APLD, and according to the author's classification, postoperative complications and long outcome of each patient can be predicted before surgery.

Peer review

The paper analyzed and summarized some practicable experience for the treatment of APLD and recommended a new classification. It is valuable to see the actual results from various therapies and the new classification by the authors over the last 12 years.

REFERENCES

1 **Gigot JF**, Jadoul P, Que F, Van Beers BE, Etienne J, Horsmans Y, Collard A, Geubel A, Pringot J, Kestens PJ. Adult polycystic liver disease: is fenestration the most adequate operation for long-term management? *Ann Surg* 1997; **225**: 286-294

2 **Grimm PC**, Crocker JF, Malatjalian DA, Ogborn MR. The microanatomy of the intrahepatic bile duct in polycystic disease: comparison of the cpk mouse and human. *J Exp Pathol* (Oxford) 1990; **71**: 119-131

3 **Ramos A**, Torres VE, Holley KE, Offord KP, Rakela J, Ludwig J. The liver in autosomal dominant polycystic kidney disease. Implications for pathogenesis. *Arch Pathol Lab Med* 1990; **114**: 180-184

4 **Perrone RD**, Grubman SA, Rogers LC, Lee DW, Moy E, Murray SL, Torres VE, Jefferson DM. Continuous epithelial cell lines from ADPKD liver cysts exhibit characteristics of intrahepatic biliary epithelium. *Am J Physiol* 1995; **269**: G335-G345

5 **Milutinovic J**, Fialkow PJ, Rudd TG, Agodoa LY, Phillips LA, Bryant JI. Liver cysts in patients with autosomal dominant polycystic kidney disease. *Am J Med* 1980; **68**: 741-744

6 **Levine E**, Cook LT, Grantham JJ. Liver cysts in autosomal-dominant polycystic kidney disease: clinical and computed tomographic study. *AJR Am J Roentgenol* 1985; **145**: 229-233

7 **D'Agata ID**, Jonas MM, Perez-Atayde AR, Guay-Woodford LM. Combined cystic disease of the liver and kidney. *Semin Liver Dis* 1994; **14**: 215-228

8 **Comfort MW**, Gray HK, Dahlin DC, Whitesell FB Jr. Polycystic disease of the liver: a study of 24 cases. *Gastroenterology* 1952; **20**: 60-78

9 **Kairaluoma MI**, Leinonen A, Stahlberg M, Paivansalo M, Kiviniemi H, Siniluoto T. Percutaneous aspiration and alcohol sclerotherapy for symptomatic hepatic cysts. An alternative to surgical intervention. *Ann Surg* 1989; **210**: 208-215

10 **Tikkakoski T**, Makela JT, Leinonen S, Paivansalo M, Merikanto J, Karttunen A, Siniluoto T, Kairaluoma MI. Treatment of symptomatic congenital hepatic cysts with single-session percutaneous drainage and ethanol sclerosis: technique and outcome. *J Vasc Interv Radiol* 1996; **7**: 235-239

11 **Koperna T**, Vogl S, Satzinger U, Schulz F. Nonparasitic cysts of the liver: results and options of surgical treatment. *World J Surg* 1997; **21**: 850-854; discussion 854-855

12 **Morino M**, De Giuli M, Festa V, Garrone C. Laparoscopic management of symptomatic nonparasitic cysts of the liver. Indications and results. *Ann Surg* 1994; **219**: 157-164

13 **Kabbej M**, Sauvanet A, Chauveau D, Farges O, Belghiti J. Laparoscopic fenestration in polycystic liver disease. *Br J Surg* 1996; **83**: 1697-1701

14 **Martin IJ**, McKinley AJ, Currie EJ, Holmes P, Garden OJ. Tailoring the management of nonparasitic liver cysts. *Ann Surg* 1998; **228**: 167-172

15 **Lin TY**, Chen CC, Wang SM. Treatment of non-parasitic cystic disease of the liver: a new approach to therapy with polycystic liver. *Ann Surg* 1968; **168**: 921-927

16 **van Erpecum KJ**, Janssens AR, Terpstra JL, Tjon A Tham RT. Highly symptomatic adult polycystic disease of the liver. A report of fifteen cases. *J Hepatol* 1987; **5**: 109-117

17 **Sanchez H**, Gagner M, Rossi RL, Jenkins RL, Lewis WD, Munson JL, Braasch JW. Surgical management of nonparasitic cystic liver disease. *Am J Surg* 1991; **161**: 113-118; discussion 118-119

18 **Turnage RH**, Eckhauser FE, Knol JA, Thompson NW. Therapeutic dilemmas in patients with symptomatic polycystic liver disease. *Am Surg* 1988; **54**: 365-372

19 **Vauthey JN**, Maddern GJ, Blumgart LH. Adult polycystic disease of the liver. *Br J Surg* 1991; **78**: 524-527

20 **Que F**, Nagorney DM, Gross JB Jr, Torres VE. Liver resection and cyst fenestration in the treatment of severe polycystic liver disease. *Gastroenterology* 1995; **108**: 487-494

21 **Vons C**, Chauveau D, Martinod E, Smadja C, Capron F, Grunfeld JP, Franco D. [Liver resection in patients with polycystic liver disease] *Gastroenterol Clin Biol* 1998; **22**: 50-54

22 **Yang GS**, Li QG, Lu JH, Yang N, Zhang HB, Zhou XP. Combined hepatic resection with fenestration for highly symptomatic polycystic liver disease: A report on seven patients. *World J Gastroenterol* 2004; **10**: 2598-2601

23 **Kirchner GI**, Rifai K, Cantz T, Nashan B, Terkamp C, Becker T, Strassburg C, Barg-Hock H, Wagner S, Luck R, Klempnauer J, Manns MP. Outcome and quality of life in patients with polycystic liver disease after liver or combined liver-kidney transplantation. *Liver Transpl* 2006; **12**: 1268-1277

24 **Lang H**, von Woellwarth J, Oldhafer KJ, Behrend M, Schlitt HJ, Nashan B, Pichlmayr R. Liver transplantation in patients with polycystic liver disease. *Transplant Proc* 1997; **29**: 2832-2833

25 **Pirenne J**, Aerts R, Yoong K, Gunson B, Koshiba T, Fourneau I, Mayer D, Buckels J, Mirza D, Roskams T, Elias E, Nevens F, Fevery J, McMaster P. Liver transplantation for polycystic liver disease. *Liver Transpl* 2001; **7**: 238-245

26 **Demirci G**, Becker T, Nyibata M, Lueck R, Bektas H, Lehner F, Tusch G, Strassburg C, Schwarz A, Klempnauer J, Nashan B. Results of combined and sequential liver-kidney transplantation. *Liver Transpl* 2003; **9**: 1067-1078

27 **Armitage NC**, Blumgart LH. Partial resection and fenestration in the treatment of polycystic liver disease. *Br J Surg* 1984; **71**: 242-244

28 **Newman KD**, Torres VE, Rakela J, Nagorney DM. Treatment of highly symptomatic polycystic liver disease. Preliminary experience with a combined hepatic resection-fenestration procedure. *Ann Surg* 1990; **212**: 30-37

29 **Feldman M**. Polycystic disease of the liver. *Am J Gastroenterol* 1958; **29**: 83-86
30 **Gabow PA**, Johnson AM, Kaehny WD, Manco-Johnson ML, Duley IT, Everson GT. Risk factors for the development of hepatic cysts in autosomal dominant polycystic kidney disease. *Hepatology* 1990; **11**: 1033-1037
31 **Ratcliffe PJ**, Reeders S, Theaker JM. Bleeding oesophageal varices and hepatic dysfunction in adult polycystic kidney disease. *Br Med J* (Clin Res Ed) 1984; **288**: 1330-1331
32 **Wittig JH**, Burns R, Longmire WP Jr. Jaundice associated with polycystic liver disease. *Am J Surg* 1978; **136**: 383-386
33 **Washburn WK**, Johnson LB, Lewis WD, Jenkins RL. Liver transplantation for adult polycystic liver disease. *Liver Transpl Surg* 1996; **2**: 17-22
34 **Marks J**, Mouiel J, Katkhouda N, Gugenheim J, Fabiani P. Laparoscopic liver surgery. A report on 28 patients. *Surg Endosc* 1998; **12**: 331-334
35 **Henne-Bruns D**, Klomp HJ, Kremer B. Non-parasitic liver cysts and polycystic liver disease: results of surgical treatment. *Hepatogastroenterology* 1993; **40**: 1-5
36 **Soravia C**, Mentha G, Giostra E, Morel P, Rohner A. Surgery for adult polycystic liver disease. *Surgery* 1995; **117**: 272-275
37 **Everson GT**, Emmett M, Brown WR, Redmond P, Thickman D. Functional similarities of hepatic cystic and biliary epithelium: studies of fluid constituents and in vivo secretion in response to secretin. *Hepatology* 1990; **11**: 557-565
38 **Starzl TE**, Reyes J, Tzakis A, Mieles L, Todo S, Gordon R. Liver transplantation for polycystic liver disease. *Arch Surg* 1990; **125**: 575-577
39 **Swenson K**, Seu P, Kinkhabwala M, Maggard M, Martin P, Goss J, Busuttil R. Liver transplantation for adult polycystic liver disease. *Hepatology* 1998; **28**: 412-415
40 **Russell RT**, Pinson CW. Surgical management of polycystic liver disease. *World J Gastroenterol* 2007; **13**: 5052-5059

S- Editor Zhong XY **L- Editor** Alpini GD **E- Editor** Yin DH

Online Submissions: wjg.wjgnet.com
wjg@wjgnet.com
doi:10.3748/wjg.14.5073

World J Gastroenterol 2008 August 28; 14(32): 5073-5077
World Journal of Gastroenterology ISSN 1007-9327
© 2008 The WJG Press. All rights reserved.

RAPID COMMUNICATION

Treatment of upper gastrointestinal fistula and leakage with personal stage nutrition support

Qun Wang, Zhi-Su Liu, Qun Qian, Quan Sun, Ding-Yu Pan, Yue-Ming He

Qun Wang, Zhi-Su Liu, Qun Qian, Quan Sun, Ding-Yu Pan, Department of General Surgery, Zhongnan Hospital, Wuhan University, Wuhan 430071, Hubei Province, China
Yue-Ming He, Department of Digestive Disease Research Center of Zhongnan Hospital, Wuhan University, Wuhan 430071, Hubei Province, China
Author contributions: Wang Q and Liu ZS contributed equally to this work; Wang Q, Liu ZS and Pan DY designed the research; Wang Q, Liu ZS, Pan DY ,Qian Q and Sun Q performed the research; Wang Q, He YM, Liu ZS and Pan DY analyzed the data; and Wang Q wrote the paper.
Correspondence to: Zhi-Su Liu, Professor, Department of General Surgery, Zhongnan Hospital, Wuhan University, No. 169, Donghu Road, Wuhan 430071, Hubei Province, China. swander@126.com
Telephone: +86-27-67813007 Fax: +86-27-87330795
Received: December 23, 2007 Revised: July 14, 2008
Accepted: July 21, 2008
Published online: August 28, 2008

Abstract

AIM: To investigate the feasibility of treatment for upper gastrointestinal fistula and leakage with personal stage nutrition support.
METHODS: Forty-three patients with upper gastrointestinal fistula and leakage were randomly divided into two groups. Patients in group A were treated with personal stage nutrition support and patients in group B were treated with total parental nutrition (TPN) in combination with operation. Nutritional states of the candidates were evaluated by detecting albumin (Alb) and pre-Alb. The balance between nutrition and hepatic function was evaluated by measurement of aspartate aminotransferase (AST), alanine aminotransferase (ALT) and total bilirubin (Tbill) before and after operation. At the same time their complications and hospitalized time were surveyed.
RESULTS: Personal stage nutrition support improved upper gastrointestinal fistula and leakage. The nutrition state and hepatic function were better in patients who received personal stage nutrition support than in those who did not receive TPN. There was no significant difference in the complication and hospitalized time in the two groups of patients.
CONCLUSION: Upper gastrointestinal fistula and leakage can be treated with personal stage nutrition support which is more beneficial for the post-operation recovery and more economic than surgical operation.

© 2008 The WJG Press. All rights reserved.

Key words: Personal stage nutrition support; Treatment; Upper gastrointestinal fistula and leakage; Total parental nutrition; Enteral nutrition

Peer reviewer: Dr. Bernardino Rampone, Department of General Surgery and Surgical Oncology, University of Siena, viale Bracci, Siena 53100, Italy

Wang Q, Liu ZS, Qian Q, Sun Q, Pan DY, He YM. Treatment of upper gastrointestinal fistula and leakage with personal stage nutrition support. *World J Gastroenterol* 2008; 14(32): 5073-5077 Available from: URL: http://www.wjgnet.com/1007-9327/14/5073.asp DOI: http://dx.doi.org/10.3748/wjg.14.5073

INTRODUCTION

The primary causes of death secondary to gastrointestinal fistulae and leakage include malnutrition, electrolyte imbalance, and sepsis. Without help of an experienced nutrition team, patients with gastrointestinal fistulae and leakage may not tolerate nutrition support and would have more severe pain due to the doctor's negligence. Nutritional support can improve wound healing[1] and gastrointestinal permeability[2], decrease catabolic response to injury[3] and bacterial translocation[4], and achieve better clinical outcomes, including a decrease in complications and hospital stay time and cost saving[5-8]. It is necessary to find a perfect treatment for gastrointestinal fistulas. More studies have been done on the gastrointestinal fistula, especially on upper gastrointestinal fistula and leakage. Absolute diet has been recognized as a routine diet during treatment of digestive fistula and leakage, and total parental nutrition (TPN) has been accepted by many doctors. We have successfully treated acute pancreatitis with "personal stage nutrition support" in the past 10 years. On this basis, we wonder if we can develop a new way of "personal stage nutrition support" for upper gastrointestinal fistula and leakage.

METERIALS AND METHODS

Patients

Forty-three patients (27 males and 16 females) with upper gastrointestinal fistula and leakage were selected

from Zhongnan Hospital Wuhan University from January 2005 to November 2007. Their age was 20 to 72 years with a mean age of 51.3 ± 2.6 years. The occurrence of upper gastrointestinal fistula was due to emergency of trauma in 6 patients, post-operation for gastric ulcer in 13 patients, excision of duodenum ulcer in 8 patients. Sixteen patients had leakage after gastric perforation neoplasty. Patients with malnutrition or liver dysfunction induced by cancer, tuberculosis, severe anemia, malabsorption, hepatitis, hepatic cirrhosis and other severe cardiovascular disease were excluded. Endoscopy revealed the position of the fistula and leakage above the Vater ampulla. All patients had no severe abdominal cavity infection before surgery and were divided into group A and group B. Group A, that received personal stage nutritional support, served as an experimental group. Group B that received TPN served as a control group. Those who did not finish the treatment plan were excluded. All patients were numbered randomly. During the treatment, all data including electrolyte, liver function, renal function, blood analysis and complications were submitted to professor Yue-Ming He to decide whether it was necessary for the patients to quit from or receive the treatment plan.

Treatment intervention

Nutrition support for group A was carried out in three steps: TPN stage, parental nutrition (PN) + enteral nutrition (EN) stage, and total enteral nutrition (TEN) stage. (1) TPN stage lasted 4-10 d (mean 7.8 ± 2.2 d). All the patients were asked to take absolute diet and supplied with 10-20 g/d albumin (Alb) and somatostatin. (2) PN + EN stage lasted 8-15 d (mean 11.6 ± 3.0 d). When the function of stomach and intestine recovered with the signal of outgas or defecation, EN was performed. In brief, one spiral nasojejunal feeding tube (Nutricia Company, Holland) was placed in the intestine below Treitz ligament (Figure 1) with the help of intestine enterokinesia after removal of the spiral coil guide wire. The distance from the tip of the tube to the orificium fistula was greater than 30 cm. The position of the nasojejunal tube should be confirmed by X-ray after 8-12 h since auscultation and pH aspiration techniques are inconclusive[9]. Nutrient substance was injected into jejunum through the spiral nasojejunal feeding tube. At the same time, we provided the patients with part parental nutrition as supplements. Chinese folk foods such as rice-water, fruit juice, vegetable soup, gravy soup, bean juice, as well as milk and peptison, could be used as nutrient substances and must be discontinued as soon as complications including stomachache, abdominal distension or diarrhea occurred. After we changed the speed and quantity of injection, all patients finished the stage. During this stage, somatotropin was also used. (3) TEN stage lasted 6-8 d (mean 7.5 ± 1.2 d). After completion of the PN + EN stage, we started the third stage, namely TEN stage which was started with closure of the fistula by endoscopic examination. After 35 d, the patients were asked to drink fresh water and take food. Gastrointestinal decompression and drain were performed through the spiral nasojejunal feeding tube in the first stage. At the same time, water and electrolyte disturbances must be prevented by changing ingredient and quantity of nutrient substances. Antibiotics (ceftriaxone sodium) and gastric acid secretion inhibitors (omeprazole) were given by intravenous drip in the first stage.

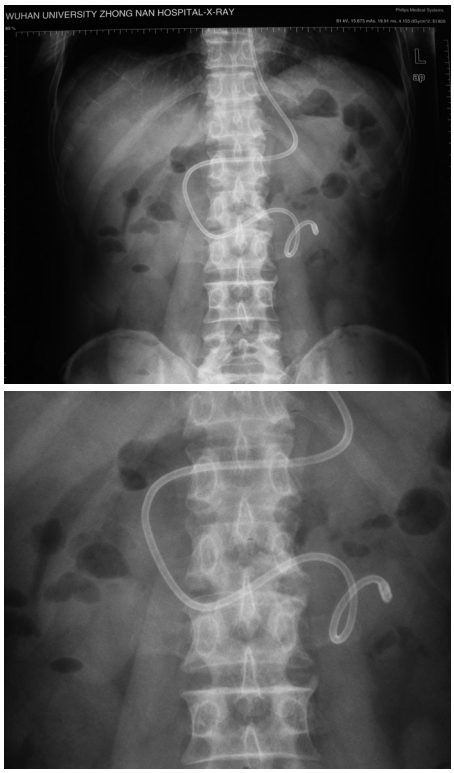

Figure 1 Placement of a spiral nasojejunal feeding tube in the intestine below Treitz ligament, 48 h after X-ray examination.

Patients in group B were given TPN through a central venous catheter which was inserted into the superior vena cava *via* one of the subclavian veins and advanced into the superior vena cava before and after operation. Basic heat energy was calculated depending on Harris-Benedict's formula, the mean heat energy was 10460kJ (2000-2500 kcal) per day. Nutritional liquids containing glucose and amino acids were supplied with 8368 kJ (2000 kcal). Amino acids (9.4-14.1 g) were provided every day and 500-1000 mL of 10% intralipid was given to meet the need of fat. No hyperlipemia occurred in our patients. Gastrointestinal decompression and drain were carried out for 7 d. Antibiotics (ceftriaxone sodium) and gastric acid secretion inhibitors (omeprazole) were given by intravenous drip for 7 d.

The electrolyte, liver and renal function, and blood analysis were monitored for preventing electrolyte disturbances and infection. Fluid needs could usually be met by giving 30-35 mL/kg body weight although allowance must be made for excessive losses from drains and fistulae, *etc.* The feeds contain adequate electrolytes to meet the daily requirement of sodium, potassium, calcium, magnesium and phosphate, although specific requirements may vary greatly.

Table 1 Levels of Alb, TSF and pre-Alb at different time points in the two groups (mean ± SD)

Time	Alb (g/L)			TSF (g/L)			Pre-Alb (mg/L)		
	A	B	*P*	A	B	*P*	A	B	*P*
1 d before treatment	40 ± 2.1	39 ± 3.2	0.11	3.51 ± 0.17	3.49 ± 0.14	0.78	340 ± 51	341 ± 28	0.64
1 d after treatment	39 ± 3.6	37 ± 2.5	0.06	3.27 ± 0.26	3.18 ± 0.21	0.26	327 ± 43	308 ± 19	0.15
15 d after treatment	37 ± 2.7	35 ± 3.5	0.05	3.20 ± 0.33	2.98 ± 0.25	0.45	321 ± 37	271 ± 21	0.001
30 d after treatment	38 ± 3.8	33 ± 3.2	0.001	3.28 ± 0.35	2.77 ± 0.22	0.001	325 ± 24	236 ± 17	0.001

Table 2 Nitrogen balance between the two groups at different time points (mean ± SD)

Time	Nitrogen balance (g)		
	A	B	*P*
1 d before treatment	-10 ± 3.6	-8 ± 4.1	0.17
1 d after treatment	-11 ± 2.1	-9 ± 4.5	0.81
15 d after treatment	2 ± 2.9	2 ± 3.1	0.95
30 d after treatment	6 ± 4.2	5 ± 4.8	0.51

Plasma protein measurement and liver function evaluation

Five hundred microliter serum segregated from peripheral blood was analyzed by chromatometry to measure the levels of Alb, TSF and pre-Alb. Liver function analysis was completed by Department of Laboratory, Zhongnan Hospital, Wuhan University

Examination of nitrogen balance

Twenty four-hour urine was collected to determine the level of nitrogen output as previously described[10] 1 d before operation and 1, 15 and 30 d after operation, respectively. Total nitrogen was calculated with the following formula: total nitrogen = nitrogen input-(nitrogen output + 3).

Comparison between complications, hospitalized time and expenditure

The complications, hospitalize time and expenditure were compared after recovery and discharge of the patients.

Statistical analysis

Data were analyzed with unpaired *t* test using SPSS 13.0. $P < 0.05$ was considered statistically significant.

RESULTS

Two patients were excluded from our study because they had to accept abdominal cavity drainage for severe abdominal cavity infection. As one of them could not tolerate nasojejunal feeding tube, his data were not included in our statistical analysis. The remaining 40 patients were divided into group A and group B, 20 in each group. Patients in group A received personal stage nutrition support, patients in group B underwent operation and received TPN. We found that there was no significant difference in the levels of Alb, TSF and pre- Alb between the two groups of patients before and after operation. The levels of Alb (g/L), TSF (g/L) and pre-Alb (mg/L) in patients of group B were lower than those in patients of group A (Table 1). No significant difference in nitrogen balance was found between the two groups (Table 2). Thirty days after operation, the levels of aspartate aminotransferase (AST, U/L), alanine aminotransferase (ALT, U/L) and total bilirubin (Tbill, mol/L) were much higher in group B than in group A (Table 3), indicating that personal stage nutrition support can alleviate the impairment of liver function caused by extended TPN. The complications and the mean hospital stay time of the patients in group A were less than those of the patients in group B (Table 4). The mean cost for the patients in group A was lower than that for the patients in group B.

DISSCUSSION

The traditional treatment of gastrointestinal fistula is surgical operation in combination with prolonged nutrition support. So it is very important to find the best way to support patients with enough nutrition which may achieve good results. Gastrointestinal fistula, especially upper gastrointestinal fistula and leakage are hard to recover. TPN has been widely used in treatment of gastrointestinal fistula. Priorities of the management of gastrointestinal fistulas include restoration of blood volume and correction of fluid, electrolyte and acid-base imbalance, control of infection and sepsis with appropriate antibiotics and drainage of abscesses, as well as TPN and TEN[11].

TPN has many advantages. For example, it is accepted by patients more easily, the supplement of water and electrolyte are more convenient, nutrient substances are infused through veins, *etc*[12]. TPN is a form of nutritional support most suitable to patients with gut failure[13]. On the other hand, TPN provides sufficient heat and nutrient substances to meet the need of metabolism. Glyconeogenesis can be inhibited, thus keeping a positive nitrogen balance. In our research, there was no significant difference in nitrogen balance between the two groups. All the patients were switched from negative nitrogen balance to positive nitrogen balance. At the same time many disadvantages were discovered such as metabolic disturbance, catheter septicemia alteration in liver function and cholestasis[14], especially when patients received prolonged TPN, which is consistent with our findings. The levels of AST, ALT and Tbill were much higher in group B than in group A 30 d after TPN. In the stress condition, proper nutritional support may provide necessary nutrients, reduce clinical complications

Table 3 Liver function of patients in the two groups at different time points (mean ± SD)

Time	AST (U/L)			ALT (U/L)			T bill (mol/L)		
	A	B	*P*	A	B	*P*	A	B	*P*
1 d before treatment	26 ± 2.2	27 ± 1.9	0.27	27 ± 1.9	26 ± 1.6	0.85	15 ± 1.6	14 ± 1.8	0.68
1 d after treatment	28 ± 2.4	29 ± 2.6	0.31	29 ± 2.3	30 ± 2.4	0.24	18 ± 2.1	19 ± 2.4	0.14
15 d after treatment	42 ± 3.5	44 ± 3.1	0.07	52 ± 1.8	60 ± 1.5	0.001	30 ± 1.4	32 ± 2.6	0.004
30 d after treatment	35 ± 3.3	63 ± 3.6	0.001	36 ± 2.7	65 ± 2.3	0.001	26 ± 3.7	48 ± 3.1	0.001

Table 4 Complications, hospitalized time and cost of the two groups

	A (*n* = 20)	B (*n* = 20)	*P*
Stoma fistula	0	2	
Infection of incisional wound	0	3	
Abdominal distension	2	0	
Diarrhoea	1	0	
Infection of abdominal cavity	1	1	
Total incidence rate (%)	20%(4/20)	30%(6/20)	0.53
Average stay (d)	40 ± 2.6	50 ± 3.7	0.001
Average expenditure(10 thousand yuan)	2.3 ± 0.5	3.9 ± 0.8	0.001

and promote patients' recovery from illness[12]. TPN provides significant benefits to patients[15]. In the stress stage, all of our patients were given TPN. When the stress condition of patients improved, they should be supported with EN followed by TEN. Gramlich *et al*[16] reported that EN could significantly decrease the incidence of infectious complications and may cost less, and they believe that EN should be the first choice of nutritional support. Goonetilleke[17] holds that all patients should accept EN after operation. Zaloga[18] and Marik[19] believe that the gastrointestinal tract is the preferred route for nutritional support in hospitalized patients. Patients with a functioning gastrointestinal tract should be fed enterally. Patients with upper gastrointestinal fistula and leakage have a functioning intestine and can receive EN through a spiral nasogastric feeding tube which can arrive at the upper jejunum enterokinesia. In our study, patients with upper gastrointestinal fistula could accept EN after the stress condition was over. EN has many advantages. For instance, it can relieve the burden on the liver and protect the liver against damage and infection and maintain the balance of visceral blood flow compared with TPN. Enteral nutrition after stress can maintain immunocompetence and gut barrier integrity, and promote wound healing and reduce septic complications[20]. Early enteral feeding can prevent enterogenic infection in severely burned patients[21]. However, EN also has many disadvantages leading to abdominal distension, diarrhea, nausea and vomiting, *etc*, which are consistent with the findings in our study. It was reported that TPN can substantially improve the prognosis of gastrointestinal fistula patients by increasing the rate of spontaneous closure and improving the nutritional status of patients requiring repeat operations[11]. In the stress stage, EN is not suggested because a lot of digestive fluid is secreted in the gastrointestinal tract and pancreas which may destroy gastrointestinal fistula. Therefore, TPN was used in all of our patients in the first stage. However, the length of stress stage, nutrition state and recovery speed were all different in each patient. This is why we established the "personal stage nutrition support". As soon as the stress stage was over, we could give the patients EN together with PN in the PN + EN stage. Satinsky[22] reported that all patients should be supported with PN + EN after operation. We suggest that even surgical patients could be provided with personal stage nutrition support including PN + EN. We should provide nutrition support in the three stages for patients with upper gastrointestinal fistula and leakage. Since TPN and EN have their advantages and disadvantages, we should make use of their advantages as much as we possibly can. Significant differences were found in complications, hospitalized time and cost between the two groups. When EN and PN are applied, strategies should be adopted to optimize their benefits and minimize their potential harms. This is why we used personal stage nutrition support but not operation in treatment of patients with upper gastrointestinal fistula. We believe that it is feasible to cure upper gastrointestinal fistula with personal stage nutrition support.

COMMENTS

Background

Much research work has been done on gastrointestinal fistula, especially on upper gastrointestinal fistula and leakage, but there are many discussions about how to provide nutrition for patients. Absolute diet has been accepted as a routine diet in the treatment of digestive fistula and leakage, and total parental nutrition (TPN) is widely used by many doctors. We tried to find a better treatment modality for upper gastrointestinal fistula and leakage in this study.

Research frontiers

Many randomized controlled clinical trials as well as meta-analysis and systematic reviews have been performed to compare enteral nutrition (EN) with parental nutrition (PN). However, no definite conclusion is available. Some people considered that EN with PN should be employed according to the state and development of disease.

Innovations and breakthroughs

In the present study, we, for the first time, put forward the concept of personal stage nutrition support and applied it in the treatment of upper gastrointestinal fistula and leakage in combination with operation.

Applications

We have successfully treated acute pancreatitis with "personal stage nutrition support" in the last 10 years. On this basis, we wonder if we can develop a new treatment modality with "personal stage nutrition support" for patients with upper gastrointestinal fistula. A spiral nasojejunal feeding tube has been used for provision of enteral nutrition for several years outside of China.

Peer review

The research provides a new treatment modality for upper gastrointestinal fistula and leakage with personal stage nutrition support. The new concept is interesting and informative. The paper is well organized except for correction of some errors in writing and punctuation.

REFERENCES

1 **Schroeder D**, Gillanders L, Mahr K, Hill GL. Effects of immediate postoperative enteral nutrition on body composition, muscle function, and wound healing. *JPEN J Parenter Enteral Nutr* 1991; **15**: 376-383

2 **Hadfield RJ**, Sinclair DG, Houldsworth PE, Evans TW. Effects of enteral and parenteral nutrition on gut mucosal permeability in the critically ill. *Am J Respir Crit Care Med* 1995; **152**: 1545-1548

3 **Mochizuki H**, Trocki O, Dominioni L, Brackett KA, Joffe SN, Alexander JW. Mechanism of prevention of postburn hypermetabolism and catabolism by early enteral feeding. *Ann Surg* 1984; **200**: 297-310

4 **Gianotti L**, Alexander JW, Nelson JL, Fukushima R, Pyles T, Chalk CL. Role of early enteral feeding and acute starvation on postburn bacterial translocation and host defense: prospective, randomized trials. *Crit Care Med* 1994; **22**: 265-272

5 **Carr CS**, Ling KD, Boulos P, Singer M. Randomised trial of safety and efficacy of immediate postoperative enteral feeding in patients undergoing gastrointestinal resection. *BMJ* 1996; **312**: 869-871

6 **Taylor SJ**, Fettes SB, Jewkes C, Nelson RJ. Prospective, randomized, controlled trial to determine the effect of early enhanced enteral nutrition on clinical outcome in mechanically ventilated patients suffering head injury. *Crit Care Med* 1999; **27**: 2525-2531

7 **Delmi M**, Rapin CH, Bengoa JM, Delmas PD, Vasey H, Bonjour JP. Dietary supplementation in elderly patients with fractured neck of the femur. *Lancet* 1990; **335**: 1013-1016

8 **Kudsk KA**, Croce MA, Fabian TC, Minard G, Tolley EA, Poret HA, Kuhl MR, Brown RO. Enteral versus parenteral feeding. Effects on septic morbidity after blunt and penetrating abdominal trauma. *Ann Surg* 1992; **215**: 503-511; discussion 511-513

9 **Stroud M**, Duncan H, Nightingale J. Guidelines for enteral feeding in adult hospital patients. *Gut* 2003; **52** Suppl 7: vii1-vii12

10 **Thompson M**, Owen L, Wilkinson K, Wood R, Damant A. A comparison of the Kjeldahl and Dumas methods for the determination of protein in foods, using data from a proficiency testing scheme. *Analyst* 2002; **127**: 1666-1668

11 **Dudrick SJ**, Maharaj AR, McKelvey AA. Artificial nutritional support in patients with gastrointestinal fistulas. *World J Surg* 1999; **23**: 570-576

12 **Makhdoom ZA**, Komar MJ, Still CD. Nutrition and enterocutaneous fistulas. *J Clin Gastroenterol* 2000; **31**: 195-204

13 **Jeejeebhoy KN**. Total parenteral nutrition: potion or poison? *Am J Clin Nutr* 2001; **74**: 160-163

14 **Ren JA**, Mao Y, Wang GF, Wang XB, Fan CG, Wang ZM, Li JS. Enteral refeeding syndrome after long-term total parenteral nutrition. *Chin Med J* (Engl) 2006; **119**: 1856-1860

15 **Jiang XH**, Li N, Li JS. Intestinal permeability in patients after surgical trauma and effect of enteral nutrition versus parenteral nutrition. *World J Gastroenterol* 2003; **9**: 1878-1880

16 **Gramlich L**, Kichian K, Pinilla J, Rodych NJ, Dhaliwal R, Heyland DK. Does enteral nutrition compared to parenteral nutrition result in better outcomes in critically ill adult patients? A systematic review of the literature. *Nutrition* 2004; **20**: 843-848

17 **Goonetilleke KS**, Siriwardena AK. Systematic review of peri-operative nutritional supplementation in patients undergoing pancreaticoduodenectomy. *JOP* 2006; **7**: 5-13

18 **Zaloga GP**. Parenteral nutrition in adult inpatients with functioning gastrointestinal tracts: assessment of outcomes. *Lancet* 2006; **367**: 1101-1111

19 **Marik PE**. Maximizing efficacy from parenteral nutrition in critical care: appropriate patient populations, supplemental parenteral nutrition, glucose control, parenteral glutamine, and alternative fat sources. *Curr Gastroenterol Rep* 2007; **9**: 345-353

20 **Braunschweig CL**, Levy P, Sheean PM, Wang X. Enteral compared with parenteral nutrition: a meta-analysis. *Am J Clin Nutr* 2001; **74**: 534-542

21 **Peng YZ**, Yuan ZQ, Xiao GX. Effects of early enteral feeding on the prevention of enterogenic infection in severely burned patients. *Burns* 2001; **27**: 145-149

22 **Satinsky I**, Mittak M, Foltys A, Kretek J, Dostalik J. [Comparison various types of artificial nutrition on postoperative complications after major surgery] *Rozhl Chir* 2005; **84**: 134-141

S- Editor Zhong XY **L- Editor** Wang XL **E- Editor** Lin YP

Online Submissions: wjg.wjgnet.com
wjg@wjgnet.com
doi:10.3748/wjg.14.5078

World J Gastroenterol 2008 August 28; 14(32): 5078-5083
World Journal of Gastroenterology ISSN 1007-9327
© 2008 The WJG Press. All rights reserved.

RAPID COMMUNICATION

Polymorphisms of alcohol dehydrogenase 2 and aldehyde dehydrogenase 2 and colorectal cancer risk in Chinese males

Chang-Ming Gao, Toshiro Takezaki, Jian-Zhong Wu, Xiao-Mei Zhang, Hai-Xia Cao, Jian-Hua Ding, Yan-Ting Liu, Su-Ping Li, Jia Cao, Keitaro Matsuo, Nobuyuki Hamajima, Kazuo Tajima

Chang-Ming Gao, Jian-Zhong Wu, Xiao-Mei Zhang, Hai-Xia Cao, Jian-Hua Ding, Yan-Ting Liu, Su-Ping Li, Division of Epidemiology, Jiangsu Provincial Institute of Cancer Research, 42 Baiziting, Nanjing 210009, Jiangsu Province, China
Toshiro Takezaki, Department of International Island and Community Medicine, Kagoshima University Graduate School of Medical and Dental Sciences, 8-35-1 Sakuragaoka, Kagoshima 890-8544, Japan
Jia Cao, Hygiene Toxicology Department, Third Military Medical University Preventive medicine college, 30 Gaotanyan Avenue, Shapingba District, Chongqing 400038, China
Keitaro Matsuo, Kazuo Tajima, Division of Epidemiology and Prevention, Aichi Cancer Center Research Institute, Nagoya 464-8681, Japan
Nobuyuki Hamajima, Department of Preventive Medicine Biostatistics and Medical Decision Making, Nagoya University School of Medicine, Nagoya 466-8550, Japan
Author contributions: Gao CM and Tajima K contributed equally to this work; Gao CM, Tajima K, Cao Jia, Takezaki T, Matsuo K and Hamajima N designed research; Gao CM, Ding JH and Wu JZ performed research; Wu JZ, Cao HX and Zhang XM contributed experimental analysis; Liu YT and Li SP collected Environmental data; Gao CM analyzed data; and Gao CM and Tajima K wrote the paper.
Supported by (in part) A Grant-in Aid for International Scientific Research; Special Cancer Research from the Ministry of Education, Science, Sports, Culture and Technology of Japan, No. 11137311; Major International (Regional) Joint Research Projects from the National Natural Science Foundation of China (NSFC), No. 30320140461
Correspondence to: Chang-Ming Gao, Division of Epidemiology, Jiangsu Provincial Institute of Cancer Research, 42 Baiziting, Nanjing 210009, China. gaocm888@126.com
Telephone: +86-25-83283486 Fax: +86-25-83641062
Received: May 22, 2008 Revised: August 11, 2008
Accepted: August 18, 2008
Published online: August 28, 2008

Abstract

AIM: To evaluate the relationship between drinking and polymorphisms of alcohol dehydrogenase 2 (*ADH2*) and/or aldehyde dehydrogenase 2 (*ALDH2*) for risk of colorectal cancer (CRC) in Chinese males.
METHODS: A case-control study was conducted in 190 cases and 223 population-based controls. *ADH2* Arg47His (G-A) and *ALDH2* Glu487Lys (G-A) genotypes were identified by PCR and denaturing high-performance liquid chromatography (DHPLC). Information on smoking and drinking was collected and odds ratio (OR) was estimated.
RESULTS: The *ADH2* A/A and *ALDH2* G/G genotypes showed moderately increased CRC risk. The age- and smoking-adjusted OR for *ADH2* A/A relative to G/A and G/G was 1.60 (95% CI=1.08-2.36), and the adjusted OR for *ALDH2* G/G relative to G/A and A/A was 1.79 (95% CI=1.19-2.69). Significant interactions between *ADH2*, *ALDH2* and drinking were observed. As compared to the subjects with *ADH2* G and *ALDH2* A alleles, those with *ADH2* A/A and *ALDH2* G/G genotypes had a significantly increased OR (3.05, 95% CI= 1.67-5.57). The OR for CRC among drinkers with the *ADH2* A/A genotype was increased to 3.44 (95% CI= 1.84-6.42) compared with non-drinkers with the *ADH2* G allele. The OR for CRC among drinkers with the *ALDH2* G/G genotype was also increased to 2.70 (95% CI= 1.57-4.66) compared with non-drinkers with the *ALDH2* A allele.
CONCLUSION: Polymorphisms of the *ADH2* and *ALDH2* genes are significantly associated with CRC risk. There are also significant gene-gene and gene-environment interactions between drinking and *ADH2* and *ALDH2* polymorphisms regarding CRC risk in Chinese males.

© 2008 The WJG Press. All rights reserved.

Key words: Alcohol dehydrogenase 2; Aldehyde dehydrogenase 2; Gene polymorphisms; Alcohol drinking; Colorectal cancer

Peer reviewer: Dr. Bernd Sido, Department of General and Abdominal Surgery, Hospital Barmherzige Brüder, Teaching Hospital of the University of Regensburg, Prüfeninger Strasse 86, Regensburg D-93049, Germany

Gao CM, Takezaki T, Wu JZ, Zhang XM, Cao HX, Ding JH, Liu YT, Li SP, Cao J, Matsuo K, Hamajima N, Tajima K. Polymorphisms of alcohol dehydrogenase 2 and aldehyde dehydrogenase 2 and colorectal cancer risk in Chinese males. *World J Gastroenterol* 2008; 14(32): 5078-5083 Available from: URL: http://www.wjgnet.com/1007-9327/14/5078.asp DOI: http://dx.doi.org/10.3748/wjg.14.5078

INTRODUCTION

There is epidemiological evidence that alcohol intake is associated with increased colorectal cancer risk[1]. The oxidative metabolites of ethanol, acetaldehyde, is recognized to be carcinogenic in animals and suspected to have similar effects on human beings[2]. Since acetaldehyde accumulates in the blood causing uncomfortable symptoms of facial flushing, palpitation and headache, even when a small amount of alcohol is consumed, greater alcohol consumption is often limited in sensitive individuals.

Ethanol is oxidized to acetaldehyde and then to acetate by alcohol dehydrogenase (*ADH*) and aldehyde dehydrogenase (*ALDH*) in the liver. Most of the acetaldehyde generated during alcohol metabolism *in vivo* is promptly eliminated by *ALDH2*, a low-Km mitochondrial *ALDH*[3]. The gene for the homotetrameric enzyme *ALDH2* has a polymorphism and its mutant *ALDH2* *2 allele (Glu487Lys, Lys or A allele) encodes a catalytically inactive subunit[4]. *ADH2* is also polymorphic and its mutant *ADH2*2* allele (Arg47His) encodes a superactive subunit of *ADH2*[3,4]. The *ALDH2* Glu487Lys and *ADH2* His47Arg polymorphisms thus have a strong impact on alcohol metabolism. Inactive *ALDH2* and superactive *ADH2* are considered to contribute to alcohol flushing and prevent people from developing alcoholism[5-7].

Our previous studies have shown that males with a habit of drinking are at a significantly higher risk for colorectal cancer[8,9]. In this study, we attempted to define the role of *ADH2* and *ALDH2* polymorphisms and drinking habit in the development of colorectal cancer.

MATERIALS AND METHODS

Study subjects

We recruited colorectal cancer patients from the Cancer Registries in Huian and Jintan Cities of Jiangsu Province of China, and also recruited patients who visited Jiangsu Provincial Cancer Hospital from August 2000 to September 2002. All patients were histopathologically diagnosed as having a primary colorectal cancer. Physicians at the hospital asked eligible patients to participate in our study, and doctors or nurses interviewed the subjects and collected blood samples from a peripheral vein after obtaining informed consent. Population-based controls were selected from healthy residents in eight villages or towns of Huian and Jintan Cities. Doctors of the public health centers randomly selected one or two controls for each patient, after matching for ethnicity, sex and age within 2 years using the records of residents at the local governmental office, and then asked eligible residents for their participation. Interviews and blood collection were performed as for the cancer patients. A few patients and residents refused to participate in our study, but the response rate was 97% for patients and 93% for controls, respectively. The Ethics Committee of Jiangsu Provincial Institute of Cancer Research approved this study. Associations could not be assessed in women because of sparse drinking habits.

Environmental factors

Smoking and drinking habits were covered in our questionnaire. Each subject was asked whether he had ever smoked at least one cigarette per day for six months or longer. If he answered yes, he was further asked about the age at which he started to smoke cigarettes regularly, the average number of cigarettes smoked per day, and the number of years he had smoked. If the subject had quit smoking at least one year ago, the age at which he stopped smoking was recorded. Each subject was asked whether he had ever drunk alcoholic beverages at least once a month for one year or longer. If his answer was yes, he was asked to provide the age at which he started to drink regularly, frequency and usual amount of hot wine, beer and grape wine consumed separately every time. If the subject had quit his drinking habit at least one year ago, the age at which he stopped drinking was recorded. Consumption of ethanol every month was calculated according to 25 g/100 g of hot wine, 3.5 g/100 g of beer and 12 g/100 g of grape wine. In the present study, smoking status was categorized as never and ever-smokers (including both current and former smokers) and alcohol consumption as drinkers/non-drinkers (the latter including individuals whose alcohol intake was less than 30 g/mo).

DNA extraction and genotyping

Whole blood was collected into EDTA-coated tubes and centrifuged for 15 min. The buffy coat layer was isolated. Genomic DNA was extracted from 200 μL of buffy coat using a Qiagen QIAamp DNA blood mini kit (QIAGEN Inc., Valencia, CA).

Genotyping of *ADH2* and *ALDH2* was determined by polymerase chain reaction (PCR) and denaturing high-performance liquid chromatography (DHPLC). The sequences of primers used in this study are F: 5'-GGGCTTTAGACTGAATAACCTTGG-3'and R: 5'-AGGGAAAGAGGAAACTCCTGAA-3' for *ADH2* Arg47His, and F: 5'-TGCTATGATGTGTTTGGAGCC-3' and R: 5'-GGCTCCGAGCCACCA-3' for *ALDH2* Glu487Lys. Reactions were carried out in a total volume of 25 μL containing 20 pmol of each primer, 0.25 mmol/L each dNTPs, 2.0 mmol/L $MgCl_2$, 2.5 μL 10 × buffer, 1 IU hotTag polymerase and 0.5 μL genomic DNA. PCR conditions were as follows: denaturation at 95℃ for 7 min, followed by 35 cycles at 95℃ for 30 s, at 62℃ for 30 s, at 72℃ for 30 s, and a final extension at 72℃ for 5 min. The products were denatured at 94℃ for 4 min, and their temperature was declined to 25℃ step by step according to 0.1℃/s.

Transgenomic WAVE DNA fragment analysis system (WAVE-300, Transgenomic, USA) and associated WAVEMAKER software were used for genotyping. An aliquot (5 μL) of the PCR products was directly injected into a DNASep column. The column mobile phase for sample elution consisted of a mixture of buffer A

[0.1 mol/L triethylammonium acetate (TEAA)] and buffer B (0.1 mol/L TEAA with 25% acetonitrile). Samples were eluted at a linear gradient of buffer B over a 4.5-min period at a constant flow rate of 0.9 mL/min. For each DNA region, DHPLC conditions were established by a titration analysis at 1-3℃ above and below the mean melting temperature predicted by software simulation. There were three genotypes: namely G/G, G/A, and A/A, for *ADH2* Arg47His and *ALDH2* Glu487Lys, respectively.

Statistical analysis

Associations between the *ADH2* and *ALDH2* polymorphisms and colorectal cancer risk were estimated by OR, using the unconditional logistic regression model. The procedure LOGISTIC from the statistical package SAS was employed for the calculations. The probability of Hardy-Weinberg equilibrium was assessed by the χ^2 test.

RESULTS

The numbers of 190 patients with colorectal cancer and 222 controls are listed in Table 1. The proportional distributions of age and smoking did not significantly differ in patients and controls, but the proportional distributions of alcohol drinkers (including current and former drinkers) were significantly higher in colorectal cancer patients than in controls.

The frequencies of *ALDH2* G/G, G/A and A/A genotypes were 68.95%, 28.42% and 2.63% in patients and 55.41%, 40.54% and 4.05% in controls, respectively (Table 2). The distribution of *ALDH2* genotypes was significantly different in controls and patients (χ^2=7.938, P = 0.019). The frequencies of *ADH2* A/A, A/G and G/G genotypes were 53.68%, 38.42% and 7.89% in patients and 41.89%, 49.10% and 9.01% in controls, with no significant difference (χ^2=5.786, P = 0.055). The allelic distribution of *ADH2* and *ALDH2* polymorphisms in controls was in the Hardy-Weinberg equilibrium (P > 0.05). Therefore, the controls from the general population could be considered as a representative.

The *ADH2* A/A and *ALDH2* G/G genotypes showed a moderately increased risk for colorectal cancer. The age- and smoking-adjusted OR relative to G/A and G/G was 1.60 (95% CI=1.08-2.36), and the adjusted OR for *ALDH2* G/G relative to G/A and A/A was 1.79 (95% CI= 1.19-2.69).

The ORs and 95% CIs for association of alcohol drinking with colorectal cancer risk are shown in Table 3. Compared with non-drinkers, the age-adjusted and smoking-adjusted OR for colorectal cancer among alcohol drinkers was 2.04 (95% CI=1.36-3.08). Furthermore, a significant increase trend in the risk of colorectal cancer with amount of alcohol intake was also observed (P = 0.0001).

The results of multivariant analysis of smoking, alcohol drinking, *ALDH2* and *ADH2* genotypes and risk of colorectal cancer are shown in Table 4. After adjustment of all these variables for each other, *ADH2* A/A, *ALDH2* G/G genotypes and alcohol drinking were associated with an increased risk for colorectal cancer, but smoking was not.

As compared to the subjects with *ADH2* G and *ALDH2* A alleles, those with *ADH2* A/A and *ALDH2* G/G genotypes had a significantly increased OR (3.05, 95% CI=1.67-5.57, Table 5). The OR for CRC among alcohol drinkers with *ADH2* A/A genotype was markedly increased to 3.44 (95% CI=1.84-6.42) compared to non-drinkers with *ADH2* G allele. The OR for colorectal cancer among alcohol drinkers with

Table 1 Background characteristics of male colorectal cancer patients and controls

	Controls		Patients		χ^2_{MH}	P
	No.	%	No.	%		
Age (yr)						
< 40	25	11.26	21	11.05	4.467	0.346
40-49	33	14.86	39	20.53		
50-59	76	34.23	50	26.32		
60-69	62	27.93	53	27.89		
> 70	26	11.71	27	14.21		
Total	222		190			
Smoking status						
Nonsmoker	87	39.19	67	35.26	3.794	0.150
Current smoker	122	54.95	102	53.68		
Former smoker	13	5.86	21	11.05		
Drinking status						
Nondrinker	124	55.86	73	38.42	15.952	0.001
Current drinker	91	40.99	99	52.11		
Former drinker	7	3.15	18	9.47		
Kinds of alcoholic beverage						
Hot wine	68	69.39	77	40.53	3.453	0.327
Beer	0	0	2	1.05		
Wine	3	3.06	1	0.53		
All kinds	27	27.55	37	31.62		
Alcohol consumption (g/mo)						
0-29	124	55.86	73	38.42	15.437	0.001
30-299	20	9.01	14	7.37		
300-599	17	7.66	20	10.53		
⩾ 600	61	27.46	83	43.68		

Table 2 Adjusted odds ratio (OR) and 95% confidence interval (CI) for colorectal cancer with reference to *ALDH2* and *ADH2* polymorphisms

	Controls *n* (%)	Cases *n* (%)	OR[1] (95% CI)	OR[2] (95% CI)
ALDH2 genotype				
G/G	123 (55.41)	131 (68.95)	1.00	1.00
G/A	90 (40.54)	54 (28.42)	0.56 (0.37-0.86)	0.56 (0.37-0.86)
A/A	9 (4.05)	5 (2.63)	0.52 (0.15-1.76)	0.52 (0.17-1.60)
G/A + A/A	99 (44.59)	59 (31.05)	0.56 (0.37-0.86)	0.56 (0.37-0.84)
A/A + A/G	99 (44.59)	59 (31.05)	1.00	1.00
G/G	123 (55.41)	131 (68.95)	1.79 (1.19-2.68)	1.79 (1.19-2.69)
ADH2 genotype				
A/A	93 (41.89)	102 (53.68)	1.00	1.00
A/G	109 (49.10)	73 (38.42)	0.61 (0.41-0.92)	0.62 (0.41-0.93)
G/G	20 (9.01)	15 (7.89)	0.68 (0.33-1.41)	0.68 (0.33-1.40)
A/G + G/G	129 (58.11)	88 (46.32)	0.62 (0.41-0.94)	0.63 (0.42-0.93)
G/G + G/A	129 (58.11)	88 (46.32)	1.00	1.00
A/A	93 (41.89)	102 (53.68)	1.61 (1.09-2.38)	1.60 (1.08-2.36)

[1]Crude OR, [2]OR was adjusted by age and smoking status.

Table 3 Adjusted OR and 95% CI for colorectal cancer with reference to alcohol drinking

	Controls	Cases	OR[1] (CI)	OR[2] (CI)
Alcohol drinking status				
Non-drinker	124	73	1.00	1.00
Current drinker	91	99	1.85 (1.21-2.83)	1.84 (1.20 -2.82)
Former drinker	7	18	4.37 (1.62-12.17)	4.19 (1.64-0.71)
Current and former	98	107	2.03 (1.37-3.01)	2.04 (1.36-3.08)
Alcohol consumption (g/mo)				
0-29	124	73	1.00	1.00
30-299	20	14	1.19 (0.53-2.65)	1.22 (0.58-2.58)
300-599	17	20	2.00 (0.93-4.30)	1.98 (0.96-4.09)
⩾ 600	61	83	2.31 (1.46-3.68)	2.33 (1.47-3.71)
			P for trend = 0.0001	

[1]Crude OR, [2]OR was adjusted for age and smoking status.

Table 4 Multivariant analysis of smoking, alcohol drinking, *ALDH2* and *ADH2* genotypes and risk of colorectal cancer

	OR[1]	95% CI	χ^2	*P*
ALDH2	1.62	1.06-2.47	5.0035	0.0253
ADH2	1.73	1.15-2.58	7.0548	0.0079
Smokers	0.97	0.63-1.50	0.0138	0.9063
Alcohol drinkers	1.95	1.27-2.98	9.3884	0.0022

[1]Logistic regression model included age (continuous), smoking (nonsmokers, current + former), alcohol drinking (nondrinkers, current + former drinkers), *ALDH2* (A/A+A/G, G/G) and *ADH2* genotype (G/G + G/A, A/A).

ALDH2 G/G genotype was markedly increased to 2.70 (95% CI=1.57-4.66) compared to non-drinkers with *ALDH2* A allele (Table 6).

DISCUSSION

Our previous studies showed that drinking is associated with increased colorectal cancer risk[8-10]. We also found that a polymorphism of cytochrome P450 2E1 (*CYP2E1*), an alcohol metabolizing enzyme, could influence susceptibility to colorectal cancer and *CYP2E1* C2/C2 genotype and alcohol drinking have a coordinated effect on the development of colorectal cancer[9]. In the present study, polymorphisms of the *ADH2* and *ALDH2* genes were significantly associated with the risk of colorectal cancer in Chinese males. Significant gene-gene and gene-environment interactions were also found between alcohol drinking and *ADH2* and *ALDH2* polymorphisms.

Colorectal carcinogenesis, as with other cancers, is complex and due to the coordinated effects of environmental and genetic factors. Thus, the exposure dosage to chemical carcinogens could vary with enzyme activity. In theory, when *ADH2* activity is increased or *ALDH2* activity is decreased, the blood acetaldehyde level also increases in drinkers, thus increasing the risk of developing colorectal cancer. However, inconsistent results have been reported in many studies on the relation between *ADH2* and *ALDH2* gene polymorphisms and cancer susceptibility[11-18]. Yokoyama *et al*[11] found *ALDH2* G/A genotype encoding inactive

Table 5 Interaction between *ALDH2* and *ADH2* genotypes and OR for colorectal cancer

ALDH2	*ADH2*	Controls	Cases	OR[1] (95% CI)
A/A + A/G	G/G + G/A	55	25	1.00
A/A + A/G	A/A	44	34	1.64 (0.85-3.18)
G/G	G/G + G/A	74	63	1.87 (1.05-3.35)
G/G	A/A	49	68	3.05 (1.67-5.57)

[1]OR was adjusted for age and smoking in a logistic regression model.

Table 6 Interaction between alcohol drinking and polymorphisms of the *ALDH2* and *ADH2* genes, and the odds ratio (OR) for colorectal cancer

Genotypes	Drinker	Controls	Cases	OR[1] (95% CI)
ALDH2				
A/A + A/G	No	64	32	1.00
G/G	No	60	41	1.36 (0.76-2.43)
A/A + A/G	Yes	35	27	1.39 (0.69-2.81)
G/G	Yes	63	90	2.70 (1.57-4.66)
ADH2				
G/G + G/A	No	65	34	1.00
A/A	No	59	39	1.27 (0.71-2.26)
G/G + G/A	Yes	64	54	1.65 (0.94-2.91)
A/A	Yes	34	63	3.44 (1.84-6.42)

[1]OR was adjusted for age and smoking status.

ALDH2 and *ADH2* G/G genotype encoding the low-activity form of *ADH2* can enhance the risk of esophageal cancer in Japanese alcoholics. For those individuals with both *ALDH2* G/A and *ADH2* G/G genotypes, the risk of esophageal cancer is increased in a multiplicative fashion. It was reported that after adjustment for age, daily alcohol consumption and amount of cigarette smoking, the risk of developing oropharyngolaryngeal, esophageal, stomach, colon, lung and multiple primary cancers is significantly increased in the presence of *ALDH2* A allele[12]. In a study on the association between genetic polymorphisms of tobacco- and alcohol-related metabolizing enzymes and esophageal squamous cell carcinoma susceptibility, Hori *et al*[13] showed that there is a significant difference in the distribution of *ADH2* and *ALDH2* genotypes between healthy controls and esophageal cancer patients, and that *ADH2* G/G and *ALDH2* G/A genotypes are significantly higher in esophageal cancer patients than in healthy controls. Furthermore, persons with combined genotypes of *ADH2* G/G and *ALDH2* G/A are at a high risk of developing esophageal squamous cell carcinoma. Chao *et al*[14] reported that Chinese alcoholic patients with *ADH2* G and *ALDH2* A alleles are more susceptible to esophageal cancer. However, Ohhira *et al*[15] showed that 10 patients with hepatocellular carcinoma (HCC) associated with pure alcoholic liver disease all have *ALDH2* G/G genotype. Takeshita *et al*[16] also examined associations between *ADH2* and *ALDH2* polymorphisms, alcohol drinking and HCC development in Japanese, and showed that a greater cumulative amount of alcohol consumption is significantly associated with HCC development but

not with *ADH2* and *ALDH2* genotypes, indicating that ethanol is directly involved in the development of HCC rather than acetaldehyde. The latest evaluation in 2007 by the International Agency for Research on Cancer (IARC) confirmed that alcoholic beverages are carcinogenic to human beings (Group 1), thus increasing the occurrence of cancer in many sites, such as oral cavity, pharynx, larynx esophagus, liver, colorectum and female breast[17,18].

Our previous study showed that *ADH2* and *ALDH2* polymorphisms are not significantly associated with the risk of developing liver, stomach and esophageal cancer[19-21]. However, those with *ALDH2* G allele drinking a greater amount of alcohol significantly elevates the risk of developing HCC and those with *ALDH2* G/G genotype drinking a larger amount of alcohol are at a significantly increased risk of developing gastric cancer. Matsuo *et al*[22] evaluated the relationship between genetic polymorphisms of *ADH2* His47Arg and *ALDH2* Glu487Lys and occurrence of colorectal cancer in Japan, and showed that *ADH2* Arg allele is associated with an increased risk of CRC. However, no significant association was found with the *ALDH2* polymorphism itself, a significant interaction between *ALDH2* and *ADH2* polymorphisms was observed in their study.

In the present study, *ADH2* A/A and *ALDH2* G/G genotypes moderately increased the risk of developing colorectal cancer in Chinese males. Significant gene-gene and gene-environment interactions were also observed between alcohol drinking and *ADH2* and *ALDH2* polymorphisms regarding colorectal cancer risk. However, further study is needed to confirm our results with a large sample size.

ACKNOWLEDGMENTS

The authors would like to thank the medical staff of Huaian Municipal Hospital and the staff of the Public Health Centers of Huaian and Jintan Cities for their assistance in data collection.

COMMENTS

Background

Colorectal cancer (CRC) is the fifth most common cancer in China. There is epidemiological evidence that alcohol intake is associated with an increased CRC risk. Alcohol dehydrogenase 2 (*ADH2*) and aldehyde dehydrogenase 2 (*ALDH2*) have a strong impact on alcohol metabolism. To evaluate the relationship between habitual drinking and genetic polymorphisms of *ADH2* and *ALDH2* with reference to the risk of CRC in Chinese males, we conducted a population based case-control study of CRC in Jiangsu Province of China.

Research frontiers

Susceptibility to cancer is generally thought to be the sum of complex interactions between environmental and genetic factors. Therefore, interaction between environmental and genetic factors is a hotspot of cancer epidemiology. We studied interactions between *ADH2* and/or *ALDH2* and habitual alcohol drinking in CRC development.

Innovations and breakthroughs

The present study showed that *ADH2* A/A and *ALDH2* G/G genotypes were correlated with the increased risk of CRC. Furthermore, a significant cooperative role of *ADH2* A/A and/or *ALDH2* G/G genotypes and alcohol consumption was also observed in the development of CRC.

Applications

This research showed the genetic risk factors and the role of gene environment interactions in identifying individuals at risk of CRC, which have certain theoretical and application values for studying the etiology of CRC and its prevention.

Peer review

The correlation between habitual drinking and genetic polymorphisms of *ADH2* and *ALDH2* was studied with reference to the risk of CRC in Chinese males. Furthermore, significant gene-gene and gene-environment interactions between alcohol drinking and *ADH2* and *ALDH2* polymorphisms were also found regarding the CRC risk. The experiments contained appropriate controls and data about the age, smoking status and alcohol consumption. This research also reported the genetic risk factors and the role of gene-environment interactions in identifying patients at risk of developing colorectal cancer in Chinese males.

REFERENCES

1 **Moskal A**, Norat T, Ferrari P, Riboli E. Alcohol intake and colorectal cancer risk: a dose-response meta-analysis of published cohort studies. *Int J Cancer* 2007; **120**: 664-671

2 **Matsuo K**, Hamajima N, Shinoda M, Hatooka S, Inoue M, Takezaki T, Tajima K. Gene-environment interaction between an aldehyde dehydrogenase-2 (ALDH2) polymorphism and alcohol consumption for the risk of esophageal cancer. *Carcinogenesis* 2001; **22**: 913-916

3 **Bosron WF**, Li TK. Genetic polymorphism of human liver alcohol and aldehyde dehydrogenases, and their relationship to alcohol metabolism and alcoholism. *Hepatology* 1986; **6**: 502-510

4 **Yoshida A**, Hsu LC, Yasunami M. Genetics of human alcohol-metabolizing enzymes. *Prog Nucleic Acid Res Mol Biol* 1991; **40**: 255-287

5 **Harada S**, Agarwal DP, Goedde HW, Tagaki S, Ishikawa B. Possible protective role against alcoholism for aldehyde dehydrogenase isozyme deficiency in Japan. *Lancet* 1982; **2**: 827

6 **Chen WJ**, Chen CC, Yu JM, Cheng AT. Self-reported flushing and genotypes of ALDH2, ADH2, and ADH3 among Taiwanese Han. *Alcohol Clin Exp Res* 1998; **22**: 1048-1052

7 **Thomasson HR**, Edenberg HJ, Crabb DW, Mai XL, Jerome RE, Li TK, Wang SP, Lin YT, Lu RB, Yin SJ. Alcohol and aldehyde dehydrogenase genotypes and alcoholism in Chinese men. *Am J Hum Genet* 1991; **48**: 677-681

8 **Gao CM**, Takezaki T, Wu JZ, Ding JH, Zhou JN, Liu YT, Li SP, Su P, Cao J, Hamajima N, Tajima K. Correlation of genetic polymorphisms of methylenetetrahydrofolate reductase with susceptibility of colorectal cancer. *Zhongliu Fangzhi Zazhi* 2005; **12**: 1215-1222

9 **Gao CM**, Takezaki T, Wu JZ, Chen MB, Liu YT, Ding JH, Sugimura H, Cao J, Hamajima N, Tajima K. CYP2E1 Rsa I polymorphism impacts on risk of colorectal cancer association with smoking and alcohol drinking. *World J Gastroenterol* 2007; **13**: 5725-5730

10 **Gong JP**, Zhou JN, Gao CM, Takezaki T, Wu JZ, Chen MB, Cao HX, Cao J, Hamajima N, Tajima K. Relationship of CYP2E1 Rsa I genetic polymorphism and smoking, alcohol drinking habit with risk of rectal cancer. *Nanjing Yikedaxue Xuebao* 2006; **26**: 1163-1167

11 **Yokoyama A**, Muramatsu T, Omori T, Matsushita S, Yoshimizu H, Higuchi S, Yokoyama T, Maruyama K, Ishii H. Alcohol and aldehyde dehydrogenase gene polymorphisms influence susceptibility to esophageal cancer in Japanese alcoholics. *Alcohol Clin Exp Res* 1999; **23**: 1705-1710

12 **Yokoyama A**, Muramatsu T, Ohmori T, Yokoyama T, Okuyama K, Takahashi H, Hasegawa Y, Higuchi S, Maruyama K, Shirakura K, Ishii H. Alcohol-related cancers and aldehyde dehydrogenase-2 in Japanese alcoholics.

Carcinogenesis 1998; **19**: 1383-1387
13 **Hori H**, Kawano T, Endo M, Yuasa Y. Genetic polymorphisms of tobacco- and alcohol-related metabolizing enzymes and human esophageal squamous cell carcinoma susceptibility. *J Clin Gastroenterol* 1997; **25**: 568-575
14 **Chao YC**, Wang LS, Hsieh TY, Chu CW, Chang FY, Chu HC. Chinese alcoholic patients with esophageal cancer are genetically different from alcoholics with acute pancreatitis and liver cirrhosis. *Am J Gastroenterol* 2000; **95**: 2958-2964
15 **Ohhira M**, Fujimoto Y, Matsumoto A, Ohtake T, Ono M, Kohgo Y. Hepatocellular carcinoma associated with alcoholic liver disease: a clinicopathological study and genetic polymorphism of aldehyde dehydrogenase 2. *Alcohol Clin Exp Res* 1996; **20**: 378A-382A
16 **Takeshita T**, Yang X, Inoue Y, Sato S, Morimoto K. Relationship between alcohol drinking, ADH2 and ALDH2 genotypes, and risk for hepatocellular carcinoma in Japanese. *Cancer Lett* 2000; **149**: 69-76
17 **Baan R**, Straif K, Grosse Y, Secretan B, El Ghissassi F, Bouvard V, Altieri A, Cogliano V. Carcinogenicity of alcoholic beverages. *Lancet Oncol* 2007; **8**: 292-293
18 **International Agency for Research on Cancer**. Alcoholic Beverage Consumption and Ethyl Carbamate (Urethane). *IARC Momographs* 2007; **96**: 1-5
19 **Ding BG**, Wang RH, Zhou XF, Liu YT, Su P, Zhou JN, Zang Y, Gao CM, Wu JZ, Li SP, Ding JH. Polymorphisms of Aldehyde Dehydrogenase-2 Genotypes and Alcohol Consumption for the Susceptibility of the Liver Cancer, Stomach Cancer and Esophageal Cancer. *Zhongguo Zhongliu* 2002; **11**: 450-452
20 **Ding JH**, Wu JZ, Gao CM, Li SP, Zhou JN, Cao HX, Su P, Liu YT, Zhou XF, Ding BG, Wang RH. Genetic polymorphisms of alcohol dehydrogenase-2 and alcohol drinking for the susceptibility of the primary hepatocellular carcinoma. *Zhongliu Fangzhi Zazhi* 2005; **12**: 251-254
21 **Ding JH**, Wu JZ, Gao CM, Li SP, Zhou JN, Cao HX, Su P, Zhou XF, Ding BG, Wang RH. The relationship between genetic polymorphism of aldehyde dehydrogenase-2 and alcohol drinking for the susceptibility of the primary hepatocellular carcinoma. *Zhongliu* 2004; **24**: 309-312
22 **Matsuo K**, Wakai K, Hirose K, Ito H, Saito T, Suzuki T, Kato T, Hirai T, Kanemitsu Y, Hamajima N, Tajima K. A gene-gene interaction between ALDH2 Glu487Lys and ADH2 His47Arg polymorphisms regarding the risk of colorectal cancer in Japan. *Carcinogenesis* 2006; **27**: 1018-1023

S- Editor Zhong XY **L- Editor** Wang XL **E- Editor** Lin YP

Online Submissions: wjg.wjgnet.com
wjg@wjgnet.com
doi:10.3748/wjg.14.5084

World J Gastroenterol 2008 August 28; 14(32): 5084-5089
World Journal of Gastroenterology ISSN 1007-9327
© 2008 The WJG Press. All rights reserved.

RAPID COMMUNICATION

Ivor Lewis subtotal esophagectomy with two-field lymphadenectomy for squamous cell carcinoma of the lower thoracic esophagus

Jie Wu, Ying Chai, Xing-Ming Zhou, Qi-Xun Chen, Fu-Lai Yan

Jie Wu, Xing-Ming Zhou, Qi-Xun Chen, Fu-Lai Yan, Department of Thoracicoabdominal Surgery, Zhejiang Cancer Hospital, Hangzhou 310022, Zhejiang Province, China
Ying Chai, Department of Thoracic Surgery, 2nd Affiliated Hospital, School of Medicine, Zhejiang University, Hangzhou 310009, Zhejiang Province, China
Author contributions: Wu J and Chai Y designed the research; Wu J, Zhou XM, Chen QX and Yan FL performed the research; Wu J analyzed the data and wrote the paper.
Correspondence to: Jie Wu, MD, Department of Thoracico-abdominal Surgery, Zhejiang Cancer Hospital, 38 Guangji Road, Bangshan, Hangzhou 310022, Zhejiang Province, China. wujiephd729@126.com
Telephone: +86-571-88122031 Fax: +86-571-88122508
Received: April 17, 2008 Revised: August 11, 2008
Accepted: August 18, 2008
Published online: August 28, 2008

Abstract

AIM: To evaluate the clinical outcome of Ivor Lewis subtotal esophagectomy with two-field lymphadenectomy for patients with squamous cell carcinoma of the lower thoracic esophagus.
METHODS: From January 1998 to December 2001, 73 patients with lower thoracic esophageal carcinoma underwent Ivor-Lewis subtotal esophagectomy with two-field lymphadenectomy. Clinicopathological information, postoperative complications, mortality and long term survival of all these patients were analyzed retrospectively.
RESULTS: The operative morbidity and mortality was 15.1% and the mortality was 2.7%. Lymph node metastases were found in 52 patients (71.2%). Nodal metastases to the upper, middle, lower mediastini and upper abdomen were found in 13 (17.8%), 15 (20.5%), 30 (41.1%), and 25 (34.2%) patients, respectively. Postoperative staging was as follows: stage Ⅰ in 5 patients, stage Ⅱ in 34 patients, stage Ⅲ in 32 patients, and stage Ⅳ in 2 patients, respectively. The overall 5-year survival rate was 23.3%. For N0 and N1 patients, the 5-year survival rate was 38.1% and 17.3%, respectively (χ^2 = 22.65, P < 0.01). The 5-year survival rate for patients in stages Ⅱa, Ⅱb and Ⅲ was 31.2%, 27.8% and 12.5%, respectively (χ^2 = 29.18, P < 0.01).
CONCLUSION: Ivor Lewis subtotal esophagectomy with two-field (total mediastinum) lymphadenectomy is a safe and appropriate operation for squamous cell carcinoma of the lower thoracic esophagus.

© 2008 The WJG Press. All rights reserved.

Key words: Esophageal neoplasm; Ivor Lewis approach; Two-field lymphadenectomy

Peer reviewer: Dusan M Jovanovic, Professor, Institute of Oncology, Institutski Put 4, Sremska Kamenica 21204, Serbia

Wu J, Chai Y, Zhou XM, Chen QX, Yan FL. Ivor Lewis subtotal esophagectomy with two-field lymphadenectomy for squamous cell carcinoma of the lower thoracic esophagus. *World J Gastroenterol* 2008; 14(32): 5084-5089 Available from: URL: http://www.wjgnet.com/1007-9327/14/5084.asp DOI: http://dx.doi.org/10.3748/wjg.14.5084

INTRODUCTION

Radical esophagectomy with lymphadenectomy remains the mainstay of curative therapy for esophageal carcinoma. Complete resection of esophagus and regional lymph node (R_0 resection) are essential to improve long-term survival[1-3]. For carcinomas of the lower thoracic esophagus, different tumor characteristics between the Western and Eastern countries cause various attitudes on their surgical management[4]. Depending on the attending surgeon's philosophy, surgical approaches to carcinomas of the lower thoracic esophagus vary from the conventional left thoraco-abdominal approach[5,6] to the transhiatal approach without thoracotomy[7-9], Ivor Lewis approach[10-12], and recently reported thoracoscopic approach[13-15]. On the other hand, controversy continues over the optimal extent of lymphadenectomy to be performed with esophagectomy. Some authors do not favor lymphadenectomy considering lymph node involvement as systemic disease with no hope for cure, and the primary goal of surgical intervention is palliative, with a low surgical morbidity and mortality[8]. However, some authors prefer two-field lymphadenectomy and regard it as a standard surgical procedure[10,12,16]. What is more, other authors, mainly from Japan, advocate three-field lymphadenectomy in order to obtain accurate staging,

control locoregional recurrence and improve long-term survival[17-20].

At our hospital, the main surgical approach to lower thoracic esophageal carcinoma is the Ivor Lewis approach, instead of left thoraco-abdominal approach that is widely adopted in China, because Ivor Lewis approach provides a wider extent of lymphadenectomy than left thoraco-abdominal approach, and the chance of obtaining R_0 resection is greater. The aim of this study was to retrospectively assess our results of Ivor Lewis subtotal esophagectomy with two-field lymphadenectomy for patients with squamous cell carcinoma of the lower thoracic esophagus.

MATERIALS AND METHODS

Patients

From January 1998 to December 2001, 73 patients with squamous cell carcinoma of the lower thoracic esophagus underwent Ivor Lewis subtotal esophagectomy with two-field lymph node dissection at Zhejiang Cancer Hospital, Hangzhou, China. There were 65 men and 8 women. Median age was 57 years (range, 39 to 78 years). Preoperative evaluation was performed for all patients with a barium swallow examination, endoscopy with biopsy, ultrasonography of the neck and upper abdominal compartment. Cardiac and pulmonary functions were also routinely performed for these patients to determine their ability to withstand the planned surgical procedure. Before treatment, diagnosis of all patients was established histologically. No patient received chemotherapy or radiotherapy before operation. Postoperative staging was based on the 2002 UICC-TNM classification[21].

Duration of surgery, operative blood loss, and the number of lymph nodes were recorded. Postoperative complications were also recorded. Operative mortality was defined as any death during the first 30 d after operation or during the same hospital stay.

Surgical technique

All patients underwent Ivor Lewis subtotal esophagectomy with two-field lymphadenectomy. In brief, all resections were carried out by initial abdominal exploration through an upper midline laparotomy. The stomach was mobilized on the right gastric and gastroepiploic arteries. The left gastric artery was divided at its origin, and all lymph nodes along the celiac axis and its three branches along the left aspect of the portal vein, in front of the inferior vena cava, along the diaphragmatic pillars, and in front of the left adrenal gland were *en bloc* resected. A pyloromyotomy was performed routinely for all the patients. No drainage procedure was done. After the abdominal stage, a right posterolateral thoracotomy was performed. The thoracic dissection included removal of azygous arch with its associated lymph nodes, thoracic duct, and the low paratracheal, subcarinal, paraesophageal, and parahiatal nodes in continuity with the resected esophagus. In addition, upper mediastinal, paratracheal lymphatic tissue including lymph nodes of the left and right recurrent laryngeal nerves were also removed. Denudation of the lesser curvature was usually performed in the pleural cavity. After resection of the specimen, an anastomosis was constructed between the stomach and esophagus. The anastomosis was located in the apex of the chest in all patients.

After surgery, all patients returned to the intensive care unit for 2 d on average. On day 5 after surgery, patients underwent contrast X-ray study for assessment of esophagogastric anastomosis and then received enteral feeding.

Table 1 Postoperative pathological staging in 73 patients with esophageal carcinoma

Stage	TNM	Patients, *n* (%)
Ⅰ (*n* = 5)	T1N0M0	5 (6.8)
Ⅱa (*n* = 16)	T2N0M0	7 (9.6)
	T3N0M0	9 (12.3)
Ⅱb (*n* = 19)	T1N1M0	3 (4.1)
	T2N1M0	15 (20.5)
Ⅲ (*n* = 32)	T3N1M0	29 (39.7)
	T4N1M0	3 (4.1)
Ⅳ (*n* = 2)	T3N1M1	2 (2.7)

Follow-up

Postoperative data were collected at the outpatient clinic. Follow-up data were obtained by telephone. The follow-up time ranged 0-88 mo (median 47 mo). Survival time was defined as the period from the date of surgery until death or the most recent follow-up investigation (September 2005), with none lost to follow-up.

Statistical analysis

Survival analysis was carried out with the Kaplan-Meier method, and the log-rank test was used for comparisons. Estimates and 95% confidence intervals (CI_{95}) were given for 5 years. Fisher's exact two-tailed test was used to compare categorical data. $P < 0.05$ was considered statistically significant.

RESULTS

Pathological findings

All the 73 patients acquired complete resection (R_0 resection). The postoperative stage and TNM classification are shown in Table 1. Of the 8 patients with pathological T1 tumors, 2 had muscularis mucosae tumors and 6 had submucosal tumors. Nodal involvement was found in 3 of the 6 patients with submucosal tumors. Of the 3 patients with pathological T4 tumors, 2 had liver involvement and 1 had lung involvement. Combined resections were performed for the 3 patients. Metastases were found in celiac nodes of 2 patients with M1 disease.

Operative outcomes

The operation time was 243 ± 40 min. The operative blood loss was 365 ± 230 mL. The number of lymph

Table 2 Postoperative complications in 73 patients with esophageal carcinoma *n* (%)

Complications	Patients	Patients died
Pneumonia	4 (5.5)	1 (1.4)
Vocal cord palsy	3 (4.1)	0 (0)
Arrhythmia	3 (4.1)	0 (0)
Anastomotic leakage	2 (2.7)	1 (1.4)
Postoperative bleeding	1 (1.4)	0 (0)
Wound infection	1 (1.4)	0 (0)

Table 3 Relation between depth of tumor infiltration (T) and lymph node metastasis (N)

T	N0	N1	Prevalence of nodal metastases (%)
T1 (n = 8)	5	3	37.5
T2 (n = 22)	7	15	68.2
T3 (n = 40)	9	31	77.5
T4 (n = 3)	0	3	100

P = 0.888.

nodes resected was 31 ± 11 (median, 27). Postoperative complications are listed in Table 2. Complications occurred in 11 patients (15.1%, CI_{95} 6.9%-23.3%). Of the 73 patients, 2 (2.7%, CI_{95} 0%-6.5%) died due to pneumonia and anastomotic leakage, respectively, within 30 d of the operation.

Tumor depth and lymph node metastases

Lymph node metastases were found in 52 patients and the prevalence of nodal metastasis was 71.2% (CI_{95} 60.8%-81.6%). As shown in Table 3, the prevalence of nodal metastases increased with increasing tumor depth, but the difference was not statistically significant. The prevalence of nodal metastases was 37.5% in T1 stage patients, 77.5% in T3 stage patients, which was statistically significant (χ^2 = 5.06, P = 0.025). Other differences in the two stages were not statistically significant (T1 *vs* T2, T1 *vs* T4, T2 *vs* T3, T2 *vs* T4, T3 *vs* T4).

Distribution of metastatic lymph node

The frequencies of nodal metastases in different anatomical regions are shown in Table 4, which were statistically significant (P = 0.004). The frequency in lower mediastinum (41.1%) was higher than that in upper (17.8%, χ^2 = 9.53, P = 0.007), and middle mediastini (20.5%, χ^2 = 7.23, P = 0.007). The frequency in upper abdomen (34.2%) was higher than that in upper mediastinum (17.8%) (χ^2 = 5.12, P = 0.024). Other differences in frequencies between the two regions were not statistically significant. Among the 52 patients with lymph node involvement, 13 (25.0%, CI_{95} 13.3%-36.7%) had skip nodal metastases without invasion of peritumoral nodes. Isolated lymph node involvement was observed in the upper mediastinum of 6 patients (4 with positive left recurrent laryngeal nerve nodes, 2 positive right left laryngeal nerve nodes) and in the upper abdomen of 7 patients with positive left gastric arterial nodes, respectively. These patients (17.8%, CI_{95} 9.0%-26.6%) did not undergo two-field lymphadenectomy but received incomplete resections (R_1 resection of microscopically residual tumors or R_2 resection of macroscopically residual tumors). Had upper mediastinal lymphadenectomy not been performed, six patients (8.2%, CI_{95} 1.9%-15.5%) would not have undergone upper mediastinal lymphadenectomy but received inaccurate staging.

Table 4 Distribution of lymph node metastatic locations

Metastatic location	Patients with negative lymph node (n)	Patients with positive lymph node (n)	Frequency of nodal metastases (%)
Upper mediastinum	60	13	17.8
Middle mediastinum	58	15	20.5
Lower mediastinum	43	30	41.1
Upper abdomen	48	25	34.2

P = 0.004.

Survival rate

The 5-year survival rate was 23.3% (CI_{95} 13.5%-32.9%) for all patients (Figure 1A). The 5-year survival rate was 38.1% (CI_{95} 17.4%-58.8%) and 17.3% (CI_{95} 7.0%-27.6%) for N0 and N1 patients, respectively (χ^2 = 22.65, P < 0.01, Figure 1B). The 5-year survival rate for patients in stages Ⅱa, Ⅱb, and Ⅲ was 31.2% (CI_{95} 8.9%-53.5%), 27.8% (CI_{95} 7.1%-48.5%) and 12.5% (CI_{95} 1.0%-24.0%), respectively (χ^2 = 29.18, P < 0.01, Figure 1C).

DISCUSSION

Studies demonstrated that extensive submucosal lymphatic drainage to the esophageal wall causes a unique pattern of nodal metastases[1,2,4]. It was reported that the prevalence of nodal metastases of lower thoracic esophageal carcinoma is up to 70%[1-3]. Lymphatic dissemination is an early event of esophageal carcinoma, and involved nodes are found in 30%-40% of submucosal tumors[2,3]. These data are consistent with our results (71.2% and 50%, respectively). It has been documented that the likelihood of nodal metastases of esophageal carcinoma depends on the depth of tumor invasion of the esophageal wall[2,3]. The prevalence of nodal metastases increased with the increasing tumor invasion depth in this study. The prevalence of nodal metastases had no difference between the two groups according to their T status, suggesting that it may be related to the small sample size. Unlike squamous cell carcinoma of the upper thoracic esophagus, which shows lymphatic flow is mainly in the upward direction along the esophageal wall, squamous cell carcinoma of the lower thoracic esophagus, which shows lymphatic spread is mainly in the downward direction along the esophageal wall[2,4], which is consistent with our findings. Although to some degree, the frequencies of lower mediastinal and upper abdominal metastases were higher than those of upper and middle mediastinal metastases, the frequency of upper mediastinal metastases (17.8%) was still not as low as that of middle mediastinal

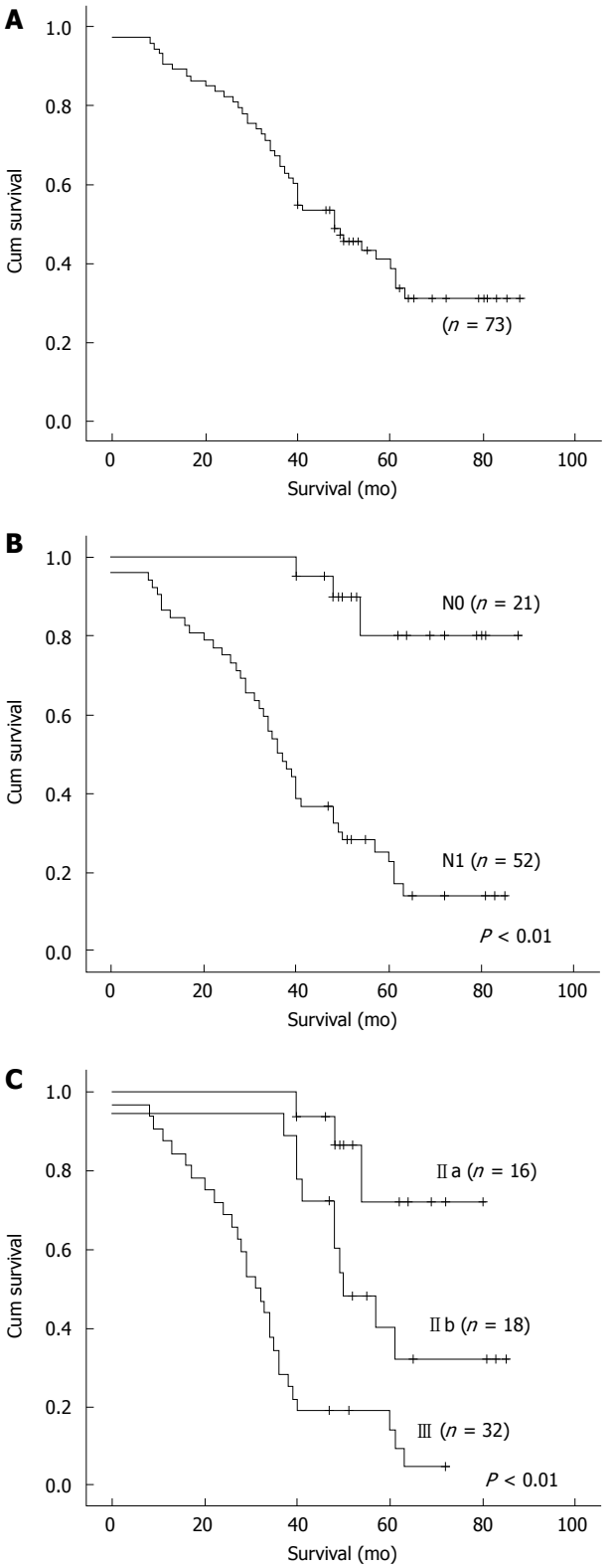

Figure 1 Survival curves for the 73 patients with squamous cell carcinoma of the lower thoracic esophagus (**A**), according to the N status (**B**), and the TNM stage (**C**).

metastases (20.5%) in the patients with lower thoracic esophageal carcinoma. An even higher frequency of upper and/or middle mediastinal metastases (30%-40%) has been reported[2,4]. In our study, skip nodal metastases were found in 25% of nodal positive patients. Of the 52 patients, 6 (11.5%) and 7 (13.5%) had positive nodes in the upper mediastinum and abdomen, respectively. Hosch *et al*[22] reported that skip metastases nodal positive patients and a frequent event in esophageal cancer. Based on these nodal metastatic features, in order to obtain R_0 resection, lymphadenectomy with upper mediastinal dissection should be performed for squamous cell carcinoma of the lower esophagus.

The greater the number of lymph nodes is removed, the greater the chance of obtaining a R_0 resection, and the more precisely the disease can be staged[1-3,11]. The extent of lymphadenectomy for a cancer in the thoracic esophagus has been classified by the Consensus Conference of the International Society for Diseases of the Esophagus (ISDE) as a standard, extended, total, or three-field lymphadenectomy[23]. The optimal lymphadenectomy for squamous cell carcinoma of the lower thoracic esophagus is still debatable. Of the 4 types of lymphadenectomy, three-field lymphadenectomy can, most likely, achieve a R_0 resection and accurate staging. The question is whether it definitely improves the long-term survival of patients. However, most data are available from nonrandomized retrospective historical studies in Japan. Igaki *et al*[4] reported that three-field lymphadenectomy could prolong the survival time of patients with squamous cell carcinoma of the lower thoracic esophagus compared to 2-field lymphadenectomy for nodal metastases present in the upper and/or middle mediastinum. Fujita *et al*[24] reported that there is no difference in survival rate for patients with lower thoracic esophageal cancer between the two procedures of lymphadenectomy. Three-field lymphadenectomy has its obvious advantages and disadvantages[16,18]. Hence, two field lymphadenectomy seems to be a more reasonable choice of treatment for squamous cell carcinoma of the lower thoracic esophagus. This viewpoint is far out weighed by the fact that the emphasis on three-field lymphadenectomy has shifted to lymphadenectomy along the recurrent laryngeal nerve chains, where lymph nodes could be dissected through two-field lymphadenectomy[16]. Among the other three types of lymphadenectomy, total (mediastinal) lymphadenectomy which was applied in this study, provides more chances to obtain a R0 resection and accurate staging than the other two types of lymphadenectomy. As our data show, if a standard lymphadenectomy was performed, positive nodes would be left intact, thus only R_1 or R_2 resection could be achieved, leading to stage migration from N0 to N1 in 6 patients (8.2%). If an extended lymphadenectomy was performed, stage migration from N0 to N1 would occur in 4 patients (5.5%), which can be explained by the fact that the extent of standard lymphadenectomy does not cover the upper and left upper mediastini. Total (mediastinal) lymphadenectomy is therefore an alternative for squamous cell carcinoma of the lower thoracic esophagus. Then, which surgical approach could satisfy the demand for total lymphadenectomy? Transhiatal approach without thoracotomy is unlikely to be chosen. In the left thoraco-abdominal approach we used previously, upper mediastinal lymph nodes are

not available. In the McKeown approach (anterolateral right thoracotomy), a radical lymphadenectomy is more difficult to achieve than the Ivor Lewis approach[5,12]. Thoracoscopic approach to esophageal carcinoma remains to be investigated and no systemic data are available to support its advantages over the minimally invasive approach to esophagectomy[25]. Ivor Lewis approach which allows complete visualization of mediastinum, especially upper mediastinum, seems to be most appropriate for squamous cell carcinoma of the lower thoracic esophagus.

Morbidity increases with the extent of lymphadenectomy but does not lead to a higher mortality[11]. Pneumonia was the most common complication in this study, which is consistent with previous reports[10-12]. Vocal cord palsy caused by lymphadenectomy around recurrent laryngeal nerves also occurs occasionally. Functional mediastinal lymphadenectomy can preserve the bronchial artery and bronchial branches of the vagus nerve, thus reducing the respiratory complications[20,26]. To prevent vocal cord palsy, electrocautery close to the recurrent laryngeal nerve and drawing the nerve with a vessel tape should be avoided during lymphadene-ctomy[19].

The overall 5-year survival rate of our patients was only 23.3%, which may be due to the small sample size in our study. On the other hand, the survival of patients was ascertained in September 2005 when 15 patients were alive at the most recent follow-up. Accordingly, this overall survival rate could not completely explain the effect of treatment since we did not make comparisons with others. However, there was a significant difference in the survival rate between the two groups of patients with different N status and different stages. This series were proved to be more homogenous with regard to the clinical variables, such as tumor site and pathological type. The surgical procedure performed in this series revealed more R_0 resection and staging information than other surgical procedures (except three-field lymphadenectomy). Compared to other surgical procedures, Ivor Lewis esophagectomy with two-field (total mediastinal) lymphadenectomy could achieve better results in patients with squamous cell carcinoma of the lower thoracic esophagus. Because of the small sample size used in this study, further studies are needed to confirm our results.

In conclusion, Ivor Lewis subtotal esophagectomy with two-field (total mediastinal) lymphadenectomy is a safe and appropriate surgical procedure for squamous cell carcinoma of the lower esophagus.

COMMENTS

Background

Radical esophagectomy with lymphadenectomy is still the mainstay of curative therapy for esophageal carcinoma. This study retrospectively analyzed the clinical outcome of Ivor Lewis subtotal esophagectomy with two-field lymphadenctomy for squamous cell carcinoma of the lower thoracic esophagus.

Research frontiers

Adenocarcinoma of the lower thoracic esophagus is a common pathological type in Western countries, while squamous cell carcinoma is the main type in Eastern countries. The attitudes to the surgical approach and the extent of the lymphadenectomy for the lower thoracic esophageal carcinoma are different in Western and Eastern countries. Western general thoracic surgeons prefer the transhiatal approach and limited extent of lymphadenectomy, whereas Eastern general thoracic surgeons prefer the transthoracic approach and 2-field or 3-field lymphadenectomy.

Innovations and breakthroughs

In China, the left thoracoabdominal approach and standard 2-field lymphadenectomy are widely performed for lower thoracic esophageal carcinoma. In our clinical practice, however, they are widely performed as upper mediastinal lymphadenectomy. Furthermore, the prevalence of upper mediastinal nodal involvement is not low. 3-field lymphadenectomy is still controversial. This type of lymphadenectomy is not routinely performed in our institution. We prefer the Ivor Lewis approach with total mediastinal 2-field lymphadenectomy in the treatment of this disease.

Applications

Ivor Lewis subtotal esophagectomy with 2-field lymphadenectomy is a safe surgical procedure for squamous cell carcinoma of the lower thoracic esophagus.

Terminology

Ivor Lewis subtotal esophagectomy is a laparotomy followed by a right thoracotomy. Two-field total mediastinal lymphadenectomy involves resection of bilateral upper mediastinum in addition to a standard lymphadenectomy.

Peer review

The paper is scientific, innovative and readable, showing the advanced level of clinical research in gastroenterology both at home and abroad.

REFERENCES

1 **Lerut T**, Coosemans W, Decker G, De Leyn P, Moons J, Nafteux P, Van Raemdonck D. Extended surgery for cancer of the esophagus and gastroesophageal junction. *J Surg Res* 2004; **117**: 58-63

2 **Akiyama H**, Tsurumaru M, Udagawa H, Kajiyama Y. Radical lymph node dissection for cancer of the thoracic esophagus. *Ann Surg* 1994; **220**: 364-372; discussion 372-373

3 **Collard JM**, Otte JB, Fiasse R, Laterre PF, De Kock M, Longueville J, Glineur D, Romagnoli R, Reynaert M, Kestens PJ. Skeletonizing en bloc esophagectomy for cancer. *Ann Surg* 2001; **234**: 25-32

4 **Igaki H**, Tachimori Y, Kato H. Improved survival for patients with upper and/or middle mediastinal lymph node metastasis of squamous cell carcinoma of the lower thoracic esophagus treated with 3-field dissection. *Ann Surg* 2004; **239**: 483-490

5 **Lerut T**, Coosemans W, Decker G, De Leyn P, Moons J, Nafteux P, Van Raemdonck D. Surgical techniques. *J Surg Oncol* 2005; **92**: 218-229

6 **Forshaw MJ**, Gossage JA, Ockrim J, Atkinson SW, Mason RC. Left thoracoabdominal esophagogastrectomy: still a valid operation for carcinoma of the distal esophagus and esophagogastric junction. *Dis Esophagus* 2006; **19**: 340-345

7 **Hulscher JB**, van Sandick JW, de Boer AG, Wijnhoven BP, Tijssen JG, Fockens P, Stalmeier PF, ten Kate FJ, van Dekken H, Obertop H, Tilanus HW, van Lanschot JJ. Extended transthoracic resection compared with limited transhiatal resection for adenocarcinoma of the esophagus. *N Engl J Med* 2002; **347**: 1662-1669

8 **Orringer MB**. Transhiatal esophagectomy without thoracotomy for carcinoma of the thoracic esophagus. *Ann Surg* 1984; **200**: 282-288

9 **Sanders G**, Borie F, Husson E, Blanc PM, Di Mauro G, Claus C, Millat B. Minimally invasive transhiatal esophagectomy: lessons learned. *Surg Endosc* 2007; **21**: 1190-1193

10 **Stilidi I**, Davydov M, Bokhyan V, Suleymanov E. Subtotal esophagectomy with extended 2-field lymph node dissection for thoracic esophageal cancer. *Eur J Cardiothorac Surg* 2003; **23**: 415-420

11 **D'Journo XB**, Doddoli C, Michelet P, Loundou A, Trousse D, Giudicelli R, Fuentes PA, Thomas PA. Transthoracic esophagectomy for adenocarcinoma of the oesophagus: standard versus extended two-field mediastinal lymphadenectomy? *Eur J Cardiothorac Surg* 2005; **27**: 697-704

12 **Visbal AL**, Allen MS, Miller DL, Deschamps C, Trastek VF, Pairolero PC. Ivor Lewis esophagogastrectomy for esophageal cancer. *Ann Thorac Surg* 2001; **71**: 1803-1808
13 **Taguchi S**, Osugi H, Higashino M, Tokuhara T, Takada N, Takemura M, Lee S, Kinoshita H. Comparison of three-field esophagectomy for esophageal cancer incorporating open or thoracoscopic thoracotomy. *Surg Endosc* 2003; **17**: 1445-1450
14 **Nguyen TN**, Hinojosa M, Fayad C, Gray J, Murrell Z, Stamos M. Laparoscopic and thoracoscopic Ivor Lewis esophagectomy with colonic interposition. *Ann Thorac Surg* 2007; **84**: 2120-2124
15 **Smithers BM**, Gotley DC, Martin I, Thomas JM. Comparison of the outcomes between open and minimally invasive esophagectomy. *Ann Surg* 2007; **245**: 232-240
16 **Law S**, Wong J. Two-field dissection is enough for esophageal cancer. *Dis Esophagus* 2001; **14**: 98-103
17 **Altorki N**. En-bloc esophagectomy--the three-field dissection. *Surg Clin North Am* 2005; **85**: 611-619, xi
18 **Fang W**, Kato H, Tachimori Y, Igaki H, Sato H, Daiko H. Analysis of pulmonary complications after three-field lymph node dissection for esophageal cancer. *Ann Thorac Surg* 2003; **76**: 903-908
19 **Tachibana M**, Kinugasa S, Yoshimura H, Shibakita M, Tonomoto Y, Dhar DK, Nagasue N. Clinical outcomes of extended esophagectomy with three-field lymph node dissection for esophageal squamous cell carcinoma. *Am J Surg* 2005; **189**: 98-109
20 **Kakegawa T**. Forty years' experience in surgical treatment for esophageal cancer. *Int J Clin Oncol* 2003; **8**: 277-288
21 **International union against cancer**. In: Sobin LH, Wittekind CH, editors. TNM Classification of Malignant Tumours. 6th ed. New York: Wiley-Liss, 2002
22 **Hosch SB**, Stoecklein NH, Pichlmeier U, Rehders A, Scheunemann P, Niendorf A, Knoefel WT, Izbicki JR. Esophageal cancer: the mode of lymphatic tumor cell spread and its prognostic significance. *J Clin Oncol* 2001; **19**: 1970-1975
23 **Bumm R**, Wong J. More or less surgery for esophageal cancer: extent of lymphadenectomy for squamous cell esophageal carcinoma: How much is necessary? *Dis Esophagus* 1994; **7**: 151-155
24 **Fujita H**, Sueyoshi S, Tanaka T, Fujii T, Toh U, Mine T, Sasahara H, Sudo T, Matono S, Yamana H, Shirouzu K. Optimal lymphadenectomy for squamous cell carcinoma in the thoracic esophagus: comparing the short- and long-term outcome among the four types of lymphadenectomy. *World J Surg* 2003; **27**: 571-579
25 **Wu PC**, Posner MC. The role of surgery in the management of oesophageal cancer. *Lancet Oncol* 2003; **4**: 481-488
26 **Pramesh CS**, Mistry RC, Sharma S, Pantvaidya GH, Raina S. Bronchial artery preservation during transthoracic esophagectomy. *J Surg Oncol* 2004; **85**: 202-203

S- Editor Li DL **L- Editor** Wang XL **E- Editor** Ma WH

Online Submissions: wjg.wjgnet.com
wjg@wjgnet.com
doi:10.3748/wjg.14.5090

World J Gastroenterol 2008 August 28; 14(32): 5090-5095
World Journal of Gastroenterology ISSN 1007-9327
© 2008 The WJG Press. All rights reserved.

RAPID COMMUNICATION

Lactobacilli inhibit interleukin-8 production induced by *Helicobacter pylori* lipopolysaccharide-activated Toll-like receptor 4

Chao Zhou, Feng-Zhen Ma, Xue-Jie Deng, Hong Yuan, Hong-Sheng Ma

Chao Zhou, Feng-Zhen Ma, Xue-Jie Deng, Hong Yuan, Hong-Sheng Ma, Department of Gastroenterology, West China Hospital of Sichuan University, Chengdu 610041, Sichuan Province, China
Author contributions: Ma HS and Zhou C designed the research; Zhou C, Ma FZ, Deng XJ and Yuan H performed the research; Ma HS and Zhou C analyzed the data and wrote the paper.
Supported by Basic Research Project of Science and Technology Office of Sichuan Province, No. 04JY029-090-1
Correspondence to: Hong-Sheng Ma, Department of Gastroenterology, West China Hospital of Sichuan University, 37 Guoxue Alley, Chengdu 610041, Sichuan Province, China. mhswch@163.com
Telephone: +86-28-85423988 Fax: +86-28-85582944
Received: May 28, 2008 Revised: August 12, 2008
Accepted: August 19, 2008
Published online: August 28, 2008

Abstract

AIM: To investigate the effect of *Lactobacillus bulgaricus* (LBG) on the Toll-like receptor 4 (TLR4) pathway and interleukin-8 (IL-8) production in SGC-7901 cells treated with *Helicobacter pylori* Sydney strain 1 lipopolysaccharide (*H pylori* SS1-LPS).

METHODS: SGC-7901 cells were treated with *H pylori* SS1-LPS in the presence or absence of pretreatment for 1 h with viable LBG or supernatant recovered from LBG culture MRS broth (LBG-$_S$). Cellular lysates were prepared for Western blot with anti-TLR4, anti-transforming growth factor β-activated kinase 1 (TAK1), anti-phospho-TAK1, anti-nuclear factor κB (NF-κB), anti-p38 mitogen-activated protein kinase (p38MAPK), and anti-phospho-p38MAPK antibodies. The amount of IL-8 in cell culture medium was measured by ELISA.

RESULTS: *H pylori* SS1-LPS up-regulated the expression of TLR4, stimulated the phosphorylation of TAK1, subsequently enhanced the activation of NF-κB and the phosphorylation of p38MAPK in a time-dependent manner, leading to augmentation of IL-8 production in SGC-7901 cells. Viable LBG or LBG-$_S$ pretreatment attenuated the expression of TLR4, inhibited the phosphorylation of TAK1 and p38MAPK, prevented the activation of NF-κB, and consequently blocked IL-8 production.

CONCLUSION: *H pylori* SS1-LPS induces IL-8 production through activating TLR4 signaling in SGC-7901 cells and viable LBG or LBG-$_S$ prevents *H pylori* SS1-LPS-mediated IL-8 production via inhibition of the TLR4 pathway.

© 2008 The WJG Press. All rights reserved.

Key words: *Lactobacillus*; *Helicobacter pylori*; Lipopolysaccharide; Toll-like receptor 4; Interleukin-8

Peer reviewer: Tomasz Brzozowski, Professor, Department of Physiology, Jagiellonian University Medical College, 16 Grzegorzecka Str, Cracow 31-531, Poland

Zhou C, Ma FZ, Deng XJ, Yuan H, Ma HS. *Lactobacilli* inhibit interleukin-8 production induced by *Helicobacter pylori* lipopolysaccharide-activated Toll-like receptor 4. *World J Gastroenterol* 2008; 14(32): 5090-5095 Available from: URL: http://www.wjgnet.com/1007-9327/14/5090.asp DOI: http://dx.doi.org/10.3748/wjg.14.5090

INTRODUCTION

Infection with the human gastric pathogen *Helicobacter pylori* (*H pylori*) can develop into chronic gastritis, peptic ulcer and gastric cancer. Some studies[1-5] demonstrated that *H pylori* can stimulate interleukin-8 (IL-8) production in gastric mucosal epithelia, which induces accumulation of neutrophilic granulocytes in mucosa. Chemotactic response initiates inflammatory damage to gastric mucosa, which plays a crucial role in the pathogenesis of *H pylori*. However, signal transduction through which *H pylori* modulates IL-8 production from gastric epithelia is not fully understood.

The product of particular significance for the virulent action of *H pylori* is its cell wall lipopolysaccharide (LPS). The effects of *H pylori* lipopolysaccharide (*H pylori*-LPS) have been manifested by the marked increase of nitric oxide and proinflammatory cytokines including IL-8 in gastric mucosa[6,7], abrogation of proliferation and induction of apoptosis in gastric epithelia[8]. Mammalian Toll-like receptors trigger the signaling pathways involved in innate immune responses to microbial challenge after recognizing pathogen-associated molecular patterns.

H pylori-LPS is the natural ligand for Toll-like receptor 4 (TLR4) in gastric epithelia. It has been proposed that *H pylori*-LPS induces IL-8 production in gastric epithelia through activating the TLR4 signaling pathway[7,9].

Probiotics are living microorganisms with no or low pathogenicity, which exert beneficial effects on the host. *Lactobacillus bulgaricus* (LBG), a bacterium used in the production of yogurt, is one of the best-studied probiotics. There is increasing evidence[10,11] that LBG has therapeutic effects on *H pylori*-related diseases, including enhanced eradication of *H pylori*, amelioration of resistance to antibiotics, down-regulated side effects of antibiotic-based therapy, decreased recurrence of *H pylori* infection, and inhibition of *H pylori*-induced apoptosis. The mechanisms underlying these effects include inhibition of *H pylori* growth and attachment to epithelial cells, inactivation of virulent factors such as urease, and decrease in production of *H pylori*-induced proinflammatory cytokines[12-16]. However, the signaling pathways which are modulated by LBG in gastric epithelia have not been well elucidated.

In this experiment, we demonstrated that viable LBG inhibited the activation of the TLR4 signaling pathway and IL-8 production induced by *H pylori*Sydney strain 1 lipopolysaccharide (*H pylori*SS1-LPS) in SGC-7901 cells. Furthermore, supernatant recovered from the LBG culture MRS broth (LBG-$_S$) also exerted these effects on SGC-7901 cells treated with *H pylori*SS1-LPS. These observations provide the novel insight into the rationale for LBG as a potential treatment for *H pylori*-related diseases.

MATERIALS AND METHODS

*H pylori*SS1 culture and *H pylori*SS1-LPS preparation

*H pylori*SS1 was kindly offered by Professor Qian Yu (School of Public Health, Sichuan University). *H pylori*SS1 was incubated in Brucella broth (bioMérieux Corporate, La Balme-Les Grottes, France) supplemented with 10% fetal calf serum (FCS; Invitrogen GIBCO, Carlsbad, California, USA), 10 mg/L vancomycin, 10 mg/L amphotericin and 2500 U/L polymycin B in a shaking incubator (100 r/min) at 37℃ in an atmosphere containing 50 mL/L O_2, 100 mL/L CO_2 and 850 mL/L N_2 for 48 h. *H pylori*SS1 was precipitated from Brucella broth by centrifuging at 10000 r/min for 10 min at 4℃ and washed twice with PBS. Then the concentration of *H pylori*SS1 in PBS was adjusted to 10^8 colony forming units (CFU)/mL with optical density determined as 1 at A_{660}. The *H pylori*SS1-containing PBS was used to prepare *H pylori*SS1-LPS with the LPS extraction kit (bioMérieux) following guidelines from its manufacturer. *H pylori*SS1-LPS concentrations were determined with the kinetic Limulus amebocyte lysate assay kit (Cambrex, Walkersville, Maryland, USA) according to the manufacturer's instructions.

LBG culture and LBG-$_S$ preparation

LBG, kindly offered by Professor Qian Yu (School of Public Health, Sichuan University), was incubated in MRS broth (bioMérieux) in a candle jar at 37℃ for 24-48 h, precipitated from MRS broth by centrifuging at 5000 r/min for 10 min and washed twice with PBS. Then the concentration of LBG in PBS was adjusted to 10^7 CFU/mL with optical density determined as 0.5 at A_{600}. LBG was precipitated from PBS by centrifuging at 5000 r/min for 10 min and resuspended with an equivalent volume of RPMI 1640 medium (Invitrogen GIBCO) for pretreatment of SGC-7901 cells.

LBG-$_S$ was generated by centrifuging at 1000 × *g* for 15 min and filtering (0.2 μm) LBG culture MRS broth, then the filtrate was concentrated using Centricon Plus-20 (5-100 kDa; Millipore, Bedford, Massachusetts, USA) by centrifugation at 4000 × *g* for 1 h following guidelines from the manufacturer. Protein concentrations were determined with the Pierce protein assay kit (Pierce, Rockford, Illinois, USA) using MRS broth as the control.

Cell culture

SGC-7901 cell line was established from human gastric adenocarcinoma cells. Though the characteristics of cell apoptosis and proliferation are different from the cell line derived from normal gastric epithelia, SGC-7901 cells have been widely used as models for investigations on *H pylori*-induced gastric epithelial inflammatory responses because their inflammatory responsibility is similar to normal gastric epithelia. Therefore, SGC-7901 cells were used in our experiment. They were grown in RPMI 1640 medium supplemented with 10% FCS, 100 U/mL penicillin and 100 μg/mL streptomycin at 37℃ in an atmosphere containing 50 mL/L CO_2. After 3-4 times of passage, SGC-7901 cells were seeded to generate 1 × 10^6 cells per 6 cm culture dish and incubated in RPMI 1640 medium containing 10% FCS, 100 U/mL penicillin and 100 μg/mL streptomycin at 37℃ in an atmosphere containing 50 mL/L CO_2 for 24 h. Then all cells were serum-starved (0.5% FCS) for 24 h before experimentation.

Treatment of cell line

SGC-7901 cells were treated with 25 endotoxin units (EU)/mL *H pylori*SS1-LPS for 0, 30, 60 min or 120 min in the absence or presence of pretreatment for 1 h with 10^7 CFU/mL viable LBG or 10^{-2} mg/mL LBG-$_S$. At the end of each time point, cells were collected for Western blot, and RPMI 1640 medium was collected for ELISA. Each experiment was in triplicate.

Preparation of cellular lysates and Western blot analysis

Nuclear and cytoplasmic extraction from SGC-7901 cells was performed using the nuclear-cytosol extraction kit (Cell Signaling Technology, Danvers, Massachusetts, USA) following guidelines from the manufacturer. Protein concentrations of all extracts were determined with the Pierce protein assay kit. Each extract was mixed with an equal amount of 2 × loading buffer and heated at 100℃ for 5 min. Thirty micrograms of protein was loaded in each lane, resolved in sodium dodecyl

sulphate-polyacrylamide gels and electrotransferred to polyvinylidene difluoride membrane (1.2 mA/cm^2, 1 h). After blocked with 5% fat-free dried milk in Tris-buffered saline containing 0.1% Tween-20 (TBST) for 1 h, the membrane was incubated overnight at 4℃ with the following primary antibodies: anti-TLR4, anti-transforming growth factor β-activated kinase 1 (TAK1), anti-phospho-TAK1 (p-TAK1), anti-nuclear factor κB (NF-κB), anti-p38 mitogen-activated protein kinase (p38MAPK), anti-phospho-p38MAPK (p-p38MAPK; all at the dilution of 1:1000, Cell Signaling Technology). Anti-β-actin and anti-lamin B1 (both at the dilution of 1:1000, Santa Cruz Biotechnology, Santa Cruz, California, USA) were used for the control of equal protein loading. After washed three times in TBST, the membrane was incubated with horseradish peroxidase-conjugated IgG (1:5000, Santa Cruz Biotechnology) as the secondary antibody at room temperature for 1 h. The photographic film was exposed to bands visualized with the Supersignal West Pico chemiluminescent substrate kit (Pierce). The integrated optical density (I*A*) of each band was quantified using Quantity One software 4.5.0 (Bio-Rad Laboratories, Hercules, California, USA). Each value for TLR4 band was normalized as the ratio of I*A* of TLR4 band to that of β-actin band. Each value for p-TAK1 band was normalized as the ratio of I*A* of p-TAK1 band to that of TAK1 band. Each value for p-p38MAPK band was normalized as the ratio of I*A* of p-p38MAPK band to that of p38MAPK band. Each value for NF-κB band was normalized as the ratio of I*A* of NF-κB band to that of lamin B1 band. Each Western blot analysis of extract samples was performed in triplicate.

Detection of IL-8 production

The concentration of IL-8 in RPMI 1640 medium was determined with a commercially available ELISA kit (R&D Systems, Minneapolis, Minnesota, USA) following guidelines from the manufacturer. Each sample was detected thrice.

Statistical analysis

The data were expressed as mean ± SD, and analyzed by SPSS13.0 software (SPSS, Chicago, Illinois, USA) for One-Way ANOVA test. $P < 0.05$ was considered statistically significant.

RESULTS

Viable LBG or LBG-$_S$ inhibited *H pylori*SS1-LPS-induced activation of TLR4 signaling pathway

Twenty-five EU/mL *H pylori*SS1-LPS up-regulated the expression of TLR4, enhanced the phosphorylation of TAK1 and p38MAPK, and induced the translocation of NF-κB into nuclei in a time-dependent manner (Figure 1A and B, Table 1). These results demonstrate that *H pylori*SS1-LPS could activate the TLR4 signaling pathway. Pretreatment for 1 h with 10^7 CFU/mL viable LBG (Figure 1A) or 10^{-2} mg/mL LBG-$_S$ (Figure 1B) significantly inhibited these effects of *H pylori*SS1-LPS on the TLR4 pathway in SGC-7901 cells to a great extent (Table 1).

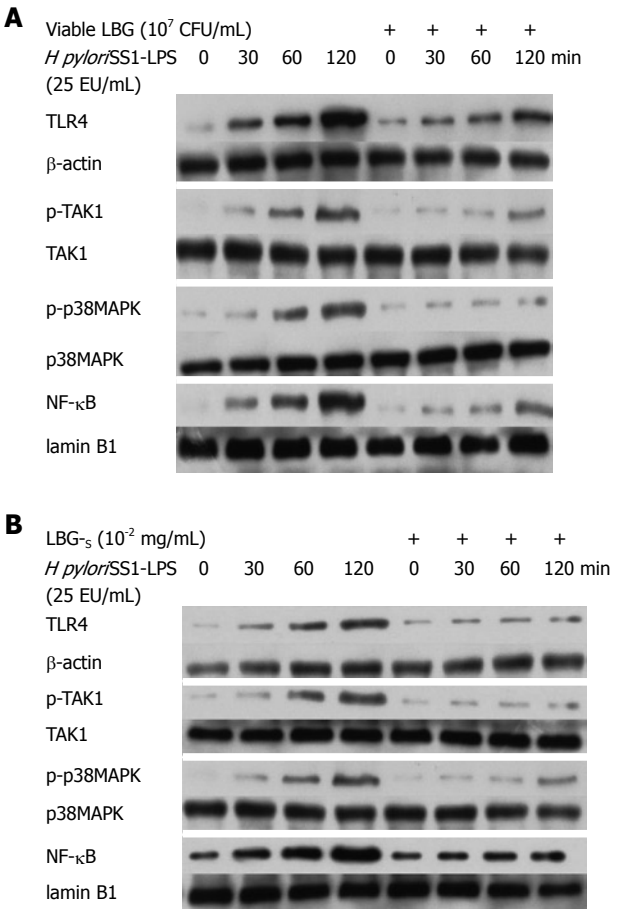

Figure 1 Expression of TLR4 and activation of TAK1, p38MAPK and NF-κB in SGC-7901 cells treated with *H pylori*SS1-LPS in the absence or presence of pretreatment with viable LBG (**A**) and LBG-$_S$ (**B**).

Viable LBG or LBG-$_S$ inhibited *H pylori*SS1-LPS-induced IL-8 production

The production of IL-8 in SGC-7901 cells treated with 25 EU/mL *H pylori*SS1-LPS for 0, 30 or 60 min in the absence or presence of pretreatment for 1 h with 10^7 CFU/mL viable LBG or 10^{-2} mg/mL LBG-$_S$ was almost undetectable (Table 2). No significant difference in these data was possibly attributed to their extremely small value. Thirty or 60 min of treatment with *H pylori*SS1-LPS might be too short for SGC-7901 cells to produce enough IL-8 for ELISA, because cytokine production usually is posterior to the process of corresponding signal transduction. If we detected IL-8 mRNA in SGC-7901 cells using the retro-transcriptional polymerase chain reaction, results at 30 min or 60 min should have been significantly higher than those at 0 min. Only 120 min of treatment with 25 EU/mL *H pylori*SS1-LPS augmented IL-8 production in SGC-7901 cells (Table 2), which was, however, down-regulated by pretreatment for 1 h with 10^7 CFU/mL viable LBG or 10^{-2} mg/mL LBG-$_S$ (Table 2).

Table 1 Effects of viable LBG, LBG-$_S$ and *H pylori*SS1-LPS on the expression of TLR4 and activation of TAK1, p38MAPK and NF-κB in SGC-7901 cells

	LPS 0 min	LPS 30 min	LPS 60 min	LPS 120 min		LBG + LPS 0 min	LBG + LPS 30 min	LBG + LPS 60 min	LBG + LPS 120 min	LBG-$_S$ + LPS 0 min	LBG-$_S$ + LPS 30 min	LBG-$_S$ + LPS 60 min	LBG-$_S$ + LPS 120 min
TLR4/β-actin	0.014 ± 0.003	0.21 ± 0.03[1]	0.43 ± 0.05[1]	1.21 ± 0.11[1]		0.016 ± 0.003	0.08 ± 0.01[2]	0.15 ± 0.02[2]	0.40 ± 0.05[2]	0.016 ± 0.003	0.088 ± 0.013[2]	0.12 ± 0.02[2]	0.18 ± 0.03[2]
[1]*t*		2.588	3.068	3.502	[2]*t*		2.328	2.425	2.302		2.182	2.733	2.901
[1]*P*		0.012	0.003	< 0.001	[2]*P*		0.031	0.021	0.033		0.041	0.01	0.007
p-TAK1/TAK1	0.008 ± 0.002	0.075 ± 0.009[1]	0.17 ± 0.03[1]	0.49 ± 0.06[1]		0.008 ± 0.001	0.025 ± 0.003[2]	0.051 ± 0.006[2]	0.15 ± 0.02[2]	0.007 ± 0.002	0.031 ± 0.005[2]	0.086 ± 0.011[2]	0.13 ± 0.02[2]
[1]*t*		2.445	2.871	3.421	[2]*t*		2.408	2.502	2.530		2.278	2.108	2.682
[1]*P*		0.018	0.005	< 0.001	[2]*P*		0.022	0.018	0.017		0.035	0.044	0.012
p-p38MAPK/ p38MAPK	0.010 ± 0.002	0.079 ± 0.011[1]	0.18 ± 0.03[1]	0.48 ± 0.08[1]		0.009 ± 0.002	0.031 ± 0.004[2]	0.058 ± 0.008[2]	0.16 ± 0.03[2]	0.013 ± 0.003	0.029 ± 0.004[2]	0.079 ± 0.012[2]	0.12 ± 0.02[2]
[1]*t*		2.401	2.819	3.403	[2]*t*		2.261	2.445	2.506		2.289	2.093	2.704
[1]*P*		0.019	0.006	< 0.001	[2]*P*		0.036	0.02	0.018		0.034	0.046	0.011
NF-κB/lamin B1	0.012 ± 0.002	0.18 ± 0.03[1]	0.32 ± 0.05[1]	1.02 ± 0.13[1]		0.012 ± 0.002	0.042 ± 0.005[2]	0.084 ± 0.009[2]	0.26 ± 0.04[2]	0.014 ± 0.002	0.091 ± 0.012[2]	0.17 ± 0.02[2]	0.23 ± 0.04[2]
[1]*t*		2.523	2.968	3.458	[2]*t*		2.796	2.690	2.711		2.088	2.068	2.787
[1]*P*		0.014	0.004	< 0.001	[2]*P*		0.009	0.012	0.011		0.046	0.048	0.009

[1]*t* and *P* value of each group *vs* corresponding LPS 0 min group; [2]*t* and *P* value of each group *vs* corresponding LPS group at the same time point.

Table 2 Inhibitory effects of viable LBG or LBG-$_S$ on *H pylori*SS1-LPS-induced IL-8 production (pg/mL)

	*H pylori*SS1-LPS		Viable LBG + LPS	LBG-$_S$ + LPS
0 min	2.62 ± 0.43		2.56 ± 0.46	2.52 ± 0.51
30 min	2.78 ± 0.38		2.67 ± 0.42	2.61 ± 0.47
60 min	3.07 ± 0.35		2.93 ± 0.51	2.89 ± 0.48
120 min	40.39 ± 3.0[1]		24.12 ± 3.05[1,2]	18.41 ± 1.83[1,2]
[1]*t*	2.832		2.601	2.506
[1]*P*	0.006		0.011	0.015
		[2]*t*	2.121	2.175
		[2]*P*	0.047	0.044

[1]*t* and *P* value of each group *vs H pylori*SS1-LPS group at 0 min; [2]*t* and *P* value of each group *vs H pylori*SS1-LPS group at 120 min.

DISCUSSION

H pylori have recently been considered an indigenous biota of human stomach and a dominant niche in gastric microecology including *Lactobacilli* and Sacharomyces with the capability of cross-species communication[17-19]. There is evidence that Helicobacter species are ancient inhabitants of human stomachs for at least 60 000 years which have co-evolved with the host and developed their excellent adaption to humans[20,21]. Though the vast majority of people in developing countries carry *H pylori*, most of them have no clinical manifestations at all[22]. More and more observations are consistent with the hypothesis that *H pylori* have both pathogenetic and symbiotic features, thus relatively balance their cost and benefit[23,24]. Changes in life style and sanitation conditions cause a probable disturbance of gastric microecology, which plays a more important role in the pathogenetic mechanism of *H pylori* in the modern era[25,26]. Therefore, eradiation of *H pylori* does not seem justified for all individuals, especially children. These findings lead to the speculation that we are supposed to domesticate *H pylori* through restoring the homeostasis of the gastric microecosystem. It was reported that administration of exogenous *Lactobacilli* has therapeutic effects on *H pylori*-associated diseases by interfering with the pathogenetic progress of *H pylori*[27-30]. Inhibition of *H pylori*-induced proinflammatory factor production by *Lactobacilli* is a very important aspect. It has been demonstrated that *Lactobacilli* abrogate *H pylori*-mediated IL-8 release *in vitro* and *in vivo*[31,32]. A large body of evidence has shown that *H pylori*-LPS-induced inflammation in gastric mucosa has nearly the same pathological characteristics as the mucosal inflammation initiated by *H pylori* infection[6,7]. Bhattacharyya *et al*[33] reported that pretreatment with LPS inhibitor greatly attenuated *H pylori* extract-mediated gastric mucosal inflammation, suggesting that *H pylori*-LPS may be a major virulent factor for *H pylori*-associated mucosal inflammation, which urged us to research the effect of *Lactobacilli* on *H pylori*-LPS-induced IL-8 production. It has been documented that *H pylori*-LPS induces mucosal inflammation including IL-8 production via TLR4 signaling. In brief, *H pylori*-LPS is recognized by TLR4 of the gastric epithelium, and then activates interleukin-1 receptor- associated kinase, tumor necrosis factor receptor-associated factor-6, TAK1 and TAK1-binding protein 1/2, p38MAPK and NF-κB at last in a cascade mechanism[7,9]. However, whether *Lactobacilli* have the capability of inhibiting *H pylori*-LPS-activated TLR4 pathway through interacting with gastric epithelia directly has not been extensively researched. Our findings demonstrate that viable LBG and LBG-$_S$ can prevent TLR4 signaling activation and IL-8 production mediated by *H pylori*SS1-LPS in SGC-7901 cells, which strongly supports the hypothesis that some soluble proteins secreted by LBG and (or) somatic constituents of LBG exert inhibitory effects on the TLR4 pathways in SGC-7901 cells treated with *H pylori*SS1-LPS. Yan *et al*[34] reported that Lactobacillus rhamnosus GG (LGG) or supernatant recovered from LGG culture MRS

broth (LGG-$_S$) ameliorated apoptosis of young adult mouse colon cells treated with tumor necrosis factor α (TNF-α), interferon-γ or interleukin-1α through blocking p38MAPK and stress-activated protein kinase/c-Jun amino-terminal kinase pathway. In addition, they have identified two proteins in LGG-$_S$ with molecular sizes of 80 and 42 kDa, which may be possible substantial effectors in LGG-$_S$[34]. In a recent study, they purified the two proteins from LGG-$_S$ again, ultimately determined their molecular weight as 75 and 40 kDa, and named them p75 and p40 respectively[35]. Their results demonstrate that both p75 and p40 can inhibit TNF-α-induced apoptosis of intestinal epithelia and promote cell growth through activating Akt[35]. LBG-$_S$ in our experiment probably contained the similar or even same proteins, which could intervene in *H pylori*SS1-LPS-activated TLR4 signaling through modulating other pathways in SGC-7901 cells. Further study is needed to evaluate the hypothesis. In the purification and characterization of the aforementioned potential soluble proteins secreted by LBG, we also detected the effect of heat-killed LBG (hk-LBG) on *H pylori*SS1-LPS-activated TLR4 signaling for evaluating the presumption that some somatic constituents of LBG may inhibit the effect of *H pylori*SS1-LPS. The incomplete data indicate that hk-LBG could also disrupt the *H pylori*SS1-LPS-activated TLR4 pathway. Nevertheless, the effect of hk-LBG was obviously smaller than that of viable LBG at the same concentration.

In conclusion, our evaluation of LBG as a model probiotic organism reveals an important and novel relationship between *H pylori*-LPS-activated TLR4 signaling and selective microflora, and further our understanding of the signal pathways in gastric epithelia involved in inflammatory responses that are regulated by probiotics and pathogenic bacteria composing the gastric microecosystem.

ACKNOWLEDGMENTS

The authors thank Professor Qian Yu (School of Public Health, Sichuan University) for her kind donation of *H pylori* Sydney strain 1 and *Lactobacillus bulgaricus* as well as Drs. Xiang Liu, Ming-Jiang Bie and Jian Wang (Laboratory of Medical Laboratory Sciences, School of Public Health, Sichuan University) for their assistance in performing the experiments.

COMMENTS

Background

Some studies have demonstrated that *Helicobacter pylori* (*H pylori*) can stimulate the release of interleukin-8 (IL-8) from gastric epithelia, which initiates inflammatory damage to gastric mucosa and plays a crucial role in the pathogenesis of *H pylori* infection. *H pylori* lipopolysaccharide (*H pylori*-LPS) is a major virulent factor for *H pylori*-associated mucosal inflammation, which induces IL-8 production via activation of the Toll-like receptor 4 (TLR4) signaling pathway in gastric epithelia. Since *H pylori* is an indigenous biota in gastric microflora including *Lactobacilli* and disturbance of the gastric microecosystem plays a more important role in pathogenetic mechanisms of *H pylori*, eradiation of *H pylori* in all individuals does not seem justifiable. The gastric microecosystem was restored after treatment with exogenous *Lactobacilli*. However, whether *Lactobacilli* inhibit *H pylori*-LPS-induced IL-8 production through blocking *H pylori*-LPS-activated TLR4 pathway needs further study.

Research frontiers

Though there is more and more evidence that *Lactobacilli* have beneficial effects on gastrointestinal diseases, the molecular mechanisms are not well understood, especially in *H pylori*-associated diseases. Whether certain soluble proteins secreted by *Lactobacillus bulgaricus* (LBG) and somatic constituents of LBG directly interact with some signaling pathways in gastric epithelia has not been clearly demonstrated. Our study indicated that Lactobacillus rhamnosus GG secreted p75 and p40, two proteins with a molecular size of 75 and 40 kDa respectively, could ameliorate apoptosis of intestinal epithelia treated with tumor necrosis factor α, interferon-γ or interleukin-1α and promote cell growth through activating Akt, blocking p38 mitogen-activated protein kinase and stress-activated protein kinase/c-Jun amino-terminal kinase signaling. The supernatant recovered from LBG culture MRS broth (LBG-$_S$) in our experiment may contain the similar or even same proteins, which could intervene in *H pylori* Sydney strain 1 lipopolysaccharide (*H pylori*SS1-LPS)-activated TLR4 signaling through modulating other pathways in SGC-7901 cells, suggesting that probiotic bacterial components may be useful in preventing *H pylori*-associated diseases.

Innovations and breakthroughs

Viable LBG or LBG-$_S$ blocked the *H pylori*SS1-LPS-activated TLR4 pathway in SGC-7901 cells, leading to their inhibitory effects on IL-8 production induced by *H pylori*SS1-LPS.

Applications

This study implied that certain soluble proteins secreted by *Lactobacilli* could directly interact with some signaling pathways in gastric epithelia and partly block the noxious effects of *H pylori*. This may benefit the exploration of new drugs for the treatment of *H pylori*-associated diseases.

Peer review

The results of this study indicate that *H pylori*SS1-LPS could increase IL-8 production through TLR4 signaling in gastric epithelia and probiotic bacteria attenuate IL-8 production via inhibition of the TLR4 pathway. The manuscript contains some interesting data, viable probiotics and their extracts against *H pylori*-LPS cytotoxicity.

REFERENCES

1 **Felley CP**, Pignatelli B, Van Melle GD, Crabtree JE, Stolte M, Diezi J, Corthesy-Theulaz I, Michetti P, Bancel B, Patricot LM, Ohshima H, Felley-Bosco E. Oxidative stress in gastric mucosa of asymptomatic humans infected with Helicobacter pylori: effect of bacterial eradication. *Helicobacter* 2002; **7**: 342-348

2 **Yoshimura N**, Suzuki Y, Saito Y. Suppression of Helicobacter pylori-induced interleukin-8 production in gastric cancer cell lines by an anti-ulcer drug, geranylgeranylacetone. *J Gastroenterol Hepatol* 2002; **17**: 1153-1160

3 **Ismail S**, Hampton MB, Keenan JI. Helicobacter pylori outer membrane vesicles modulate proliferation and interleukin-8 production by gastric epithelial cells. *Infect Immun* 2003; **71**: 5670-5675

4 **Nozawa Y**, Nishihara K, Akizawa Y, Orimoto N, Nakano M, Uji T, Ajioka H, Kanda A, Matsuura N, Kiniwa M. Lafutidine inhibits Helicobacter pylori-induced interleukin-8 production in human gastric epithelial cells. *J Gastroenterol Hepatol* 2004; **19**: 506-511

5 **Lopes AI**, Quiding-Jarbrink M, Palha A, Ruivo J, Monteiro L, Oleastro M, Santos A, Fernandes A. Cytokine expression in pediatric Helicobacter pylori infection. *Clin Diagn Lab Immunol* 2005; **12**: 994-1002

6 **Slomiany BL**, Piotrowski J, Slomiany A. Up-regulation of endothelin-converting enzyme-1 in gastric mucosal inflammatory responses to Helicobacter pylori lipopolysaccharide. *Biochem Biophys Res Commun* 2000; **267**: 801-805

7 **Ogawa T**, Asai Y, Sakai Y, Oikawa M, Fukase K, Suda Y, Kusumoto S, Tamura T. Endotoxic and immunobiological activities of a chemically synthesized lipid A of Helicobacter pylori strain 206-1. *FEMS Immunol Med Microbiol* 2003; **36**: 1-7

8 **Kawahara T**, Teshima S, Oka A, Sugiyama T, Kishi K, Rokutan K. Type I Helicobacter pylori lipopolysaccharide stimulates toll-like receptor 4 and activates mitogen oxidase 1 in gastric pit cells. *Infect Immun* 2001; **69**: 4382-4389

9 **Su B**, Ceponis PJ, Lebel S, Huynh H, Sherman PM. Helicobacter pylori activates Toll-like receptor 4 expression in gastrointestinal epithelial cells. *Infect Immun* 2003; **71**: 3496-3502

10 **Johnson-Henry KC**, Mitchell DJ, Avitzur Y, Galindo-Mata E, Jones NL, Sherman PM. Probiotics reduce bacterial colonization and gastric inflammation in H. pylori-infected mice. *Dig Dis Sci* 2004; **49**: 1095-1102

11 **Sheu BS**, Wu JJ, Lo CY, Wu HW, Chen JH, Lin YS, Lin MD. Impact of supplement with Lactobacillus- and Bifidobacterium-containing yogurt on triple therapy for Helicobacter pylori eradication. *Aliment Pharmacol Ther* 2002; **16**: 1669-1675

12 **Mukai T**, Asasaka T, Sato E, Mori K, Matsumoto M, Ohori H. Inhibition of binding of Helicobacter pylori to the glycolipid receptors by probiotic Lactobacillus reuteri. *FEMS Immunol Med Microbiol* 2002; **32**: 105-110

13 **Oh Y**, Osato MS, Han X, Bennett G, Hong WK. Folk yoghurt kills Helicobacter pylori. *J Appl Microbiol* 2002; **93**: 1083-1088

14 **Aiba Y**, Suzuki N, Kabir AM, Takagi A, Koga Y. Lactic acid-mediated suppression of Helicobacter pylori by the oral administration of Lactobacillus salivarius as a probiotic in a gnotobiotic murine model. *Am J Gastroenterol* 1998; **93**: 2097-2101

15 **Michetti P**, Dorta G, Wiesel PH, Brassart D, Verdu E, Herranz M, Felley C, Porta N, Rouvet M, Blum AL, Corthesy-Theulaz I. Effect of whey-based culture supernatant of Lactobacillus acidophilus (johnsonii) La1 on Helicobacter pylori infection in humans. *Digestion* 1999; **60**: 203-209

16 **Linsalata M**, Russo F, Berloco P, Caruso ML, Matteo GD, Cifone MG, Simone CD, Ierardi E, Di Leo A. The influence of Lactobacillus brevis on ornithine decarboxylase activity and polyamine profiles in Helicobacter pylori-infected gastric mucosa. *Helicobacter* 2004; **9**: 165-172

17 **Blaser MJ**, Parsonnet J. Parasitism by the "slow" bacterium Helicobacter pylori leads to altered gastric homeostasis and neoplasia. *J Clin Invest* 1994; **94**: 4-8

18 **Sathar MA**, Gouws E, Simjee AE, Mayat AM. Seroepidemiological study of Helicobacter pylori infection in South African children. *Trans R Soc Trop Med Hyg* 1997; **91**: 393-395

19 **Hadley C**. The infection connection. Helicobacter pylori is more than just the cause of gastric ulcers--it offers an unprecedented opportunity to study changes in human microecology and the nature of chronic disease. *EMBO Rep* 2006; **7**: 470-473

20 **Falush D**, Wirth T, Linz B, Pritchard JK, Stephens M, Kidd M, Blaser MJ, Graham DY, Vacher S, Perez-Perez GI, Yamaoka Y, Megraud F, Otto K, Reichard U, Katzowitsch E, Wang X, Achtman M, Suerbaum S. Traces of human migrations in Helicobacter pylori populations. *Science* 2003; **299**: 1582-1585

21 **Linz B**, Balloux F, Moodley Y, Manica A, Liu H, Roumagnac P, Falush D, Stamer C, Prugnolle F, van der Merwe SW, Yamaoka Y, Graham DY, Perez-Trallero E, Wadstrom T, Suerbaum S, Achtman M. An African origin for the intimate association between humans and Helicobacter pylori. *Nature* 2007; **445**: 915-918

22 **Go MF**. Review article: natural history and epidemiology of Helicobacter pylori infection. *Aliment Pharmacol Ther* 2002; **16** Suppl 1: 3-15

23 **Rajendra S**, Ackroyd R, Robertson IK, Ho JJ, Karim N, Kutty KM. Helicobacter pylori, ethnicity, and the gastroesophageal reflux disease spectrum: a study from the East. *Helicobacter* 2007; **12**: 177-183

24 **Ackermark P**, Kuipers EJ, Wolf C, Breumelhof R, Seldenrijk CA, Timmer R, Segeren KC, Kusters JG, Smout AJ. Colonization with cagA-positive Helicobacter pylori strains in intestinal metaplasia of the esophagus and the esophagogastric junction. *Am J Gastroenterol* 2003; **98**: 1719-1724

25 **Blaser MJ**. Hypothesis: the changing relationships of Helicobacter pylori and humans: implications for health and disease. *J Infect Dis* 1999; **179**: 1523-1530

26 **Tovey FI**, Hobsley M, Kaushik SP, Pandey R, Kurian G, Singh K, Sood A, Jehangir E. Duodenal gastric metaplasia and Helicobacter pylori infection in high and low duodenal ulcer-prevalent areas in India. *J Gastroenterol Hepatol* 2004; **19**: 497-505

27 **Sakamoto I**, Igarashi M, Kimura K, Takagi A, Miwa T, Koga Y. Suppressive effect of Lactobacillus gasseri OLL 2716 (LG21) on Helicobacter pylori infection in humans. *J Antimicrob Chemother* 2001; **47**: 709-710

28 **Shimizu T**, Haruna H, Hisada K, Yamashiro Y. Effects of Lactobacillus gasseri OLL 2716 (LG21) on Helicobacter pylori infection in children. *J Antimicrob Chemother* 2002; **50**: 617-618

29 **Gotteland M**, Cruchet S. Suppressive effect of frequent ingestion of Lactobacillus johnsonii La1 on Helicobacter pylori colonization in asymptomatic volunteers. *J Antimicrob Chemother* 2003; **51**: 1317-1319

30 **Armuzzi A**, Cremonini F, Bartolozzi F, Canducci F, Candelli M, Ojetti V, Cammarota G, Anti M, De Lorenzo A, Pola P, Gasbarrini G, Gasbarrini A. The effect of oral administration of Lactobacillus GG on antibiotic-associated gastrointestinal side-effects during Helicobacter pylori eradication therapy. *Aliment Pharmacol Ther* 2001; **15**: 163-169

31 **Sgouras DN**, Panayotopoulou EG, Martinez-Gonzalez B, Petraki K, Michopoulos S, Mentis A. Lactobacillus johnsonii La1 attenuates Helicobacter pylori-associated gastritis and reduces levels of proinflammatory chemokines in C57BL/6 mice. *Clin Diagn Lab Immunol* 2005; **12**: 1378-1386

32 **Bergonzelli GE**, Granato D, Pridmore RD, Marvin-Guy LF, Donnicola D, Corthesy-Theulaz IE. GroEL of Lactobacillus johnsonii La1 (NCC 533) is cell surface associated: potential role in interactions with the host and the gastric pathogen Helicobacter pylori. *Infect Immun* 2006; **74**: 425-434

33 **Bhattacharyya A**, Pathak S, Datta S, Chattopadhyay S, Basu J, Kundu M. Mitogen-activated protein kinases and nuclear factor-kappaB regulate Helicobacter pylori-mediated interleukin-8 release from macrophages. *Biochem J* 2002; **368**: 121-129

34 **Yan F**, Polk DB. Probiotic bacterium prevents cytokine-induced apoptosis in intestinal epithelial cells. *J Biol Chem* 2002; **277**: 50959-50965

35 **Yan F**, Cao H, Cover TL, Whitehead R, Washington MK, Polk DB. Soluble proteins produced by probiotic bacteria regulate intestinal epithelial cell survival and growth. *Gastroenterology* 2007; **132**: 562-575

S- Editor Zhong XY **L- Editor** Wang XL **E- Editor** Lin YP

Online Submissions: wjg.wjgnet.com
wjg@wjgnet.com
doi:10.3748/wjg.14.5096

World J Gastroenterol 2008 August 28; 14(32): 5096-5097
World Journal of Gastroenterology ISSN 1007-9327
© 2008 The WJG Press. All rights reserved.

CASE REPORT

Large solitary ovarian metastasis from colorectal cancer diagnosed by endoscopic ultrasound

Bhavani Moparty, Guillermo Gomez, Manoop S Bhutani

Bhavani Moparty, Department of Internal Medicine, University of Texas Medical Branch, Galveston, Texas 77555, United States
Guillermo Gomez, Department of Surgery, University of Texas Medical Branch, Galveston, Texas 77555, United States
Manoop S Bhutani, Department of Gastrointestinal Medicine and Nutrition, UT MD Anderson Cancer Center, Houston TX 77030-4009, United States
Author contributions: Moparty B, Gomez G and Bhutani MS designed the study; Moparty B wrote the paper; Gomez G and Bhutani MS edited and revised the paper; Bhutani MS approved the final manuscript.
Correspondence to: Manoop S Bhutani, MD, FASGE, FACG, FACP, Professor of Medicine, Department of Gastrointestinal Medicine and Nutrition, Unit 436, UT MD Anderson Cancer Center, Faculty Center Room 10.2028, 1515 Holcombe Blvd, Houston TX 77030-4009,
United States. manoop.bhutani@mdanderson.org
Telephone: +1-713-7945073 Fax: +1-713-5634398
Received: January 5, 2008 Revised: July 18, 2008
Accepted: July 25, 2008
Published online: August 28, 2008

Abstract

A case is presented of rectal carcinoma in which during staging by endoscopic ultrasound (EUS) a second large extrarectal mass was seen not otherwise visualized on computer tomography (CT) that was a solitary ovarian metastasis. The surgeon was alerted to the EUS finding prior to the planned laparoscopic colectomy. On retrospective review of the CT pelvis after surgery, the radiologist could still not diagnose the ovarian lesion separated from the primary rectal tumor due to their close proximity. However, on EUS we were able to clearly see on real-time imaging that there was a distinct peri-rectal mass apart from the primary rectal tumor.

© 2008 The WJG Press. All rights reserved.

Key words: Colorectal cancer; Endoscopic ultrasound; Ovary; Ovarian metastasis; Endoscopic ultrasound; Endosonography

Peer reviewer: Otto Schiueh-Tzang Lin, MD, C3-Gas, Gastroenterology Section, Virginia Mason Medical Center, 1100 Ninth Avenue, Seattle WA 98101, United States

Moparty B, Gomez G, Bhutani MS. Large solitary ovarian metastasis from colorectal cancer diagnosed by endoscopic ultrasound. *World J Gastroenterol* 2008; 14(32): 5096-5097 Available from: URL: http://www.wjgnet.com/1007-9327/14/5096.asp DOI: http://dx.doi.org/10.3748/wjg.14.5096

INTRODUCTION

Approximately 148 000 new cases of colorectal cancer are detected yearly in the USA[1]. Ovarian metastasis has been reported in various studies to occur in 3%-14% of patients[2-5]. Endoscopic ultrasound (EUS) has been shown to have high accuracy in staging rectal cancer[6]. The use of EUS for detecting ovarian metastasis from colorectal cancer has not been established. We describe a case of a patient with ovarian metastasis from a rectal cancer that was not detected on computer tomography (CT) scan but detected as a peri-rectal mass on preoperative EUS.

CASE REPORT

A 46-year-old female had a colonoscopy revealing an obstructing circumferential mass at 15 cm confirmed to be an invasive rectal adenocarcinoma (Figure 1). CT scan demonstrated a large rectal mass. EUS performed for staging showed a hypoechoic mass that was suspicious for a T3 lesion with penetration through the muscularis propria into the adventitia (Figure 2A). An 8 mm oval peri-tumorous lymph node was also visualized which was suspicious for malignant invasion. Inferior to the mass, EUS visualized another extra-rectal hypoechoic mass with anechoic areas. The mass measured about 5 cm and was seen in the peri-rectal area (Figure 2B). Colorectal surgery was performed and revealed a moderately differentiated rectal adenocarcinoma. Another pelvic mass was also noted (consistent with EUS findings) and found to be an ovarian metastasis (Figure 3). EUS was able to demonstrate a second mass not otherwise visualized on CT. The surgeon was alerted to the EUS finding prior to the planned laparoscopic colectomy. Based on this finding, the surrounding area was explored for a second mass and a pelvic tumor was found. On retrospective review of the CT pelvis after surgery, the radiologist could still not diagnose the ovarian lesion separated from the primary rectal tumor due to their close proximity. However, on EUS we were able to clearly see on real-time imaging that there was a distinct peri-rectal mass apart from the primary rectal tumor.

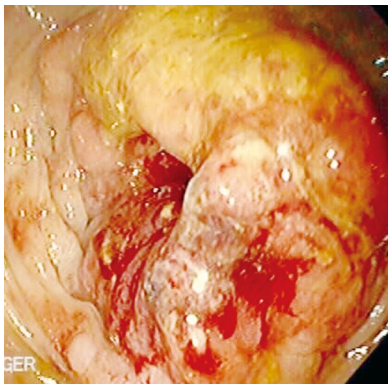

Figure 1 Colonoscopic view of an obstructing rectal cancer.

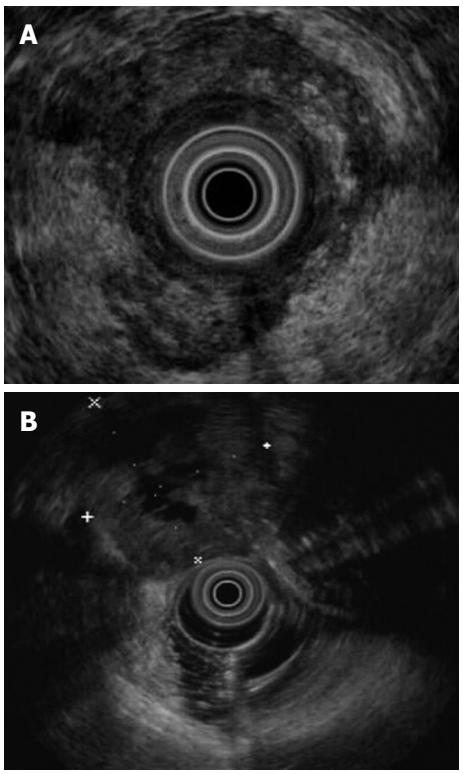

Figure 2 Radial EUS. **A**: Cancer in Figure 1 demonstrating it to be a T3 lesion; **B**: Revealing an extra-rectal hypoechoic round mass (between the calipers) measuring 5 cm in size, inferior to and clearly distinct from the primary rectal mass shown in Figures 1 and 2A.

DISCUSSION

Colorectal cancer with ovarian metastasis has been reported in multiple studies[2-5]. Patients generally present with vague symptoms[7]. Colonoscopy or barium enema can help identify an intrinsic colonic lesion. If a rectal cancer is detected, EUS is performed to stage the cancer by assessing the extent of infiltration, and the presence/absence of lymph nodes[6]. EUS also allows for visualization of adjacent organs such as bladder or prostate. CT abdomen/pelvis is generally performed to evaluate metastasis of the colorectal cancer to the liver and other organs. It may be difficult at times to assess on CT, concomitant adjacent pelvic organ metastasis due to the close proximity to the bowel or to be able to differentiate the origin of a pelvic mass, whether colorectal or perirectal.

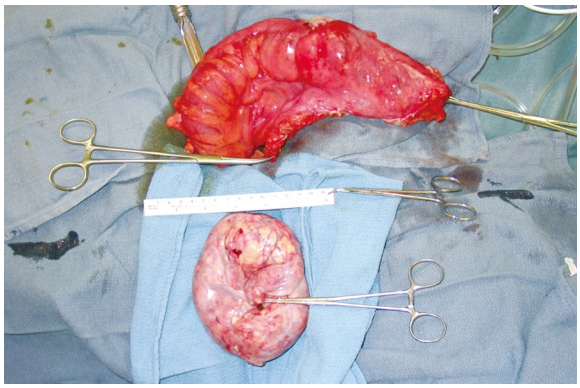

Figure 3 Gross pathologic findings at surgery showing the resected rectal carcinoma and the solitary ovarian metastases correlating with the findings in Figure 2.

Our case demonstrates the utility of EUS in detecting peri-rectal lesion, which in our patient was difficult to detect even on retrospective review of the CT. Combining information from imaging modalities such as CT and EUS may be even more important when minimally invasive surgical techniques are employed for cancer surgery to provide the surgeon with the maximal amount of preoperative information. If a solitary ovarian lesion is noted, oophorectomy is generally performed. There has been debate on whether routine bilateral oophorectomy should be performed routinely in those undergoing surgery for colorectal cancer[8]. Some recommend discussing this option with the patient prior to surgery since reports suggest that ovarian metastasis occurs in 3%-14%[2-5].

In conclusion, for patients who present with a pelvic mass, and are found to have a colorectal cancer, EUS may be performed preoperatively to detect adjacent perirectal masses such as ovarian metastatic lesions.

REFERENCES

1 **Jemal A**, Siegel R, Ward E, Murray T, Xu J, Smigal C, Thun MJ. Cancer statistics, 2006. *CA Cancer J Clin* 2006; **56**: 106-130
2 **Banerjee S**, Kapur S, Moran BJ. The role of prophylactic oophorectomy in women undergoing surgery for colorectal cancer. *Colorectal Dis* 2005; **7**: 214-217
3 **Koves I**, Vamosi-Nagy I, Besznyak I. Ovarian metastases of colorectal tumours. *Eur J Surg Oncol* 1993; **19**: 633-635
4 **Abrams HL**, Spiro R, Goldstein N. Metastases in carcinoma; analysis of 1000 autopsied cases. *Cancer* 1950; **3**: 74-85
5 **Demopoulos RI**, Touger L, Dubin N. Secondary ovarian carcinoma: a clinical and pathological evaluation. *Int J Gynecol Pathol* 1987; **6**: 166-175
6 **Harewood GC**, Wiersema MJ, Nelson H, Maccarty RL, Olson JE, Clain JE, Ahlquist DA, Jondal ML. A prospective, blinded assessment of the impact of preoperative staging on the management of rectal cancer. *Gastroenterology* 2002; **123**: 24-32
7 **Wright JD**, Powell MA, Mutch DG, Rader JS, Gibb RK, Huettner PC, Herzog TJ. Synchronous ovarian metastases at the time of laparotomy for colon cancer. *Gynecol Oncol* 2004; **92**: 851-855
8 **Young-Fadok TM**, Wolff BG, Nivatvongs S, Metzger PP, Ilstrup DM. Prophylactic oophorectomy in colorectal carcinoma: preliminary results of a randomized, prospective trial. *Dis Colon Rectum* 1998; **41**: 277-283; discussion 283-285

S- Editor Li DL **L- Editor** Wang XL **E- Editor** Ma WH

Online Submissions: wjg.wjgnet.com
wjg@wjgnet.com
doi:10.3748/wjg.14.5098

World J Gastroenterol 2008 August 28; 14(32): 5098-5099
World Journal of Gastroenterology ISSN 1007-9327
© 2008 The WJG Press. All rights reserved.

CASE REPORT

Serious drug-induced liver disease secondary to ezetimibe

José Castellote, Javier Ariza, Rosa Rota, Anna Girbau, Xavier Xiol

José Castellote, Javier Ariza, Rosa Rota, Anna Girbau, Xavier Xiol, Hepatology and Liver Transplant Unit, Idibell, Hospital Universitario de Bellvitge, Barcelona 08907, Spain
Author contributions: Castellote J and Xiol X substantially contributed to the design of the study; Ariza J, Rota R and Girbau A helped write the manuscript and made intellectual corrections.
Correspondence to: Dr. José Castellote, PhD, Hepatology and Liver Transplant Unit, Idibell, Hospital Universitario de Bellvitge, C/Feixa Llarga s/n, L'Hospitalet de Llobregat, Barcelona 08907, Spain. jcastellote@csub.scs.es
Telephone: +34-93-2607516 Fax: +34-93-2607883
Received: May 15, 2008 Revised: June 23, 2008
Accepted: June 30, 2008
Published online: August 28, 2008

Abstract

Ezetimibe is the first member of a new family of lipid-lowering drugs that inhibits uptake of dietary and biliary cholesterol. It was approved by the FDA in 2002 for hypercholesterolemia alone or in combination with statins. Its use has been spreading over the last years. Ezetimibe was considered a safe drug. We report a case of a woman who developed a serious hepatocellular drug-induced liver disease after 4 mo therapy with 10 mg daily of ezetimibe. After withdrawal of the drug, the patient recovered slowly. Ezetimibe may produce serious toxic hepatitis and prompt withdrawal is mandatory in case of a significant abnormality in liver testing after beginning or during treatment with ezetimibe.

© 2008 The WJG Press. All rights reserved.

Key words: Ezetimibe; Hepatitis; Drug-induced liver disease

Peer reviewers: Dr. Maribel Rodriguez-Torres, FundAcion De Investigacion De Diego, Ave. De Diego 359 Suite 302, Santurce 00909, Puerto Rico; Dr. Vincent Lai, Derby NHS Foundation Trust, Utooxeter Road, Derby DE22 3NE, United Kingdom

Castellote J, Ariza J, Rota R, Girbau A, Xiol X. Serious drug-induced liver disease secondary to ezetimibe. *World J Gastroenterol* 2008; 14(32): 5098-5099 Available from: URL: http://www.wjgnet.com/1007-9327/14/5098.asp DOI: http://dx.doi.org/10.3748/wjg.14.5098

INTRODUCTION

Ezetimibe is the first lipid-lowering drug that inhibits intestinal uptake of dietary and biliary cholesterol. It was approved by the FDA in 2002 for hypercholesterolemia alone or associated with statins. Since then, the use of ezetimibe has increased, especially in the United States[1]. Some guidelines suggest that ezetimibe may become the first choice for patients who do not tolerate statins[2]. Randomized clinical trials showed that ezetimibe caused significant liver function abnormalities in 1% of the treatment group. These changes were asymptomatic and entirely reversible. We report a case of serious hepatitis secondary to ezetimibe.

CASE REPORT

A 56-year-old woman was admitted because of painless jaundice and pruritus. Her past medical history revealed essential hypertension, uterine myoma and a hiatal hernia. She never consumed more than 1 alcoholic drink per day. In the last three years, her medication was unchanged and consisted of bisoprolol 10 mg/d and omeprazol 20 mg/d. Because of persistent hypercholesterolemia, her family doctor prescribed ezetimibe 10 mg/d for 4 mo before admission. She was referred to our unit because of apparition of jaundice, a progressive scretching and liver test abnormalities.

At physical exam, there was intense jaundice and some scraping lesions. Her liver was not palpable and there were no further abnormalities. Laboratory investigation showed the following results: aspartate transaminase, 16.64 kat/L (normal, < 0.5 μkat/L); alanine transaminase, 26.26 μkat/L (normal, < 0.56 μkat/L); γ-glutamyl transferase, 1.15 μkat/L (normal, < 0.43 μkat/L); alkaline phosphatase, 1.9 μkat/L (normal, < 1.5 μkat/L); total bilirubin, 602 μmol/L (normal, < 18 μmol/L). Blood count, prothrombin time and kidney function test were normal. Viral serology tests were negative (hepatitis A, B, C, Epstein-Barr virus, Herpes virus, HIV and cytomegalovirus). Autoimmune serology (antinuclear, antimitochondrial, anti-liver-kidney microsomal and anti-smooth muscle) was all negative. At ultrasonography, the liver showed no abnormality and biliary obstruction was disclosed.

Ezetimibe was stopped. Jaundice and pruritus improved slowly as well as laboratory results. Four weeks later a laboratory exam was completely normal.

DISCUSSION

The temporal association, the improvement after

cessation of the drug and the exclusion of alternative possible causes permit us to diagnose ezetimibe-induced hepatotoxicity with confidence. Although rechallenge with the same drug could give us a definitive diagnosis, the clinical severity of the hepatitis made us exclude this possibility. Liver biopsy can suggest hepatotoxicity or exclude alternative diagnoses but it was not performed in this case.

Ezetimibe does not affect the cytochrome P450 system; it undergoes extensive glucuronidation in the wall of the small intestine and liver to form the active metabolite ezetimibe glucuronide. Ezetimibe does not induce or inhibit enzyme systems in the liver but undergoes enterohepatic circulation and is exposed to the liver and bile.

Statins rarely cause clinically significant liver injury, although asymptomatic elevations in aminotransferases are common. It has been suggested that this laboratory abnormality may result from muscle damage and not by hepatic injury[3]. Ezetimibe does not interfere with plasma levels of HMG-coA reductase inhibitors such as atorvastatin and simvastatin. Association of ezetimibe and statins does not lead to an apparent increase of hepatic side effects. Ezetimibe was expected to be even less hepatotoxic than statins and has been considered a safe drug. Nevertheless, it should be kept in mind that in a newly marketed drug, finding hepatotoxicity with an incidence of 1:10 000 (the approximate incidence of most idiosyncratic reactions) would require 30 000 patients treated with this drug[4].

The pattern of drug-related liver injury can be classified in hepatocellular, cholestatic or mixed according to laboratory data[5]. Until now, four cases of significant drug-induced liver injury associated with ezetimibe have been reported[6-8], three of them associated with atorvastatin. One case was a cholestatic type, another one was hepatocellular and the last two were drug-induced acute autoimmune hepatitis. Our patient presented as serious hepatocellular hepatitis[9]. Patients with acute toxic hepatocellular damage are at high risk of acute liver failure. Mortality, or its surrogate marker, liver transplantation, is superior to 10%; this is known as "Hy's rule".

Although causes of ezetimibe toxicity are unclear, apart from an idiosyncratic drug reaction, it could be hypothesized that a conjugation defect leads to accumulation of toxic levels of ezetimibe or their metabolites. As hepatotoxicity by ezetimibe has been reported in different types according to laboratory data, several mechanisms may be implied.

The current recommendation to monitor liver function after beginning therapy with statins is controversial with some experts calling for its re-examination. Ezetimibe, alone or associated to statins, may produce serious toxic hepatitis. Caution should be taken and the necessity of analytical follow-up after beginning or during the treatment with ezetimibe is unknown. A prompt withdrawal of the drug is mandatory in case of a significant abnormality in liver tests.

REFERENCES

1 **Jackevicius CA**, Tu JV, Ross JS, Ko DT, Krumholz HM. Use of ezetimibe in the United States and Canada. *N Engl J Med* 2008; **358**: 1819-1828

2 **Civeira F**. Guidelines for the diagnosis and management of heterozygous familial hypercholesterolemia. *Atherosclerosis* 2004; **173**: 55-68

3 **Bhardwaj SS**, Chalasani N. Lipid-lowering agents that cause drug-induced hepatotoxicity. *Clin Liver Dis* 2007; **11**: 597-613, vii

4 **Andrade RJ**, Robles M, Fernandez-Castaner A, Lopez-Ortega S, Lopez-Vega MC, Lucena MI. Assessment of drug-induced hepatotoxicity in clinical practice: a challenge for gastroenterologists. *World J Gastroenterol* 2007; **13**: 329-340

5 **Maddrey WC**. Drug-induced hepatotoxicity: 2005. *J Clin Gastroenterol* 2005; **39**: S83-S89

6 **van Heyningen C**. Drug-induced acute autoimmune hepatitis during combination therapy with atorvastatin and ezetimibe. *Ann Clin Biochem* 2005; **42**: 402-404

7 **Stolk MF**, Becx MC, Kuypers KC, Seldenrijk CA. Severe hepatic side effects of ezetimibe. *Clin Gastroenterol Hepatol* 2006; **4**: 908-911

8 **Liu Q**, Tobias H, Petrovic LM. Drug-induced liver injury associated with ezetimibe therapy. *Dig Dis Sci* 2007; **52**: 602-605

9 **Sabate M**, Ibanez L, Perez E, Vidal X, Buti M, Xiol X, Mas A, Guarner C, Forne M, Sola R, Castellote J, Rigau J, Laporte JR. Risk of acute liver injury associated with the use of drugs: a multicentre population survey. *Aliment Pharmacol Ther* 2007; **25**: 1401-1409

S- Editor Zhong XY **L- Editor** Ma JY **E- Editor** Ma WH

Online Submissions: wjg.wjgnet.com
wjg@wjgnet.com
www.wjgnet.com

World J Gastroenterol 2008 August 28; 14(32): 5100
World Journal of Gastroenterology ISSN 1007-9327
© 2008 The WJG Press. All rights reserved.

ACKNOWLEDGMENTS

Acknowledgments to Reviewers of *World Journal of Gastroenterology*

Many reviewers have contributed their expertise and time to the peer review, a critical process to ensure the quality of *World Journal of Gastroenterology*. The editors and authors of the articles submitted to the journal are grateful to the following reviewers for evaluating the articles (including those published in this issue and those rejected for this issue) during the last editing time period.

Dr. Philip Abraham, Professor
Consultant Gastroenterologist & Hepatologist, P. D. Hinduja National Hospital & Medical Research Centre, Veer Savarkar Marg, Mahim, Mumbai 400 016, India

Ronan A Cahill
Department of General Surgery, Waterford Regional Hospital, Waterford, Cork, Ireland

Xiao-Ping Chen, Professor
Institute of Hepato-Pancreato-Biliary Surgery, Tongji Hospital, 1095# Jie-fang Da-dao, Wuhan 430030, China

Chi-Hin Cho, Chair and Professor
Department of Pharmacology, The University of Hong Kong, 21 Sassoon Road, Hong Kong, China

Christoph F Dietrich, MD
Innere Medizin 2, Caritas-Krankenhaus, Uhlandstr. 7, Bad Mergentheim 97980, Germany

Alessandro Fichera, MD, FACS, FASCRS, Assistant Professor
Department of Surgery-University of Chicago, 5841 S. Maryland Ave, MC 5031, Chicago, IL 60637, United States

Zvi Fireman, MD, Associate Professor of Medicine, Head
Gastroenterology Department, Hillel Yaffe Med Ctr , POB 169, 38100, Hadera, Israel

Yoshihide Fujiyama, Professor
Internal Medicine, Division of Gastroenterol, Shiga University of Medical Science, Tsukinowa, Seta, Otsu 520-2192, Japan

James Henry Grendell, Professor of Medicine, Chief
Division of Gastroenterology, Hepatology & Nutrition, Winthrop University Hospital, 222 Station Plaza N. #429, Mineola, New York 11501, United States

Kazuhiro Hanazaki, MD, Professor and Chairman
Department of Surgery, Kochi Medical School, Kochi University, Kohasu, Okohcho, Nankoku, Kochi 783-8505, Japan

Keiji Hirata, MD
Surgery 1, University of Occupational and Environmental Health, 1-1 Iseigaoka, Yahatanishi-ku, Kitakyushu 807-8555, Japan

Toru Hiyama, MD, PhD
Health Service Center, Hiroshima University, 1-7-1 Kagamiyama, Higashihiroshima 739-8521, Japan

Yik-Hong Ho, Professor
Department of Surgery, School of Medicine, James Cook University, Townsville 4811, Australia

Wayne HC Hu, MD
Department of Medicine, University of Hong Kong, 302, New Clinical Building, Queen Mary Hospital, Pokfulam Road, Hong Kong, China

Kenichi Ikejima, MD, PhD
Department of Gastroenterology, Juntendo University School of Medicine, 2-1-1, Hongo, Bunkyo-ku, 113-8421, Japan

Roger Jones, Professor
Department of General Practice and Primary Care, King's College London, 5 Lambeth Walk, London SE11 6SP, United Kingdom

Leonidas G Koniaris, Professor
Alan Livingstone Chair in Surgical Oncology, 3550 Sylvester Comprehensive Cancer Center (310T), 1475 NW 12th Ave., Miami, FL 33136, United States

Shiu-Ming Kuo, MD
University at Buffalo, 15 Farber Hall, 3435 Main Street, Buffalo 14214, United States

Kenji Miki, MD
Department of Surgery, Showa General Hospital, 2-450 Tenjin-cho, Kodaira, Tokyo 187-8510, Japan

Atsushi Nakajima, Professor
Division of Gastroenterology, Yokohama City University Graduate School of Medicine, 3-9 Fuku-ura, Kanazawa-ku, Yokohama 236-0004, Japan

Robert D Odze, MD, FRCPc, Chief
Gastrointestinal Pathology Service, Associate Professor of Pathology, Brigham and Women's Hospital, Harvard Medical School, Boston MA, United States

Ian C Roberts-Thomson, Professor
Department of Gastroenterology and Hepatology, The Queen Elizabeth Hospital, 28 Woodville Road, Woodville South 5011, Australia

Damian Casadesus Rodriguez, MD, PhD
Calixto Garcia University Hospital, J and University, Vedado, Havana City, Cuba

James M Scheiman, Professor
Division of Gastroenterology, University of Michigan Medical Center, 3912 Taubman Center, Box 0362, Ann Arbor, Michigan 48109-0362, United States

Sun-Lung Tsai, MD, PhD, Professor, Director
Hepatogastroenterology Section, Department of Internal Medicine and Liver Research Unit, Department of Medical Research, Chi Mei Medical Center, 901 Chung Hwa Road, Young-Kang City, Tainan County 710, Taiwan, China

Shingo Tsuji, Professor
Department of Internal Medicine and Therapeutics, Osaka University Graduate School of Medicine(A8), 2-2 Yamadaoka, Suita, Osaka 565-0871, Japan

Eddie Wisse, Professor
Irisweg 16, Keerbergen 3140, Belgium

George Y Wu, Professor
Department of Medicine, Division of Gastroenterology-Hepatology, University of Connecticut Health Center, 263 Farmington Ave, Farmington, CT 06030, United States

Takayuki Yamamoto, MD
Inflammatory Bowel Disease Center, Yokkaichi Social Insurance Hospital, 10-8 Hazuyamacho, Yokkaichi 510-0016, Japan

Yuan Yuan, Professor
Cancer Institute of China Medical University, 155 North Nanjing Street, Heping District, Shenyang 110001, Liaoning Province, China

Bo-Jian Zheng, MD, PhD
Department of Microbiology, the University of Hong Kong, University Pathology Building, Queen Mary Hospital, Pokfulam Road, Hong Kong, China

Shu Zheng, Professor, Scientific Director of Cancer Institute
Zhejiang University, Secondary Affiliated Hospital, Zhejiang University, 88# Jiefang Road, Hangzhou 310009, Zhejiang Province, China

Online Submissions: wjg.wjgnet.com
wjg@wjgnet.com
www.wjgnet.com

World J Gastroenterol 2008 August 28; 14(32): 5101
World Journal of Gastroenterology ISSN 1007-9327
© 2008 The WJG Press. All rights reserved.

Meetings

Events Calendar 2008-2009

FALK SYMPOSIA 2008
January 24-25, Frankfurt, Germany
Falk Workshop: Perspectives in Liver
Transplantation

International Gastroenterological Congresses 2008
February 14-16, Paris, France
EASL-AASLD-APASL-ALEH-IASL Conference Hepatitis B and C virus resistance to antiviral therapies
www.easl.ch/hepatitis-conference

February 14-17, Berlin, Germany
8th International Conference on New Trends in Immunosuppression and Immunotherapy
www.kenes.com/immuno

February 28, Lyon, France
3rd Congress of ECCO - the European Crohn's and Colitis Organisation
Inflammatory Bowel Diseases 2008
www.ecco-ibd.eu

February 29, Québec, Canada
Canadian Association of Gastroenterology
E-mail: general@cag-acg.org

March 10-13, Birmingham, UK
British Society of Gastroenterology Annual Meeting
E-mail: BSG@mailbox.ulcc.ac.uk

March 14-15, HangZhou, China
Falk Symposium 163: Chronic Inflammation of Liver and Gut

March 23-26, Seoul, Korea
Asian Pacific Association for the Study of the Liver
18th Conference of APASL: New Horizons in Hepatology
www.apaslseoul2008.org

March 29-April 1, Shanghai, China
Shanghai-Hong Kong International Liver Congress
www.livercongress.org

April 05-09, Monte-Carlo (Grimaldi Forum), Monaco
OESO 9th World Congress, The Gastro-esophageal Reflux Disease: from Reflux to Mucosal Inflammation-Management of Adeno-carcinomas
E-mail: robert.giuli@oeso.org

April 9-12, Los Angeles, USA
SAGES 2008 Annual Meeting - part of Surgical Spring Week
www.sages.org/08program/html/

April 18-22, Buenos Aires, Argentina
9th World Congress of the International Hepato-Pancreato Biliary Association
Association for the Study of the Liver
www.ca-ihpba.com.ar

April 23-27, Milan, Italy
43rd Annual Meeting of the European Association for the Study of the Liver
www.easl.ch

May 2-3, Budapest, Hungary
Falk Symposium 164: Intestinal Disorders

May 18-21, San Diego, California, USA
Digestive Disease Week 2008

May 21-22, California, USA
ASGE Annual Postgraduate Course
Endoscopic Practice 2008: At the Interface of Evidence and Expert Opinion
E-mail: education@asge.org

June 4-7, Helsinki, Finland
The 39th Nordic Meeting of Gastroenterology
www.congrex.com/ngc2008

June 5-8, Sitges (Barcelona), Spain
Semana de las Enfermedades Digestivas
E-mail: sepd@sepd.es

June 6-8, Prague, Czech Republic
3rd Annual European Meeting: Perspectives in Inflammatory Bowel Diseases
E-mail: meetings@imedex.com

June 10-13, Istanbul, Turkey
ESGAR 2008 19th Annual Meeting and Postgraduate Course
E-mail: fca@netvisao.pt

June 11-13, Stockholm, Sweden
16th International Congress of the European Association for Endoscopic Surgery
E-mail: info@eaes-eur.org

June 13-14, Amsterdam, Netherlands
Falk Symposium 165: XX International Bile Acid Meeting. B ile Acid Biology and Therapeutic Actions

June 13-14, Prague, Czech Republic
Central and Eastern European Conference on Colorectal "Cancer" Screening, Prevention and Management
E-mail: idca2008@guarant.cz

June 25-28, Barcelona, Spain
10th World Congress on Gastrointestinal Cancer
Imedex and ESMO
E-mail: meetings@imedex.com

June 25-28, Lodz, Poland
Joint Meeting of the European Pancreatic Club (EPC)
and the International Association of Pancreatology (IAP)
E-mail: office@epc-iap2008.org
www.e-p-c.org
www.pancreatology.org

June 26-28, Bratislava, Slovakia
5th Central European Gastroenterology Meeting
www.ceurgem2008.cz

July 9-12, Paris, France
ILTS 14th Annual International Congress
www.ilts.org

September 10-13, Budapest, Hungary
11th World Congress of the International Society for Diseases of the Esophagus
E-mail: isde@isde.net

September 13-16, New Delhi, India
Asia Pacific Digestive Week
E-mail: apdw@apdw2008.net

APDW 2008
September 13-16, New Delhi, Indian
Organized: Indian Society of Gastroenterology

III FALK GASTRO-CONFERENCE
September 17, Mainz, Germany
Falk Workshop: Strategies of Cancer Prevention in Gastroenterology

September 18-19, Mainz, Germany
Falk Symposium 166:
GI Endoscopy - Standards & Innovations

September 18-20, Prague, Czech Republic
Prague Hepatology Meeting 2008
www.czech-hepatology.cz/phm2008

September 20-21, Mainz, Germany
Falk Symposium 167:
Liver Under Constant Attack - From Fat to Viruses

September 24-27, Nantes, France
Third Annual Meeting
European Society of Coloproctology
www.escp.eu.com

October 8-11, Istanbul, Turkey
18th World Congress of the International Association of Surgeons,
Gastroenterologists and Oncologists
E-mail: orkun.sahin@serenas.com.tr

October 18-22, Vienna, Austria
16th United European Gastroenterology Week
www.negf.org
www.acv.at

October 22-25, Minnesota, USA
Anstralian Gastroenterology Week 2008
E-mail: gesa@gesa.org.au

October 22-25, Brisbane, Australia
71st Annual Colon and Rectal Surgery Conference
E-mail: info@colonrectalcourse.org

October 31-November 4, Moscone West Convention Center, San Francisco, CA
59th AASLD Annual Meeting and Postgraduate Course
The Liver Meeting
Information: www.aasld.org

November 6-9, Lucerne, Switzerland
Neurogastroenterology & Motility Joint International Meeting 2008
E-mail: ngm2008@mci-group.com
www.ngm2008.com

November 12, Santiago de Chile, Chile
Falk Workshop: Digestive Diseases: State of the Art and Daily Practice

November 28-29, Cairo, Egypt
1st Hepatology and Gastroenterology Post Graduate Course
www.egyptgastrohep.com

December 7-9, Seoul, Korea
6th International Meeting
Hepatocellular Carcinoma: Eastern and Western Experiences
E-mail: sglee@amc.seoul.kr

INFORMATION FOR ALL
FALK FOUNDATION e.V.
E-mail: symposia@falkfoundation.de
www.falkfoundation.de

Advanced Courses - European
Institute of Telesurgery EITS - 2008
Strasbourg, France
January 18-19, March 28-29, June 6-7, October 3-4

N.O.T.E.S
April 3-5, November 27-29
Laparoscopic Digestive Surgery

June 27-28, November 7-8
Laparoscopic Colorectal Surgery

July 3-5
Interventional GI Endoscopy Techniques
Contact address for all courses:
E-mail: info@eits.fr

International Gastroenterological Congresses 2009
March 23-26, Glasgow, Scotland
Meeting of the British Society of Gastroenterology (BSG)
E-mail: bsg@mailbox.ulcc.ac.uk

May 17-20, Denver, Colorado, USA
Digestive Disease Week 2009

November 21-25, London, UK
Gastro 2009 UEGW/World Congress of Gastroenterology
www.gastro2009.org

Global Collaboration for Gastroenterology

For the first time in the history of gastroenterology, an international conference will take place which joins together the forces of four pre-eminent organisations: Gastro 2009, UEGW/WCOG London. The United European Gastroenterology Federation (UEGF) and the World Gastroenterology Organisation (WGO), together with the World Organisation of Digestive Endoscopy (OMED) and the British Society of Gastroenterology (BSG), are jointly organising a landmark meeting in London from November 21-25, 2009. This collaboration will ensure the perfect balance of basic science and clinical practice, will cover all disciplines in gastroenterology (endoscopy, digestive oncology, nutrition, digestive surgery, hepatology, gastroenterology) and ensure a truly global context; all presented in the exciting setting of the city of London. Attendance is expected to reach record heights as participants are provided with a compact "all-in-one" programme merging the best of several GI meetings. Faculty and participants from all corners of the earth will merge to provide a truly global environment conducive to the exchange of ideas and the forming of friendships and collaborations.

Online Submissions: wjg.wjgnet.com
wjg@wjgnet.com
www.wjgnet.com

World J Gastroenterol 2008 August 28; 14(32): 5102-5104
World Journal of Gastroenterology ISSN 1007-9327
© 2008 The WJG Press. All rights reserved.

Instructions to authors

GENERAL INFORMATION

World Journal of Gastroenterology (*World J Gastroenterol* ISSN 1007-9327 CN 14-1219/R) is a weekly open access peer-reviewed journal supported by an editorial board consisting of 1208 experts in gastroenterology and hepatology from 60 countries. The aim of the journal is to deliver the most clinically relevant original and commentary articles to readers, and to make the full text publicly available to all clinicians, scientists, patients and biomedical students on an unrestricted platform, so that they can access and learn about the most recent key advances in the field.

In addition to the open access nature, another key characteristic of *WJG* is its reading guidance for each article which includes background, research frontier, related reports, breakthroughs, applications, terminology, and comments of peer reviewers for the general readers.

WJG publishes articles on esophageal, gastrointestinal, hepatobiliary and pancreatic tumors, and other esophageal, gastrointestinal, hepatic-biliary and pancreatic diseases in relation to epidermiology, immunology, microbiology, motility & nerve-gut interaction, endocrinology, nutrition & obesity, endoscopy, imaging and advanced hi-technology.

The main goal of *WJG* is to publish high quality commentary articles contributed by leading experts in gastroenterology and hepatology and original articles that combine the clinical practice and advanced basic research, to provide an interactive platform for clinicians and researchers in internal medicine, surgery, infectious diseases, traditional Chinese medicine, oncology, integrated Chinese and Western medicine, imaging, endoscopy, interventional therapy, pathology and other basic medical specialities, and thus eventually improving the clinical practice and healthcare for patients.

Indexed and abstracted in

Current Contents®/Clinical Medicine, Science Citation Index Expanded (also known as SciSearch®) and Journal Citation Reports/Science Edition, Index Medicus, MEDLINE and PubMed, Chemical Abstracts, EMBASE/Excerpta Medica, Abstracts Journals, *Nature Clinical Practice Gastroenterology* and *Hepatology*, CAB Abstracts and Global Health. ISI JCR 2003-2000 IF: 3.318, 2.532, 1.445 and 0.993.

Published by

The WJG Press

SUBMISSION OF MANUSCRIPTS

Manuscripts should be typed in 1.5 line spacing and 12 pt. Book Antiqua with ample margins. Number all pages consecutively, and start each of the following sections on a new page: Title Page, Abstract, Introduction, Materials and Methods, Results, Discussion, Acknowledgements, References, Tables, Figures, and Figure Legends. Neither the editors nor the publisher are responsible for the opinions expressed by contributors. Manuscripts formally accepted for publication become the permanent property of The WJG Press, and may not be reproduced by any means, in whole or in part, without the written permission of both the authors and the publisher. We reserve the right to copy-edit and put onto our website accepted manuscripts. Authors should follow the relevant guidelines for the care and use of laboratory animals of their institution or national animal welfare committee. For the sake of transparency in regard to the performance and reporting of clinical trials, we endorse the policy of the International Committee of Medical Journal Editors to refuse to publish papers on clinical trial results if the trial was not recorded in a publicly-accessible registry at its outset. The only register now available, to our knowledge, is http://www. clinicaltrials.gov sponsored by the United States National Library of Medicine and we encourage all potential contributors to register with it. However, in the case that other registers become available you will be duly notified. A letter of recommendation from each author's organization should be provided with the contributed article to ensure the privacy and secrecy of research is protected.

Authors should retain one copy of the text, tables, photographs and illustrations because rejected manuscripts will not be returned to the author(s) and the editors will not be responsible for loss or damage to photographs and illustrations sustained during mailing.

Online submissions

Manuscripts should be submitted through the Online Submission System at: http://wjg.wjgnet.com/wjg. Authors are highly recommended to consult the ONLINE INSTRUCTIONS TO AUTHORS (http://www.wjgnet.com/wjg/help/instructions.jsp) before attempting to submit online. For assistance, authors encountering problems with the Online Submission System may send an email describing the problem to submission@wjgnet.com, or by telephone: +86-10-85381892. If you submit your manuscript online, do not make a postal contribution. Repeated online submission for the same manuscript is strictly prohibited.

MANUSCRIPT PREPARATION

All contributions should be written in English. All articles must be submitted using word-processing software. All submissions must be typed in 1.5 line spacing and 12 pt. Book Antiqua with ample margins. Style should conform to our house format. Required information for each of the manuscript sections is as follows:

Title page

Full manuscript title, running title, all author(s) name(s), affiliations, institution(s) and/or department(s) where the work was carried out; author contributions; disclosure of any financial support for the research; and the name, full address, telephone and fax numbers and email address of the corresponding author should be included. Titles should be concise and informative (remove all unnecessary words), emphasize what is new, and avoid abbreviations. A short running title of less than 40 letters should be provided. List the author(s)' name(s) as follows: initial and/or first name, middle name or initial(s), and full family name.

Author controbutions: The format of this section should be like this: Author contributions: Wang CL and Liang L contributed equally to this work; Wang CL, Liang L, Fu JF, Zou CC, Hong F and Wu XM designed research; Wang CL, Zou CC, Hong F and Wu XM performed research; Xue JZ and Lu JR contributed new reagents/analytic tools; Wang CL, Liang L and Fu JF analyzed data; and Wang CL, Liang L and Fu JF wrote the paper.

Peer reviewers: All articles received are subject to peer review. Normally, three experts are invited for each article. Decision for acceptance is made only when at least two experts recommend an article for publication. Reviewers for accepted manuscripts are acknowledged in each manuscript, and reviewers of articles which were not accepted will be acknowledged at the end of each issue. To ensure the quality of the articles published in *WJG*, reviewers of accepted manuscripts will be announced by publishing the name, title/position and institution of the reviewer in the footnote accompanying the printed article. For example, reviewers: Professor Jing-Yuan Fang, Shanghai Institute of Digestive Disease, Shanghai, Affiliated Renji Hospital, Medical Faculty, Shanghai Jiaotong University, Shanghai, China; Professor Xin-Wei Han, Department of Radiology, The First Affiliated Hospital, Zhengzhou University, Zhengzhou, Henan Province, China; and Professor Anren Kuang, Department of Nuclear Medicine, Huaxi Hospital, Sichuan University, Chengdu, Sichuan Province, China.

Abstract

An informative, structured abstract of no more than 350 words should accompany each manuscript. Abstracts for original contributions should be structured into the following sections: AIM: Only the purpose should be included. METHODS: The materials, techniques, instruments and equipment, and the experimental procedures should be included. RESULTS: The observed and experimental results, including data, effects, outcome, *etc.* should be included. Authors should present *P* value where necessary, and also include any significant data. CONCLUSION: Accurate view and the value of the results should be included.

The format for structured abstracts can be found at: http://www.wjgnet.com/wjg/help/11.doc.

Key words

Please list 5-10 key words, selected mainly from *Index Medicus*, which reflect the content of the study.

Text

For articles of these sections, original articles, rapid communication

and case reports, the main text should be structured into the following sections: INTRODUCTION, MATERIALS AND METHODS, RESULTS and DISCUSSION, and should include appropriate Figures and Tables. Data should be presented in the body text or in Figures and Tables, but not in both. The main text format of these sections, editorial, topic highlight, case report, letters to the editors, should be found at: http://www.wjgnet.com/wjg/help/instructions.jsp.

Illustrations

Figures should be numbered as 1, 2, 3, *etc.*, and mentioned clearly in the main text. Provide a brief title for each figure on a separate page. Detailed legends should not be provided under the figures. This part should be added into the text where the figures are applicable. Figures should be either Photoshop or Illustrator files (in tiff, eps, jpeg formats) at high-resolution. Examples can be found at: http://www.wjgnet.com/1007-9327/13/4520.pdf; http://www.wjgnet.com/1007-9327/13/4554.pdf; http://www.wjgnet.com/1007-9327/13/4891.pdf; http://www.wjgnet.com/1007-9327/13/4986.pdf; http://www.wjgnet.com/1007-9327/13/4498.pdf. Keeping all elements compiled is necessary in line-art image. Scale bars should be used rather than magnification factors, with the length of the bar defined in the legend rather than on the bar itself. File names should identify the figure and panel. Avoid layering type directly over shaded or textured areas. Please use uniform legends for the same subjects. For example: Figure 1 Pathological changes in atrophic gastritis after treatment. A: ...; B: ...; C: ...; D: ...; E: ...; F: ...; G: …*etc.* It is our principle to publish high resolution-figures for the printed and E-versions.

Tables

Three-line tables should be numbered 1, 2, 3, *etc.*, and mentioned clearly in the main text. Provide a brief title for each table. Detailed legends should not be included under tables, but rather added into the text where applicable. The information should complement but not duplicate the text. Use one horizontal line under the title, a second under column heads, and a third below the Table, above any footnotes. Vertical and italic lines should be omitted.

Notes in tables and illustrations

Data that are not statistically significant should not be noted. $^{a}P < 0.05$, $^{b}P < 0.01$ should be noted ($P > 0.05$ should not be noted). If there are other series of P values, $^{c}P < 0.05$ and $^{d}P < 0.01$ are used. A third series of P values can be expressed as $^{e}P < 0.05$ and $^{f}P < 0.01$. Other notes in tables or under illustrations should be expressed as ^{1}F, ^{2}F, ^{3}F; or sometimes as other symbols with a superscript (Arabic numerals) in the upper left corner. In a multi-curve illustration, each curve should be labeled with ●, ○, ■, □, ▲, △, *etc.*, in a certain sequence.

Acknowledgments

Brief acknowledgments of persons who have made genuine contributions to the manuscripts and who endorse the data and conclusions should be included. Authors are responsible for obtaining written permission to use any copyrighted text and/or illustrations.

REFERENCES

Coding system

The author should number the references in Arabic numerals according to the citation order in the text. Put reference numbers in square brackets in superscript at the end of citation content or after the cited author's name. For citation content which is part of the narration, the coding number and square brackets should be typeset normally. For example, "Crohn's disease (CD) is associated with increased intestinal permeability[1,2]". If references are cited directly in the text, they should be put together within the text, for example, "From references[19,22-24], we know that..."

When the authors write the references, please ensure that the order in text is the same as in the references section, and also ensure the spelling accuracy of the first author's name. Do not list the same citation twice.

PMID requirement

PMID roots in the abstract serial number indexed by PubMed (http://www.ncbi.nlm.nih.gov/entrez/query.fcgi?db=PubMed). The author should supply the PMID for journal citation. For those references that have not been indexed by PubMed, a printed copy of the first page of the full reference should be submitted.

The accuracy of the information for journal citations is very important. Using the reference testing system, the authors and editor should check the authors name, title, journal title, publication date, volume number, start page, and end page. We will interlink all references with PubMed in an ASP file so that the readers can immediately access the abstract of the citations online.

DOI requirement

A CrossRef DOI® (Digital Object Identifier) name is a unique string created to identify a piece of scholarly content in the online environment. The author should supply the DOIs for journal citation(doi:10.3748/wjg.13.6458). This link (http://www.crossref.org/SimpleTextQuery/) allows you to retrieve Digital Object Identifiers (DOIs) for journal articles, books, and chapters by simply cutting and pasting the reference list into the box. You may use the form with any reference style, although the tool works most reliably if references are formatted in a standard style such as shown in this example: Assimakopoulos SF, Scopa CD, Vagianos CE. Pathophysiology of increased intestinal permeability in obstructive jaundice. *World J Gastroenterol* 2007; 13(48): 6458-6464

The accuracy of the information of journal citations is very important. We will interlink all references with DOI in ASP file so that readers can access the abstracts of cited articles online immediately.

Style for journal references

Authors: the name of the first author should be typed in bold-faced letters. The family name of all authors should be typed with the initial letter capitalized, followed by their abbreviated first and middle initials. (For example, Lian-Sheng Ma is abbreviated as Ma LS, Bo-Rong Pan as Pan BR). The title of the cited article and italicized journal title (journal title should be in its abbreviated form as shown in PubMed), publication date, volume number (in black), start page, and end page [PMID: 11819634 DOI: 10.3748/wjg.13.5396].

Style for book references

Authors: the name of the first author should be typed in bold-faced letters. The surname of all authors should be typed with the initial letter capitalized, followed by their abbreviated middle and first initials. (For example, Lian-Sheng Ma is abbreviated as Ma LS, Bo-Rong Pan as Pan BR) Book title. Publication number. Publication place: Publication press, Year: start page and end page.

Format

Journals

English journal article (list all authors and include the PMID where applicable)

1 **Jung EM**, Clevert DA, Schreyer AG, Schmitt S, Rennert J, Kubale R, Feuerbach S, Jung F. Evaluation of quantitative contrast harmonic imaging to assess malignancy of liver tumors: A prospective controlled two-center study. *World J Gastroenterol* 2007; **13**: 6356-6364 [PMID: 18081224 DOI: 10.3748/wjg.13.6356]

Chinese journal article (list all authors and include the PMID where applicable)

2 **Lin GZ**, Wang XZ, Wang P, Lin J, Yang FD. Immunologic effect of Jianpi Yishen decoction in treatment of Pixu-diarrhoea. *Shijie Huaren Xiaohua Zazhi* 1999; **7**: 285-287

In press

3 **Tian D**, Araki H, Stahl E, Bergelson J, Kreitman M. Signature of balancing selection in Arabidopsis. *Proc Natl Acad Sci USA* 2006; In press

Organization as author

4 **Diabetes Prevention Program Research Group**. Hypertension, insulin, and proinsulin in participants with impaired glucose tolerance. *Hypertension* 2002; **40**: 679-686 [PMID: 12411462]

Both personal authors and an organization as author

5 **Vallancien G**, Emberton M, Harving N, van Moorselaar RJ; Alf-One Study Group. Sexual dysfunction in 1, 274 European men suffering from lower urinary tract symptoms. *J Urol* 2003; **169**: 2257-2261 [PMID: 12771764]

No author given

6 21st century heart solution may have a sting in the tail. *BMJ* 2002; **325**: 184 [PMID: 12142303]

Volume with supplement

7 **Geraud G**, Spierings EL, Keywood C. Tolerability and safety of frovatriptan with short- and long-term use for treatment

of migraine and in comparison with sumatriptan. *Headache* 2002; **42** Suppl 2: S93-99 [PMID: 12028325]

Issue with no volume

8 **Banit DM**, Kaufer H, Hartford JM. Intraoperative frozen section analysis in revision total joint arthroplasty. *Clin Orthop Relat Res* 2002; (**401**): 230-238 [PMID: 12151900]

No volume or issue

9 Outreach: Bringing HIV-positive individuals into care. *HRSA Careaction* 2002; 1-6 [PMID: 12154804]

Books

Personal author(s)

10 **Sherlock S**, Dooley J. Diseases of the liver and billiary system. 9th ed. Oxford: Blackwell Sci Pub, 1993: 258-296

Chapter in a book (list all authors)

11 **Lam SK**. Academic investigator's perspectives of medical treatment for peptic ulcer. In: Swabb EA, Azabo S. Ulcer disease: investigation and basis for therapy. New York: Marcel Dekker, 1991: 431-450

Author(s) and editor(s)

12 **Breedlove GK**, Schorfheide AM. Adolescent pregnancy. 2nd ed. Wieczorek RR, editor. White Plains (NY): March of Dimes Education Services, 2001: 20-34

Conference proceedings

13 **Harnden P**, Joffe JK, Jones WG, editors. Germ cell tumours V. Proceedings of the 5th Germ cell tumours Conference; 2001 Sep 13-15; Leeds, UK. New York: Springer, 2002: 30-56

Conference paper

14 **Christensen S**, Oppacher F. An analysis of Koza's computational effort statistic for genetic programming. In: Foster JA, Lutton E, Miller J, Ryan C, Tettamanzi AG, editors. Genetic programming. EuroGP 2002: Proceedings of the 5th European Conference on Genetic Programming; 2002 Apr 3-5; Kinsdale, Ireland. Berlin: Springer, 2002: 182-191

Electronic journal (list all authors)

15 Morse SS. Factors in the emergence of infectious diseases. Emerg Infect Dis serial online, 1995-01-03, cited 1996-06-05; 1(1): 24 screens. Available from: URL: http//www.cdc.gov/ncidod/EID/eid.htm

Patent (list all authors)

16 **Pagedas AC**, inventor; Ancel Surgical R&D Inc., assignee. Flexible endoscopic grasping and cutting device and positioning tool assembly. United States patent US 20020103498. 2002 Aug 1

Inappropriate references

Authors should always cite references that are relevant to their article, and avoid any inappropriate references. Inappropriate references include those linked with a hyphen when the difference between the two numbers is greater than five. For example, [1-6], [2-14] and [1, 3, 4-10, 22] are all considered inappropriate references. Authors should not cite their own unrelated published articles.

Statistical data

Write as mean ± SD or mean ± SE.

Statistical expression

Express *t* test as *t* (in italics), *F* test as *F* (in italics), chi square test as χ^2 (in Greek), related coefficient as *r* (in italics), degree of freedom as υ (in Greek), sample number as *n* (in italics), and probability as *P* (in italics).

Units

Use SI units. For example: body mass, m (B) = 78 kg; blood pressure, p (B) = 16.2/12.3 kPa; incubation time, t (incubation) = 96 h, blood glucose concentration, c (glucose) 6.4 ± 2.1 mmol/L; blood CEA mass concentration, p (CEA) = 8.6 24.5 μg/L; CO_2 volume fraction, 50 mL/L CO_2, not 5% CO_2; likewise for 40 g/L formaldehyde, not 10% formalin; and mass fraction, 8 ng/g, *etc.* Arabic numerals such as 23, 243, 641 should be read 23 243 641.

The format for how to accurately write common units and quantums can be found at: http://www.wjgnet.com/wjg/help/15.doc.

Abbreviations

Standard abbreviations should be defined in the abstract and on first mention in the text. In general, terms should not be abbreviated unless they are used repeatedly and the abbreviation is helpful to the reader. Permissible abbreviations are listed in Units, Symbols and Abbreviations: A Guide for Biological and Medical Editors and Authors (Ed. Baron DN, 1988) published by The Royal Society of Medicine, London. Certain commonly used abbreviations, such as DNA, RNA, HIV, LD50, PCR, HBV, ECG, WBC, RBC, CT, ESR, CSF, IgG, ELISA, PBS, ATP, EDTA, mAb, can be used directly without further explanation.

Italics

Quantities: *t* time or temperature, *c* concentration, *A* area, *l* length, *m* mass, *V* volume.
Genotypes: *gyrA*, *arg* 1, *c myc*, *c fos*, *etc.*
Restriction enzymes: *Eco*RI, *Hin*dI, *Bam*HI, *Kbo* I, *Kpn* I, *etc.*
Biology: *H pylori*, *E coli*, *etc.*

SUBMISSION OF THE REVISED MANUSCRIPTS AFTER ACCEPTED

Please revise your article according to the revision policies of *WJG*. The revised version including manuscript and high-resolution image figures (if any) should be copied on a floppy or compact disk. The author should send the revised manuscript, along with printed high-resolution color or black and white photos, copyright transfer letter, and responses to the reviewers by courier (such as EMS/DHL).

Editorial Office

World Journal of Gastroenterology
Editorial Department: Room 903
Ocean International Center, Building D
No. 62 Dongsihuan Zhonglu
Chaoyang District, Beijing 100025, China
E-mail: wjg@wjgnet.com
http://www.wjgnet.com
Telephone: +86-10-59080039
Fax: +86-10-85381893

Language evaluation

The language of a manuscript will be graded before it is sent for revision. (1) Grade A: priority publishing; (2) Grade B: minor language polishing; (3) Grade C: a great deal of language polishing needed; (4) Grade D: rejected. Revised articles should reach Grade A or B.

Copyright assignment form

Please download a Copyright assignment form from http://www.wjgnet.com/wjg/help/9.doc.

Responses to reviewers

Please revise your article according to the comments/suggestions provided by the reviewers. The format for responses to the reviewers' comments can be found at: http://www.wjgnet.com/wjg/help/10.doc.

Proof of financial support

For paper supported by a foundation, authors should provide a copy of the document and serial number of the foundation.

Links to documents related to the manuscript

WJG will be initiating a platform to promote dynamic interactions between the editors, peer reviewers, readers and authors. After a manuscript is published online, links to the PDF version of the submitted manuscript, the peer-reviewers' report and the revised manuscript will be put on-line. Readers can make comments on the peer reviewer's report, authors' responses to peer reviewers, and the revised manuscript. We hope that authors will benefit from this feedback and be able to revise the manuscript accordingly in a timely manner.

Science news releases

Authors of accepted manuscripts are suggested to write a science news item to promote their articles. The news will be released rapidly at EurekAlert/AAAS (http://www.eurekalert.org). The title for news items should be less than 90 characters; the summary should be less than 75 words; and main body less than 500 words. Science news items should be lawful, ethical, and strictly based on your original content with an attractive title and interesting pictures.

Publication fee

Authors of accepted articles must pay a publication fee.
EDITORIAL, TOPIC HIGHLIGHTS, BOOK REVIEWS and LETTERS TO THE EDITOR are published free of charge.