

# World Journal of *Gastrointestinal Endoscopy*

*World J Gastrointest Endosc* 2022 January 16; 14(1): 1-62



## REVIEW

- 1 Safety considerations in laparoscopic surgery: A narrative review

*Madhok B, Nanayakkara K, Mahawar K*

## MINIREVIEWS

- 17 Endoscopic cryotherapy: Indications, techniques, and outcomes involving the gastrointestinal tract

*Dhaliwal A, Saghir SM, Mashiana HS, Braseth A, Dhindsa BS, Ramai D, Taunk P, Gomez-Esquivel R, Dam A, Klapman J, Adler DG*

- 29 Is gastroscopy necessary before bariatric surgery?

*Kanat BH, Doğan S*

- 35 Current role of endoscopic ultrasound in the diagnosis and management of pancreatic cancer

*Salom F, Prat F*

## ORIGINAL ARTICLE

## Retrospective Study

- 49 Feasibility of gastric endoscopic submucosal dissection in elderly patients aged  $\geq 80$  years

*Inokuchi Y, Ishida A, Hayashi K, Kaneta Y, Watanabe H, Kano K, Furuta M, Takahashi K, Fujikawa H, Yamada T, Yamamoto K, Machida N, Ogata T, Oshima T, Maeda S*

**ABOUT COVER**

Editorial Board Member of *World Journal of Gastrointestinal Endoscopy*, Saurabh Chawla, FACG, MD, Associate Professor, Doctor, Digestive Diseases, Grady Memorial Hospital, Atlanta, GA 30322, United States.  
schawla2@gmail.com

**AIMS AND SCOPE**

The primary aim of *World Journal of Gastrointestinal Endoscopy* (WJGE, *World J Gastrointest Endosc*) is to provide scholars and readers from various fields of gastrointestinal endoscopy with a platform to publish high-quality basic and clinical research articles and communicate their research findings online.

WJGE mainly publishes articles reporting research results and findings obtained in the field of gastrointestinal endoscopy and covering a wide range of topics including capsule endoscopy, colonoscopy, double-balloon enteroscopy, duodenoscopy, endoscopic retrograde cholangiopancreatography, endosonography, esophagoscopy, gastrointestinal endoscopy, gastroscopy, laparoscopy, natural orifice endoscopic surgery, proctoscopy, and sigmoidoscopy.

**INDEXING/ABSTRACTING**

The WJGE is now abstracted and indexed in Emerging Sources Citation Index (Web of Science), PubMed, PubMed Central, China National Knowledge Infrastructure (CNKI), and Superstar Journals Database. The 2021 edition of Journal Citation Reports® cites the 2020 Journal Citation Indicator (JCI) for WJGE as 0.36.

**RESPONSIBLE EDITORS FOR THIS ISSUE**

Production Editor: Hua-Ge Yu; Production Department Director: Xu Guo; Editorial Office Director: Jia-Ping Yan.

**NAME OF JOURNAL**

*World Journal of Gastrointestinal Endoscopy*

**ISSN**

ISSN 1948-5190 (online)

**LAUNCH DATE**

October 15, 2009

**FREQUENCY**

Monthly

**EDITORS-IN-CHIEF**

Anastasios Koulaouzidis, Bing Hu, Sang Chul Lee, Joo Young Cho

**EDITORIAL BOARD MEMBERS**

<https://www.wjgnet.com/1948-5190/editorialboard.htm>

**PUBLICATION DATE**

January 16, 2022

**COPYRIGHT**

© 2022 Baishideng Publishing Group Inc

**INSTRUCTIONS TO AUTHORS**

<https://www.wjgnet.com/bpg/gerinfo/204>

**GUIDELINES FOR ETHICS DOCUMENTS**

<https://www.wjgnet.com/bpg/gerinfo/287>

**GUIDELINES FOR NON-NATIVE SPEAKERS OF ENGLISH**

<https://www.wjgnet.com/bpg/gerinfo/240>

**PUBLICATION ETHICS**

<https://www.wjgnet.com/bpg/gerinfo/288>

**PUBLICATION MISCONDUCT**

<https://www.wjgnet.com/bpg/gerinfo/208>

**ARTICLE PROCESSING CHARGE**

<https://www.wjgnet.com/bpg/gerinfo/242>

**STEPS FOR SUBMITTING MANUSCRIPTS**

<https://www.wjgnet.com/bpg/gerinfo/239>

**ONLINE SUBMISSION**

<https://www.f6publishing.com>



## Safety considerations in laparoscopic surgery: A narrative review

Brij Madhok, Kushan Nanayakkara, Kamal Mahawar

**ORCID number:** Brij Madhok 0000-0001-9212-5588; Kushan Nanayakkara 0000-0003-1422-880X; Kamal Mahawar 0000-0003-2551-3462.

**Author contributions:** Madhok B wrote the initial draft and outline of the article, and reviewed, edited, and finalised the manuscript written by Nanayakkara K; Nanayakkara K reviewed the current literature, wrote the initial paper, and reference list; Mahawar K reviewed final version and rewrote parts of the article; all authors have approved the final version.

**Conflict-of-interest statement:** Brij Madhok-None; Kushan Nanayakkara-None; Kamal Mahawar-Mr. Mahawar has been paid honoraria and consultancy fees by Ethicon®, Medtronic®, Olympus®, Gore®, and various NHS Trusts for educational and mentoring activities.

**Country/Territory of origin:** United Kingdom

**Specialty type:** Gastroenterology and hepatology

**Provenance and peer review:** Invited article; Externally peer reviewed.

**Peer-review model:** Single blind

**Peer-review report's scientific quality classification**

**Brij Madhok, Kushan Nanayakkara,** Upper GI Surgery, University Hospitals of Derby and Burton NHS Foundation Trust, Derby DE22 3NE, United Kingdom

**Kamal Mahawar,** Department of General Surgery, South Tyneside and Sunderland NHS Foundation Trust, Sunderland SR4 7TP, United Kingdom

**Corresponding author:** Brij Madhok, FRCS, MBBS, MD, MS, Surgeon, Upper GI Surgery, University Hospitals of Derby and Burton NHS Foundation Trust, Uttoxeter Road, Derby DE22 3NE, United Kingdom. [brijeshmadhok@gmail.com](mailto:brijeshmadhok@gmail.com)

### Abstract

Laparoscopic surgery has many advantages over open surgery. At the same time, it is not without its risks. In this review, we discuss steps that could enhance the safety of laparoscopic surgery. Some of the important safety considerations are ruling out pregnancy in women of the childbearing age group; advanced discussion with the patient regarding unexpected intraoperative situations, and ensuring appropriate equipment is available. Important perioperative safety considerations include thromboprophylaxis; antibiotic prophylaxis; patient allergies; proper positioning of the patient, stack, and monitor(s); patient appropriate pneumoperitoneum; ergonomic port placement; use of lowest possible intra-abdominal pressure; use of additional five-millimetre (mm) ports as needed; safe use of energy devices and laparoscopic staplers; low threshold for a second opinion; backing out if unsafe to proceed; avoiding hand-over in the middle of the procedure; ensuring all planned procedures have been performed; inclusion of laparoscopic retrieval bags and specimens in the operating count; avoiding 10-15 mm ports for placement of drains; appropriate port closures; and use of long-acting local anaesthetic agents for analgesia. Important postoperative considerations include adequate analgesia; early ambulation; careful attention to early warning scores; and appropriate discharge advice.

**Key Words:** Laparoscopy; Laparoscopic surgery; Minimally invasive surgery; Key-hole surgery; Patient safety; Safe surgery; Safe laparoscopy

©The Author(s) 2022. Published by Baishideng Publishing Group Inc. All rights reserved.

**Core Tip:** Check for pregnancy in women of the childbearing age group. Make an alternative advanced plan with the patient regarding unexpected intra-abdominal



Grade A (Excellent): A  
Grade B (Very good): B, B  
Grade C (Good): C, C  
Grade D (Fair): 0  
Grade E (Poor): 0

**Open-Access:** This article is an open-access article that was selected by an in-house editor and fully peer-reviewed by external reviewers. It is distributed in accordance with the Creative Commons Attribution NonCommercial (CC BY-NC 4.0) license, which permits others to distribute, remix, adapt, build upon this work non-commercially, and license their derivative works on different terms, provided the original work is properly cited and the use is non-commercial. See: <http://creativecommons.org/licenses/by-nc/4.0/>

**Received:** March 18, 2021

**Peer-review started:** March 18, 2021

**First decision:** July 17, 2021

**Revised:** August 11, 2021

**Accepted:** December 10, 2021

**Article in press:** December 10, 2021

**Published online:** January 16, 2022

**P-Reviewer:** Di Saverio S, Dilek ON, He YF, Piozzi GN, Zhang L

**S-Editor:** Fan JR

**L-Editor:** A

**P-Editor:** Fan JR



circumstances. Consider adequate thromboprophylaxis and antibiotic prophylaxis. Intraoperatively, surgeons should ensure correct patient positioning and placement of stack and monitor(s). Establishing pneumoperitoneum safely, proper use of energy devices/staplers, use of lowest possible intra-abdominal pressure, avoidance of 10-15 millimetre ports for placement of drains; and a thorough “time out” at the end are some of the other important intraoperative considerations. The operating count by nurses should include specimens and retrieval bags. Important postoperative considerations include analgesia, early ambulation, and careful attention to early warning scores.

**Citation:** Madhok B, Nanayakkara K, Mahawar K. Safety considerations in laparoscopic surgery: A narrative review. *World J Gastrointest Endosc* 2022; 14(1): 1-16

**URL:** <https://www.wjgnet.com/1948-5190/full/v14/i1/1.htm>

**DOI:** <https://dx.doi.org/10.4253/wjge.v14.i1.1>

## INTRODUCTION

Laparoscopic surgery could be regarded as one of the greatest advances in the field of surgery. It has brought with it a revolution in the use of digital and robotic technology in surgical practice. It has radically shortened the patient recovery times compared to the ‘open’ operations. Even more remarkably, these gains have been made whilst simultaneously enhancing the quality of surgery[1,2]. Laparoscopic surgery is associated with less pain, fewer wound infections, reduced hospital stay, reduced morbidity and mortality and early return to work and improved overall quality of life [3,4]. However, when laparoscopy was first introduced there were concerns regarding its safety[5,6]. Fortunately, with time as surgical teams have progressed over their learning curves, many of the initially reported complications have become relatively infrequent[7].

In this article, we review some of the key areas that could enhance the safety of laparoscopic surgery. We have structured this article to simulate a patient's journey into preoperative, perioperative, and postoperative considerations.

## PRE-OPERATIVE PLANNING

### Patient selection

Patient selection plays a key role in enhancing the safety of laparoscopic surgery[8,9]. In addition to the risks associated with a general anaesthetic, laparoscopy is associated with risks due to increased intra-abdominal pressure (IAP) and in some cases extreme patient positioning[10]. There is no absolute contraindication to laparoscopic surgery but patients with significant medical comorbidities should be treated with caution just like any other surgery. Some patients may be suitable for laparoscopic surgery but not the corresponding open procedure and this should be discussed with the patient in advance. The morbidity and mortality of the open surgery may be too high (such as frail patients or those suffering from severe obesity) and surgeons may need to either back out without performing any procedure (such as when faced with extensive adhesions or a cirrhotic liver or a huge liver) or perform a different procedure to the one planned (such as a subtotal cholecystectomy instead of a total cholecystectomy; or sleeve gastrectomy in place of Roux-en-Y gastric bypass). An advanced discussion with patients and their families regarding these aspects can help surgeons take the most appropriate course of action in such challenging circumstances.

Another potentially serious issue could be surgery without the knowledge that the patient is pregnant. Though this has implications for all pregnant women and the unborn baby, the implications are even more severe after operations such as bariatric and metabolic surgery[11]. All women in the childbearing age group should, therefore, be offered a routine urine pregnancy test at preassessment to rule out pregnancy[12].

Additionally, laparoscopic surgery may be challenging in a patient who has previously undergone an open abdominal operation especially an emergency laparotomy. In these patients, safe access to the peritoneal cavity may be difficult[8]. Surgeons should generally try to avoid areas where intra-abdominal adhesions are

likely to be maximum for pneumoperitoneum and first port insertion. For example, authors would suggest optical pneumoperitoneum in left upper quadrant as the entry point in patients who have had a previous midline laparotomy.

Like any other surgery, non-urgent procedures may be deferred to allow for patient optimisation. This may include treatment of underlying co-morbidities, smoking cessation, or assisted weight loss. Similarly, patients with obesity could be offered appropriate liver shrinking diet to facilitate cholecystectomy and bariatric procedures [13].

### **Procedure selection**

Over the last couple of decades, an increasing variety of operations are being performed laparoscopically[14-16]. In many cases, the laparoscopic approach has become the norm. For instance, it is difficult to believe that gastric bypass for obesity was once performed using an open approach. A similar expansion of laparoscopy is also being observed in emergency surgery in haemodynamically stable patients[17,18]. Laparoscopy has also been reported to be safe with reduced risks of nontherapeutic laparotomy and mortality in patients with blunt abdominal trauma[19]. Though its role in penetrating abdominal trauma is less clear, some surgeons believe it may be useful as a screening tool for identifying patients who would require laparotomy[20]. Procedures can be laparoscopic (such as gastric bypass for morbid obesity), or hybrid-combined open and laparoscopy (such as anterior resection for rectal cancer) depending on the underlying pathology and experience of the surgeon.

### **Review of pre-operative investigations**

The main drawbacks of laparoscopic surgery are reduced tactile and depth perception, which could be critical in many surgical procedures (*e.g.*, segmental colectomy for small malignant polyps)[21]. Where feasible, we suggest endoscopic procedures for such lesions and, if surgery is required, preoperative endoscopic tattooing could help intraoperative identification of the pathology[22,23]. A preoperative review of radiological imaging with an experienced radiologist can also be helpful.

---

## **PERI-OPERATIVE CONSIDERATIONS**

---

### **Team brief and safe surgery checklist**

A good and effective team brief is crucial before any operation. All members of the team including the consultant surgeon, surgical assistants/trainees, anaesthetist, anaesthetic trainee/operating department practitioners, scrub nurse, and circulating nurse should be present during the team brief. These sessions provide an opportunity for discussion of any anticipated difficulties, measures for prophylaxis of venous thromboembolism, antibiotic prophylaxis, glycaemic control, patient allergies, patient warming, patient positioning, location of the screen, need for X-ray, *etc.* We strongly recommend team briefings are done as part of the World Health Organisation (WHO) "safe-surgery" checklist, which has been shown to reduce human error and adverse effects while improving communication and teamwork[11,24]. While discussing allergies, particular attention should be paid to allergies to something that would normally be used during or after surgery. Some elective procedures may need to be deferred while patient is referred to appropriate specialists for further testing and confirmation of allergies.

### **Patient positioning**

Proper patient position is essential for the safe performance of laparoscopic surgery. Appropriate precautions must be taken to ensure neutral positioning of major joints and padding of pressure points[25,26]. Some surgeons prefer a "French" position (surgeon stands between the legs of the patient) whereas others prefer standing on the right side of the patient. Regardless of these preferences, basic principles of positioning remain the same. The patient must be secured with a strap over the chest/thighs with or without footrests (depending on whether reverse Trendelenburg position is anticipated during the surgery) to avoid lateral and caudal slippage[11]. Likewise, for pelvic surgery, the patient may need to be in Trendelenburg position. In these cases, hips and knees should be kept in a neutral position in secured leg supports with soft cushions for all pressure points. Shoulder supports can also help prevent cephalad sliding of patients. If stationary retractors are required, such as Nathanson's liver retractor, they should be fastened securely to the operating table to minimise intra-operative adverse events, such as liver injuries[27]. One should use utmost care while

introducing and removing these retractors. The liver may be densely adherent to underlying vascular structures and careless lifting may lead to traction injuries. Moving the patient on and off the operating table should be carried out properly to avoid patient and staff injuries especially for patients with obesity where air mattresses (such as HoverMatt®, HoverTech International, Allentown, PA, United States) may be useful[28].

### **Laparoscopy setup**

A significant number of laparoscopic surgeons suffer from work-related musculo-skeletal injuries (up to 70%)[29], and as such ergonomics are more pertinent to laparoscopic surgery than probably open or even robotic surgery. The patient's position, height of the operating table, port position, and laparoscopic monitor setup are some of the important factors to consider in this regard[30,31]. One key suggestion is that the surgeon, the operating field, and the monitor should be in a straight line with triangulation between the camera and main operating ports. The height of the monitor should be just below the surgeon's eye level (preferably 0 to 150) to avoid sprain due to prolonged neck extension[32,33]. Fatigue amongst the surgeon and assistant may increase the risk of error during the procedure, and hence every effort should be made to improve ergonomics. To overcome some of these ergonomic challenges, modern laparoscopic theatre suites are equipped with permanently installed ceiling suspended multiple flat-screen monitors with adjustable inclination[34]. Relative lack of depth perception (2D view) has been a major disadvantage with laparoscopy compared to open surgery. To overcome this, 4K ultra high definition technology[35] and 3D laparoscopic technology have been introduced[36], and several trials have compared the two[35,37]. Neither seems superior to the other, and a recent consensus statement from the European Association of Endoscopic Surgeons concluded that further robust research is required to investigate the advantages of 3D laparoscopy system[38]. Higher cost as well as the stress of the 3D laparoscopy system and issues with surgeon's vision mean that these systems are not yet in widespread usage[39].

### **Port positioning and insertion techniques**

It has been suggested that up to 50% of major complications in laparoscopic surgery occur at the time of port insertion[4]. Surgeons should, therefore, be proficient with different techniques for establishing pneumoperitoneum. Open Hasson technique[40], closed Veress needle entry (named after Janos Veres)[41] and optical ports (with or without prior pneumoperitoneum using a Veress needle) are the most common methods currently used. A recent Cochrane review showed none of these approaches stand out in terms of complications such as visceral injuries and major vascular injuries[42]. However, open Hasson's method is associated with the least chance of entry failures compared to the other two modalities[42]. Even though many surgeons have a preferred technique, the selection of entry technique should probably be based on patient characteristics. For example, the open juxta-umbilical approach is safe and quick for thin to averagely built patients with less abdominal wall fat and with no previous midline laparotomy; whereas optical port insertion in left upper quadrant (with or without prior Veress needle pneumoperitoneum) might be safer for patients with previous midline laparotomy or obesity[43]. In any closed technique, the first port should always be introduced using optical guidance and left upper abdomen (Palmer's point) is regarded to the safest place for this purpose by many surgeons[44].

The size of the primary port (10-12 mm or 5 mm) also depends on the surgeon's preference and type of surgery. For example, some surgeons prefer a 5 mm primary port for paediatric patients to minimise tissue trauma. However, the quality of the picture obtained through a 5 mm scope can be inferior to a standard 10 mm scope due to fewer optical fibres. The size and position of subsequent ports depend on the operation and anticipated instruments in use. Most of the instruments can be safely used through 5 mm ports, but staplers, large clip applicators, retrieval graspers usually require 12 mm ports. Surgeons should also bear in mind that a curved needle will not go through a 5 mm port whereas a ski-shaped needle will. Curved needles can be lost intra-abdominally in an attempt to retrieve them through a 5 mm port[11]. Surgeons should always follow any needle during insertion and removal from the abdominal cavity. Occasionally, larger 15 mm ports are required for thick stapler devices as well as to extract large specimens. However, in the authors' experience, this is rare as most specimens can be removed through a 12 mm port site with some stretch. However, if a 15 mm port is used, the port site should always be closed irrespective of the patient's body mass index. All subsequent port placements, after the primary port insertion, should be under direct vision to avoid injury to the underlying viscera. Injury to inferior epigastric vessels is reported to be the commonest cause of

port site bleeding[45,46]. In thin patients, transillumination can help reduce the chance of inadvertently injuring these vessels.

There are two types of trocars: Bladed and non-bladed that are available for subsequent port placements. The data on comparing the two types are very limited, but non-bladed trocars are probably associated with less trocar-site bleeding with no difference in visceral injury[47]. It is our view that surgeons should only use blunt-tipped non-bladed trocars in laparoscopic surgery as they are less likely to result in inadvertent injuries to epigastric vessels and viscera. All ports should be placed according to the triangulation principle for the better ergonomics[48]. After all the ports are inserted, a gross inspection of the peritoneal cavity is important to identify any inadvertent injury or any unexpected finding. Standard laparoscopic ports are 100 mm in length and suitable for most regular laparoscopic procedures. However, extra-length (150 mm) ports may be necessary to gain access to patients with thick abdominal walls. Usage of appropriate length ports helps to prevent repeated port displacement and fascial injury caused by repeated insertions. If available, balloon tip ports can prevent port displacement.

### ***Pneumoperitoneum***

Optimal pneumoperitoneum is vital for safe laparoscopic surgery to ensure adequate visualisation. But, it can also have adverse effects especially on the cardiovascular system[49-51]. Good communication with the anaesthetist is important at the start of insufflation. The rate of insufflation and intra-peritoneal pressure are the key considerations for each procedure[52]. A rapid rise in IAP rise could result in hemodynamic instability from bradycardia or other life-threatening cardiac arrhythmias especially in elderly patients and those with pre-existing cardiac disease[49,50,53,54]. An initial slow rate of insufflation especially at the beginning of the procedure could minimise such events. IAP > 12 mmHg is considered intra-abdominal hypertension with adverse effects on the cardio-respiratory system mainly due to diaphragmatic splinting and carbon dioxide-induced hypercarbia[52].

As a general rule, the lowest possible IAP should be maintained, and an IAP > 15 mmHg is very rarely required. Additionally, good abdominal wall relaxation could improve surgical view[50]. The patient's position could further exaggerate these adverse effects of pneumoperitoneum. For example, in the Trendelenburg position, pressure of viscera on the diaphragm can lead to a reduction in the functional residual capacity[50,51].

### ***Safe handling of the camera***

The camera is the eye of the surgeon! Compared to old low-resolution scopes, modern laparoscopes provide high-resolution images enabling the smooth performance of complex and delicate procedures[55,56]. The assistant holding the camera is responsible for providing a clear, focused image to the surgeon. It is important that the assistant knows operative steps and ideally also, the manoeuvres unique to each surgeon. Appropriate training and experience are key to this[57]. The camera is located at the tip of the scope with a fixed angle ranging from 0° to 70°[53], and some with flexible tip allow complete 0 to 180° visualization (LTF-V2 Deflectable Tip Laparoscope, Olympus America Inc., Melville, New York). The familiarity of these angles is important for assistants. Additionally, the camera holder must try to keep the surgical field in the centre of the screen with minimal turbulence.

Sharp instruments such as a diathermy hook and scissors should be followed with the camera during insertion and withdrawal to avoid any inadvertent injuries to the viscera. Before usage, white balancing should be done to achieve a digital image with true colours. White surfaces, such as clean swabs reflect the light enhancing the image, while dark surfaces such as blood, absorb the light and compromise the view. Therefore, the assistant must try to avoid blood-stained and reflective surfaces. The surgeon at the same time should attempt to keep the surgical field tidy. Fogging is a common problem in laparoscopy especially at the beginning of the procedure due to the temperature difference between cold scope and warm peritoneal cavity. Pre-warming with warm water[58-60] or liquid scope warmer (WarmORTM, The O.R. Company, Antioch, TN, United States), anti-fog solutions (FREDTM, United States Surgical, North Haven, CT) are some of the options available for preventing fog formation.

The high intensity of the light can generate significant heat at the tip of the laparoscope. This can burn the drapes and even skin of the patient if due care is not taken.



### ***Instruments in laparoscopy***

Correct selection and proper usage of laparoscopic instruments are vital for safe performance of laparoscopic surgery. Describing all laparoscopic instruments is out of the scope of this article. However, we would like to highlight some of the key aspects of commonly used instruments. Tissue graspers, laparoscopic scissors, clip applicators, needle holders, staplers, and suction devices are some of the commonly used instruments in laparoscopic practice. Choice of the instrument depends on multiple factors such as nature of the tissue (delicate *vs* tough), characteristics of the instrument (traumatic *vs* non-traumatic), expected function (dissection *vs* retraction). For example, tissue graspers can be traumatic or non-traumatic depending on the surface characteristics of the jaw blades of the force used by the surgeon. Maryland's forceps are a traumatic device, which should not be used to handle delicate structures such as the small or large intestine. Instead, Johan's non-traumatic forceps should be used for the bowel. It is worth bearing in mind that even atraumatic graspers can lead to tissue trauma if not handled gently. Similarly, Maryland's forceps are useful for blunt dissection and hold tissues (such as bleeding vessels) with their pointed tips. Sharp instruments such as laparoscopic scissors and diathermy hook should always be used under direct vision. Articulated instruments offer "robot-like dexterity" with an improved degree of freedom at lower cost[61,62]

### ***Special instruments***

Laparoscopic staplers of appropriate length and staple height should be used depending on the tissue[63-65]. Although modern tri-staplers are shown to be safe and robust, utmost care should be exercised with attention to detail[66,67]. The surgeon needs to be familiar with the type of stapler they are using, and also have good working knowledge of different type of cartridges. Before firing a stapler in Upper Gastro-Intestinal (UGI) surgery, a routine check and communication with the anaesthetist are mandatory to avoid inadvertently catching the orogastric tube or temperature probe, or nasogastric tube within the stapler. All of these have been reported as never events[68]. Routine use of nasogastric tubes and temperature probes should be avoided, especially in UGI surgery.

Powered staplers and flexible stapler devices (ECHELON FLEXTM, Johnson and Johnson, United States) have also shown some promising results in laparoscopic surgery[69,70]. For most operative procedures (including most bariatric surgery) standard length instruments are adequate. However extra-long instruments may be needed in some patients with severe obesity[71]. Surgical procedures requiring access to gastro-oesophageal junction such as hiatal hernia repair or bariatric surgery require a liver retractor. Different types are available and can be used based on the surgeon's preference and availability (Nathanson Liver Retraction System, Cook® Medical, United States and PretzelFlex Surgical Retraction System, Surgical Innovations, United Kingdom). However, utmost care is required to avoid tissue injury especially to the liver[27,72,73]. Laparoscopic ultrasound, yet another useful tool especially in hepatopancreatic and biliary operations can be helpful to localise lesions and reduced the incidence of complications[74-76]. More recently, use of Indocyanine Green for fluorescence-guided laparoscopic surgery has shown some initial promising results in hepatobiliary surgery, colorectal surgery, and surgical oncology. It can be useful in tumour localisation, lymph node mapping, and intra-operative angiography as well as cholangiography[77-79]. However, the protocols and technique need to be standardised and validated with further research.

### ***Energy devices in laparoscopy***

Modern energy devices have facilitated the progress and development of laparoscopic surgery. Monopolar diathermy is the most basic energy device used in current practice utilised commonly for tissue dissection and haemostasis through hook or Maryland's forceps. Compared to other devices, monopolar diathermy is known to cause significant lateral thermal spread, which requires cautious application close to delicate structures such as the bowel[80,81]. Additionally, inadvertent injuries due to cracked insulation, capacitance coupling due to the usage of metal or hybrid ports are other complications associated with monopolar diathermy[82-84]. Regular inspection and usage of plastic ports are effective means of preventing these potentially disastrous complications. The authors recommend avoiding metal ports for this reason. Surgeons or other team members can also accidentally step on the cutting pedal during the procedure as pedals are on the floor and often hidden under the drapes. We recommend reducing the default cutting setting down to zero as it is rarely needed during routine laparoscopic surgery.

Bipolar diathermy is often a safe alternative when monopolar diathermy is risky *e.g.* close to delicate tissues due to minimal lateral thermal spread or is contraindicated *e.g.* patients with cardiac pacemakers[74]. Several advanced energy devices are available and utilise different technology[80,85]. LigasureTM (Medtronic Technologies, Dublin, Ireland) uses bipolar energy with pressure to seal blood vessels up to 7 mm. HarmonicTM (Ethicon technologies, Raritan, NJ, United States), and SonoSurgTM (Olympus Technologies, Tokyo, Japan), use high-frequency ultrasonic waves to generate heat, thereby causing tissue coagulation and dissection with significantly lower lateral thermal spread compared to monopolar devices[80]. These devices can be safely used even in patients with cardiac pacemakers, in whom monopolar diathermy is contraindicated[86]. During usage, the active blade of these devices should be kept under direct vision to prevent any inadvertent injury to underlying tissues. Studies demonstrate heat at the tip of the device can lead to temperatures as high as > 100 °C and can last up to 20 s after usage[87]. Therefore, tip contact with vulnerable tissues should be avoided immediately after usage and surgeons should allow some time for it to cool down before using again. ThunderbeatTM (Olympus Technologies, Tokyo, Japan) is another device that combines both high-frequency ultrasonic waves and bipolar diathermy, which allows tissue dissection as well as sealing of vessels up to 7 mm[88]. Energy devices related burns may not be immediately apparent and result in late perforations with disastrous consequences[89,90].

### ***Tissue dissection in laparoscopy***

Tissue dissection in laparoscopy can be a challenging task even for experienced surgeons due to a relative lack of haptic feedback. Laparoscopic scissors are often used for sharp dissection, whilst advanced energy devices could be used where tissues are expected to bleed. Pointed tip devices such as Maryland's forceps are useful to open-up the tissue planes. Suction devices or laparoscopic pledgets can also be used to create tissue planes[91].

### ***Haemostasis in laparoscopy***

Any discrete bleeding vessel should be identified, isolated, and properly controlled before proceeding to the next step of the procedure. Diathermy is the most frequently used modality for haemostasis and is advocated for a capillary-sized vessel. Laparoscopic clips or Hem-o-lok® (Teleflex®, Morrisville, NC, United States) ligating clips are indicated for defined, named vessels. For larger vessels such as a splenic artery or ileocolic pedicle, we suggest using either locking clips *e.g.*, Hem-o-lok® (Teleflex®, Morrisville, NC, United States) or vascular staplers (1.0 mm to 2.0 mm Endo GIATM, Medtronic, Minneapolis, United States, and Ethicon, Johnson & Johnson Medical, Belgium).

Bleeding from raw or inflamed tissue *e.g.*, liver bed after a difficult cholecystectomy or pelvis during rectal resection can be difficult to control[91-93]. These can sometimes be controlled with topical haemostatic agents such as gelatins, collagens, thrombin, and fibrin sealants (BioGlue®, Cryolife Inc., Kennesaw, GA, United States), and synthetic glues[94,95]. Some of these agents *e.g.*, Surgicel (Ethicon, Johnson & Johnson Medical, Belgium) can cause an intense inflammatory reaction, and lead to the formation of an abscess[96-99]. Occasionally, ligating or transfixing the pedicle with sutures provides the most secure control. We believe all laparoscopic surgeons should be able to carry out laparoscopic suturing. All energy devices can cause injury to nearby structures due to lateral thermal spread and as such, it is vital to keep the instrument completely under vision during use[80,85]. Once metal clips are applied, further diathermy should be avoided as it causes shrinkage of tissues underneath with subsequent loosening and slippage of the clip, and the metal clip could lead to the spread of the diathermy current to adjacent tissue causing thermal injury[82,83,100].

### ***Laparoscopic suturing and anchoring***

Laparoscopic suturing is an essential skill for all laparoscopic surgeons. Selection of correct needle size, length of the suture, proper handling of the needle at various angles are vital considerations for safe laparoscopic suturing. Additionally, pre-prepared laparoscopic knots with loops (ENDOLOOP®, Johnson & Johnson Medical, Belgium) are commercially available as a quick option for certain procedures as laparoscopic appendicectomy. Specific anchoring devices (such as ProTackTM, Medtronic Ltd., United Kingdom, and Securestrap®, Johnson and Johnson Medical, Belgium) can be used for mesh fixation during a laparoscopic hernia repair. However, they can be associated with complications such as chronic pain or erosions[101,102]. More recently, absorbable tackers have been introduced in an attempt to reduce the

odds of these complications (AbsorbaTack™, Medtronic Ltd., United Kingdom).

### **Timeouts during the procedure and second opinion**

Laparoscopic surgery can be physically and mentally demanding for the surgeon and could easily lead to fatigue and errors[103,104]. We recommend short breaks during long or difficult procedures for the whole team. If the operation is not progressing as expected, a second opinion from an experienced colleague could be invaluable[105]. Surgeons should not regard conversion as a failure.

### **Final check**

Towards the end of the procedure, surgeons should ensure adequate haemostasis and check for any inadvertent bowel injury. We also recommend ensuring adequate blood pressure and reducing the pressure while checking for haemostasis. A haemostasis check with low blood pressure and high-pressure pneumoperitoneum may be falsely reassuring.

Surgeons should consider closing all internal defects and 15 mm port sites. Most 10-12 mm port sites should also be closed except in patients with severe obesity where many surgeons do not recommend closing blunt 10-12mm port sites especially when ports have been angled during placement[106,107]. After the withdrawal of ports, all port sites should be checked for bleeding and adequate haemostasis must be ensured. Surgeons should finally check the operating count with nurses and do a proper "time out" to ensure all planned procedures have been performed. The operating count should include surgical specimens and specimen retrieval bags as it is not uncommon during laparoscopic surgery for surgeons to leave a specimen/retrieval bag intraabdominally during the surgery for later removal[11]. At the end of the procedure, we recommend a mental pause for the surgeon to reflect on the procedure – especially consider if all planned procedures have been performed; all foreign bodies such as tonsil swabs, retrieval bags, removed previously placed foreign bodies such as gastric bands, and specimens have been removed; and all ports that needed closing have been closed.

---

## **POST-OPERATIVE CONSIDERATIONS**

---

Laparoscopic surgery has transformed post-operative care and reduced the length of in-hospital stay to the extent that many surgical procedures can be undertaken as day cases[108,109]. This is probably because of minimal physiological disturbances and stress with laparoscopy[110]. Early discharge is beneficial for patients and should be routine after in-hospital care is no longer needed.

### **Analgesia**

Pain management plays a vital role in recovery post-laparoscopy as in any other type of surgery. We recommend effective multi-modal analgesia[111] following any laparoscopic surgery including the infiltration of long-acting local anaesthetic agents at port sites. Deep breathing exercises and chest physiotherapy can reduce respiratory complications[112].

### **Thromboprophylaxis**

Appropriate thromboprophylaxis is crucial for laparoscopic surgery because of the higher IAP[113]. A recent study by our group identified failure to prescribe the correct thromboprophylaxis as one of the commonest serious clinical incidents after bariatric surgery[11]. A combination of mechanical and pharmacological thromboprophylaxis should be used. We recommend continuing to use the calf compression devices in the immediate post-operative period till the patient is ambulatory, and compression stockings even after discharge till the patient has resumed near-normal levels of mobility. Low molecular weight heparin is an effective pharmacological thromboprophylaxis usually started preoperatively and continued for variable duration post-operatively for those at highest risk.

### **Enhanced recovery after surgery**

We would strongly advocate incorporating an Enhanced Recovery After Surgery (ERAS) programme[114-116]. For certain specialties and procedures, separate ERAS protocols have been developed[117-120].

**Table 1 Summary of various safety considerations throughout the patient journey when undergoing a laparoscopic procedure**

Stage of surgery	Safety considerations	
Pre-operative	Patient selection	Rule out pregnancy for elective procedures in women of child bearing age group
		Optimisation of risk factors
	Procedure selection	Elective surgery
		Emergency general surgery
		Abdominal trauma
Intra-operative	Pre-operative investigations	Supplementary procedures ( <i>e.g.</i> , endoscopic tattooing)
		Review of radiological investigations
	Before start	Effective communication and surgical check list
		Ensure correct patient, correct procedure, correct site
		Consider allergies, antibiotic prophylaxis, DVT prophylaxis, and glycaemic control
		Safe and appropriate patient positioning
		Ensure comfortable and effective laparoscopy set-up
		Safe pneumoperitoneum and ergonomically favourable port positioning
		Use lowest possible pneumoperitoneum pressure
	During surgery	Accurate selection and handling of instruments ( <i>e.g.</i> , camera, energy devices)
		Meticulous tissue dissection and haemostasis
		Regular evaluation of operative steps
		Low threshold for seeking second opinion
		Check for haemostasis with reduced intra-abdominal pressure and adequate blood pressure
Post-operative	Early recovery	Proper closure of port sites
		Multimodal analgesia
		Thromboprophylaxis
		Clear plan for oral intake and patient's routine medications
	Complications	Use Enhanced Recovery Protocols for elective surgery
		Early recognition of warning signs and prompt intervention
		Tachycardia not reliable as an early warning sign for patients on Beta blockers
	Discharge advices	Appropriate training of nursing staff and early escalation. Use Early Warning Scores
		Clear discharge documentation for patient and their primary care doctor
		Patient education on complications and anticipated recovery times

DVT: Deep vein thrombosis.

### **Management of diabetes**

Poor perioperative glycaemic control is shown to be associated with increased infection rate and mortality across many surgical specialties[121-123]. Therefore, it is highly recommended to have a strict policy for peri-operative glycaemic control, especially in patients on insulin[124].

### **Patient's routine medications**

Many patients admitted for elective surgery may be on regular medications for a variety of medical conditions, which may need to be withheld peri-operatively. Incorrect management of patients' regular medications[12] can lead to avoidable harm [125]. Close collaboration with physicians, pharmacists, and specialist nurses can help. For medications that are commonly omitted perioperatively such as antiplatelets and anticoagulants, it is good practice to have clear local perioperative guidelines/ protocols, to minimise errors. Surgeons should clearly document when these can be



restarted safely after surgery and in what dosages in their operation notes. It is equally important to ensure patients' regular medications such as antihypertensives are prescribed correctly especially in the post-operative period. A thorough review by a pharmacist at pre-assessment and/or on the ward after surgery can help prevent these errors.

### Post-operative complications and management

It is important to ensure that the junior doctors and nursing staff are appropriately trained to identify a complication early. Tachycardia is often the first sign of an unwell patients. However, its limitations as an early warning sign in patients who are on Beta-blockers should be understood. Shoulder tip pain and port site pain are frequently reported after laparoscopic surgery. Diaphragmatic irritation due to retained carbon dioxide can trigger referred pain to shoulders, which can last up to a few days post-operatively[126-128].

Overall, laparoscopic surgery is associated with reduced abdominal pain and discomfort. Surgical teams should take excessive pain and regular use of opiate analgesia more than 24 h after surgery seriously. Such a patient could be developing an early complication such as bowel perforation or bile leak after cholecystectomy and a Computed Tomography scan may be falsely negative[129]. We recommend having a low threshold for re-laparoscopy.

### Discharge advice

Surgical teams should provide clear information to patients and their carers about the expected recovery times after surgery. They should also be advised regarding warning symptoms and who to contact in such cases. This is crucial as laparoscopy has reduced the length of stay in the hospital, and patients will usually be home when complications develop. Unwell patients should have rapid access to senior surgical input during the early postoperative period.

## CONCLUSION

This review presents some of the key considerations in the safe performance of laparoscopic surgery. We have attempted to summarise them in Table 1 for readers. Many of our recommendations are based on experience and need to be examined scientifically. There is also a need for consensus-building amongst experts in this crucial area of patient safety.

## REFERENCES

- 1 **Kang SB**, Park JW, Jeong SY, Nam BH, Choi HS, Kim DW, Lim SB, Lee TG, Kim DY, Kim JS, Chang HJ, Lee HS, Kim SY, Jung KH, Hong YS, Kim JH, Sohn DK, Kim DH, Oh JH. Open versus laparoscopic surgery for mid or low rectal cancer after neoadjuvant chemoradiotherapy (COREAN trial): short-term outcomes of an open-label randomised controlled trial. *Lancet Oncol* 2010; **11**: 637-645 [PMID: 20610322 DOI: 10.1016/S1470-2045(10)70131-5]
- 2 **Scaletta G**, Dinoi G, Capozzi V, Cianci S, Pelligra S, Ergasti R, Fagotti A, Scambia G, Fanfani F. Comparison of minimally invasive surgery with laparotomic approach in the treatment of high risk endometrial cancer: A systematic review. *Eur J Surg Oncol* 2020; **46**: 782-788 [PMID: 31818527 DOI: 10.1016/j.ejso.2019.11.519]
- 3 **Hewett PJ**, Allardye RA, Bagshaw PF, Frampton CM, Frizelle FA, Rieger NA, Smith JS, Solomon MJ, Stephens JH, Stevenson AR. Short-term outcomes of the Australasian randomized clinical study comparing laparoscopic and conventional open surgical treatments for colon cancer: the ALCCaS trial. *Ann Surg* 2008; **248**: 728-738 [PMID: 18948799 DOI: 10.1097/SLA.0b013e31818b7595]
- 4 **Alkatout I**. Complications of Laparoscopy in Connection with Entry Techniques. *J Gynecol Surg* 2017; **33**: 81-91 [PMID: 28663686 DOI: 10.1089/gyn.2016.0111]
- 5 **Litynski GS**. Kurt Semm and the fight against skepticism: endoscopic hemostasis, laparoscopic appendectomy, and Semm's impact on the "laparoscopic revolution". *JSLS* 1998; **2**: 309-313 [PMID: 9876762]
- 6 **Antoniou SA**, Antoniou GA, Antoniou AI, Granderath FA. Past, Present, and Future of Minimally Invasive Abdominal Surgery. *JSLS* 2015; **19** [PMID: 26508823 DOI: 10.4293/JSLS.2015.00052]
- 7 **Olsen DO**. Bile duct injuries during laparoscopic cholecystectomy: a decade of experience. *J Hepatobiliary Pancreat Surg* 2000; **7**: 35-39 [PMID: 10982589 DOI: 10.1007/s005340050151]
- 8 **Chandio A**, Timmons S, Majeed A, Twomey A, Aftab F. Factors influencing the successful completion of laparoscopic cholecystectomy. *JSLS* 2009; **13**: 581-586 [PMID: 20202401 DOI: 10.4293/108680809X1258998404560]

- 9 **Neto RML**, Herbella FAM. Preoperative workup, patient selection, surgical technique and follow-up for a successful laparoscopic Nissen fundoplication. *Mini-invasive Sur* 2017; **1**: 6-11 [DOI: [10.20517/2574-1225.2016.04](https://doi.org/10.20517/2574-1225.2016.04)]
- 10 **Joris JL**, Chiche JD, Canivet JL, Jacquet NJ, Legros JJ, Lamy ML. Hemodynamic changes induced by laparoscopy and their endocrine correlates: effects of clonidine. *J Am Coll Cardiol* 1998; **32**: 1389-1396 [PMID: [9809953](https://pubmed.ncbi.nlm.nih.gov/9809953/) DOI: [10.1016/s0735-1097\(98\)00406-9](https://doi.org/10.1016/s0735-1097(98)00406-9)]
- 11 **Omar I**, Graham Y, Singhal R, Wilson M, Madhok B, Mahawar KK. Identification of Common Themes from Never Events Data Published by NHS England. *World J Surg* 2021; **45**: 697-704 [PMID: [33216170](https://pubmed.ncbi.nlm.nih.gov/33216170/) DOI: [10.1007/s00268-020-05867-7](https://doi.org/10.1007/s00268-020-05867-7)]
- 12 **NICE**. Tests before surgery. [cited 10 January 2021]. Available from: <https://www.nice.org.uk/guidance/ng45/resources/tests-before-surgery-pdf-3141108622789>
- 13 **Salman MA**, Qassem MG, Aboul-Enein MS, A Ameen M, Abdallah A, Omar H, Hussein AM, Tourky MS, Monazea K, M Hassan A, Salman A, Moustafa A, Shaaban HE, Soliman A, Sarhan MD. Effect of preoperative diet regimen on liver size before laparoscopic sleeve gastrectomy in morbidly obese patients. *Surg Endosc* 2021 [PMID: [34231075](https://pubmed.ncbi.nlm.nih.gov/34231075/) DOI: [10.1007/s00464-021-08592-x](https://doi.org/10.1007/s00464-021-08592-x)]
- 14 **Li WK**, Ma FH, Liu H, Li Y, Ma S, Kang WZ, Zhong YX, Xie YB, Tian YT. [Comparison of short-term clinical outcome between laparoscopic distal pancreatectomy and open distal pancreatectomy]. *Zhonghua Zhong Liu Za Zhi* 2020; **42**: 495-500 [PMID: [32575947](https://pubmed.ncbi.nlm.nih.gov/32575947/) DOI: [10.3760/cma.j.cn112152-20190627-00398](https://doi.org/10.3760/cma.j.cn112152-20190627-00398)]
- 15 **Ziogas IA**, Esagian SM, Giannis D, Hayat MH, Kosmidis D, Matsuka LK, Montenegro MI, Tsoulfas G, Geller DA, Alexopoulos SP. Laparoscopic versus open hepatectomy for intrahepatic cholangiocarcinoma: An individual patient data survival meta-analysis. *Am J Surg* 2021; **222**: 731-738 [PMID: [33840443](https://pubmed.ncbi.nlm.nih.gov/33840443/) DOI: [10.1016/j.amjsurg.2021.03.052](https://doi.org/10.1016/j.amjsurg.2021.03.052)]
- 16 **Lyu Y**, Cheng Y, Wang B, Zhao S, Chen L. Assessment of laparoscopic vs open distal pancreatectomy: a systematic review and meta-analysis. *Minim Invasive Ther Allied Technol* 2020; **1-9** [DOI: [10.1080/13645706.2020.1812664](https://doi.org/10.1080/13645706.2020.1812664)]
- 17 **Panin SI**, Beburishvili AG, Prudkov MI, Sovtsov SA, Timerbulatov VM, Bykov AV, Abdullaev EG, Khasanov AG, Nishnevich EV, Fedorov AV. [Open and laparoscopic surgery via minimally invasive approach in the treatment of perforated ulcer: a systematic review and metaanalysis]. *Khirurgiia (Mosk)* 2021; **94**: 94-100 [PMID: [33570362](https://pubmed.ncbi.nlm.nih.gov/33570362/) DOI: [10.17116/hirurgia202102194](https://doi.org/10.17116/hirurgia202102194)]
- 18 **Azin A**, Hirpara D, Jackson T, Okrainec A, Elnahas A, Chadi SA, Queresy FA. Emergency laparoscopic and open repair of incarcerated ventral hernias: a multi-institutional comparative analysis with coarsened exact matching. *Surg Endosc* 2019; **33**: 2812-2820 [PMID: [30421078](https://pubmed.ncbi.nlm.nih.gov/30421078/) DOI: [10.1007/s00464-018-6573-6](https://doi.org/10.1007/s00464-018-6573-6)]
- 19 **Ki YJ**, Jo YG, Park YC, Kang WS. The Efficacy and Safety of Laparoscopy for Blunt Abdominal Trauma: A Systematic Review and Meta-Analysis. *J Clin Med* 2021; **10** [PMID: [33923206](https://pubmed.ncbi.nlm.nih.gov/33923206/) DOI: [10.3390/jcm10091853](https://doi.org/10.3390/jcm10091853)]
- 20 **Buiset C**, Mazeaud C, Postillon A, Nominé-Criqui C, Fouquet T, Reibel N, Brunaud L, Perez M. Evaluation of diagnostic laparoscopy for penetrating abdominal injuries: About 131 anterior abdominal stab wound. *Surg Endosc* 2021 [PMID: [34076764](https://pubmed.ncbi.nlm.nih.gov/34076764/) DOI: [10.1007/s00464-021-08566-z](https://doi.org/10.1007/s00464-021-08566-z)]
- 21 **Huang C**, Wang Q, Zhao M, Chen C, Pan S, Yuan M. Tactile Perception Technologies and Their Applications in Minimally Invasive Surgery: A Review. *Front Physiol* 2020; **11**: 611596 [PMID: [33424634](https://pubmed.ncbi.nlm.nih.gov/33424634/) DOI: [10.3389/fphys.2020.611596](https://doi.org/10.3389/fphys.2020.611596)]
- 22 **Arteaga-González I**, Martín-Malagón A, Fernández EM, Arranz-Durán J, Parra-Blanco A, Nicolas-Perez D, Quintero-Carrión E, Luis HD, Carrillo-Pallares A. The use of preoperative endoscopic tattooing in laparoscopic colorectal cancer surgery for endoscopically advanced tumors: a prospective comparative clinical study. *World J Surg* 2006; **30**: 605-611 [PMID: [16555023](https://pubmed.ncbi.nlm.nih.gov/16555023/) DOI: [10.1007/s00268-005-0473-3](https://doi.org/10.1007/s00268-005-0473-3)]
- 23 **Feingold DL**, Addona T, Forde KA, Arnell TD, Carter JJ, Huang EH, Whelan RL. Safety and reliability of tattooing colorectal neoplasms prior to laparoscopic resection. *J Gastrointest Surg* 2004; **8**: 543-546 [PMID: [15239988](https://pubmed.ncbi.nlm.nih.gov/15239988/) DOI: [10.1016/j.gassur.2003.12.016](https://doi.org/10.1016/j.gassur.2003.12.016)]
- 24 **Haynes AB**, Weiser TG, Berry WR, Lipsitz SR, Breizat AH, Dellinger EP, Herbosa T, Joseph S, Kibatala PL, Lapitan MC, Merry AF, Moorthy K, Reznick RK, Taylor B, Gawande AA; Safe Surgery Saves Lives Study Group. A surgical safety checklist to reduce morbidity and mortality in a global population. *N Engl J Med* 2009; **360**: 491-499 [PMID: [19144931](https://pubmed.ncbi.nlm.nih.gov/19144931/) DOI: [10.1056/NEJMs0810119](https://doi.org/10.1056/NEJMs0810119)]
- 25 **Winfree CJ**, Kline DG. Intraoperative positioning nerve injuries. *Surg Neurol* 2005; **63**: 5-18; discussion 18 [PMID: [15639509](https://pubmed.ncbi.nlm.nih.gov/15639509/) DOI: [10.1016/j.surneu.2004.03.024](https://doi.org/10.1016/j.surneu.2004.03.024)]
- 26 **American Society of Anesthesiologists Task Force on Prevention of Perioperative Peripheral Neuropathies**. Practice advisory for the prevention of perioperative peripheral neuropathies: an updated report by the American Society of Anesthesiologists Task Force on prevention of perioperative peripheral neuropathies. *Anesthesiology* 2011; **114**: 741-754 [PMID: [21364463](https://pubmed.ncbi.nlm.nih.gov/21364463/) DOI: [10.1097/ALN.0b013e3181fcbf3](https://doi.org/10.1097/ALN.0b013e3181fcbf3)]
- 27 **Tamhankar AP**, Keltly CJ, Jacob G. Retraction-related liver lobe necrosis after laparoscopic gastric surgery. *JSLs* 2011; **15**: 117-121 [PMID: [21902957](https://pubmed.ncbi.nlm.nih.gov/21902957/) DOI: [10.4293/108680811X13022985131651](https://doi.org/10.4293/108680811X13022985131651)]
- 28 **Barry J**. The HoverMatt system for patient transfer: enhancing productivity, efficiency, and safety. *J Nurs Adm* 2006; **36**: 114-117 [PMID: [16601512](https://pubmed.ncbi.nlm.nih.gov/16601512/) DOI: [10.1097/00005110-200603000-00003](https://doi.org/10.1097/00005110-200603000-00003)]
- 29 **Stomberg MW**, Tronstad SE, Hedberg K, Bengtsson J, Jonsson P, Johansen L, Lindvall B. Work-related musculoskeletal disorders when performing laparoscopic surgery. *Surg Laparosc Endosc*

- Percutan Tech* 2010; **20**: 49-53 [PMID: 20173622 DOI: 10.1097/SLE.0b013e3181ceded54]
- 30 **Meng WC**, Kwok SP, Leung KL, Chung CC, Lau WY, Li AK. Optimal position of working ports in laparoscopic surgery: an in vitro study. *Surg Laparosc Endosc* 1996; **6**: 278-281 [PMID: 8840449]
  - 31 **Haveran LA**, Novitsky YW, Czerniach DR, Kaban GK, Taylor M, Gallagher-Dorval K, Schmidt R, Kelly JJ, Litwin DE. Optimizing laparoscopic task efficiency: the role of camera and monitor positions. *Surg Endosc* 2007; **21**: 980-984 [PMID: 17436042 DOI: 10.1007/s00464-007-9360-3]
  - 32 **Bauer W**, Wittig T. Influence of screen and copy holder positions on head posture, muscle activity and user judgement. *Appl Ergon* 1998; **29**: 185-192 [PMID: 9676335 DOI: 10.1016/s0003-6870(97)00060-4]
  - 33 **Seghers J**, Jochem A, Spaepen A. Posture, muscle activity and muscle fatigue in prolonged VDT work at different screen height settings. *Ergonomics* 2003; **46**: 714-730 [PMID: 12745683 DOI: 10.1080/0014013031000090107]
  - 34 **KARL STORZ ORITM Operating Rooms**. Now Assisting the Surgical Team at Spital Thun, Switzerland|KARL STORZ Endoskope|United Kingdom. [cited 10 January 2021]. Available from: <https://www.karlstorz.com/gb/en/14295.htm>
  - 35 **Mari GM**, Crippa J, Achilli P, Miranda A, Santurro L, Riggio V, Gerosa M, Ascheri P, Cordaro G, Costanzi ATM, Maggioni D. 4K ultra HD technology reduces operative time and intraoperative blood loss in colorectal laparoscopic surgery. *F1000Res* 2020; **9**: 106 [PMID: 32789007 DOI: 10.12688/f1000research.21297.1]
  - 36 **Wenzl R**, Pateisky N, Husslein P. [First use of a 3D video-endoscope in gynecology]. *Geburtshilfe Frauenheilkd* 1993; **53**: 776-778 [PMID: 8293943 DOI: 10.1055/s-2007-1023725]
  - 37 **Parshad R**, Nanjakla Jayappa S, Bhattacharjee HK, Suhani S, Joshi MK, Bhoi D, Kashyap L. Comparison of three-dimensional (3D) endovision system versus ultra-high-definition 4K endovision system in minimally invasive surgical procedures: a randomized-open label pilot study. *Surg Endosc* 2021 [PMID: 33638108 DOI: 10.1007/s00464-021-08377-2]
  - 38 **Arezzo A**, Vettoretto N, Francis NK, Bonino MA, Curtis NJ, Amparore D, Arolfo S, Barberio M, Boni L, Brodie R, Bouvy N, Cassinotti E, Carus T, Checcucci E, Custers P, Diana M, Jansen M, Jaspers J, Marom G, Momose K, Müller-Stich BP, Nakajima K, Nickel F, Perretta S, Porpiglia F, Sánchez-Margallo F, Sánchez-Margallo JA, Schijven M, Silecchia G, Passera R, Mintz Y. The use of 3D laparoscopic imaging systems in surgery: EAES consensus development conference 2018. *Surg Endosc* 2019; **33**: 3251-3274 [PMID: 30515610 DOI: 10.1007/s00464-018-06612-x]
  - 39 **Alaraimi B**, El Bakbak W, Sarker S, Makkiyah S, Al-Marzouq A, Goriparthi R, Bouhelal A, Quan V, Patel B. A randomized prospective study comparing acquisition of laparoscopic skills in three-dimensional (3D) vs. two-dimensional (2D) laparoscopy. *World J Surg* 2014; **38**: 2746-2752 [PMID: 25002241 DOI: 10.1007/s00268-014-2674-0]
  - 40 **Hasson HM**. A modified instrument and method for laparoscopy. *Am J Obstet Gynecol* 1971; **110**: 886-887 [PMID: 4254516 DOI: 10.1016/0002-9378(71)90593-x]
  - 41 **Palmer R**. Safety in laparoscopy. *J Reprod Med* 1974; **13**: 1-5 [PMID: 4276707]
  - 42 **Ahmad G**, Baker J, Finnerty J, Phillips K, Watson A. Laparoscopic entry techniques. *Cochrane Database Syst Rev* 2019; **1**: CD006583 [PMID: 30657163 DOI: 10.1002/14651858.CD006583.pub5]
  - 43 **Vilos GA**, Ternamian A, Dempster J, Laberge PY; CLINICAL PRACTICE GYNAECOLOGY COMMITTEE. Laparoscopic entry: a review of techniques, technologies, and complications. *J Obstet Gynaecol Can* 2007; **29**: 433-447 [PMID: 17493376 DOI: 10.1016/S1701-2163(16)35496-2]
  - 44 **Chang FH**, Lee CL, Soong YK. Use of Palmer's Point for Insertion of the Operative Laparoscope in Patients with Severe Pelvic Adhesions: Experience of Seventeen Cases. *J Am Assoc Gynecol Laparosc* 1994; **1**: S7 [PMID: 9073666 DOI: 10.1016/s1074-3804(05)80888-6]
  - 45 **Geraci G**, Sciume C, Pisello F, Li Volsi F, Facella T, Modica G. Trocar-related abdominal wall bleeding in 200 patients after laparoscopic cholecistectomy: Personal experience. *World J Gastroenterol* 2006; **12**: 7165-7167 [PMID: 17131480 DOI: 10.3748/wjg.v12.i44.7165]
  - 46 **Lee VS**, Chari RS, Cucchiario G, Meyers WC. Complications of laparoscopic cholecystectomy. *Am J Surg* 1993; **165**: 527-532 [PMID: 8480896 DOI: 10.1016/s0002-9610(05)80955-9]
  - 47 **Antoniou SA**, Antoniou GA, Koch OO, Pointner R, Granderath FA. Blunt vs bladed trocars in laparoscopic surgery: a systematic review and meta-analysis of randomized trials. *Surg Endosc* 2013; **27**: 2312-2320 [DOI: 10.1007/s00464-013-2793-y]
  - 48 **Supe AN**, Kulkarni GV, Supé PA. Ergonomics in laparoscopic surgery. *J Minim Access Surg* 2010; **6**: 31-36 [PMID: 20814508 DOI: 10.4103/0972-9941.65161]
  - 49 **Harris SN**, Ballantyne GH, Luther MA, Perrino AC Jr. Alterations of cardiovascular performance during laparoscopic colectomy: a combined hemodynamic and echocardiographic analysis. *Anesth Analg* 1996; **83**: 482-487 [PMID: 8780267 DOI: 10.1097/00000539-199609000-00007]
  - 50 **Hein HA**, Joshi GP, Ramsay MA, Fox LG, Gawey BJ, Hellman CL, Arnold JC. Hemodynamic changes during laparoscopic cholecystectomy in patients with severe cardiac disease. *J Clin Anesth* 1997; **9**: 261-265 [PMID: 9195345 DOI: 10.1016/s0952-8180(97)00001-9]
  - 51 **McLaughlin JG**, Scheeres DE, Dean RJ, Bonnell BW. The adverse hemodynamic effects of laparoscopic cholecystectomy. *Surg Endosc* 1995; **9**: 121-124 [PMID: 7597577 DOI: 10.1007/BF00191950]
  - 52 **Kyle EB**, Maheux-Lacroix S, Boutin A, Laberge PY, Lemyre M. Low vs Standard Pressures in Gynecologic Laparoscopy: a Systematic Review. *JSLS* 2016; **20** [PMID: 26955258 DOI: 10.4293/JSLS.2015.00113]

- 53 **Kelman GR**, Swapp GH, Smith I, Benzie RJ, Gordon NL. Cardiac output and arterial blood-gas tension during laparoscopy. *Br J Anaesth* 1972; **44**: 1155-1162 [PMID: [4265051](#) DOI: [10.1093/bja/44.11.1155](#)]
- 54 **Staehr-Rye AK**, Rasmussen LS, Rosenberg J, Juul P, Lindekaer AL, Riber C, Gätke MR. Surgical space conditions during low-pressure laparoscopic cholecystectomy with deep versus moderate neuromuscular blockade: a randomized clinical study. *Anesth Analg* 2014; **119**: 1084-1092 [PMID: [24977638](#) DOI: [10.1213/ANE.0000000000000316](#)]
- 55 **Harada H**, Kanaji S, Hasegawa H, Yamamoto M, Matsuda Y, Yamashita K, Matsuda T, Oshikiri T, Sumi Y, Nakamura T, Suzuki S, Kakeji Y. The effect on surgical skills of expert surgeons using 3D/HD and 2D/4K resolution monitors in laparoscopic phantom tasks. *Surg Endosc* 2018; **32**: 4228-4234 [PMID: [29603005](#) DOI: [10.1007/s00464-018-6169-1](#)]
- 56 **Rigante M**, La Rocca G, Lauretti L, D'Alessandris GQ, Mangiola A, Anile C, Olivi A, Paludetti G. Preliminary experience with 4K ultra-high definition endoscope: analysis of pros and cons in skull base surgery. *Acta Otorhinolaryngol Ital* 2017; **37**: 237-241 [PMID: [28516968](#) DOI: [10.14639/0392-100X-1684](#)]
- 57 **Chiu A**, Bowne WB, Sookraj KA, Zenilman ME, Fingerhut A, Ferzli GS. The role of the assistant in laparoscopic surgery: important considerations for the apprentice-in-training. *Surg Innov* 2008; **15**: 229-236 [PMID: [18757384](#) DOI: [10.1177/1553350608323061](#)]
- 58 **Klein MI**, Wheeler NJ, Craig C. Sideways camera rotations of 90° and 135° result in poorer performance of laparoscopic tasks for novices. *Hum Factors* 2015; **57**: 246-261 [PMID: [25850156](#) DOI: [10.1177/0018720814553027](#)]
- 59 **Van Deurzen DF**, Mannaerts GH, Jakimowicz JJ, Cuschieri A. Prevention of lens condensation in laparoscopic surgery by lens heating with a thermos flask. *Surg Endosc* 2005; **19**: 299-300 [PMID: [15580442](#) DOI: [10.1007/s00464-004-8231-4](#)]
- 60 **Brown JA**, Inocencio MD, Sundaram CP. Use of a warming bath to prevent lens fogging during laparoscopy. *J Endourol* 2008; **22**: 2413-2414 [PMID: [19046081](#) DOI: [10.1089/end.2008.0212](#)]
- 61 **Anderson PL**, Lathrop RA, Webster RJ III. Robot-like dexterity without computers and motors: a review of hand-held laparoscopic instruments with wrist-like tip articulation. *Expert Rev Med Devices* 2016; **13**: 661-672 [PMID: [26808896](#) DOI: [10.1586/17434440.2016.1146585](#)]
- 62 **Riojas KE**, Anderson PL, Lathrop RA, Herrell SD, Rucker DC, Webster Iii RJ. A Hand-Held Non-Robotic Surgical Tool With a Wrist and an Elbow. *IEEE Trans Biomed Eng* 2019; **66**: 3176-3184 [PMID: [30835205](#) DOI: [10.1109/TBME.2019.2901751](#)]
- 63 **Huang R**, Gagner M. A Thickness Calibration Device Is Needed to Determine Staple Height and Avoid Leaks in Laparoscopic Sleeve Gastrectomy. *Obes Surg* 2015; **25**: 2360-2367 [PMID: [26024735](#) DOI: [10.1007/s11695-015-1705-8](#)]
- 64 **Rosenthal RJ**; International Sleeve Gastrectomy Expert Panel, Diaz AA, Arvidsson D, Baker RS, Basso N, Bellanger D, Boza C, El Mourad H, France M, Gagner M, Galvao-Neto M, Higa KD, Himpens J, Hutchinson CM, Jacobs M, Jorgensen JO, Jossart G, Lakdawala M, Nguyen NT, Nocca D, Prager G, Pomp A, Ramos AC, Rosenthal RJ, Shah S, Vix M, Wittgrove A, Zundel N. International Sleeve Gastrectomy Expert Panel Consensus Statement: best practice guidelines based on experience of >12,000 cases. *Surg Obes Relat Dis* 2012; **8**: 8-19 [PMID: [22248433](#) DOI: [10.1016/j.soard.2011.10.019](#)]
- 65 **Lundvall E**, Ottosson J, Stenberg E. The influence of staple height on postoperative complication rates after laparoscopic gastric bypass surgery using linear staplers. *Surg Obes Relat Dis* 2019; **15**: 404-408 [PMID: [30738736](#) DOI: [10.1016/j.soard.2019.01.017](#)]
- 66 **Scuderi V**, Troisi RI. Tissue management with tri-staple technology in major and minor laparoscopic liver resections. *Int Surg* 2014; **99**: 606-611 [PMID: [25216429](#) DOI: [10.9738/INTSURG-D-13-00101.1](#)]
- 67 **Deng DY**, Meng MV, Nguyen HT, Bellman GC, Stoller ML. Laparoscopic linear cutting stapler failure. *Urology* 2002; **60**: 415-9; discussion 419 [PMID: [12350475](#) DOI: [10.1016/s0090-4295\(02\)01778-8](#)]
- 68 **Omar I**, Madhok B, Parmar C, Khan O, Wilson M, Mahawar K. Analysis of National Bariatric Surgery Related Clinical Incidents: Lessons Learned and a Proposed Safety Checklist for Bariatric Surgery. *Obes Surg* 2021; **31**: 2729-2742 [PMID: [33675021](#) DOI: [10.1007/s11695-021-05330-z](#)]
- 69 **Roy S**, Yoo A, Yadalam S, Fegelman EJ, Kalsekar I, Johnston SS. Comparison of economic and clinical outcomes between patients undergoing laparoscopic bariatric surgery with powered versus manual endoscopic surgical staplers. *J Med Econ* 2017; **20**: 423-433 [PMID: [28270023](#) DOI: [10.1080/13696998.2017.1296453](#)]
- 70 **Miller DL**, Roy S, Kassis ES, Yadalam S, Ramisetty S, Johnston SS. Impact of Powered and Tissue-Specific Endoscopic Stapling Technology on Clinical and Economic Outcomes of Video-Assisted Thoracic Surgery Lobectomy Procedures: A Retrospective, Observational Study. *Adv Ther* 2018; **35**: 707-723 [PMID: [29663180](#) DOI: [10.1007/s12325-018-0679-z](#)]
- 71 **Carbonell AM**, Joels CS, Sing RF, Heniford BT. Laparoscopic gastric bypass surgery: equipment and necessary tools. *J Laparoendosc Adv Surg Tech A* 2003; **13**: 241-245 [PMID: [14561252](#) DOI: [10.1089/10926420332233566](#)]
- 72 **Midya S**, Ramus J, Hakim A, Jones G, Sampson M. Comparison of Two Types of Liver Retractors in Laparoscopic Roux-en-Y Gastric Bypass for Morbid Obesity. *Obes Surg* 2020; **30**: 233-237 [PMID: [31440956](#) DOI: [10.1007/s11695-019-04142-6](#)]
- 73 **Harikrishnan J**, Jackson P, Patel R, Najmaldin A. Segmental Liver Atrophy: A Complication of the



- Nathanson Retractor. *JSM Clin Case Rep* 2014; **2**: 1012 [DOI: [10.1002/ccr3.671](https://doi.org/10.1002/ccr3.671)]
- 74 **Hublet A**, Dili A, Lemaire J, Mansvelt B, Molle G, Bertrand C. Laparoscopic ultrasonography as a good alternative to intraoperative cholangiography (IOC) during laparoscopic cholecystectomy: results of prospective study. *Acta Chir Belg* 2009; **109**: 312-316 [PMID: [19943585](https://pubmed.ncbi.nlm.nih.gov/19943585/) DOI: [10.1080/00015458.2009.11680431](https://doi.org/10.1080/00015458.2009.11680431)]
- 75 **Olsen AK**, Bjerkeset OA. Laparoscopic ultrasound (LUS) in gastrointestinal surgery. *Eur J Ultrasound* 1999; **10**: 159-170 [PMID: [10586020](https://pubmed.ncbi.nlm.nih.gov/10586020/) DOI: [10.1016/s0929-8266\(99\)00053-1](https://doi.org/10.1016/s0929-8266(99)00053-1)]
- 76 **Buddingh KT**, Nieuwenhuijs VB, van Buuren L, Hulscher JB, de Jong JS, van Dam GM. Intraoperative assessment of biliary anatomy for prevention of bile duct injury: a review of current and future patient safety interventions. *Surg Endosc* 2011; **25**: 2449-2461 [PMID: [21487883](https://pubmed.ncbi.nlm.nih.gov/21487883/) DOI: [10.1007/s00464-011-1639-8](https://doi.org/10.1007/s00464-011-1639-8)]
- 77 **Lim SH**, Tan HTA, Shelat VG. Comparison of indocyanine green dye fluorescent cholangiography with intra-operative cholangiography in laparoscopic cholecystectomy: a meta-analysis. *Surg Endosc* 2021; **35**: 1511-1520 [PMID: [33398590](https://pubmed.ncbi.nlm.nih.gov/33398590/) DOI: [10.1007/s00464-020-08164-5](https://doi.org/10.1007/s00464-020-08164-5)]
- 78 **Son GM**, Ahn HM, Lee IY, Ha GW. Multifunctional Indocyanine Green Applications for Fluorescence-Guided Laparoscopic Colorectal Surgery. *Ann Coloproctol* 2021; **37**: 133-140 [PMID: [34102813](https://pubmed.ncbi.nlm.nih.gov/34102813/) DOI: [10.3393/ac.2021.05.07](https://doi.org/10.3393/ac.2021.05.07)]
- 79 **Felli E**, Ishizawa T, Cherkaoui Z, Diana M, Tripon S, Baumert TF, Schuster C, Pessaux P. Laparoscopic anatomical liver resection for malignancies using positive or negative staining technique with intraoperative indocyanine green-fluorescence imaging. *HPB (Oxford)* 2021; **23**: 1647-1655 [PMID: [34289953](https://pubmed.ncbi.nlm.nih.gov/34289953/) DOI: [10.1016/j.hpb.2021.05.006](https://doi.org/10.1016/j.hpb.2021.05.006)]
- 80 **Diamantis T**, Kontos M, Arvelakis A, Syroukis S, Koronarchis D, Papalois A, Agapitos E, Bastounis E, Lazaris AC. Comparison of monopolar electrocoagulation, bipolar electrocoagulation, Ultracision, and Ligasure. *Surg Today* 2006; **36**: 908-913 [PMID: [16998685](https://pubmed.ncbi.nlm.nih.gov/16998685/) DOI: [10.1007/s00595-006-3254-1](https://doi.org/10.1007/s00595-006-3254-1)]
- 81 **Chapron C**, Pierre F, Harchaoui Y, Lacroix S, Béguin S, Querleu D, Lansac J, Dubuisson JB. Gastrointestinal injuries during gynaecological laparoscopy. *Hum Reprod* 1999; **14**: 333-337 [PMID: [10099974](https://pubmed.ncbi.nlm.nih.gov/10099974/) DOI: [10.1093/humrep/14.2.333](https://doi.org/10.1093/humrep/14.2.333)]
- 82 **Vilos G**, Latendresse K, Gan BS. Electrophysical properties of electrosurgery and capacitive induced current. *Am J Surg* 2001; **182**: 222-225 [PMID: [11587681](https://pubmed.ncbi.nlm.nih.gov/11587681/) DOI: [10.1016/s0002-9610\(01\)00712-7](https://doi.org/10.1016/s0002-9610(01)00712-7)]
- 83 **Massarweh NN**, Cosgriff N, Slakey DP. Electrosurgery: history, principles, and current and future uses. *J Am Coll Surg* 2006; **202**: 520-530 [PMID: [16500257](https://pubmed.ncbi.nlm.nih.gov/16500257/) DOI: [10.1016/j.jamcollsurg.2005.11.017](https://doi.org/10.1016/j.jamcollsurg.2005.11.017)]
- 84 **Montero PN**, Robinson TN, Weaver JS, Stiegmann GV. Insulation failure in laparoscopic instruments. *Surg Endosc* 2010; **24**: 462-465 [PMID: [19572175](https://pubmed.ncbi.nlm.nih.gov/19572175/) DOI: [10.1007/s00464-009-0601-5](https://doi.org/10.1007/s00464-009-0601-5)]
- 85 **Harold KL**, Pollinger H, Matthews BD, Kercher KW, Sing RF, Heniford BT. Comparison of ultrasonic energy, bipolar thermal energy, and vascular clips for the hemostasis of small-, medium-, and large-sized arteries. *Surg Endosc* 2003; **17**: 1228-1230 [PMID: [12799888](https://pubmed.ncbi.nlm.nih.gov/12799888/) DOI: [10.1007/s00464-002-8833-7](https://doi.org/10.1007/s00464-002-8833-7)]
- 86 **American Society of Anesthesiologists**. Practice advisory for the perioperative management of patients with cardiac implantable electronic devices: pacemakers and implantable cardioverter-defibrillators: an updated report by the american society of anesthesiologists task force on perioperative management of patients with cardiac implantable electronic devices. *Anesthesiology* 2011; **114**: 247-261 [PMID: [21245737](https://pubmed.ncbi.nlm.nih.gov/21245737/) DOI: [10.1097/ALN.0b013e3181fbc7f6](https://doi.org/10.1097/ALN.0b013e3181fbc7f6)]
- 87 **Govekar HR**, Robinson TN, Stiegmann GV, McGreevy FT. Residual heat of laparoscopic energy devices: how long must the surgeon wait to touch additional tissue? *Surg Endosc* 2011; **25**: 3499-3502 [PMID: [21594739](https://pubmed.ncbi.nlm.nih.gov/21594739/) DOI: [10.1007/s00464-011-1742-x](https://doi.org/10.1007/s00464-011-1742-x)]
- 88 **Devassy R**, Hanif S, Krentel H, Verhoeven HC, la Roche LAT, De Wilde RL. Laparoscopic ultrasonic dissectors: technology update by a review of literature. *Med Devices (Auckl)* 2019; **12**: 1-7 [PMID: [30643470](https://pubmed.ncbi.nlm.nih.gov/30643470/) DOI: [10.2147/MDER.S113262](https://doi.org/10.2147/MDER.S113262)]
- 89 **Levy BS**, Soderstrom RM, Dail DH. Bowel injuries during laparoscopy. Gross anatomy and histology. *J Reprod Med* 1985; **30**: 168-172 [PMID: [3158738](https://pubmed.ncbi.nlm.nih.gov/3158738/)]
- 90 **Chapron C**, Querleu D, Bruhat MA, Madelenat P, Fernandez H, Pierre F, Dubuisson JB. Surgical complications of diagnostic and operative gynaecological laparoscopy: a series of 29,966 cases. *Hum Reprod* 1998; **13**: 867-872 [PMID: [9619539](https://pubmed.ncbi.nlm.nih.gov/9619539/) DOI: [10.1093/humrep/13.4.867](https://doi.org/10.1093/humrep/13.4.867)]
- 91 **Hussain A**. Difficult laparoscopic cholecystectomy: current evidence and strategies of management. *Surg Laparosc Endosc Percutan Tech* 2011; **21**: 211-217 [PMID: [21857467](https://pubmed.ncbi.nlm.nih.gov/21857467/) DOI: [10.1097/SLE.0b013e318220f1b1](https://doi.org/10.1097/SLE.0b013e318220f1b1)]
- 92 **Zama N**, Fazio VW, Jagelman DG, Lavery IC, Weakley FL, Church JM. Efficacy of pelvic packing in maintaining hemostasis after rectal excision for cancer. *Dis Colon Rectum* 1988; **31**: 923-928 [PMID: [3215096](https://pubmed.ncbi.nlm.nih.gov/3215096/) DOI: [10.1007/BF02554887](https://doi.org/10.1007/BF02554887)]
- 93 **Pollard CW**, Nivatvongs S, Rojanasakul A, Ilstrup DM. Carcinoma of the rectum. Profiles of intraoperative and early postoperative complications. *Dis Colon Rectum* 1994; **37**: 866-874 [PMID: [8076485](https://pubmed.ncbi.nlm.nih.gov/8076485/) DOI: [10.1007/BF02052590](https://doi.org/10.1007/BF02052590)]
- 94 **Seyednejad H**, Imani M, Jamieson T, Seifalian AM. Topical haemostatic agents. *Br J Surg* 2008; **95**: 1197-1225 [PMID: [18763249](https://pubmed.ncbi.nlm.nih.gov/18763249/) DOI: [10.1002/bjs.6357](https://doi.org/10.1002/bjs.6357)]
- 95 **Vecchio R**, Catalano R, Basile F, Spataro C, Caputo M, Intagliata E. Topical hemostasis in laparoscopic surgery. *G Chir* 2016; **37**: 266-270 [PMID: [28350974](https://pubmed.ncbi.nlm.nih.gov/28350974/) DOI: [10.11138/gchir/2016.37.6.266](https://doi.org/10.11138/gchir/2016.37.6.266)]

- 96 **Patanè F**, Zingarelli E, Verzini A, di Summa M. Complication due to excessive use of Surgicel. *Eur J Cardiothorac Surg* 2001; **20**: 1034 [PMID: [11675198](#) DOI: [10.1016/s1010-7940\(01\)00967-8](#)]
- 97 **Sandhu GS**, Elexpuru-Camiruaga JA, Buckley S. Oxidized cellulose (Surgicel) granulomata mimicking tumour recurrence. *Br J Neurosurg* 1996; **10**: 617-619 [PMID: [9115663](#) DOI: [10.1080/02688699646989](#)]
- 98 **Ibrahim MF**, Aps C, Young CP. A foreign body reaction to Surgicel mimicking an abscess following cardiac surgery. *Eur J Cardiothorac Surg* 2002; **22**: 489-90; author reply 490 [PMID: [12204761](#) DOI: [10.1016/s1010-7940\(02\)00328-7](#)]
- 99 **Piozzi GN**, Reitano E, Panizzo V, Rubino B, Bona D, Tringali D, Micheletto G. Practical Suggestions for Prevention of Complications Arising from Oxidized Cellulose Retention: A Case Report and Review of the Literature. *Am J Case Rep* 2018; **19**: 812-819 [PMID: [29991675](#) DOI: [10.12659/AJCR.910060](#)]
- 100 **Jones CM**, Pierre KB, Nicoud IB, Stain SC, Melvin WV 3rd. Electrosurgery. *Curr Surg* 2006; **63**: 458-463 [PMID: [17084778](#) DOI: [10.1016/j.cursur.2006.06.017](#)]
- 101 **Chandra P**, Phalgune D, Shah S. Comparison of the Clinical Outcome and Complications in Laparoscopic Hernia Repair of Inguinal Hernia With Mesh Fixation Using Fibrin Glue vs Tacker. *Indian J Surg* 2016; **78**: 464-470 [PMID: [28100943](#) DOI: [10.1007/s12262-015-1410-9](#)]
- 102 **Sajid MS**, Ladwa N, Kalra L, Hutson K, Sains P, Baig MK. A meta-analysis examining the use of tacker fixation vs no-fixation of mesh in laparoscopic inguinal hernia repair. *Int J Surg* 2012; **10**: 224-231 [DOI: [10.1016/j.ijssu.2012.03.001](#)]
- 103 **Arora S**, Sevdalis N, Nestel D, Woloshynowych M, Darzi A, Kneebone R. The impact of stress on surgical performance: a systematic review of the literature. *Surgery* 2010; **147**: 318-330, 330.e1 [PMID: [20004924](#) DOI: [10.1016/j.surg.2009.10.007](#)]
- 104 **Berguer R**, Smith WD, Chung YH. Performing laparoscopic surgery is significantly more stressful for the surgeon than open surgery. *Surg Endosc* 2001; **15**: 1204-1207 [PMID: [11727101](#) DOI: [10.1007/s004640080030](#)]
- 105 **The SAGES Safe Cholecystectomy Program**. Strategies for Minimizing Bile Duct Injuries. SAGES. [cited 10 January 2021]. Available from: <https://www.sages.org/safe-cholecystectomy-program/>
- 106 **Chowbey P**, Baijal M, Kantharia NS, Khullar R, Sharma A, Soni V. Mesenteric Defect Closure Decreases the Incidence of Internal Hernias Following Laparoscopic Roux-En-Y Gastric Bypass: a Retrospective Cohort Study. *Obes Surg* 2016; **26**: 2029-2034 [PMID: [26757920](#) DOI: [10.1007/s11695-016-2049-8](#)]
- 107 **de la Cruz-Muñoz N**, Cabrera JC, Cuesta M, Hartnett S, Rojas R. Closure of mesenteric defect can lead to decrease in internal hernias after Roux-en-Y gastric bypass. *Surg Obes Relat Dis* 2011; **7**: 176-180 [PMID: [21126922](#) DOI: [10.1016/j.soard.2010.10.003](#)]
- 108 **Palser TR**, Ceney A, Navarro A, Swift S, Bowrey DJ, Beckingham IJ. Variation in laparoscopic anti-reflux surgery across England: a 5-year review. *Surg Endosc* 2018; **32**: 3208-3214 [PMID: [29368285](#) DOI: [10.1007/s00464-018-6038-y](#)]
- 109 **Edwin B**, Raeder I, Trondsen E, Kaarsen R, Buanes T. Outpatient laparoscopic adrenalectomy in patients with Conn's syndrome. *Surg Endosc* 2001; **15**: 589-591 [PMID: [11591947](#) DOI: [10.1007/s004640090021](#)]
- 110 **Buunen M**, Gholghesaei M, Veldkamp R, Meijer DW, Bonjer HJ, Bouvy ND. Stress response to laparoscopic surgery: a review. *Surg Endosc* 2004; **18**: 1022-1028 [PMID: [15136930](#) DOI: [10.1007/s00464-003-9169-7](#)]
- 111 **Jin F**, Chung F. Multimodal analgesia for postoperative pain control. *J Clin Anesth* 2001; **13**: 524-539 [PMID: [11704453](#) DOI: [10.1016/s0952-8180\(01\)00320-8](#)]
- 112 **Miskovic A**, Lumb AB. Postoperative pulmonary complications. *Br J Anaesth* 2017; **118**: 317-334 [PMID: [28186222](#) DOI: [10.1093/bja/aex002](#)]
- 113 **Patel MI**, Hardman DT, Nicholls D, Fisher CM, Appleberg M. The incidence of deep venous thrombosis after laparoscopic cholecystectomy. *Med J Aust* 1996; **164**: 652-654, 656 [PMID: [8657026](#)]
- 114 **Leissner KB**, Shanahan JL, Bekker PL, Amirfarzan H. Enhanced Recovery After Surgery in Laparoscopic Surgery. *J Laparoendosc Adv Surg Tech A* 2017; **27**: 883-891 [PMID: [28829221](#) DOI: [10.1089/lap.2017.0239](#)]
- 115 **Rockall TA**, Demartines N. Laparoscopy in the era of enhanced recovery. *Best Pract Res Clin Gastroenterol* 2014; **28**: 133-142 [PMID: [24485261](#) DOI: [10.1016/j.bpg.2013.11.001](#)]
- 116 **Vlug MS**, Bartels SA, Wind J, Ubbink DT, Hollmann MW, Bemelman WA; Collaborative LAFA Study Group. Which fast track elements predict early recovery after colon cancer surgery? *Colorectal Dis* 2012; **14**: 1001-1008 [PMID: [21985079](#) DOI: [10.1111/j.1463-1318.2011.02854.x](#)]
- 117 **Melloul E**, Hübner M, Scott M, Snowden C, Prentis J, Dejong CH, Garden OJ, Farges O, Kokudo N, Vauthey JN, Clavien PA, Demartines N. Guidelines for Perioperative Care for Liver Surgery: Enhanced Recovery After Surgery (ERAS) Society Recommendations. *World J Surg* 2016; **40**: 2425-2440 [PMID: [27549599](#) DOI: [10.1007/s00268-016-3700-1](#)]
- 118 **Melloul E**, Lassen K, Roulin D, Grass F, Perinel J, Adham M, Wellge EB, Kunzler F, Besselink MG, Asbun H, Scott MJ, Dejong CHC, Vrochides D, Aloia T, Izbickei JR, Demartines N. Guidelines for Perioperative Care for Pancreatoduodenectomy: Enhanced Recovery After Surgery (ERAS) Recommendations 2019. *World J Surg* 2020; **44**: 2056-2084 [PMID: [32161987](#) DOI: [10.1007/s00268-020-05462-w](#)]

- 119 **Gustafsson UO**, Scott MJ, Hubner M, Nygren J, Demartines N, Francis N, Rockall TA, Young-Fadok TM, Hill AG, Soop M, de Boer HD, Urman RD, Chang GJ, Fichera A, Kessler H, Grass F, Whang EE, Fawcett WJ, Carli F, Lobo DN, Rollins KE, Balfour A, Baldini G, Riedel B, Ljungqvist O. Guidelines for Perioperative Care in Elective Colorectal Surgery: Enhanced Recovery After Surgery (ERAS<sup>®</sup>) Society Recommendations: 2018. *World J Surg* 2019; **43**: 659-695 [PMID: [30426190](#) DOI: [10.1007/s00268-018-4844-y](#)]
- 120 **Low DE**, Allum W, De Manzoni G, Ferri L, Immanuel A, Kuppusamy M, Law S, Lindblad M, Maynard N, Neal J, Pramesh CS, Scott M, Mark Smithers B, Addor V, Ljungqvist O. Guidelines for Perioperative Care in Esophagectomy: Enhanced Recovery After Surgery (ERAS<sup>®</sup>) Society Recommendations. *World J Surg* 2019; **43**: 299-330 [PMID: [30276441](#) DOI: [10.1007/s00268-018-4786-4](#)]
- 121 **Ban KA**, Minei JP, Laronga C, Harbrecht BG, Jensen EH, Fry DE, Itani KM, Dellinger EP, Ko CY, Duane TM. American College of Surgeons and Surgical Infection Society: Surgical Site Infection Guidelines, 2016 Update. *J Am Coll Surg* 2017; **224**: 59-74 [PMID: [27915053](#) DOI: [10.1016/j.jamcollsurg.2016.10.029](#)]
- 122 **Pomposelli JJ**, Baxter JK 3rd, Babineau TJ, Pomfret EA, Driscoll DF, Forse RA, Bistrian BR. Early postoperative glucose control predicts nosocomial infection rate in diabetic patients. *JPEN J Parenter Enteral Nutr* 1998; **22**: 77-81 [PMID: [9527963](#) DOI: [10.1177/014860719802200277](#)]
- 123 **Meister KM**, Hufford T, Tu C, Khorgami Z, Schauer PR, Brethauer SA, Aminian A. Clinical significance of perioperative hyperglycemia in bariatric surgery: evidence for better perioperative glucose management. *Surg Obes Relat Dis* 2018; **14**: 1725-1731 [PMID: [30245036](#) DOI: [10.1016/j.soard.2018.07.028](#)]
- 124 **Dhatariya K**, Levy N, Kilvert A, Watson B, Cousins D, Flanagan D, Hilton L, Jairam C, Leyden K, Lipp A, Lobo D, Sinclair-Hammersley M, Rayman G; Joint British Diabetes Societies. NHS Diabetes guideline for the perioperative management of the adult patient with diabetes. *Diabet Med* 2012; **29**: 420-433 [PMID: [22288687](#) DOI: [10.1111/j.1464-5491.2012.03582.x](#)]
- 125 **Jørgensen ME**, Andersson C, Venkatesan S, Sanders RD. Beta-blockers in noncardiac surgery: Did observational studies put us back on safe ground? *Br J Anaesth* 2018; **121**: 16-25 [PMID: [29935568](#) DOI: [10.1016/j.bja.2018.02.004](#)]
- 126 **Kaloo P**, Armstrong S, Kaloo C, Jordan V. Interventions to reduce shoulder pain following gynaecological laparoscopic procedures. *Cochrane Database Syst Rev* 2019; **1**: CD011101 [PMID: [30699235](#) DOI: [10.1002/14651858.CD011101.pub2](#)]
- 127 **Donatsky AM**, Bjerrum F, Gögenur I. Intraperitoneal instillation of saline and local anesthesia for prevention of shoulder pain after laparoscopic cholecystectomy: a systematic review. *Surg Endosc* 2013; **27**: 2283-2292 [PMID: [23355159](#) DOI: [10.1007/s00464-012-2760-z](#)]
- 128 **Sao CH**, Chan-Tiopianco M, Chung KC, Chen YJ, Horng HC, Lee WL, Wang PH. Pain after laparoscopic surgery: Focus on shoulder-tip pain after gynecological laparoscopic surgery. *J Chin Med Assoc* 2019; **82**: 819-826 [PMID: [31517775](#) DOI: [10.1097/JCMA.000000000000190](#)]
- 129 **Farooqui MO**, Bazzoli JM. Significance of radiologic evidence of free air following laparoscopy. *J Reprod Med* 1976; **16**: 119-125 [PMID: [130487](#)]



## Endoscopic cryotherapy: Indications, techniques, and outcomes involving the gastrointestinal tract

Amaninder Dhaliwal, Syed M Saghir, Harmeet S Mashiana, Annie Braseth, Banreet S Dhindsa, Daryl Ramai, Pushpak Taunk, Rene Gomez-Esquivel, Aamir Dam, Jason Klapman, Douglas G Adler

**ORCID number:** Amaninder Dhaliwal 0000-0002-9761-437X; Syed M Saghir 0000-0001-5462-1767; Harmeet S Mashiana 0000-0002-9019-7657; Annie Braseth 0000-0002-2288-4711; Banreet S Dhindsa 0000-0002-9858-0941; Daryl Ramai 0000-0002-2460-7806; Pushpak Taunk 0000-0002-1695-6563; Rene Gomez-Esquivel 0000-0003-4666-1544; Aamir Dam 0000-0002-2696-708X; Jason Klapman 0000-0002-0763-5151; Douglas G Adler 0000-0003-3214-6285.

**Author contributions:** All authors contributed to the conception and design, acquisition of data and drafting of manuscript; all authors approved the final version of the article, including the authorship list.

### Conflict-of-interest statement:

There is no conflict of interest from any of the authors.

**Country/Territory of origin:** United States

**Specialty type:** Gastroenterology and hepatology

### Provenance and peer review:

Invited article; Externally peer reviewed.

**Peer-review model:** Single blind

**Peer-review report's scientific quality classification**

**Amaninder Dhaliwal**, Division of Gastroenterology and Advanced Endoscopy, McLeod Regional Medical Center, Florence, SC 29501, United States

**Syed M Saghir**, Division of Gastroenterology, Creighton University School of Medicine, Omaha, NE 68124, United States

**Harmeet S Mashiana, Banreet S Dhindsa**, Division of Gastroenterology and Hepatology, University of Nebraska Medical Center, Omaha, NE 68198-2000, United States

**Annie Braseth**, Division of Gastroenterology, University of Iowa, Iowa City, IA 52242-1009, United States

**Daryl Ramai**, Division of Gastroenterology and Hepatology, University of Utah School of Medicine, Salt Lake City, UT 84132, United States

**Pushpak Taunk, Rene Gomez-Esquivel**, Division of Gastroenterology, USF Health, Tampa, FL 33612, United States

**Aamir Dam**, Division of Gastroenterology and Hepatology, Moffitt Cancer Center, Tampa, FL 33612, United States

**Jason Klapman**, Gastrointestinal Tumor Program, Moffitt Cancer Center, Tampa, FL 33612, United States

**Douglas G Adler**, Center for Advanced Therapeutic Endoscopy, Porter Adventist Hospital, Center Health, Denver, CO 80210, United States

**Corresponding author:** Douglas G Adler, AGAF, FACG, FASGE, MD, Center for Advanced Therapeutic Endoscopy, Porter Adventist Hospital, Center Health, 2525 S Downing St, Denver, CO 80210, United States. [dougraham2001@gmail.com](mailto:dougraham2001@gmail.com)

## Abstract

Endoscopic cryotherapy is a technique utilized for the ablation of target tissue within the gastrointestinal tract. A cryotherapy system utilizes the endoscopic application of cryogen such as liquid nitrogen, carbon dioxide or liquid nitrous oxide. This leads to disruption of cell membranes, apoptosis, and thrombosis of local blood vessels within the target tissue. Several trials utilizing cryotherapy for Barrett's esophagus (BE) with variable dysplasia, gastric antral vascular ectasia (GAVE), esophageal carcinoma, radiation proctitis, and metastatic esophageal



Grade A (Excellent): 0  
 Grade B (Very good): B  
 Grade C (Good): C  
 Grade D (Fair): 0  
 Grade E (Poor): 0

**Open-Access:** This article is an open-access article that was selected by an in-house editor and fully peer-reviewed by external reviewers. It is distributed in accordance with the Creative Commons Attribution NonCommercial (CC BY-NC 4.0) license, which permits others to distribute, remix, adapt, build upon this work non-commercially, and license their derivative works on different terms, provided the original work is properly cited and the use is non-commercial. See: <https://creativecommons.org/licenses/by-nc/4.0/>

**Received:** January 8, 2021

**Peer-review started:** January 8, 2021

**First decision:** October 17, 2021

**Revised:** October 31, 2021

**Accepted:** December 25, 2021

**Article in press:** December 25, 2021

**Published online:** January 16, 2022

**P-Reviewer:** Gunay S, Xi K

**S-Editor:** Wang JL

**L-Editor:** A

**P-Editor:** Wang JL



carcinomas have shown safety and efficacy. More recently, liquid nitrogen cryotherapy (cryodilation) was shown to be safe and effective for the treatment of a benign esophageal stricture which was refractory to dilations, steroid injections, and stenting. Moreover, liquid nitrogen cryotherapy is associated with less post procedure pain as compared to radiofrequency ablation in BE with comparable ablation rates. In patients with GAVE, cryotherapy was found to be less tedious as compared to argon plasma coagulation. Adverse events from cryotherapy most commonly include chest pain, esophageal strictures, and bleeding. Gastric perforations did occur as well, but less often. In summary, endoscopic cryotherapy is a promising and growing field, which was first demonstrated in BE, but the use now spans for several other disease processes. Larger randomized controlled trials are needed before its role can be established for these different diseases.

**Key Words:** Cryotherapy; Gastric antral vascular ectasia; Barrett's esophagus; Esophageal cancer; Palliative therapy

©The Author(s) 2022. Published by Baishideng Publishing Group Inc. All rights reserved.

**Core Tip:** Cryotherapy involves freeze-thaw cycles of tissue to eradicate problematic lesions such as Barrett's esophagus with variable dysplasia, gastric antral vascular ectasia, radiation proctitis, esophageal carcinomas and metastatic esophageal carcinomas. Two of the most used cryotherapy systems involve liquid nitrogen and carbon dioxide. Cryoballoon focal ablation system is another system, but not widely available. Cryotherapy systems have shown efficacy for these conditions even in patients who were refractory to the current standards of care.

**Citation:** Dhaliwal A, Saghir SM, Mashiana HS, Braseth A, Dhindsa BS, Ramai D, Taunk P, Gomez-Esquivel R, Dam A, Klapman J, Adler DG. Endoscopic cryotherapy: Indications, techniques, and outcomes involving the gastrointestinal tract. *World J Gastrointest Endosc* 2022; 14(1): 17-28

**URL:** <https://www.wjgnet.com/1948-5190/full/v14/i1/17.htm>

**DOI:** <https://dx.doi.org/10.4253/wjge.v14.i1.17>

## INTRODUCTION

Endoscopic cryotherapy is a technique utilized for the ablation of target tissue within the gastrointestinal (GI) tract. A cryotherapy system utilizes the endoscopic application of cryogen such as liquid nitrogen or liquid nitrous oxide to the target tissue leading to disruption of cell membranes, apoptosis, and thrombosis of local blood vessels. Endoscopic cryotherapy first showed success in the treatment of Barrett's esophagus (BE), but over time has been used for both treatment and symptomatic relief of many disease processes throughout the GI tract. This review will discuss the current and future roles of cryotherapy in GI endoscopy.

## MECHANISM OF ACTION

Cryotherapy achieves tissue destruction *via* two mechanisms, which include both immediate and delayed effects, while simultaneously preserving the cryo-resistant structures. The initial effect of cryotherapy is the formation of ice crystals by freezing the intracellular and extracellular water in the tissues. The ice crystals lead to the disruption of the cell membranes and protein denaturation. This creates an osmotic gradient, which draws water from the intracellular compartment leading to the cell dehydration and destruction[1-3]. The degree of cell death is similar to other modalities which are heat based like radiofrequency ablation (RFA) or argon plasma coagulation (APC) but this method preserves the architecture of the underlying tissue and the extracellular matrix which reduces scarring[1]. Cellular death of peripheral tissues that does not occur from direct injury by cryoablation may eventually die *via*

apoptosis, caused by activation of cytochrome C due to the mitochondrial injury[4,5].

The thawing process follows the initial freezing mechanism[6]. During this phase, there is fusion of intracellular ice crystals, with the maximum effect occurring at -20-degrees-C to -50-degrees-C, which further damages the cell membranes. In addition, there is an indirect injury to the vascular endothelium *via* the fusion of ice crystals resulting in tissue necrosis and ischemia, due to the platelet aggregation, thrombus formation and regional hyperemia[7-9]. The risk of perforation in cryotherapy is decreased as collagen and elastin fibers are cryo-resistant as compared to the epithelial cells[10,11].

## TYPES OF ENDOSCOPIC CRYOTHERAPY METHODS

Currently, the two types of endoscopic cryotherapy methods which are commercially available include liquid nitrogen cryotherapy and carbon dioxide (CO<sub>2</sub>) cryotherapy.

### **Liquid nitrogen cryotherapy**

In this technique, a contact-free low-pressure spray of liquid nitrogen is delivered through a 7F catheter and reaches a temperature of -196-degrees-C, which freezes the GI mucosa (Figure 1). During this process, the catheter and the endoscope experience a rapid drop in temperature and become less compliant, which makes it difficult to operate the endoscope and/or move the catheter in the biopsy channel[2,12]. As nitrogen gas expands at room temperature, it leads to rapid cooling due to the Joule-Thompson effect (rapid expansion of a gas leading to a change in temperature of a gas). To warm the cryoprobe, the depressurized gas can be vented out and a heating circuit within in the catheter is necessary to maintain pliability of the device[2,13].

Prior to liquid nitrogen cryotherapy, a 20 F dual-channel decompression oral-gastric tube is placed to allow for both active and passive gas venting to reduce the risk of GI perforation[14]. This is utilized because after the liquid nitrogen spray freezes the tissue, the warmth transforms it into nitrogen gas, which expands at a rate of 6-8 L in a 20 s liquid nitrogen spray[15]. During the procedure, the abdomen is frequently examined by palpation, usually by an assistant, to ensure adequate decompression and to alert staff if distention is recognized[16].

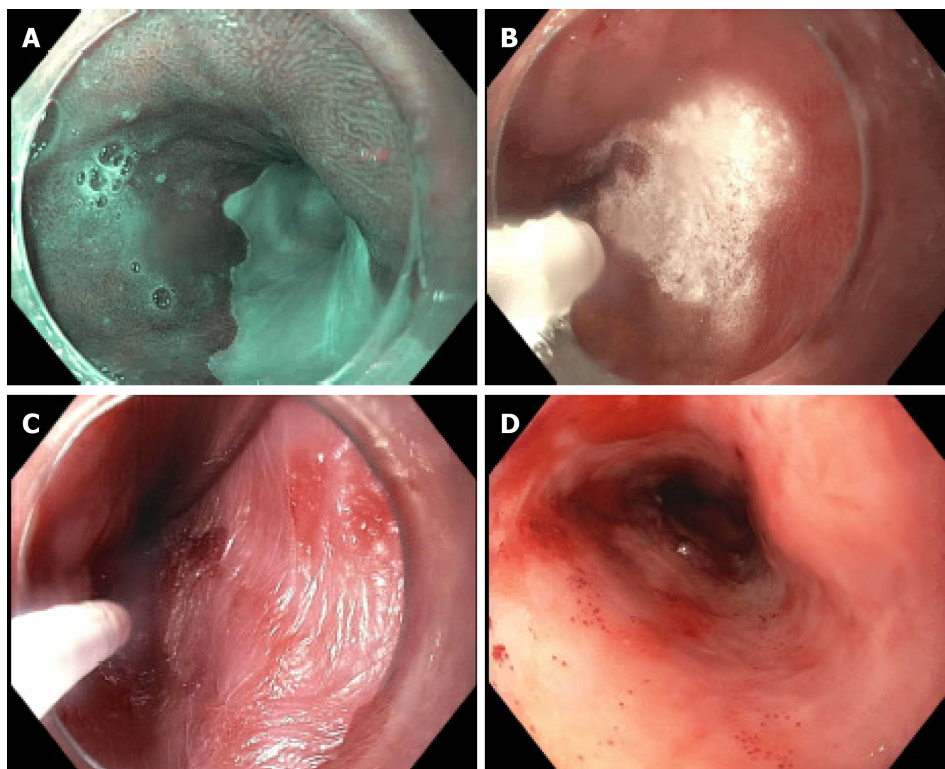
### **CO<sub>2</sub>-based cryotherapy**

In this technique, a compressed CO<sub>2</sub> gas spray is applied through a catheter with a 0.005-inch diameter tip opening. The CO<sub>2</sub> gas reaches a temperature of -78-degrees-C and is delivered at a rate of 6-8 L/min at a pressure of 450-750 psi[14]. A suction cap is placed on the distal end of the endoscope which is connected to the CO<sub>2</sub> evacuation system, and this allows venting of the CO<sub>2</sub> gas build up to avoid distention[14,17]. The CO<sub>2</sub> gas is vented simultaneously as cryotherapy is being delivered. Unlike liquid nitrogen cryotherapy, a heating circuit is not necessary since the endoscope and the catheter delivering the CO<sub>2</sub> gas are not at risk of freezing[12].

### **Differences between liquid nitrogen cryotherapy and CO<sub>2</sub> based cryotherapy:**

Several differences exist between liquid nitrogen cryotherapy and CO<sub>2</sub> cryotherapy systems aside from the type of gases and temperatures utilized. Both systems can cause abdominal distension as the cryogen changes to a gaseous state, however, this is less problematic with the CO<sub>2</sub>-based system because of a low-profile catheter which evacuates the excess CO<sub>2</sub>. Both systems have issues with fogging of the endoscope lens, which compromises visualization. The CO<sub>2</sub> based system is comparatively cheaper and can be stored at room temperature as compared to the liquid nitrogen system, which requires storage in expensive containers to maintain a temperature between 195.8-210-degrees-C[12,18].

**Duration and dosage of cryotherapy:** Cryotherapy involves two stepwise processes: Freezing and thawing, often performed in cycles. The amount of tissue injury caused by cryotherapy depends on the rate and duration of cooling, the number of freeze-thaw cycles, and the distance from the target tissue to the origin of the spray. A critical limitation of cryotherapy is that dosimetry data for this technology is lacking, and is, for all intents and purposes, largely unknown. Initial dosing regimens on BE patients consisted of 3 cycles of 20 s each, which was changed to 4 cycles of 10 s each after over distention in a Marfans syndrome patient led to a gastric perforation. The clinical experience suggests that freeze times of 10-15 s may be efficacious for short term in ablation of BE[19].



**Figure 1 Liquid nitrogen cryotherapy for Barrett's esophagus.** A: Long segment Barrett's esophagus pre-cryotherapy intervention under narrow band imaging; B: Application of liquid nitrogen cryotherapy in Barrett's esophagus; C: Crystallization post cryotherapy in Barrett's esophagus; D: Post cryotherapy changes seen in Barrett's esophagus.

In a study performed in a porcine animal model, the CO<sub>2</sub> system demonstrated a dose-dependent effect on tissue damage based on seconds of CO<sub>2</sub> spray. A 15 s spray caused minimal necrosis, a 30 s spray caused damage to the submucosa and a 120 s spray caused damage to the muscularis propria[20]. In another porcine study, liquid nitrogen was sprayed for 10-60 s and did not appear to show a dose-dependent effect on tissue[21]. This emphasizes how poorly the technology is understood.

Despite our poor understanding of dosimetry, the varying doses of cryotherapy used to date have shown efficacy with an acceptable safety profile in clinical settings. It is believed that longer freeze times maybe needed for the palliative treatment of esophageal cancer. There is limited data describing the clinical outcomes to compare the various freeze durations and number of freeze-thaw cycles[19].

## UTILITY OF CRYOTHERAPY IN VARIOUS GI ETIOLOGIES

### BE

BE, first described in 1950 by Dr. Norman Barrett, a British thoracic surgeon, refers to replacement of normal squamous epithelium of the esophagus by columnar epithelium, at least 1 cm above the gastro-esophageal junction, and is a precursor lesion of esophageal adenocarcinoma (EAC)[22]. Although the incidence of BE is increasing in the western world, the risk of EAC in patients with BE is now estimated to be at least 10 fold higher when compared to the general population[23].

BE is traditionally classified based on endoscopic length of salmon colored mucosa, as long segment BE (LSBE > 3 cm) or short segment BE (SSBE < 3 cm). However, the diagnosis of BE needs histological correlation in addition to endoscopic appearance, which takes into account replacement of esophageal squamous epithelium by columnar epithelium along with presence of goblet cells, a marker of intestinal metaplasia (IM)[22].

Endoscopic ablative techniques remain the treatment of choice for BE patients with dysplasia and/or early esophageal cancer without lymphatic spread[24]. The available endoscopic ablative techniques include RFA, photodynamic therapy and cryotherapy. RFA combined with endoscopic mucosal resection (EMR) has become the standard treatment for BE because of its demonstrated efficacy, cost effectiveness, and better

side effect profile[25]. For limited surface areas, APC and bipolar probes are a less expensive alternative compared to cryotherapy. However, these procedures may have higher BE recurrence rates[13,26,27].

**Liquid nitrogen cryotherapy in BE:** A pilot study of liquid nitrogen cryotherapy published in 2005 reporting on only 11 patients with BE and variable dysplasia achieved complete endoscopic and histologic eradication in 82% of patients[28]. A subsequent multi-center study of 77 patients utilizing liquid nitrogen cryotherapy therapy for BE high grade dysplasia (HGD), BE dysplasia, and BE IM achieved complete eradication at rates of 94%, 88% and 53%, respectively. Additionally, complete remission of intramucosal cancer and carcinoma was seen in all 7 patients. The most common adverse event (AE) was chest pain at 17.6%. Three patients developed a stricture which was successfully managed endoscopically with dilation. Gastric distention from liquid nitrogen therapy led to a perforation in a patient with Marfan's syndrome[29].

A recent study by Ramay *et al*[30] looked at the efficacy of liquid nitrogen cryotherapy on BE-HGD and intramucosal adenocarcinoma (IMC). This study included 50 patients who were analyzed over 3 years and 40 patients who were analyzed over 5 years. The initial rates of complete remission of HGD, dysplasia, and IM were 98%, 90%, and 60% and were found to be comparable at 3 and 5 years. Incidence rates of recurrent IM, dysplasia, and HGD/EAC on follow-up after initial complete eradication of IM were 12.2%, 4.0%, and 1.4% per person-year for the 5-year cohort.

**Cryotherapy ablation compared against RFA for BE:** A recently published non-inferiority trial comparing RFA with liquid nitrogen cryotherapy in 31 patients with HGD and early adenocarcinoma found similar results between the two groups. Complete remission of BE in patients undergoing RFA *vs* liquid nitrogen was 21% *vs* 12%, respectively. Pain scores were significantly lower in the liquid nitrogen cryotherapy group as compared to the RFA group. There was no major procedure related AEs. These results are preliminary as we are awaiting results of the complete trial[31]. Similar findings were demonstrated in a different study regarding lower post procedure pain scores in those undergoing liquid nitrogen cryotherapy as compared to RFA[32].

A retrospective study with 154 patients were treated for Barrett's dysplasia, IM or HGD with either RFA or liquid nitrogen cryotherapy. Complete remission of HGD was comparable between both groups at 88%. Complete remission of IM was more successful in RFA *vs* cryotherapy (67% *vs* 41%) and statistically significant. Complete remission of dysplasia was also comparable between RFA *vs* cryotherapy (88% *vs* 79%) [33]. Similar results were also seen in a recent retrospective study by Fasullo *et al*[34] which included 100 patients in the RFA group and 62 patients in the liquid nitrogen cryotherapy group.

Cryotherapy has several potential advantages over RFA, which include fewer complications (pain, stricture), cost effectiveness and a no contact technique. Disadvantages of cryotherapy include the following: abdominal distention due to gas, difficulty in visualization during the endoscopic procedure due to freezing of tissue and barotrauma, poor dosimetry, and limited outcome data compared to RFA.

**CO<sub>2</sub> cryotherapy in BE:** Data to establish the durability of CO<sub>2</sub> cryotherapy as a treatment for BE is limited. In a single center study of 64 patients with BE reported complete remission of IMC, HGD and IM in 77%, 94% and 55% of patients, respectively[35]. This was the largest study demonstrating the safety and long-term efficacy results of CO<sub>2</sub> cryotherapy and the results were comparable to that seen with liquid nitrogen cryotherapy[35].

According to a small single center prospective case series of 10 patients, a negative experience led to an early termination of a study due to an insufficient effect of CO<sub>2</sub> cryoablation in BE and early neoplasia. Most patients underwent EMR prior to cryotherapy. Complete remission of IM and dysplasia in 9 patients was reported to be 11% and 44% at the 6 mo follow up, respectively. Two noteworthy AEs included gastric perforation and esophageal laceration[36].

**Cryoballoon focal ablation system using nitrous oxide for BE:** A cryoballoon-based system is the most recent developed endoscopic cryotherapy system and ablates mucosa *via* direct contact of an inflated balloon tip catheter filled with nitrous oxide [14,37]. The balloon reaches temperatures close to -80-degrees-C[38]. The device has been slow to achieve widespread commercial release.



In a study published the same year by Sawas *et al*[39], 42 patients underwent cryoballoon focal ablation system (CbFAS) of which 37 had unsuccessful prior BE treatments indicating a more challenging cohort. Complete remission of dysplasia and IM were achieved in 54.8% and 9.5% of patients over a mean follow up period of  $7.5 \pm 5.7$  mo.

A multicenter non-randomized comparative study of 46 patients utilizing CbFAS *vs* RFA showed comparable outcomes (88% *vs* 90%) for SSBE regression. There were 20 patients in the CbFAS group and 26 in the RFA group. Peak pain and duration of pain was reported to be significantly lower in the CbFAS group[40].

Canto *et al*[41] recently published a large multicenter trial on 120 patients of which 45% had previously received EMR for BE. The rates of complete remission of dysplasia and IM rates in 94 patients who have completed 12 mo of follow up are 97% and 91%, respectively. Fifteen patients developed strictures, which were treated with dilation. Three other patients developed serious AEs: 1 perforation after stricture dilation, 1 deep laceration after dilation, and 1 upper GI bleed. So far BE has not been seen on follow up biopsies post CbFAS. This is the largest trial to date representing the efficacy of CbFAS for BE.

Outcomes regarding this technique are variable and require confirmation by further studies. There are a few clinical trials being conducted for CbFAS effect on BE and we await their results.

**CbFAS compared to liquid nitrogen cryotherapy for BE:** Recently, a retrospective study compared cryoballoon therapy to liquid nitrogen cryospray. Forty-six patients were treated with CbFAS and 25 were treated with liquid nitrogen cryospray. They reported the complete eradication rates of dysplasia and IM to be comparable at 95.6% *vs* 96% and 84.75% *vs* 80% in the cryoballoon group *vs* liquid nitrogen cryospray group, respectively. Strictures were reported in 4 of the cryoballoon patients and 3 of the cryospray patients, which were treated with dilation. The authors reported cryoballoon to be more convenient since it uses cartridges prefilled with nitrous oxide as compared to handling a large nitrogen tank. In instances where patients had a large hiatal hernia, needed to be treated in a retroflexed position, or required a large surface area to be targeted, liquid nitrogen cryospray was used instead[37].

### **Gastric antral vascular ectasia**

Gastric antral vascular ectasia (GAVE), also known as ‘watermelon stomach’, is an uncommon cause of GI bleeding but can often cause clinically significant chronic and severe bleeding. The prevalence of GAVE is estimated to be 0.3% in a large endoscopic series and 4% in highly selected cohorts for obscure GI bleeding. It is often misdiagnosed as antral gastritis and can be difficult to differentiate from portal hypertensive gastropathy[42,43]. Majority of patients with GAVE become transfusion dependent despite iron supplementation[43,44]. The best approach for the treatment has not yet been identified but the standard treatment in most countries is endoscopy based. APC has been a preferred treatment, however, can be very labor intensive due to the large surface area covered and multiple sessions required. Moreover, patients can develop recurrence overtime and may become transfusion dependent[45]. Cryotherapy is another intervention that has been utilized for GAVE, but the data is limited.

The etiology of GAVE is poorly understood however the histopathology demonstrates specific abnormalities involving mucosa and lamina propria[44]. It is commonly associated in patients with cirrhosis, renal disease, cardiac disease and autoimmune disease such as scleroderma[46]. There are 4 alterations seen: Vascular ectasia of mucosal capillaries, focal thrombosis, spindle cell proliferation and fibrohyalinosis consisting of homogenous substance around the ectatic capillaries of lamina propria[42]. By utilizing cryotherapy, superficial necrosis of the mucosa and submucosa occur followed by re-epithelialization[12].

**CO<sub>2</sub> based cryotherapy for GAVE:** In a single center pilot study by Cho *et al*[47], 12 patients with GAVE received 36 CO<sub>2</sub> based cryotherapy treatments with complete response in 50% and partial response in 50%. Eight patients in this cohort had prior unsuccessful APC treatments of which 6 had complete response after CO<sub>2</sub> based cryotherapy. There were no immediate cryotherapy related complications. Some late complications seen on follow up endoscopy included bleeding from a disrupted Schatzki’s ring and minor scarring/ulceration in the gastric antrum.

**CbFAS with nitrous oxide for GAVE:** In a pilot study of 7 patients, complete eradication was seen in 71% after undergoing CbFAS with nitrous oxide. All patients had undergone laser, thermal and APC intervention previously without success. No major AE occurred related to cryotherapy[48]. In another study of 23 patients utilizing

CbFAS, 83% of patients were transfusion independent and 87% had more than 75% eradication of their GAVE at 6 mo[46]. Similar result was reported in a case report using CbFAS in a patient with GAVE who had failed previous treatment with APC [49].

Cryotherapy for GAVE has seemingly promising results but has limited data and requires further investigation with larger trials. One major advantage of cryotherapy in comparison to APC is that it can treat larger surface areas in a shorter amount of time.

### **Radiation proctitis**

One of the most frequent complications after radiation therapy for pelvic malignancies is radiation proctitis[50,51]. The consensus has been that the incidence is related to the dose of radiation, exposure area, delivery method and the use of cytoprotective agents. The dose for most treatments is 45-50 Gy and up to 90 Gy. Complications are less for doses from 45-70 Gy, but doses above 70 Gy cause significant long-standing damage. Depending on the type of radiation therapy used, the incidence for proctitis varies from 1% to as high as 39%[50].

Radiation proctitis can be acute or chronic. Acute proctitis is an inflammatory process occurring within 3 mo of the initial therapy and is usually self-limiting after the radiation treatment has stopped. The treatment of acute proctitis is generally supportive with hydration, anti-diarrheal, steroids or 5-aminosalicylic acid enemas. Chronic proctitis on the other hand, can start during the acute phase of radiation but symptoms do not become obvious until the treatment is stopped around a median of 8-12 mo[52,53]. The treatment for chronic proctitis involves non-invasive methods such as anti-inflammatory agents, sucralbate, short-chain fatty acids, hyperbaric oxygen, antioxidants, or more invasive methods such as ablation and surgery. Invasive methods are reserved for refractory symptoms that have failed medical management. The ablation methods involve formalin, endoscopic coagulation with APC, yttrium-aluminum-garnet laser or potassium titanyl phosphate laser, cryotherapy, bipolar electrocoagulation, and hyperbaric oxygen[50,51,54,55]. Surgery carries the risk of morbidity and mortality[56]. APC has shown to be an effective and safe treatment for chronic proctitis with success rates of 80%-95% for bleeding cessation, but controlled trials are lacking[51,57,58]. Complications from these therapies may result in deep tissue injuries like ulcerations, perforation and fistulas, whereas cryotherapy has the potential to avoid these problems since the ablation of the mucosa is superficial[57].

**CbFAS with nitrous oxide for radiation proctitis:** In a small pilot study of 7 patients who underwent nitrous oxide cryotherapy, 100% resolution of lower GI bleeding was observed with no major AE. All patients had previous unsuccessful treatment with APC[48].

**Liquid nitrogen cryotherapy for radiation proctitis:** In a small prospective study of 10 patients who underwent liquid nitrogen cryoablation, the rectal telangiectasia density improved in 70% and the symptom severity scores improved in 80%. Cecal perforation due to gaseous overdistention occurred in 1 patient and was managed surgically. Rectal ulceration occurred in another patient, which improved from conservative management[57]. Similar results were seen in another small prospective study of 10 patients. There were no major complications[55].

**Differences between APC and cryotherapy for radiation proctitis:** Best results with APC have been achieved in mild to moderate radiation proctitis but its role has been limited for severe disease. Cryotherapy on the other hand has shown efficacy in patients with refractory chronic radiation proctitis[59]. Utilization of APC as compared to cryotherapy can be very time consuming, require bowel preparation to reduce the risk of perforation and may require multiple sessions. Cryotherapy can also be carried out with little or no sedation[55]. Larger studies need to be conducted to validate these findings and to determine the role of cryotherapy in acute and chronic radiation proctitis.

### **Squamous cell carcinoma and adenocarcinoma of esophagus**

**Treatment of symptoms:** Dysphagia can be a debilitating symptom in patients with inoperable esophageal carcinoma. Further, it can lead to malnutrition and significant decrease in overall quality of life. Currently the two most common palliative treatments included radiation therapy or esophageal stent placement[60]. These methods may have advantages, but their disadvantages can impair quality of life as well.

In a case series of 49 patients with inoperable malignant dysphagia, 120 liquid nitrogen cryotherapy sessions were conducted, and overall dysphagia scores had improved. Minor AEs were seen in 5% with one patient developing a dilation-related perforation[60]. Cryotherapy may be an alternative treatment option for improving dysphagia with minimal side effects in esophageal carcinoma, however larger studies are needed.

**Treatment of EAC and squamous cell cancer:** Globally, squamous cell carcinoma of the esophagus comprises 80% of all esophageal carcinomas. These patients have a poor prognosis, however, if diagnosed at the stage of squamous cell neoplasia, then curative endoscopic therapy can be performed. Currently, there is limited data assessing its overall effectiveness.

**Cryoballoon focal ablation with liquid nitrous oxide for esophageal cancer:** In a prospective trial from China of 80 patients, CbFAS was utilized in patients with one flat intraepithelial neoplasm that was less than 6 cm. Complete eradication occurred in 90% after a single treatment. At the one-year mark, 97% had complete eradication and one had a persistent moderate grade intraepithelial neoplasia. Self-limiting lacerations of the mucosa occurred in 3 patients and no strictures developed[61]. Cryotherapy with CbFAS seems promising, but further studies are needed.

**Liquid nitrogen cryotherapy for esophageal cancer:** Cash *et al*[62] had described a 73-year-old male with stage 3 squamous cell carcinoma of the esophagus who was not a candidate for radiation therapy or surgery, and he achieved complete remission for 24 mo after treatment with liquid nitrogen cryotherapy. The patient did develop a significant stricture, which required several dilations, steroid injections, and temporary stenting.

Tsai *et al*[63] conducted a prospective study utilizing liquid nitrogen cryotherapy in patients with EAC. Eighty-eight patients were analyzed with stages T1a-T2. Complete eradication rates in patients with T1a and T2 were 76.3% and 6.7%, respectively. The most common side effect was stricture and developed in 13.6% of patients. Cryotherapy may be of benefit for treatment in early disease.

Another study done by Ramay *et al*[64] utilized liquid nitrogen cryotherapy for palliation in patients with both invasive adenocarcinoma and squamous esophageal carcinoma. At fifty months, 50% (26) of patients remained alive after treatments. There were few AEs including hematemesis in one patient and stricture formation in 3 with 2 requiring dilations. Overall this method may be a viable treatment palliative treatment option, however larger scale studies are needed.

**Survival benefits in metastatic disease:** Beyond treatment, another study assessed the impact on overall survival in patients with metastatic esophageal carcinoma. This study retrospectively studied 83 patients with stage IV metastatic esophageal cancer. Thirty-nine patients received chemotherapy alone and 44 patients received chemotherapy and palliative liquid nitrogen cryotherapy. All patients that underwent treatment with cryotherapy had malignant dysphagia. The median overall survival was 19.2 in cryotherapy with chemotherapy and 9.5 mo in with chemotherapy alone. This study demonstrated that cryotherapy might have survival benefits for patients with metastatic esophageal cancer. While the etiology for this is unknown, the authors of the study postulated that cryotherapy can improve dysphagia and thus nutritional status[65].

The role for cryotherapy in palliative treatment of esophageal carcinoma and symptomatic improvement is promising however larger scale studies are needed.

### **Other uses for cryotherapy**

Liquid nitrogen cryotherapy followed by dilation (cryodilation) has been utilized in benign tracheal strictures and stenoses by pulmonologists and thoracic surgeons with improved airway narrowing. Recently a case report described its use in a patient with a benign refractory esophageal stricture who had previously undergone an esophagectomy for an EAC. The patient underwent 7 procedures with liquid nitrogen cryotherapy followed by dilation. Each procedure incorporated 20 s of cryotherapy and 60 s of thaw time for a total of 3 freeze-thaw cycles followed by stricture dilation to 18 mm. The patient's dysphagia had improved, and weight loss was no longer an issue. This procedure was useful in a patient with refractory esophageal stricture, however its role has yet to be established and further randomized controlled trials are needed to evaluate its safety and efficacy in a larger population[66].

## CONCLUSION

Endoscopic cryotherapy is a promising and growing field. First demonstrated in BE, the use now spans from cancer treatment to symptomatic improvement in GAVE. Most studies done have been on small populations. Large scale randomized control studies are needed to determine the overall effectiveness and utility of endoscopic cryotherapy in treatment of various GI disorders. The ease of use and the ability for relatively safe and noninvasive procedures makes it a very promising modality for the future.

## REFERENCES

- 1 **Greenwald BD**, Dumot JA, Abrams JA, Lightdale CJ, David DS, Nishioka NS, Yachimski P, Johnston MH, Shaheen NJ, Zfass AM, Smith JO, Gill KR, Burdick JS, Mallat D, Wolfsen HC. Endoscopic spray cryotherapy for esophageal cancer: safety and efficacy. *Gastrointest Endosc* 2010; **71**: 686-693 [PMID: [20363410](#) DOI: [10.1016/j.gie.2010.01.042](#)]
- 2 **Erinjeri JP**, Clark TW. Cryoablation: mechanism of action and devices. *J Vasc Interv Radiol* 2010; **21**: S187-S191 [PMID: [20656228](#) DOI: [10.1016/j.jvir.2009.12.403](#)]
- 3 **Gage AA**, Baust J. Mechanisms of tissue injury in cryosurgery. *Cryobiology* 1998; **37**: 171-186 [PMID: [9787063](#) DOI: [10.1006/cryo.1998.2115](#)]
- 4 **Clarke DM**, Robilotto AT, Rhee E, VanBuskirk RG, Baust JG, Gage AA, Baust JM. Cryoablation of renal cancer: variables involved in freezing-induced cell death. *Technol Cancer Res Treat* 2007; **6**: 69-79 [PMID: [17375969](#) DOI: [10.1177/153303460700600203](#)]
- 5 **Hanai A**, Yang WL, Ravikumar TS. Induction of apoptosis in human colon carcinoma cells HT29 by sublethal cryo-injury: mediation by cytochrome c release. *Int J Cancer* 2001; **93**: 526-533 [PMID: [11477556](#) DOI: [10.1002/ijc.1359](#)]
- 6 **Baust JG**, Gage AA. The molecular basis of cryosurgery. *BJU Int* 2005; **95**: 1187-1191 [PMID: [15892798](#) DOI: [10.1111/j.1464-410X.2005.05502.x](#)]
- 7 **Kahlenberg MS**, Volpe C, Klippenstein DL, Penetrante RB, Petrelli NJ, Rodriguez-Bigas MA. Clinicopathologic effects of cryotherapy on hepatic vessels and bile ducts in a porcine model. *Ann Surg Oncol* 1998; **5**: 713-718 [PMID: [9869518](#) DOI: [10.1007/bf02303482](#)]
- 8 **Weber SM**, Lee FT. Cryoablation: history, mechanism of action, and guidance modalities. *Tumor Ablat* 2005; 250-265 [DOI: [10.1007/0-387-28674-8\\_20](#)]
- 9 **Weber SM**, Lee FT Jr, Chinn DO, Warner T, Chosy SG, Mahvi DM. Perivascular and intralesional tissue necrosis after hepatic cryoablation: results in a porcine model. *Surgery* 1997; **122**: 742-747 [PMID: [9347851](#) DOI: [10.1016/s0039-6060\(97\)90082-9](#)]
- 10 **Gage AA**, Baust JM, Baust JG. Experimental cryosurgery investigations in vivo. *Cryobiology* 2009; **59**: 229-243 [PMID: [19833119](#) DOI: [10.1016/j.cryobiol.2009.10.001](#)]
- 11 **Shepherd JP**, Dawber RP. Wound healing and scarring after cryosurgery. *Cryobiology* 1984; **21**: 157-169 [PMID: [6713945](#) DOI: [10.1016/0011-2240\(84\)90207-4](#)]
- 12 **Hu SNY**, Adler DG. Endoscopic Cryotherapy: Indications and Efficacy. *Pract Gastroenterol* 2015; **39**: 19-45
- 13 **Muguruma N**, Marcon NE. Technique and emerging role of cryotherapy. *Tech Gastroint Endos* 2010; **12**: 44-48 [DOI: [10.1016/j.tgie.2010.02.002](#)]
- 14 **ASGE Technology Committee**; Parsi MA, Trindade AJ, Bhutani MS, Melson J, Navaneethan U, Thosani N, Trikudanathan G, Watson RR, Maple JT. Cryotherapy in gastrointestinal endoscopy. *VideoGIE* 2017; **2**: 89-95 [PMID: [29905303](#) DOI: [10.1016/j.vgie.2017.01.021](#)]
- 15 **Halsey KD**, Greenwald BD. Cryotherapy in the management of esophageal dysplasia and malignancy. *Gastrointest Endosc Clin N Am* 2010; **20**: 75-87 [PMID: [19951795](#) DOI: [10.1016/j.giec.2009.07.009](#)]
- 16 **Kaul V**, Bittner K, Ullah A, Kothari S. Liquid nitrogen spray cryotherapy-based multimodal endoscopic management of dysplastic Barrett's esophagus and early esophageal neoplasia: retrospective review and long-term follow-up at an academic tertiary care referral center. *Dis Esophagus* 2020; **33** [PMID: [31909783](#) DOI: [10.1093/dote/doz095](#)]
- 17 **Chen AM**, Pasricha PJ. Cryotherapy for Barrett's esophagus: Who, how, and why? *Gastrointest Endosc Clin N Am* 2011; **21**: 111-118 [PMID: [21112501](#) DOI: [10.1016/j.giec.2010.09.007](#)]
- 18 **Dumot JA**, Greenwald BD. Cryotherapy for Barrett's esophagus: does the gas really matter? *Endoscopy* 2011; **43**: 432-433 [PMID: [21448854](#) DOI: [10.1055/s-0030-1256332](#)]
- 19 **Greenwald BD**, Lightdale CJ, Abrams JA, Horwhat JD, Chuttani R, Komanduri S, Upton MP, Appelman HD, Shields HM, Shaheen NJ, Sontag SJ. Barrett's esophagus: endoscopic treatments II. *Ann N Y Acad Sci* 2011; **1232**: 156-174 [PMID: [21950812](#) DOI: [10.1111/j.1749-6632.2011.06050.x](#)]
- 20 **Raju GS**, Ahmed I, Xiao SY, Brining D, Bhutani MS, Pasricha PJ. Graded esophageal mucosal ablation with cryotherapy, and the protective effects of submucosal saline. *Endoscopy* 2005; **37**: 523-526 [PMID: [15933923](#) DOI: [10.1055/s-2005-861312](#)]
- 21 **Johnston CM**, Schoenfeld LP, Mysore JV, Dubois A. Endoscopic spray cryotherapy: a new technique for mucosal ablation in the esophagus. *Gastrointest Endosc* 1999; **50**: 86-92 [PMID: [10555555](#) DOI: [10.1016/j.gie.1999.05.015](#)]



- 10385730 DOI: [10.1016/s0016-5107\(99\)70352-4](https://doi.org/10.1016/s0016-5107(99)70352-4)
- 22 **Booth CL**, Thompson KS. Barrett's esophagus: A review of diagnostic criteria, clinical surveillance practices and new developments. *J Gastrointest Oncol* 2012; **3**: 232-242 [PMID: [22943014](https://pubmed.ncbi.nlm.nih.gov/22943014/) DOI: [10.3978/j.issn.2078-6891.2012.028](https://doi.org/10.3978/j.issn.2078-6891.2012.028)]
- 23 **Hvid-Jensen F**, Pedersen L, Drewes AM, Sørensen HT, Funch-Jensen P. Incidence of adenocarcinoma among patients with Barrett's esophagus. *N Engl J Med* 2011; **365**: 1375-1383 [PMID: [21995385](https://pubmed.ncbi.nlm.nih.gov/21995385/) DOI: [10.1056/NEJMoa1103042](https://doi.org/10.1056/NEJMoa1103042)]
- 24 **Sharma P**, Shaheen NJ, Katzka D, Bergman JJGHM. AGA Clinical Practice Update on Endoscopic Treatment of Barrett's Esophagus With Dysplasia and/or Early Cancer: Expert Review. *Gastroenterology* 2020; **158**: 760-769 [PMID: [31730766](https://pubmed.ncbi.nlm.nih.gov/31730766/) DOI: [10.1053/j.gastro.2019.09.051](https://doi.org/10.1053/j.gastro.2019.09.051)]
- 25 **Becq A**, Camus M, Rahmi G, de Parades V, Marteau P, Dray X. Emerging indications of endoscopic radiofrequency ablation. *United European Gastroenterol J* 2015; **3**: 313-324 [PMID: [26279839](https://pubmed.ncbi.nlm.nih.gov/26279839/) DOI: [10.1177/2050640615571159](https://doi.org/10.1177/2050640615571159)]
- 26 **Dumot JA**, Greenwald BD. Argon plasma coagulation, bipolar cautery, and cryotherapy: ABC's of ablative techniques. *Endoscopy* 2008; **40**: 1026-1032 [PMID: [19065487](https://pubmed.ncbi.nlm.nih.gov/19065487/) DOI: [10.1055/s-0028-1103414](https://doi.org/10.1055/s-0028-1103414)]
- 27 **Frederiks CN**, Canto MI, Weusten BLAM. Updates in Cryotherapy for Barrett's Esophagus. *Gastrointest Endosc Clin N Am* 2021; **31**: 155-170 [PMID: [33213793](https://pubmed.ncbi.nlm.nih.gov/33213793/) DOI: [10.1016/j.giec.2020.09.005](https://doi.org/10.1016/j.giec.2020.09.005)]
- 28 **Johnston MH**, Eastone JA, Horwhat JD, Cartledge J, Mathews JS, Foggy JR. Cryoablation of Barrett's esophagus: a pilot study. *Gastrointest Endosc* 2005; **62**: 842-848 [PMID: [16301023](https://pubmed.ncbi.nlm.nih.gov/16301023/) DOI: [10.1016/j.gie.2005.05.008](https://doi.org/10.1016/j.gie.2005.05.008)]
- 29 **Greenwald BD**, Dumot JA, Horwhat JD, Lightdale CJ, Abrams JA. Safety, tolerability, and efficacy of endoscopic low-pressure liquid nitrogen spray cryotherapy in the esophagus. *Dis Esophagus* 2010; **23**: 13-19 [PMID: [19515183](https://pubmed.ncbi.nlm.nih.gov/19515183/) DOI: [10.1111/j.1442-2050.2009.00991.x](https://doi.org/10.1111/j.1442-2050.2009.00991.x)]
- 30 **Ramay FH**, Cui Q, Greenwald BD. Outcomes after liquid nitrogen spray cryotherapy in Barrett's esophagus-associated high-grade dysplasia and intramucosal adenocarcinoma: 5-year follow-up. *Gastrointest Endosc* 2017; **86**: 626-632 [PMID: [28235596](https://pubmed.ncbi.nlm.nih.gov/28235596/) DOI: [10.1016/j.gie.2017.02.006](https://doi.org/10.1016/j.gie.2017.02.006)]
- 31 **Jovani M**, Lee M, Hur C, Stump N, Chan AT, Nishioka NS. Mo1123 Cryotherapy (Trufreeze™) vs. Radio Frequency Ablation (Barrx™) for the Treatment of Barrett's Esophagus with High-Grade Dysplasia and/or Early Adenocarcinoma: Ad Interim Results of a Non-Inferiority Randomized Clinical Trial. *Gastrointest Endosc* 2018; **87**: AB408 [DOI: [10.1016/j.gie.2018.04.1884](https://doi.org/10.1016/j.gie.2018.04.1884)]
- 32 **Solomon SS**, Kothari S, Smallfield GB, Inamdar S, Stein P, Rodriguez VA, Sima AP, Bittner K, Zfass AM, Kaul V, Trindade AJ. Liquid Nitrogen Spray Cryotherapy is Associated With Less Postprocedural Pain Than Radiofrequency Ablation in Barrett's Esophagus: A Multicenter Prospective Study. *J Clin Gastroenterol* 2019; **53**: e84-e90 [PMID: [29351156](https://pubmed.ncbi.nlm.nih.gov/29351156/) DOI: [10.1097/MCG.0000000000000999](https://doi.org/10.1097/MCG.0000000000000999)]
- 33 **Thota PN**, Arora Z, Dumot JA, Falk G, Benjamin T, Goldblum J, Jang S, Lopez R, Vargo JJ. Cryotherapy and Radiofrequency Ablation for Eradication of Barrett's Esophagus with Dysplasia or Intramucosal Cancer. *Dig Dis Sci* 2018; **63**: 1311-1319 [PMID: [29524114](https://pubmed.ncbi.nlm.nih.gov/29524114/) DOI: [10.1007/s10620-018-5009-4](https://doi.org/10.1007/s10620-018-5009-4)]
- 34 **Fasullo M**, Shah T, Patel M, Mutha P, Zfass A, Lippman R, Smallfield G. Outcomes of Radiofrequency Ablation Compared to Liquid Nitrogen Spray Cryotherapy for the Eradication of Dysplasia in Barrett's Esophagus. *Dig Dis Sci* 2021 [PMID: [33954846](https://pubmed.ncbi.nlm.nih.gov/33954846/) DOI: [10.1007/s10620-021-06991-7](https://doi.org/10.1007/s10620-021-06991-7)]
- 35 **Canto MI**, Shin EJ, Khashab MA, Molena D, Okolo P, Montgomery E, Pasricha P. Safety and efficacy of carbon dioxide cryotherapy for treatment of neoplastic Barrett's esophagus. *Endoscopy* 2015; **47**: 591 [PMID: [25920007](https://pubmed.ncbi.nlm.nih.gov/25920007/) DOI: [10.1055/s-0034-1392200](https://doi.org/10.1055/s-0034-1392200)]
- 36 **Verbeek RE**, Vleggaar FP, Ten Kate FJ, van Baal JW, Siersema PD. Cryospray ablation using pressurized CO<sub>2</sub> for ablation of Barrett's esophagus with early neoplasia: early termination of a prospective series. *Endosc Int Open* 2015; **3**: E107-E112 [PMID: [26135648](https://pubmed.ncbi.nlm.nih.gov/26135648/) DOI: [10.1055/s-0034-1390759](https://doi.org/10.1055/s-0034-1390759)]
- 37 **Alshelleh M**, Raphael KL, Inamdar S, McKinley MJ, Trindade AJ. Cryoballoon and Cryospray Ablation Therapies are Equivalent for Eradication of Barrett's Esophagus. *Tech Innovations Gastrointest Endosc* 2021; **23**: 110-112 [DOI: [10.1016/j.tige.2020.07.004](https://doi.org/10.1016/j.tige.2020.07.004)]
- 38 **Sullivan R**, Mulki R, Peter S. The role of ablation in the treatment of dysplastic Barrett's esophagus. *Ther Adv Gastrointest Endosc* 2021; **14**: 26317745211049967 [PMID: [34708203](https://pubmed.ncbi.nlm.nih.gov/34708203/) DOI: [10.1177/26317745211049967](https://doi.org/10.1177/26317745211049967)]
- 39 **Sawas T**, Visrodia K, Zakko L, Leggett C, Wang KK. A Western Experience in the Use of a Novel CryoBalloon Focal Ablation System for the Management of Barrett's Neoplasia: 378. *Am J Gastroenterol* 2018; **113**: S220-S221
- 40 **van Munster SN**, Overwater A, Haidry R, Bisschops R, Bergman J, Weusten BL. 478 Cryoballoon Ablation of Dysplastic Barrett's Esophagus Causes Shorter Duration and Less Severe Post-Procedural Pain as Compared to Radiofrequency Ablation. *Gastrointest Endosc* 2018; **87**: AB81-AB82
- 41 **Canto MI**, Trindade AJ, Abrams J, Rosenblum M, Dumot J, Chak A, Iyer P, Diehl D, Khara HS, Corbett FS, McKinley M, Shin EJ, Waxman I, Infantolino A, Tofani C, Samarasena J, Chang K, Wang B, Goldblum J, Voltaggio L, Montgomery E, Lightdale CJ, Shaheen NJ. Multifocal Cryoballoon Ablation for Eradication of Barrett's Esophagus-Related Neoplasia: A Prospective Multicenter Clinical Trial. *Am J Gastroenterol* 2020; **115**: 1879-1890 [PMID: [33156107](https://pubmed.ncbi.nlm.nih.gov/33156107/) DOI: [10.14309/ajg.0000000000000822](https://doi.org/10.14309/ajg.0000000000000822)]

- 42 **Fuccio L**, Mussetto A, Laterza L, Eusebi LH, Bazzoli F. Diagnosis and management of gastric antral vascular ectasia. *World J Gastrointest Endosc* 2013; **5**: 6-13 [PMID: [23330048](#) DOI: [10.4253/wjge.v5.i1.6](#)]
- 43 **Gostout CJ**, Viggiano TR, Ahlquist DA, Wang KK, Larson MV, Balm R. The clinical and endoscopic spectrum of the watermelon stomach. *J Clin Gastroenterol* 1992; **15**: 256-263 [PMID: [1479175](#) DOI: [10.1097/00004836-199210000-00019](#)]
- 44 **Jabbari M**, Cherry R, Lough JO, Daly DS, Kinnear DG, Goresky CA. Gastric antral vascular ectasia: the watermelon stomach. *Gastroenterology* 1984; **87**: 1165-1170 [PMID: [6332757](#)]
- 45 **Dias de Castro F**, Boal Carvalho P, Cúrdia Gonçalves T, Magalhães J, Moreira MJ, Marinho C, Cotter J. Treating Gastric Antral Vascular Ectasia - When Argon Therapy Is Not Enough. *GE Port J Gastroenterol* 2016; **23**: 249-253 [PMID: [28868470](#) DOI: [10.1016/j.jpgc.2016.01.002](#)]
- 46 **Patel AA**, Trindade AJ, Diehl DL, Khara HS, Lee TP, Lee C, Sethi A. Nitrous oxide cryotherapy ablation for refractory gastric antral vascular ectasia. *United European Gastroenterol J* 2018; **6**: 1155-1160 [PMID: [30288277](#) DOI: [10.1177/2050640618783537](#)]
- 47 **Cho S**, Zanati S, Yong E, Cirocco M, Kandel G, Kortan P, May G, Marcon N. Endoscopic cryotherapy for the management of gastric antral vascular ectasia. *Gastrointest Endosc* 2008; **68**: 895-902 [PMID: [18640673](#) DOI: [10.1016/j.gie.2008.03.1109](#)]
- 48 **Kantsevoy SV**, Cruz-Correa MR, Vaughn CA, Jagannath SB, Pasricha PJ, Kalloo AN. Endoscopic cryotherapy for the treatment of bleeding mucosal vascular lesions of the GI tract: a pilot study. *Gastrointest Endosc* 2003; **57**: 403-406 [PMID: [12612530](#) DOI: [10.1067/mge.2003.115](#)]
- 49 **Trindade AJ**, Inamdar S, Sejpal DV. Nitrous oxide CryoBalloon therapy of refractory gastric antral vascular ectasia. *Endoscopy* 2017; **49**: 923-924 [PMID: [28679138](#) DOI: [10.1055/s-0043-111009](#)]
- 50 **Do NL**, Nagle D, Poylin VY. Radiation proctitis: current strategies in management. *Gastroenterol Res Pract* 2011; **2011**: 917941 [PMID: [22144997](#) DOI: [10.1155/2011/917941](#)]
- 51 **Sebastian S**, O'Connor H, O'Morain C, Buckley M. Argon plasma coagulation as first-line treatment for chronic radiation proctopathy. *J Gastroenterol Hepatol* 2004; **19**: 1169-1173 [PMID: [15377295](#) DOI: [10.1111/j.1440-1746.2004.03448.x](#)]
- 52 **Denton AS**, Andreyev HJ, Forbes A, Maher EJ. Systematic review for non-surgical interventions for the management of late radiation proctitis. *Br J Cancer* 2002; **87**: 134-143 [PMID: [12107832](#) DOI: [10.1038/sj.bjc.6600360](#)]
- 53 **Denton A**, Forbes A, Andreyev J, Maher EJ. Non surgical interventions for late radiation proctitis in patients who have received radical radiotherapy to the pelvis. *Cochrane Database Syst Rev* 2002; CD003455 [PMID: [11869662](#) DOI: [10.1002/14651858.CD003455](#)]
- 54 **Sarin A**, Safar B. Management of radiation proctitis. *Gastroenterol Clin North Am* 2013; **42**: 913-925 [PMID: [24280407](#) DOI: [10.1016/j.gtc.2013.08.004](#)]
- 55 **Moawad FJ**, Maydonovitch CL, Horwhat JD. Efficacy of cryospray ablation for the treatment of chronic radiation proctitis in a pilot study. *Dig Endosc* 2013; **25**: 174-179 [PMID: [23362977](#) DOI: [10.1111/j.1443-1661.2012.01355.x](#)]
- 56 **Tabaja L**, Sidani SM. Management of Radiation Proctitis. *Dig Dis Sci* 2018; **63**: 2180-2188 [PMID: [29948565](#) DOI: [10.1007/s10620-018-5163-8](#)]
- 57 **Hou JK**, Abudayyeh S, Shaib Y. Treatment of chronic radiation proctitis with cryoablation. *Gastrointest Endosc* 2011; **73**: 383-389 [PMID: [21295650](#) DOI: [10.1016/j.gie.2010.10.044](#)]
- 58 **Leiper K**, Morris AI. Treatment of radiation proctitis. *Clin Oncol (R Coll Radiol)* 2007; **19**: 724-729 [PMID: [17728120](#) DOI: [10.1016/j.clon.2007.07.008](#)]
- 59 **Karamanolis G**, Psatha P, Triantafyllou K. Endoscopic treatments for chronic radiation proctitis. *World J Gastrointest Endosc* 2013; **5**: 308-312 [PMID: [23858374](#) DOI: [10.4253/wjge.v5.i7.308](#)]
- 60 **Kachaamy T**, Prakash R, Kundranda M, Batish R, Weber J, Hendrickson S, Yoder L, Do H, Magat T, Nayar R, Gupta D, DaSilva T, Sangal A, Kothari S, Kaul V, Vashi P. Liquid nitrogen spray cryotherapy for dysphagia palliation in patients with inoperable esophageal cancer. *Gastrointest Endosc* 2018; **88**: 447-455 [PMID: [29750984](#) DOI: [10.1016/j.gie.2018.04.2362](#)]
- 61 **Ke Y**, van Munster SN, Chen J, Liu F, Zhao D, Li W, He S, Zhang Y, Dou L, Liu Y. 1031 Endoscopic Cryoballoon Ablation is Safe, Well-Tolerated and Highly Effective in the Eradication of Esophageal Squamous Cell Neoplasia. *Gastrointest Endosc* 2018; **87**: AB141-AB142 [DOI: [10.1016/j.gie.2018.04.1364](#)]
- 62 **Cash BD**, Johnston LR, Johnston MH. Cryospray ablation (CSA) in the palliative treatment of squamous cell carcinoma of the esophagus. *World J Surg Oncol* 2007; **5**: 34 [PMID: [17367523](#) DOI: [10.1186/1477-7819-5-34](#)]
- 63 **Tsai FC**, Ghorbani S, Greenwald BD, Jang S, Dumot JA, McKinley MJ, Shaheen NJ, Habr F, Wolfsen HC, Abrams JA, Lightdale CJ, Nishioka NS, Johnston MH, Zfass A, Coyle WJ. Safety and efficacy of endoscopic spray cryotherapy for esophageal cancer. *Dis Esophagus* 2017; **30**: 1-7 [PMID: [28881903](#) DOI: [10.1093/dote/dox087](#)]
- 64 **Ramay FH**, Shaheen NJ, Kaul V, Nieto J, Joshi V, Litle V, Fernando HC, Fukami N, Hoffman BJ, Bizakis C. Tu1147 Liquid Nitrogen Spray Cryotherapy for Palliation of Invasive Esophageal Carcinoma: Results from a Multicenter us Registry. *Gastrointest Endosc* 2018; **87**: AB541 [DOI: [10.1016/j.gie.2018.04.2177](#)]
- 65 **Prakash RK**, Kachaamy T, Ambrosius M, Magat T, Shin JS, Gupta D, Vashi PG. Tu1256 Impact of Liquid Nitrogen Endoscopic Spray Cryotherapy on Overall Survival in Metastatic Esophageal Cancer. *Gastrointest Endosc* 2017; **85**: AB603-AB604 [DOI: [10.1016/j.gie.2017.03.1394](#)]
- 66 **Roccato MK**, Duh E, Mai D, Chehade NEH, Hashimoto R, Samarasekera J. CryoDilation: A Novel

Treatment for Benign Esophageal Strictures Using Liquid Nitrogen Spray Cryotherapy: 1828. *Am J Gastroenterol* 2019; **114**: S1025-S1026 [DOI: [10.14309/01.ajg.0000596844.98021.7c](https://doi.org/10.14309/01.ajg.0000596844.98021.7c)]



## Is gastroscopy necessary before bariatric surgery?

Burhan Hakan Kanat, Serhat Doğan

**ORCID number:** Burhan Hakan Kanat 0000-0003-1168-0833; Serhat Doğan 0000-0002-3288-2963.

**Author contributions:** Kanat BH and Doğan S contributed equally to this work; all authors have read and approved the final manuscript.

**Conflict-of-interest statement:** The authors declare that they have no conflict of interest to disclose.

**Country/Territory of origin:** Turkey

**Specialty type:** Surgery

**Provenance and peer review:** Invited article; Externally peer reviewed.

**Peer-review model:** Single blind

**Peer-review report's scientific quality classification**

Grade A (Excellent): 0  
Grade B (Very good): B  
Grade C (Good): 0  
Grade D (Fair): D, D  
Grade E (Poor): 0

**Open-Access:** This article is an open-access article that was selected by an in-house editor and fully peer-reviewed by external reviewers. It is distributed in accordance with the Creative Commons Attribution NonCommercial (CC BY-NC 4.0) license, which permits others to distribute, remix, adapt, build upon this work non-commercially,

**Burhan Hakan Kanat, Serhat Doğan,** Department of General Surgery, Malatya Turgut Özal University, School of Medicine, Malatya 44100, Turkey

**Corresponding author:** Burhan Hakan Kanat, MD, Associate Professor, Chief Doctor, Department of General Surgery, Malatya Turgut Özal University, School of Medicine, Alacakapı Mahallesi Kırkgöz Caddesi No. 70, Malatya 44100, Turkey.  
[burhankanat@hotmail.com](mailto:burhankanat@hotmail.com)

### Abstract

Obesity is the abnormal accumulation of fat or adipose tissue in the body. It has become a serious health problem in the world in the last 50 years and is considered a pandemic. Body mass index is a widely used classification. Thus, obese individuals can be easily classified and standardized. Obesity is the second cause of preventable deaths after smoking. Obesity significantly increases mortality and morbidity. We thought of preparing a publication about routine procedures for the preoperative evaluation of obesity. The question that we asked as bariatric and metabolic surgeons but which was not exactly answered in the literature was "Is esophagogastroduodenoscopy (EGD) necessary before bariatric surgery?" We found different answers in our literature review. The European Association of Endoscopic Surgery guidelines recommend EGD for all bariatric procedures. They strongly recommend it for Roux-en-Y gastric bypass (RYGB). As a result of a recent study by the members of the British Obesity & Metabolic Surgery Society, preoperative EGD is routinely recommended for patients undergoing sleeve gastrectomy, even if they are asymptomatic, but not recommended for RYGB. It is recommended for symptomatic patients scheduled for RYGB. According to the International Sleeve Gastrectomy Expert Panel Consensus Statement, preoperative EGD is definitely recommended for patients scheduled for sleeve gastrectomy, but its routine use for RYGB is controversial. However, a different view is that the American Society for Gastrointestinal Endoscopy recommends endoscopy only for symptomatic patients scheduled for bariatric surgery. In the literature, the primary goal of EGD recommended for sleeve gastrectomy has been interpreted as determining esophagitis caused by gastroesophageal reflux. In the light of the literature, it is stated that this procedure is not necessary in America, while it is routinely recommended in the European continent. Considering medicolegal cases that may occur in the future, we are in favor of performing EGD before bariatric surgery. In conclusion, EGD before bariatric surgery is insurance for both patients and physicians. There is a need for larger and prospective studies to reach more precise conclusions on the subject.



and license their derivative works on different terms, provided the original work is properly cited and the use is non-commercial. See: <http://creativecommons.org/licenses/by-nc/4.0/>

**Received:** February 18, 2021

**Peer-review started:** February 18, 2021

**First decision:** May 5, 2021

**Revised:** May 26, 2021

**Accepted:** December 22, 2021

**Article in press:** December 22, 2021

**Published online:** January 16, 2022

**P-Reviewer:** Ghannam WM, Kidambi TD, Tulumović E

**S-Editor:** Zhang H

**L-Editor:** Wang TQ, Kerr C

**P-Editor:** Zhang H



**Key Words:** Bariatric surgery; Preoperative endoscopy; Preoperative bariatric preparation; Esophagogastroduodenoscopy

©The Author(s) 2022. Published by Baishideng Publishing Group Inc. All rights reserved.

**Core tip:** The European Association of Endoscopic Surgery guidelines recommend esophagogastroduodenoscopy (EGD) for all bariatric procedures. They strongly recommend it for Roux-en-Y gastric bypass (RYGB). The British Obesity & Metabolic Surgery Society recommends routine perioperative EGD for sleeve gastrectomy (SG), even if patients are asymptomatic, but not for RYGB. It is recommended for symptomatic patients scheduled for RYGB. According to the International Sleeve Gastrectomy Expert Panel Consensus Statement, preoperative EGD is definitely recommended for SG, but its routine use for RYGB is controversial. The American Gastrointestinal Endoscopy Association recommends that endoscopy be performed only on symptomatic patients scheduled for bariatric surgery.

**Citation:** Kanat BH, Doğan S. Is gastroscopy necessary before bariatric surgery? *World J Gastrointest Endosc* 2022; 14(1): 29-34

**URL:** <https://www.wjgnet.com/1948-5190/full/v14/i1/29.htm>

**DOI:** <https://dx.doi.org/10.4253/wjge.v14.i1.29>

## INTRODUCTION

Obesity is the accumulation of excess fat in the body. It is defined by body mass index (BMI). BMI is calculated by dividing body weight in kilograms by the square of height in meters. It is an easy and practical method. Obesity is a serious global public health problem and is considered a pandemic. It is the second most common preventable cause of death after smoking[1-5].

According to the data of the World Health Organization, it is predicted that in 2030, approximately 60% of the world's population will be affected by and 1.1 billion people will be obese[6]. It has been reported that the prevalence of obesity in Turkey has increased in parallel with that in other European countries and has reached high rates of 37% of overweight individuals and 36% of obese individuals[1]. Obesity causes more than 700 billion dollars of health expenditure globally every year.

Studies such as waist-to-hip ratio, skinfold thickness, bioelectrical impedance analysis, computed tomography, magnetic resonance imaging, dual energy radiographic absorptiometry, and air densitometry are used to define obesity[2,4,7-9].

The etiology of obesity is multifactorial. Genetic and environmental factors are diverse.

Obesity is a disease that is difficult to treat. It is necessary to follow step by step the treatment algorithm. The first step includes healthy eating and lifestyle changes. Exercise is added to the first step treatment in second-line therapy. Behavioral changes are added to the third-line treatment. In the fourth-line treatment, additional drug therapy is added to these. Surgical treatment remains the only option for patients who fail despite all these treatments.

Surgery is not completely safe and can cause fatal complications. The disadvantages of drug treatments are the high number of undesirable side effects, limited effects, and rapid weight gain when patients stop taking drugs[10,11]. The aim of surgical treatment is to reduce morbidity and mortality due to obesity. Providing long-term permanent weight loss with bariatric surgery reduces the metabolic effects of obesity and increases survival. Bariatric surgery can reduce > 50% of excess weight. Compared to nonsurgical methods, surgery causes more effective and permanent weight loss in the long term. In a study conducted by Çoşkun *et al*[12], it was shown that in obese patients who underwent gastric bypass, it provided a 16.4 kg/m<sup>2</sup> reduction in BMI in 1 year.

Today, it is generally accepted that bariatric surgery is the most effective and permanent method used in the treatment of obesity. Studies on bariatric surgery have been carried out and clear information and algorithms about which surgical procedure to choose for which patient, postoperative complications and what should be

**Table 1 Benefits of gastroscopy before bariatric surgery**

Possible finding	Effect
Detection of gastroesophageal reflux disease	Selection of surgical technique
Evaluation of esophagitis	Selection of surgical technique
Evaluation of gastric mucosa (with biopsy result)	Selection of surgical technique
	Selection of stapler to be used
Evaluation of gastric outlet obstruction	Selection of surgical technique
	Prediction of additional procedure
<i>Helicobacter pylori</i> test	Treatment plan
Detection of possible malignancy	Canceling the surgery
Polyp excisions	Postponing the surgery until the pathology result
Detection of alkaline reflux gastritis	Selection of surgical technique
	Treatment planning
Detection of hiatal hernia	Selection of surgical technique
	Prediction of additional procedure

considered when dealing with them, and postoperative diet and follow-up issues have been created by various centers. However, this is not the case for preoperative preparation. Routine preoperative examinations are performed in obese patients before each operation.

The main theme of this article is esophagogastroduodenoscopy (EGD), which is part of the gastrointestinal evaluation before bariatric surgery. Our aim is to clarify whether routine EGD examination is necessary before bariatric surgery. In our clinic, we perform routine EGD in all patients before bariatric surgery and colonoscopy in patients who need it.

However, while discussing in the article, we made an independent evaluation in the light of the literature, except for our practice.

## IS GASTROSCOPY NECESSARY BEFORE BARIATRIC SURGERY?

Routine preoperative EGD screening is controversial in patients undergoing bariatric surgery. There are surgical societies that recommend and do not recommend routine EGD screening to detect suspected gastric lesions/findings. To begin with, we should state the views of two separate associations.

The European Association of Endoscopic Surgery guidelines recommends EGD for all bariatric procedures, and strongly recommends it for Roux N-Y gastric bypass (RNYGB)[13]. The American Gastrointestinal Endoscopy Association recommends endoscopy only for symptomatic patients scheduled for bariatric surgery[14].

Schigt *et al*[15] stated that the standard preoperative evaluation of EGD in bariatric patients is not indicated because a high number of patients need to be screened to find clinically significant abnormalities. Gómez *et al*[16] identified age > 55 years and gastroesophageal reflux disease as risk factors on endoscopy screening. They concluded that although abnormalities are common in preoperative EGD, they rarely change the surgical treatment technique due to these findings. Due to the poor correlation between patients' complaints and endoscopic findings, routine preoperative endoscopy may be useful in detecting both lesion and inflammation[17-19].

Schlottmann *et al*[20] reported that 29.4% of asymptomatic patients were found to have abnormal findings by EGD.

The rate of conditions such as hiatal hernia, gastritis, or esophagitis detected during preoperative EGD of a patient who will undergo bariatric surgery with or without symptoms is as high as 62%–67%. Preoperative EGD is important before bariatric surgery[21]. Malignant findings are not commonly detected by EGD in patients undergoing bariatric surgery. For example, Wolter *et al*[22] in a study of 801 patients, found that malignancy was observed in 0.5% of all patients. D'Hondt *et al*[23] found two cases of distal adenocarcinoma in the esophagus during preoperative EGD in 371

patients with gastric banding. Praveenraj *et al*[24] did not find malignant lesions during EGD in 613 bariatric patients. However, they reported a case of low-grade gastric-mucosa-associated lymphoid tissue lymphoma after histopathological evaluation of tissue biopsies.

Wolter *et al*[22] recommends performing routine endoscopy before bariatric surgery to predict possible malignant lesions. Mihmanli *et al*[25] in their series of 157 cases, reported that one case changed the operation type as a result of preoperative endoscopic examination. Gómez *et al*[16] have changed only 1.7% of surgical operation types in routine bariatric preoperative endoscopy.

The results of histopathological examination of the excised gastric sample can give information about the prevalence of malignant cases, especially after laparoscopic sleeve gastrectomy (LSG). In a meta-analysis of 48 different articles, it was reported that the rate of total surgical procedures ranged from 4% to 7.8%. According to the pathology results of all cases, malignancy was found in 0.4%[26].

Yormaz *et al*[27] studied 232 patients and argued that performing preoperative EGD would decrease postoperative complications. They talked about the importance of EGD findings in surgery selection. They recommended preoperative EGD to only symptomatic patients.

A recent study of Members of the British Obesity & Metabolic Surgery Society found that 10% of clinics dealing with bariatric surgery in the UK considered preoperative EGD to be completely unnecessary, and 31% showed that they included it in their routine preoperative evaluations. Important findings were detected in 23% of the patients scheduled for SG. As a result, the British Obesity & Metabolic Surgery Society recommends EGD routinely in the preoperative period, even if patients undergoing SG are asymptomatic, but not for RNYGB. They recommend RNYGB to planned symptomatic patients[28].

It is important to determine esophagitis with gastroesophageal reflux as the main purpose of EGD recommended for SG. It is estimated that sleeve gastrectomy in such patients worsens the situation and increases the risk of cancer in the long term[29]. Already, according to the International Sleeve Gastrectomy Expert Panel Consensus Statement, severe esophagitis and Barrett esophagus are contraindications for SG[30]. Therefore, preoperative EGD is definitely recommended for patients who are planned to undergo SG. In contrast, routine use of RNYGB is controversial.

Mihmanlı *et al*[25] retrospectively evaluated 157 patients who underwent EGD before bariatric surgery (SG or RNYGB) between March 2013 and March 2015. They obtained abnormal findings in 67% of these patients. Only 17% of these patients were symptomatic cases. EGD findings classified 54% of gastritis, 10% of esophagitis, 17% of hiatal hernia, 5% of gastric ulcer, and 3% of other cases. *Helicobacter pylori* was positive in 62% of the patients.

Mazahreh *et al*[31] prospectively evaluated 219 patients scheduled for LSG, and 1 year later, all individuals were evaluated for the presence of symptomatic gastroesophageal reflux disease, and no significant difference was found between the two groups, so they stated that they did not require routine EGD. Gastric biopsy was performed on 148 patients. Chronic inflammation was found in 65%, inflammatory activity in 32%, and intestinal metaplasia in 2%. While endoscopic findings caused the operation to be delayed in 54% of the patients, it caused the surgical procedure to be changed in one patient due to the heterotopic pancreatic tissue. Mihmanlı *et al*[25] showed that more than half of the obese patients (54%) had a disease that required perioperative treatment (67%) and recommended EGD before bariatric surgery.

While EGD is not routinely recommended before bariatric surgery in the American continent, it is recommended in the European continent. In cases where it is not possible to see the remaining part of the stomach such as mini-gastric bypass, it is useful to make the final evaluation of the stomach.

Performing EGD in a patient with no complaints has negative aspects in terms of time, cost, and any complications that may develop during the procedure. Of course, the advantages of this process are too many to ignore, such as the capture of a premalignant or malignant lesion. It will provide early diagnosis and treatment. It will improve the patient's quality of life.

The cost-benefit analysis of routine EGD in each patient may also be a matter of debate, which naturally will increase the cost of this procedure.

## CONCLUSION

EGD before bariatric surgery is an insurance for both patients and physicians. When

endoscopy is used perioperatively, it will be more comfortable to use preoperatively. Unfortunately, a missed case of stomach tumor can incur a great cost. This is also life-threatening. Benefits of gastroscopy before bariatric surgery are summarized in [Table 1](#). Larger and prospective studies are needed to yield more precise results on the subject. Regional, national and international associations should create an algorithm on this issue within a short time. Thus, a worldwide standard should be provided for health care. An end must be found to these long-running discussions.

## REFERENCES

- 1 **Mercado-Gonzales SI**, Carpio-Rodríguez AN, Carrillo-Larco RM, Bernabé-Ortiz A. Sleep Duration and Risk of Obesity by Sex: Nine-Year Follow-Up of the Young Lives Study in Peru. *Child Obes* 2019; **15**: 237-243 [PMID: [30810346](#) DOI: [10.1089/chi.2018.0247](#)]
- 2 **Shiozawa B**, Madsen C, Banaag A, Patel A, Koehlmoos T. Body Mass Index Effect on Health Service Utilization Among Active Duty Male United States Army Soldiers. *Mil Med* 2019; **184**: 447-453 [PMID: [30811530](#) DOI: [10.1093/milmed/usz032](#)]
- 3 **Al-Nimr RI**. Optimal Protein Intake during Weight Loss Interventions in Older Adults with Obesity. *J Nutr Gerontol Geriatr* 2019; **38**: 50-68 [PMID: [30806592](#) DOI: [10.1080/21551197.2018.1544533](#)]
- 4 **Walsh K**, Grech C, Hill K. Health advice and education given to overweight patients by primary care doctors and nurses: A scoping literature review. *Prev Med Rep* 2019; **14**: 100812 [PMID: [30805277](#) DOI: [10.1016/j.pmedr.2019.01.016](#)]
- 5 **Kelly T**, Yang W, Chen CS, Reynolds K, He J. Global burden of obesity in 2005 and projections to 2030. *Int J Obes (Lond)* 2008; **32**: 1431-1437 [PMID: [18607383](#) DOI: [10.1038/ijo.2008.102](#)]
- 6 **Satman I**, Omer B, Tutuncu Y, Kalaca S, Gedik S, Dinccag N, Karsidag K, Genc S, Telci A, Canbaz B, Turker F, Yilmaz T, Cakir B, Tuomilehto J; TURDEP-II Study Group. Twelve-year trends in the prevalence and risk factors of diabetes and prediabetes in Turkish adults. *Eur J Epidemiol* 2013; **28**: 169-180 [PMID: [23407904](#) DOI: [10.1007/s10654-013-9771-5](#)]
- 7 **Pasarica M**, Topping D. An Evidence-Based Approach to Teaching Obesity Management to Medical Students. *MedEdPORTAL* 2017; **13**: 10662 [PMID: [30800862](#) DOI: [10.15766/mep\\_2374-8265.10662](#)]
- 8 **Adan RA**, Vanderschuren LJ, la Fleur SE. Anti-obesity drugs and neural circuits of feeding. *Trends Pharmacol Sci* 2008; **29**: 208-217 [PMID: [18353447](#) DOI: [10.1016/j.tips.2008.01.008](#)]
- 9 **Bianchi P**. Reply to Z. Bayraktar. *J Matern Fetal Neonatal Med* 2019; **1** [PMID: [31875729](#) DOI: [10.1080/14767058.2019.1704249](#)]
- 10 **Çoşkun H**, Bostancı Ö, Dilege E, Yüksel E, Mıhmanlı M. Morbid obezite tedavisinde gastrik bypass uygulamasının erken postopertaif dönem sonuçları. *Ulusal Cerrahi Dergisi* 2006; **22**: 59-62
- 11 **Sauerland S**, Angrisani L, Belachew M, Chevallier JM, Favretti F, Finer N, Fingerhut A, Garcia Caballero M, Guisado Macias JA, Mittermair R, Morino M, Msika S, Rubino F, Tacchino R, Weiner R, Neugebauer EA; European Association for Endoscopic Surgery. Obesity surgery: evidence-based guidelines of the European Association for Endoscopic Surgery (EAES). *Surg Endosc* 2005; **19**: 200-221 [PMID: [15580436](#) DOI: [10.1007/s00464-004-9194-1](#)]
- 12 **Smeltzer SC**, Bare BG, Hinkle JL, Cheever KH. Gastrointestinal intubation and special nutritional modalities. In: *Textbook of Medical-Surgical Nursing*. Philadelphia: Lippicott Williams&Wilkins, 2008: 1203-1227
- 13 **Voelker M**. Assessing quality of life in gastric bypass clients. *J Perianesth Nurs* 2004; **19**: 89-101; quiz 102 [PMID: [15069648](#) DOI: [10.1016/j.jopan.2004.01.005](#)]
- 14 **ASGE Standards of Practice Committee**. Anderson MA, Gan SI, Fanelli RD, Baron TH, Banerjee S, Cash BD, Dominitz JA, Harrison ME, Ikenberry SO, Jagannath SB, Lichtenstein DR, Shen B, Lee KK, Van Guilder T, Stewart LE. Role of endoscopy in the bariatric surgery patient. *Gastrointest Endosc* 2008; **68**: 1-10 [PMID: [18577471](#) DOI: [10.1016/j.gie.2008.01.028](#)]
- 15 **Schigt A**, Coblijn U, Lagarde S, Kuiken S, Scholten P, van Wagenveld B. Is esophagogastroduodenoscopy before Roux-en-Y gastric bypass or sleeve gastrectomy mandatory? *Surg Obes Relat Dis* 2014; **10**: 411-417 [PMID: [24951067](#) DOI: [10.1016/j.soard.2014.01.015](#)]
- 16 **Gómez V**, Bhalla R, Heckman MG, Florit PT, Diehl NN, Rawal B, Lynch SA, Loeb DS. Routine Screening Endoscopy before Bariatric Surgery: Is It Necessary? *Bariatric Surg Pract Patient Care* 2014; **9**: 143-149 [PMID: [25516819](#) DOI: [10.1089/bari.2014.0024](#)]
- 17 **Sharaf RN**, Weinshel EH, Bini EJ, Rosenberg J, Sherman A, Ren CJ. Endoscopy plays an important preoperative role in bariatric surgery. *Obes Surg* 2004; **14**: 1367-1372 [PMID: [15603653](#) DOI: [10.1381/0960892042583806](#)]
- 18 **Küper MA**, Kratt T, Kramer KM, Zdichavsky M, Schneider JH, Glatzle J, Stüker D, Königsrainer A, Brücher BL. Effort, safety, and findings of routine preoperative endoscopic evaluation of morbidly obese patients undergoing bariatric surgery. *Surg Endosc* 2010; **24**: 1996-2001 [PMID: [20135170](#) DOI: [10.1007/s00464-010-0893-5](#)]
- 19 **Csendes A**, Burgos AM, Smok G, Beltran M. Endoscopic and histologic findings of the foregut in 426 patients with morbid obesity. *Obes Surg* 2007; **17**: 28-34 [PMID: [17355765](#) DOI: [10.1007/s11695-007-9002-9](#)]
- 20 **Schlottmann F**, Sadava EE, Reino R, Galvarini M, Buxhoeveden R. Preoperative endoscopy in



- bariatric patients may change surgical strategy. *Acta Gastroenterol Latinoam* 2017; **47**: 117-121
- 21 **Yıldız İ**, Savaş Koca Y. Retrospective Analysis of Upper Gastrointestinal Endoscopy Application Performed by General Surgeon: One Physician Experience. *SDÜ Sağlık Bilimleri Dergisi* 2016; **3**: 15-17 [DOI: [10.22312/sbed.43496](https://doi.org/10.22312/sbed.43496)]
- 22 **Wolter S**, Duprée A, Miro J, Schroeder C, Jansen MI, Schulze-Zur-Wiesch C, Groth S, Izbicki J, Mann O, Busch P. Upper Gastrointestinal Endoscopy prior to Bariatric Surgery-Mandatory or Expendable? *Obes Surg* 2017; **27**: 1938-1943 [PMID: [28243860](https://pubmed.ncbi.nlm.nih.gov/28243860/) DOI: [10.1007/s11695-017-2622-9](https://doi.org/10.1007/s11695-017-2622-9)]
- 23 **D'Hondt M**, Steverlynck M, Pottel H, Elewaut A, George C, Vansteenkiste F, Van Rooy F, Devriendt D. Value of preoperative esophagogastroduodenoscopy in morbidly obese patients undergoing laparoscopic Roux-en-Y gastric bypass. *Acta Chir Belg* 2013; **113**: 249-253 [PMID: [24224432](https://pubmed.ncbi.nlm.nih.gov/24224432/) DOI: [10.1080/00015458.2013.11680922](https://doi.org/10.1080/00015458.2013.11680922)]
- 24 **Praveenraj P**, Gomes RM, Kumar S, Senthilnathan P, Parathasarathi R, Rajapandian S, Palanivelu C. Diagnostic Yield and Clinical Implications of Preoperative Upper Gastrointestinal Endoscopy in Morbidly Obese Patients Undergoing Bariatric Surgery. *J Laparoendosc Adv Surg Tech A* 2015; **25**: 465-469 [PMID: [25942627](https://pubmed.ncbi.nlm.nih.gov/25942627/) DOI: [10.1089/lap.2015.0041](https://doi.org/10.1089/lap.2015.0041)]
- 25 **Mihmanli M**, Yazici P, Isil G, Tanik C. Should We Perform Preoperative Endoscopy Routinely in Obese Patients Undergoing Bariatric Surgery? *Bariatric Surg Pract Patient Care* 2016; **11**: 73-77 [DOI: [10.1089/bari.2015.0050](https://doi.org/10.1089/bari.2015.0050)]
- 26 **Bennett S**, Gostimir M, Shorr R, Mallick R, Mamazza J, Neville A. The role of routine preoperative upper endoscopy in bariatric surgery: a systematic review and meta-analysis. *Surg Obes Relat Dis* 2016; **12**: 1116-1125 [PMID: [27320221](https://pubmed.ncbi.nlm.nih.gov/27320221/) DOI: [10.1016/j.soard.2016.04.012](https://doi.org/10.1016/j.soard.2016.04.012)]
- 27 **Yormaz S**, Yılmaz H. Midenin endoskopik patolojileri. *Gastrointestinal Sistem Endoskopisi* 2016; 157-244
- 28 **Saarinén T**, Kettunen U, Pietiläinen KH, Juuti A. Is preoperative gastroscopy necessary before sleeve gastrectomy and Roux-en-Y gastric bypass? *Surg Obes Relat Dis* 2018; **14**: 757-762 [PMID: [29477376](https://pubmed.ncbi.nlm.nih.gov/29477376/) DOI: [10.1016/j.soard.2018.01.021](https://doi.org/10.1016/j.soard.2018.01.021)]
- 29 **Genco A**, Soricelli E, Casella G, Maselli R, Castagneto-Gissey L, Di Lorenzo N, Basso N. Gastroesophageal reflux disease and Barrett's esophagus after laparoscopic sleeve gastrectomy: a possible, underestimated long-term complication. *Surg Obes Relat Dis* 2017; **13**: 568-574 [PMID: [28089434](https://pubmed.ncbi.nlm.nih.gov/28089434/) DOI: [10.1016/j.soard.2016.11.029](https://doi.org/10.1016/j.soard.2016.11.029)]
- 30 **Stenard F**, Iannelli A. Laparoscopic sleeve gastrectomy and gastroesophageal reflux. *World J Gastroenterol* 2015; **21**: 10348-10357 [PMID: [26420961](https://pubmed.ncbi.nlm.nih.gov/26420961/) DOI: [10.3748/wjg.v21.i36.10348](https://doi.org/10.3748/wjg.v21.i36.10348)]
- 31 **Mazahreh TS**, Aleshawi AJ, Al-Zoubi NA, Allouh MZ, Jadallah KA, Elayyan R, Novotny NM. Preoperative esophagogastroduodenoscopy in patients without reflux symptoms undergoing laparoscopic sleeve gastrectomy: utility or futility? *Clin Exp Gastroenterol* 2019; **12**: 295-301 [PMID: [31456645](https://pubmed.ncbi.nlm.nih.gov/31456645/) DOI: [10.2147/CEG.S216188](https://doi.org/10.2147/CEG.S216188)]



## Current role of endoscopic ultrasound in the diagnosis and management of pancreatic cancer

Federico Salom, Frédéric Prat

**ORCID number:** Federico Salom 0000-0002-6377-0454; Frédéric Prat 0000-0002-6018-0491.

**Author contributions:** Salom F was responsible for the preparation of the manuscript; Prat F was responsible for revising and final approval of the article; all authors agree with the final version of this manuscript.

**Conflict-of-interest statement:** The authors of this manuscript have no conflicts of interest to disclose.

**Country/Territory of origin:** Costa Rica

**Specialty type:** Gastroenterology and hepatology

**Provenance and peer review:** Invited article; Externally peer reviewed.

**Peer-review model:** Single blind

**Peer-review report's scientific quality classification**

Grade A (Excellent): 0  
Grade B (Very good): 0  
Grade C (Good): 0  
Grade D (Fair): 0  
Grade E (Poor): 0

**Open-Access:** This article is an open-access article that was selected by an in-house editor and fully peer-reviewed by external

**Federico Salom**, Department of Gastroenterology, Hospital Mexico, Uruca 1641-2050, San Jose, Costa Rica

**Frédéric Prat**, Service d'Endoscopie, Hopital Beaujon, Université Paris et INSERM U1016, Clichy 92118, Paris, France

**Corresponding author:** Federico Salom, MD, Medical Assistant, Department of Gastroenterology, Hospital Mexico, Avenida 41, Transversal 74, Barrio Arboles, Uruca 1641-2050, San Jose, Costa Rica. [fedesalom@yahoo.com](mailto:fedesalom@yahoo.com)

### Abstract

Endoscopic ultrasound (EUS) has emerged as an invaluable tool for the diagnosis, staging and treatment of pancreatic ductal adenocarcinoma (PDAC). EUS is currently the most sensitive imaging tool for the detection of solid pancreatic tumors. Conventional EUS has evolved, and new imaging techniques, such as contrast-enhanced harmonics and elastography, have been developed to improve diagnostic accuracy during the evaluation of focal pancreatic lesions. More recently, evaluation with artificial intelligence has shown promising results to overcome operator-related flaws during EUS imaging evaluation. Currently, an appropriate diagnosis is based on a proper histological assessment, and EUS-guided tissue acquisition is the standard procedure for pancreatic sampling. Newly developed cutting needles with core tissue procurement provide the possibility of molecular evaluation for personalized oncological treatment. Interventional EUS has modified the therapeutic approach, primarily for advanced pancreatic cancer. EUS-guided fiducial placement for local targeted radiotherapy treatment or EUS-guided radiofrequency ablation has been developed for local treatment, especially for patients with pancreatic cancer not suitable for surgical resection. Additionally, EUS-guided therapeutic procedures, such as celiac plexus neurolysis for pain control and EUS-guided biliary drainage for biliary obstruction, have dramatically improved in recent years toward a more effective and less invasive procedure to palliate complications related to PDAC. All the current benefits of EUS in the diagnosis and management of PDAC will be thoroughly discussed.

**Key Words:** Endoscopic ultrasound; Contrast-enhanced harmonic; Elastography; Artificial intelligence; Radiofrequency ablation; Celiac plexus neurolysis; Biliary drainage

reviewers. It is distributed in accordance with the Creative Commons Attribution NonCommercial (CC BY-NC 4.0) license, which permits others to distribute, remix, adapt, build upon this work noncommercially, and license their derivative works on different terms, provided the original work is properly cited and the use is noncommercial. See: <http://creativecommons.org/licenses/bync/4.0/>

**Received:** May 5, 2021

**Peer-review started:** May 5, 2021

**First decision:** June 17, 2021

**Revised:** July 3, 2021

**Accepted:** December 21, 2021

**Article in press:** December 21, 2021

**Published online:** January 16, 2022

**P-Reviewer:** Kuraoka N

**S-Editor:** Fan JR

**L-Editor:** A

**P-Editor:** Fan JR



©The Author(s) 2022. Published by Baishideng Publishing Group Inc. All rights reserved.

**Core Tip:** Endoscopic ultrasound (EUS) is currently an essential tool in the diagnostic work-up and treatment of pancreatic cancer. Contrast-enhanced harmonics, elastography and artificial intelligence provide additional information in the evaluation of focal pancreatic lesions to improve diagnostic accuracy during EUS evaluation. Interventional EUS has dramatically improved the palliative treatment of patients with pancreatic cancer, basically for local ablation therapies, adequate pain control with celiac plexus neurolysis and EUS-guided biliary drainage for the treatment of biliary obstruction.

**Citation:** Salom F, Prat F. Current role of endoscopic ultrasound in the diagnosis and management of pancreatic cancer. *World J Gastrointest Endosc* 2022; 14(1): 35-48

**URL:** <https://www.wjgnet.com/1948-5190/full/v14/i1/35.htm>

**DOI:** <https://dx.doi.org/10.4253/wjge.v14.i1.35>

## INTRODUCTION

Pancreatic cancer is a serious oncological condition with a very poor outcome and survival. Pancreatic ductal adenocarcinoma (PDAC) is the most frequent pancreatic cancer, which represents 85% of the pathological diagnoses[1]. It is the 14<sup>th</sup> most common cancer and has the 7<sup>th</sup> highest cancer-related mortality in the world[2], and it has the fourth highest mortality in the United States[3]. The incidence is increasing, mainly in the Western world. It is predicted to increase to the second most common cause of cancer-related death in the United States and Western Europe by 2030[4]. The 5-year survival rate is very low, ranging from 2% to 9%. The most important factor that influences survival is tumor stage at diagnosis, although only 20% of patients are candidates for surgical resection at the time of diagnosis[5,6]. Its indolent clinical presentation, proximity to major vessels and absence of accurate serum markers and imaging modalities for early diagnosis are features that complicate early detection and screening for this severe disease. However, an accurate histological diagnosis and proper staging are essential in the treatment strategy of pancreatic cancer.

Multidetector computed tomography (MDCT) is the mainstay imaging technique for the evaluation of solid pancreatic lesions suggestive of potential PDAC, not so much for adequate characterization of the lesion as for accurate staging of potential malignant disease[7]. Preoperative evaluation for surgical resectability is currently based on MDCT staging[8]. Magnetic resonance imaging (MRI) is also an interesting imaging modality, but it does not reach the accuracy of MDCT with regard to resectability and particular vascular involvement[9].

Endoscopic ultrasound (EUS) was introduced in the 1980s as a high-precision tool for the analysis of the gastrointestinal wall and adjacent structures. High-quality images that have dramatically improved over time and the proximity of the transducer to the pancreatic parenchyma make EUS an invaluable tool for the description of pancreatic parenchyma and, thus, for pancreatic cancer diagnosis and staging.

The performance of EUS has been compared with that of computed tomography (CT) for pancreatic cancer staging. A meta-analysis did not find any difference in determining tumor resectability when these two techniques were compared[10]. However, rapid and recent progress in CT technology and the ability to review CT scan imaging studies during multidisciplinary meetings for treatment planning make CT the method of choice for initial staging and subsequent follow-up. In contrast, EUS has a higher sensitivity for the detection of solid pancreatic tumors, mainly for lesions under 2 cm in diameter, when compared with CT and MRI[11]. Hence, EUS is the preferred imaging technique for the screening of pancreatic cancer in high-risk populations[12]. Due to the benefits of EUS imaging provides in pancreatic cancer evaluation, many additional technological tools have been developed in recent years to try to improve the quality of EUS imaging and increase the diagnostic accuracy of this technique. In addition, the availability of large working channel linear array probes, or “therapeutic EUS scopes”, has opened a new range of possibilities beyond tissue acquisition for an accurate pathological diagnosis. It is also highly useful for therapeutic interventions, mainly for the palliation of pancreatic cancer-associated

symptoms or to deliver targeted local treatment. The role of EUS in the evaluation and treatment of pancreatic cancer will be thoroughly discussed.

## ANCILLARY EUS IMAGING TECHNIQUES FOR PANCREATIC CANCER EVALUATION

### ***Contrast-enhanced harmonic EUS***

Contrast-enhanced (CE) harmonic EUS is an ultrasonographic technique that uses a microbubble-based contrast agent (Sonovue™, Sonazoid™ or Definity™, depending on local market availability) to visualize vascularization and perfusion patterns in the liver, pancreatic parenchyma or lymph nodes. This technique was made available for EUS during the late 2000s. Harmonic components of the signal generated by intravenously injected microbubbles improve the evaluation of the microcirculation without Doppler-related artifacts[13]. Two main features are evaluated during contrast evaluation: one is the enhancement of the lesion with the contrast agent, which can be non-, hypo-, iso- or hyperenhancement, and the second is the contrast distribution, which can be classified as homogeneous or heterogeneous. Regarding focal pancreatic lesions, contrast is a useful tool to differentiate pancreatic adenocarcinoma from other focal lesions. Whereas pancreatic adenocarcinoma has a hypoenhanced pattern, other focal lesions, such as neuroendocrine tumors, metastatic lesions and inflammatory diseases, are either iso- or hyperenhanced[14,15]. Two different meta-analyses have shown a pooled sensitivity between 92% and 93% and a pooled specificity between 87% and 88% for the differential diagnosis between pancreatic cancer and other focal pancreatic lesions[16,17]. CE-EUS also plays a role in patients with suspected pancreatic adenocarcinoma, but negative results after EUS fine needle aspiration (FNA), mainly in the setting of chronic pancreatitis, improve biopsy targeting at a second attempt[18,19]. Finally, CE-EUS is an important tool in deciding between surgery or surveillance of focal lesions with a negative or inconclusive histological diagnosis after EUS FNA or FNB. Being an operator-dependent procedure is one of the pitfalls of CE-EUS, but this disadvantage has been counterbalanced by an optimized technique of quantification analysis including a time-intensity curve for the region of interest[20,21].

### ***Elastography***

Elastography is an ancillary technique for the endosonographic evaluation of solid pancreatic lesions that evaluates tissue stiffness. There are two different types of elastography, namely, strain and shear wave elastography. However, only strain elastography is available for EUS, which measures tissue distortion after applying a predetermined pressure. Three different elastography measurements are available: The pattern of recognition in which the stiffness is defined by colors in which green represents the normal pancreatic tissue stiffness, blue stands for hard tissue and red represents softer tissue. This measurement is highly operator-dependent and does not provide objective information. The second measure, called the strain ratio, is a method of stiffness comparison between the target area and a reference area in a grayscale image. The distance and the selected area of reference can induce some bias with this technique[22]. Finally, the strain histogram is a computer-enhanced method for dynamic analysis, where color images are transformed into a grayscale of 256 tones. These two latter quantitative measurements provide more objective information than the pattern of recognition color evaluation. Interestingly, a meta-analysis did not show any difference in accuracy between qualitative and quantitative evaluations. It showed a pooled sensitivity of 98% and specificity of 63% for qualitative measurement and a pooled sensitivity of 95% and specificity of 61% for quantitative endoscopic ultrasound elastography measurement for correct differentiation between malignant and benign solid pancreatic lesions[23]. However, the low specificity of elastography suggests that the stiffness of a lesion is not perfectly correlated with the presence of neoplastic tissue.

### ***Contrast vs elastography***

Few studies have addressed this comparison. One of the first studies compared CE power Doppler EUS and EUS elastography[24]. No difference was found between the two techniques regarding sensitivity, specificity or accuracy. A more recent prospective study evaluated this query and found that quantitative elastography had a higher sensitivity than CE-EUS[25]. In this study, the combination of both techniques

did not improve the ability to differentiate benign from malignant solid pancreatic lesions. The addition of CE harmonic evaluation to elastography did not increase the diagnostic accuracy but may have improved the characterization of the pancreatic lesion to differentiate between distinct malignant lesions.

### Artificial intelligence

It is well known that the performance of EUS for an accurate diagnosis depends highly on the technical capacity, knowledge and experience of the endoscopist. To overcome this flaw, a strong effort has been made in the development of artificial intelligence (AI) in the evaluation and differential diagnosis of pancreatic lesions[26]. AI is a mathematical prediction technique that recognizes patterns after analyzing data in computer-based programs, performing tasks supposedly mimicking some of the processes of human intelligence. Computer-aided diagnosis (CAD) refers to diagnoses based on image processing by computer programs[27].

The first study using CAD for pancreatic endoscopic ultrasound was reported 20 years ago by Norton *et al*[28], who concluded that digital image analysis of the pancreas is feasible and at least comparable to human interpretation, setting the basis for future AI studies in the field of pancreatic diseases[28]. Subsequent studies have evaluated the performance of AI for the differential diagnosis of pancreatic lesions, with a reported accuracy of 94%[29].

Deep learning techniques refer to more advanced AI algorithms that use deep neural networks to provide high-performance predictions in which computers improve their own performance by taking advantage of previous success and error without further human intervention[30]. Deep learning is used in computer vision for imaging classification. Automatic image feature detection is its most prominent advantage[31]. Few studies have described the use of deep learning for EUS image analysis since its introduction in 2019. One study was designed for IPMN malignancy diagnosis with an accuracy of 94%[32], and another study by Tonozyuka *et al*[33] was the first deep learning AI study that evaluated the ability of AI to detect pancreatic cancer. This study showed promising results with a sensitivity of 92.4%, specificity of 84.1%, positive predictive values of 86.8% and negative predictive values of 90.7%[33].

In the future, AI can probably help in the treatment strategy ahead of tissue acquisition or in cases where biopsy is not feasible. AI can also decrease the risk of missing a lesion due to inattention and help in the training process of future endosonographers [34].

---

## INTERVENTIONAL EUS IN PANCREATIC CANCER

---

### EUS-guided tissue acquisition

The mainstay for an accurate diagnosis of pancreatic cancer is based on tissue acquisition. EUS FNA has been the standard method to acquire pancreatic tissue for more than 25 years. Great effort has been made to improve the diagnostic accuracy of FNA. Different changes in the standard technique have been adapted to improve FNA performance. Regarding technical issues, the fanning technique, which involves sampling different areas of the lesion during a single needle pass, can decrease the number of passes needed for an adequate diagnosis and increase the number of patients in which the diagnosis can be achieved at the first attempt. The use of suction during FNA has been reported in a randomized controlled trial to improve diagnostic accuracy[35], but the slow-pull technique in which no suction is applied has also been shown to yield equivalent results with less blood contamination[36]. Finally, the number of passes recommended for a better diagnostic yield is 3 or 4. More than 4 passes have no proven additional benefit[37]. Other technical variations, such as puncture with or without the use of the stylet or the availability of an on-site cytologic evaluation, have provided no significant improvements in the diagnostic yield to ensure adequate EUS tissue acquisition.

A variety of needles with modifications in the type of tip and needle size (diameter) have been manufactured, and their diagnostic performance has been evaluated. Different sizes, from 25G to 19G, were produced to try to improve the sample size and ease of manipulation. No significant difference was seen in sample quality when different needle sizes were compared for solid pancreatic lesions[38,39].

Recently, FNB needles have been made available. One can differentiate two types of FNB needles, namely, fenestrated needles, introduced in approximately 2010, and more recently, “cutting” needles with a bevelless, dented tip. Both types aim to provide core tissue samples. The performance of regular FNA needles with reverse



bevel needles was compared. A randomized controlled trial reported that fewer passes are needed to obtain an adequate sample and better histological diagnosis with reverse bevel needles[40]. Nevertheless, a different meta-analysis showed no significant difference in diagnostic accuracy between these two different needle types[41].

“Cutting” needles provide core biopsy tissue and permit the preservation of cellular architecture, allowing FNB molecular profiles of pancreatic samples to be obtained for personalized oncological treatment. Two different types of “cutting” needles are available: A Franseen needle and a fork-tip needle.

A recent meta-analysis including only randomized controlled trials comparing FNA and FNB for solid pancreatic needles showed comparable results regarding sample adequacy and diagnostic accuracy, with similar sensitivity for both needles (93.1% for FNB and 90.4% for FNA)[42]. One of these studies yielded a higher quality histological sample with the FNB needle when compared with the standard FNA needle, with the former achieving better histological architecture retainment[43] (Figure 1).

Complications due to EUS-guided tissue acquisition have been described in 0.5%-3% of cases, including acute pancreatitis, infection, perforation, and bleeding[44]. Although less frequently, needle tract seeding has also been described. This complication has a prevalence of 0.003%-0.009% with FNA needles, and to our knowledge, only one case of needle tract seeding has been reported with FNB needles [45]. Even though the risk is low, we should be aware of this risk mainly for cases in which surgery is performed, but the needle site of puncture is not within the scope of surgical resection[44,45].

### **EUS fiducials placement**

The only curative option in patients with pancreatic cancer is surgical resection. Unfortunately, only 20% of patients are surgical candidates after adequate diagnostic evaluation and staging[46]. In advanced stages, chemotherapy and radiotherapy can improve survival and quality of life[47]. Image-guided radiotherapy (IGRT) can precisely deliver radiation to the target lesion through real-time advanced imaging guidance to decrease toxicity to surrounding tissue. Stereotactic body radiotherapy (SBRT) is a form of IGRT in which multiple beam radiation allows high-dose radiation therapy to a select location for a precise target treatment[48]. This technique allows adequate control of local disease with a significant decrease in radiation toxicity[49]. To achieve this goal, implantable markers (fiducials) are needed as landmarks for precise radiation delivery. Fiducials are radiopaque markers, usually made of gold, placed in the target lesion to ease accurate radiation treatment. Originally, fiducials were placed either percutaneously or surgically. The former has the limitation of intervening structures in the needle tract, and the latter requires a more invasive procedure. EUS fiducial placement has emerged as a potential alternative to avoid these hurdles. Initially, they were placed with a 19G FNA needle, but due to the stiffness of these needles, smaller fiducials were developed for 22G FNA needle placement. Recently, preloaded needles became available to ease this procedure. A recent meta-analysis evaluated technical aspects of EUS-guided fiducial placement specifically for pancreatic cancer. This study showed an overall technical success rate of 96.27%, a migration rate of 4.33% and an adverse event rate of 4.85%[50].

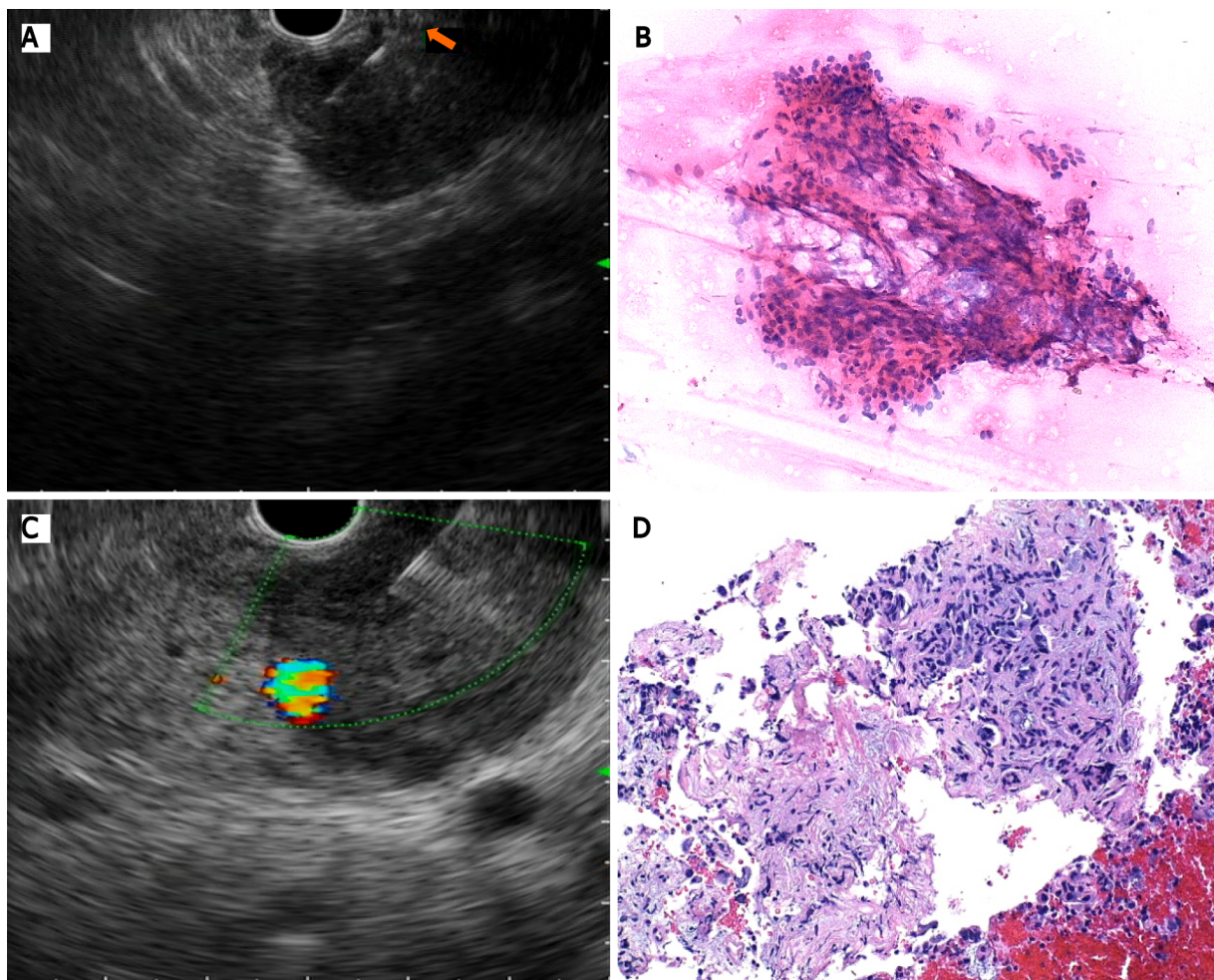
### **Radiofrequency ablation**

Radiofrequency ablation (RFA) is a local procedure that generates tissue coagulative necrosis induced by high temperature[51]. This is a well-established treatment for solid tumors of the kidney, lung and liver. Recently, an EUS RFA device composed of a specifically designed 19G needle and a purpose-built RF generator was developed to perform RFA treatment under EUS guidance. This technique produces local ablation through thermal coagulation and is also assumed by some authors to stimulate the immune response by the release of antitumoral-specific antigens (also known as the abscopal effect), thus potentially offering two different therapeutic mechanisms[52]. It is important to point out that this latter effect has been adequately described in many reports, but it is a rarely recognized clinical event[53].

As with every invasive procedure, there are potential adverse events, including pancreatitis, pancreatic duct strictures, bowel perforation, bleeding and peritonitis [54]. EUS FRA has recently been evaluated for two indications: one for the local treatment of unresectable pancreatic cancer and the other for neuroendocrine pancreatic tumors unsuitable for surgical resection.

### **Unresectable pancreatic cancer**

RFA for unresectable pancreatic cancer is a safe and feasible procedure. A recent study



**Figure 1 Endoscopic ultrasound-guided tissue acquisition.** A: Puncture with a conventional fine needle aspiration needle; B: Pancreatic adenocarcinoma after cytologic evaluation; C: Tissue acquisition with a Franseen needle; D: Pancreatic tissue with preservation of cellular architecture.

that enrolled 10 patients with unresectable pancreatic cancer reported a technical feasibility of 100% and no major adverse events[55]. To date, none of the published studies have reported any significant efficacy data.

### Neuroendocrine tumors

Pancreatic neuroendocrine tumors (NETs) are infrequent tumors (1% of all pancreatic neoplasms) usually exhibiting indolent behavior that occur sporadically or in the context of hereditary multiple endocrine neoplasia (MEN) type 1[56]. Small nonfunctional NETs (diameter under 20 mm) are usually followed with CT, MRI and/or positron emission tomography[57], whereas surgical resection is advised in larger or hormone-producing NETs. Adverse events, such as pancreatic fistula, have been reported in 45% of cases after tumor enucleation and 14% after pancreatectomy[58]. RFA has emerged as a potential treatment option for these cases. Some data have been published in recent years regarding the usefulness of RFA for NET treatment. In a prospective study that evaluated the efficacy of EUS RFA in 12 patients bearing a total of 14 treated tumors, the 1-year complete resolution rate was 86%[59]. The role of RFA has also been described for functional NETs[60]. In a recent meta-analysis, the role of RFA in pancreatic neuroendocrine tumors demonstrated an overall effectiveness of 96% without differences between functional and nonfunctional NETs[61].

Another meta-analysis evaluated this technique for the treatment of different types of pancreatic tumors and showed a technical success of 100%, a clinical success of 91.5% and an overall adverse event rate of 14.6%, where abdominal pain was the most frequently reported[62]. Most available studies that have evaluated this technique are small-sized studies with fewer than 10 patients and uncontrolled protocols. Many different settings of ablation time and energy delivery were used in each study, but this had no impact on the final results. One prospective study evaluated EUS RFA plus chemotherapy *vs* chemotherapy alone for unresectable pancreatic cancer. Even though

there was a decrease in the morphine dose requirement for pain control, no difference was seen regarding survival[63]. Larger multicentric prospective and controlled trials are needed to determine the utility of this potential therapeutic resource in the treatment of pancreatic cancer.

### ***Celiac plexus neurolysis***

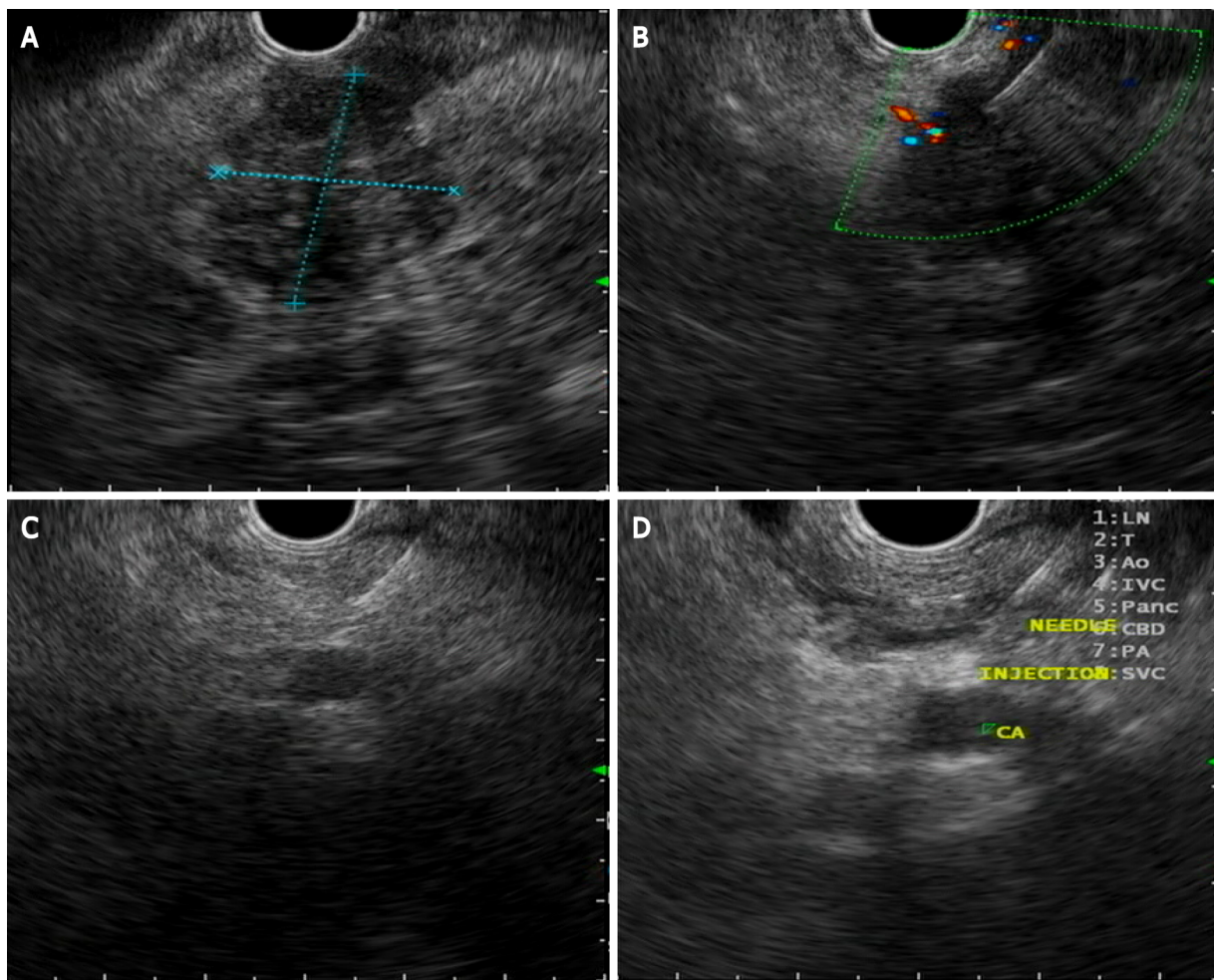
Endoscopic ultrasound celiac plexus neurolysis was introduced in 1996 for the management of pain caused by pancreatic cancer[64], which is the most common symptom in pancreatic cancer and the main impairment in quality of life of this group of patients. Pain is present in 60% of patients at presentation and in 80% of patients with advanced pancreatic cancer[65]. During celiac plexus neurolysis, absolute alcohol is injected as a neurolytic agent directly into the celiac plexus area to disrupt the transmission of pain signals. Bupivacaine 0.25% is additionally injected as an analgesic agent (Figure 2).

Three techniques have been described: A central technique in which the total amount of the agent is injected at the origin of the celiac artery, a bilateral technique in which the injection is done on both sides of the celiac artery with an equal distribution, and the most recently described direct celiac ganglia neurolysis. A meta-analysis evaluated the efficacy of this procedure, with pain relief being obtained in 72% of patients[66]. Conflicting results have been obtained regarding the best EUS neurolysis technique, but visibility and direct injection of the celiac ganglia substantially increase the response to treatment[67]. Regarding the timing of neurolysis, a randomized controlled trial concluded that early CPN reduces pain and decreases morphine consumption in patients with advanced pancreatic adenocarcinoma[68]. A systematic review described CPN having minimal superiority over analgesic drugs but with fewer adverse effects than opioids[69]. The most commonly described complications associated with CPN are transient and include diarrhea (23%), hypotension (33%) and pain exacerbation (36%)[70]. A mildly higher risk of retroperitoneal bleeding has been described with the bilateral technique[71]. EUS-guided celiac plexus neurolysis is a good option for pain treatment in patients needing high doses of opioids or with important adverse events related to these medications.

### ***EUS-guided biliary drainage***

Biliary duct obstruction is one of the main complications related to pancreatic cancer. Endoscopic retrograde cholangiopancreatography (ERCP) with stent placement is the standard treatment to drain biliary duct obstruction. Nevertheless, ERCP fails in 5-7% of the cases[72]. Until recently, percutaneous transhepatic biliary drainage (PTBD) was the most frequent approach for biliary drainage after ERCP failures. Although PTBD has significant morbidity, it is uncomfortable and generally requires more than one procedure[73]. This is why EUS biliary drainage emerged as an option for obstructive jaundice in patients with pancreatic cancer where ERCP fails with similar technical and clinical success compared with PTBD, with a lower incidence of adverse events. The first EUS biliodigestive anastomosis was described in 2001[74]. Since then, many advances in this endoscopic technique have been developed. A meta-analysis reported a technical success rate of 90% and adverse event rate in 17% of patients treated by EUS BD[75]. EUS biliary drainage can be divided into two distinct approaches, namely, gastrohepatic (or EUS-guided hepaticogastrostomy) and extrahepatic (or EUS-guided choledocoduodenostomy) approaches (Figure 3). Each approach can be divided into direct drainage and the Rendez-vous technique. The latter has been preferred by some for benign diseases, but it is important to note that it is technically challenging, with a higher risk of failure and complications. We consider this technique to be discouraged. When the duodenum is accessible, choledocoduodenostomy can be attempted, and the development of lumen-apposable metallic stents (LAMs) has simplified this approach. Recently, EUS BD has been evaluated as a first-line treatment instead of ERCP for malignant biliary obstruction, mainly due to the high technical success rate and the absence of papilla manipulation, which can decrease the risk of pancreatitis. A recent meta-analysis evaluated EUS BD as the primary palliation option for distal biliary obstruction, describing equivalent technical and clinical success, with no difference in adverse events between EUS BD and ERCP [76]. Further high-quality multicenter and controlled studies are clearly needed to determine the right place for EUS-guided BD techniques beyond ERCP failures. Choledocoduodenostomy, equivalent to side-to-side biliodigestive anastomosis, is prone to alimentary biliary reflux, causing cholangitis, and may thus be preferred for short-term drainage. For a nonaccessible duodenum, the gastrohepatic approach with hepaticogastrostomy is the best approach, which can also be considered in benign conditions and in cases of biliodigestive anastomosis dysfunction after Whipple





**Figure 2 Celiac plexus neurolysis.** A: Pancreatic ductal adenocarcinoma located in the head of the pancreas; B: Endoscopic ultrasound (EUS)-guided tissue acquisition with a fine needle aspiration needle; C: EUS-guided puncture of the celiac plexus area; D: EUS-guided neurolysis with absolute alcohol injection.

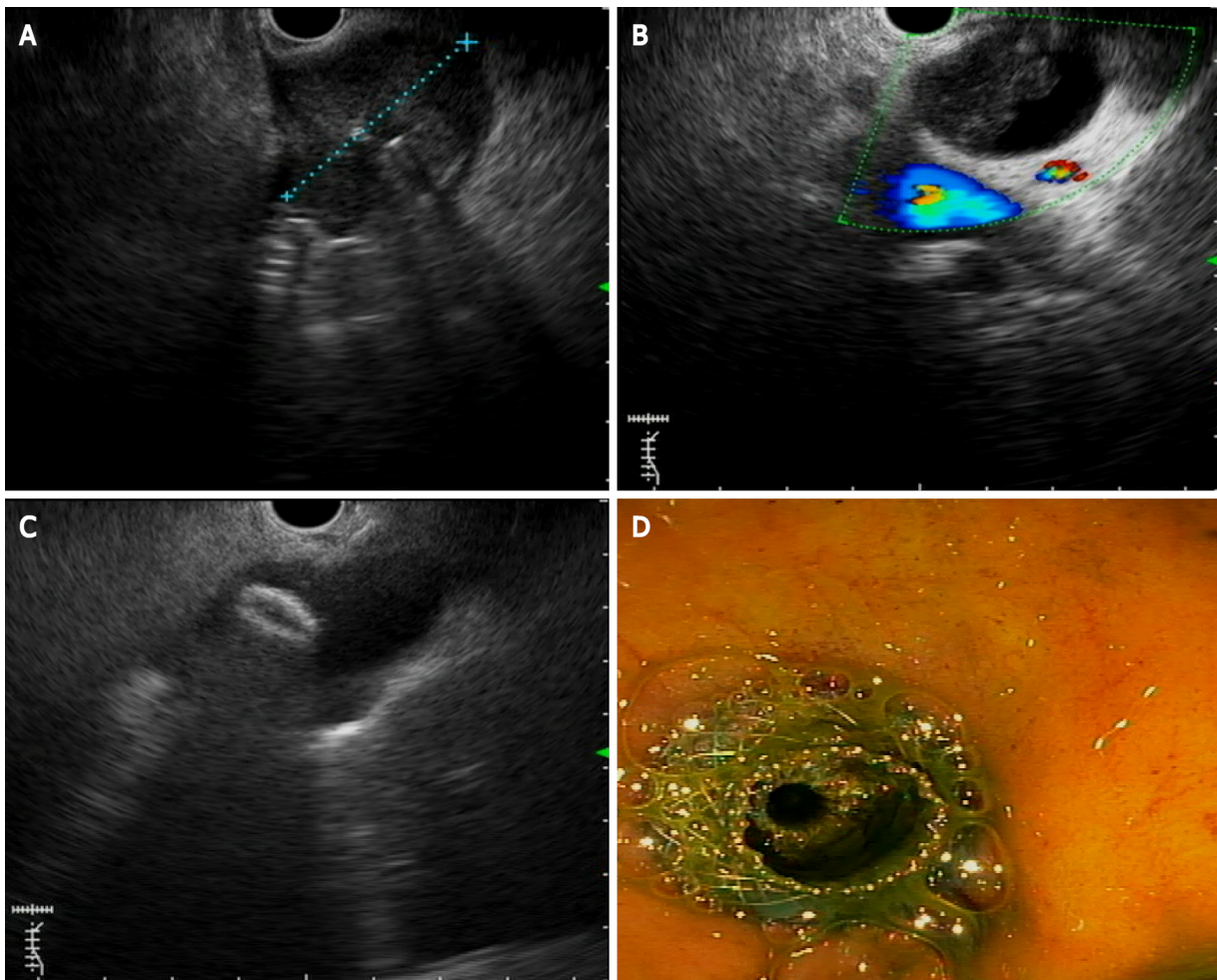
resection. A dilated left intrahepatic duct is needed to succeed in this route. A partially covered metallic stent (uncovered intrahepatic portion) has been developed for this approach, with promising results. A systematic review that evaluated the efficacy and safety of EUS BD found no difference in technical success and adverse event rates between transgastric and transduodenal approaches[77].

Even though LAMSs are highly useful for the EUS BD approach, they are a regionally limited device. Regarding the risk of recurrent biliary obstruction, EUS BD has a lower risk of tumor ingrowth but a higher risk of food impaction than ERCP BD. Stent patency for EUS BD is comparable to ERCP BD. A study by Park *et al*[78] described a cumulative stent patency of 379 d for EUS BD[78].

### **EUS-guided gastroenterostomy**

Gastric outlet obstruction (GOO) is present in 15%-25% of patients with PDAC[79] and has a severe impact on quality of life. Traditionally, this complication is treated either surgically or with self-expandable metallic stents (SEMSs) placed by the endoscopic route. Recently, EUS-guided gastroenterostomy has emerged as a successful alternative for GOO management[80]. To achieve this goal, LAMSs are used to create a communication between the stomach and the small bowel distal to the obstruction. A recent meta-analysis described a technical success rate of 92% and clinical success rate of 90%, with a pooled incidence of adverse events of 12%[81].

Another application of interventional EUS is for the treatment of afferent limb syndrome (ALS). This is a rare late postsurgical complication of PDAC pancreaticoduodenectomy, most frequently due to local cancer recurrence and mechanical obstruction, with dilation of the afferent limb and accumulation of biliopancreatic fluid. EUS-guided drainage with a LAMS has been described, which provides an adequate therapeutic approach to decompress the limb for palliative and symptomatic treatment[82]. Most of the evidence for these two EUS therapeutic applications is



**Figure 3 Endoscopic ultrasound-guided choledocoduodenostomy.** A: Pancreatic ductal adenocarcinoma (PDAC) located in the pancreatic head; B: Common bile duct dilation caused by PDAC; C: Lumen-apposable metallic stents (LAMS) distal flange opening inside the bile duct; D: Biliary drainage after LAMS placement.

primarily retrospective. Even though they seem to be promising techniques, well-designed multicentric, prospective, controlled trials are needed to validate these resources.

## CONCLUSION

Since its introduction as an endoscopic technique, EUS has evolved from a diagnostic imaging device toward a therapeutic tool, primarily for palliative cancer management. Considerable progress has been made, particularly in the diagnosis and management of PDAC. New imaging techniques can improve the differential diagnosis of focal pancreatic lesions and can decrease the bias of human imaging interpretation. EUS is the standard method for tissue acquisition, and the development of new “cutting” needles allows the procurement of core tissue for molecular profiling and personalized oncological treatment. Outstanding progress has been made in EUS interventional procedures, mainly for biliary drainage and local tumor ablation, with good technical and clinical success and fewer complications compared to other techniques. Future randomized controlled trials should be directed to evaluate the role of EUS-guided treatment, such as RFA, for unresectable pancreatic cancer or patients unsuitable for surgery. Diagnostic and interventional EUS have become essential in the workup and management of PDAC.



## REFERENCES

- 1 **Ferlay J**, Colombet M, Soerjomataram I, Dyba T, Randi G, Bettio M, Gavin A, Visser O, Bray F. Cancer incidence and mortality patterns in Europe: Estimates for 40 countries and 25 major cancers in 2018. *Eur J Cancer* 2018; **103**: 356-387 [PMID: [30100160](#) DOI: [10.1016/j.ejca.2018.07.005](#)]
- 2 **International Agency for Research on Cancer**. World Health Organization. Global Cancer Observatory 2018. [cited 5 May 2021]. Available from: <http://geo.iarc.fr>
- 3 **Siegel RL**, Miller KD, Jemal A. Cancer statistics, 2019. *CA Cancer J Clin* 2019; **69**: 7-34 [PMID: [30620402](#) DOI: [10.3322/caac.21551](#)]
- 4 **Rahib L**, Smith BD, Aizenberg R, Rosenzweig AB, Fleshman JM, Matrisian LM. Projecting cancer incidence and deaths to 2030: the unexpected burden of thyroid, liver, and pancreas cancers in the United States. *Cancer Res* 2014; **74**: 2913-2921 [PMID: [24840647](#) DOI: [10.1158/0008-5472.CAN-14-0155](#)]
- 5 **Society TAC**. Key Statistics for Pancreatic Cancer. 2017. [cited 5 May 2021]. Available from: <https://www.cancer.org/cancer/pancreatic-cancer/about/key-statistics.html>
- 6 **Vicent A**, Herman J, Schulick R, Hruban RH, Goggins M. Pancreatic cancer. *Lancet* 2011; **378**: 607-620 [DOI: [10.1016/S0140-6736\(10\)62307-0](#)]
- 7 **Kinney T**. Evidence-based imaging of pancreatic malignancies. *Surg Clin North Am* 2010; **90**: 235-249 [PMID: [20362784](#) DOI: [10.1016/j.suc.2009.12.003](#)]
- 8 **Bockhorn M**, Uzunoglu FG, Adham M, Imrie C, Milicevic M, Sandberg AA, Asbun HJ, Bassi C, Büchler M, Charnley RM, Conlon K, Cruz LF, Dervenis C, Fingerhut A, Friess H, Gouma DJ, Hartwig W, Lillemoe KD, Montorsi M, Neoptolemos JP, Shrikhande SV, Takaori K, Traverso W, Vashist YK, Vollmer C, Yeo CJ, Izbicki JR; International Study Group of Pancreatic Surgery. Borderline resectable pancreatic cancer: a consensus statement by the International Study Group of Pancreatic Surgery (ISGPS). *Surgery* 2014; **155**: 977-988 [PMID: [24856119](#) DOI: [10.1016/j.surg.2014.02.001](#)]
- 9 **Bipat S**, Phoa SS, van Delden OM, Bossuyt PM, Gouma DJ, Laméris JS, Stoker J. Ultrasonography, computed tomography and magnetic resonance imaging for diagnosis and determining resectability of pancreatic adenocarcinoma: a meta-analysis. *J Comput Assist Tomogr* 2005; **29**: 438-445 [PMID: [16012297](#) DOI: [10.1097/01.ret.0000164513.23407.b3](#)]
- 10 **Nawaz H**, Fan CY, Kloke J, Khalid A, McGrath K, Landsittel D, Papachristou GI. Performance characteristics of endoscopic ultrasound in the staging of pancreatic cancer: a meta-analysis. *JOP* 2013; **14**: 484-497 [PMID: [24018593](#) DOI: [10.6092/1590-8577/1512](#)]
- 11 **Müller MF**, Meyenberger C, Bertschinger P, Schaer R, Marincek B. Pancreatic tumors: evaluation with endoscopic US, CT, and MR imaging. *Radiology* 1994; **190**: 745-751 [PMID: [8115622](#) DOI: [10.1148/radiology.190.3.8115622](#)]
- 12 **Lu C**, Xu CF, Wan XY, Zhu HT, Yu CH, Li YM. Screening for pancreatic cancer in familial high-risk individuals: A systematic review. *World J Gastroenterol* 2015; **21**: 8678-8686 [PMID: [26229410](#) DOI: [10.3748/wjg.v21.i28.8678](#)]
- 13 **de Jong N**, Frinking PJ, Bouakaz A, Ten Cate FJ. Detection procedures of ultrasound contrast agents. *Ultrasonics* 2000; **38**: 87-92 [PMID: [10829635](#) DOI: [10.1016/s0041-624x\(99\)00071-2](#)]
- 14 **Yamashita Y**, Shimokawa T, Napoléon B, Fusaroli P, Gincul R, Kudo M, Kitano M. Value of contrast-enhanced harmonic endoscopic ultrasonography with enhancement pattern for diagnosis of pancreatic cancer: A meta-analysis. *Dig Endosc* 2019; **31**: 125-133 [PMID: [30338569](#) DOI: [10.1111/den.13290](#)]
- 15 **Fusaroli P**, Spada A, Mancino MG, Caletti G. Contrast harmonic echo-endoscopic ultrasound improves accuracy in diagnosis of solid pancreatic masses. *Clin Gastroenterol Hepatol* 2010; **8**: 629-34.e1 [PMID: [20417721](#) DOI: [10.1016/j.cgh.2010.04.012](#)]
- 16 **He XK**, Ding Y, Sun LM. Contrast-enhanced endoscopic ultrasound for differential diagnosis of pancreatic cancer: an updated meta-analysis. *Oncotarget* 2017; **8**: 66392-66401 [PMID: [29029521](#) DOI: [10.18632/oncotarget.18915](#)]
- 17 **Mei S**, Wang M, Sun L. Contrast-Enhanced EUS for Differential Diagnosis of Pancreatic Masses: A Meta-Analysis. *Gastroenterol Res Pract* 2019; **2019**: 1670183 [PMID: [30962802](#) DOI: [10.1155/2019/1670183](#)]
- 18 **Iordache S**, Costache MI, Popescu CF, Streba CT, Cazacu S, Săftoiu A. Clinical impact of EUS elastography followed by contrast-enhanced EUS in patients with focal pancreatic masses and negative EUS-guided FNA. *Med Ultrason* 2016; **18**: 18-24 [PMID: [26962549](#) DOI: [10.11152/mu.2013.2066.181.ich](#)]
- 19 **Sugimoto M**, Takagi T, Hikichi T, Suzuki R, Watanabe K, Nakamura J, Kikuchi H, Konno N, Waragai Y, Watanabe H, Obara K, Ohira H. Conventional vs contrast-enhanced harmonic endoscopic ultrasonography-guided fine-needle aspiration for diagnosis of solid pancreatic lesions: A prospective randomized trial. *Pancreatol* 2015; **15**: 538-541 [PMID: [26145837](#) DOI: [10.1016/j.pan.2015.06.005](#)]
- 20 **Matsubara H**, Itoh A, Kawashima H, Kasugai T, Ohno E, Ishikawa T, Itoh Y, Nakamura Y, Hiramatsu T, Nakamura M, Miyahara R, Ohmiya N, Ishigami M, Katano Y, Goto H, Hirooka Y. Dynamic quantitative evaluation of contrast-enhanced endoscopic ultrasonography in the diagnosis of pancreatic diseases. *Pancreas* 2011; **40**: 1073-1079 [PMID: [21633317](#) DOI: [10.1097/MPA.0b013e31821f57b7](#)]
- 21 **Seicean A**, Badea R, Stan-Iuga R, Mocan T, Gulei I, Pascu O. Quantitative contrast-enhanced

- harmonic endoscopic ultrasonography for the discrimination of solid pancreatic masses. *Ultraschall Med* 2010; **31**: 571-576 [PMID: [21080306](#) DOI: [10.1055/s-0029-1245833](#)]
- 22 **Havre RF**, Waage JR, Gilja OH, Ødegaard S, Nesje LB. Real-Time Elastography: Strain Ratio Measurements Are Influenced by the Position of the Reference Area. *Ultraschall Med* 2012; **33**: 559-568 [PMID: [21667433](#) DOI: [10.1055/s-0031-1273247](#)]
  - 23 **Zhang B**, Zhu F, Li P, Yu S, Zhao Y, Li M. Endoscopic ultrasound elastography in the diagnosis of pancreatic masses: A meta-analysis. *Pancreatology* 2018; **18**: 833-840 [PMID: [30093353](#) DOI: [10.1016/j.pan.2018.07.008](#)]
  - 24 **Figueiredo FA**, da Silva PM, Monges G, Bories E, Pesenti C, Caillol F, Delpero JR, Giovannini M. Yield of Contrast-Enhanced Power Doppler Endoscopic Ultrasonography and Strain Ratio Obtained by EUS-Elastography in the Diagnosis of Focal Pancreatic Solid Lesions. *Endosc Ultrasound* 2012; **1**: 143-149 [PMID: [24949352](#) DOI: [10.7178/eus.03.005](#)]
  - 25 **Iglesias-Garcia J**, Lindkvist B, Lariño-Noia J, Abdulkader-Nallib I, Dominguez-Muñoz JE. Differential diagnosis of solid pancreatic masses: contrast-enhanced harmonic (CEH-EUS), quantitative-elastography (QE-EUS), or both? *United European Gastroenterol J* 2017; **5**: 236-246 [PMID: [28344791](#) DOI: [10.1177/2050640616640635](#)]
  - 26 **Kuwahara T**, Hara K, Mizuno N, Haba S, Okuno N, Koda H, Miyano A, Fumihara D. Current status of artificial intelligence analysis for endoscopic ultrasonography. *Dig Endosc* 2021; **33**: 298-305 [PMID: [33098123](#) DOI: [10.1111/den.13880](#)]
  - 27 **Doi K**. Computer-aided diagnosis in medical imaging: historical review, current status and future potential. *Comput Med Imaging Graph* 2007; **31**: 198-211 [PMID: [17349778](#) DOI: [10.1016/j.compmedimag.2007.02.002](#)]
  - 28 **Norton ID**, Zheng Y, Wiersema MS, Greenleaf J, Clain JE, Dimagno EP. Neural network analysis of EUS images to differentiate between pancreatic malignancy and pancreatitis. *Gastrointest Endosc* 2001; **54**: 625-629 [PMID: [11677484](#) DOI: [10.1067/mge.2001.118644](#)]
  - 29 **Zhu M**, Xu C, Yu J, Wu Y, Li C, Zhang M, Jin Z, Li Z. Differentiation of pancreatic cancer and chronic pancreatitis using computer-aided diagnosis of endoscopic ultrasound (EUS) images: a diagnostic test. *PLoS One* 2013; **8**: e63820 [PMID: [23704940](#) DOI: [10.1371/journal.pone.0063820](#)]
  - 30 **LeCun Y**, Bengio Y, Hinton G. Deep learning. *Nature* 2015; **521**: 436-444 [PMID: [26017442](#) DOI: [10.1038/nature14539](#)]
  - 31 **Rawat W**, Wang Z. Deep Convolutional Neural Networks for Image Classification: A Comprehensive Review. *Neural Comput* 2017; **29**: 2352-2449 [PMID: [28599112](#) DOI: [10.1162/NECO\\_a\\_00990](#)]
  - 32 **Kuwahara T**, Hara K, Mizuno N, Okuno N, Matsumoto S, Obata M, Kurita Y, Koda H, Toriyama K, Onishi S, Ishihara M, Tanaka T, Tajika M, Niwa Y. Usefulness of Deep Learning Analysis for the Diagnosis of Malignancy in Intraductal Papillary Mucinous Neoplasms of the Pancreas. *Clin Transl Gastroenterol* 2019; **10**: 1-8 [PMID: [31117111](#) DOI: [10.14309/ctg.0000000000000045](#)]
  - 33 **Tonozuka R**, Itoi T, Nagata N, Kojima H, Sofuni A, Tsuchiya T, Ishii K, Tanaka R, Nagakawa Y, Mukai S. Deep learning analysis for the detection of pancreatic cancer on endosonographic images: a pilot study. *J Hepatobiliary Pancreat Sci* 2021; **28**: 95-104 [PMID: [32910528](#) DOI: [10.1002/jhbp.825](#)]
  - 34 **Tonozuka R**, Mukai S, Itoi T. The Role of Artificial Intelligence in Endoscopic Ultrasound for Pancreatic Disorders. *Diagnostics (Basel)* 2020; **11** [PMID: [33374181](#) DOI: [10.3390/diagnostics11010018](#)]
  - 35 **Tarantino I**, Di Mitri R, Fabbri C, Pagano N, Barresi L, Granata A, Liotta R, Moccia F, Maimone A, Baccarini P, Fabio T, Curcio G, Repici A, Traina M. Is diagnostic accuracy of fine needle aspiration on solid pancreatic lesions aspiration-related? *Dig Liver Dis* 2014; **46**: 523-526 [PMID: [24704290](#) DOI: [10.1016/j.dld.2014.02.023](#)]
  - 36 **El Haddad R**, Barret M, Beuvon F, Grabar S, Leblanc S, Terris B, Coriat R, Chaussade S, Prat F. The slow-pull capillary technique increases the quality of endoscopic ultrasound fine needle biopsy samples in solid pancreatic lesions. *Eur J Gastroenterol Hepatol* 2016; **28**: 911-916 [PMID: [27140228](#) DOI: [10.1097/MEG.0000000000000638](#)]
  - 37 **Mohamadnejad M**, Mullady D, Early DS, Collins B, Marshall C, Sams S, Yen R, Rizeq M, Romanas M, Nawaz S, Ulusarac O, Hollander T, Wilson RH, Simon VC, Kushnir V, Amateau SK, Brauer BC, Gaddam S, Azar RR, Komanduri S, Shah R, Das A, Edmundowicz S, Muthusamy VR, Rastogi A, Wani S. Increasing Number of Passes Beyond 4 Does Not Increase Sensitivity of Detection of Pancreatic Malignancy by Endoscopic Ultrasound-Guided Fine-Needle Aspiration. *Clin Gastroenterol Hepatol* 2017; **15**: 1071-1078.e2 [PMID: [28025154](#) DOI: [10.1016/j.cgh.2016.12.018](#)]
  - 38 **Lee JK**, Lee KT, Choi ER, Jang TH, Jang KT, Lee JK, Lee KH. A prospective, randomized trial comparing 25-gauge and 22-gauge needles for endoscopic ultrasound-guided fine needle aspiration of pancreatic masses. *Scand J Gastroenterol* 2013; **48**: 752-757 [PMID: [23600919](#) DOI: [10.3109/00365521.2013.786127](#)]
  - 39 **Fabbri C**, Polifemo AM, Luigiano C, Cennamo V, Baccarini P, Collina G, Fornelli A, Macchia S, Zanini N, Jovine E, Fisciarelli M, Alibrandi A, D'Imperio N. Endoscopic ultrasound-guided fine needle aspiration with 22- and 25-gauge needles in solid pancreatic masses: a prospective comparative study with randomisation of needle sequence. *Dig Liver Dis* 2011; **43**: 647-652 [PMID: [21592873](#) DOI: [10.1016/j.dld.2011.04.005](#)]
  - 40 **Alatawi A**, Beuvon F, Grabar S, Leblanc S, Chaussade S, Terris B, Barret M, Prat F. Comparison of 22G reverse-beveled vs standard needle for endoscopic ultrasound-guided sampling of solid

- pancreatic lesions. *United European Gastroenterol J* 2015; **3**: 343-352 [PMID: [26279842](#) DOI: [10.1177/2050640615577533](#)]
- 41 **Oh HC**, Kang H, Lee JY, Choi GJ, Choi JS. Diagnostic accuracy of 22/25-gauge core needle in endoscopic ultrasound-guided sampling: systematic review and meta-analysis. *Korean J Intern Med* 2016; **31**: 1073-1083 [PMID: [27586867](#) DOI: [10.3904/kjim.2016.066](#)]
  - 42 **Facciorusso A**, Bajwa HS, Menon K, Buccino VR, Muscatiello N. Comparison between 22G aspiration and 22G biopsy needles for EUS-guided sampling of pancreatic lesions: A meta-analysis. *Endosc Ultrasound* 2020; **9**: 167-174 [PMID: [31031330](#) DOI: [10.4103/eus.eus\\_4\\_19](#)]
  - 43 **Bang JY**, Hebert-Magee S, Navaneethan U, Hasan MK, Hawes R, Varadarajulu S. EUS-guided fine needle biopsy of pancreatic masses can yield true histology. *Gut* 2018; **67**: 2081-2084 [PMID: [28988195](#) DOI: [10.1136/gutjnl-2017-315154](#)]
  - 44 **Katanuma A**, Maguchi H, Yane K, Hashigo S, Kin T, Kaneko M, Kato S, Kato R, Harada R, Osanai M, Takahashi K, Nojima M. Factors predictive of adverse events associated with endoscopic ultrasound-guided fine needle aspiration of pancreatic solid lesions. *Dig Dis Sci* 2013; **58**: 2093-2099 [PMID: [23423501](#) DOI: [10.1007/s10620-013-2590-4](#)]
  - 45 **Gao RY**, Wu BH, Shen XY, Peng TL, Li DF, Wei C, Yu ZC, Luo MH, Xiong F, Wang LS, Yao J. Overlooked risk for needle tract seeding following endoscopic ultrasound-guided minimally invasive tissue acquisition. *World J Gastroenterol* 2020; **26**: 6182-6194 [PMID: [33177792](#) DOI: [10.3748/wjg.v26.i40.6182](#)]
  - 46 **Gillen S**, Schuster T, Meyer Zum Büschenfelde C, Friess H, Kleeff J. Preoperative/neoadjuvant therapy in pancreatic cancer: a systematic review and meta-analysis of response and resection percentages. *PLoS Med* 2010; **7**: e1000267 [PMID: [20422030](#) DOI: [10.1371/journal.pmed.1000267](#)]
  - 47 **Yip D**, Karapetis C, Strickland A, Steer CB, Goldstein D. Chemotherapy and radiotherapy for inoperable advanced pancreatic cancer. *Cochrane Database Syst Rev* 2006; CD002093 [PMID: [16855985](#) DOI: [10.1002/14651858.CD002093.pub2](#)]
  - 48 **Timmerman RD**, Kavanagh BD, Cho LC, Papiez L, Xing L. Stereotactic body radiation therapy in multiple organ sites. *J Clin Oncol* 2007; **25**: 947-952 [PMID: [17350943](#) DOI: [10.1200/JCO.2006.09.7469](#)]
  - 49 **Tchelebi LT**, Lehrer EJ, Trifiletti DM, Sharma NK, Gusani NJ, Crane CH, Zaorsky NG. Conventionally fractionated radiation therapy vs stereotactic body radiation therapy for locally advanced pancreatic cancer (CRiSP): An international systematic review and meta-analysis. *Cancer* 2020; **126**: 2120-2131 [PMID: [32125712](#) DOI: [10.1002/cncr.32756](#)]
  - 50 **Patel JB**, Revanur V, Forcione DG, Bechtold ML, Puli SR. Endoscopic ultrasound-guided fiducial marker placement in pancreatic cancer: A systematic review and meta-analysis. *World J Gastrointest Endosc* 2020; **12**: 231-240 [PMID: [32879658](#) DOI: [10.4253/wjge.v12.i8.231](#)]
  - 51 **Tatli S**, Tapan U, Morrison PR, Silverman SG. Radiofrequency ablation: technique and clinical applications. *Diagn Interv Radiol* 2012; **18**: 508-516 [PMID: [22407695](#) DOI: [10.4261/1305-3825.DIR.5168-11.1](#)]
  - 52 **Slovak R**, Ludwig JM, Gettinger SN, Herbst RS, Kim HS. Immuno-thermal ablations - boosting the anticancer immune response. *J Immunother Cancer* 2017; **5**: 78 [PMID: [29037259](#) DOI: [10.1186/s40425-017-0284-8](#)]
  - 53 **Kaminski JM**, Shinohara E, Summers JB, Niermann KJ, Morimoto A, Brousal J. The controversial abscopal effect. *Cancer Treat Rev* 2005; **31**: 159-172 [PMID: [15923088](#) DOI: [10.1016/j.ctrv.2005.03.004](#)]
  - 54 **Rossi S**, Viera FT, Ghittoni G, Cobianchi L, Rosa LL, Siciliani L, Bortolotto C, Veronese L, Vercelli A, Gallotti A, Ravetta V. Radiofrequency ablation of pancreatic neuroendocrine tumors: a pilot study of feasibility, efficacy, and safety. *Pancreas* 2014; **43**: 938-945 [PMID: [24717825](#) DOI: [10.1097/MPA.000000000000133](#)]
  - 55 **Scopelliti F**, Pea A, Conigliaro R, Butturini G, Frigerio I, Regi P, Giardino A, Bertani H, Paini M, Pederzoli P, Girelli R. Technique, safety, and feasibility of EUS-guided radiofrequency ablation in unresectable pancreatic cancer. *Surg Endosc* 2018; **32**: 4022-4028 [PMID: [29766302](#) DOI: [10.1007/s00464-018-6217-x](#)]
  - 56 **Yao JC**, Hassan M, Phan A, Dagohoy C, Leary C, Mares JE, Abdalla EK, Fleming JB, Vauthey JN, Rashid A, Evans DB. One hundred years after "carcinoid": epidemiology of and prognostic factors for neuroendocrine tumors in 35,825 cases in the United States. *J Clin Oncol* 2008; **26**: 3063-3072 [PMID: [18565894](#) DOI: [10.1200/JCO.2007.15.4377](#)]
  - 57 **Rosenberg AM**, Friedmann P, Del Rivero J, Libutti SK, Laird AM. Resection vs expectant management of small incidentally discovered nonfunctional pancreatic neuroendocrine tumors. *Surgery* 2016; **159**: 302-309 [PMID: [26547726](#) DOI: [10.1016/j.surg.2015.10.013](#)]
  - 58 **Jilesen AP**, van Eijck CH, in't Hof KH, van Dieren S, Gouma DJ, van Dijkum EJ. Postoperative Complications, In-Hospital Mortality and 5-Year Survival After Surgical Resection for Patients with a Pancreatic Neuroendocrine Tumor: A Systematic Review. *World J Surg* 2016; **40**: 729-748 [PMID: [26661846](#) DOI: [10.1007/s00268-015-3328-6](#)]
  - 59 **Barthet M**, Giovannini M, Lesavre N, Boustiere C, Napoleon B, Koch S, Gasmi M, Vanbiervliet G, Gonzalez JM. Endoscopic ultrasound-guided radiofrequency ablation for pancreatic neuroendocrine tumors and pancreatic cystic neoplasms: a prospective multicenter study. *Endoscopy* 2019; **51**: 836-842 [PMID: [30669161](#) DOI: [10.1055/a-0824-7067](#)]
  - 60 **Choi JH**, Seo DW, Song TJ, Park DH, Lee SS, Lee SK, Kim MH. Endoscopic ultrasound-guided radiofrequency ablation for management of benign solid pancreatic tumors. *Endoscopy* 2018; **50**:

- 1099-1104 [PMID: 29727904 DOI: 10.1055/a-0583-8387]
- 61 **Imperatore N**, de Nucci G, Mandelli ED, de Leone A, Zito FP, Lombardi G, Manes G. Endoscopic ultrasound-guided radiofrequency ablation of pancreatic neuroendocrine tumors: a systematic review of the literature. *Endosc Int Open* 2020; **8**: E1759-E1764 [PMID: 33269308 DOI: 10.1055/a-1261-9605]
  - 62 **Dhaliwal A**, Kolli S, Dhindsa BS, Choa J, Mashiana HS, Ramai D, Chandan S, Bhogal N, Sayles H, Bhat I, Singh S, Adler DG. Efficacy of EUS-RFA in pancreatic tumors: Is it ready for prime time? *Endosc Int Open* 2020; **8**: E1243-E1251 [PMID: 33015325 DOI: 10.1055/a-1221-5012]
  - 63 **Tiankanon K**, Kongkam P, Orprayoon T, Luangsukrer T, Seo DW, Sriuranpong V, Nantavithya C, Jantarattana T, Cañones A, Angsuwatcharakon P, Ridditit W, Kullavanijaya P, Rerknimitr R. EUS-guided radiofrequency ablation plus chemotherapy vs chemotherapy alone for unresectable pancreatic cancer (ERAP): preliminary results of a prospective comparative study. *Endoscopy* 2019; **51**: 59
  - 64 **Faigel DO**, Veloso KM, Long WB, Kochman ML. Endosonography-guided celiac plexus injection for abdominal pain due to chronic pancreatitis. *Am J Gastroenterol* 1996; **91**: 1675 [PMID: 8759702]
  - 65 **Caraceni A**, Portenoy RK. Pain management in patients with pancreatic carcinoma. *Cancer* 1996; **78**: 639-653 [PMID: 8681303 DOI: 10.1002/(SICI)1097-0142(19960801)78:3<639::AID-CNCR45>3.0.CO;2-X]
  - 66 **Kaufman M**, Singh G, Das S, Concha-Parra R, Erber J, Micames C, Gress F. Efficacy of endoscopic ultrasound-guided celiac plexus block and celiac plexus neurolysis for managing abdominal pain associated with chronic pancreatitis and pancreatic cancer. *J Clin Gastroenterol* 2010; **44**: 127-134 [PMID: 19826273 DOI: 10.1097/MCG.0b013e3181bb854d]
  - 67 **Minaga K**, Kitano M, Sakamoto H, Miyata T, Imai H, Yamao K, Kamata K, Omoto S, Kadosaka K, Sakurai T, Nishida N, Chiba Y, Kudo M. Predictors of pain response in patients undergoing endoscopic ultrasound-guided neurolysis for abdominal pain caused by pancreatic cancer. *Therap Adv Gastroenterol* 2016; **9**: 483-494 [PMID: 27366217 DOI: 10.1177/1756283X16644248]
  - 68 **Wyse JM**, Carone M, Paquin SC, Usatii M, Sahai AV. Randomized, double-blind, controlled trial of early endoscopic ultrasound-guided celiac plexus neurolysis to prevent pain progression in patients with newly diagnosed, painful, inoperable pancreatic cancer. *J Clin Oncol* 2011; **29**: 3541-3546 [PMID: 21844506 DOI: 10.1200/JCO.2010.32.2750]
  - 69 **Arcidiacono PG**, Calori G, Carrara S, McNicol ED, Testoni PA. Celiac plexus block for pancreatic cancer pain in adults. *Cochrane Database Syst Rev* 2011; CD007519 [PMID: 21412903 DOI: 10.1002/14651858.CD007519.pub2]
  - 70 **Yasuda I**, Wang HP. Endoscopic ultrasound-guided celiac plexus block and neurolysis. *Dig Endosc* 2017; **29**: 455-462 [PMID: 28160344 DOI: 10.1111/den.12824]
  - 71 **Sahai AV**, Lemelin V, Lam E, Paquin SC. Central vs. bilateral endoscopic ultrasound-guided celiac plexus block or neurolysis: a comparative study of short-term effectiveness. *Am J Gastroenterol* 2009; **104**: 326-329 [PMID: 19174816 DOI: 10.1038/ajg.2008.64]
  - 72 **Coté GA**, Singh S, Bucksot LG, Lazzell-Pannell L, Schmidt SE, Fogel E, McHenry L, Watkins J, Lehman G, Sherman S. Association between volume of endoscopic retrograde cholangiopancreatography at an academic medical center and use of pancreatobiliary therapy. *Clin Gastroenterol Hepatol* 2012; **10**: 920-924 [PMID: 22387254 DOI: 10.1016/j.cgh.2012.02.019]
  - 73 **Khashab MA**, Valeshabad AK, Afghani E, Singh VK, Kumbhari V, Messallam A, Saxena P, El Zein M, Lennon AM, Canto MI, Kalloo AN. A comparative evaluation of EUS-guided biliary drainage and percutaneous drainage in patients with distal malignant biliary obstruction and failed ERCP. *Dig Dis Sci* 2015; **60**: 557-565 [PMID: 25081224 DOI: 10.1007/s10620-014-3300-6]
  - 74 **Giovannini M**, Moutardier V, Pesenti C, Bories E, Lelong B, Delpero JR. Endoscopic ultrasound-guided bilioduodenal anastomosis: a new technique for biliary drainage. *Endoscopy* 2001; **33**: 898-900 [PMID: 11571690 DOI: 10.1055/s-2001-17324]
  - 75 **Khan MA**, Akbar A, Baron TH, Khan S, Kocak M, Alastal Y, Hammad T, Lee WM, Sofi A, Artifon EL, Nawras A, Ismail MK. Endoscopic Ultrasound-Guided Biliary Drainage: A Systematic Review and Meta-Analysis. *Dig Dis Sci* 2016; **61**: 684-703 [PMID: 26518417 DOI: 10.1007/s10620-015-3933-0]
  - 76 **Han SY**, Kim SO, So H, Shin E, Kim DU, Park DH. EUS-guided biliary drainage vs ERCP for first-line palliation of malignant distal biliary obstruction: A systematic review and meta-analysis. *Sci Rep* 2019; **9**: 16551 [PMID: 31719562 DOI: 10.1038/s41598-019-52993-x]
  - 77 **Hedjoudje A**, Sportes A, Grabar S, Zhang A, Koch S, Vuitton L, Prat F. Outcomes of endoscopic ultrasound-guided biliary drainage: A systematic review and meta-analysis. *United European Gastroenterol J* 2019; **7**: 60-68 [PMID: 30788117 DOI: 10.1177/2050640618808147]
  - 78 **Park JK**, Woo YS, Noh DH, Yang JI, Bae SY, Yun HS, Lee JK, Lee KT, Lee KH. Efficacy of EUS-guided and ERCP-guided biliary drainage for malignant biliary obstruction: prospective randomized controlled study. *Gastrointest Endosc* 2018; **88**: 277-282 [PMID: 29605722 DOI: 10.1016/j.gie.2018.03.015]
  - 79 **Tendler DA**. Malignant gastric outlet obstruction: bridging another divide. *Am J Gastroenterol* 2002; **97**: 4-6 [PMID: 11808968 DOI: 10.1111/j.1572-0241.2002.05391.x]
  - 80 **Tyberg A**, Perez-Miranda M, Sanchez-Ocaña R, Peñas I, de la Serna C, Shah J, Binmoeller K, Gaidhane M, Grimm I, Baron T, Kahaleh M. Endoscopic ultrasound-guided gastrojejunostomy with a lumen-apposing metal stent: a multicenter, international experience. *Endosc Int Open* 2016; **4**: E276-E281 [PMID: 27004243 DOI: 10.1055/s-0042-101789]

- 81 **Iqbal U**, Khara HS, Hu Y, Kumar V, Tufail K, Confer B, Diehl DL. EUS-guided gastroenterostomy for the management of gastric outlet obstruction: A systematic review and meta-analysis. *Endosc Ultrasound* 2020; **9**: 16-23 [PMID: [31898587](#) DOI: [10.4103/eus.eus\\_70\\_19](#)]
- 82 **El Bacha H**, Leblanc S, Bordachar B, Briau B, Barret M, Savier E, Soubrane O, Dousset B, Prat F. Endoscopic Ultrasound-Guided Enteroenterostomy for Afferent Limb Syndrome. *ACG Case Rep J* 2020; **7**: e00442 [PMID: [32821770](#) DOI: [10.14309/crj.0000000000000442](#)]



## Retrospective Study

Feasibility of gastric endoscopic submucosal dissection in elderly patients aged  $\geq 80$  years

Yasuhiro Inokuchi, Ayaka Ishida, Kei Hayashi, Yoshihiro Kaneta, Hayato Watanabe, Kazuki Kano, Mitsuhiro Furuta, Kosuke Takahashi, Hirohito Fujikawa, Takanobu Yamada, Kouji Yamamoto, Nozomu Machida, Takashi Ogata, Takashi Oshima, Shin Maeda

**ORCID number:** Yasuhiro Inokuchi 0000-0003-1890-3470; Ayaka Ishida 0000-0002-0733-2839; Kei Hayashi 0000-0002-2088-5729; Yoshihiro Kaneta 0000-0003-1125-5116; Hayato Watanabe 0000-0001-6254-2903; Kazuki Kano 0000-0003-2002-3077; Mitsuhiro Furuta 0000-0003-4706-2615; Kosuke Takahashi 0000-0002-5684-0733; Hirohito Fujikawa 0000-0002-9787-9319; Takanobu Yamada 0000-0003-3564-6891; Kouji Yamamoto 0000-0003-0696-9659; Nozomu Machida 0000-0001-9570-3670; Takashi Ogata 0000-0002-6453-6408; Takashi Oshima 0000-0001-5818-8649; Shin Maeda 0000-0002-0246-1594.

**Author contributions:** Inokuchi Y and Maeda S designed the study; Inokuchi Y, Ishida A, Hayashi K, Kaneta Y were involved in collection of data; Inokuchi Y, Yamamoto K, and Furuta M were involved in the data analysis; Inokuchi Y, Ishida A, Hayashi K, Kaneta Y, Watanabe H, Kano K, Furuta M, Takahashi K, Fujikawa H, Yamada T, Yamamoto K, Machida N, Ogata T, Oshima T, and Maeda S were involved in data interpretation; Inokuchi Y wrote the manuscript; Ishida A, Hayashi K, Kaneta Y, Watanabe H, Kano K, Furuta M, Takahashi K, Fujikawa H, Yamada T, Yamamoto K,

**Yasuhiro Inokuchi, Ayaka Ishida, Kei Hayashi, Yoshihiro Kaneta, Mitsuhiro Furuta, Nozomu Machida,** Department of Gastroenterology, Kanagawa Cancer Center, Yokohama 241-8515, Kanagawa, Japan

**Hayato Watanabe, Kazuki Kano, Kosuke Takahashi, Hirohito Fujikawa, Takanobu Yamada, Takashi Ogata, Takashi Oshima,** Department of Gastrointestinal Surgery, Kanagawa Cancer Center, Yokohama 241-8515, Kanagawa, Japan

**Kouji Yamamoto,** Department of Biostatistics, Yokohama City University School of Medicine., Yokohama 236-0004, Kanagawa, Japan

**Shin Maeda,** Department of Gastroenterology, Yokohama City University, Yokohama 236-0004, Kanagawa, Japan

**Corresponding author:** Yasuhiro Inokuchi, MD, PhD, Chief Doctor, Department of Gastroenterology, Kanagawa Cancer Center, 2-3-2 Asahi-ku, Nakao, Yokohama 241-8515, Kanagawa, Japan. [inokuchiy@kcch.jp](mailto:inokuchiy@kcch.jp)

## Abstract

## BACKGROUND

Endoscopic resection, especially endoscopic submucosal dissection (ESD), is increasingly performed in elderly patients with early gastric cancer, and lesions beyond the expanded indications are also resected endoscopically in some patients. It is essential to assess whether gastric ESD is safe and suitable for elderly patients and investigate what type of lesions carry an increased risk of ESD-related complications.

## AIM

To assess the efficacy and feasibility of gastric ESD for elderly patients, and define high-risk lesions and prognostic indicators.

## METHODS

Among a total of 1169 sessions of gastric ESD performed in Kanagawa Cancer Center Hospital from 2006 to 2014, 179 sessions (15.3%) were performed in patients aged  $\geq 80$  years, and 172 of these sessions were done in patients with a final diagnosis of gastric cancer. These patients were studied retrospectively to

Machida N, Ogata T, Oshima T, and Maeda S edited the manuscript; all authors critically revised the report, commented on drafts of the manuscript, and approved the final report.

#### Institutional review board

**statement:** This study has been approved by the research ethics committee of Kanagawa Cancer Center, which complies with International Guidelines for Ethical Review of Epidemiological Studies.

#### Informed consent statement:

Patients were not required to give informed consent to the study because the analysis used anonymous clinical data that were obtained after each patient agreed to treatment by written consent. According to "Ethical Guidelines for Medical and Health Research Involving Human Subjects" published by Japanese Ministry of Health, Labor and Welfare, opt-out is accepted for practical procedure to obtain informed consent from the recruited patients, in retrospective study without any invasion or newly investigated information after recruitment. For our study, we have put information concerning the study on Kanagawa Cancer Center HP, to give recruited patients a chance to refuse entry to the study.

**Conflict-of-interest statement:** The authors have declared no conflict of interest.

**Data sharing statement:** No additional data are available.

**Country/Territory of origin:** Japan

**Specialty type:** Gastroenterology and hepatology

**Provenance and peer review:** Invited article; Externally peer reviewed.

**Peer-review model:** Single blind

**Peer-review report's scientific quality classification**

Grade A (Excellent): 0  
Grade B (Very good): B  
Grade C (Good): C, C  
Grade D (Fair): 0

evaluate short-term outcomes and survival. The short-term outcomes included the rates of *en bloc* resection and curative resection, complications, and procedure-related mortality. Curability was assessed according to the Japanese Gastric Cancer Treatment Guidelines 2010. Fisher's exact test was used to statistically analyze risk factors. Clinical characteristics of each group were compared using Fisher's exact test and Mann-Whitney *U* test. Survival rates at each time point were based on Kaplan-Meier estimation. Overall survival rates were compared between patients with gastric cancer in each group with use of the log-rank test. To identify prognostic factors that jointly predict the hazard of death while controlling for model overfitting, we used the least absolute shrinkage and selection operator (LASSO) Cox regression model including factors curative/noncurative, age, gender, body mass index, prognostic nutritional index, Charlson comorbidity index (CCI), Glasgow prognostic score, neutrophil-to-lymphocyte ratio, and antithrombotic agent use. We selected the LASSO Cox regression model that resulted in minimal prediction error in 10-fold cross-validation.  $P < 0.05$  was considered statistically significant.

#### RESULTS

The *en bloc* dissection rate was 97.1%, indicating that a high quality of treatment was achieved even in elderly patients. As for complications, the rates of bleeding, perforation and aspiration pneumonitis were 3.4%, 1.1% and 0.6%, respectively. These complication rates indicated that ESD was not associated with a particularly higher risk in elderly patients than in nonelderly patients. A dissection incision  $> 40$  mm, lesions associated with depressions, and lesions with ulcers were risk factors for post-ESD bleeding, and location of the lesion in the upper third of the stomach was a risk factor for perforation in elderly patients ( $P < 0.05$ ). Location of the lesion in the lower third of the stomach tended to be associated with a higher risk of bleeding. The overall survival (OS) did not differ significantly between curative and noncurative ESD ( $P = 0.69$ ). In patients without additional surgery, OS rate was significantly lower in patients with a high CCI ( $\geq 2$ ) than in those with a low CCI ( $\leq 1$ ) ( $P < 0.001$ ).

#### CONCLUSION

Gastric ESD is feasible even in patients aged  $\geq 80$  years. Observation without additional surgery after noncurative ESD is reasonable, especially in elderly patients with CCI  $\geq 2$ .

**Key Words:** Endoscopic submucosal dissection; Elderly; Charlson comorbidity index; Early gastric cancer; Complications; Prognostic indicators

©The Author(s) 2022. Published by Baishideng Publishing Group Inc. All rights reserved.

**Core Tip:** This was a retrospective study to evaluate the efficacy and feasibility of gastric endoscopic submucosal dissection in elderly patients aged  $\geq 80$  years. The rates of *en bloc* dissection, bleeding, perforation and aspiration pneumonitis were 97.1%, 3.4%, 1.1% and 0.6%, respectively. These rates are similar to the rates in nonelderly patients reported previously. Risk factors for bleeding were incision  $> 40$  mm, lesions associated with depressions, and ulcerative lesions. A risk factor for perforation was location in the upper third of the stomach. Charlson comorbidity index  $\geq 2$  was an indicator of poor prognosis regardless of curability.

**Citation:** Inokuchi Y, Ishida A, Hayashi K, Kaneta Y, Watanabe H, Kano K, Furuta M, Takahashi K, Fujikawa H, Yamada T, Yamamoto K, Machida N, Ogata T, Oshima T, Maeda S. Feasibility of gastric endoscopic submucosal dissection in elderly patients aged  $\geq 80$  years. *World J Gastrointest Endosc* 2022; 14(1): 49-62

**URL:** <https://www.wjgnet.com/1948-5190/full/v14/i1/49.htm>

**DOI:** <https://dx.doi.org/10.4253/wjge.v14.i1.49>

Grade E (Poor): 0

**Open-Access:** This article is an open-access article that was selected by an in-house editor and fully peer-reviewed by external reviewers. It is distributed in accordance with the Creative Commons Attribution NonCommercial (CC BY-NC 4.0) license, which permits others to distribute, remix, adapt, build upon this work non-commercially, and license their derivative works on different terms, provided the original work is properly cited and the use is non-commercial. See: <http://creativecommons.org/licenses/by-nc/4.0/>

**Received:** April 27, 2021**Peer-review started:** April 27, 2021**First decision:** June 13, 2021**Revised:** June 16, 2021**Accepted:** December 11, 2021**Article in press:** December 11, 2021**Published online:** January 16, 2022**P-Reviewer:** Garbarino GM, Hu B, Santos-Antunes J**S-Editor:** Wu YXJ**L-Editor:** Kerr C**P-Editor:** Wu YXJ

## INTRODUCTION

Early gastric cancer (EGC) is defined as gastric cancer confined to the mucosa and submucosa[1]. Increasing numbers of EGCs are being detected in Japan[2,3], and EGCs currently account for  $> 60\%$  of all detected cases of gastric cancer[4]. Since the development of endoscopic submucosal dissection (ESD), the treatment of EGC has changed dramatically[5,6]. Various techniques have considerably reduced the technical limitations of endoscopic resection (ER), and EGCs can now be freely resected, independently of size and shape[6-8]. Many EGCs that would have been surgically resected previously are now resected endoscopically. The most attractive point of ESD as compared with open surgery is its lower invasiveness and the ability to avoid deterioration in the quality of life.

The elderly population is increasing rapidly in Japan. The average life span is 80.50 years for men and 86.83 years for women, according to statistics reported by the Ministry of Health, Labour and Welfare, Japan in 2014. Surgery carries an increased risk in elderly patients because of poor physical status or serious underlying diseases [9,10]. Thus ER, especially ESD, is being increasingly performed in elderly patients[10-14]. Because this trend is expected to continue, it is necessary to assess whether ESD is actually safe and suitable for elderly patients. In addition, more clearly defining high-risk lesions associated is prerequisite to safe treatment.

## MATERIALS AND METHODS

### Patients

A total of 1169 sessions of ESD were performed to treat gastric diseases (mainly EGCs and gastric adenomas, as well as some non-neoplastic lesions) in Kanagawa Cancer Center Hospital between January 2006 and December 2014, and 179 (15.3%) of these sessions were performed in a total of 131 patients who were aged  $\geq 80$  years. Among the resected specimens, gastric cancers were finally diagnosed in 175 lesions treated by 172 sessions of ESD in 124 patients. These cases were studied retrospectively.

### ESD procedure

Around-the-lesion biopsy was performed beforehand to confirm the margin of the lesions, if necessary. On the day of ESD, the margin was identified again using white light endoscopy, chromoendoscopy with indigo carmine solution, and narrow-band imaging. All-around-the-lesion marking was carried out with the use of small multiple cautery units. Submucosal injection was performed to lift the mucosal layer. Glyceol (10% glycerol and 5% fructose; Chugai Pharmaceutical Co., Tokyo, Japan) or MucoUp (0.4% sodium hyaluronate; Johnson & Johnson, New Brunswick, NJ, United States) with a small amount of indigo carmine was used as the injection solution. A circumferential mucosal incision and submucosal dissection were performed using a needle knife (Olympus Optical Co. Ltd., Tokyo, Japan). The high-frequency generators used were ICC200 or VIO300D (ERBE Elektromedizin GmbH, Tübingen, Germany).

### Short-term outcomes

The short-term outcomes included the rates of *en bloc* resection and curative resection, complications, and procedure-related mortality. Curability was assessed according to the Japanese Gastric Cancer Treatment Guidelines 2010[15]. A curative resection was defined as satisfying all the following conditions: *en bloc* resection, negative horizontal and vertical margin, no lymphovascular infiltration, and absolute or expanded indication for ER. Differentiated type intramucosal cancer  $\leq 20$  mm in size without ulceration was categorized as a lesion of absolute indication. A lesion of expanded indications was as follows: Differentiated type intramucosal cancer  $> 20$  mm in size without ulceration; differentiated type intramucosal cancer  $\leq 30$  mm in size with ulceration; differentiated type submucosal superficial cancer  $\leq 30$  mm in size; and undifferentiated type intramucosal cancer  $\leq 20$  mm in size without ulceration.

As for complications, bleeding, perforation and aspiration pneumonitis were assessed. Bleeding was defined as the occurrence of melena or hematemesis; detection of ongoing hemorrhage; or the presence of coagulated blood in the stomach with apparent bleeding spots on endoscopic examination, which was basically performed routinely in all patients on the next day of ESD. Perforation was confirmed by observation of mesenteric fat during ESD or by detection of free air on X-ray films. Aspiration pneumonitis was diagnosed on the basis of clinical findings and X-ray films. Procedure-related mortality was defined as death within 30 d due to complica-

ations. In patients who had complications, patient-related factors, such as World Health Organization performance status and underlying disease, as well as lesion-related factors, such as location, size, and macroscopic aspects were investigated.

### Long-term outcomes

For evaluation of long-term outcomes, a patient who had experienced noncurative ESD within the last 5 years ( $n = 1$ ) and patients who underwent additional surgery after ESD ( $n = 3$ ) were excluded from the target of analysis. Overall survival (OS) was evaluated starting from the date of ESD to the date of death or the last verified date of survival. To determine the prognostic indicators for elderly patients with EGC treated by ESD, we also evaluated the clinical characteristics of the patients who did not undergo additional surgery after ESD ( $n = 120$ ), using age, gender, body mass index (BMI), prognostic nutritional index (PNI), Charlson comorbidity index (CCI), Glasgow prognostic score (GPS), neutrophil-to-lymphocyte ratio (NLR), and use of antithrombotic agents.

### Statistical analysis

To estimate affecting factors related to complications, relative risks were calculated. Fisher's exact test was used to statistically analyze risk factors. Clinical characteristics of each group were compared using Fisher's exact test and Mann-Whitney *U* test. Survival rates at each time point were based on Kaplan-Meier estimation. OS rates were compared with the log-rank test between patients with gastric cancer in each group. To identify prognostic factors that jointly predict the hazard of death while controlling for model overfitting, the least absolute shrinkage and selection operator (LASSO) Cox regression model including factors curative/noncurative, age, gender, BMI, PNI, CCI, GPS, NLR and antithrombotic agent use was used (R package glmnet) [16]. We selected the LASSO Cox regression model that resulted in minimal prediction error in 10-fold cross-validation.  $P < 0.05$  was considered statistically significant.

All statistical analyses were conducted using the EZR software, version 1.54 (Saitama Medical Center, Jichi Medical University, Saitama, Japan)[17] and R version 4.0.3 (The R Foundation for Statistical Computing, Vienna, Austria). The statistical review of the study was performed by a biomedical statistician.

## RESULTS

### Short-term outcomes

Short-term outcomes are shown in Table 1. Within 172 sessions of ESD, two different specimens of multiple lesions were resected at the same time in three sessions; only one specimen was resected for each treatment in 168 sessions; and one lesion was unresectable in one session. A total of 174 specimens were thus resected from 175 lesions in 172 sessions of ESD. The *en bloc* dissection rate and the curative dissection rate were 97.1% and 77.1%, respectively. Six lesions (3.4%) had postoperative bleeding, two (1.1%) had intraoperative perforation, and one patient (0.6%) had aspiration pneumonitis after ESD. Blood transfusion was required in one patient. There were no procedure-related deaths.

The characteristics of the treated lesions and patients are shown in Table 2. Macroscopically, flat-type shaped lesions (85.7%) predominated over protruded-type lesions (13.7%). There was one advanced type 1 lesion, which was misdiagnosed as EGC type 0-I before treatment. Of 124 recruited patients, 38 (30.6%) had circulatory underlying diseases, nine (7.3%) had respiratory underlying diseases, and 22.6% of the patients were receiving at least one antithrombotic agent.

In the present study of elderly patients, lesions that did not meet the indication criteria were also treated. The details of noncurative lesions and noncurative factors are shown in Table 3. Among 40 noncurative lesions, 32 (80.0%) were differentiated type, and eight (20.0%) were undifferentiated type. The noncurative factors were depth of invasion in 30.0%, oversize in 20.0%, positive ulceration associated with undifferentiated components in 12.5%, and positive or uncertain lymph vascular invasion in 35.0% of the noncurative lesions.

The patients with complications are summarized in Table 4. One patient had both postoperative bleeding and aspiration pneumonitis, and the others had one complication each. None of patients with postoperative bleeding was receiving any antithrombotic agents.

**Table 1 Short-term outcomes of ESD, *n* (%)**

Location of the lesions ( <i>n</i> = 175) <sup>1</sup>	
Upper third	33 (18.9)
Middle third	57 (32.6)
Lower third	85 (48.6)
Size of dissected specimen ( <i>n</i> = 174) <sup>2</sup>	
Range	9-110 mm
Median	30 mm
Average	33.4 mm
ESD quality ( <i>n</i> = 175) <sup>2</sup>	
En bloc dissection	170 (97.1)
Fractional dissection	4 (2.3)
Not dissected endoscopically	1 (0.6)
Curability ( <i>n</i> = 175) <sup>1</sup>	
Curative dissection	135 (77.1)
Non-curative dissection	40 (22.9)
Complications	
ESD sessions ( <i>n</i> = 172) with any complication	8 (4.7)
Bleeding ( <i>n</i> = 175) <sup>1</sup>	6 (3.4)
Perforation ( <i>n</i> = 175) <sup>1</sup>	2 (1.1)
Aspiration pneumonitis ( <i>n</i> = 172) <sup>3</sup>	1 (0.6)
Procedure-related death ( <i>n</i> = 172) <sup>3</sup>	0

<sup>1</sup>Location, Endoscopic submucosal dissection (ESD) quality (*en bloc* or fractional dissection rate), curability (curative or noncurative dissection rate), and complications of bleeding and perforation calculated with respect to the total number of 175 treated lesions.

<sup>2</sup>Size of dissected specimen measured only in endoscopically resected cases (*n* = 174).

<sup>3</sup>Number of ESD sessions (total *n* = 172) associated with aspiration pneumonitis. ESD: Endoscopic submucosal dissection.

The relation of complications to lesion location and size of resected specimen is summarized in Table 5. Lesion location in the lower third of the stomach and a resected specimen size  $> 40$  mm tended to have higher bleeding rates. Lesion location in the upper third of the stomach and a resected specimen size  $> 40$  mm tended to be associated with higher perforation rates.

The relative risks of lesion location and resected specimen size are shown in Table 6. Resected specimens  $> 40$  mm, macroscopic shape with depressive component, and presence of ulceration were determined to be risk factors for bleeding ( $P < 0.05$ ). Location of the lesion in the upper third of the stomach was determined to be a risk factor for perforation ( $P < 0.05$ ).

### Long-term outcomes

Survival curves according to the curability are shown in Figure 1. The patients were divided into two groups: Those who underwent only curative ESD (curative ESD group, *n* = 87), and those who underwent noncurative ESD without additional surgery (noncurative ESD group, *n* = 33). Patients who had undergone dissection more than once were classified as noncurative when ESD was noncurative at least once. A total of 32 patients (26.7%) died during a median follow-up period of 2005 d (range, 83-4774 d). Twenty-four of the patients who died were in the curative ESD group and eight were in the noncurative ESD group. The cause of death was gastric cancer in none of them. The OS rate did not differ significantly between the curative and the non-curative ESD groups ( $P = 0.69$ ).

Prognostic factors for OS using LASSO in the patients who did not undergo additional surgery (*n* = 120) are shown in Table 7. Among these clinical characteristics, gender and CCI, one of most widely used and validated comorbidity scoring system to



**Table 2 Characteristics of treated lesions and patients, *n* (%)**

<b>(A) Lesions (<i>n</i> = 175)</b>	
Macroscopic type	
Protruded type (0-I, 0-I+IIa, 0-I+IIb, 0-I+IIc)	24 (13.7)
Flat type (0-IIa, 0-IIa+IIc, 0-IIb, 0-IIc, 0-IIc+IIa)	150 (85.7)
Advanced (type 1)	1 (0.6)
Ulceration	
UL (+)	22 (12.6)
UL ( )	153 (87.4)
Depth of invasion	
M	152 (86.9)
$\geq$ SM	23 (13.1)
<b>(B) Patients (<i>n</i> = 124)</b>	
Underlying disease	
Circulatory	38 (30.6)
Respiratory	9 (7.3)
Renal	0
Antithrombotic agent	
Taking	28 (22.6)

UL: Ulceration; M: Mucosa; SM: Submucosa.

measure comorbidity status, were significantly associated with OS. As median CCI in each group was 1, patients were divided in two groups according to CCI  $\leq 1$  or  $> 1$ . The survival curve of patients with low CCI  $\leq 1$  ( $n = 100$ ) and those with high CCI  $\geq 2$  ( $n = 20$ ) are shown in [Figure 2](#). The OS rate was significantly different between the two groups ( $P < 0.001$ ).

## DISCUSSION

In Japan, the morbidity rate of gastric cancer has been rapidly decreasing according to the Center for Cancer Control and Information Services, National Cancer Center, Japan. Nonetheless, the number of EGCs treated endoscopically has dramatically increased. The increased use of ER seems to be attributed to three reasons. The first reason is the expansion of the indications for ER. Because ER is a local resection procedure without lymphadenectomy, the indications for ER are limited to conditions expected to have no lymph node metastasis[15]. Previous studies of patients who underwent surgery for gastric cancer have evaluated conditions associated with no lymph node metastasis. The second reason is progress in endoscopic techniques[6-8]. The final reason is the minimal invasiveness of ESD. ESD is far less invasive than open surgery, and can prevent symptoms associated with a small capacity of stomach after surgery.

Although minimal invasiveness is undoubtedly attractive for elderly patients because they have higher incidences of underlying diseases than younger patients have and are sometimes in poor general condition[9,10], the feasibility of ESD remains to be fully evaluated. In our study, complications occurred only in 4.7% of patients, without any procedure-related deaths. In previous studies of elderly patients, the rate of bleeding ranged from 2.5% to 9.6%[10-14], except for the study by Hirasaki *et al*[10], which reported a bleeding rate of 43.4%[3], and the rates of perforation and of pneumonia ranged from 1.5% to 5.0% and 0.5% to 2.2%, respectively. In most of these studies, ESD was not associated with particularly higher risk in elderly than in nonelderly patients. Indeed, the rates of bleeding and perforation among patients of all ages were reported to range from 3.7% to 15.6% and 1.2% to 6.7%, respectively[18-22].

**Table 3 Details of noncurative lesions, and estimated noncurative factors of 40 noncurative lesions**

<b>(A) Details of noncurative lesions (n = 40)</b>				
	Depth of invasion			
	M	SM1	SM2	$\geq$ MP
Histological type				
Differentiated (tub1, tub2, pap)	19	4	8	1
Undifferentiated (por, sig, muc)	4	2	2	0
<b>(B) Estimated non-curative factors of 40 non-curative lesions, n (%)</b>				
Depth of invasion				
$\geq$ SM2, differentiated			8 (20)	
$\geq$ SM, undifferentiated			4 (10)	
Lesion size				
$\geq 30$ mm, differentiated, UL (+)			2 (5)	
$\geq 30$ mm, differentiated, SM1			1 (2.5)	
$\geq 20$ mm, undifferentiated			5 (12.5)	
Ulceration				
UL (+) with undifferentiated components			5 (12.5)	
Lymphovascular invasion				
Ly +/-uncertain			7 (17.5)	
V +/-uncertain			7 (17.5)	
Surgical margin				
Positive			7 (17.5)	
Uncertain			21 (52.5)	
Not dissected endoscopically			1 (2.5)	

M: Mucosa; SM: Submucosa; MP: Muscularis propria; UL: Ulceration; Ly: Lymphatic invasion; V: Venous invasion.

In nonelderly patients, Lin *et al*[23] reported that the rates of bleeding, perforation and procedure-related pneumonia were 2.9%, 1.1% and 0.4%, respectively, in their meta-analysis of nine previous studies of gastric ESD. These previous reports and present study suggest that the rates of complications of ESD in elderly patients are not particularly higher than the rates in nonelderly or patients of all ages. Accordingly, we argue that gastric ESD is feasible even in elderly patients aged  $\geq 80$  years.

However, some studies have reported that ESD carries a higher risk in elderly patients than in younger patients[13,21]. Toyokawa *et al*[13] reported that the bleeding rate was significantly higher in the elderly group (age  $\geq 75$  years) than in the nonelderly group (age  $< 75$  years). However, in multivariate analysis, high age was not in itself an independent predictor of bleeding, and the reason why the bleeding rate was higher in the elderly group was unclear. It was also reported by Toyokawa *et al* [21] in another report that age  $\geq 80$  years was associated with a significantly higher risk of delayed bleeding after ESD, and they concluded that the use of antiplatelet agents or anticoagulants was not the reason for delayed bleeding in elderly patients. Also in that study, they could not specify the reason why delayed bleeding was predominant in elderly patients over nonelderly patients. In our institution, endoscopic examination on the next day of ESD was routinely performed, and coagulation of visible vessels at the ulcer floor was carried out. This endoscopic examination may have contributed to low incidence of bleeding in our present study. In any case, attentive precautionary endoscopic hemostasis after dissection is crucial for aged patients, as they demonstrate age-related physiological decline with higher incidence of underlying diseases and worse overall condition[13].

Even if gastric ESD is feasible in elderly patients, complications can have severe consequences. To acknowledge the characteristics of lesions associated with higher

Table 4 Details of patients who had complications of endoscopic submucosal dissection

Age (yr)	Gender	Ps	Underlying disease	Past history	Location <sup>1</sup>	Size (mm)	Macroscopic type	Final pathology	Curability	Specimen (mm)	Complications
83	F	1		Post-BHA	L, Ant	40	0-IIc, UL (+)	Tub2 > por2, M, ly0, v0, HM0, VM0	Noncurative	60	Bleeding G2
83	M	0			L, Ant	10	0-IIc, UL (+)	Tub1 > tub2, M, ly0, v0, HM0, VM0	Curative	20	Bleeding G2
92	M	0		Laryngeal cancer	U, Post	50	Type1	Surgical resection: pap > tub, SS, ly0, v1, NX, HMX	Noncurative	52 <sup>2</sup>	Perforation G3
89	M	3		Brain cancer	M, Les	33	0-IIc, UL (+)	Sig/por2, M, ly0, v0, HM0, VM0	Noncurative	68	Bleeding G3, pneumonitis G2
83	F	2	AD, Depression		U, Les	15	0-IIa	Tub1, M, ly0, v0, HM0, VM0	Curative	30	Perforation G2
82	F	0			(1) L, Ant	(1) 20	(1) 0-IIc	(1) Tub2 > tub1 > por, M, ly0, v0, HM0, VM0	(1) Curative	54	Bleeding G2
					(2) L, Ant	(2) 10	(2) 0-IIc	(2) Tub1-tub2, M, ly0, v0, HM0, VM0	(2) Curative		
84	M	2	AP, COPD		L, Les	15	0-IIc	Por1, M, ly0, v0, HMX, VMX	Noncurative	40	Bleeding G2
80	M	0		Colon cancer, EGC	L, Les	16	0-IIa+IIc, UL (+)	Tub1 > tub2 > por, M, ly0, v0, HM0, VM0	Curative	47	Bleeding G2

<sup>1</sup>Location divided into three regions of the stomach; U (upper third), M (middle third), and L (lower third), respectively.

<sup>2</sup>Size of all-around incision of endoscopic submucosal dissection measured in a surgically resected specimen.

PS: Performance status; BHA: Bipolar hip arthroplasty; AD: Alzheimer disease; UL: Ulceration; AP: Angina pectoris; COPD: Chronic obstructive pulmonary disease; EGC: Early gastric cancer; M: Mucosa; SM: Submucosa; SS: Subserosa; ly: Lymphatic invasion; v: Venous invasion; HM: Horizontal margin; VM: Vertical margin; N: Lymph node metastasis; L: Lower third; M: Middle third; U: Upper third.

risks in elderly patients is essential to a safe procedure. Kim *et al*[22] reported that the risk of perforation associated with ESD is higher for lesions located in the gastric body than those located in the antrum. Toyokawa *et al*[21] reported that ESD carried a high risk of perforation when EGCs located in the upper third of the stomach were dissected. Our results that lesion location in the upper third of the stomach was a significant risk factor, and lesion size > 40 mm tended toward a higher risk of perforation in elderly patients seem to be consistent with previous studies performed in patients of all ages.

As for bleeding, Chung *et al*[18] reported that the risk of delayed bleeding after ESD was significantly higher for lesions located in the upper portion of the stomach. In contrast, in our study focusing on elderly patients, lesions located in the lower portion of the stomach tended to have a higher risk of bleeding. As for macroscopic shape, lesions with depressive components such as 0-IIc, 0-IIa + IIc, 0-IIc + IIa, and 0-I + IIc and lesions with ulceration were associated with bleeding after ESD. In contrast, treatment with antithrombotic agents was not associated with bleeding. We speculate that strong peristaltic contractions of the gastric antrum increased the risk of bleeding in the lower portion of the stomach. In addition, a resected lesion size > 40 mm in diameter was determined to be a risk factor for bleeding. Moreover, the median lesion size in patients with bleeding was 50.5 mm (range, 20-68 mm), which was about 70% larger than median lesion size of 30 mm (range, 9-110 mm) in the study group as a whole. We therefore recommend meticulous preventive endoscopic hemostasis after resecting lesions > 40 mm, especially those located in the lower third of the stomach, and lesions with depressive aspects or ulceration, when treating elderly patients.

**Table 5 Relations of complications to location or dissected size of endoscopic submucosal dissection specimens, *n* (%)**

	Bleeding (+)	Bleeding (-)	Perforation (+)	Perforation (-)	Total
	<i>n</i> = 6	<i>n</i> = 169	<i>n</i> = 2	<i>n</i> = 173	<i>n</i> = 175
Location					
Upper third	0	33 (100)	2 (6.1)	31 (93.9)	33
Middle third	1 (1.6)	56 (98.4)	0	57 (100)	57
Lower third	5 (5.9)	80 (94.1)	0	85 (100)	85
Size of specimen					
$\leq 20$ mm	1 (3.3)	29 (96.7)	0	30 (100)	30
21-40 mm	1 (1.0)	102 (99.0)	1 (1.0)	102 (99.0)	103
41-60 mm	3 (8.1)	34 (91.9)	1 (2.7) <sup>1</sup>	36 (97.3)	37
$\geq 61$ mm	1 (20.0)	4 (80.0)	0	5 (100)	5

<sup>1</sup>Not endoscopically dissected case.

Size of all-around incision of endoscopic submucosal dissection measured in a surgically resected specimen.

To prevent aspiration during ESD, an overtube was inserted in all patients. Accordingly, the rate of aspiration pneumonitis was as low as 0.6%. In contrast, Isomoto *et al*[12] reported that aspiration pneumonitis occurred in 2.2% of patients aged  $\geq 75$  years, which was more frequent than in younger patients. In contrast, Lee *et al*[24] reported that the risk of aspiration might be increased by endoscopic procedures with a longer duration.

In the present study of elderly patients, lesions that did not meet the indication criteria were also treated. Accordingly, the curative dissection rate of ESD was only 77.1%. Abe *et al*[14] reported that the curative rate of ESD was 77.9% in their multicenter study of ESD in patients aged  $\geq 80$  years, consistent with our results. The question arises whether dissecting lesions beyond expanded indications was meaningless? Kang *et al*[25] recently reported that even if the lesions are beyond expanded indications, ESD reduces the risk of death from gastric cancer, although it does not completely cure the disease in some patients. In our study, the disease-specific 5-year survival rate and 5-year OS rate in the noncurative ESD group were as high as 100% and 76.9%, respectively. These rates were higher than 5-year survival rate of patients with EGC who did not undergo resection (62.8%) as reported by Tsukuma *et al*[26]. Furthermore, the OS of the noncurative ESD group was equivalent to that of the curative ESD group. Although the number of patients in our study was small, and our results may have been influenced by selection bias, our findings suggest that ESD might be effective for EGC beyond expanded indications. Indeed, although 32 of 120 recruited patients died during the follow-up period, none of them died of gastric cancer. The causes of death in the other patients were malignancy in other organs in seven patients, respiratory diseases in five patients, and uncertain in 20 patients.

Tsukuma *et al*[26] reported that the median interval required for EGC to progress to an advanced stage was 44 mo. Moreover, older patients tended to have shorter intervals to the development of advanced disease, and it was 36 mo in patients aged  $> 75$  years[27]. We thus consider it reasonable to endoscopically resect lesions beyond expanded indications if surgery is unacceptable, with the goal of preventing symptoms that may develop in the future, in patients who are expected to survival for longer than 36 mo.

In this study, local recurrence developed in only one (3.0%) of 33 patients in the noncurative ESD group. Similarly, Abe *et al*[14] reported that local recurrence developed in 3.3% and distant metastasis developed in 5.5% of patients who did not undergo additional surgery after noncurative ESD. Kusano *et al*[28] reported that survival was improved by additional surgery following noncurative ER in elderly patients. In contrast, Ahn *et al*[29] reported that the mortality rate was significantly higher in the presence of lymphovascular invasion than in the absence of such invasion in patients with differentiated EGC who underwent nonsurgical follow-up after noncurative ER. Thus, if possible, additional surgery is advisable after noncurative ESD, even in elderly patients, especially when lymphovascular invasion is

**Table 6 Relative risks of location and size for bleeding or perforation**

(A) Relative risk of location lower third, size > 40 mm, macroscopic shape, presence or absence of ulceration, and depth of invasion for bleeding			
	Bleeding (+)	Relative risk	P value
Location			
Lower third	5.9% (5/85)	5.3	0.11
Upper third, middle third	1.1% (1/90)		
Dissected size			
≥ 41 mm	9.5% (4/42)	6.3	0.030
≤ 40 mm	1.5% (2/133)		
Macroscopic shape			
Depressive component (+)	8.2% (6/73)		0.005
Depressive component ()	0% (0/102)		
Ulceration			
UL (+)	18.2% (4/22)	13.9	0.003
UL ()	1.3% (2/153)		
Depth of invasion			
≥ SM	3.9% (6/152)		1
M	0% (0/23)		
(B) Relative risk of location upper third, size > 40 mm, macroscopic shape, presence or absence of ulceration, and depth of invasion for perforation			
	Perforation (+)	Relative risk	P value
Location			
Upper third	6.3% (2/32)		0.033
Middle third, lower third	0% (1/143)		
Dissected size			
≥ 41 mm	2.4% (1/42)	3.2	0.423
≤ 40 mm	0.8% (1/133)		
Macroscopic shape			
Depressive component (+)	0% (0/73)	-	0.511
Depressive component ()	2.0% (2/102)		
Ulceration			
UL (+)	0% (0/22)	-	1
UL ()	1.3% (2/153)		
Depth of invasion			
≥ SM	0.7% (1/152)	6.6	0.246
M	4.3% (1/23)		

UL: Ulceration; M: Mucosa; SM: Submucosa.

confirmed histologically.

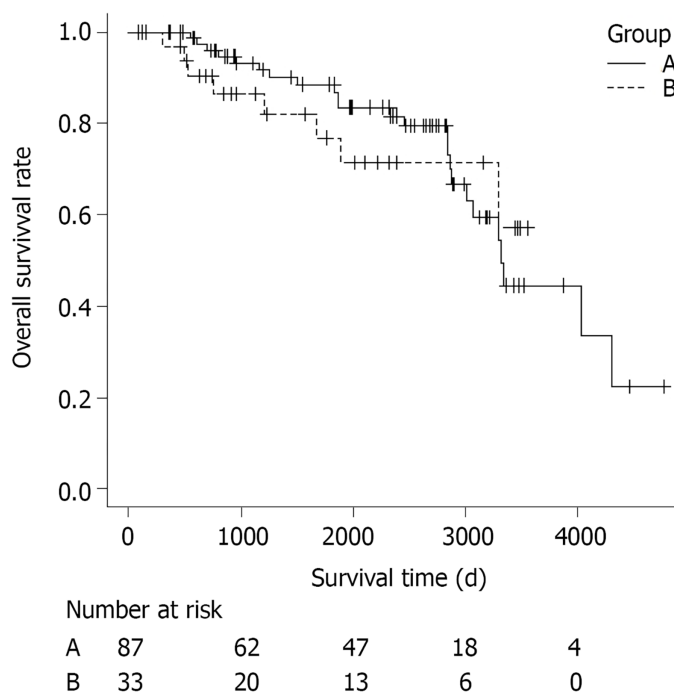
CCI was developed to assess the risk of death from comorbidities and has been widely used to evaluate clinical outcomes, such as prognosis or complications. CCI was calculated as the sum of the scores assigned to several comorbidities (myocardial infarction, congestive heart failure, cerebrovascular disease, uncomplicated diabetes, moderate-to-severe chronic kidney disease, moderate-to-severe liver disease, solid tumor, leukemia *etc.*) based on the original definition[30]. In our study, curability of ESD was not associated with OS rate. CCI was indicated to be the only factor



**Table 7 Prognostic factors for overall survival ( $n = 120$ )**

	Cox LASSO
Curability	
Noncurative	-
Patient	-
Age	-
Gender: Male	0.416
BMI	-
PNI	-
CCI > 1	0.477
GPS	-
NLR	-
Antithrombotic agent (+)	-

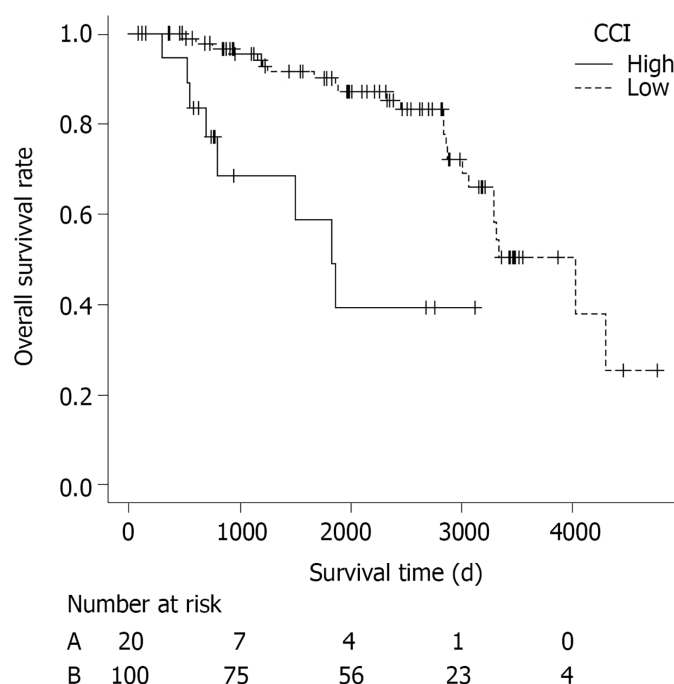
LASSO: Least absolute shrinkage and selection operator; BMI: Body mass index; PNI: Prognostic nutritional index; CCI: Charlson comorbidity index; GPS: Glasgow prognostic score; NLR: neutrophil-to-lymphocyte ratio.



**Figure 1 Overall survival of curative and noncurative patients.** Group A: Curative endoscopic submucosal dissection (ESD) group ( $n = 87$ ); Group B: Noncurative ESD group ( $n = 33$ ). A total of 32 patients (26.7%) died during a median follow-up of 2005 d (range, 83–4774 d). Twenty-four of the patients who died were in the curative ESD group and eight were in the noncurative ESD group. The cause of death was gastric cancer in none of them. The overall survival rate did not differ significantly between the curative and noncurative ESD groups ( $P = 0.69$ ).

associated with prognosis, among various clinical characteristics such as BMI, PNI, GPS and NLR. However, Iwai *et al*[31] reported that  $CCI \geq 3$  and  $PNI < 47.7$  were both significantly associated with lower OS rate. Whether nutritional status is truly a predictor of long-term prognosis is controversial. According to our results, we suggest that observation without additional surgery after noncurative ESD may be considered, especially in elderly patients with  $CCI > 1$ .

The limitation of our study was that it was retrospective. Although complications are expected to differ depending on concomitant diseases, we cannot confirm the patients' characteristics in detail. Moreover, we had only a few cases of bleeding and perforation, as this was a single-center study with a limited number of recruited



**Figure 2 Overall survival of patients with high and low Charlson comorbidity index.** Charlson comorbidity index (CCI) High: Patients with CCI  $\geq 2$  ( $n = 20$ ); CCI Low: Patients with CCI  $\leq 1$  ( $n = 100$ ). Overall survival rate was significantly different between the two groups ( $P < 0.001$ ).

patients, and our results may have been influenced by selection bias. Therefore, a multicenter prospective trial needs to be performed to confirm the risk factors of ESD related to underlying disease.

## CONCLUSION

Gastric ESD is feasible and permissible in elderly patients aged  $\geq 80$  years. To ensure a safe procedure, meticulous preventive endoscopic hemostasis is recommended after resecting specimens  $> 40$  mm or lesions with depressive aspects or ulceration, especially those located in the lower third of the stomach, when treating aged patients. Concerning their long-term prognosis, male gender and CCI  $> 1$  are negative predictors.

## ARTICLE HIGHLIGHTS

### Research background

Endoscopic submucosal dissection (ESD) is increasingly performed in elderly patients with early gastric cancer (EGC).

### Research motivation

Whether gastric ESD is safe and suitable for elderly patients, type of lesions which carry an increased risk of procedure-related complications, indicators of prognosis for elderly patients after ESD are unclear.

### Research objectives

To investigate short-term and long-term outcomes of gastric ESD for elderly patients, and to determine the risk factors of procedure-related complications and the indicators of prognosis.

### Research methods

This study included patients aged  $\geq 80$  years who underwent ESD for EGC in Kanagawa Cancer Center Hospital. These patients were studied retrospectively to evaluate short-term outcomes and survival of gastric ESD.

### Research results

The *en bloc* dissection rate was as high as 97.1%, and the complication rates of bleeding, perforation and aspiration pneumonitis were as low as 3.4%, 1.1% and 0.6%, respectively, which were similar to the rates of ESD for nonelderly patients. A dissection incision  $> 40$  mm, lesions associated with depressions, and lesions with ulcers were risk factors for bleeding, and location of the lesion in the upper third of the stomach was a risk factor for perforation ( $P < 0.05$ ). The overall survival (OS) did not differ significantly between curative and noncurative ESD groups ( $P = 0.69$ ). In patients without additional surgery, OS rate was significantly lower in patients with a high Charlson comorbidity index (CCI)  $\geq 2$  than in patients with a low CCI  $\leq 1$  ( $P < 0.001$ ).

### Research conclusions

Gastric ESD is feasible even in elderly patients aged  $\geq 80$  years. Meticulous preventive endoscopic hemostasis after resecting specimens  $> 40$  mm, or lesions associated with depressions or ulcers is recommended. CCI is a prognostic indicator. Observation without additional surgery after noncurative ESD is reasonable, especially in elderly patients with CCI  $\geq 2$ .

### Research perspectives

As our institution is a hub hospital specializing in cancer treatment, relatively healthy patients without severe underlying diseases tend to visit the hospital. Therefore, a selection bias of target patients may have existed in our study. A multicenter prospective trial with a large number of patients is desirable to confirm the feasibility of gastric ESD in patients with various health problems, and the risk factors and the prognostic indicators related to each underlying disease.

## REFERENCES

- 1 Sano T, Kobori O, Muto T. Lymph node metastasis from early gastric cancer: endoscopic resection of tumour. *Br J Surg* 1992; **79**: 241-244 [PMID: 1313325 DOI: 10.1002/bjs.1800790319]
- 2 Shimizu S, Tada M, Kawai K. Early gastric cancer: its surveillance and natural course. *Endoscopy* 1995; **27**: 27-31 [PMID: 7601031 DOI: 10.1055/s-2007-1005628]
- 3 Kitano S, Shiraishi N. Current status of laparoscopic gastrectomy for cancer in Japan. *Surg Endosc* 2004; **18**: 182-185 [PMID: 14691704 DOI: 10.1007/s00464-003-8820-7]
- 4 Foundation for Promotion of Cancer Research. CANCER STATISTICS IN JAPAN-2014 2014; 24
- 5 Gotoda T, Kondo H, Ono H, Saito Y, Yamaguchi H, Saito D, Yokota T. A new endoscopic mucosal resection procedure using an insulation-tipped electrosurgical knife for rectal flat lesions: report of two cases. *Gastrointest Endosc* 1999; **50**: 560-563 [PMID: 10502182 DOI: 10.1016/s0016-5107(99)70084-2]
- 6 Ono H, Kondo H, Gotoda T, Shirao K, Yamaguchi H, Saito D, Hosokawa K, Shimoda T, Yoshida S. Endoscopic mucosal resection for treatment of early gastric cancer. *Gut* 2001; **48**: 225-229 [PMID: 11156645 DOI: 10.1136/gut.48.2.225]
- 7 Gotoda T, Yamamoto H, Soetikno RM. Endoscopic submucosal dissection of early gastric cancer. *J Gastroenterol* 2006; **41**: 929-942 [PMID: 17096062 DOI: 10.1007/s00535-006-1954-3]
- 8 Abe N, Yamaguchi Y, Takeuchi H, Izumisato Y, Yanagida O, Masaki T, Mori T, Sugiyama M, Atomi Y. Key factors for successful en bloc endoscopic submucosal dissection of early stage gastric cancer using an insulation-tipped diathermic knife. *Hepatogastroenterology* 2006; **53**: 639-642 [PMID: 16995479]
- 9 Mohri Y, Omori Y, Hiro J, Yokoe T, Konishi N, Tanaka K, Tonouchi H, Kusunoki M. Clinicopathological features and prognosis of gastric cancer patients  $>$  or  $= 75$  years of age after laparotomy. *Int Surg* 2009; **94**: 38-42 [PMID: 20099425]
- 10 Hirasaki S, Tanimizu M, Nasu J, Shinji T, Koide N. Treatment of elderly patients with early gastric cancer by endoscopic submucosal dissection using an insulated-tip diathermic knife. *Intern Med* 2005; **44**: 1033-1038 [PMID: 16293912 DOI: 10.2169/internalmedicine.44.1033]
- 11 Kakushima N, Fujishiro M, Kodashima S, Muraki Y, Tateishi A, Yahagi N, Omata M. Technical feasibility of endoscopic submucosal dissection for gastric neoplasms in the elderly Japanese population. *J Gastroenterol Hepatol* 2007; **22**: 311-314 [PMID: 17295759 DOI: 10.1111/j.1440-1746.2006.04563.x]
- 12 Isomoto H, Ohnita K, Yamaguchi N, Fukuda E, Ikeda K, Nishiyama H, Akiyama M, Ozawa E, Nakao K, Kohno S, Shikuwa S. Clinical outcomes of endoscopic submucosal dissection in elderly patients with early gastric cancer. *Eur J Gastroenterol Hepatol* 2010; **22**: 311-317 [PMID: 19494784 DOI: 10.1097/MEG.0b013e32832c61d7]
- 13 Toyokawa T, Fujita I, Morikawa T, Okamoto A, Miyasaka R, Watanabe K, Horii J, Gobaru M, Terao M, Murakami T, Tomoda J. Clinical outcomes of ESD for early gastric neoplasms in elderly patients.

- Eur J Clin Invest* 2011; **41**: 474-478 [PMID: [21128933](#) DOI: [10.1111/j.1365-2362.2010.02428.x](#)]
- 14 **Abe N**, Gotoda T, Hirasawa T, Hoteya S, Ishido K, Ida Y, Imaeda H, Ishii E, Kokawa A, Kusano C, Maehata T, Ono S, Takeuchi H, Sugiyama M, Takahashi S. Multicenter study of the long-term outcomes of endoscopic submucosal dissection for early gastric cancer in patients 80 years of age or older. *Gastric Cancer* 2012; **15**: 70-75 [PMID: [21667133](#) DOI: [10.1007/s10120-011-0067-8](#)]
- 15 **Japanese Gastric Cancer Association**. Japanese gastric cancer treatment guidelines 2010 (ver. 3). *Gastric Cancer* 2011; **14**: 113-123 [PMID: [21573742](#) DOI: [10.1007/s10120-011-0042-4](#)]
- 16 **Tibshirani R**. The lasso method for variable selection in the Cox model. *Stat Med* 1997; **16**: 385-395 [PMID: [9044528](#) DOI: [10.1002/\(sici\)1097-0258\(19970228\)16:4<385::aid-sim380>3.0.co;2-3](#)]
- 17 **Kanda Y**. Investigation of the freely available easy-to-use software 'EZ' for medical statistics. *Bone Marrow Transplant* 2013; **48**: 452-458 [PMID: [23208313](#) DOI: [10.1038/bmt.2012.244](#)]
- 18 **Chung IK**, Lee JH, Lee SH, Kim SJ, Cho JY, Cho WY, Hwangbo Y, Keum BR, Park JJ, Chun HJ, Kim HJ, Kim JJ, Ji SR, Seol SY. Therapeutic outcomes in 1000 cases of endoscopic submucosal dissection for early gastric neoplasms: Korean ESD Study Group multicenter study. *Gastrointest Endosc* 2009; **69**: 1228-1235 [PMID: [19249769](#) DOI: [10.1016/j.gie.2008.09.027](#)]
- 19 **Kato M**, Nishida T, Tsutsui S, Komori M, Michida T, Yamamoto K, Kawai N, Kitamura S, Zushi S, Nishihara A, Nakanishi F, Kinoshita K, Yamada T, Iijima H, Tsujii M, Hayashi N. Endoscopic submucosal dissection as a treatment for gastric noninvasive neoplasia: a multicenter study by Osaka University ESD Study Group. *J Gastroenterol* 2011; **46**: 325-331 [PMID: [21107615](#) DOI: [10.1007/s00535-010-0350-1](#)]
- 20 **Sugimoto T**, Okamoto M, Mitsuno Y, Kondo S, Ogura K, Ohmae T, Mizuno H, Yoshida S, Isomura Y, Yamaji Y, Kawabe T, Omata M, Koike K. Endoscopic submucosal dissection is an effective and safe therapy for early gastric neoplasms: a multicenter feasible study. *J Clin Gastroenterol* 2012; **46**: 124-129 [PMID: [21959325](#) DOI: [10.1097/MCG.0b013e31822f3988](#)]
- 21 **Toyokawa T**, Inaba T, Omote S, Okamoto A, Miyasaka R, Watanabe K, Izumikawa K, Horii J, Fujita I, Ishikawa S, Morikawa T, Murakami T, Tomoda J. Risk factors for perforation and delayed bleeding associated with endoscopic submucosal dissection for early gastric neoplasms: analysis of 1123 lesions. *J Gastroenterol Hepatol* 2012; **27**: 907-912 [PMID: [22142449](#) DOI: [10.1111/j.1440-1746.2011.07039.x](#)]
- 22 **Kim M**, Jeon SW, Cho KB, Park KS, Kim ES, Park CK, Seo HE, Chung YJ, Kwon JG, Jung JT, Kim EY, Jang BI, Lee SH, Kim KO, Yang CH; Daegu-Kyungpook Gastrointestinal Study Group (DGSG). Predictive risk factors of perforation in gastric endoscopic submucosal dissection for early gastric cancer: a large, multicenter study. *Surg Endosc* 2013; **27**: 1372-1378 [PMID: [23239296](#) DOI: [10.1007/s00464-012-2618-4](#)]
- 23 **Lin JP**, Zhang YP, Xue M, Chen SJ, Si JM. Endoscopic submucosal dissection for early gastric cancer in elderly patients: a meta-analysis. *World J Surg Oncol* 2015; **13**: 293 [PMID: [26438198](#) DOI: [10.1186/s12957-015-0705-4](#)]
- 24 **Lee IL**, Wu CS, Tung SY, Lin PY, Shen CH, Wei KL, Chang TS. Endoscopic submucosal dissection for early gastric cancers: experience from a new endoscopic center in Taiwan. *J Clin Gastroenterol* 2008; **42**: 42-47 [PMID: [18097288](#) DOI: [10.1097/01.mcg.0000225696.54498.f1](#)]
- 25 **Kang MS**, Hong SJ, Kim DY, Han JP, Choi MH, Kim HK, Ko BM, Lee MS. Long-term outcome after endoscopic submucosal dissection for early gastric cancer: focusing on a group beyond the expanded indication. *J Dig Dis* 2015; **16**: 7-13 [PMID: [25366382](#) DOI: [10.1111/1751-2980.12208](#)]
- 26 **Tsukuma H**, Oshima A, Narahara H, Morii T. Natural history of early gastric cancer: a non-concurrent, long term, follow up study. *Gut* 2000; **47**: 618-621 [PMID: [11034575](#) DOI: [10.1136/gut.47.5.618](#)]
- 27 **Tsukuma H**, Ioka A, Iishi H, Yamazaki H. Prospective study of early gastric cancer, with considerations concerning clinical practice for gastric cancer. *Stomach Intestine* 2008; **43**: 1777-1783
- 28 **Kusano C**, Iwasaki M, Kaltenbach T, Conlin A, Oda I, Gotoda T. Should elderly patients undergo additional surgery after non-curative endoscopic resection for early gastric cancer? *Am J Gastroenterol* 2011; **106**: 1064-1069 [PMID: [21407189](#) DOI: [10.1038/ajg.2011.49](#)]
- 29 **Ahn JY**, Jung HY, Choi JY, Kim MY, Lee JH, Choi KS, Kim DH, Choi KD, Song HJ, Lee GH, Kim JH, Park YS. Natural course of noncurative endoscopic resection of differentiated early gastric cancer. *Endoscopy* 2012; **44**: 1114-1120 [PMID: [23188661](#) DOI: [10.1055/s-0032-1325676](#)]
- 30 **Charlson ME**, Pompei P, Ales KL, MacKenzie CR. A new method of classifying prognostic comorbidity in longitudinal studies: development and validation. *J Chronic Dis* 1987; **40**: 373-383 [PMID: [3558716](#) DOI: [10.1016/0021-9681\(87\)90171-8](#)]
- 31 **Iwai N**, Dohi O, Naito Y, Inada Y, Fukui A, Takayama S, Ogita K, Terasaki K, Nakano T, Ueda T, Okayama T, Yoshida N, Katada K, Kamada K, Uchiyama K, Ishikawa T, Handa O, Takagi T, Konishi H, Yagi N, Itoh Y. Impact of the Charlson comorbidity index and prognostic nutritional index on prognosis in patients with early gastric cancer after endoscopic submucosal dissection. *Dig Endosc* 2018; **30**: 616-623 [PMID: [29532961](#) DOI: [10.1111/den.13051](#)]



Published by **Baishideng Publishing Group Inc**  
7041 Koll Center Parkway, Suite 160, Pleasanton, CA 94566, USA

**Telephone:** +1-925-3991568

**E-mail:** [bpgoffice@wjgnet.com](mailto:bpgoffice@wjgnet.com)

**Help Desk:** <https://www.f6publishing.com/helpdesk>

<https://www.wjgnet.com>

