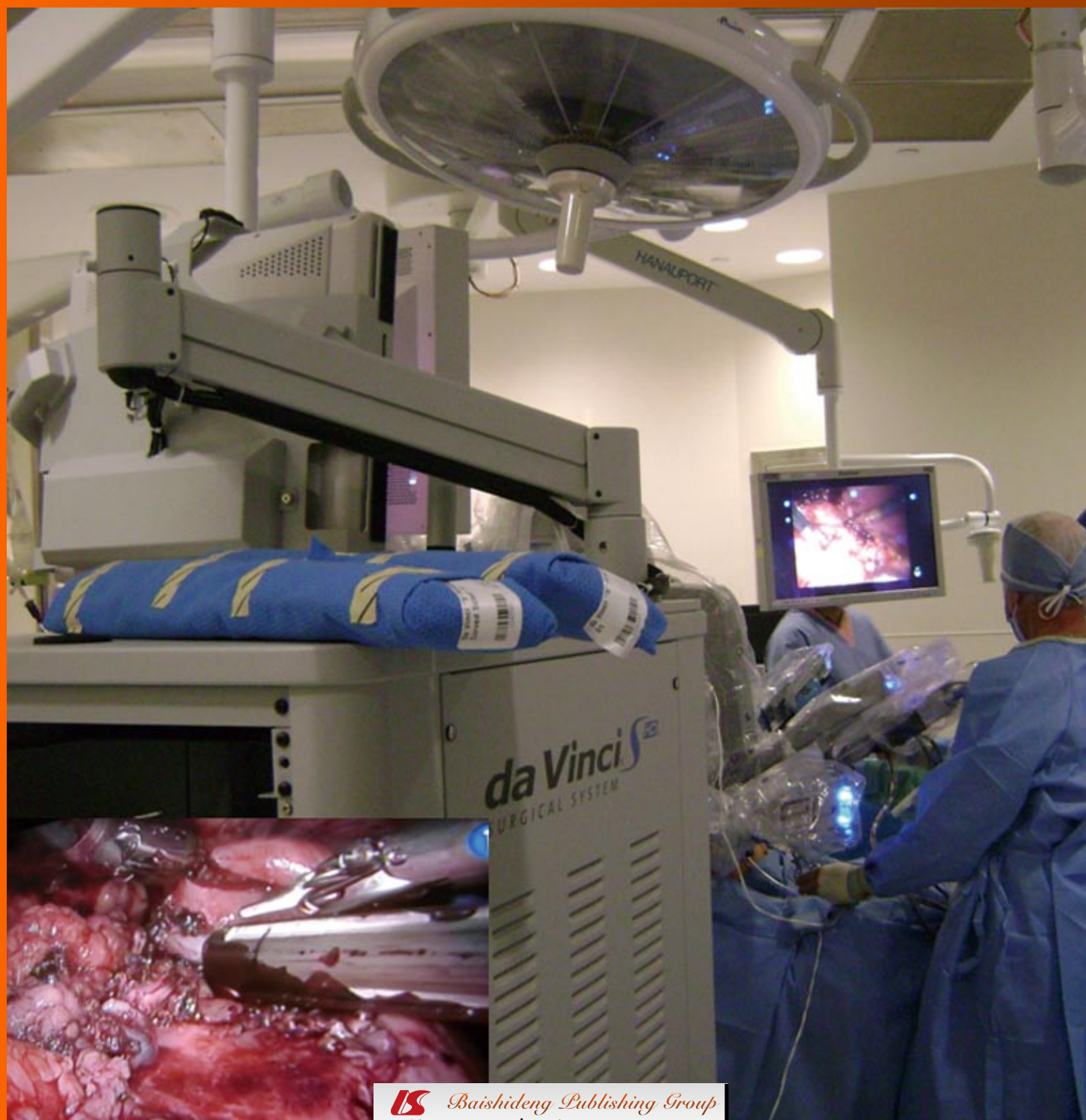

World Journal of *Gastrointestinal Surgery*

World J Gastrointest Surg 2011 June 27; 3(6): 73-88





Editorial Board

2009-2013

The *World Journal of Gastrointestinal Surgery* Editorial Board consists of 336 members, representing a team of worldwide experts in gastrointestinal surgery research. They are from 35 countries, including Australia (6), Austria (2), Belgium (6), Brazil (9), Bulgaria (2), Canada (8), China (30), Denmark (1), Finland (1), France (10), Germany (22), Greece (6), India (10), Ireland (3), Israel (3), Italy (48), Jamaica (1), Japan (47), Malaysia (1), Netherlands (9), Pakistan (1), Poland (1), Portugal (1), Russia (1), Singapore (6), Serbia (1), South Korea (9), Spain (5), Sweden (2), Switzerland (4), Thailand (2), Tunisia (1), Turkey (8), United Kingdom (7), and United State (62).

PRESIDENT AND EDITOR-IN-CHIEF

Lian-Sheng Ma, *Beijing*

STRATEGY ASSOCIATE EDITORS-IN-CHIEF

Elijah Dixon, *Calgary*
Antonello Forgione, *Milan*
Tobias Keck, *Freiburg*
Tsuyoshi Konishi, *Tokyo*
Natale Di Martino, *Naples*

GUEST EDITORIAL BOARD MEMBERS

Chao-Long Chen, *Kaohsiung*
Chien-Hung Chen, *Taipei*
Jong-Shiaw Jin, *Taipei*
Chen-Guo Ker, *Kaohsiung*
King-Teh Lee, *Kaohsiung*
Wei-Jei Lee, *Taoyuan*
Shiu-Ru Lin, *Kaohsiung*
Wan-Yu Lin, *Taichung*
Yan-Shen Shan, *Tainan*
Jaw-Yuan Wang, *Kaohsiung*
Li-Wha Wu, *Tainan*
Fang Hsin-Yuan, *Taichung*

MEMBERS OF THE EDITORIAL BOARD



Australia

Ned Abraham, *Coffs Harbour*
Christopher Christophi, *Melbourne*
M Michael, *Victoria*
David Lawson Morris, *Kogarah*
Jas Singh Samra, *St Leonards*
Matthias W Wichmann, *Millicent*



Austria

Harald R Rosen, *Vienna*
Franz Sellner, *Vienna*



Belgium

Giovanni Dapri, *Brussels*
Jean-François Gigot, *Brussels*
Lerut Jan Paul Marthe, *Brussels*
Gregory Peter Sergeant, *Leuven*
Hans Van Vlierberghe, *Gent*
Jean-Louis Vincent, *Brussels*



Brazil

Jose E Aguilar-Nascimento, *Cuiaba*
MR Álvares-da-Silva, *Porto Alegre*
Fernando M Biscione, *Minas Gerais*
Julio Coelho, *Curitiba*
Marcel A Machado, *São Paulo*
MAF Ribeiro Jr, *Santana de Parnaíba*
José Sebastião dos Santos, *São Paulo*
Marcus VM Valadão, *Rio de Janeiro*
Ricardo Zorron, *Rio de Janeiro*



Bulgaria

Krassimir D Ivanov, *Varna*
Belev Nikolai, *Plovdiv*



Canada

Runjan Chetty, *Toronto*

Laura A Dawson, *Toronto*
Mahmoud A Khalifa, *Toronto*
Peter Kim, *Toronto*
Peter Metrakos, *Quebec*
Reda S Saad, *Toronto*
Manuela Santos, *Montreal*



China

Yue-Zu Fan, *Shanghai*
Wen-Tao Fang, *Shanghai*
Yong-Song Guan, *Chengdu*
Shao-Liang Han, *Wenzhou*
Michael G Irwin, *Hong Kong*
Long Jiang, *Shanghai*
Wai Lun Law, *Hong Kong*
Ting-Bo Liang, *Hangzhou*
Quan-Da Liu, *Beijing*
Yu-Bin Liu, *Guangdong*
Ding Ma, *Wuhan*
Jian-Yang Ma, *Chengdu*
Kwan Man, *Hong Kong*
Tang Chung Ngai, *Hong Kong*
Yan-Ning Qian, *Nanjing*
Ai-Wen Wu, *Beijing*
Yin-Mo Yang, *Beijing*
Yun-Fei Yuan, *Guangzhou*



Denmark

Thue Bisgaard, *Lykkebæk*



Finland

Helena M Isoniemi, *Helsinki*



France

Chapel Alain, *Far*
 Mustapha Adham, *Lyon*
 Brice Gayet, *Paris*
 Jean-François Gillion, *Antony*
 D Heresbach, *Rennes Cedex*
 Romaric Loffroy, *Dijon Cedex*
 Jacques Marescaux, *Strasbourg Cedex*
 Yves Panis, *Clichy*
 Aurélie Plessier, *Clichy*
 Eric Savier, *Paris*



Germany

Vollmar Brigitte, *Rostock*
 Dieter C Broering, *Kiel*
 Hans G Beger, *Ulm*
 Ansgar M Chromik, *Bochum*
 Marc-H Dahlke, *Regensburg*
 Irene Esposito, *Neuherberg*
 Stefan Fichtner-Feigl, *Regensburg*
 Benedikt Josef Folz, *Bad Lippspringe*
 Helmut Friess, *München*
 Reinhart T Grundmann, *Burghausen*
 Bertram Illert, *Würzburg*
 Jakob R Izbicki, *Hamburg*
 Haier Jörg, *Münster*
 Jörg H Kleeff, *Munich*
 Axel Kleespies, *Munich*
 Uwe Klinge, *Aachen*
 Martin G Mack, *Frankfurt*
 Klaus Erik Mönkemüller, *Bottrop*
 Matthias Peiper, *Dusseldorf*
 Hubert Scheidbach, *Magdeburg*
 Joerg Theisen, *Munich*



Greece

Eelco de Bree, *Herakleion*
 Stavros J Gourgiotis, *Athens*
 Andreas Manouras, *Athens*
 Theodoros E Pavlidis, *Thessaloniki*
 George H Sakorafas, *Athens*
 Vassilios E Smyrniotis, *Athens*



India

Anil K Agarwal, *New Delhi*
 Shams-ul-Bari, *Kashmir*
 Somprakas Basu, *Varanasi*
 Pravin J Gupta, *Nagpur*
 Vinay Kumar Kapoor, *Lucknow*
 Chandra Kant Pandey, *Lucknow*
 Shailesh V Shrikhande, *Mumbai*
 Sadiq S Sikora, *Bangalore*
 Prod Rakesh K Tandon, *New Delhi*
 Imtiaz Ahmed Wani, *Srinagar*



Ireland

Kevin C P Conlon, *Dublin*

Prem Puri, *Dublin*
 Eamonn M Quigley, *Cork*



Israel

Tulchinsky Hagit, *Tel Aviv*
 Ariel Halevy, *Zerifin*
 Jesse Lachter, *Haifa*



Italy

Angelo Andriulli, *San Giovanni Rotondo*
 Giuseppe Aprile, *Udine*
 Gianni Biancofiore, *Pisa*
 Stefania Boccia, *Rome*
 Luigi Bonavina, *San Donato*
 Pier Andrea Borea, *Ferrara*
 Giovanni Cesana, *Milan*
 Stefano Crippa, *Verona*
 Giovanni D De Palma, *Napoli*
 Giovanni De Simone, *Napoli*
 Giuseppe Malleo, *Verona*
 Giorgio Ercolani, *Bologna*
 Carlo Feo, *Ferrara*
 Simone Ferrero, *Genova*
 Valenza Franco, *Milano*
 Leandro Gennari, *Rozzano*
 Felice Giuliant, *Roma*
 Salvatore Gruttadauria, *Palermo*
 Calogero Iacono, *Verona*
 Riccardo Lencioni, *Pisa*
 Dottor Fabrizio Luca, *Milan*
 Paolo Massucco, *Candiolo*
 Giorgio Di Matteo, *Roma*
 Giulio Melloni, *Milan*
 Manuela Merli, *Roma*
 Paolo Morgagni, *Forlì*
 Chiara Mussi, *Rozzano*
 Gabriella Nesi, *Florence*
 Angelo Nespoli, *Monza*
 Fabio Pacelli, *Rome*
 Corrado Pedrazzani, *Siena*
 Roberto Persiani, *Rome*
 Piero Portincasa, *Bari*
 Pasquale Petronella, *Napoli*
 Stefano Rauseri, *Varese*
 Carla Ida Ripamonti, *Milan*
 Antonio Russo, *Palermo*
 Giulio A Santoro, *Treviso*
 Stefano Scabini, *Genoa*
 Gianfranco Silecchia, *Roma*
 Guido AM Tiberio, *Brescia*
 Umberto Veronesi, *Milano*
 Bruno Vincenzi, *Rome*
 Marco Vivarelli, *Bologna*
 Alberto Zaniboni, *Brescia*
 Alessandro Zerbi, *Milan*



Jamaica

Joseph M Plummer, *Kingston*



Japan

Yasunori Akutsu, *Chiba*

Ryuichiro Doi, *Kyoto*
 Yosuke Fukunaga, *Sakai*
 Akira Furukawa, *Shiga*
 Shigeru Goto, *Oita*
 Kazuhiko Hayashi, *Tokyo*
 Naoki Hiki, *Tokyo*
 Takeyama Hiromitsu, *Nagoya*
 Tsujimoto Hironori, *Tokorozawa*
 Tsukasa Hotta, *Wakayama*
 Yutaka Iida, *Gifu*
 Kazuaki Inoue, *Yokohama*
 Masashi Ishikawa, *Tokushima*
 Tatsuo Kanda, *Niigata*
 Tatsuyuki Kawano, *Tokyo*
 Keiji Koda, *Chiba*
 Hajime Kubo, *Kyoto*
 Iruru Maetani, *Tokyo*
 Yoshimasa Maniwa, *Kobe*
 Toru Mizuguchi, *Hokkaido*
 Zenichi Morise, *Toyoake*
 Yoshihiro Moriwaki, *Yokohama*
 Yoshihiro Moriya, *Tokyo*
 Satoru Motoyama, *Akita*
 Hiroaki Nagano, *Osaka*
 Masato Nagino, *Nagoya*
 Toshio Nakagohri, *Kashiwa*
 Kazuyuki Nakamura, *Yamaguchi*
 Shingo Noura, *Osaka*
 Kazuo Ohashi, *Tokyo*
 Yoichi Sakurai, *Toyoake*
 Hirozumi Sawai, *Nagoya*
 Masayuki Sho, *Nara*
 Yasuhiko Sugawara, *Tokyo*
 Hiroshi Takamori, *Kumamoto*
 Sonshin Takao, *Kagoshima*
 Kuniya Tanaka, *Yokohama*
 Masanori Tokunaga, *Shizuoka*
 Yasunobu Tsujinaka, *Kashiwa*
 Akira Tsunoda, *Kamogawa*
 Toshifumi Wakai, *Niigata*
 Jiro Watari, *Nishinomiya*
 Shinichi Yachida, *Kagawa*
 Yasushi Yamauchi, *Fukuoka*
 Hiroki Yamaue, *Wakayama*
 Yutaka Yonemura, *Osaka*



Malaysia

Way Seah Lee, *Kuala Lumpur*



Netherlands

Lee H Bouwman, *Hague*
 Wim A Buuman, *Maastricht*
 Robert Chamuleau, *Amsterdam*
 Miguel A Cuesta, *Amsterdam*
 Jeroen Heemskerk, *Roermond*
 Buis Carljin Ineke, *Deventer*
 Wjhj Meijerink, *Amsterdam*
 Chj van Eijck, *Rotterdam*
 Alexander L Vahrmeijer, *Leiden*



Pakistan

Kamran Khalid, *Lahore*

**Poland**

Bogusław Machaliński, *Szczecin*

**Portugal**

Jorge Correia-Pinto, *Braga*

**Russia**

Grigory G Karmazanovsky, *Moscow*

**Singapore**

Brian KP Goh, *Singapore*
Salleh bin Ibrahim, *Singapore*
John M Luk, *Singapore*
Francis Seow-Choen, *Singapore*
Vishalkumar G Shelat, *Singapore*
Melissa Teo, *Singapore*

**Serbia**

Ivan Jovanovic, *Belgrade*

**South Korea**

Joon Koo Han, *Seoul*
Hyung-Ho Kim, *Seongnam*
Woo Ho Kim, *Seoul*
Sang Y Lee, *Gyeongangnam-do*
Woo Yong Lee, *Seoul*
Hyo K Lim, *Seoul*
Jae-Hyung Noh, *Seoul*
Sung Hoon Noh, *Seoul*
Hee Jung Wang, *Suwon*

**Spain**

Antonio M Lacy Fortuny, *Barcelona*
Laura L Garriga, *Barcelona*
Francisco José Vizoso, *Gijón*
David Parés, *Sant Boi de Llobregat*
Prieto Jesus, *Pamplona*

**Sweden**

Helgi Birgisson, *Uppsala*
Jörgen Rutegård, *Umeå*

**Switzerland**

Andrea Frilling, *Zürich*
Pascal Gervaz, *Genève*
Bucher Pascal, *Geneva*
Marc Pusztaszeri, *Carouge*

**Thailand**

Varut Lohsiriwat, *Bangkok*
Rungsun Rerknimitr, *Bangkok*

**Tunisia**

Nafaa Arfa, *Tunis*

**Turkey**

Ziya Anadol, *Ankara*
Unal Aydin, *Gaziantep*
Mehmet Fatih Can, *Ankara*
Gözde Kir, *Istanbul*
Adnan Narci, *Afyonkarahisar*
Ilgin Ozden, *Istanbul*
Mesut Abdulkemim Ünsal, *Trabzon*
Omer Yoldas, *Ordu*

**United Kingdom**

Graeme Alexander, *Cambridge*
Simon R Bramhall, *Birmingham*
Giuseppe Fusai, *London*
Najib Haboubi, *Manchester*
Gianpiero Gravante, *Leicester*
Aftab Alam Khan, *Kent*
Caroline S Verbeke, *Leeds*

**United States**

Eddie K Abdalla, *Houston*

Forse Robert Armour, *Omaha*
Samik K Bandyopadhyay, *Kolkata*
Marc D Basson, *Lansing*
James M Becker, *Boston*
Thomas D Boyer, *Tucson*
Michael E de Vera, *Pittsburgh*
Andrew J Duffy, *New Haven*
Kelli Bullard Dunn, *Buffalo*
Thomas Fabian, *New Haven*
P Marco Fisichella, *Maywood*
Raja M Flores, *New York*
Markus Frank, *Boston*
Niraj J Gusani, *Hershey*
Douglas W Hanto, *Boston*
John P Hoffman, *Philadelphia*
Scott A Hundahl, *California*
Michel Kahaleh, *Charlottesville*
David S Kauvar, *Maryland*
Mary M Kemeny, *New York*
Nancy E Kemeny, *New York*
Vijay P Khatri, *Sacramento*
Joseph Kim, *Duarte*
Andrew Klein, *Los Angeles*
Richard A Kozarek, *Seattle*
Robert A Kozol, *Farmington*
Sunil Krishnan, *Houston*
Atul Kumar, *New York*
Wei Li, *Seattle*
Keith D Lillemoe, *Indianapolis*
Henry T Lynch, *Omaha*
Paul Ellis Marik, *Philadelphia*
Robert C Miller, *Rochester*
Thomas J Miner, *Providence*
Ravi Murthy, *Houston*
Atsunori Nakao, *Pittsburgh*
Hirofumi Noguchi, *Dallas*
Jeffrey A Norton, *Stanford*
Timothy M Pawlik, *Baltimore*
Nicholas J Petrelli, *Newark*
Alessio Pigazzi, *Duarte*
James John Pomposelli, *Carlisle*
Mitchell C Posner, *Chicago*
Alexander S Rosemurgy, *Florida*
Ng Chaaan S, *Houston*
Sukamal Saha, *Flint*
Reza F Saidi, *Boston*
Aaron R Sasson, *Omaha*
Christian M Schmidt, *Indianapolis*
Perry Shen, *Winston-Salem*
Ali A Siddiqui, *Dallas*
Frank A Sinicropo, *Rochester*
Thomas Earl Starzl, *Pittsburgh*
John H Stewart, *Winston-Salem*
Paul H Sugarbaker, *Washington*
Douglas S Tyler, *Durham*
Vic Velanovich, *Detroit*
Alan Wilkinson, *Los Angeles*
M Michael Wolfe, *Boston*
Christopher L Wolfgang, *Baltimore*
You-Min Wu, *Little Rock*
Zhi Zhong, *Charleston*



EDITORIAL

- 73 Current trends in the diagnosis and management of post-herniorrhaphy chronic groin pain
Hakeem A, Shanmugam V

CASE REPORT

- 82 Successful treatment of esophageal metastasis from hepatocellular carcinoma using the da Vinci robotic surgical system
Boonnuch W, Akaraviputh T, Nino C, Yiengpruksawan A, Christiano AA
- 86 Pneumatosis intestinalis and pneumoperitoneum on computed tomography: Beware of non-therapeutic laparotomy
Hsueh KC, Tsou SS, Tan KT

ACKNOWLEDGMENTS I Acknowledgments to reviewers of *World Journal of Gastrointestinal Surgery*

APPENDIX I Meetings
I-V Instructions to authors

ABOUT COVER Boonnuch W, Akaraviputh T, Nino C, Yiengpruksawan A, Christiano AA. Successful treatment of esophageal metastasis from hepatocellular carcinoma using the da Vinci robotic surgical system.
World J Gastrointest Surg 2011; 3(6): 82-85
<http://www.wjgnet.com/1948-9366/full/v3/i6/82.htm>

AIM AND SCOPE *World Journal of Gastrointestinal Surgery* (*World J Gastrointest Surg*, *WJGS*, online ISSN 1948-9366, DOI: 10.4240), is a monthly, open-access, peer-reviewed journal supported by an editorial board of 336 experts in gastrointestinal surgery from 35 countries.

The major task of *WJGS* is to rapidly report the most recent results in basic and clinical research on gastrointestinal surgery, specifically including micro-invasive surgery, laparoscopy, hepatic surgery, biliary surgery, pancreatic surgery, splenic surgery, surgical nutrition, portal hypertension, as well as the associated subjects such as epidemiology, cancer research, biomarkers, prevention, pathology, radiology, genetics, genomics, proteomics, pharmacology, pharmacokinetics, pharmacogenetics, molecular biology, clinical trials, diagnosis and therapeutics and multimodality treatment. Emphasis is placed on original research articles and clinical case reports. This journal will also provide balanced, extensive and timely review articles on selected topics.

FLYLEAF I-III Editorial Board

EDITORS FOR THIS ISSUE

Responsible Assistant Editor: *Le Zhang*
Responsible Electronic Editor: *Jin-Lei Wang*
Proofing Editor-in-Chief: *Lian-Sheng Ma*

Responsible Science Editor: *Jin-Lei Wang*
Proofing Editorial Office Director: *Jin-Lei Wang*

NAME OF JOURNAL
World Journal of Gastrointestinal Surgery

LAUNCH DATE
November 30, 2009

SPONSOR
Beijing Baishideng BioMed Scientific Co., Ltd.,
Room 903, Building D, Ocean International Center,
No. 62 Dongsihuan Zhonglu, Chaoyang District,
Beijing 100025, China
Telephone: +86-10-8538-1892
Fax: +86-10-8538-1893
E-mail: baishideng@wjgnet.com
<http://www.wjgnet.com>

EDITING
Editorial Board of *World Journal of Gastrointestinal Surgery*,
Room 903, Building D, Ocean International Center,
No. 62 Dongsihuan Zhonglu, Chaoyang District,
Beijing 100025, China
Telephone: +86-10-8538-1891
Fax: +86-10-8538-1893
E-mail: wjgs@wjgnet.com
<http://www.wjgnet.com>

PUBLISHING
Baishideng Publishing Group Co., Limited,
Room 1701, 17/F, Henan Building,
No.90 Jaffe Road, Wanchai,

Hong Kong, China
Fax: +852-3115-8812
Telephone: +852-5804-2046
E-mail: baishideng@wjgnet.com
<http://www.wjgnet.com>

SUBSCRIPTION
Beijing Baishideng BioMed Scientific Co., Ltd.,
Room 903, Building D, Ocean International Center,
No. 62 Dongsihuan Zhonglu, Chaoyang District,
Beijing 100025, China
Telephone: +86-10-8538-1892
Fax: +86-10-8538-1893
E-mail: baishideng@wjgnet.com
<http://www.wjgnet.com>

PUBLICATION DATE
June 27, 2011

ISSN
ISSN 1948-9366 (online)

PRESIDENT AND EDITOR-IN-CHIEF
Lian-Sheng Ma, *Beijing*

STRATEGY ASSOCIATE EDITORS-IN-CHIEF
Elijah Dixon, *Calgary*
Antonello Forgione, *Milan*
Tobias Keck, *Freiburg*
Tsuyoshi Konishi, *Tokyo*
Natale Di Martino, *Naples*

EDITORIAL OFFICE
Jin-Lei Wang, Director
World Journal of Gastrointestinal Surgery
Room 903, Building D, Ocean International Center,
No. 62 Dongsihuan Zhonglu, Chaoyang District,
Beijing 100025, China
Telephone: +86-10-8538-1891
Fax: +86-10-8538-1893
E-mail: wjgs@wjgnet.com
<http://www.wjgnet.com>

COPYRIGHT
© 2011 Baishideng. Articles published by this Open-Access journal are distributed under the terms of the Creative Commons Attribution Non-commercial License, which permits use, distribution, and reproduction in any medium, provided the original work is properly cited, the use is non commercial and is otherwise in compliance with the license.

SPECIAL STATEMENT
All articles published in this journal represent the viewpoints of the authors except where indicated otherwise.

INSTRUCTIONS TO AUTHORS
Full instructions are available online at http://www.wjgnet.com/1948-9366/g_info_20100305152206.htm.

ONLINE SUBMISSION
<http://www.wjgnet.com/1948-9366office>

Current trends in the diagnosis and management of post-herniorraphy chronic groin pain

Abdul Hakeem, Venkatesh Shanmugam

Abdul Hakeem, Department of General Surgery, Aintree University Hospital NHS Trust, Longmoor Lane, Liverpool, L9 7AL, United Kingdom

Venkatesh Shanmugam, Department of General and Colorectal Surgery, Nottingham University Hospital NHS Trust, Queens Medical Centre, Nottingham, NG7 2UH, United Kingdom

Author contributions: Hakeem A did the literature search and wrote the initial draft; Shanmugam V cross-checked the literature search, edited the paper and conceptualised the idea.

Correspondence to: Mr. Abdul Hakeem, MRCS, Department of General Surgery, Aintree University Hospital NHS Trust, Longmoor Lane, Liverpool, L9 7AL, United Kingdom. drhabdulrahman@yahoo.com

Telephone: +44-113-8085924 Fax: +44-132-5490293

Received: March 1, 2011 Revised: April 24, 2011

Accepted: May 1, 2011

Published online: June 27, 2011

Peer reviewers: Hayrullah Derici, MD, Associate Professor, Department of General Surgery, Balikesir University Medical Faculty, Balikesir 10145, Turkey; Marty Zdichavsky, MD, Department of General, Visceral and Transplant Surgery, University Hospital Tübingen, Hoppe-Seyler-Str. 3, 72076 Tübingen, Germany

Hakeem A, Shanmugam V. Current trends in the diagnosis and management of post-herniorraphy chronic groin pain. *World J Gastrointest Surg* 2011; 3(6): 73-81 Available from: URL: <http://www.wjgnet.com/1948-9366/full/v3/i6/73.htm> DOI: <http://dx.doi.org/10.4240/wjgs.v3.i6.73>

Abstract

Inguinodynia (chronic groin pain) is one of the recognised complications of the commonly performed Lichtenstein mesh inguinal hernia repair. This has major impact on quality of life in a significant proportion of patients. The pain is classified as neuropathic and non-neuropathic related to nerve damage and to the mesh, respectively. Correct diagnosis of this problem is relatively difficult. A thorough history and clinical examination are essential, as is a good knowledge of the groin nerve distribution. In spite of the common nature of the problem, the literature evidence is limited. In this paper we discuss the diagnostic tools and treatment options, both non-surgical and surgical. In addition, we discuss the criteria for surgical intervention and its optimal timing.

© 2011 Baishideng. All rights reserved.

Key words: Hernia; Lichtenstein repair; Chronic groin pain; Inguinodynia; Neuropathic pain; Neurectomy; Nerve block

INTRODUCTION

Mesh inguinal hernia repair is one of the most common operations performed worldwide. Inguinodynia or Chronic Groin Pain following this operation is a potential complication and its incidence can be as high as 62.9%^[1]. A quarter of these patients suffer from severe impairment in carrying out their daily routines^[2-4]. Courtney *et al*^[5] showed the effect of chronic groin pain on physical and social functioning, thereby limiting the individual's ability to participate in any paid employment. The rate of chronic groin pain following both open and laparoscopic hernia repair is vastly underreported^[6,7]. Hindmarsh *et al*^[8] shown that only 1% of patients with chronic groin pain post-herniorrhaphy were referred for further treatment. The main purpose of this review is to look at the available evidence on diagnostic modalities for this chronic problem and to discuss the varied treatment options practised worldwide.

AETIOLOGY OF CHRONIC GROIN PAIN

The exact aetiology of this complex pain is unknown, although various theories have been proposed. Chronic groin pain has been classified empirically as neuropathic or non-neuropathic in origin. Neuropathic pain is con-

sidered to be due to damage to the inguinal nerves and usually develops in the sensory distribution of the injured nerve. Non-neuropathic pain is caused by either mesh-related fibrosis or post-operative fibrosis. The nerves involved are the Ilioinguinal nerve (IIN), the Iliohypogastric nerve (IHN), the genital branch of the Genito-Femoral nerve (GFN) and, rarely, the Lateral Femoral Cutaneous nerve (LFC). These nerves can be damaged either by partial or complete transection, stretching, contusion, crushing, electrical damage or by being caught in the suture used in open repair or the tacks used in laparoscopic repair. Secondary nerve damage can also occur as a result of adjacent inflammatory processes, such as granuloma, or because of excess fibrotic reaction or mesh encasement^[9]. Wantz *et al*^[10] showed that handling of the sensory nerves during surgery leads to chronic residual neuralgia.

Heise *et al*^[11] were the first to describe non-neuropathic pain caused by rolling up of the mesh or mesh-related excess fibrosis. Similarly, another pain syndrome, termed “somatic pain”, has been described secondary to damage to the pubic tubercle while anchoring the mesh^[12]. A small group of patients have been shown to suffer from diffuse pain around the spermatic cord (funiculodynia), resulting in ejaculatory pain^[13]. This has been described as “visceral pain” and is due to venous congestion of the spermatic cord or to mesh encasement of the cord. A combination of neuropathic, non-neuropathic, visceral and somatic pain is common, making clinical or radiological differentiation of the cause extremely difficult.

During laparoscopic repair, the IIN is at risk lateral to the internal ring and the GFN medial to the ring. The IHN is commonly damaged by tacks or staples along its entire length, making it highly vulnerable during laparoscopic mesh fixation^[14-16]. Occasional damage to the LFC nerve^[17,18] and the femoral nerve^[19] have also been shown during laparoscopic repair. Although laparoscopic repair has been shown to result in reduced chronic groin pain, exact reasons for this are unclear^[20-23].

COMPLEX SYMPTOMS OF CHRONIC GROIN PAIN

The complex symptoms of post-herniorrhaphy chronic pain vary depending on the involvement of the nerve or nerves, amount of mesh-related fibrosis and damage to spermatic cord structures. The neuropathic symptoms include pain (neuralgia), burning sensation (paraesthesia), reduced sensation (hypoesthesia) and increased sensation (hyperaesthesia). The pain may radiate to the hemiscrotum, upper leg or back.

Neuropathic pain is usually characterised by the presence of a trigger point, its episodic nature and by being aggravated by walking or sitting. It is variously described as a stabbing, burning, shooting or pricking sensation^[24]. In contrast, non-neuropathic pain is a constant dull-ache over the entire groin area with no specific trigger point and is usually aggravated by strenuous exercise. Patients

commonly describe it as a gnawing, tender, pulling or pounding sensation^[11].

A small group of patients also report numbness over the groin or thigh, with the most common point of maximal tenderness at the pubic tubercle. These patients have inflammation of the pubic tubercle either due to stitches made on the pubic bone during open repair or application of tacks in laparoscopic repair^[13]. Another range of symptoms are related to sexual dysfunction due to vas engulment and inflammatory reaction caused by the mesh. Patients describe ejaculatory pain in the region of superficial ring or testicular or labial pain due to GFN irritation^[25]. Other complaints included diminished quality of life, mood swings and depression^[26,27].

DIAGNOSIS OF CHRONIC GROIN PAIN

The diagnosis of chronic groin pain begins with a comprehensive patient history and good knowledge of the anatomy of inguinal nerves. The history should include the commonly encountered risk factors for chronic groin pain which include age below median, female gender, postoperative complications, recurrent hernia repair, open repair techniques, history of preoperative pain and an interval of less than 3 years from surgery^[28].

Due to the infrequent presentation of chronic groin pain, there is no clear consensus on the diagnosis of this iatrogenic problem. Neuropathic pain is usually distributed along the sensory innervations of the affected nerve(s) and can be reproduced by tapping the skin medial to the antero-superior iliac spine or over an area of local tenderness (Tinel's test). The clinical differentiation of ilioinguinal, iliohypogastric and genitofemoral neuralgia is difficult, frequently resulting in misdiagnosis and inappropriate treatment^[29,30]. This is because of the overlapping sensory innervations of these three nerves, peripheral communication between their nerve twigs and, most importantly, their common roots of origin^[31]. Along with these anatomical factors, fibrosis caused by the procedure and the mesh causes a degree of non-neuropathic pain in most cases, thereby making it difficult to delineate the neuropathic cause clinically.

Deysine *et al*^[32] and Starling *et al*^[33] used IIN block and recommended IIN neurectomy if the block relieved pain. If pain persisted after IIN block, L1-L2 plexus block was carried out and, if this relieved pain, GFN neurectomy was then performed. If pain was partially relieved by both blocks, groin exploration of both nerves was then carried out. There is no consensus on how these nerve blocks should be performed and how the results should be interpreted. Bower *et al*^[34] showed that after an unspecified nerve block, 13 out of 15 patients had pain relief and went on to have their IIN, IHN and/or LFC nerve excised. Again, there were no clear criteria for putting the patient through neurectomy.

Heise *et al*^[11] suggested that nerve block neither predicts nor changes outcome. They suggested that if hernia is done without mesh, then nerve blocks are needed to

identify nerve involvement. However, if a mesh is present, the sensitivity of the test is poor due to lack of spread of anaesthetic agent because of mesh-related fibrosis. Though peripheral nerve blocks or paravertebral blocks have been tried, they lack the ability to differentiate the involved nerve and are only helpful temporarily as a means of relieving pain.

CT or MRI scans are helpful in identifying non-neuropathic causes of chronic groin pain by identifying mesh-related pathologies, recurrent hernias and occasionally neuromas^[35,36]. A few studies have used MR Neurography to differentiate the involved nerves by studying the water content of the inguinal nerves^[37]. Kim *et al*^[38] carried out electromyograms on all patients, specifically looking for denervation of the pyramidalis muscle which is supplied by the IIN nerve. They showed that 91% of IIN neurectomies and 90% of combined neurectomies were successful, although there was no mention of the rate of pain recurrence.

TREATMENT OPTIONS FOR CHRONIC GROIN PAIN

The treatment of chronic groin pain can be a difficult ordeal for both the patient and the clinician. Many algorithms have been put forward for management of chronic groin pain^[2,39], but none of them has been proved in randomised trials. Pain related to neuropraxia (intact axon and myelin sheath), is usually temporary and may resolve itself in around 6 mo post-herniorraphy. As time progresses, chronic groin pain disappears without treatment in 30% of the patients, remains mild in 45% and in 25% of them it persists as severe pain affecting their everyday life^[5].

NON-SURGICAL TREATMENT

Lifestyle modification

Chronic groin pain has been shown to be aggravated by walking, stooping or hyper-extension of the hip and relieved by recumbent position and flexion of the hip and thigh^[35]. Hence, some clinicians have advised lifestyle changes, advocating sedentary lifestyle or sedentary occupations to negate the neuropathic pain caused by movement. This leads to poor quality of life and loss of productivity^[5] and is not now recommended because of the availability of better medical and surgical modalities.

Analgesics

Many clinicians use pharmacologic agents to manage chronic groin pain. These include non-steroidal anti-inflammatory drugs (NSAIDs), opioids, muscle relaxants, antiepileptics and antidepressants. However, these drugs may not prove helpful in relieving all types of chronic groin pain. The anti-depressants and antiepileptics are helpful in neuropathic pain whereas opioids or NSAIDs are usually minimally effective or ineffective for neuropathies^[40]. In most studies, NSAIDs were used as the first

line analgesic treatment. Kim *et al*^[38] used gabapentin or oral steroids as second line agents following the failure of NSAIDs. The steroids work by reducing the inflammation and oedema surrounding entrapped nerves. The efficacy of these treatment regimens has not been proven and majority of patients suffer recurrence with worse pain due to development of resistance to analgesics.

Physical and psychological therapies

Physical therapies including massage, physiotherapy and acupuncture have been tried^[24]. Keller *et al*^[41] used thermotherapy to temporarily negate the painful stimulus. Ferzli *et al*^[42] tried Capsaicin cream applied topically as a counter-irritant to desensitize painful stimulus. These physical techniques may reduce pain temporarily but few, if any, can prevent the recurrence of pain.

Nerve blocks

Nerve blocks reversibly interfere with neuronal transmission, leading to temporary pain relief. This can, therefore, be both diagnostic and therapeutic. The ideal nerve block would specifically anaesthetise the nerve proximal to the injury but this is technically challenging. Various chemical agents used for blockade are shorter- or longer- acting local anaesthetics, steroids and glycerol as well as neurolytic solutions such as alcohol or phenol^[11]. Commonly, these agents prevent neuronal transmission through nerve fibres either by blocking membrane ion channels or by denaturation of axon proteins. They can also be used with non-pharmacologic techniques like cryoanalgesia and transcutaneous electrical nerve stimulation, depending upon the response to the anaesthetic agents. All these therapeutic modalities have their own risks, therefore a positive diagnostic block should guide the further use of therapeutic blocks.

There is little published information on the success rate of nerve block as this depends on the experience of the surgeon or the anaesthetist performing the procedure. There is no consensus on approach or the type of anaesthetic agent to be used for therapeutic inguinal nerve blockade. Previously, blind injection of local anaesthetics was practiced, based on knowledge of the anatomy of the nerves. Recently Ultrasound guided blocks have been shown to be highly accurate and selective for blockade of either the IIN or the IHN, thereby increasing success rates^[43]. In a case reported by Hartrick, GFN block was attempted through a trans-psoas approach using the L3-L4 vertebral space as a guide^[44]. This anecdotal evidence cannot be generalised to the population and more extensive controlled trials are needed.

Alcohol or phenol injection has been tried for reducing chronic inflammation caused by mesh or post-operative fibrosis^[45]. Neuro-destructive procedures, such as cryo-ablation which destroy the nerve fibres by coagulation at very low temperatures (-40°C), have been shown to give some temporary pain relief^[46]. Following cryo treatment pain recurred due to axonal regeneration. Radiofrequency pulses, working by thermo-coagulating

nerves at very high temperatures, have been shown to cause temporary pain relief in ilioinguinal neuralgia^[47]. Again, definite evidence for their effectiveness is lacking.

SURGICAL TREATMENT

The surgical treatment of chronic groin pain was first described by Stulz *et al*^[48] in 1982. They performed IIN neurectomy on 5 patients with chronic groin pain following inguinal hernia repair, achieving a 100% success rate. However, surgical explorations and neurectomy carried out by other groups during this period were quite unsuccessful. Hameroff *et al*^[49] performed IIN neurectomy on 2 patients with 100% recurrent pain after few months. Harms *et al*^[30] reported similar problems, also in two patients. The first patient had 2 unsuccessful explorations, followed by successful GFN block and 3rd exploration leading to GFN neurectomy. Second patient had IIN neurectomy on 1st exploration and, due to recurrence of pain further, exploration and GFN neurectomy. Since then a number of studies have shown success rates ranging from 70%-100%^[11,12,24,27,29,30,32-34,38,41,48-59] (Table 1).

Principles of surgical treatment

Removal of the foreign body (mesh) alone has not been shown to relieve chronic groin pain. It is thought that it is due to chronic inflammation around the nerves from the mesh-induced reaction and the consequent degenerative nerve damage. Traditionally, surgical treatment of chronic groin pain includes groin exploration, mesh removal and neurectomy. Open chemical neurolysis has been tried, but does not resolve the problem of neuromas and secondary scarification^[33]. Freeing the nerve alone (physical neurolysis) has been tried but with high failure rates^[27,53]. Similarly simple division of the nerves without resection is not recommended. The entire length of the nerves should be excised, in order to involve all the neural connections between the nerves. Neurectomy with or without mesh excision is usually the preferred surgical treatment but there are no current consensus on which surgical approach should be chosen and which nerve should be excised. Heise *et al*^[11] found that 62% of patients who had mesh removal plus neurectomy achieved excellent results in comparison with the mesh-removal-alone group where the success rate was 50%. They concluded that concurrent neurectomy affords better results than mesh removal alone. Recently radio-frequency ablation of inguinal nerves have used with the aim for ablating the painful impulses transmitted by injured nerves. Rozen *et al*^[60] found that after radio-frequency ablation at T12, L1, L2 root level 4 out of 5 patients showed complete resolution of pain 4 to 9 mo later. Again, there is a lack of systematic evidence to support these findings.

The IIN can be identified lateral to the internal ring and then traced towards the external ring and resected as distally as possible. The IHN can be identified by the separation of the external oblique aponeurosis from the underlying internal oblique muscle as proximally as possible. With the IHN, dissection should include the intra-

muscular section, in order to look for nerve entrapped by sutures, mesh plugs or tacks. The GFN is usually identified through a retro-peritoneal (flank) approach. In a very rare case of LFC nerve involvement, decompression was performed by releasing the inguinal ligament on the anterior superior iliac spine and the lateral fibres of internal oblique aponeurosis^[27].

Amid adopted an anterior approach, where the nerve could be identified within the lateral crus of the internal ring, within the internal ring or between the spermatic cord and the inguinal ligament. He showed that complete resection might not be possible with this approach, but that even partial resection is sufficient if the other 2 nerves are resected completely^[54]. He devised a single stage procedure, where simultaneous IIN, IHN and GFN neurectomies were performed under local anaesthetic with proximal end implantation of these nerves. Amid also devised a technique of implanting the cut end of the IIN and IHN within the fibres of the internal oblique, reducing the risk of adherence with aponeurotic structures and thereby reducing the chance of recurrent pain^[36]. For GFN, the nerve was cut under tension in order to retract the nerve into the internal ring. In a retrospective review of 225 patients who underwent surgery for neuropathic and non-neuropathic pain, 11% had traumatic neuroma, 32% had nerve entrapment by suture, staple or mesh and 57% had perineural fibrosis^[36]. They showed complete improvement in 85% of their patients, while 15% of them had transient insignificant pain with no functional impairment. Four of the 225 patients showed no benefit from this triple neurectomy^[36]. Krähenbühl *et al*^[55] performed laparoscopic triple neurectomies using a retro-peritoneal approach and showed complete cure in three patients. Ducic *et al*^[56] adopted an open inguinal approach to identify the GFN postero-lateral to the cord, traced the nerve from there all the way to the pre-peritoneum and resected under tension. They showed 100% pain relief in 4 patients treated with GFN neurectomy.

Resected tissue from neurectomy should be sent for histology to confirm the removal of the involved nerve. Most importantly, there should be an informed decision about post-neurectomy numbness in the area of corresponding nerve innervation.

Criteria for surgical treatment

Surgical treatment is required if refractory pain persists after treatment with oral analgesics and/or local nerve(s) blockades. Nerve block must have resulted in a complete or substantial decrease in pain before neurectomy can be recommended. There are no defined limits on how often nerve blocks can be carried out and the practice has varied among surgeons worldwide. Deysine *et al*^[32] employed IIN block and if it was effective on first use, IIN neurectomy was then considered. No information is given on the success rate of nerve blockade from this study or the reasons for selecting successful IIN block alone as an indication for surgical treatment. Kim *et al*^[38] also relied on nerve blocks alone as an indication for neurectomy. They concluded that the nerve blocks were sensitive enough if

Table 1 Studies showing neurectomy performed by open, laparoscopic or a combination of both open and laparoscopic approach

Author	Country	No. of pts	Surgical approach	Which nerve excised?	Was mesh excised?	Follow-up duration	Recurrence/Persistent pain	Complications	Remarks
Hameroff <i>et al</i> ^[49] , 1981	USA	2	Open	IIN	N/A	NM	2/2	Nil	Only temporary pain relief following neurectomy
Stulz <i>et al</i> ^[48] , 1982	Switzerland	5	Open	IIN	N/A	NM	No separate data for inguinal hernia patients	Nil	Out of 22 patients who underwent neurectomy, 5 had previous inguinal hernia repair. In all inguinal hernia cases, IIN was entrapped within the scarred tissue and was excised
Harms <i>et al</i> ^[30] , 1984	USA	2	Open	GFN, IIN + GFN	N/A	18 mo (patient 1), NM in other patient	2/2	Wound infection (2)	First patient had 2 unsuccessful exploration, followed by successful GFN block and 3rd exploration with GFN neurectomy. Second patient had IIN neurectomy on 1st exploration and due to recurrence of pain further exploration and GFN neurectomy
Starling <i>et al</i> ^[33] , 1987	USA	26	Open	IIN or GFN	N/A	NM	2/13 in IIN group and 3/13 in all GFN group patients	Nil	No differentiation possible in GFN group to establish only patients with previous hernia repair. Overall 10 out of 13 with GFN neurectomy were pain free
Starling <i>et al</i> ^[29] , 1989	USA	31	Open	IIN or GFN	NM	NM	2/19 in IIN 4/12 in GFN	Nil	Selective nerve blocks used to identify involved nerve(s). In GFN group, no data was given to differentiate those patients who had hernia repair and those who had other abdominal operations
Bower <i>et al</i> ^[34] , 1996	USA	15	Open	IIN, IHN, GFN or LFC	No	66 mo	3/12	Nil	Three patients had persistent pain following redo exploration. Redo explorations could not identify involved nerve in two patients and identified a recurrent hernia in the other patient
Nahabedian <i>et al</i> ^[51] , 1997	USA	2	Open	IIN, IHN or GFN	NM	21 mo	0/2	Nil	In one of the patients, no nerve was identified intra-operatively and on the tissue excised, but pain relief was noted post-operatively
Heise <i>et al</i> ^[11] , 1998	USA	20	Open	IIN or IHN or GFN	Yes	16 ± 3 mo	8/20	Haematoma (1), Testicular atrophy (1)	4 patients had only mesh excised and 6 patients underwent selective neurectomy based on operative findings plus mesh excision
Lee <i>et al</i> ^[53] , 2000	USA	11	Open	IIN, IHN, GFN or LFC	Yes	10 mo	NM	Haematoma (1) and recurrent hernia (1)	History and clinical examination alone was done for pre-operative assessment. Mesh removal alone did not relieve pain in any patients. IIN was commonly excised. Majority of patients had excellent pain relief, no differentiation could be done to identify those with hernia repair
Deysine <i>et al</i> ^[32] , 2002	USA	22	Open	IIN	No	NM	0/22	Nil	Diagnostic nerve blocks were attempted in all patients. 8 out of 30 patients responded to conservative treatment and the rest were subjected to IIN neurectomy alone. No follow-up data was available and complications were not mentioned
Ducic <i>et al</i> ^[56] , 2004	USA	4	Open	GFN + IIN	No	9 mo	0/4	Nil	All patients had failed medical treatment. No clear information on diagnosis of nerve entrapment, One patient had previous unsuccessful GFN resection and another patient had previous failed IIN resection
Kim <i>et al</i> ^[38] , 2005	USA	16 (33 total)	Open	IIN, IIN + IHN	NM	12-46 mo	3/33, 10% had recurrent pain, but no clear mention about hernia patients	NM for hernia patients	33 patients were operated for CGP, but only 16 had previous hernia repair. Diagnostic nerve blocks done on all patients. Of all 33 patients operated, 91% of IIN neurectomies and 90% of combined IIN + IHN neurectomies were successful

Amid <i>et al</i> ^[54] , 2004	USA	225	Open	Triple neurectomy	Yes	6 mo	15% had transitional incisional pain with no functional impairment	Nil	Proposed 1-stage procedure of simultaneous neurectomy of all three nerves without mobilisation of spermatic cord. The nerve ends were implanted proximally into the fibres of internal oblique muscle
Murovic <i>et al</i> ^[50] , 2005	USA	1	Open	GFN	No	NM	0/1	Nil	Ten patients with Genitofemoral neuralgia were analysed, but only one patient had previous hernia repair. Diagnostic nerve blocks were used prior to GFN neurectomy by lateral extraperitoneal approach
Ducic <i>et al</i> ^[27] , 2008	USA	18	Open	IIN, IHN, GFN or LFC	NM	12-24 mo	3/18	Nil	Nerve blocks not routinely done. Patients selected for surgical intervention based on history and physical findings
Delikoukos <i>et al</i> ^[12] , 2008	Greece	6	Open	IIN	Yes	28 mo	0/6	Nil	No nerve blocks were utilised. Persistent pain in spite of analgesics were indication for surgery in this study. IIN were either excised or freed from the mesh, if entrapped
Vuilleumier <i>et al</i> ^[24] , 2009	Switzerland	43	Open	IIN + IHN	Yes	12 mo	2/43	Recurrent hernia (1)	Diagnosis of neuropathy was done using clinical findings and positive Tinel's sign. All patients had failed conservative treatment with systemic analgesics, injection of local anaesthetics and steroids, and physiotherapy. Radical neurectomy done in all cases. GFN not excised in any case
Zacast <i>et al</i> ^[58] , 2010	USA	27	Open	IIN, GFN	Yes	35 mo	6/19 (followed-up patients)	Nil	Diagnosis was made using selective nerve blocks. Only 19 of the 27 patients responded to telephone follow-up and 67% mentioned either complete pain relief or pain lesser than before
Loos <i>et al</i> ^[52] , 2010	Netherlands	54	Open	IIN, IHN, GFN	Yes	18 mo	24%	Haematoma (1), wound infection (1), haemorrhage (1), ischaemic orchitis (1)	Diagnostic nerve blocks were used in majority of them (78%) and some patients underwent CT or MRI (22%). Tailored neurectomy performed depending on intra-operative findings
Krähenbühl <i>et al</i> ^[55] , 1997	Switzerland	2	Laparoscopic (Retro- peritoneal)	GFN and IIN	No	3 mo	0/2	Nil	No information given about the diagnosis of CGP and indication for laparoscopic neurectomy. Retroperitoneal neurectomy done, but no clear mention about how the nerves were identified intra-operatively
Wong <i>et al</i> ^[59] , 2001	Canada	1	Laparoscopic (pre-peritoneal approach, under fluoroscopic guidance)	Nerve not excised	Yes (mesh and staples)	NM	0/1	Nil	Single patient report with 5 month history of groin pain following laparoscopic hernia repair. Mesh and tackers were found to entrap the IIN and were removed laparoscopically aided by fluoroscopy
Rosen <i>et al</i> ^[57] , 2006	USA	12	Combined open and laparoscopic	IIN + IHN	Yes	6 wk	0/12	Nil	All patients had previous open hernia repair and 2 failed percutaneous nerve blocks to treat CGP. TAPP repair done initially, followed by groin exploration, mesh removal and nerve transection. Too short follow-up
Keller <i>et al</i> ^[41] , 2008	USA	21	Combined open and laparoscopic	Triple neurectomy	Yes	6 wk	1/19 (followed up patients)	Nil	Percutaneous nerve block was unsuccessful in all patients. Initially transabdominal diagnostic laparoscopy was performed irrespective of the route of initial surgery. Mesh was placed in the opposite location to the first mesh (laparoscopic if the first was open and <i>vice-versa</i>). Too short follow-up

NM: Not mentioned; IIN: Ilioinguinal neurectomy; IHN: Iliohypogastric neurectomy; GFN: Genitofemoral neurectomy; LFC: Lateral femoral cutaneous neurectomy; CGP: Chronic groin pain; N/A: Not applicable; Triple Neurectomy: IIN + IHN + GFN neurectomy; TAPP: Trans-abdominal pre-peritoneal repair; CT: Computed tomographic; MRI: Magnetic resonance imaging.

carried out by an experienced anaesthetist. Bower *et al*^[34] showed temporary pain relief in 13 of their 17 patients following unspecified nerve block. These patients went on to have IIN, IHN or LFC neurectomy depending on operative findings. Failure or recurrence of pain following at least two attempted nerve blocks is the criterion for choosing surgery followed in most units worldwide.

Loos *et al*^[52] showed that previous pain treatment is a predictor of poor operative treatment result. Kehlet *et al*^[61] studied factors for persistent post-surgical pain and found that a few patients suffer from central nervous system sensitisation, making them refractory to any form of treatment and poor candidates for surgical exploration. Nerve blocks and TENS are effective treatments for such patients and surgery should be avoided^[52]. Currently there is no consensus on the type of assessment tool for patients needing neurectomy and, as a result, there is no definitive protocol available for selecting patients for surgical exploration.

Timing of surgical intervention

Differences in the assessment of chronic groin pain, and variations in diagnostic practice and in the length of trial period with nerve blocks, have meant that the timing of surgical intervention has been widely varied. The timing of surgical intervention should ideally be at least 6 mo after herniorraphy to give adequate time for any neuropraxia to settle and time to try medical management^[62].

Surgical approach

A combined open and laparoscopic approach has been proposed by two groups^[41,57]. Keller *et al*^[41] used a protocol where after removal of mesh from the previous hernia repair, further mesh was placed in the opposite location to the first mesh (laparoscopic, if previously open repair and *vice versa*). Twenty of 21 patients reported significant resolution of symptoms at 6 wk follow-up. Results showed that an initial laparoscopic approach aids examination of the inguinal areas to rule out a recurrent hernia or any other inguinal pathology. At the same time if a previous laparoscopic repair was performed, the mesh was excised and triple neurectomy plus re-do repair carried out using an open approach. Conversely, if an open repair was done previously, the inguinal areas were checked initially using laparoscopy and a TAPP repair performed, followed by mesh removal plus triple neurectomy through the previous open incision. These authors also found that one patient with testicular pain and a previous plug-and-patch repair, had the vas engulfed by mesh. Removal of the plug with the vas cured his symptoms, thereby avoiding an unnecessary neurectomy which would have been performed if open approach alone was applied.

Rosen *et al*^[57] took a similar approach in patients with previous open inguinal hernia repair, using initial laparoscopic evaluation and TAPP repair, followed by open exploration, removal of mesh and then IIN and IHN neurectomy. They believed that removal of GFN was not needed, as none of their patients had any ejaculatory or other sexual symptoms. In one patient with chronic or-

chalgia following previous plug and patch repair, the initial diagnostic laparoscopy showed plug mesh engulfing the vas deferens, and the resection of both led to permanent relief of pain. The other 11 patients showed significant improvement in their pain following neurectomy. To date, there are no randomised studies comparing the open and laparoscopic approaches for neurectomy. The majority of the available results are from individual case series and are, therefore, biased by individual surgeon's laparoscopic abilities and the small number of patients reported.

Which nerve should be excised?

A review of surgical treatment for chronic groin pain carried out by Aasvang *et al*^[63] showed that the details of surgical treatments used were not evidence based and varied between different published studies. There was no clear explanation in most studies of why only one or two nerve were resected, rather than all three. Neurectomy should ideally resect the entire length of the nerve as far proximally as possible, to leave a smoothly cut end. There is still no consensus on whether only the affected or the entrapped nerve should be removed, or whether three nerves should be removed on the basis that remaining nerve branches may still transfer pain stimuli^[35]. Resection of the three nerves, IIN, IHN and GFN, has been shown to permanently relieve chronic groin pain at the expense of inguinal numbness.

Ilioinguinal neurectomy alone has also been shown to be an effective treatment for relieving chronic groin pain in several studies^[29,32,38]. Starling *et al*^[29] performed IIN neurectomy alone in 17 patients and showed complete pain relief in 15 of them. Kim *et al*^[38] showed similar results, with 19 of their 21 patients showing considerable pain relief following isolated IIN neurectomy. In a retrospective review of 19 patients, Keller *et al*^[41] showed that triple neurectomy was performed in 7, dual neurectomy in 9 and at least one nerve was excised in 18 patients. Of 19 patients only one had recurrent pain a year after neurectomy.

Loos *et al*^[52] followed a tailored neurectomy approach where, depending on intra-operative findings of nerve involvement or mesh pathology, the nerve was excised with or without mesh. According to these authors, this protocol avoids the removal of all three nerves, as proposed by Amid, avoiding the consequent chronic numbness^[56]. In a retrospective review of 68 patients who underwent tailored neurectomy, 12 patients (17.6%) needed further operation because of persistent pain. This study showed a complete pain relief in 52%, partial pain relief in 24% and pain unchanged in 24% at 1.5 years median follow-up.

Vuilleumier *et al*^[24] in a prospective cohort study of neuropathic groin pain patients, defined a radical neurectomy where the inguinal canal was explored through an anterior approach and mesh, IIN and IHN were removed radically by sharp dissection, ends of the nerves being tied with prolene sutures. They showed that median pain score (VAS) decreased significantly post-operatively, with 41 (95%) reporting complete relief and 2 (5%) having partial relief from pain. There had been a median of 6 mo

work incapacity in these patients but all of them returned to work 6 wk post-operatively. Vuilleumier *et al*^[24] suggested that as GFN is a small nerve and neurectomy of GFN can cause damage to spermatic blood vessels, the procedure should not be recommended. Overall, there is no consensus on which nerve should be excised for the treatment of chronic groin pain.

Dealing with neurectomized nerve ends

The transected nerve can be ligated, cauterised or buried within the muscle fibres. Keller *et al*^[41] did not ligate the cut nerve ends until bleeding occurred, because of the risk of neuroma formation at the tied end. Majority of surgeons usually tie the nerve end with absorbable suture and tuck it under the internal oblique muscle.

Mesh excision

Currently there are no long-term results available from large studies on the safety of surgical mesh removal with or without neurectomy.

Pubic periosteal reaction or osteitis

If there is pubic periosteal reaction or osteitis, then possible causative agents such as suture materials, staples or rolled up meshes should be removed. Steroid injection can be useful when used intra-operatively or post-operatively if pain persists^[62].

CONCLUSION

Chronic groin pain is not uncommon. It is particularly common in patients with pre-operative pain due to hernia and in patients who are of younger age. Diagnosing chronic groin pain is difficult and needs a high level of patient co-operation. Pain severity is subjective and will remain difficult to evaluate until better scoring systems are developed. In most studies pain is measured subjectively prior to initiation of medical or surgical treatment. Occasionally, objective assessment tools like VAS are used or there is correlation with pre-operative pain scores before treatment is given. There is currently a lack of consensus on the appropriate transition from medical to surgical management of these patients.

The role of surgery in patients with chronic groin pain is controversial and due to various surgical methodologies adopted by surgeons worldwide, data are highly confusing and difficult to interpret. Moreover, the current treatment regimens for chronic groin pain have limited success and their long-term benefits and quality of life effects are still uncertain. A randomised clinical trial comparing nerve blocks *vs* surgical neurectomy is currently being undertaken^[64] to obtain a definitive answer to this difficult problem.

REFERENCES

- 1 Poobalan AS, Bruce J, King PM, Chambers WA, Krukowski ZH, Smith WC. Chronic pain and quality of life following open inguinal hernia repair. *Br J Surg* 2001; **88**: 1122-1126

- 2 Bay-Nielsen M, Perkins FM, Kehlet H. Pain and functional impairment 1 year after inguinal herniorrhaphy: a nationwide questionnaire study. *Ann Surg* 2001; **233**: 1-7
- 3 Staal E, Nienhuijs SW, Keemers-Gels ME, Rosman C, Strobbe LJ. The impact of pain on daily activities following open mesh inguinal hernia repair. *Hernia* 2008; **12**: 153-157
- 4 Kalliomäki ML, Sandblom G, Gunnarsson U, Gordh T. Persistent pain after groin hernia surgery: a qualitative analysis of pain and its consequences for quality of life. *Acta Anaesthesiol Scand* 2009; **53**: 236-246
- 5 Courtney CA, Duffy K, Serpell MG, O'Dwyer PJ. Outcome of patients with severe chronic pain following repair of groin hernia. *Br J Surg* 2002; **89**: 1310-1314
- 6 Nienhuijs S, Staal E, Strobbe L, Rosman C, Groenewoud H, Bleichrodt R. Chronic pain after mesh repair of inguinal hernia: a systematic review. *Am J Surg* 2007; **194**: 394-400
- 7 Beldi G, Haupt N, Ipaktchi R, Wagner M, Candinas D. Postoperative hypoesthesia and pain: qualitative assessment after open and laparoscopic inguinal hernia repair. *Surg Endosc* 2008; **22**: 129-133
- 8 Hindmarsh AC, Cheong E, Lewis MP, Rhodes M. Attendance at a pain clinic with severe chronic pain after open and laparoscopic inguinal hernia repairs. *Br J Surg* 2003; **90**: 1152-1154
- 9 Cunningham J, Temple WJ, Mitchell P, Nixon JA, Preshaw RM, Hagen NA. Cooperative hernia study. Pain in the postrepair patient. *Ann Surg* 1996; **224**: 598-602
- 10 Wantz GE. Testicular atrophy and chronic residual neuralgia as risks of inguinal hernioplasty. *Surg Clin North Am* 1993; **73**: 571-581
- 11 Heise CP, Starling JR. Mesh inguinodynia: a new clinical syndrome after inguinal herniorrhaphy? *J Am Coll Surg* 1998; **187**: 514-518
- 12 Delikoukos S, Fafoulakis F, Christodoulidis G, Theodoropoulos T, Hatzitheofilou C. Re-operation due to severe late-onset persisting groin pain following anterior inguinal hernia repair with mesh. *Hernia* 2008; **12**: 593-595
- 13 Loos MJ, Roumen RM, Scheltinga MR. Classifying post-herniorrhaphy pain syndromes following elective inguinal hernia repair. *World J Surg* 2007; **31**: 1760-1765; discussion 1766-1767
- 14 O'Dwyer PJ, Alani A, McConnachie A. Groin hernia repair: postherniorrhaphy pain. *World J Surg* 2005; **29**: 1062-1065
- 15 Davis CJ, Arregui ME. Laparoscopic repair for groin hernias. *Surg Clin North Am* 2003; **83**: 1141-1161
- 16 Amid PK. Commentary on: Pokorny H, Klingler A, Schmid T, Fortelny R, Hollinsky C, Kawji R, Steiner E, Pernthaler H, Függer R, Scheyer M (2008) Recurrence and complications after laparoscopic versus open inguinal hernia repair: results of a prospective randomized multicenter trial. *Hernia* 2008; **12**: 441
- 17 Broin EO, Horner C, Mealy K, Kerin MJ, Gillen P, O'Brien M, Tanner WA. Meralgia paraesthetica following laparoscopic inguinal hernia repair. An anatomical analysis. *Surg Endosc* 1995; **9**: 76-78
- 18 Sampath P, Yeo CJ, Campbell JN. Nerve injury associated with laparoscopic inguinal herniorrhaphy. *Surgery* 1995; **118**: 829-833
- 19 Keating JP, Morgan A. Femoral nerve palsy following laparoscopic inguinal herniorrhaphy. *J Laparoendosc Surg* 1993; **3**: 557-559
- 20 Grant AM, Scott NW, O'Dwyer PJ. Five-year follow-up of a randomized trial to assess pain and numbness after laparoscopic or open repair of groin hernia. *Br J Surg* 2004; **91**: 1570-1574
- 21 Heikkinen T, Bringman S, Ohtonen P, Kunelius P, Haukipuro K, Hulkko A. Five-year outcome of laparoscopic and Lichtenstein hernioplasties. *Surg Endosc* 2004; **18**: 518-522
- 22 Kumar S, Wilson RG, Nixon SJ, Macintyre IM. Chronic pain after laparoscopic and open mesh repair of groin hernia. *Br J Surg* 2002; **89**: 1476-1479

- 23 **Myers E**, Browne KM, Kavanagh DO, Hurley M. Laparoscopic (TEP) versus Lichtenstein inguinal hernia repair: a comparison of quality-of-life outcomes. *World J Surg* 2010; **34**: 3059-3064
- 24 **Vuilleumier H**, Hübner M, Demartines N. Neuropathy after herniorrhaphy: indication for surgical treatment and outcome. *World J Surg* 2009; **33**: 841-845
- 25 **Aasvang EK**, Møhl B, Kehlet H. Ejaculatory pain: a specific postherniotomy pain syndrome? *Anesthesiology* 2007; **107**: 298-304
- 26 **Hair A**, Paterson C, Wright D, Baxter JN, O'Dwyer PJ. What effect does the duration of an inguinal hernia have on patient symptoms? *J Am Coll Surg* 2001; **193**: 125-129
- 27 **Ducic I**, West J, Maxted W. Management of chronic postoperative groin pain. *Ann Plast Surg* 2008; **60**: 294-298
- 28 **Kalliomäki ML**, Meyerson J, Gunnarsson U, Gordh T, Sandblom G. Long-term pain after inguinal hernia repair in a population-based cohort; risk factors and interference with daily activities. *Eur J Pain* 2008; **12**: 214-225
- 29 **Starling JR**, Harms BA. Diagnosis and treatment of genitofemoral and ilioinguinal neuralgia. *World J Surg* 1989; **13**: 586-591
- 30 **Harms BA**, DeHaas DR, Starling JR. Diagnosis and management of genitofemoral neuralgia. *Arch Surg* 1984; **119**: 339-341
- 31 **Rab M**, Ebmer A, Dellon AL. Anatomic variability of the ilioinguinal and genitofemoral nerve: implications for the treatment of groin pain. *Plast Reconstr Surg* 2001; **108**: 1618-1623
- 32 **Deysine M**, Deysine GR, Reed WP. Groin pain in the absence of hernia: a new syndrome. *Hernia* 2002; **6**: 64-67
- 33 **Starling JR**, Harms BA, Schroeder ME, Eichman PL. Diagnosis and treatment of genitofemoral and ilioinguinal entrapment neuralgia. *Surgery* 1987; **102**: 581-586
- 34 **Bower S**, Moore BB, Weiss SM. Neuralgia after inguinal hernia repair. *Am Surg* 1996; **62**: 664-667
- 35 **Amid PK**, Hiatt JR. New understanding of the causes and surgical treatment of postherniorrhaphy inguinodynia and orchalgia. *J Am Coll Surg* 2007; **205**: 381-385
- 36 **Amid PK**. Radiologic images of meshoma: a new phenomenon causing chronic pain after prosthetic repair of abdominal wall hernias. *Arch Surg* 2004; **139**: 1297-1298
- 37 **Filler A**. Magnetic resonance neurography and diffusion tensor imaging: origins, history, and clinical impact of the first 50,000 cases with an assessment of efficacy and utility in a prospective 5000-patient study group. *Neurosurgery* 2009; **65**: A29-A43
- 38 **Kim DH**, Murovic JA, Tiel RL, Kline DG. Surgical management of 33 ilioinguinal and iliohypogastric neuralgias at Louisiana State University Health Sciences Center. *Neurosurgery* 2005; **56**: 1013-1020; discussion 1013-1020
- 39 **Lichtenstein IL**, Shulman AG, Amid PK, Montllor MM. Cause and prevention of postherniorrhaphy neuralgia: a proposed protocol for treatment. *Am J Surg* 1988; **155**: 786-790
- 40 **Sen H**, Sizlan A, Yanarateş O, Senol MG, Inangil G, Sücüllü I, Ozkan S, Dağlı G. The effects of gabapentin on acute and chronic pain after inguinal herniorrhaphy. *Eur J Anaesthesiol* 2009; **26**: 772-776
- 41 **Keller JE**, Stefanidis D, Dolce CJ, Iannitti DA, Kercher KW, Heniford BT. Combined open and laparoscopic approach to chronic pain after inguinal hernia repair. *Am Surg* 2008; **74**: 695-700; discussion 700-701
- 42 **Ferzli GS**, Edwards ED, Khoury GE. Chronic pain after inguinal herniorrhaphy. *J Am Coll Surg* 2007; **205**: 333-341
- 43 **Eichenberger U**, Greher M, Kirchmair L, Curatolo M, Moriggl B. Ultrasound-guided blocks of the ilioinguinal and iliohypogastric nerve: accuracy of a selective new technique confirmed by anatomical dissection. *Br J Anaesth* 2006; **97**: 238-243
- 44 **Hartrick CT**. Genitofemoral nerve block: a transpsoas technique. *Reg Anesth* 1994; **19**: 432-433
- 45 **Aasvang EK**, Brandsborg B, Christensen B, Jensen TS, Kehlet H. Neurophysiological characterization of postherniotomy pain. *Pain* 2008; **137**: 173-181
- 46 **Fanelli RD**, DiSiena MR, Lui FY, Gersin KS. Cryoanalgesic ablation for the treatment of chronic postherniorrhaphy neuropathic pain. *Surg Endosc* 2003; **17**: 196-200
- 47 **Rozen D**, Ahn J. Pulsed radiofrequency for the treatment of ilioinguinal neuralgia after inguinal herniorrhaphy. *Mt Sinai J Med* 2006; **73**: 716-718
- 48 **Stulz P**, Pfeiffer KM. Peripheral nerve injuries resulting from common surgical procedures in the lower portion of the abdomen. *Arch Surg* 1982; **117**: 324-327
- 49 **Hameroff SR**, Carlson GL, Brown BR. Ilioinguinal pain syndrome. *Pain* 1981; **10**: 253-257
- 50 **Murovic JA**, Kim DH, Tiel RL, Kline DG. Surgical management of 10 genitofemoral neuralgias at the Louisiana State University Health Sciences Center. *Neurosurgery* 2005; **56**: 298-303; discussion 298-303
- 51 **Nahabedian MY**, Dellon AL. Outcome of the operative management of nerve injuries in the ilioinguinal region. *J Am Coll Surg* 1997; **184**: 265-268
- 52 **Loos MJ**, Scheltinga MR, Roumen RM. Tailored neurectomy for treatment of postherniorrhaphy inguinal neuralgia. *Surgery* 2010; **147**: 275-281
- 53 **Lee CH**, Dellon AL. Surgical management of groin pain of neural origin. *J Am Coll Surg* 2000; **191**: 137-142
- 54 **Amid PK**. Causes, prevention, and surgical treatment of postherniorrhaphy neuropathic inguinodynia: triple neurectomy with proximal end implantation. *Hernia* 2004; **8**: 343-349
- 55 **Krähenbühl L**, Striffeler H, Baer HU, Büchler MW. Retroperitoneal endoscopic neurectomy for nerve entrapment after hernia repair. *Br J Surg* 1997; **84**: 216-219
- 56 **Ducic I**, Dellon AL. Testicular pain after inguinal hernia repair: an approach to resection of the genital branch of genitofemoral nerve. *J Am Coll Surg* 2004; **198**: 181-184
- 57 **Rosen MJ**, Novitsky YW, Cobb WS, Kercher KW, Heniford BT. Combined open and laparoscopic approach to chronic pain following open inguinal hernia repair. *Hernia* 2006; **10**: 20-24
- 58 **Zacest AC**, Magill ST, Anderson VC, Burchiel KJ. Long-term outcome following ilioinguinal neurectomy for chronic pain. *J Neurosurg* 2010; **112**: 784-789
- 59 **Wong J**, Anvari M. Treatment of inguinodynia after laparoscopic herniorrhaphy: a combined laparoscopic and fluoroscopic approach to the removal of helical tacks. *Surg Laparosc Endosc Percutan Tech* 2001; **11**: 148-151
- 60 **Rozen D**, Parvez U. Pulsed radiofrequency of lumbar nerve roots for treatment of chronic inguinal herniorrhaphy pain. *Pain Physician* 2006; **9**: 153-156
- 61 **Kehlet H**, Jensen TS, Woolf CJ. Persistent postsurgical pain: risk factors and prevention. *Lancet* 2006; **367**: 1618-1625
- 62 **Amid PK**. A 1-stage surgical treatment for postherniorrhaphy neuropathic pain: triple neurectomy and proximal end implantation without mobilization of the cord. *Arch Surg* 2002; **137**: 100-104
- 63 **Aasvang E**, Kehlet H. Surgical management of chronic pain after inguinal hernia repair. *Br J Surg* 2005; **92**: 795-801
- 64 **Loos MJ**, Verhagen T, Scheltinga MR, Roumen RM. A randomised controlled trial of injection therapy versus neurectomy for post-herniorrhaphy inguinal neuralgia: rationale and study design. *Hernia* 2010; **14**: 593-597

S- Editor Wang JL L- Editor Hughes D E- Editor Zheng XM

Successful treatment of esophageal metastasis from hepatocellular carcinoma using the da Vinci robotic surgical system

Wiroon Boonnuch, Thawatchai Akaraviputh, Carnivale Nino, Anusak Yiengpruksawan, Arthur Andrew Christiano

Wiroon Boonnuch, Thawatchai Akaraviputh, Minimally Invasive Surgery Center, Division of General Surgery, Department of Surgery, Faculty of Medicine Siriraj Hospital, Mahidol University, Bangkok, 10700, Thailand

Carnivale Nino, Anusak Yiengpruksawan, Department of Surgery, the Valley Hospital, Valley Health System, NJ 07652, United States

Arthur Andrew Christiano, Department of Pathology, the Valley Hospital, Valley Health System, NJ 07652, United States

Author contributions: Boonnuch W originated the idea and drafted up the manuscript; Nino C collected the data; Yiengpruksawan A and Christiano AA wrote a portion of the manuscript; Akaraviputh T critically reviewed and edited the manuscript.

Correspondence to: Thawatchai Akaraviputh, MD, Minimally Invasive Surgery Center, Division of General Surgery, Department of Surgery, Faculty of Medicine Siriraj Hospital, Mahidol University, Bangkok, 10700, Thailand. sitak@mahidol.ac.th

Telephone: +66-2-4198006 Fax: +66-2-4121370

Received: July 8, 2010 Revised: April 2, 2011

Accepted: April 9, 2011

Published online: June 27, 2011

© 2011 Baishideng. All rights reserved.

Key words: Hepatocellular carcinoma; Esophageal metastasis; da Vinci robotic surgery

Peer reviewer: Mehmet Fatih Can, Assistant Professor, Gulhane School of Medicine, Department of Surgery, Etlik 06018, Ankara, Turkey

Boonnuch W, Akaraviputh T, Nino C, Yiengpruksawan A, Christiano AA. Successful treatment of esophageal metastasis from hepatocellular carcinoma using the da Vinci robotic surgical system. *World J Gastrointest Surg* 2011; 3(6): 82-85 Available from: URL: <http://www.wjgnet.com/1948-9366/full/v3/i6/82.htm> DOI: <http://dx.doi.org/10.4240/wjgs.v3.i6.82>

Abstract

A 59-year-old man with metastatic an esophageal tumor from hepatocellular carcinoma (HCC) presented with progressive dysphagia. He had undergone liver transplantation for HCC three and a half years previously. At presentation, his radiological and endoscopic examinations suggested a submucosal tumor in the lower esophagus, causing a luminal stricture. We performed complete resection of the esophageal metastases and esophagogastronomy reconstruction using the da Vinci robotic system. Recovery was uneventful and he was been doing well 2 mo after surgery. α -fetoprotein level decreased from 510 ng/mL to 30 ng/mL postoperatively. During the follow-up period, he developed a recurrent esophageal stricture at the anastomosis site and this was successfully treated by endoscopic esophageal dilatation.

INTRODUCTION

The incidence of metastatic esophageal tumor (MET) is low, ranging from 0.3%-6.1% in autopsy series^[1-3], with hepatocellular carcinoma (HCC) was accounting for less than 0.4% of primary lesions^[4]. The majority of METs are associated with diffuse metastases or with mediastinal carcinomatosis, and thus are not candidates for aggressive local treatments. Recently, we performed a robot-assisted local resection of an isolated partially obstructing MET using the da Vinci surgical system in a patient who had undergone liver transplantation for cirrhotic liver associated with HCC. The case is reported herein.

CASE REPORT

The patient was a 59-year-old man who underwent liver transplantation for cirrhotic liver associated with a solitary HCC. Three and a half years later, he developed progressive dysphagia. Esophagography showed severe narrowing of the distal esophagus. Computed tomography (CT)

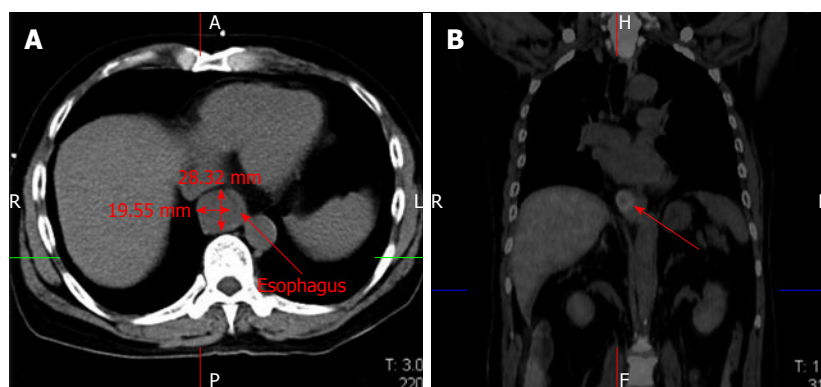


Figure 1 Computed tomography scan demonstrated marked thickening of the esophageal wall (A). Positron emission tomography scan showed marked uptake by the esophageal lesion without any recurrence of hepatocellular carcinoma at other sites (B).

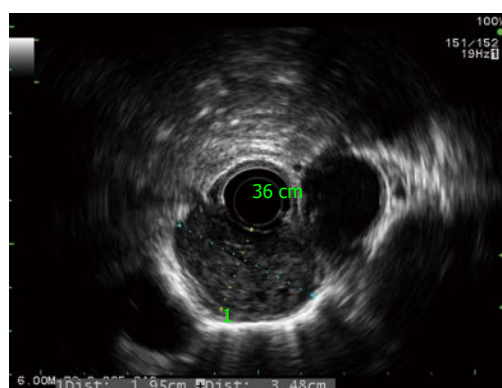


Figure 2 Radial echoendoscopy showed a heterogeneous submucosal tumor about 2 cm × 3.5 cm in diameter without periesophageal lymph node.

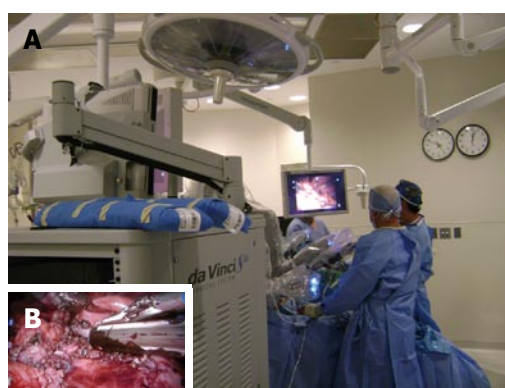

Figure 3 Intraoperative finding of the da Vinci S Robotic surgical system (A), the dense adhesion was resected using endoGIA staple (B).

scan demonstrated marked thickening of the esophageal wall around the stricture (Figure 1A). Endoscopic study revealed an extrinsic compression at 35 cm from the incisors, causing severe stenosis but without any mucosal irregularity. Positron emission tomography (PET) scan showed marked uptake by the esophageal tumor without any recurrence of HCC at other sites (Figure 1B). Endoscopic ultrasonography revealed a large submucosal tumor of 1.9 cm × 3.5 cm in diameter in the lower esophagus (Figure 2). Laboratory analysis revealed an elevated α -fetoprotein level of 510 ng/mL. The patient was diagnosed with MET from recurrent HCC. Since his general condition was excellent, we decided to perform surgical resection.

Surgical technique

After induction of general anesthesia with a single-lumen endotracheal tube, the patient was placed in the lithotomy position. An arterial line, a central venous catheter, and a Foley catheter were placed. Pneumatic compression stockings were placed on both legs. Preoperative antibiotics were administered. The abdomen was prepared and draped in the usual sterile fashion. After placing the trocar, the abdomen was insufflated to 14 mmHg. The abdominal cavity was inspected for any evidence of carcinomatosis. Lysis adhesion was performed using standard

laparoscopy. Part of the dense adhesion of the omentum was transected using endoGIA staples for prevention of intra-operative bleeding. Laparoscopic ultrasonography of the liver demonstrated no recurrence of HCC.

The da Vinci surgical system was then brought into position, cephalad to the patient, and the arms of the system were attached to the trocars. The robotic camera and the two operating robotic instruments were secured in their ports. Transabdominal dissection of the distal esophagus and stomach was started and continued in a cephalad direction along the circumferential borders of the esophagus. The articulated hook cautery was used for this maneuver, allowing precise circumferential dissection of the esophagus, and division of each individual periesophageal attachment with minimal blood loss and trauma. The tumor of the lower esophagus was mobilized so esophageal metastectomy and esophagogastrotomy were performed using the robotic system (Figure 3). The esophagogastrotomy anastomosis was created by the robotic hand-sew technique with vicryl #3/0 interrupted stitches.

Pathological study confirmed the resected specimen was a HCC, suggesting metastatic lesions from the liver (Figure 4). The patient was discharged 14 d later with no apparent symptoms after the surgery. The α -fetoprotein level decreased to 30 ng/mL. Two months later, he devel-

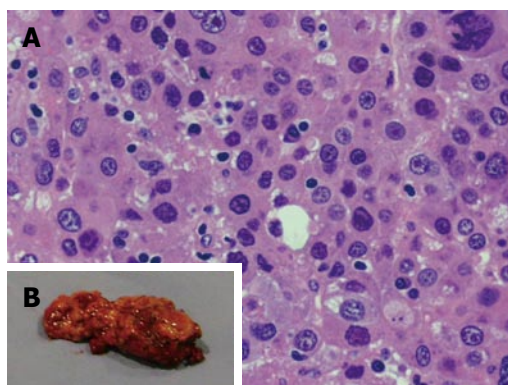


Figure 4 Pathological result of the resected specimen confirmed metastasis from hepatocellular carcinoma.

oped anastomosis stricture causing dysphagia which was successfully treated by endoscopic esophageal dilatation.

DISCUSSION

Since Gross firstly reported a case of metastatic esophageal cancer from the prostate^[5], many reports have shown the esophagus to be a frequent metastatic site from a variety of malignancies including breast^[6], lung^[7], ovary^[8], liver^[9], rectum^[10] and others^[11-14]. In autopsy studies, the overall incidence of esophageal metastases is 0.3%-6%^[1-3]. The most common primary tumor-bearing organs are breast and lung^[6,7]. Esophageal metastasis from HCC has only been described in one previous report^[9]. Our case was diagnosed as an esophageal metastasis from HCC, which is extremely rare especially post liver transplantation.

The possible routes of esophageal involvement are direct extension from adjacent organs, mediastinal nodes or hematogenous spreading from a distant primary^[15]. In this case it is most likely that the HCC developed secondary metastasis in the esophageal wall through hematogenous spread.

METs are usually located in the submucosal layer and cause progressive dysphagia^[3,16]. Esophagography and endoscopy show severe luminal stricture with normal overlying mucosa, often making histological diagnosis difficult^[16]. CT scan demonstrates concentric thickening of the esophageal wall over the stricture without an apparent extrinsic mass^[16,17]. In our patient, the diagnosis was confirmed by PET scan which showed marked uptake by the tumor (SUV - MAX = 4.5) and by an increase in α fetoprotein level to 510 ng/mL. Standard treatment for metastatic esophageal cancer has not yet been established. However, as the majority of such patients already have advanced malignant disease or metastases at multiple sites, systemic chemotherapy and/or local radiation are usually considered as the first choice of treatment. Unfortunately, when the symptoms appear, the majority of the patients already have distant metastases^[9]. Therefore, treatment has been directed toward palliation, for which a variety of options exist, including endoscopic di-

lation and stent placement or esophagectomy^[7]. As metastatic HCC shows poor response to chemo-radiation, we discussed with the patient that surgical removal is the optimal treatment. However, recent reports have shown that esophagectomy can provide excellent palliation and long-term survival in certain cases without metastases to other sites^[3,6-8,11,18-21]. The prognosis varied from 7 mo to 14 years after esophagectomy, depending on the biological characteristics of the primary malignancy.

The use of the da Vinci Robotic Surgical System (Intuitive Surgical, Sunnyvale, California) provides the advantages of three-dimensional visualization through a stereo endoscope, tremor reduction, motion scaling, and wristed instrumentation with additional degrees of freedom compared to standard laparoscopic instruments^[22,23]. It may be that advanced robotics will be reserved for only the most complex operations, such as esophagectomy and reconstruction. The system allows the surgeon to work in the narrow space of the mediastinum, overcoming spatial limitations experienced while using thoracoscopic or laparoscopic techniques. The robotic system is of tremendous help in accessing remote areas through a small esophageal hiatus. The extent of lymphadenectomy and the total operative time were not issues in this procedure, but might be improved on with further experience^[24]. In authors' opinion, robotic surgery can ameliorate the technical difficulties encountered laparoscopically and may allow surgeons to perform this and other delicate procedures without increased operative time, because of the maneuverability and increased length of the instruments as well as the excellent three-dimensional operative view. From our experience with this new robotic system, aggressive surgery might be considered as a therapeutic procedure for metastatic HCC of the esophagus, as long as the primary tumor is satisfactorily controlled.

In conclusion, we report a rare case of pre-mortem-diagnosed esophageal metastasis from HCC in a patient who had previously undergone liver transplantation. We performed what is possibly the first reported successful esophageal metastatectomy and reconstruction esophagogastrectomy using the da Vinci robotic system.

REFERENCES

- 1 **Abrams HL**, Spiro R, Goldstein N. Metastases in carcinoma; analysis of 1000 autopsied cases. *Cancer* 1950; **3**: 74-85
- 2 **Telerman A**, Gerard B, Van den Heule B, Bleiberg H. Gastrointestinal metastases from extra-abdominal tumors. *Endoscopy* 1985; **17**: 99-101
- 3 **Mizobuchi S**, Tachimori Y, Kato H, Watanabe H, Nakanishi Y, Ochiai A. Metastatic esophageal tumors from distant primary lesions: report of three esophagectomies and study of 1835 autopsy cases. *Jpn J Clin Oncol* 1997; **27**: 410-414
- 4 Primary liver cancer in Japan. Clinicopathologic features and results of surgical treatment. Liver Cancer Study Group of Japan. *Ann Surg* 1990; **211**: 277-287
- 5 **Gross P**, Freedman LJ. Obstructive secondary carcinoma of the esophagus as a cause of dysphagia. *Arch Pathol* 1942; **38**: 361-364
- 6 **Fujii K**, Nakanishi Y, Ochiai A, Tsuda H, Yamaguchi H, Tachimori Y, Kato H, Watanabe H, Shimoda T. Solitary

- esophageal metastasis of breast cancer with 15 years' latency: a case report and review of the literature. *Pathol Int* 1997; **47**: 614-617
- 7 **Oka T**, Ayabe H, Kawahara K, Tagawa Y, Hara S, Tsuji H, Kusano H, Nakano M, Tomita M. Esophagectomy for metastatic carcinoma of the esophagus from lung cancer. *Cancer* 1993; **71**: 2958-2961
 - 8 **Asamura H**, Goya T, Hirata K, Suemasu K, Itabashi M, Matsuno Y, Hirota T. Esophageal and pulmonary metastases from ovarian carcinoma: a case report of long-term survival following metastatic resections. *Jpn J Clin Oncol* 1991; **21**: 211-217
 - 9 **Tsubouchi E**, Hirasaki S, Kataoka J, Hidaka S, Kajiwarra T, Yamauchi Y, Masumoto T, Hyodo I. Unusual metastasis of hepatocellular carcinoma to the esophagus. *Intern Med* 2005; **44**: 444-447
 - 10 **Lohsiriwat V**, Boonnuch W, Suttinont P. Esophageal metastasis from rectal carcinoma. *J Clin Gastroenterol* 2005; **39**: 744
 - 11 **Eng J**, Pradhan GN, Sabanathan S, Mearns AJ. Malignant melanoma metastatic to the esophagus. *Ann Thorac Surg* 1989; **48**: 287-288
 - 12 **Jung JL**, Abouelfadel Z, Prevot-Maupoix M, Villeval C. [Esophageal metastasis of cancer of the bladder]. *Ann Urol (Paris)* 1997; **31**: 205-206
 - 13 **Trentino P**, Rapacchietta S, Silvestri F, Marzullo A, Fantini A. Esophageal metastasis from clear cell carcinoma of the kidney. *Am J Gastroenterol* 1997; **92**: 1381-1382
 - 14 **Káposztás Z**, Cseke L, Horváth OP. [Resectable esophageal metastasis of stomach cancer]. *Magy Seb* 2003; **56**: 207-208
 - 15 **Agha FP**. Secondary neoplasms of the esophagus. *Gastrointest Radiol* 1987; **12**: 187-193
 - 16 **Simchuk EJ**, Low DE. Direct esophageal metastasis from a distant primary tumor is a submucosal process: a review of six cases. *Dis Esophagus* 2001; **14**: 247-250
 - 17 **Itai Y**, Kogure T, Nomura M. Secondary esophageal carcinoma: report of two cases showing intraluminal tumor. *Radiat Med* 1983; **1**: 53-54
 - 18 **Shimada Y**, Imamura M, Tobe T. Successful esophagectomy for metastatic carcinoma of the esophagus from breast cancer—a case report. *Jpn J Surg* 1989; **19**: 82-85
 - 19 **de los Monteros-Sanchez AE**, Medina-Franco H, Arista-Nasr J, Cortes-Gonzalez R. Resection of an esophageal metastasis from a renal cell carcinoma. *Hepatogastroenterology* 2004; **51**: 163-164
 - 20 **Papadimitriou J**, Smyrniotis B, Condís J, Antoniou S. Metastatic mixed mullerian tumour of the esophagus. *Int Surg* 1989; **74**: 195-197
 - 21 **Inoshita T**, Youngberg GA, Thur De Koos P. Esophageal metastasis from a peripheral lung carcinoma masquerading as a primary esophageal tumor. *J Surg Oncol* 1983; **24**: 49-52
 - 22 **Ballantyne GH**, Moll F. The da Vinci telerobotic surgical system: the virtual operative field and telepresence surgery. *Surg Clin North Am* 2003; **83**: 1293-1304, vii
 - 23 **Lanfranco AR**, Castellanos AE, Desai JP, Meyers WC. Robotic surgery: a current perspective. *Ann Surg* 2004; **239**: 14-21
 - 24 **Gutt CN**, Bintintan VV, Köninger J, Müller-Stich BP, Reiter M, Büchler MW. Robotic-assisted transhiatal esophagectomy. *Langenbecks Arch Surg* 2006; **391**: 428-434

S- Editor Wang JL L- Editor Hughes D E- Editor Zheng XM

Pneumatosis intestinalis and pneumoperitoneum on computed tomography: Beware of non-therapeutic laparotomy

Kuan-Chun Hsueh, Shung-Sheng Tsou, Kok-Tong Tan

Kuan-Chun Hsueh, Shung-Sheng Tsou, Kok-Tong Tan, Department of Surgery, Tungs' Taichung MetroHarbor Hospital, Taichung City 435, Taiwan, China

Author contributions: All authors wrote this case report.

Correspondence to: Kok-Tong Tan, MD, Department of Surgery, Tungs' Taichung MetroHarbor Hospital, No. 699, Chung-Chi Rd, Sec 1, Wuchi District, Taichung City 435, Taiwan, China. ericktan@gmail.com

Telephone: +886-4-26581919-4300 Fax: +886-4-26582193

Received: July 13, 2010

Revised: March 14, 2011

Accepted: March 21, 2011

Published online: June 27, 2011

Peer reviewers: Ned Abraham, MBBS, FRACS, FRCS, PhD, Coffs Colorectal and Capsule Endoscopy Centre, University of New South Wales, 187 Rose Avenue (POB 2244), Coffs Harbour, NSW 2450, Australia; Hubert Scheidbach, MD, Professor, Department of Surgery, Otto von Guericke University, Junoweg 31, D-39118 Magdeburg, Magdeburg, Germany

Hsueh KC, Tsou SS, Tan KT. Pneumatosis intestinalis and pneumoperitoneum on computed tomography: Beware of non-therapeutic laparotomy. *World J Gastrointest Surg* 2011; 3(6): 86-88 Available from: URL: <http://www.wjgnet.com/1948-9366/full/v3/i6/86.htm> DOI: <http://dx.doi.org/10.4240/wjgs.v3.i6.86>

Abstract

Pneumatosis intestinalis (PI) is defined as gas within the gastrointestinal wall and is associated with a variety of disorders. As a concurrent occurrence with pneumoperitoneum, it can easily be mistaken for bowel ischemia with perforated peritonitis. In fact, air dissection or rupture from subserosal cysts may be the cause of intraperitoneal and intraluminal free air, with clinical symptoms such as abdominal pain and fullness occurring as a result. We hereby report a case of an 82-year-old male with a history of chronic obstructive pulmonary disease who was diagnosed with bowel ischemia and received emergency laparotomy because of the appearance of PI and pneumoperitoneum on abdominal computed tomography scan. However, no perforated hollow organ or necrotic bowel segment was found, only diffusely distributed massive intraperitoneal air and PI of gastrointestinal tract. The laparotomy seemed non-therapeutic for this patient. This is significant warning for clinicians to differentiate the associated conditions of PI, and to evaluate whether or not emergency surgery is necessary.

© 2011 Baishideng. All rights reserved.

Key words: Pneumatosis intestinalis; Pneumoperitoneum; Computed tomography

INTRODUCTION

Pneumatosis intestinalis (PI) is indicated, radiologically or pathologically, as gas within the gastrointestinal wall. Air dissection or rupture from subserosal cysts may be the cause of intraperitoneal and intraluminal free air, which causes clinical symptoms such as abdominal pain and fullness^[1,2]. In the past, this was regarded as a sign of intestinal ischemia, which was indicated for surgical intervention, especially when it coexisted with the presence of pneumoperitoneum. However, new evidence indicates that a conservative approach may be sufficient in certain cases presenting with PI^[3,4].

We hereby report a case of an 82-year-old male with a history of chronic obstructive pulmonary disease (COPD) who presented with abdominal pain. The computed tomography (CT) scan showed intramural gas of the gastrointestinal (GI) tract and massive pneumoperitoneum, which mimicked intestinal ischemia and perforation. The diagnosis of PI with pneumoperitoneum was confirmed *via* exploratory laparotomy and subsequent pathological analysis, though the etiology remained uncertain. An operation was probably unnecessary for this patient as there are other ways to determine the possible need for laparotomy, such as repeated laboratory and radiological tests. Conservative treatment is probably more suitable for the relief of PI.

CASE REPORT

An 82-year-old man with a past medical history of COPD visited our emergency department because of generalized abdominal pain with fullness and intermittent vomiting for three days. Physical examinations revealed tenderness over the whole abdomen and his hemodynamic status was relatively stable. C-reactive protein was 1.0 mg/dL, marginally elevated from the normal upper limit of 0.8 mg/dL, but other laboratory data were all within normal limits. The abdominal CT scan revealed generalized bowel distention, intramural air within stomach, small and large intestines, and massive intraperitoneal free air (Figure 1). Laparotomy was performed due to the suspected diagnosis of bowel ischemia and hollow organ perforation. Pneumoperitoneum, bowel wall congestion and edematous cystic changes were identified in a CT scan, whereas no bowel perforation was detected. The most prominent pneumatized jejunal segment around 50 cm in length was resected with primary anastomosis because of the suspicion of bowel ischemia and necrosis. In addition, loop ileostomy was conducted for decompression of the dilated large bowel. Pathologically, the sections of intestinal wall showed diffuse gas-filled cysts of variable size (Figure 2A and B), leading to the diagnosis of PI. Autoimmune or rheumatological diseases were excluded by unremarkable results from laboratory analysis of markers including rheumatoid factor, antinuclear antibody and subtypes (antibodies to dsDNA, Sm, Ro, La), anti-cardiolipin antibody, and serum immunoglobulins, as well as normal results from physical examinations. The possible cause of PI may be associated with underlying COPD. In the following days, the patient received chest physical therapy and medications including bronchodilators and mucolytics for exacerbated COPD and superimposed pneumonia. Repeated abdominal CT scan 2 mo later confirmed the resolution of PI. The patient was discharged uneventfully with no further complaints.

DISCUSSION

Conventional PI has been classified as primary (idiopathic) and secondary^[5]. Primary PI is referred to as the cystic collection of air in the colonic wall with an unknown cause. Secondary PI has been associated with numerous clinical conditions. The most common sources of PI possibly are intraluminal GI gas, bacterial production of gas, and pulmonary gas^[1,6]. The increase in the intraluminal pressure and extent of mucosal injury, as seen in intestinal obstruction, endoscopic exam, trauma, mucosal injury incited by autoimmune diseases, acquired immunodeficiency, immunosuppressive therapy, and cytotoxic therapy^[1,2], may lead to intraluminal gas dissection into the injured GI tract intramurally. The invasion of gas-producing bacteria into the injured GI mucosa may be responsible for the bacterial theory of PI. Pulmonary gas formation may arise from alveolar rupture, which results in the dissection of air along vascular channels in the mediastinum, tracking caudally to the retroperitoneum and

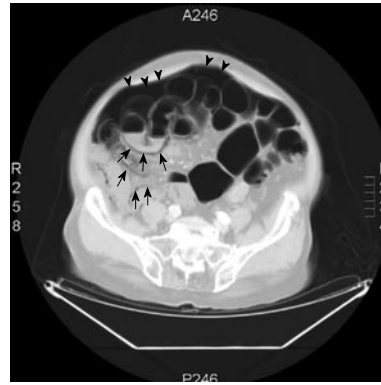


Figure 1 Use of lung window setting in abdominal computed tomography scan revealed massive intraperitoneal free air (arrowheads) and diffuse air collected within the bowel wall (arrows).

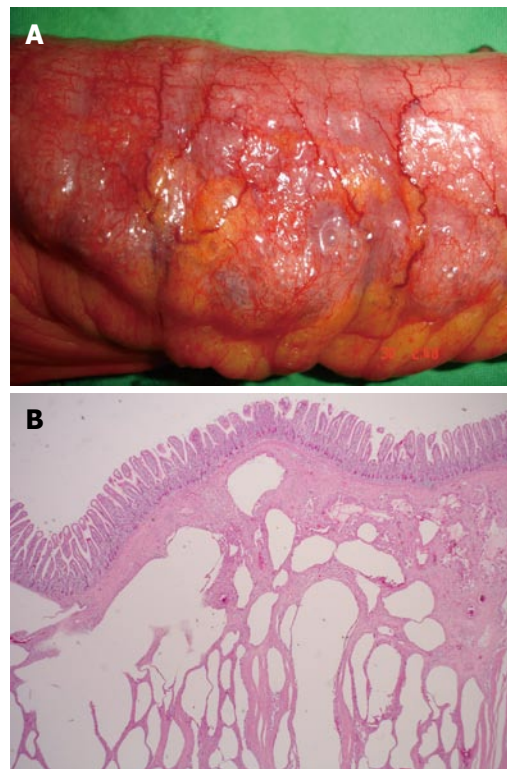


Figure 2 Intestinal wall was grossly thickened, congested, with bubbles on the surface (A) and microscopically the section of small intestine showed diffuse variable sized gas-filled cysts in the submucosa and serosa (B).

then to the vascular supply of the viscera^[1,6]. A review from Boerner and colleagues revealed that 20% out of the 123 patients have had COPD^[7].

The overall incidence of PI may be as low as 0.03%, according to an autopsy series^[8]. In recent times, due to the increased use of the CT scan, the reported incidence of PI has increased to 0.3%^[9]. Of those patients diagnosed with PI, 30%-40% have bowel ischemia/necrosis, and another 30% have bowel obstruction^[3,9]. In another study, of 97 patients diagnosed with PI by CT scan, approximately 50% could have been successfully managed non-operatively, indicating that CT scan is non-specific

and should not be used as the sole indicator for laparotomy^[4]. Conventionally, exploratory laparotomies were performed for patients with PI and pneumoperitoneum because the CT scan indicated possible bowel necrosis and perforation, although the appearance of pneumoperitoneum on CT scan may be attributed to the rupture of PI-associated subserosal cysts^[10-12]. However, there are no large-scale reports of the incidence of pneumoperitoneum in patients with PI.

For patients diagnosed radiologically with PI and a complete history should be taken and physical examinations carried out, especially where there are pulmonary diseases such as COPD^[1,2], systemic diseases as scleroderma, AIDS and inflammatory bowel diseases^[1,2] or medications such as chemotherapeutics, steroids or immunosuppressive agents^[1,2,13]. Appropriate medical treatment should be adopted according to pre-existing illness. In fact, around 50% of patients with PI can be successfully managed non-operatively^[4].

Nonetheless, following the identification of PI urgent surgery may be essential, especially in conditions such as strangulated bowel obstruction or ischemia. Abdominal rebound tenderness, sepsis and failure to respond to conservative treatment are clear clinical indications for surgical treatment. The presence of metabolic acidosis, higher APACHE II score and serum lactic acid level > 2.0 mmol/L at the time of diagnosis are indicators of poor prognosis^[2,4,9]. The appearance of PI on abdominal CT scan gives a definitive diagnosis of bowel ischemia in only 60% of cases^[14]. Signs of the appearances of intramural gas, thromboembolism in the mesenteric vessels, portal venous gas, absence of bowel wall enhancement, or ischemic signs in other organs are considered more specific indications of bowel ischemia^[15]. A broad spectrum of conditions appear as PI on CT scan, and it is reported that patients with PI and other CT findings of ischemia are more likely to have gangrenous bowel^[14], especially where there is portal venous gas, or portal mesenteric gas, which is associated with 81% of patients with transmural bowel infarction^[16].

Meticulous integration of the laboratory data, the appearance on abdominal CT scan and clinical presentations permit clinicians to distinguish benign from life-threatening PI and to decide whether or not urgent surgical intervention is necessary. As described in this case report, it is sometimes difficult to deal with ambiguous findings. For example, the coexistence of PI and intraperitoneal free air on CT scan can be easily mistaken for bowel ischemia and perforation peritonitis^[17]. Since normal laboratory results are not typically consistent with the symptoms of bowel ischemia, surgical intervention would be non-therapeutic, in such cases. To manage patients

with uncertain diagnoses, diagnostic peritoneal lavage or laparoscopy could be performed as an adjunct to confirm bowel necrosis or hollow visceral perforation.

REFERENCES

- 1 St Peter SD, Abbas MA, Kelly KA. The spectrum of pneumatosis intestinalis. *Arch Surg* 2003; **138**: 68-75
- 2 Greenstein AJ, Nguyen SQ, Berlin A, Corona J, Lee J, Wong E, Factor SH, Divino CM. Pneumatosis intestinalis in adults: management, surgical indications, and risk factors for mortality. *J Gastrointest Surg* 2007; **11**: 1268-1274
- 3 Knechtle SJ, Davidoff AM, Rice RP. Pneumatosis intestinalis. Surgical management and clinical outcome. *Ann Surg* 1990; **212**: 160-165
- 4 Morris MS, Gee AC, Cho SD, Limbaugh K, Underwood S, Ham B, Schreiber MA. Management and outcome of pneumatosis intestinalis. *Am J Surg* 2008; **195**: 679-682; discussion 682-683
- 5 Koss LG. Abdominal gas cysts (pneumatosis cystoides intestinum hominis); an analysis with a report of a case and a critical review of the literature. *AMA Arch Pathol* 1952; **53**: 523-549
- 6 Pear BL. Pneumatosis intestinalis: a review. *Radiology* 1998; **207**: 13-19
- 7 Boerner RM, Fried DB, Warshauer DM, Isaacs K. Pneumatosis intestinalis. Two case reports and a retrospective review of the literature from 1985 to 1995. *Dig Dis Sci* 1996; **41**: 2272-2285
- 8 Heng Y, Schuffler MD, Haggitt RC, Rohrmann CA. Pneumatosis intestinalis: a review. *Am J Gastroenterol* 1995; **90**: 1747-1758
- 9 Hawn MT, Canon CL, Lockhart ME, Gonzalez QH, Shore G, Bondora A, Vickers SM. Serum lactic acid determines the outcomes of CT diagnosis of pneumatosis of the gastrointestinal tract. *Am Surg* 2004; **70**: 19-23; discussion 23-24
- 10 Mularski RA, Ciccolo ML, Rappaport WD. Nonsurgical causes of pneumoperitoneum. *West J Med* 1999; **170**: 41-46
- 11 Mularski RA, Sippel JM, Osborne ML. Pneumoperitoneum: a review of nonsurgical causes. *Crit Care Med* 2000; **28**: 2638-2644
- 12 Maltz C. Benign pneumoperitoneum and pneumatosis intestinalis. *Am J Emerg Med* 2001; **19**: 242-243
- 13 Ho LM, Paulson EK, Thompson WM. Pneumatosis intestinalis in the adult: benign to life-threatening causes. *AJR Am J Roentgenol* 2007; **188**: 1604-1613
- 14 Kernagis LY, Levine MS, Jacobs JE. Pneumatosis intestinalis in patients with ischemia: correlation of CT findings with viability of the bowel. *AJR Am J Roentgenol* 2003; **180**: 733-736
- 15 Saba L, Mallarini G. Computed tomographic imaging findings of bowel ischemia. *J Comput Assist Tomogr* 2008; **32**: 329-340
- 16 Wiesner W, Mortelé KJ, Glickman JN, Ji H, Ros PR. Pneumatosis intestinalis and portomesenteric venous gas in intestinal ischemia: correlation of CT findings with severity of ischemia and clinical outcome. *AJR Am J Roentgenol* 2001; **177**: 1319-1323
- 17 Sakurai Y, Hikichi M, Isogaki J, Furuta S, Sunagawa R, Inaba K, Komori Y, Uyama I. Pneumatosis cystoides intestinalis associated with massive free air mimicking perforated diffuse peritonitis. *World J Gastroenterol* 2008; **14**: 6753-6756

S- Editor Wang JL L- Editor Hughes D E- Editor Zheng XM



ACKNOWLEDGMENTS

Acknowledgments to reviewers of *World Journal of Gastrointestinal Surgery*

Many reviewers have contributed their expertise and time to the peer review, a critical process to ensure the quality of *World Journal of Gastrointestinal Surgery*. The editors and authors of the articles submitted to the journal are grateful to the following reviewers for evaluating the articles (including those published in this issue and those rejected for this issue) during the last editing time period.

Ned Abraham, MBBS, FRACS, FRCS, PhD, Coffs Colorectal and Capsule Endoscopy Centre, University of New South Wales, 187 Rose Avenue, PO Box 2244, Coffs Harbour, NSW 2450, Australia

Chapel Alain, PhD, Department of Men Radioprotection, Laboratory of Radio Pathology and Innovative Therapy, Institute of nuclear Safety and radioprotection, PO Box 17, Far 92262, France

Vollmar Brigitte, MD, Professor, Institute of Experimental Surgery, University of Rostock, Schillingallee 69a, Rostock 18057, Germany

Chien-Hung Chen, MD, PhD, Department of Internal Medicine, National Taiwan University Hospital and National Taiwan University College of Medicine, No. 7, Chung-Shan South Road, Taipei 100, Taiwan, China

Stavros J Gourgiotis, MD, PhD, Department of Second Surgical, 401 General Army Hospital of Athens, 41 Zakinthinou Street, Papagou, Athens 15669, Greece

Helena M Isoniemi, MD, PhD, Professor, Transplantation and Liver Surgery Clinic, Helsinki University Hospital, box 263, Helsinki 00029-HUCH, Finland

Chen-Guo Ker, MD, PhD, Professor, Department of Surgery, Kaohsiung Medical University, No. 100, Tz-You 1st Rd, Kaohsiung, Taiwan, China

Adnan Narci, Professor, Department of Pediatric Surgery, Afyon Kocatepe University School of Medicine, Izmir Street, 7km, Afyonkarahisar 03200, Turkey

Marcelo AF Ribeiro, MD, PhD, TCBC, TCBCD, FACS, Department of Surgery, Santo Amaro University, Alameda Gregorio Bogossian Sobrinho, 80/155, Santana de Parnaíba, SP 06543-385, Brazil

Sukamal Saha, MD, FACS, FRCS, FICS, Department of Orthopedics, 3500 Calkins Rd, Suite A, Flint, MI 48532, United States

Manuela Santos, PhD, Associate Professor, Department of Medicine, University of Montreal, Montreal Cancer Institute, CRCHUM/Notre-Dame Hospital, Pavillon De Seve Y5625, 1560 Sherbrooke Est, Montreal, QC, H2L 4M1, Canada

Christian Max Schmidt, MD, PhD, MBA, FACS, Departments of Surgery and Biochemistry/Molecular Biology, Indiana University School of Medicine, 980 W Walnut St C522, Indianapolis, IN 46202, United States

Gregory Peter Sergeant, MD, Department of General Surgery, University Hospital Leuven, Herestraat 49, Leuven B-3000, Belgium

Douglas S Tyler, MD, Department of Surgery, Duke University Medical Center, Box 3118, Durham, NC 27710, United States

Marcus VM Valadao, MD, Instituto Nacional de Cancer, Hospital do Cancer Unidade I, Hc2., Rua do Equador 831, Santo Cristo, Rio de Janeiro 20220-410, RJ, Brazil

Caroline S Verbeke, MD, PhD, Department of Histopathology, Bexley Wing Level 5 St James's University, Hospital Beckett Street, Leeds LS9 7TF, United Kingdom



Events Calendar 2011

January 15-19, 2011

EAES Advanced Laparoscopic GI
Surgery Course, Cairo, Egypt

January 20-22, 2011

Gastrointestinal Cancers Symposium
(ASCO GI), San Francisco, CA,
United States

January 26-30, 2011

5th UK Alpine Liver and Pancreatic
Surgery Meeting, Carlo Magno
Zeledria Hotel, Madonna di
Campiglio, Italy

February 01-03, 2011

6th Annual Academic Surgical
Congress, Huntington Beach, CA,
United States

February 21-26, 2011

Minimally Invasive Surgery
Symposium 2011, The Grand
America Hotel, Salt Lake City, Utah,
United States

March 03-06, 2011

The Society of Surgical Oncology

63rd Annual Meeting, San Antonio,
TX, United States

March 10-13, 2011

The American Hepato-Pancreato-
Biliary Association Annual Meeting,
Miami Beach, FL, United States

March 14-17, 2011

British Society for Gastroenterology
Annual Meeting, International
Convention Centre, Birmingham,
United Kingdom

March 25-27, 2011

NZAGS Conference 2011 GI Surgery,
New Plymouth, New Zealand

March 30-April 02, 2011

The Society of American
Gastrointestinal and Endoscopic
Surgeons 2011 Annual Meeting, San
Antonio Convention Center, San
Antonio, TX, United States

April 02-06, 2011

The American Association for
Cancer Research 102nd Annual
Meeting, Orlando, FL, United States

April 10-12, 2011

The American Association of
Endocrine Surgeons 32nd Annual
Meeting, Houston, TX, United States

April 14-16, 2011

The American Surgical Association
131st Annual Meeting, Boca Raton,
FL, United States

May 07-10, 2011

Digestive Disease Week, Chicago,
IL, United States

May 07-10, 2011

45th Annual Meeting of the Pancreas
Club, Chicago, IL, United States

June 15-18, 2011

19th International Congress of
the European Association for
Endoscopic Surgery, in collaboration
with and incorporating the 15th
National Congress of the Italian
Society of Endoscopic Surgery,
Torino, Italy

September 10-14, 2011

International Congress of
Endoscopy, Los Angeles, CA,

United States

September 22-24, 2011

5th joint EAES and ESGE, European
Workshop on NOTES, Frankfurt,
Germany

September 23-25, 2011

The New England Surgical Society
92nd Annual Meeting, Breton
Woods, NH, United States

September 23-27, 2011

ECCO-European Society for Medical
Oncology Congress, Stockholm,
Sweden

October 23-27, 2011

The American College of Surgeons
97th Annual Clinical Congress, San
Francisco, CA, United States

November 02-05, 2011

American Pancreatic Association
42nd Annual Meeting, Chicago, IL,
United States

November 13-16, 2011

The Western Surgical Association
119th Scientific Session, Tucson, AZ,
United States



INSTRUCTIONS TO AUTHORS

GENERAL INFORMATION

World Journal of Gastrointestinal Surgery (*World J Gastrointest Surg*, *WJGS*, online ISSN 1948-9366, DOI: 10.4240), is a monthly, open-access (OA), peer-reviewed journal supported by an editorial board of 336 experts in gastrointestinal surgery from 35 countries.

The biggest advantage of the OA model is that it provides free, full-text articles in PDF and other formats for experts and the public without registration, which eliminates the obstacle that traditional journals possess and usually delays the speed of the propagation and communication of scientific research results. The open access model has been proven to be a true approach that may achieve the ultimate goal of the journals, i.e. the maximization of the value to the readers, authors and society.

Maximization of personal benefits

The role of academic journals is to exhibit the scientific levels of a country, a university, a center, a department, and even a scientist, and build an important bridge for communication between scientists and the public. As we all know, the significance of the publication of scientific articles lies not only in disseminating and communicating innovative scientific achievements and academic views, as well as promoting the application of scientific achievements, but also in formally recognizing the "priority" and "copyright" of innovative achievements published, as well as evaluating research performance and academic levels. So, to realize these desired attributes of *WJGS* and create a well-recognized journal, the following four types of personal benefits should be maximized. The maximization of personal benefits refers to the pursuit of the maximum personal benefits in a well-considered optimal manner without violation of the laws, ethical rules and the benefits of others. (1) Maximization of the benefits of editorial board members: The primary task of editorial board members is to give a peer review of an unpublished scientific article *via* online office system to evaluate its innovativeness, scientific and practical values and determine whether it should be published or not. During peer review, editorial board members can also obtain cutting-edge information in that field at first hand. As leaders in their field, they have priority to be invited to write articles and publish commentary articles. We will put peer reviewers' names and affiliations along with the article they reviewed in the journal to acknowledge their contribution; (2) Maximization of the benefits of authors: Since *WJGS* is an open-access journal, readers around the world can immediately download and read, free of charge, high-quality, peer-reviewed articles from *WJGS* official website, thereby realizing the goals and significance of the communication between authors and peers as well as public reading; (3) Maximization of the benefits of readers: Readers can read or use, free of charge, high-quality peer-reviewed articles without any limits, and cite the arguments, viewpoints, concepts, theories, methods, results, conclusion or facts and data of pertinent literature so as to validate the innovativeness, scientific and practical values of their own research achievements, thus ensuring that their articles have novel arguments or viewpoints, solid evidence and correct conclusion; and (4) Maximization of the benefits of employees: It is an iron law that a first-class journal is unable to exist without first-class editors, and only first-class editors can create a first-class academic journal. We insist on strengthening our team cultivation and construction so that every employee, in an open, fair and transparent environment, could contribute their wisdom to edit and publish high-quality articles,

thereby realizing the maximization of the personal benefits of editorial board members, authors and readers, and yielding the greatest social and economic benefits.

Aims and scope

The major task of *WJGS* is to rapidly report the most recent results in basic and clinical research on gastrointestinal surgery, specifically including micro-invasive surgery, laparoscopy, hepatic surgery, biliary surgery, pancreatic surgery, splenic surgery, surgical nutrition, portal hypertension, as well as the associated subjects such as epidemiology, cancer research, biomarkers, prevention, pathology, radiology, genetics, genomics, proteomics, pharmacology, pharmacokinetics, pharmacogenetics, molecular biology, clinical trials, diagnosis and therapeutics and multimodality treatment. Emphasis is placed on original research articles and clinical case reports. This journal will also provide balanced, extensive and timely review articles on selected topics.

Columns

The columns in the issues of *WJGS* will include: (1) Editorial: To introduce and comment on major advances and developments in the field; (2) Frontier: To review representative achievements, comment on the state of current research, and propose directions for future research; (3) Topic Highlight: This column consists of three formats, including (A) 10 invited review articles on a hot topic, (B) a commentary on common issues of this hot topic, and (C) a commentary on the 10 individual articles; (4) Observation: To update the development of old and new questions, highlight unsolved problems, and provide strategies on how to solve the questions; (5) Guidelines for Basic Research: To provide guidelines for basic research; (6) Guidelines for Clinical Practice: To provide guidelines for clinical diagnosis and treatment; (7) Review: To review systemically progress and unresolved problems in the field, comment on the state of current research, and make suggestions for future work; (8) Original Article: To report innovative and original findings in gastrointestinal surgery; (9) Brief Article: To briefly report the novel and innovative findings in gastrointestinal surgery; (10) Case Report: To report a rare or typical case; (11) Letters to the Editor: To discuss and make reply to the contributions published in *WJGS*, or to introduce and comment on a controversial issue of general interest; (12) Book Reviews: To introduce and comment on quality monographs of gastrointestinal surgery; and (13) Guidelines: To introduce consensus and guidelines reached by international and national academic authorities worldwide on basic research and clinical practice in gastrointestinal surgery.

Name of journal

World Journal of Gastrointestinal Surgery

ISSN

ISSN 1948-9366 (online)

Indexing/abstracting

PubMed Central, PubMed, Digital Object Identifier, and Directory of Open Access Journals.

Published by

Baishideng Publishing Group Co., Limited

SPECIAL STATEMENT

All articles published in this journal represent the viewpoints of the authors except where indicated otherwise.

Biostatistical editing

Statistical review is performed after peer review. We invite an expert in Biomedical Statistics from to evaluate the statistical method used in the paper, including *t*-test (group or paired comparisons), chi-squared test, Redit, probit, logit, regression (linear, curvilinear, or stepwise), correlation, analysis of variance, analysis of covariance, *etc.* The reviewing points include: (1) Statistical methods should be described when they are used to verify the results; (2) Whether the statistical techniques are suitable or correct; (3) Only homogeneous data can be averaged. Standard deviations are preferred to standard errors. Give the number of observations and subjects (*n*). Losses in observations, such as drop-outs from the study should be reported; (4) Values such as ED50, LD50, IC50 should have their 95% confidence limits calculated and compared by weighted probit analysis (Bliss and Finney); and (5) The word 'significantly' should be replaced by its synonyms (if it indicates extent) or the *P* value (if it indicates statistical significance).

Conflict-of-interest statement

In the interests of transparency and to help reviewers assess any potential bias, *WJGS* requires authors of all papers to declare any competing commercial, personal, political, intellectual, or religious interests in relation to the submitted work. Referees are also asked to indicate any potential conflict they might have reviewing a particular paper. Before submitting, authors are suggested to read "Uniform Requirements for Manuscripts Submitted to Biomedical Journals: Ethical Considerations in the Conduct and Reporting of Research: Conflicts of Interest" from International Committee of Medical Journal Editors (ICMJE), which is available at: http://www.icmje.org/ethical_4conflicts.html.

Sample wording: [Name of individual] has received fees for serving as a speaker, a consultant and an advisory board member for [names of organizations], and has received research funding from [names of organization]. [Name of individual] is an employee of [name of organization]. [Name of individual] owns stocks and shares in [name of organization]. [Name of individual] owns patent [patent identification and brief description].

Statement of informed consent

Manuscripts should contain a statement to the effect that all human studies have been reviewed by the appropriate ethics committee or it should be stated clearly in the text that all persons gave their informed consent prior to their inclusion in the study. Details that might disclose the identity of the subjects under study should be omitted. Authors should also draw attention to the Code of Ethics of the World Medical Association (Declaration of Helsinki, 1964, as revised in 2004).

Statement of human and animal rights

When reporting the results from experiments, authors should follow the highest standards and the trial should conform to Good Clinical Practice (for example, US Food and Drug Administration Good Clinical Practice in FDA-Regulated Clinical Trials; UK Medicines Research Council Guidelines for Good Clinical Practice in Clinical Trials) and/or the World Medical Association Declaration of Helsinki. Generally, we suggest authors follow the lead investigator's national standard. If doubt exists whether the research was conducted in accordance with the above standards, the authors must explain the rationale for their approach and demonstrate that the institutional review body explicitly approved the doubtful aspects of the study.

Before submitting, authors should make their study approved by the relevant research ethics committee or institutional review board. If human participants were involved, manuscripts must be accompanied by a statement that the experiments were undertaken with the understanding and appropriate informed consent of each. Any per-

sonal item or information will not be published without explicit consents from the involved patients. If experimental animals were used, the materials and methods (experimental procedures) section must clearly indicate that appropriate measures were taken to minimize pain or discomfort, and details of animal care should be provided.

SUBMISSION OF MANUSCRIPTS

Manuscripts should be typed in 1.5 line spacing and 12 pt. Book Antiqua with ample margins. Number all pages consecutively, and start each of the following sections on a new page: Title Page, Abstract, Introduction, Materials and Methods, Results, Discussion, Acknowledgements, References, Tables, Figures, and Figure Legends. Neither the editors nor the publisher are responsible for the opinions expressed by contributors. Manuscripts formally accepted for publication become the permanent property of Baishideng Publishing Group Co., Limited, and may not be reproduced by any means, in whole or in part, without the written permission of both the authors and the publisher. We reserve the right to copy-edit and put onto our website accepted manuscripts. Authors should follow the relevant guidelines for the care and use of laboratory animals of their institution or national animal welfare committee. For the sake of transparency in regard to the performance and reporting of clinical trials, we endorse the policy of the ICMJE to refuse to publish papers on clinical trial results if the trial was not recorded in a publicly-accessible registry at its outset. The only register now available, to our knowledge, is <http://www.clinicaltrials.gov> sponsored by the United States National Library of Medicine and we encourage all potential contributors to register with it. However, in the case that other registers become available you will be duly notified. A letter of recommendation from each author's organization should be provided with the contributed article to ensure the privacy and secrecy of research is protected.

Authors should retain one copy of the text, tables, photographs and illustrations because rejected manuscripts will not be returned to the author(s) and the editors will not be responsible for loss or damage to photographs and illustrations sustained during mailing.

Online submissions

Manuscripts should be submitted through the Online Submission System at: <http://www.wjgnet.com/1948-9366office>. Authors are highly recommended to consult the ONLINE INSTRUCTIONS TO AUTHORS (http://www.wjgnet.com/1948-9366/g_info_20100305152206.htm) before attempting to submit online. For assistance, authors encountering problems with the Online Submission System may send an email describing the problem to wjgs@wjgnet.com, or by telephone: +86-10-85381891. If you submit your manuscript online, do not make a postal contribution. Repeated online submission for the same manuscript is strictly prohibited.

MANUSCRIPT PREPARATION

All contributions should be written in English. All articles must be submitted using word-processing software. All submissions must be typed in 1.5 line spacing and 12 pt. Book Antiqua with ample margins. Style should conform to our house format. Required information for each of the manuscript sections is as follows:

Title page

Title: Title should be less than 12 words.

Running title: A short running title of less than 6 words should be provided.

Authorship: Authorship credit should be in accordance with the standard proposed by International Committee of Medical Journal Editors, based on (1) substantial contributions to conception and design, acquisition of data, or analysis and interpretation of data; (2) drafting the article or revising it critically for important intellectual content; and (3) final approval of the version to be published. Authors should meet conditions 1, 2, and 3.

Institution: Author names should be given first, then the complete name of institution, city, province and postcode. For example, Xu-Chen Zhang, Li-Xin Mei, Department of Pathology, Chengde Medical College, Chengde 067000, Hebei Province, China. One author may be represented from two institutions, for example, George Sgourakis, Department of General, Visceral, and Transplantation Surgery, Essen 45122, Germany; George Sgourakis, 2nd Surgical Department, Korgialenio-Benakio Red Cross Hospital, Athens 15451, Greece

Author contributions: The format of this section should be: Author contributions: Wang CL and Liang L contributed equally to this work; Wang CL, Liang L, Fu JF, Zou CC, Hong F and Wu XM designed the research; Wang CL, Zou CC, Hong F and Wu XM performed the research; Xue JZ and Lu JR contributed new reagents/analytic tools; Wang CL, Liang L and Fu JF analyzed the data; and Wang CL, Liang L and Fu JF wrote the paper.

Supportive foundations: The complete name and number of supportive foundations should be provided, e.g. Supported by National Natural Science Foundation of China, No. 30224801

Correspondence to: Only one corresponding address should be provided. Author names should be given first, then author title, affiliation, the complete name of institution, city, postcode, province, country, and email. All the letters in the email should be in lower case. A space interval should be inserted between country name and email address. For example, Montgomery Bissell, MD, Professor of Medicine, Chief, Liver Center, Gastroenterology Division, University of California, Box 0538, San Francisco, CA 94143, United States. montgomery.bissell@ucsf.edu

Telephone and fax: Telephone and fax should consist of +, country number, district number and telephone or fax number, e.g. Telephone: +86-10-85381891 Fax: +86-10-85381893

Peer reviewers: All articles received are subject to peer review. Normally, three experts are invited for each article. Decision for acceptance is made only when at least two experts recommend an article for publication. Reviewers for accepted manuscripts are acknowledged in each manuscript, and reviewers of articles which were not accepted will be acknowledged at the end of each issue. To ensure the quality of the articles published in *WJGS*, reviewers of accepted manuscripts will be announced by publishing the name, title/position and institution of the reviewer in the footnote accompanying the printed article. For example, reviewers: Professor Jing-Yuan Fang, Shanghai Institute of Digestive Disease, Shanghai, Affiliated Renji Hospital, Medical Faculty, Shanghai Jiaotong University, Shanghai, China; Professor Xin-Wei Han, Department of Radiology, The First Affiliated Hospital, Zhengzhou University, Zhengzhou, Henan Province, China; and Professor Anren Kuang, Department of Nuclear Medicine, Huaxi Hospital, Sichuan University, Chengdu, Sichuan Province, China.

Abstract

There are unstructured abstracts (no more than 256 words) and structured abstracts (no more than 480). The specific requirements for structured abstracts are as follows:

An informative, structured abstracts of no more than 480 words should accompany each manuscript. Abstracts for original contributions should be structured into the following sections. AIM (no more than 20 words): Only the purpose should be included. Please write the aim as the form of "To investigate/study/..."; MATERIALS AND METHODS (no more than 140 words); RESULTS (no more than 294 words): You should present *P* values where appropriate and must provide relevant data to illustrate how they were obtained, e.g. 6.92 ± 3.86 vs 3.61 ± 1.67 , $P < 0.001$; CONCLUSION (no more than 26 words).

Key words

Please list 5-10 key words, selected mainly from *Index Medicus*,

which reflect the content of the study.

Text

For articles of these sections, original articles and brief articles, the main text should be structured into the following sections: INTRODUCTION, MATERIALS AND METHODS, RESULTS and DISCUSSION, and should include appropriate Figures and Tables. Data should be presented in the main text or in Figures and Tables, but not in both. The main text format of these sections, editorial, topic highlight, case report, letters to the editors, can be found at: http://www.wjgnet.com/1948-9366/g_info_list.htm.

Illustrations

Figures should be numbered as 1, 2, 3, *etc.*, and mentioned clearly in the main text. Provide a brief title for each figure on a separate page. Detailed legends should not be provided under the figures. This part should be added into the text where the figures are applicable. Figures should be either Photoshop or Illustrator files (in tiff, eps, jpeg formats) at high-resolution. Examples can be found at: <http://www.wjgnet.com/1007-9327/13/4520.pdf>; <http://www.wjgnet.com/1007-9327/13/4554.pdf>; <http://www.wjgnet.com/1007-9327/13/4891.pdf>; <http://www.wjgnet.com/1007-9327/13/4986.pdf>; <http://www.wjgnet.com/1007-9327/13/4498.pdf>. Keeping all elements compiled is necessary in line-art image. Scale bars should be used rather than magnification factors, with the length of the bar defined in the legend rather than on the bar itself. File names should identify the figure and panel. Avoid layering type directly over shaded or textured areas. Please use uniform legends for the same subjects. For example: Figure 1 Pathological changes in atrophic gastritis after treatment. A: ...; B: ...; C: ...; D: ...; E: ...; F: ...; G: ...*etc.* It is our principle to publish high resolution-figures for the printed and E-versions.

Tables

Three-line tables should be numbered 1, 2, 3, *etc.*, and mentioned clearly in the main text. Provide a brief title for each table. Detailed legends should not be included under tables, but rather added into the text where applicable. The information should complement, but not duplicate the text. Use one horizontal line under the title, a second under column heads, and a third below the Table, above any footnotes. Vertical and italic lines should be omitted.

Notes in tables and illustrations

Data that are not statistically significant should not be noted. ^a*P* < 0.05, ^b*P* < 0.01 should be noted (*P* > 0.05 should not be noted). If there are other series of *P* values, ^c*P* < 0.05 and ^d*P* < 0.01 are used. A third series of *P* values can be expressed as ^e*P* < 0.05 and ^f*P* < 0.01. Other notes in tables or under illustrations should be expressed as ¹F, ²F, ³F; or sometimes as other symbols with a superscript (Arabic numerals) in the upper left corner. In a multi-curve illustration, each curve should be labeled with ●, ○, ■, □, ▲, △, *etc.*, in a certain sequence.

Acknowledgments

Brief acknowledgments of persons who have made genuine contributions to the manuscript and who endorse the data and conclusions should be included. Authors are responsible for obtaining written permission to use any copyrighted text and/or illustrations.

REFERENCES

Coding system

The author should number the references in Arabic numerals according to the citation order in the text. Put reference numbers in square brackets in superscript at the end of citation content or after the cited author's name. For citation content which is part of the narration, the coding number and square brackets should be typeset normally. For example, "Crohn's disease (CD) is associated with increased intestinal permeability^[1,2]". If references are cited directly in the text, they should be put together within the text, for

Instructions to authors

example, "From references^[19,22-24], we know that..."

When the authors write the references, please ensure that the order in text is the same as in the references section, and also ensure the spelling accuracy of the first author's name. Do not list the same citation twice.

PMID and DOI

Pleased provide PubMed citation numbers to the reference list, e.g. PMID and DOI, which can be found at <http://www.ncbi.nlm.nih.gov/sites/entrez?db=pubmed> and <http://www.crossref.org/SimpleTextQuery/>, respectively. The numbers will be used in E-version of this journal.

Style for journal references

Authors: the name of the first author should be typed in bold-faced letters. The family name of all authors should be typed with the initial letter capitalized, followed by their abbreviated first and middle initials. (For example, Lian-Sheng Ma is abbreviated as Ma LS, Bo-Rong Pan as Pan BR). The title of the cited article and italicized journal title (journal title should be in its abbreviated form as shown in PubMed), publication date, volume number (in black), start page, and end page [PMID: 11819634 DOI: 10.3748/wjg.13.5396].

Style for book references

Authors: the name of the first author should be typed in bold-faced letters. The surname of all authors should be typed with the initial letter capitalized, followed by their abbreviated middle and first initials. (For example, Lian-Sheng Ma is abbreviated as Ma LS, Bo-Rong Pan as Pan BR) Book title. Publication number. Publication place: Publication press, Year: start page and end page.

Format

Journals

English journal article (list all authors and include the PMID where applicable)

- 1 **Jung EM**, Clevert DA, Schreyer AG, Schmitt S, Rennert J, Kubale R, Feuerbach S, Jung F. Evaluation of quantitative contrast harmonic imaging to assess malignancy of liver tumors: A prospective controlled two-center study. *World J Gastroenterol* 2007; **13**: 6356-6364 [PMID: 18081224 DOI: 10.3748/wjg.13.6356]

Chinese journal article (list all authors and include the PMID where applicable)

- 2 **Lin GZ**, Wang XZ, Wang P, Lin J, Yang FD. Immunologic effect of Jianpi Yishen decoction in treatment of Pixu-diarhoea. *Shijie Huaren Xiaobua Zazhi* 1999; **7**: 285-287

In press

- 3 **Tian D**, Araki H, Stahl E, Bergelson J, Kreitman M. Signature of balancing selection in Arabidopsis. *Proc Natl Acad Sci USA* 2006; In press

Organization as author

- 4 **Diabetes Prevention Program Research Group**. Hypertension, insulin, and proinsulin in participants with impaired glucose tolerance. *Hypertension* 2002; **40**: 679-686 [PMID: 12411462 PMCID:2516377 DOI:10.1161/01.HYP.0000035706.28494.09]

Both personal authors and an organization as author

- 5 **Vallancien G**, Emberton M, Harving N, van Moorselaar RJ; Alf-One Study Group. Sexual dysfunction in 1, 274 European men suffering from lower urinary tract symptoms. *J Urol* 2003; **169**: 2257-2261 [PMID: 12771764 DOI:10.1097/01.ju.0000067940.76090.73]

No author given

- 6 21st century heart solution may have a sting in the tail. *BMJ* 2002; **325**: 184 [PMID: 12142303 DOI:10.1136/bmj.325.7357.184]

Volume with supplement

- 7 **Geraud G**, Spierings EL, Keywood C. Tolerability and safety of frovatriptan with short- and long-term use for treatment of migraine and in comparison with sumatriptan. *Headache* 2002; **42** Suppl 2: S93-99 [PMID: 12028325 DOI:10.1046/

j.1526-4610.42.s2.7.x]

Issue with no volume

- 8 **Banit DM**, Kaufer H, Hartford JM. Intraoperative frozen section analysis in revision total joint arthroplasty. *Clin Orthop Relat Res* 2002; (**401**): 230-238 [PMID: 12151900 DOI:10.1097/00003086-200208000-00026]

No volume or issue

- 9 Outreach: Bringing HIV-positive individuals into care. *HRS-A Careaction* 2002; 1-6 [PMID: 12154804]

Books

Personal author(s)

- 10 **Sherlock S**, Dooley J. Diseases of the liver and biliary system. 9th ed. Oxford: Blackwell Sci Pub, 1993: 258-296

Chapter in a book (list all authors)

- 11 **Lam SK**. Academic investigator's perspectives of medical treatment for peptic ulcer. In: Swabb EA, Azabo S. Ulcer disease: investigation and basis for therapy. New York: Marcel Dekker, 1991: 431-450

Author(s) and editor(s)

- 12 **Breedlove GK**, Schorfheide AM. Adolescent pregnancy. 2nd ed. Wiczorek RR, editor. White Plains (NY): March of Dimes Education Services, 2001: 20-34

Conference proceedings

- 13 **Harnden P**, Joffe JK, Jones WG, editors. Germ cell tumours V. Proceedings of the 5th Germ cell tumours Conference; 2001 Sep 13-15; Leeds, UK. New York: Springer, 2002: 30-56

Conference paper

- 14 **Christensen S**, Oppacher F. An analysis of Koza's computational effort statistic for genetic programming. In: Foster JA, Lutton E, Miller J, Ryan C, Tettamanzi AG, editors. Genetic programming. EuroGP 2002: Proceedings of the 5th European Conference on Genetic Programming; 2002 Apr 3-5; Kinsdale, Ireland. Berlin: Springer, 2002: 182-191

Electronic journal (list all authors)

- 15 Morse SS. Factors in the emergence of infectious diseases. *Emerg Infect Dis* serial online, 1995-01-03, cited 1996-06-05; 1(1): 24 screens. Available from: URL: <http://www.cdc.gov/ncidod/cid/index.htm>

Patent (list all authors)

- 16 **Pagedas AC**, inventor; Ancel Surgical R&D Inc., assignee. Flexible endoscopic grasping and cutting device and positioning tool assembly. United States patent US 20020103498. 2002 Aug 1

Statistical data

Write as mean \pm SD or mean \pm SE.

Statistical expression

Express *t* test as *t* (in italics), *F* test as *F* (in italics), chi square test as χ^2 (in Greek), related coefficient as *r* (in italics), degree of freedom as *v* (in Greek), sample number as *n* (in italics), and probability as *P* (in italics).

Units

Use SI units. For example: body mass, *m* (B) = 78 kg; blood pressure, *p* (B) = 16.2/12.3 kPa; incubation time, *t* (incubation) = 96 h; blood glucose concentration, *c* (glucose) 6.4 ± 2.1 mmol/L; blood CEA mass concentration, *p* (CEA) = 8.6 ± 24.5 μ g/L; CO₂ volume fraction, 50 mL/L CO₂, not 5% CO₂; likewise for 40 g/L formaldehyde, not 10% formalin; and mass fraction, 8 ng/g, etc. Arabic numerals such as 23, 243, 641 should be read 23 243 641.

The format for how to accurately write common units and quantum can be found at: http://www.wjgnet.com/1948-9366/g_info_20100312191949.htm.

Abbreviations

Standard abbreviations should be defined in the abstract and on first mention in the text. In general, terms should not be abbreviated unless they are used repeatedly and the abbreviation is helpful to the reader. Permissible abbreviations are listed in Units, Symbols

and Abbreviations: A Guide for Biological and Medical Editors and Authors (Ed. Baron DN, 1988) published by The Royal Society of Medicine, London. Certain commonly used abbreviations, such as DNA, RNA, HIV, LD50, PCR, HBV, ECG, WBC, RBC, CT, ESR, CSF, IgG, ELISA, PBS, ATP, EDTA, mAb, can be used directly without further explanation.

Italics

Quantities: *t* time or temperature, *c* concentration, *A* area, *l* length, *m* mass, *V* volume.

Genotypes: *gyrA*, *arg 1*, *c myc*, *c fos*, etc.

Restriction enzymes: *EcoRI*, *HindII*, *BamHI*, *Kho I*, *Kpn I*, etc.

Biology: *H. pylori*, *E. coli*, etc.

Examples for paper writing

Editorial: http://www.wjnet.com/1948-9366/g_info_20100312190249.htm

Frontier: http://www.wjnet.com/1948-9366/g_info_20100312190321.htm

Topic highlight: http://www.wjnet.com/1948-9366/g_info_20100312190447.htm

Observation: http://www.wjnet.com/1948-9366/g_info_20100312190550.htm

Guidelines for basic research: http://www.wjnet.com/1948-9366/g_info_20100312190653.htm

Guidelines for clinical practice: http://www.wjnet.com/1948-9366/g_info_20100312190758.htm

Review: http://www.wjnet.com/1948-9366/g_info_20100312190907.htm

Original articles: http://www.wjnet.com/1948-9366/g_info_20100312191047.htm

Brief articles: http://www.wjnet.com/1948-9366/g_info_20100312191203.htm

Case report: http://www.wjnet.com/1948-9366/g_info_20100312191328.htm

Letters to the editor: http://www.wjnet.com/1948-9366/g_info_20100312191431.htm

Book reviews: http://www.wjnet.com/1948-9366/g_info_20100312191548.htm

Guidelines: http://www.wjnet.com/1948-9366/g_info_20100312191635.htm

SUBMISSION OF THE REVISED MANUSCRIPTS AFTER ACCEPTED

Please revise your article according to the revision policies of *WJGS*. The revised version including manuscript and high-resolution image figures (if any) should be copied on a floppy or compact disk. The author should send the revised manuscript, along with printed high-resolution color or black and white photos, copyright transfer letter, and responses to the reviewers by courier (such as EMS/DHL).

Editorial Office

World Journal of Gastrointestinal Surgery

Editorial Department: Room 903, Building D,
Ocean International Center,
No. 62 Dongsihuan Zhonglu,
Chaoyang District, Beijing 100025, China
E-mail: wjgs@wjnet.com
<http://www.wjnet.com>
Telephone: +86-10-8538-1891
Fax: +86-10-8538-1893

Language evaluation

The language of a manuscript will be graded before it is sent for revision. (1) Grade A: priority publishing; (2) Grade B: minor language polishing; (3) Grade C: a great deal of language polishing needed; and (4) Grade D: rejected. Revised articles should reach Grade A or B.

Copyright assignment form

Please download a Copyright assignment form from http://www.wjnet.com/1948-9366/g_info_20100312191901.htm.

Responses to reviewers

Please revise your article according to the comments/suggestions provided by the reviewers. The format for responses to the reviewers' comments can be found at: http://www.wjnet.com/1948-9366/g_info_20100312191818.htm.

Proof of financial support

For paper supported by a foundation, authors should provide a copy of the document and serial number of the foundation.

Links to documents related to the manuscript

WJGS will be initiating a platform to promote dynamic interactions between the editors, peer reviewers, readers and authors. After a manuscript is published online, links to the PDF version of the submitted manuscript, the peer-reviewers' report and the revised manuscript will be put on-line. Readers can make comments on the peer reviewer's report, authors' responses to peer reviewers, and the revised manuscript. We hope that authors will benefit from this feedback and be able to revise the manuscript accordingly in a timely manner.

Science news releases

Authors of accepted manuscripts are suggested to write a science news item to promote their articles. The news will be released rapidly at EurekAlert/AAAS (<http://www.eurekalert.org>). The title for news items should be less than 90 characters; the summary should be less than 75 words; and main body less than 500 words. Science news items should be lawful, ethical, and strictly based on your original content with an attractive title and interesting pictures.

Publication fee

WJGS is an international, peer-reviewed, Open-Access, online journal. Articles published by this journal are distributed under the terms of the Creative Commons Attribution Non-commercial License, which permits use, distribution, and reproduction in any medium, provided the original work is properly cited, the use is non commercial and is otherwise in compliance with the license. Authors of accepted articles must pay a publication fee. The related standards are as follows. Publication fee: 1300 USD per article. Editorial, topic highlights, book reviews and letters to the editor are published free of charge.