


World Journal of *Orthopedics*

World J Orthop 2023 October 18; 14(10): 733-783



MINIREVIEWS

- 733 Triggering, clicking, locking and crepitus of the finger: A comprehensive overview
Jordaan PW, Klumpp R, Zeppieri M

ORIGINAL ARTICLE**Case Control Study**

- 741 Machine learning applications for the prediction of extended length of stay in geriatric hip fracture patients
Tian CW, Chen XX, Shi L, Zhu HY, Dai GC, Chen H, Rui YF

Observational Study

- 755 Catania flatfoot score: A diagnostic-therapeutic evaluation tool in children
Vescio A, Testa G, Caldaci A, Sapienza M, Pavone V
- 763 Total hip arthroplasty following the failure of intertrochanteric nailing: First implant or salvage surgery?
Solarino G, Bizzoca D, Dramisino P, Vicenti G, Moretti L, Moretti B, Piazzolla A

CASE REPORT

- 771 Vancomycin flushing syndrome in orthopaedic practice: A case report
Al-Anii FM, Sadat-Ali M, Al-Tabash KW, AlMulhim AI, AlMousa SA, AlHawas AM
- 776 Late brachial plexopathy after a mid-shaft clavicle fracture: A case report
Alzahrani MM

ABOUT COVER

Editor-in-Chief of *World Journal of Orthopedics*, Xiao-Jian Ye, MD, Chief Physician, Department of Orthopedics, Tongren Hospital Affiliated to Shanghai Jiaotong University School of Medicine, Shanghai 200233, China. yexj2002@163.com

AIMS AND SCOPE

The primary aim of *World Journal of Orthopedics* (*WJO*, *World J Orthop*) is to provide scholars and readers from various fields of orthopedics with a platform to publish high-quality basic and clinical research articles and communicate their research findings online.

WJO mainly publishes articles reporting research results and findings obtained in the field of orthopedics and covering a wide range of topics including arthroscopy, bone trauma, bone tumors, hand and foot surgery, joint surgery, orthopedic trauma, osteoarthropathy, osteoporosis, pediatric orthopedics, spinal diseases, spine surgery, and sports medicine.

INDEXING/ABSTRACTING

WJO is now abstracted and indexed in PubMed, PubMed Central, Emerging Sources Citation Index (Web of Science), Scopus, Reference Citation Analysis, China Science and Technology Journal Database, and Superstar Journals Database. The 2023 Edition of Journal Citation Reports® cites the 2022 impact factor (IF) for *WJO* as 1.9. The *WJO*'s CiteScore for 2022 is 2.6.

RESPONSIBLE EDITORS FOR THIS ISSUE

Production Editor: Zi-Hang Xu, Production Department Director: Xiang Li, Editorial Office Director: Jin-Lei Wang.

NAME OF JOURNAL

World Journal of Orthopedics

ISSN

ISSN 2218-5836 (online)

LAUNCH DATE

November 18, 2010

FREQUENCY

Monthly

EDITORS-IN-CHIEF

Massimiliano Leigheb, Xiao-Jian Ye

EXECUTIVE ASSOCIATE EDITORS-IN-CHIEF

Xin Gu

EDITORIAL BOARD MEMBERS

<http://www.wjnet.com/2218-5836/editorialboard.htm>

PUBLICATION DATE

October 18, 2023

COPYRIGHT

© 2023 Baishideng Publishing Group Inc

PUBLISHING PARTNER

The Minimally Invasive Spine Surgery Research Center Of Shanghai Jiaotong University

INSTRUCTIONS TO AUTHORS

<https://www.wjnet.com/bpg/gerinfo/204>

GUIDELINES FOR ETHICS DOCUMENTS

<https://www.wjnet.com/bpg/gerinfo/287>

GUIDELINES FOR NON-NATIVE SPEAKERS OF ENGLISH

<https://www.wjnet.com/bpg/gerinfo/240>

PUBLICATION ETHICS

<https://www.wjnet.com/bpg/gerinfo/288>

PUBLICATION MISCONDUCT

<https://www.wjnet.com/bpg/gerinfo/208>

POLICY OF CO-AUTHORS

<https://www.wjnet.com/bpg/gerinfo/310>

ARTICLE PROCESSING CHARGE

<https://www.wjnet.com/bpg/gerinfo/242>

STEPS FOR SUBMITTING MANUSCRIPTS

<https://www.wjnet.com/bpg/gerinfo/239>

ONLINE SUBMISSION

<https://www.f6publishing.com>

PUBLISHING PARTNER'S OFFICIAL WEBSITE

https://www.shtrhospital.com/zkjs/info_29.aspx?itemid=647



Triggering, clicking, locking and crepitus of the finger: A comprehensive overview

Pieter W Jordaan, Raymond Klumpp, Marco Zeppieri

Specialty type: Orthopedics

Provenance and peer review:

Invited article; Externally peer reviewed.

Peer-review model: Single blind

Peer-review report's scientific quality classification

Grade A (Excellent): 0

Grade B (Very good): 0

Grade C (Good): 0

Grade D (Fair): 0

Grade E (Poor): 0

P-Reviewer: Lee S, South Korea

Received: August 21, 2023

Peer-review started: August 21, 2023

First decision: September 13, 2023

Revised: September 13, 2023

Accepted: October 8, 2023

Article in press: October 8, 2023

Published online: October 18, 2023



Pieter W Jordaan, Department of Orthopaedic, Garden Route Hand Unit, George 6530, South Africa

Raymond Klumpp, UOC Ortopedia e Traumatologia, Ospedale Treviglio-Caravaggio ASST, Bergamo Ovest 24047, Italy

Marco Zeppieri, Department of Ophthalmology, University Hospital of Udine, Udine 33100, Italy

Corresponding author: Marco Zeppieri, BSc, MD, PhD, Doctor, Department of Ophthalmology, University Hospital of Udine, p.le S. Maria della Misericordia 15, Udine 33100, Italy.

markzeppieri@hotmail.com

Abstract

Triggering, locking, clicking, and crepitus of the fingers are common symptoms patients present with. Even though crepitus and triggering can occur as part of the same underlying diagnosis, it is important to differentiate between them, as they usually indicate different possible diagnoses. The differential diagnoses that should be considered include trigger finger, metacarpophalangeal joint (MCPJ) arthritis, fractures or dislocations, extensor digitorum communis subluxation or dislocation, locked MCPJ, avascular necrosis of the metacarpal head, and Dupuytren's disease. A thorough clinical examination with appropriate special investigations can permit the clinician to make the correct diagnosis. Appropriate management of a confirmed diagnosis is successful in providing symptomatic improvement.

Key Words: Trigger finger; Locking; Crepitus; Metacarpophalangeal joint; Dislocation; Differential diagnosis

©The Author(s) 2023. Published by Baishideng Publishing Group Inc. All rights reserved.

Core Tip: Despite trigger fingers being one of the most common causes of hand pain and disability, there are other possible causes of triggering, locking, clicking, and crepitus of the fingers. Failure to recognize and diagnose these other causes can lead to treatment errors and inappropriate management of patients.

Citation: Jordaan PW, Klumpp R, Zeppieri M. Triggering, clicking, locking and crepitus of the finger: A comprehensive overview. *World J Orthop* 2023; 14(10): 733-740

URL: <https://www.wjgnet.com/2218-5836/full/v14/i10/733.htm>

DOI: <https://dx.doi.org/10.5312/wjo.v14.i10.733>

INTRODUCTION

Trigger fingers are one of the most common causes of pain and disability of the adult hand[1,2]. Even though a trigger finger is commonly associated with locking of the finger in flexion and a painful snapping (clicking) during extension[3, 4], a mild trigger finger (Green 1)[5] may present with only pain, swelling and stiffness in the morning[6,7], whereas a severe one (Green 4)[5], may have a locked digit[7], presenting like a flexion contracture[7] which has to be distinguished from a Dupuytren's contracture.

When associated with severe flexor synovitis, patients with trigger fingers may even have crepitus in the palm[7], but when crepitus is present, a clinician will tend to consider metacarpophalangeal joint (MCPJ) arthritis as a diagnosis. A well-known medical cliché is: "common things occur commonly." This is important to remember, but at the same time, as clinicians, we have to keep in mind that "not all that glitters is gold."

In this minireview, we provide a short summary of the broad differential diagnosis for triggering and crepitus of the finger and briefly discuss the clinical presentation, workup, and treatment of these different conditions.

PRESENTING SYMPTOMS

In this modern day and age, many patients, after extensive internet research, will present to their doctor with a diagnosis. The majority of patients will still present with troublesome symptoms, which include the following.

Pain is probably the most common symptom. It is important to differentiate between pain in the mornings (inflammatory) and pain with motion (mechanical). A trigger finger will often be more painful in the mornings or evenings and will also experience pain with extension when triggering. Arthritis will generally cause pain with all motion of the joint and less pain when resting, except in cases of inflammatory arthritis, which can also present with morning and evening pain.

Stiffness is often associated with many conditions affecting the hand. It is important to determine whether there is a fixed decreased range of motion or just temporary stiffness or uneven motion.

Triggering can be reported in some individuals. Most patients will describe it as clicking or locking, depending on the severity of the disease.

Crepitus is a symptom that patients tend not to complain about; however, patients commonly describe it as grinding or they say it feels as though they have sand or gravel around the tendon when they try and move. In the case of a fracture, they may even describe a feeling of cracking.

The history is important as acute onset following trauma would guide the diagnosis more towards a fracture or sagittal band injury.

DIFFERENTIAL DIAGNOSIS

Several conditions need to be considered in the differential diagnosis of these symptoms. The most common conditions are listed below and reported in [Table 1](#).

Trigger finger

Trigger finger remains the most common diagnosis[1]. It is caused by a discrepancy in the size of the flexor tendon and the A1 pulley[8], but in 1% of cases, the triggering can occur at the A2 pulley[5]. There is a bimodal distribution with pediatric trigger fingers presenting before the age of 8 and adult cases presenting in the 5th and 6th decade[1,3]. It is more common in females[3] and tends to affect the ring and middle fingers more commonly[1]. Many conditions are associated with trigger fingers including diabetes, inflammatory conditions, carpal tunnel syndrome, hypothyroidism, gout, storage diseases, De Quervain's tenosynovitis, and Dupuytren's contracture[7,8].

MCPJ arthritis[9]

Arthritis causes pain, swelling, and a limited range of motion. Rheumatoid and other inflammatory arthritis used to be the most common causes of MCPJ arthritis. With improved medical control, this is seen less than it used to be. Osteoarthritis, posttraumatic arthritis, and crystalline deposition disorders should be included in the differential diagnosis.

Fractures and dislocations

This seems like an obvious diagnosis, but can be missed if not considered. There should be a clear trauma history with a

Table 1 Differential diagnosis of triggering, clicking, and locking of the finger

Differential diagnoses
Trigger finger
Metacarpophalangeal joint arthritis
Fractures and dislocations
Extensor digitorum communis subluxation/dislocation
Locked metacarpophalangeal joint
Avascular necrosis of the metacarpal head
Dupuytren's contracture

painful, swollen, and bruised finger and crepitus and pain with motion. Consider metacarpal head and neck fractures and fractures at the base of the proximal phalanx as well as MCPJ dislocations.

Extensor digitorum communis subluxation/dislocation

In acute traumatic injury, Boxer's Knuckle, there is a rupture of the sagittal band (most commonly the radial sagittal band), causing subluxation or dislocation of the extensor digitorum communis (EDC) tendon[10,11]. It can also occur due to attrition as seen in Rheumatoid Arthritis patients or occasionally in osteoarthritis[10]. The middle finger is most affected in a Boxer's Knuckle[10-12]. The MCPJ is swollen and tender[11] and patients can complain of clicking with crepitus found during examination, which is called pseudo triggering[10]. In mild cases (Rayan and Murray grade 1)[13] the MCPJ is just swollen and tender, but in cases of complete EDC dislocation (Rayan and Murray grade 3)[13] active extension may not be possible[10,11] and can create the impression of a locked MCPJ or even an extensor tendon rupture.

Locked MCPJ

A patient can present with a loss of active and passive MCPJ extension, without affecting interphalangeal joint motion and while maintaining full flexion[14,15]. This is caused by entrapment of the collateral ligament (usually the radial collateral ligament)[15] behind an osteophyte of the metacarpal head in flexion, which prevents extension. In certain cases, the ligament does not get stuck but just causes snapping as it passes over the osteophyte[16]. It can be caused by any condition that causes an abnormal shape of the metacarpal head, such as acromegaly or achondroplasia[15]. Impingement of a torn palmar plate can cause locking of the MCPJ[15,16], but in these cases, flexion can often be limited rather than extension[15].

Avascular necrosis of the metacarpal head (Dietrich's/Mauclaire's disease)

Avascular necrosis (AVN) of the metacarpal head is very rare. It occurs more commonly in young men and more commonly in the middle finger[17,18]. Patients can present with pain and crepitus, very similar to arthritis, and it is associated with anatomical variations in blood flow, trauma, steroid use, systemic lupus erythematosus (SLE), hypercoagulability, alcoholism or it can be idiopathic[17,18].

Dupuytren's disease

Dupuytren's disease is an idiopathic fibrosis of the palmar aponeurosis leading to contractures of the fingers[19]. It can be associated with trigger fingers, but should also be considered as a differential diagnosis for a locked finger. Even though the diagnosis may seem obvious, some patients can have subtle cords, making it less obvious. It should also be remembered that Dupuytren's can be associated with trigger fingers and both diagnoses can co-exist on the same finger.

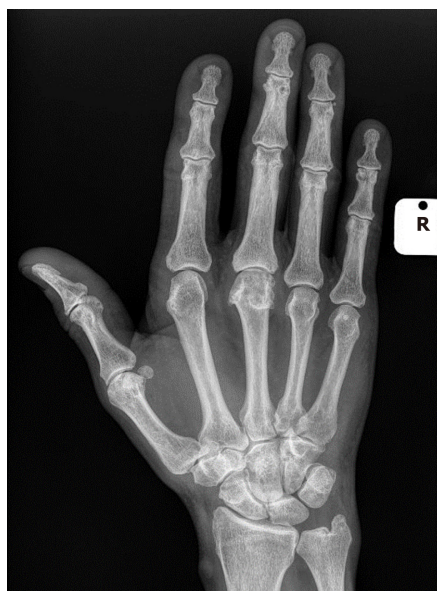DIAGNOSIS

Clinical

In many cases, the diagnosis can be made through history and clinical examination. In the case of a trigger finger, the patient will present with a typical history of temporary locking of the finger in flexion and painful snapping during extension[4]. Triggering may not be elicited in all cases, but there is generally mild swelling of the finger and tenderness over the A1 pulley[1,3].

In MCPJ arthritis, the patient will complain of pain with motion and a decreased range of motion. On examination, the joint will be swollen and tender, with a decreased range of active and passive motion[9] and a positive grind test. Crepitus may be felt.

Fractures and dislocations around the MCPJ should present with a typical trauma history with a painful swollen and bruised finger and hand. There can be a deformity and any motion will be extremely painful and may even produce crepitus. With a dislocation, the joint may seem locked in a certain position.



DOI: 10.5312/wjo.v14.i10.733 Copyright ©The Author(s) 2023.

Figure 1 X-ray of a hand with crepitus. Osteoarthritis of the middle finger metacarpophalangeal joint.

EDC subluxation may present with a trauma history[20] in cases of sagittal band rupture, but may also have a spontaneous onset[20] in cases of sagittal band attrition[10]. The MCPJ will generally be swollen and tender dorsally with clicking (pseudo triggering)[10] noted during motion[11]. In Rayan and Murray[13] grade 3 cases, there may be an extensive deficit during active motion, with normal passive extension. During full active MCPJ flexion, the EDC can be observed to sublux/dislocate out of its central position over the MCPJ.

A patient who presents with a locked MCPJ may suggest a trivial traumatic event as a cause of their condition. There may be signs of osteoarthritis of the other small joints in the hand and the MCPJ is often not swollen and non-tender. There will be decreased active and passive extension with normal interphalangeal joint motion and full active flexion of the finger[14,15].

AVN of the metacarpal head is a rare condition[17,18] and a diagnosis of exclusion[18]. There will be pain and possibly crepitus[17,18] and a decreased range of motion in a patient who is younger than would be normally expected to be seen in an arthritic joint. Conditions associated with AVN such as steroid use, alcoholism, SLE, and hypercoagulability[17,18] may be present.

In a patient with Dupuytren's contracture, there will be a fixed contracture limiting full extension and there should be a visible and palpable cord and possible family history. A careful examination is mandatory as some patients can have very subtle cords and be aware that there may be a co-existing grade 1 trigger finger with a tender A1 pulley.

X-ray

Where the diagnosis is not obvious on clinical examination, radiographs should be the first special investigation and will assist with the diagnosis of a fracture, dislocation, and arthritis (Figure 1). In sagittal band attrition, there may be signs of underlying arthritis and in a locked MCPJ an osteophyte may be visible (Figure 2). X-rays may be normal in early cases of AVN, but in more advanced cases collapse will be present.

Ultrasound

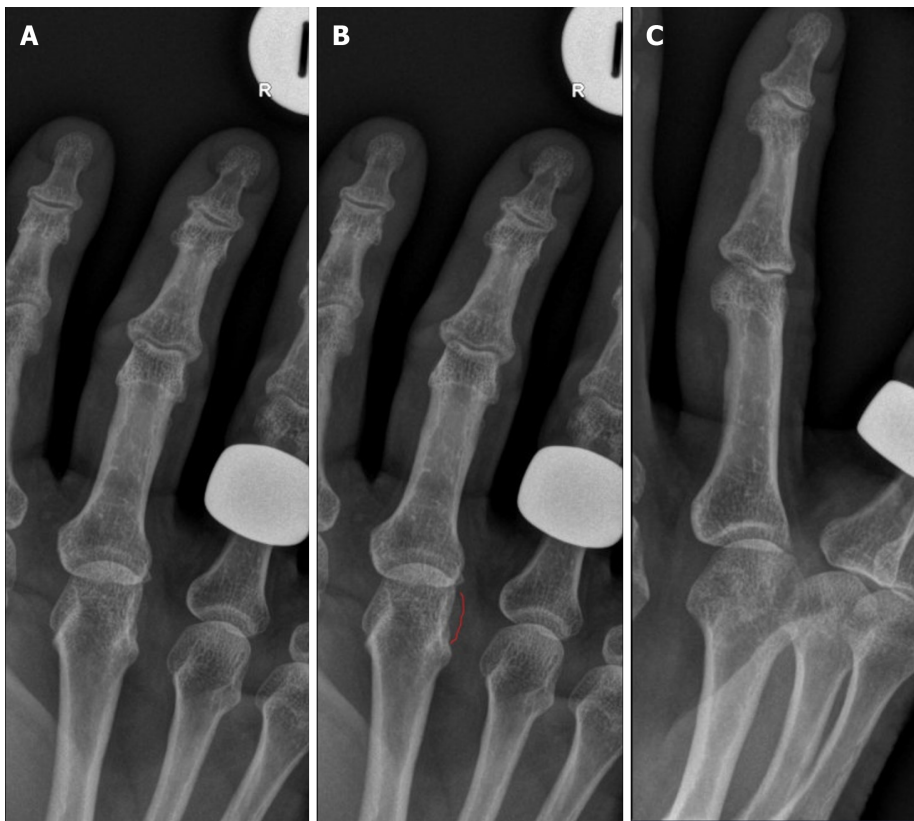
Ultrasound can be used to confirm the diagnosis of a trigger finger if there is any doubt, and it will show a thickening of the A1 pulley and possibly the flexor tendon with or without signs of flexor synovitis. Dynamic scanning is possible for cases of suspected EDC subluxation/dislocation to assist with the diagnosis. Ultrasound can also be used in cases of a locked MCPJ to diagnose an entrapped collateral ligament or torn palmar plate. Even Dupuytren's nodules and cords can be confirmed with ultrasound[21].

Laboratory investigations

Blood tests will not help to differentiate between the diagnosis discussed here, but where a possible inflammatory or crystalline arthropathy is suspected or in cases of AVN it may be useful to determine the underlying cause.

Magnetic resonance imaging

The main purpose of magnetic resonance imaging (MRI) is in the detection of early AVN[17] (Figure 3) where the x-ray is still normal and other diagnoses have been excluded and it can assist in the diagnosis of a locked MCPJ[15]. Even though MRI will pick up trigger fingers, arthritis, sagittal band attrition/rupture, fractures, and Dupuytren's cords/nodules, it is not recommended as first-line investigation for any of these conditions.



DOI: 10.5312/wjo.v14.i10.733 Copyright ©The Author(s) 2023.

Figure 2 X-ray of a hand with locking. A: X-rays of locked metacarpophalangeal joint (MCPJ); B: X-rays with ulnar osteophyte marked; C: Oblique view of locked MCPJ.

TREATMENT

An in-depth discussion of the treatment of all these conditions is outside the scope of this article, but we will discuss some general treatment principles and in brief discuss specific treatments for each condition.

General measures

Lifestyle modification and diet change is the simplest early treatment. As long as lifestyle modification does not affect quality of life, it can be very effective. Therapy with or without the use of splints is the next line of non-invasive therapy. A Prospective, Randomized, Double-Blind, Placebo-Controlled, Multicenter Clinical Trial showed that avocado/soybean unsaponifiables are more effective than placebo in providing symptomatic relief in hip and knee osteoarthritis[22]. Other medications such as non-steroidal anti-inflammatory medication can also be very effective in providing symptomatic relief. Cortisone injections, which in some cases only provide temporary symptomatic relief, can potentially be curable in for instance trigger fingers. Surgery is generally the last line of treatment, but in most cases is the most reliable solution for providing long-term relief.

Trigger fingers

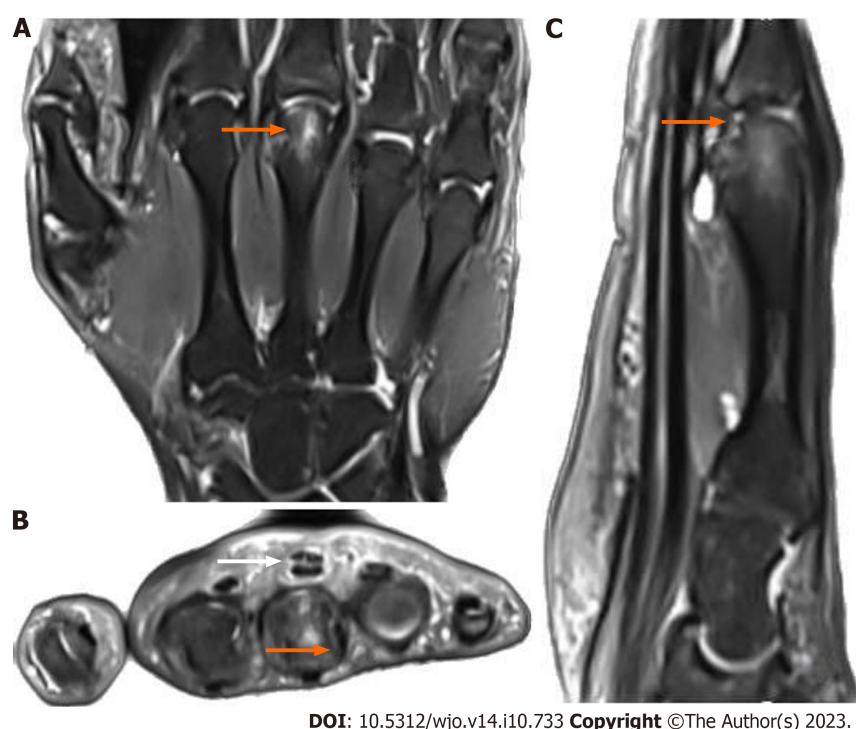
It is important to remember that 52% of trigger fingers will resolve spontaneously without any intervention within 8 mo of the onset of symptoms[23]. Splints can be effective in up to 55% of cases in 1 year, but it is uncertain how many of these would have resolved spontaneously[1]. A single cortisone injection can be curative in 45%-80% of cases with repeat injections being effective in 30%-40% of cases[1]. There seems to be no difference between an injection into the flexor sheath *vs* an injection outside the flexor sheath[24]. Surgery can be performed as either open or percutaneous[7] and provides the best chance of a long-term symptom-free result.

MCPJ arthritis

When conservative management fails (see under general measures), arthroplasty is usually the surgical option of choice [9]. In cases of inflammatory or crystalline arthropathy, it is important to refer the patient to a Rheumatologist to adequately manage the underlying cause. It is worth remembering that hemochromatosis can cause arthritis of the index and middle finger MCPJs[25] and the patient should be worked up for this and referred for treatment if indicated.

Fractures and dislocations

Fractures should be managed according to the fracture type, displacement, angulation, rotation, and shortening. Most



DOI: 10.5312/wjo.v14.i10.733 Copyright ©The Author(s) 2023.

Figure 3 Magnetic resonance imaging of a hand with pain and symptoms. A: Edema in the third metacarpal head (orange arrow) shown on magnetic resonance imaging (MRI) coronal view T2; B: Edema in the third metacarpal head (orange arrow) and flexor tendons with minimal effusion (white arrow) shown on magnetic resonance imaging transverse view; C: Edema in the third metacarpal head with effusion and joint surface involvement (orange arrow) shown on MRI sagittal view T2.

fractures can be managed conservatively in a splint, but if the position is not acceptable, may require a closed reduction with or without k-wires or an open reduction and internal fixation. Dislocations require reduction and this can mostly be achieved by closed means. In case of failed closed reduction or incongruent reduction, open surgery must be performed.

Extensor tendon subluxation/dislocation

The majority of cases can be managed in a splint[10,12], especially within 3 wk of the injury[11,20]. Surgery is reserved for the professional athlete, chronic cases, or those who failed conservative treatment and can be either a direct repair or sagittal band reconstruction[10,11].

Locked MCPJ

Closed reduction can be attempted by injecting local anesthetic into the joint and then applying gentle traction and rotation, but this does carry the risk of a potential fracture. Most cases are managed surgically by open reduction and excision of the osteophyte[14,15].

AVN of the metacarpal head

The first line of treatment should be rest and medication, but if this fails, then the surgical options are curettage and bone graft, osteotomy, osteochondral grafts, denervation, arthrodesis, or arthroplasty[17].

Dupuytren's contracture

Once there is the progression of the contracture and it becomes functionally debilitating, surgery, either percutaneous needle aponeurotomy or fasciectomy (partial or segmental), becomes the treatment of choice[19].

PROGNOSIS

The success of cortisone injections in trigger fingers has already been discussed. Surgery, whether open or percutaneous can have success rates of 90%-100%[1]. Arthroplasty for MCPJ arthritis is successful in improving pain and function and has patient satisfaction rates of up to 90% in certain studies, especially in osteoarthritis[9]. Conservative and surgical management, when indicated, is very effective in the treatment of EDC subluxation/dislocation in terms of symptom improvement[10]. In a case series of locked MCPJs, 13 of 14 patients (1 was lost to follow-up) had an excellent outcome with no pain and a normal range of motion[15]. AVN of the metacarpal head is rare and therefore little is known about the long-term prognosis[17]. Fractures, dislocations, and Dupuytren's contractures have so many treatment options and are such vast topics in themselves, that the discussion of treatment specifics and prognosis falls outside the scope of this

article.

SUMMARY

With regards to what we currently know about this condition, triggering, clicking, locking, and crepitus of the finger are symptoms typically associated with a condition known as “trigger finger” or stenosing tenosynovitis. This condition primarily affects the flexor tendons of the fingers and is characterized by certain signs and symptoms. Triggering is a sensation where the finger gets stuck in a bent position and then suddenly releases with a “click” or “pop.” Clicking can be defined as an audible or palpable clicks or snaps during finger movement. Locking occurs when the finger becomes locked in a flexed position, requiring manual assistance to extend it. Crepitus can be described as the sensation or sound of grinding, popping, or crackling within the affected finger during movement.

Current knowledge suggests that these symptoms arise due to inflammation or thickening of the tendon sheath, obstructing the smooth gliding of the flexor tendon. The exact causes of the trigger finger are multifactorial, with risk factors including repetitive gripping activities, underlying medical conditions, and genetic predisposition.

The current theories that drive the clinical applications in the management include the inflammation within the tendon sheath plays a key role in trigger finger symptoms. Treatments often involve anti-inflammatory medications, corticosteroid injections, or physical therapy. The Structural Theory is thought that structural changes in the tendon, such as nodules or thickening, are responsible for the condition. Surgical interventions, such as tenosynovectomy or release, aim to address these structural issues. The Biomechanical Theory includes mechanical factors, like repetitive strain or improper hand ergonomics, which are thought to contribute to the development of trigger fingers. Occupational therapy and ergonomic modifications are employed to alleviate symptoms.

Further research on the trigger finger is essential for several reasons. Trigger finger is a common hand condition, and its prevalence is increasing, possibly due to changes in lifestyles and work habits. Understanding it better can help address this growing health concern. The condition can significantly impact an individual's quality of life, affecting their ability to perform daily activities and work. Improved management strategies can enhance patients' well-being. Trigger finger is associated with healthcare costs, including treatments, lost workdays, and rehabilitation. Better management approaches could reduce the economic burden.

Advancements in treatment are fundamental. As our understanding of the condition deepens, more targeted and effective treatment options can be developed, potentially reducing the need for surgery and minimizing recurrence rates. Research should focus on the long-term outcomes of different treatment modalities, including surgery, corticosteroid injections, and conservative therapies, to determine which provides the best-sustained relief.

Understanding the underlying pathophysiological mechanisms of the trigger finger can lead to more precise diagnostic tools and therapeutic targets. Identifying additional risk factors beyond those currently recognized can help with early detection and preventive measures. The efficacy of non-surgical treatments, such as physical therapy, occupational therapy, and ergonomic modifications, needs more extensive study to establish their role in managing the trigger finger.

Studies investigating the long-term outcomes of various treatment approaches, elucidating the precise pathophysiological mechanisms, identifying novel risk factors, and assessing the effectiveness of non-surgical interventions, can provide a more comprehensive understanding of this condition. Clinicians must seek to improve patient care and quality of life by guiding the development of more effective and evidence-based management strategies for trigger finger.

CONCLUSION

Triggering (locking, clicking) and crepitus of the fingers are symptoms that commonly occur. It can co-exist as part of the same pathology, but more often occur separately and point towards different pathologies. Even though trigger fingers are the most common cause of pain and disability in the hand, it is important to consider the other possible diagnoses. A thorough history and clinical examination with appropriate special investigations will aid in making the correct diagnosis. Adequate treatment has a high success rate in terms of resolution of symptoms and good functional recovery.

FOOTNOTES

Author contributions: Jordan PW, Klumpp R, and Zeppieri M contributed equally to this work; All authors have read and approved the final manuscript.

Conflict-of-interest statement: The authors have no conflicts of interest to declare.

Open-Access: This article is an open-access article that was selected by an in-house editor and fully peer-reviewed by external reviewers. It is distributed in accordance with the Creative Commons Attribution NonCommercial (CC BY-NC 4.0) license, which permits others to distribute, remix, adapt, build upon this work non-commercially, and license their derivative works on different terms, provided the original work is properly cited and the use is non-commercial. See: <https://creativecommons.org/licenses/by-nc/4.0/>

Country/Territory of origin: Italy

ORCID number: Pieter W Jordaan 0000-0003-3022-2715; Raymond Klumpp 0000-0002-4824-4384; Marco Zeppieri 0000-0003-0999-5545.

S-Editor: Lin C

L-Editor: Filipodia

P-Editor: Xu ZH

REFERENCES

- Gil JA, Hresko AM, Weiss AC. Current Concepts in the Management of Trigger Finger in Adults. *J Am Acad Orthop Surg* 2020; **28**: e642-e650 [PMID: 32732655 DOI: 10.5435/JAAOS-D-19-00614]
- Merry SP, O'Grady JS, Boswell CL. Trigger Finger? Just Shoot! *J Prim Care Community Health* 2020; **11**: 2150132720943345 [PMID: 32686570 DOI: 10.1177/2150132720943345]
- Vasiliadis AV, Itsiopoulos I. Trigger Finger: An Atraumatic Medical Phenomenon. *J Hand Surg Asian Pac Vol* 2017; **22**: 188-193 [PMID: 28506168 DOI: 10.1142/S021881041750023X]
- Weng W. Symptoms, Diagnosis, and Treatments of Stenosing Tenosynovitis. *Highlights in Science, Engineering and Technology* 2023; **36**: 246-53 [DOI: 10.54097/hset.v36i.5678]
- Wolfe SW, Pederson WC, Kozin SH, Cohen MS. Green's Operative Hand Surgery. 8th ed. Amsterdam: Elsevier, 2021
- Blough C, Najdawi J, Kuschner S. Patient preference for trigger finger treatment. *World J Orthop* 2022; **13**: 1006-1014 [PMID: 36439373 DOI: 10.5312/wjo.v13.i11.1006]
- David M, Rangaraju M, Raine A. Acquired triggering of the fingers and thumb in adults. *BMJ* 2017; **359**: j5285 [PMID: 29191846 DOI: 10.1136/bmj.j5285]
- Lunsford D, Valdes K, Hengy S. Conservative management of trigger finger: A systematic review. *J Hand Ther* 2019; **32**: 212-221 [PMID: 29290504 DOI: 10.1016/j.jht.2017.10.016]
- Rizzo M. Metacarpophalangeal joint arthritis. *J Hand Surg Am* 2011; **36**: 345-353 [PMID: 21276901 DOI: 10.1016/j.jhsa.2010.11.035]
- Kleinhenz BP, Adams BD. Closed Sagittal Band Injury of the Metacarpophalangeal Joint. *J Am Acad Orthop Surg* 2015; **23**: 415-423 [PMID: 26111875 DOI: 10.5435/JAAOS-D-13-00203]
- James N, Farrell N, Mauck B, Calandruccio J. Sagittal Band Injury and Extensor Tendon Realignment. *Orthop Clin North Am* 2022; **53**: 319-325 [PMID: 35725040 DOI: 10.1016/j.oel.2022.02.004]
- Hong IT, Oh CH, Sim YS, Han SH. Direct repair of the sagittal band for extensor tendon subluxation caused by finger flicking. *Orthopade* 2017; **46**: 755-760 [PMID: 28721447 DOI: 10.1007/s00132-017-3450-2]
- Rayan GM, Murray D. Classification and treatment of closed sagittal band injuries. *J Hand Surg Am* 1994; **19**: 590-594 [PMID: 7963312 DOI: 10.1016/0363-5023(94)90261-5]
- VanHelmond TA, Kim MT, Wang ED. Middle Finger Metacarpophalangeal Joint Locked in Flexion Caused by Entrapped Ulnar Collateral Ligament. *J Hand Surg Glob Online* 2022; **4**: 379-381 [PMID: 36425365 DOI: 10.1016/j.jhsg.2022.08.003]
- Thomsen L, Roulot E, Barbato B, Dumontier C. Locked metacarpophalangeal joint of long fingers: classification, definition and treatment based on 15 cases and literature review. *Chir Main* 2011; **30**: 269-275 [PMID: 21530351 DOI: 10.1016/j.main.2011.01.019]
- Cavalcanti KuBmaul A, Ayache A, Unglaub F. [Trigger finger-pitfalls and differential diagnosis]. *Orthopadie (Heidelb)* 2023; **52**: 604-608 [PMID: 37233746 DOI: 10.1007/s00132-023-04390-6]
- Fan XL, Wang WT, Wang J, Xiao R. Current management of avascular necrosis of the metacarpal head: a comprehensive literature review. *Int J Surg* 2023; **109**: 1509-1517 [PMID: 37042565 DOI: 10.1097/JS9.0000000000000377]
- McGoldrick NP, McGoldrick FJ. Avascular necrosis of the metacarpal head: a case of Dietrich's disease and review of the literature. *Am J Case Rep* 2015; **16**: 12-15 [PMID: 25594915 DOI: 10.12659/AJCR.892389]
- Ruettermann M, Hermann RM, Khatib-Chahidi K, Werker PMN. Dupuytren's Disease-Etiology and Treatment. *Dtsch Arztebl Int* 2021; **118**: 781-788 [PMID: 34702442 DOI: 10.3238/arztebl.m2021.0325]
- Wu K, Masschelein G, Suh N. Treatment of Sagittal Band Injuries and Extensor Tendon Subluxation: A Systematic Review. *Hand (N Y)* 2021; **16**: 854-860 [PMID: 31965857 DOI: 10.1177/1558944719895622]
- Molenkamp S, van Straalen RJM, Werker PMN, Broekstra DC. Imaging for Dupuytren disease: a systematic review of the literature. *BMC Musculoskelet Disord* 2019; **20**: 224 [PMID: 31101038 DOI: 10.1186/s12891-019-2606-0]
- Maheu E, Mazières B, Valat JP, Loyau G, Le Loët X, Bourgeois P, Grouin JM, Rozenberg S. Symptomatic efficacy of avocado/soybean unsaponifiables in the treatment of osteoarthritis of the knee and hip: a prospective, randomized, double-blind, placebo-controlled, multicenter clinical trial with a six-month treatment period and a two-month followup demonstrating a persistent effect. *Arthritis Rheum* 1998; **41**: 81-91 [PMID: 9433873 DOI: 10.1002/1529-0131(199801)41:1<81::AID-ART11>3.0.CO;2-9]
- McKee D, Lalonde J, Lalonde D. How Many Trigger Fingers Resolve Spontaneously Without Any Treatment? *Plast Surg (Oakv)* 2018; **26**: 52-54 [PMID: 29619360 DOI: 10.1177/2292550317740691]
- Mardani-Kivi M, Karimi-Mobarakeh M, Babaei Jandaghi A, Keyhani S, Saheb-Ekhtiari K, Hashemi-Motlagh K. Intra-sheath versus extra-sheath ultrasound guided corticosteroid injection for trigger finger: a triple blinded randomized clinical trial. *Phys Sportsmed* 2018; **46**: 93-97 [PMID: 29125382 DOI: 10.1080/00913847.2018.1400897]
- Wimalawansa SM, Alsamkari R. Unusual presentation of hemochromatosis as isolated metacarpophalangeal joint osteoarthritis: a case report. *Hand (N Y)* 2011; **6**: 329-332 [PMID: 22942860 DOI: 10.1007/s11552-011-9335-7]



Case Control Study

Machine learning applications for the prediction of extended length of stay in geriatric hip fracture patients

Chu-Wei Tian, Xiang-Xu Chen, Liu Shi, Huan-Yi Zhu, Guang-Chun Dai, Hui Chen, Yun-Feng Rui

Specialty type: Orthopedics

Provenance and peer review:

Unsolicited article; Externally peer reviewed.

Peer-review model: Single blind

Peer-review report's scientific quality classification

Grade A (Excellent): 0

Grade B (Very good): B, B, B

Grade C (Good): C

Grade D (Fair): 0

Grade E (Poor): 0

P-Reviewer: Lee KS, South Korea;
Mijwil MM, Iraq

Received: July 22, 2023

Peer-review started: July 22, 2023

First decision: September 4, 2023

Revised: September 8, 2023

Accepted: September 28, 2023

Article in press: September 28, 2023

Published online: October 18, 2023



Chu-Wei Tian, Xiang-Xu Chen, Liu Shi, Huan-Yi Zhu, Guang-Chun Dai, Hui Chen, Yun-Feng Rui,
Department of Orthopaedics, Zhongda Hospital, School of Medicine, Southeast University,
Nanjing 210009, Jiangsu Province, China

Chu-Wei Tian, Xiang-Xu Chen, Liu Shi, Huan-Yi Zhu, Guang-Chun Dai, Hui Chen, Yun-Feng Rui,
Multidisciplinary Team for Geriatric Hip Fracture Comprehensive Management, Zhongda
Hospital, School of Medicine, Southeast University, Nanjing 210009, Jiangsu Province, China

Chu-Wei Tian, Xiang-Xu Chen, Liu Shi, Huan-Yi Zhu, Guang-Chun Dai, Hui Chen, Yun-Feng Rui,
Trauma Center, Zhongda Hospital, School of Medicine, Southeast University, Nanjing 210009,
Jiangsu Province, China

Corresponding author: Yun-Feng Rui, MD, PhD, Chief Doctor, Deputy Director, Professor,
Surgeon, Department of Orthopaedics, Zhongda Hospital, School of Medicine, Southeast
University, No. 87 Dingjiaqiao, Nanjing 210009, Jiangsu Province, China.
ruiyunfeng@126.com

Abstract

BACKGROUND

Geriatric hip fractures are one of the most common fractures in elderly individuals, and prolonged hospital stays increase the risk of death and complications. Machine learning (ML) has become prevalent in clinical data processing and predictive models. This study aims to develop ML models for predicting extended length of stay (eLOS) among geriatric patients with hip fractures and to identify the associated risk factors.

AIM

To develop ML models for predicting the eLOS among geriatric patients with hip fractures, identify associated risk factors, and compare the performance of each model.

METHODS

A retrospective study was conducted at a single orthopaedic trauma centre, enrolling all patients who underwent hip fracture surgery between January 2018 and December 2022. The study collected various patient characteristics, encompassing demographic data, general health status, injury-related data, laboratory examinations, surgery-related data, and length of stay. Features that exhibited significant differences in univariate analysis were integrated into the ML model

establishment and subsequently cross-verified. The study compared the performance of the ML models and determined the risk factors for eLOS.

RESULTS

The study included 763 patients, with 380 experiencing eLOS. Among the models, the decision tree, random forest, and extreme Gradient Boosting models demonstrated the most robust performance. Notably, the artificial neural network model also exhibited impressive results. After cross-validation, the support vector machine and logistic regression models demonstrated superior performance. Predictors for eLOS included delayed surgery, D-dimer level, American Society of Anaesthesiologists (ASA) classification, type of surgery, and sex.

CONCLUSION

ML proved to be highly accurate in predicting the eLOS for geriatric patients with hip fractures. The identified key risk factors were delayed surgery, D-dimer level, ASA classification, type of surgery, and sex. This valuable information can aid clinicians in allocating resources more efficiently to meet patient demand effectively.

Key Words: Machine learning; Extended length of stay; Hip fracture; Enhanced recovery after surgery; Risk factors

©The Author(s) 2023. Published by Baishideng Publishing Group Inc. All rights reserved.

Core Tip: Traditional models have been built to identify risk factors for extended length of stay (eLOS), offering new insights for optimizing treatment for hip fracture patients under the enhanced recovery after surgery concept. However, these traditional statistical methods suffer from poor performance and lack of features. Machine learning (ML) is a scientific discipline focused on teaching computers to learn from data, showing superior predictive performance compared to traditional methods. This study aims to develop ML models for predicting eLOS among geriatric patients with hip fractures, identify associated risk factors, and compare the performance of each model.

Citation: Tian CW, Chen XX, Shi L, Zhu HY, Dai GC, Chen H, Rui YF. Machine learning applications for the prediction of extended length of stay in geriatric hip fracture patients. *World J Orthop* 2023; 14(10): 741-754

URL: <https://www.wjgnet.com/2218-5836/full/v14/i10/741.htm>

DOI: <https://dx.doi.org/10.5312/wjo.v14.i10.741>

INTRODUCTION

Hip fractures have become more prevalent as the global geriatric population increases[1]. They are associated with higher incidence, mortality, and disability, significantly impacting the quality of life of affected individuals[2,3]. Prolonged length of stay (LOS) not only places a financial burden on patients but also elevates the risk of mortality and complications[4]. Enhanced recovery after surgery (ERAS) refers to the integration of perioperative concepts using evidence-based medicine tools to reduce surgical stress and complications, shorten hospital stays, lower financial costs, and hasten postoperative recovery[5-7]. Based on this concept, Andrew *et al*[8] developed a logistic regression (LR) model to identify risk factors for extended length of stay (eLOS), offering new insights for optimizing treatment for hip fracture patients. However, traditional statistical methods suffer from poor performance and lack of features.

Machine learning (ML) is a scientific discipline focused on teaching computers to learn from data[9]. In recent times, ML has shown superior predictive performance compared to traditional methods and has found extensive application in clinical data processing and predictive modelling[10,11]. Mijwil and Aggarwal[12] enhanced the ML based estimation method for detecting acute appendicitis in individuals, achieving high accuracy. In the context of hip fractures among geriatric individuals, Oosterhoff *et al*[13] and Shtar *et al*[14] established ML models to predict prognosis and mortality, enhancing clinician decision-making ability. With the establishment of a clinical database for elderly hip fracture patients and advancements in ML algorithms, predicting the eLOS for this patient group through ML has become feasible.

This study aims to develop ML models for predicting the eLOS among geriatric patients with hip fractures, identify associated risk factors, and compare the performance of each model.

MATERIALS AND METHODS

Study design, setting and population

A retrospective study was conducted at a single orthopaedic trauma centre between January 2018 and December 2022. The study employed specific inclusion and exclusion criteria as follows inclusion criteria: (1) Age older than 60 years at the time of injury; (2) confirmed diagnosis of hip fracture; and (3) hospitalization at our centre. The study employed specific inclusion and exclusion criteria as follows exclusion criteria: (1) Admission with multiple fractures, pathological

fractures, or fractures around the prosthesis; (2) receipt of conservative treatment due to severe comorbidities; and (3) presence of missing data.

The enrolled patients had a median hospital stay of 9.5 d. Based on this median LOS, the patients were retrospectively divided into two groups: None LOS (LOS \leq 9.5 d, $n = 383$, 50.2%) and eLOS (LOS $>$ 9.5 d, $n = 380$, 49.8%).

Perioperative treatment and surgical procedure

All patients underwent comprehensive perioperative assessments to ensure standardized diagnosis and treatment. Our centre boasts a multidisciplinary team comprising geriatricians, anaesthetists, and intensive care unit (ICU) doctors who collaborate to review the perioperative care of patients with comorbidities[15]. Upon admission, a rapid preoperative risk assessment is performed, considering the patient's physical condition and specific needs. Subsequently, an individualized treatment plan is promptly devised. For patients requiring surgical intervention, a consistent surgical team oversees all procedures. Patients with femoral neck fractures receive surgical treatments such as total hip arthroplasty (THA), hemiarthroplasty of the hip, or internal fixation. Those with intertrochanteric fractures undergo surgical treatment, such as internal fixation. Throughout the surgery, the patient's temperature, blood volume, and haemodynamics are meticulously managed with the collaborative efforts of anaesthesia and surgical nurses.

Data collection

Data for the study were retrospectively gathered from electronic patient records at the institution. Demographic data encompassed sex, age, body mass index, general health status categorized by the American Society of Anaesthesiologists (ASA) classification, history of smoking, oral anticoagulant use, and comorbidities[16]. Injury-related data included fracture type, time from injury to admission, and the day of admission. Surgery-related data consisted of the type of surgery, anaesthesia used, ICU transfer, time to surgery, duration of surgery, intraoperative blood loss, and transfusion. Laboratory examinations conducted at admission and after surgery were also collected. Age was stratified into 60-85 and $>$ 85 age groups; ASA classification was grouped as I-II and III-IV; admission day was grouped into Monday to Thursday and Friday to Sunday; injury time was stratified into \leq 24 and $>$ 24 h; and delayed surgery was defined as an operation performed more than 48 h after admission. Laboratory examinations were stratified according to normal values.

ML and statistical analysis

In the study, normally distributed data are presented as the means and standard deviations. Nonnormally distributed variables were expressed as medians along with their interquartile ranges. Categorical variables are represented as counts and percentages. To analyse the overall data, continuous variables were subjected to Student's t test or the Mann-Whitney U test, depending on their distribution. Categorical variables were analysed using the chi-square test, as appropriate. Variables showing significant differences in the univariate analysis were selected and included in the establishment of the ML model.

The predictive eLOS ML model was established according to the selected features, including basic algorithms for LR, decision tree (DT), random forest (RF), support vector machine (SVM), naïve Bayes, K-nearest neighbour, eXtreme Gradient Boosting (XGBoost) and artificial neural network (ANN) models. Next, we used a Shapley Additive Interpretation (SHAP) summary plot to determine the relationship between the eLOS and its main predictors in each model. Each ML model was integrated to ascertain feature importance. Then, the original data were split into a training set and a test set (training: test = 7:3), and 10-fold cross-validation was carried out. The accuracy score, precision score, recall score, F1 score, receiver operating characteristic (ROC) curve and area under the ROC curve (AUC) were used to evaluate the performance of the ML model of the original data and cross-validation. All statistical analyses were conducted using Python (version 3.8.2, Python Software Foundation, <https://www.python.org>) and the sklearn package (version 0.24.1). A 2-sided P value $<$ 0.05 was considered significant. The flow diagram of the research process is shown in Figure 1.

RESULTS

Population and patient characteristics

Overall, 763 patients were enrolled in the final analysis; patients were divided into none LOS ($n = 383$) and eLOS ($n = 380$) groups based on LOS. The characteristics of the two groups are compared in Table 1. Univariate analysis showed that there were significant differences in sex, fracture type, ASA classification, admission day, injury to admission time, hypertension, diabetes, cerebral infarction, deep venous thrombosis (DVT), delayed surgery, THA, reduction and fixation, aspartate aminotransferase and D-dimer levels and aortic velocity at admission between the two groups ($P <$ 0.05).

Establishment and evaluation of the ML model in the original data

We used 8 ML models to evaluate the predictors of LOS in the original data. Figure 2 shows the ROC curve, and Table 2 shows the performance indicators of each model. The tree models, including the DT (accuracy = 0.924, AUC = 0.988), RF (accuracy = 0.924, AUC = 0.985) and XGBoost (accuracy = 0.912, AUC = 0.976) models, showed stronger performance among the models. In addition, the performance of the ANN (accuracy = 0.886, AUC = 0.963) model was impressive.

Table 1 Baseline data comparison. Counts (%) unless otherwise specified

Features	Non-eLOS (n = 383)	eLOS (n = 380)	Statistic (t/χ^2)	P value
Sex			5.418	0.020
Male	107 (27.9)	136 (35.8)		
Female	276 (72.1)	244 (64.2)		
Age (yr)			0.096	0.757
60-85	255 (66.6)	257 (67.6)		
> 85	128 (33.4)	123 (32.4)		
BMI (kg/m ²)			2.578	0.461
< 18.5	48 (12.5)	44 (11.6)		
18.5-24.9	220 (57.4)	239 (62.9)		
25.0-29.9	99 (25.8)	82 (21.6)		
> 30.0	16 (4.2)	15 (3.9)		
Fracture type			20.516	P < 0.001
Femoral neck fracture	165 (43.1)	226 (59.5)		
Intertrochanteric fracture	218 (56.9)	154 (40.5)		
ASA classification			20.313	P < 0.001
I-II	197 (51.4)	134 (35.3)		
III-IV	186 (48.6)	246 (64.7)		
Admission time			5.340	0.021
Monday to Thursday	248 (64.8)	215 (56.6)		
Friday to Sunday	135 (35.2)	165 (43.2)		
Time from injury to admission			5.513	0.019
≤ 24 h	322 (84.1)	294 (77.4)		
> 24 h	61 (15.9)	86 (22.6)		
Comorbidities	3.99 2.22	4.19 2.25	1.221	0.223
Hypertension	207 (54.0)	245 (64.5)	8.588	0.003
Diabetes	85 (22.2)	112 (29.5)	5.279	0.022
ACS	59 (15.4)	66 (17.4)	0.537	0.464
Cerebral infarction	120 (31.3)	150 (39.5)	5.531	0.019
AKI	8 (2.1)	17 (4.5)	3.423	0.064
DVT	66 (17.2)	91 (23.9)	5.263	0.022
History of smoking	14 (3.4)	17 (4.5)	0.328	0.567
Oral anticoagulant use	71 (18.5)	71 (18.7)	0.003	0.959
History of fracture	77 (20.1)	83 (21.8)	0.348	0.556
Hip fracture	21 (5.5)	29 (7.6)	1.438	0.230
Lumbar fracture	25 (6.5)	24 (6.3)	0.014	0.905
Delayed surgery	153 (39.9)	267 (70.3)	70.842	P < 0.001
Type of surgery				
THA	52 (13.6)	95 (25.0)	16.002	P < 0.001
HHA	106 (27.7)	127 (33.4)	2.968	0.085
Reduction and fixation	225 (58.7)	158 (41.6)	22.488	P < 0.001
Duration of surgery	96.62 ± 27.83	118.43 ± 24.32	1.743	0.082

Intraoperative blood loss	164.54 ± 85.26	162.33 ± 104.20	-0.321	0.748
Blood transfusion	127 (33.2)	132 (34.7)	0.212	0.645
ICU transfer	103 (26.9)	111 (29.2)	0.508	0.476
Type of anaesthesia			0.769	0.380
General	336 (87.7)	341 (89.7)		
Regional	47 (12.3)	39 (10.3)		
Heart rate at admission (60-100)	339 (88.5)	331 (87.1)	0.353	0.553
Laboratory examination at admission				
RBC (≥ 4.3)	86 (22.5)	87 (22.9)	0.021	0.884
WBC (3.5-9.5)	208 (54.3)	217 (57.1)	0.605	0.437
Hb (≥ 110)	251 (65.5)	268 (70.5)	2.184	0.139
PLT (125-350)	321 (83.8)	306 (80.5)	1.406	0.236
N (40-75)	65 (17.0)	81 (21.3)	2.327	0.127
HCT (≥ 40)	82 (21.4)	65 (17.1)	2.272	0.132
K (3.5-5.1)	260 (67.9)	265 (69.7)	0.305	0.581
Ca (≥ 2.1)	257 (67.1)	260 (68.4)	0.152	0.697
Na (137-145)	248 (64.8)	229 (60.3)	1.640	0.200
ALB (30-40)	233 (60.8)	243 (63.9)	0.787	0.375
ALT (9-50)	347 (90.5)	342 (90.0)	0.079	0.779
AST (15-40)	338 (88.3)	316 (83.2)	4.040	0.044
LDH (120-246)	188 (49.1)	179 (47.1)	3.000	0.584
BUN (3.6-9.5)	304 (79.4)	302 (79.5)	0.001	0.973
Cr (58-110)	205 (53.5)	221 (58.2)	1.660	0.198
PT (9.4-12.5)	77 (20.1)	93 (24.5)	2.103	0.147
APTT (25.1-36.5)	326 (85.1)	331 (87.1)	0.630	0.427
INR (0.8-1.2)	311 (81.2)	304 (80.0)	0.176	0.675
FIB (2.38-4.98)	344 (89.8)	344 (90.5)	0.108	0.742
D-dimer (≤ 6500)	218 (56.9)	165 (43.4)	13.902	<i>P</i> < 0.001
Cardiac colour ultrasound at admission				
AV (≥ 1.0)	367 (95.8)	347 (91.3)	6.446	0.011
EF (≥ 70)	208 (54.3)	217 (57.1)	0.605	0.437
Laboratory examination after surgery				
Hb (≥ 110)	87 (22.7)	92 (24.2)	0.237	0.626
ALB (30-40)	310 (80.9)	303 (79.7)	0.175	0.676
Cr (58-110)	222 (58.0)	232 (61.1)	0.755	0.385

BMI: Body mass index; ASA: American society of anaesthesiologists; ACS: Acute coronary syndromes; AKI: Acute kidney injury; DVT: Deep venous thrombosis; THA: Total hip arthroplasty; HHA: Hip hemiarthroplasty; ICU: Intensive care unit; RBC: Red blood cell; WBC: White blood cell; Hb: Hemoglobin; PLT: Platelets; N: Neutrophil granulocyte; HCT: Hematocrit; K: Kalium; Ca: Calcium; Na: Natrium; ALB: Albumin; ALT: Alanine aminotransferase; AST: Aspartate aminotransferase; LDH: Lactate dehydrogenase; BUN: Blood urea nitrogen; Cr: Creatinine; PT: Prothrombin time; APTT: Activated partial thromboplastin time; INR: International normalized ratio; FIB: Fibrinogen; AV: Aortic velocity; EF: Ejection fraction.

Table 2 Evaluation of machine learning models in the original data

Model name	Accuracy	Precision	Recall	F1 score	AUC
LR	0.680	0.680	0.676	0.678	0.747
DT	0.924	0.994	0.853	0.918	0.988
RF	0.924	0.940	0.905	0.922	0.985
SVM	0.651	0.636	0.703	0.667	0.739
NB	0.657	0.676	0.598	0.634	0.709
KNN	0.747	0.748	0.742	0.745	0.828
XGB	0.912	0.941	0.879	0.901	0.976
ANN	0.886	0.899	0.868	0.883	0.963

AUC: Area under curve; LR: Logistic regression; DT: Decision tree; RF: Random forest; SVM: Support vector machine; NB: Naïve bayes; KNN: K-nearest Neighbour; XGB: eXtreme Gradient Boosting; ANN: Artificial neural network.

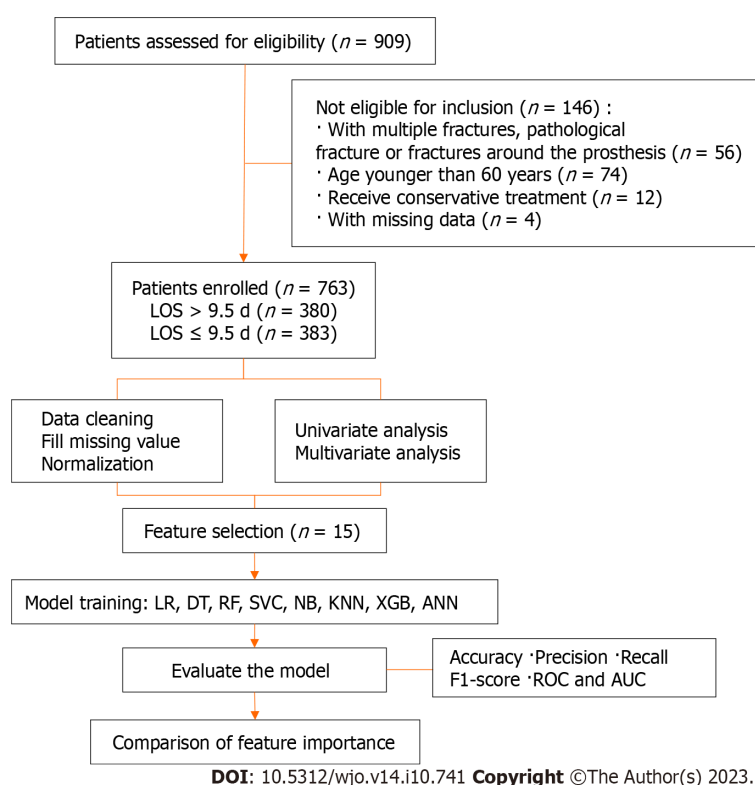


Figure 1 The flow diagram of the research process. LOS: Length of stay; LR: Logistic regression; DT: Decision tree; RF: Random forest; SVC: Support vector classifier; NB: Naïve bayes; KNN: K-nearest neighbour; XGB: eXtreme Gradient Boosting; ANN: Artificial neural network; ROC: Receiver operating characteristic; AUC: area under the receiver operating characteristic curve.

Feature importance

Figure 3 shows the results of the SHAP analysis. We can intuitively understand the importance of features in each model and the direction of their association with the eLOS. Then, we summarized the importance of the features output by each model. Figure 4 shows the feature weights in descending order; delayed surgery was the most important feature in eLOS prediction. The other most important features that influenced the prediction of the eLOS were D-dimer level, ASA classification, type of surgery and sex.

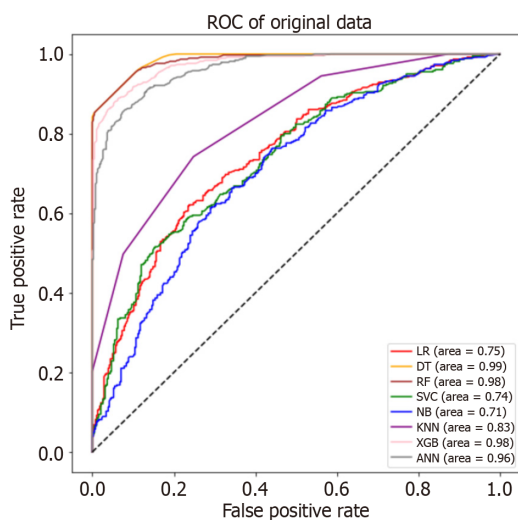
Evaluation of ML models after 10-fold cross-validation

We split the original data into training and test sets (training: test = 7:3) and carried out 10-fold cross-validation. Figure 5 shows the ROC curve, and Table 3 indicates the performance indicators of each model after cross-validation. We found that the performance of the model decreased after cross-validation compared to the original data. The best results were found by using the SVM (accuracy = 0.664, AUC = 0.712) model. Furthermore, the LR (accuracy = 0.650, AUC = 0.650)

Table 3 Evaluation of machine learning models after 10-fold cross-validation

Model name	Accuracy	Precision	Recall	F1 score	AUC
LR	0.650	0.643	0.668	0.655	0.650
DT	0.606	0.616	0.552	0.583	0.605
RF	0.619	0.618	0.613	0.616	0.619
SVM	0.664	0.656	0.659	0.658	0.712
NB	0.644	0.657	0.595	0.624	0.643
KNN	0.617	0.611	0.639	0.625	0.617
XGB	0.630	0.632	0.616	0.624	0.630
ANN	0.606	0.596	0.645	0.619	0.606

AUC: Area under curve; LR: Logistic regression; DT: Decision tree; RF: Random forest; SVM: Support vector machine; NB: Naïve bayes; KNN: K-nearest Neighbour; XGB: eXtreme Gradient Boosting; ANN: Artificial neural network.



DOI: 10.5312/wjo.v14.i10.741 Copyright ©The Author(s) 2023.

Figure 2 Receiver operating characteristic curve for machine learning models in the original data. ROC: Receiver operating characteristic; LR: Logistic regression; DT: Decision tree; RF: Random forest; SVC: Support vector classifier; NB: Naïve Bayes; KNN: K-nearest Neighbour; XGB: eXtreme Gradient Boosting; ANN: Artificial neural network.

model showed good performance after cross-validation.

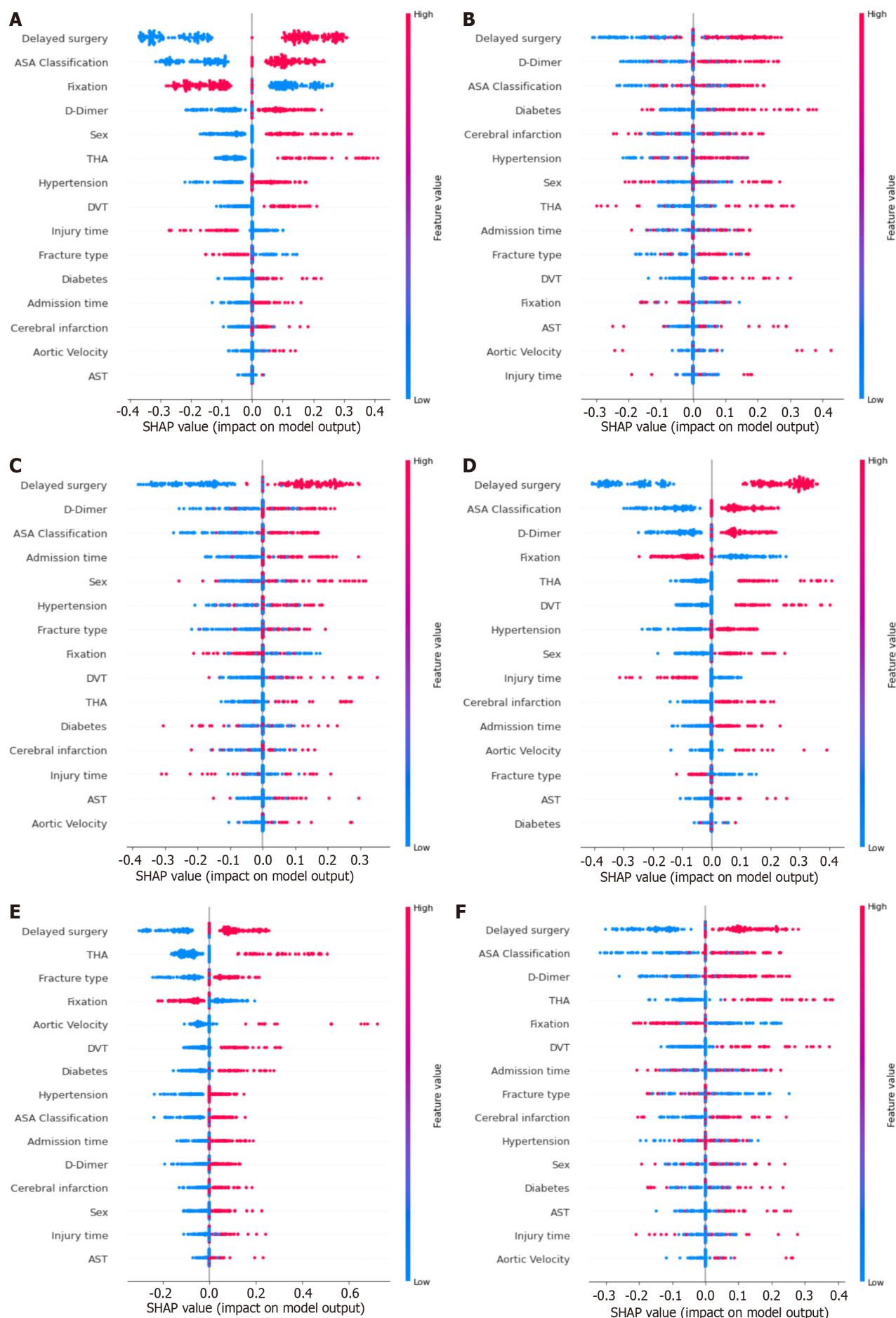
DISCUSSION

This study aimed to develop ML models for predicting eLOS in geriatric patients with hip fractures and to identify associated risk factors. Additionally, we assessed and compared the performance of each ML model. The DT and ANN models demonstrated the best performance with the original data. After cross-validation, the SVM and LR models also performed well.

Risk factors for eLOS among geriatric hip fracture patients

Although methods such as multidisciplinary management and ERAS have been shown to decrease LOS and lower inpatient hospitalization costs, geriatric hip fracture patients continue to be disproportionately large resource consumers [8,17,18]. Long-term LOS not only results in inefficient use of medical resources but also increases the risk of complications among hip fracture patients [19]. In addition, the length of hospital stay varies greatly among healthcare systems [17,18,20]. The identification of risk factors associated with the eLOS may be helpful in cost forecasting and patient management [21]. In our study, we used the median LOS to group the data.

In previous studies, delayed surgery was considered the key factor that affected LOS. A retrospective study by Pincus *et al* [22] showed that patients who underwent surgery 1 day after admission had a longer postoperative stay. Hecht *et al* [23] developed a predictive model for LOS that showed that the prevention of reduced time to surgery was a significant



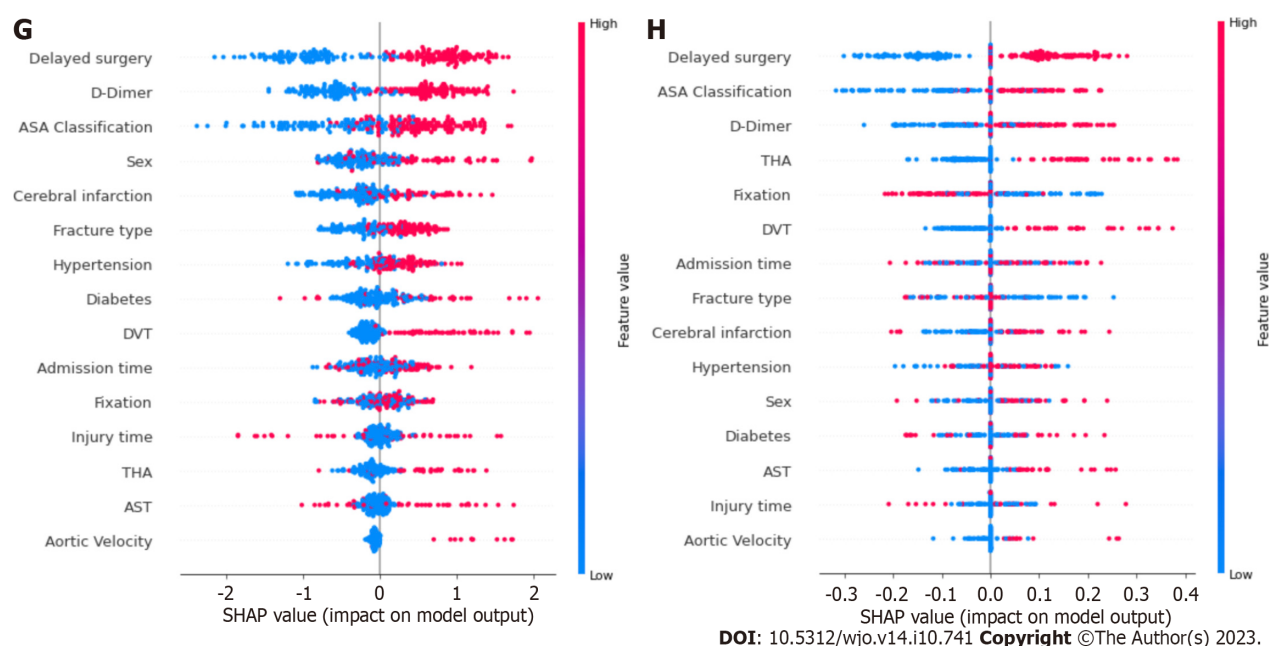


Figure 3 Shapley additive explanations summary plots of each model. A: Logistic regression; B: Decision tree; C: Random forest; D: Support vector classifier; E: Naïve bayes; F: K-nearest neighbour; G: eXtreme Gradient Boosting; H: Artificial neural network. ASA: American society of anaesthesiologists; THA: Total hip arthroplasty; DVT: Deep venous thrombosis; AST: Aspartate aminotransferase.

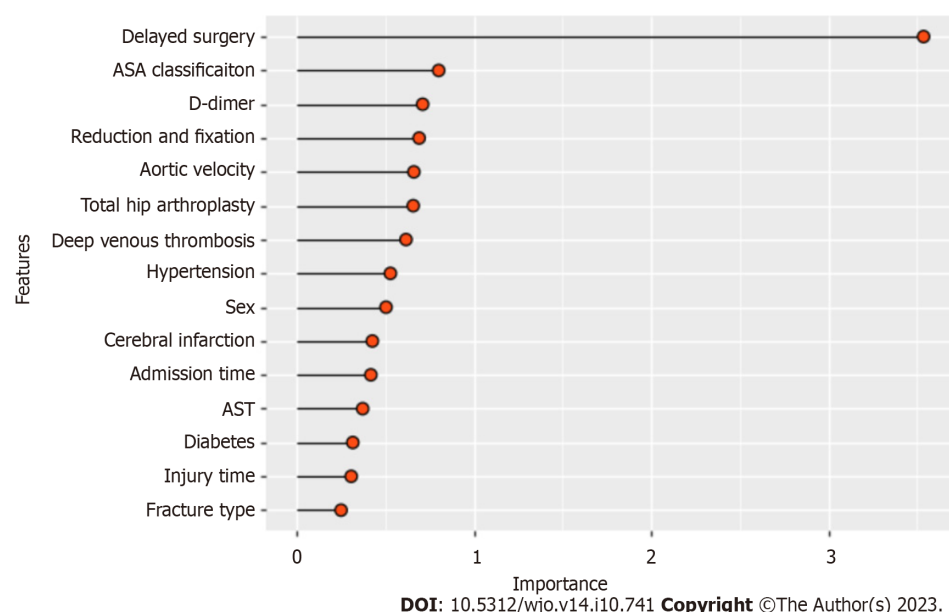


Figure 4 Comprehensive importance of features. ASA: American society of anaesthesiologists; AST: Aspartate aminotransferase.

predictor of reduced LOS. In addition, the authors suggested that ASA classification was a stronger predictor of LOS than the Charlson comorbidity index. Similar findings were shown by Kristan *et al*[24], who found that the eLOS was associated with delayed surgery, ASA classification, anticoagulant therapy and surgery type. Furthermore, a higher D-dimer level, as a possible predictor of DVT, suggested that patients were at higher risk of thrombosis, which was also the cause of eLOS[25]. Our study achieved similar results to those described above. This result suggests that clinicians and multidisciplinary teams should continue to explore possible interventions to shorten LOS among hip fracture patients.

At the same time, our model identified male sex and fracture type as predictors of the eLOS. This is consistent with findings from the study by Garcia *et al*[26]. The results of their study showed that while the majority of hip fracture patients were female, male patients appeared to have a longer hospital stay. A meta-analysis by Haentjens *et al*[27] showed that male hip fracture patients had a higher risk of death, which appeared to be associated with more severe osteoporosis and a higher comorbidity burden among male patients with hip fractures[28]. In addition, patients with joint replacement surgery had higher functional requirements, which was why such patients took longer to stay and recover [29,30]. However, some studies mentioned the influence of age and comorbidities on the eLOS, but these factors were not

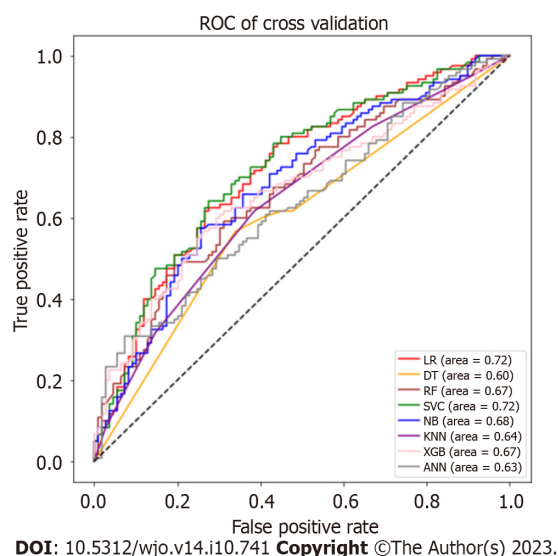


Figure 5 Receiver operating characteristic curve for machine learning models after cross-validation. ROC: Receiver operating characteristic; LR: Logistic regression; DT: Decision tree; RF: Random forest; SVC: Support vector classifier; NB: Naïve bayes; KNN: K-nearest Neighbour; XGB: eXtreme Gradient Boosting; ANN: Artificial neural network.

identified by our model[24,27,30]. This might be due to changes in the management of hip fracture patients and the popularity of ERAS, which have allowed an increasing number of older patients with comorbidities to receive timely surgical treatment and rehabilitation guidance.

Predictive performance of ML models for eLOS

With the development of science and technology, ML is also being used in the field of medicine to improve patient outcomes and diagnostic accuracy[31]. Recently, ML has been widely used in the diagnosis, classification, identification and prognosis of hip fracture patients[32-34]. Promising results were obtained by Forssten *et al*[35], who used ML to predict 1-year mortality after hip fracture surgery, and by Galassi *et al*[36], who used ML to assess hip fracture risk. With the establishment of clinical databases, ML models will have better practical value in the future.

Most of the previous studies on the construction of prediction models were based on regression algorithms[9]. For binary clinical decision data, the tree model has a natural advantage[37]. The RF algorithm and the XGBoost integration algorithm also show similar results[38]. Based on gradient-boosted DTs, the XGBoost algorithm applied a second-order Taylor expansion to calculate the loss function and performed well in both computational speed and predictive precision [39]. Previous studies have also demonstrated this point. Hou *et al*[40] used XGBoost to predict 30-d mortality for the medical information mart for intensive care III patients with sepsis-3 and obtained high accuracy. Noh *et al*[41] similarly achieved good accuracy in identifying the optimal features of gait parameters to predict fall risk among older adults by XGBoost. In the original data set of our research, the performance of the tree model was far superior to that of other models, which might be the result of overfitting. Through cross-verification, we found that the performance evaluation index of the tree model declined the most. With the continuous expansion of the sample size, the performance of the tree model would also be improved. However, the performance of the traditional binary classification algorithm was stable. In our study, the SVM and LR models had the best performance after cross-validation.

Recently, ANNs have become a new hotspot in ML development. An ANN is a kind of ML algorithm inspired by biological neural networks[10]. Figure 6 shows the computational flow of the ANN in our study (hidden layer size = 15, 10, 10). The ANN contains nodes that communicate with other nodes *via* connections. Chen *et al*[42] showed that the ANN was more accurate than Cox regression in predicting mortality after hip fracture surgery. Using an ANN model can enable more appropriate and accurate processing of inputs that are incomplete or inputs that introduce noise[43,44]. Moreover, the results of Klemm *et al*[45] demonstrated its good application in binary data. In our research, the ANN model showed performance second only to that of the tree model in terms of original data and had considerable accuracy after cross-verification.

Strengths and limitations

This study conducted a novel experiment to develop and compare ML models for predicting eLOS among patients with hip fractures. Subsequently, risk factors for the eLOS were identified. The findings revealed that ML models outperformed traditional statistical methods in terms of accuracy. This provides clinicians with a valuable tool to efficiently identify populations at high risk of eLOS. By doing so, the diagnosis and treatment process can be optimized to reduce the LOS and allocate medical resources effectively, aligning with the ERAS concept.

However, there are several limitations to consider in our study. First, it was a single-centre study, and the length of hospital stay might vary significantly across different healthcare systems. Moreover, the high proportion of patients with ASA III-IV in our hospital indicates a higher prevalence of severe comorbidities and advanced disease compared to those treated in the community, leading to potential selection bias. Second, since this study aimed to establish ML models, the

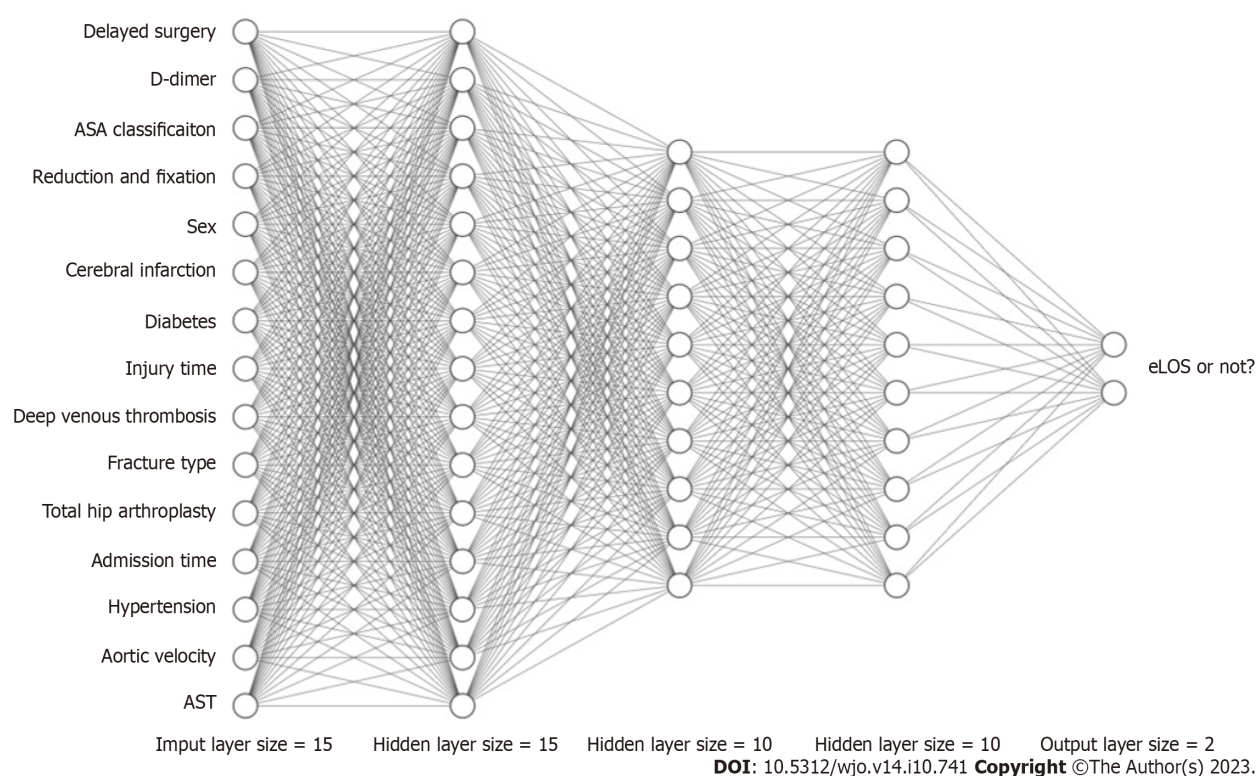


Figure 6 Schematic diagram of an artificial neural network. ASA: American society of anaesthesiologists; eLOS: Extended length of stay; AST: Aspartate aminotransferase.

sample size might be relatively small, resulting in some ML models being prone to overfitting. As a result, the findings of this study should be further validated and made applicable to a broader population through multicentre and large-sample studies.

CONCLUSION

In conclusion, we have effectively developed a highly accurate ML model for eLOS prediction in hip fracture patients. Notably, delayed surgery, elevated D-dimer levels, ASA classification, surgical type, and sex were significantly associated with the eLOS. By applying ML in clinical practice, we can optimize the diagnosis and treatment of elderly hip fracture patients, guide clinicians in decision-making, and allocate medical resources more efficiently.

ARTICLE HIGHLIGHTS

Research background

Geriatric hip fractures are a frequent occurrence and can lead to increased risks of complications and mortality during prolonged hospital stays. This study focuses on utilizing machine learning (ML) to create predictive models aimed at forecasting extended length of stay (eLOS) in elderly patients with hip fractures.

Research motivation

This research endeavor seeks to construct ML models to forecast eLOS in geriatric patients afflicted with hip fractures. Additionally, the study aims to discern the pertinent risk factors contributing to eLOS and conduct a comparative assessment of the performance of each developed model.

Research objectives

This research endeavors to construct ML models for the purpose of forecasting eLOS in geriatric patients who have suffered hip fractures. Furthermore, it seeks to discern the pertinent risk factors associated with this outcome and conduct a comparative analysis of the model performances. We have successfully formulated a highly precise ML model for the prediction of eLOS in patients with hip fractures. Significantly, factors such as delayed surgical intervention, elevated D-dimer levels, American Society of Anaesthesiologists (ASA) classification, surgical procedure type, and gender exhibited notable associations with eLOS. The integration of ML into clinical settings holds the potential to enhance the diagnostic

and therapeutic processes for elderly hip fracture patients, assist clinicians in informed decision-making, and optimize the allocation of healthcare resources.

Research methods

A retrospective investigation was carried out at a sole orthopaedic trauma center, encompassing all individuals who underwent surgery for hip fractures from January 2018 to December 2022. This study compiled a comprehensive array of patient characteristics, encompassing demographics, general health status, injury-related information, laboratory results, surgical data, and length of hospital stay. Features that demonstrated significant distinctions in univariate analysis were incorporated into the development of ML models, which were subsequently subjected to cross-validation. The research then undertook a comparative assessment of the ML models' performance and identified the risk factors associated with eLOS.

Research results

Incorporating a cohort of 763 patients, of which 380 experienced eLOS, the study evaluated the predictive performance of various ML models, with decision tree random forest, and eXtreme Gradient Boosting models emerging as the most robust. Additionally, the artificial neural network model demonstrated commendable results. Following cross-validation, the support vector machine and logistic regression models displayed superior predictive capabilities. Key predictors for eLOS encompassed delayed surgery, D-dimer levels, ASA classification, type of surgery, and gender.

Research conclusions

The application of ML yielded exceptional accuracy in forecasting eLOS among geriatric hip fracture patients. Notably, the study identified significant risk factors, including delayed surgery, D-dimer levels, ASA classification, surgical procedure type, and gender. This valuable insight has the potential to assist clinicians in optimizing resource allocation to meet patient demands more effectively.

Research perspectives

Future research in ML applications for predicting eLOS in geriatric hip fracture patients will likely focus on refining models, integrating them into clinical practice, ensuring interpretability, and addressing ethical and practical considerations to enhance the utility and impact of these predictive tools in healthcare.

ACKNOWLEDGEMENTS

The authors wish to express their gratitude to Dr. Rui for the proofreading of this manuscript.

FOOTNOTES

Author contributions: Tian CW and Chen XX contributed equally to this work; Tian CW and Chen XX designed this study and wrote the manuscript; Zhu HY performed the experiments and analyzed the data; Tian CW and Zhu HY collected the clinical data; Shi L, Dai GC and Chen H provided technical support; Rui YF provided the idea and revised and proofread the paper; All the authors have read and approved the final manuscript.

Supported by Winfast Charity Foundation for Financial Support, No. YL20220525.

Institutional review board statement: This study was reviewed and approved by the Ethics Committee of the Zhongda Hospital, Affiliated to Southeast University (2022ZDSYLL183-P01).

Informed consent statement: All study participants or their legal guardian provided informed written consent about personal and medical data collection prior to study enrolment.

Conflict-of-interest statement: The authors declare no competing financial interests or conflicts of interest that could have influenced the design, data collection, analysis, interpretation, or publication of this study.

Data sharing statement: Requests for data access should be directed to the corresponding author at ruiyunfeng@126.com.

Open-Access: This article is an open-access article that was selected by an in-house editor and fully peer-reviewed by external reviewers. It is distributed in accordance with the Creative Commons Attribution NonCommercial (CC BY-NC 4.0) license, which permits others to distribute, remix, adapt, build upon this work non-commercially, and license their derivative works on different terms, provided the original work is properly cited and the use is non-commercial. See: <https://creativecommons.org/licenses/by-nc/4.0/>

Country/Territory of origin: China

ORCID number: Yun-Feng Rui 0000-0001-9019-5531.

S-Editor: Qu XL

L-Editor: A

P-Editor: Zhao S

REFERENCES

- Veronese N, Maggi S. Epidemiology and social costs of hip fracture. *Injury* 2018; **49**: 1458-1460 [PMID: 29699731 DOI: 10.1016/j.injury.2018.04.015]
- Aasvang EK, Luna IE, Kehlet H. Challenges in postdischarge function and recovery: the case of fast-track hip and knee arthroplasty. *Br J Anaesth* 2015; **115**: 861-866 [PMID: 26209853 DOI: 10.1093/bja/aeu257]
- Soffin EM, YaDeau JT. Enhanced recovery after surgery for primary hip and knee arthroplasty: a review of the evidence. *Br J Anaesth* 2016; **117**: iii62-iii72 [PMID: 27940457 DOI: 10.1093/bja/aew362]
- Rosman M, Rachminov O, Segal O, Segal G. Prolonged patients' In-Hospital Waiting Period after discharge eligibility is associated with increased risk of infection, morbidity and mortality: a retrospective cohort analysis. *BMC Health Serv Res* 2015; **15**: 246 [PMID: 26108373 DOI: 10.1186/s12913-015-0929-6]
- Paton F, Chambers D, Wilson P, Eastwood A, Craig D, Fox D, Jayne D, McGinnes E. Effectiveness and implementation of enhanced recovery after surgery programmes: a rapid evidence synthesis. *BMJ Open* 2014; **4**: e005015 [PMID: 25052168 DOI: 10.1136/bmjopen-2014-005015]
- Slim K. Fast-track surgery: the next revolution in surgical care following laparoscopy. *Colorectal Dis* 2011; **13**: 478-480 [PMID: 21435146 DOI: 10.1111/j.1463-1318.2011.02589.x]
- Xie T, Ma B, Li Y, Zou J, Qiu X, Chen H, Wang C, Rui Y. [Research status of the enhanced recovery after surgery in the geriatric hip fractures]. *Zhongguo Xiu Fu Chong Jian Wai Ke Za Zhi* 2018; **32**: 1038-1046 [PMID: 30238732 DOI: 10.7507/1002-1892.201712083]
- Schneider AM, Denyer S, Brown NM. Risk Factors Associated With Extended Length of Hospital Stay After Geriatric Hip Fracture. *J Am Acad Orthop Surg Glob Res Rev* 2021; **5**: e21.00073 [PMID: 33945514 DOI: 10.5435/JAAOSGlobal-D-21-00073]
- Deo RC. Machine Learning in Medicine. *Circulation* 2015; **132**: 1920-1930 [DOI: 10.1161/CIRCULATIONAHA.115.001593]
- De Silva T, Hess K, Grisso P, Thavikulwat AT, Wiley H, Keenan TDL, Chew EY, Jeffrey BG, Cukras CA. Deep Learning-Based Modeling of the Dark Adaptation Curve for Robust Parameter Estimation. *Transl Vis Sci Technol* 2022; **11**: 40 [PMID: 36315120 DOI: 10.1167/tvst.11.10.40]
- Karan Aggarwal, Maad M. Mijwil, Sonia, Abdel-Hameed Al-Mistarehi, Safwan Alomari, Murat Gök, Anas M. Zein Alaabdin, Safaa H. Abdulrhman. Has the Future Started? The Current Growth of Artificial Intelligence, Machine Learning, and Deep Learning. *Iraqi Journal for Computer Science and Mathematics* 2022; **115**-123 [DOI: 10.52866/ijcsm.2022.01.01.013]
- Mijwil MM, Aggarwal K. A diagnostic testing for people with appendicitis using machine learning techniques. *Multimed Tools Appl* 2022; **81**: 7011-7023 [PMID: 35095329 DOI: 10.1007/s11042-022-11939-8]
- Oosterhoff JHF, Savelberg ABMC, Karhade AV, Gravesteyn BY, Doornberg JN, Schwab JH, Heng M. Development and internal validation of a clinical prediction model using machine learning algorithms for 90 day and 2 year mortality in femoral neck fracture patients aged 65 years or above. *Eur J Trauma Emerg Surg* 2022; **48**: 4669-4682 [PMID: 35643788 DOI: 10.1007/s00068-022-01981-4]
- Shtar G, Rokach L, Shapira B, Nissan R, Hershkovitz A. Using Machine Learning to Predict Rehabilitation Outcomes in Postacute Hip Fracture Patients. *Arch Phys Med Rehabil* 2021; **102**: 386-394 [PMID: 32949551 DOI: 10.1016/j.apmr.2020.08.011]
- Rui Y, Qiu X, Zou J, Xie T, Ma B, Lu P, Li Y, Liu S, Jin J, Deng C, Cui Y, Wang X, Ma M, Ren L, Yang Y, Wang C, Chen H. [Clinical application of multidisciplinary team co-management in geriatric hip fractures]. *Zhongguo Xiu Fu Chong Jian Wai Ke Za Zhi* 2019; **33**: 1276-1282 [PMID: 31544439 DOI: 10.7507/1002-1892.201905017]
- Poitrass S, Au K, Wood K, Dervin G, Beaulé PE. Predicting hospital length of stay and short-term function after hip or knee arthroplasty: are both performance and comorbidity measures useful? *Int Orthop* 2018; **42**: 2295-2300 [PMID: 29453585 DOI: 10.1007/s00264-018-3833-y]
- Konda SR, Johnson JR, Kelly EA, Chan J, Lyon T, Egol KA. Can We Accurately Predict Which Geriatric and Middle-Aged Hip Fracture Patients Will Experience a Delay to Surgery? *Geriatr Orthop Surg Rehabil* 2020; **11**: 2151459320946021 [PMID: 32821470 DOI: 10.1177/2151459320946021]
- Lott A, Haglin J, Belayneh R, Konda SR, Egol KA. Admitting Service Affects Cost and Length of Stay of Hip Fracture Patients. *Geriatr Orthop Surg Rehabil* 2018; **9**: 2151459318808845 [PMID: 30479850 DOI: 10.1177/2151459318808845]
- Mathew PJ, Jehan F, Kulvatunyou N, Khan M, O'Keeffe T, Tang A, Gries L, Hamidi M, Zakaria ER, Joseph B. The burden of excess length of stay in trauma patients. *Am J Surg* 2018; **216**: 881-885 [PMID: 30082028 DOI: 10.1016/j.amjsurg.2018.07.044]
- Diaz-Ledezma C, Mardones R. Predicting Prolonged Hospital Stays in Elderly Patients With Hip Fractures Managed During the COVID-19 Pandemic in Chile: An Artificial Neural Networks Study. *HSS J* 2023; **19**: 205-209 [PMID: 37051613 DOI: 10.1177/15563316221120582]
- Gabriel RA, Sharma BS, Doan CN, Jiang X, Schmidt UH, Vaida F. A Predictive Model for Determining Patients Not Requiring Prolonged Hospital Length of Stay After Elective Primary Total Hip Arthroplasty. *Anesth Analg* 2019; **129**: 43-50 [PMID: 30234533 DOI: 10.1213/ANE.00000000000003798]
- Pincus D, Wasserstein D, Ravi B, Huang A, Paterson JM, Jenkinson RJ, Kreder HJ, Nathens AB, Wodchis WP. Medical Costs of Delayed Hip Fracture Surgery. *J Bone Joint Surg Am* 2018; **100**: 1387-1396 [PMID: 30106820 DOI: 10.2106/JBJS.17.01147]
- Hecht G, Slee CA, Goodell PB, Taylor SL, Wolinsky PR. Predictive Modeling for Geriatric Hip Fracture Patients: Early Surgery and Delirium Have the Largest Influence on Length of Stay. *J Am Acad Orthop Surg* 2019; **27**: e293-e300 [PMID: 30358636 DOI: 10.5435/JAAOS-D-17-00447]
- Kristan A, Omahen S, Tosounidis TH, Cimerman M. When does hip fracture surgery delay affects the length of hospital stay? *Eur J Trauma Emerg Surg* 2022; **48**: 701-708 [PMID: 33388817 DOI: 10.1007/s00068-020-01565-0]
- Niikura T, Sakai Y, Lee SY, Iwakura T, Nishida K, Kuroda R, Kurosaka M. D-dimer levels to screen for venous thromboembolism in patients with fractures caused by high-energy injuries. *J Orthop Sci* 2015; **20**: 682-688 [PMID: 25797331 DOI: 10.1007/s00776-015-0711-y]
- Garcia AE, Bonnaig JV, Yoneda ZT, Richards JE, Ehrenfeld JM, Obremskey WT, Jahangir AA, Sethi MK. Patient variables which may predict length of stay and hospital costs in elderly patients with hip fracture. *J Orthop Trauma* 2012; **26**: 620-623 [PMID: 22832431 DOI: 10.1097/BOT.0b013e3182695416]

- 27 **Haentjens P**, Magaziner J, Colón-Emeric CS, Vanderschueren D, Milisen K, Velkeniers B, Boonen S. Meta-analysis: excess mortality after hip fracture among older women and men. *Ann Intern Med* 2010; **152**: 380-390 [PMID: [20231569](#) DOI: [10.7326/0003-4819-152-6-201003160-00008](#)]
- 28 **Hawkes WG**, Wehren L, Orwig D, Hebel JR, Magaziner J. Gender differences in functioning after hip fracture. *J Gerontol A Biol Sci Med Sci* 2006; **61**: 495-499 [PMID: [16720747](#) DOI: [10.1093/gerona/61.5.495](#)]
- 29 **Castelli A**, Daidone S, Jacobs R, Kasteridis P, Street AD. The Determinants of Costs and Length of Stay for Hip Fracture Patients. *PLoS One* 2015; **10**: e0133545 [PMID: [26204450](#) DOI: [10.1371/journal.pone.0133545](#)]
- 30 **Lefavre KA**, Macadam SA, Davidson DJ, Gandhi R, Chan H, Broekhuysen HM. Length of stay, mortality, morbidity and delay to surgery in hip fractures. *J Bone Joint Surg Br* 2009; **91**: 922-927 [PMID: [19567858](#) DOI: [10.1302/0301-620X.91B7.22446](#)]
- 31 **Obermeyer Z**, Emanuel EJ. Predicting the Future - Big Data, Machine Learning, and Clinical Medicine. *N Engl J Med* 2016; **375**: 1216-1219 [PMID: [27682033](#) DOI: [10.1056/NEJMp1606181](#)]
- 32 **Cha Y**, Kim JT, Park CH, Kim JW, Lee SY, Yoo JI. Artificial intelligence and machine learning on diagnosis and classification of hip fracture: systematic review. *J Orthop Surg Res* 2022; **17**: 520 [PMID: [36456982](#) DOI: [10.1186/s13018-022-03408-7](#)]
- 33 **Kang YJ**, Yoo JI, Cha YH, Park CH, Kim JT. Machine learning-based identification of hip arthroplasty designs. *J Orthop Translat* 2020; **21**: 13-17 [PMID: [32071870](#) DOI: [10.1016/j.jot.2019.11.004](#)]
- 34 **Lalehzarian SP**, Gowd AK, Liu JN. Machine learning in orthopaedic surgery. *World J Orthop* 2021; **12**: 685-699 [PMID: [34631452](#) DOI: [10.5312/wjo.v12.i9.685](#)]
- 35 **Forssten MP**, Bass GA, Ismail AM, Mohseni S, Cao Y. Predicting 1-Year Mortality after Hip Fracture Surgery: An Evaluation of Multiple Machine Learning Approaches. *J Pers Med* 2021; **11** [PMID: [34442370](#) DOI: [10.3390/jpm11080727](#)]
- 36 **Galassi A**, Martín-Guerrero JD, Villamor E, Monserrat C, Rupérez MJ. Risk Assessment of Hip Fracture Based on Machine Learning. *Appl Bionics Biomech* 2020; **2020**: 8880786 [PMID: [33425008](#) DOI: [10.1155/2020/8880786](#)]
- 37 **Luo X**, Wen X, Zhou M, Abusorrah A, Huang L. Decision-Tree-Initialized Dendritic Neuron Model for Fast and Accurate Data Classification. *IEEE Trans Neural Netw Learn Syst* 2022; **33**: 4173-4183 [PMID: [33729951](#) DOI: [10.1109/TNNLS.2021.3055991](#)]
- 38 **Wang R**, Zhang J, Shan B, He M, Xu J. XGBoost Machine Learning Algorithm for Prediction of Outcome in Aneurysmal Subarachnoid Hemorrhage. *Neuropsychiatr Dis Treat* 2022; **18**: 659-667 [PMID: [35378822](#) DOI: [10.2147/NDT.S349956](#)]
- 39 **Chen T**, G Carlos. XGBoost: A Scalable Tree Boosting System. *Proceedings of the 22nd ACM SIGKDD International Conference on Knowledge Discovery and Data Mining* 2016 [DOI: [10.1145/2939672.2939785](#)]
- 40 **Hou N**, Li M, He L, Xie B, Wang L, Zhang R, Yu Y, Sun X, Pan Z, Wang K. Predicting 30-days mortality for MIMIC-III patients with sepsis-3: a machine learning approach using XGboost. *J Transl Med* 2020; **18**: 462 [PMID: [33287854](#) DOI: [10.1186/s12967-020-02620-5](#)]
- 41 **Noh B**, Youm C, Goh E, Lee M, Park H, Jeon H, Kim OY. XGBoost based machine learning approach to predict the risk of fall in older adults using gait outcomes. *Sci Rep* 2021; **11**: 12183 [PMID: [34108595](#) DOI: [10.1038/s41598-021-91797-w](#)]
- 42 **Chen CY**, Chen YF, Chen HY, Hung CT, Shi HY. Artificial Neural Network and Cox Regression Models for Predicting Mortality after Hip Fracture Surgery: A Population-Based Comparison. *Medicina (Kaunas)* 2020; **56** [PMID: [32438724](#) DOI: [10.3390/medicina56050243](#)]
- 43 **Tzzy-Chyang Lu**, Gwo-Ruey Yu, Jyh-Ching Juang. Quantum-based algorithm for optimizing artificial neural networks. *IEEE Trans Neural Netw Learn Syst* 2013; **24**: 1266-1278 [PMID: [24808566](#) DOI: [10.1109/TNNLS.2013.2249089](#)]
- 44 **Lapuerta P**, Azen SP, LaBree L. Use of neural networks in predicting the risk of coronary artery disease. *Comput Biomed Res* 1995; **28**: 38-52 [PMID: [7614823](#) DOI: [10.1006/cbmr.1995.1004](#)]
- 45 **Klemm C**, Yeo I, Cohen-Levy WB, Melnic CM, Habibi Y, Kwon YM. Artificial Neural Networks Can Predict Early Failure of Cementless Total Hip Arthroplasty in Patients With Osteoporosis. *J Am Acad Orthop Surg* 2022; **30**: 467-475 [PMID: [35202042](#) DOI: [10.5435/JAAOS-D-21-00775](#)]



Observational Study

Catania flatfoot score: A diagnostic-therapeutic evaluation tool in children

Andrea Vescio, Gianluca Testa, Alessia Caldaci, Marco Sapienza, Vito Pavone

Specialty type: Orthopedics

Provenance and peer review:

Unsolicited article; Externally peer reviewed.

Peer-review model: Single blind

Peer-review report's scientific quality classification

Grade A (Excellent): 0

Grade B (Very good): 0

Grade C (Good): C, C

Grade D (Fair): 0

Grade E (Poor): 0

P-Reviewer: Jankowicz-Szymanska A, Poland; Vimal AK, India

Received: January 3, 2023

Peer-review started: January 3, 2023

First decision: April 13, 2023

Revised: April 26, 2023

Accepted: June 9, 2023

Article in press: June 9, 2023

Published online: October 18, 2023



Andrea Vescio, Gianluca Testa, Alessia Caldaci, Marco Sapienza, Vito Pavone, Department of General Surgery and Medical Surgical Specialties, Section of Orthopaedics and Traumatology, A.O.U. Policlinico "Rodolico-San Marco", University of Catania, Catania 95123, Italy

Corresponding author: Gianluca Testa, MD, Professor, Research Assistant Professor, Department of General Surgery and Medical Surgical Specialties, Section of Orthopaedics and Traumatology, A.O.U. Policlinico "Rodolico-San Marco", University of Catania, Via Santa Sofia 78, Catania 95123, Italy. gianpavel@hotmail.com

Abstract

BACKGROUND

Flexible flatfoot (FFF) is a very common condition in children, but no evidence-based guidelines or assessment tools exist. Yet, surgical indication is left to the surgeon's experience and preferences.

AIM

To develop a functional clinical score for FFF [Catania flatfoot (CTF) score] and a measure of internal consistency; to evaluate inter-observer and intra-observer reliability of the CTF Score; to provide a strong tool for proper FFF surgical indication.

METHODS

CTF is a medically compiled score of four main domains for a total of twelve items: Patient features, Pain, Clinical Parameters, and Functionality. Each item refers to a specific rate. Five experienced observers answered 10 case reports according to the CTF. To assess inter- and intra-observer reliability of the CTF score, the intra-class correlation coefficients' (ICCs) statistics test was performed, as well as to gauge the correlation between the CTF score and the surgical or conservative treatment indication. Values of 75% were chosen as the score cut-off for surgical indication. Sensitivity, specificity, positive likelihood ratio (PLHR), negative likelihood ratio (NLHR), positive predictive value (PPV), and negative predictive value (NPV).

RESULTS

Overall interobserver reliability ICC was 0.87 [95% confidence interval (CI): 0.846-0.892; $P < 0.001$]. Overall intra-observer reliability ICC was 0.883 (95% CI: 0.854-0.909; $P < 0.001$). A direct correlation between the CTF score and surgical treatment indication [Pearson correlation coefficient = 0.94 ($P < 0.001$)] was found.

According to the 75% cut-off, the sensitivity was 100% (95%CI: 83.43%-100%), specificity was 85.71% (95%CI: 75.29%-92.93%), PLHR was 7 (95%CI: 3.94-12.43), NLHR was 0 (95%CI: 0-0), PPV was 75% (95%CI: 62.83%-84.19%) and NPV was 100% (95%CI: 100%-100%).

CONCLUSION

CTF represents a useful tool for orthopedic surgeons in the FFF evaluation. The CTF score is a quality questionnaire to reproduce suitable clinical research, survey studies, and clinical practice. Moreover, the 75% cut-off is an important threshold for surgical indication and helps in the decision-making process.

Key Words: Pes planus; Score; Assessment; Clinic; Surgery; Outcome; Reparability

©The Author(s) 2023. Published by Baishideng Publishing Group Inc. All rights reserved.

Core Tip: There was no validated children's flexible flatfoot questionnaire in the literature. Catania flatfoot is a medical score of four main domains for a total of twelve items: Patient features, pain, clinical parameters, and functionality. The tool was easy to perform and reproduce in clinical research, survey studies, or clinical practice. The 75% cut-off is an important threshold for surgical indication and help in the decision-making process.

Citation: Vescio A, Testa G, Caldaci A, Sapienza M, Pavone V. Catania flatfoot score: A diagnostic-therapeutic evaluation tool in children. *World J Orthop* 2023; 14(10): 755-762

URL: <https://www.wjgnet.com/2218-5836/full/v14/i10/755.htm>

DOI: <https://dx.doi.org/10.5312/wjo.v14.i10.755>

INTRODUCTION

The flexible flatfoot (FFF), known as pes planus, is a very common condition in children characterized by loss of the medial arch and an increase in the support base along with valgus of the hindfoot, yet 40 different definitions were formulated[1]. FFF is associated with anatomical conditions, including valgus heel, subluxation of the subtalar joint with intra-rotation of the talus and flexion of plantar abduction of the mid-tarsal joint with naval dorsal subluxation[2]. Generally, FFF is an age-related physiological variant, not a disease, and its incidence decreases significantly in terms of increased age: In children 3-years-old, it is 54%, whereas in children 6-years-old, it is 24%[3]. A history should include pain, location, intensity, functional problems, while trauma or recurrent ankle sprains should be specifically questioned. FFF is typically an asymptomatic condition[4]. Lower limb pain[5] and lower limb function[6] were found as the main manifestations in symptomatic FFF. Until 2022, more than 300 scientific articles were published, without evidence-based guidelines. The challenge for health professionals is to identify when a child's foot is consistent with developmental expectations, particularly in relation to foot posture, and/or function to reassure, monitor or intervene accordingly[7-10]. Therefore, the measure to indicate where foot posture is outside of expected flatness in children (*i.e.*, the diagnoses of flat foot) must be valid, reliable, and appropriate for developing foot posture typically observed. Recently, a systematic review[1] highlighted there was no consistency used to determine pediatric FFF in the literature or the choice of foot posture measures, in relation to validity and reliability, which was rarely justified. A surgical indication was in effect for the surgeon's experience[11,12]. The purpose of the study was to develop new functional clinical scores for FFF to assess toddlers and adolescent patients' characteristic functionality [Catania flatfoot (CTF) Score] and measure of internal consistency; to evaluate inter- and intra-observer reliability of the CTF Score; and to provide a reliable tool for proper FFF surgical indication.

MATERIALS AND METHODS

CTF score development

The CTF Score development was composed of two parts, the CTF Score Conception and CTF Score Composition and Scoring.

CTF score conception: An orthopedic team was involved in developing the questionnaire. The CTF score was designed to be used in different clinical settings, including clinical research, survey studies, and clinical practice to assess FFF-affected patients and possibly assess changes with treatment. The development team was composed of two senior orthopedic and trauma surgeons (Vito Pavone and Gianluca Testa), and one pediatric orthopedic (fully-trained) resident (Andrea Vescio). At an early stage, an author (Andrea Vescio) search was done to analyze the functional foot and ankle score previously described and developed as the CTF score. Senior authors (Vito Pavone and Gianluca Testa) reviewed and validated the scores.

CTF score composition and scoring: The questionnaire is a medically-compiled score of four main domains for a total of twelve items: Patient features (2 items), pain (1 item), clinical parameters (5 items), and functionality (4 items). Each item refers to a specific rate as reported in [Supplementary Table 1](#). The lowest achievable value is -80, while the highest is 170. Calculation of the CTF score is based on the following formula:

$$\left[\frac{(\text{Sum of items score} + 80)}{250} \right] \times 100$$

The value is expressed as a percentage: Higher percentages are associated with a lower clinical presentation.

CTF score patient features domain: Patient features are composed of two items aimed to assess the principal general parameters of the evaluated subject. The first item is related to age; the second is linked to laxity. Hypermobility can be assessed according to the passive dorsiflexion of the fifth hand finger and thumbs, elbow, and knee hyperextension.

CTF score pain domain: The pain domain was composed of one item to assess generalized pain of the foot or ankle, as well as in the plantar arch, heel, tibialis posterior tendon, and fascia.

CTF score clinical parameters domain: The clinical parameters domain is composed of five items to assess the callous present, valgus of hindfoot, longitudinal arch, forefoot abduction, and triceps contracture. For each item, three answers are admissible: “none”, “mild”, and “severe”. The first item “callous” allows for two answers: “yes” and “no”.

CTF score functionality domain: The functionality domain provides four items to evaluate the patient’s capacities. Fatigue, inadequate physical and sport performance, and wear of orthosis is recorded. The first and last items of the section (“fatigue” and “orthosis”) allow for two answers: “yes” and “no”, while others provide “none”, “mild”, and “severe”.

Evaluation materials

A review of all infants, toddlers, and adolescents admitted through the pediatric orthopedic ambulatory were carried out. For each patient the following demographic and clinical data captured: Gender, age, the involved side, and presence or absence of associated syndromes or deformities, past and recent medical history for foot and ankle discomfort or pain. Frontal, lateral, and posterior view photos were taken. The pictures were performed in the same positions to provide the more possible objectivity and recorded in an online database. The inclusion criteria were as follows: (1) Chronological age 17-years-old; (2) physical and podoscopic examination; (3) complete photographic history; and (4) positive Tip Toe and Jack test; all cases were examined by the same expected pediatric orthopedic team.

Evaluation contributors

Children in the study were independently examined and assessed by two orthopedic surgeons and three residents in pediatric orthopedics: All evaluators had previous experience of at least twenty-four months. Three assessors, two surgeons, and a resident completed a full program while treating over 50 FFF patients in the previous two years. All observers had 1 h of theoretical FFF clinical manifestation and score system training before patients’ assessment. Each contributor was provided with a summary of the medical history and clinical examination of the frontal, lateral, and posterior view photos. As per the web-based score, observers were asked about conservative or surgical indication. Answers were submitted *via* a link hosted by <https://www.google.com/> forms and recorded by an Excel spreadsheet (Microsoft, Redmond, WA, United States). The CTF score was submitted at two different points.

Primary outcome measurement

To assess the inter- and intra-observer reliability of the CTF score, the intra-class correlation coefficients (ICCs) statistics test was performed. For scale development, it is generally accepted there should be at least five times the number of respondents as questions, for at least 60 in total[11].

Secondary outcome measurement

To assess the correlation between the CTF score and surgical or conservative treatment, values of 75% were used as a score cut-off for surgery. Sensitivity, specificity, positive likelihood ratio (PLHR), negative likelihood ratio (NLHR), positive predictive value (PPV), and negative predictive value (NPV) were used.

Statistical analysis

Continuous data are presented as the mean and standard deviation when appropriate. The ICC (two-way random effects model, with single-measure reliability) was performed to evaluate intra- and interobservers’ agreement. According to the Koo and Li guideline, agreement below 0.50 was considered “poor”; between 0.50 and 0.74 as “moderate”; between 0.75 and 0.89 as “good”; and above 0.90 as “excellent”[12]. The Pearson correlation coefficient (PCC) was utilized to assess the correlation between conservative or surgical treatment and the CTF score. PCC vales between -1 and 1, where values close to -1 indicated high negative correlation, with values close to 1 indicating a high positive correlation, and values close to 0 indicating no or a very weak correlation.

A rule of thumb for interpreting the coefficient is provided by Colton *et al*[13]: (1) 0 to 0.25 (0 to -0.25) little or no relationship; (2) 0.25 to 0.50 (-0.25 to -0.50) fair degree of a relationship; (3) 0.50 to 0.75 (-0.50 to -0.75) moderate to good degree of a relationship; and (4) 0.75 to 1.00 (-0.75 to -1.00) very good to excellent relationship.

The Bland and Altman plot was produced to analyze differences between cohort measurements. The limits of agreement were calculated as the mean difference ± 1.96 SD[14]. A value of 75% was chosen as a score cut-off for surgical indication. Sensitivity, specificity, PLHR, NLHR, PPV, and NPV were recorded. *P* values of less than 0.05 were considered statistically significant. All statistical analyses were performed using IBM SPSS, Version 24.0 (IBM Corp., Armonk, NY, United States).

RESULTS

Five different experienced observers answered 10 case reports. For each patient, observers responded to 14 questions (12 items and 2 treatment indications) for a total of 140 responses. The web-based survey was submitted at two different times, while 280 observations were reported.

Inter- and intra-observer reliability

Overall interobserver reliability ICC was 0.87 [95% confidence interval (CI): 0.846-0.892; $P < 0.001$; “good”]. The ICC value for specialists was 0.809 (95%CI: 0.761-0.849; $P < 0.001$; “good”), but was 0.852 (95%CI: 0.821-0.879; $P < 0.001$; “good”) for residents (Table 1).

The overall intra-observer reliability ICC was 0.883 (95%CI: 0.854-0.909; $P < 0.001$) and considered “good” (Table 2 and Figure 1).

The ICC value for specialists was 0.869 (95%CI: 0.832-0.901; $P < 0.001$; “good”), but was 0.878 (95%CI: 0.846-0.907; $P < 0.001$; “good”) for residents (Table 1).

CTF score treatment indication correlation

A fair inverse correlation occurred between the CTF score and conservative treatment indication (PCC = -0.483; $P < 0.001$) (Figure 2A).

The direct correlation between the CTF score and surgical treatment indication (PCC = 0.94; $P < 0.001$) was rated “from good to excellent” (Figure 2B).

CTF score for linear regression

According to the 75% cut-off, sensitivity was 100% (95%CI: 83.43%-100%), specificity was 85.71% (95%CI: 75.29%-92.93%), PLHR was 7 (95%CI: 3.94-12.43), NLHR was 0 (95%CI: 0-0), PPV was 75% (95%CI: 62.83%-84.19%), and NPV was 100% (95%CI: 100%-100%).

DISCUSSION

The CTF score was found to be a valid, effective tool in flatfoot assessment. The scale was seen as good or excellent for inter- and intra-observer reliability, done independently with experience levels. Higher score values were directly correlated with surgical treatment needs, while an increase in score reduced conservative management indication. In addition, the 75% CTF score values were discovered as reasonable cut-off points for surgical treatment, while high percentages of sensitivity and specificity guaranteed safe tool utilization.

In recent surveys, European[9] and Italian[10] pediatric orthopedics underlined the absence of a specific and universally-recognized clinical evaluation score for juvenile FFF. The CTF Score fills the literature void and, considering the good results, can be proposed as a helpful tool for clinical research, survey studies, and clinical practice to assess FFF-affected patients as well as changes with treatment.

Each domain scale was developed according to the weighted preferences of European and Italian pediatric orthopedics which ensure that each scale is internally consistent, *i.e.*, measures a single trait and that each item has different levels of difficulty or severity.

The final instrument comprises 12 questions divided into four domains which measure problems in domains titled *Patient features* (2 items), *pain* (1 item), *clinical parameters* (5 items), and *functionality* (4 items). Raw domain scores can be transformed into percentage scores to make them easier to interpret; higher scores indicate more severe disability. The item has strong face validity and is included as a categorical descriptive variable but not allied to any domain scale. The instrument is not suitable for those who are unable to walk, or who have a significant proximal component to their disability.

In 2005, the American Orthopedic Foot and Ankle Society (AOFAS) members identified the Foot Function Index, and the American Academy of Orthopaedic Surgeons Foot and Ankle module scores as the most frequently used in the literature[15]. Yet, AOFAS[16], Foot and Ankle Ability Measure[17], and the Rowan Foot Pain Assessment Questionnaire [18] were commonly utilized for foot and ankle disorder evaluation. On the other hand, previous scores were not specific for children or flatfoot, because they were developed for adult generalized foot and ankle disease or ankle osteoarthritis.

The Oxford Ankle Foot Questionnaire for Children (OxAFQ-C) is the only validated tool in the pediatric population to measure the subjective well-being of children from 5- to 16-years-old with foot and ankle conditions[19]. The major limit of the OxAFQ-C is its patient-reported nature, as several studies report a tendency in children to score themselves higher than their parents[20,21], while the physician CTF Score report an intra-observer reliability of 0.883, with the OxAFQ-C domain reliability rating at 0.6 and 0.83. In addition, the tool was useful for physicians with an intra- and interobserver reliability of 0.852 and 0.878, respectively.

Table 1 Intra-observer reliability intra-class correlation coefficients values

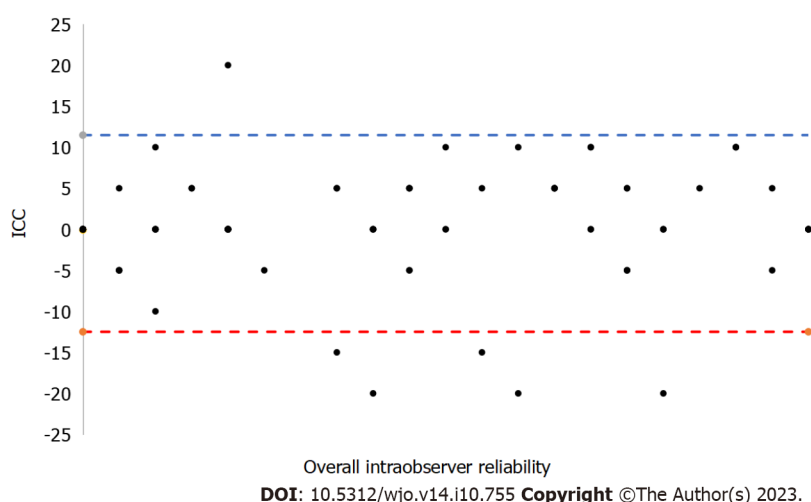
Sample	ICC	95% confidence interval		Value	P value
		Lower limit	Upper limit		
Overall	0.883	0.854	0.909	7.513	< 0.0001
Specialists	0.869	0.832	0.901	27.523	< 0.0001
Residents	0.878	0.846	0.907	44.351	< 0.0001

ICC: Intra-class correlation coefficients.

Table 2 Interobserver reliability intra-class correlation coefficients values

Sample	ICC	95% confidence interval		Value	P value
		Lower limit	Upper limit		
Overall	0.870	0.846	0.892	34.479	< 0.0001
Specialists	0.809	0.761	0.849	9.475	< 0.0001
Residents	0.852	0.821	0.879	18.272	< 0.0001

ICC: Intra-class correlation coefficients.

**Figure 1 Bland Altman plots according overall intra-observer reliability intra-class correlation coefficients.** ICC: Intra-class correlation coefficients.

Since March 2020, the pandemic emergency raised questions about alternatives to normal clinical activity to avoid overcrowding in departments; for less risk of contagions, many checkups were procrastinated. This issue caused a possible loss of patient follow-up, which can reflect on the clinic and its outcomes. The necessity to develop management protocols highlights telemedicine as a valid alternative in particular conditions *vs* the face-to-face clinic, with safety margins and economic savings. The CTF score was administered with a web-based database, well-tolerated by observers; moreover, despite assessment of foot functionality, the CTF Score does not include a range of motion evaluation. The score was considered a good remote follow-up tool. The authors intend to promote the distribution of the score and face-to-face and remote validation.

Surgical treatment is still debated, as Bouchard and Mosca[22] suggested that surgical management be used only in Achilles' tendon retraction, while several authors highlighted issues of fatigue, inadequate physical performance, and pain as the main parameters for the decision-making process[23]. The 75% CTF score cut-off presented high sensitivity and specificity as reasonable cut-offs for surgical treatment. The tool does not replace the surgeon's experience, but represents a helpful orthopedic decision-making process. The CTF provides to general or pediatric physicians, podiatrist, physiotherapists, young or non-pediatric orthopedic trained orthopedic surgeons a common accepted and objective additional tool for the correct flatfoot grade and eventually surgical indication. The patient and family history, body posture assessment remain mandatory for the proper assessment. Future research into the development and validation of

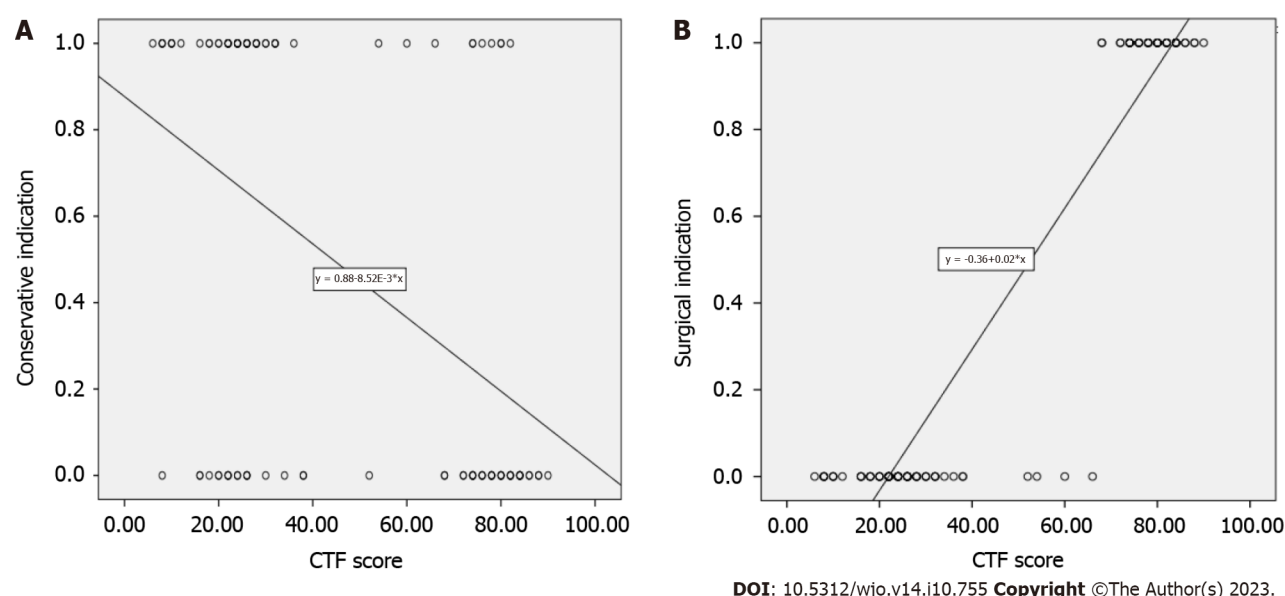


Figure 2 Scatter plot. A: The correlation between the Catania flatfoot (CTF) score and the conservative treatment indication; B: The correlation between the CTF score and the surgical treatment indication.

the questionnaire will assess whether the instrument is responsive to change. We will administer the questionnaire to general non-pediatric orthopedic surgeons, and reassess test-retest reliability while monitoring dimensionality and scaling of the instrument as more data become available.

The limits of the score are related to the domains compilation, in fact, the valgus of the hindfoot, longitudinal arch, forefoot abduction, and triceps contracture assessment are related to the physician or surgeon experience, and the fatigue, inadequate physical and sport performance items are related to the patient consciousness. In the future, the development of new and more objective criteria could make the CTF more usable.

CONCLUSION

In conclusion, the CTF Score is useful for orthopedic surgeons in the juvenile FFF evaluation. The CTF score is derived from a high-quality questionnaire for clinical research, survey studies, or clinical practice. The 75% cut-off point is a good threshold for surgical indication and decision-making. Given widespread use of telemedicine, the CTF score is also seen as an objective remote clinical examination.

ARTICLE HIGHLIGHTS

Research background

Flexible flatfoot (FFF) is a very common condition in children, but no evidence-based guidelines or assessment tools exist. Yet, surgical indication is left to the surgeon's experience and preferences.

Research motivation

The lack of common diagnostic criteria for FFF.

Research objectives

To develop a functional clinical score for FFF [Catania flatfoot (CTF) score] and a measure of internal consistency; to evaluate interobserver and intra-observer reliability of the CTF Score; to provide a strong tool for proper FFF surgical indication.

Research methods

CTF is a medically compiled score of four main domains for a total of twelve items: Patient features, Pain, Clinical Parameters, and Functionality. Each item refers to a specific rate. Five experienced observers answered 10 case reports according to the CTF. To assess inter- and intra-observer reliability of the CTF score, the intra-class correlation coefficients' (ICCs) statistics test was performed, as well as to gauge the correlation between the CTF score and the surgical or conservative treatment indication. Values of 75% were chosen as the score cut-off for surgical indication. Sensitivity, specificity, positive likelihood ratio (PLHR), negative likelihood ratio (NLHR), positive predictive value (PPV), and

negative predictive value (NPV).

Research results

Overall interobserver reliability ICC was 0.87 (95%CI: 0.846-0.892; $P < 0.001$). Overall intra-observer reliability ICC was 0.883 (95%CI: 0.854-0.909; $P < 0.001$). A direct correlation between the CTF score and surgical treatment indication [Pearson correlation coefficient = 0.94 ($P < 0.001$)] was found. According to the 75% cut-off, the sensitivity was 100% (95%CI: 83.43%-100%), specificity was 85.71% (95%CI: 75.29%-92.93%), PLHR was 7 (95%CI: 3.94-12.43), NLHR was 0 (95%CI: 0-0), PPV was 75% (95%CI: 62.83%-84.19%) and NPV was 100% (95%CI: 100%-100%).

Research conclusions

CTF represents a useful tool for orthopedic surgeons in the FFF evaluation. The CTF score is a quality questionnaire to reproduce suitable clinical research, survey studies, and clinical practice. Moreover, the 75% cut-off is an important threshold for surgical indication and helps in the decision-making process.

Research perspectives

CTF needs further multicentric studies to increase its validity for diagnostic and surgical indications in FFF.

FOOTNOTES

Author contributions: Vescio A and Testa G contributed equally to this work; Vescio A, Testa G and Pavone V designed the research study; Caldaci A and Sapienza M performed the research; Vescio A contributed new reagents and analytic tools; Vescio A and Testa G analyzed the data and wrote the manuscript; All authors have read and approve the final manuscript.

Institutional review board statement: No ethical committee approval is needed because of the retrospective nature of the study.

Informed consent statement: All study participants or their legal guardian provided informed written consent about personal and medical data collection prior to study enrolment.

Conflict-of-interest statement: All the authors report no relevant conflicts of interest for this article.

Data sharing statement: Data are available on request.

STROBE statement: The authors have read the STROBE Statement – checklist of items, and the manuscript was prepared and revised according to the STROBE Statement – checklist of items.

Open-Access: This article is an open-access article that was selected by an in-house editor and fully peer-reviewed by external reviewers. It is distributed in accordance with the Creative Commons Attribution NonCommercial (CC BY-NC 4.0) license, which permits others to distribute, remix, adapt, build upon this work non-commercially, and license their derivative works on different terms, provided the original work is properly cited and the use is non-commercial. See: <https://creativecommons.org/licenses/by-nc/4.0/>

Country/Territory of origin: Italy

ORCID number: Andrea Vescio 0000-0002-1677-927X; Gianluca Testa 0000-0001-5246-9714; Alessia Caldaci 0000-0002-0191-087X; Marco Sapienza 0000-0002-8311-9132; Vito Pavone 0000-0001-5664-8066.

S-Editor: Fan JR

L-Editor: A

P-Editor: Yuan YY

REFERENCES

- 1 Banwell HA, Paris ME, Mackintosh S, Williams CM. Paediatric flexible flat foot: how are we measuring it and are we getting it right? A systematic review. *J Foot Ankle Res* 2018; **11**: 21 [PMID: 29854006 DOI: 10.1186/s13047-018-0264-3]
- 2 Vescio A, Testa G, Amico M, Lizzio C, Sapienza M, Pavone P, Pavone V. Arthroereisis in juvenile flexible flatfoot: Which device should we implant? A systematic review of literature published in the last 5 years. *World J Orthop* 2021; **12**: 433-444 [PMID: 34189081 DOI: 10.5312/wjo.v12.i6.433]
- 3 Pfeiffer M, Kotz R, Ledl T, Hauser G, Sluga M. Prevalence of flat foot in preschool-aged children. *Pediatrics* 2006; **118**: 634-639 [PMID: 16882817 DOI: 10.1542/peds.2005-2126]
- 4 Halabchi F, Mazaheri R, Mirshahi M, Abbasian L. Pediatric flexible flatfoot; clinical aspects and algorithmic approach. *Iran J Pediatr* 2013; **23**: 247-260 [PMID: 23795246]
- 5 Lin CJ, Lai KA, Kuan TS, Chou YL. Correlating factors and clinical significance of flexible flatfoot in preschool children. *J Pediatr Orthop* 2001; **21**: 378-382 [PMID: 11371824]
- 6 Kosashvili Y, Fridman T, Backstein D, Safir O, Bar Ziv Y. The correlation between pes planus and anterior knee or intermittent low back pain. *Foot Ankle Int* 2008; **29**: 910-913 [PMID: 18778669 DOI: 10.3113/FAL2008.0910]

- 7 **Labovitz JM.** The algorithmic approach to pediatric flexible pes planovalgus. *Clin Podiatr Med Surg* 2006; **23**: 57-76, viii [PMID: 16598910 DOI: 10.1016/j.cpm.2005.10.001]
- 8 **Evans AM.** The flat-footed child -- to treat or not to treat: what is the clinician to do? *J Am Podiatr Med Assoc* 2008; **98**: 386-393 [PMID: 18820042 DOI: 10.7547/0980386]
- 9 **Pavone V, Testa G, Vescio A, Wirth T, Andreacchio A, Accadbled F, Canavese F.** Diagnosis and treatment of flexible flatfoot: results of 2019 flexible flatfoot survey from the European Paediatric Orthopedic Society. *J Pediatr Orthop B* 2021; **30**: 450-457 [PMID: 33399292 DOI: 10.1097/BPB.0000000000000849]
- 10 **Pavone V, Vescio A, Andreacchio A, Memeo A, Gigante C, Lucenti L, Farsetti P, Canavese F, Moretti B, Testa G, De Pellegrin M.** Results of the Italian Pediatric Orthopedics Society juvenile flexible flatfoot survey: diagnosis and treatment options. *J Pediatr Orthop B* 2022; **31**: e17-e23 [PMID: 34101678 DOI: 10.1097/BPB.0000000000000881]
- 11 **Vaisrub N.** Biostatistics: The Bare Essentials. *JAMA* 2009; **302**: 2260-2264 [DOI: 10.1001/jama.2009.1734]
- 12 **Mejabi J, Esan O, Adegbehingbe O, Orimolade A, Asuquo J, Badmus H, Anipole O, Anand A, Bin H, Razak A.** The Pirani Scoring System is Effective in Assessing Severity and Monitoring Treatment of Clubfeet in Children. *Br J Med Med Res* 2016; **17**: 1-9 [DOI: 10.9734/BJMMR/2016/27439]
- 13 **Colton T, Johnson T, Machin D.** Statistics in Medicine. In: Encyclopedia of Statistical Sciences. John Wiley & Sons, Ltd, 2006
- 14 **Altman DG, Bland JM.** Assessing Agreement between Methods of Measurement. *Clin Chem* 2017; **63**: 1653-1654 [PMID: 28588121 DOI: 10.1373/clinchem.2016.268870]
- 15 **Lau JT, Mahomed NM, Schon LC.** Results of an Internet survey determining the most frequently used ankle scores by AOFAS members. *Foot Ankle Int* 2005; **26**: 479-482 [PMID: 15960915 DOI: 10.1177/107110070502600609]
- 16 **Leigheb M, Janicka P, Andorno S, Marcuzzi A, Magnani C, Grassi F.** Italian translation, cultural adaptation and validation of the "American Orthopaedic Foot and Ankle Society's (AOFAS) ankle-hindfoot scale". *Acta Biomed* 2016; **87**: 38-45 [PMID: 27163894]
- 17 **Martin RL, Irrgang JJ, Burdett RG, Conti SF, Van Swearingen JM.** Evidence of validity for the Foot and Ankle Ability Measure (FAAM). *Foot Ankle Int* 2005; **26**: 968-983 [PMID: 16309613 DOI: 10.1177/107110070502601113]
- 18 **Rowan K.** The development and validation of a multi-dimensional measure of chronic foot pain: the Rowan Foot Pain Assessment Questionnaire (ROFPAQ). *Foot Ankle Int* 2001; **22**: 795-809 [PMID: 11642531 DOI: 10.1177/107110070102201005]
- 19 **Morris C, Doll HA, Wainwright A, Theologis T, Fitzpatrick R.** The Oxford ankle foot questionnaire for children: scaling, reliability and validity. *J Bone Joint Surg Br* 2008; **90**: 1451-1456 [PMID: 18978264 DOI: 10.1302/0301-620X.90B11.21000]
- 20 **Ennett ST, DeVellis BM, Earp JA, Kredich D, Warren RW, Wilhelm CL.** Disease experience and psychosocial adjustment in children with juvenile rheumatoid arthritis: children's vs mothers' reports. *J Pediatr Psychol* 1991; **16**: 557-568 [PMID: 1744805 DOI: 10.1093/jpepsy/16.5.557]
- 21 **Cronin CA.** Measuring Health-Related Quality of Life in Children: the Development of the TACQOL Parent Form. *J Neurol Phys Ther* 2000; **24**: 161
- 22 **Bouchard M, Mosca VS.** Flatfoot deformity in children and adolescents: surgical indications and management. *J Am Acad Orthop Surg* 2014; **22**: 623-632 [PMID: 25281257 DOI: 10.5435/JAAOS-22-10-623]
- 23 **De Pellegrin M, Moharamzadeh D, Strobl WM, Biedermann R, Tschauner C, Wirth T.** Subtalar extra-articular screw arthroereisis (SESA) for the treatment of flexible flatfoot in children. *J Child Orthop* 2014; **8**: 479-487 [PMID: 25413354 DOI: 10.1007/s11832-014-0619-7]



Observational Study

Total hip arthroplasty following the failure of intertrochanteric nailing: First implant or salvage surgery?

Giuseppe Solarino, Davide Bizzoca, Pasquale Dramisino, Giovanni Vicenti, Lorenzo Moretti, Biagio Moretti, Andrea Piazzolla

Specialty type: Orthopedics

Provenance and peer review:

Invited article; Externally peer reviewed.

Peer-review model: Single blind

Peer-review report's scientific quality classification

Grade A (Excellent): 0

Grade B (Very good): B

Grade C (Good): C

Grade D (Fair): 0

Grade E (Poor): 0

P-Reviewer: Mostafavinia A, Iran; Veltman ES, Netherlands

Received: May 31, 2023

Peer-review started: May 31, 2023

First decision: July 19, 2023

Revised: August 16, 2023

Accepted: September 6, 2023

Article in press: September 6, 2023

Published online: October 18, 2023



Giuseppe Solarino, Pasquale Dramisino, Giovanni Vicenti, Biagio Moretti, DiBrain, University of Bari Aldo Moro, Bari 70154, Italy

Davide Bizzoca, DiMePre-J, University of Bari Aldo Moro, Bari 70154, Italy

Lorenzo Moretti, Orthopaedic and Trauma Unit Policlinico di Bari, Bari 70124, Italy

Andrea Piazzolla, UOSD Vertebral Surgery, Policlinico di Bari, Bari 70124, Italy

Corresponding author: Davide Bizzoca, MD, PhD, Surgeon, DiMePre-J, University of Bari Aldo Moro, 11 Piazza Giulio Cesare, Bari 70154, Italy. davide.bizzoca@uniba.it

Abstract

BACKGROUND

Proximal femur fractures, including both intracapsular (femoral neck fractures) and extracapsular fractures (intertrochanteric femoral fractures, IFFs), affect around 1.5 million people per year worldwide. Mechanical failures of intertrochanteric nailing in IFFs could be managed with revision total hip arthroplasty (THA).

AIM

To describe the surgical complexity and the procedure-related complication rates in patients with trochanteric nailing failure and treated with THA.

METHODS

Patients referred to our level I trauma center between April 2012 and July 2018 with failed cephalomedullary nailing following trochanteric fractures were retrospectively recruited. All patients underwent a salvage surgical procedure, *i.e.*, cephalomedullary nail removal and conversion to THA. The same surgical and anesthesiology team performed the surgical procedures under spinal anesthesia. All patients underwent clinical and radiographic follow-ups for at least 24 mo. Complications and re-operations were recorded.

RESULTS

Seventy-four patients met the inclusion criteria (male: 29; female: 45; mean age: 73.8-years-old; range: 65-89) and were included in the current study. The average operative time was 117 min (76-192 min). The average blood loss was 585 mL

(430-1720 mL). Among the 74 patients, 43 (58.1%) required transfusion of three or more blood units. Two patients died within the 4th d after surgery because of pulmonary embolism, and 1 patient died 9 mo after surgery due to ischemic myocardial infarction. The complication rate in the 71 patients who completed the minimum 24-mo follow-up was 22.5%. In 3 cases out of 71 (4.2%) periprosthetic acetabular fracture was observed during the follow-up. One of these periacetabular fractures occurred intraoperatively. An intraoperative periprosthetic femur fracture was observed in 5 patients out of 71 (7.0%). Four of these patients needed a re-operation to fix the fracture with plates and cerclages; in one of these patients, femoral stem revision was also necessary. In 4 patients out of 71 (5.6%), an early THA dislocation was observed, whereas in 1 case (1.4%) a late THA dislocation was observed. Three patients out of 71 (4.2%) developed a periprosthetic joint infection during the study follow-up.

CONCLUSION

The present study demonstrated that salvage options for IFF fixation failure are complex procedures with a relevant intraoperative and postoperative complication rate.

Key Words: Femoral nailing; Total hip arthroplasty; Proximal femur fractures; Osteoporosis; Fragility fractures; Geriatric patients; Hip traumatology; Hip replacement

©The Author(s) 2023. Published by Baishideng Publishing Group Inc. All rights reserved.

Core Tip: The present study demonstrated that salvage options for intertrochanteric femoral fracture fixation failure deal with intraoperative and postoperative complications at a higher rate compared to primary elective total hip arthroplasty.

Citation: Solarino G, Bizzoca D, Dramisino P, Vicenti G, Moretti L, Moretti B, Piazzolla A. Total hip arthroplasty following the failure of intertrochanteric nailing: First implant or salvage surgery? *World J Orthop* 2023; 14(10): 763-770

URL: <https://www.wjgnet.com/2218-5836/full/v14/i10/763.htm>

DOI: <https://dx.doi.org/10.5312/wjo.v14.i10.763>

INTRODUCTION

Proximal femur fractures (PFFs), including both intracapsular (femoral neck fractures, FNFs) and extracapsular fractures (intertrochanteric femoral fractures, IFFs), affect around 1.5 million people per year worldwide, thus constituting a major public health problem[1]. PFFs are the most common traumatic injuries in elderly people and significantly impact patients' health status, potentially leading to a reduced quality of life, increased disability and higher mortality rate[1,2]. In Italy, PFFs have an estimated annual prevalence of 78000, with 90% of injuries occurring in patients older than 65 years [3]. Nonetheless, as life expectancy is constantly increasing, the annual number is supposed to steadily increase by reaching 8.2 million fractures in 2050 worldwide[3-6].

IFFs, accounting for more than 60% of PFFs, have an annual mortality rate of 15%-20%[4]. It has also been reported that the incidence of IFF is increasing more than the incidence of PFF in the elderly[7]. Fox *et al*[7], in a prospective study on 923 elderly patients comparing patients with IFF and FNF, observed that patients with IFFs were older and showed a worse pre-injury health status. They also were less likely to recover to the pre-fracture level of functioning at the 2-mo follow-up.

IFFs need surgical management and could be treated both with intramedullary and extramedullary implants[1,3]. However, a recent meta-analysis by Zhang *et al*[8] stated that the current evidence indicates short intramedullary nails may be a better choice than dynamic hip screws in the treatment of IFFs. Compared to dynamic hip screws, intramedullary nailing has the theoretical advantages of being less invasive and biomechanically superior, providing a buttress to limit fracture collapse[1]. Moreover, in patients managed with cephalomedullary nails, a better recovery to pre-injury activity level, less blood loss, and fewer complications have been reported[1,3,8].

The surgical planning of IFFs and implant choice is critically influenced by the stability of the fracture pattern[9]. A stable fracture resists displacement after adequate reduction and fixation and generally includes two fragment fractures with an intact posteromedial cortical calcar[9]. The intact medial buttress allows the proximal femur to redistribute stress and resist medial compressive loads[10]. On the other hand, an unstable fracture may collapse even after adequate reduction and fixation[10]. Unstable patterns include fractures with a compromised medial calcar (comminuted patterns or fractures with a large posteromedial fragment), fractures with a subtrochanteric extension, reverse obliquity fractures, or intertrochanteric fractures that involve the lateral cortical wall[9,10].

Treatment of unstable fractures is still challenging, and several factors may influence the surgical technique and implant choice[9,10]. Cephalomedullary nailing revealed a biomechanical superiority compared with an extramedullary fixation for unstable fracture patterns since it can resist higher loading forces and provide greater stability reducing the distance from the implant and the hip joint diminishing the bending moment across the implant/fracture construct[11-15]. Fixation failure after surgery to treat IFF is a serious complication. Many factors seem to influence the stability of the fixation during follow-up including the patient's age, female sex, poor bone quality, device choice, fracture reduction

Table 1 Main data of the study

Item	Patients, <i>n</i> = 74
Age in yr	
mean \pm SD	73.80 \pm 7.85
Range	65-89
Sex	
Female	45 (60.8)
BMI in kg/m ²	
mean \pm SD	28.70 \pm 4.43
Side	
Right	43 (58.1)
Mean operating time in min, mean \pm SD	77.0 \pm 35.5
Patients undergoing \geq 3, blood transfusion	43 (58.1)

Data are *n* (%) unless otherwise indicated. BMI: Body mass index; SD: Standard deviation.

quality, and presence of neurological comorbidities that may affect the rehabilitation process[16].

This study aimed to describe the surgical complexity and the procedure-related complication rates, in patients referring with trochanteric nailing failure and treated with total hip arthroplasty (THA) or hemiarthroplasty.

MATERIALS AND METHODS

Patients referred to our level I trauma center between April 2012 and July 2018 with failed trochanteric nailing were retrospectively recruited according to inclusion and exclusion criteria. Ethical clearance was obtained from our center's clinical research ethics board as per the 1964 Declaration of Helsinki, and all patients gave informed consent before enrolment in the study.

The inclusion criteria included: age greater than 65-years-old; good cognitive state; and osteoporosis, defined as lumbar T-score \leq -2.5 (all patients performed a DEXA scan during hospitalization). The exclusion criteria included: Moderate cognitive impairment (defined as mini-mental state examination $<$ 19); a history of malignant neoplasm; hemoglobin $<$ 10 g/dL at baseline; severely obese patients, *i.e.*, body mass index \geq 35 kg/m²; a life expectancy of fewer than 3 mo; medical illness or cognitive disorders precluding participation in the follow-up examination; concomitant lower-limb fractures; and traumatic head injury.

Patient demographics, including age, sex, body mass index, and comorbidities were recorded at recruitment. All patients underwent THA *via* the Hardinge approach, with the patient positioned in lateral decubitus. Adhesions were cleared around scar tissue, fully exposing the trochanter and enabling assessment of the greater and lesser trochanters and calcar femoral. The surgical procedures were performed by the same surgical and anesthesiology team under spinal anesthesia.

Cefazolin (2 g intravenously) or, if contraindicated, clindamycin (600 mg *i.v.*) was given 60 min before incision. Subcutaneous injection of low molecular-weight heparin (enoxaparin 4000 UI once a day, started 12 h after surgery) was administered for antithrombotic prophylaxis in all patients until the return to full weight-bearing.

Surgical time, blood transfusion rate and perioperative and major complications were assessed. All patients underwent a minimum 24-mo clinical and radiographic follow-up. Complications and reoperations were recorded.

Statistical analysis was performed using STATA/MP 14 for Windows (StataCorp LP, College Station, United States). All data were described as mean, median, and standard deviation.

RESULTS

The main data of the study are reported in Table 1. Seventy-four patients met the inclusion and exclusion criteria (male: 29; female: 45; mean age: 73.8-years-old; range: 65-89) and were included in the current study. The recruited patients were originally referred with the following fracture patterns: 31-A1.2 (58 out of 74; 78.38%); 31-A1.3 (9 out of 74; 12.16%); 31-A2.2 (5 out of 74; 6.76%); and 31-A2.3 (2 out of 74; 2.7%).

The trochanteric nail failure modality included: cut-out in 39 cases out of 74 (50.65%); non-union in 13 patients out of 74 (17.56%); peri-implant fracture in 12 patients out of 74 (16.20%); cut-through in 8 patients out of 74 (10.80%); and femoral head avascular necrosis in 2 patients out of 74 (2.70%).

The average operation time was 117 min (76-192 min). The average blood loss was 585 mL (430-1720 mL). Among the 74 patients, 43 patients (58.10%) required transfusion of three or more blood units.

All the patients underwent nail conversion to THA. Cemented stems were used in 19 patients out of 64 (25.68%), whereas uncemented stems were employed in 55 patients out of 74 (74.32%). Among the latter, long stems were used in 39 patients out of 74 (52.70%). Cemented cups were implanted in 18 patients out of 74 (24.32%), whereas in 56 patients out of 74 (75.68%) cementless cups were used. Dual-mobility cups were implanted in 16 patients out of 74 (21.62%).

Table 2 shows the complications observed during the study follow-up. Seventy-one patients completed the minimum 24 mo of clinical and radiological follow-up (range: 25-85 mo). Two patients (2.70%) died within 4 d after surgery because of pulmonary embolism. One patient (1.35%) died 9 mo after surgery due to ischemic myocardial infarction. The overall complication rate in the 71 patients who completed the minimum 24-mo follow-up was 22.5%.

In 3 cases (4.23%) periprosthetic acetabular fracture was observed during the follow-up. One of these periacetabular fractures occurred intraoperatively. In 5 patients (7.00%), an intraoperative periprosthetic femur fracture was observed. Four of these patients needed a re-operation to fix the fracture with plates and cerclages; in one of these patients, femoral stem revision was also necessary. In 4 patients (5.60%) an early THA dislocation was observed, and 1 case (1.40%) a late THA dislocation was observed.

Three patients (4.23%) developed a periprosthetic joint infections (PJI) during the study follow-up. Two of them were early treated with debridement, antibiotics, irrigation, and retention of the prosthesis protocol; the other one was a late-onset infection requiring the THA explant and definitive conversion to Girdlestone procedure.

Table 3 shows the study data detailed by patients' sexes. Note that a higher percentage of perioperative complications was observed in male patients.

Figure 1 shows a case of complex femoral nailing failure in a female patient aged 81.

DISCUSSION

IFF is a common fracture injury among the elderly. Conservative treatment can result in prolonged periods in bed and/or lower limb shortening with varus deformity and is limited to very unstable patients with high perioperative risk[17]. Surgical treatment with cephalomedullary nails, compression hip screws, and the paracortical proximal plate has become the standard of care[9]. Despite the advanced knowledge and skills in the surgical management of IFF, internal fixation is often associated with significant failure, ranging from 3%-12%.

The patients at increased risk of failure are the elderly, females, and osteoporotic patients[18,19]. Fixation failure depends on several factors, including poor bone quality, fracture comminution and biomechanical stability, quality of reduction, and fixation. Despite several technological improvements that have been produced in the last two decades, fixation failure due to mechanical and biological complications still occurs and can lead to potentially devastating scenarios[20-23]. Mechanical complications are cut-out, cut-through, peri-implant fractures, or implant fractures.

The most common mechanical complication observed in our study was the lateral mobilization of the cephalic screw, *i.e.*, cutting out (55.71% of cases). Many factors are associated with a higher risk of cut-out, including a tip-to-apex distance greater than 25 mm, an unstable fracture pattern, an inadequate fracture reduction that may lead to a varus deformity of the femoral neck, and positioning of lag screw outside of the center-center or inferior center of the femoral neck[24-26]. The medial mobilization of the cephalic screw or blade toward the hip joint is also called cut-through.

Salvage procedures currently used for failed internal fixation of IFF are revision osteosynthesis or conversion to hip arthroplasty. The term salvage procedures in patients undergoing salvage surgeries are used to indicate a considerable decrease in pain level and an increase in functional recovery after treatment[27-34].

Revision osteosynthesis is mostly utilized in patients younger than 50-years-old, with high life expectancy and satisfactory bone quality[27,28]. It implies femoral head sparing and re-fixation performed *via* hardware exchange (blade/screw), bone graft augmentation (autologous or allograft) acting as a plug-in case of joint perforation, and a new blade/screw insertion either cemented or uncemented[29]. On the other hand, conversion to THA as a salvage option is preferred for elderly patients with severely impaired articular surfaces allowing early weight bearing and mobilization [20,21,29]. As already mentioned, salvage THA is a complex procedure and includes several technical hurdles hindering successful surgical outcomes including bone loss and/or deformity, poor bone stock, and the presence of non-union or malunion[20].

Our study differentiated salvage procedure-related complications into intraoperative and postoperative complications. Intraoperatively, we considered major complications, such as an increased skin-to-skin operative time compared to primary THA implant, intraoperative blood loss, and intraoperative fractures. Intraoperative fractures were the most common intraoperative complication including one acetabular fracture and five femoral fractures occurring during acetabular reaming and femoral canal broaching, respectively. They may be related to a combination of factors such as previous osteoporosis, incomplete fracture union, and weakening of the bone after hardware removal.

Intraoperative acetabular fractures may be related to disuse osteopenia and/or the presence of previous osteoporosis. Great trochanter fractures may be attributable to an amount of bone loss to the medial aspect of the greater trochanter due to a wider diameter of proximal nails, a lateral entry site of the lag screw in the greater trochanter, and excessive stress during hardware removal[35].

Skin-to-skin operative time and intraoperative bleeding were higher. Compared to patients undergoing primary THA, salvage procedures require two steps. The first operative time includes adhesion clearance around scar tissue, exposure of the greater trochanter, and hardware removal. The second operative time includes prosthetic joint implantation. This procedure is challenging and technically demanding because of distorted proximal femur anatomy, poor bone stock,

Table 2 Recorded complications, *n* (%)

Item	Patients, <i>n</i> = 74
Dead	3 (4.00)
Periprosthetic acetabular fractures	3 (4.00)
Periprosthetic femoral fractures	5 (6.76)
THA dislocation	5 (6.76)
Periprosthetic joint infections	3 (4.00)

THA: Total hip arthroplasty.

Table 3 Study data reported by sex

Item	Males, <i>n</i> = 29	Females, <i>n</i> = 45	<i>P</i> value
Age in yr			
mean \pm SD	72.90 \pm 9.85	74.40 \pm 8.65	0.087
Range	67-89	65-87	
BMI in kg/m ²			
mean \pm SD	28.60 \pm 4.03	28.90 \pm 4.55	0.650
Side			
Right	17 (58.62)	26 (57.78)	0.580
Operating time in min, mean \pm SD	84.0 \pm 41.50	72.22 \pm 32.34	0.003 ^a
Patients undergoing \geq 3, blood transfusion	19 (65.50)	24 (53.30)	0.002 ^a
Complications			
Dead	2 (6.89)	1 (2.22)	0.001 ¹
Periprosthetic acetabular fractures	2 (6.89)	1 (2.22)	0.001 ^a
Periprosthetic femoral fractures	1 (3.45)	4 (8.90)	0.001 ^a
THA dislocation	2 (6.89)	3 (6.70)	0.630
Periprosthetic joint infections	2 (6.89)	1 (2.22)	0.001 ^a

^aStatistical significance.

Data are *n* (%) unless otherwise indicated. BMI: Body mass index; SD: Standard deviation; THA: Total hip arthroplasty.

medial or lateral wall incompetence, and the presence of screw holes causing potential cement extrusion[30,31].

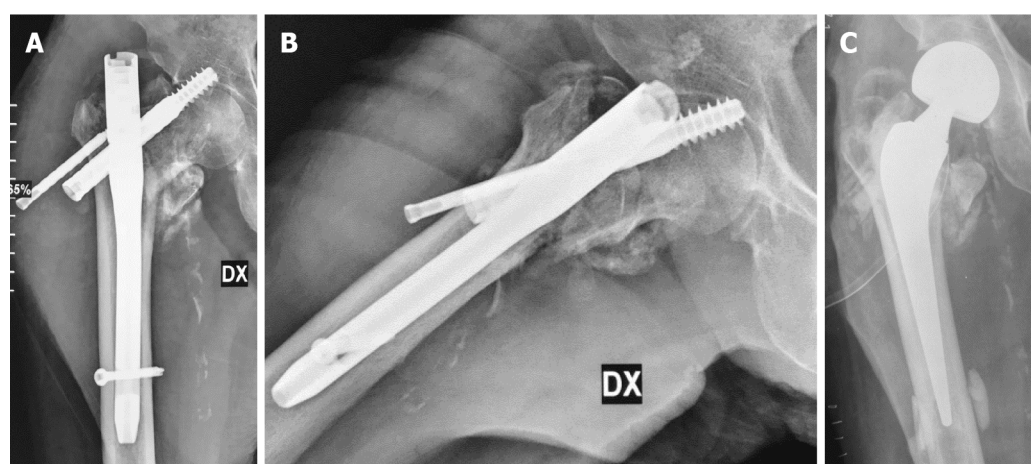
During the postoperative period after patient discharge, complications were further categorized as early major and late major complications. Early major complications included four cases of dislocation and two PJIs. Late major complications included 1 case of late dislocation and 1 case of periprosthetic infection.

Early postoperative dislocation is an important orthopedic complication after the salvage of THA. The dislocation rate in patients undergoing salvage arthroplasty after fixation failure of IFF seems to be higher compared to patients undergoing primary THA or salvage arthroplasty for FNF. This complication may be related to many factors: loss of abductor mechanism; shortening of limb length; and misorientation of prosthetic components[32].

The surgical site infection risk rate increases with an increasing number of revision surgeries performed. Our results (two early and one late PJI), similar to other results available within the current literature, revealed an increased PJI rate in salvage options compared to primary elective THA[36,37].

CONCLUSION

Surgical treatment for IFF fixation failure is a challenging procedure. Despite updated surgical skills in the surgical management of IFF, internal fixation failure rates are diagnosed in up to 12% of cases. Salvage options are the mainstay of their treatment allowing early weight bearing and stimulating functional recovery to the pre-injury level. This study analyzed difficulties during a salvage procedure, *i.e.*, cephalomedullary nail removal and THA implant, after failed



DOI: 10.5312/wjo.v14.i10.763 Copyright ©The Author(s) 2023.

Figure 1 A case of complex femoral nailing failure in a female patient aged 81 years. A and B: Anti-rotational screw cut-out, concomitant varus deformity of the neck, and cephalic screw cut-through; C: The patient underwent cemented bipolar hemiarthroplasty. Note the cement leakage through the former distal screw hole.

fixation of IFF. The present study demonstrated that salvage options for IFF fixation failure deal with intraoperative and postoperative complications at a higher rate than primary elective THA. Based on the present study findings, it is mandatory to adequately plan the surgical treatment in patients with PFFs since high rates of perioperative local and systemic complications are more common during revision surgery (or a salvage procedure).

ARTICLE HIGHLIGHTS

Research background

Proximal femur fractures (PFFs), including both intracapsular (femoral neck fractures) and extracapsular fractures (intertrochanteric femoral fractures, IFFs), affect around 1.5 million people per year worldwide. Mechanical failures of intertrochanteric nailing in IFFs could be managed with revision total hip arthroplasty (THA).

Research motivation

To assess if the conversion of failed nailing to THA in patients with previous PFFs has a high perioperative complication rate.

Research objectives

To describe the surgical complexity and the procedure-related complication rates, in patients referring with trochanteric nailing failure and treated with THA

Research methods

Patients referred to our level I trauma center between April 2012 and July 2018 with failed cephalomedullary nailing following trochanteric fractures were retrospectively recruited. All patients underwent a salvage surgical procedure, *i.e.*, cephalomedullary nail removal and conversion to THA. The surgical procedures were performed by the same surgical and anesthesiology team under spinal anesthesia. All patients underwent clinical and radiographic follow-ups for a minimum of 24 mo. Complications and re-operations were recorded.

Research results

Seventy-four patients met the inclusion criteria (male: 29; female: 45; mean age: 73.8-years-old; range: 65-89) and were included in the current study. The average operative time was 117 min (76-192 min). The average blood loss was 585 mL (430-1720 mL). Of the 74 patients, 43 patients (58.1%) required transfusion of three or more blood units. Two patients died within the 4th d after surgery because of pulmonary embolism. One patient died 9 mo after surgery due to ischemic myocardial infarction. The complication rate in the 71 patients who completed the minimum 24-mo follow-up was 22.50%. In 3 cases (4.23%) periprosthetic acetabular fracture was observed during the follow-up. One of these periacetabular fractures occurred intraoperatively. An intraoperative periprosthetic femur fracture was observed in 5 patients (7.00%). Four of these patients needed a re-operation to fix the fracture with plates and cerclages; in one of these patients, femoral stem revision was also necessary. In 4 patients (5.60%) an early THA dislocation was observed, whereas in 1 patient (1.40%) a late THA dislocation was observed. Three patients (4.23%) developed a periprosthetic joint infection during the study follow-up.

Research conclusions

The present study demonstrated that salvage options for IFF fixation failure are complex procedures with a relevant intraoperative and postoperative complication rate.

Research perspectives

Based on the present study findings, it is mandatory to adequately plan the surgical treatment in patients with PFFs since a revision surgery has a risk of high rates of perioperative local and systemic complications.

FOOTNOTES

Author contributions: Bizzoca D and Solarino G contributed to the investigation, data analysis, and writing; Dramisino P, Vicenti G, and Moretti L contributed to writing the first draft; Moretti B and Piazzolla A contributed to supervision and funding acquisition.

Institutional review board statement: Ethical clearance was obtained from our center's clinical research ethics board as per the 1964 Declaration of Helsinki.

Informed consent statement: All study participants, or their legal guardian, provided informed written consent prior to study enrollment.

Conflict-of-interest statement: All the authors declare having no conflicts of interest.

Data sharing statement: No additional data are available.

Open-Access: This article is an open-access article that was selected by an in-house editor and fully peer-reviewed by external reviewers. It is distributed in accordance with the Creative Commons Attribution NonCommercial (CC BY-NC 4.0) license, which permits others to distribute, remix, adapt, build upon this work non-commercially, and license their derivative works on different terms, provided the original work is properly cited and the use is non-commercial. See: <https://creativecommons.org/licenses/by-nc/4.0/>

Country/Territory of origin: Italy

ORCID number: Giuseppe Solarino 0000-0001-6325-9691; Davide Bizzoca 0000-0002-7516-2333; Lorenzo Moretti 0000-0003-0106-6215; Biagio Moretti 0000-0002-1234-8616; Andrea Piazzolla 0000-0003-2319-2108.

S-Editor: Chen YL

L-Editor: Filipodia

P-Editor: Chen YL

REFERENCES

- 1 Kanis JA, Odén A, McCloskey EV, Johansson H, Wahl DA, Cooper C; IOF Working Group on Epidemiology and Quality of Life. A systematic review of hip fracture incidence and probability of fracture worldwide. *Osteoporos Int* 2012; **23**: 2239-2256 [PMID: 22419370 DOI: 10.1007/s00198-012-1964-3]
- 2 Mattisson L, Bojan A, Enocson A. Epidemiology, treatment and mortality of trochanteric and subtrochanteric hip fractures: data from the Swedish fracture register. *BMC Musculoskelet Disord* 2018; **19**: 369 [PMID: 30314495 DOI: 10.1186/s12891-018-2276-3]
- 3 Innocenti M, Civinini R, Carulli C. Proximal femoral fractures: Epidemiology. *Cases in Miner and Bone Metabol* 2009; **6**: 117-119 [DOI: 10.11138/ccmbm/2017.14.1.041]
- 4 Sambrook P, Cooper C. Osteoporosis. *Lancet* 2006; **367**: 2010-2018 [PMID: 16782492 DOI: 10.1016/S0140-6736(06)68891-0]
- 5 Piazzolla A, Bizzoca D, Solarino G, Moretti L, Moretti B. Vertebral fragility fractures: clinical and radiological results of augmentation and fixation-a systematic review of randomized controlled clinical trials. *Aging Clin Exp Res* 2020; **32**: 1219-1232 [PMID: 31471888 DOI: 10.1007/s40520-019-01289-1]
- 6 Veronese N, Maggi S. Epidemiology and social costs of hip fracture. *Injury* 2018; **49**: 1458-1460 [PMID: 29699731 DOI: 10.1016/j.injury.2018.04.015]
- 7 Fox KM, Magaziner J, Hebel JR, Kenzora JE, Kashner TM. Intertrochanteric versus femoral neck hip fractures: differential characteristics, treatment, and sequelae. *J Gerontol A Biol Sci Med Sci* 1999; **54**: M635-M640 [PMID: 10647970 DOI: 10.1093/gerona/54.12.m635]
- 8 Zhang K, Zhang S, Yang J, Dong W, Wang S, Cheng Y, Al-Qwbani M, Wang Q, Yu B. Proximal femoral nail vs. dynamic hip screw in treatment of intertrochanteric fractures: a meta-analysis. *Med Sci Monit* 2014; **20**: 1628-1633 [PMID: 25213190 DOI: 10.12659/MSM.890962]
- 9 Tawari AA, Kempegowda H, Suk M, Horwitz DS. What makes an intertrochanteric fracture unstable in 2015? *J Orthop Trauma* 2015; **29** Suppl 4: S4-S9 [PMID: 25756825 DOI: 10.1097/BOT.0000000000000284]
- 10 Lu Y, Uppal HS. Hip Fractures: Relevant Anatomy, Classification, and Biomechanics of Fracture and Fixation. *Geriatr Orthop Surg Rehabil* 2019; **10**: 2151459319859139 [PMID: 31321116 DOI: 10.1177/2151459319859139]
- 11 Marsillo E, Pintore A, Asparago G, Oliva F, Maffulli N. Cephalomedullary nailing for reverse oblique intertrochanteric fractures 31A3 (AO/OTA). *Orthop Rev (Pavia)* 2022; **14**: 38560 [PMID: 36267220 DOI: 10.52965/001c.38560]
- 12 Queally JM, Harris E, Handoll HH, Parker MJ. Intramedullary nails for extracapsular hip fractures in adults. *Cochrane Database Syst Rev* 2014; CD004961 [PMID: 25212485 DOI: 10.1002/14651858.CD004961.pub4]

- 13 **Bizzoca D**, Bortone I, Vicenti G, Caringella N, Rifino F, Moretti B. Gait analysis in the postoperative assessment of intertrochanteric femur fractures. *J Biol Regul Homeost Agents* 2020; **34**: 345-351 [PMID: [33261299](#)]
- 14 **Méndez-Ojeda MM**, Herrera-Rodríguez A, Álvarez-Benito N, González-Pacheco H, García-Bello MA, Álvarez-de la Cruz J, Pais-Brito JL. Treatment of Trochanteric Hip Fractures with Cephalomedullary Nails: Single Head Screw vs. Dual Integrated Compression Screw Systems. *J Clin Med* 2023; **12** [PMID: [37240518](#) DOI: [10.3390/jcm12103411](#)]
- 15 **Zeelenberg ML**, Nugteren LHT, Plaisier AC, Loggers SAI, Joosse P, Den Hartog D, Verhofstad MHJ, van Lieshout EMM; STABLE-HIP Study Group. Extramedullary versus intramedullary fixation of stable trochanteric femoral fractures: a systematic review and meta-analysis. *Arch Orthop Trauma Surg* 2023; **143**: 5065-5083 [PMID: [37129692](#) DOI: [10.1007/s00402-023-04902-1](#)]
- 16 **Haidukewych GJ**, Berry DJ. Hip arthroplasty for salvage of failed treatment of intertrochanteric hip fractures. *J Bone Joint Surg Am* 2003; **85**: 899-904 [PMID: [12728042](#) DOI: [10.2106/00004623-200305000-00019](#)]
- 17 **Valera M**, Bonifacio L, Basman S. Outcome of surgery for unstable intertrochanteric fractures in octogenarians. *Malays Orthop J* 2014; **8**: 26-31 [PMID: [25279081](#) DOI: [10.5704/MOJ.1403.014](#)]
- 18 **Matre K**, Havelin LI, Gjertsen JE, Vinje T, Espehaug B, Fevang JM. Sliding hip screw versus IM nail in reverse oblique trochanteric and subtrochanteric fractures. A study of 2716 patients in the Norwegian Hip Fracture Register. *Injury* 2013; **44**: 735-742 [PMID: [23305689](#) DOI: [10.1016/j.injury.2012.12.010](#)]
- 19 **Ovesen O**, Andersen M, Poulsen T, Nymark T, Overgaard S, Rock ND. The trochanteric gamma nail versus the dynamic hip screw: a prospective randomised study. One-year follow-up of 146 intertrochanteric fractures. *Hip Int* 2006; **16**: 293-298 [PMID: [19219808](#) DOI: [10.1177/112070000601600409](#)]
- 20 **Luthringer TA**, Elbuluk AM, Behery OA, Cizmici Z, Deshmukh AJ. Salvage of failed internal fixation of intertrochanteric hip fractures: clinical and functional outcomes of total hip arthroplasty vs hemiarthroplasty. *Arthroplast Today* 2018; **4**: 383-391 [DOI: [10.1016/j.artd.2018.06.002](#)]
- 21 **Mabry TM**, Prpa B, Haidukewych GJ, Harmsen WS, Berry DJ. Long-term results of total hip arthroplasty for femoral neck fracture nonunion. *J Bone Joint Surg Am* 2004; **86**: 2263-2267 [PMID: [15466737](#) DOI: [10.2106/00004623-200410000-00019](#)]
- 22 **Goodnough LH**, Wadhwa H, Tigheelaar SS, DeBaun MR, Chen MJ, Graves ML, Gardner MJ. Indications for cement augmentation in fixation of geriatric intertrochanteric femur fractures: a systematic review of evidence. *Arch Orthop Trauma Surg* 2022; **142**: 2533-2544 [PMID: [33829301](#) DOI: [10.1007/s00402-021-03872-6](#)]
- 23 **Ibrahim I**, Appleton PT, Wixted JJ, DeAngelis JP, Rodriguez EK. Implant cut-out following cephalomedullary nailing of intertrochanteric femur fractures: Are helical blades to blame? *Injury* 2019; **50**: 926-930 [PMID: [30885393](#) DOI: [10.1016/j.injury.2019.02.015](#)]
- 24 **Baumgaertner MR**, Curtin SL, Lindskog DM, Keggi JM. The value of the tip-apex distance in predicting failure of fixation of peritrochanteric fractures of the hip. *J Bone Joint Surg Am* 1995; **77**: 1058-1064 [PMID: [7608228](#) DOI: [10.2106/00004623-199507000-00012](#)]
- 25 **Aicale R**, Maffulli N. Greater rate of cephalic screw mobilisation following proximal femoral nailing in hip fractures with a tip-apex distance (TAD) and a calcar referenced TAD greater than 25 mm. *J Orthop Surg Res* 2018; **13**: 106 [PMID: [29720223](#) DOI: [10.1186/s13018-018-0814-1](#)]
- 26 **Haynes RC**, Pöll RG, Miles AW, Weston RB. Failure of femoral head fixation: a cadaveric analysis of lag screw cut-out with the gamma locking nail and AO dynamic hip screw. *Injury* 1997; **28**: 337-341 [PMID: [9764228](#) DOI: [10.1016/s0020-1383\(97\)00035-1](#)]
- 27 **Lionel L**, Guido C, Rodrigo B, Danilo T, Jorge B, Carlos S. Salvage procedure for cut-through after surgical fixation of trochanteric fractures with TFN. *Eur J Orthop Surg Traumatol* 2022; **32**: 611-618 [PMID: [34052921](#) DOI: [10.1007/s00590-021-03021-0](#)]
- 28 **Dziadosz D**. Considerations with failed intertrochanteric and subtrochanteric femur fractures: how to treat, revise, and replace. *J Orthop Trauma* 2015; **29** Suppl 4: S17-S21 [PMID: [25756822](#) DOI: [10.1097/BOT.0000000000000289](#)]
- 29 **Angelini M**, McKee MD, Waddell JP, Haidukewych G, Schemitsch EH. Salvage of failed hip fracture fixation. *J Orthop Trauma* 2009; **23**: 471-478 [PMID: [19550237](#) DOI: [10.1097/BOT.0b013e3181acfc8e](#)]
- 30 **Zhang B**, Chiu KY, Wang M. Hip arthroplasty for failed internal fixation of intertrochanteric fractures. *J Arthroplasty* 2004; **19**: 329-333 [PMID: [15067646](#) DOI: [10.1016/j.arth.2003.10.010](#)]
- 31 **DeHaan AM**, Groat T, Priddy M, Ellis TJ, Duwelius PJ, Friess DM, Mirza AJ. Salvage hip arthroplasty after failed fixation of proximal femur fractures. *J Arthroplasty* 2013; **28**: 855-859 [PMID: [23489728](#) DOI: [10.1016/j.arth.2012.10.027](#)]
- 32 **Mortazavi SM**, R Greenky M, Bican O, Kane P, Parvizi J, Hozack WJ. Total hip arthroplasty after prior surgical treatment of hip fracture is it always challenging? *J Arthroplasty* 2012; **27**: 31-36 [PMID: [21798695](#) DOI: [10.1016/j.arth.2011.05.014](#)]
- 33 **Taheriazam A**, Saeidinia A. Salvage of failed dynamic hip screw fixation of intertrochanteric fractures. *Orthop Res Rev* 2019; **11**: 93-98 [PMID: [31686921](#) DOI: [10.2147/ORR.S215240](#)]
- 34 **Srivastav S**, Mittal V, Agarwal S. Total hip arthroplasty following failed fixation of proximal hip fractures. *Indian J Orthop* 2008; **42**: 279-286 [PMID: [19753153](#) DOI: [10.4103/0019-5413.41851](#)]
- 35 **Exaltacion JJ**, Incavo SJ, Mathews V, Parsley B, Noble P. Hip arthroplasty after intramedullary hip screw fixation: a perioperative evaluation. *J Orthop Trauma* 2012; **26**: 141-147 [PMID: [22011634](#) DOI: [10.1097/BOT.0b013e318221ea6b](#)]
- 36 **Douglas SJ**, Remily EA, Sax OC, Pervaiz SS, Delanois RE, Johnson AJ. How Does Conversion Total Hip Arthroplasty Compare to Primary? *J Arthroplasty* 2021; **36**: S155-S159 [PMID: [33422393](#) DOI: [10.1016/j.arth.2020.12.023](#)]
- 37 **Qin CD**, Helfrich MM, Fitz DW, Oyer MA, Hardt KD, Manning DW. Differences in Post-Operative Outcome Between Conversion and Primary Total Hip Arthroplasty. *J Arthroplasty* 2018; **33**: 1477-1480 [PMID: [29295772](#) DOI: [10.1016/j.arth.2017.11.039](#)]



Vancomycin flushing syndrome in orthopaedic practice: A case report

Fawaz M Al-Anii, Mir Sadat-Ali, Khalid Waleed Al-Tabash, Ahmad I AlMulhim, Sulaiman A AlMousa, Abdulaziz M AlHawas

Specialty type: Orthopedics

Provenance and peer review:

Unsolicited article; Externally peer reviewed.

Peer-review model: Single blind

Peer-review report's scientific quality classification

Grade A (Excellent): 0

Grade B (Very good): 0

Grade C (Good): C

Grade D (Fair): 0

Grade E (Poor): 0

P-Reviewer: Surani S, United States

Received: June 13, 2023

Peer-review started: June 13, 2023

First decision: August 16, 2023

Revised: August 16, 2023

Accepted: September 7, 2023

Article in press: September 7, 2023

Published online: October 18, 2023



Fawaz M Al-Anii, Mir Sadat-Ali, Khalid Waleed Al-Tabash, Ahmad I AlMulhim, Sulaiman A AlMousa, Abdulaziz M AlHawas, Orthopaedic Surgery, Imam AbdulRahman Bin Faisal University and King Fahd Hospital of the University, AlKhobar 31952, Saudi Arabia

Corresponding author: Mir Sadat-Ali, FRCS, FRCS (Gen Surg), MBBS, MS, Full Professor, Professor, Senior Scientist, Orthopaedic Surgery, Imam AbdulRahman Bin Faisal University and King Fahd Hospital of the University, Pobox 40071, AlKhobar 31952, Saudi Arabia.
drsadat@hotmail.com

Abstract

BACKGROUND

Vancomycin flushing syndrome (VFS), also known as red man syndrome, is an allergic reaction to vancomycin. It typically presents as a rash on the face, neck, and upper torso after intravenous administration of vancomycin. VFS is blamed on rapid intravenous infusion of vancomycin during management and rarely happens after local use. A review of the literature showed that in the last 23 years, 4 such cases have been reported. Here, we add another case of VFS developed after slow local absorption of vancomycin in cement beads.

CASE SUMMARY

A 44-year-old male with a known case of hypertension, no history of allergies to medications, and a history of chronic osteomyelitis of the right tibia with discharging sinus over the anterolateral aspect of the leg. The pus culture grew *Staphylococcus aureus*, which was sensitive to clindamycin and vancomycin. The patient underwent irrigation and debridement with the placement of vancomycin cement beads made from 4 g of vancomycin powder and 40 g of polymethyl methacrylate. Three hours postoperatively, the patient developed a pruritic, erythematous, macular rash predominantly on his face, neck, chest, and lower extremities and to a lesser extent his upper extremities. A diagnosis of VFS was made and was successfully treated with cetirizine (10 mg, oral) and methylprednisolone sodium succinate (125 mg, intravenous). The patient continued to have itching with a facial rash for 12 h with gradual improvement. A decision was made to not remove the beads as the patient continued to improve. Gradually, the rash disappeared after 96 h with no further sequela.

CONCLUSION

VFS can occur not only after rapid intravenous injection of vancomycin but also

with local release, as in our case. As orthopaedic surgeons routinely use vancomycin with polymethyl methacrylate in chronic osteomyelitis and revision arthroplasty, they should be aware of such a complication occurring.

Key Words: Vancomycin; Anaphylactic reactions; Red man syndrome; Vancomycin flushing syndrome; Case report

©The Author(s) 2023. Published by Baishideng Publishing Group Inc. All rights reserved.

Core Tip: Vancomycin-related allergic skin reactions are not uncommon and are typically reported to occur after rapid intravenous infusion. However, this complication can also occur when vancomycin is implanted for slow release. Since orthopaedic surgeons routinely use vancomycin with polymethyl methacrylate, they should be aware of this complication occurring despite its rarity.

Citation: Al-Anii FM, Sadat-Ali M, Al-Tabash KW, AlMulhim AI, AlMousa SA, AlHawas AM. Vancomycin flushing syndrome in orthopaedic practice: A case report. *World J Orthop* 2023; 14(10): 771-775

URL: <https://www.wjgnet.com/2218-5836/full/v14/i10/771.htm>

DOI: <https://dx.doi.org/10.5312/wjo.v14.i10.771>

INTRODUCTION

Vancomycin inhibits cell wall synthesis of bacteria, making it a potent bactericidal against the majority of Gram-positive cocci[1]. Even though it has its own complications of resistance and other allergic reactions, it is still in use. One of the serious complications of using vancomycin is vancomycin flushing syndrome (VFS), also known as Red man syndrome (RMS), which is an anaphylactoid reaction. It presents as a pruritic, erythematous rash on the face, neck, and upper torso, hypotension, angioedema, and cardiac arrest[2-5]. The initial reports of this complication were reported due to rapid infusion of vancomycin at 1000 mg over 1 h[6]. Later reports did suggest it can happen even after slow infusion as well[7].

Vancomycin is routinely used in orthopaedic practice preoperatively as a prophylactic antibiotic and postoperatively to treat bone and joint infections[8,9]. Serious allergic reactions like VFS can occur. VFS developed in our patient with chronic osteomyelitis after the insertion of vancomycin-impregnated beads. A review of the literature on VFS in orthopaedic patients showed that 4 cases of VFS occurring after local implantation have been reported in the last 23 years (Table 1)[10-13].

CASE PRESENTATION

Chief complaints

A 44-year-old male presented with chronic osteomyelitis of the right tibia. The patient presented to the orthopaedic clinic due to right leg pain and swelling, the inability to bear weight, and multiple attacks of subjective fever. The right leg pain suddenly progressed over the prior 3 mo, without a history of recent trauma. The pain increased at night and later became constant even during rest. The pain was located mainly on the proximal right tibia with radiation to the right knee and middle third of the right leg. The patient also experienced multiple attacks of fever and night sweats.

History of present illness

The patient had an open fracture 22 years ago with an infection and was diagnosed with chronic osteomyelitis with a discharging sinus. The sinus had closed, but the pain continued. He was treated with evacuation of the abscess and courses of antibiotics.

History of past illness

The patient had a history of hypertension.

Personal and family history

No personal or family history relevant to the presentation. No history of allergy to medications was reported.

Physical examination

On inspection, there was swelling of the right leg and skin redness on the anterior aspect of the proximal third of the right leg. We observed a skin scar with thin scar tissue over the tibia directly. There was no underlying soft tissue on the anterior aspect of the proximal right tibia with massive swelling and tenderness around this area. The patient had an intact neurovascular examination.

Table 1 Review of literature of vancomycin flushing syndrome after local implantation of vancomycin

Ref.	Vancomycin used	Outcome
Hinarejos <i>et al</i> [10], 2015	Bone cement	Recovered
Juyal <i>et al</i> [12], 2015	Bone cement beads	Recovered
Chen <i>et al</i> [11], 2018	Cement spacer	Recovered
Harper and Incavo[13], 2019	Cement spacer	Recovered
Present case, 2023	Bone cement beads	Recovered

Laboratory examinations

Laboratory findings included slightly increased leukocytes ($12.3 \times 10^9/L$; normal range: $4.5\text{--}11.0 \times 10^9/L$), haematocrit (40.2%; normal range: 41%–50%), platelets (522,000 mcL; normal range: 150,000 to 450,000 mcL), elevated erythrocyte sedimentation rate (95 mm/h, normal range: < 20 mm/h), and high C-reactive protein (133 mg/L; normal range: 0–10 mg/L). The patient had a discharging sinus on the anterior proximal third of the right leg in the centre of the previous scar. Culture from the sinus grew *Staphylococcus aureus*.

Imaging examinations

Anteroposterior and lateral X-ray views showed multiple opacities, and magnetic resonance imaging showed a collection with high signal intensity in the proximal right tibia. The radiological studies revealed an intramedullary collection of the proximal right tibia with the impression of subacute osteomyelitis with multiple Brodie's abscesses of the proximal right tibia (Figure 1).

FINAL DIAGNOSIS

Chronic osteomyelitis of the right tibia.

TREATMENT

The patient underwent irrigation and debridement with the placement of vancomycin cement beads made from 4 g of vancomycin powder and 40 g of cement (1 g of vancomycin for each 10 g of cement) attached to size 1 proline and was placed intramedullary in the cavity through the two bone windows on the proximal and mid right tibia. Three hours postoperatively, the patient developed a pruritic, erythematous, macular rash predominantly on his face, neck, chest, and lower extremities and to a lesser extent his upper extremities. There were no signs of vital instability observed at the time (maximum area of skin rash was the infected, right lower limb and the patient's face and chest) (Figure 2). The patient started to become agitated due to itchiness. However, he remained clearly conscious, and the fine oxygen saturation was 98% in room air. The patient remained stable.

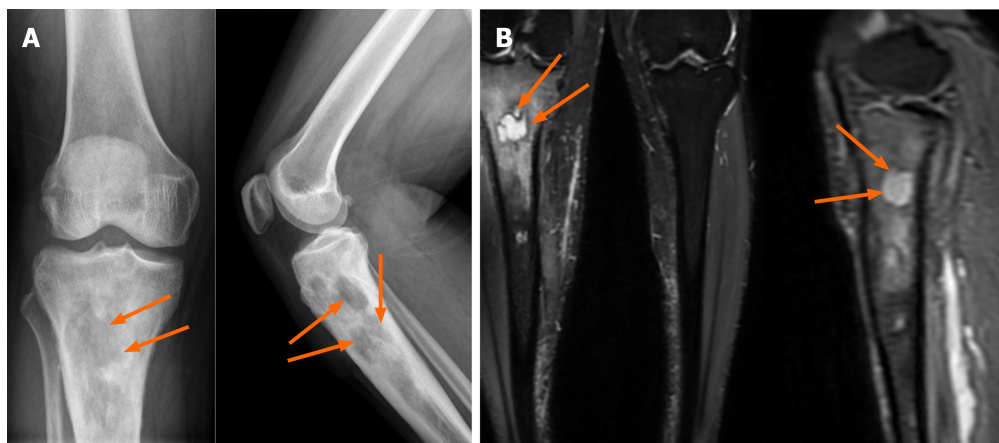
Urgent consultation of the on-call medical and infectious disease teams was completed; they examined the patient and recommended starting the patient immediately on cetirizine (10 mg, oral) and methylprednisolone sodium succinate (125 mg, intravenously). The patient continued to experience itching with a facial rash for 12 h with gradual improvement after therapy. He remained on close observation with close monitoring of respiration and other vital signs. The orthopaedic team made the decision to remove the antibiotics beads only if the patient hemodynamically deteriorated. The patient showed marked improvement 18 h after starting the medications; gradually, the rash started to decrease until it completely disappeared after around 96 h with no further sequela.

OUTCOME AND FOLLOW-UP

The beads were removed 4 mo postoperatively. The patient also received progressive irrigation and debridement with bone graft to the distal metaphyseal bone defect (window). The patient completed the antibiotics course according to the infectious disease team's recommendation (2 wk parenteral and 10 wk oral).

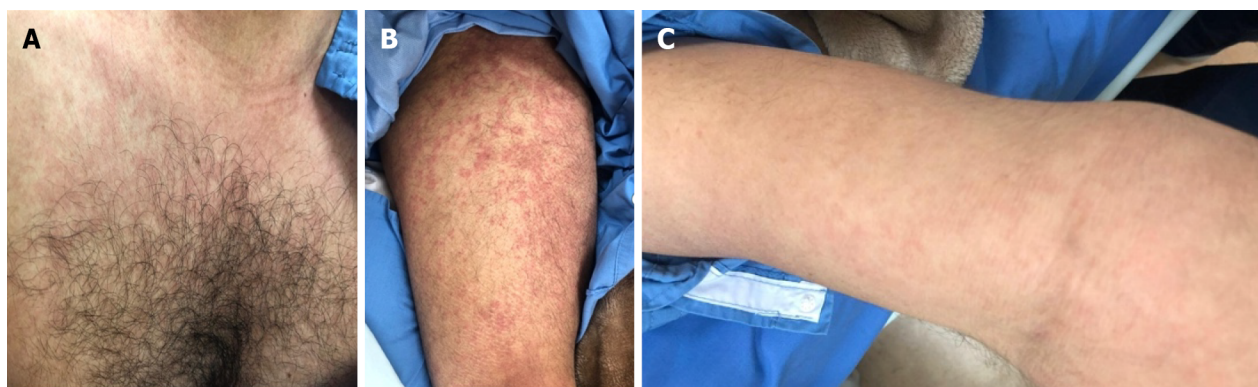
DISCUSSION

Our patient who developed VFS due to vancomycin exposure during after a prolonged release was contrary to the initial reports of rapid infusion being the cause of VFS. Only 4 other orthopaedic cases in the last two decades have been reported where the complication occurred due to the slow release of vancomycin. It is believed that the side effects are



DOI: 10.5312/wjo.v14.i10.771 Copyright ©The Author(s) 2023.

Figure 1 Imaging examinations. A: An X-ray showed changes of chronic osteomyelitis in the right upper tibia; B: Magnetic resonance imaging showed changes of chronic osteomyelitis with abscess formation in the right upper tibia. The arrows indicate cavitation and changes due to chronic osteomyelitis.



DOI: 10.5312/wjo.v14.i10.771 Copyright ©The Author(s) 2023.

Figure 2 Allergic reactions due to vancomycin. A: Chest; B: Legs; C: Forearm.

due to impurities. However, even after increasing the purity, the side effects still occur. At present, it is recommended that vancomycin should be infused at a rate no faster than 1 g/h or 10 mg/min[13,14].

There are two issues that need to be addressed. Vancomycin induces allergic reactions due to its activation of mast cells, which release histamine independent of preformed immunoglobulin E or complement. The side effects range from pruritis to angioedema to cardiac arrest. It is prudent that antihistamines are started at the same time as vancomycin to avoid the reactions.

Secondly, the term “RMS” needs to be retired from the medical language as this term has racial implications relating to native American nations. Because reactions to vancomycin are not known to be race dependent and occur in children and women, RMS is a misnomer. Hence the term VFS should be used.

CONCLUSION

In conclusion, VFS can occur either through rapid infusion or slow release of vancomycin, as in our patient. Since vancomycin-impregnated cement beads and spacers are routinely used in orthopaedic service, orthopaedic surgeons and trainees should be aware of such complications and should be ready to recognize and treat them early.

FOOTNOTES

Author contributions: Al-Anii FM, Sadat-Ali M, Al-Tabash KW, AlMulhim AI, AlMousa SA, and AlHawas AM participated in the study of the case, review of the literature, and the writing of the manuscript.

Informed consent statement: Informed consent was obtained from the patient to publish the photographs and the data.

Conflict-of-interest statement: All authors declare there are no conflicts of interests.

CARE Checklist (2016) statement: The authors have read the CARE Checklist (2016), and the manuscript was prepared and revised according to the CARE Checklist (2016).

Open-Access: This article is an open-access article that was selected by an in-house editor and fully peer-reviewed by external reviewers. It is distributed in accordance with the Creative Commons Attribution NonCommercial (CC BY-NC 4.0) license, which permits others to distribute, remix, adapt, build upon this work non-commercially, and license their derivative works on different terms, provided the original work is properly cited and the use is non-commercial. See: <https://creativecommons.org/licenses/by-nc/4.0/>

Country/Territory of origin: Saudi Arabia

ORCID number: Fawaz M Al-Anii 0000-0001-6264-1207; Mir Sadat-Ali 0000-0001-8590-0830; Khalid Waleed Al-Tabash 0000-0001-9996-099X.

S-Editor: Chen YL

L-Editor: Filipodia

P-Editor: Chen YL

REFERENCES

- 1 Moellering RC Jr. Vancomycin: a 50-year reassessment. *Clin Infect Dis* 2006; **42** Suppl 1: S3-S4 [PMID: 16323117 DOI: 10.1086/491708]
- 2 Crumpton MW, Thornton JB, Mackall LL. Anaphylactoid reaction to vancomycin during general anesthesia in a child patient. *Pediatr Dent* 1983; **5**: 276-279 [PMID: 6587333]
- 3 Symons NL, Hobbes AF, Leaver HK. Anaphylactoid reactions to vancomycin during anaesthesia: two clinical reports. *Can Anaesth Soc J* 1985; **32**: 178-181 [PMID: 3986655 DOI: 10.1007/BF03010047]
- 4 Markman M, Lim HW, Bluestein HG. Vancomycin-induced vasculitis. *South Med J* 1986; **79**: 382-383 [PMID: 2937155 DOI: 10.1097/00007611-198603000-00033]
- 5 Khakurel S, Rawal S. Vancomycin induced cardiac arrest: a case report. *J Med Case Rep* 2021; **15**: 77 [PMID: 33593409 DOI: 10.1186/s13256-020-02639-8]
- 6 Polk RE, Healy DP, Schwartz LB, Rock DT, Garson ML, Roller K. Vancomycin and the red-man syndrome: pharmacodynamics of histamine release. *J Infect Dis* 1988; **157**: 502-507 [PMID: 2449506 DOI: 10.1093/infdis/157.3.502]
- 7 Arroyo JC, Rosansky SJ, Rosenzweig PN. Red neck syndrome with slow infusion of vancomycin. *Am J Kidney Dis* 1986; **7**: 511 [PMID: 2424306 DOI: 10.1016/s0272-6386(86)80194-9]
- 8 Kanj WW, Flynn JM, Spiegel DA, Dormans JP, Baldwin KD. Vancomycin prophylaxis of surgical site infection in clean orthopedic surgery. *Orthopedics* 2013; **36**: 138-146 [PMID: 23379827 DOI: 10.3928/01477447-20130122-10]
- 9 Molinari RW, Khera OA, Molinari WJ 3rd. Prophylactic intraoperative powdered vancomycin and postoperative deep spinal wound infection: 1,512 consecutive surgical cases over a 6-year period. *Eur Spine J* 2012; **21** Suppl 4: S476-S482 [PMID: 22160172 DOI: 10.1007/s00586-011-2104-z]
- 10 Hinarejos P, Guirio P, Puig-Verdie L, Torres-Claramunt R, Leal-Blanquet J, Sanchez-Soler J, Monllau JC. Use of antibiotic-loaded cement in total knee arthroplasty. *World J Orthop* 2015; **6**: 877-885 [PMID: 26716084 DOI: 10.5312/wjo.v6.i11.877]
- 11 Chen CT, Ng KJ, Lin Y, Kao MC. Red man syndrome following the use of vancomycin-loaded bone cement in the primary total knee replacement: A case report. *Medicine (Baltimore)* 2018; **97**: e13371 [PMID: 30572442 DOI: 10.1097/MD.00000000000013371]
- 12 Juyal A, Khurana G, Maheshwari R. Red man syndrome: an unusual complication of vancomycin beads. *Bangladesh J Med Sci* 2015; **14**: 290-291 [DOI: 10.3329/bjms.v14i3.17955]
- 13 Harper KD, Incavo SJ. Drug reaction with eosinophilia and systemic symptoms syndrome after total knee arthroplasty infection and placement of antibiotic spacer. *Arthroplast Today* 2019; **5**: 148-151 [PMID: 31286034 DOI: 10.1016/j.artd.2019.04.005]
- 14 Alvarez-Arango S, Ogunwale SM, Sequist TD, Burk CM, Blumenthal KG. Vancomycin Infusion Reaction - Moving beyond "Red Man Syndrome". *N Engl J Med* 2021; **384**: 1283-1286 [PMID: 33830710 DOI: 10.1056/NEJMp2031891]



Late brachial plexopathy after a mid-shaft clavicle fracture: A case report

Mohammad M Alzahrani

Specialty type: Orthopedics

Provenance and peer review:

Unsolicited article; Externally peer reviewed.

Peer-review model: Single blind

Peer-review report's scientific quality classification

Grade A (Excellent): 0
Grade B (Very good): B
Grade C (Good): C, C
Grade D (Fair): 0
Grade E (Poor): 0

P-Reviewer: Mesregah MK, Egypt;
Primadhi RA, Indonesia

Received: August 1, 2023

Peer-review started: August 1, 2023

First decision: September 4, 2023

Revised: September 5, 2023

Accepted: September 22, 2023

Article in press: September 22, 2023

Published online: October 18, 2023



Mohammad M Alzahrani, Department of Orthopaedic Surgery, College of Medicine, Imam Abdulrahman Bin Faisal University, Dammam 31441, Saudi Arabia

Corresponding author: Mohammad M Alzahrani, FRSC, MBBS, MSc, Assistant Professor, Department of Orthopaedic Surgery, College of Medicine, Imam Abdulrahman Bin Faisal University, King Faisal Road, Dammam 31441, Saudi Arabia. mmalzahrani@iau.edu.sa

Abstract

BACKGROUND

Clavicle fractures can rarely be associated with brachial plexus injury. These are commonly caused by tractional injury at the time of trauma, but unfrequently can be caused by compression of the brachial plexus from excessive callus or granulation tissue formation.

CASE SUMMARY

We report a rare case of an adult male who sustained a mid-shaft clavicle fracture and had a late presentation of brachial plexus palsy due to compression from excessive callus formation.

CONCLUSION

We reported a case of a rare occurrence of delayed brachial plexus palsy due to compression from excessive callus formation in a midshaft clavicle fracture. Early diagnosis and surgical decompression of the brachial plexus is critical, as when managed efficiently, a full recovery of the brachial plexus palsy can be expected in these patients.

Key Words: Clavicle; Fracture; Brachial plexus; Palsy; Case report

©The Author(s) 2023. Published by Baishideng Publishing Group Inc. All rights reserved.

Core Tip: Brachial plexus palsy due to compression from excessive callus formation in a midshaft clavicle fracture is a rare occurrence. We reported a case of a of delayed brachial plexus palsy due to compression from excessive callus formation in a midshaft clavicle fracture. Early diagnosis and surgical decompression of the brachial plexus is critical for improved patient outcomes.

Citation: Alzahrani MM. Late brachial plexopathy after a mid-shaft clavicle fracture: A case report. *World J Orthop* 2023; 14(10): 776-783

URL: <https://www.wjgnet.com/2218-5836/full/v14/i10/776.htm>

DOI: <https://dx.doi.org/10.5312/wjo.v14.i10.776>

INTRODUCTION

Clavicle fractures are a common injury in the adult population, accounting for 2%-3% of all fractures[1-3]. While these injuries are common, an associated brachial plexus injury is considered rare with an incidence of less than 1%, while this incidence can reach 2% in displaced fractures[4,5]. These brachial plexus injuries commonly occur due to tractional injury at the time of trauma. A rare cause of brachial plexus lesion is compression due to excessive callus or granulation tissue formation and these patients typically have a late presentation[6,7].

CASE PRESENTATION

Chief complaints

A 58-year-old male was involved in a frontal impact motor vehicle accident as a restrained driver. Patient had no history of loss of consciousness and was brought by ambulance to the emergency department. Primary survey was found to be normal, while on secondary survey patient was found to have tenderness over the right clavicle with obvious deformity. In addition, patient had limited right shoulder range of motion in all planes due to severe pain. Plain radiographs diagnosed multiple right sided rib fractures (which were managed conservatively) and a right mid-shaft comminuted clavicle fracture. Neurological and vascular exam was found to be normal at the time of the initial assessment and there was no sign of skin tenting or skin breakage over the clavicle fracture.

History of present illness

Patient was immobilized in a sling and discharged with a follow up in the orthopaedic clinic in 2 wk. At the time of the follow up 2 wk post-injury, plain radiographs were performed again and re-documented a displaced mid-shaft comminuted clavicle fracture (Figure 1A). Patient again was found to have tenderness over a deformed right clavicle with pain and limited right shoulder range of motion. The neurological and vascular exam of the right upper extremity was still found to be normal. Patient was offered open reduction and internal fixation of the clavicle fracture, but patient declined surgery and opted for conservative management and was given follow up in 4 wk.

At the time of the 4 wk follow up, patients' tenderness over the right clavicle improved and follow up imaging showed progression of callus formation at the fracture site (Figure 1B). Interestingly, patient was complaining to intermittent right upper extremity mild to moderate shooting pain but was found to have a normal motor and sensory exam of the extremity.

History of past illness

There was no significant past medical illness.

Personal and family history

There was no significant personal and family history.

Physical examination

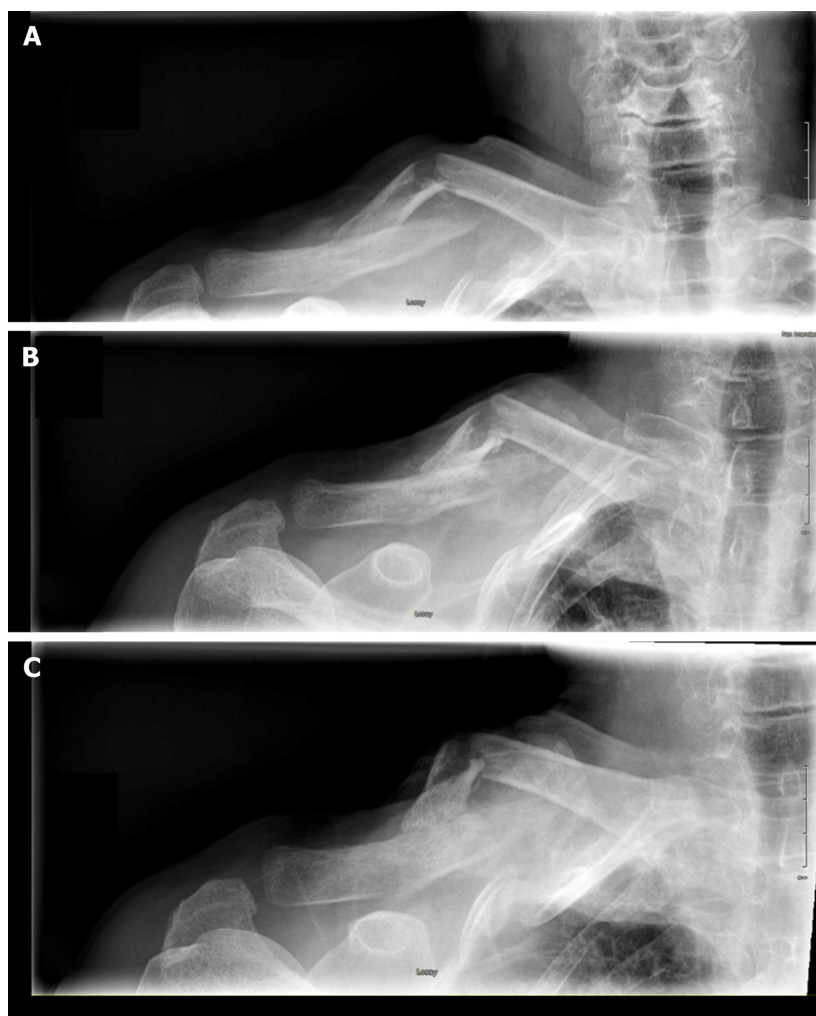
At the following office visit at 3 mo post-injury, the patient's shoulder and clavicle pain resolved, but patient was complaining of significant right upper extremity weakness, with inability to hold a cup in his hand and decreased grip strength. On further history, patient also gave history of loss of sensation in the hand and forearm region (C7, C8 and T1 distribution). On physical exam there was resolution of the localized right clavicle tenderness with a large bony deformity in the region. Motor power showed weakness in right upper extremity muscle power globally, but more pronounced in finger flexion, adduction and abduction, in addition to weakness in thumb flexion and adduction. On sensory exam, there was loss of sensation over the ulnar aspect of the hand and medial forearm. Distal pulses were present, including radial and ulnar pulses at the wrist.

Laboratory examinations

There were no significant laboratory examinations.

Imaging examinations

Plain radiograph of the clavicle showed large formation of callus at the fracture site (Figure 1C). A computed tomography (CT) scan was performed which confirmed the midshaft comminuted fracture with hypertrophic callus formation around the fracture site (Figures 2 and 3). Due to the patient's neurological deficit, a magnetic resonance imaging (MRI) of the region was performed and showed that the hypertrophic callus formation was causing compression of the brachial plexus



DOI: 10.5312/wjo.v14.i10.776 Copyright ©The Author(s) 2023.

Figure 1 Antero-posterior right clavicle radiograph 2 wk, 6 wk and 3 mo post-injury. A: 2 wk; B: 6 wk; C: 3 mo.

trunks in the infraclavicular region (Figure 4).

A nerve conduction study was arranged for the patient. But as the patient was exhibiting significant neurological deficits due to brachial plexus compression from the hypertrophic callus formation, an urgent surgical decompression and clavicle open reduction internal fixation was planned.

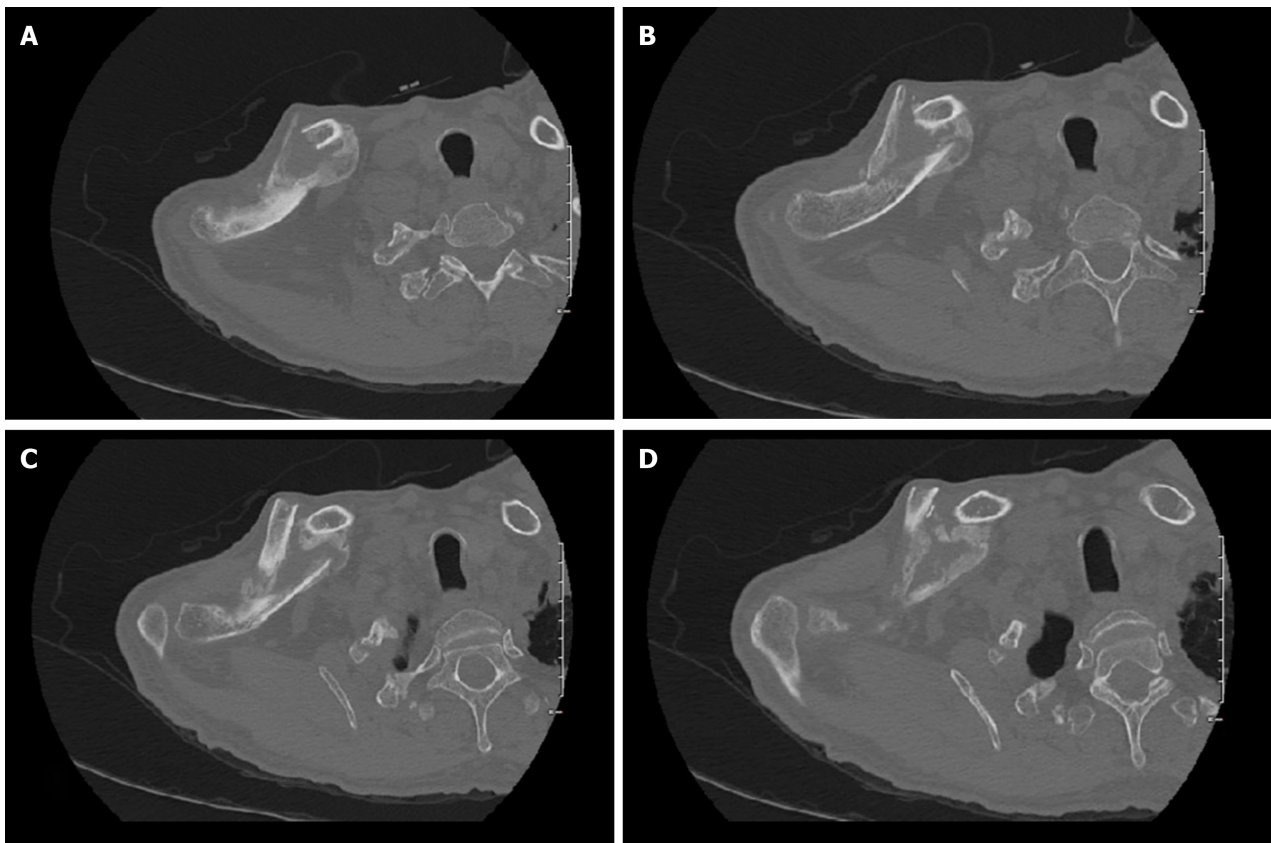
FINAL DIAGNOSIS

Right mid-shaft clavicle fracture with hypertrophic callus formation causing compression of the brachial plexus trunks in the infraclavicular region.

TREATMENT

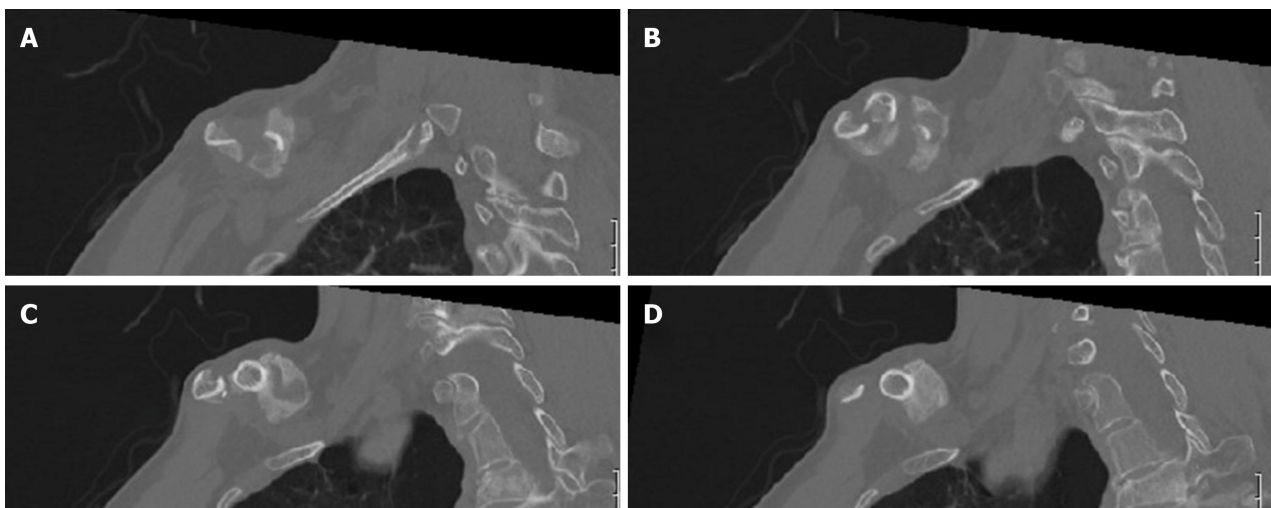
The surgery was performed under general anesthesia. After 2 g of intravenous cefazolin was administered, the patient was positioned in the supine position and the right upper extremity was sterilely prepped and draped up to the mid-sternal region. A direct surgical incision over the right clavicle was performed extending from the sternoclavicular joint medial to the distal clavicle laterally. The incision was performed through skin and subcutaneous tissue and hemostasis was obtained. Due to the mass effect of the callus formation over the fracture site, only a thin layer of muscle and fascia was identified and was sharply dissected through. Normal clavicle bone both medial and laterally to the fracture site was exposed to allow application of the internal fixation.

Once adequate exposure was obtained, the area of the bridging callus was carefully osteotomized using small osteotomes and a small handheld burr. The callus was then excised using the burr and small rongeur until the native fracture site was identified. After complete removal and decompression of the hypertrophic callus (Figure 5), we identified the medial and lateral end of the fracture with a small butterfly piece. We confirmed that the infra-clavicular



DOI: 10.5312/wjo.v14.i10.776 Copyright ©The Author(s) 2023.

Figure 2 Sequential axial images of non-contrast computed tomography scan. A-D: At 3 mo post-injury showing mid-shaft clavicle fracture with abundant callus formation.

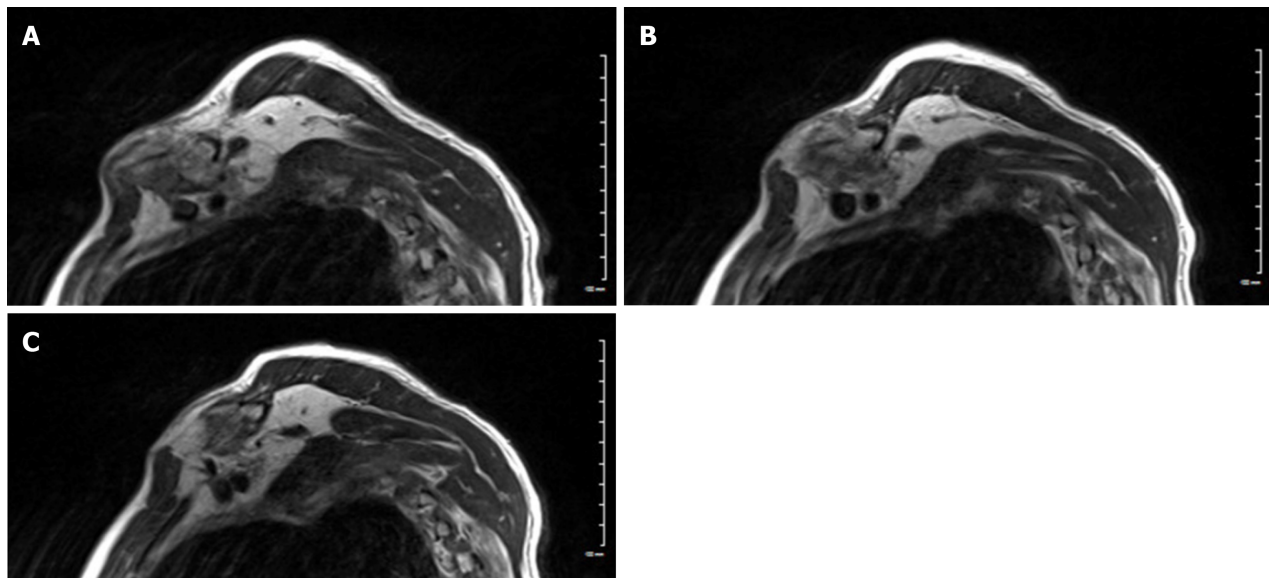


DOI: 10.5312/wjo.v14.i10.776 Copyright ©The Author(s) 2023.

Figure 3 Sequential sagittal images of non-contrast computed tomography scan. A-D: At 3 mo post-injury showing mid-shaft clavicle fracture with abundant callus formation.

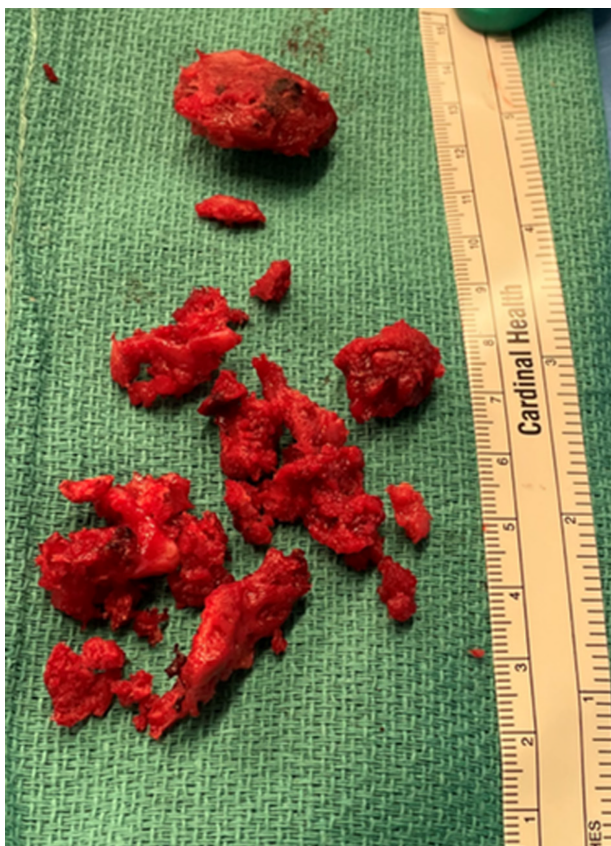
region was decompressed, and no remanent callus or granulation tissue was still present.

The comminuted fracture was then reduced and held provisionally with pointed reduction clamps and then provisionally fixed with an anterior contoured 2.7 mm reconstruction plate and then a superior pre-contoured 3.5 mm clavicular plate was applied. Intra-operative fluoroscopic images were obtained confirming adequate fracture reduction and implant positioning (Figure 6). The wound was then copiously irrigated with normal saline. The wound was closed in layers and a sterile dressing was applied.



DOI: 10.5312/wjo.v14.i10.776 Copyright ©The Author(s) 2023.

Figure 4 Sequential sagittal T2 weighted images of magnetic resonance imaging scan. A-C: At 3 mo post-injury showing mid-shaft clavicle fracture with abundant callus formation causing a mass effect on adjacent brachial plexus trunks.

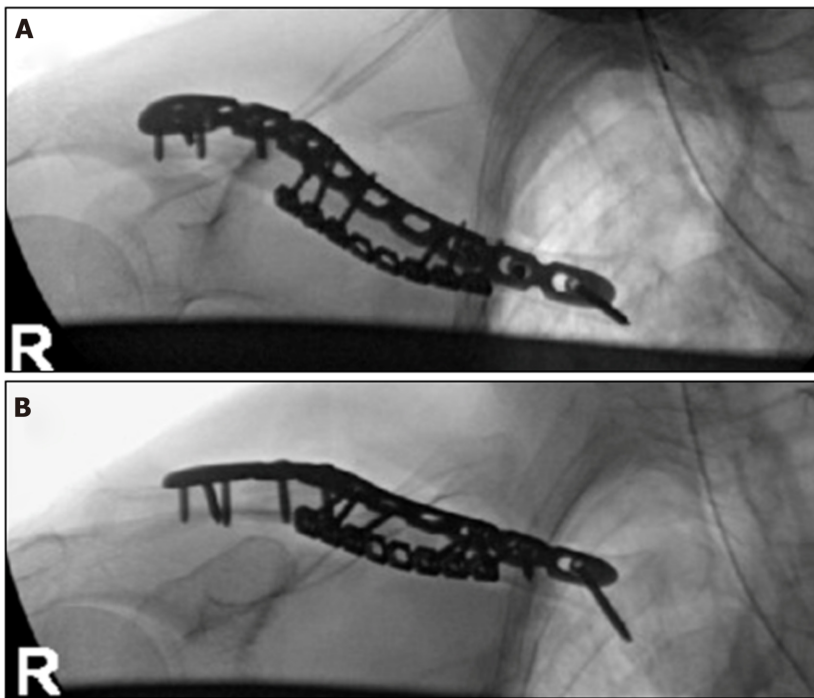


DOI: 10.5312/wjo.v14.i10.776 Copyright ©The Author(s) 2023.

Figure 5 Clinical intra-operative picture showing the excised hypertrophied callus after surgical decompression.

OUTCOME AND FOLLOW-UP

Patient was allowed gentle shoulder range of motion but instructed to avoid any weight bearing through the right upper extremity for the first six weeks post-operatively. In the early post-operative phase, patient noted significant improvement in his symptoms and formal physical therapy was initiated at 6 wk post-operatively.



DOI: 10.5312/wjo.v14.i10.776 Copyright ©The Author(s) 2023.

Figure 6 Superior and anteroposterior radiographs of right clavicle after open reduction and internal fixation. A: Superior radiographs; B: Anteroposterior radiographs.

At both 3 and 6 mo follow ups the patient noted improved motor function of the hand and gradual resolution of his sensory deficits. He also indicated improvement of the radiculopathic pain in the right upper extremity. Plain radiographs of the right clavicle showed progression of the fracture healing and maintained implant fixation (Figure 7).

DISCUSSION

Brachial plexus injuries are rarely caused by clavicle fractures with the majority of cases being caused by tractional injury at the time of trauma, which commonly affect the supraclavicular region of the brachial plexus. Della Santa *et al* [7] reported an incidence of only 1% of clavicle fractures associated with brachial plexus palsy during a 20-year period.

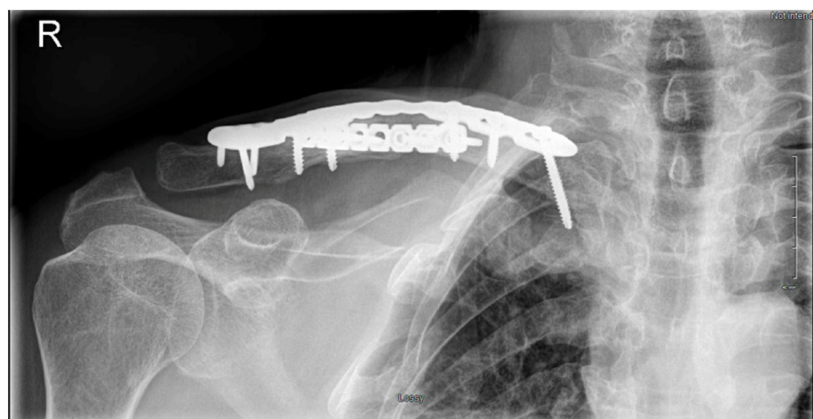
In our case report, the patient had a delayed palsy of the brachial plexus due to compression from the excessive callus formation. This entity is considered extremely rare, with only some case reports and case series reported in the literature [6-9]. The resultant compression can be due to excessive callus or granulation tissue formation, hypertrophic nonunion or vascular pseudo-aneurysm [10-12]. Commonly this compression affects the infra- or retroclavicular region of the brachial plexus, and these patients have a delayed presentation with late onset neurological deficits in the ipsilateral upper extremity [8,11,13].

A high index of suspicion and careful physical exam are required to avoid misdiagnosis and delay in management. Documentation of motor and sensory exam both at the time of injury and in subsequent visits is critical to identify any evidence of brachial plexus palsy in the early phase. In addition, adequate plain radiographs and CT scan can identify any excessive callus formation or hypertrophic nonunion as the cause of compression. A CT angiogram can be indicated to rule out a subclavian pseudoaneurysm as the cause of compression [12]. Documentation of brachial plexus compression can be identified with an MRI of the clavicular and brachial plexus region, which can also identify other causes of compression (*i.e.*, excessive granulation tissue). Nerve conduction studies and electromyography can also help identify level of compression and involved brachial plexus region.

Management of these injuries involves decompression of the brachial plexus and open reduction internal fixation of the associated clavicle fracture. Typically, these injuries have good prognosis when compared to injuries due to tractional injuries [7,8,13]. The majority of patients can be expected to have a complete neurological recovery once the brachial plexus is decompressed, and fracture adequately stabilized [4,9,14].

CONCLUSION

We reported a case of a rare occurrence of delayed brachial plexus palsy due to compression from excessive callus formation in a midshaft clavicle fracture. Early diagnosis and surgical decompression of the brachial plexus is critical, as when managed efficiently, a full recovery of the brachial plexus palsy can be expected in these patients.



DOI: 10.5312/wjo.v14.i10.776 Copyright ©The Author(s) 2023.

Figure 7 Anteroposterior radiographs of right clavicle at 3 mo post-surgery showing progression of the fracture healing and maintained implant fixation.

FOOTNOTES

Author contributions: Alzahrani MM contributed to the concept, design, study execution, manuscript writing and review.

Informed consent statement: The patient was informed that data concerning the case would be submitted for publication and patient agreed.

Conflict-of-interest statement: The author has no relevant conflict of interests.

CARE Checklist (2016) statement: The authors have read the CARE Checklist (2016), and the manuscript was prepared and revised according to the CARE Checklist (2016).

Open-Access: This article is an open-access article that was selected by an in-house editor and fully peer-reviewed by external reviewers. It is distributed in accordance with the Creative Commons Attribution NonCommercial (CC BY-NC 4.0) license, which permits others to distribute, remix, adapt, build upon this work non-commercially, and license their derivative works on different terms, provided the original work is properly cited and the use is non-commercial. See: <https://creativecommons.org/licenses/by-nc/4.0/>

Country/Territory of origin: Saudi Arabia

ORCID number: Mohammad M Alzahrani 0000-0003-1299-1529.

S-Editor: Wang JJ

L-Editor: A

P-Editor: Zhang YL

REFERENCES

- 1 Postacchini F, Gumina S, De Santis P, Albo F. Epidemiology of clavicle fractures. *J Shoulder Elbow Surg* 2002; **11**: 452-456 [PMID: 12378163 DOI: 10.1067/mse.2002.126613]
- 2 Kihlström C, Möller M, Lönn K, Wolf O. Clavicle fractures: epidemiology, classification and treatment of 2 422 fractures in the Swedish Fracture Register; an observational study. *BMC Musculoskelet Disord* 2017; **18**: 82 [PMID: 28202071 DOI: 10.1186/s12891-017-1444-1]
- 3 Alzahrani MM, Cota A, Alkhelaifi K, Aleidan A, Berry G, Reindl R, Harvey E. Are clinical outcomes affected by type of plate used for management of mid-shaft clavicle fractures? *J Orthop Traumatol* 2018; **19**: 8 [PMID: 30112628 DOI: 10.1186/s10195-018-0492-0]
- 4 Saito T, Matusmura T, Takeshita K. Brachial plexus palsy after clavicle fracture: 3 cases. *J Shoulder Elbow Surg* 2020; **29**: e60-e65 [PMID: 31784383 DOI: 10.1016/j.jse.2019.09.027]
- 5 Kim MS. Conservative treatment for brachial plexus injury after a displaced clavicle fracture: a case report and literature review. *BMC Musculoskelet Disord* 2022; **23**: 632 [PMID: 35780083 DOI: 10.1186/s12891-022-05601-5]
- 6 Chen CE, Liu HC. Delayed brachial plexus neurapraxia complicating malunion of the clavicle. *Am J Orthop (Belle Mead NJ)* 2000; **29**: 321-322 [PMID: 10784023]
- 7 Della Santa D, Narakas A, Bonnard C. Late lesions of the brachial plexus after fracture of the clavicle. *Ann Chir Main Memb Super* 1991; **10**: 531-540 [PMID: 1725119 DOI: 10.1016/s0753-9053(05)80325-4]
- 8 Kay SP, Eckardt JJ. Brachial plexus palsy secondary to clavicular nonunion. Case report and literature survey. *Clin Orthop Relat Res* 1986; 219-222 [PMID: 3708979]
- 9 Rumball KM, Da Silva VF, Preston DN, Carruthers CC. Brachial-plexus injury after clavicular fracture: case report and literature review. *Canadian J Surg* 1991; **34**: 264-266

- 10 **Thavarajah D**, Scadden J. Iatrogenic postoperative brachial plexus compression secondary to hypertrophic non-union of a clavicle fracture. *Ann R Coll Surg Engl* 2013; **95**: e55-e57 [PMID: [23827280](#) DOI: [10.1308/003588413X13511609956174](#)]
- 11 **Gadinsky NE**, Smolev ET, Ricci MJ, Mintz DN, Wellman DS. Two cases of brachial plexus compression secondary to displaced clavicle fractures. *Trauma Case Rep* 2019; **23**: 100219 [PMID: [31467966](#) DOI: [10.1016/j.tcr.2019.100219](#)]
- 12 **Hansky B**, Murray E, Minami K, Körfer R. Delayed brachial plexus paralysis due to subclavian pseudoaneurysm after clavicular fracture. *Eur J Cardiothorac Surg* 1993; **7**: 497-498 [PMID: [8217229](#) DOI: [10.1016/1010-7940\(93\)90281-f](#)]
- 13 **Barbier O**, Malghem J, Delaere O, Vande Berg B, Rombouts JJ. Injury to the brachial plexus by a fragment of bone after fracture of the clavicle. *J Bone Joint Surg Br* 1997; **79**: 534-536 [PMID: [9250732](#) DOI: [10.1302/0301-620x.79b4.7552](#)]
- 14 **McGillivray MK**, Doherty C, Bristol SG, Lawlor DK, Baxter KA, Lefaivre KA. Surgical Management of Delayed Brachial Plexopathy After Clavicle Nonunion. *J Orthop Trauma* 2022; **36**: e399-e404 [PMID: [34992193](#) DOI: [10.1097/BOT.0000000000002343](#)]



Published by **Baishideng Publishing Group Inc**
7041 Koll Center Parkway, Suite 160, Pleasanton, CA 94566, USA

Telephone: +1-925-3991568

E-mail: bpgoffice@wjgnet.com

Help Desk: <https://www.f6publishing.com/helpdesk>

<https://www.wjgnet.com>

