

World Journal of *Neurology*

World J Neurol 2022 November 15; 8(2): 10-13



CASE REPORT

- 10 Possible convulsion and electroencephalographic abnormality in a patient taking long-term oral clarithromycin: A case report

Shiraishi W

ABOUT COVER

Peer Reviewer of *World Journal of Neurology*, Ramazan Kahveci, MD, Assoc. Professor, Department of Neurosurgery, Health Practice and Research Hospital, Balıkesir University, Paşaköy, on Bigadiç road, 10145 Balıkesir Center/Altieylül/Balıkesir, Turkey. ramazan.kahveci@balikesir.edu.tr

AIMS AND SCOPE

The primary aim of *World Journal of Neurology* (WJN, *World J Neurol*) is to provide scholars and readers from various fields of neurology with a platform to publish high-quality basic and clinical research articles and communicate their research findings online.

WJN mainly publishes articles reporting research results and findings obtained in the field of neurology and covering a wide range of topics including autoimmune diseases of the nervous system, autonomic nervous system diseases, central nervous system diseases, chronobiology disorders, cranial nerve diseases, demyelinating diseases, nervous system malformations, nervous system neoplasms, neurocutaneous syndromes, neurodegenerative diseases, neurologic manifestations, neuromuscular diseases, neurotoxicity syndromes, restless legs syndrome, sleep disorders, and nervous system trauma.

INDEXING/ABSTRACTING

The WJN is now abstracted and indexed in Reference Citation Analysis, China National Knowledge Infrastructure, China Science and Technology Journal Database, and Superstar Journals Database.

RESPONSIBLE EDITORS FOR THIS ISSUE

Production Editor: Xiang-Di Zhang; Production Department Director: Xu Guo; Editorial Office Director: Ji-Hong Lin.

NAME OF JOURNAL

World Journal of Neurology

ISSN

ISSN 2218-6212 (online)

LAUNCH DATE

December 28, 2011

FREQUENCY

Continuous Publication

EDITORS-IN-CHIEF

Bin Jiang

EDITORIAL BOARD MEMBERS

<https://www.wjnet.com/2218-6212/editorialboard.htm>

PUBLICATION DATE

November 15, 2022

COPYRIGHT

© 2022 Baishideng Publishing Group Inc

INSTRUCTIONS TO AUTHORS

<https://www.wjnet.com/bpg/gerinfo/204>

GUIDELINES FOR ETHICS DOCUMENTS

<https://www.wjnet.com/bpg/GerInfo/287>

GUIDELINES FOR NON-NATIVE SPEAKERS OF ENGLISH

<https://www.wjnet.com/bpg/gerinfo/240>

PUBLICATION ETHICS

<https://www.wjnet.com/bpg/GerInfo/288>

PUBLICATION MISCONDUCT

<https://www.wjnet.com/bpg/gerinfo/208>

ARTICLE PROCESSING CHARGE

<https://www.wjnet.com/bpg/gerinfo/242>

STEPS FOR SUBMITTING MANUSCRIPTS

<https://www.wjnet.com/bpg/GerInfo/239>

ONLINE SUBMISSION

<https://www.f6publishing.com>



Possible convulsion and electroencephalographic abnormality in a patient taking long-term oral clarithromycin: A case report

Wataru Shiraishi

Specialty type: Neurosciences

Provenance and peer review:

Unsolicited article; Externally peer reviewed.

Peer-review model: Single blind

Peer-review report's scientific quality classification

Grade A (Excellent): 0
Grade B (Very good): B, B
Grade C (Good): 0
Grade D (Fair): 0
Grade E (Poor): 0

P-Reviewer: Bello AK, Nigeria;
Liao JX, China

Received: September 10, 2022

Peer-review started: September 10, 2022

First decision: October 24, 2022

Revised: October 25, 2022

Accepted: October 31, 2022

Article in press: October 31, 2022

Published online: November 15, 2022



Wataru Shiraishi, Department of Neurology, Kokura Memorial Hospital, Kitakyushu 802-8555, Fukuoka, Japan

Corresponding author: Wataru Shiraishi, MD, PhD, Deputy Director, Doctor, Department of Neurology, Kokura Memorial Hospital, 3-2-1 Asano, Kokurakita-ku, Kitakyushu 802-8555, Fukuoka, Japan. whitestone_db5@yahoo.co.jp

Abstract

BACKGROUND

Clarithromycin is a macrolide antibiotic commonly prescribed to patients with upper respiratory and otolaryngological infections. Neuropsychiatric adverse effects of clarithromycin include agitation, insomnia, delirium, psychosis, and seizure.

CASE SUMMARY

A 52-year-old man was admitted to our hospital with a convulsion. He had > 10-year history of clarithromycin intake for chronic sinusitis. One week before admission, he started to take diltiazem for angina pectoris. On admission, his convulsion subsided. His electroencephalography showed frontal intermittent rhythmic delta activity. One week after he ceased clarithromycin, his electroencephalographic abnormalities disappeared. We suggested that the patient developed convulsions due to increased blood levels of clarithromycin caused by oral administration of diltiazem, which is involved in CYP3A metabolism.

CONCLUSION

Clarithromycin has a relatively high safety profile and is a frequently prescribed drug. However, there are a few previous reports of clarithromycin-related convulsive disorders. Clinicians should be aware of the drug interaction and rare side effects of seizures.

Key Words: Clarithromycin; Convulsion; QT interval prolongation; Seizures; Case report

©The Author(s) 2022. Published by Baishideng Publishing Group Inc. All rights reserved.

Core Tip: Clarithromycin is a frequently used medication and has a long history of use. The rarity of reports of convulsions induced by clarithromycin suggests that the induction of convulsions by clarithromycin is a rare phenomenon or has been overlooked. Clarithromycin is a frequently prescribed drug but has many interactions. Therefore, we report this case as a cautionary statement for all neurologists. Also, the measurement of QT time may be a valuable method of assessing clarithromycin excess.

Citation: Shiraishi W. Possible convulsion and electroencephalographic abnormality in a patient taking long-term oral clarithromycin: A case report. *World J Neurol* 2022; 8(2): 10-13

URL: <https://www.wjgnet.com/2218-6212/full/v8/i2/10.htm>

DOI: <https://dx.doi.org/10.5316/wjn.v8.i2.10>

INTRODUCTION

Although many drugs are known to cause drug-induced seizures, there are very few reports of clarithromycin-induced seizures[1,2]. Clarithromycin is a macrolide antibiotic that is used frequently for upper respiratory tract infections and otolaryngological infections and is considered to be safe[3]. In this case report, we show a case of convulsions with electroencephalography (EEG) abnormalities in a patient who had been taking clarithromycin for over ten years. After the discontinuation of clarithromycin, the EEG abnormality disappeared, and there was no recurrence of convulsive seizures.

In this case, the QTc showed a prolonged tendency in the electrocardiography (ECG) during the convulsions, which may have reflected the excessive clarithromycin state. Thus, clarithromycin-induced epilepsy is sporadic, and we report this case based on a discussion of its pathophysiological mechanisms.

CASE PRESENTATION

Chief complaints

Seizure.

History of present illness

A 52-year-old Japanese male with no past history of seizure was admitted to our hospital with generalized tonic-clonic seizure.

History of past illness

A detailed interview revealed that the patient had been taking clarithromycin (400 mg/d) for > 10 years to treat chronic sinusitis and had recently added diltiazem (100 mg/d) for hypertension, as prescribed by his family doctor.

Personal and family history

Nothing particular.

Physical examination

On admission, his seizure subsided. His vital signs showed no remarkable abnormalities. He had bit his tongue, but no incontinence was observed. He was alert and showed no neurological deficits.

Laboratory examinations

Laboratory examination showed a mild increase of HbA1c (6.6%; normal, 4.6%-6.2%). Since it was a night emergency, the blood concentration of clarithromycin could not be measured. No other abnormalities, including electrolytes, serum creatine phosphokinase, and lactate, were observed. Electroencephalography (EEG) showed frequent frontal intermittent rhythmic delta activities (FIRDA) (Figure 1A). On ECG, his QTc interval was 448 milliseconds (Bazett's formula[4]; normal, < 450 milliseconds[5]).

Imaging examinations

Head computed tomography, and magnetic resonance imaging revealed no brain abnormalities.

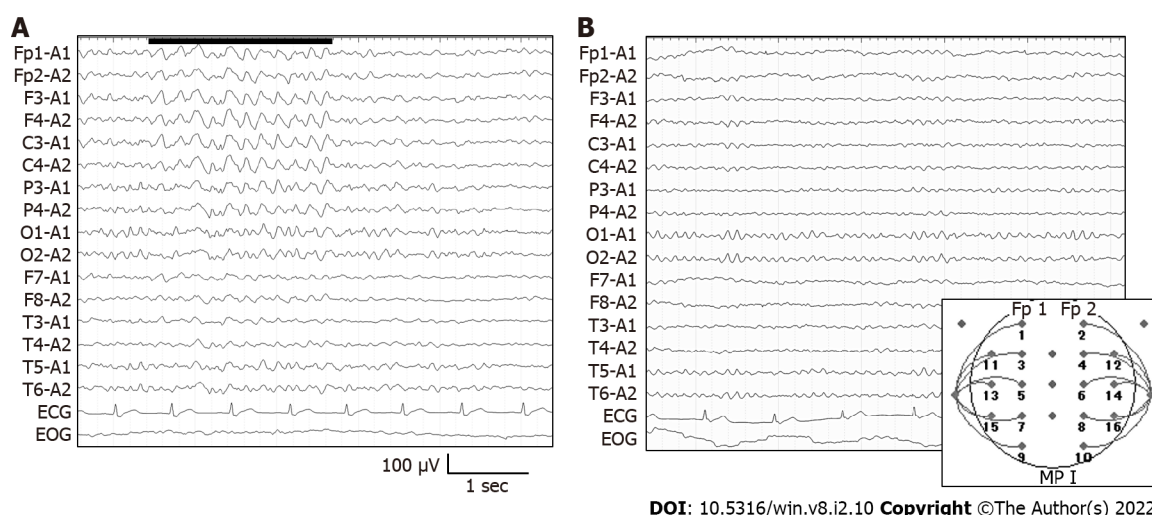


Figure 1 Electroencephalography on admission and on day 7. A: Frontal intermittent rhythmic delta activities (FIRDA) were detected on admission; B: Electroencephalography at 7 d after the cessation of clarithromycin. FIRDA has disappeared and 10 Hz alpha waves were observed.

FINAL DIAGNOSIS

We diagnosed clarithromycin-induced seizures and determined that antiepileptic drugs were unnecessary.

TREATMENT

The cessation of clarithromycin ameliorated the EEG abnormalities. Also, he experienced no seizures to date.

OUTCOME AND FOLLOW-UP

His EEG showed a normal pattern without FIRDA (Figure 1B), and his QTc interval was 385 milliseconds. Medications other than clarithromycin were continued. We diagnosed clarithromycin-induced seizures and determined that antiepileptic drugs were unnecessary.

CONCLUSION

Clarithromycin has often been reported to cause psychiatric symptoms such as delirium[6] and manic episodes[7], suggesting that clarithromycin may sometimes show central nervous system side effects. However, the clarithromycin-induced seizure is quite rare, with few previous reports[1,2]. Clarithromycin is reported to increase neuronal activity, stimulate CA3 pyramidal neurons of the hippocampus by reducing GABAergic signaling, and cause neuronal hyperexcitability[8]. However, the detailed mechanism of these effects is unknown, and further study is needed. Long-term macrolide usage is common for bronchiectasis, chronic obstructive pulmonary disease, and chronic rhinosinusitis[3]. Our patient had been prescribed clarithromycin for chronic sinusitis for > 10 years. Liver CYP3A4 has been reported to metabolize clarithromycin[2]. In the present case, diltiazem was added as an antihypertensive just before the seizure. Diltiazem is also reported to inhibit CYP3A[9]. Thus, in the present case, the introduction of diltiazem may have increased the blood concentration of clarithromycin. Administering azithromycin instead of clarithromycin may be an option. Clarithromycin also causes QT interval prolongation. Our case showed a QTc time of 448 milliseconds at admission, and after discontinuation of clarithromycin, his QTc time improved to 385 milliseconds. Measurement of QT time may be a valuable method of assessing clarithromycin excess. Clarithromycin is a frequently used medication and has a long history of use. The rarity of reports of convulsions induced by clarithromycin suggests that the induction of convulsions by clarithromycin is a rare phenomenon or has been overlooked. Clarithromycin is a frequently prescribed drug but has many interactions. Therefore, we report this case as a cautionary statement for all neurologists.

ACKNOWLEDGEMENTS

We thank all the neurophysiological department workers for obtaining excellent EEG and ECG.

FOOTNOTES

Author contributions: Shiraishi W contributed to data collection, writing, and editing of the manuscript.

Informed consent statement: Informed consent was obtained from the patient for publication of this case.

Conflict-of-interest statement: All the authors declare no conflict of interest.

CARE Checklist (2016) statement: The authors have read the CARE Checklist (2016), and the manuscript was prepared and revised according to the CARE Checklist (2016).

Open-Access: This article is an open-access article that was selected by an in-house editor and fully peer-reviewed by external reviewers. It is distributed in accordance with the Creative Commons Attribution NonCommercial (CC BY-NC 4.0) license, which permits others to distribute, remix, adapt, build upon this work non-commercially, and license their derivative works on different terms, provided the original work is properly cited and the use is non-commercial. See: <https://creativecommons.org/licenses/by-nc/4.0/>

Country/Territory of origin: Japan

ORCID number: Wataru Shiraishi 0000-0001-8528-2622.

S-Editor: Liu JH

L-Editor: A

P-Editor: Liu JH

REFERENCES

- 1 **Wanleenuwat P**, Suntharampillai N, Iwanowski P. Antibiotic-induced epileptic seizures: mechanisms of action and clinical considerations. *Seizure* 2020; **81**: 167-174 [PMID: 32827980 DOI: 10.1016/j.seizure.2020.08.012]
- 2 **Bandettini di Poggio M**, Anfosso S, Audenino D, Primavera A. Clarithromycin-induced neurotoxicity in adults. *J Clin Neurosci* 2011; **18**: 313-318 [PMID: 21269833 DOI: 10.1016/j.jocn.2010.08.014]
- 3 **Smith D**, Du Rand I, Addy CL, Collyns T, Hart SP, Mitchelmore PJ, Rahman NM, Saggu R. British Thoracic Society guideline for the use of long-term macrolides in adults with respiratory disease. *Thorax* 2020; **75**: 370-404 [PMID: 32303621 DOI: 10.1136/thoraxjnl-2019-213929]
- 4 **HC B**. An Analysis of the Time-Relations of Electrocardiograms. *Heart* 1920; 353 [DOI: 10.1016/0002-8703(46)90430-9]
- 5 **Schwartz PJ**, Crotti L, Insolia R. Long-QT syndrome: from genetics to management. *Circ Arrhythm Electrophysiol* 2012; **5**: 868-877 [PMID: 22895603 DOI: 10.1161/CIRCEP.111.962019]
- 6 **Pejčić AV**. Delirium associated with the use of macrolide antibiotics: a review. *Int J Psychiatry Clin Pract* 2022; **26**: 29-42 [PMID: 33026877 DOI: 10.1080/13651501.2020.1828933]
- 7 **Neufeld NH**, Mohamed NS, Grujich N, Shulman K. Acute Neuropsychiatric Symptoms Associated With Antibiotic Treatment of Helicobacter Pylori Infections: A Review. *J Psychiatr Pract* 2017; **23**: 25-35 [PMID: 28072642 DOI: 10.1097/PRA.0000000000000205]
- 8 **Bichler EK**, Elder CC, García PS. Clarithromycin increases neuronal excitability in CA3 pyramidal neurons through a reduction in GABAergic signaling. *J Neurophysiol* 2017; **117**: 93-103 [PMID: 27733592 DOI: 10.1152/jn.00134.2016]
- 9 **Renton KW**. Inhibition of hepatic microsomal drug metabolism by the calcium channel blockers diltiazem and verapamil. *Biochem Pharmacol* 1985; **34**: 2549-2553 [PMID: 4015695 DOI: 10.1016/0006-2952(85)90541-6]



Published by **Baishideng Publishing Group Inc**
7041 Koll Center Parkway, Suite 160, Pleasanton, CA 94566, USA

Telephone: +1-925-3991568

E-mail: bpgoffice@wjgnet.com

Help Desk: <https://www.f6publishing.com/helpdesk>

<https://www.wjgnet.com>

