

# World Journal of *Surgical Procedures*

*World J Surg Proced* 2024 March 1; 14(2): 8-14



**CASE REPORT**

- 8 Sternocleidomastoid flap for reconstruction of tongue small cell carcinoma: A case report

*Irawan H, Bharata MBS*

## Contents

*World Journal of Surgical Procedures*

Continuous Publication Volume 14 Number 2 March 1, 2024

### ABOUT COVER

Peer reviewer for *World Journal of Surgical Procedures*, TingLiang Fu, Doctor, MD, Professor, Pediatric Surgery, Binzhou Medical University Hospital, Binzhou 256603, Shandong, China. drfutl@sina.com

### AIMS AND SCOPE

The primary aim of *World Journal of Surgical Procedures* (*WJSP*, *World J Surg Proced*) is to provide scholars and readers from various fields of surgical procedures with a platform to publish high-quality basic and clinical research articles and communicate their research findings online.

*WJSP* mainly publishes articles reporting research results and findings obtained in the field of surgical procedures and covering a wide range of topics including ablation techniques, ambulatory surgical procedures, surgical anastomosis, assisted circulation, bariatric surgery, biopsy, bloodless medical and surgical procedures, non-therapeutic body modification, cardiovascular surgical procedures, curettage, debridement, surgical decompression, deep brain stimulation, device removal, digestive system surgical procedures, dissection, etc.

### INDEXING/ABSTRACTING

The *WJSP* is now abstracted and indexed in Reference Citation Analysis, China Science and Technology Journal Database, and Superstar Journals Database.

### RESPONSIBLE EDITORS FOR THIS ISSUE

Production Editor: *Yun-Qing Zhao*; Production Department Director: *Xu Guo*; Editorial Office Director: *Yun-Xiaojiao Wu*.

#### NAME OF JOURNAL

*World Journal of Surgical Procedures*

#### ISSN

ISSN 2219-2832 (online)

#### LAUNCH DATE

December 29, 2011

#### FREQUENCY

Continuous Publication

#### EDITORS-IN-CHIEF

Dinesh Vyas, Pankaj Kumar Garg

#### EDITORIAL BOARD MEMBERS

<https://www.wjgnet.com/2219-2832/editorialboard.htm>

#### PUBLICATION DATE

March 1, 2024

#### COPYRIGHT

© 2024 Baishideng Publishing Group Inc

#### INSTRUCTIONS TO AUTHORS

<https://www.wjgnet.com/bpg/gerinfo/204>

#### GUIDELINES FOR ETHICS DOCUMENTS

<https://www.wjgnet.com/bpg/gerinfo/287>

#### GUIDELINES FOR NON-NATIVE SPEAKERS OF ENGLISH

<https://www.wjgnet.com/bpg/gerinfo/240>

#### PUBLICATION ETHICS

<https://www.wjgnet.com/bpg/gerinfo/288>

#### PUBLICATION MISCONDUCT

<https://www.wjgnet.com/bpg/gerinfo/208>

#### ARTICLE PROCESSING CHARGE

<https://www.wjgnet.com/bpg/gerinfo/242>

#### STEPS FOR SUBMITTING MANUSCRIPTS

<https://www.wjgnet.com/bpg/gerinfo/239>

#### ONLINE SUBMISSION

<https://www.f6publishing.com>

© 2024 Baishideng Publishing Group Inc. All rights reserved. 7041 Koll Center Parkway, Suite 160, Pleasanton, CA 94566, USA

E-mail: [office@baishideng.com](mailto:office@baishideng.com) <https://www.wjgnet.com>



## Sternocleidomastoid flap for reconstruction of tongue small cell carcinoma: A case report

Hendry Irawan, Made Bagus Sastrapramaya Bharata

**Specialty type:** Dentistry, oral surgery and medicine

**Provenance and peer review:** Unsolicited article; Externally peer reviewed.

**Peer-review model:** Single blind

**Peer-review report's scientific quality classification**

Grade A (Excellent): 0  
Grade B (Very good): B  
Grade C (Good): 0  
Grade D (Fair): 0  
Grade E (Poor): 0

**P-Reviewer:** Boffano P, Italy

**Received:** November 21, 2023

**Peer-review started:** November 21, 2023

**First decision:** December 29, 2023

**Revised:** January 6, 2024

**Accepted:** February 1, 2024

**Article in press:** February 1, 2024

**Published online:** March 1, 2024



**Hendry Irawan**, Surgical Oncology Division, Department of Surgery, Medical Faculty Universitas Udayana, Denpasar 80113, Bali, Indonesia

**Made Bagus Sastrapramaya Bharata**, General Surgery Resident, Department of Surgery, Medical Faculty Universitas Udayana, Prof. Dr. I.G.N.G. Ngoerah General Hospital, Denpasar 80113, Bali, Indonesia

**Corresponding author:** Hendry Irawan, MD, Doctor, Lecturer, Surgical Oncologist, Surgical Oncology Division, Department of Surgery, Medical Faculty Universitas Udayana, Jl. Diponegoro, Denpasar 80113, Bali, Indonesia. [hendry\\_irawan@rocketmail.com](mailto:hendry_irawan@rocketmail.com)

### Abstract

#### BACKGROUND

The management of tongue carcinoma is excision and radical neck dissection followed with reconstruction. This is a case report of a patient with tongue squamous cell carcinoma (SCC) who underwent the procedure with sternocleidomastoid (SCM) flap reconstruction.

#### CASE SUMMARY

A 52-year-old woman without smoking history complained tongue ulcer since 3 years ago. Based on the histopathological examination, the patient was diagnosed with T2N2M0 right tongue SCC and underwent wide excision of tumor; right mandibular; neck dissection and were reconstructed with SCM flap.

#### CONCLUSION

SCC of the tongue requires wide excision and dissection of the neck and mandible if infiltration into the surrounding lymph nodes has been found. The SCM flap reconstruction could be used post-surgery.

**Key Words:** Sternocleidomastoid flap; Neck dissection; Mandibular dissection; Squamous cell carcinoma of the tongue; Case report

©The Author(s) 2024. Published by Baishideng Publishing Group Inc. All rights reserved.

**Core Tip:** The sternocleidomastoid flap can be used for closing defects after resection of the tongue and floor of the mouth. We can choose this flap if there is no lymph node enlargement or metastasis at level 2, level 3, and level 4.

**Citation:** Irawan H, Bharata MBS. Sternocleidomastoid flap for reconstruction of tongue small cell carcinoma: A case report. *World J Surg Proced* 2024; 14(2): 8-14

**URL:** <https://www.wjgnet.com/2219-2832/full/v14/i2/8.htm>

**DOI:** <https://dx.doi.org/10.5412/wjssp.v14.i2.8>

## INTRODUCTION

Carcinoma originating from the tongue tissue is an uncommon disease. The incidence of tongue carcinoma in Africa is 2.6 over 100000 populations, while in the United States the incidence number reaches 1.6-2.9 over 100000 populations. On the other hand, the incidence of tongue carcinoma in the Europe is 1.4 over 100000 populations, yet the information of tongue carcinoma prevalence in Indonesia has not been established[1]. About ninety percent of this neoplasm is squamous cell carcinoma (SCC)[2]. Histologically, carcinoma of the tongue has similar figures with carcinoma of the oral cavity. However, carcinoma from the base of the tongue has an important implication which makes this malignancy a disease to consider, with different managements, prognosis, and follow-ups[3]. Carcinoma of the tongue is usually found in elderly men with history of smoking and alcohol consumption. Nevertheless, in the last decades carcinoma of the tongue incidences in women and young patients with no history of smoking or alcohol consumption have increased. This may be associated with HPV infection or changes of genetic factors[4].

The primary management of tongue carcinoma is through surgery. The surgery is conducted in order to remove the primary tumor with wide margins from the normal surrounding tissues. The current standard is to eliminate the primary lesion with a macroscopic margin of 1.5-2 cm. With this standard, the parts of the tongue musculature that is needed to be removed could not be clearly determined by the pre-operative process. Other considerations that might complicate the surgery are the anatomy of the tongue, the size of the tumor, the extrinsic muscle invasion depth, and the presence of non-functional muscles for reconstructive purposes. In the last ten years, these considerations have been the main thoughts in developing surgical techniques for carcinoma of the tongue. Neck and mandibular dissection for the management of tongue carcinoma will leave defects that could not be closed directly, hence reconstruction by using flaps is required. One kind of flap which may be used to reconstruct the neck and mandible is sternocleidomastoid (SCM) flap[5]. This case report aims to report a case of patient with SCC of the tongue who had undergone a wide excision along with neck and mandibular dissection, continued by reconstruction with SCM flap.

## CASE PRESENTATION

### Chief complaints

A 52-year-old woman came with mouth ulcer on the tongue in the last three years ago.

### History of present illness

This complaint was also accompanied by pain. The lesion size and the pain were said to be increasing over time. These complaints were aggravated especially while eating. The patient said that the mouth ulcer appeared suddenly without any previous history of trauma. The patient brushed her teeth twice a day. History of weight lost, shortness of breath, and active bleeding were denied. History of smoking and consuming alcohol were denied.

### History of past illness

The patient claimed that she had not experienced any similar complaints before. There was no history of hypertension, diabetes mellitus, heart disease, or allergies.

### Physical examination

From the physical examinations, it was found that the vital signs and general status were in normal limits. The general condition of the patient was sufficient. From the local status of the tongue region, a mass was found, sized 6 cm × 6 cm, with a solid and bumpy consistency, and unclearly-defined irregular margin.

### Laboratory examinations

Laboratory findings such as complete blood count, electrolyte, kidney and liver function, blood sugar, as well as prothrombin time and activated partial thromboplastin time examination were within normal limits.

### Imaging examinations

Chest X-ray results did not show any sign of lung metastasis. On the other hand, multi slice computed tomography (MSCT) with contrast examination showed partial compaction on the edge of the right tongue which on contrast adminis-

tration appears to be heterogeneous contrast enhancement as shown on [Figure 1](#).

The infiltration was suspected to be found on the right mylohyoid and hyoglossus muscles. Other findings were atypical right and left lymphadenopathy with the grade of IA/B, IIA/B, III, and IV, right sphenoid sinusitis, bilateral ethmoid and maxillary sinusitis, bilateral inferior nasal conchae hypertrophy, conchae bullosa of the right middle conchae, and cervical spondylosis as shown on [Figure 1](#). Thyroid ultrasonography (USG) examination showed normal figures of the right and left thyroid glands and isthmus. In addition, multiple atypical lymphadenopathies were found on the right submandibular, right neck, and right post auricular region.

---

## MULTIDISCIPLINARY EXPERT CONSULTATION

---

The patients tongue histopathological examination result showed there were moderately differentiated SCC.

---

## FINAL DIAGNOSIS

---

The patient was diagnosed with right tongue SCC with moderately differentiated, T2N2M0.

---

## TREATMENT

---

The patient was diagnosed with right tongue SCC with moderately differentiated, T2N2M0. The surgical site marking was done on the patient's right side of the neck as shown on [Figure 2](#). It was planned to undergo a wide excision of tumor, right mandibular and neck dissection as it is shown on [Figure 3](#). The surgery was performed perfectly without any complication. Pathological result of the surgery was moderately differentiated SCC (pT2), with one metastatic lymph node of 4 at level IB, no metastatic of three lymph nodes at level IA, no metastatic of seven lymph nodes at level II, and the free margin was very close.

---

## OUTCOME AND FOLLOW-UP

---

The therapy plan continued with chemotherapy but the patient died more than two months after surgery due to treatment for coronavirus disease 2019 infection.

---

## DISCUSSION

---

SCC of the tongue is one of the malignancies that is found in the oral cavity. In this case, the patient was an elderly woman. Tongue SCC are usually found in elderly men populations with a history of smoking however there are numerous studies from the last decades showed that the incidence of this carcinoma has been increasing in women and younger patients without any history of smoking nor alcohol consumption. This condition could be associated with the incidence of HPV infection or genetic alterations[4].

The clinical manifestation that is found in this patient was typical for SCC of the tongue, which was a lesion on the tongue that had not been resolved for three years. Besides, the patient also complained local pain on the surrounding tissues. Physical examinations had been comprehensively done on this patient, along with a specific examination of the tongue as well as an investigation for metastatic signs on the lymph nodes[6]. The gold standard in diagnosing carcinoma of the tongue is through histopathological examination from tongue tissue biopsy. Histopathological examination of the lymph nodes may also be conducted to evaluate the signs of ongoing metastatic process. The pathological anatomy findings of this patient supported the theory that about ninety percent of carcinoma of the tongue are SCC[2]. Radiological examinations that are usually conducted for the suspicion of carcinoma of the head and neck include head and neck CT scan, and USG to observe any possible spreading to the thyroid glands and their surroundings. Moreover, radiological findings might also be useful as an assessment tool for any anatomical defect and planning the following reconstruction needed to optimize patient's function and life quality[3].

The management that is chosen for this patient had been consistent according to the theory, in which the patient with the stadium of T2 should be treated through surgical approaches. Patients in the early stadium, T1 and T2, could be managed with single modality like surgery or radiation, with surgical approaches being the most commonly picked modality[7]. Another treatment such as drainage insertion was conducted in order to anticipate possible hematoma formation. In addition, wound care and antibiotic administration were executed to prevent furthermore infection of the wound and oro-cutaneous fistula. These are the complications that are commonly found subsequently the surgical managements in patients with SCC of the tongue[8].

There are several surgical techniques for carcinoma of the tongue, such as: (1) Type I mucosectomy; (2) Type II partial glossectomy; (3) Type III glossectomy: IIIa hemiglossectomy and IIIb compartmental hemiglossectomy; (4) Type IV glossectomy: IVa subtotal glossectomy and IVb near total glossectomy; and (5) Type V total glossectomy. The technique



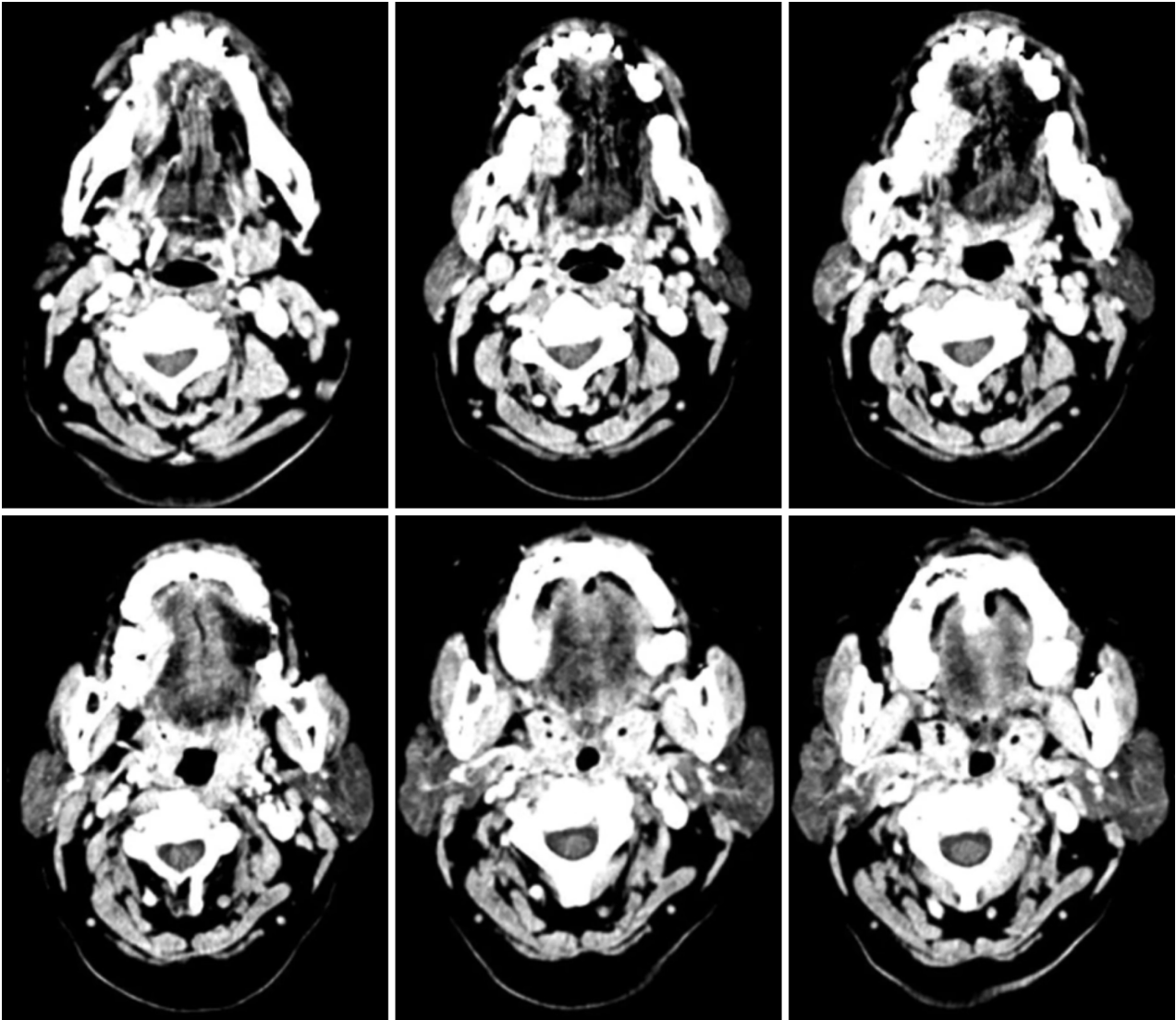
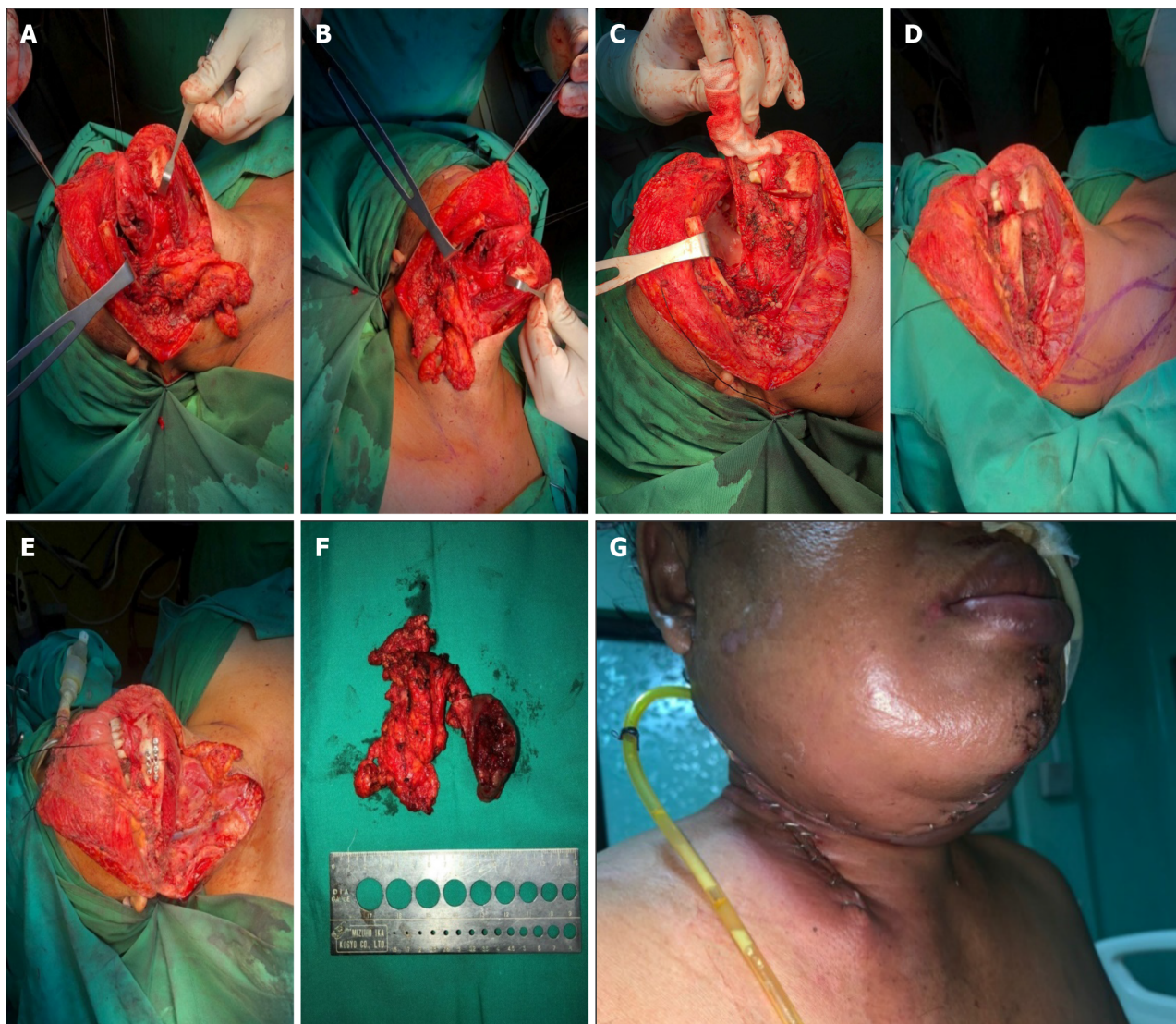


Figure 1 Multi-slice computed tomography of the midface. Mass of the right tongue with contrast enhancement.

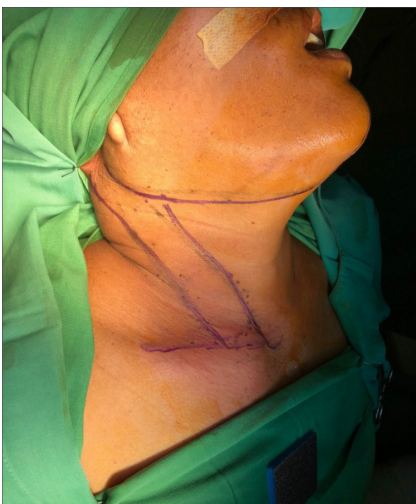

Figure 2 Surgical site marking.



**Figure 3 Intraoperative procedure.** A-C: Wide excision right tongue with neck and mandibular dissection; D: Sternocleidomastoid (SCM) flap design; E: After reconstruction of SCM flap for floor of the mouth and fixation of mandible bone; F: Mass excised from the right tongue, neck, and mandible; G: After surgery at ward with drain.

that were chosen for this patient was compartmental hemiglossectomy, in which the specimens that were removed includes the mucosal membrane, submucosal membrane, intrinsic and extrinsic muscles on the ipsilateral side of the lesion, genioglossus muscle, hyoglossus muscle, styloglossus muscle, and the inferior part of palatoglossal muscle. The lingual nerve was resected as far as possible towards the cranium and the hypoglossal nerve were also eliminated. The lingual artery and vein will also be ligated at the proximal edge of the hyoid bone. All the specimens and nodes in the neck will be removed en bloc[9]. This was the appropriate technique for this patient, considering the MSCT results that showed the figures of atypical lymphadenopathy which required resection of the nodes.

Compartmental tongue surgery (CTS) technique is the most commonly picked modality of the surgery due to its ability to maintain the function of every tongue compartment and explore tumor better. This technique allows the muscles in the compartment to be removed totally, which is essential to prevent any potential of micro metastatic process in partial tumors. This approach is a game-changer that creates a new paradigm for the resection methods, which were resection around the lesion into longitudinal resection. By this method, the surgeon will be able to do resection radically as well as non-selective demolition elimination with wide margin resection principle, especially on the early stages. However, this surgical approach by using CTS technique requires a wide resection area, therefore some anatomical and functional defects would be left. These functional defects are only associated with the muscles that were removed, which eventually considered as a similar outcome as the other surgical technique that only removes the muscles partially. The technique itself could be used to reconstruct and maintain the remaining function of the tongue aside from preventing functional [10]. A study by Piazza *et al*[11] stated that CTS showed remarkable oncological outcomes. The overall survival of 2 years was 80%, the disease-free survival was 91%, the local control was 100%, and the loco-regional control was 94%. Another study by Grammatica *et al*[12] with 1 year of follow-up found that CTS did not alter the speech function significantly.

The mandible and neck dissection will leave defects that require reconstruction. One of the considerable reconstruction techniques for head and neck surgery is by using SCM flap. This technique is usually conducted for intraoral and



pharyngeal reconstruction. The principle of the reconstruction by using SCM flap is the utilization of the blood supplies from occipital artery, superior thyroid artery, and supracapsular artery. The SCM flap can be a useful alternative in patients who are unable to have prolonged free flap surgery, or in the absence of a microvascular surgeon. Some advantages that make the SCM flap is preferable include shorter operating time compared to the free flap, reduction of muscle mass, lower morbidity, easily-shaped characteristic, and better comfort and hairless[13]. From a study of 20 patients with oral carcinoma, it was found that the application of the SCM flap for reconstruction purposes had great and favorable results, with only one case of partial flap loss[5].

## CONCLUSION

SCC of the tongue should be managed through wide excision along with neck and mandibular dissection if infiltration to the surrounding lymph nodes has already been found. The SCM flap could be utilized to reconstruct the defect remained after the neck and mandibular dissection.

## FOOTNOTES

**Co-first authors:** Hendry Irawan and Made Bagus Sastrapramaya Bharata.

**Co-corresponding authors:** Hendry Irawan and Made Bagus Sastrapramaya Bharata.

**Author contributions:** Irawan H and Bharata MBS conceived and designed this study, did acquisition, analysis and interpretation of data, drafted and revised the article. Irawan H and Bharata MBS contributed equally to this work as co-first authors and co-corresponding authors. The research was performed as a collaborative effort, Irawan H and Bharata MBS contributed efforts of equal substance throughout the research process, the designation of co-corresponding authorship accurately reflects our team's collaborative spirit and equal contributions.

**Informed consent statement:** Informed written consent was obtained from the patient for publication of this report and any accompanying images.

**Conflict-of-interest statement:** All the authors have no relevant conflict of interest to disclose.

**CARE Checklist (2016) statement:** The authors have read the CARE Checklist (2016), and the manuscript was prepared and revised according to the CARE Checklist (2016).

**Open-Access:** This article is an open-access article that was selected by an in-house editor and fully peer-reviewed by external reviewers. It is distributed in accordance with the Creative Commons Attribution NonCommercial (CC BY-NC 4.0) license, which permits others to distribute, remix, adapt, build upon this work non-commercially, and license their derivative works on different terms, provided the original work is properly cited and the use is non-commercial. See: <https://creativecommons.org/licenses/by-nc/4.0/>

**Country/Territory of origin:** Indonesia

**ORCID number:** Hendry Irawan 0000-0003-1000-1691.

**S-Editor:** Zhang H

**L-Editor:** A

**P-Editor:** Zhao YQ

## REFERENCES

- 1 **Hamdy R**, Halim A. Squamous Cell Carcinoma of the Oral Tongue: A Single Institution Retrospective Cohort Study from Mansoura University Hospital. *Indones J Cancer* 2019; **12**: 102-108 [DOI: [10.33371/ijoc.v0i0.623](https://doi.org/10.33371/ijoc.v0i0.623)]
- 2 **Ettinger KS**, Ganry L, Fernandes RP. Oral Cavity Cancer. *Oral Maxillofac Surg Clin North Am* 2019; **31**: 13-29 [PMID: [30454788](https://pubmed.ncbi.nlm.nih.gov/30454788/) DOI: [10.1016/j.coms.2018.08.002](https://doi.org/10.1016/j.coms.2018.08.002)]
- 3 **Rivera C**. Essentials of oral cancer. *Int J Clin Exp Pathol* 2015; **8**: 11884-11894 [PMID: [26617944](https://pubmed.ncbi.nlm.nih.gov/26617944/)]
- 4 **Leoncini E**, Ricciardi W, Cadoni G, Arzani D, Petrelli L, Paludetti G, Brennan P, Luce D, Stucker I, Matsuo K, Talamini R, La Vecchia C, Olshan AF, Winn DM, Herrero R, Franceschi S, Castellsague X, Muscat J, Morgenstern H, Zhang ZF, Levi F, Dal Maso L, Kelsey K, McClean M, Vaughan TL, Lazarus P, Purdue MP, Hayes RB, Chen C, Schwartz SM, Shangina O, Koifman S, Ahrens W, Matos E, Laggiou P, Lissowska J, Szeszenia-Dabrowska N, Fernandez L, Menezes A, Agudo A, Daudt AW, Richiardi L, Kjaerheim K, Mates D, Betka J, Yu GP, Schantz S, Simonato L, Brenner H, Conway DI, Macfarlane TV, Thomson P, Fabianova E, Znaor A, Rudnai P, Healy C, Boffetta P, Chuang SC, Lee YC, Hashibe M, Boccia S. Adult height and head and neck cancer: a pooled analysis within the INHANCE Consortium. *Eur J Epidemiol* 2014; **29**: 35-48 [PMID: [24271556](https://pubmed.ncbi.nlm.nih.gov/24271556/) DOI: [10.1007/s10654-013-9863-2](https://doi.org/10.1007/s10654-013-9863-2)]
- 5 **Chen HC**, Chang HS. The Sternocleidomastoid Flap for Oral Cavity Reconstruction: Extended Indications and Technical Modifications. *J Oral Maxillofac Surg* 2015; **73**: 2429-2439 [PMID: [26358725](https://pubmed.ncbi.nlm.nih.gov/26358725/) DOI: [10.1016/j.joms.2015.07.027](https://doi.org/10.1016/j.joms.2015.07.027)]

- 6 **Smith EM**, Wang D, Kim Y, Rubenstein LM, Lee JH, Haugen TH, Turek LP. P16INK4a expression, human papillomavirus, and survival in head and neck cancer. *Oral Oncol* 2008; **44**: 133-142 [PMID: [17360226](#) DOI: [10.1016/j.oraloncology.2007.01.010](#)]
- 7 **Abu-Ghanem S**, Yehuda M, Carmel NN, Leshno M, Abergel A, Gutfeld O, Fliss DM. Elective Neck Dissection vs Observation in Early-Stage Squamous Cell Carcinoma of the Oral Tongue With No Clinically Apparent Lymph Node Metastasis in the Neck: A Systematic Review and Meta-analysis. *JAMA Otolaryngol Head Neck Surg* 2016; **142**: 857-865 [PMID: [27442962](#) DOI: [10.1001/jamaoto.2016.1281](#)]
- 8 **Kim YJ**, Kim JH. Increasing incidence and improving survival of oral tongue squamous cell carcinoma. *Sci Rep* 2020; **10**: 7877 [PMID: [32398670](#) DOI: [10.1038/s41598-020-64748-0](#)]
- 9 **Ansarin M**, Bruschini R, Navach V, Giugliano G, Calabrese L, Chiesa F, Medina JE, Kowalski LP, Shah JP. Classification of GLOSSECTOMIES: Proposal for tongue cancer resections. *Head Neck* 2019; **41**: 821-827 [PMID: [30600861](#) DOI: [10.1002/hed.25466](#)]
- 10 **Paderno A**, Morello R, Piazza C. Tongue carcinoma in young adults: a review of the literature. *Acta Otorhinolaryngol Ital* 2018; **38**: 175-180 [PMID: [29984792](#) DOI: [10.14639/0392-100X-1932](#)]
- 11 **Piazza C**, Grammatica A, Montalto N, Paderno A, Del Bon F, Nicolai P. Compartmental surgery for oral tongue and floor of the mouth cancer: Oncologic outcomes. *Head Neck* 2019; **41**: 110-115 [PMID: [30536781](#) DOI: [10.1002/hed.25480](#)]
- 12 **Grammatica A**, Piazza C, Montalto N, Del Bon F, Frittoli B, Mazza M, Paderno A, Lancini D, Fior M, Deganello A, Lombardi D, Nicolai P. Compartmental Surgery for Oral Tongue Cancer: Objective and Subjective Functional Evaluation. *Laryngoscope* 2021; **131**: E176-E183 [PMID: [32239760](#) DOI: [10.1002/lary.28627](#)]
- 13 **Jones LF**, Farrar EM, Roberts DJH, Moor JW. Revisiting the sternocleidomastoid flap as a reconstructive option in head and neck surgery. *J Laryngol Otol* 2019; **133**: 742-746 [PMID: [31422777](#) DOI: [10.1017/S0022215119001592](#)]



Published by **Baishideng Publishing Group Inc**  
7041 Koll Center Parkway, Suite 160, Pleasanton, CA 94566, USA

**Telephone:** +1-925-3991568

**E-mail:** [office@baishideng.com](mailto:office@baishideng.com)

**Help Desk:** <https://www.f6publishing.com/helpdesk>

<https://www.wjgnet.com>

